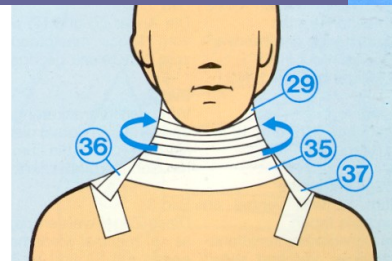
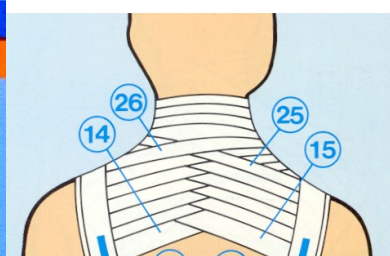
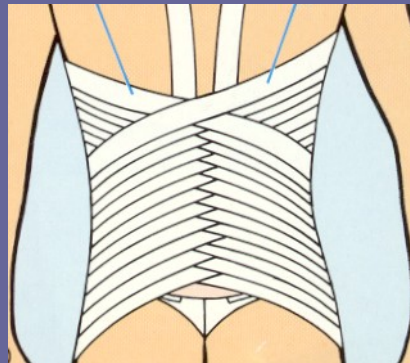
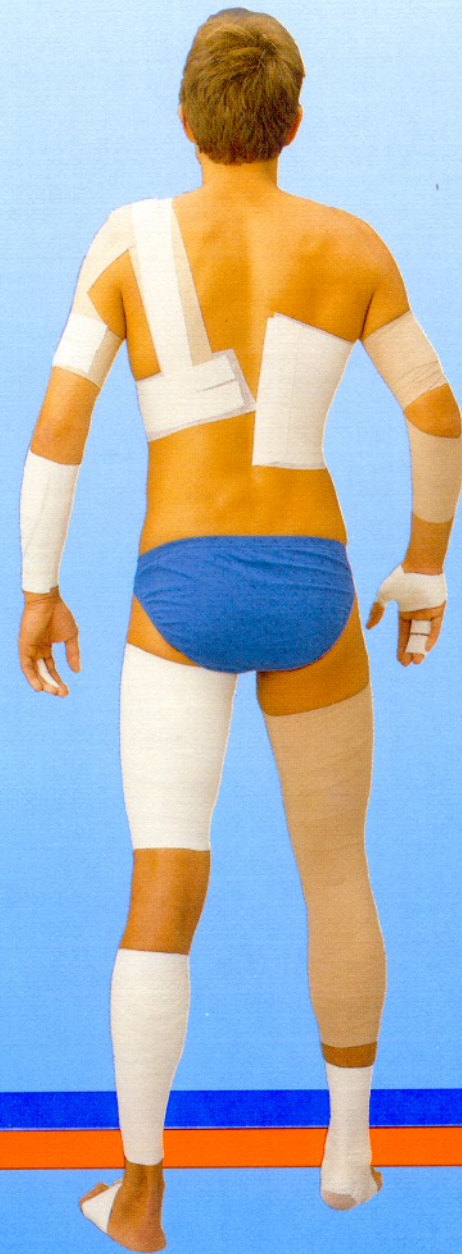
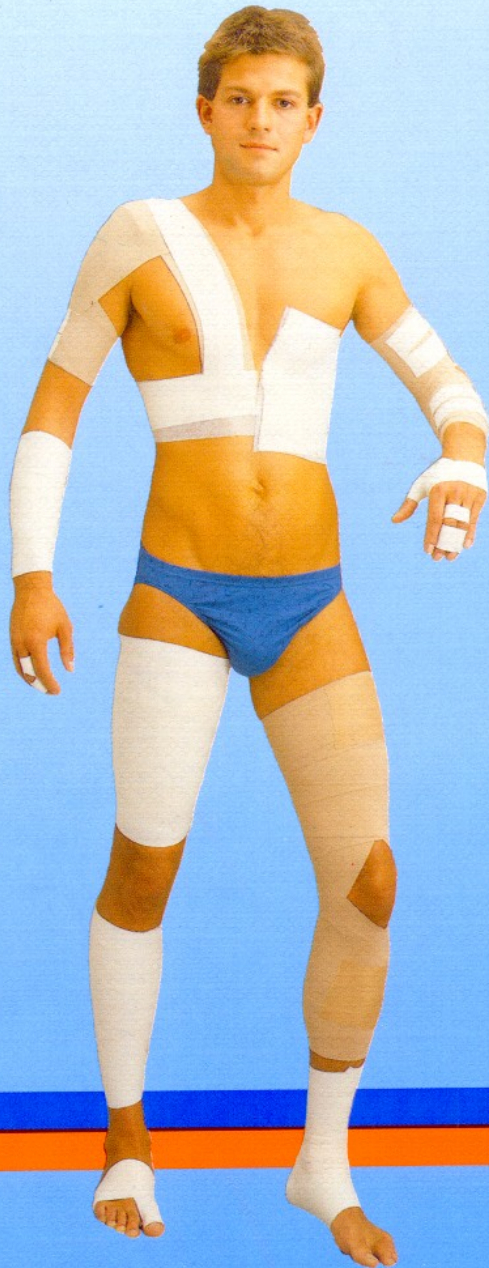
# Taping - náplast'ová fixace

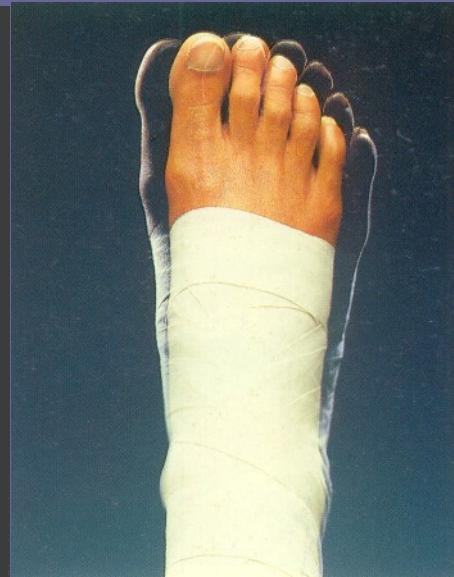
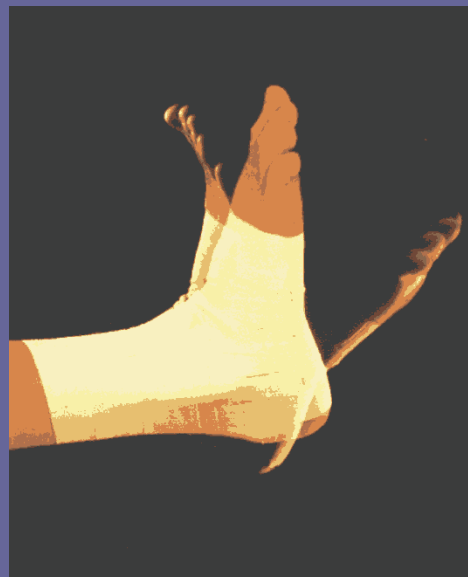

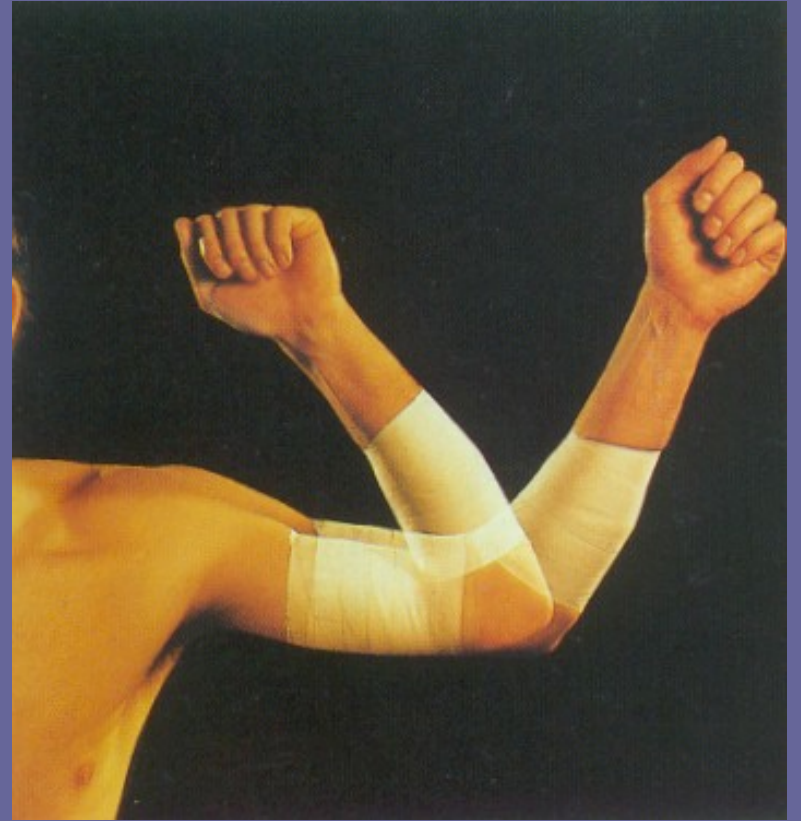# historie

- A.Hoffa – 1900  
Mnichov
- 1930-Leukoplast-Atlas

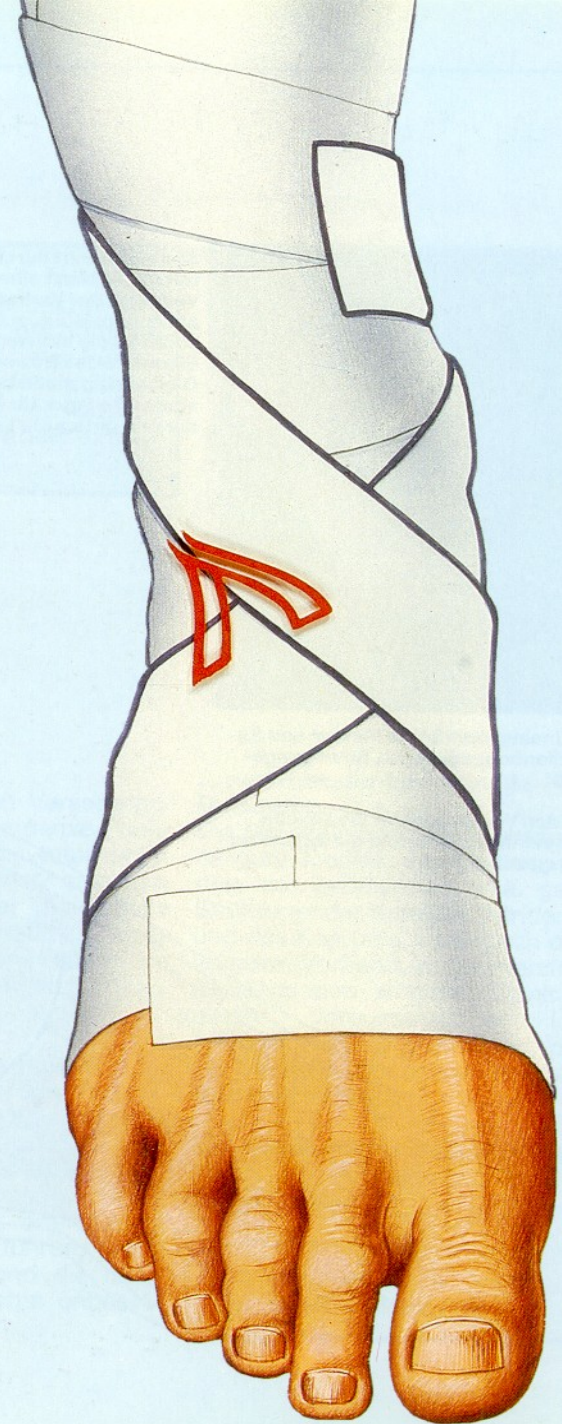
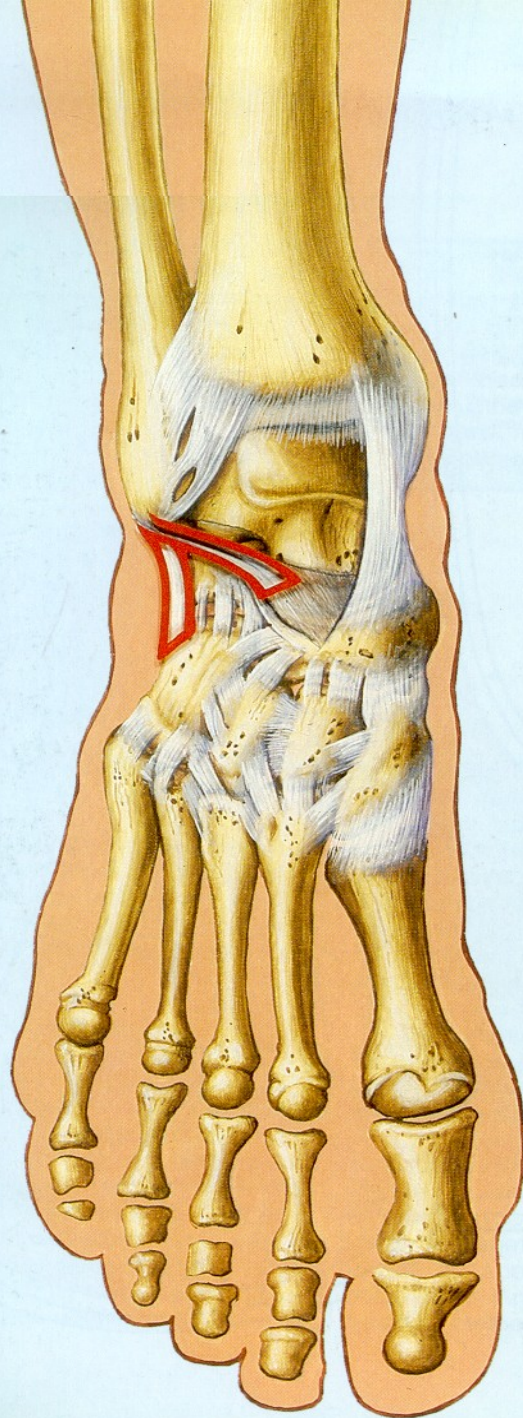


- mechanická stabilizace
- modifikace funkce
- stimulace propriocepce

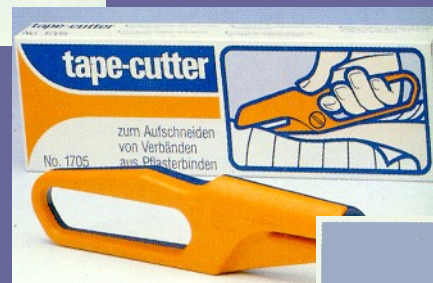
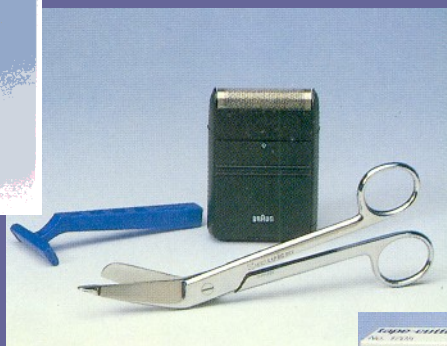


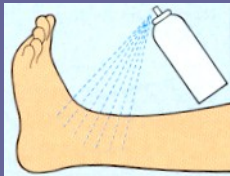# Tape a poraněná struktúra



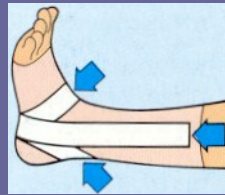
# Vybavení



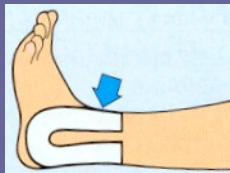# Pracovní postup



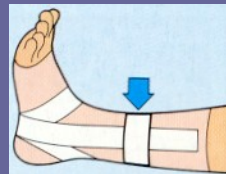Podlepení



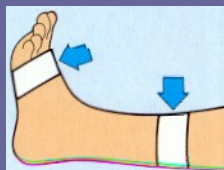
Vodící tahy



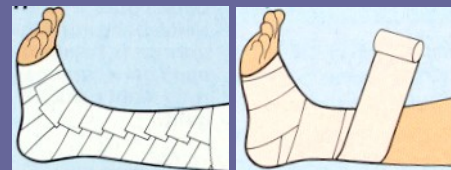
Podložení



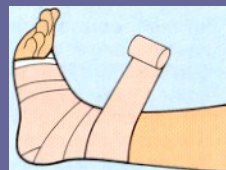Fixační tahy



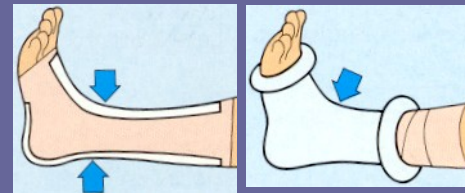
Kotvící  
tahy



Zabezpečovací  
tape



Základní  
podtape



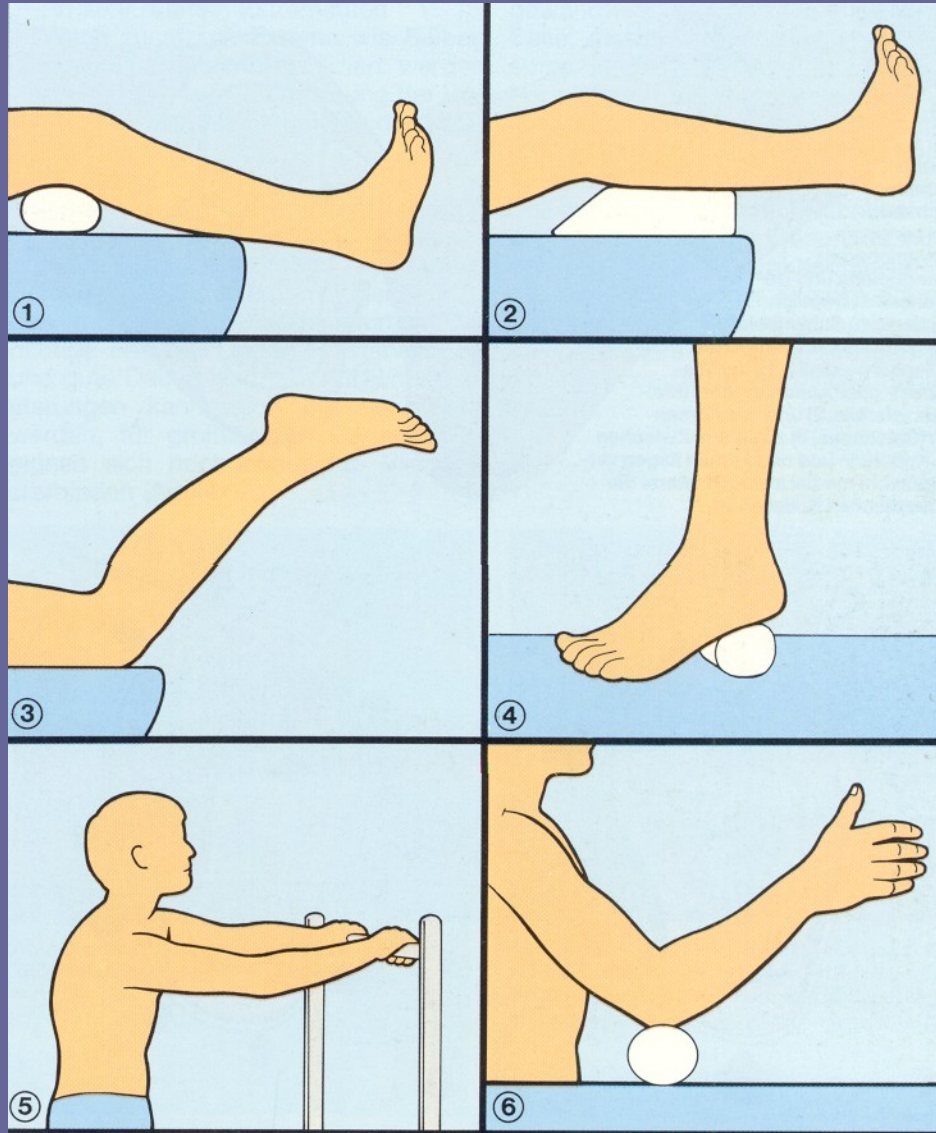
Krytí

# Postavení kloubu

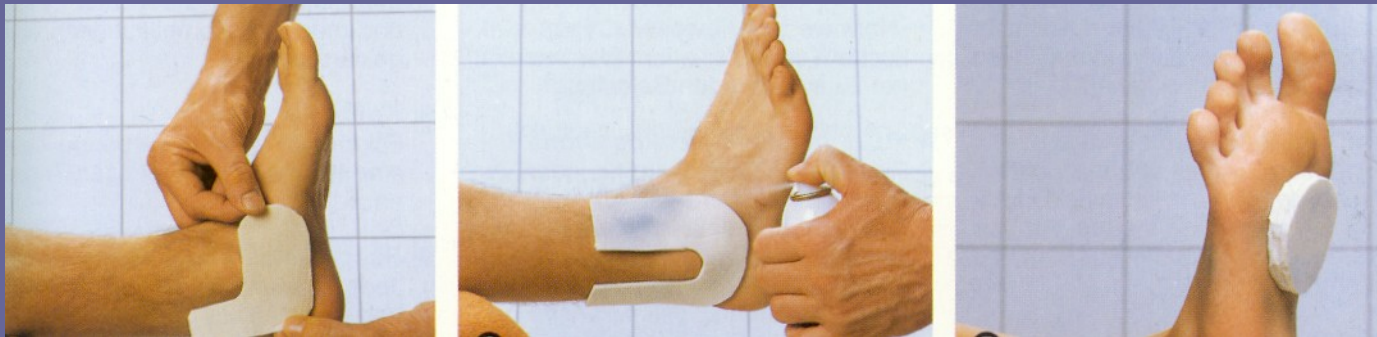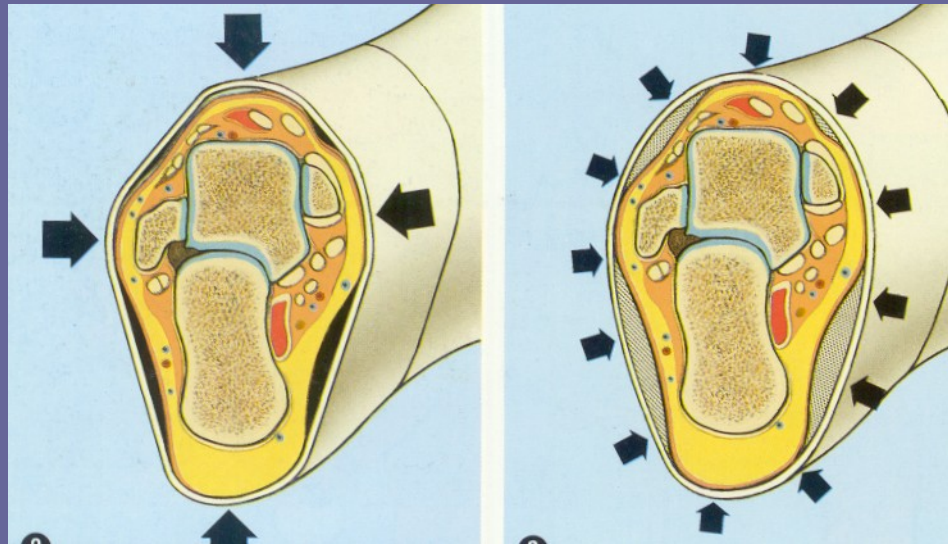




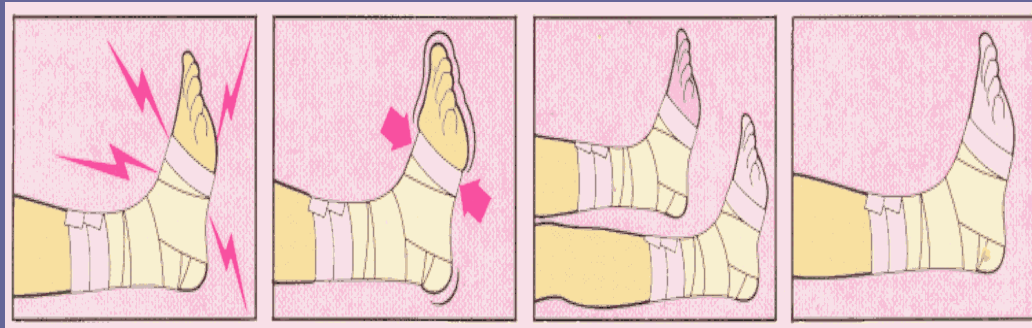
# Poloha



# Podložení



# Chybná aplikace



Bolest

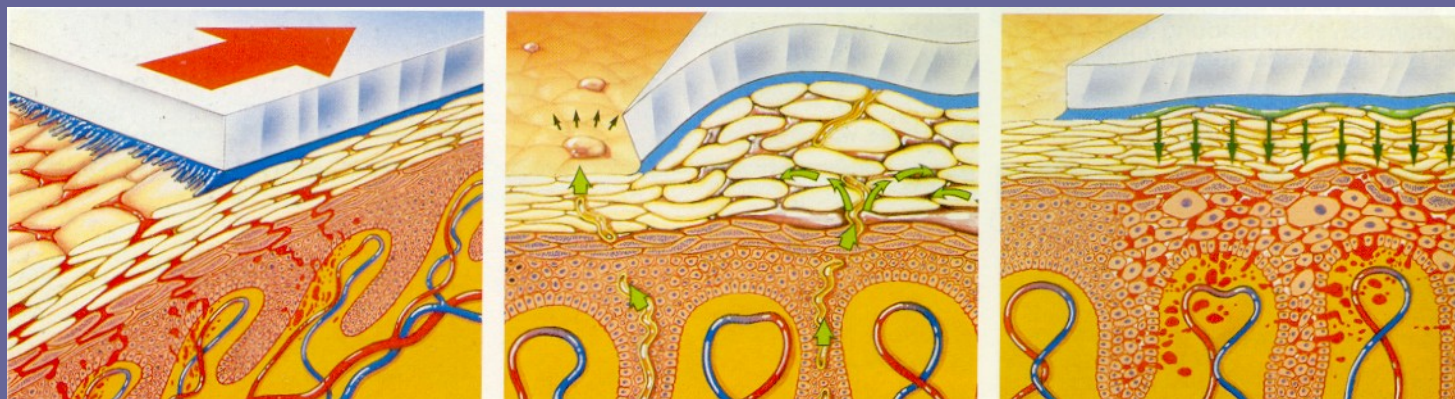
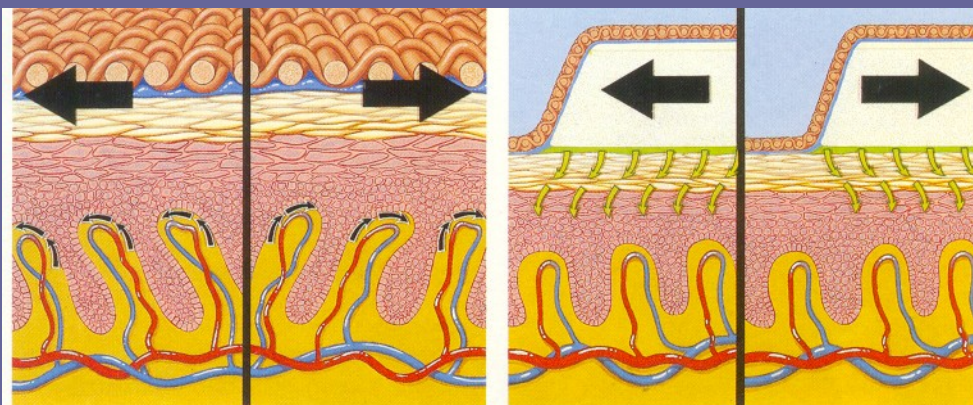
Otok

Změna  
barvy

Dyskomfort  
Nervový  
útlak

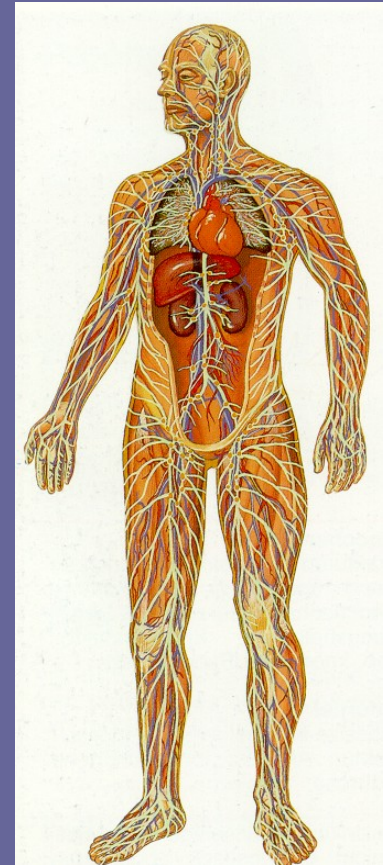
**Nutnost okamžitého uvolnění fixace!!!**

# Tape a kůže

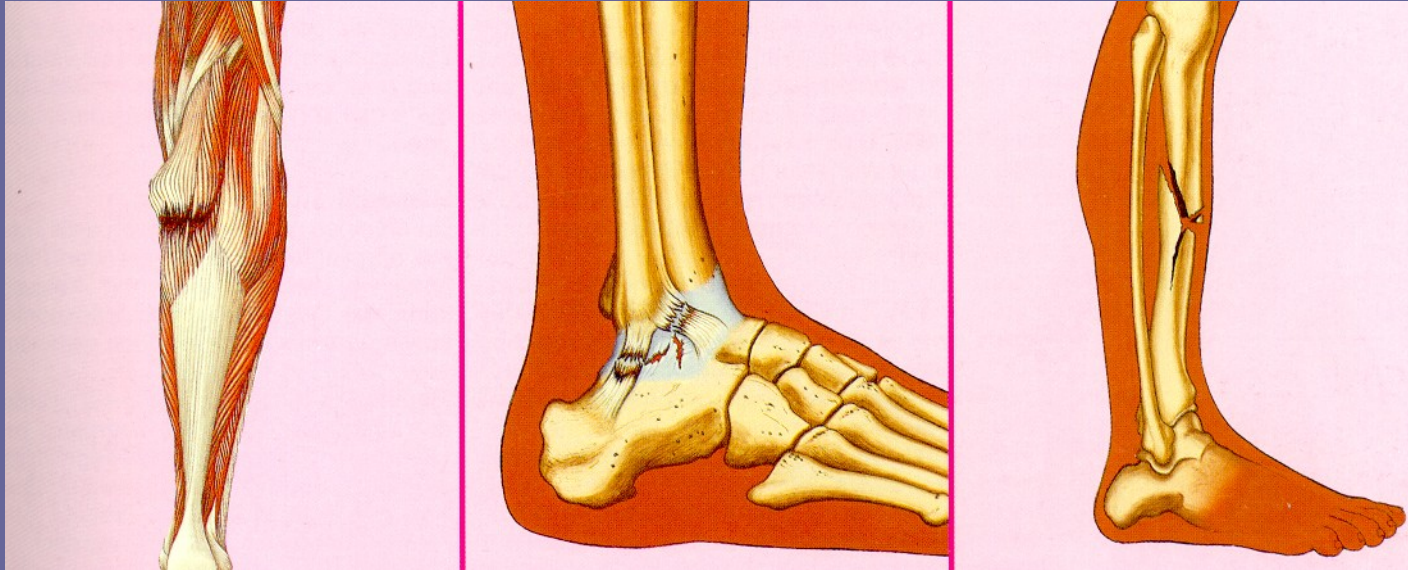


# Tape a cévní systém

- Zlepšení lymfatické drenáže
- Zlepšení žilního návratu
- Masážní efekt
- Urychlení vstřebávání hematomů



# Kontraindikace

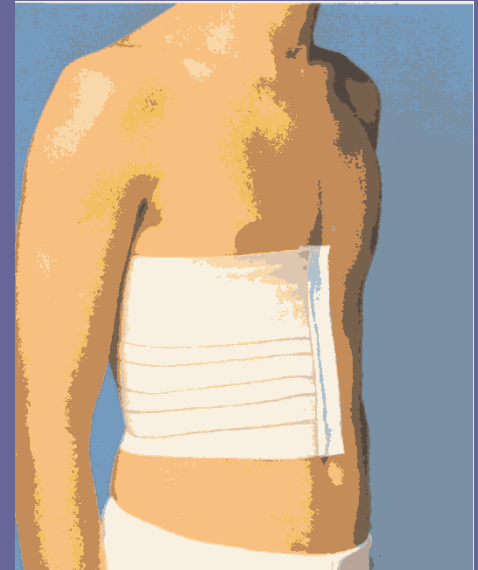
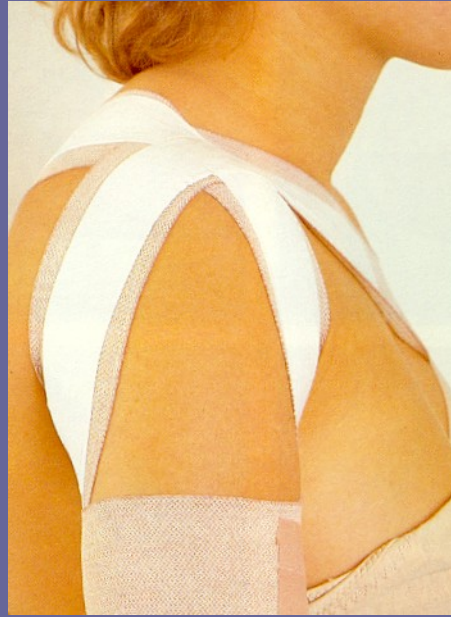
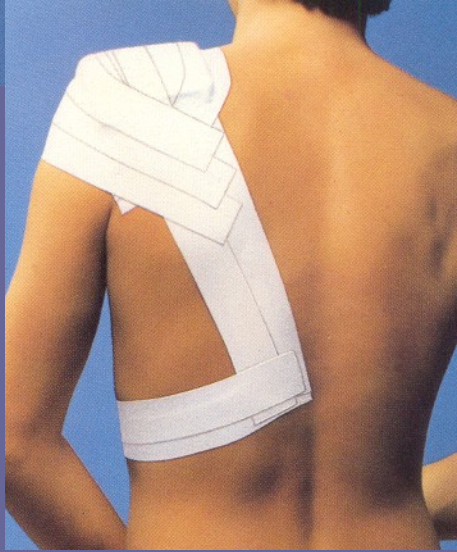
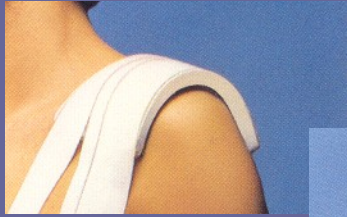
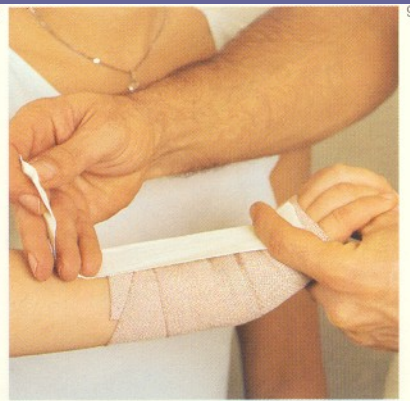
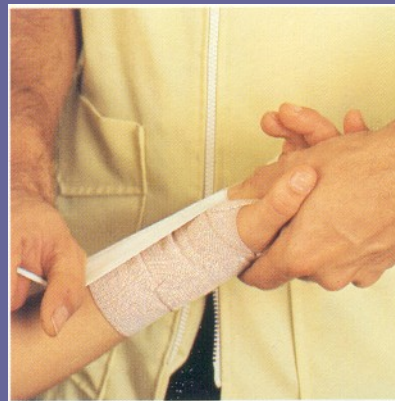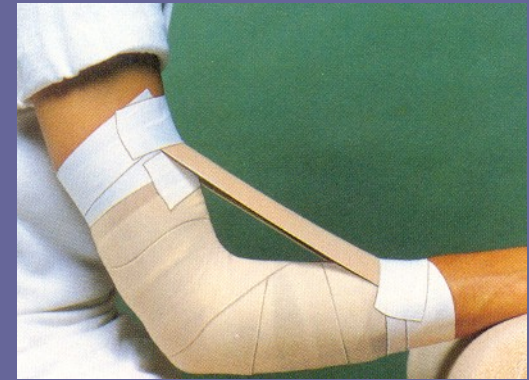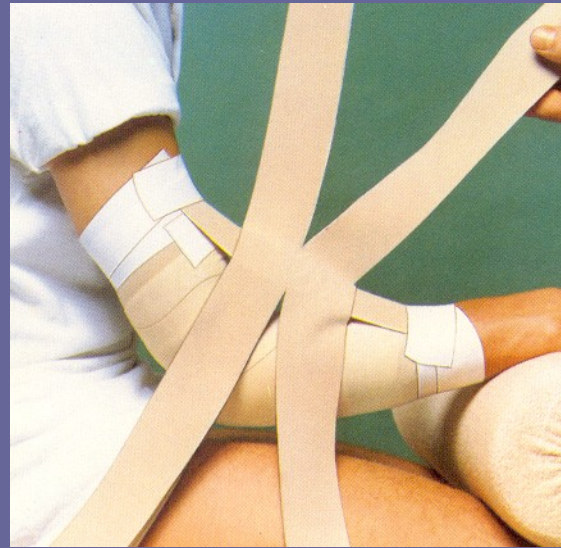
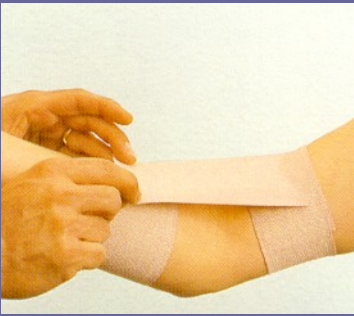- °Kompletní svalové ruptury
- °Velké hematomy

- °Kompletní ruptury vazů
- °Nitrokloubní zlomeniny

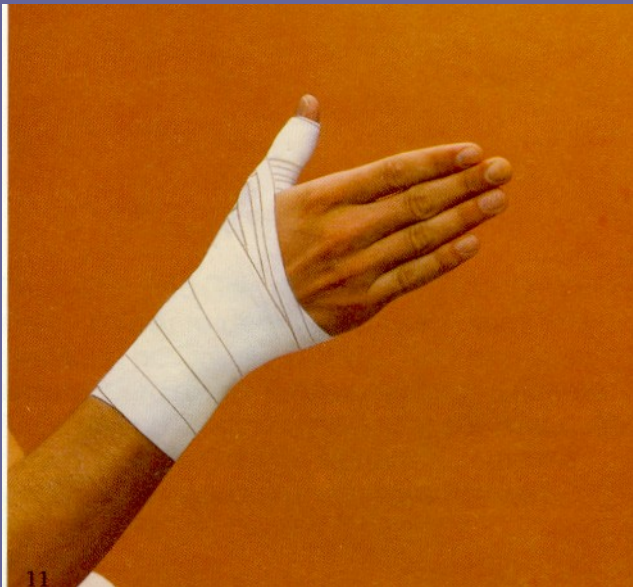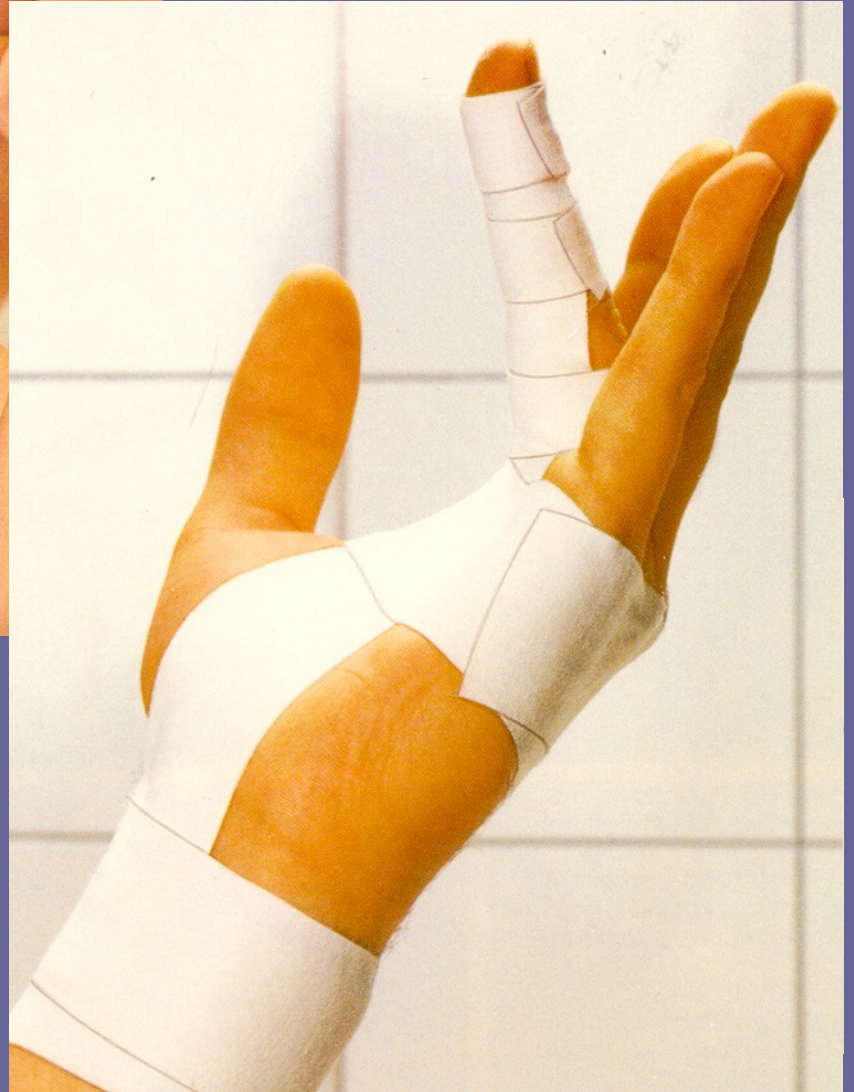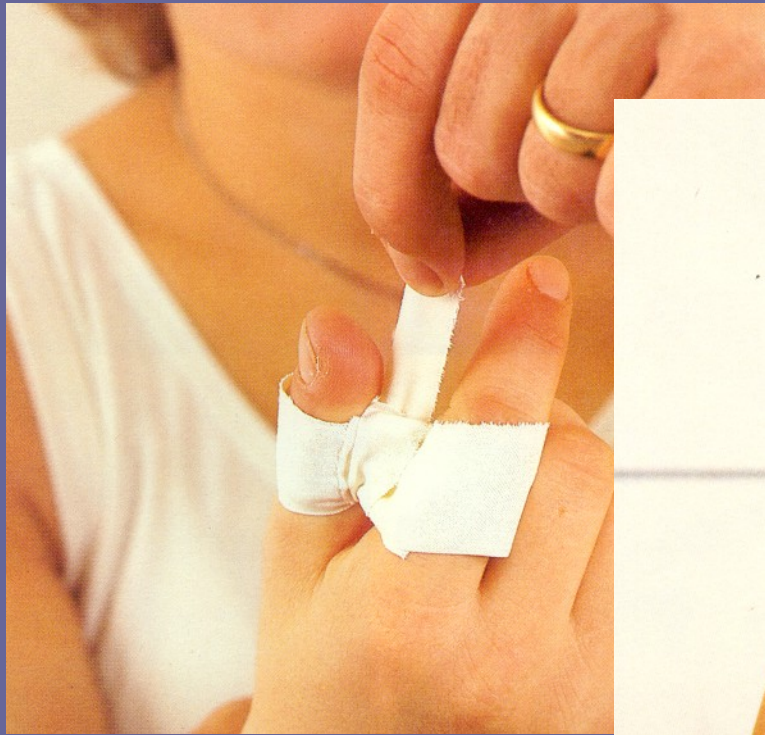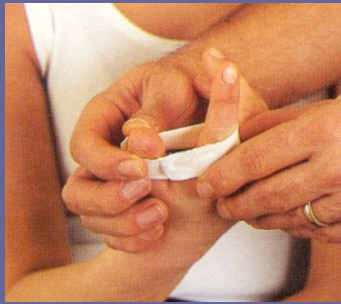- °Zlomeniny nosných kostí

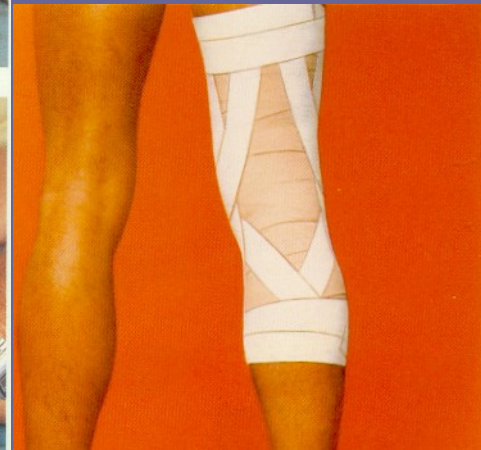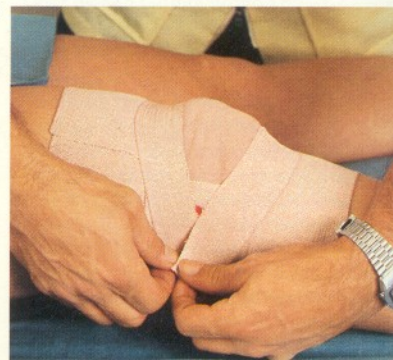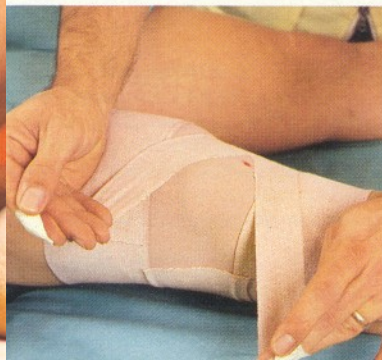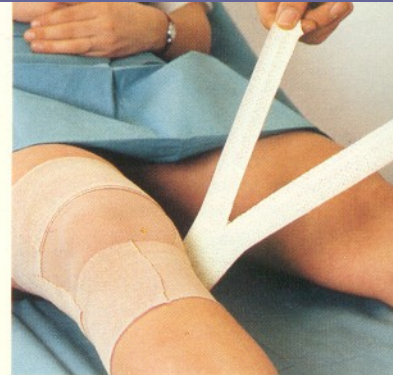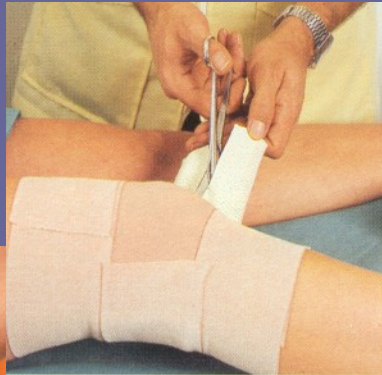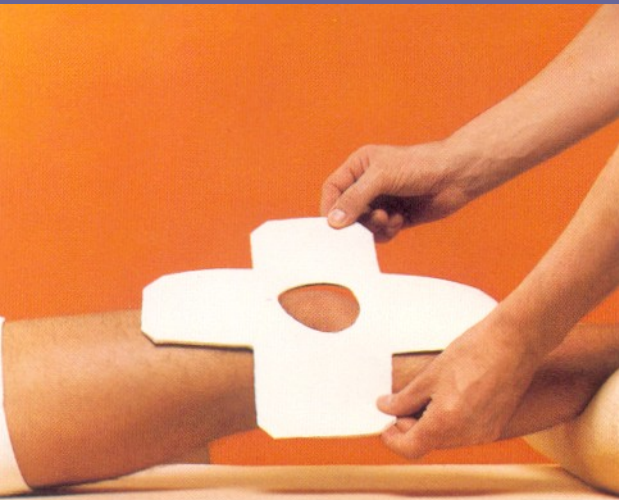
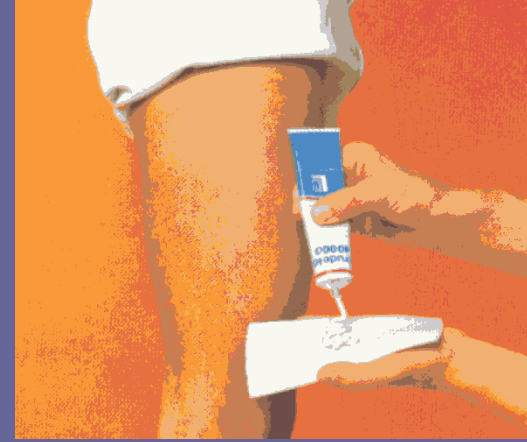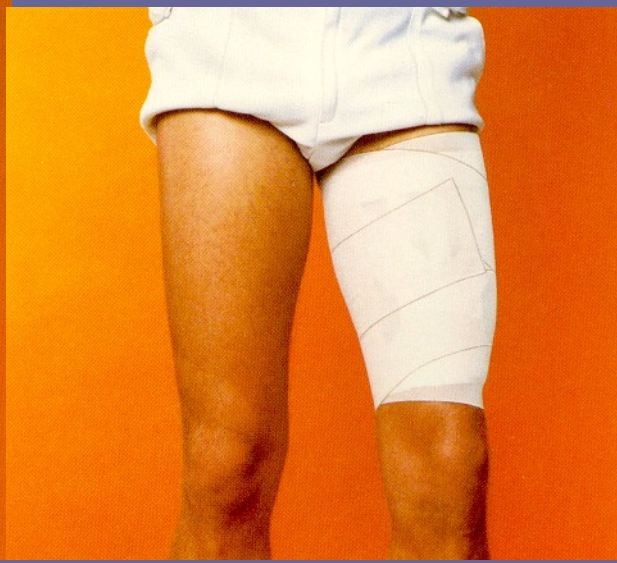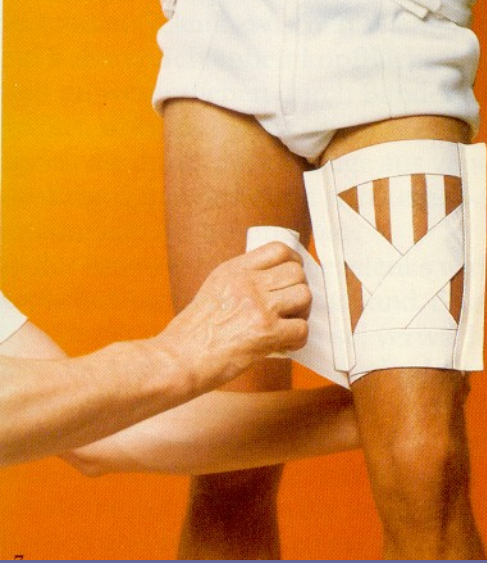Kožní onemocnění a přecitlivělost na náplast

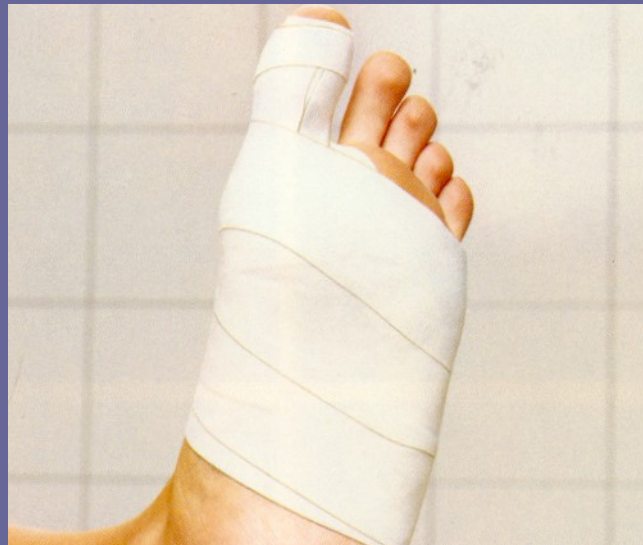












# Ostranění tape

