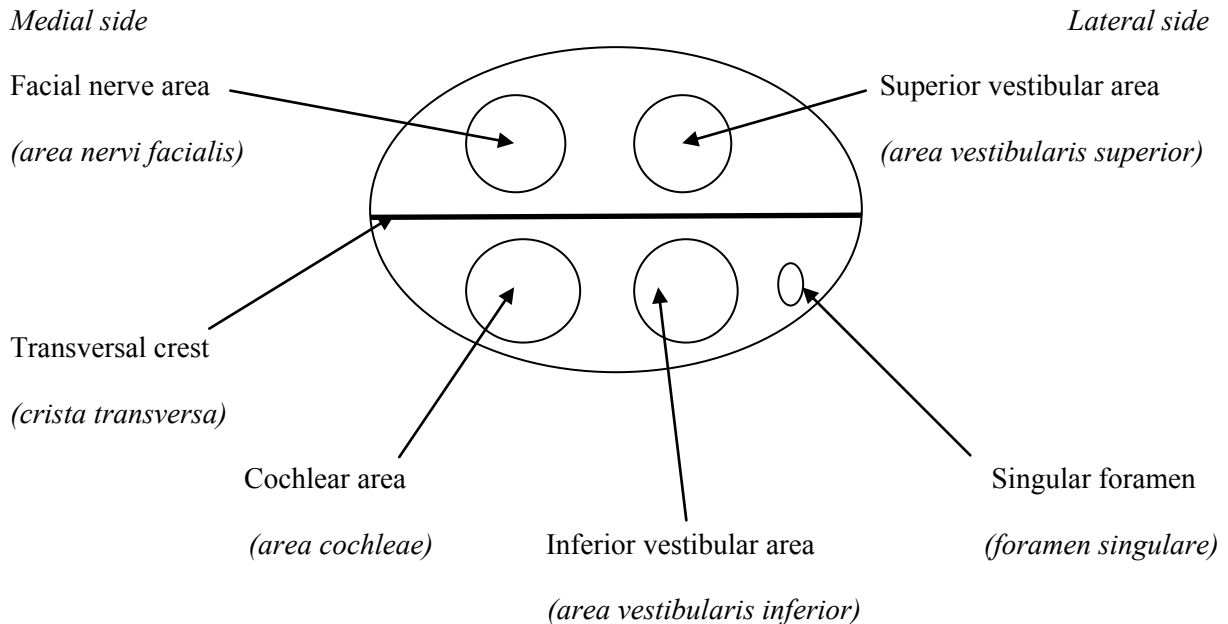


Temporal canals

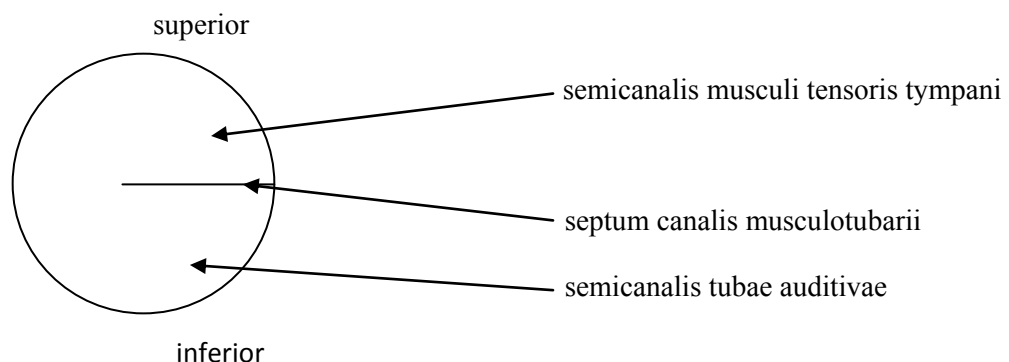
1. **Facial canal (canalis nervi facialis)**– begins at the bottom of internal acoustic meatus (*meatus acusticus internus*) and ends in stylomastoid foramen (*foramen stylomastoideum*); (serves for facial nerve)

The bottom of internal acoustic meatus (*fundus meatus acustici interni*):



- The canal has three parts:
 1. After the canal began at bottom of internal acoustic meatus it goes upright to the longitudinal axis of pyramid (there goes out the branch called greater petrosal nerve (*nervus petrosus major*)).
 2. Near the greater petrosal nerve hiatus it turns to the lateral side and goes at the medial wall of middle ear cavity (*cavum tympani*). Then the canal is located at the dorsal wall of middle ear cavity. (parallel with the longitudinal axis)
 3. The last part of facial canal turns downwards and ends in stylomastoid foramen (*foramen stylomastoideum*).

1. **Canaliculus of chorda tympani (canaliculus chordae tympani)** – chorda tympani is branch of facial nerve and begins in the 3rd part of facial canal and ends in petrotympanic fissure; (serves for chorda tympani)
2. **Carotid canal (canalis caroticus)** – it starts at inferior surface of pyramis (*facies interiér partis petrosae ossis temporalis*) in external aperture of carotid canal (*apertura externa canalis carotici*);- it has sigmoid shape (because the blood pressure is too high for nerve tissue, it could cause damage of brain. So that the function of this canal is to reduce blood pressure before the blood enters to the brain);-ends at the top of pyramis in internal aperture of carotid canal (*apertura interna canalis carotici*); (serves for internal carotid artery)
3. **Caroticotympanic canaliculi (canaliculi caroticotympanici)** – they start within the carotid canal (*canalis caroticus*) (first curvature) and end in the middle ear cavity (*davûm tympani*); (serve for caroticotympanic nerves)
4. **Mastoid canaliculus (canaliculus mastoideus)** - starts at the bottom of jugular fossa (*fossa jugularis*) and ends in tympanomastoid fissure (*fissura tympanomastoidea*); (serves for auricular branch of vagus nerve)
5. **Tympanic canaliculus (canaliculus tympanicus)** - starts at the bottom of fossula petrosa (between the jugular fossa and external aperture of carotid canal), it goes through the middle ear cavity (*davûm tympani*) and ends in lesser petrosal hiatus; (serves for tympanic nerve → lesser petrosal nerve)
6. **Musculotubarius canal (canalis musculotubarius)** – begins at the top of pyramis more ventrally than the internal aperture of carotid canal; is divided by the musculotubarial septum (*septum canalis musculotubarii*) into two levels: upper (semicanalis musculi tensoris tympani) and lower (semicanalis tubae auditivae); ends in middle ear cavity (*davûm tympani*);(serves for tensor tympani muscle and Eustachian tube)



7. Vestibular canaliculus (canaliculus vestibuli) – this canaliculus is for endolymfa drainage; it starts in the inner ear and ends at the posterior surface of pyramis in external aperture of aqueductus vestibuli (*apertura externa aqueductus vestibuli*)

8. Cochlear canaliculus (canaliculus cochleae) this canaliculus is for perilymfa drainage; it starts in the inner ear and ends in external aperture of cochlear canaliculus (*apertura externa canaliculi cochleae*)