



CLINICAL SESSIONS



Gynecology



Topics:

- Examination and main conditions
- Breast examination
- Bimanual vaginal examination
- Cervical (pap) smear

Gynecology

- From the Greek, gynaika meaning woman, is the medical practice dealing with the health of the female reproductive system (uterus, vagina and ovaries)
- Literally, outside medicine, it means "the science of women"

Main conditions:

- Cancer and pre-cancerous diseases of the reproductive organs including ovaries, fallopian tubes, uterus, cervix, vagina, and vulva
- Incontinence of urine;
- Amenorrhea (absent menstrual periods);
- Dysmenorrhea (painful menstrual periods);
- Infertility;
- Menorrhagia (heavy menstrual periods). This is a common indication for hysterectomy;
- Prolapse of pelvic organs;
- Infections of the vagina, cervix and uterus (including fungal, bacterial, viral and protozoal).

History

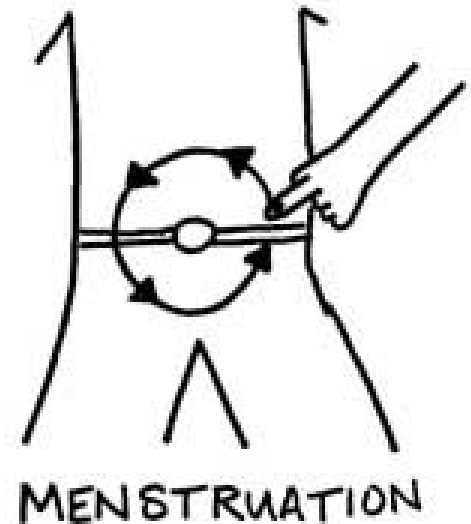The questions should seek information about woman's:

- Menstrual history;
- Obstetric history;
- Previous medical history (past illnesses and operations) and family history;
- Current medications;
- Sexual history;
- Details of contraceptive use, including any side-effects
- History of the main complaint;

History

□ Menstrual History:

- Age at menarche
- Duration of menstrual cycle
- Menstrual pain
- Duration and severity of menstruation



History



- **Obstetric history (if any):**
 - The number of pregnancies and the outcome (spontaneous miscarriages or induced abortions);
 - Ectopic gestation;
 - Children born, their birth weights and the year of birth of each;
 - Complications occurring during pregnancy, labour or the puerperium (the end of the third stage of labour until involution of the uterus is complete, i.e. approximately 6 weeks)

History

Note:

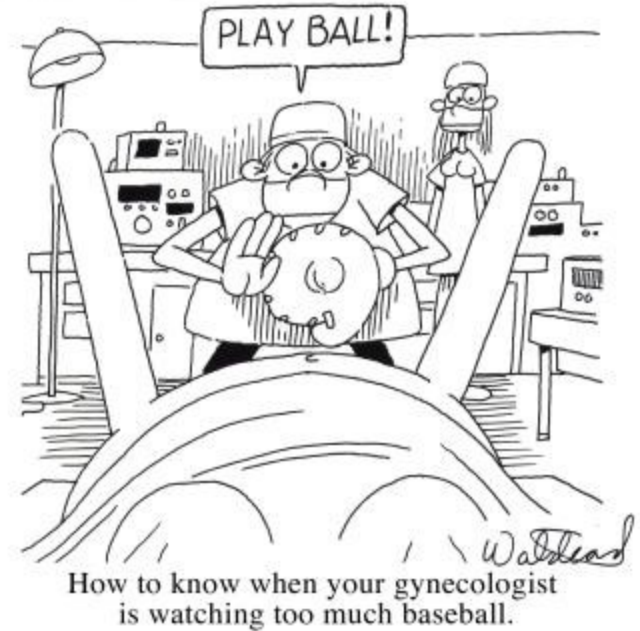
In an older women more emphasis should be placed on the **menopausal history** rather than menarche and menstruation



Examination

- Breast examination;
- Abdominal examination;
- Inspection of external genitalia;
- Pelvic examination, by speculum, and then digitally as a bimanual vaginoabdominal examination;
- Rectal examination in certain instances.

© Original Artist
Reproduction rights obtainable from
www.CartoonStock.com




Breast Examination

- Inspection of the breasts - the patient's arms at her side
- Inspection of the breasts – the patient's arms are raised above her head
 - ▣ Contour of the breasts
 - ▣ Size and shape of aureola
 - ▣ Condition of the nipples
- Placing hand on hip tenses the pectoralis major, accentuating any tethering from an infiltrating neoplasm
- Palpation of the upper outer quadrant of the breast
- Systemic examination of four quadrants of the breast
- Axillary and supraclavicular palpation (with relaxed pectoral muscles)

Note

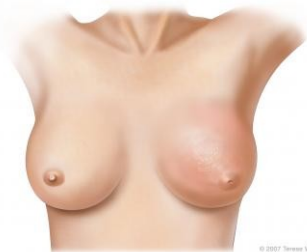- Palpation should be gentle and orderly, using the flat of the fingers of one hand.
- Each portion of the breast should be palpated systematically, beginning at the upper quadrant, inner quadrant, followed by palpation of each portion sequentially until the upper, outer quadrant is finally examined.

<http://www.youtube.com/watch?v=YC0VZzOxIIY>

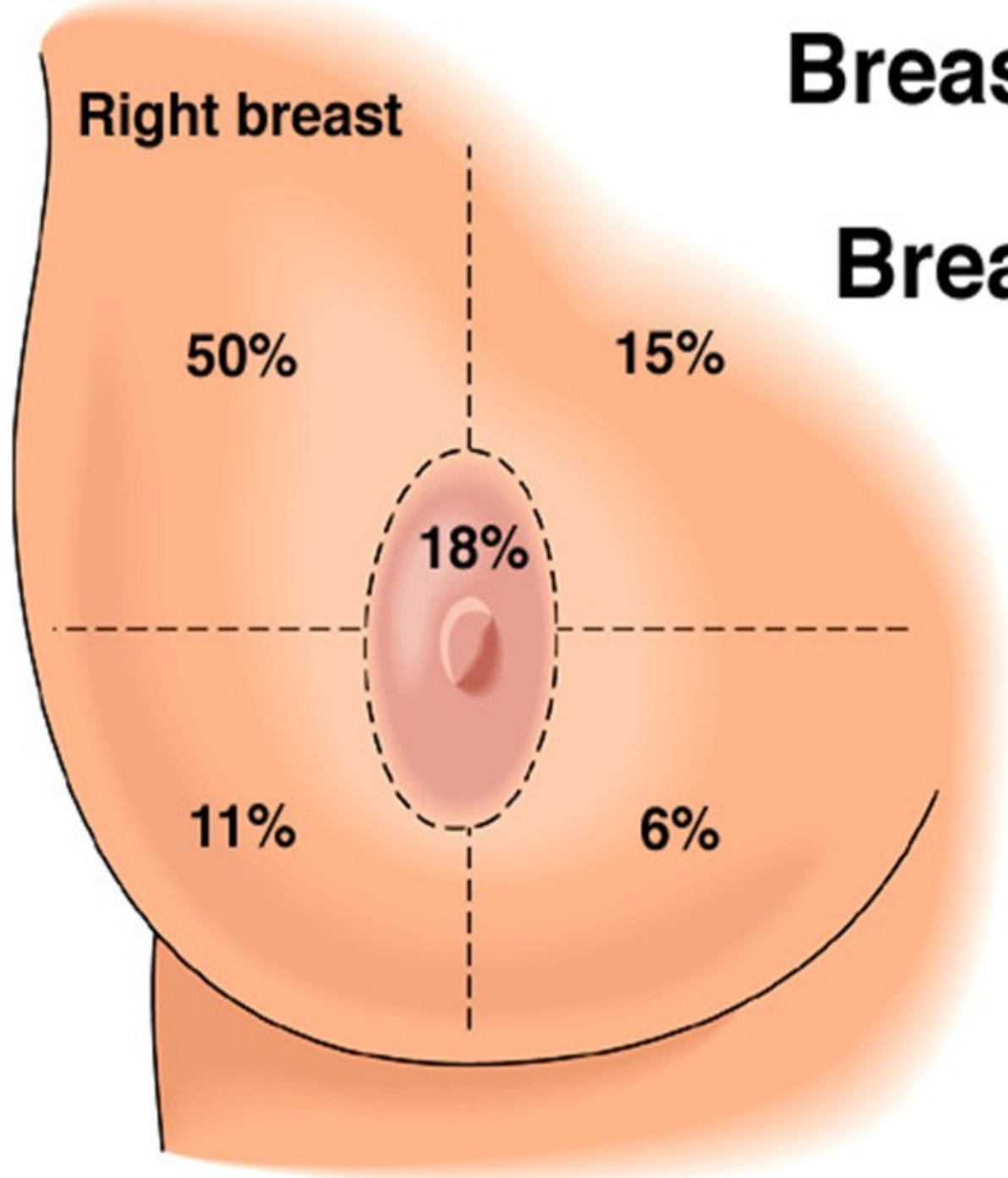


When to do the breast examination?

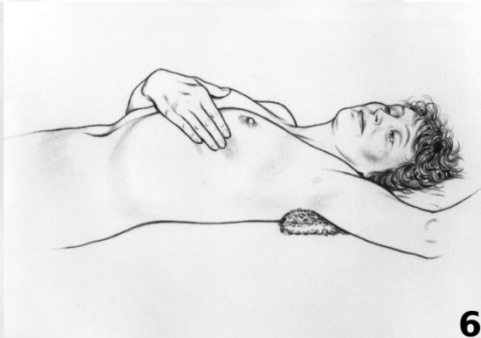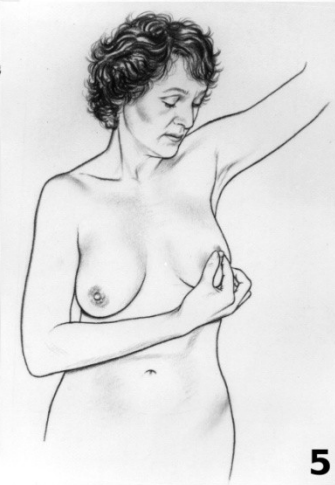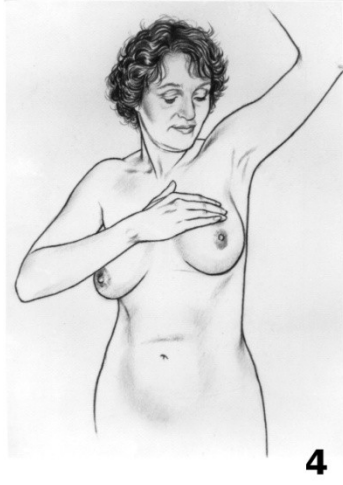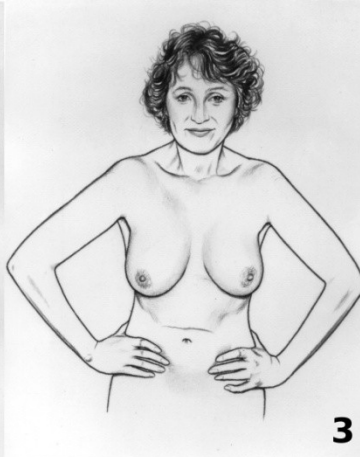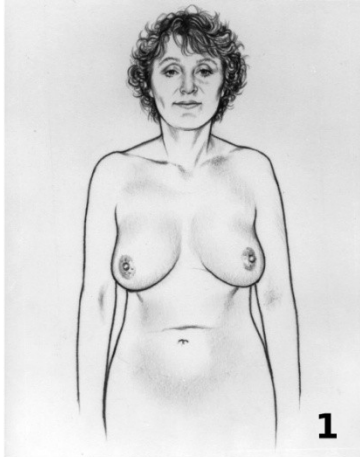
- First consultations of women over the age of 45
- Presence of secretions of milk at times **not** associated with pregnancy (galactorrhoea)
- Breast lumps/nodules felt on palpation
- Discoloration or change in the quality of the skin:
 - ***Redness suggests infection/inflammation***
 - ***'Peau d'orange' quality - an "Orange Peel" like texture that's caused by an uncommon, aggressive inflammatory malignancy***



Breast Quadrants and Breast Cancers



Breast self-examination



- **Breast self-examination (BSE)** is a screening method used in an attempt to detect early breast cancer. The method involves the woman herself looking at and feeling each breast for possible lumps, distortions or swelling.

□ **Method:**

- stand in front of a mirror with the torso exposed to view.
- Find visual signs of dimpling, swelling, or redness on or near the breasts.
- Repeat in several positions, such as while having hands on the hips, and then again with arms held overhead.

Breast self-examination

- The woman then palpates her breasts with the pads of her fingers to feel for lumps (either superficial or deeper in tissue) or soreness.
- Common patterns (designed to ensure complete coverage):
 - ▣ The [vertical strip pattern](#) involves moving the fingers up and down over the breast.
 - ▣ The [pie-wedge pattern](#) starts at the nipple and moves outward.
 - ▣ The [circular pattern](#) involves moving the fingers in concentric circles from the nipple outward.
 - ▣ Some guidelines suggest mentally dividing the breast into four quadrants and checking each quadrant separately.

The palpation process covers the entire breast, including the "axillary tail" of each breast that extends toward the axilla (armpit).

This is usually done once while standing in front of the mirror and again while lying down.

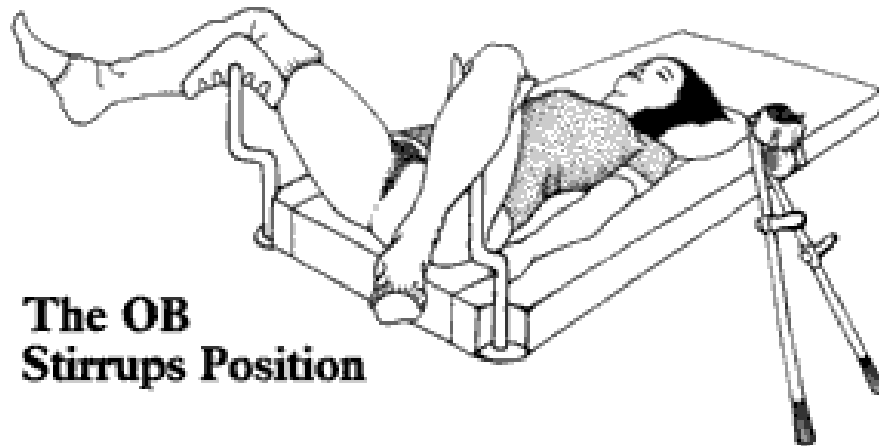
Abdominal examination



- Patient is lying comfortable on her back, after having emptied her bladder immediately beforehand.
 1. Inspection of the abdomen (contour, striae, scars, and dilated veins) — If patient raises her head and coughs, hernias and divarication of the rectus abdominis muscles will be evident;
 2. Palpation of the viscera is performed systematically (liver, gallbladder, spleen and kidneys);
 3. The caecum and colon are palpated next (the hand pressing down gently as the patient breaths out);
 4. Percussion may be required if the presence of free fluid is suspected.

Pelvic Examination

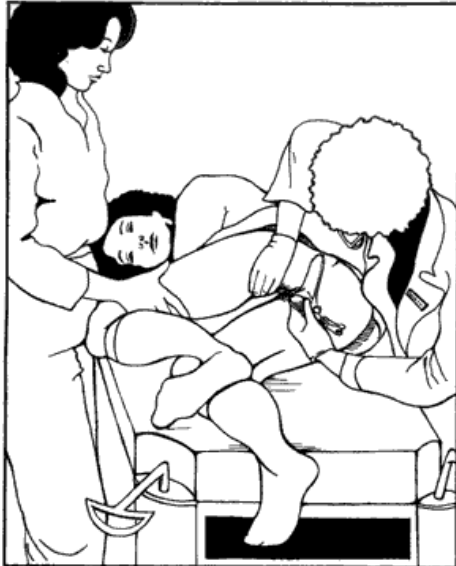- Should follow the abdominal examination, and **should never be omitted unless the patient is virgin.**
- ▣ The external genitalia are first inspected under a good light, with the patient in a dorsal position, the hips flexed and abducted, and knees flexed.



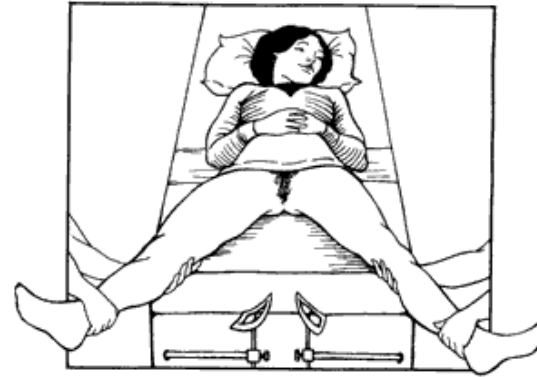
Pelvic Examination

Other positions:

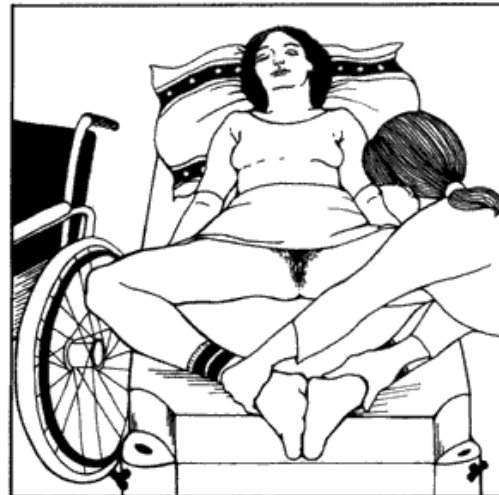
The Knee-Chest Position



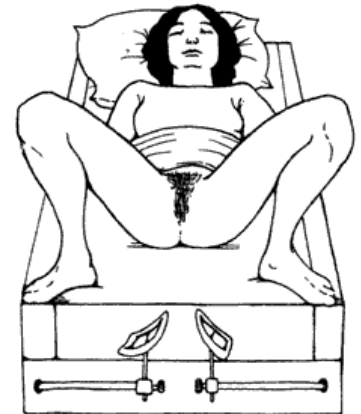The V-Shaped Position



The Diamond-Shaped Position

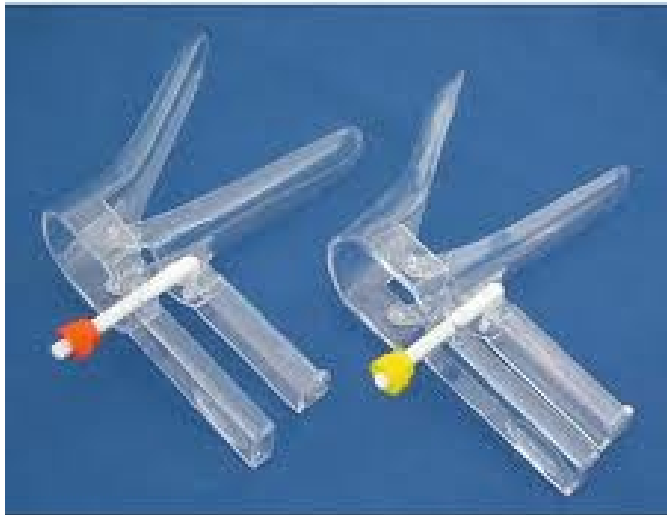

The M-Shaped Position



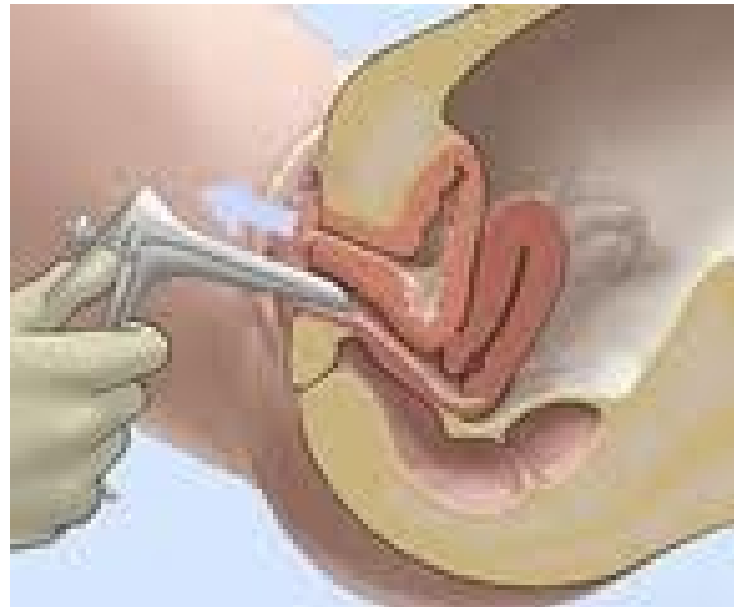
Pelvic Examination – Bivalve Speculum

- The patient is asked to strain down – detection of any evidence of prolapse
- Insertion of a bivalve speculum and visualization of cervix



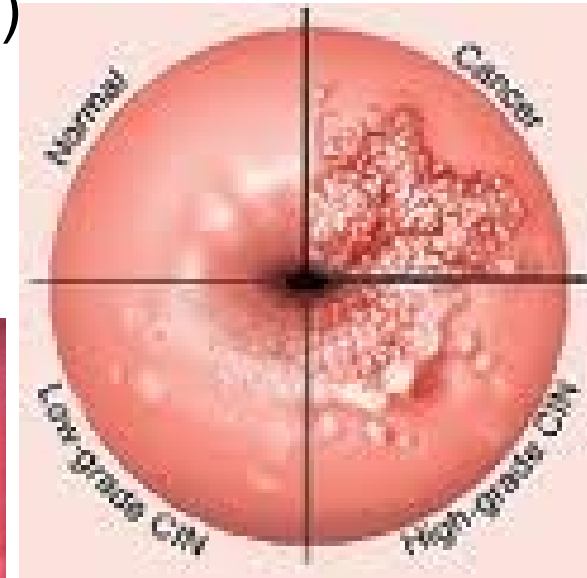
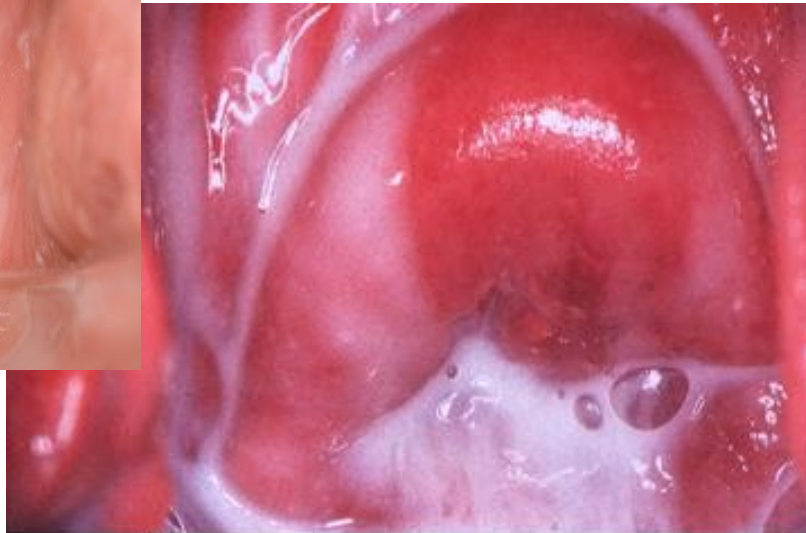
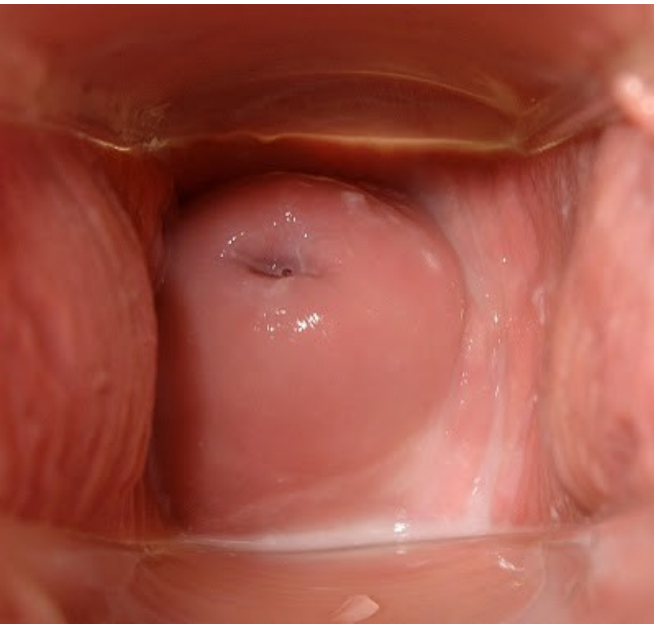How to use a speculum?

- Should be warmed
- Use a lubricant
- Insert it initially obliquely
- Doctor's approach sensitive and communicative



Pelvic Examination – Bivalve Speculum

- The vagina and cervix are inspected
- Perform Pap Test (in this case, no lubricant apart from water should be used on the speculum)



Cervical (pap) Smear

Owww!



I'm sorry! I just
put this thing in
your cervix



Cervical (pap) Smear

□ Definition:

- A Pap smear, also called a Pap test, is a procedure to test for cervical cancer in women. A Pap smear involves collecting cells from your cervix — the lower, narrow end of your uterus.
- Pap smear is your first step in halting the possible development of cervical cancer.

Cervical (pap) Smear

□ Why it's done?

- Is typically done in conjunction with a pelvic examination, although pelvic examinations can screen for reproductive problems or abnormalities, only a Pap smear will detect early cervical cancer or precancers.

□ Who should have a Pap smear?

- First Pap smear should be done about three years after first having sexual relations or at age 21, whichever comes first.

(ACOG - American College of Obstetricians and Gynecologists)

Age	ACOG
21 to 29	Annual Pap tests
Over 30	Every two or three years if you've had three negative tests in a row

Cervical (pap) Smear



- If you have certain risk factors you should undergo a Pap smear annually, regardless of your age. These risk factors include:
 - A diagnosis of cervical cancer or a Pap smear that showed precancerous cells;
 - Exposure to diethylstilbestrol (DES) before birth;
 - HIV infection;
 - Weakened immune system due to organ transplant, chemotherapy or chronic corticosteroid use;

Cervical (pap) Smear

□ Who can consider stopping Pap smears?

□ After total hysterectomy:

- Due to a noncancerous condition, such as fibroids - discontinue routine Pap smears.
- Due to a precancerous or cancerous condition - annual vaginal Pap smear.

□ Older age:

- ACS (American Cancer Society) guidelines - stop having tests at 70 if she's had three negative tests in the last 10 years.
- USPSTF (U.S. Preventive Services Task Force) guidelines - stop Pap testing at 65.
- *Discuss your options with your doctor and together you can decide what's best for you based on your risk factors.*

Cervical (pap) Smear

□ How you prepare?

▣ To ensure that your Pap smear is most effective:

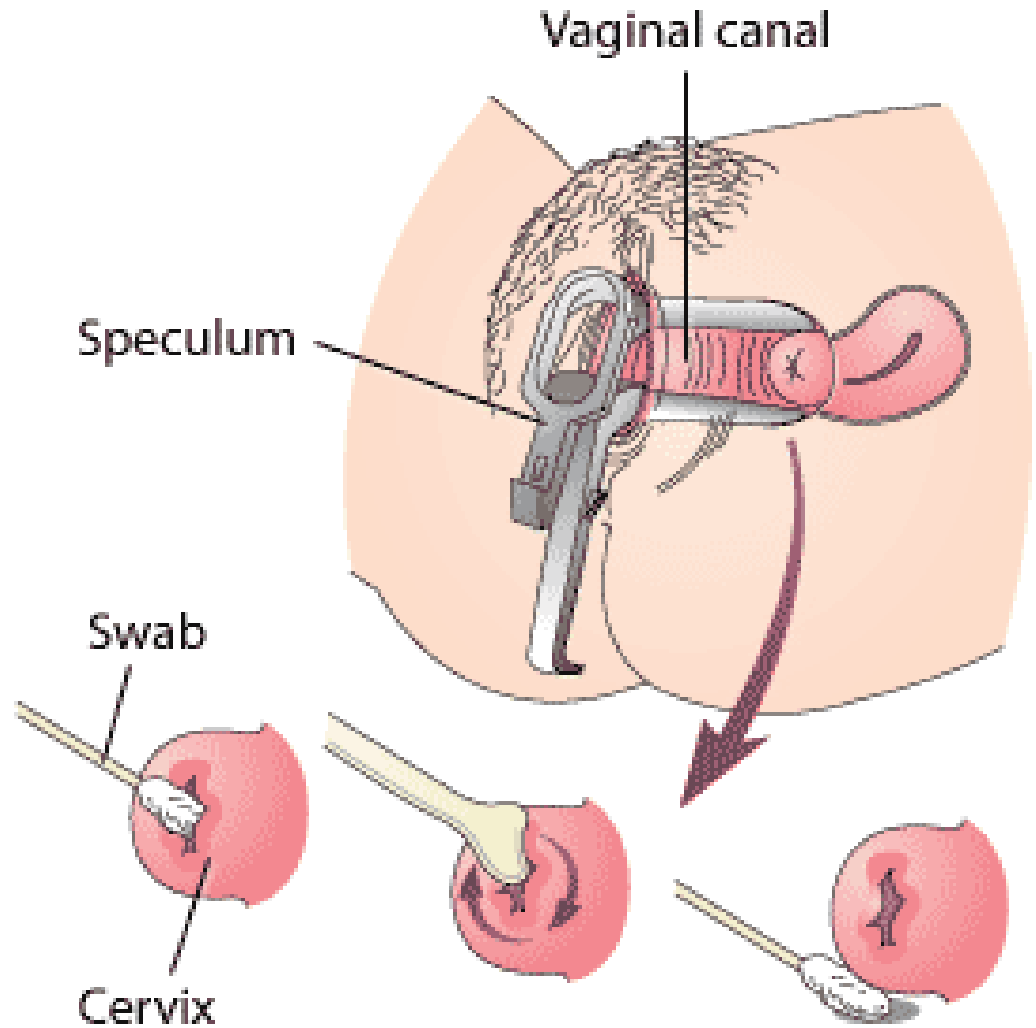

- Avoid intercourse, douching or using any vaginal medicines or spermicidal foams, creams or jellies for **two days before** having a Pap smear, as these may wash away or obscure abnormal cells.
- Try not to schedule a Pap smear during your menstrual period. Although the test can be done, it's best to avoid this time of your cycle, if possible.

Procedure

- Insert a speculum into the woman's vagina, which spreads the vagina open and allows access to the cervix
- Collect a sample of cells from the outer opening or **os** of the cervix by scraping it with an [Aylesbury spatula](#)
- An endocervical brush is rotated in the central opening of the cervix
- The cells are placed on a glass slide and taken to the laboratory to be checked for abnormalities.
- The sample is stained using the Papanicolaou technique, in which tinctorial dyes and acids are selectively retained by cells.
- Unstained cells cannot be seen with a light microscope

Cervical (pap) Smear

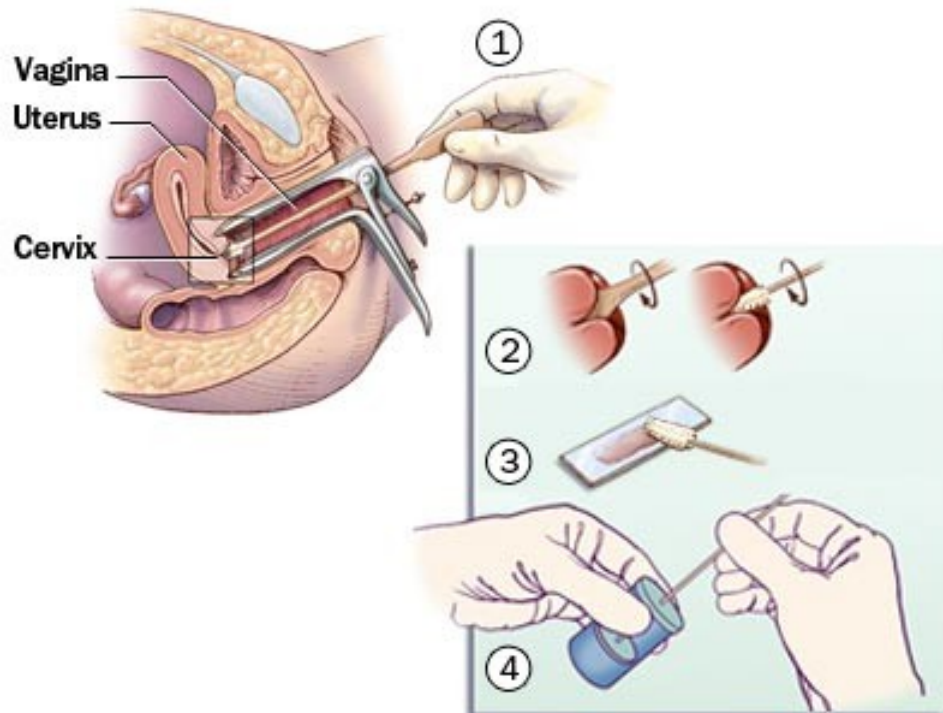
□ Aylesbury spatula



Notes:

- When performing a Pap Test **no lubricant** apart from water should be used on the speculum;
- Depending on the type of Pap test you're undergoing, your doctor transfers the cell sample collected from your cervix onto a glass slide or into a container holding a special liquid to preserve the sample (**liquid-based Pap test**).

Liquid-based Pap test

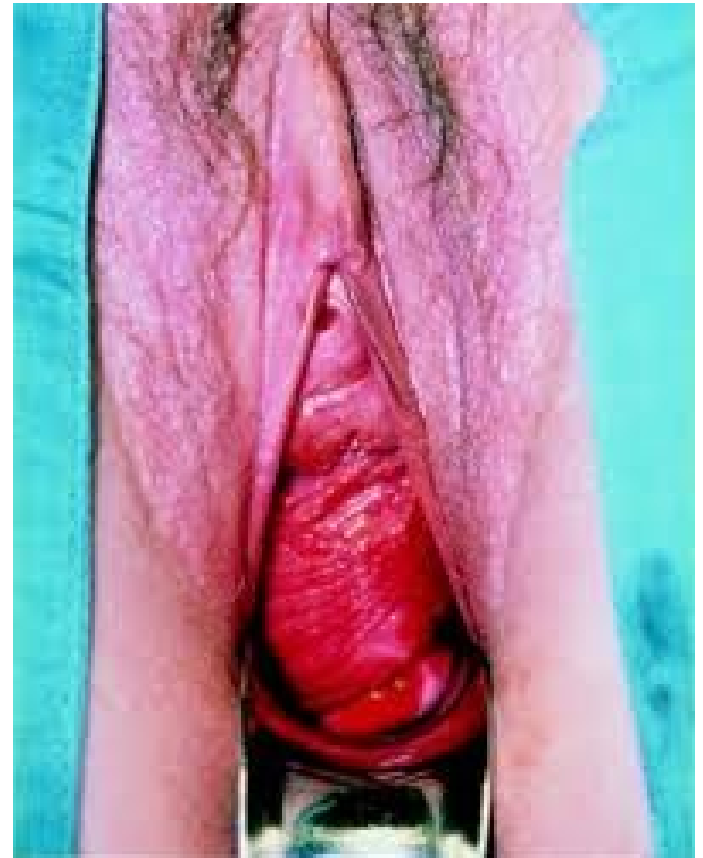
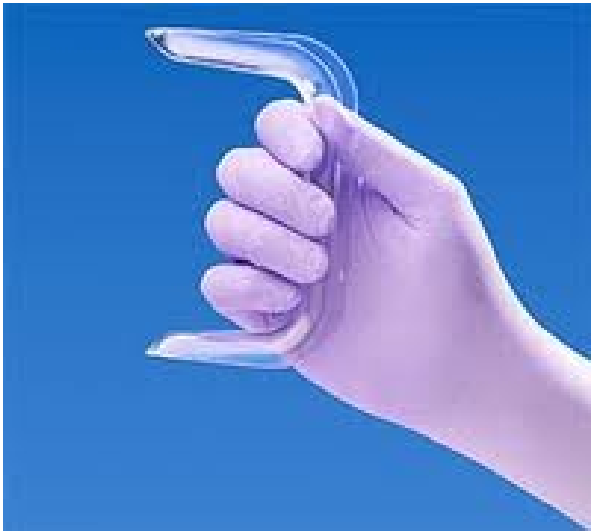
- Liquid-based Pap test, also referred to as liquid-based cytology, is a procedure used to microscopically test a small sample of cells.
- The sample of cells is preserved in liquid rather than smeared on a microscope slide, provides fewer false-negative results .
- In USA is preferred by most laboratories and has largely replaced conventional Pap tests .
- "The choice comes down to cost-effectiveness issues related to laboratory productivity, slide adequacy, and ease of ancillary molecular testing".



Pelvic examination

- If the patient has a prolapse, the degree of the vaginal wall or uterine descent can be best assessed:
 - ▣ With a Sims speculum
 - ▣ Patient in the left position




Pelvic examination

Bimanual examination

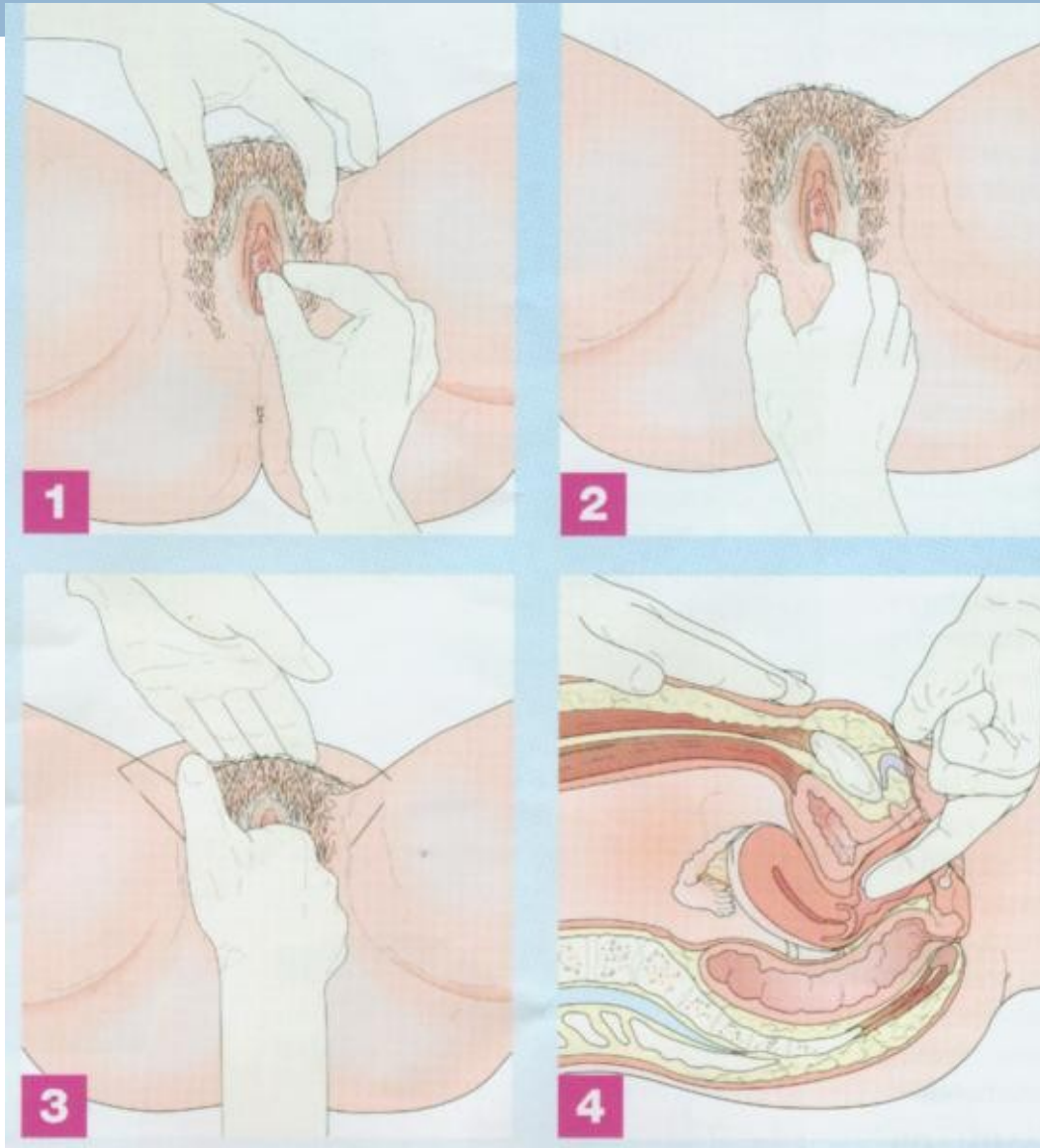
1. One or two fingers of the gloved hand are introduced (usually right hand for a right-handed person)
2. After labia minora have been separated with the left hand to expose the vestibule, the fingers are introduced, passing upwards and backwards to palpate the cervix.
3. The left hand simultaneously palpates the pelvis through the abdominal wall
4. As the intravaginal fingers push the cervix backwards, the abdominally located hand is placed just below the umbilicus and the fingers reach down into the pelvis, slowly and smoothly, until the fundus is caught between them and the fingers of the right hand and the anterior fornix of the vaginal fornix

<http://www.youtube.com/watch?v=dhbOELmVkTc>



Pelvic examination

Bimanual examination



Pelvic examination

Bimanual examination

- Information obtained:
 - ▣ By palpation of the uterus
 - Position, size, shape, consistency, mobility, tenderness, attachments;
 - Normal uterus is positioned either anteriorly or posteriorly and is about 9 cm long;
 - Is pear-shaped and firm in consistency, and can be moved in all directions
 - Is normally tender when squeezed between the two hands

Pelvic examination

Bimanual examination

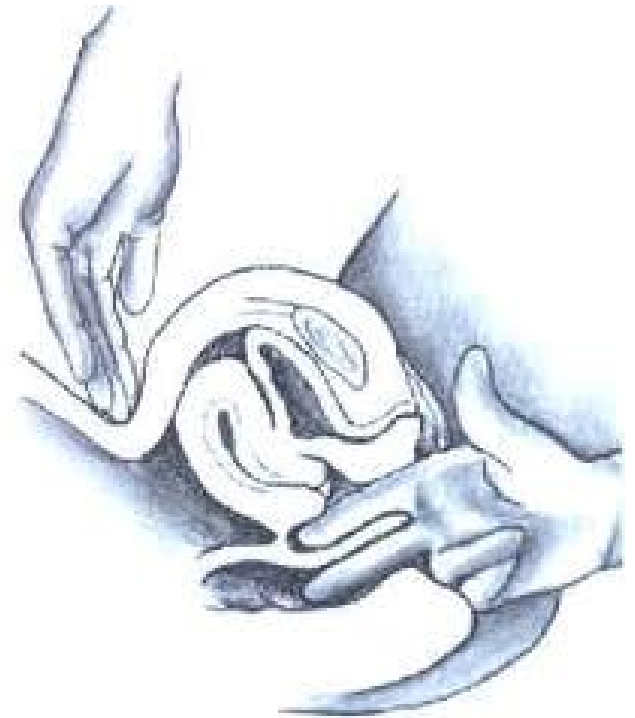- By palpation of the ovaries and Fallopian tubes:
 - Normal fallopian tubes are never palpable!
 - Ovary may or may not be felt, but if palpable is extremely tender to examinations

Procedure:

The tips of the vaginally located fingers are placed in each lateral fornix in turn and then pushed back- and upwards as far as possible without causing pain. The abdominally located fingers simultaneously press backwards about 5 cm medial and parallel to the superior iliac spine.

Rectal examination

- Rectal examination, or a **rectoabdominal bimanual examination**, may replace a vaginal examination in **children and virgin adults**.
- Less efficient and more painful
- Is a useful adjunct to a vaginal examination (when either the outer parts of the broad ligaments or the uterosacral ligaments require to be palpated)
- A **rectovaginal examination** (index finger on vagina and middle finger in the rectum) may help to determine if a lesion is in the bowel or between the rectum and the vagina.



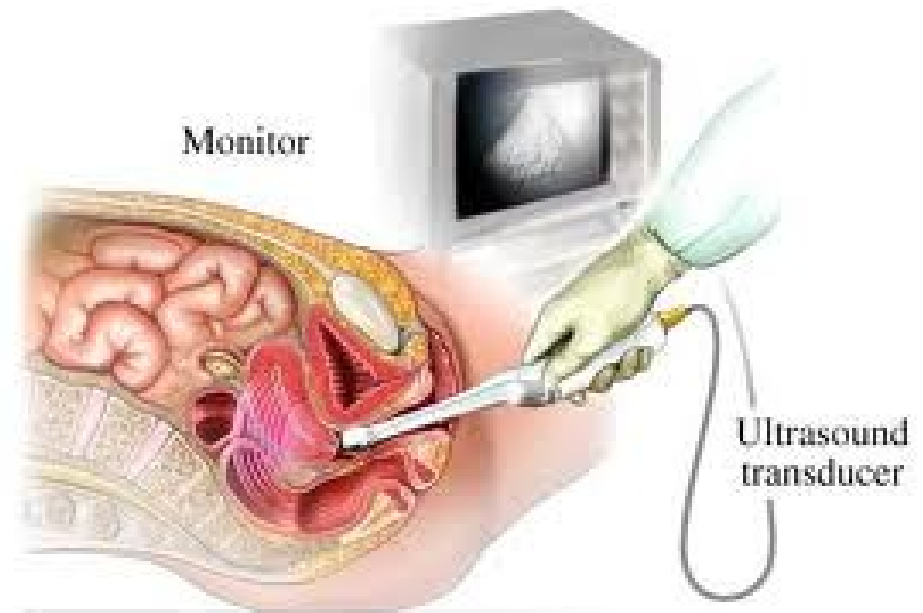
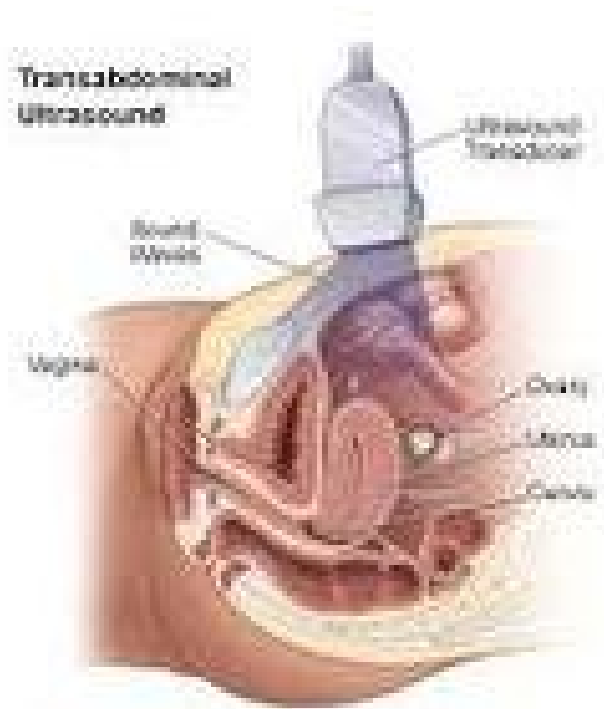
Tests

- Vaginal discharge – swabs
- Urinary symptoms – midstream specimen
- Sexually active women – cervical smear (Pap smear)

Investigations

□ Pelvic Ultrasound

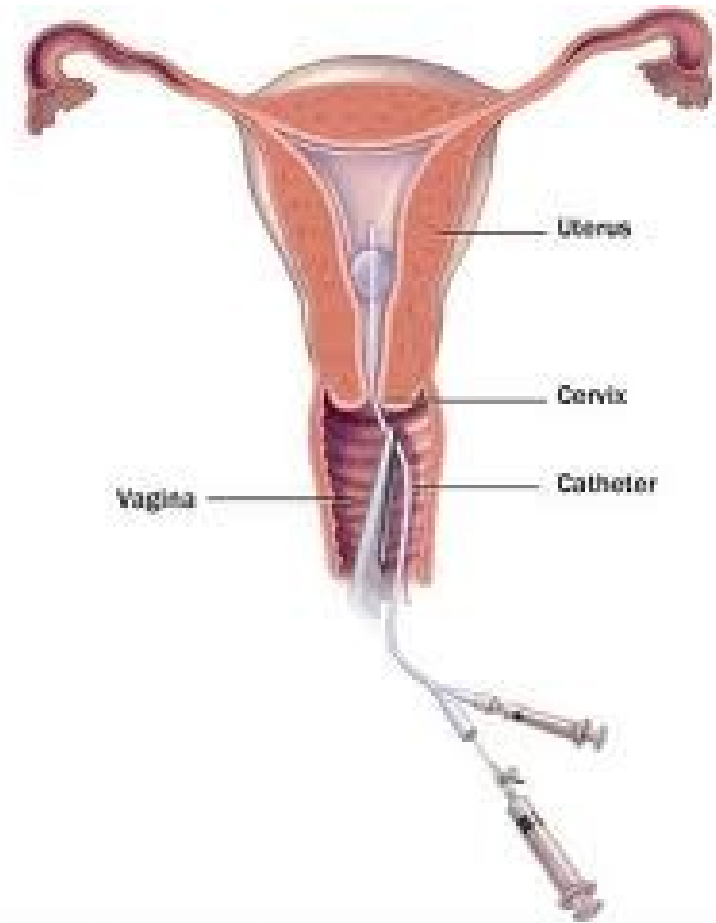
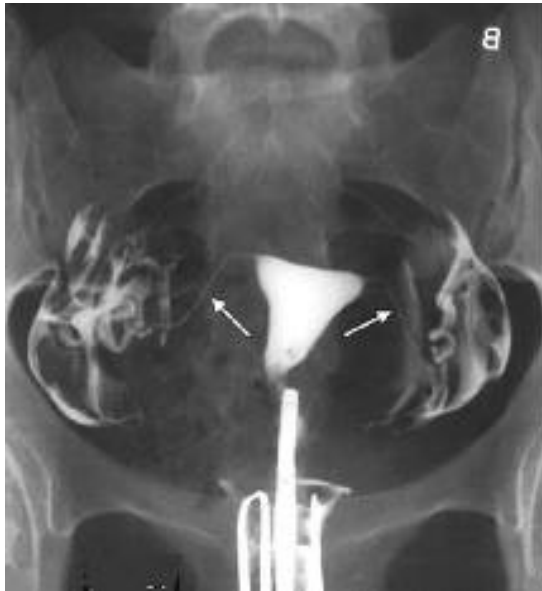- Cystic, benign and malignant tumours of the internal genitalia
- May be made **transabdominally** through full bladder, or **transvaginally** when bladder is empty



Investigations

□ Hysterosalpingography

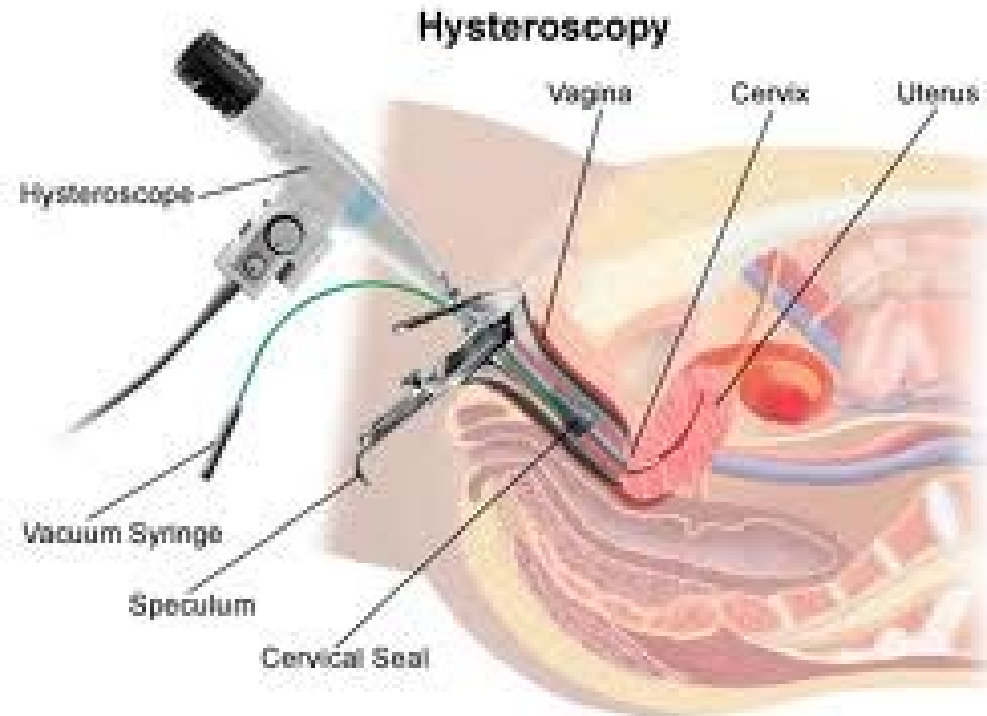
- Injection through the cervix of a radio-opaque subs. and following on a screen as it fills the uterus and fallopian tubes
- Provides information in cases of infertility



Investigations

□ Hysteroscopy

- A small fibreoptic telescope is inserted through the cervix into the uterine cavity, which is inspected.
- Reach a diagnosis in case of menstrual disorders.
- Endometrial polyps, submucous fibroids and intrauterine and septae can be removed and endometrium ablated using this technique



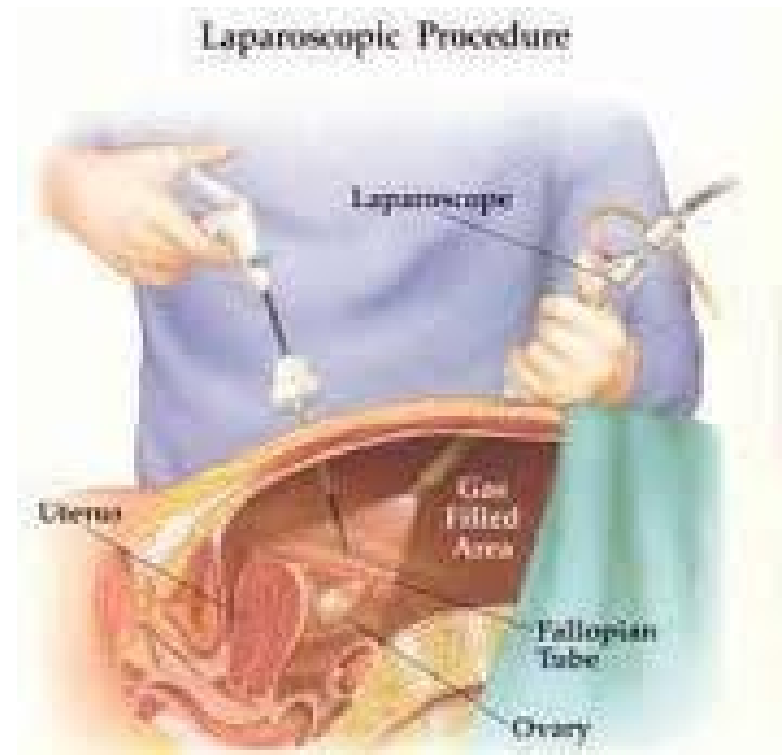
Investigations

□ CT and MRI

- ▣ Role in assessing the nature and spread of malignant disease in genital organs

□ Laparoscopy

- ▣ Inspection of the pelvic organs with a laparoscope inserted into the peritoneal cavity through a small subumbilical incision
- ▣ Provides information about: pelvic organs, chronic pelvic pain, ectopic pregnancy and cases of infertility



Investigations

□ Endometrial Biopsy

- To obtain a sample of endometrium for histological examination
- Done by introducing a small curette through the cervix without anaesthesia.
- Infertility and postmenopausal bleeding

Thank you for your attention!



Joana Almeida