

CLINICAL SESSIONS 2010

'Handbook of Clinical Procedures'



**Compiled and led by
Shan Keshri**

Manuals created by:

Shan Keshri, Devangna Bhatia, Bhavin Doshi, Shilpa Nelapatla,
Nathan Golban, Dave Utulu, Richard Dolan, Arjun Keshri, Sada Chatzialis,
Joae de Oliveira, Amit Kaushal, Pooja Mithani, Diogo Forjaz, Mubarak Al-Rasheedi
Kumaran Thanabalasingham, Nikos Lymberopoulos, Michalis Ploumidis

Teaching Room courtesy of: MIMSA



**MASARYK UNIVERSITY
FACULTY OF MEDICINE**

Preface



Clinical Sessions was a 6 week course (09.03.10 – 13.04.10) run ‘by the students, for the students’ at the Faculty of Medicine, Masaryk University, Brno.

As promised in the first session introduction, this is the ‘Handbook of Clinical Procedures’. It is the result of the efforts of the students.

Sincere thanks to everyone who took part, be it by preparing and presenting a topic, or by attending. I believe it was a huge success, and feel these notes are an invaluable reference source.

As this is the efforts of fellow students, please be understanding if you find any mistakes. Do however, be assured all efforts were made to make the information as accurate and as up-to-date as we could manage.

Once again thanks to all that took part,

Good Luck,

Shan Keshri






Pooja



Sada



Michalis



Richard



Mubarak



Nikos



Bhav



Shan



Devangna



Joae




Dave



Shilpa



Nathan



Amit



Arjun



Diogo



Kumaran

SESSION 1 (Blood & Urine procedures)

1) Taking a Patient History

Devangna Bhatia

2) Phlebotomy (taking blood)

Shan Keshri

3) Interpreting Blood Results (Heamatology, Biochemistry, Lipids, Enzymes)

Shan Keshri & Amit Kaushal

4) Urine Collection, Urinalysis

Shan Keshri

5) Cathethers and Cannulas (IV situations)

Bhavin Doshi

6) Common Drugs used to treat common respiratory disorders

Shan Keshri

SESSION 2 (Obs / Gynae)

1) Arterial Blood Sampling

Nathan Golban

2) Obs n Gynae Intro, Breast examination

Arjun Keshri & Sada Chatzialis

3) Pregnancy Test

Arjun Keshri & Sada Chatzialis

4) IM & SC injections. Insulin injection techniques

Pooja Mithani

5) Pelvic examination & Cervical Pap Smear

Shan Keshri

SESSION 3 (GIT)

- 1) Abdominal examination
- 2) Nasogastric tube insertion
- 3) First Aid overview
- 4) Central Venous Catheterisation
- 5) Sutures

Amit Kaushal & Kumeran Thanabalasingham

Shan Keshri

Devangna Bhatia

Shilpa Nelapatla

Joae de Oliviera

SESSION 4

- 1) Rectal examination
- 2) Otoscopy & Ophthalmoscopy
- 3) Urethral Catheterisation (male & female)
- 4) GALS (gait, arm, leg, spine) & joint exam

Nikos LyMBERopoulos

Shan Keshri

Diogo Forjaz

Dave Utulu

SESSION 5 (Neuro, Cardiac)

- 1) Neurological examination (cerebellar, cranial nv, reflexs)
- 2) CSF Examination
- 3) Drainage Tubes (application and removal)
- 4) Normal chest xray (things to check)
- 5) ECG (signs of heart disease)

Shan Keshri

Michalis Ploumidis

Devangna Bhatia

Mubarak Alrasheedi

Dave Utulu

SESSION 6 (Resp)

- 1) Respiratory Function Tests (peak flow, spirometry, manual ventilation)
- 2) Airway Intubation (inc. simple adjuncts e.g. Guedal airway/ laryngeal masks)
- 3) Administration of oxygen therapy (via a face mask or other equipment)
- 4) Using a Nebuliser / Inhaler correctly

Dave Utulu

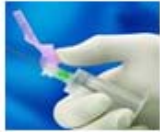Joao de Oliviera

Richard Dolan

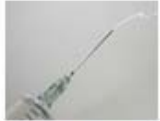Richard Dolan

CLINICAL SESSIONS

Learn & Revise step-by-step skills:



Blood Collection



Injections



History Taking



Otoscopy



Lumbar Puncture



Clinical Examinations



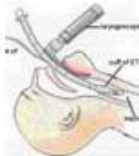
Urinary Catheters



First Aid



Ophthalmoscopy



Airway Intubation

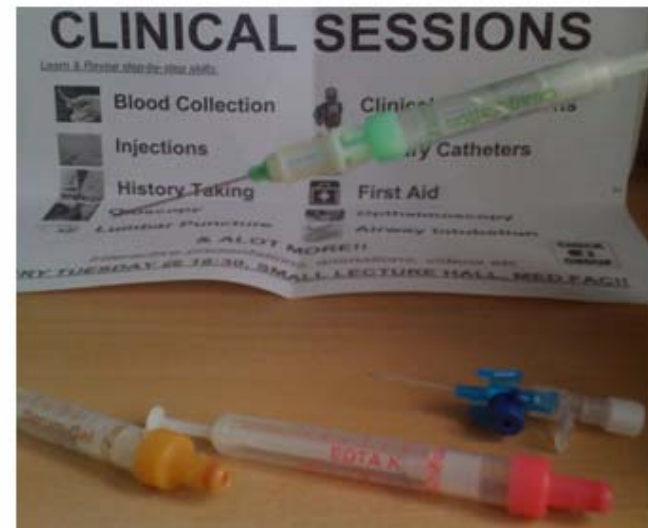& ALOT MORE!!

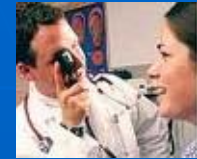
Interactive presentations, animations, videos etc

**CHECK
f
GROUP**

SESSION 1 (I-V Procedures) > TUES 9TH MARCH <

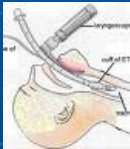- 1) Patient History
- 2) Phlebotomy (taking blood)
- 3) Interpretation of Blood results
- 4) Catheters & Cannulas (securing IV Line), IV drip.
Correct use of electronic devices which drive and regulate the rate of fluid administration. IV injections





WELCOME TO

CLINICAL SESSIONS



AIM – Quick reference guides

- Resource of 'clinical manuals' = quick reference to know step by step method and core principles
- Non-practical topics = train our minds to think differential diagnoses and treatments
 - Results of urinalysis show low urea level. What could this indicate?
 - Patients suffers from heart failure. What is the first line drugs classes; what are some names of preferred B-Blockers used in hospitals / UK today?
- Learn or revise via weekly interactive presentations
 - Q&A discussions, videos, role-play, props, anything to illustrate the concepts

Why is it important to know these things now?

- They are based on the 'basic learning outcomes of medical school', set out by the GMC UK.
- When applying for your 1st job, the 'Clinical Skills' section of form asks: Can you confidently do the following procedures
Yes or No?

Therapeutic procedures

Procedure	Description in lay terms
16. Administering oxygen	Allowing the patient to breathe a higher concentration of oxygen than normal, via a face mask or other equipment.
17. Establishing peripheral intravenous access and setting up an infusion; use of infusion devices	Puncturing a patient's vein in order to insert an indwelling plastic tube (known as a 'cannula'), to allow fluids to be infused into the vein (a 'drip'). Connecting the tube to a source of fluid. Appropriate choice of fluids and their doses. Correct use of electronic devices which drive and regulate the rate of fluid administration.
18. Making up drugs for parenteral administration	Preparing medicines in a form suitable for injection into the patient's vein. May involve adding the drug to a volume of fluid to make up the correct concentration for injection.
19. Dosage and administration of insulin and use of sliding scales	Calculating how many units of insulin a patient requires, what strength of insulin solution to use, and how it should be given (for example, into the skin, or into a vein). Use of a 'sliding scale' which links the number of units to the patient's blood glucose measurement at the time.
20. Subcutaneous and intramuscular injections	Giving injections beneath the skin and into muscle.
21. Blood transfusion	Following the correct procedures to give a transfusion of blood into the vein of a patient (including correct identification of the patient and checking blood groups). Observation for possible reactions to the transfusion, and actions if they occur.
22. Male and female urinary catheterisation	Passing a tube into the urinary bladder to permit drainage of urine, in male and female patients.

Yes No
* Assess a patient's problems and form plans to investigate and manage these, involving patients in the planning process

Yes No
* Work out drug dosage and record the outcome accurately

Yes No
* Write safe prescriptions for different types of drugs

Carry out the following procedures involving veins:

Yes No
* Venepuncture

Yes No
* Inserting a cannula into peripheral veins

Yes No
* Giving intravenous injections

Yes No
* Give intramuscular and subcutaneous injections

Yes No
* Carry out arterial blood sampling

Yes No
* Perform suturing

Yes No
* Demonstrate competency in basic life support

Yes No
* Carry out basic respiratory function tests

Yes No
* Administer oxygen therapy

Yes No
* Use a nebuliser correctly

Yes No
* Nasogastric tube insertion

Yes No
* Perform bladder catheterisation

Click the "Save" button to save any changes you have made to this section of the form. You will be able to return and edit this page any time before you submit your application.

Don't only concentrate on the core principles!

- UK students have OSCE practical exams. If they forget to wash their hands or forget to check patient identity before even touching the patient they lose marks!!
- So to maintain this standard, Safety, infection control and communication reminders will also be included in the presentations .

- We only have time to study the clinical side of things.
- With regards to the textbook science, we can make references to the key words, to give you a starting point needed to read further.

Any questions before we get started?

HISTORY TAKING





Devangna
Bhatia

Interpersonal
skills

Knowledge
of medicine


Analytical
skills

1



Case history taking

2



3



Clinical examination

INTRO

- A.k.a anamnesis
- An accurate history is the biggest step in making the correct diagnosis.
- The main aim of history taking is to find out what caused the patient to come to the surgery and seek help.
- Then it is our job, as doctors, to use this information and formulate a diagnosis and provide the medical care needed.
- The more detail you can get, the better and easier it will be for you to come up with a diagnosis.

Before taking a history...

- Put the patient at ease – developing a good relationship with the patient will help
- Shake hands, introduce yourself
- Check whether the patient is comfortable
- Have a **conversational tone** rather than an interrogative one – it will make the patient feel more comfortable and that (s)he can tell you more information

While taking the history, keep in mind...

- Don't interrupt the patient while (s)he is talking, let them finish and then ask the questions...
- Show that you are paying attention even while writing – nodding, occasionally looking up and making eye contact, or the occasional “yes, ok”
- Don't forget to write the date (& time)!
- If you ask about any malignancies in the family, you need to be tactful!
- Keep in mind the religion of the patient and be tactful, so as you don't look ignorant when asking some questions

Taking the history...

- 1) Start with general questions : name, age, DOB, occupation, martial status
- 2) Presenting Complaint (PC): “What has been the trouble recently?”

This is the complaint that caused them to seek medical help.

Use the patient's wording, when noting it down, rather than medical terms...

3) History of Presenting complaint (HPC): “When did it begin? What was the first thing you noticed? Have you had it before?”

Site

Onset – gradual or sudden

Character – sharp, dull, thumping, constant...

Radiation

Associations (sweating, nausea...)

Timing of pain/duration/frequency

Exacerbating and alleviating factors

Severity (scale of 1 to 10, or comparing it to child birth)

- 4) Direct questioning (DQ): specific questions about the diagnosis you have in mind (+ its risk factors), e.g. if you suspect the patient may have malaria, ask them about their travel history, what they may have consumed...
- 5) Past Medical History (PMH): ever been in hospital? Illnesses, especially childhood ones. Operations? Diabetes, asthma, bronchitis, TB, jaundice, hypertension, rheumatic fever, heart disease, epilepsy, stroke, peptic ulcer, anaesthetic problems.

Also, ask here about **allergies** – penicillin, dogs, cats, hay fever, dust...

- 6) Drug History (DH): taking any tablets, injections? “off the shelf” drugs, e.g. cough syrup? The pill, herbal remedies?
- 7) Social History (SH): marital status? Live alone? Any help at home? House or apartment? What does the illness prevent the patient from doing? Occupation? Sexual history – their attitude towards it...
- 8) Family History (FH): age, health and cause of death of parents, siblings and children. Diseases such as hypertension, diabetes, or malignancies in the family

9) Alcohol, Recreational drugs, tobacco: How much?
How often? When did you begin? When did you stop?

Express cigarettes in *pack-years*: 20 cigarettes
smoked per day for 1 year = 1 pack-year

We all like to present ourselves in the good light, so
be ready to **double** the stated quantities by the
patient!

The **CAGE** questionnaire can be used as a screening
test for alcoholism (later on)

Functional enquiry: to uncover un-declared symptoms...

General problems - weight loss, night sweats, any lumps, appetite, fever, recent trauma

Cardio-respiratory symptoms – cough, sputum, wheeze, haemoptysis, oedema, chest pain, dyspnoea, orthopnoea

Gut symptoms – abdominal pain, haematemesis swallowing, ingestion, nausea/vomiting, bowel habit, stool – colour, consistency, blood

Genitourinary Symptoms – incontinence, dysuria, haematuria, nocturia, frequency, polyuria, hesitancy

FEMALES: vaginal discharge, menses: freq, regularity, painful, heavy/light, first day of last menstrual period (LMP), menarche, menopause, no. of pregnancies, any chance of pregnancy right now?

Neurological Symptoms – special senses – sight, hearing, taste & smell; seizures, faints, poor balance, headaches, weakness, “pins and needles”, speech problems, sphincter problems

Important thing to do, is assess function: what can and can't the patient do at home, work etc.

Musculoskeletal symptoms – pain, stiffness, swelling of joints; functional deficit; diurnal variation in symptoms (i.e. with time of day)

CAGE Questionnaire

Been used for a long time, as a screening test for alcoholism

2 or more positive answers = alcohol problem

C: have you ever felt you should **cut down** on your drinking?

A: have you ever been **annoyed** at others' concerns about your drinking?

G: have you ever felt **guilty** about drinking?

E: have you ever had alcohol as an **eye-opener** in the morning?

Definitions

- Haemoptysis - coughing up blood
- Dyspnoea – breathlessness
- Orthopnoea - breathlessness while lying flat
- Haematemesis - vomiting blood
- Incontinence – stress or urge
- Dysuria – painful micturition
- Haematuria – bloody micurition
- Nocturia – needing to micturate at night
- Polyuria – passing excessive amounts of urine
- Hesitancy – difficulty starting micurition
- Menarche – the first menstrual period, usually occurring during puberty
- Menopause - the period of permanent cessation of menstruation, usually occurring between the ages of 45 and 55.

VENEPUNCTURE: PHLEBOTOMY



SHAN KESHRI
Clinical Sessions 2010

aka

BLOOD COLLECTION

INDICATIONS

Diagnostic:

- Obtain blood sample for analysis.

(e.g. systemic problems – Fe anemia, glucose DM, INR, infections, cholesterol, immunology, liver enzymes/ function)

INDICATIONS

Therapeutic:

- treat Polycythemia Vera (elevated RBC volume aka hematocrit)
- treat hemochromatosis (dangerously high iron levels)
- Donation for transfusion

CONTRAINDICATIONS

- Low oxygen levels in blood (hypoxemia)

RISKS

- Infection
 - negligible if sterile environment, proper use/disposal of needles, and proper management of samples.

- Hitting a nerve or artery (arterial stab)
 - remove needle and apply pressure

SIDE EFFECTS

- Some pain, possible bruising
- Fainting and light headed (vaso-vagal)
- Excessive bleeding
- Haematoma (blood acc. under skin)
- Iron deficiency anemia (in therapeutic phlebotomy)

ALTERNATIVES

- No real alternative to phlebotomy, however there are various different sites on the body that could be used.
- See Method.
- Never attempt more than twice:
 - Refer patient back.

PROCEDURE

Think Action & Rationale!



WHAT are you doing?



WHY are you doing it?

At every
step know:

WASH HANDS

EQUIPMENT: Sterile Tray with:

- Pair of gloves
- Tourniquet
- Alcohol wipes
- Gauze
- VACUTAINER barrel and Needle
- Blood bottles (color coded according to additive e.g. anticoagulant or preservative)

RULES OF ASEPSIS

STEP 2: CHECK PATIENT DETAILS

- Ask full Name, DOB, Gender and compare with blood request form!
- Check blood form has been signed by the requesting doctor
- If special requirements, check patient has complied, e.g. fasting!
- Have you had blood taken before? (preferred vein)

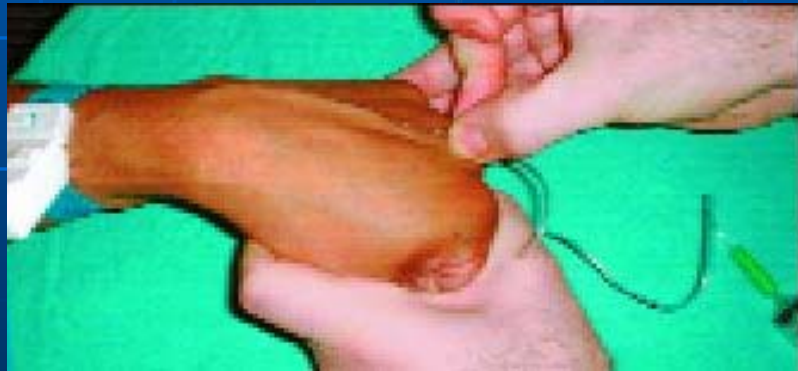Put Gloves on.

Ensure patient is in a relaxed position.

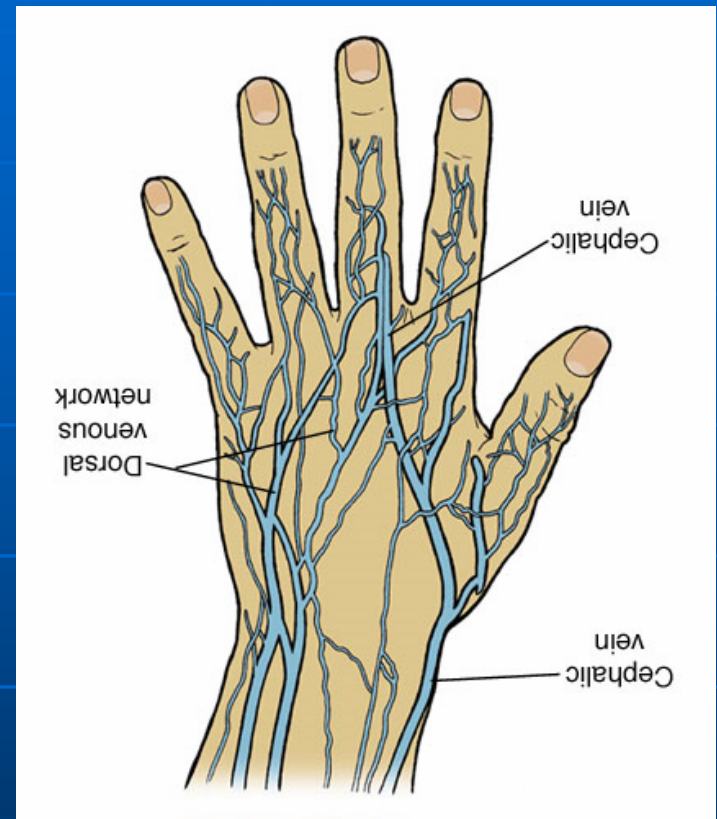
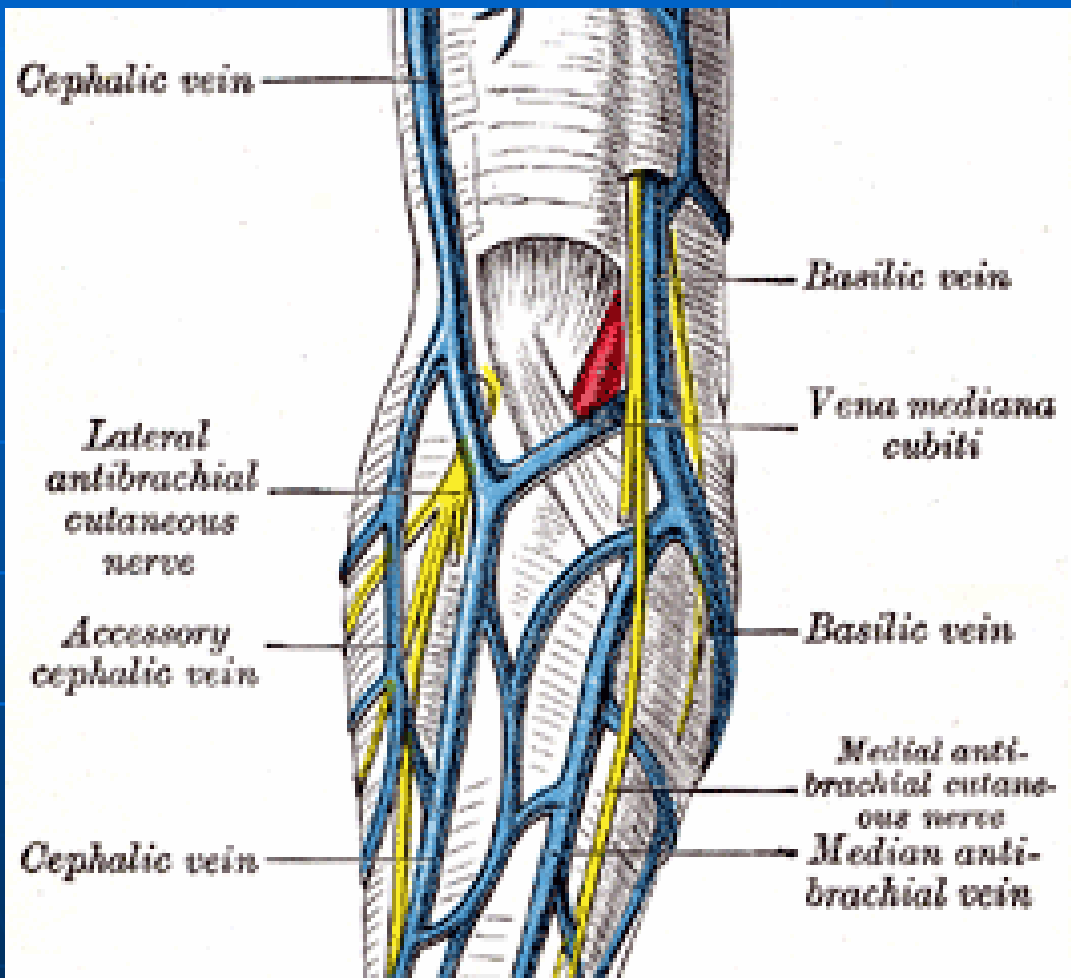
FIND A SUITABLE VEIN

(Palpation: bouncy & large & superficial)

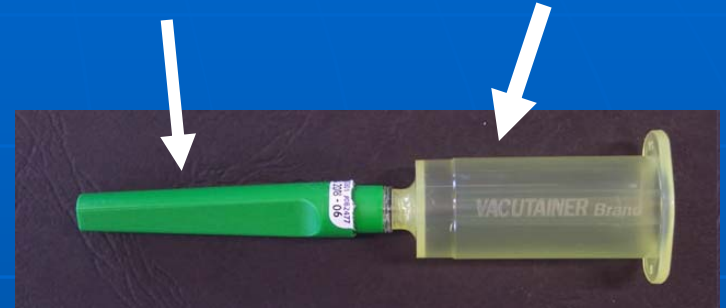- 90% used – Anterior Cubital Fossa,
– **Median Cubital vein, Cephalic, Basilic Vein**
- Back of hand- **Cephalic (housemans) vein**



- Feet, Central Line, Peripheral Venous line, Femoral stab (groin harder to disinfect)

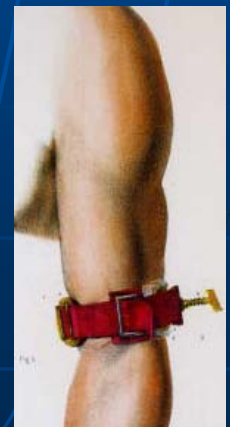

- Attach VACUTAINER needle to barrel.

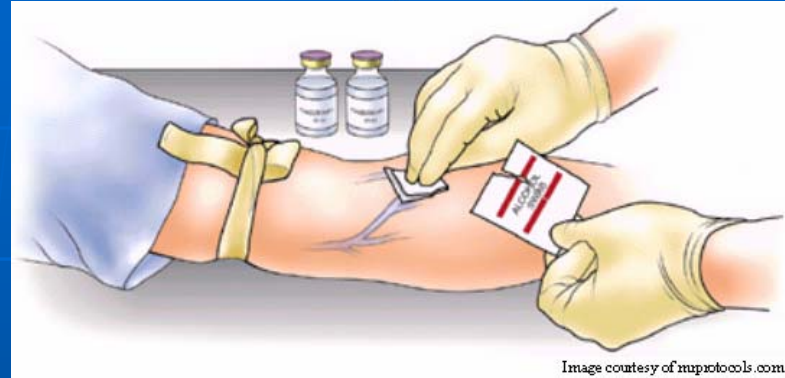


- Apply tourniquet 2 fingers above anterior cubital fossa. (increases pressure)

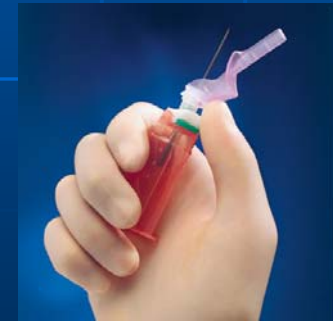Inform patient 'this may feel a little tight'.



- Disinfect skin with alcohol wipes.

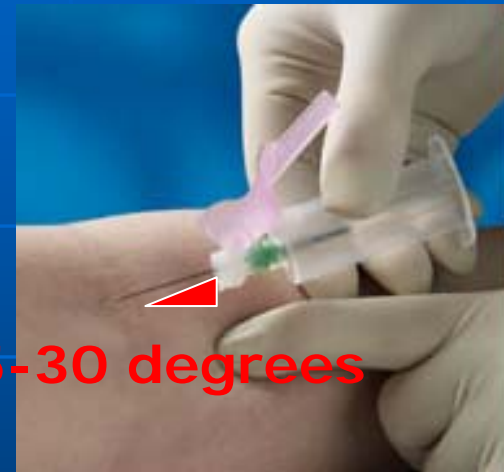


- Remove cap from needle.



- Warn Patient of Sharp Scratch.

- Stretch skin and insert needle at 15-30 degrees parallel into the vein (bevel edge of needle facing up)



15-30 degrees

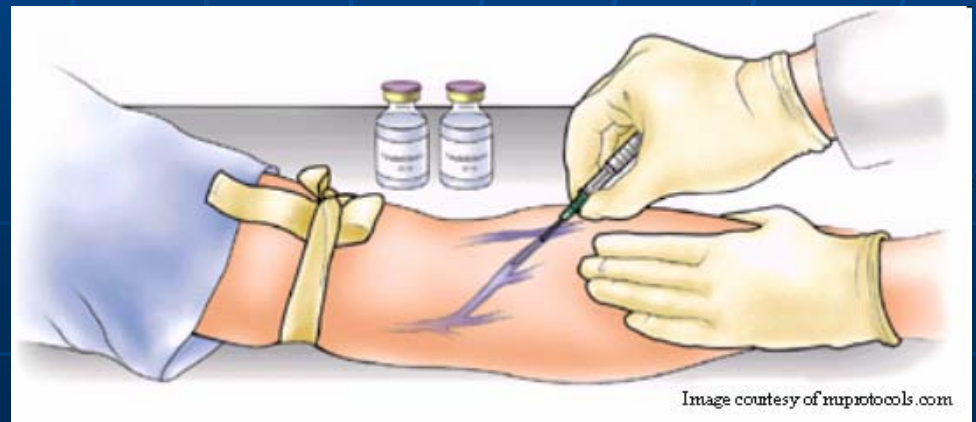
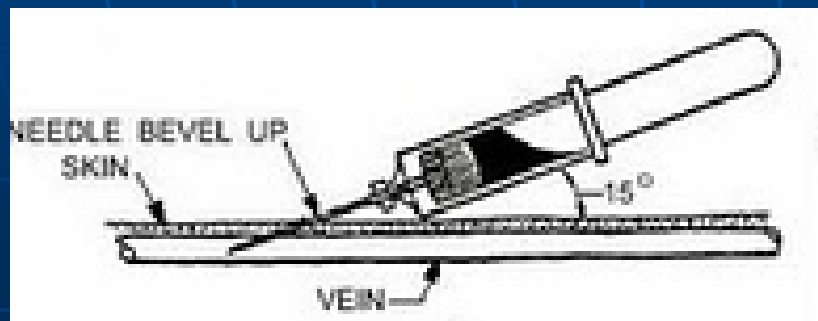
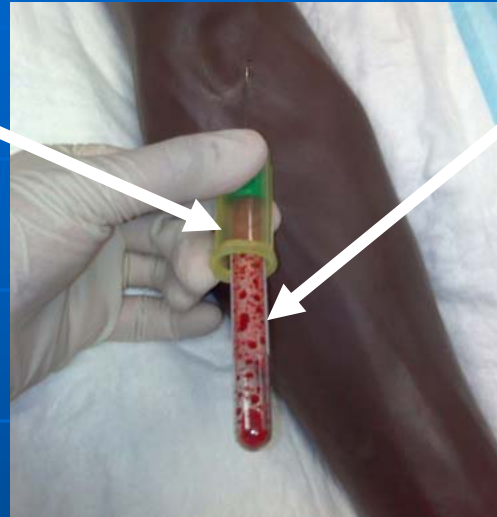
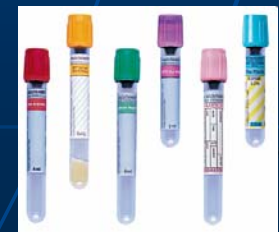
Image courtesy of nuprotocols.com

- Introduce VACUTAINER bottle into the barrel.

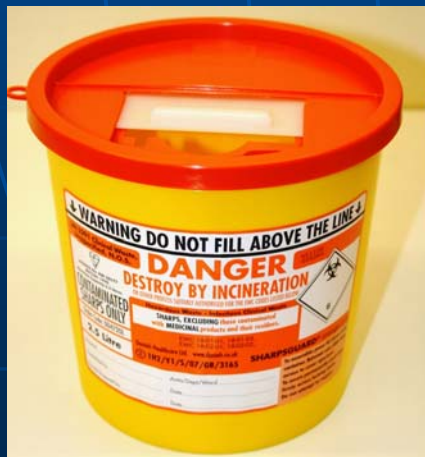

- Allow blood to collect. It will automatically stop filling when full.
- NB: Different colour bottles contain different additives and anti-coagulants etc!



- Amount drawn depends on indication (see request form)
- However normally 5-25 ml is enough.

- FIRST Remove blood BOTTLE
- THEN remove TOURNIQUET
- LASTLY, swiftly remove NEEDLE
- Safely dispose needle to sharps bin immediately –NEVER RESHEATH!!



- Apply gauze to puncture site for 1 minute, with some pressure.
- Remove gloves and wash hands

MANAGEMENT

- Invert blood bottle to ensure blood mixes with the additives in specimen bottle

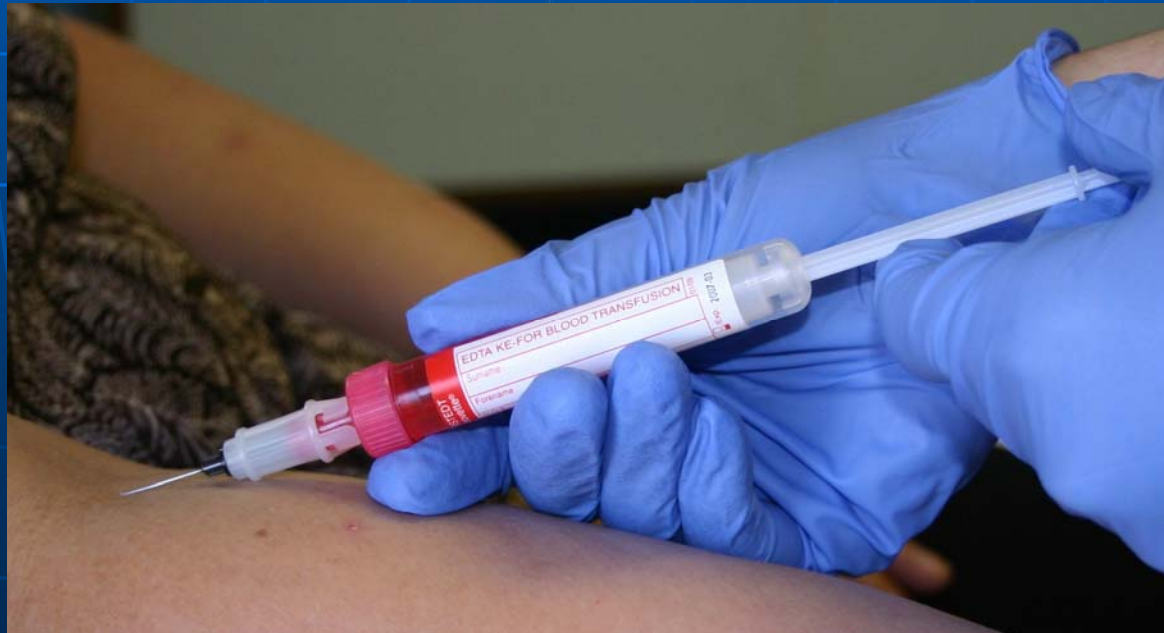Label blood bottle:

- Patient Name
- Identification Number
- Date & Time ...etc
- Document in patient record.
- Send to Pathology lab for analysis.

WASH HANDS

OLD UK / CURRENT CZ METHOD

- *MONOVETTE SARSTEDT VACUUM TUBES*
 - Pull syringe to create vacuum, then slot into needle.
 - When full, snap off handle



To Prevent Hematoma!

- Puncture only the uppermost wall of the vein
- Ensure needle fully penetrates uppermost wall of the vein. (Partial penetration may allow blood to leak)
- Remove tourniquet before removing needle (decreases pressure)
- Use major superficial veins
- Apply pressure to the puncture site

Protect Yourself!

(in addition to what has been mentioned)

- Change gloves between patients.
- Clean up spills with disinfectant.
- Do not break, or recap needle.

(avoid accidental needle puncture or splashing of contents)

Protect Yourself!


(in addition to what has been mentioned)

- In Event of being pricked with needle:
 - Remove and dispose of gloves.
 - Squeeze puncture site to promote bleeding.
 - Wash area well with soap and water.
 - Record the patient's name and ID number.
 - Follow institution's guidelines regarding treatment and follow-up.

NB Prophylactic zidovudine following blood exposure to HIV has shown effectiveness.

SUMMARY

- Tourniquet
- Antiseptic wipe
- Palpate
- Insert
- but be gentle!



- Don't forget Safety and Communication.

VIDEO



http://www.youtube.com/user/vanitagoss#p/a/u/1/9V_5Dgr9ozM

THANKYOU FOR LISTENING

Overview:

INTERPRETATION OF BLOOD RESULTS

(Hematology)



SHAN KESHRI
Clinical Sessions 2010



MASARYK UNIVERSITY
FACULTY OF MEDICINE

We will consider results of
Full / Complete Blood Count
(FBC / CBC)

✓ HAEMATOLOGY

✓ BIOCHEMISTRY

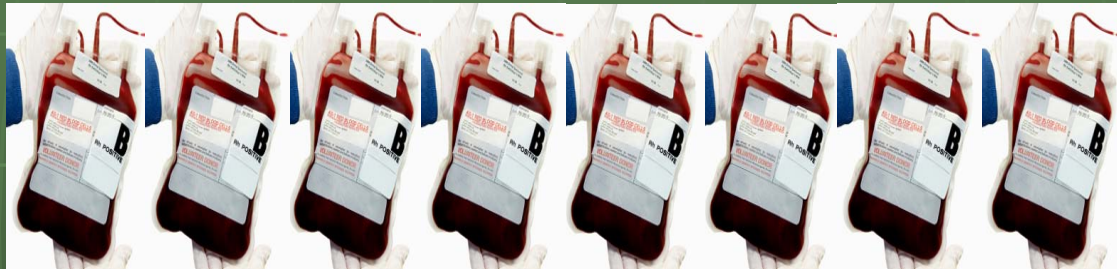✓ LIPIDS

✓ CARDIAC ENZYMES

✓ OTHER

1 Unit Blood = just under 1 pint (450ml)

- Average Body contains 8-10 pints



11 MAIN HAEMATOLOGICAL VALUES

(1) WBC (Leukocyte) COUNT

- FUNCTION: Immune cells, fight infection
Derived from Bone Marrow
- NORMAL : $4.3 - 10.8 \times 10^9 /L$
- HIGH = Leukocytosis
 - Infection?
 - Malignancy? Leukemia?
- LOW = Leucopenia
 - Bone Marrow prob?
 - Chemotherapy treatment?

(2) WBC DIFFERENTIAL COUNT

- 28% Lymphocytes : Fight infection
 - HIGH : Infection?, Leukemia?
 - LOW : Chemo?, Radiation?, Stress?
- Granulocytes:
 - 3% Eosinophils – Allergic reactions
 - Low : Steroids?
 - 65% Neutrophils / 5% Monocytes – Primary response
 - High : Acute inflam?, Malignancy?
 - Low : Chemo?, AI?, BM prob?
- 0.5% Basophils

(3) RBC (erythrocyte) COUNT

- FUNCTION : O₂ Transport. Derived from Bone marrow,
(large bones)
- NORMAL : $4.2 - 5.9 \times 10^9 /L$
- HIGH
 - Low O₂ (hypoxia) ? -> Inc. Erythropoietin
(hormone that stimulates RBC production)
- LOW – Anemia
 - Iron/ Vit. B12 Deficiency? etc.. Refer to Pathophys!
 - Bone Marrow disease
- Most common blood cell / smaller than WBC , larger than platelets / Lifetime approx 120 days.

(4) HEMOGLOBIN (Hb)

- FUNCTION : Protein within RBC, O₂ transport vehicle. Gives blood red colour.
- NORMAL MALE : 13.5 – 16.9 g/dL (M av. 15.2)
- NORMAL FEMALE : 11.5 – 14.8 g/dL (F av. 13.2)

HEMOGLOBIN (Hb) cont.

- LOW : Anemia
 - Blood Loss?
 - Nutritional (iron, b12, folate) def. ?
 - BM prob?
 - Chemotherapy?
 - Kidney failure?
 - Sickle cell anemia? / Thalassemia (hereditary low Hb)
- HIGH :
 - High altitudes?
 - Smoker?
 - Dehydration?

(5) HEMATOCRIT (Hct)

- measured via RBC sedimentation – spin blood so RBC's settle
- WHAT : % RBC volume relative to total blood volume.
- NORMAL MALE : 45 – 52 % (M av. 49%)
- NORMAL FEMALE : 37 – 48 % (F av. 43%)

HEMATOCRIT (Hct)

- LOW :

- Anemia?
- Blood Loss?
- Nutritional Def.?
- BM prob?
- Chemotherapy?
- Sickle cell anemia?

- HIGH :

- Erythropoietin abuse (athlete doping) ?
- High altitude ?
- Smoker ?
- Dehydration ?

(6) MEAN CORPUSCULAR VOLUME (MCV)

- WHAT : Average vol. of RBC
(calculated from Hct / RBC count)
- NORMAL: 80–100 femto-litres
(fraction of one millionth of a litre)

(7) MEAN CORPUSCULAR HEMOGLOBIN (MCH)

- WHAT : Average amount of Hb in RBC
- NORMAL MALE : 45 – 52 % (M av. 49%)
- NORMAL FEMALE : 37 – 48 % (F av. 43%)

(8) MEAN CORPUSCULAR HEMOGLOBIN CONC (MCHC)

- WHAT : Average Hb conc in a given volume of RBC
- NORMAL : 32 – 36 %

(9) RED CELL DISTRIBUTION WIDTH (RDW)

- WHAT : Measurement of variability of RBC size & shape
- NORMAL : 11 – 15
- Higher value – More Variation

(10) PLATELET COUNT

- FUNCTION : Role in clotting, Bleeding control.
- NORMAL 150 – 400 x 10⁹ /L
- LOW = Thrombocytopenia
 - Prolonged bleeding?
 - Drug toxicity?
- HIGH = Thrombocytosis
 - Bone Marrow prob?

(11) MEAN PLATELET VOLUME

- WHAT : Average size of platelets

- PANCYTOPNEA : Low WBC, RBC & Platelets
 - Bone Marrow Probs

Other Haematological ref values

- Vit. B12 : 179 – 1162
- Serum Folate : 2.7 – 34
- Ferritin : 10 – 204 :iron store
- PT Time : 10 – 13 seconds :clotting?
- Fibrinogen : 1.5 – 4.5 g/L
- INR : 2-4 :coagulation therapy
- APTT Activated partial thromboplastin time : 30-40s
 - Test of intrinsic coag. factor deficiency.

SUMMARY

1. WBC : 4.3 - 10.8 x 10⁹ /L
2. WBC DIFFERENTIAL : 28% Lyp/ 3% Eosinophils/ 65% Neutrophils/ 5% Monocytes/ 0.5% Basophils
3. RBC : 4.2 – 5.9 x 10⁹ /L
4. Hb: M : 45 – 52 %, F : 37 – 48 %
5. Hct : M : 45 – 52 % F : 37 – 48 %
6. MCV : 80–100 femto-litres
7. MCH : M : 45 – 52 % F : 37 – 48 %
8. MCHC : 32 – 36 %
9. RDW : 11 – 15
10. PLATELETS : 150 – 400 x 10⁹ /L

FURTHER READING

- Thrombin Time
- APTT
- Coagulation screening tests
- Platelet aggregation tests
- Euglobulin clot lysing time (ELT)
- Thrombotic diseases
- Diseases of Blood and Bone Marrow
- Anaemias, Thallasemia, Splenomegaly, Haemophilia and coagulation disorders
- History taking in relation to Blood disorders (presenting symptoms)

Overview:

INTERPRETATION OF BLOOD RESULTS

(Biochemistry, Lipids,
Enzymes & Other)



SHAN KESHRI & AMIT KAUSHAL

Clinical Sessions 2010



MASARYK UNIVERSITY
FACULTY OF MEDICINE

BIOCHEMICAL VALUES

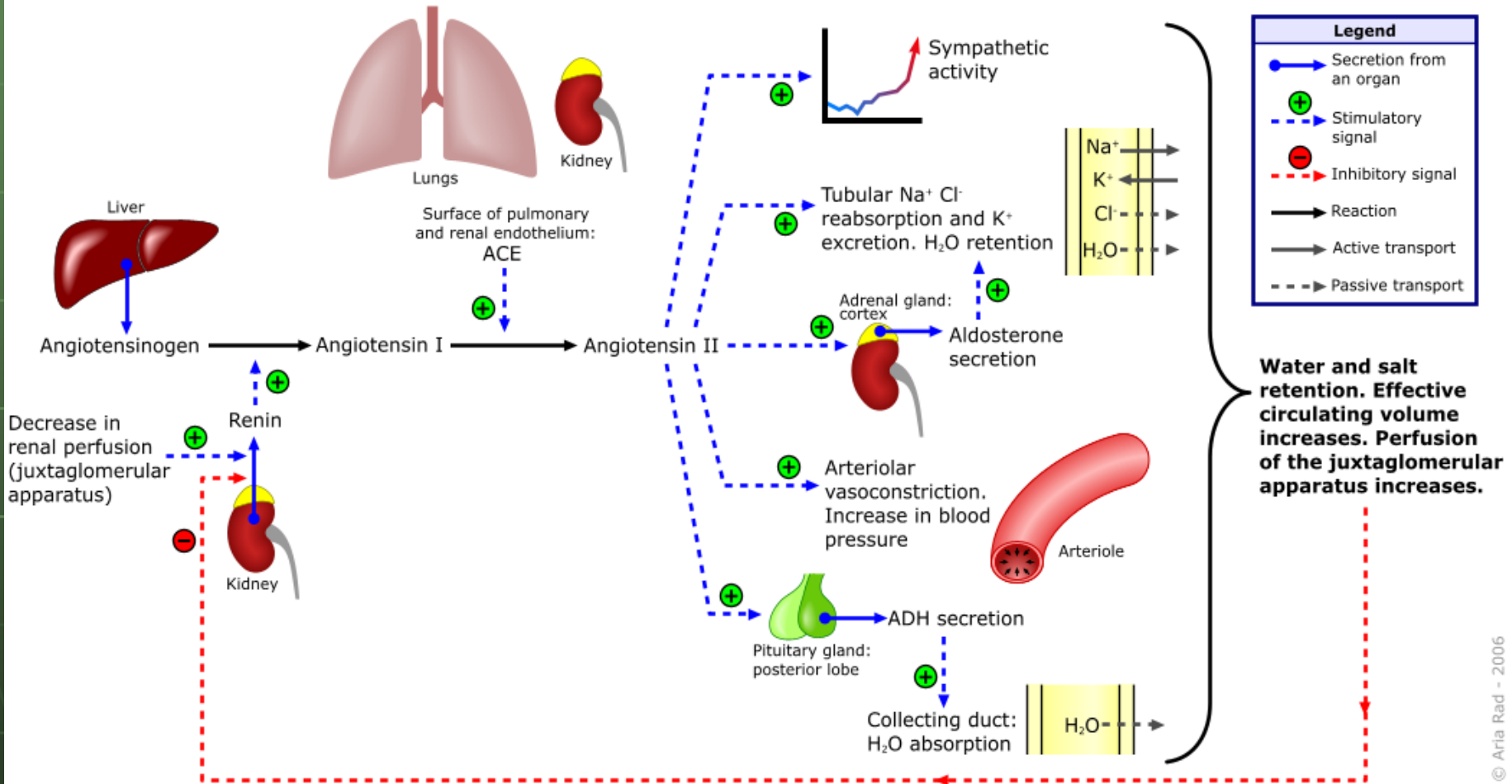
BIOCHEMICAL VALUES

- Sodium : 136 – 145 mmol/L
- Potassium : 3.5 – 5.1 mmol/L
- Urea: M – 3.2 – 7.4 / F – 2.5 – 6.7
- Creatinine : 53 – 115 μ mol/L
- GFR:
- HbA1c : 4.3 – 6.1% : Insulin therapy
- Glucose (random) : 4.0 – 7.8mmol/L
- Fasting Glucose : 3-6mmol/L
- Bilirubin : 0-20 μ mol/L
- ALT: 10-30 (IU/L)
- ALP: 39-128 (IU/L)
- Albumin : 35-50 g/L
- Magnesium : 0.7-1 mmol/L
- Phosphate : 0.74 -1.52 mmol/L
- Calcium : 2.2 - 2.6 mmol/L

Na⁺ (136 – 145 mmol/L)

- Mostly ECF
- Controlled by RAS
- Low Na⁺
 - Signs and Symptoms: Seizures, Cardiac Failure, Dehydration
 - Causes: Vomiting, Diuretics, Addison's Disease, Low ADH, Renal Failure
 - Management: **Correct underlying cause, not the [Na⁺] alone**
 - Acute Situation: Saline infusion and Furosemide

Renin-angiotensin-aldosterone system



- High Na⁺

- Signs and symptoms: Thirst, Hypertension, Dehydration, Fits, Oliguria
- Causes: **H₂O loss** (without Iron loss, eg. Vomiting & Diarrhea) **Diabetes insipidus** (ADH intolerance)
- Management: **H₂O administration**

K^+ 3.5 – 5.1 mmol/L

- Mostly ICF
- Exchanges with H^+ across memb.
- Insulin/Catecholamines stimulate K^+ uptake into cells
- High K^+ :
 - » Signs and Symptoms: Cardiac arrhythmias (sudden death)
 - » ECG: WIDE QRS Complex
 - » Causes: Diuretics, Addison's Disease, Met Acidosis, Burns, ACE Inhibitors
 - » Management: Treat underlying cause
 - » Emergency Treatment: Insulin and Glucose admin. (IV)

- **Low K^+ :**

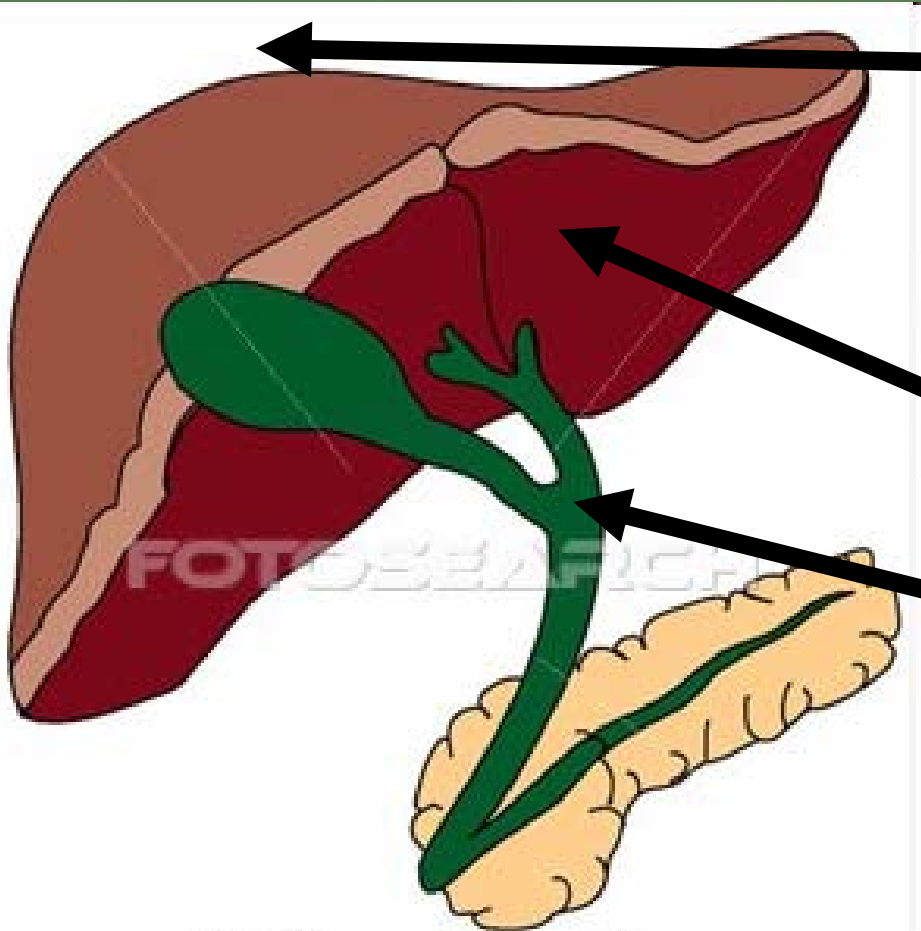
- » S & S: Muscle weakness, cramps
- » ECG: Depressed ST Segment
- » Causes: Diuretics, Conn's Syndrome, Alkalosis. High ACTH production
- » Management: K^+ supplements, IV K^+

Do not give K^+ if oliguric

Glucose: 4.0 – 7.8 mmol/L

- Fasting: 3.0-6.0 mmol/L
- Post eating (pranadial): <10 mmol/L
- High Glucose
 - » Causes: DM Type I & II, Cushing's Syndrome, Pheochromocytoma,
 - » Treatment: Insulin therapy (I) and Diet therapy (II)
 - » Diagnosis: oGTT
- Low Glucose
 - » Causes: E-PLAIN (Exogenous drugs (insulin), Pituitary Insuff., Liver Failure, Addison's, Islet cell tumour, non-pancreatic neoplasm)
 - » Treatment: Oral Glucose/Long acting starch (toast)
 - » Diagnosis: Finger-prick test

Bilirubin : 0-20 $\mu\text{mol/L}$



Pre-hepatic: *High unconjugated bilirubin (hemolysis)*

Intra-hepatic: *Hepatitis, Cirrhosis, Carcinoma*

Post-hepatic: *High conjugated bilirubin (biliary obstruction-stones, pancreatitis)*

ALT: 10-30 (IU/L)
ALP: 39-128 (IU/L)

Increase = marker of a disease

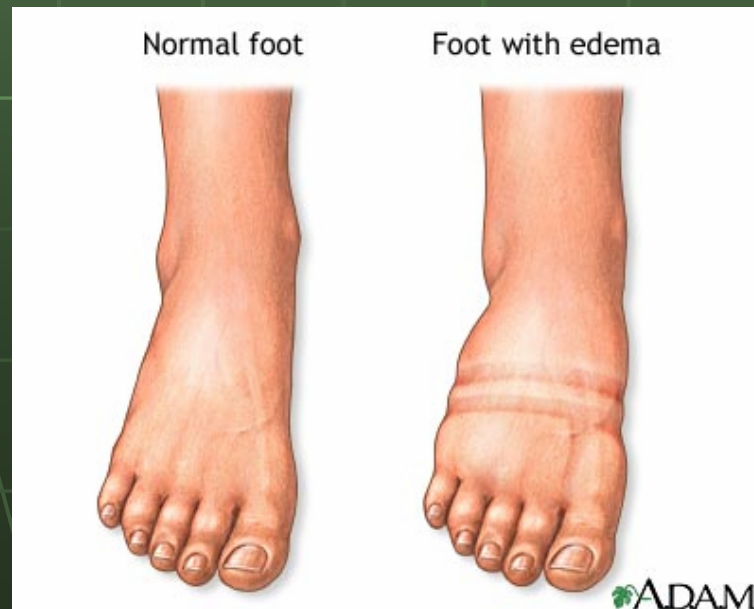
- **High ALP;**
 - Causes: Liver disease (bile duct block), Bone disease (high activity e.g. Paget's disease)
- **High ALT;**
 - Causes: Liver damage (hepatitis), Infectious mononucleosis, Biliary duct obstruction

AST:ALT > 2 = Alcoholic hepatitis

AST:ALT < 1 = Viral hepatitis

Albumin : 35-50 g/L

- **High Albumin;**
 - » Causes: Dehydration
 - » S & S: WIKI it...
- **Low Albumin;**
 - » S & S: Oedema
 - » Causes: Nephrotic Syndrome, Liver disease, Burns



Magnesium : 0.7-1 mmol/L

- 65% in bone & 35% within cells
- High Mg:
 - S & S: Neuromuscular depression and CNS depression
 - Dg: Renal failure ?
- Low Mg:
 - Dg: Diarrhea ? Ketoacidosis ?

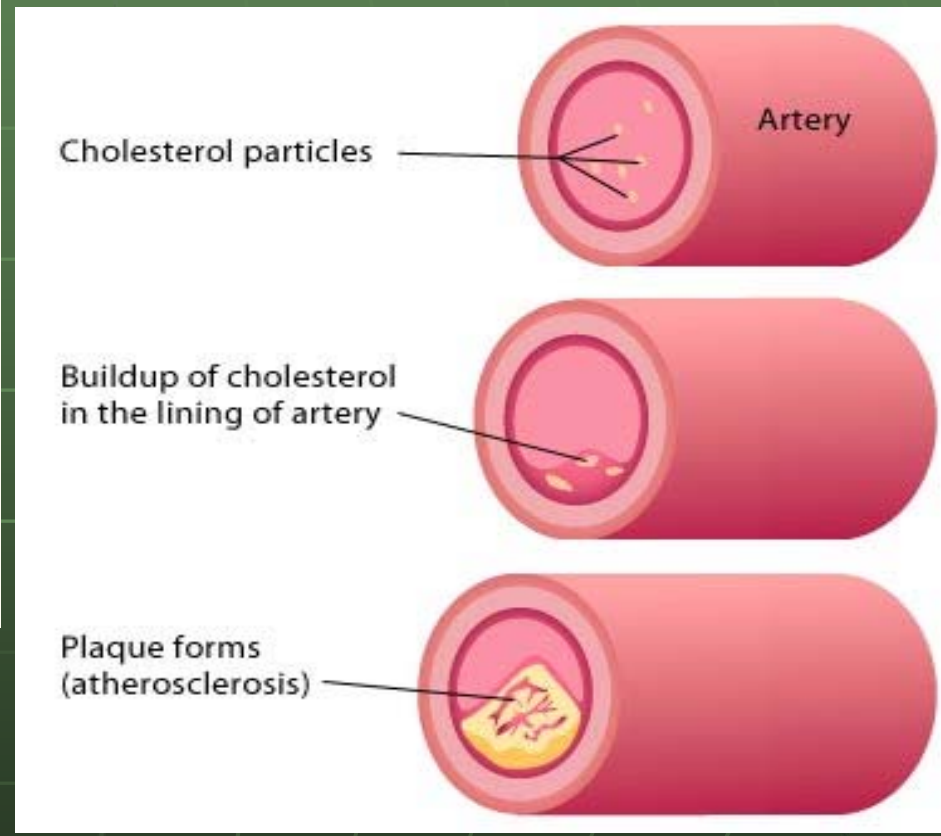
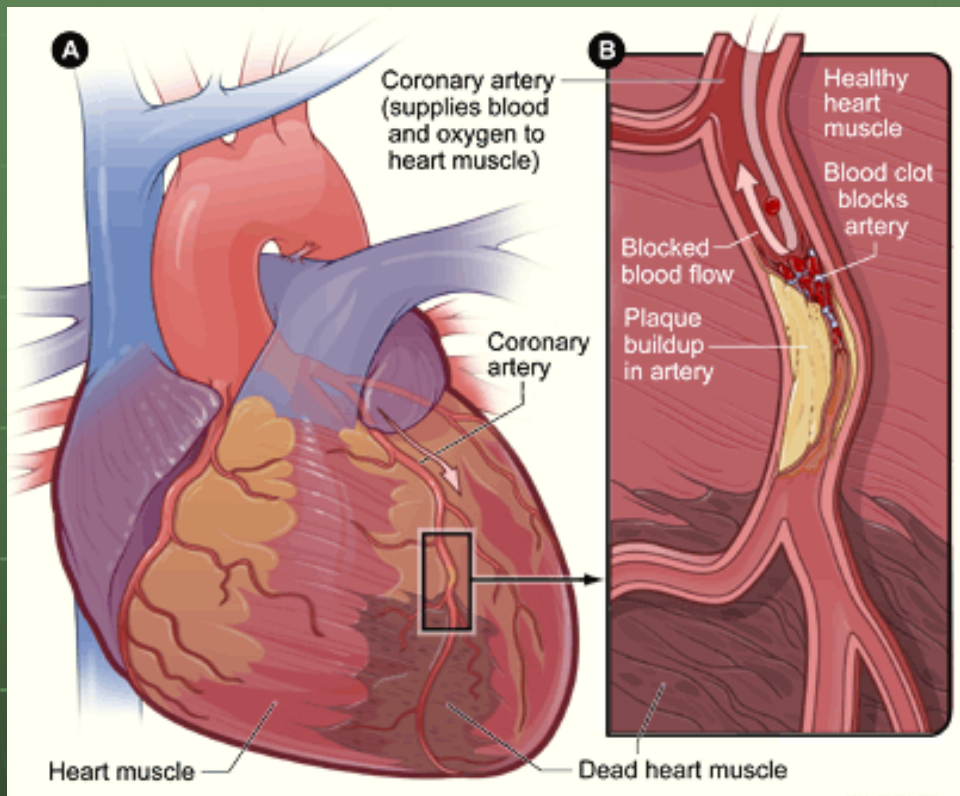
Ca²⁺ : 2.2 - 2.6 mmol/L

- **Control of Ca²⁺:**
 - *PTH,*
 - *Vitamin D (Kidney, GIT, Skin)*
 - *Calcitonin*
- **High Ca²⁺:**
 - *S & S: 'bones stones groans', Abd. pain, Constipation*
 - *Dg: Primary PTH-ism ? Sarcoidosis ?*
 - *Treatment: Diuretics, Bi-phosphates*
- **Low Ca²⁺:**
 - *S & S: Tetani, Depression, Facial muscle twitch, Chvostek sign*
 - *Dg: Chronic renal failure ? Thyroid surgery ? Low Vitamin D*
 - *Treatment: Calcium admin.*

LIPID VALUES

LIPID VALUES

- Cholesterol : <5 mmol/L
- Triglyceride : <2 mmol/L
- HDL : >1 mmol/L (good cholesterol)
- LDL : <3 mmol/L
 - *HIGH LDL and LOW HDL = Increased risk of CHD*
 - *High cholesterol can lead to Atherosclerosis*
 - *Management: Lifestyle changes, Statins e.g. SIMVASTATIN*



CARDIAC ENZYMES

CARDIAC ENZYMES

- CK-MB
- Troponin T
- Myoglobin
 - *Markers of MI / Heart disease?*

OTHER VALUES

OTHER VALUES

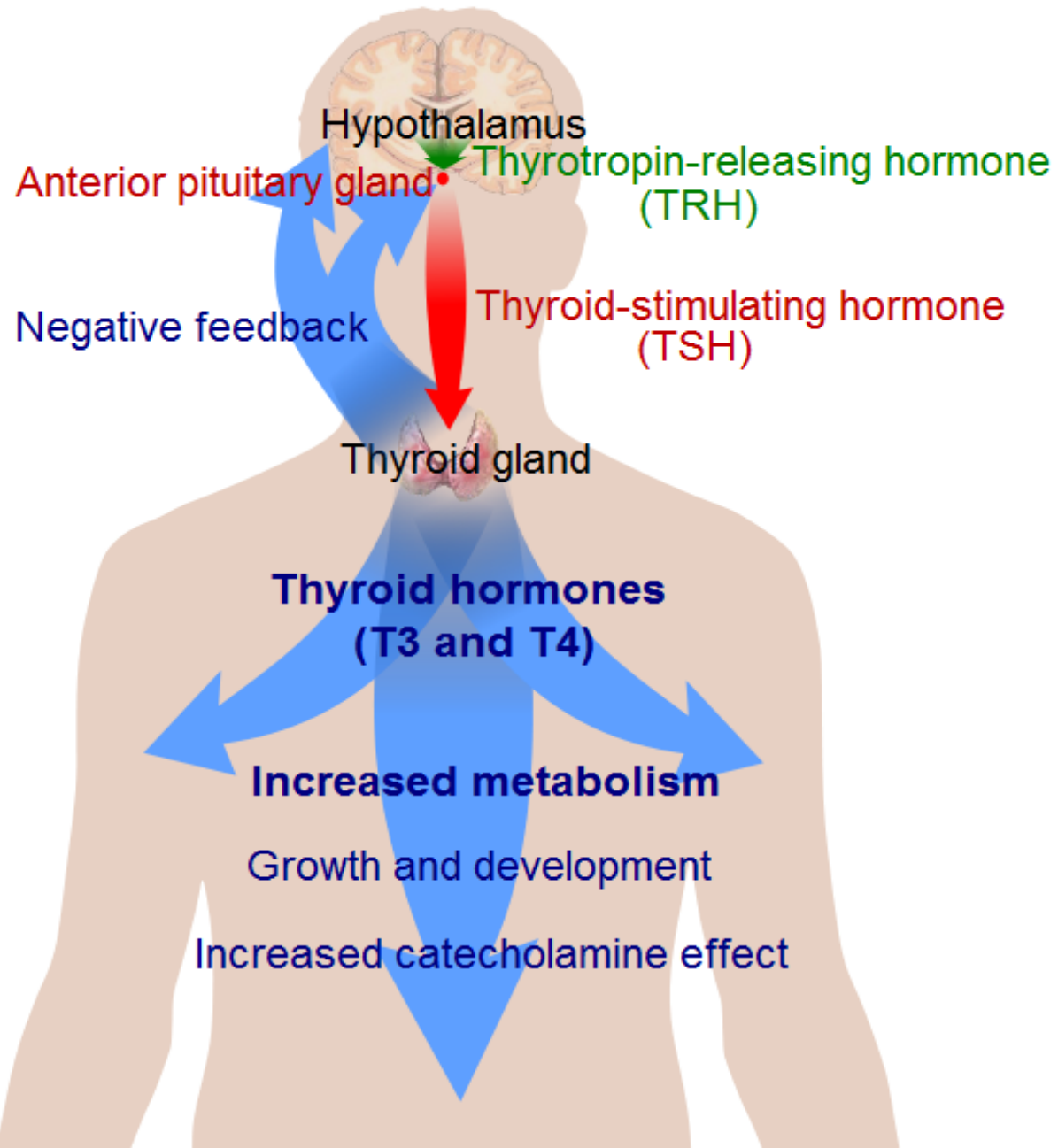
■ CRP

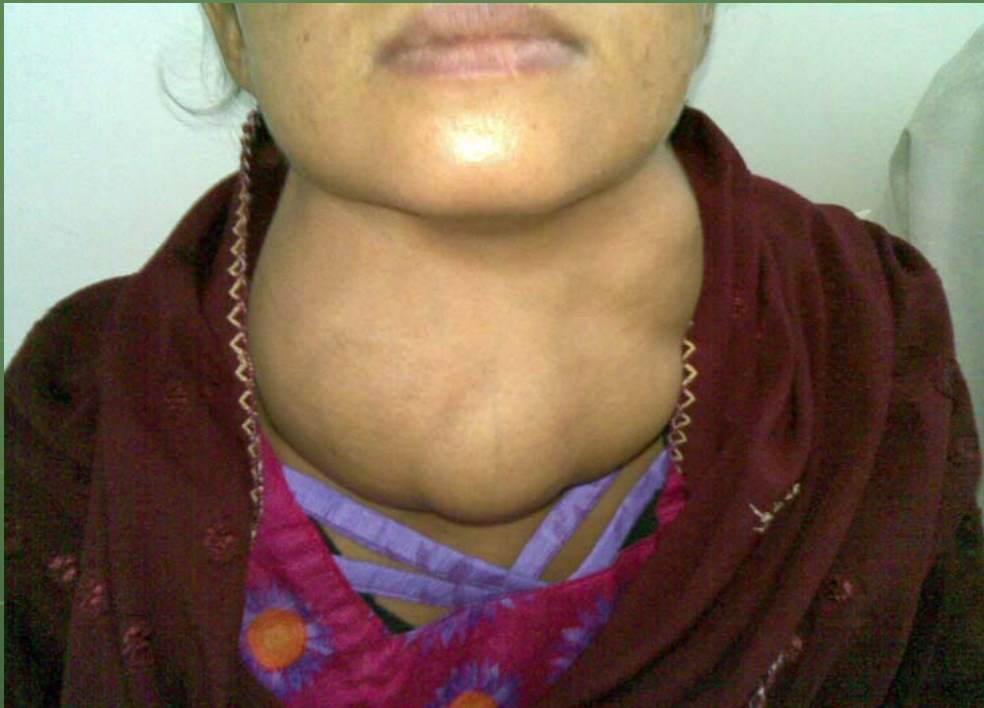- Markers of inflammation associated with acute phase response

■ TSH

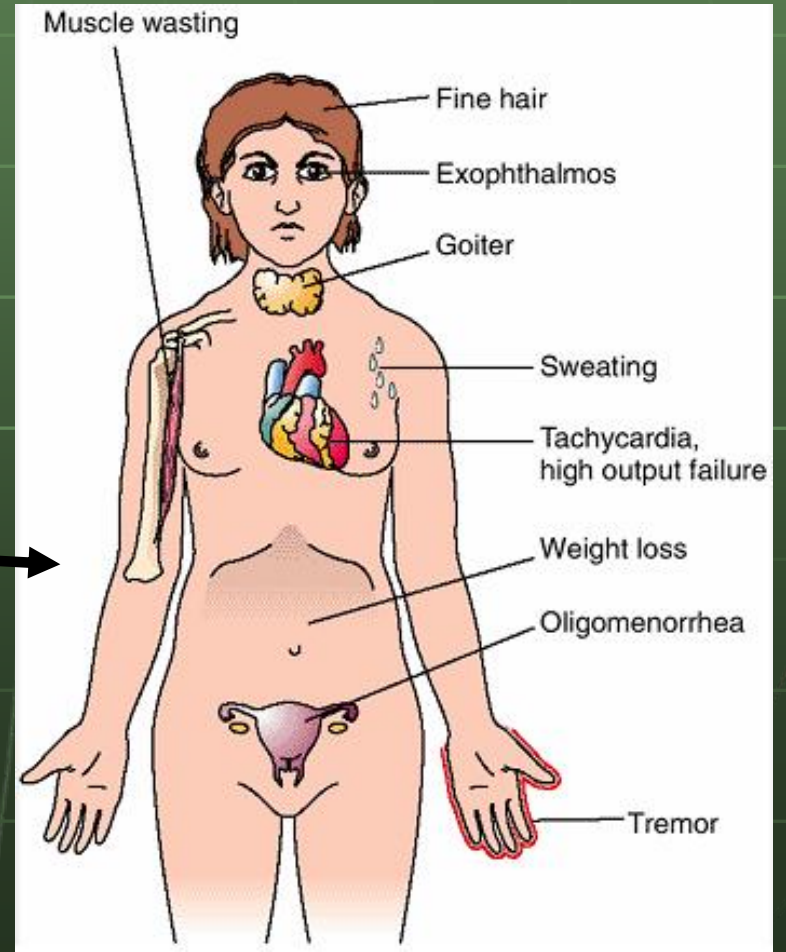
- Hyperthyroidism (Graves disease, Thyrotoxicosis)
 - S & S: Sweating, Goitres
- Hypothyroidism (Hashimoto's disease, Iodine deficiency)
 - S & S: Constipation, Mental retardation in Kids, Tiredness

Thyroid system





Graves Disease



THANKYOU FOR LISTENING

URINE COLLECTION



SHAN KESHRI
Clinical Sessions 2010



MASARYK UNIVERSITY
FACULTY OF MEDICINE

Rapid & Cost effective

INDICATIONS

■ Diagnose / Screen:

- Urinary Tract Infection?
- Presenting urinary symptoms : urgency?, frequency? etc
- Kidney Stones?
- Kidney disease? e.g. proteinuria in nephrosis?
- Hydration status of patient with fluid loss
- Monitor disease progressions (DM :glycos & keto-uria, HT)
- Early detection of substances or abnormalities of body (endo, met)
BEFORE BLOOD COMPONENTS AFFECTED!!

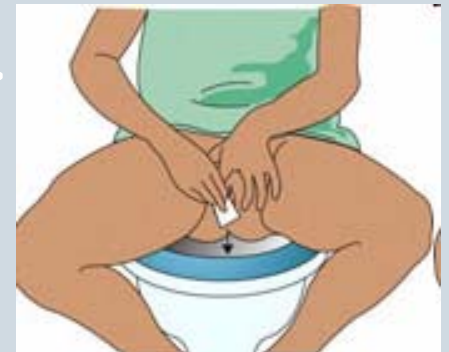PROCEDURE

'Clean catch, Mid-Stream Specimen'

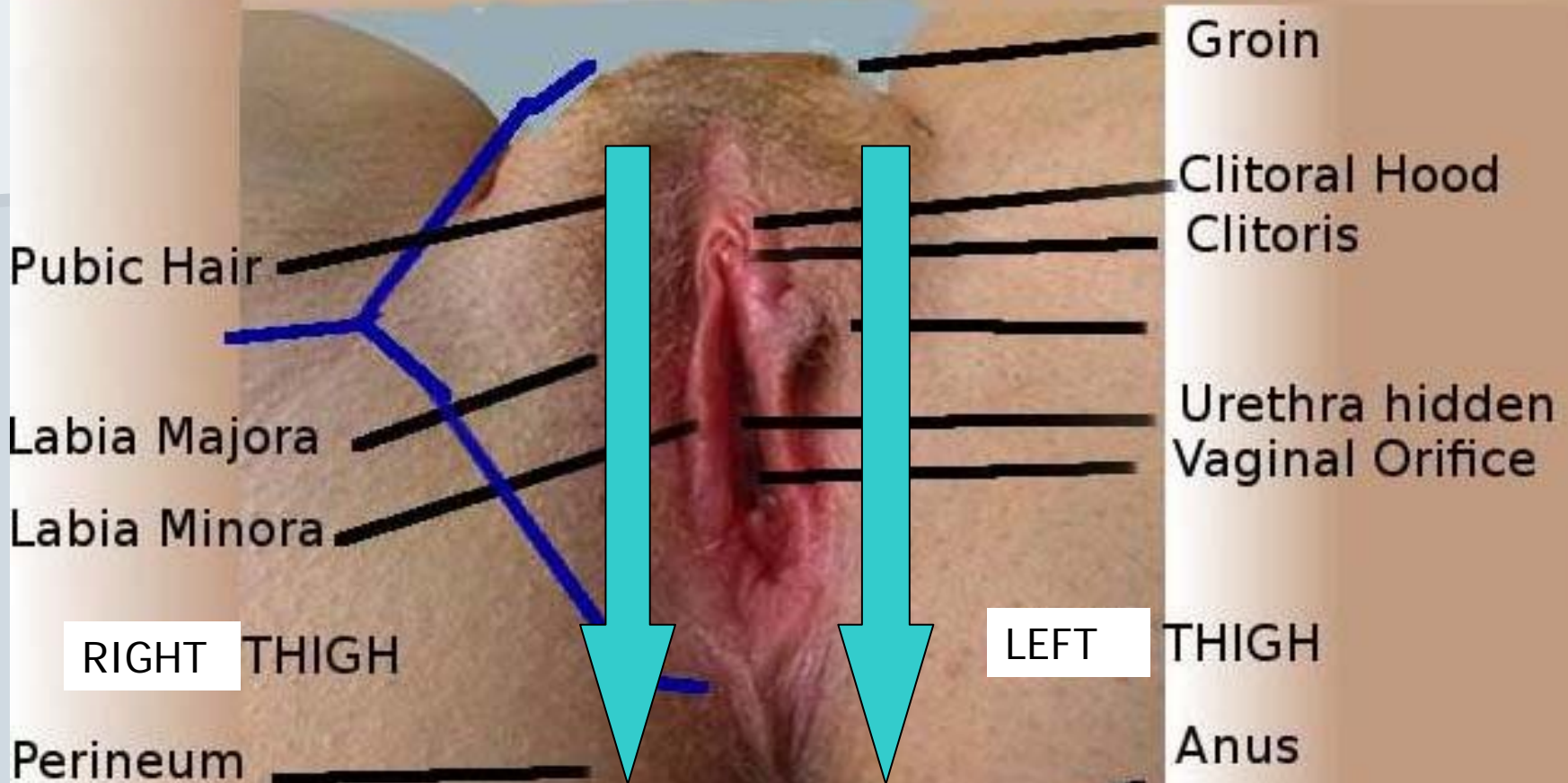
- Patient will do it themselves, so you must explain to them properly what to do!

Clean Catch

- Wipe external urethral opening clean with cleansing wipe.
- DON'T USE ALCOHOLIC WIPE – they irritate!
- WOMEN : Then spread labia of external genitalia, and wipe back to front.

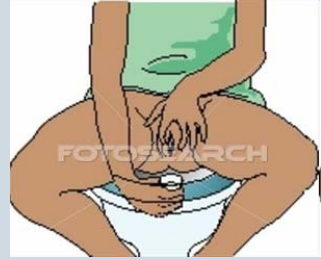

FEMALE EXTERNAL GENITALS

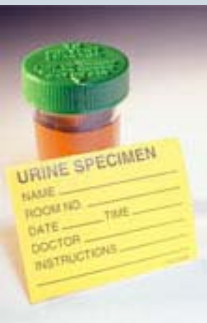

FRONT to BACK

Mid-Stream Collection

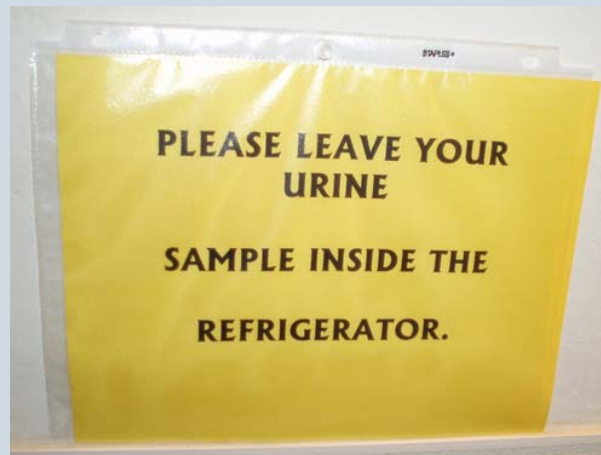

- Start urinating initial stream into the toilet (flush contaminants from outer urethra).
- Stop, then restart urinating, approx 10-15 ml in the provided sterile specimen container (till full), aka Midstream.
- Remaining urine can be voided into toilet.
- Bottle returned to requesting physician (check labeling)



Management

- If immediate analysis not possible, sample should be refrigerated.

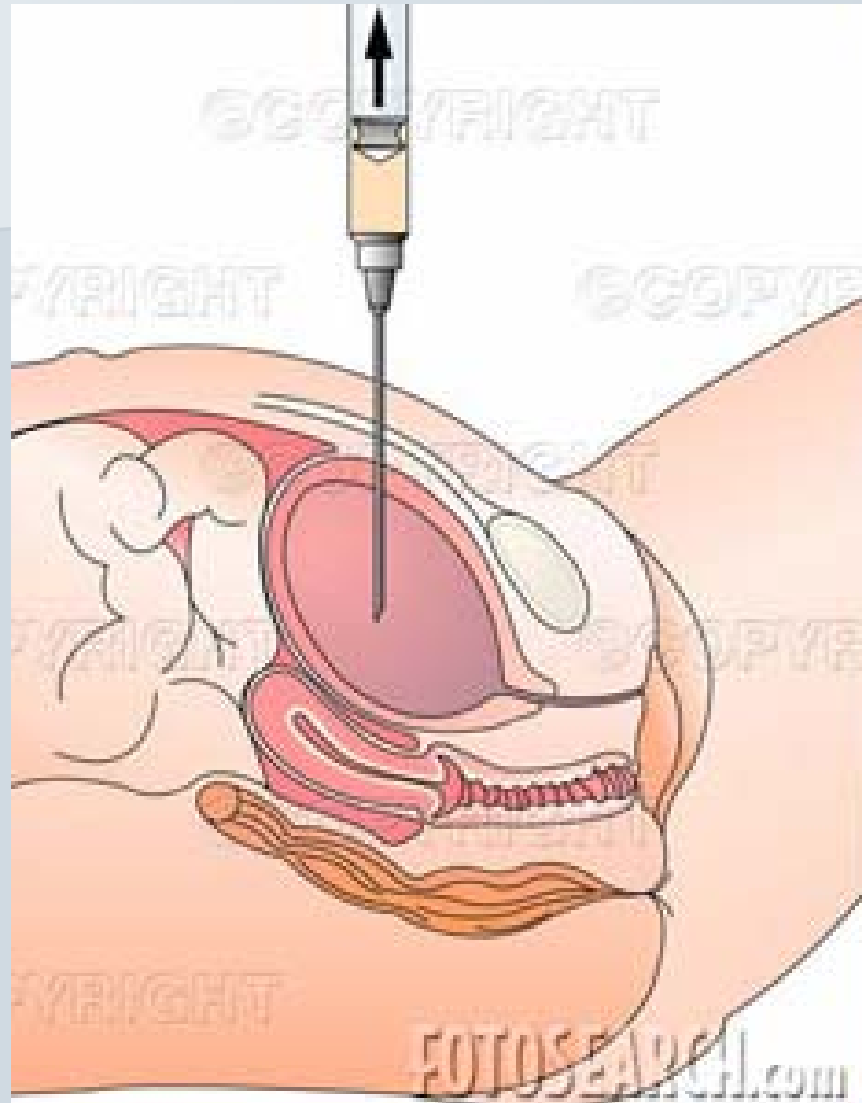


ALTERNATIVES

- Patient with urinary (Foley) catheter: analyse the urine in the bag



- Children not toilet trained : Attach collection bag to external genital region.
- Comatose/ confused patient : Urine collection by catheter
- Supra-pubic trans-abdominal needle for aspiration of urinary bladder (purest specimen)

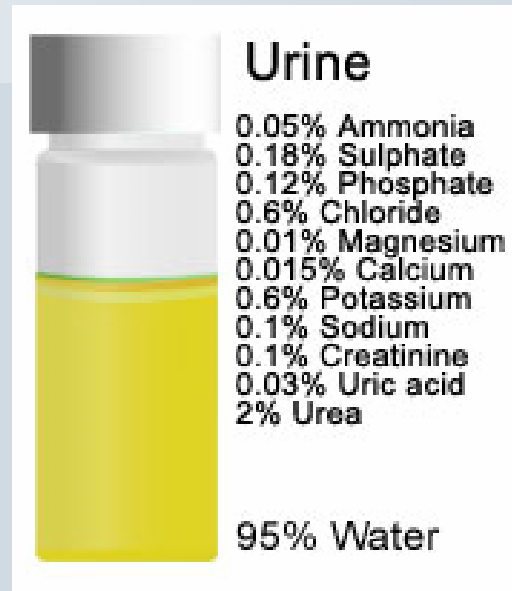


NOTES

- Female specimens may contain vaginal components e.g. trichomonads, yeast, RBC during menstruation
- Early morning sample preferred; before ingestion of any fluid is usually hypertonic and reflects ability of the kidney to concentrate urine during dehydration which occurs overnight.
- If all fluid ingestion has been avoided since 6 p.m. the previous day, the specific gravity usually exceeds 1.022 in healthy individuals.



URINALYSIS (UA)



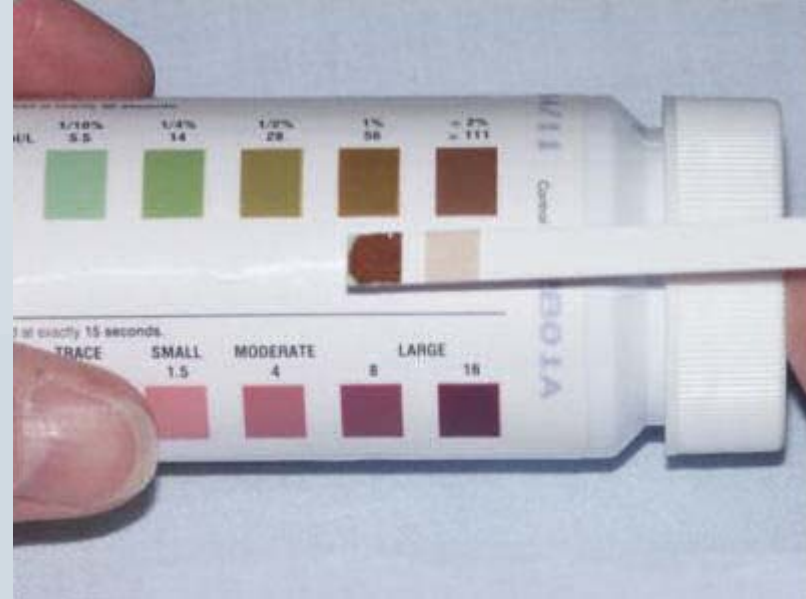
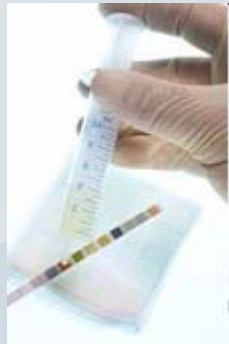SHAN KESHRI

Clinical Sessions 2010



MASARYK UNIVERSITY
FACULTY OF MEDICINE

MACROSCOPIC ANALYSIS



DIPSTICK ANALYSIS

- Leukocytes
- Nitrite
- Urobilinogen
- Protein
- pH
- Blood
- Specific Gravity
- Ketone
- Bilirubin
- Glucose
- Ascorbic Acid



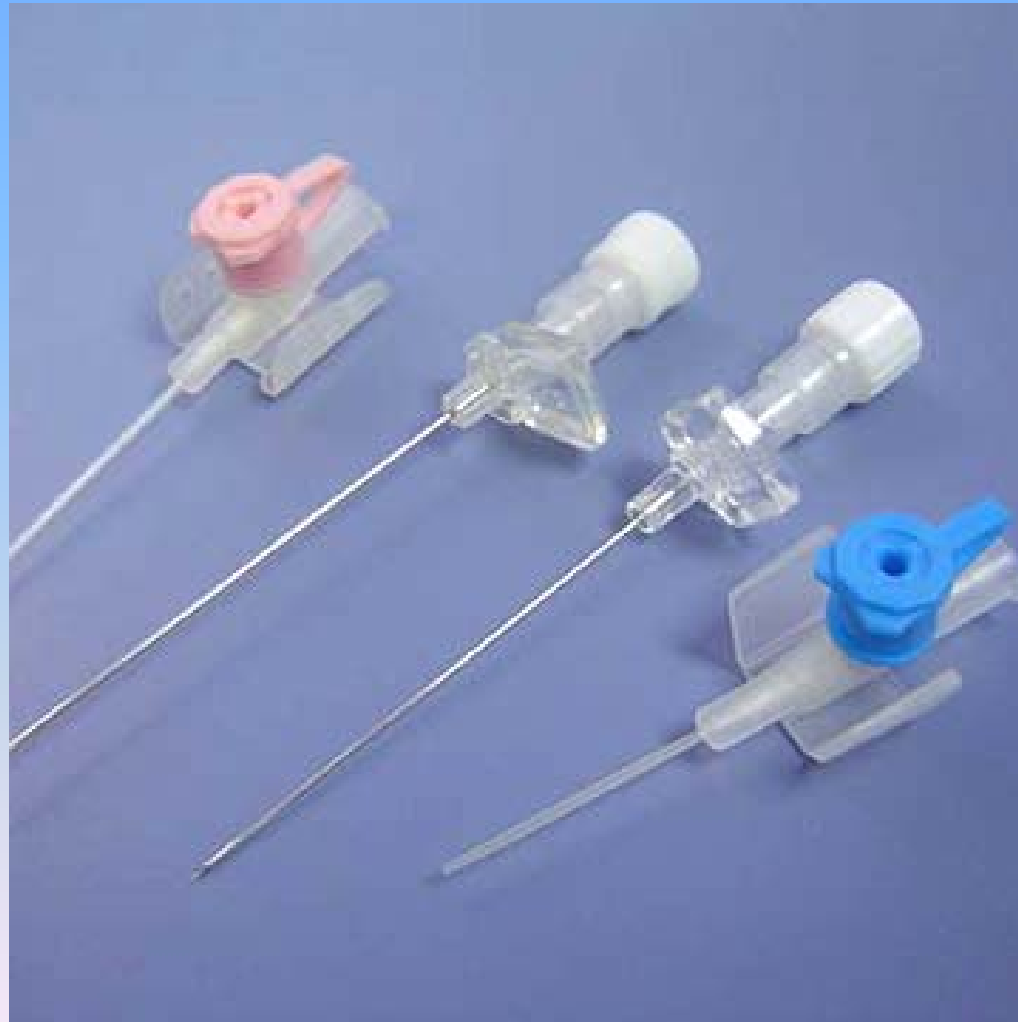THANKYOU FOR LISTENING

- http://www.emedicinehealth.com/urinalysis/page4_em.htm
- Colour change of dipstick?
- [http://en.wikipedia.org/wiki/Urinalysis#Medical urinalysis](http://en.wikipedia.org/wiki/Urinalysis#Medical_urinalysis)
- <http://library.med.utah.edu/WebPath/TUTORIAL/URINE/URINE.html>

- http://www.emedicinehealth.com/urinalysis/page3_em.htm
- http://www.youtube.com/watch?v=U1_TviVuls really good vid
- <http://www.youtube.com/watch?v=8h3GWjeT2eo&feature=related>
- <http://www.patient.co.uk/doctor/Urine-Dipstick-Analysis.htm>
- <http://archive.student.bmj.com/issues/09/02/education/68.php>
- <http://www.ucdmc.ucdavis.edu/cne/documents/competencies/poct/Urine%20Dipstick.pdf>
- Odour, blood etc

INTRAVENOUS CANNULAS

Bhavin Doshi



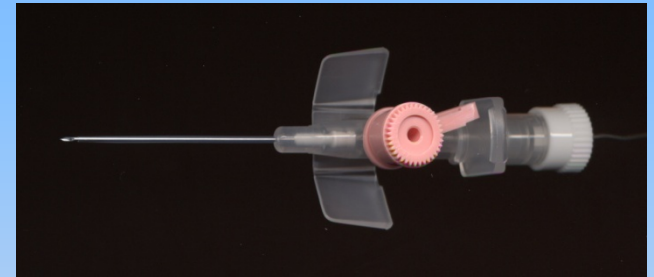
Aims & Objectives

This presentation aims to present students with an overview of cannulation, the knowledge and skills required to undertake the procedure safely and competently, how to recognise, prevent and manage associated complications.

Introduction

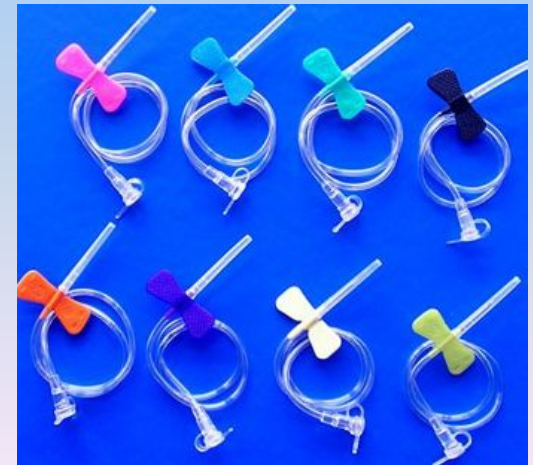Peripheral cannulation provides access for the purpose of IV hydration or feeding and the administration of medications.

A **Cannula** is a flexible tube, usually **containing a needle** (stylet), which can be inserted into a body cavity, duct, or vessel in order to **drain fluid or administer a substance** such as medications.



A **Catheter** is a flexible tube that is inserted into a body cavity in order to **withdraw or introduce fluids**.

Peripheral cannulation is a common procedure with more than 24 million cannulae of all designs sold in the U.K.



Selection of a vein

Palpation of the vein should be performed before every cannulation to determine veins from arteries (**arteries pulsate and veins do not**), and also to **locate valves**.

Palpation is achieved by placing one or two fingers over the vein and pressing lightly; then releasing the pressure to assess the vein's elasticity and rebound filling.

The ideal vein is **bouncy, refills when depressed**, is **straight** and **free of valves**.

Must choose a suitable vein for the intended purpose; (**rate of flow, type of infusion, duration of therapy, avoid joints** since it will lead to **mechanical phlebitis** or **tissuing** of cannula. And also restricts the patient's movement.

Factors that may affect cannulation

- **Age of the patient** – small and very fragile veins in young and elderly
- **Nutritional status** – friable veins in those who are malnourished, deep difficult veins in obese patients
- **Medical history** – E.g. **Amputations, lymphoedema, cerebrovascular accident, mastectomy** (the arm on the side of the unaffected breast should be used), some **surgical procedures** or the presence of a **haemodialysis shunt**
- **Prescribed medications** such as **anticoagulants** or **long-term corticosteroids**, which make the veins more fragile and prone to bruising
- **The physical condition of the patient**, for example venous access is more difficult if the patient is **dehydrated**, in **shock** or **hypothermic**
- **Skill of the practitioner**

Improving venous access

- Use a **tourniquet** – apply **7-8 cm above the chosen site**, must be **tight enough to impede venous return but not affect atrial flow**
- **Opening and closing the fist** along with **gravity** both improve vasodilation
- **Gentle tapping** or **stroking** may improve vasodilation – but **can be painful**
- **Apply heat** – such as **warm pack**, or **soaking limb in a bowl of warm water**

Which vein?

For **prolonged courses of therapy**, it is recommended, although not always practical, to **start distally and cannulate at proximal points** since sites can be maintained for longer

Cephalic vein – takes a large gauge cannula and provides a natural splint, but is at a joint

Basilic vein – awkward for cannulation due to location, but is quite large

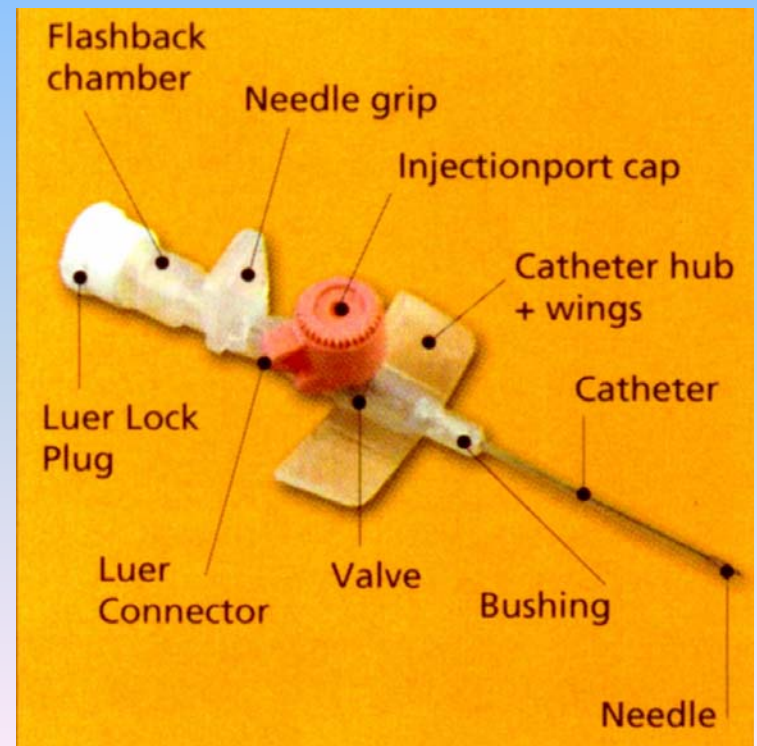
Dorsal venous network – easily accessible, visualised and palpated – contraindicated in older patients due to loss of turgor, so veins are not stable

Choosing a cannula

- Use “**over the needle**” type of cannula – where cannula is mounted on the needle – available in various **gauges (16–24g)**, **lengths (25-45mm)**, **compositions** and **designs**. Also different materials have **differing flow rates**.
- **Smallest gauge should be used** to minimise damage to the vessel intima and ensure adequate blood flow around the cannula (reduce risk of phlebitis).

- **Cannula comprises of different components**

Some have **wings** to help fix it to the skin, others have **ports** on top to enable the administration of medications without interfering with a continuous infusion. **Safety cannulae** are liable to reduce the risk of needlestick injury (have a safety button).



Preparation of the environment, the practitioner and the patient

- There should be adequate **lighting** and the room should be **warm** enough to encourage vasodilation
- **Practitioner should be in a comfortable position** (alter height of bed or chair)
- Wear **properly fitting gloves** to protect from contamination by blood spillage
- **Anxiety** in patient due to needle phobia or previous bad experience could present
- Provision of **clear and comprehensive information** should alleviate anxiety
- A **careful explanation** should be provided of the procedures and **patient consent** must be gained (**Verbal consent is usually acceptable**)
- **Patient should be in a comfortable position**. Placing arm on a **pillow** or **rolled towel** provides support and a firm, flat surface

Pain Relief

Non-pharmacological methods

- **Relaxation**
- **Distraction** – E.g. Coughing at time of insertion of needle

Pharmacological methods

- **Local anaesthetics** in the form of **cream** or **gel** or **intra-dermal injection** has been advocated to reduce pain, and anxiety in children and selected adults
- Local anaesthetic is also recommended **if the cannula is larger than 18g**, when a sensitive site is used or at the **patient's request**.

Skin preparation

- **It is important to clean the skin properly** – wash with soap and water to remove visible dirt (removes transient flora)
- **Use anti septic solution** - E.g. Chlorhexidine (2%) or alcohol (70%) for 30-60s
- **Allow skin to dry** – ensures disinfection and avoids stinging from needle
- **Do not touch or repalpate the skin** – avoids recontamination
- **Hair removal is not necessary** – but can be trimmed with scissors or clippers

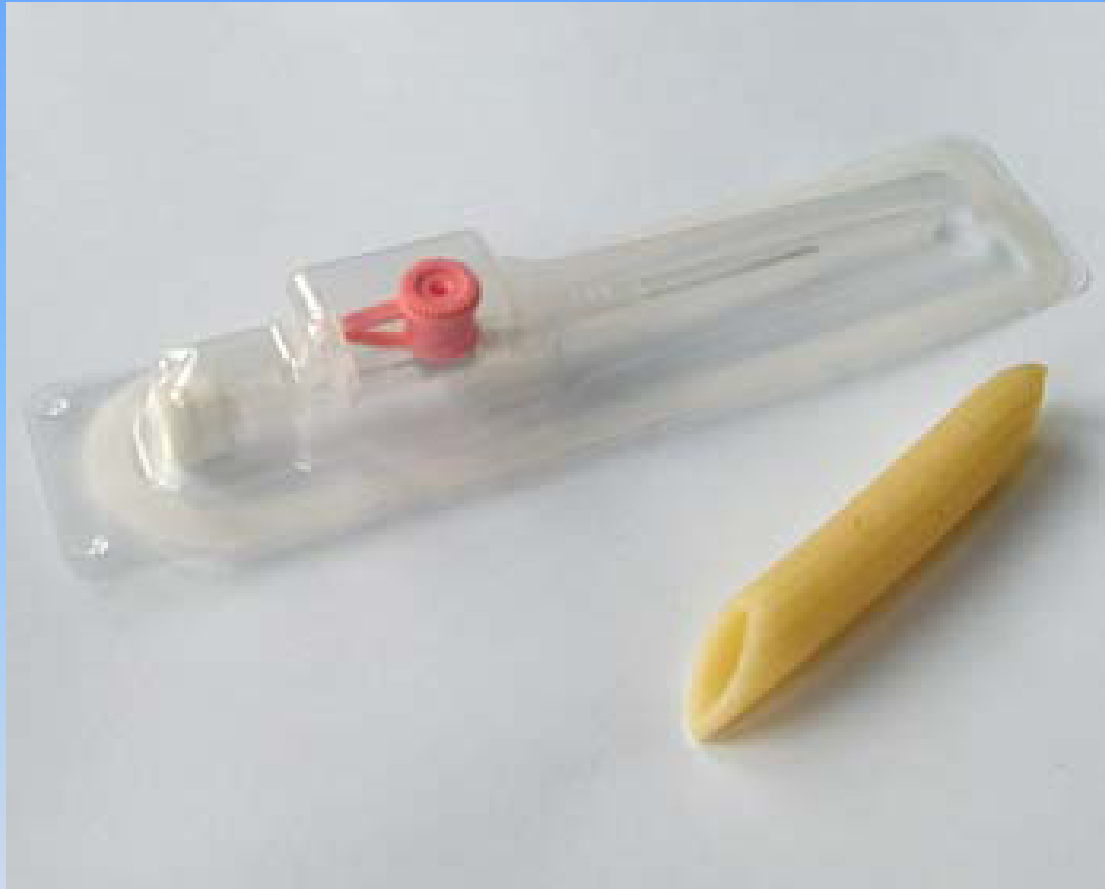The procedure

- **Stabilisation of the vein** – apply traction with non-dominant hand to the side of the insertion site or below it, using thumb and forefinger
- Stabilisation of vein should be maintained throughout the procedure until cannula is sited
- **Needle enters skin with bevel side up**, so **sharpest side penetrates skin first**
- **Angle needle enters** varies depending on type of device used and the depth of the vein in the subcutaneous tissue, from **10 to 45 degrees**
- **Once entry into the vein is achieved, angle is reduced** to prevent puncturing posterior wall of the vein
- When blood appears into chamber, it is known as “**flashback**”, indicating initial entry into the vein is successful
- Followed by a “**giving way**” sensation felt by the practitioner – overcoming of the resistance of the vessel wall


The procedure...continued

- Flashback may stop if posterior wall is pierced, or may slow if gauge of cannula is small or patient is hypotensive
- Cannula should be **advanced gently and smoothly into the vein**. The **one-handed technique** – the same hand that performs cannulation also withdraws the stylet and advances the cannula into the vein
- The **one-step technique** – where the practitioner can slide the cannula off the stylet in one movement once the cannula has entered the vein
- The **two-handed technique** – where the practitioner performs the cannulation with one hand but releases the skin traction to advance the cannula off the stylet, which **can result in puncturing of the posterior wall of the vein**
- If cannulation is unsuccessful the **stylet should never be reintroduced** as this could result in catheter fragmentation and embolism. The device should only be used once.
- Only **two attempts** should be made at cannulation before **passing the patient onto a more experienced practitioner**

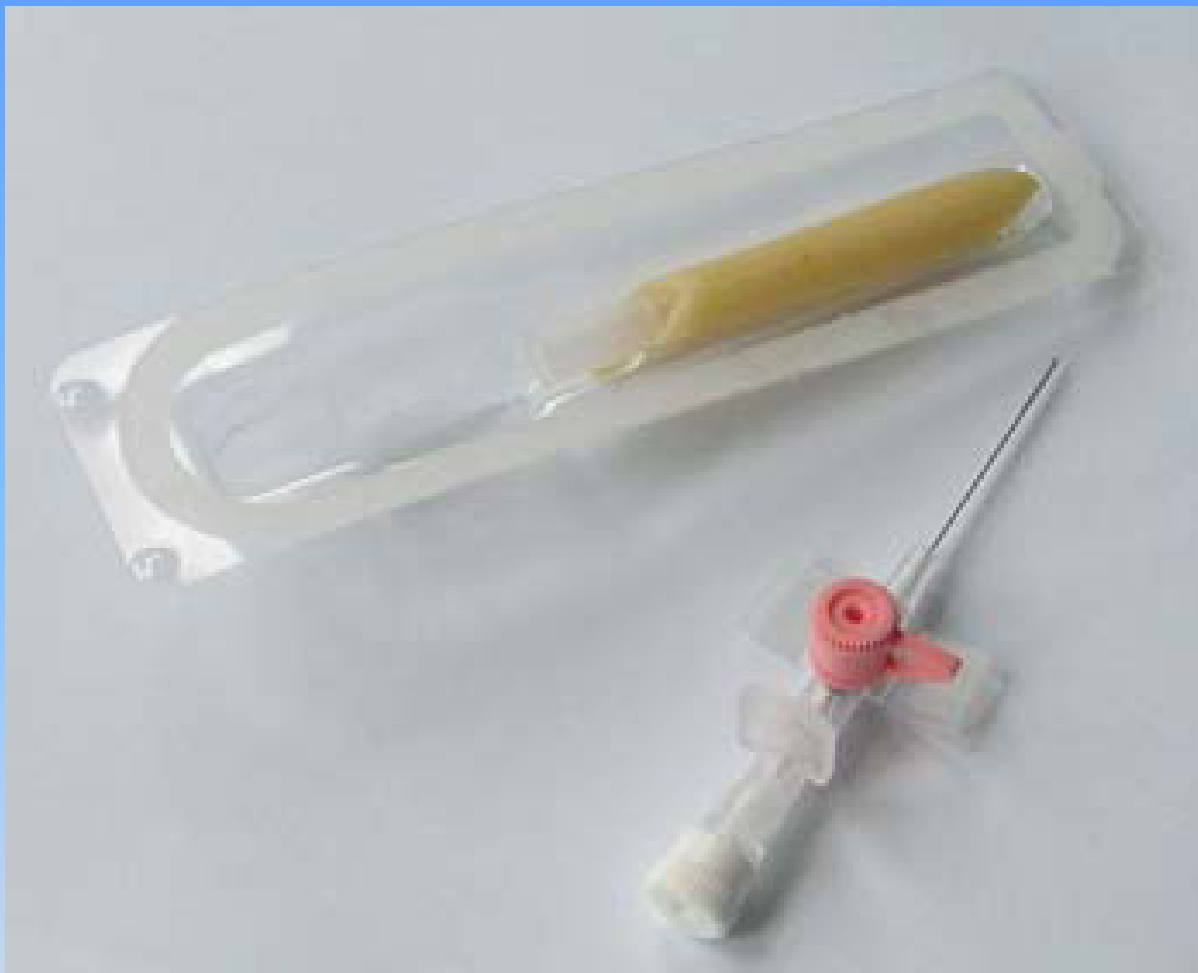Step – by – step



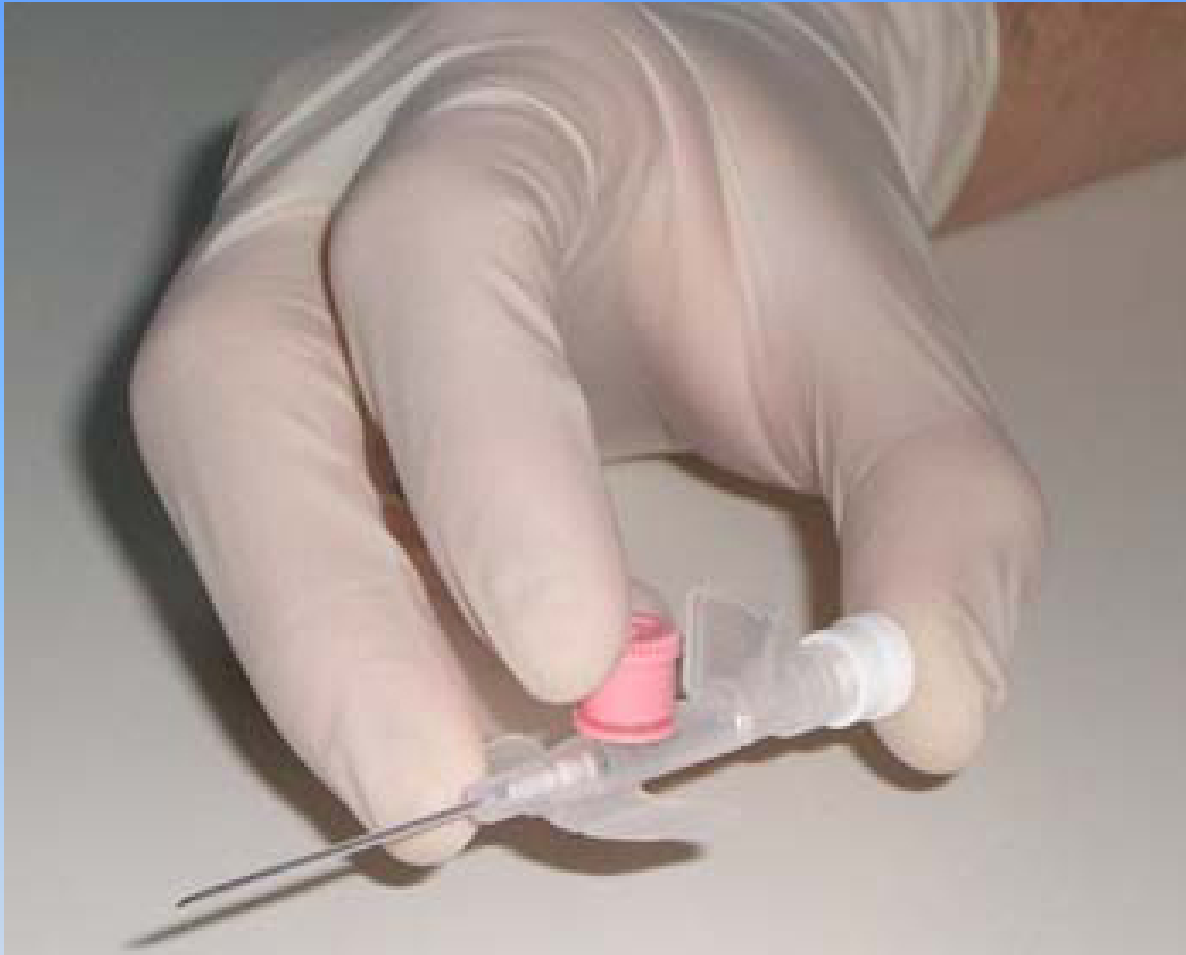Step 1: Use a BD Venflon and a cooked piece of penne pasta. Using a BD Venflon is essential because the depth of its plastic casing means that the pasta sits nicely at an accessible height for cannulation (other brands often have deeper casings).



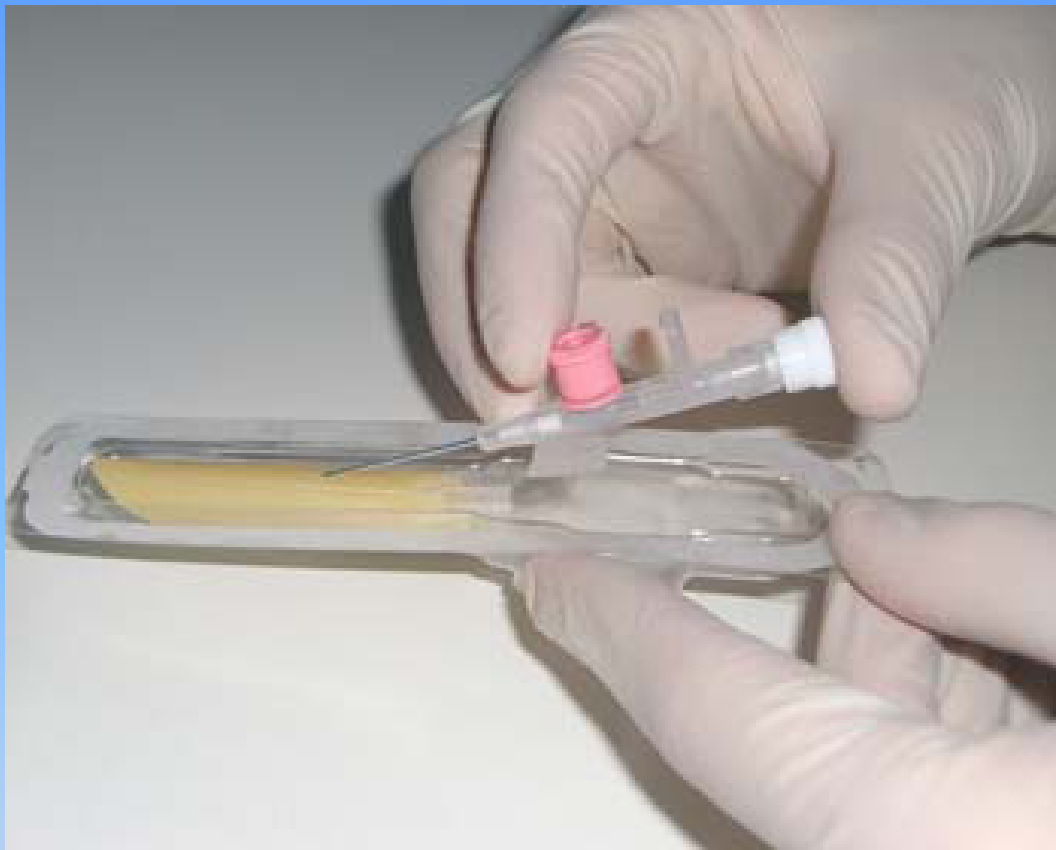Step 2: Open the cannula, unfold its wings, and remove the plastic sheath that covers the needle. Insert the sheath through the pasta to stent it. The pasta simulates the skin, and the tapering end of the sheath creates a space to cannulate, simulating the vein



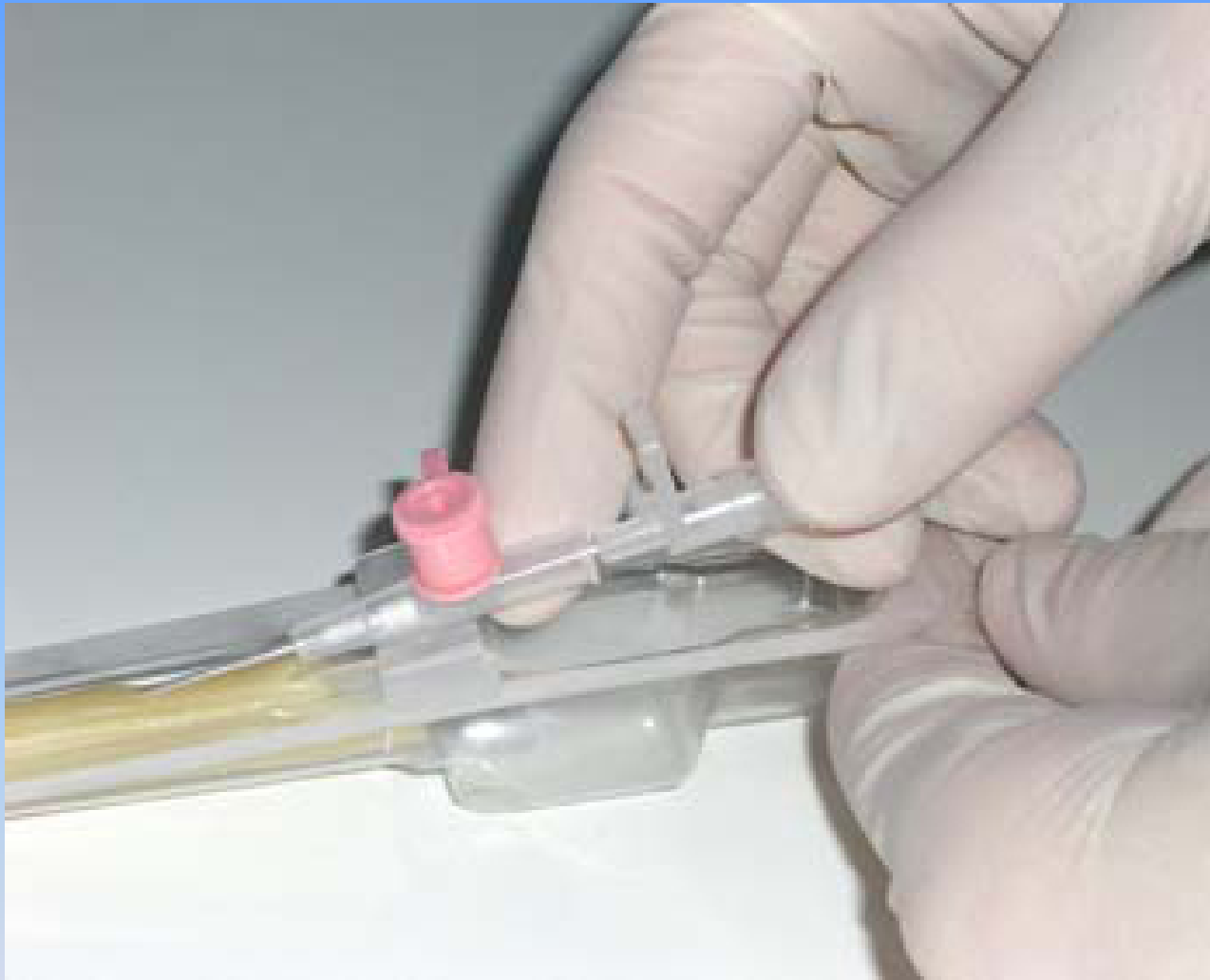Step 3: Put the stented pasta into the cannula box ready for practice. In a real scenario remember to wear gloves, clean the overlying skin, and locate a sharps box before starting. Cannulation is easier if you first try to increase venous filling. It helps to use a tourniquet; to lower the arm below the level of the heart; to ask the patient to open and close their fist; and gently to tap above the vein



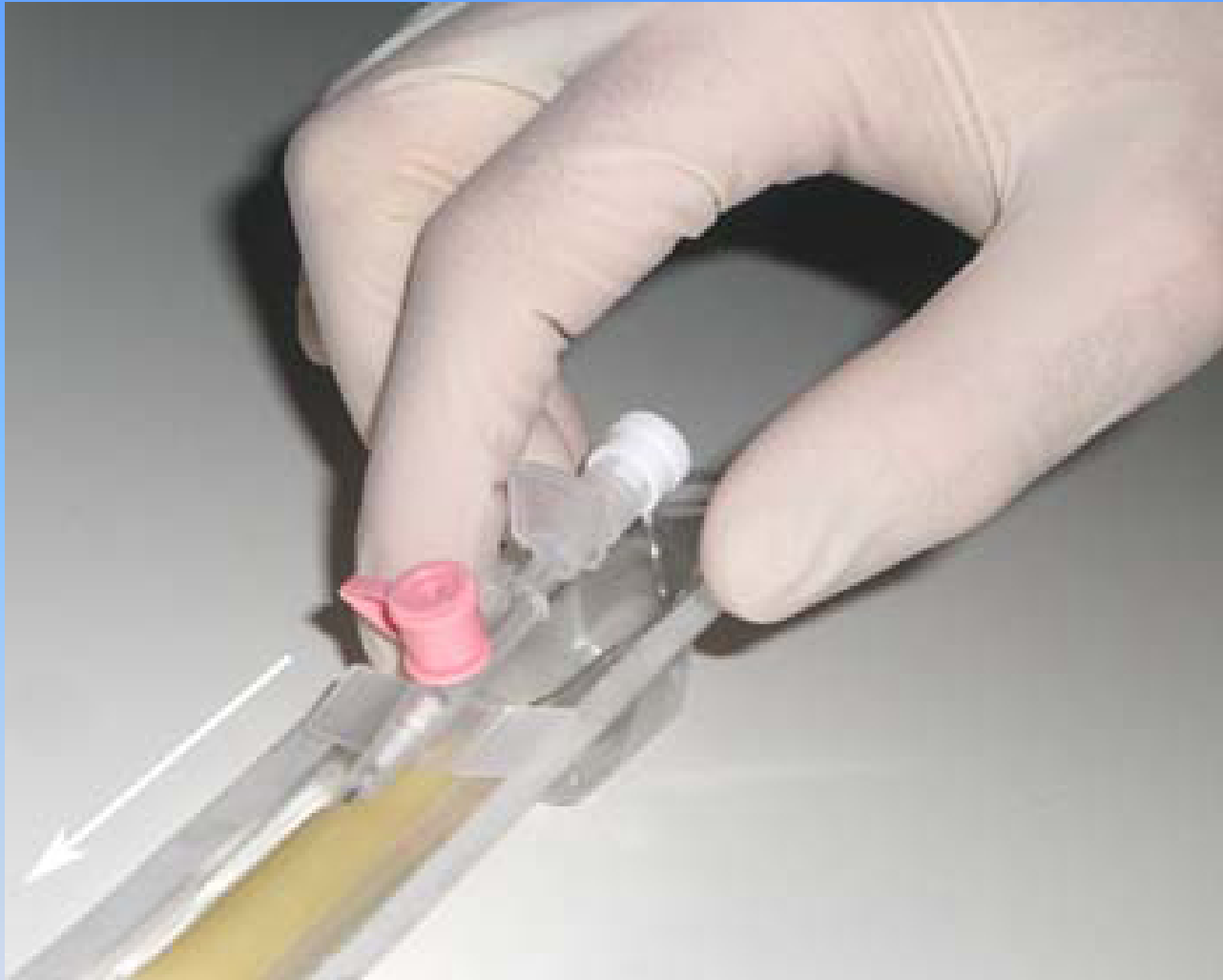Step 4: Take a three point grip of the cannula, with your thumb on the white cap, index finger on the coloured cap, and middle finger on the wing. In a real scenario apply counter-traction to the overlying skin with your other hand to help anchor the vein during insertion



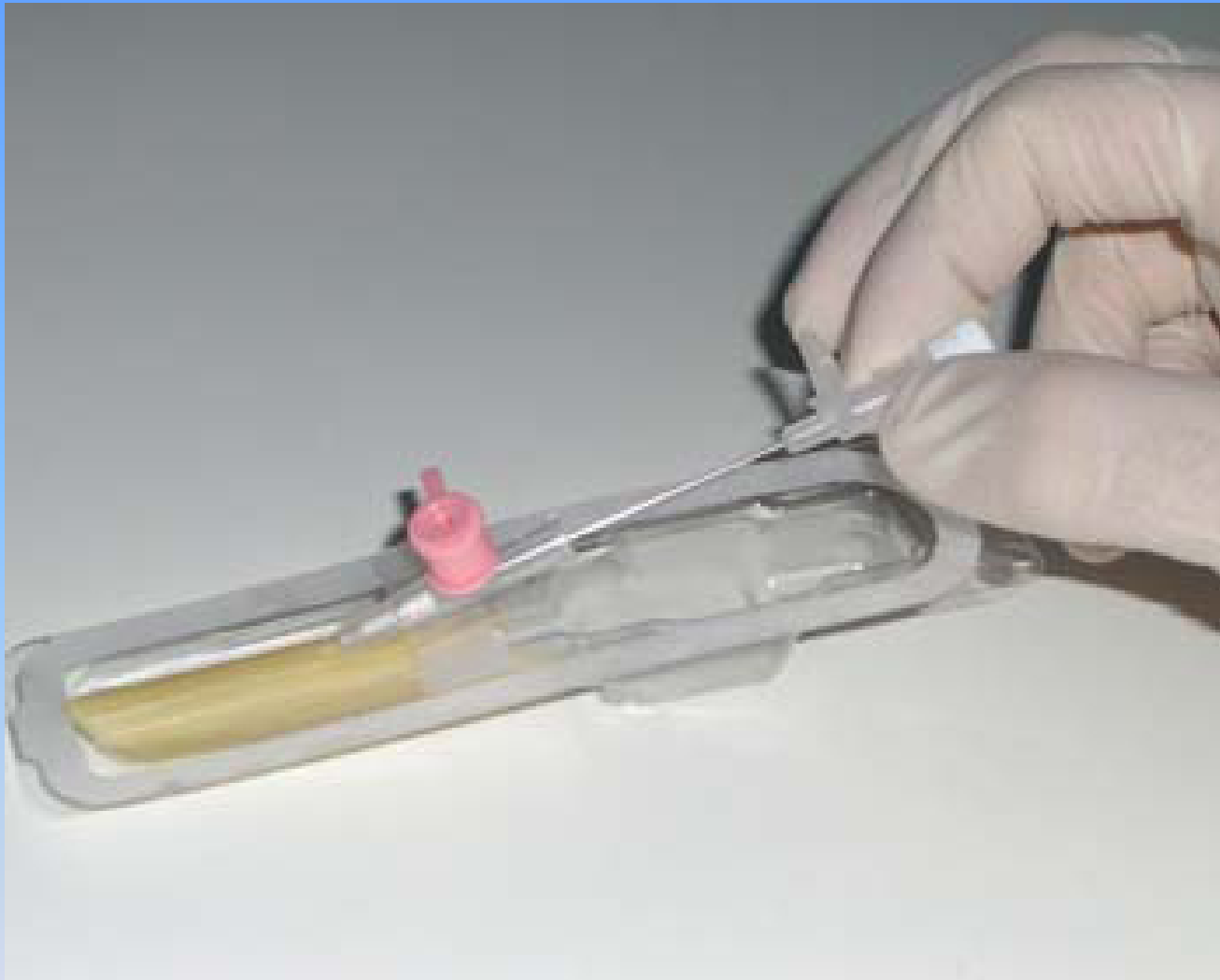
Step 5: Approach at a 30° angle to go through the skin (the outer layer of pasta) then reduce to a 15° angle to advance the needle inside the vein (the space between sheath and pasta) until you see the first flashback (in a real scenario). The flashback provides visual indication of venous entry. The first flashback occurs as you enter the vein, and the second occurs as the needle is withdrawn and blood moves to fill this space. There are three main explanations for failed needle insertions—missing the vein; perforating the posterior wall of the vein; and hitting a valve within the vein



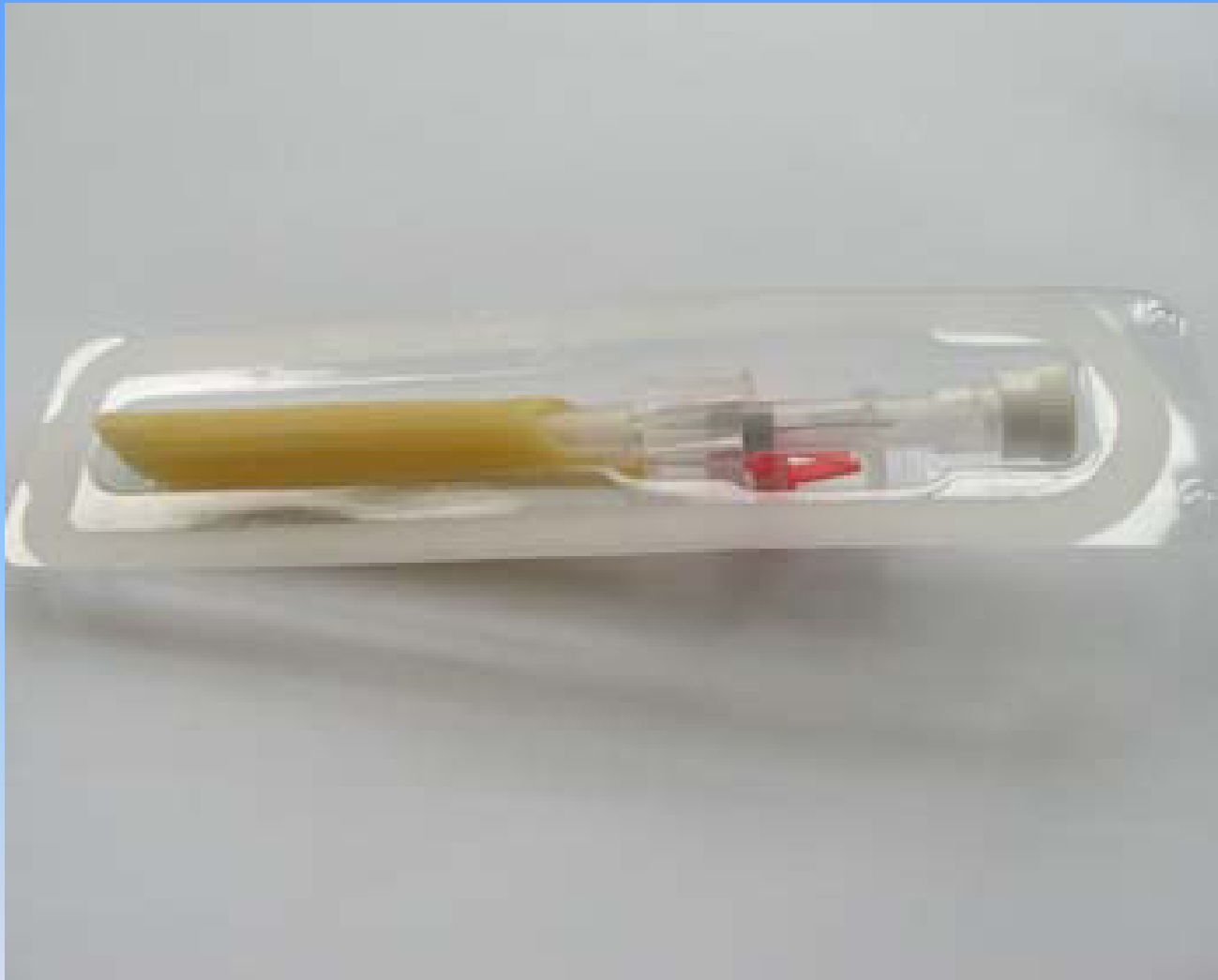
Step 6: Now change your grip, so the thumb and middle finger are on the white cap to withdraw the needle about 5 mm to produce the second flashback. Importantly the index finger provides counter-traction on the wing



Step 7: With just the index finger remaining in place at the wing, advance the cannula along the vein. In a real scenario this is the time to release the tourniquet



Step 8: Fully withdraw the needle. Remove the white cap and use it to cap the cannula promptly. To prevent bleeding in a real scenario, occlude the vein with your other hand at the tip of the inserted cannula while you remove the needle until you cap the cannula.



Step 9: When finished practising, remove the cannula, return the needle to the cannula, and return this unit to its sheath for safe storage and further practice

Care and management

- **Flushing should be performed before and after each use of the cannula**
- If not used, the **cannula should be flushed every 24 hours with 0.9% sodium chloride**, using a **pulsated (push pause)** flush to create turbulent flow and positive pressure
- **Needleless injection caps** are used to reduce significantly the incidence of catheter occlusions.
- Cannula can be **secured using clean tape or a securement device**, which have been shown to reduce the risk of dislodgement and other complications such as mechanical phlebitis.
- A **transparent dressing or low-linting gauze** should be applied **and then a bandage** may be applied. Transparent dressings, particularly moisture-permeable dressings, should not be bandaged as visibility and moisture permeability are obscured

Never forget...Documentation

- Date and time of insertion
- The location of device
- Type and gauge size of device
- Signature of the practitioner inserting the device
- Any other information that the practitioner feels is necessary to ensure continuity of care, such as problems with access and/or anxiety related to needles
- Assessment of the site should be documented using relevant tools (Visual Infusion Plebitis Score) – next slide

Visual Infusion Phlebitis (VIP) Score

Intravenous (IV) site appears healthy	0	No signs of phlebitis • Observe cannula
One of the following is evident: ▶ Slight pain near IV site ▶ Slight redness near IV site	1	Possible first signs of phlebitis • Observe cannula
Two of the following are evident: ▶ Pain near IV site ▶ Erythema ▶ Swelling	2	Early signs of phlebitis • Re-site cannula
All of the following are evident: ▶ Pain along path of cannula ▶ Erythema ▶ Induration	3	Medium stage of phlebitis • Re-site cannula • Consider treatment
All of the following are evident and extensive: ▶ Pain along path of cannula ▶ Erythema ▶ Induration ▶ Palpable venous cord	4	Advanced stage of phlebitis or start of thrombophlebitis • Re-site cannula • Consider treatment
All of the following are evident and extensive: ▶ Pain along path of cannula ▶ Erythema ▶ Induration ▶ Palpable venous cord ▶ Pyrexia	5	Advanced stage of thrombophlebitis • Initiate treatment • Re-site cannula

Removal of the device

- It is recommended that **peripheral devices should be re-sited every 72-96 hours**, although some literature supports extending the dwell time **up to 144 hours under certain circumstances** (E.g. Infusion of non-irritant medications or fluids).
- Removal of cannula should be conducted under **aseptic conditions**
- Site should be **inspected to ensure bleeding has stopped** and should be covered with a **sterile dressing**.
- Cannula integrity should be checked to ensure that the **complete device has been removed**
- **Date, time** and **reason for removal** of the cannula should be **DOCUMENTED**

Complications

Complications need to be recognised and managed at the **earliest possible stage**, as they can result in pain, patient anxiety, haematoma, inflammation, infiltration or extravasation.

- **Haematoma formation**
- **Inadvertent arterial puncture**
- **Neural puncture**

If these occur, then they **MUST BE DOCUMENTED** and the patient must be informed of **who and when to contact if they develop numbness or tingling** in the limb

- **Phlebitis** and **infiltration** are most common complications – management depends on cause and also depends on extravasated materials

A Little test

1. Peripheral cannulation provides intravenous access for:

- a) Hydration
- b) Feeding
- c) Medications
- d) All of the above

2. Which of the following statements is correct?

- a) Arteries and veins pulsate
- b) Arteries do not pulsate
- c) Veins do not pulsate
- d) Veins pulsate

3. Which of the following is not a form of phlebitis:

- a) Chemical
- b) Physical
- c) Infectious
- d) Mechanical

4. The ideal vein for cannulation should:

- a) Have a number of valves
- b) Refill when depressed
- c) Be rigid
- d) Be located over a joint

5. How often should a cannula that is not in use be flushed?

- a) Every hour
- b) Twice a day
- c) Every other day
- d) Every 24 hours

6. The success of cannulation may be influenced by a patient's

- a) Age
- b) Nutritional status
- c) Physical condition
- d) All of the above

7. What percentage of chlorhexidine solution should be used to clean the skin?

- a) 2
- b) 5
- c) 10

References

Department of Health (2007) *High Impact Intervention No 2 Peripheral Intravenous Cannula Care Bundle*. www.clean-safe-care.nhs.uk/toolfiles/16_SL_HII_2_v2.pdf (Last accessed March 2nd 2010.)

Dougherty L (1996) Intravenous cannulation. *Nursing Standard*. 11, 2, 47-51

Dougherty L (2008) *Peripheral cannulation*. *Nursing Standard*. 22, 52, 49-56

Dougherty L, Lamb J (Eds) *Intravenous Therapy in Nursing Practice*. Second edition. Blackwell Publishing Oxford, 167-196; 225-270.

Infusion Nurses society (2006) *Infusion Nursing standards of practice*. INS, Norwood MA

Lavery I, Ingram P (2005) Venepuncture: best practice. *Nursing Standard*. 19, 49, 55-56

Perucca R (2001) Obtaining vascular access. In Hankins J, Lonsway RAW, Hedrick C, Perdue MB (Eds) *Infusion Therapy in Clinical Practice*. Second edition. WB Saunders, Philadelphia PA, 375-388

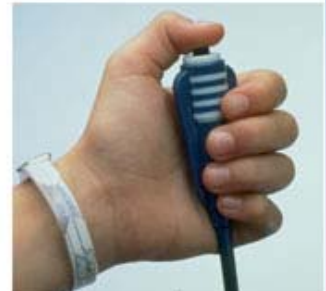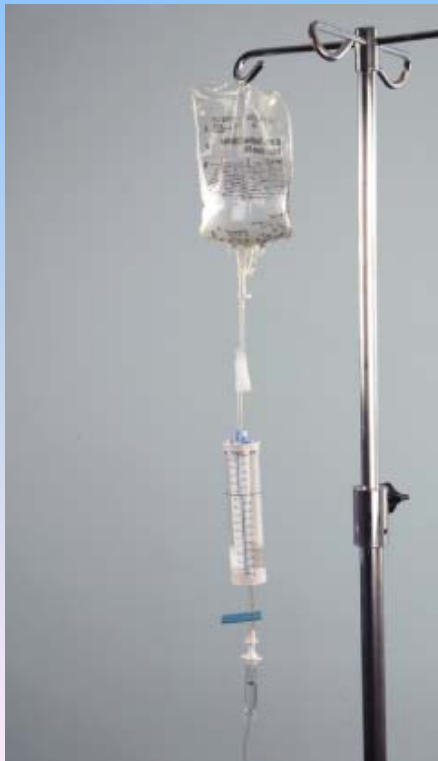Royal College of Nursing (2005) *RCN Standards for infusion Therapy*. RCN, London

Springhouse (2002) IV Therapy Made Incredibly Easy. Second edition. Lippincott Williams & Wilkins, Philadelphia PA.

<http://archive.student.bmj.com/issues/08/06/education/244.php> (Last accessed on March 6th 2010)

Intravenous infusions (IVs)

Bhavin Doshi



Introduction to IVs

Direct administration of fluids into the vein of choice

SC (subcutaneous) or IM (intramuscular) injections are limited to 3 mL since larger quantities lead to local problems

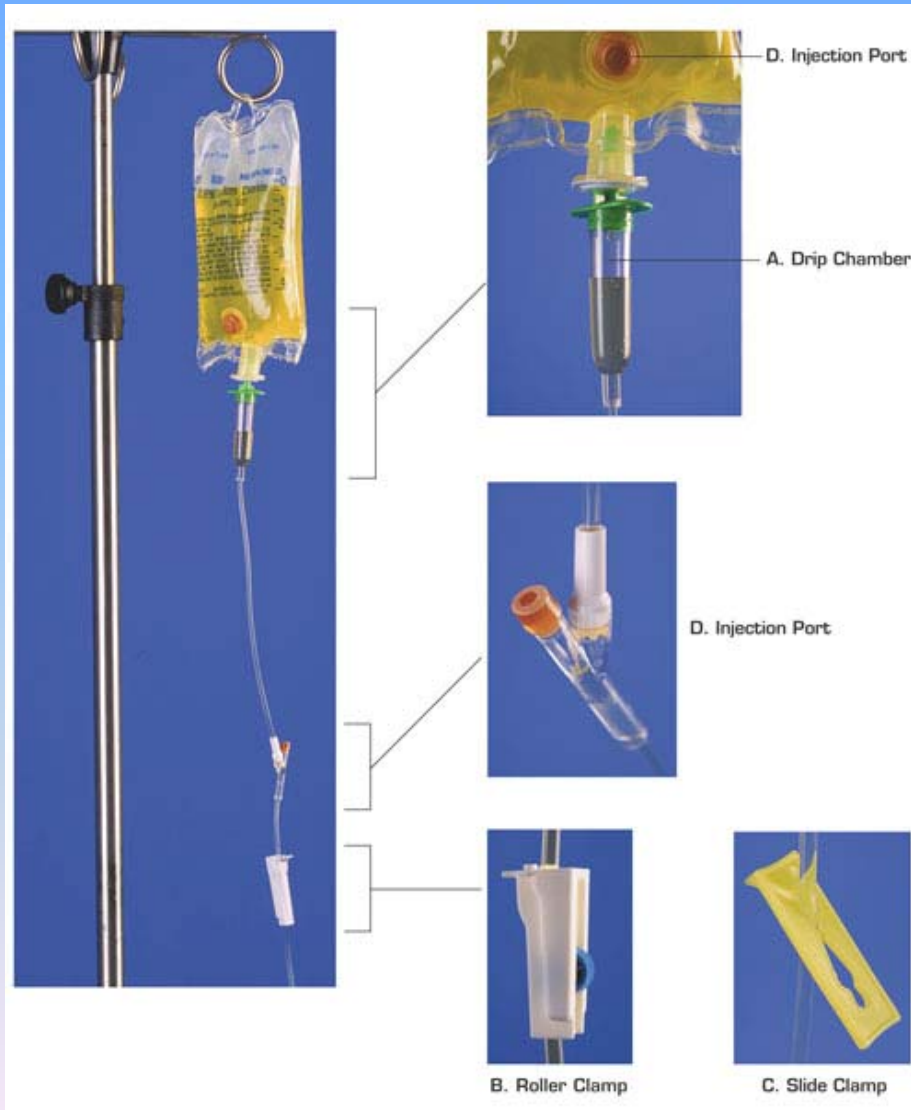
Only limit on IV is the total body fluid content, since total fluid intake should be **35-50 mL / kg body weight / day is acceptable** (in 100kg man – 3.5 – 5L per day!!)

IVs are given when we need to **give a lot of fluid**, or if we need to **dilute a medication** a lot to reduce irritation

Usually **given over longer periods of time** (15 minutes to several hours) in contrast to SC and IM which give entire dose instantly

IV administration allows **fastest method of administration** (bioavailability / bioequivalence is high) because it goes directly into the blood, so may be used for **rapid onset of medication**

Basic IV setup



IVs are usually administered by bags of fluid that come premixed. The standard sizes range from 50 mL to 1000 mL.

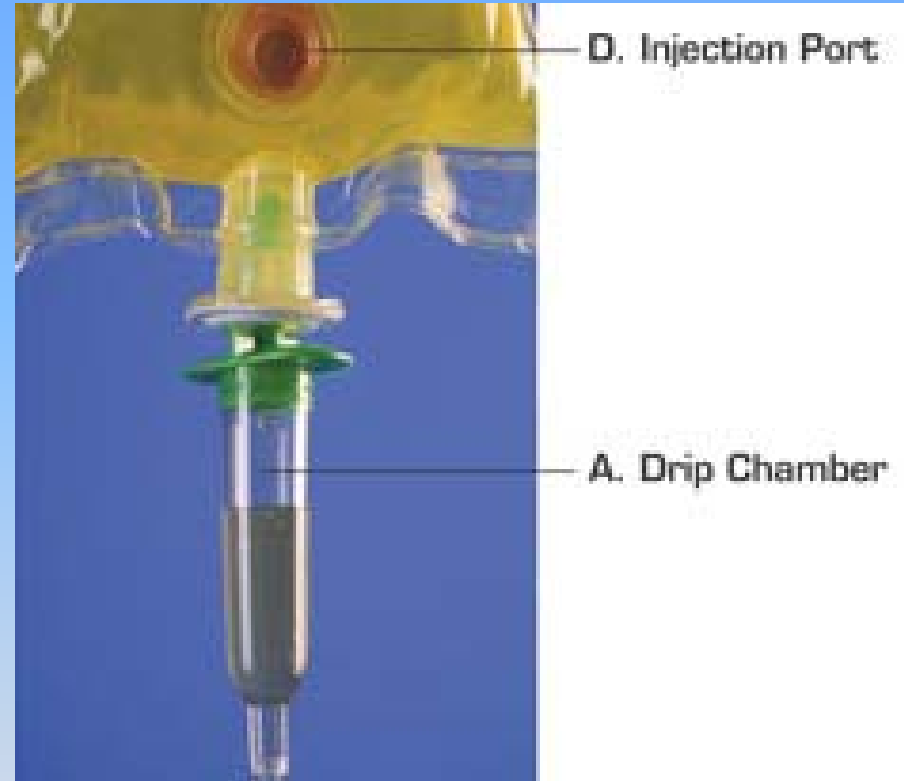The bag is hung from an **IV pole**, and **IV tubing** is attached to the bottom of the bag.

The tubing has several important parts:

- a) **Drip chamber**
- b) **Roller clamp**
- c) **Side clamp**
- d) **Injection port**

a) Drip chamber

- Located just below the bag
- Used to **visualise the fluid dripping into the tubing from the bag**
- This is where we **measure the speed of a manual IV setup** – we look at the chamber and count the number of drops per minute
- The **drip chamber should always be about half full.**



- If it is too full, we cannot see the drops, so cannot count them
- If it is not full enough, then this will allow air to get into the IV tubing and therefore into the patient's circulatory system, which can be very dangerous, blocking a blood vessel (venous air embolism – VAE), or stopping the heart

b) Roller clamp

- This is what we use to **control the rate at which the IV fluid infuses**
- If we **roll it one way, it squeezes the tubing** more tightly, making it more narrow and therefore **slowing the fluid flow** through it
- If we **roll it the other way, it loosens its pinching** of the IV tubing, making the tubing less narrow, **increasing the fluid flow** through it
- All **roller clamps on a set of IV tubing should be closed before we attach a bag of IV fluid** the top of the tubing, ensuring no air gets into the tubing
- **Every medication is ordered at a specific infusion rate (or flow rate)**



B. Roller Clamp

c) Side clamp

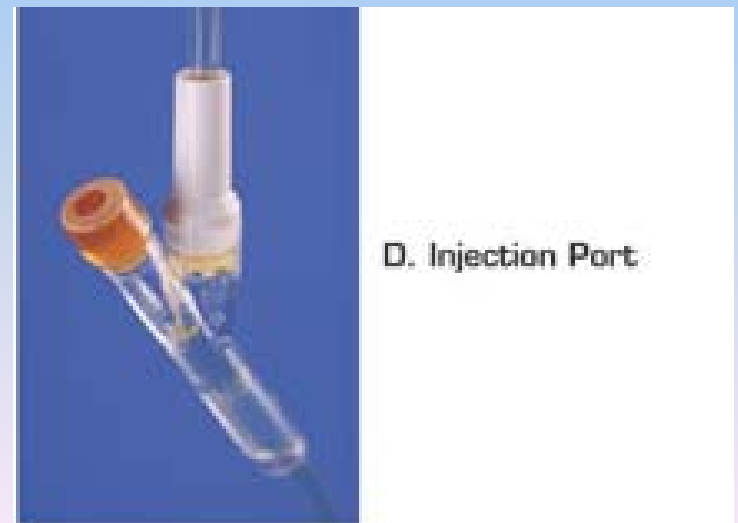
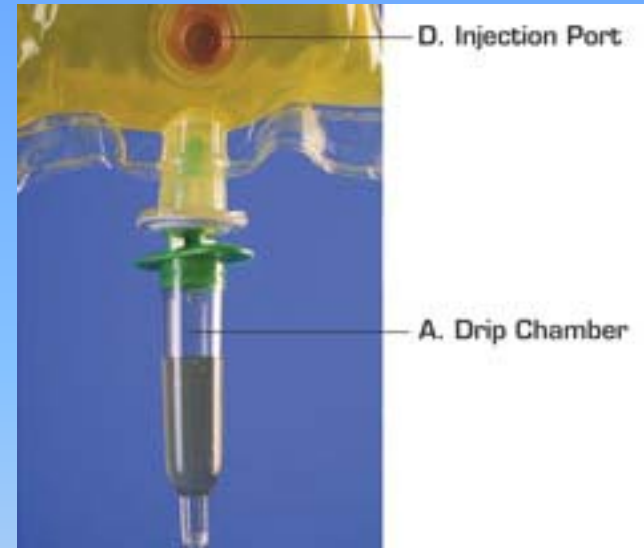
- This is used when we want to **completely stop the IV from flowing**, without having to adjust the roller clamp
- It is useful for momentary breaks in the flow, without having to reset the flow rate again by readjusting the roller clamp all over again
- It works by **completely pinching off the IV tubing** when we slide the tube through the **narrowest part of the clamp**



C. Slide Clamp

d) Injection port

- This is the place where **medicine or fluids other than those in the current IV bag can be injected** so that they will infuse into the patient's vein through the IV tubing
- Here we can see 2 ports, **one in the bag** and **one below the drip chamber**, there is also usually **one where the needle goes into the patient's vein**
- The injection port **on the IV bag is used if we want to mix some kind of medication with the fluid in the bag** (need to be compatible)
- If we want to **inject medication or a second kind of IV fluid that we've already attached**, then we will use one of the ports that are **located below the drip chamber**

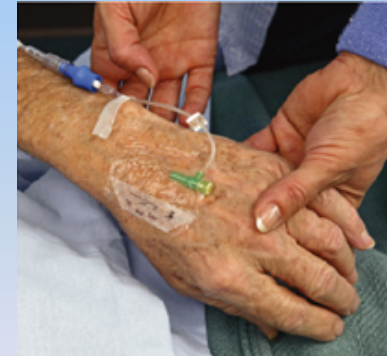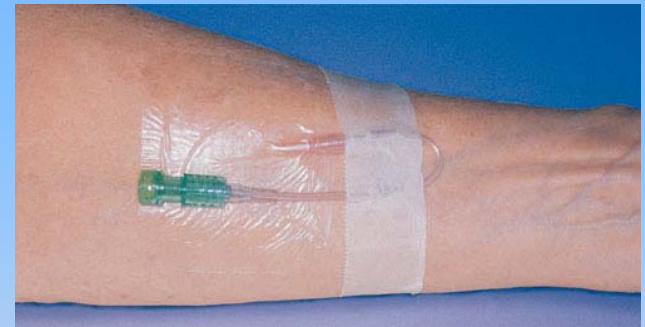

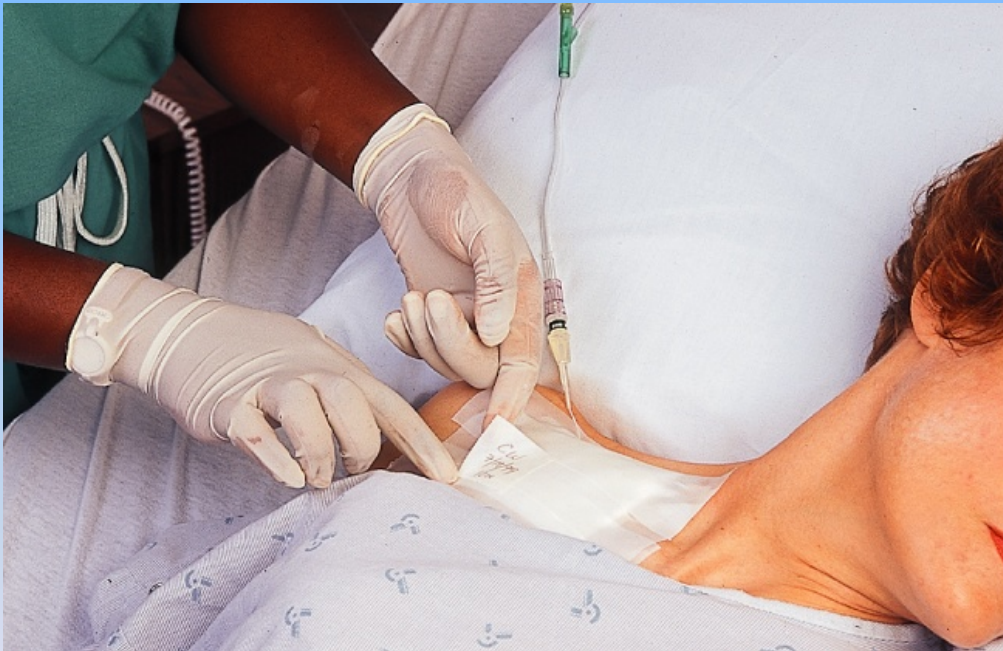
Height of the IV bag

- IV infusion works because of **GRAVITY** – pushes fluid down through tubing into the vein
- The **higher the bag is hung**, the **greater the gravitational pressure** on the IV fluid **to go downward through the tubing**, if the **bag is not high enough**, there will **not be enough pressure to force fluid into the vein**
- All **IV bags must be hung above the patient's heart** in order for there to be enough pressure for the fluid to infuse – **usually 3 feet** above an adult patient's heart
- **Change in the movement** of the patient will result in **changes in the infusion rate**, so **constant monitoring** is required – **usually every hour** and after any major change in position
- Sometimes **needle can be dislodged** from the vein so that the fluid is infusing into the tissue – **infiltration** – eventually IV will stop due to a higher pressure in the tissue compared with the IV tube. Look for **swelling, coolness** and **pain**

How is IV attached to patient

Can attach a peripheral line (to limb) – these can only be used for a short period, usually 3 days due to risk of infection, so if it is required for longer then it is standard procedure to move the injection site to a new location every 3 days



A central line is an IV attached to a vein in the chest – usually through the chest wall, or neck veins, but it is also possible to insert the cannula into a peripheral vein and move the tip of the cannula slowly upward until it reaches a central vein

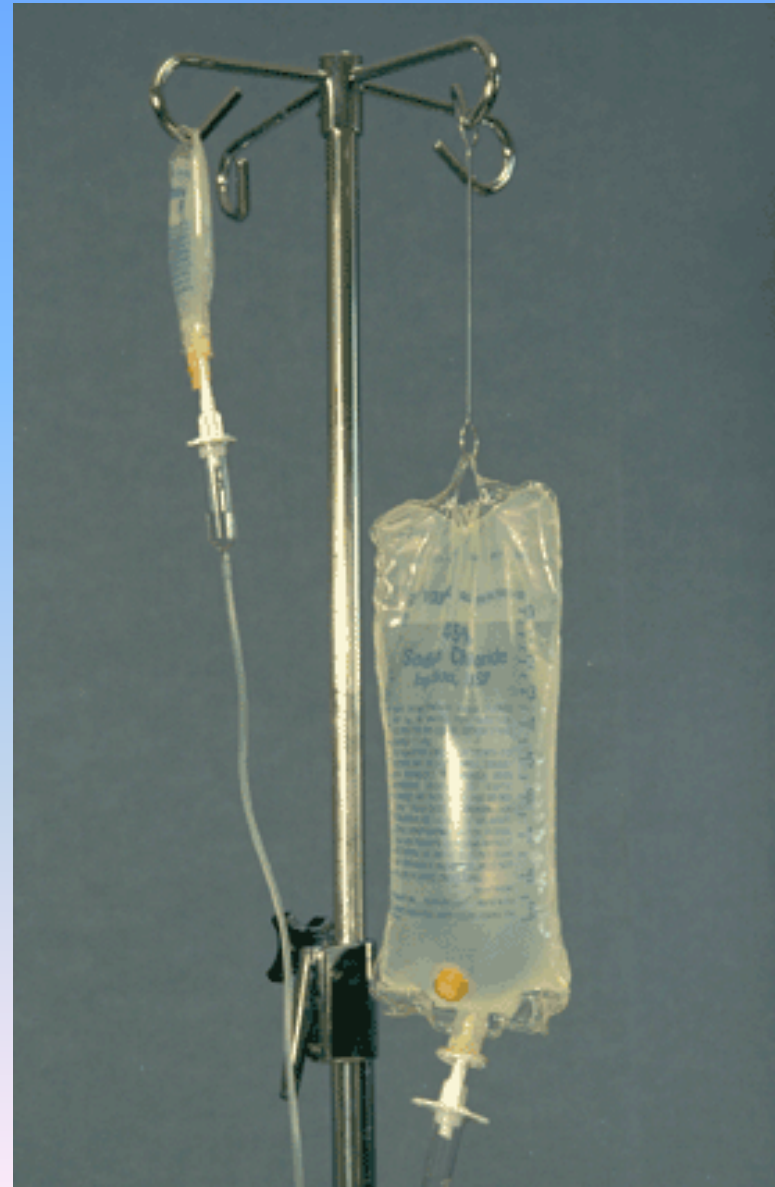Continuous vs Intermittent

- IV medication can be given **continuously**, or **intermittently**
- A patient who requires **continuous infusion** has a **constant IV setup**
- A patient who only **requires intermittent IVs** have a **cannula** setup to them continuously, which is independent of the IV infusion equipment
- The cannula has an **injection port** attached to it's end called an infusion port adapter (sometimes referred to as a heplock or saline lock/port)
- Cannula should be **flushed** since it can become blocked by clotted blood – can use **2mL saline** or **2mL heparin** (concentration of 100U/mL) **every 6-8 hours**

FOR MORE INFORMATION ON CANNULAS, SEE LECTURE ON INTRAVENOUS CANNULATION

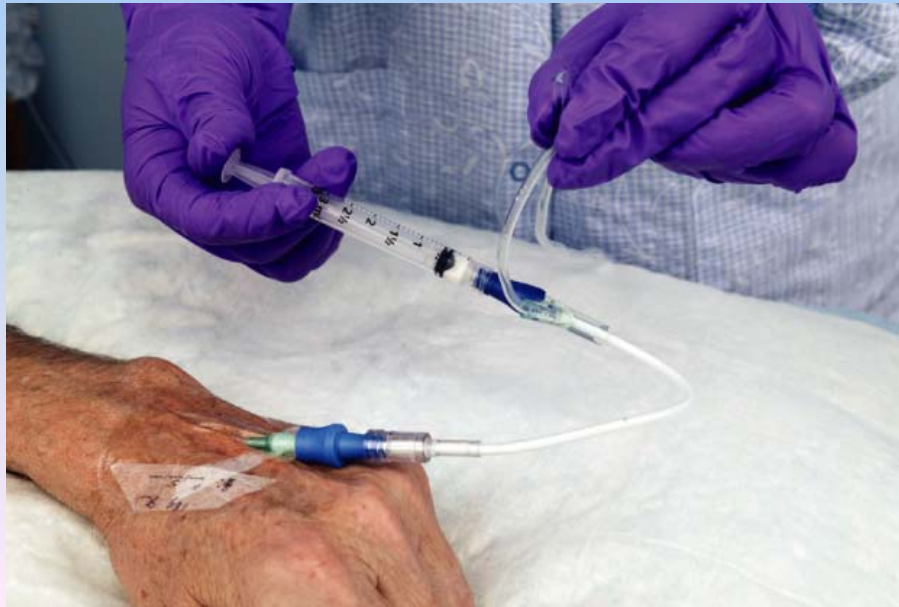Secondary IV or IV Piggyback

- If patient is receiving continuous IV fluids and/or medication and in addition must receive a second kind of **intermittent infusion**, or if a patient's **current IV infusion must be interrupted** in order to **administer a second IV medication or fluid that is more pressing**, then we need to hang a secondary IV for the patient
- **Secondary IV = IV Piggyback = IVPB** = Second IV bag hung next to first and enters patient **through first set of IV tubing** through an **injection port below the drip chamber**
- Usually used for **medications which have smaller volumes than the primary IV (50 – 250 mL)**. Is also, usually given intermittently
- Since we want the **secondary infusion** to infuse faster, we hang it **higher** than the first bag




IV Push or Bolus

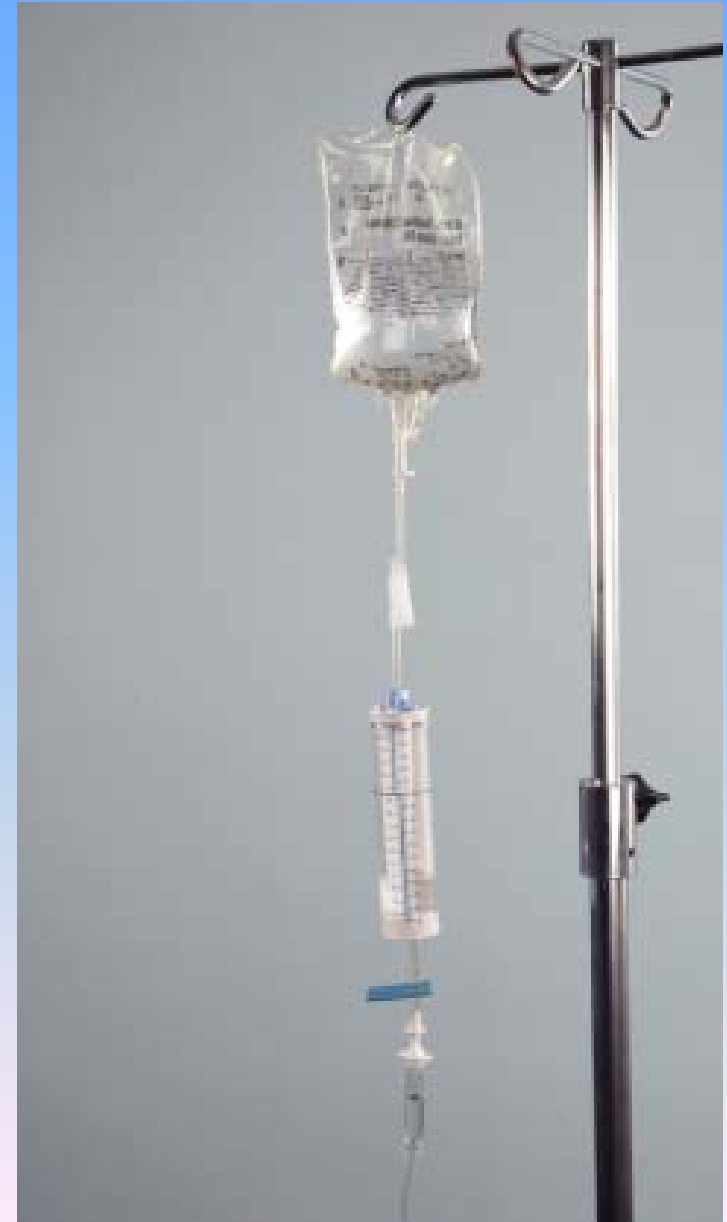- Sometimes we want to give an injection by intravenous administration, but want to give a **small volume all at once**. This could be for a few reasons: could be **larger than 3mL**; It will be **better absorbed**; avoid the **first pass effect**.
- We can **give the IV injection all at once by inserting a syringe into one of the injection ports** and this is called an **IV push** or **Bolus**
- It can be **given alongside a continuous infusion** or can be **given into a heparin lock** which has previously been setup



Smaller volume IV doses

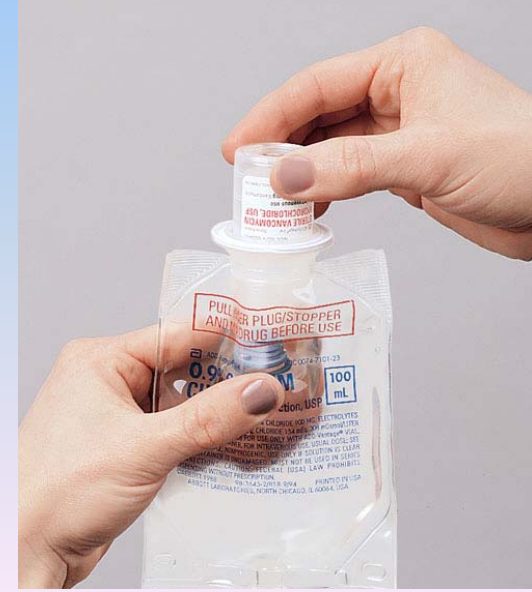
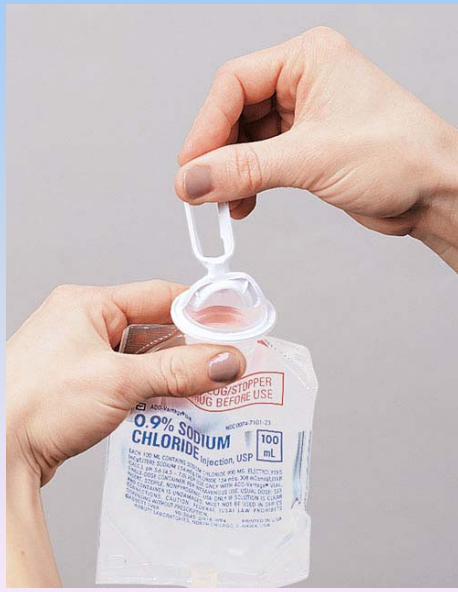
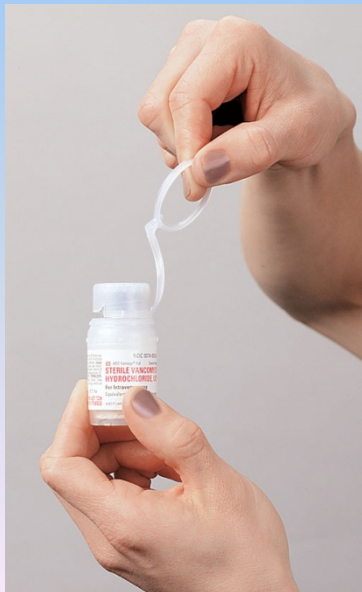- If the volume of fluid we wish to infuse is relatively small (E.g. For an infant or small child, then we need to **use a method where small volumes can be controlled.**
- We use a **volume-controlled burette** (allows measurement of **120 mL in graduations of 1mL**
- Still has **drip chamber, roller clamp** (on top so we can hang an IV bag above it, to mix a single dose) and **injection port** at the top



Medication vial ports

- Most medications are mixed with IV fluids by injecting them directly into a premixed IV fluid bag
- Some drug manufacturers also produce special IV bags which contain a **medication vial port**, which **allows specially shaped vials of powdered medication to be attached directly to the top of a special IV fluid bag**
- E.g. Powdered Vancomycin hydrochloride into 100 mL of 0.9% Sodium Chloride



Electronic infusion devices

- It is becoming more and more common to for many IV setups in hospitals to be implemented using **machines which control the infusion rate on their own**, only requiring the practitioner to **enter infusion rate in mL/hr**. There are 3 common kinds of electronic infusion devices:

1. **Volumetric Pumps** – **force fluid into the vein under pressure** and **against resistance**, but **DO NOT depend upon gravity**. **Rates** need to be **monitored regularly**. Some have an inbuilt alarm when rate is not being maintained. Also we need to **monitor regularly for infiltration**



Electronic infusion devices

2. **Syringe pumps** - these are used for **infusion of a very small amount of fluid over an extended period of time**, but we need to control the speed that the plunger is depressed. This is **difficult to conduct manually**, therefore syringe pumps are very useful. **Some medications cannot be diluted without losing their efficacy**, so these kinds of medications may be given using a syringe pump



Electronic infusion devices

3. **Patient controlled analgesia** – allows **patient to choose when they can take their IV medication, based on how they feel**. The device includes a button which the patient can press whenever they feel in need of pain relief, which triggers the machine to dispense the **pre-programmed dose of medication**. The machine is also pre-programmed to “**time-out**” so that the **patient cannot overdose**. Some machines record the **frequency with which the patient presses the button**, so that the practitioner is able to **monitor how often the patient is in pain**



IV Fluids

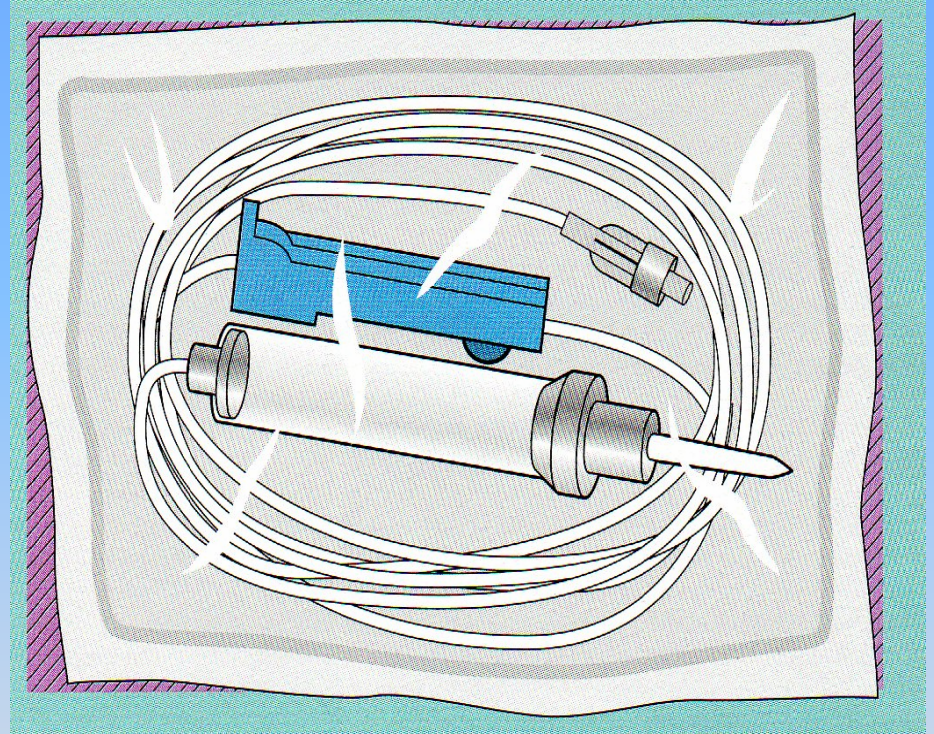
- There are many different types of IV fluids, and often these fluids are expressed using abbreviations when they are written into the drug order form.
- Any number that appear in an IV abbreviation indicate percentages. E.g. D5W is 5% dextrose in water and D2.5NS is 2.5% dextrose in 0.9% salt in water
- Remember that percentages in IV fluids and other medications actually represent number of grams in 100mL of diluent, so D2.5NS is 2.5g dextrose per 100mL normal saline, which is actually 2.5g dextrose and 0.9g salt per 100mL water

Priming an IV infusion set

- Before fluid can be given via the IV route the infusion set must be primed. This involves running the fluid to be infused through the set, to prevent an air embolus. Asepsis should be maintained during the procedure to prevent any internal or exposed areas being contaminated
- There are various types of infusion sets available:
 - Large-bore sets which have large internal diameter (reduced drops per mL ratio) so that there can be fast flow rate
 - Smaller-bore sets offer larger drops per mL value so can be used to administer crystalloid and diluted drug infusions
- Both types of devices are gravity dependent and flow is controlled by means of the roller clamp
- Only recommended sets may be used with electronic volumetric infusion devices
- All sets have a trocar and a luer lock connector
- Packaging should be sterile, intact and within expiry date


Equipment required

- Fluid to be infused
- Administration set
- Clean gloves / apron
- Receptacle for any discarded fluid
- Drip stand
- Alcohol swab
- Air inlet if using glass or rigid containers)



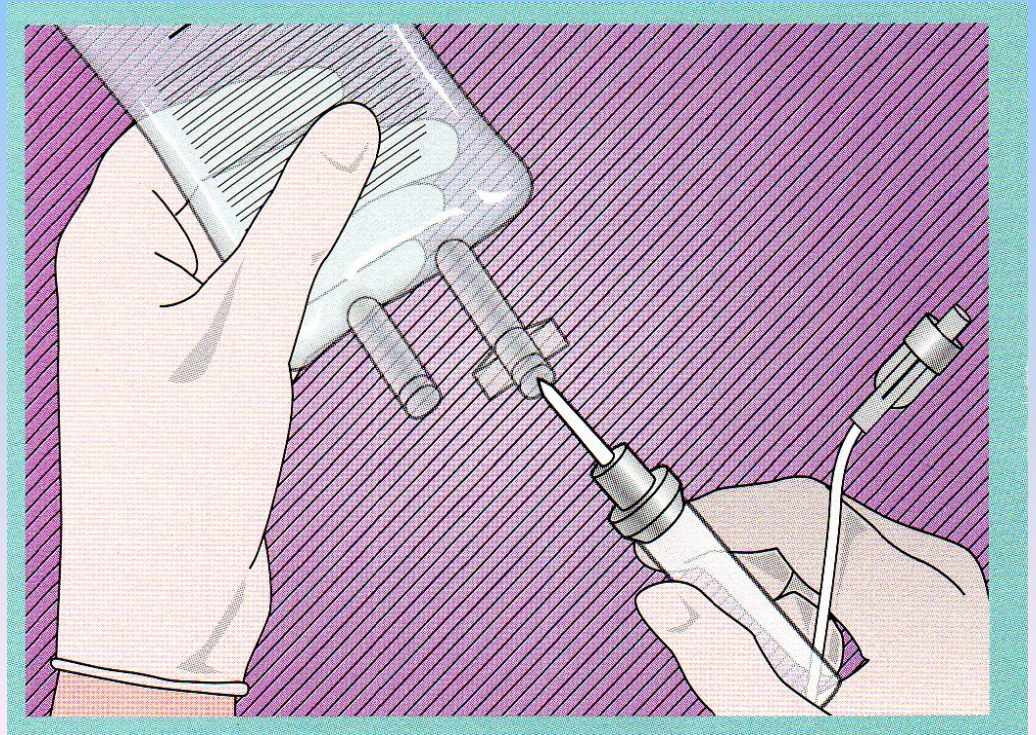
The procedure....I

- The correct patient should be identified , consent obtained and information and reassurance given
- The fluid to be infused should be checked against the prescription by two practitioners – check date of prescription, expiry date of fluid and directions
- Check infusion set contents for signs of contamination
- Wash hands, don clean gloves and apron



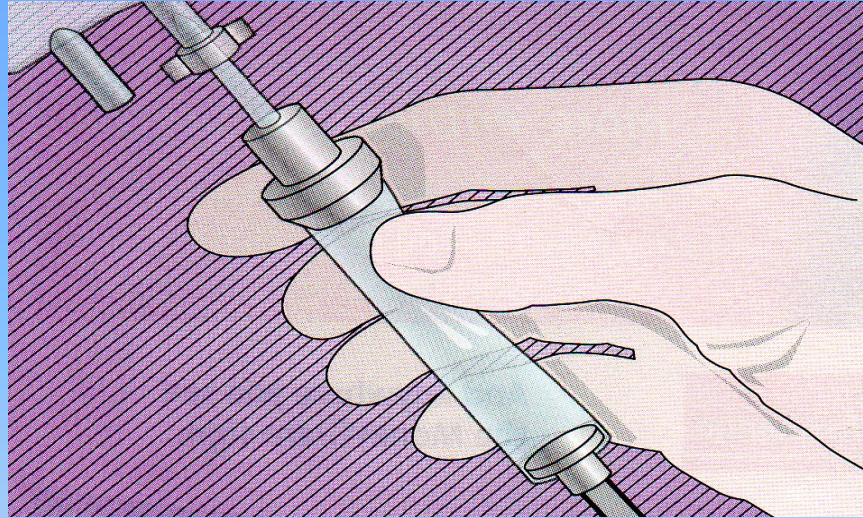
The procedure...II

- Remove any packaging. Maintaining asepsis, snap the seal where the administration set trocar is to enter the bag (invert the bag). If possible, hang fluid on a drip stand
- Close any flow controllers on the administration set. Expose the trocar without touching and advance into the appropriate port

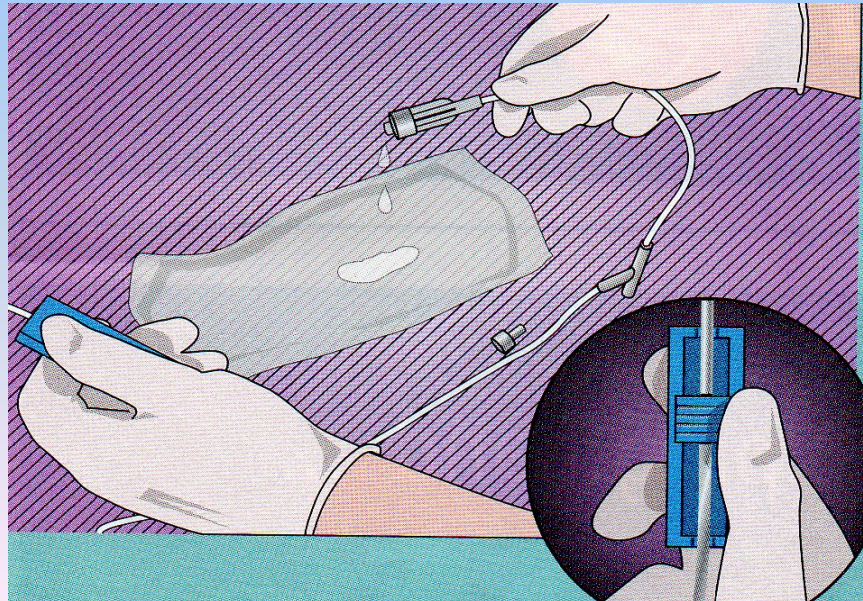


The procedure...III

- Gently squeeze the drip chamber, allowing it to partly fill with fluid

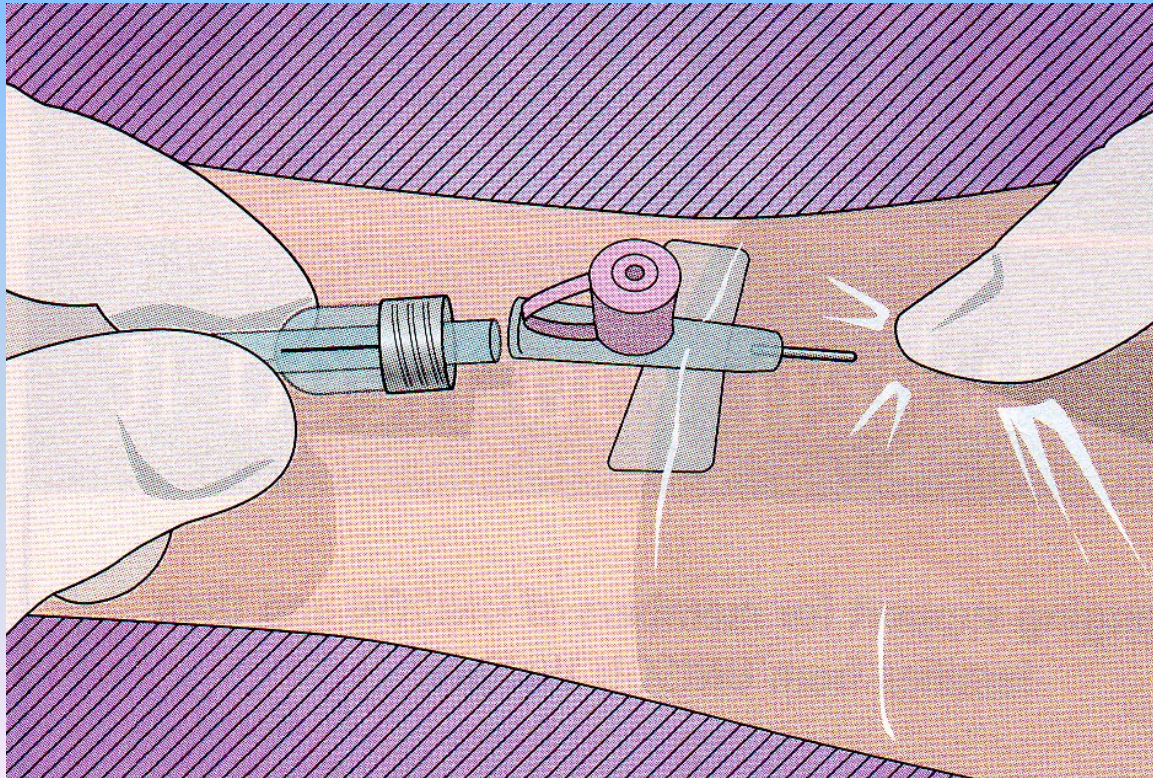


- Partially release the flow controller to allow fluid to fill and move through the tubing. This may require removing the protective cap at the luer lock connector to allow air to be expelled



The procedure...IV

- Expel any air by allowing the fluid to run through the set into a receptacle
- Connect to patient's intravascular device according to local policy and DOCUMENT the procedure



References

<http://www.cwladis.com/math104/lecture6.php> (Last accessed on March 7th 2010)

Higgins, D. (2004) Priming an IV infusion set. Nursing Times

Jamieson, E.M. (2002) Clinical Nursing Practices. Edinburgh: Churchill Livingstone

Medical Devices Agency (2003) Infusion System Device Bulletin. MDA Device Bulletin 2003: 02. London: MDA


Quinn, C. (2000) Infusion devices, functions and management. Nursing Standard; 14: 26, 35-41

RCN (2003) Standards for Infusion Therapy. London: RCN

Common Drugs used to treat common respiratory diseases

(needs further explanations!)

SHAN KESHRI
CLINICAL SESSIONS 2010



Page references relate to OXFORD HANDBOOK OF CLINICAL MEDICINE, 7th Ed.

Pneumonia (p.152)

- **Antibiotics** – infection?
- **Analgesics** – Paracetamol for pleuritic chest pain
- **IV Fluids (shock/dehydration)**
- **Oxygen** – to maintain PaO_2

Bronchio-ecstasis (p.158)

- **Antibiotics** - infection
- **Bronchodilators** – nebulised Salbutamol (β -2 agonists)
- **Corticosteroids** – Prednisolone (anti-inflammatory of mucosa)
- **Drain Sputum** – remove obstruction

ABCD

Chronic Asthma (p.166)

- Check inhaler technique
- STEP 1: short acting β -2 agonist : Salbutamol (bronchodilator and smooth muscle relaxant)
- STEP 2: steroid: Beclometasone/Fluticasone
- STEP 3: long acting β -2 agonist : Salmeterol
- STEP 4: increase doses
- STEP 5: add Prednisolone corticosteroid

Chronic Asthma

- **Corticosteroids** : Prednisolone via spacer
- **Aminophylline (met. to Theophylline)** : bronchodilator
- **β -2 agonists** : Salbutamol inhaler
- **Anticholinergics (prevent bronchoconstriction)** : Ipratropium, Tiotropium

CASA

Acute Severe Asthma (p.794)

- **Corticosteroid** : Prednisolone or Hydrocortisone
- **Aminophylline**
- **β -2 agonist**: Salbutamol nebulised with oxygen
- **Anticholinergic**: Ipratropium

CASA



COPD (stable) (p.169)

- **Anticholinergics:** Ipratropium
- β -2 agonist : Salbutamol, Salmeterol (long lasting)
- **Inhaled steroid** : Fluticasone
- Symbicort (combination of anti-inflammatory corticosteroid and long lasting β -2 agonist)
- **Diuretics for edema**
- Mucolytics
- **Flu and pneumococcal vaccinations (prophylaxis)**



COPD (acute) (p.796)

- Oxygen
- Nebulised bronchodilator: salbutamol, ipratropium
- Antibiotics: if infection, amoxicillin
- Steroid : hydrocortisone, prednisolone
- Aminophylline (decrease broncho-constriction)

O-NASA

Pulmonary Embolism (p.174)

- Investigate thrombophilia?
- Compression stockings (DVT) / Encourage mobilisation: improve venous return
- Oral warfarin (aim INR of 2-3) : prevent clots
- Massive: Morphine for pain and antiemetic
- Anticoagulant LMW Heparin : Dalteparin

I-COMA

Pulmonary Edema (p.787)

- Nitrate (vasodilation): spray sublingual, Isosorbide dinitrate
- Oxygen (aid breathing)
- Diamorphine (chest pain relief)
- Diuretic: Furosemide

NODD

DR, CAN U CHECK ME OUT?

OBS/GYNAE SESSION

TUE 1830 - 1945

Learn:

Self Breast Exam
Vaginal Exam
Pregnancy Test
+ more



Clinical Session 2!



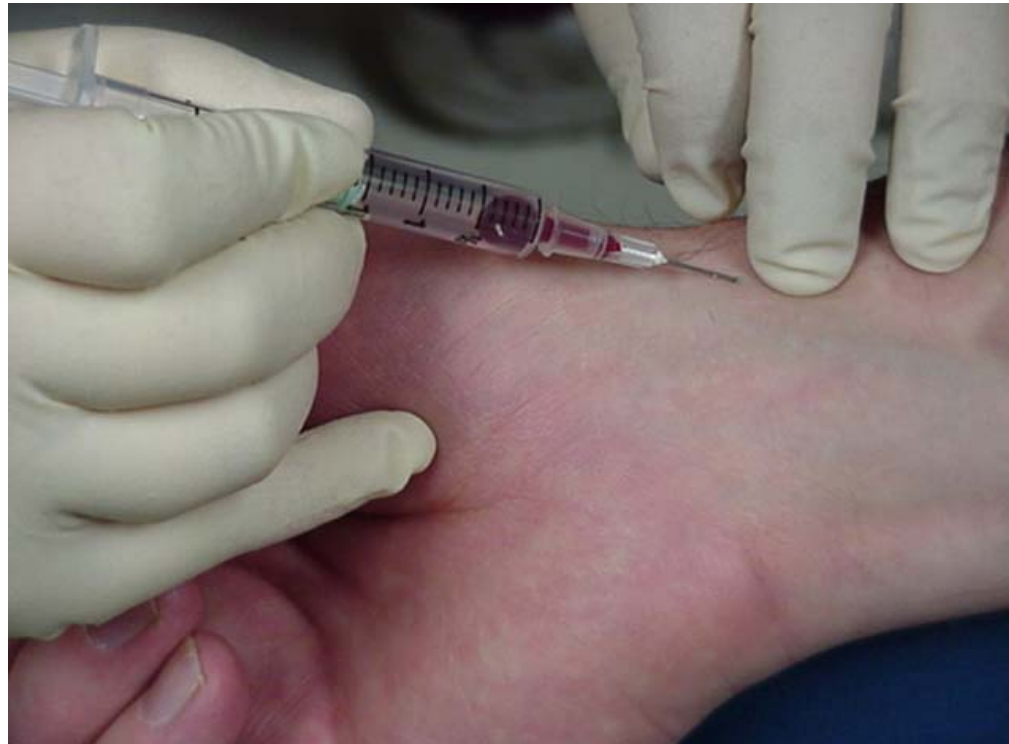SESSION 2 (Obs/Gynae) > TUES 16TH MARCH < 6.30 - 7.45PM

- 1) 6.30 - 6.45PM Arterial Blood Sampling
- 2) 6.45 - 7.00PM Obs n Gynae Intro, Breast examination
- 3) 7.00 - 7.15PM Pregnancy Test
- 4) 7.15 - 7.30PM IM & SC injections. Insulin injection techniques
- 5) 7.30 - 7.45PM Pelvic examination & Cervical Pap Smear

Arterial Blood Gas Sampling

ABG

Nathan Golban



Indications

To assess.

- **Respiratory Status**
Assess oxygenation and ventilation
- **Acid Base Balance**
- **Phlebotomy.** Used if venous route is unavailable or inaccessible due to trauma or burns. Usually a femoral puncture, uncommon variation.

Contraindications

- Overlying infection or burn at insertion site.
- Absent collateral circulation.
- Arteriovenous shunt. Often radial or brachial.
- Severe atherosclerosis
- Raynauds disease.
- Coagulopathy.

Sites

- Preferred radial or femoral arteries.
- Less common. Dorsalis pedis and posterior tibial.
- Avoid. Branches without collateral supply. Example is the brachial artery.

Complications

- Bleeding causing hematoma.
 - Arterial occlusion causing thrombus or dissection.
 - Infection causing arteritis or cellulitis.
 - Embolization
-
- Last 3 uncommon.

Normal Values

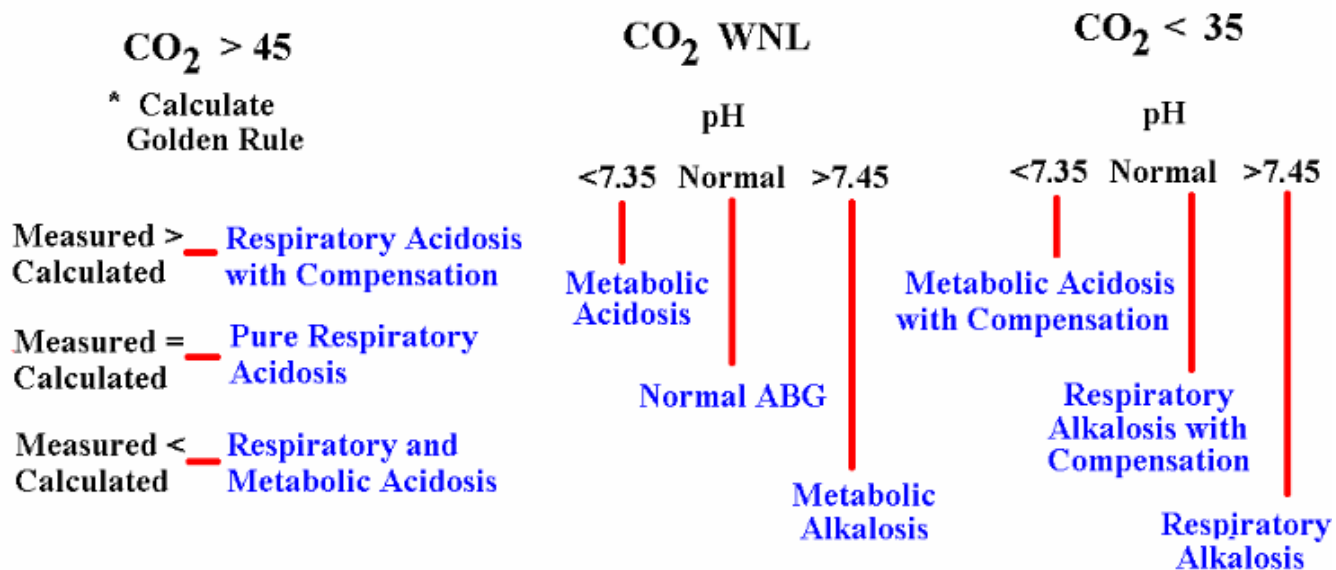
- pH, 7.36 to 7.44. For acid base status of blood.
- pCO₂, 38 to 44 mmHg. Reflects ventilation.
- pO₂, 85 to 95 mmHg. Reflects oxygenation.
- HCO₃, 21 to 27 meq per litre. Key blood buffer.
- Base excess, plus or minus 2 meq per litre

- ABG quiz.
<http://www.vectors.cx/med/apps/abg.cgi>

Pathophysiology

- Metabolic alkalosis
- Metabolic acidosis
- Respiratory alkalosis
- Respiratory acidosis

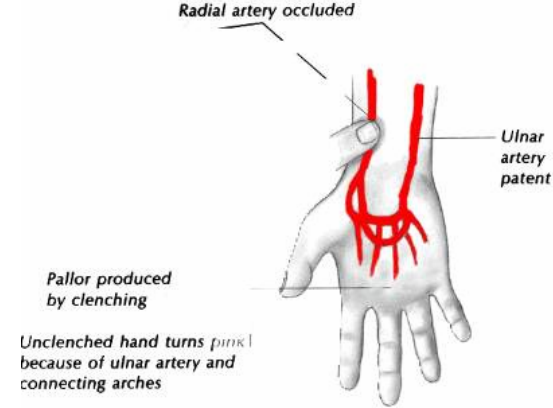
ABG



Initial Preparation

- Wash hands
- Gloves
- Protective eye wear
- Iodine swab. **Povidone-iodine, betadine.**
Followed by alcohol swab
- Arterial blood gas sampling kit
- 2 x 2 cm gauze
- Bag of ice. To store sample

Allens Test

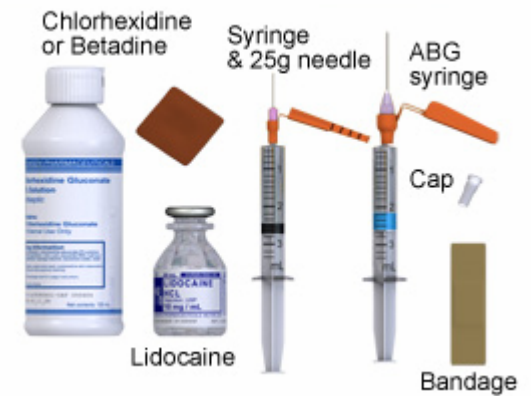

- Indicates collateral circulation to hand.
- Radial artery on non dominant hand.
- Palpate radial artery.
- Simultaneously palpate ulnar artery, or as close to that area as possible.
- Patient makes a fist. Palpate both arteries for 10 seconds.
- Release ulnar artery and witness blood flow and pinking of the hand via collateral radial artery
- Radial artery is now a candidate for testing.

Set Up

- Patient seated on stretcher
- Rolled up towel under wrist. That hyperextends wrist, bringing artery closer to surface.
- Clean area in a circular motion with iodine. Allow to dry.
- Wipe away iodine with alcohol. While drying, open sampling kit.

Sampling Kit



- **3 pieces**

1. Orange air ball or cube. Used to expel excess air from the syringe.
2. Black cap for syringe, used for transport.
3. 3 cc, cubic centimetres heparinised syringe. With needle attached.

Sampling Kit Use

- Pull back slightly on plunger, so once needle is in artery, natural pulsations will fill the syringe.
- Remove clear needle cap. Locate the bevel. Bevel is a slanted opening on one side of the needle tip. We want bevel facing upward, so you can see it.

Syringe Use

- 45 degrees, sharper angle.
- Hold like a dart or pen.
- Feeling pulse under non syringe finger is the only landmark for orientation.
- Before piercing skin, roll finger back slightly from artery, so you dont stab yourself in the finger.
- **Flash of blood** into hub of needle. Artery has been accessed.
- Blood will pulse into syringe. 1.5 to 2.0 cc required.
- Cover needle with gauze. Quickly remove needle.

After Care

- Physician applies pressure to gauze for 5 minutes. 10 minutes if patient is on anticoagulant therapy.
- Optional to ask patient to do this instead.

Blood Care

- Insert needle into orange air cube or ball. Want bevel covered, dont want needle to go through cube.
- Push down on plunger to expell excess air. So it doesnt affect results. **Key point** because we are measuring air component levels in blood.
- Remove cube and needle as one.
- Attach black cap to syringe.
- Roll test tube between hands, to ensure blood heparinisation.
- Place in iced bag. Send to lab.
- Needle and cube to sharps container.

Video

- <http://www.youtube.com/watch?v=stxntv0KkBE>

Intro to Procedures: The Arterial Blood Gas

(Source: Internet)

Information Obtained from an ABG:

- Acid base status
- Oxygenation
 - Dissolved O₂ (pO₂)
 - Saturation of hemoglobin
- CO₂ elimination
- Levels of carboxyhemoglobin and methemoglobin

Indications:

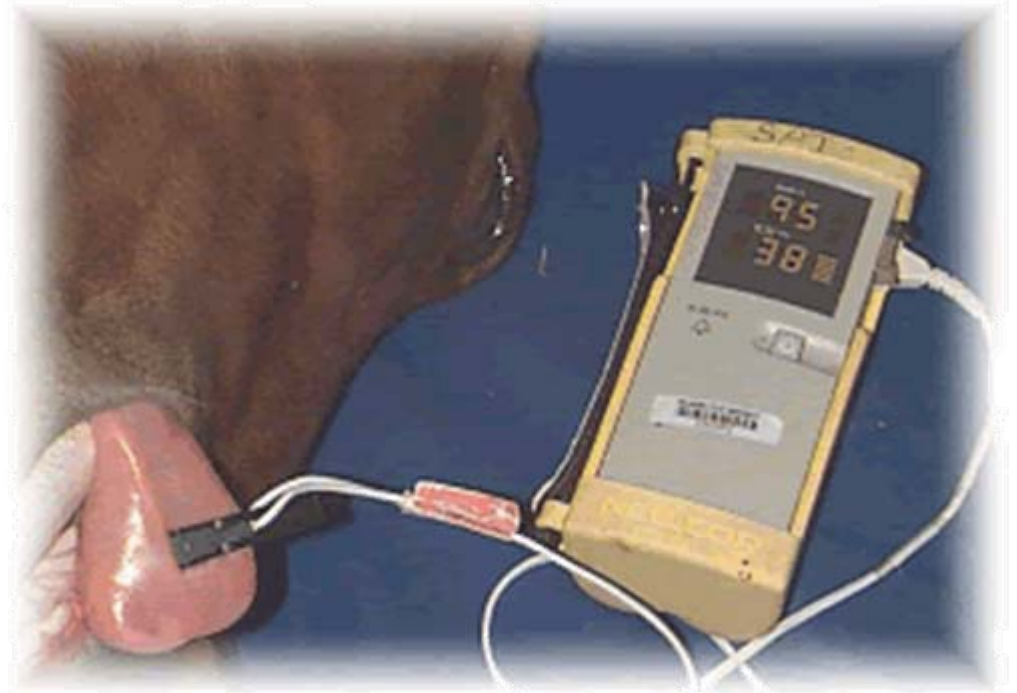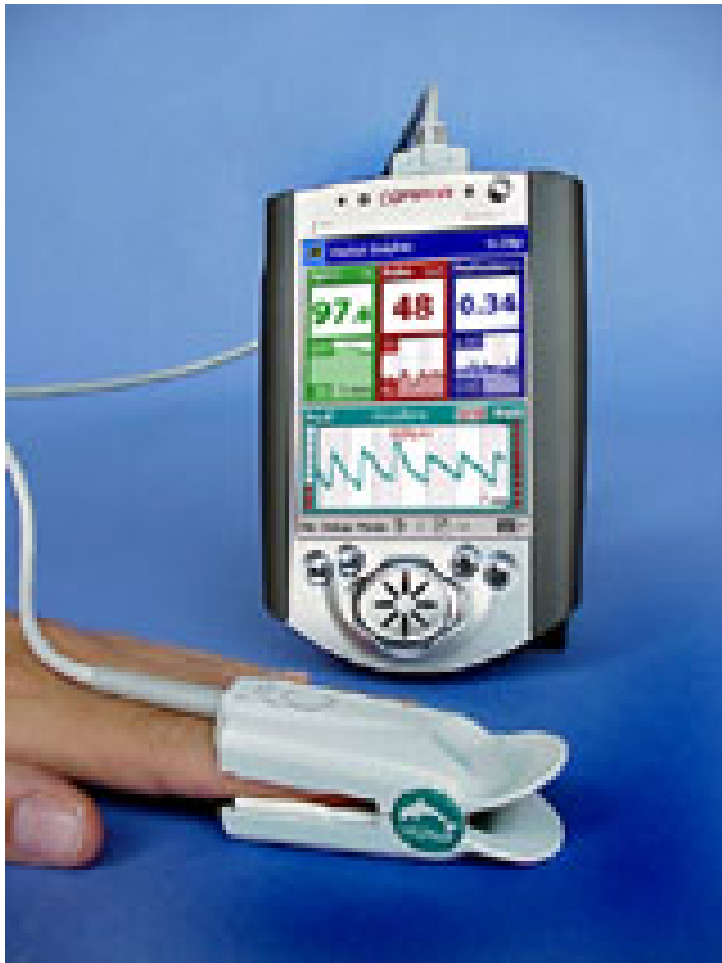- Assess the ventilatory status, oxygenation and acid base status
- Assess the response to an intervention

Contraindications:

- Bleeding diathesis
- AV fistula
- Severe peripheral vascular disease, absence of an arterial pulse
- Infection over site

Why an ABG instead of Pulse oximetry?

- Pulse oximetry uses light absorption at two wavelengths to determine hemoglobin saturation.
- Pulse oximetry is non-invasive and provides immediate and continuous data.

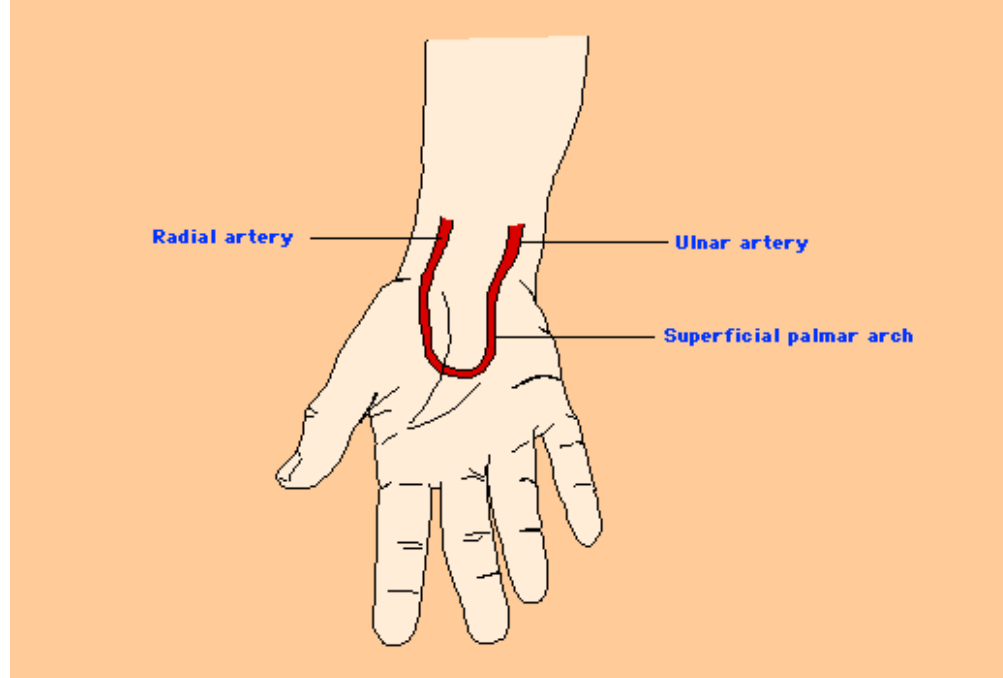


Why an ABG instead of Pulse oximetry?

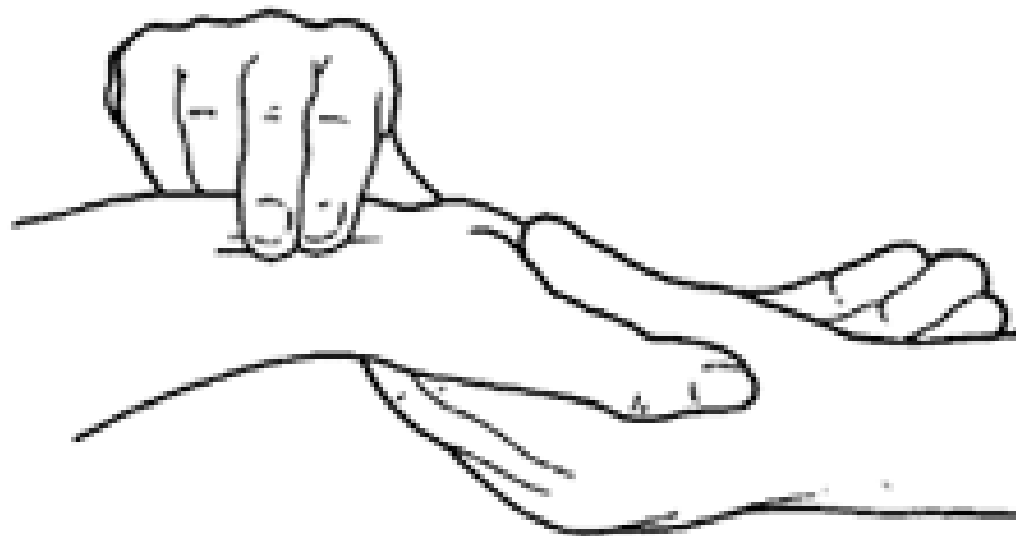
- Pulse oximetry does not assess ventilation (pCO₂) or acid base status.
- Pulse oximetry becomes unreliable when saturations fall below 70-80%.
- Technical sources of error (ambient or fluorescent light, hypoperfusion, nail polish, skin pigmentation)
- Pulse oximetry cannot interpret methemoglobin or carboxyhemoglobin.

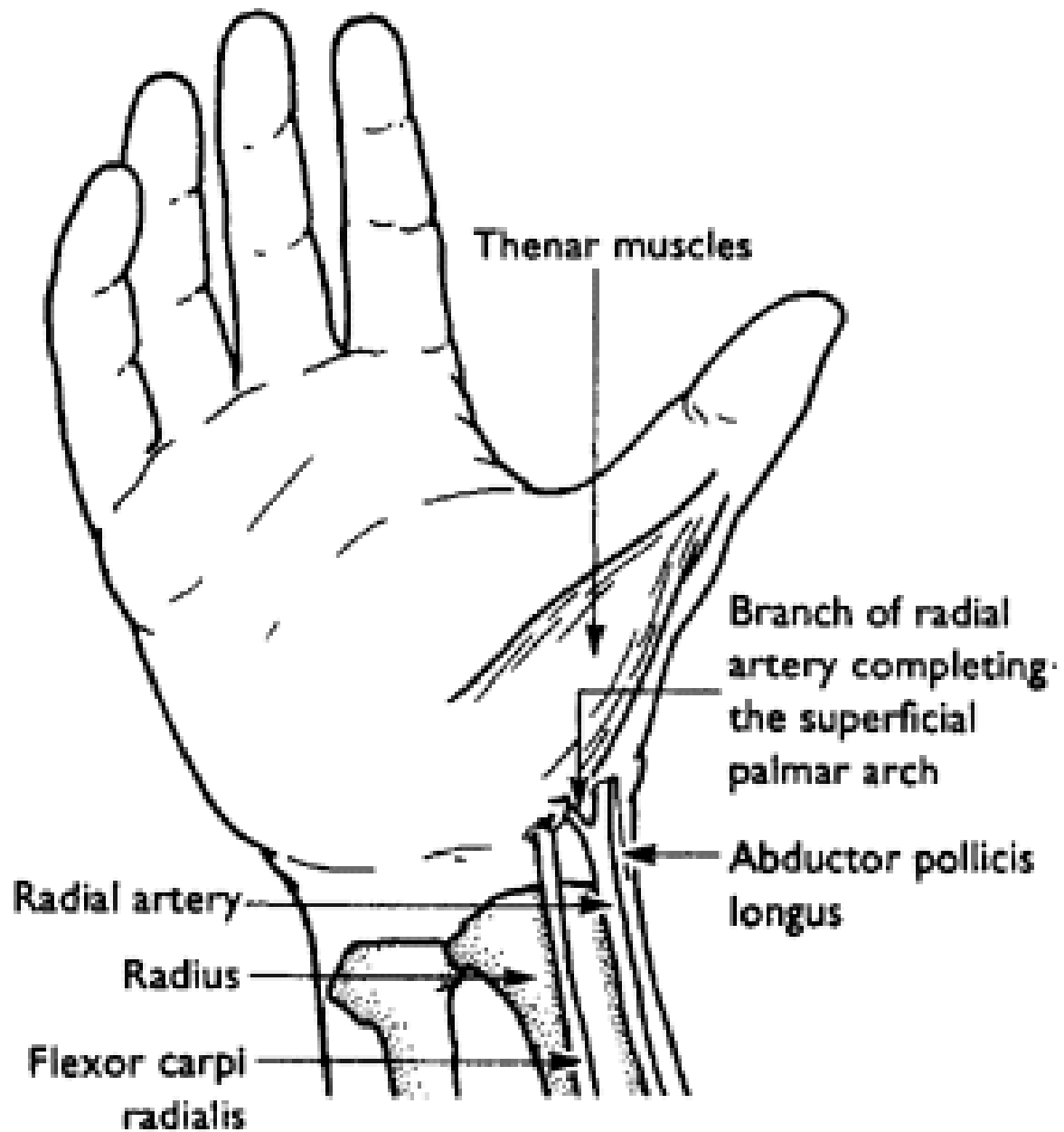
Which Artery to Choose?

- The radial artery is superficial, has collaterals and is easily compressed. It should almost always be the first choice.
- Other arteries (femoral, dorsalis pedis, brachial) can be used in emergencies.



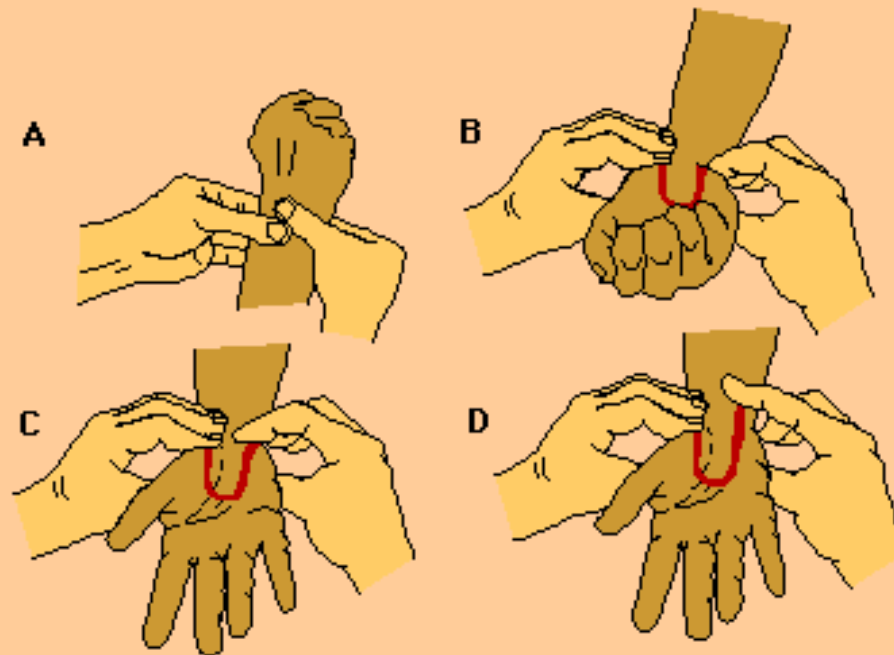
Anatomy of the radial artery Schematic representation of the arterial supply to the ventral surface of the hand. Collateral circulation to the radial artery is provided by the ulnar artery through the deep and superficial volar arterial arches. (Redrawn from American Heart Association. Textbook of





Preparing to perform the Procedure:

- Make sure you and the patient are comfortable.
- Assess the patency of the radial and ulnar arteries.



Modified Allen's test The patient's hand is initially held high while the fist is clenched and both radial and ulnar arteries are compressed (A); this allows the blood to drain from the hand. The hand is then lowered (B) and the fist is opened (C). After pressure is released over the ulnar artery (D), color should return to the hand within six seconds, indicating a patent ulnar artery and an intact superficial palmar arch. (Redrawn from American Heart Association. Textbook of Advanced Cardiac Life Support, 1994.)

Collection Problems:

- Type of syringe
 - Plastic vs. glass
- Use of heparin
- Air bubbles
- Specimen handling and transport

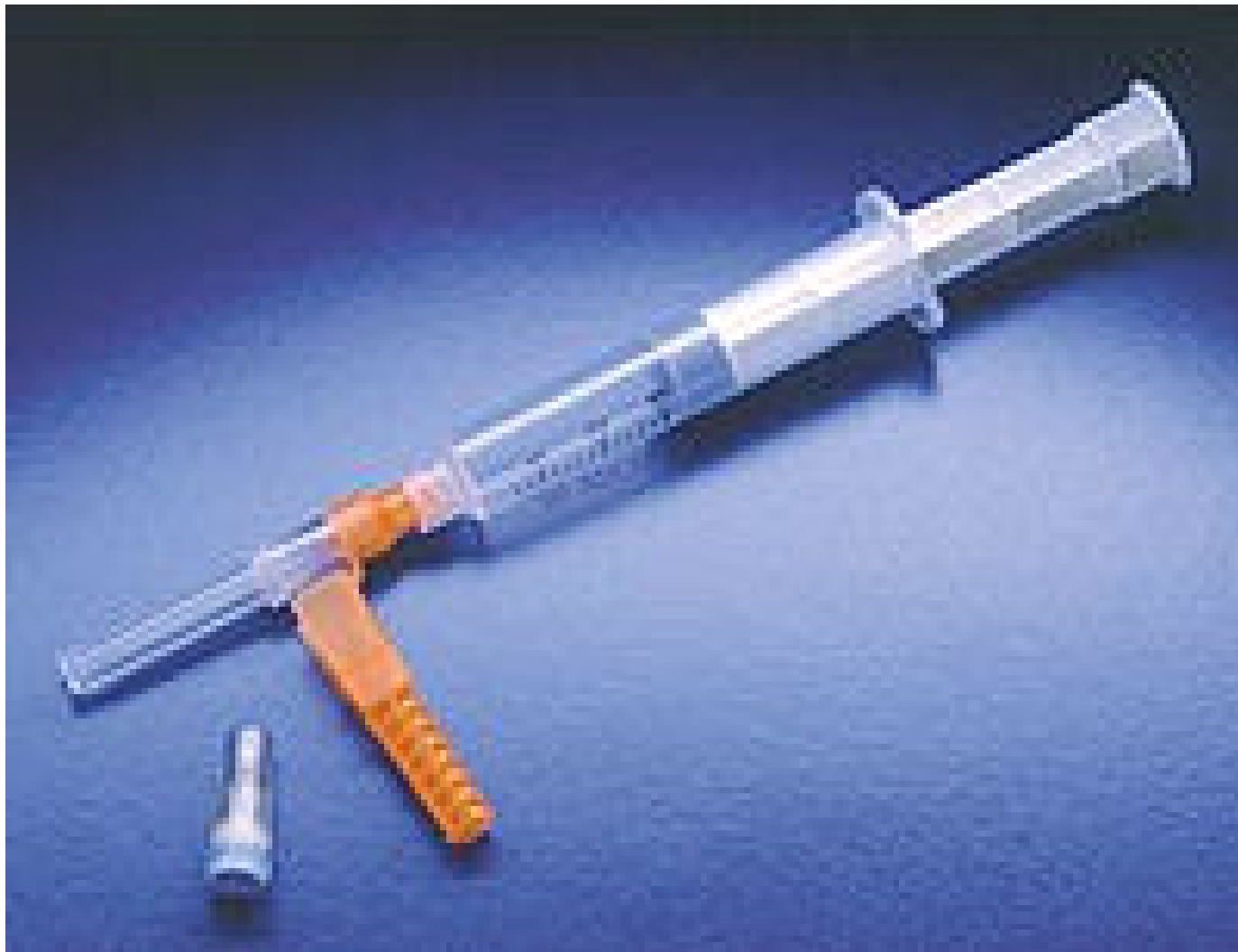Type of Syringe

- Glass-
 - Impermeable to gases
 - Expensive and impractical
- Plastic-
 - Somewhat permeable to gases
 - Disposable and inexpensive

Heparin

- Liquid
 - Dilutional effect if <2-3 ml of blood collected
- Preloaded dry heparin powder
 - Eliminates dilution problem
 - Mixing becomes more important
 - May alter sodium or potassium levels

The Kit



Air bubbles

- Gas equilibration between ambient air ($pO_2 \sim 150$, $pCO_2 \sim 0$) and arterial blood.
- pO_2 will begin to rise, pCO_2 will fall
- Effect is a function of duration of exposure and surface area of air bubble.
- Effect is amplified by pneumatic tube transport.

Transport

- After specimen collected and air bubble removed, gently mix and invert syringe.
- Because the wbc's are metabolically active, they will consume oxygen.
- Plastic syringes are gas permeable.
- Key: Minimize time from sample acquisition to analysis.

Transport

- Placing the AGB on ice may help minimize changes, depending on the type of syringe, pO₂ and white blood cell count.
- Its probably not as important if the specimen is delivered immediately.

Performing the Procedure:

- Put on gloves
- Prepare the site
 - Drape the bed
 - Cleanse the radial area with a alcohol
- Position the wrist (hyper-extended, using a rolled up towel if necessary)
- Palpate the arterial pulse and visualize the course of the artery.

Performing the Procedure:

- If you are going to use local anesthetic, infiltrate the skin with 2% xylocaine.
- Open the ABG kit
- Line the needle up with the artery, bevel side up.
- Enter the artery and allow the syringe to fill spontaneously.


Performing the Procedure:

- Withdraw the needle and hold pressure on the site.
- Protect needle
- Remove any air bubbles
- Gently mix the specimen by rolling it between your palms
- Place the specimen on ice and transport to lab immediately.

PELVIC EXAMINATION

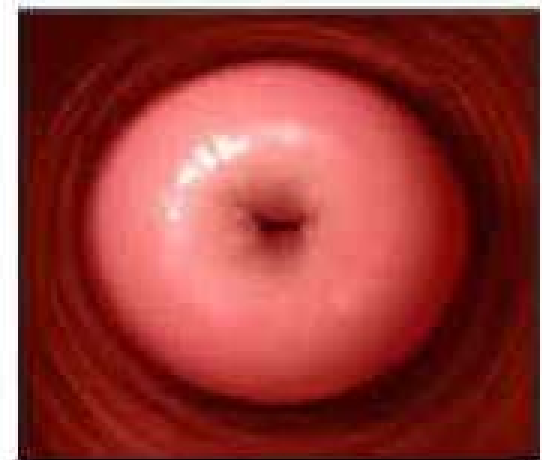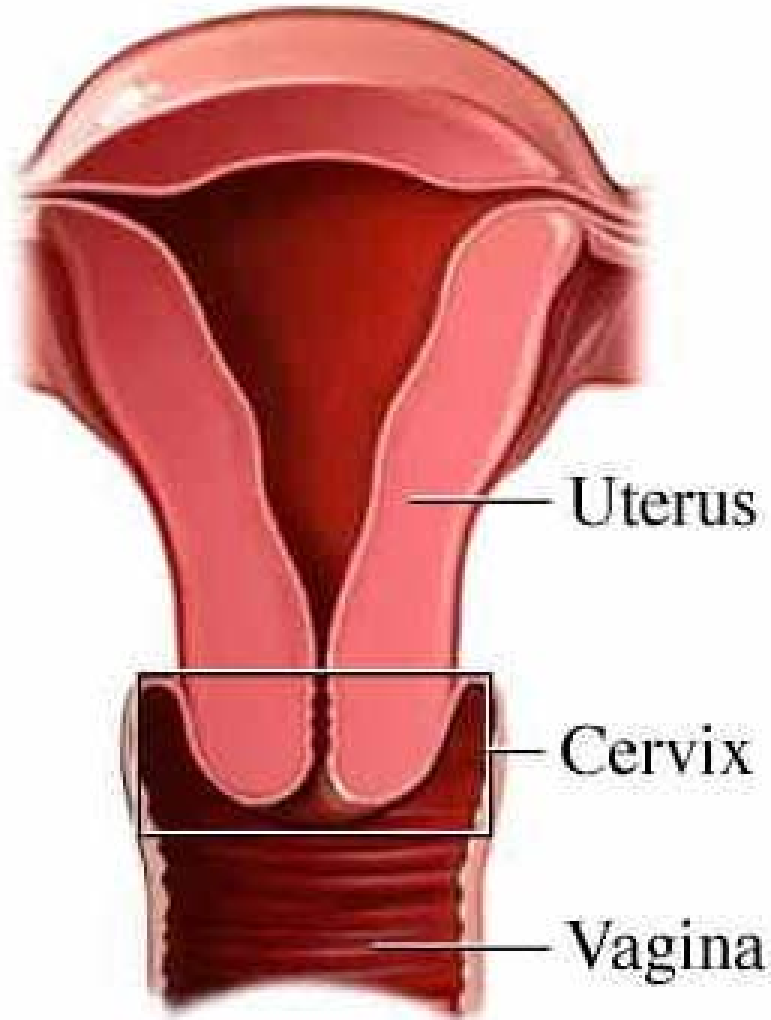



SHAN KESHRI
CLINICAL SESSIONS



MASARYK UNIVERSITY
FACULTY OF MEDICINE

Anatomical bearings



Cervix viewed
from below

INDICATIONS




- Vulva / Vaginal complaints
 - Pain, discharge, abnormal bleeding, itching, mass
- Pregnancy suspected / proven
- Exposure to STI (HPV is a factor in nearly all cases of cervical cancer!)

SCREENING PRECANCEROUS LESIONS OF CERVIX - Method



- Cervical Pap Smear
 - WHAT : Take specimen of cells of cervix for microscope examination
 - WHY : Identify cancerous changes (ep. cell abnormality) early in women at risk

SCREENING PRECANCEROUS LESIONS OF CERVIX - Guidelines



START :

- 3 years after onset of sexual activity
- 21 yrs age


CONTINUE :

- Annually until age 30
- 30yrs+, with 3 consecutive normal pap smears
 - then only need testing once per 3 years unless present with a risk factor e.g. STI, new sex partner


STOP :

- Total hysterectomy
- Low Risk women aged 65-70

PROCEDURE




- History
- Patient preparation (lithotomy position)
- External examination (vulva & glands)
- Internal examination (cervix & vaginal walls)
- Bi-Manual examination (vagina, cervix, uterus, adnexa (ovaries))
- Recto-Vaginal examination (surrounding structures)



HISTORY

- LMP : Last Menstrual Period date?
- History of abnormal pap smears?
- Birth control usage?
- Vulva and vaginal symptoms? (see 'indications')
- Num. sexual partners?, Sex. Orientation?
- STI concerns?
- Discomfort in previous pelvic exams?
- Post-menopausal?
- Pregnant?
- Hormone replacement therapy?



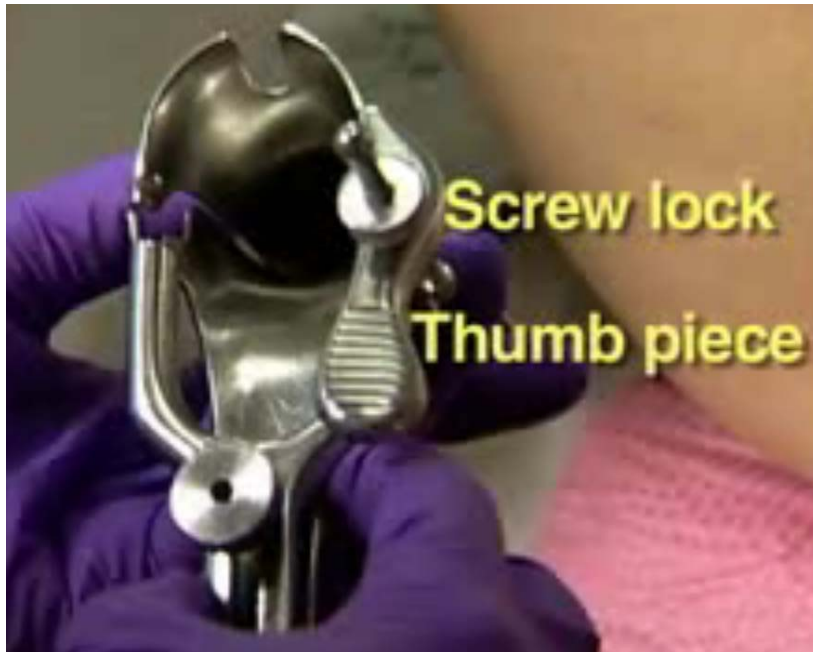WASH HANDS & GLOVE UP!




EQUIPMENT



- Speculum (check screw is working)

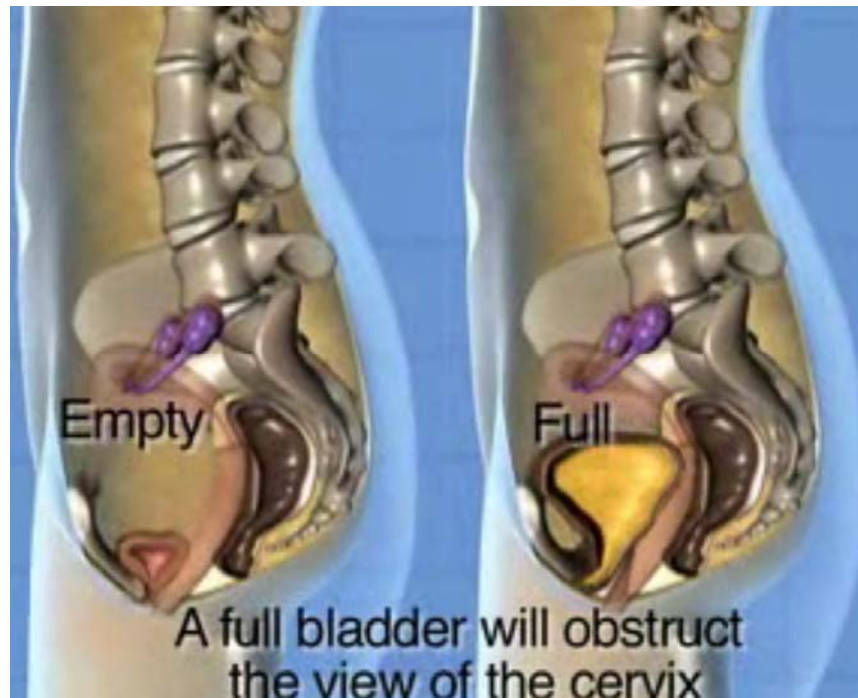


- Water Soluble Lubricant
- Light Source



PATIENT PREPARATION

- Make sure patient has emptied bladder before exam!





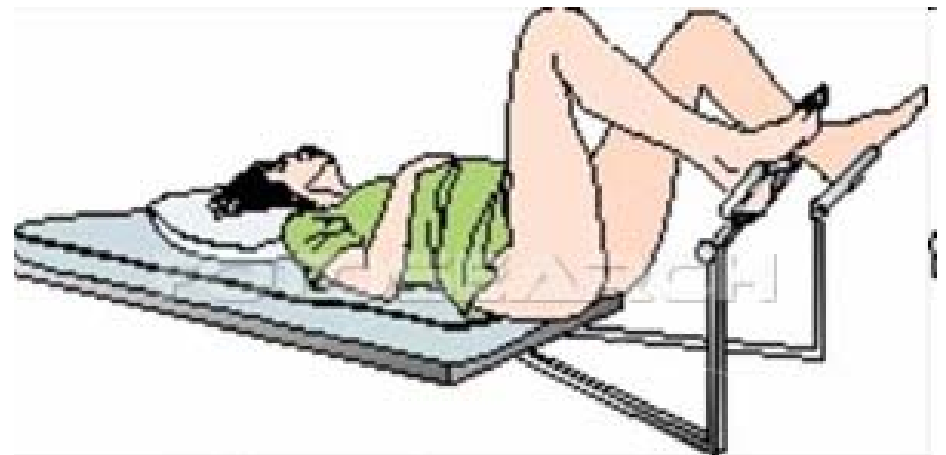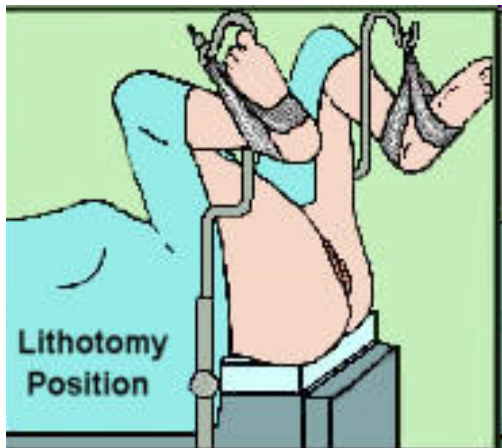
Change to gown (privacy) – sit on exam table, with drape covering legs.


- Offer to have a chaperone in room whilst you conduct examination!!!
- **COMMUNICATE:**
 - Explain procedure to patient, alert them before you insert / retract / move anything!



LITHOTOMY POSITION

- Lay down on table
- Guide feet into stirrups
- Ask 'slide buttocks to end of table'
- Relax legs into abduction
- Ensure she is draped for minimal exposure!





EXTERNAL EXAMINATION

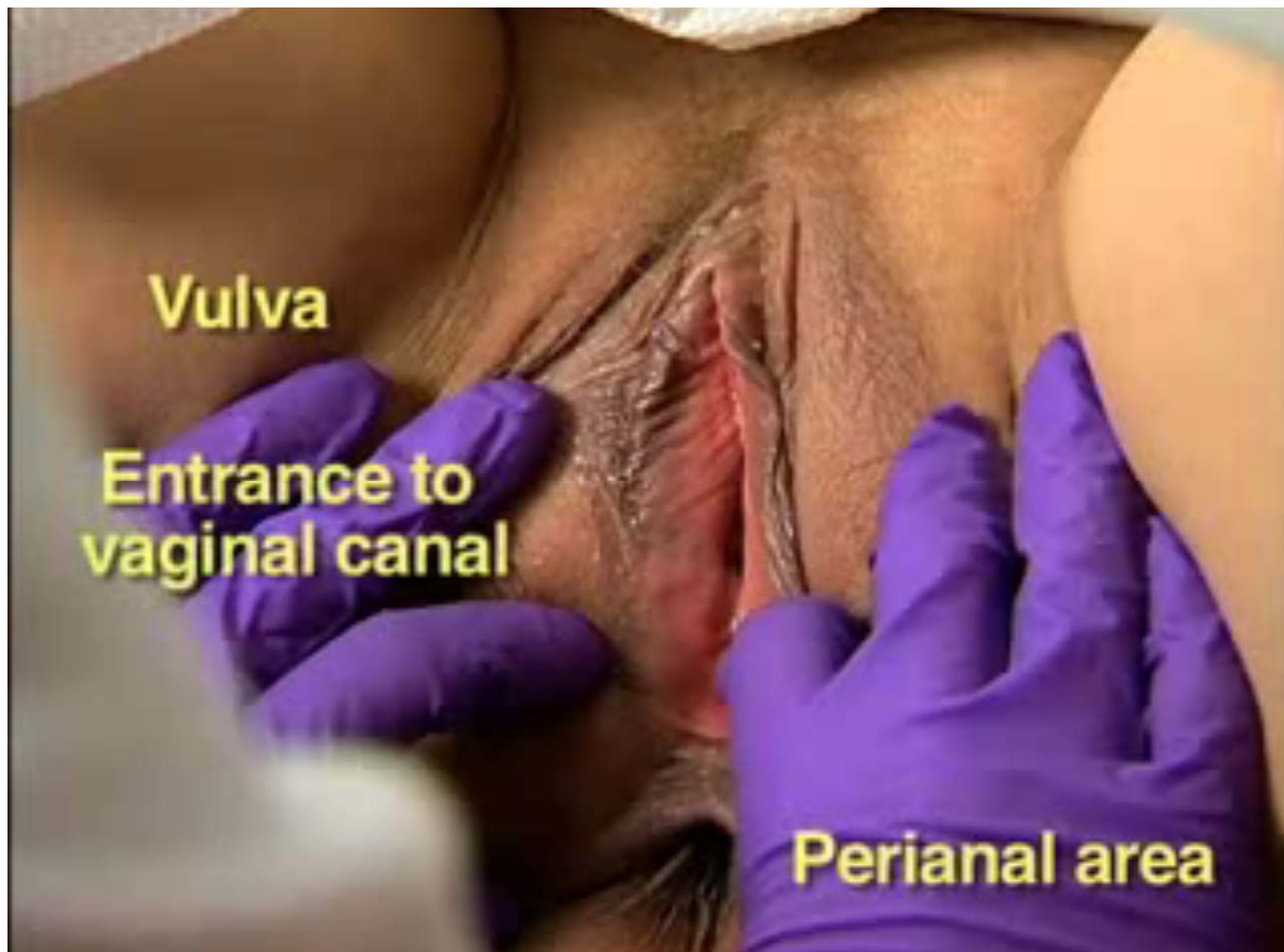(vulva & glands)



WARNING

explicit graphics

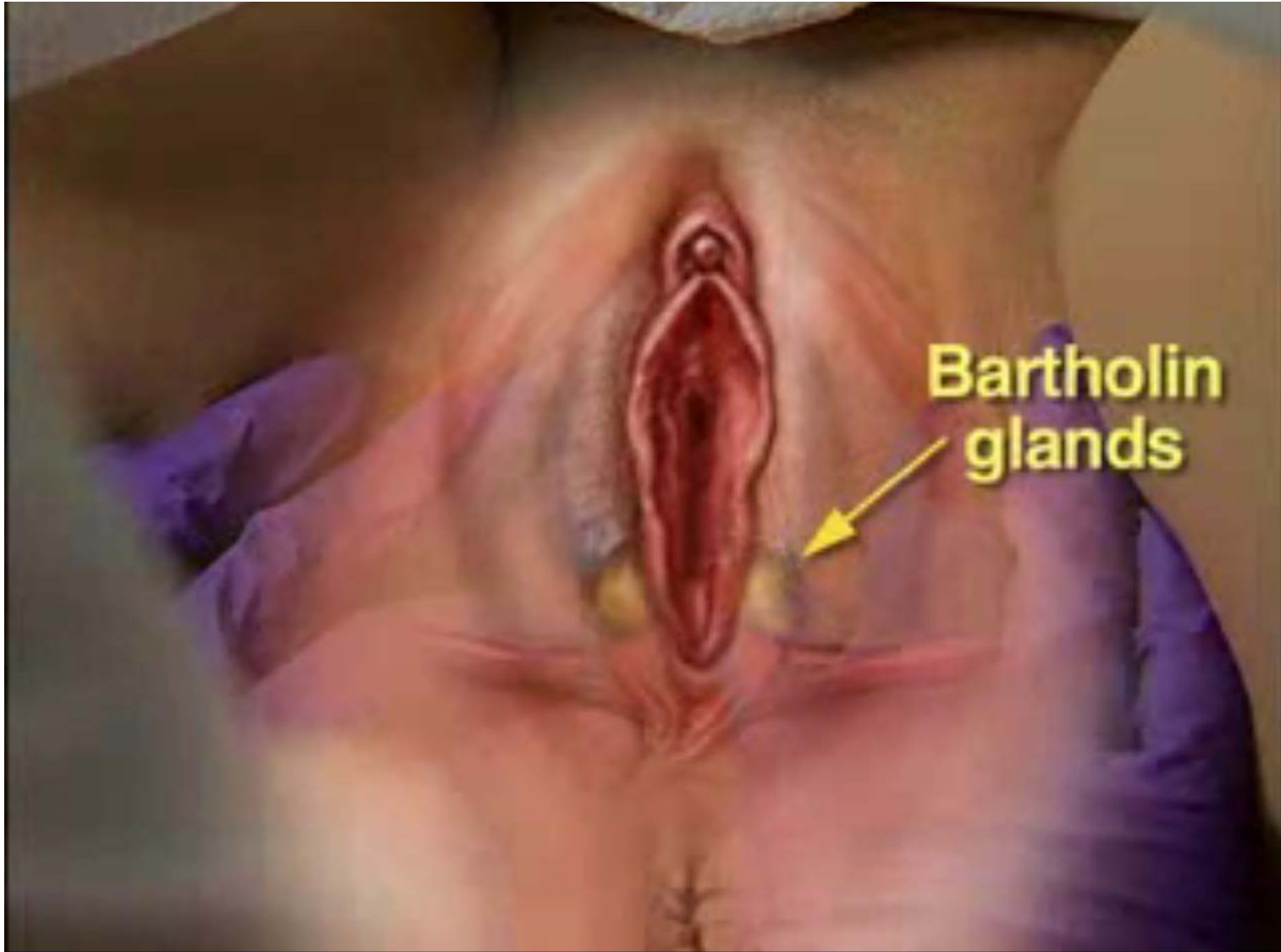
**DISCRETION
IS ADVISED**




Vulva

**Entrance to
vaginal canal**

Perianal area



**Bartholin
glands**

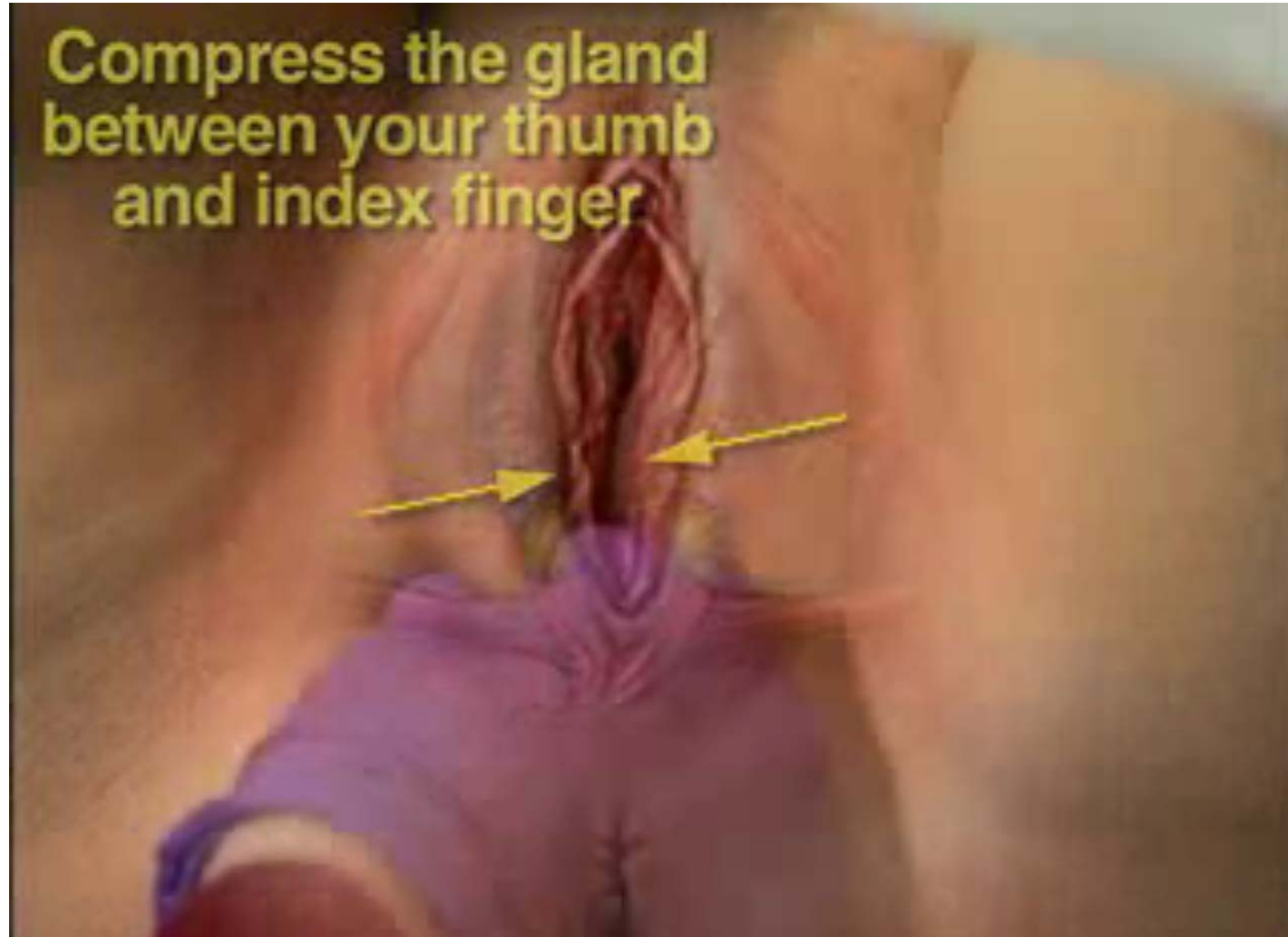



How to Examine Bartholin Glands

- Separate labia with non dominant hand
- Place Index finger of dominant hand into introitus (entrance)
+- lubricant



How to Examine Bartholin Glands

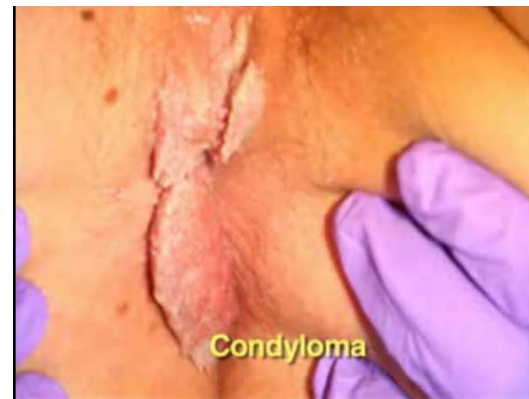
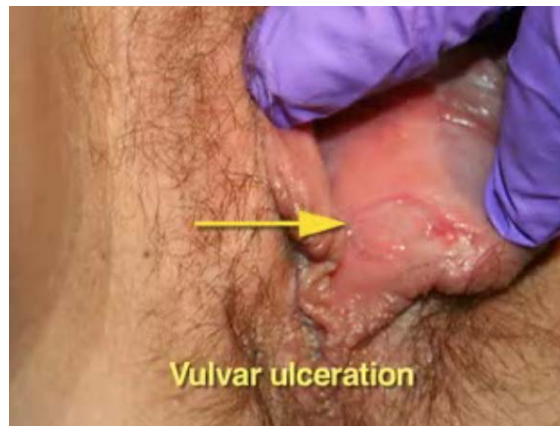
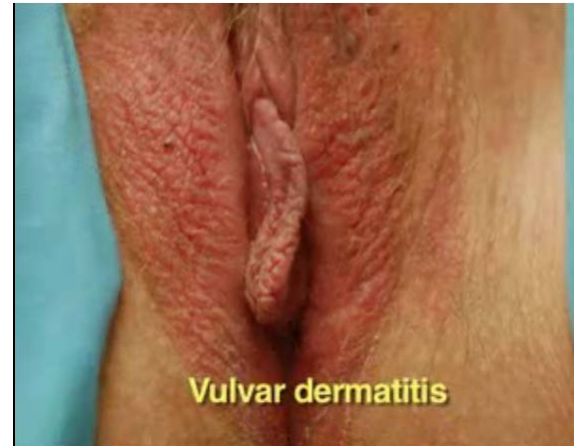
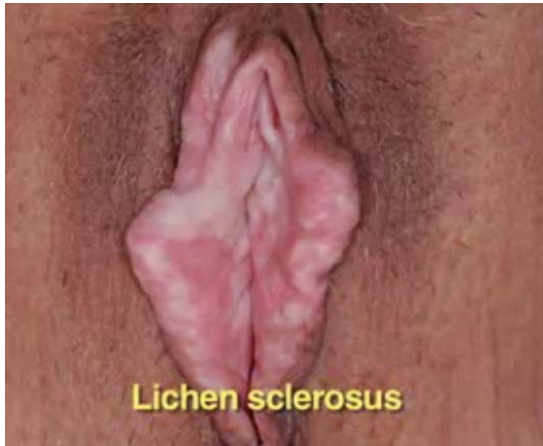
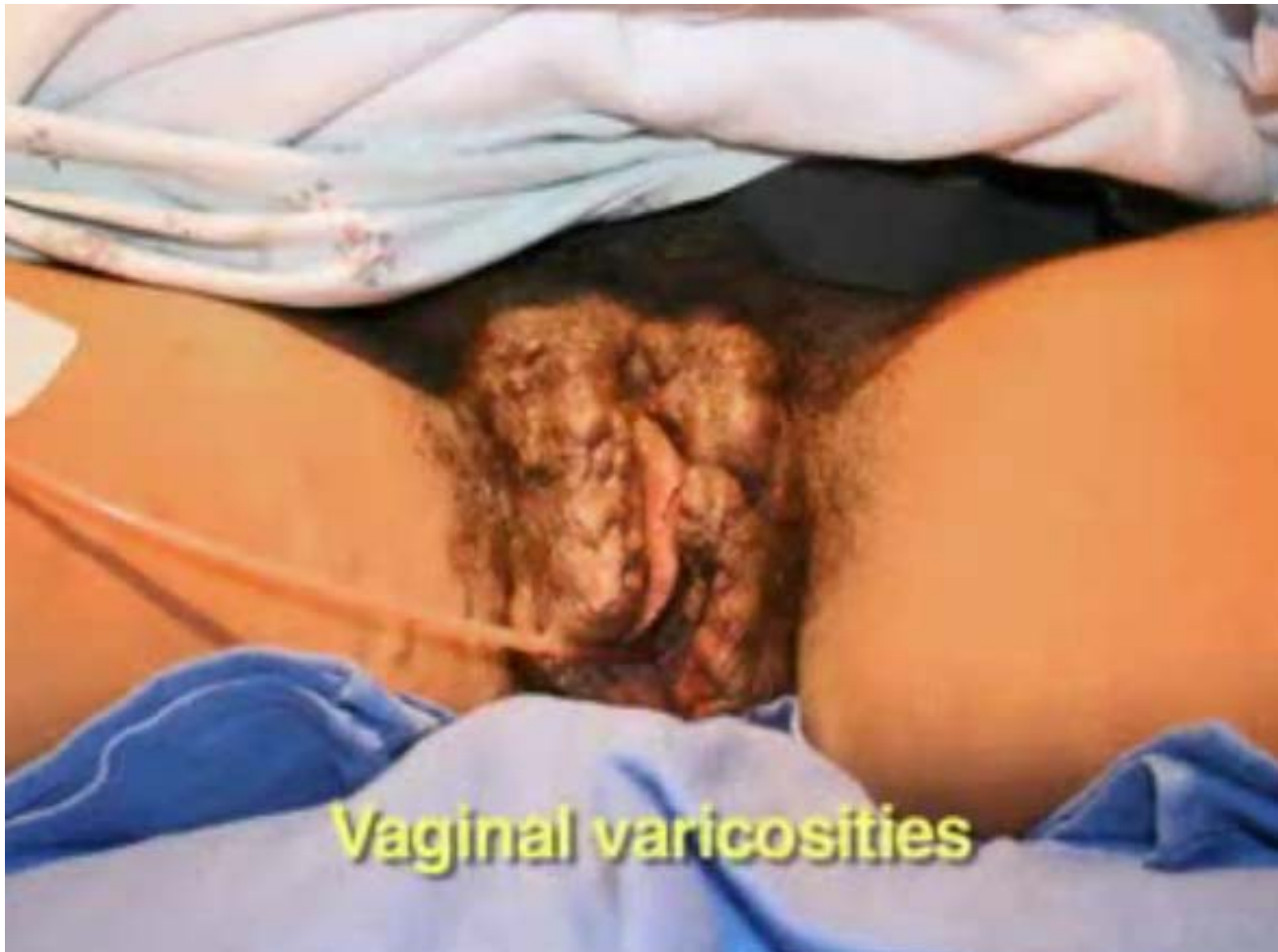Examine for what?

- Erythema
- Swelling
- Masses
- Rashes
- Tenderness, Discomfort, Irritation, Pain
- Lesions
- Trauma

Pathologies




Pathologies



Vaginal varicosities

- Often assoc. with pregnancy




INTERNAL (SPECULUM) EXAMINATION

(cervix & vaginal walls)

& Cervical pap smear

Preparation

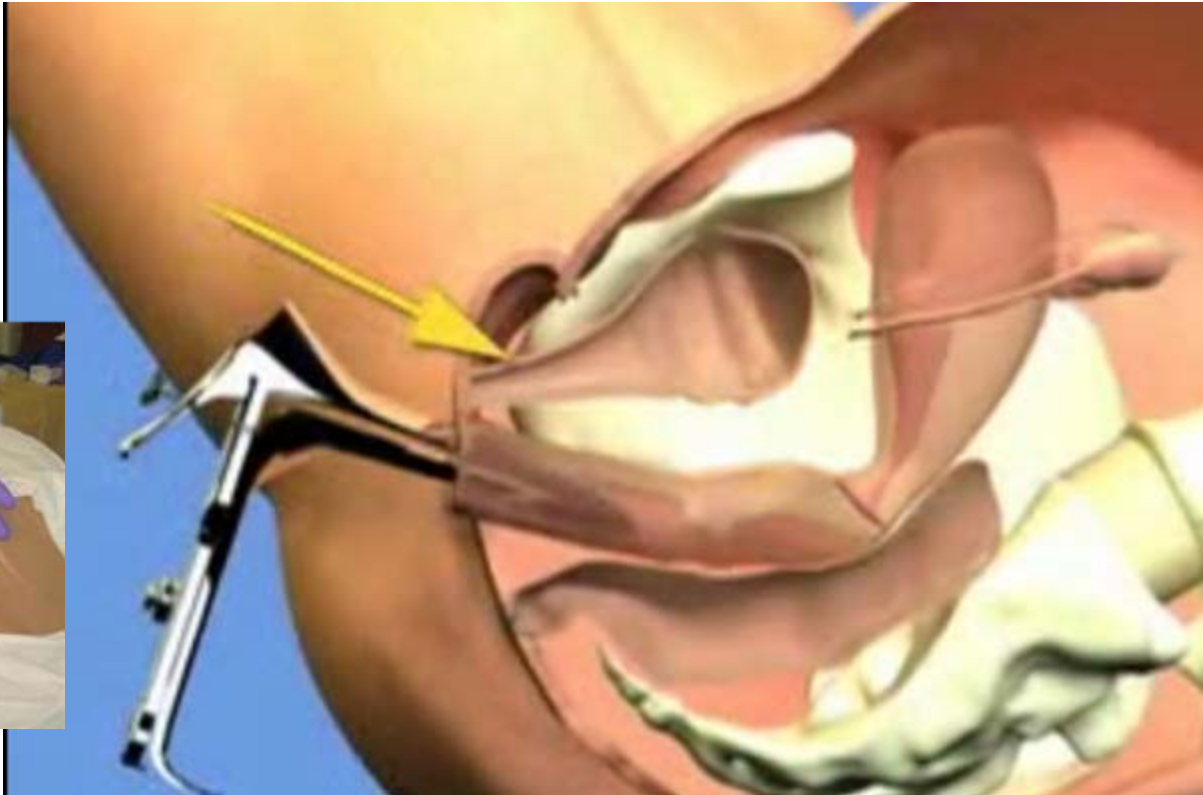
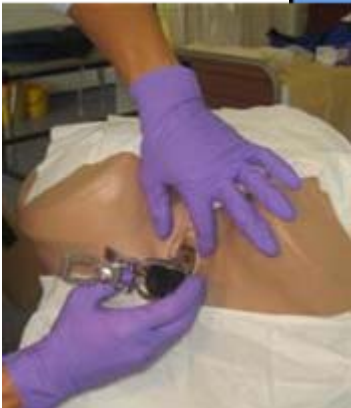


- Wear clean gloves
- Warm Speculum with warm water (check comfortable temp by touching it to thigh)
- Apply water based lubricant to speculum



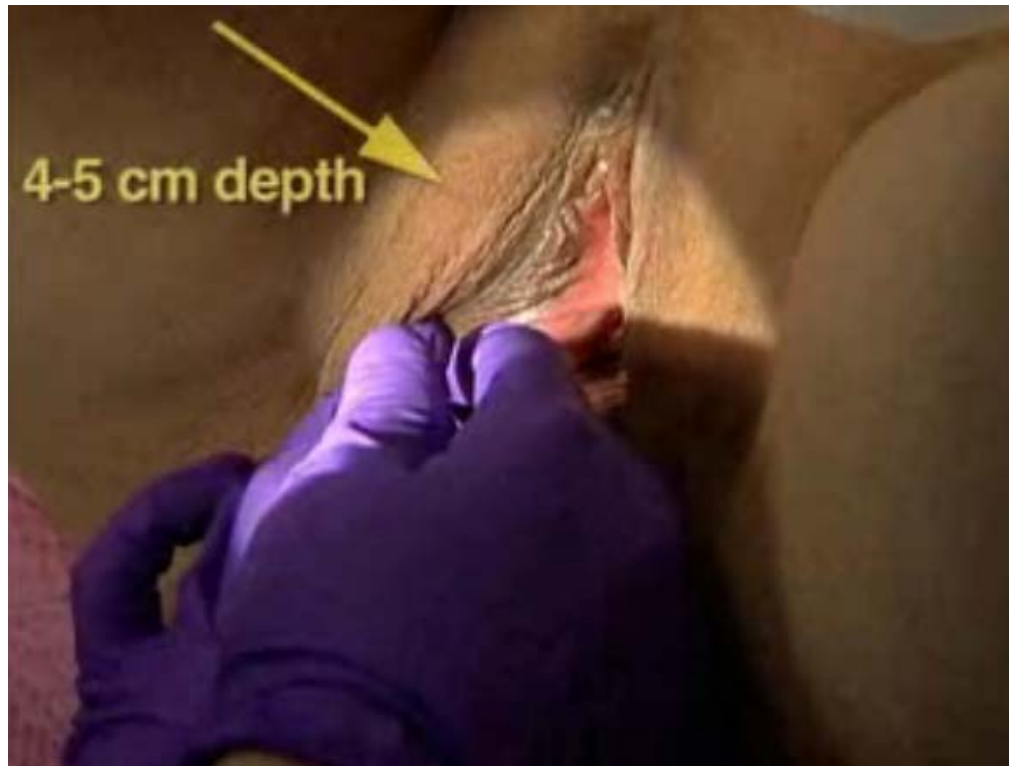Insert Speculum

- Part labia minor & insert gently & slowly at slight downward angle (care with urethra)



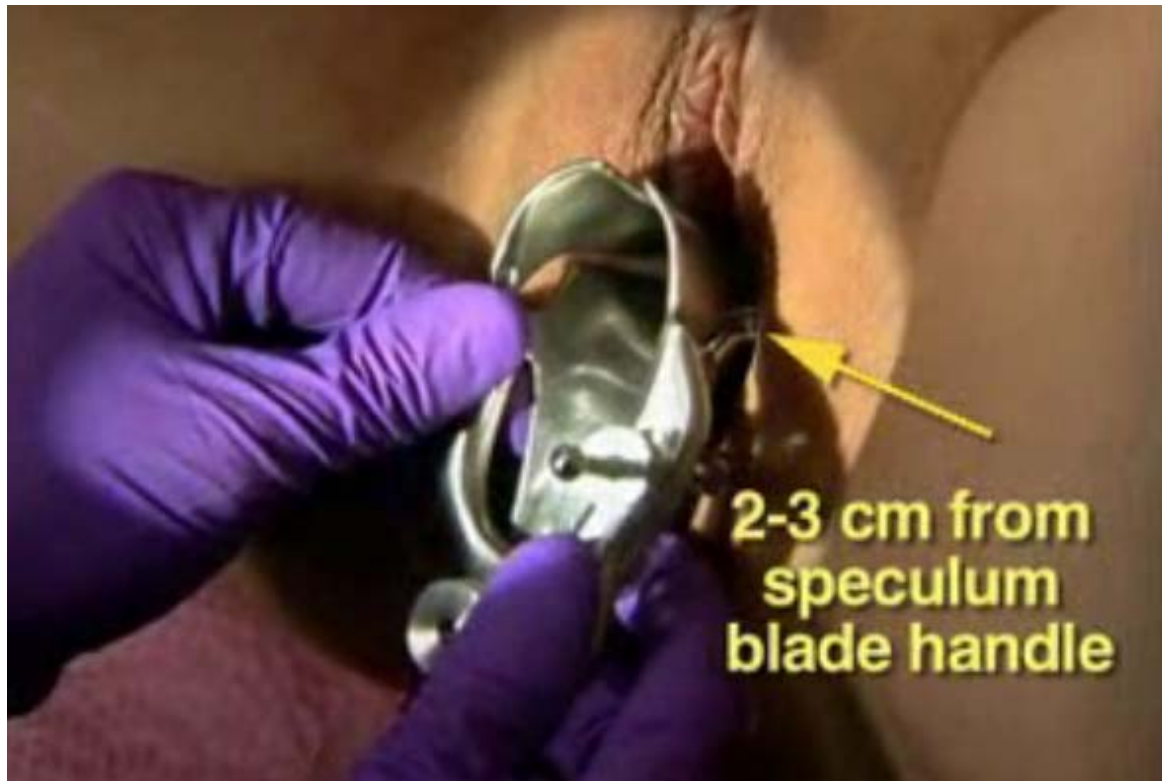


- Once past introitus (entrance of canal), insert into vagina using downward pressure to depth 4-5cm.



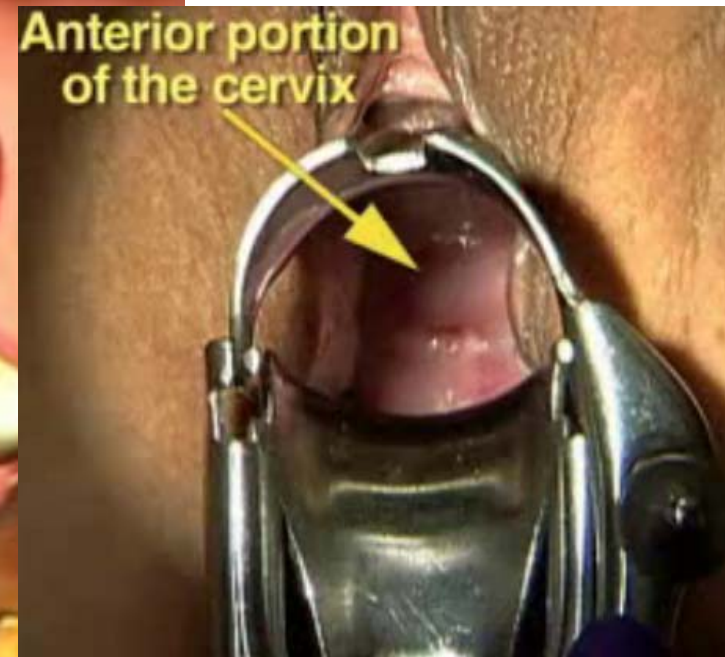
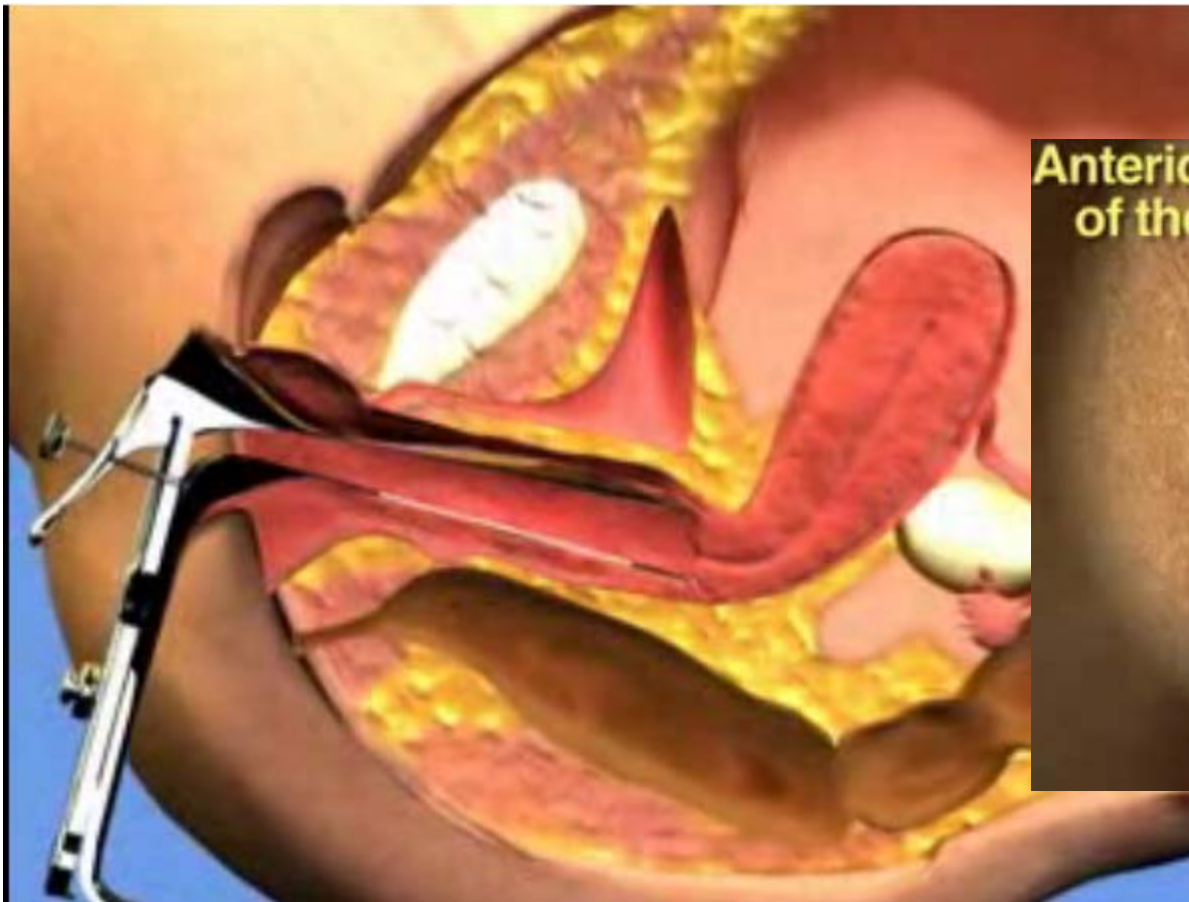

- Speculum handle 2cm away from introitus
- Only then, Open speculum



Visualise Cervix

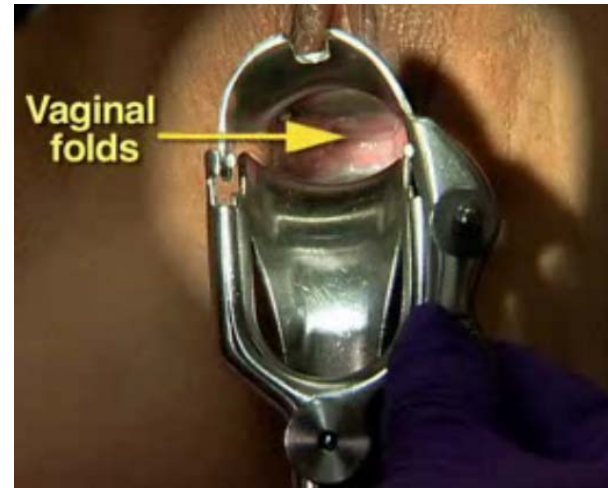- Smooth & firm & shiny



Problem finding cervix?




- Find vaginal fold to guide

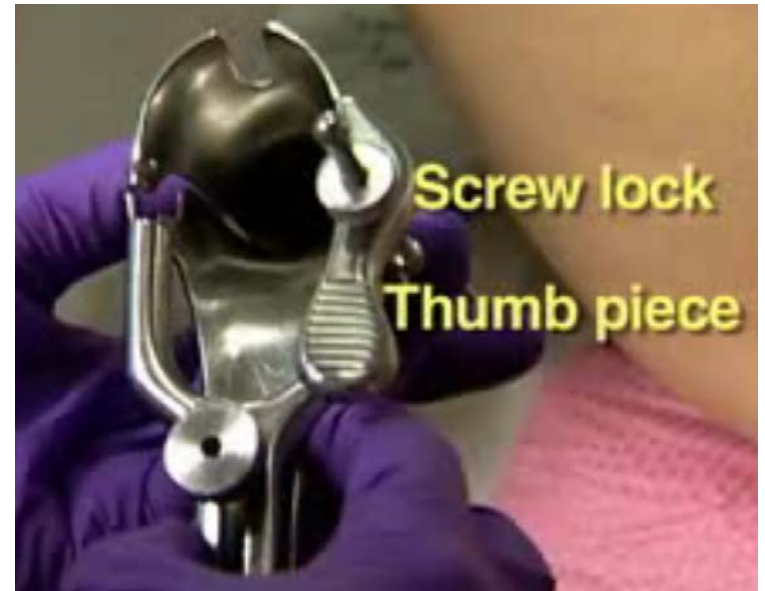

- Close speculum, back up 1-2 cm & reinsert back into vagina (using downward pressure) in direction of vaginal folds
- Re-open slightly and search for cervix.
- May need to repeat many times!

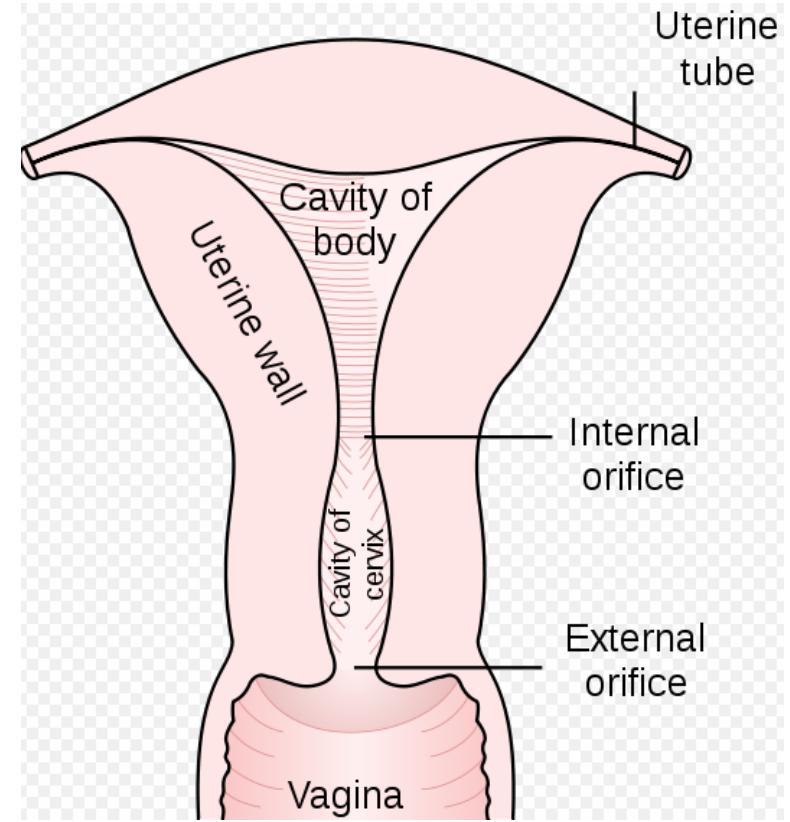
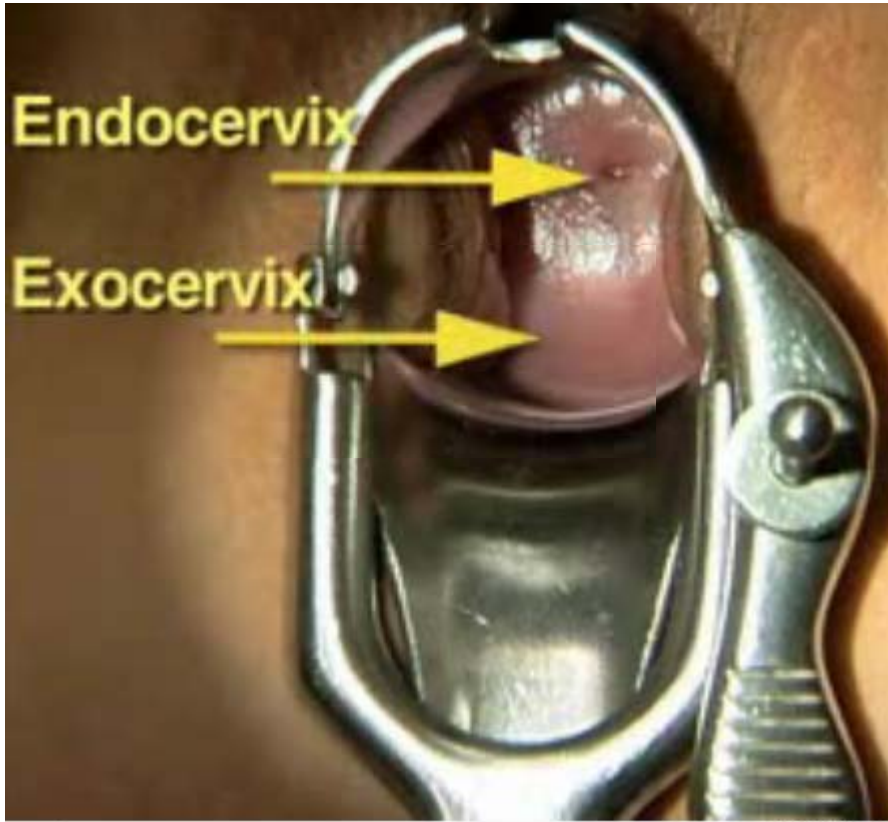

Once found cervix:




- Open speculum further, and lock in place by turning down the screw on thumb piece.



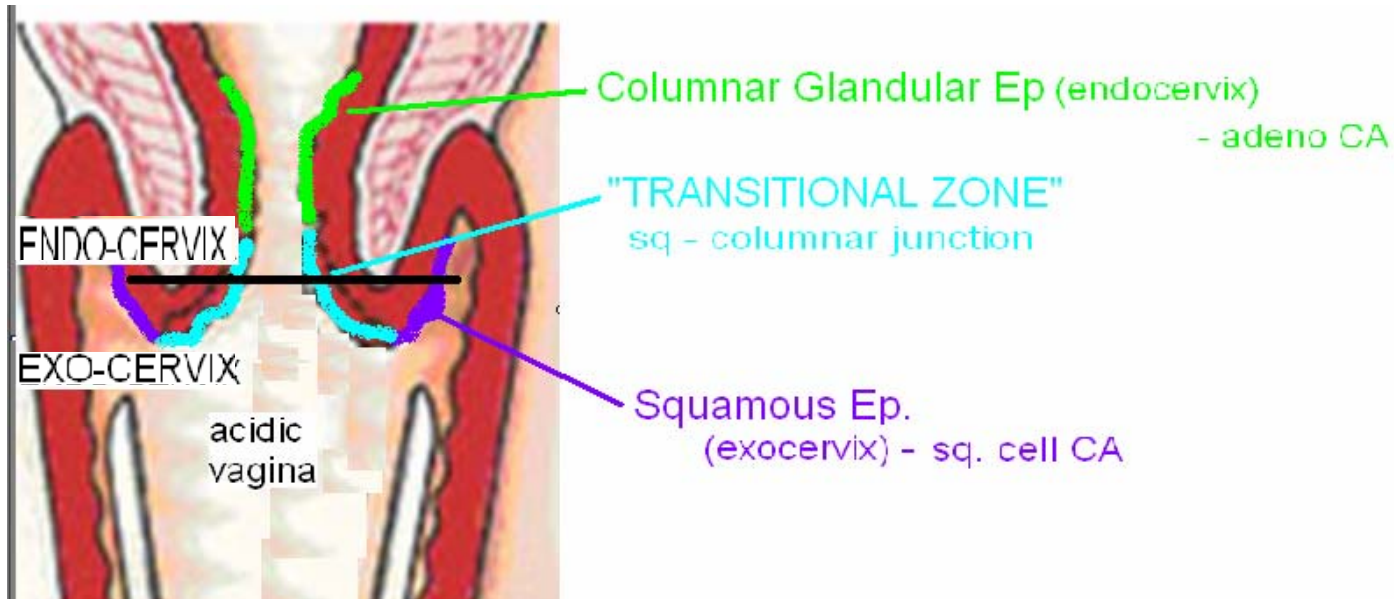
Take Specimen



Revise Pathology:




- Remember, Cervical cancer arises from the transitional zone of cervix (most vulnerable)

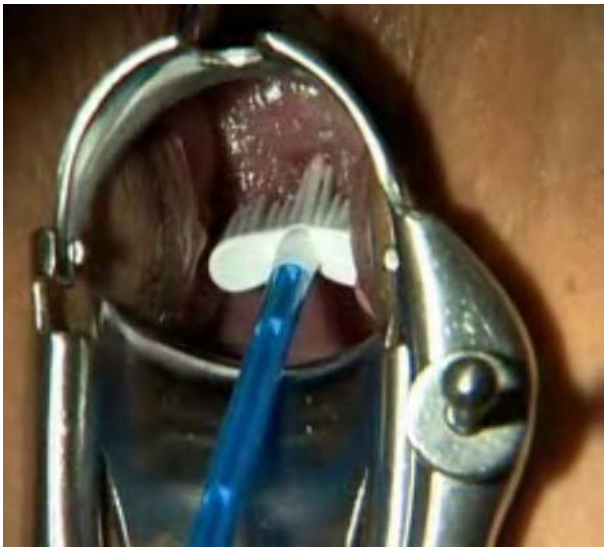

- Pre-pubertal: junction lies in endocervix
- Post-pubertal: junction MOVES to exocervix, exposed to acid of vagina and undergoes sq. metaplasia.
- Transitional zone is area between pre pubertal junction & post pubertal junction.

Liquid Based Technique (endocervix)



- Rotate broom shaped brush

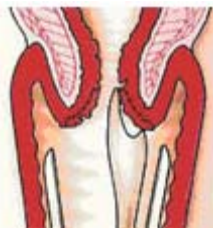
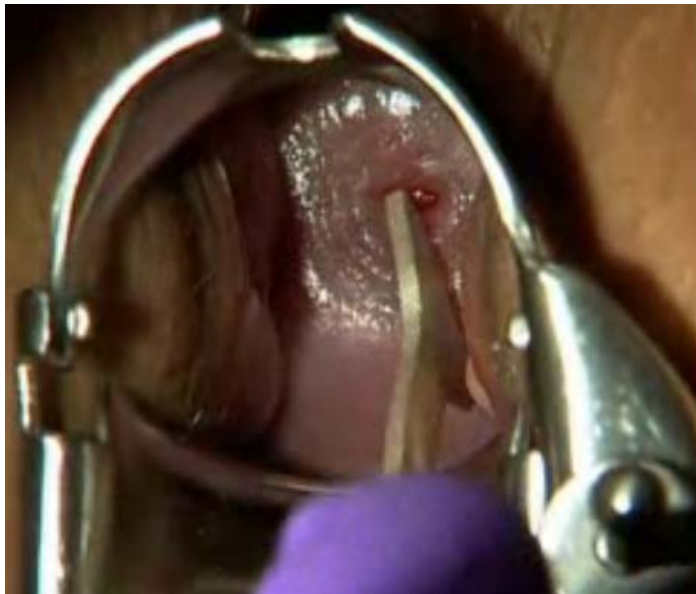

- Disconnect handle, and place brush in liquid based pap container. (maintain Sterile Conditions)

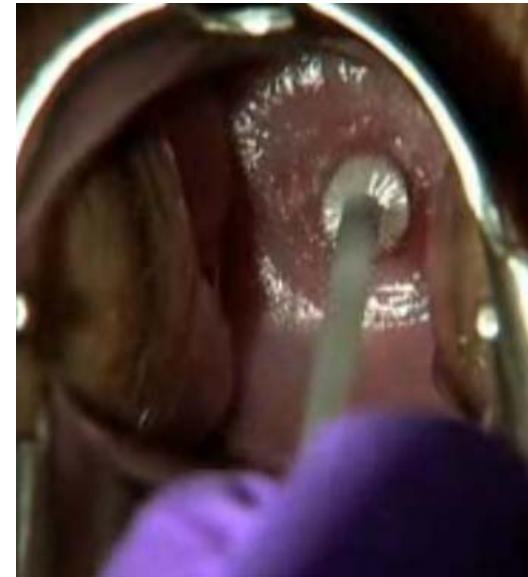Glass Slide Technique (endocervix)



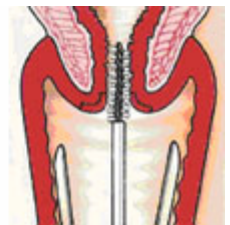
- Rotate wooden spatula




- Then, Rotate Endo-Brush in internal cervical os

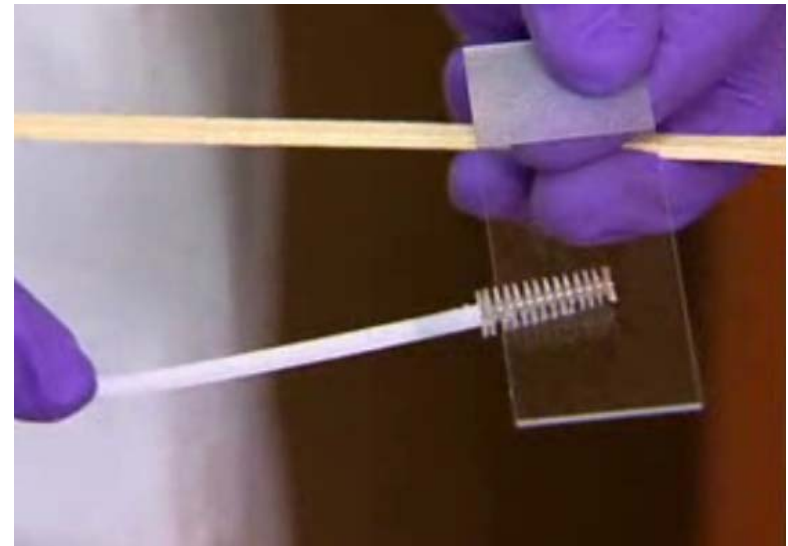



1. The round brush only samples endocervical cells. A spatula is still necessary for the ectocervical area.






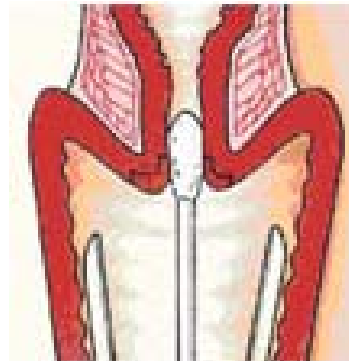
- Transfer specimen to slide



- Apply fixative to slide



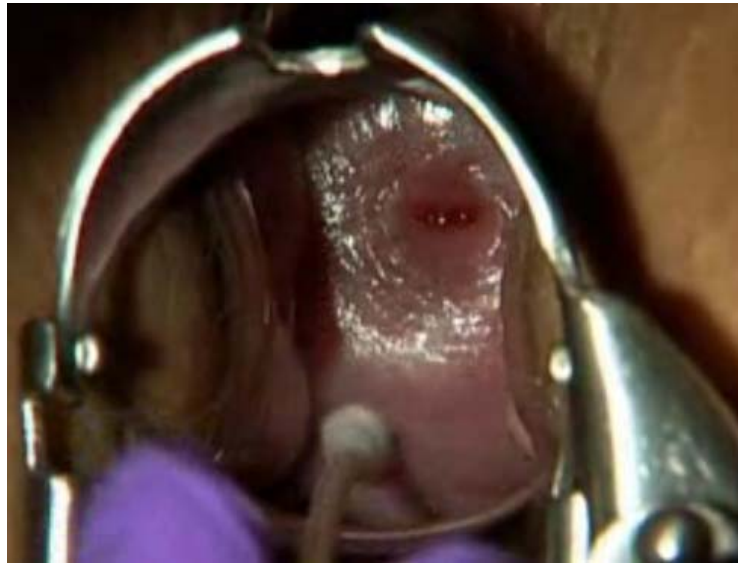- Cotton bud can be used instead of endo-brush in pregnant women to minimise risk of bleeding and irritation.





ExoCervix Specimen

- Cotton tip swab: sample vaginal discharge and exocervix for wet mount or cerv. culture. (e.g. AMIES media)

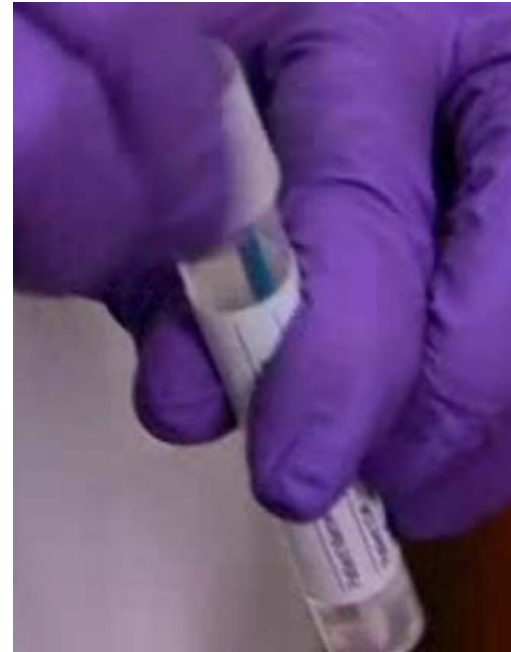
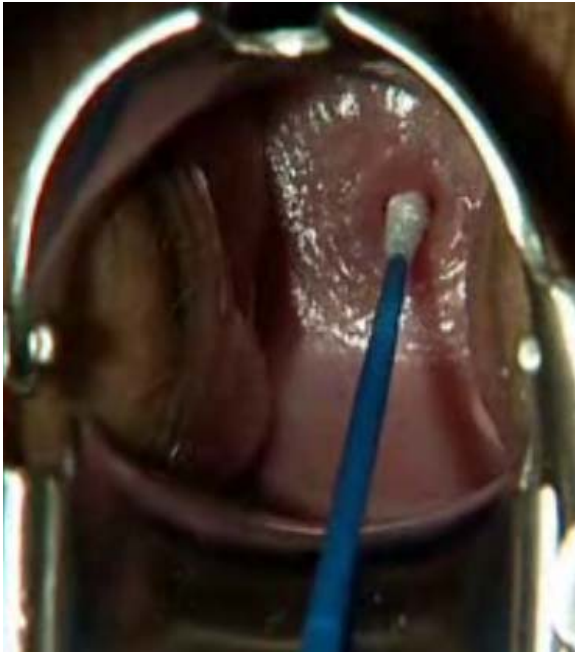

- Use swab to check pH (normal acidic = 4 / yellow pH paper)
 - Blue (alkaline) : infection



DNA, Gonococcal, Chlamydiae probes

- Position cotton tip swab in cervical os for 30s
- Place directly into medium provided & label






- If needed, a biopsy can be taken for histological examination.

Remove Speculum



- Warn patient before
- Unscrew lock and gently retract
- Slowly close blades as you retract. Observe vaginal walls.
- Blade should be completely closed when exiting introitus




After effects

- Warn there may be a small amount of bleeding

Risks

- No Medical Risks of pap smear




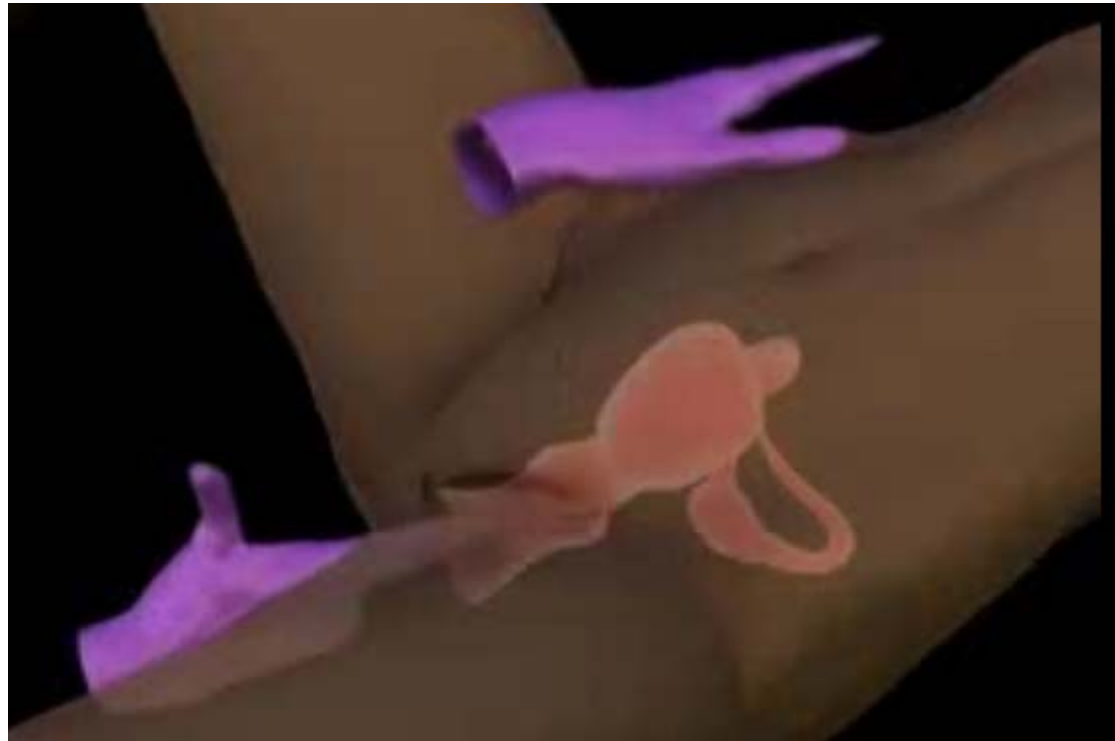
BIMANUAL VAGINAL EXAMINATION

(vagina, cervix, uterus, adnexa (ovaries))

- Insert index and middle finger of dominant hand into vagina, to palpate vagina, cervix and uterus & adnexa.

+/- lubricant

- Use non dominant hand to press on abdomen to push pelvic organs towards palpating dominant hand (which elevates them)







Try to notice:

- Size
- Shape
- Tenderness
- Mobility
- Position
- Masses

- Vaginal walls
 - with fingers
- Cervix
 - with fingertips
- Uterus
 - with fingertips and pressure on abdomen
- Ovaries (adnexa)
 - e.g. fingers in right fornix and pressure externally on right iliac fossa
 - mobile ovaries (2x3cm)




- Remove fingers
- Check glove for discharge
- Dispose
- Wash Hands




RECTO-VAGINAL EXAMINATION

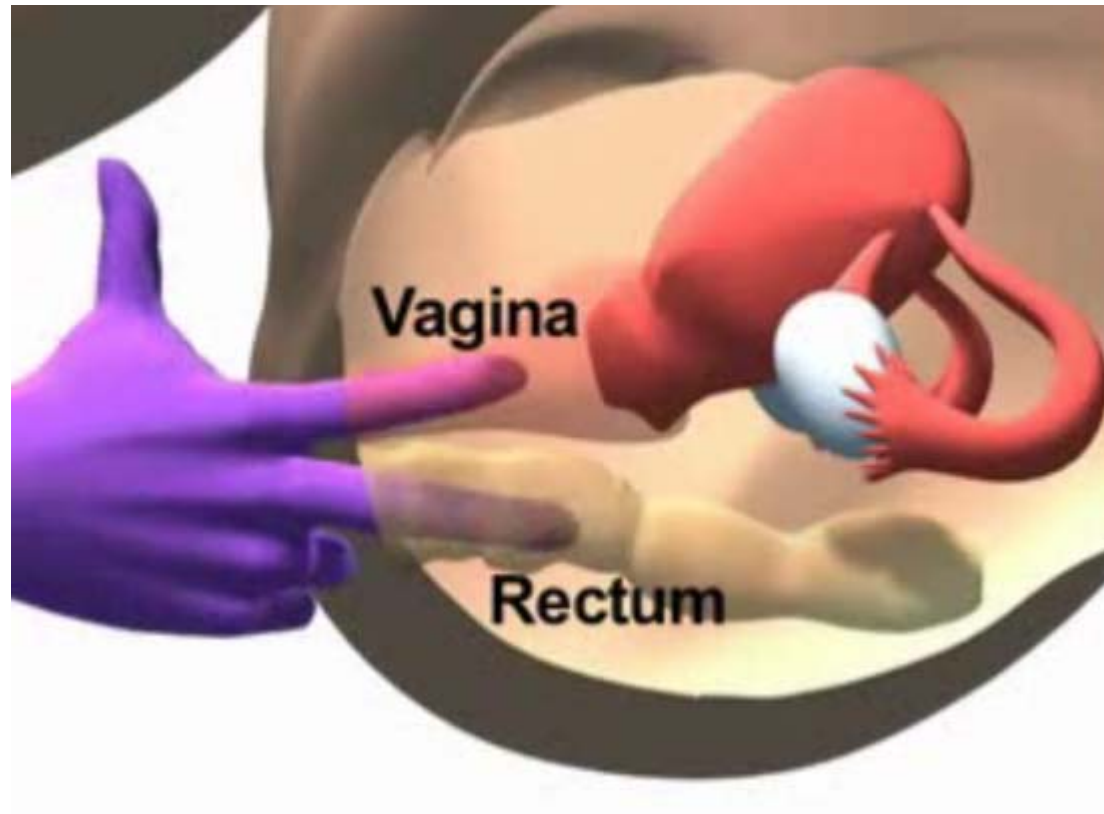
Indications

- Assess retro-verted uterus
- Screen for colorectal cancer (50yrs+)
- Evaluate pelvic pathology





- Insert index finger into vagina and middle finger into rectum. Apply pressure to palpate structures
- Use non-dominant hand to press on abdomen to push pelvic organs towards palpating dominant hand



THANKS FOR LISTENING



Video Links

- Part 1:
 - <http://video.google.com/videoplay?docid=-3683431334751191546&ei=Ch-YS-i3Apa62wLzmdXZAg&q=pelvic+examination#>
- Part 2:
 - <http://video.google.com/videoplay?docid=-3683431334751191546#docid=-1686931554619562136>


Further Reading

- Different types of speculum e.g. Sims?
- Details how to fixate the slides and perform wet mount
- Pathology: Uterine tumors

Clinical Sessions-2

- *Obstetrics' & Gynaecology*
- *Blood pressure investigations*
- *Swab analysis*

**By Arjun Bhusan Keshri &
Saanta Chatziali**



Overview of Obstetrics' and Gynaecology


What is Obstetrics?

Study and management of normal and abnormal pregnancies

Gynaecology?

Describes the study of diseases of the female genital tract and reproductive system as well as the periods of childbirth and postnatal life

Continuum between both subjects, therefore a definitive division is somewhat arbitrary



Common conditions seen in Obstetrics



- **Antenatal disorders;**
 - Hypertension
 - Anaemia (haemoglobin level <11g/dl)
 - Diabetes
- **Antepartum haemorrhages-** bleeding from the vagina after the 24th week of gestation
- **Infections;**
 - Rubella
 - Hepatitis B
 - Herpes simplex
 - HIV
 - Malaria

Common conditions seen in Gynaecology


- **Infections of the genital tract**
 - *Upper;*
 - Gonorrhoea, Chlamydia
 - *Lower;*
 - Genital herpes & warts, syphilis
 - *HIV*

Common CLINICAL SIGNS: Fever, pain, discharges, bleeding, irregular period

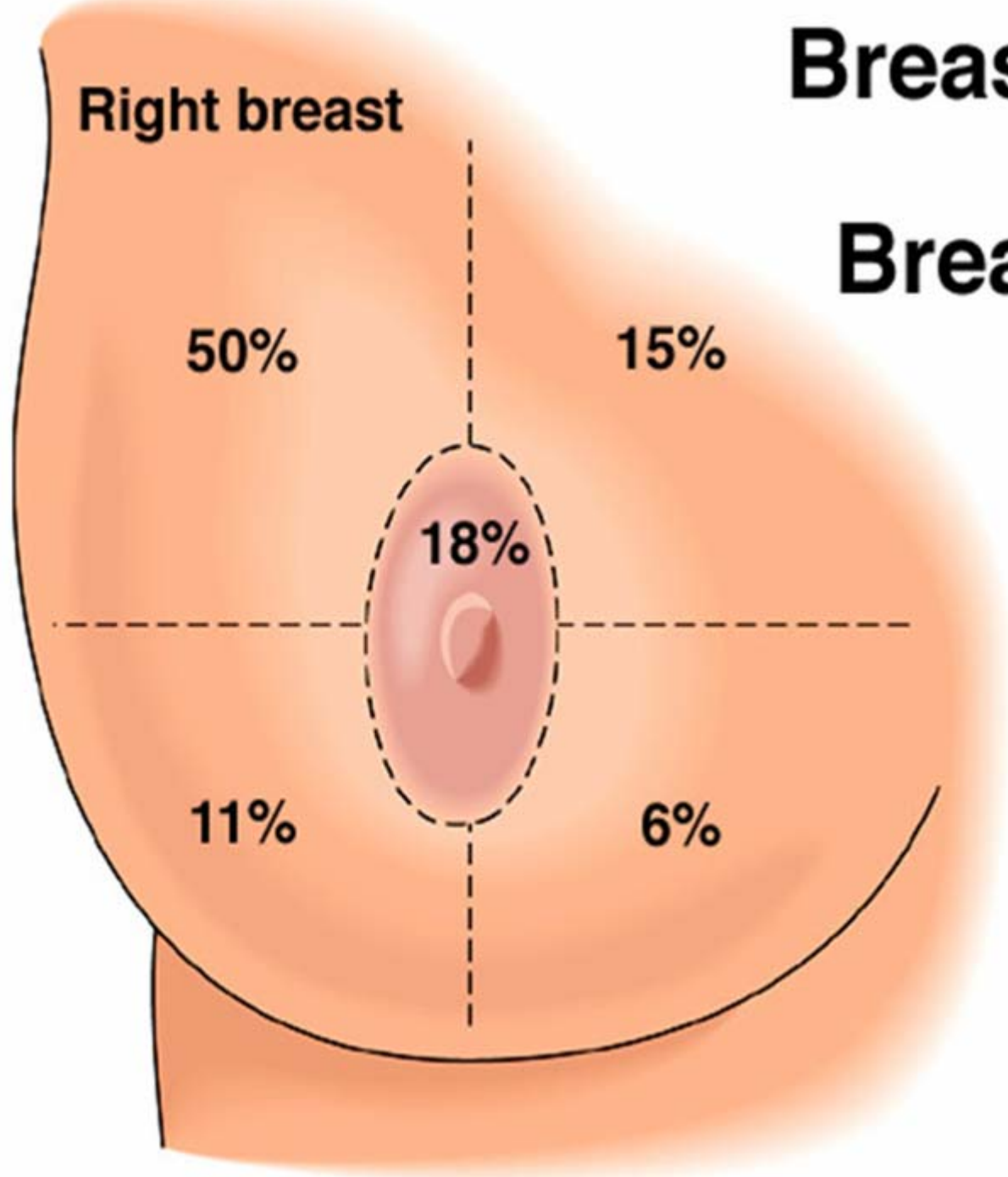
- **Pelvic Pain**
- **Infertility and disorders of sexual function**



Breast Examination



Breast Quadrants and Breast Cancers



When to do the breast examination?

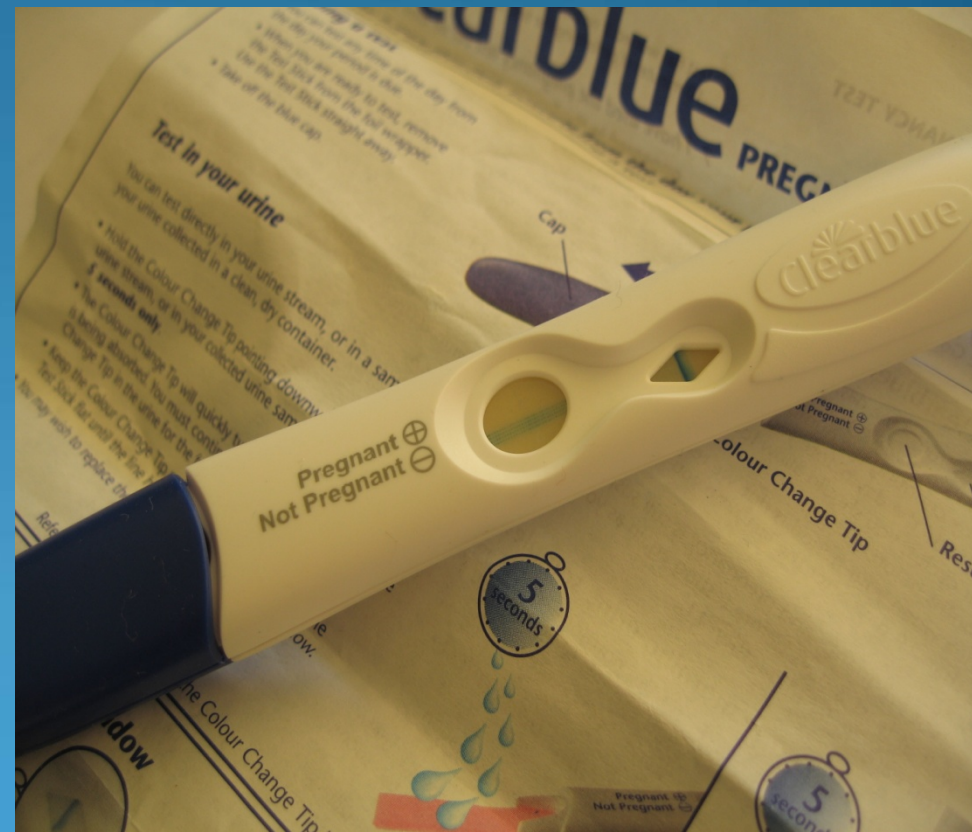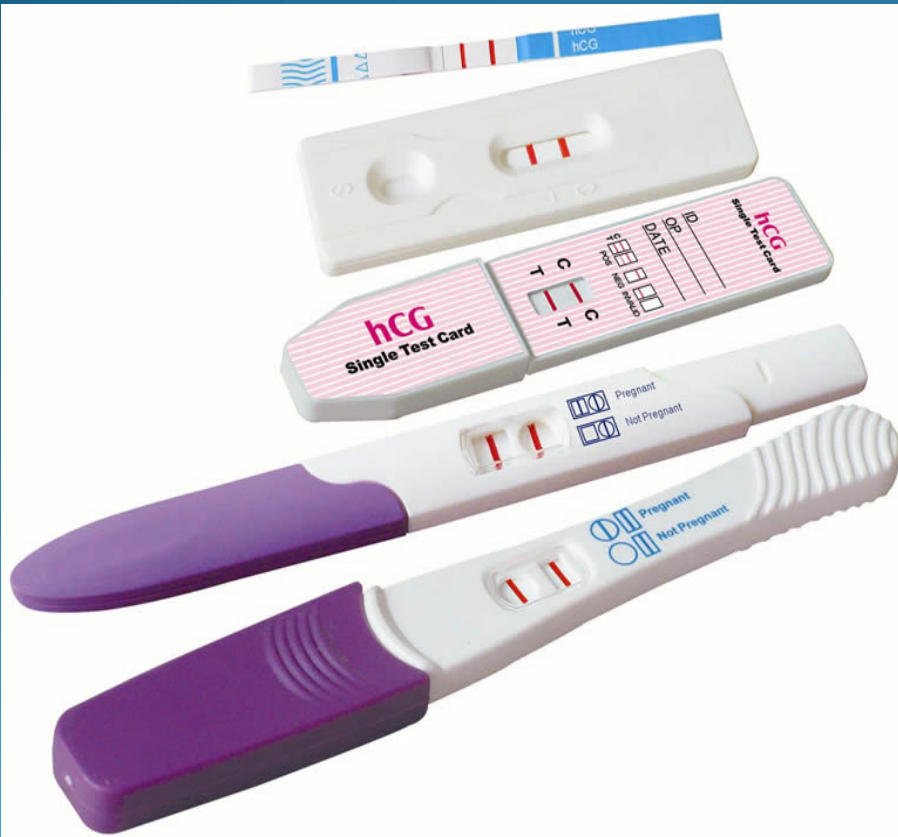- First consultations of women over the age of 45
- Presence of secretions of milk at times **not** associated with pregnancy (galactorrhoea)
- Breast lumps/nodules felt on palpation
- Pain (chart)
- Discoloration or change in the quality of the skin:
 - *Redness suggests infection/inflammation*
 - *'Peau d'orange' quality - an "Orange Peel" like texture that's caused by an uncommon, aggressive inflammatory malignancy*

Pregnancy Tests



- When pregnant, the amount of HCG hormone in the body rises rapidly in the early days & weeks
- A home pregnancy test can detect this in the urine or blood (the chemical markers)
- However, the HCG hormone can only be detected accurately after implantation (there is also a false result if the test is done too early)

Common test examples



PROBLEMS ARISING FROM PREGNANCY TEST

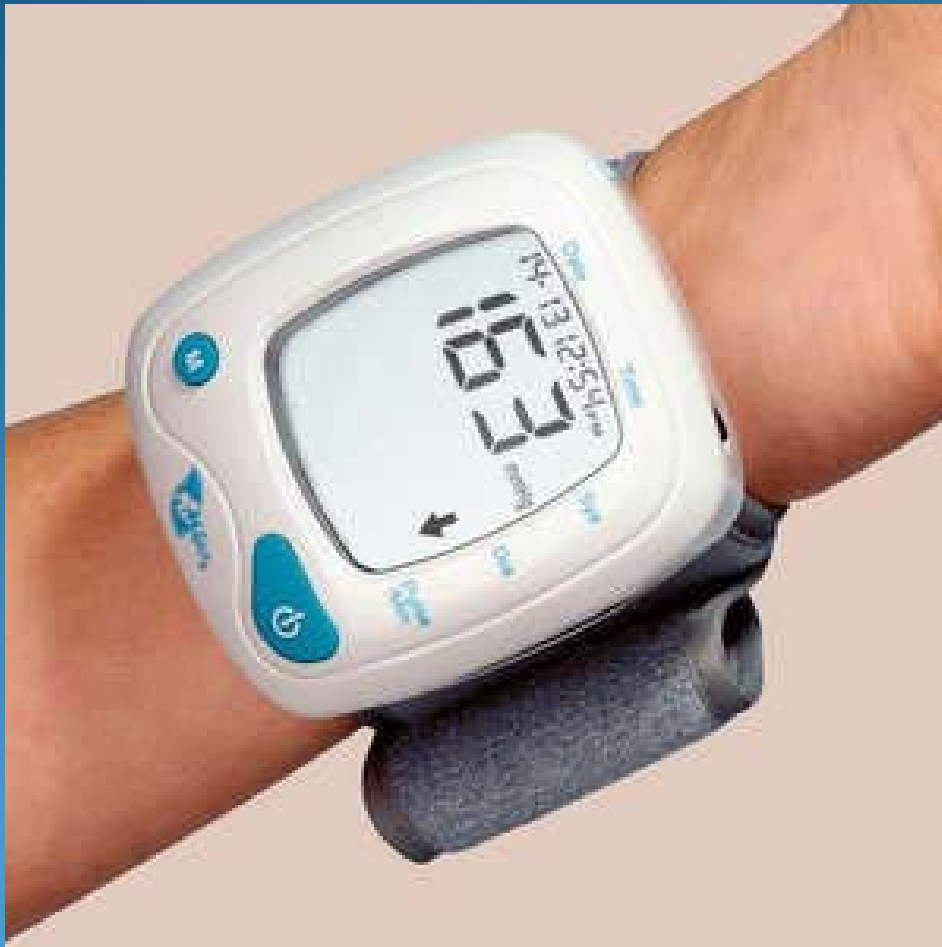- **Error in application results if urine flow is low**
- **Drugs interference**
- **Not 100% accurate (professionals estimate it to be 97% correct)**
- **Will not necessarily work if test is taken too early**



Blood Pressure Measurements: Sphygmomanometer cuff



Blood Pressure Measurements: Electric (home monitoring)



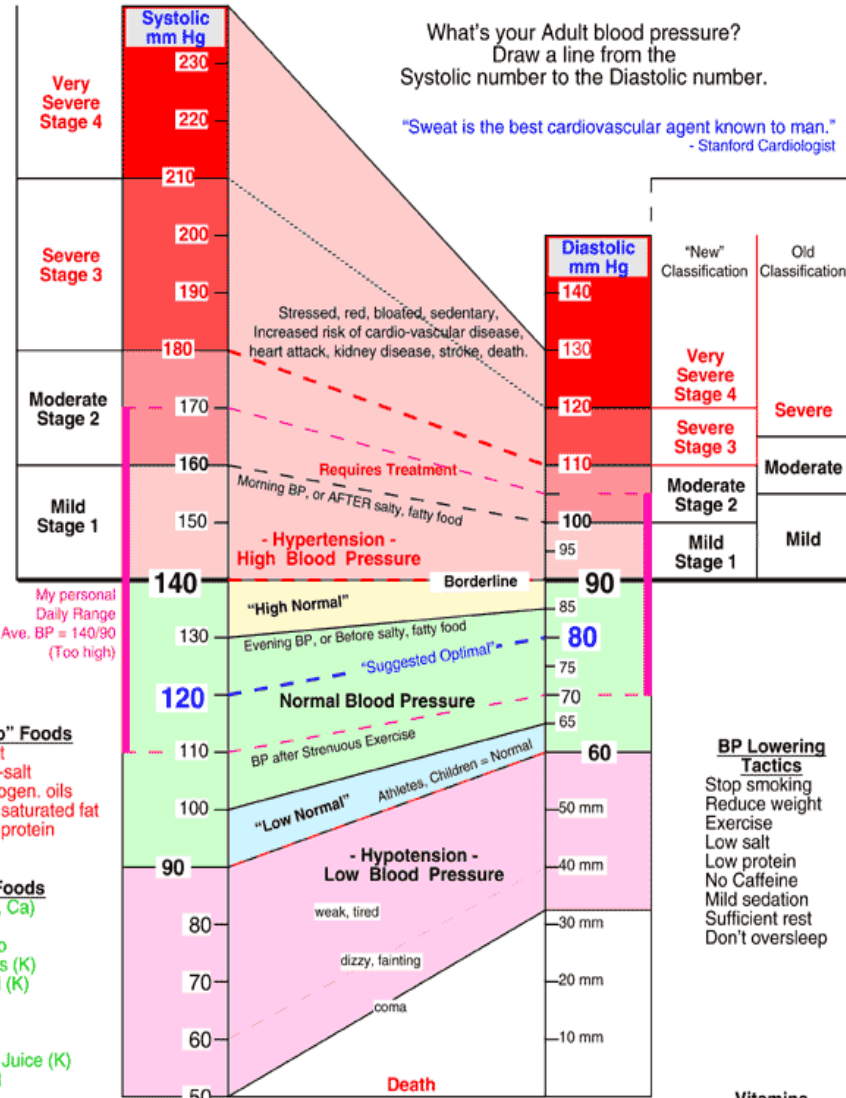
- *Wrap machine around wrist or forearm*
- *Push on/start button*
- *Read display*
- *Push off button*
- *Take machine off*



Blood Pressure Chart

What's your Adult blood pressure?
Draw a line from the Systolic number to the Diastolic number.

"Sweat is the best cardiovascular agent known to man."
- Stanford Cardiologist



My personal Daily Range
Ave. BP = 140/90
(Too high)

"No" Foods

- High-salt
- Medium-salt
- No hydrogen. oils
- Reduce saturated fat
- Reduce protein

"Yes" Foods

- (High K, Ca)
- Apples
- Avocado
- Bananas (K)
- Broccoli (K)
- Fish
- Grapes
- Oats
- Orange Juice (K)
- WATER

Amino Acids

- Co-Q10 - 120mg
- Carnitine - 1000mg
- Taurine - 500mg

Foods

- Flax oil - 1 tbl
- Fish oil- EPA 600mg
- DHA 400mg

Herbs

- Hawthorne Berry - 1.5g
- Garlic - lots (selenium)

Minerals

- calcium - 666mg
- magnesium - 266mg
- zinc - 10mcg

BP Lowering Tactics

- Stop smoking
- Reduce weight
- Exercise
- Low salt
- Low protein
- No Caffeine
- Mild sedation
- Sufficient rest
- Don't oversleep

Vitamins

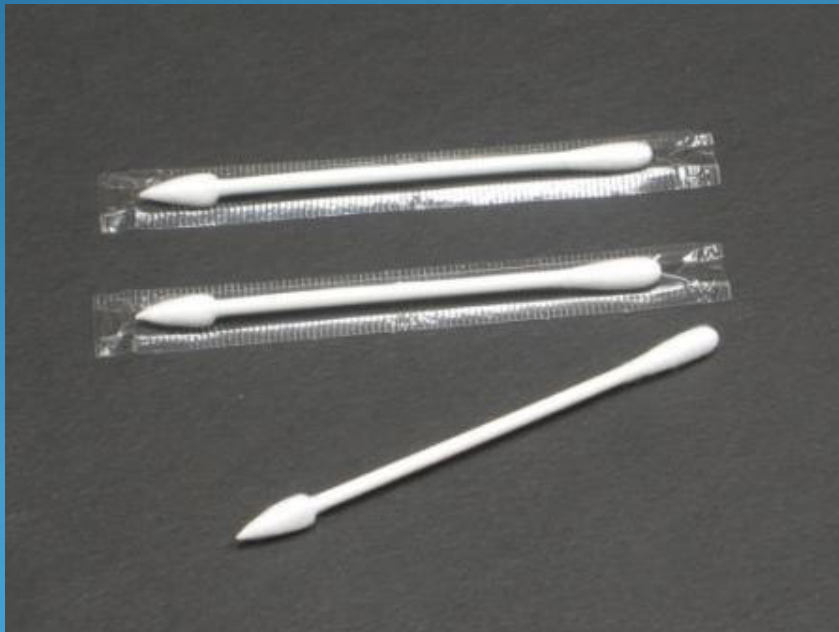- Vitamin C -1000mg
- Vitamin E - 400mg
- B complex - big-mg
- Folic Acid - 400mg
- Niacin - 100mg

Evaluating Blood Pressure Readings

Swab Analysis

- What is a swab?

- small piece of material (gauze or cotton) *used to clean wounds, apply medications, or retrieve samples of body fluids such as blood or mucus.*



Nasal Swabs

- Detection of nasal infections, especially presence *Staphylococcus aureus*
- Insert swab into the anterior nares (nostril)
- Sweep upwards towards the top of the nares
- Repeat the procedure with the same swab in the other nares
- Place swab in culture medium



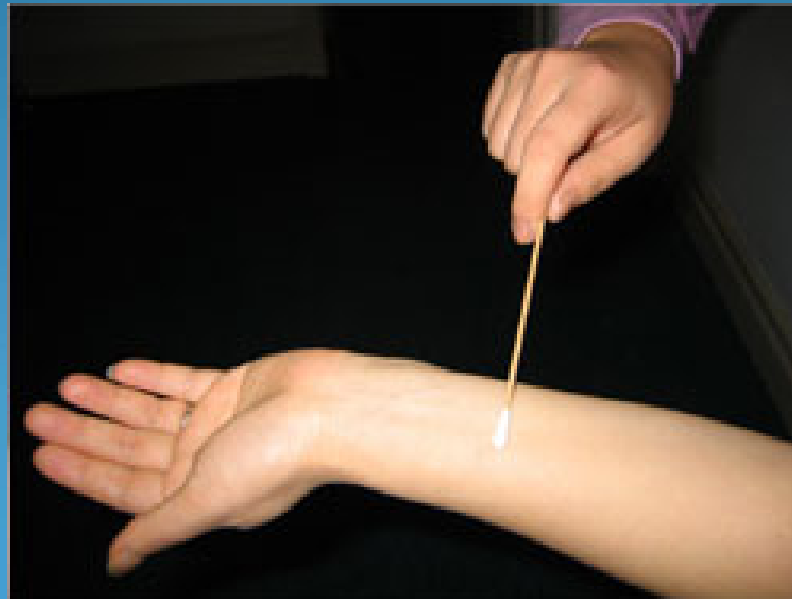Throat Swab

- **Similar technique to the nasal swab collection**
- Rub the swab along the back of the throat near the tonsils. Ask the patient to resist gagging and closing the mouth while the swab touches this area
- **Used particularly in *strep throat***
- *nb do not used antiseptic mouthwash before the test*



Skin Swabs

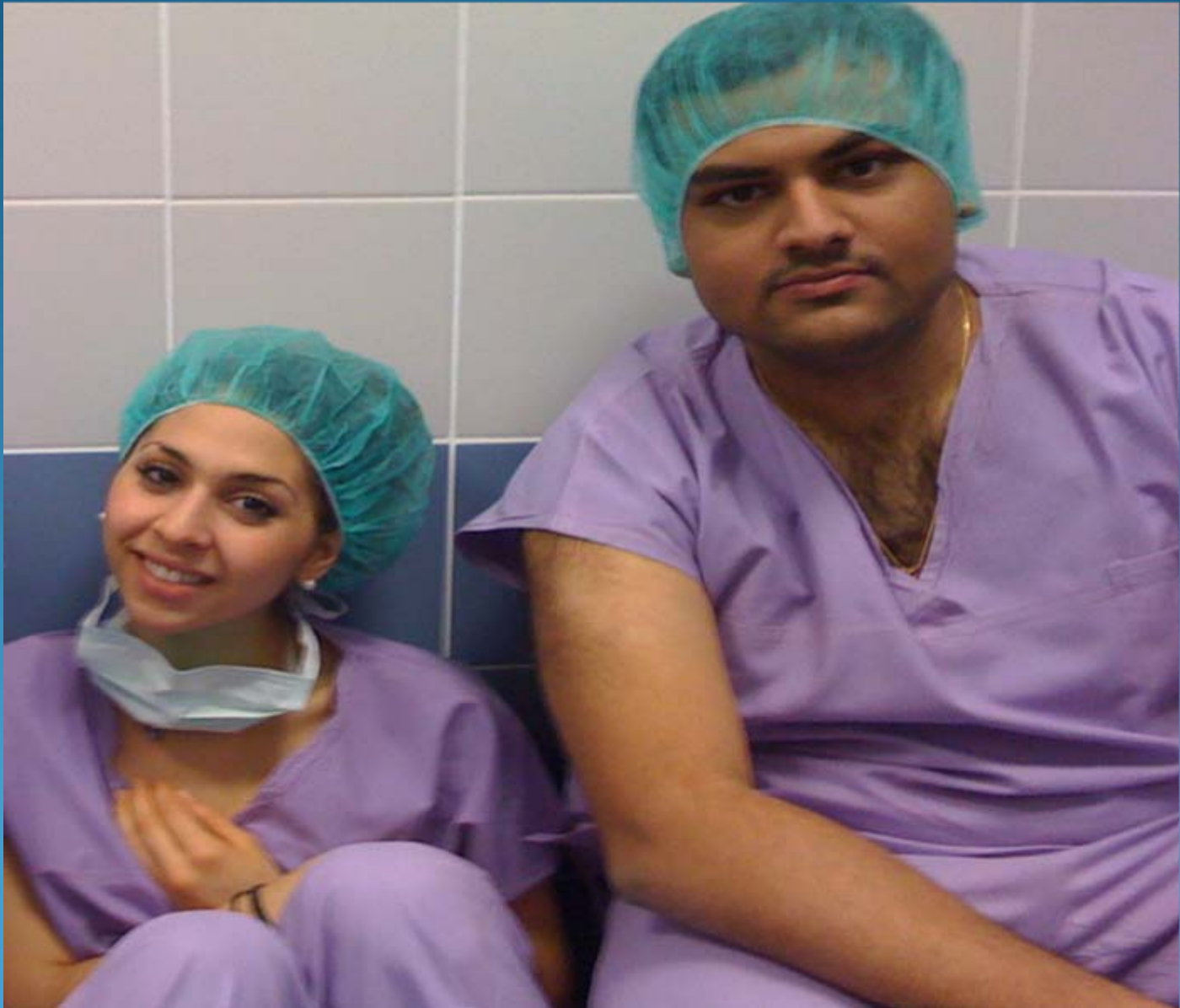- Rubbing (gently) across investigated area of skin
- Send to culture lab



You are now able to do the following:

1. Short Overview of Obstetrics' and Gynaecology; common conditions and risk factors
2. Perform and interpret value of breast examination (quadrants, common sites for lesions)
3. Perform and interpret pregnancy test (urine hormone detection)
4. Perform and interpret blood pressure measurement (manually and electronic devices)
5. Perform and value of taking sterile Nose, Throat, and Skin Swabs

Thankyou for your attention





Intramuscular Injections

Pooja Mithani



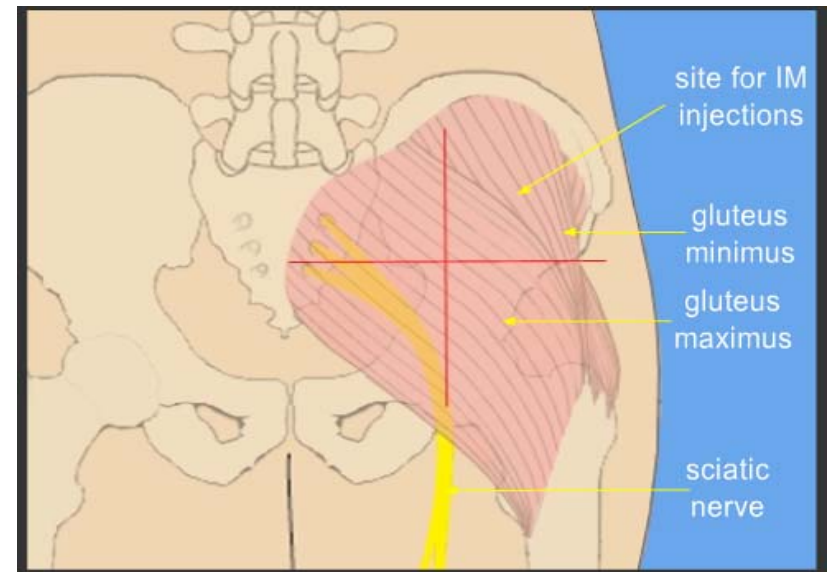
Injection of substance directly in muscle, for forms of medicine used delivered in small amounts

Indications:

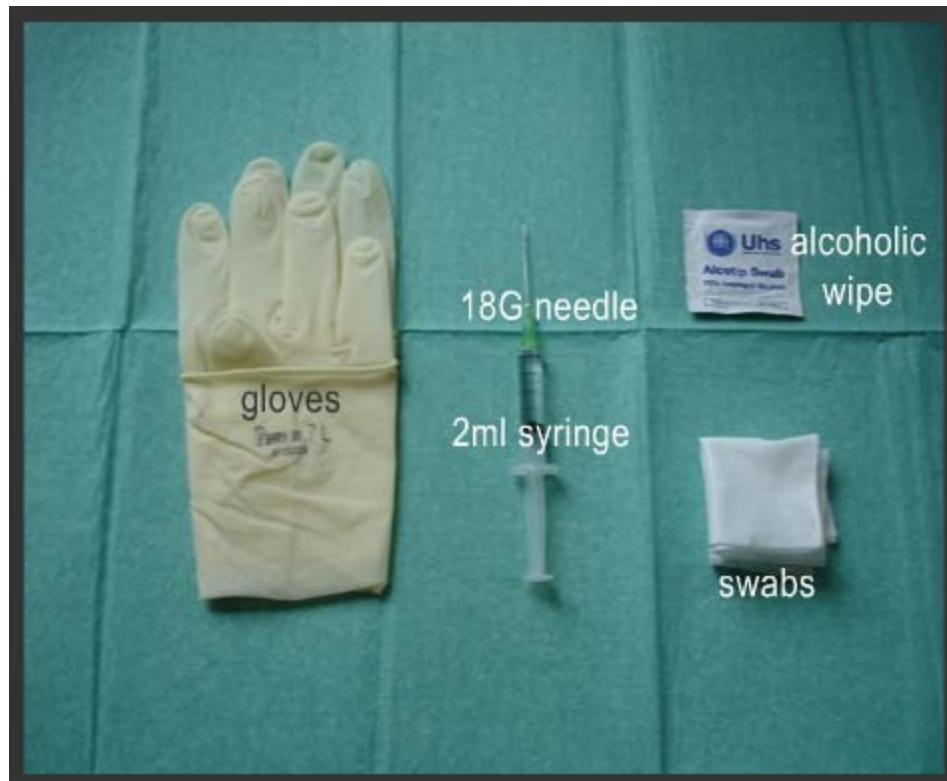- Where IV administration is not available.
- Drugs with specific actions on muscles.
- A longer half life is needed eg. Morphine for anaesthesia

Complications & contraindications

- Damage to the sciatic nerve. (Upper outer quadrant)
- Injection fibrosis - causes inability to flex muscle drug is administered to.
- Thrombocytopenia (low platelets) and coagulopathy (bleeding) can lead to hematomas.
- Local sepsis
- Arterial/IV injection
- Infection



Equipment List



Method

- Check identity of patient and contents and expiry date of drugs
- Insert needle into syringe, and fill with the required amount of drug. Tap syringe to bring any air bubbles to the top and push the air out.
- Choose a suitable injection site and inspect for signs of inflammation, swelling, infections or lesions
- 5 main sites:
 - Upper arm (deltoid) – vaccines
 - Dorsogluteal (gluteus maximus)
 - Ventrogluteal(gluteus medius)
 - Vastus lateralis (quadriceps femoris) outer side of femur
 - Rectus femoris (anterior quadriceps) – self administration or infants

Method continued...

- Swab site with alcohol and let it dry (bactericidal and decreases pain)
- Pull skin laterally and insert needle in one swift motion at 90°, aspirate to avoid an intravenous placement, if blood is drawn in, restart with new medication and slowly inject the drug.
- Remove needle and apply a pressure gauze and observe for signs of an adverse reaction.



Moving the skin may distract from the intended needle destination, therefore visualise and aim for the underlying muscle about to receive the injection.

http://www.youtube.com/watch?v=nA8i9eYW0_M



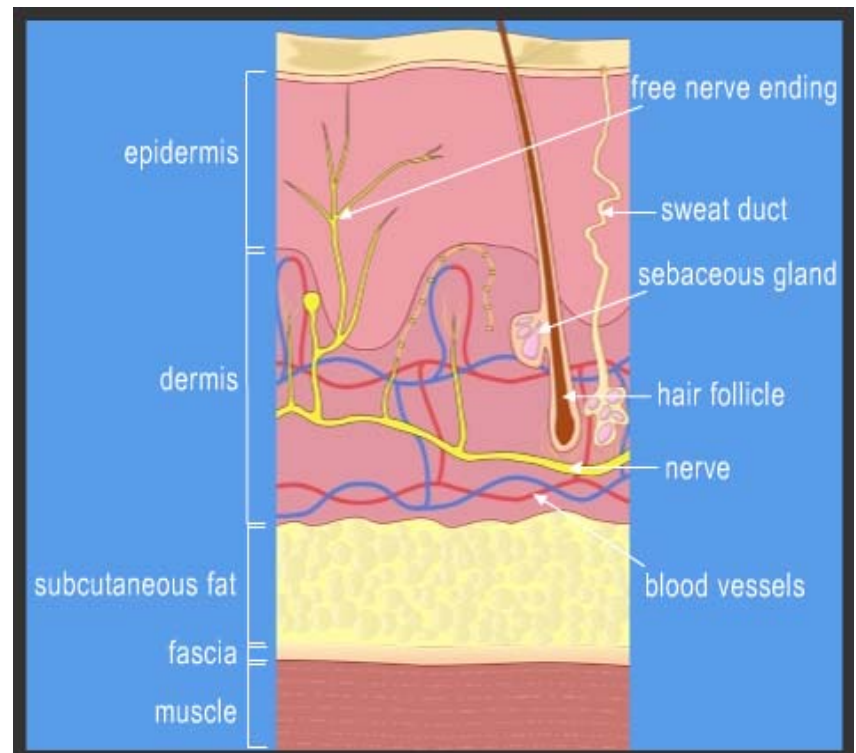
Subcutaneous Injections

Pooja Mithani

Injection of substance into the subcutaneous tissue – layer of skin directly below the dermis and epidermis.

Indications

- When drug is desired to have a slow, sustained absorption effect
- Local anaesthesia
- Administration of vaccines and medicines such as insulin and morphine

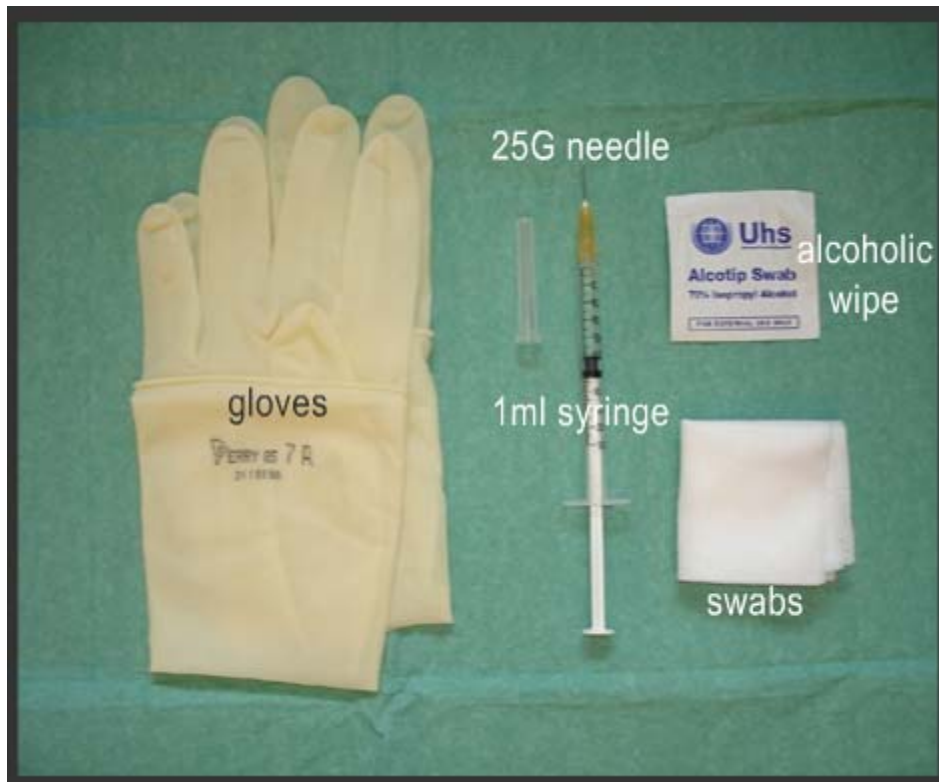

Complications & Contraindications

- Avoid using the same site repetitively which can cause lumps or dents (lypodystrophies – loss or degeneration of fat) from forming.
- Accidental IV, ID, IM injections



Equipment List



Method

- Check identity of patient and contents and expiry date of drugs
- Insert needle into syringe, and fill with the required amount of drug. Tap syringe to bring any air bubbles to the top and push the air out.
- Choose a suitable injection site and inspect for signs of inflammation, swelling, infections or lesions
- 4 main sites:
 - Upper arm outer area
 - Abdomen – above and below waist, except around navel
 - Anterior thigh – midway of outer side
 - Upper area of butt – behind hip bone

Method continued ...

- When repeated injections are needed use a hidden site to cover bruises – but the same area at the same time each day to reduce changes in the action of the insulin
- Swab site with alcohol and let it dry (bactericidal and decreases pain)
- Gently pinch skin to elevate subcutaneous fat and separate it from underlying muscle.
- Insert the needle at a 30° angle and inject the drug – aspiration before injecting the drug is unnecessary as can increase the risk of local hematoma formation for heparin.

<http://www.youtube.com/watch?v=bxGYGKz1iA>



Local Anaesthesia Injections

Pooja Mithani


Used when performing invasive medical procedures except in life saving procedures.

Contraindications

- Patient refusal – but many can be persuaded
- Allergy – rare
- DO NOT USE adrenaline containing LA on digits or penis – vasoconstriction can lead to ischaemia and necrosis.
- Anticoagulated patients have a tendency to bleed if a vessel is punctured.
- Infection at intended site may make it more painful and spread.
- Broken needles
- Acute systemic toxicity – CNS, CVS – when plasma conc., exceeds toxic limit.

Mechanism of action

- LA block fast sodium channels in nerve axons preventing propagation of nerve impulse
- Pain nerves are usually smaller and non myelinated fibres so are blocked faster than larger myelinated fibres (motor, proprioception, touch)



Parenteral LA

- Injected subcutaneously
- Onset of effect is 2 minutes, but duration varies depending on the drug.
- LA solutions are alkaline pH 10/11 therefore are more painful
- A less painful approach would be ID (instant anaesthesia)
- Avoid intra vascular injection, so aspirate first.

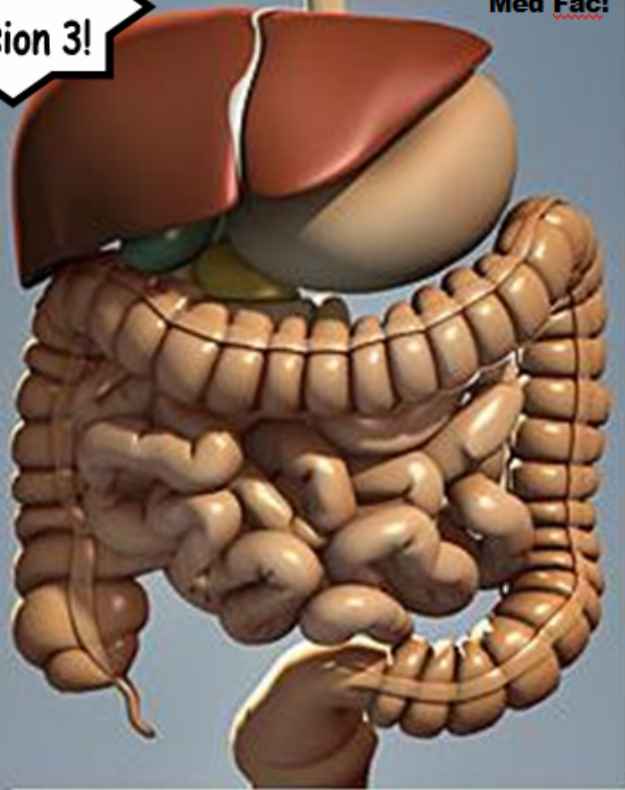

Unfortunately your HMO doesn't cover anesthesia so we're going to have to use our low-budget procedure to put you out.

**Have a good rest of your
degree!!**

Clinical
Session 3!

Small Lecture Hall
Med Fac!



DIGESTIVE SYSTEM

+ FIRST AID,
SUTURES & MORE

TUE 1830 - 1945



SESSION 3 (GIT) > TUES 23RD MARCH < 6.30 - 7.45PM

- 1) 6.30 - 6.45PM Abdominal examination : by KUMARAN & AMIT
- 2) 6.45 - 7.00PM Nasogastric tube insertion : by SHAN
- 3) 7.00 - 7.15PM First Aid overview : by DEVANGNA
- 4) 7.15 - 7.30PM Central Venous Catheterisation : by SHILPA
- 5) 7.30 - 7.45PM Sutures: by JOAE DE OLIVIERA



CHECK
f
GROUP

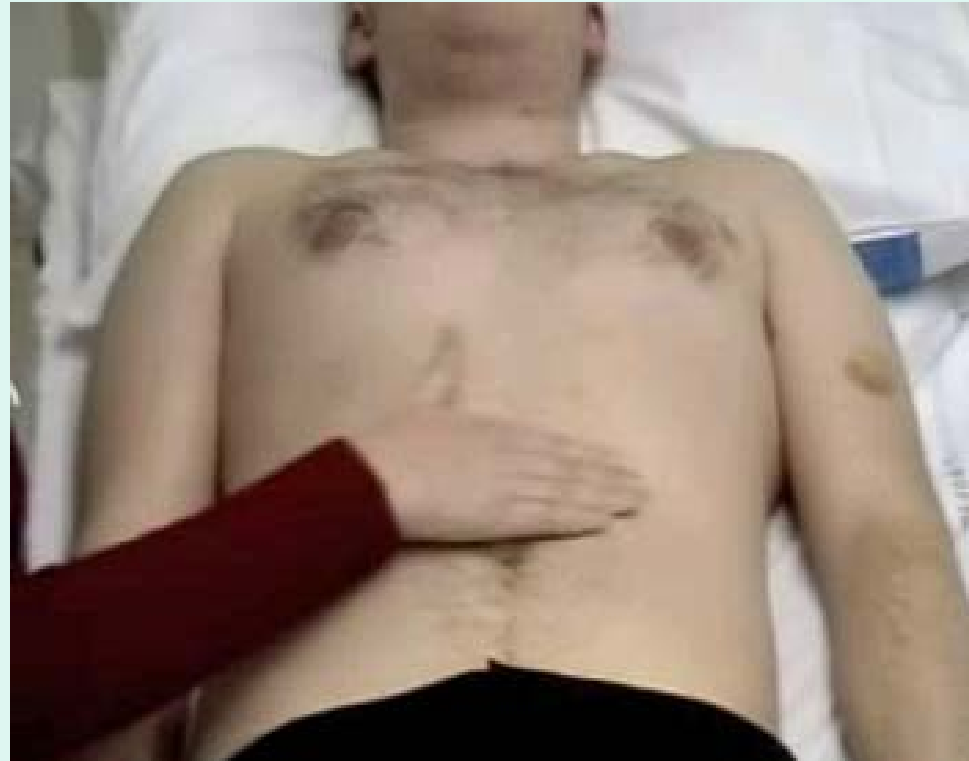CLINICAL
SESSIONS
2010

ABDOMINAL EXAMINATION

**By: Amit Kaushal
& Kumaran
Thanabalasingham**

POSITIONING

- ❑ Patients hands remain on his/hers side
- ❑ Legs, straight
- ❑ Head resting on pillow if neck is flexed, ABD muscles will tense and therefore harder to palpate ABD



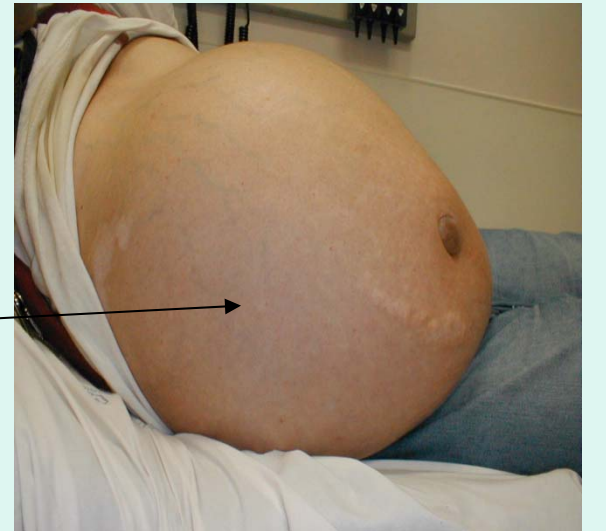
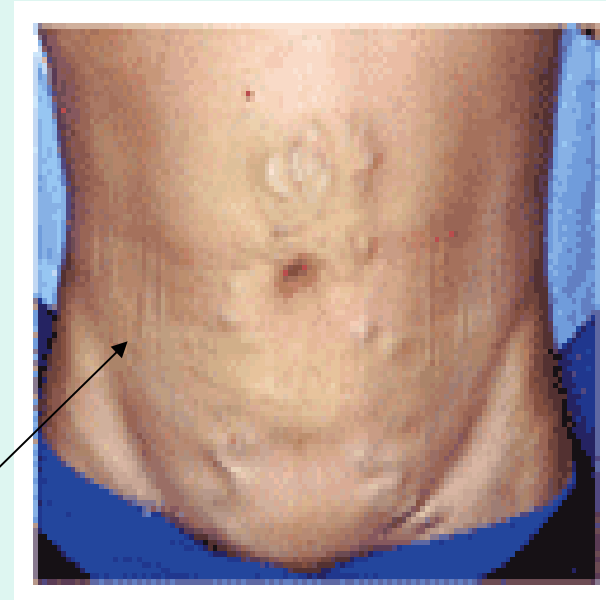
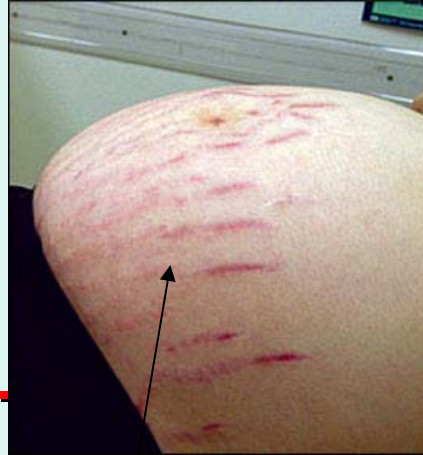- **INSPECTION**
- **AUSCULTATION**
- **PALPATION**
- **PERCUSSION**

INSPECTION



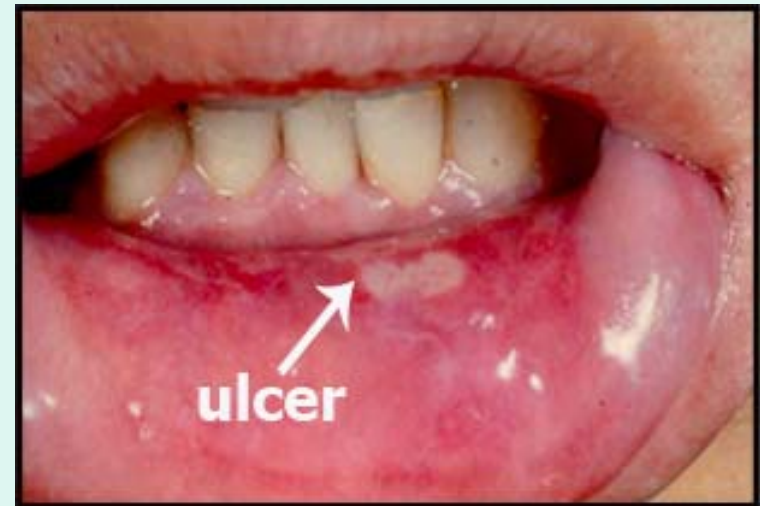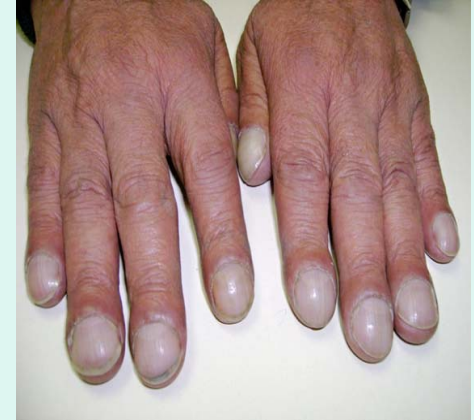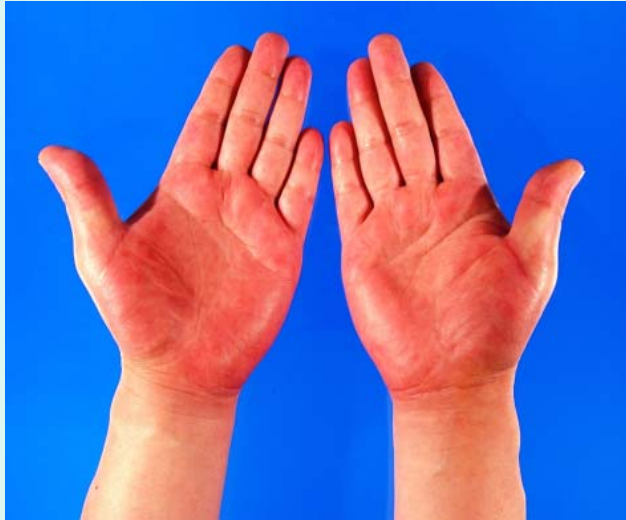INSPECTION

- Shape
- **Skin Abnormalities**
 - Masses
 - **Scars (Previous op's - laproscopy)**
 - Signs of Trauma
 - **Jaundice**
- **Caput Medusae (portal H-T)**
- **Ascities (bulging flanks)**
- Spider Navi-Pregnant women
 - **Cushings (red-violet)**



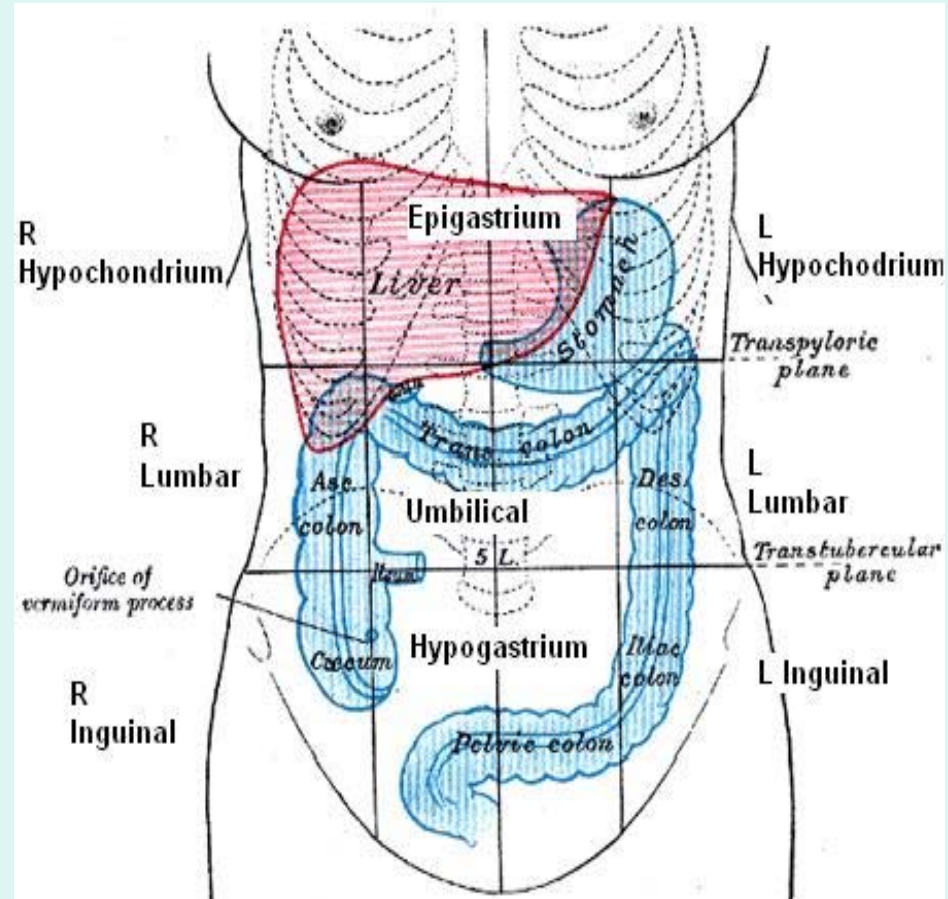
Hands + Mouth

- **Clubbing**
- **Palmer Erythraemia**
- **Mouth ulceration**
- **Breath (foeter ex ore)**



AUSCULTATION

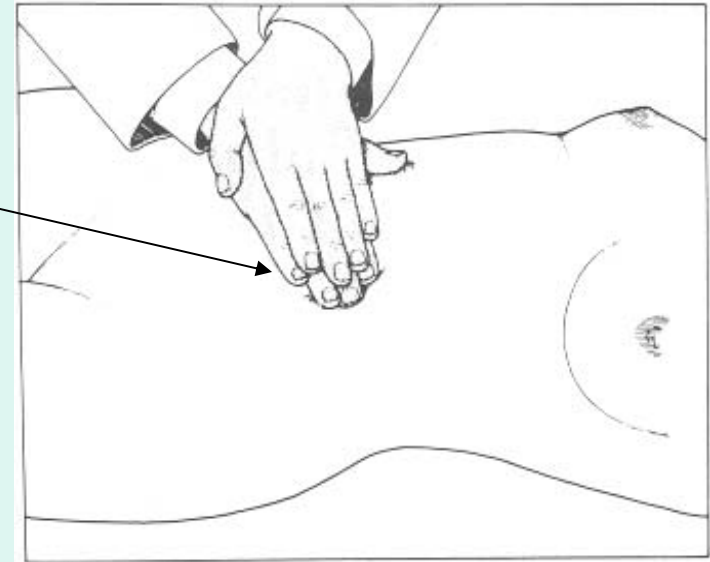
- Use stethoscope to listen to all areas
- Detection of Bowel sounds (Peristalsis/Silent?? = Ileus)
- If no bowel sounds heard – continue to auscultate up to 3mins in the different areas to determine the absence of bowel sounds
- Auscultate for **BRUITS!!!** - Swishing (pathological) sounds over the arteries (eg. Abdominal Aorta)



PALPATION

**ALWAYS ASK IF PAIN IS PRESENT
BEFORE PALPATING!!!**

- **Firstly: Superficial palpation**
- **Secondly: Deep where no pain is present. (deep organs)**
- **Assessing Muscle Tone:**
 - Guarding = muscles contract when pressure is applied
 - Ridigity = indicates peritoneal inflammation
 - Rebound = Releasing of pressure causing pain



MURPHY'S SIGN

- **Indication:**

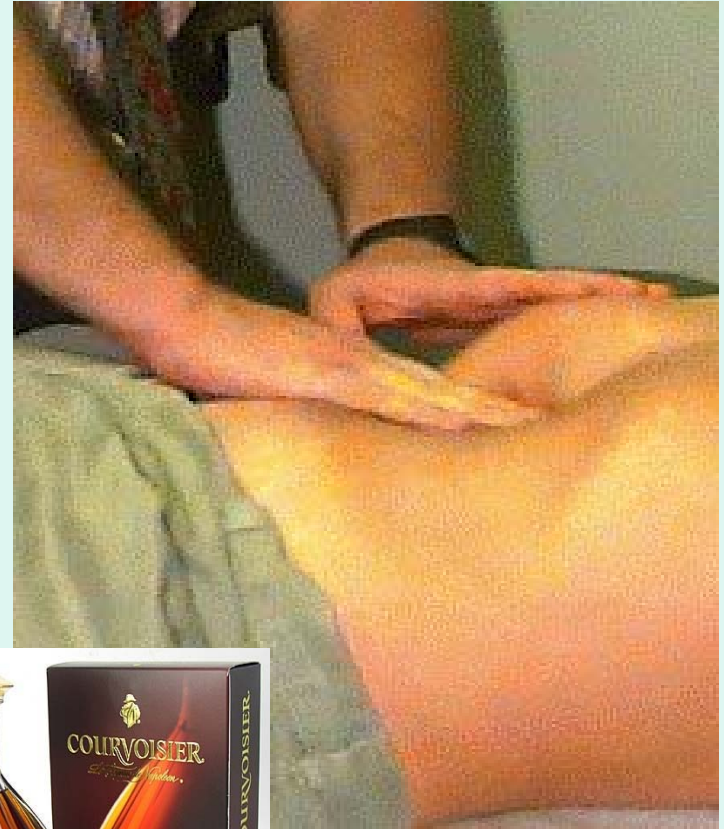
- pain in U.R.Quadrant

- **Determines:**

- cholecystitis (inflam. of gall bladder)

- Courvoisier's law – palpable gall bladder, yet painless

- cholangitis (inflam. Of bile ducts)

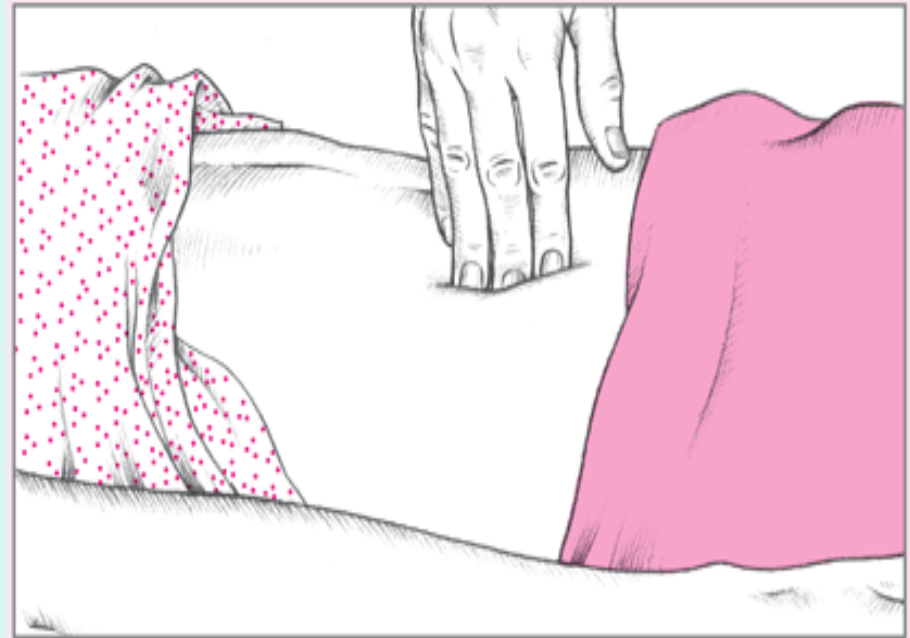


METHOD

- **Ask patient to breathe out.**
- **Gently place your hand below the costal margin on the right side at the mid-clavicular line (location of the gallbladder).**
- **Instruct to breathe in.**
- **Normally, during inspiration, the abdominal contents are pushed downward as the diaphragm moves down.**
- **If the patient stops breathing in (as the gallbladder comes in contact with the examiner's fingers) the patient feels pain with a 'catch' in breath.**
- **Test is positive.**

BLUMBERG'S SIGN

- ***Determines:***
 - peritonitis
 - appendicitis
- ***ALWAYS START OPP. SIDE TO WHERE THE PAIN IS !!!!***
- ***ABD is compressed slowly and then rapidly released.***
- ***Pain upon removal of pressure rather than application of pressure to the abdomen***
- ***Pain present = positive.***

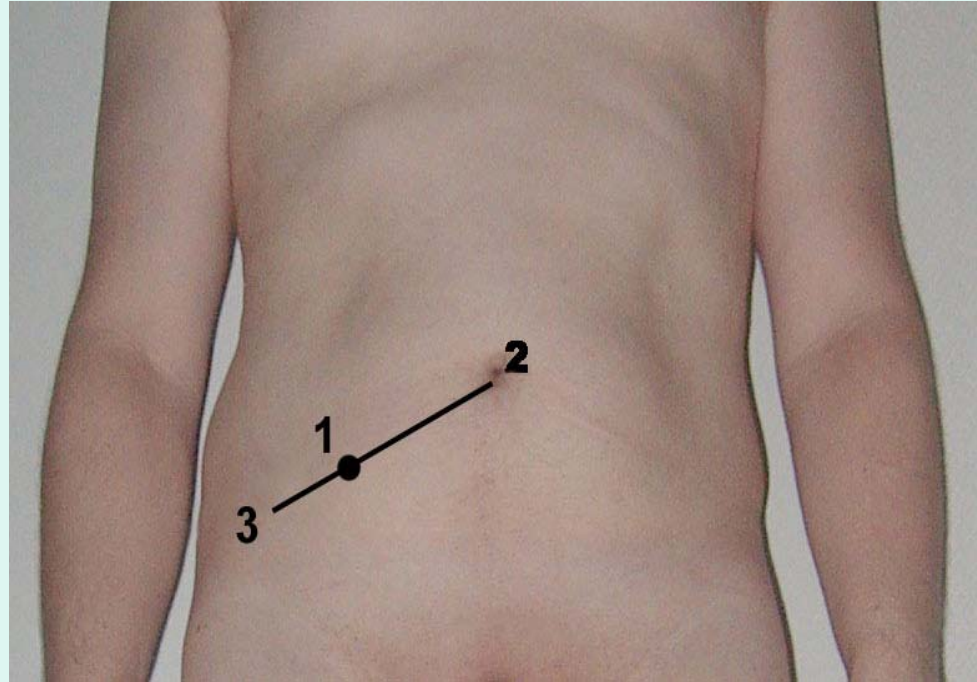


pressure. Pain that results from the rebound of palpated tissue—rebound tenderness—indicates peritoneal inflammation or peritonitis.

You can also elicit this symptom on a miniature scale by percussing the patient's abdomen lightly and indirectly (as shown). Better still, simply ask the patient to cough.

McBURNEY'S POINT

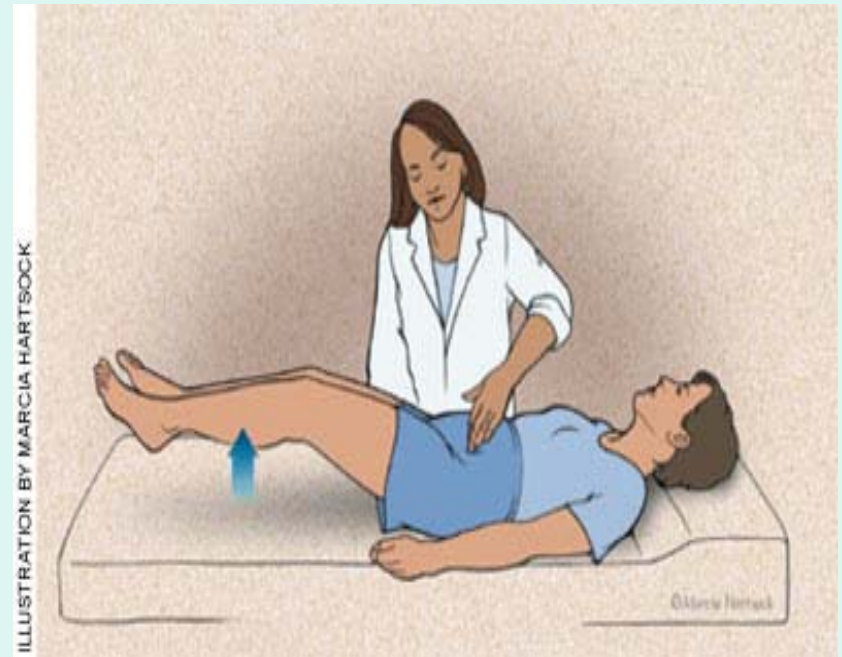- **From ASIS (anterior superior iliac spine) to the umbilicus.**
- **Determines:**
 - location of appendix (varies)
 - deep tenderness @ point = acute appendicitis



NOTE: McBURNEY'S PUNCH SIGN = *Tenderness is presented when gently tapping the area of the back overlying the kidney producing pain in people with an infection around the kidney (perinephric abscess) or pyelonephritis.*

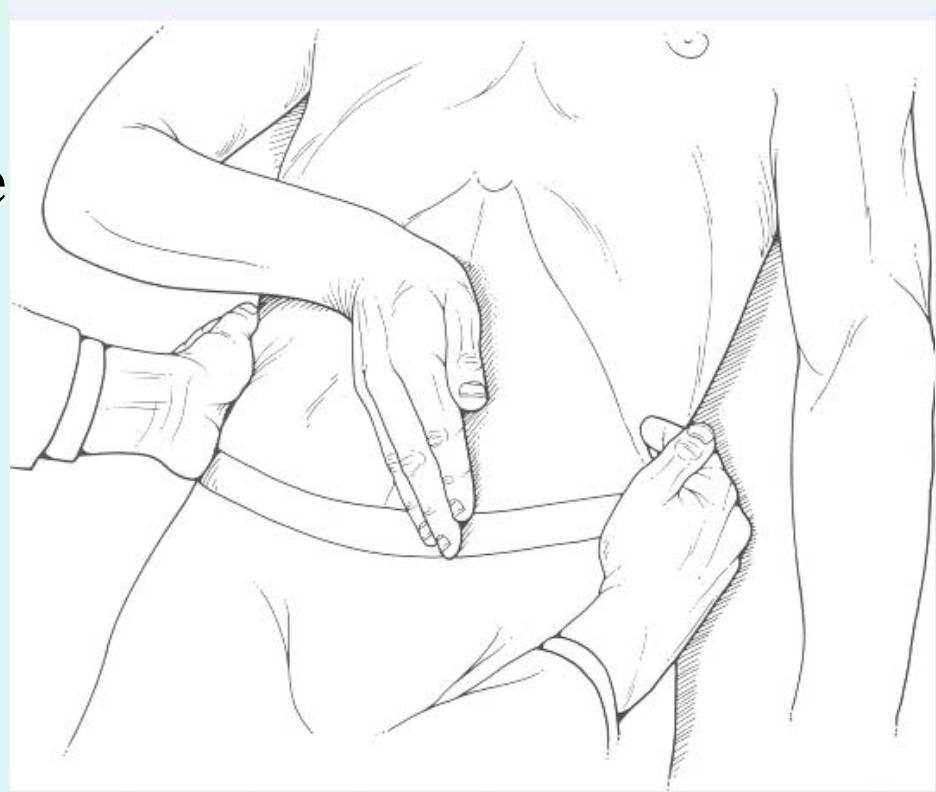
Carnett's sign

- Abd. pain remains unchanged or increases when the muscles of the abdominal wall are tensed.
- **Positive** = Abd. wall is the source of the pain (e.g. due to rectus sheath hematoma).
- **Negative** = pain decreases when the patient is asked to lift the head; this points to an intra-abdominal cause of the pain



Fluid wave test / Iceberg Sign


- **Test for ascites.**
- **Have patient push their hands down on the midline of the abdomen.**
- **Then you tap one flank, while feeling on the other flank for the tap.**
- **> 1 litre of fluid allows the tap to be felt on the other side.**



Spleen

Only palpable if enlarged; splenomegaly – indicated by Castell's sign (bulge of U.L. Quadrant).

Patient on his/her Right Side & palpate from behind.



Liver

- **PALPATE:**

- from R.ilic fossa up towards and under the last rib whilst the patient is breathing in **deeply**.

- **ASSESSING:**

Regulatrities

Smoothness

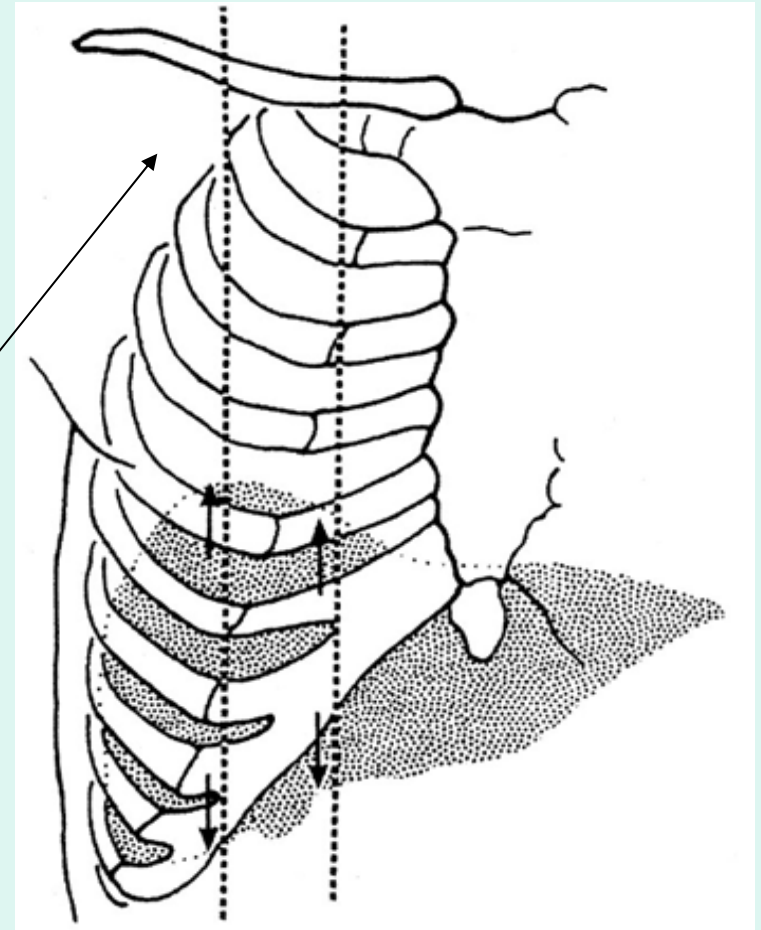
Tenderness

- **PERCUSSION:**

- Outline of liver (norm: 8-12 cms)

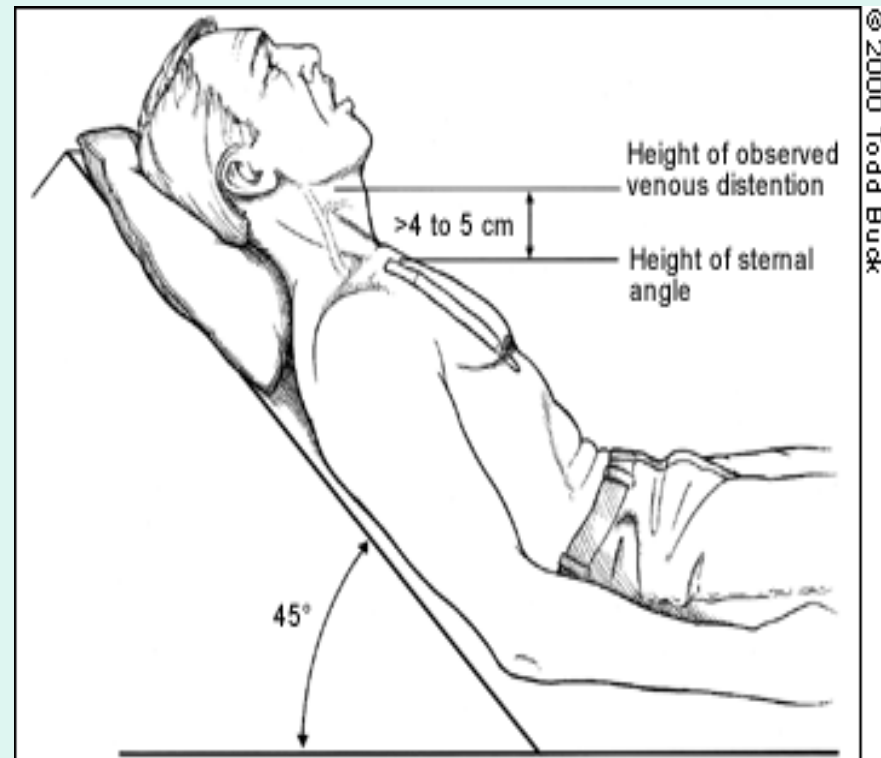
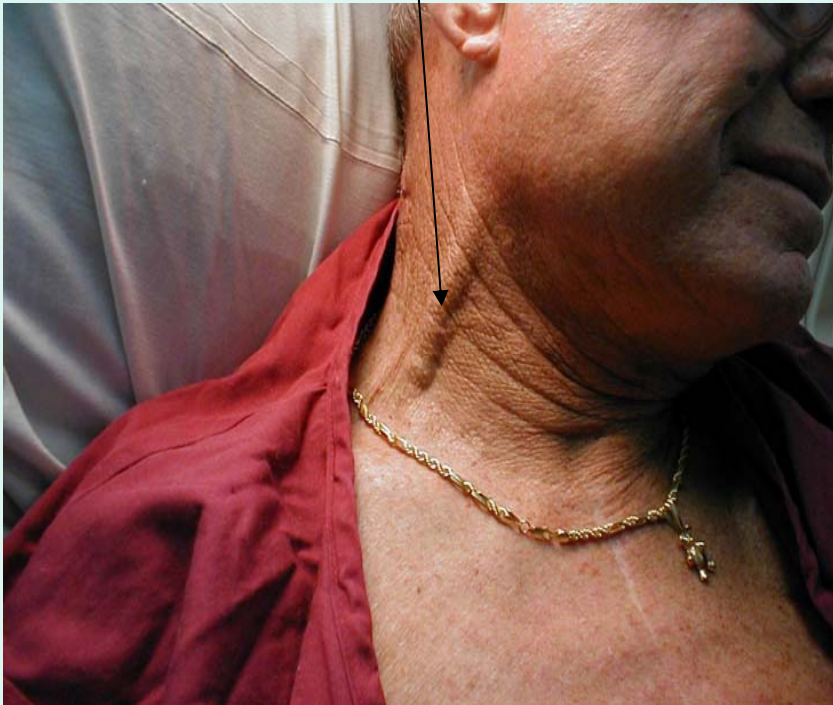
- In Mid-Clavicular Line from 2nd rib downwards

- Hollow ---> Dull ----> Hollow



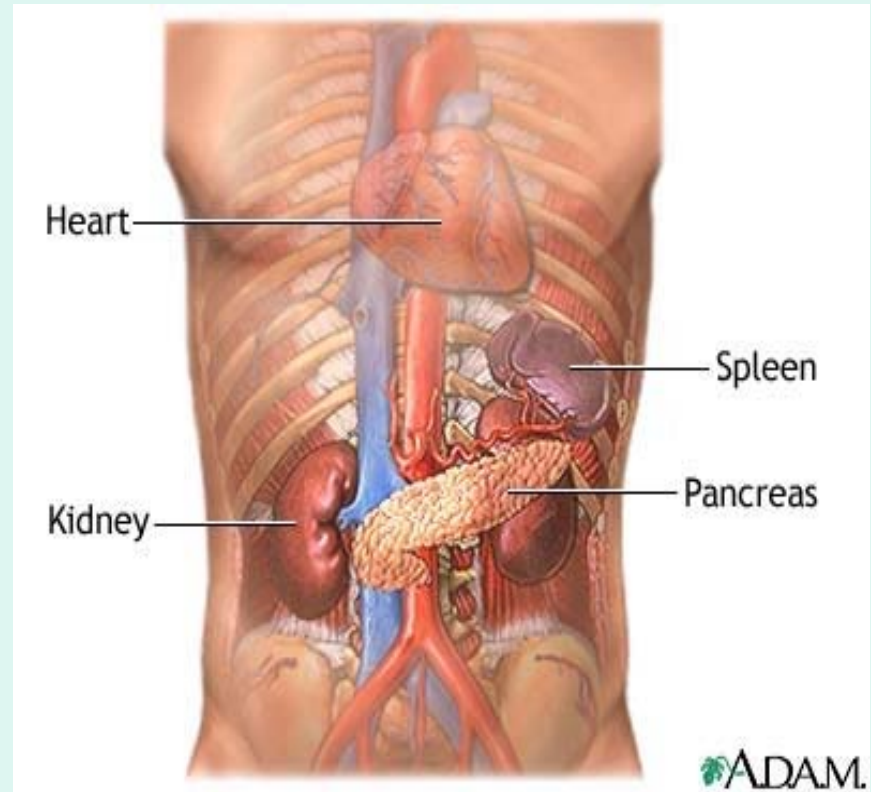
HEPATO-JUGULAR REFLUX

- **Pressing enlarged liver ---> Increases Jugular Filling ----> Hepatic congestion**
(R.Heart Failure)



Head of Pancreas

- **De Jardins Point:**
 - MCL
 - 9th Costal Cartilage
 - Right Side
- **Indication:**
 - Pancreatitis/Tumour @ head

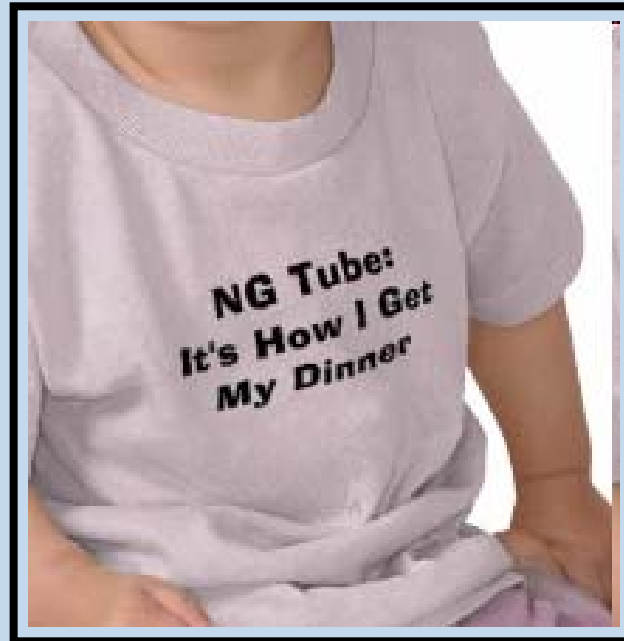

***THANK YOU FOR YOUR
ATTENTION***



NASOGASTRIC (Ryles) TUBES

(NGT)

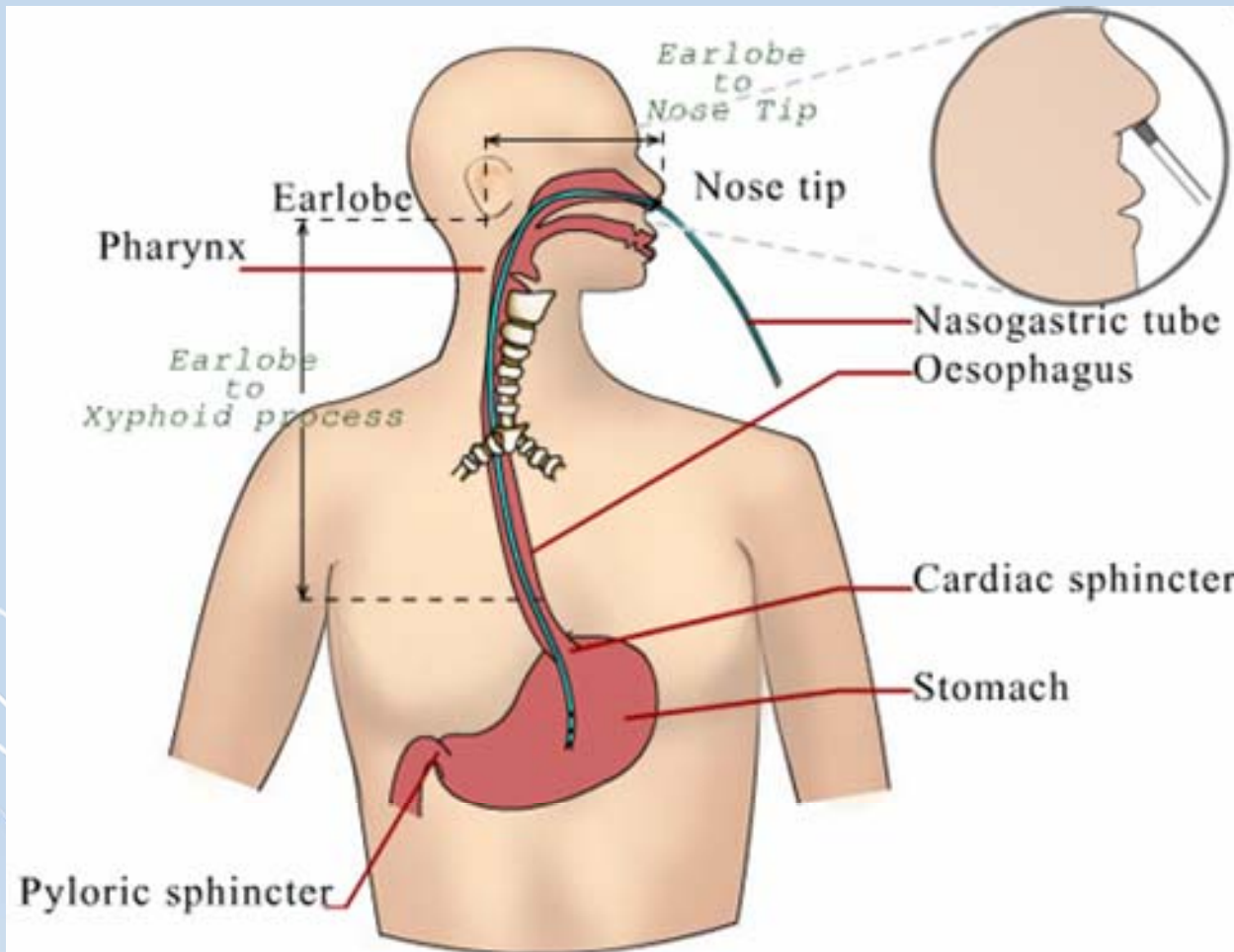


SHAN KESHRI
CLINICAL SESSIONS

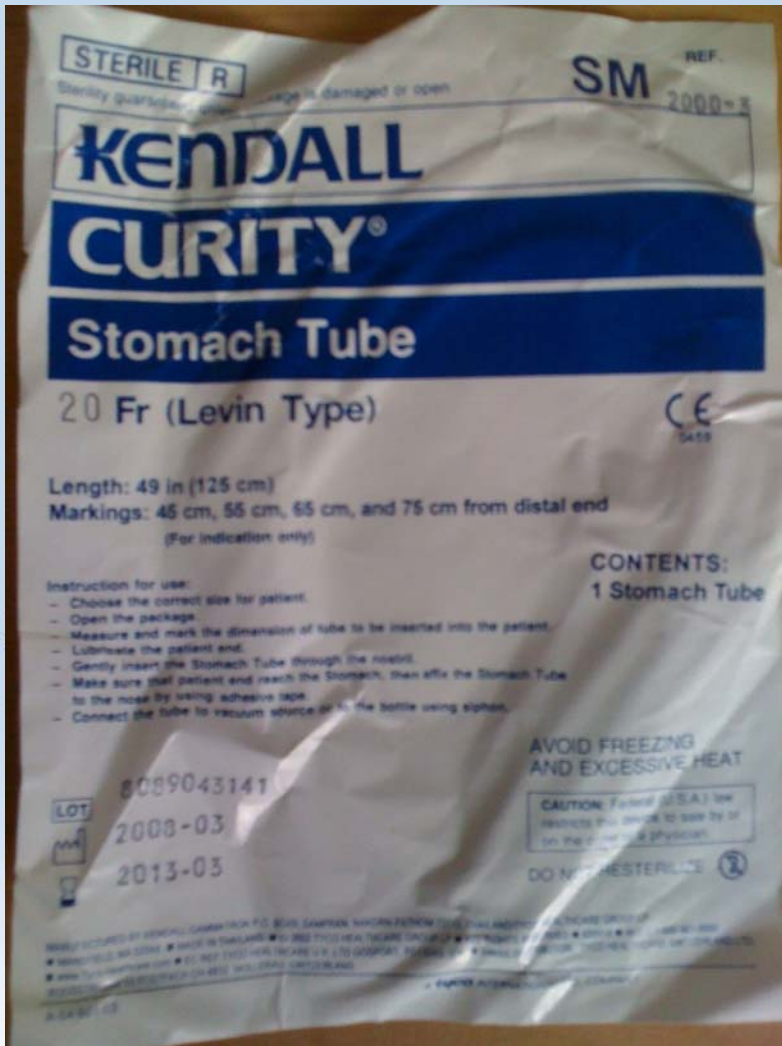


MASARYK UNIVERSITY
FACULTY OF MEDICINE

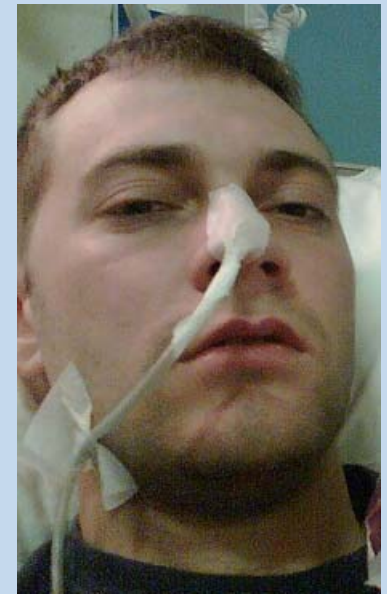WHAT



20 Fr LEVIN TYPE

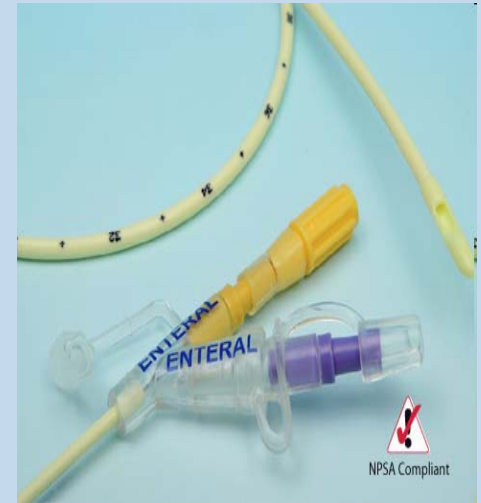


Many holes prevent blocks!



INDICATIONS

- **IN** – *Fine Bore tube 12Fr (less irritating)*
 - **Feeding**
 - e.g. anorexia nervosa to stabilise body weight
 - e.g. esophageal cancer to maintain nutritional intake
 - Swallowing difficulty (dysphagia)
 - **Administer drugs** (inject into tube)
 - **Oral substances** e.g. charcoal (poison antidote, antiflatulent, lower blood lipid)



INDICATIONS

● OUT – *Large Bore tube*

- **Aspiration** (suction) of stomach contents

- ***Gastric secretions***

- Swallowed ***air / obstructions*** / paralytic ileus

- Extract ***samples of gastric liquid*** for examination

- Extract swallowed ***toxin / poison***


- Patient who has undergone ***pneumonectomy***

(risk of anesthesia related vomiting leading to aspiration of stomach contents)




INDICATIONS

- **Intra-operatively:**
 - Inflate / Deflate stomach, to give easier access to upper abdomen



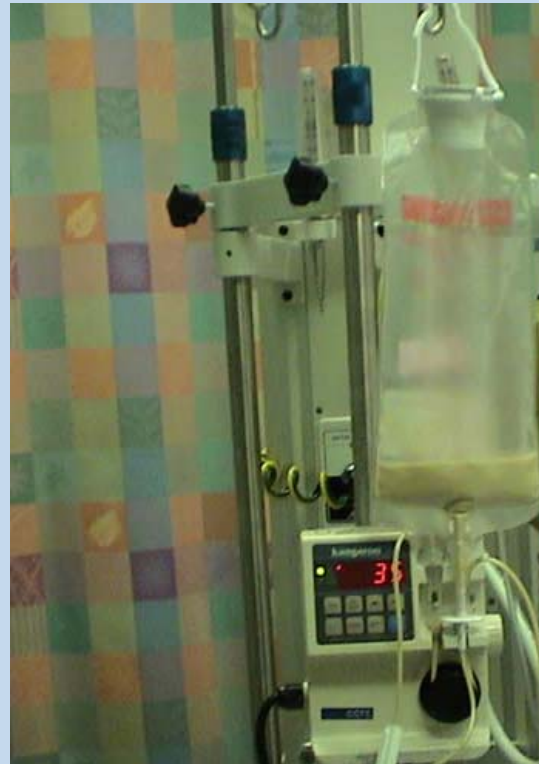Continuous Feeding

- **Gravity based system**
 - Feeding solution placed above level of stomach



Supervised feeding

- Tube is connected to **electronic pump**
 - Controls and measures intake, & signals interruptions in feeding.



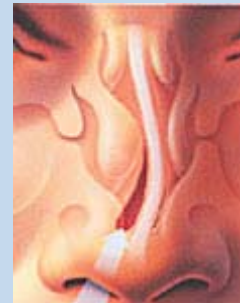
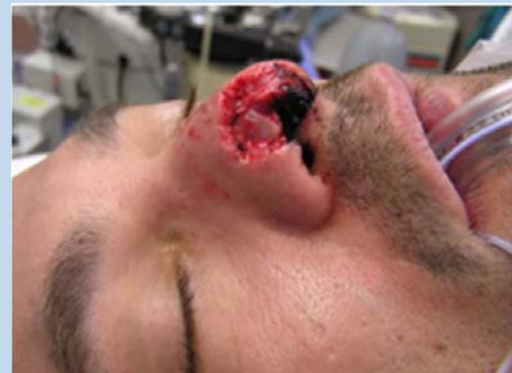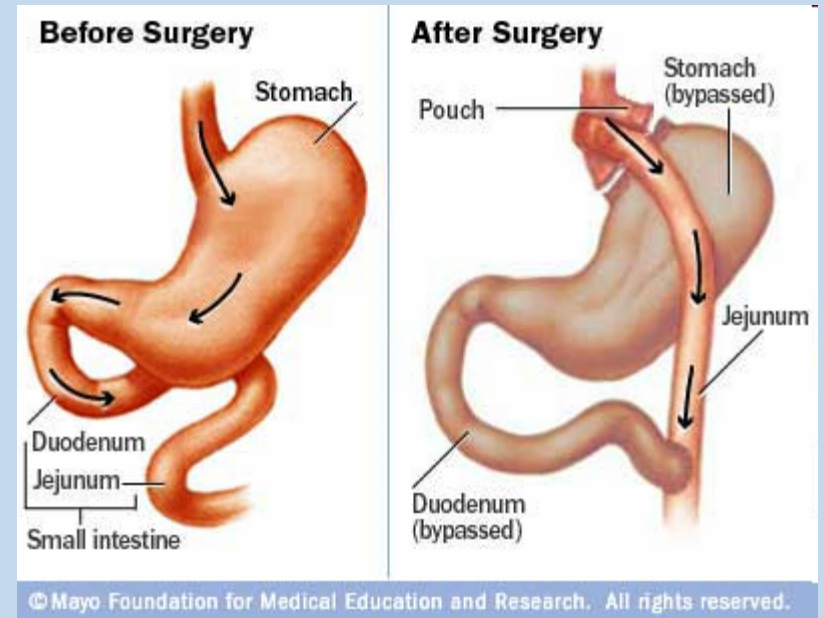
Continuous Drainage

- **Gravity Based System:**
 - Attach to collector bag. Placed below level of stomach



CONTRA-INDICATIONS

- History of / currently has:
 - Gastric bypass surgery
 - Esophageal Varices
 - Alcoholism, Liver Disease
 - Bleeding disorders
 - Fractured nose
 - Deviated septum
 - Nasal / Sinus surgery / Trauma
 - Etc...



EQUIPMENT

- Cup of **water with straw**
 - patient sip during insertion of tube
- Naso-gastric Tube (**NGT**)
- **Lubricant**
- **pH / Litmus paper**
- Pen light
- Vomiting basin
- Measuring tape
- **Surgical Tape**
- Mask and eye protection
- Non Sterile Drape
- Non sterile Gloves
- **60ml Syringe**
- Bottle of water for irrigation

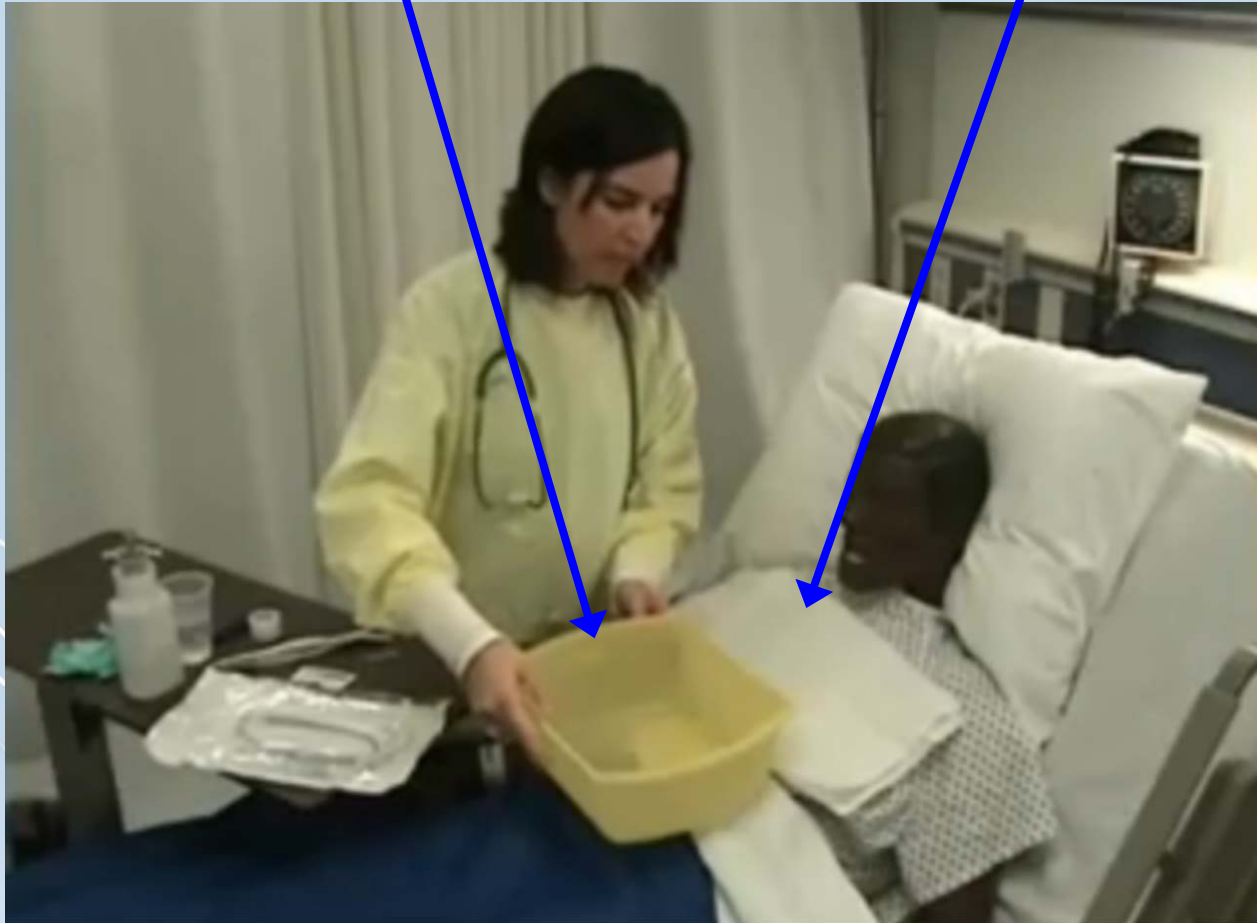

NON STERILE TECHNIQUE

- Classed as a **non-sterile procedure** because, as the NGT passes through the nose, it will pick up bacteria on the way down to the stomach anyway.

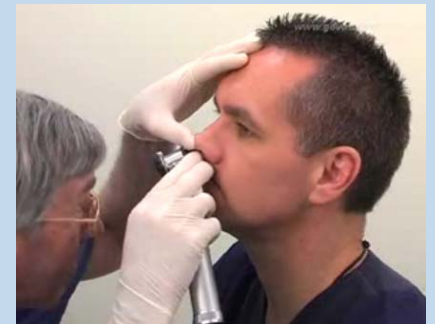
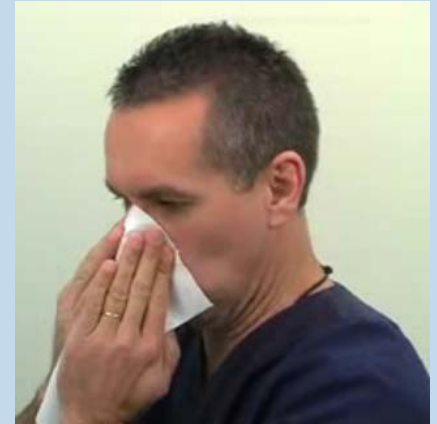
- Place non sterile drape across patients chest.
- Give patient the basin to hold
 - In case of nausea / vomiting



ASSESS

- Has patient had :
 - Nasal / Sinus Surgery?
 - Fractured nose?
 - Deviated septum?
 - Nasal Trauma
 - Difficulty breathing through a particular nostril
 - (ask them to blow nose)
- Check both nares with pen light – clear?



- Inform patient to take sips of water through the straw, during insertion of NGT, as this swallowing will help it pass more easily!
- Also explain it may cause discomfort.



PROCEDURE

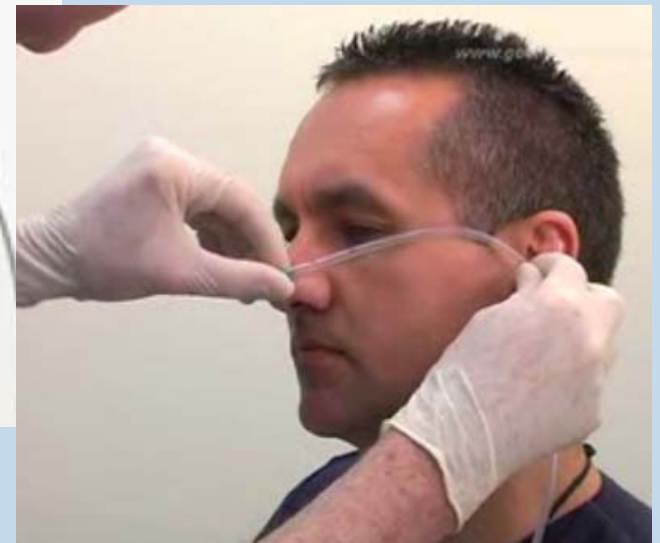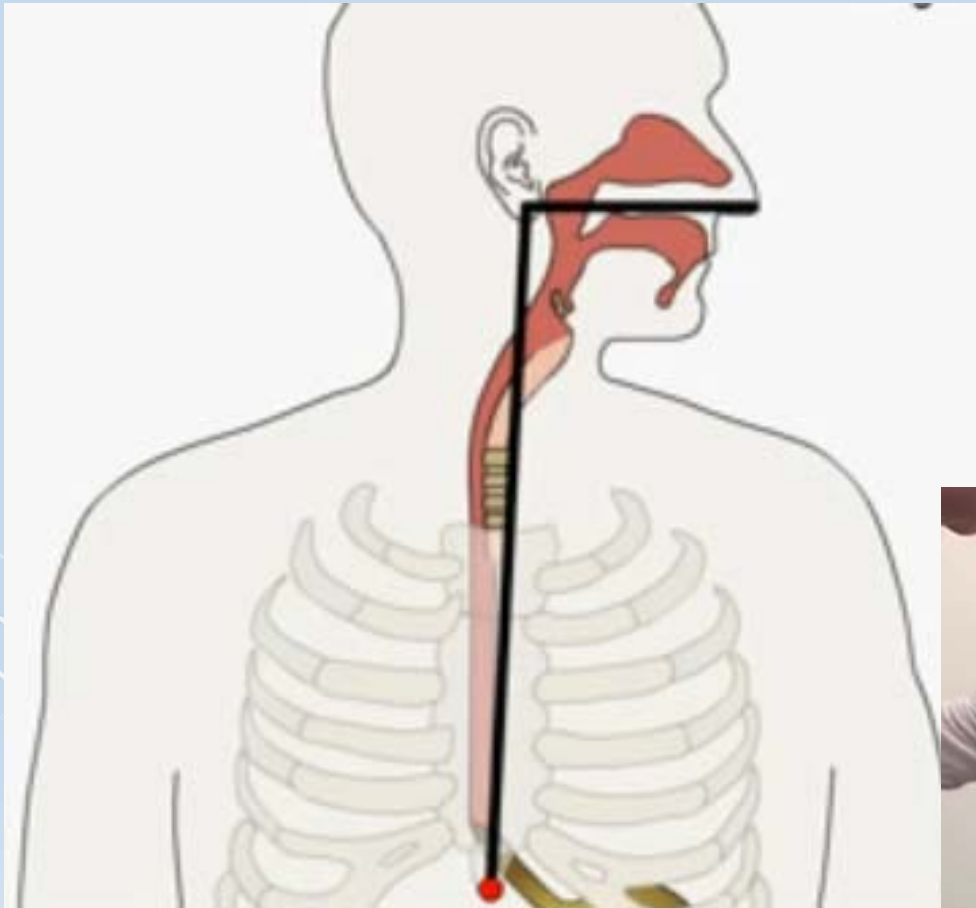
Remember:
Safety & Communication!



Prepare

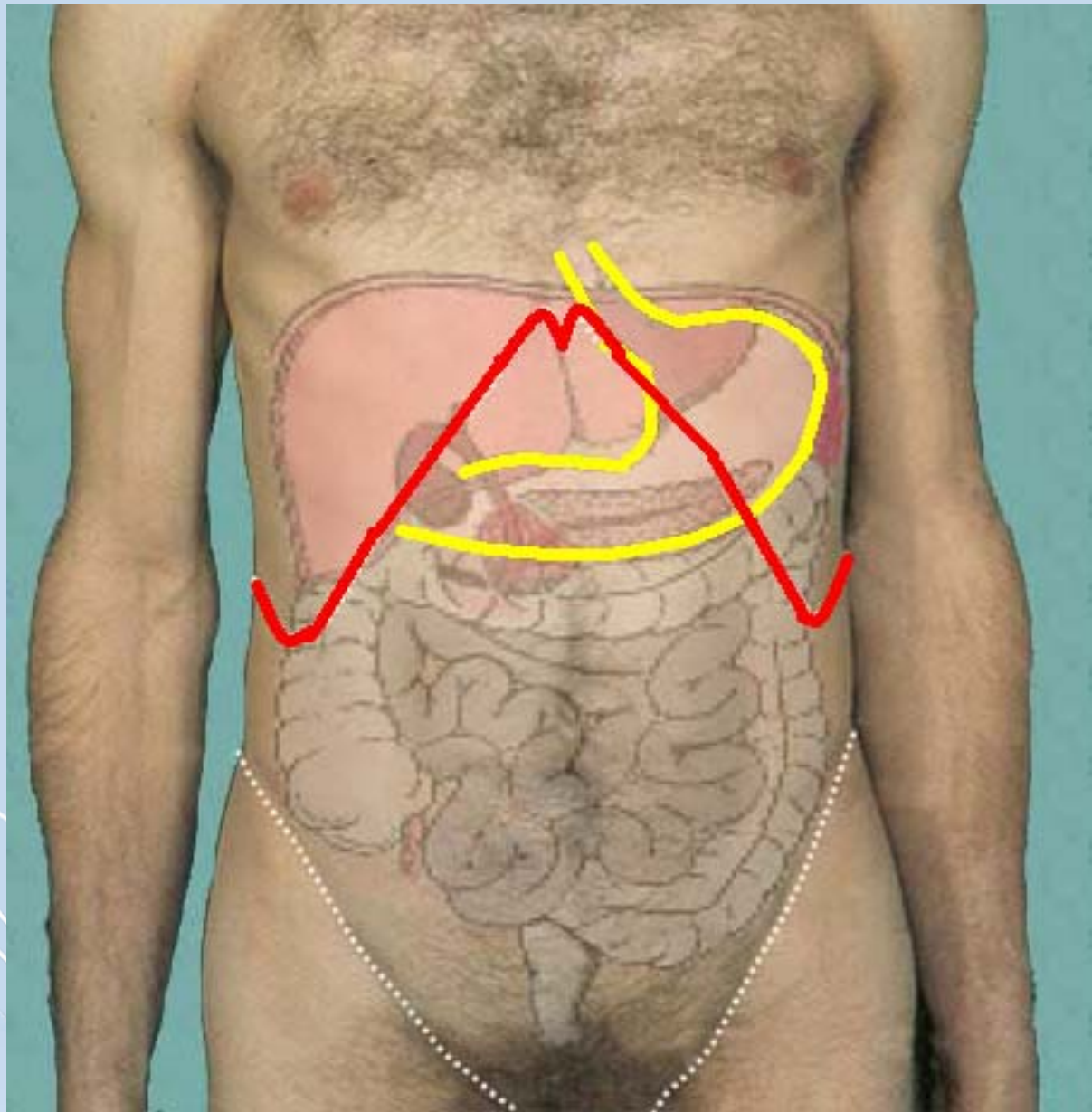
- Wash Hands
- Check identity of patient with request form / records
 - Name / DOB
- Explain procedure to patient
- Sitting position

- Measure with the tube from the **tip of the nose**, to the **tip of their earlobe** and **down to the xyphoid process**.

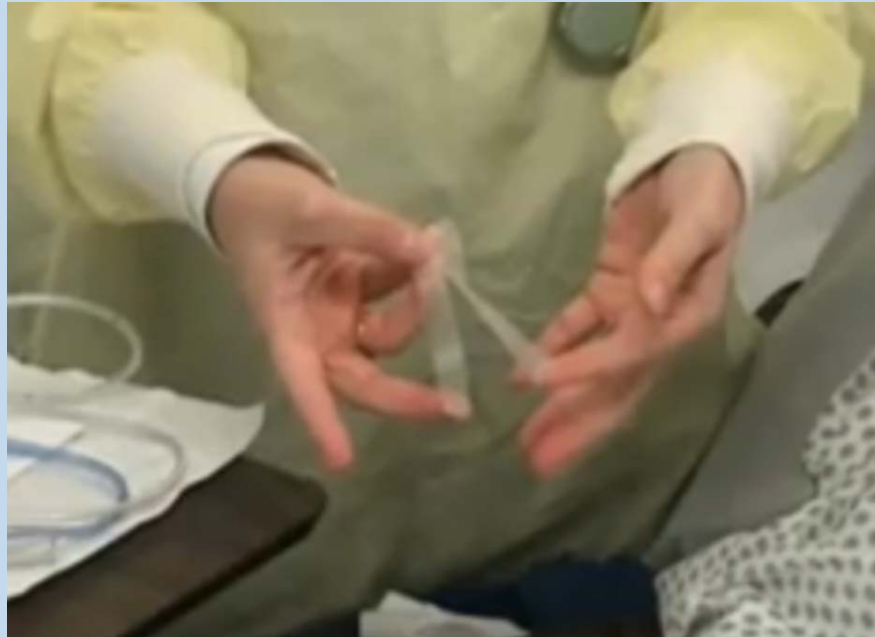


- Tube is then marked at this level indicating how far the tube must be inserted in order to reach the stomach.
- However, most tubes now have several standard depth markings
 - 18" (46cm) / 22" (56cm) / 26" (66cm) / 30" (76cm) from distal end;
 - Infant tubes have 1 cm depth markings.



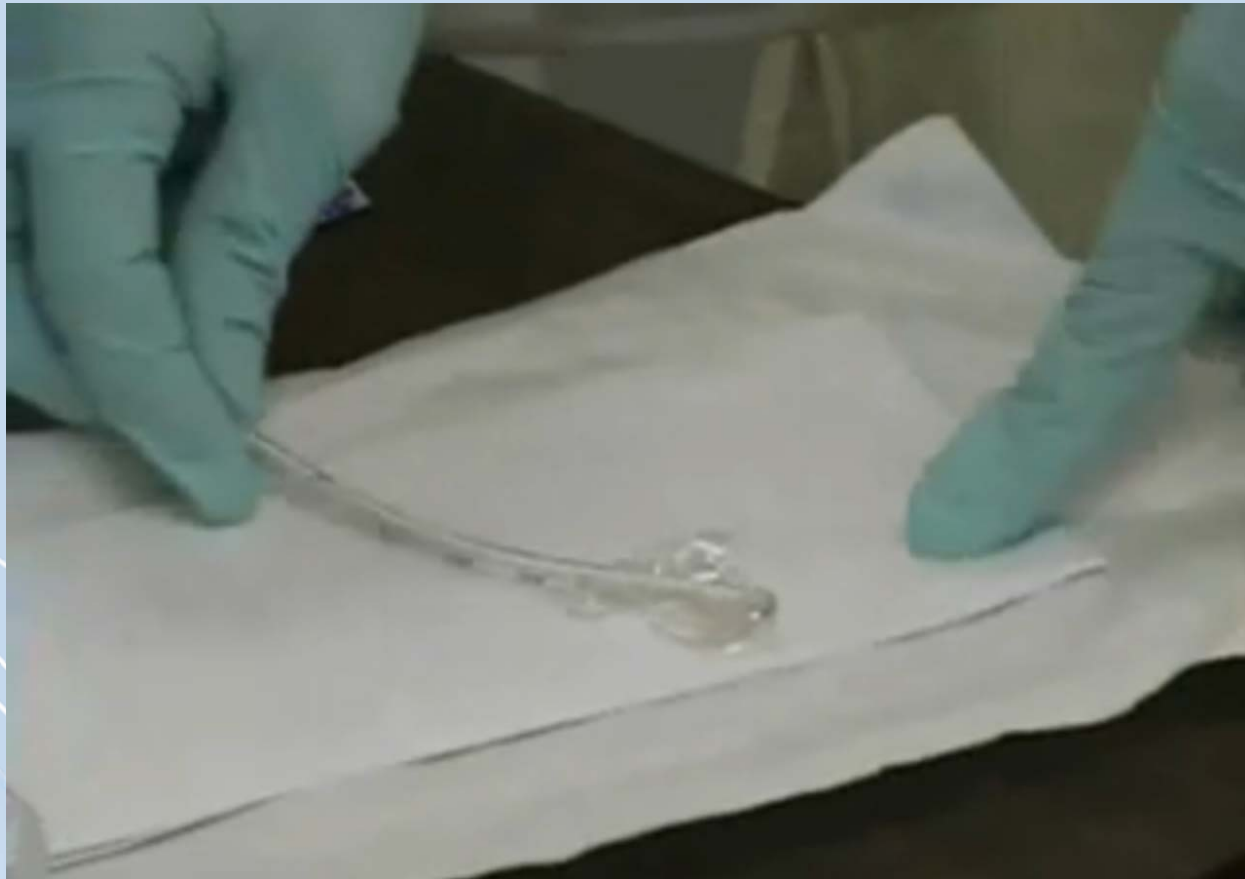

- Prepare surgical tape ready to fix tube in place after insertion



- Put Gloves on.

- Lubricate first 2-4 inches of NGT
 - Help it pass easily

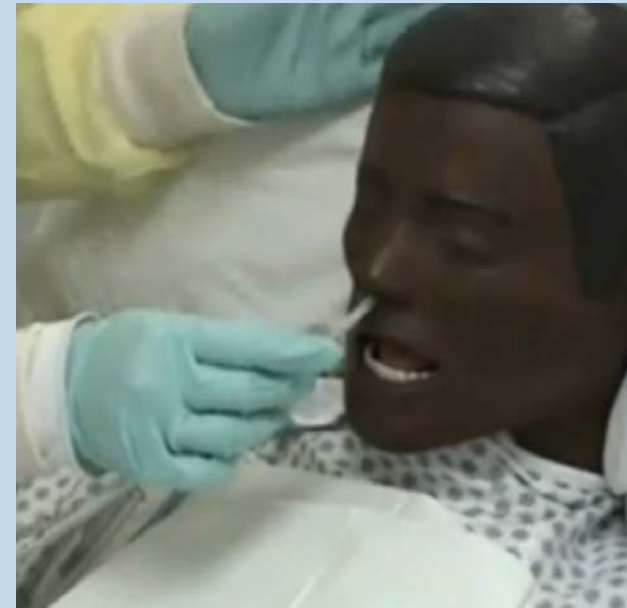
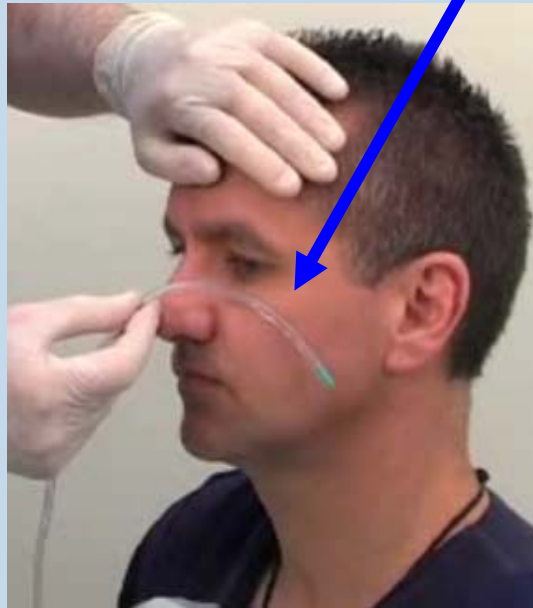
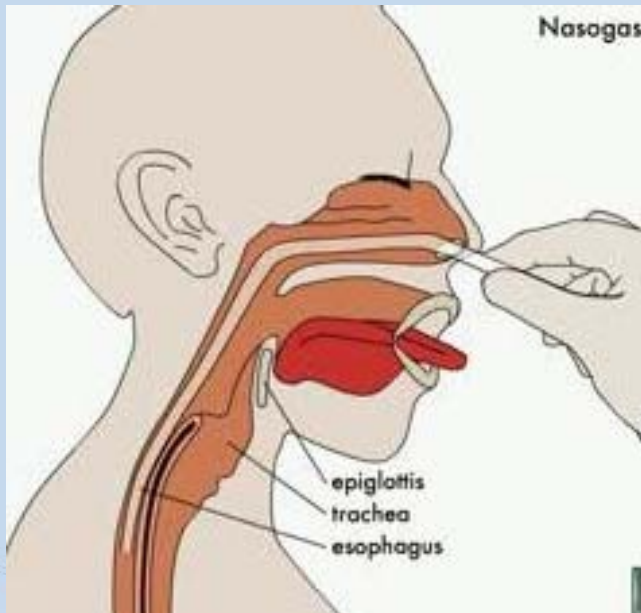Ready to insert...

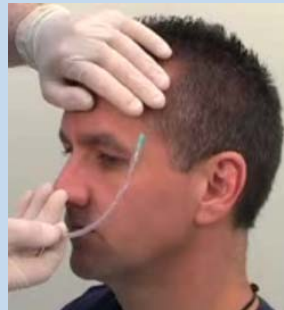Give patient water and remind to take sips during insertion.

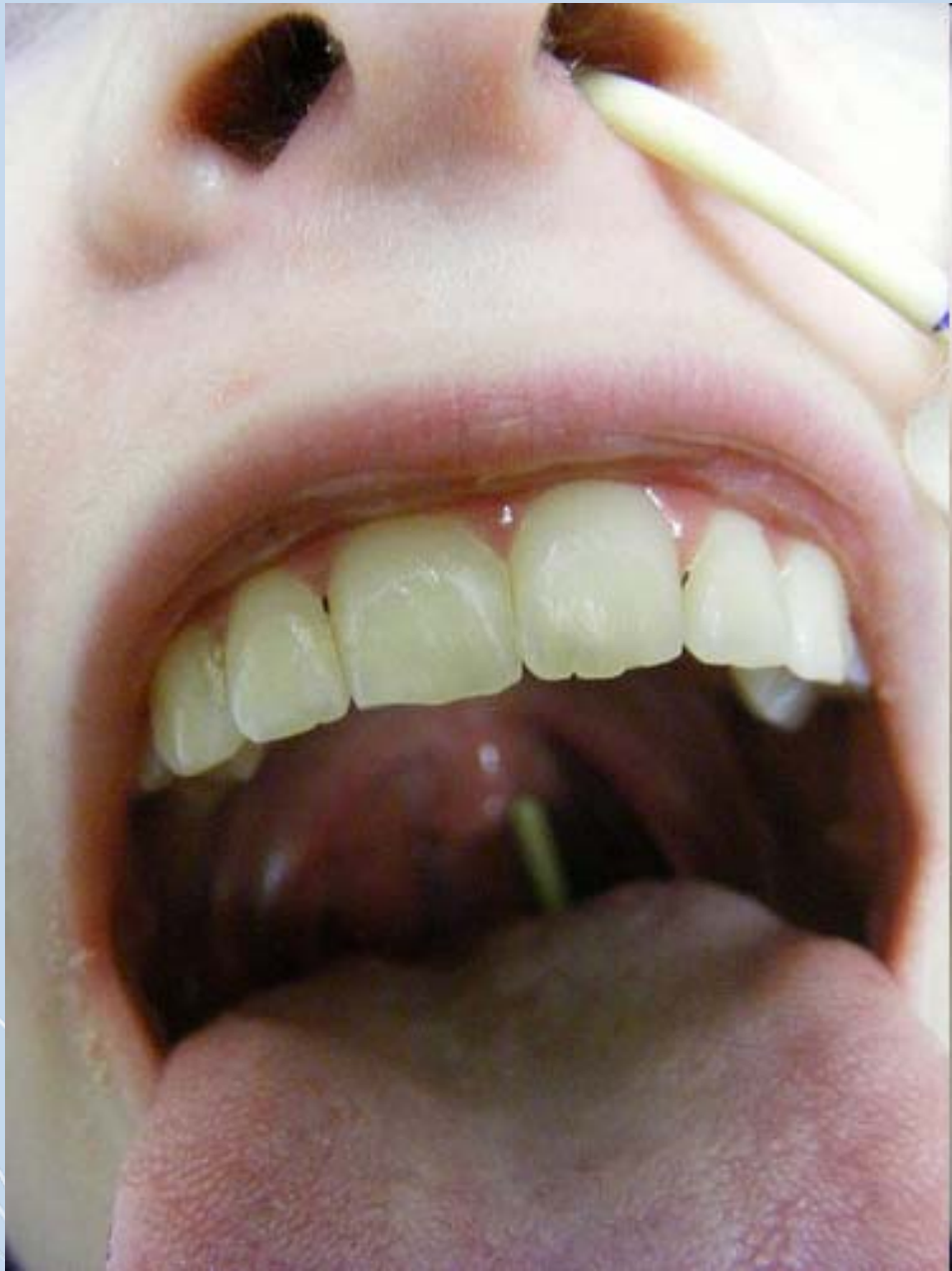

- Insert steadily, until naso-pharynx (resistance)
 - During insertion, the tube must point down

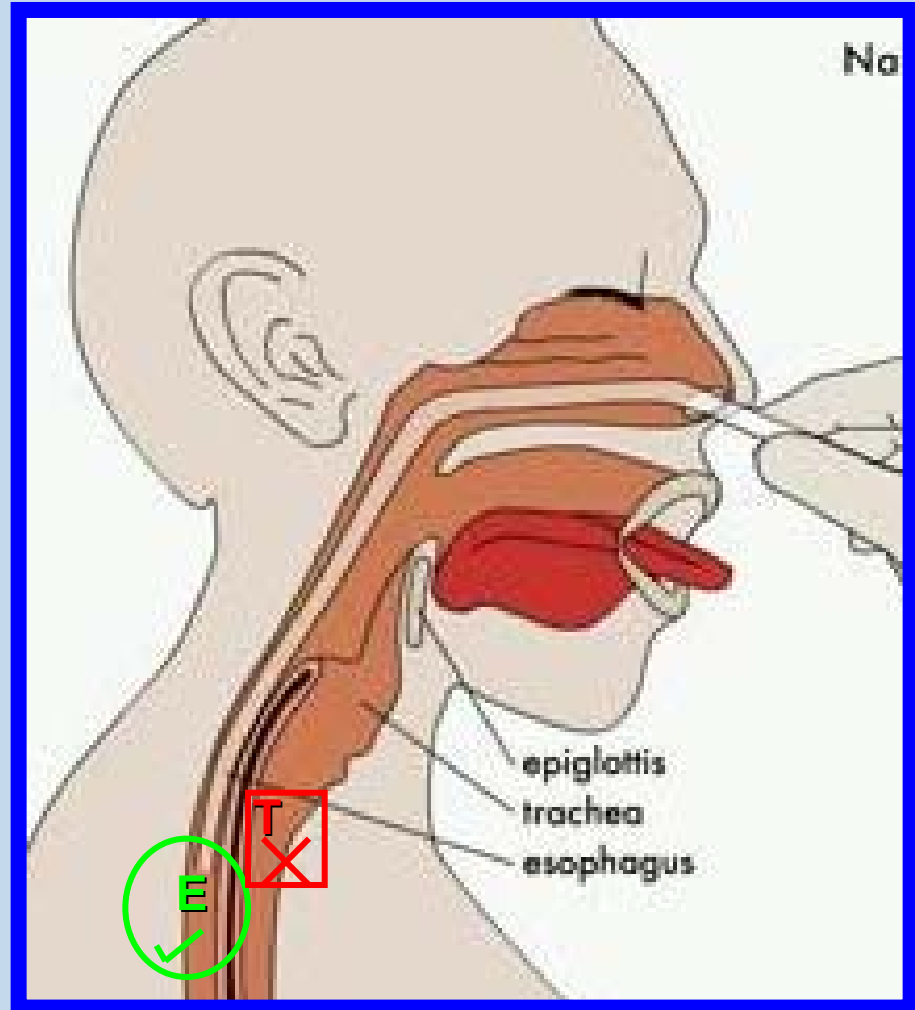
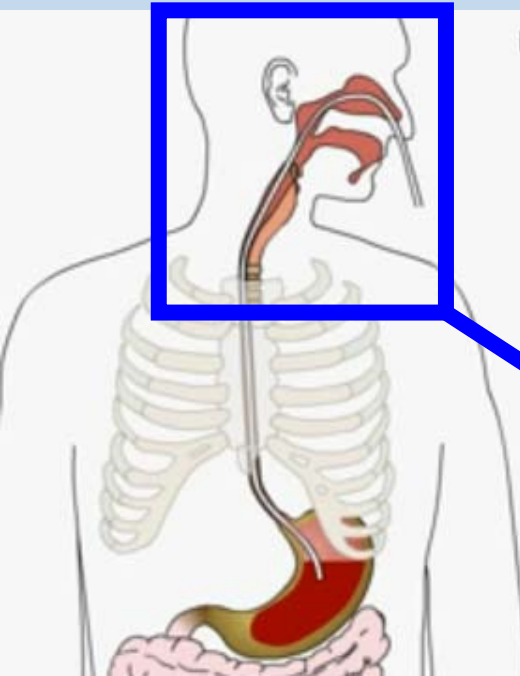


- Then, at naso-pharynx, twist the NGT 180 degrees
 - Minimises risk of the tube coiling at the back of the mouth!





Careful not to go down the wrong hole!



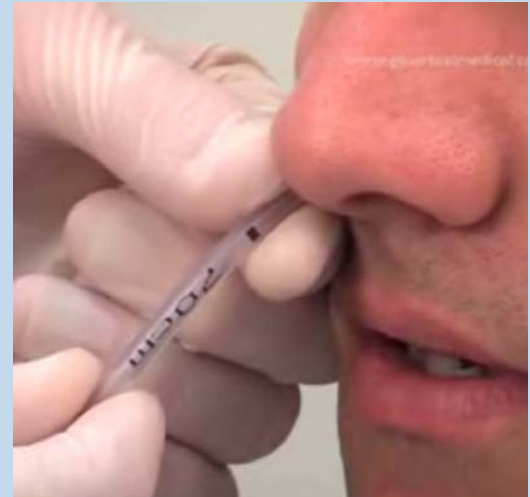- When entering oro-pharynx, greatest risk of gagging (*drink water!*)
- Once in esophagus, goes down easy.

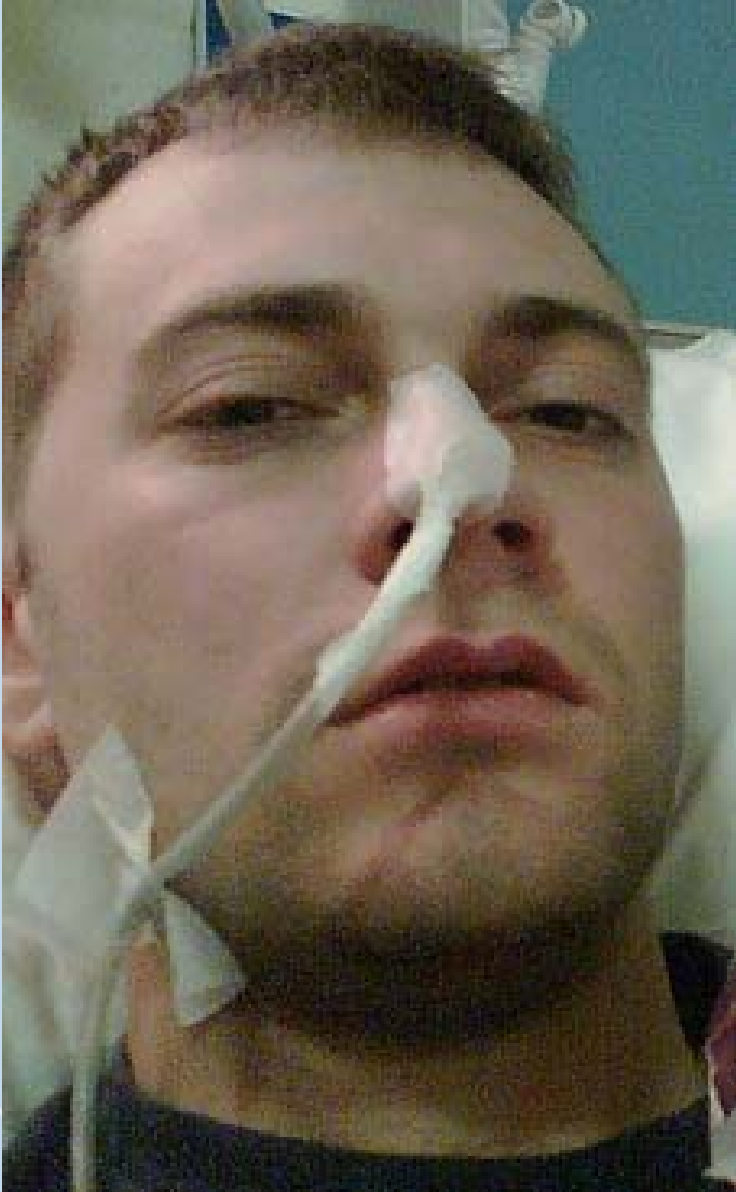- When you reach the mark:
 - Secure tube with the surgical tape

- Attach Drainage / Feeding bag

- Document Procedure in patient records

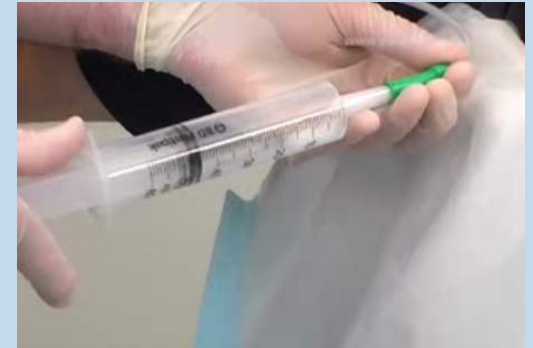- Indication
- Size of tube used
- Amount & nature of aspirate



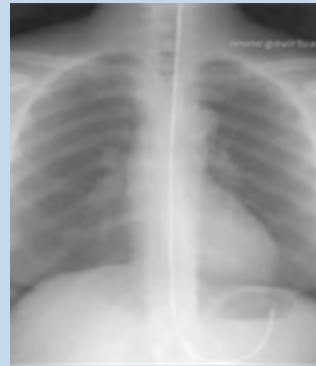

3 Ways to check correct position

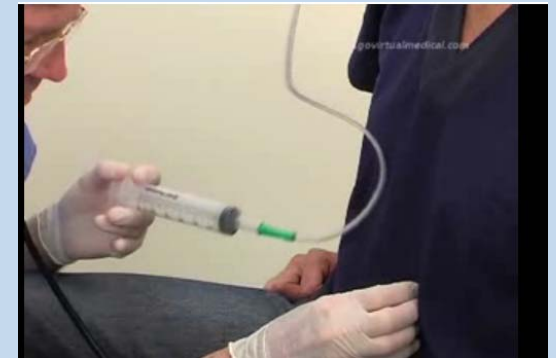1) Check pH of gastric contents



2) Chest X-Ray (CXR)



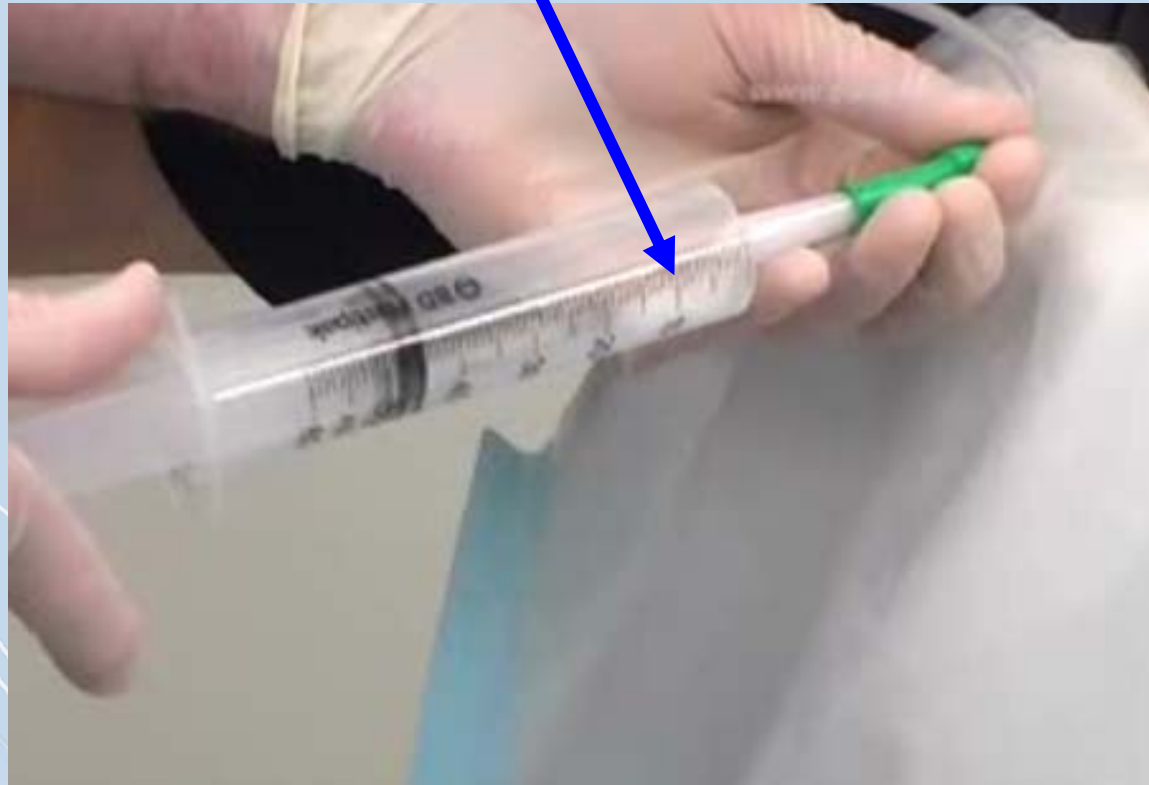
3) With Air bolus



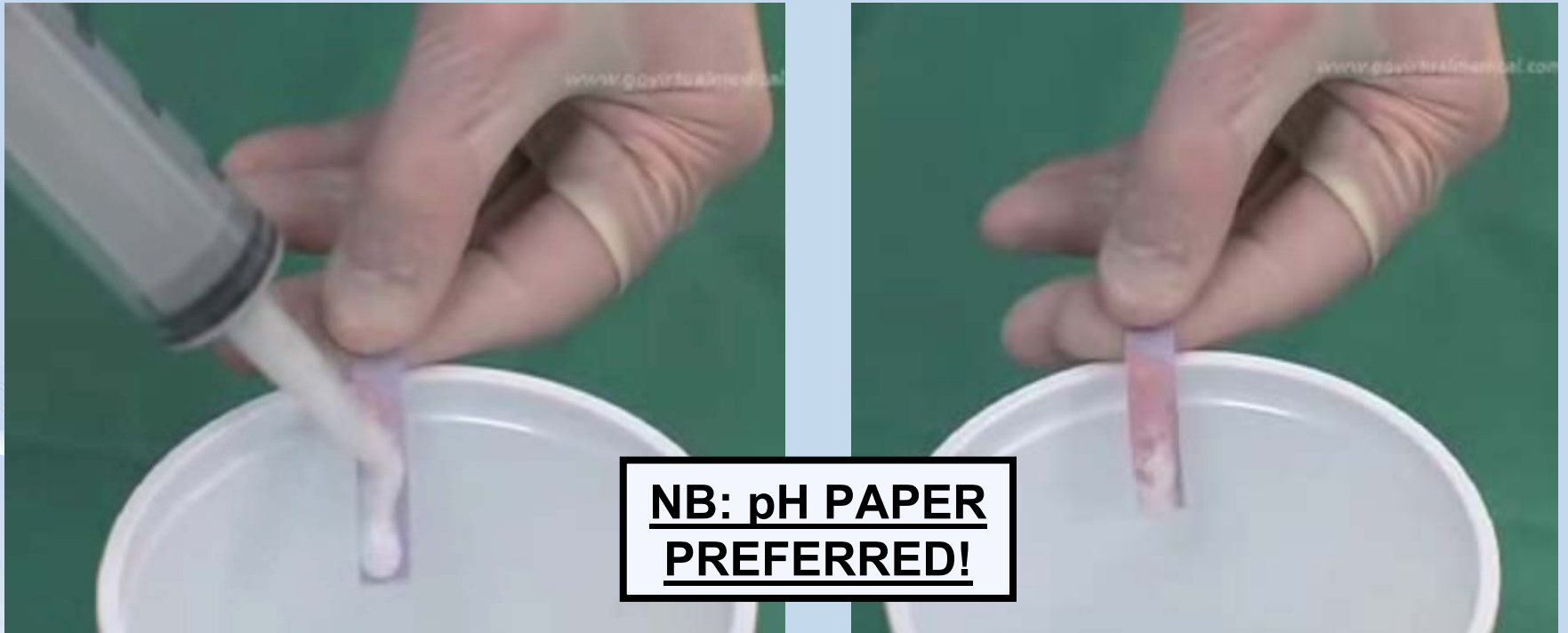
1) Checking pH of gastric contents



- Pinch tube before connecting syringe to end of NGT
- Connect 60ml Syringe
- Withdraw 5-10ml of gastric contents

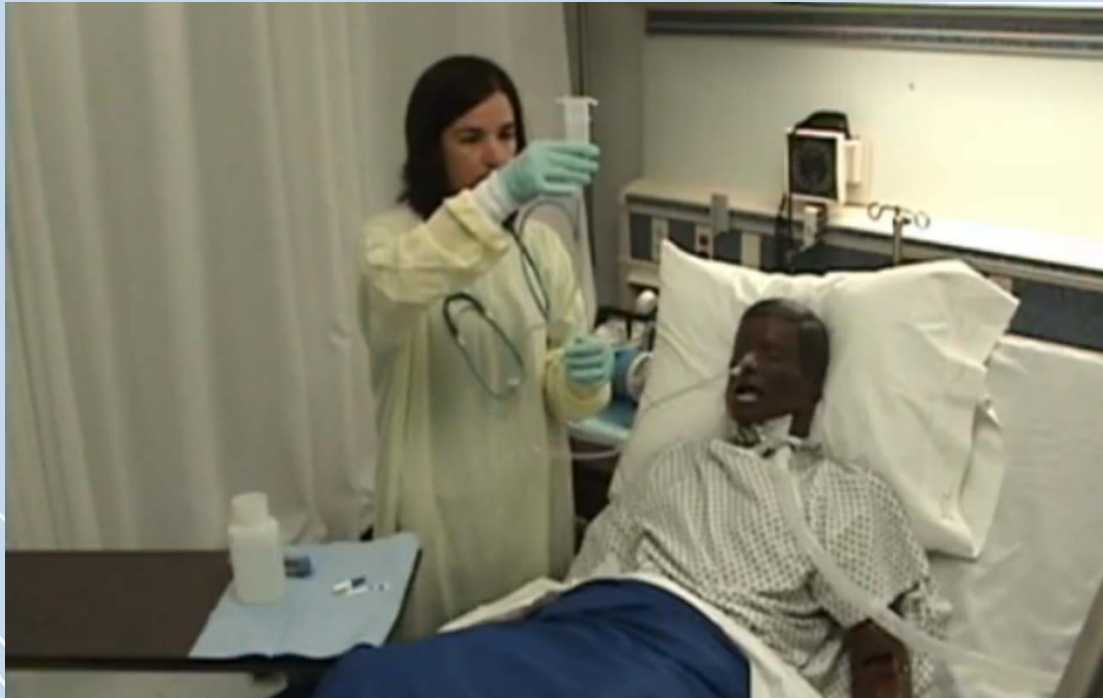

- Place a few drops of the contents on the pH / litmus paper.
 - pH paper preferred!
 - **pH <5.5 = Success!** (blue litmus strip turns red!)



- Return contents of syringe to patient via NGT.

- Flush tube with water to prevent clogging
 - Fill syringe with water, hold above stomach level and allow gravity to carry water to stomach.



- Flush tube with 30ml Air, to remove fluid from the line.

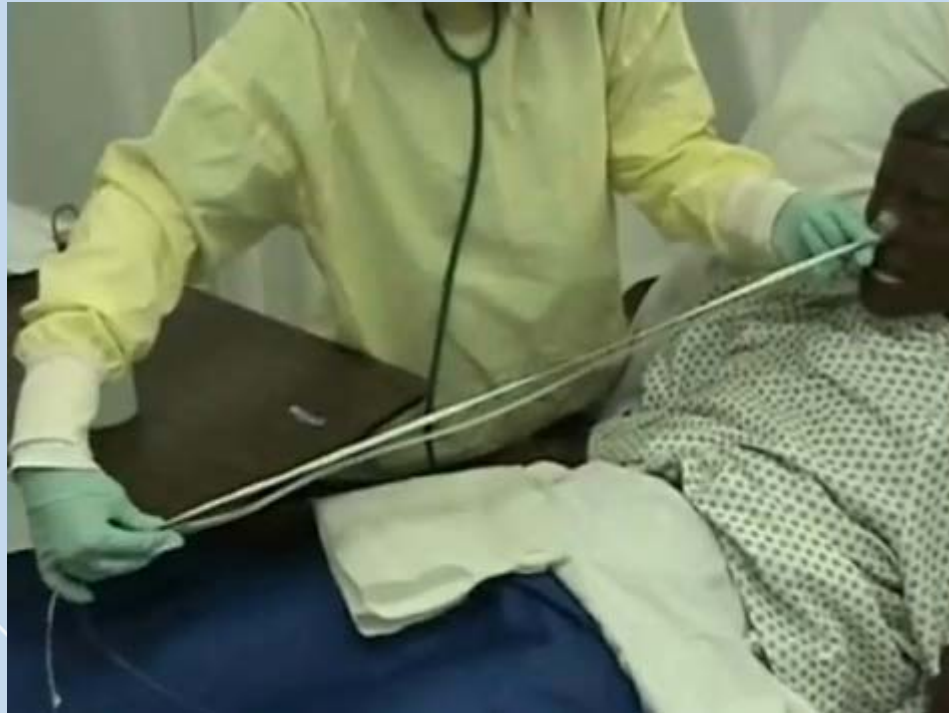

2) Chest X-Ray (CXR)

- Most Reliable

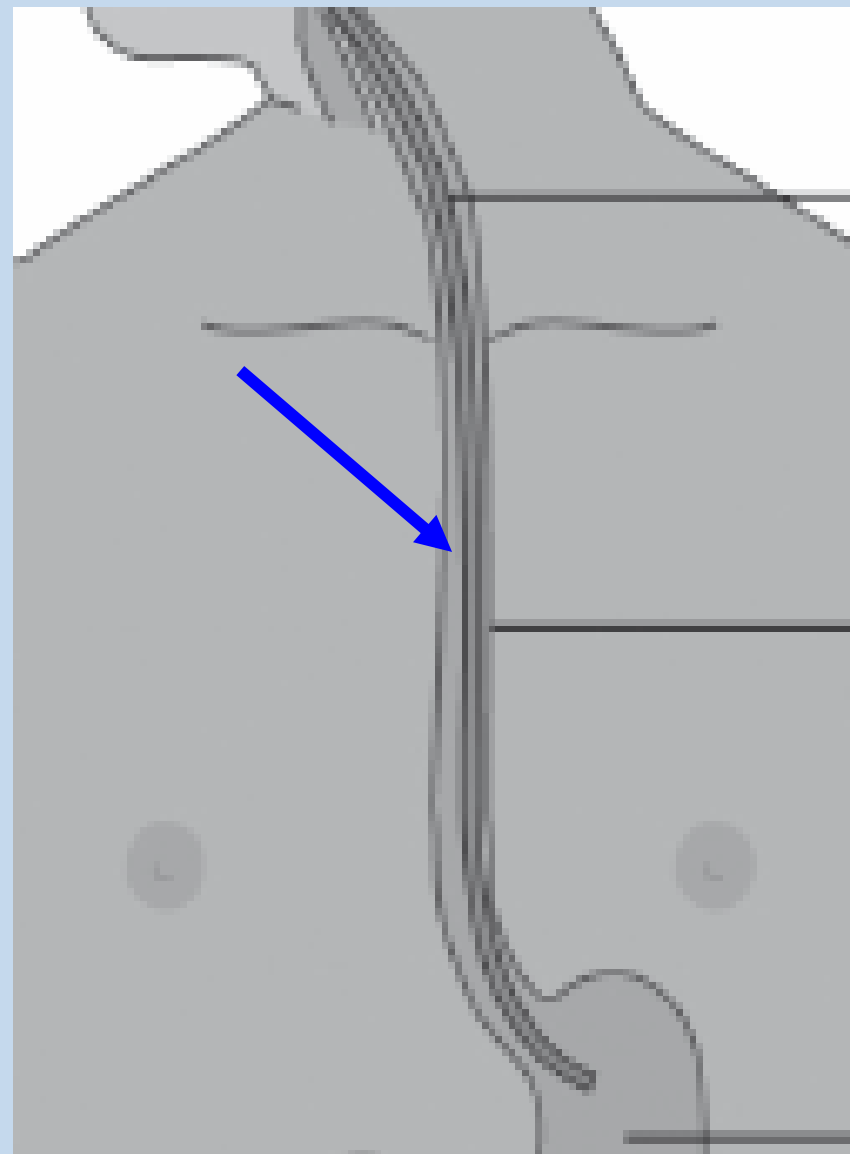
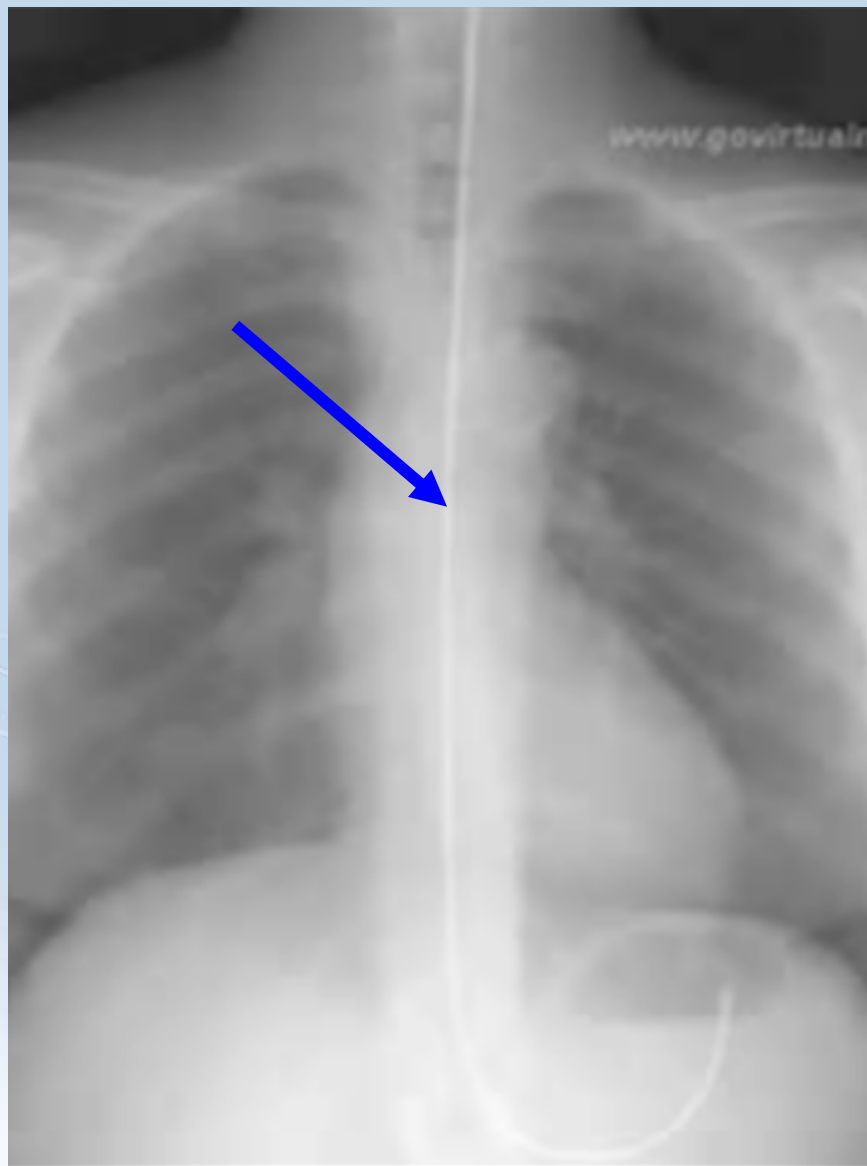
CXR

- Measure length of tube outside of the body. (tip of nose till end). Record.



- Send patient for CXR.

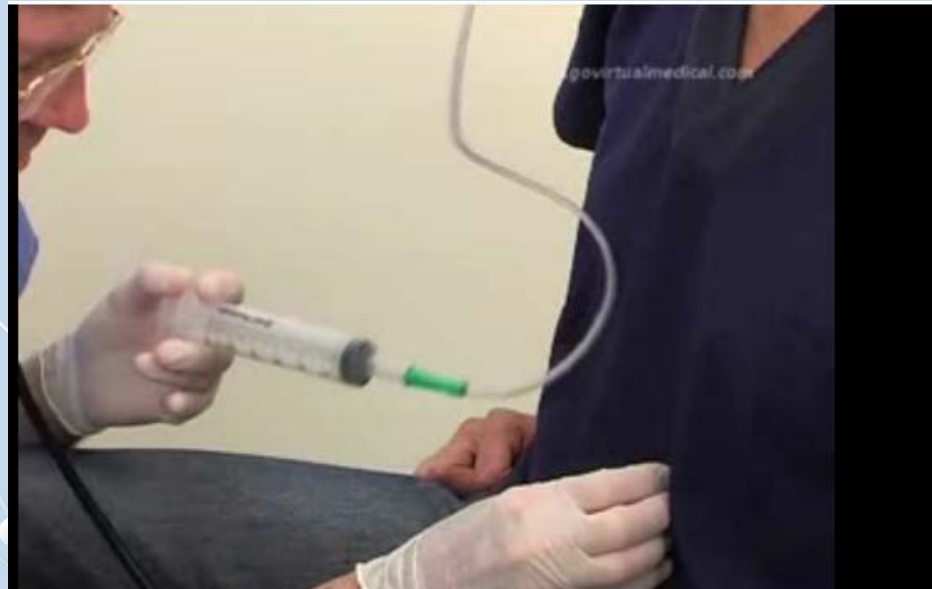- Upon return from CXR, measure tube ensuring it has not moved.



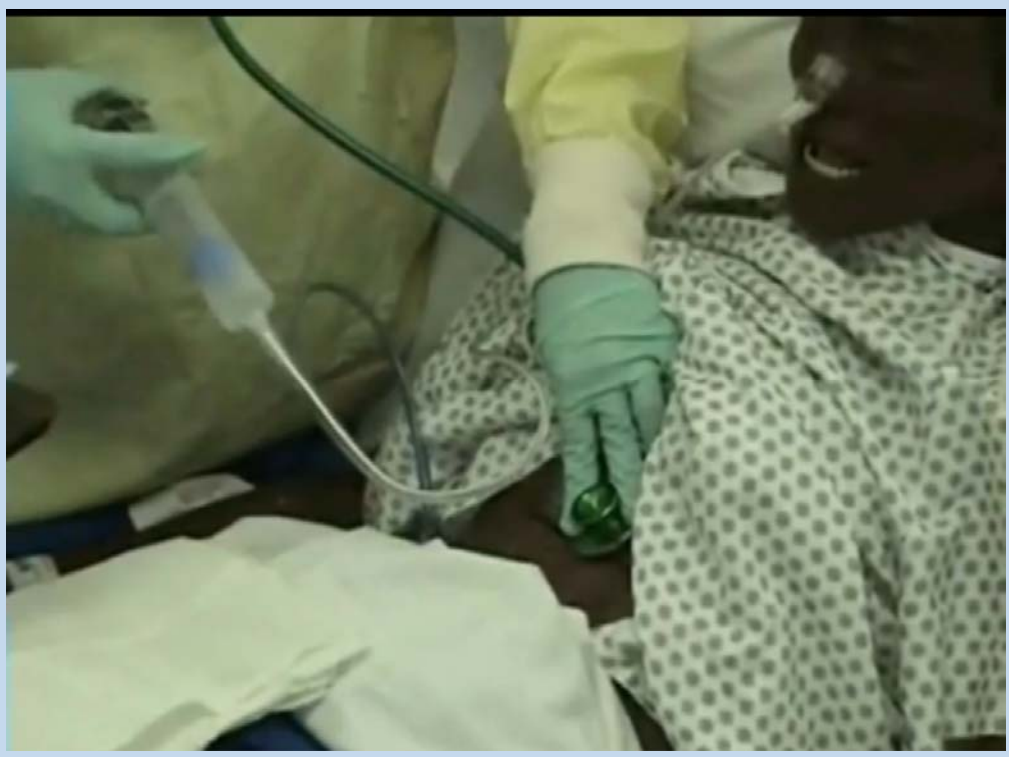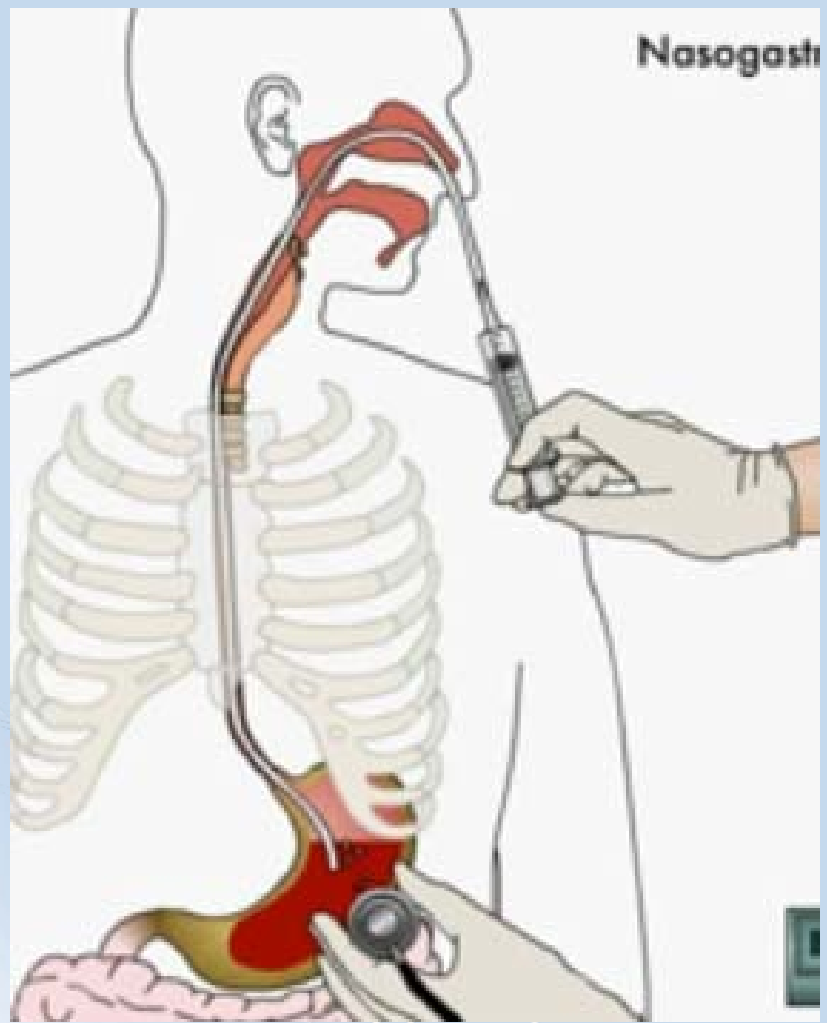
3) Using Air Bolus

- Becoming an out-dated method
Less reliable

- Take 60ml Syringe
- Pinch tube before connecting it to end of NGT
- Instill approx 30ml air to stomach.
- At the same time, listen in epi-gastric area with stethoscope for 'whoosh' & bubbling.
- YES: Tip of NGT is in stomach = Success!



Nasogastric



MAINTAINENCE

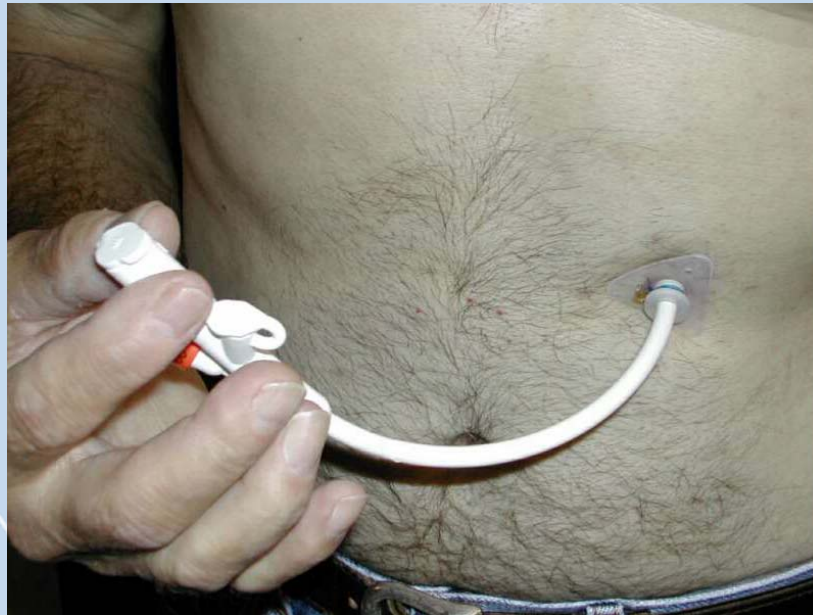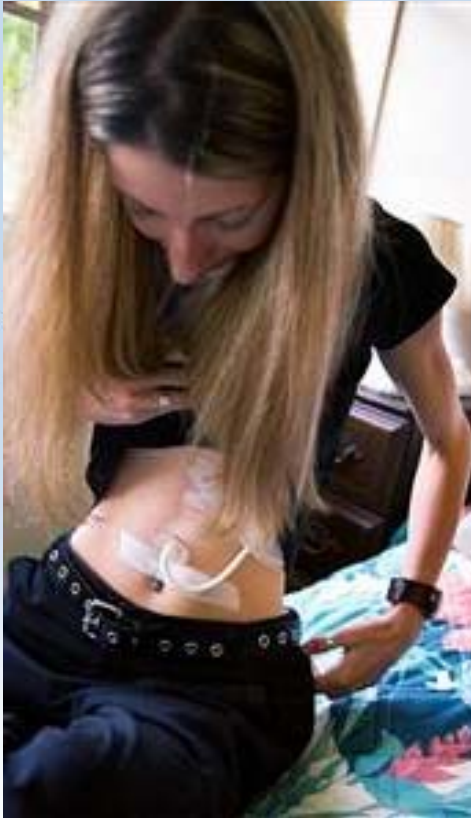- Check positioning at least one a day
 - Checking the mark OR
 - Measure length of tube outside of body
- Mouth, Lip, Nose Care every 2 hrs
 - Keep Moist
 - Tissues
 - Toothbrushing

COMPLICATIONS & SIDE EFFECTS

- Pain & Discomfort
- Nose bleeds
- Sinusitis
- Sore throat
- Vomiting
- Erosion of nose where tube is attached
- Pulmonary aspiration
- Perforation of stomach
- Esophagitis
- Tracheal/ Duodenal intubation

ALTERNATIVES

- Longer Term Feeding:
 - **PEG feeding** (percutaneous endoscopic gastrostomy)
 - More possible complications (infection, peritonitis etc)



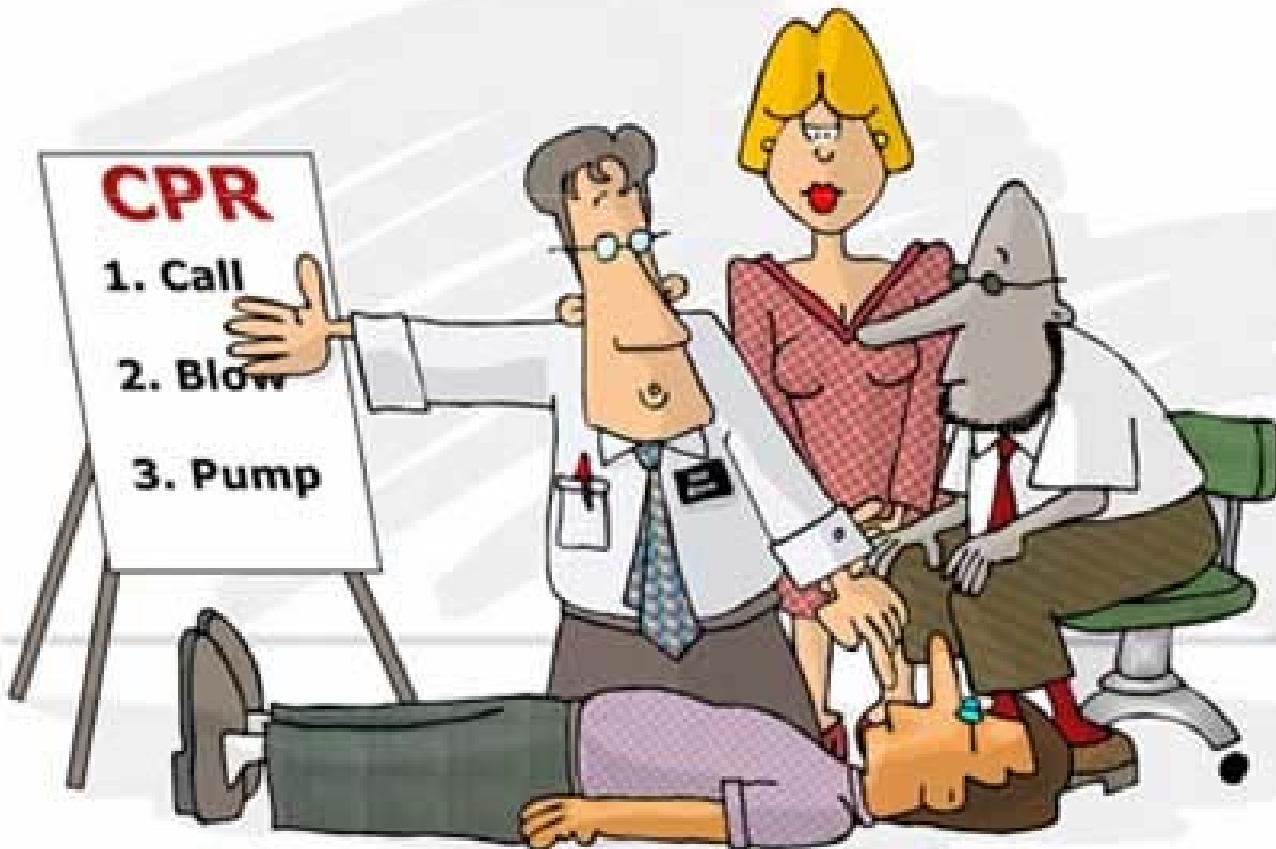
FURTHER READING

- Differences in procedure for children
- NGT Removal

LINKS

- http://www.youtube.com/watch?v=WgfNa7dzSn0&feature=player_embedded
- http://en.wikipedia.org/wiki/Nasogastric_intubation
- http://www.youtube.com/watch?v=WgfNa7dzSn0&feature=player_embedded
- Part 1:
 - <http://www.youtube.com/watch?v=TDXczuzHCeY>
- Part 2:
 - <http://www.youtube.com/watch?v=cTeEfULr0d0>
- <http://www.youtube.com/watch?v=6oxCda6FKUY&feature=related>

First Aid



EMERGENCY FIRST AID

ABC'S OF IMMEDIATE FIRST AID ACTION

A Open the Airway **B** Check for Breathing **C** Check for Circulation

MOUTH TO MOUTH RESUSCITATION

- Place victim on his/her back. Open the airway by tilting the forehead back. Head tip - Chin lift.
- Place fingertips of other hand under the bony part of the chin. Place your ear close to the victim's mouth and nose. Look at victim's chest to see if it rises and falls. Listen and feel for about 5 seconds for air to be exhaled. Pinch nostrils shut and make a tight seal around victim's mouth. Give two slow (1-1.5 seconds per ventilation) breaths.

CHOKING

If choking victim can cough, speak or breathe, do not interfere. Call a paramedic. IF VICTIM CANNOT BREATHE:

- Stand behind victim and put arms around victim's waist. Make a fist, placing thumb edge against victim's abdomen between navel and rib cage.
- Group fist with other hand and give 6-10 forceful upward thrusts. Repeat until object is dislodged.

SEVERE BLEEDING

- Place clean compress over wound and apply direct pressure. Elevate limb if bleeding severely.
- When bleeding stops, apply pressure bandage. Do not cut off circulation by tying bandage too tightly.

FRACTURE

- Do not move victim.
- Splint injured area.
- Treat for shock, being careful when handling injured area.

BURNS

- Hold burn under cold running water or apply a cold compress.
- Cover burn with clean bandage.
- DO NOT treat burn with grease or butter.

EYE INJURY

CHEMICAL BURNS OF THE EYE

- Flush eye with eye and skin neutralizer or clear water for 15 minutes.

OBJECT IN THE EYE (PARTICLE):

- Do not rub eyes.
- Put eyelid over eye and hold to cause tearing. Tears will normally cause object to wash free.
- If above procedure is unsuccessful, hold eyelid up and have victim look downward.
- Place a cotton tip applicator horizontally across the eyelid and hold back over allich.
- Carefully remove object with Eye Magnet Loop or Ramp, clean cloth.

ELECTRIC SHOCK

- Remove victim from source of shock using stick or other non-conductive object.
- Begin mouth to mouth resuscitation if breathing has stopped.
- Call for medical assistance promptly.

SHOCK DUE TO INJURY

- Clear the airway.
- If the face is pale, elevate the feet.
- If the face is red, elevate the head and shoulders.
- Keep the victim warm.

YOUR LOCATION

Paramedic _____
 Police _____
 Fire _____
 Doctor _____
 Poison Control Center _____

This sign is a compilation of general first aid information obtained from sources believed to be reliable. However, there is no guarantee as to the medical validity of the information or the results obtained from using said information. This does not represent that every acceptable safety procedure is contained herein, or that abnormal or unusual circumstances may not warrant or require further or additional procedure.

EMERGENCY TELEPHONE NUMBERS

FOR LOCAL SALES AND SERVICE

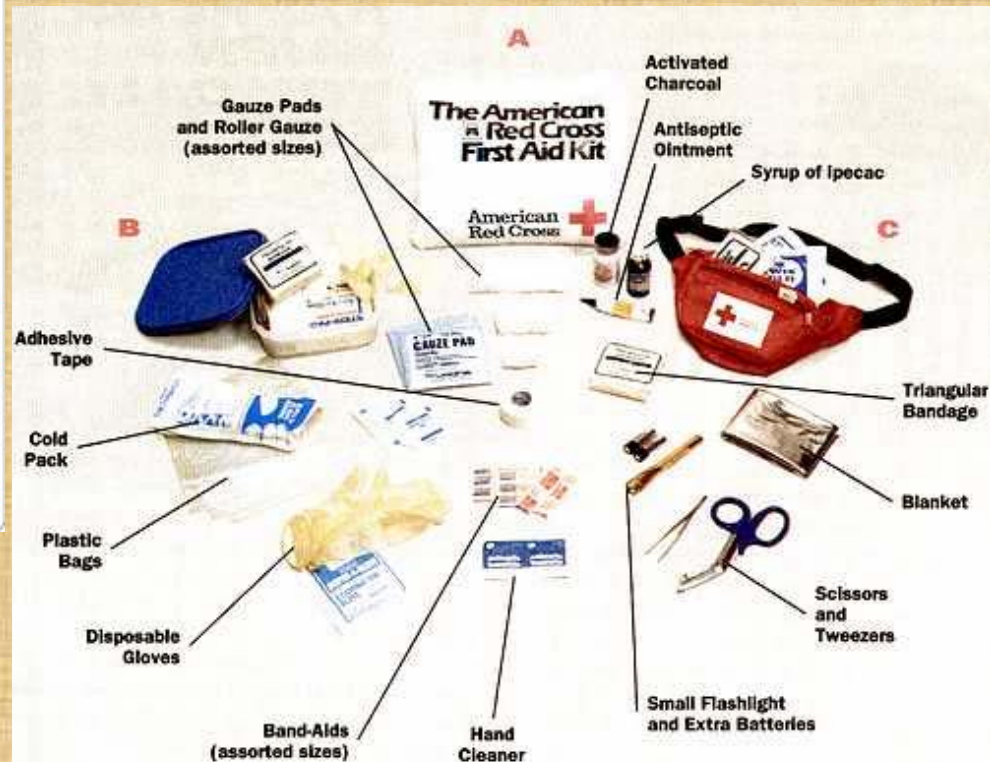FIRST AID DIRECT

ABC's:

D: Danger
 R: Response

A: Airways
 B: Breathing
 C: Circulation

D: Disability (acute problems) / defib if CPR
 E: Exposure (to more danger)



Equipment:

What is First Aid and what are its aims?

“Provision of initial care for an illness or injury.”

3 aims:

Preserve life

Prevent further harm - this covers both external factors, such as moving a patient away from any cause of harm, and applying first aid techniques to prevent worsening of the condition, such as applying pressure to stop a bleed becoming dangerous.

Promote recovery - first aid also involves trying to start the recovery process from the illness or injury, and in some cases might involve completing a treatment, such as in the case of applying a plaster to a small wound.

Before CPR – Primary Survey

- 1) **Danger** - Are you or the casualty in any danger? If you have not already done so, make the situation safe and then assess the casualty.
- 2) **Response** - If the casualty appears unconscious check this by shouting: **'Can you hear me?', 'Open your eyes'** and gently shaking their shoulders.

If there is a **response**
AND no further danger:

- 1) **leave** the casualty in the position found and summon help if needed.
- 2) Treat any condition found and **monitor vital signs** - level of response, pulse and breathing.
- 3) Continue **monitoring** the casualty either until help arrives or he recovers.

If there is **no response**:

- 1) Shout for **help**.
If possible, leave the casualty in the position found and **open the airway**.
- 2) If this is not possible, turn the casualty onto their **back** and open the airway.

3) **Airway** - Open the airway by placing one hand on the casualty's forehead and gently tilting the head back, then lift the chin using 2 fingers only.

- This will move the casualty's tongue away from the back of the mouth.

4) **Breathing:**

- **Look** to see if the chest is rising and falling.
- **Listen** for breathing.
- **Feel** for breath against your cheek.

no more than 10 seconds

- 1) If the casualty is **breathing normally**, place them in the **recovery position**.
- 2) 2) Check for other life-threatening conditions such as severe bleeding and treat as necessary.

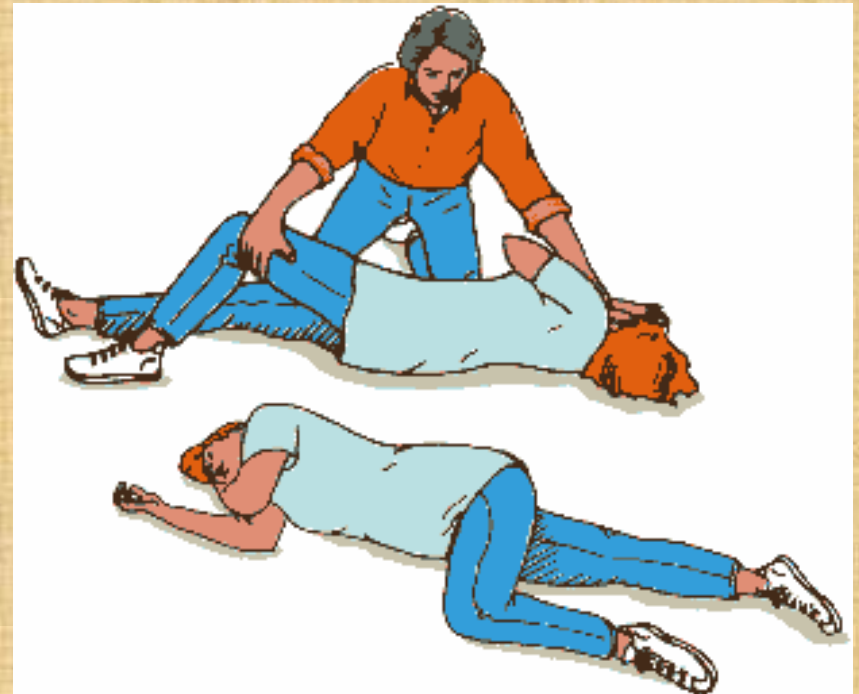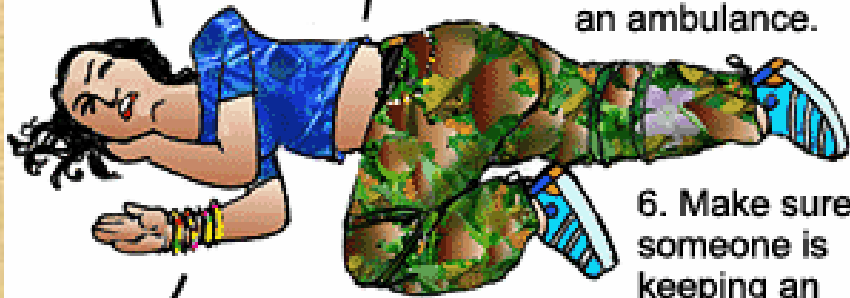1) If the casualty is **not breathing normally** or if you have any doubt whether breathing is normal **begin CPR!!**



Recovery Position

The Recovery position is for when someone is unconscious (passed out) but otherwise unhurt, and breathing normally.

1. Check for any injuries. **If they are hurt, don't move them!** Call 999 and ask for an ambulance.
2. Bend arm to stop person rolling over.
3. Gently roll person onto their side.
4. Bend leg to support position.
5. Tilt head back and tuck hand under chin to keep mouth open.
6. Make sure someone is keeping an eye on them.



CPR – Cardiopulmonary Resuscitation

- Physical interventions to create artificial circulation by **chest compressions**, and **artificial respiration** by the rescuer exhaling into the patient (or using a device to simulate this).
- Its main purpose is to maintain a flow of oxygenated blood to the brain and the heart – both are vulnerable to damage from hypoxia.
- Some brain cells start dying within **less than 5** minutes of hypoxia!

- **CPR for adults: DEEP INHALATIONS AND EXHALATIONS!**

30 compressions : 2 breaths for 2 minutes

rate of 100/min ventilation: 8 – 10 breaths/min

- **CPR for children (1 year to puberty): SHALLOW BREATHS AND DON'T EMPTY YOUR LUNGS COMPLETELY!**

Start: 5 rescue breaths & 30 compressions

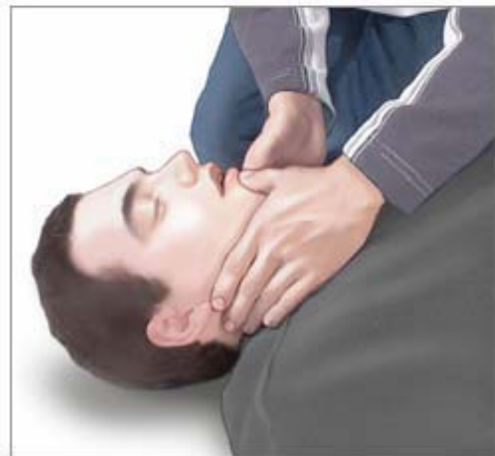then continue with 30 compressions: 2 breaths

- **CPR for babies (birth to 1 year): FILL YOUR CHEEKS WITH AIR AND USE THIS!**

Start: 5 rescue breaths & 30 compressions

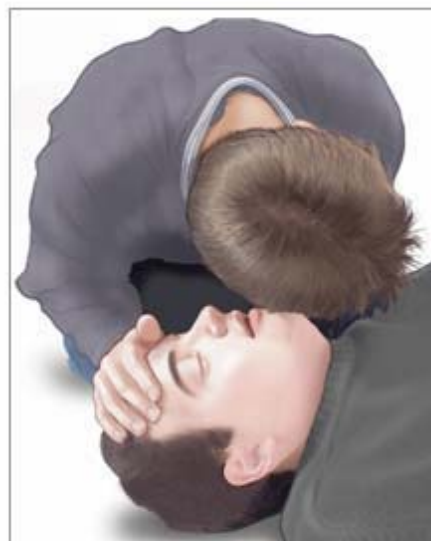then continue with 30 compressions: 2 breaths

- **Agonal breathing** : This is common in the first few minutes after a sudden cardiac arrest. It usually takes the form of **sudden irregular gasps for breath**. It should not be mistaken for normal breathing and if it is **CPR should be started**.



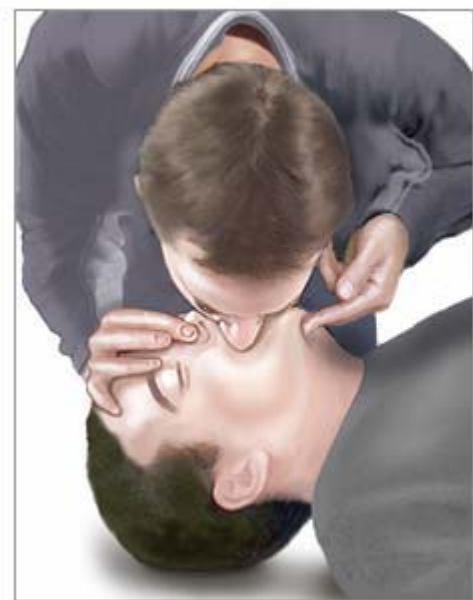
If you suspect the victim has a neck injury, place your hands alongside the cheeks and pull the face toward you with your index fingers

ADAM.



Look, listen and feel for breathing and pulse

ADAM.



Place your mouth over the victim's mouth and exhale

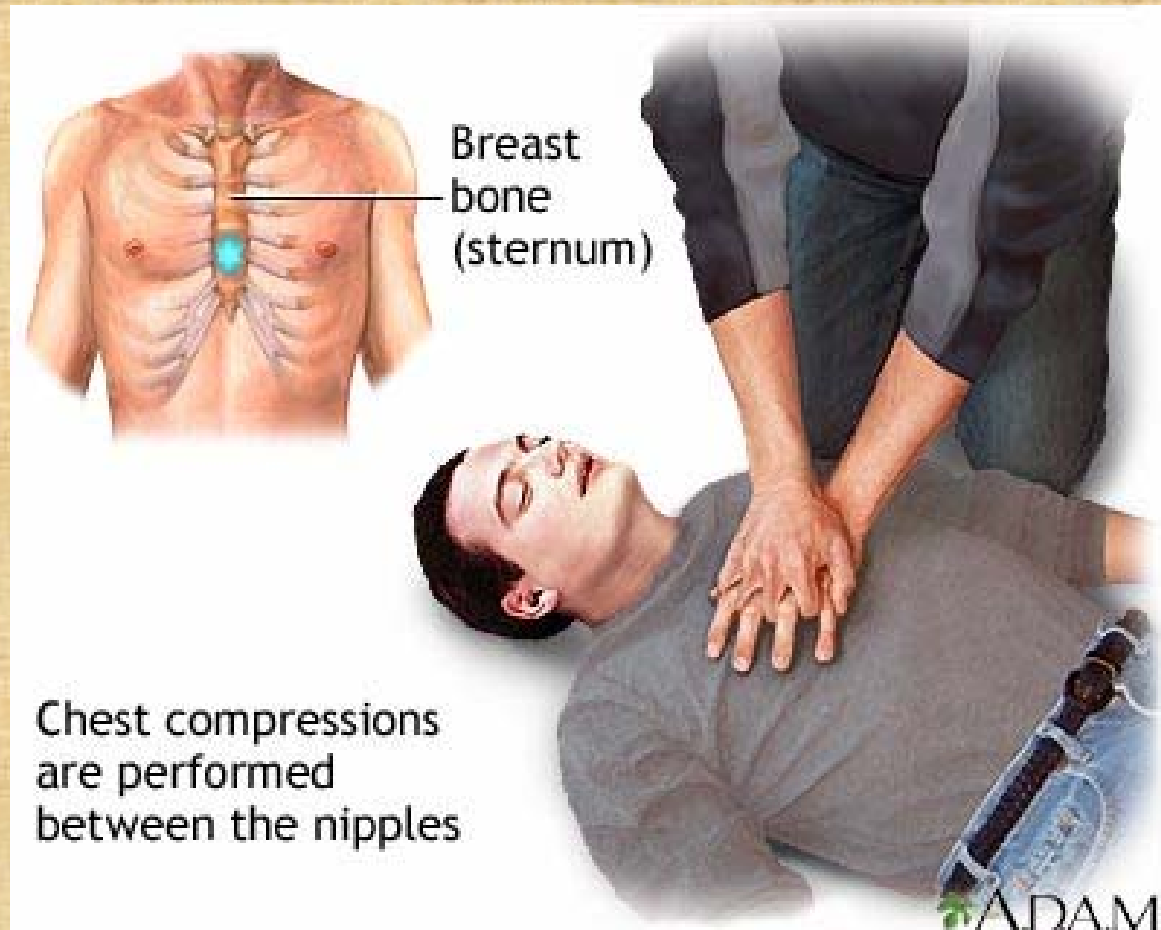
ADAM.



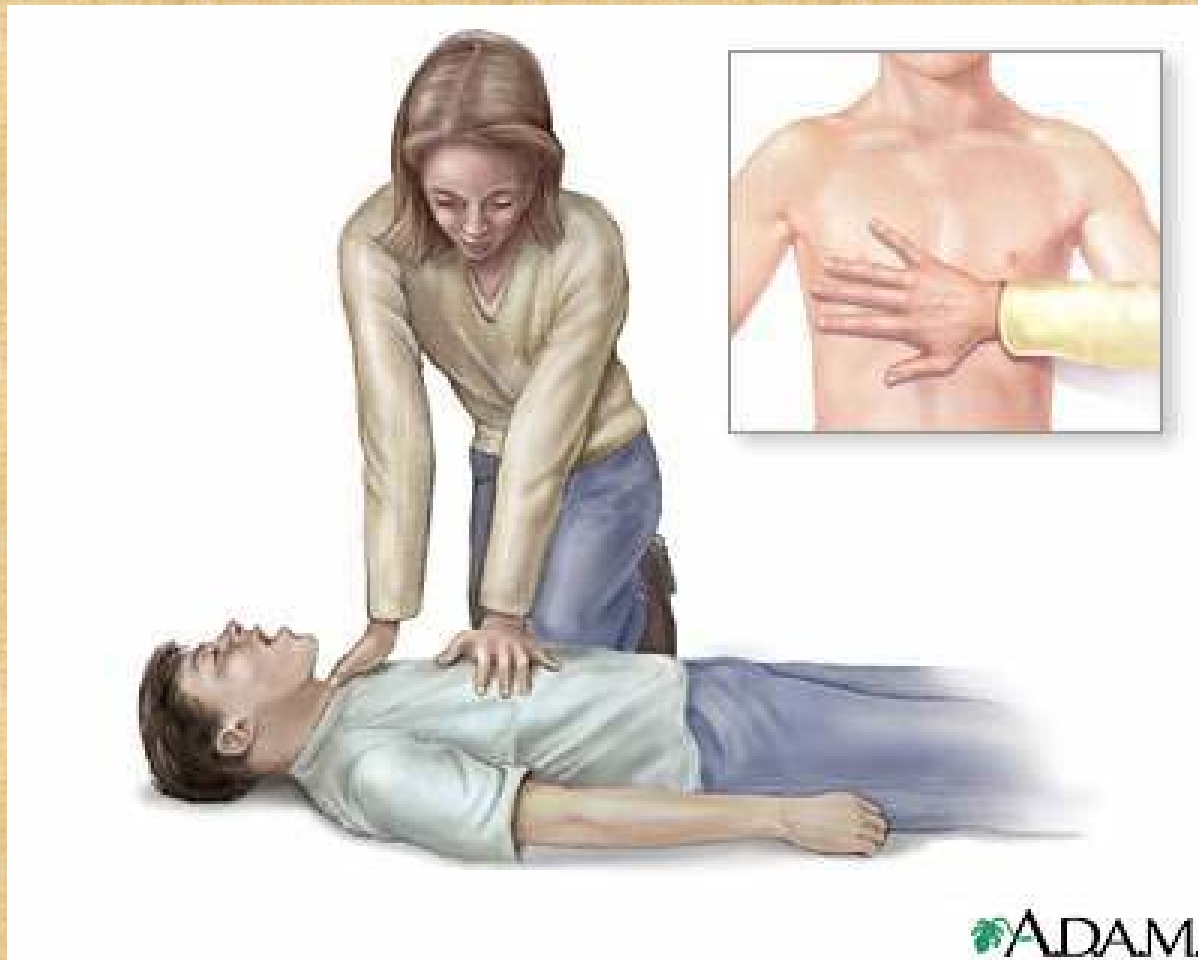
While pushing back on the forehead, use your other hand to lift the chin forward

ADAM.

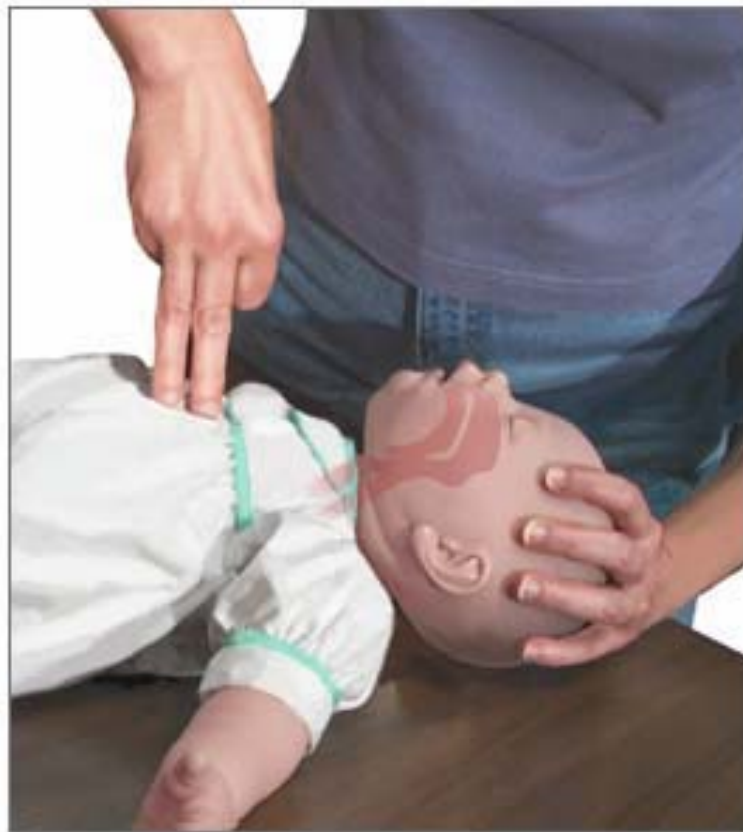CPR on adults



CPR on children: 1yr - puberty



CPR on infants:



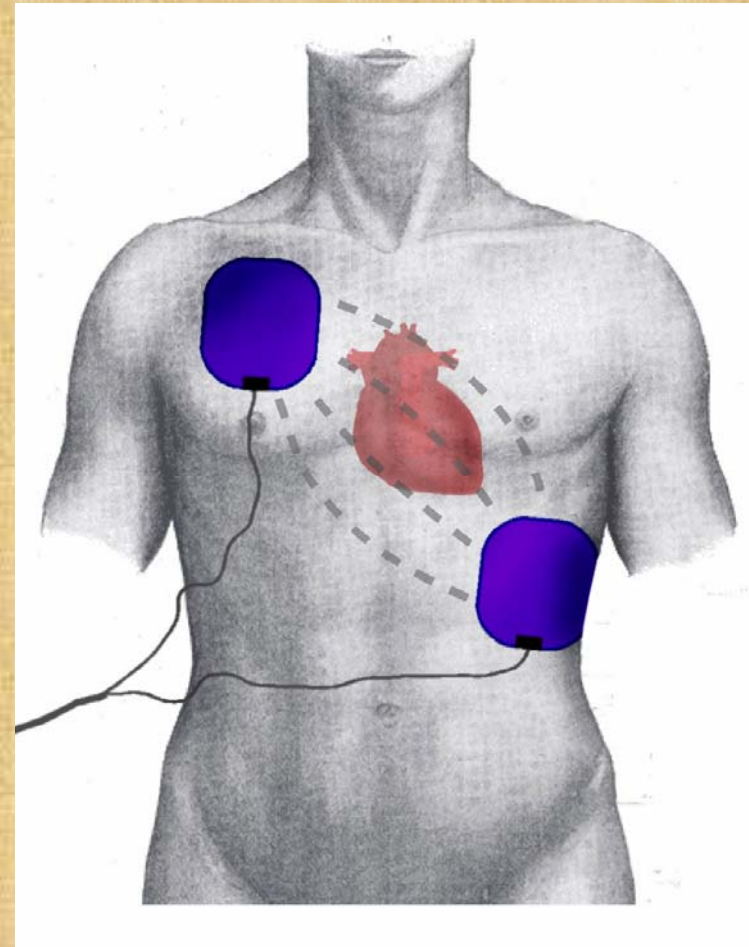
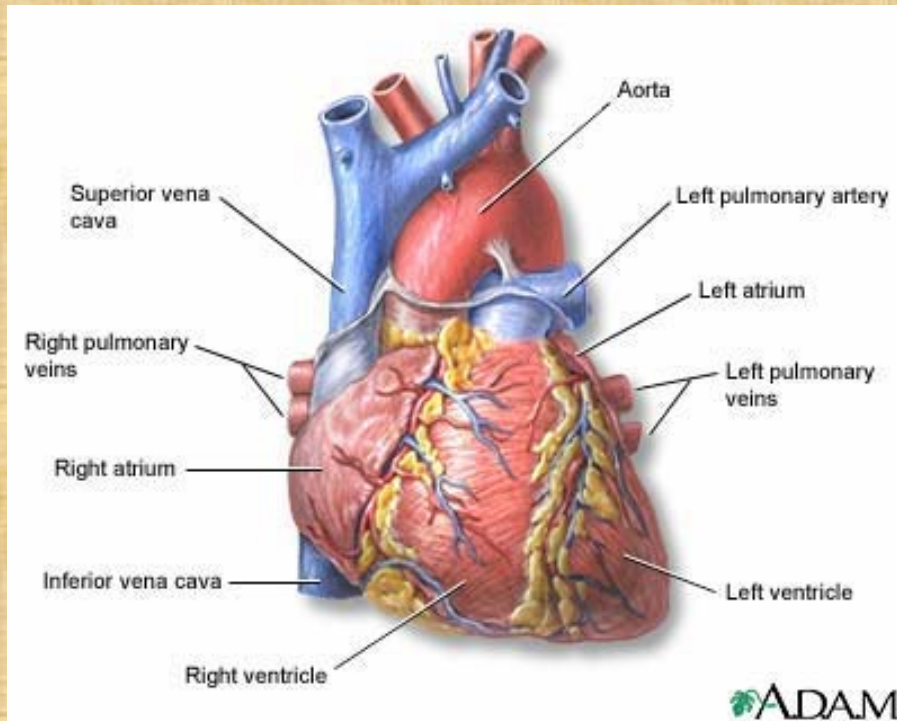
Keeping the infant's head tilted back, place two fingers on the breastbone and give five quick downward thrusts.

ALS – Advanced Life Support

- Advanced life support, including intravenous drugs and defibrillation (the administration of an electric shock to the heart) is usually needed to **restore a viable rhythm**. This only works for certain heart rhythms:
 - 1) **ventricular fibrillation (VF)** (uncoordinated contraction of the cardiac muscle of the heart ventricles, making them quiver rather than contract properly.)
 - 2) **pulse less ventricular tachycardia** (fast heart rhythm, that originates in one of the ventricles.)
- **NOT** useful in a 'flat line' **asystolic** patient, since the heart is already depolarised. CPR and injections of epinephrine/atropine will help.
- CPR is generally continued, usually in the presence of advanced life support, until the patient **regains a heart beat** (called "return of spontaneous circulation" or "ROSC") or is declared **dead**.


Defibrillation

Consists of delivering a therapeutic dose of electrical energy to the affected heart, using a **defibrillator**. This **depolarizes** a critical mass of the heart muscle, terminates the arrhythmia, and allows normal sinus rhythm to be re-established by the sinoatrial node of the heart.




1

Push the button to release the lid and turn on the defibrillator.



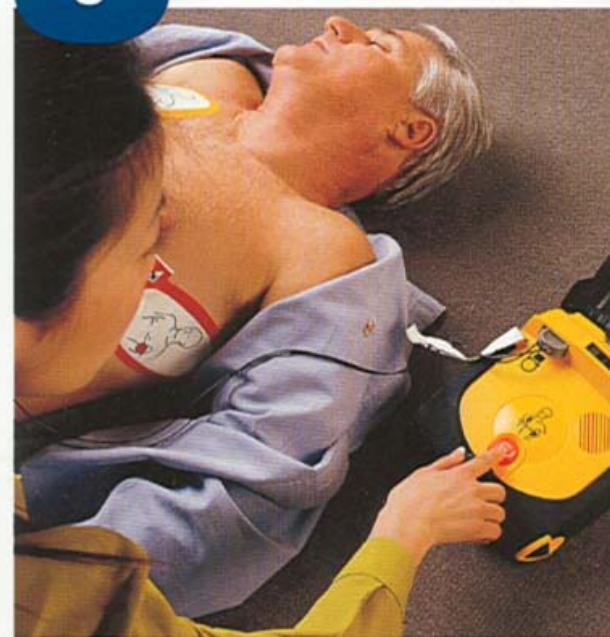2

Pull the handle to get the electrode pads and adhere them to the person's chest as shown.



3

Press the flashing button if told to do so.*



CPR Videos

- <http://www.youtube.com/watch?v=5r7haVfZXek>
- <http://www.youtube.com/watch?v=qSsHcdy4GnA>

ALS Video:

- <http://www.youtube.com/watch?v=zO3r50mlgr4>

<http://www.sja.org.uk/sja/first-aid-advice.aspx>

First aid advice

Life saving procedures

- Primary survey
- CPR for adults
- CPR for children
- CPR for infants
- The recovery position
- Choking

Heart attacks and shock

Other medical emergencies

Wounds and bleeding

Fractures

Head injuries and seizures

Effects of heat and cold

Breathing problems

Poisoning

[Home](#) > [First aid advice](#) > Life saving procedures

Life saving procedures

As a first aider the priorities when dealing with a casualty are always the same:

- **A**irway
- **B**reathing
- **C**irculation.

A [primary survey](#) of a casualty will establish your priorities. When dealing with an unconscious casualty you should open and maintain their **airway** as your first priority. If the airway should become obstructed, possibly by the tongue falling to the back of the throat, then the casualty will be unable to breathe and this will lead to death if untreated.

If the casualty is **breathing**, the simple procedure of placing the casualty in to the [recovery position](#) should ensure that the airway will remain clear of obstructions.

If the casualty has stopped breathing you can assist them by performing a combination of [chest compressions](#) and rescue breaths. You breathe out enough oxygen to potentially keep the casualty alive until the emergency services arrive, the oxygen you breathe into the casualty will need to then be pumped around the body using chest compressions.

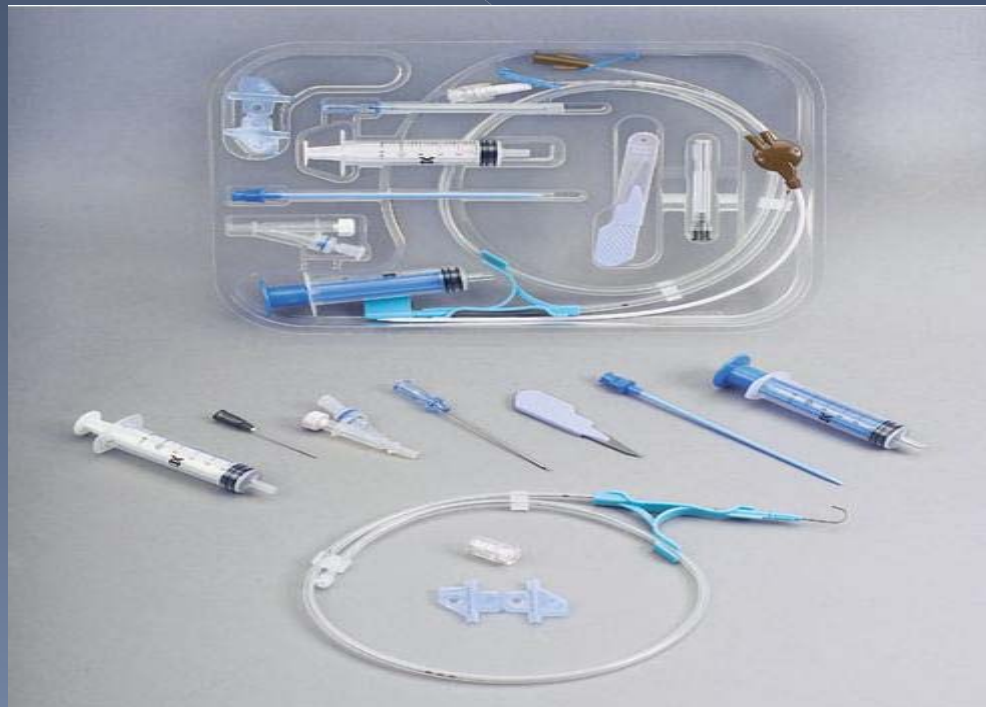
It is important to remember that in any life threatening situation the **emergency services** should be called as soon as breathing or absence of breathing has been identified.

See also

- [Training courses](#)
- [First aid kits](#)
- [Volunteer with us](#)




CENTRAL VENOUS CATHETERISATION



Shilpa
Nelapathla

INDICATIONS

- ▶ Measurement of central venous pressure (CVP)
(E.G. those with hypotension not responding to normal management, requiring infusion of inotropes)
- ▶ For long term administration of drugs for pain, infection, cancer or to supply nutrition.
- ▶ Venous access for IV fluids or antibiotics or a peripheral site is unavailable/unaccessible
- ▶ Haemodialysis



CONTRAINDICATIONS

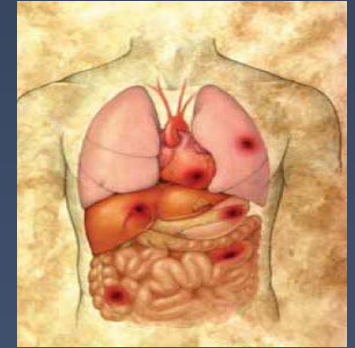
- ▶ Patients undergoing thrombolytic or anticoagulative therapy
- ▶ Bleeding disorders
- ▶ Vasculitis
- ▶ Distorted local anatomy
- ▶ Overlying skin infections(dermatitis), burns
- ▶ Uncooperative patient



COMPLICATIONS

- INFECTIOUS

Sepsis (also septic arthritis, osteomyelitis)

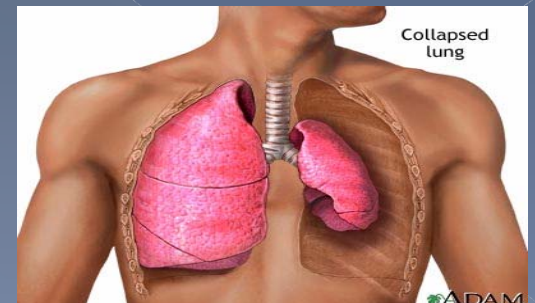


- VASCULAR

Air embolism, blood clot, hematoma, arterial puncture

- OTHERS

PNEUMOTHORAX, hemothorax, arrhythmias, nerve injury



LOCATIONS of CVC

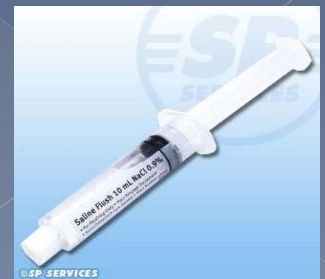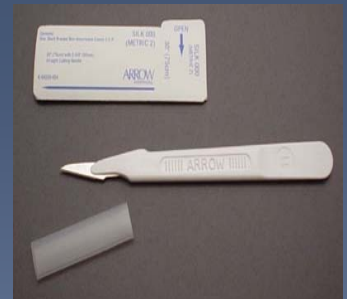- ◉ INTERNAL JUGULAR VEIN
- ◉ SUBCLAVIAN VEIN
- ◉ FEMORAL VEIN

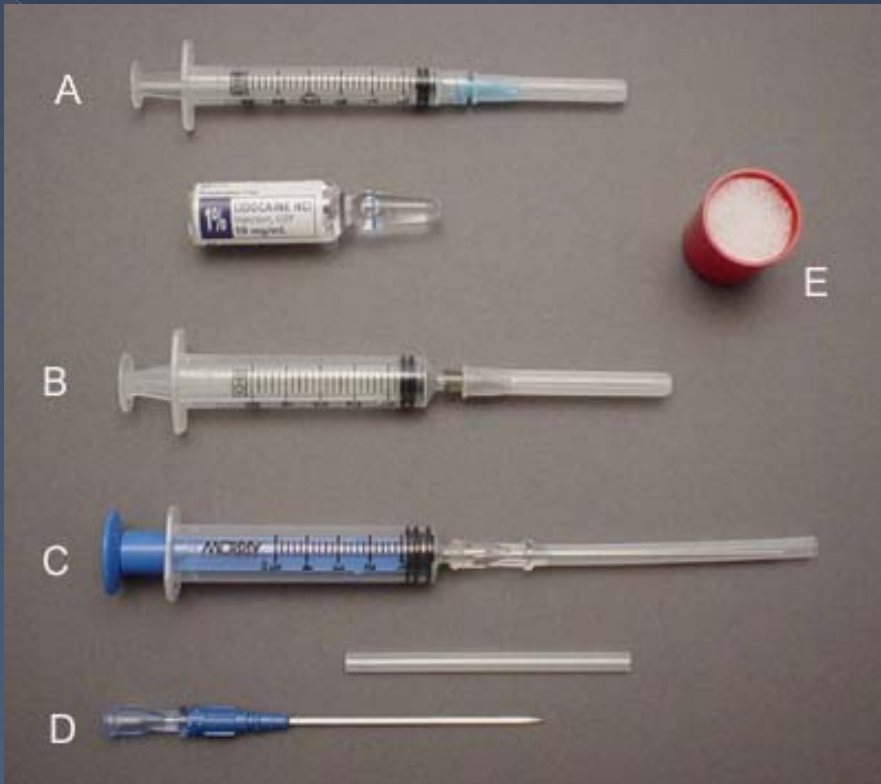
Length of catheters

- 15cm catheters for subclavian and internal jugular lines, and 60cm catheters for femoral line

EQUIPMENT USED:

- Patient on a tilting bed, trolley or operating table
- Standard multiple lumen kit
- Guide wire
- Sterile gloves
- Sterile gown
- Drapes
- Disinfectant (Povidone-iodine solution/ chlorhexidine)
- Suturing needle
- Scalpel
- Local Anaesthetic (lidocaine)
- Sterile saline flush





A= small syringe and vial of 1% Lidocaine (L.A)

B= guide needle


C= IV syringe with catheter attached- D

E= Disinfectant sponge



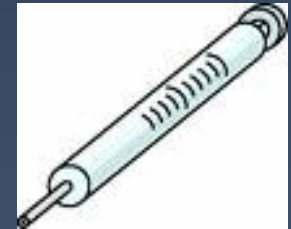Triple lumen
catheter

Dilator



Guidewire: J-shaped tip to reduce
risk of vessel perforation

TECHNIQUE

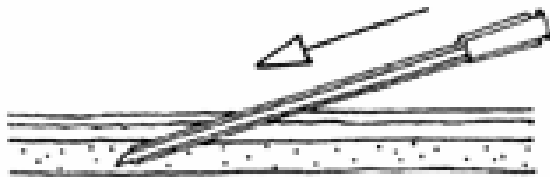


- ▶ SELDINGER TECHNIQUE (most common)
 - 1) Use guide needle to locate the vein
 - 2) Wire threaded through needle
 - 3) Remove needle
 - 4) A dilator is passed over the guide wire
 - 5) Dilator is removed and catheter is passed over wire and wire is removed
 - 6) Catheter secured in place

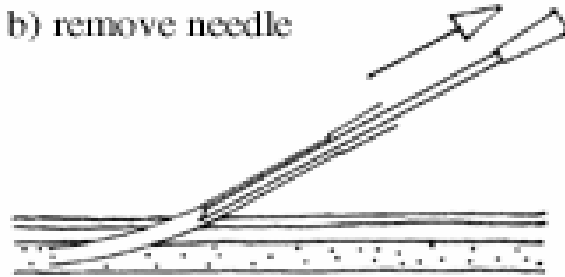
Allows larger catheters to be placed in the vein after the passage of appropriate dilators along the wire and a small incision in the skin at the point of entry.

A. Catheter over needle

a) insert into vein

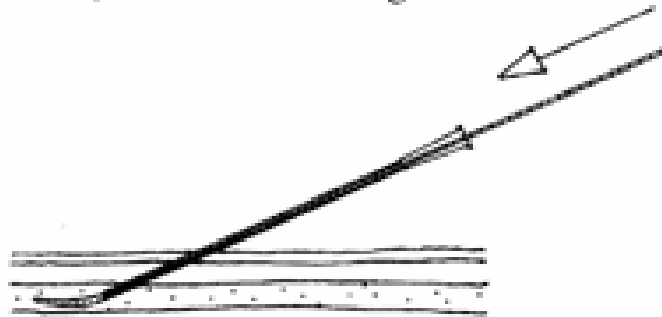


b) remove needle

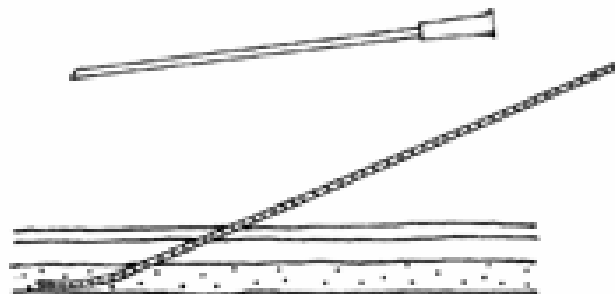


B. Catheter over guidewire (Seldinger technique)

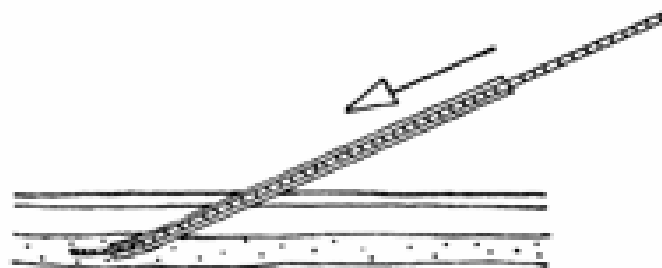
a) insert wire through needle in vein



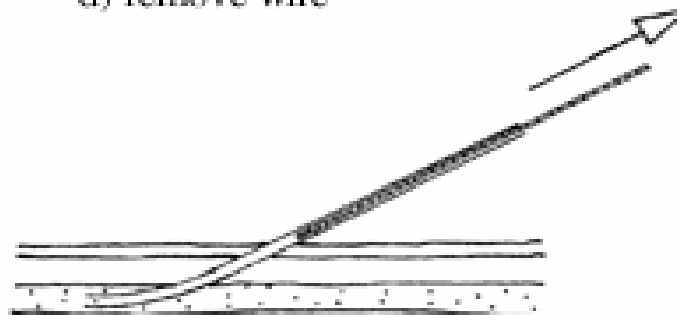
b) remove needle



c) pass catheter over wire



d) remove wire



Different methods of insertion

Fig 1

GENERAL PRINCIPLES

- Obtain informed consent and explain risks and benefits of procedure
- Optimal patient positioning and cooperation, make sure patient is comfortable
- Take your time
- Sterile technique
- Local anaesthetic should be used
- Always have a hand on your wire
- Aspirate while advancing as you withdraw the needle slowly
- Withdraw needle to the level of the skin before redirecting the angle
- Don't poke yourself with the needle
- The tip of the catheter can lie in either the superior or inferior vena cava (SVC or IVC) or into the right atrium (RA).

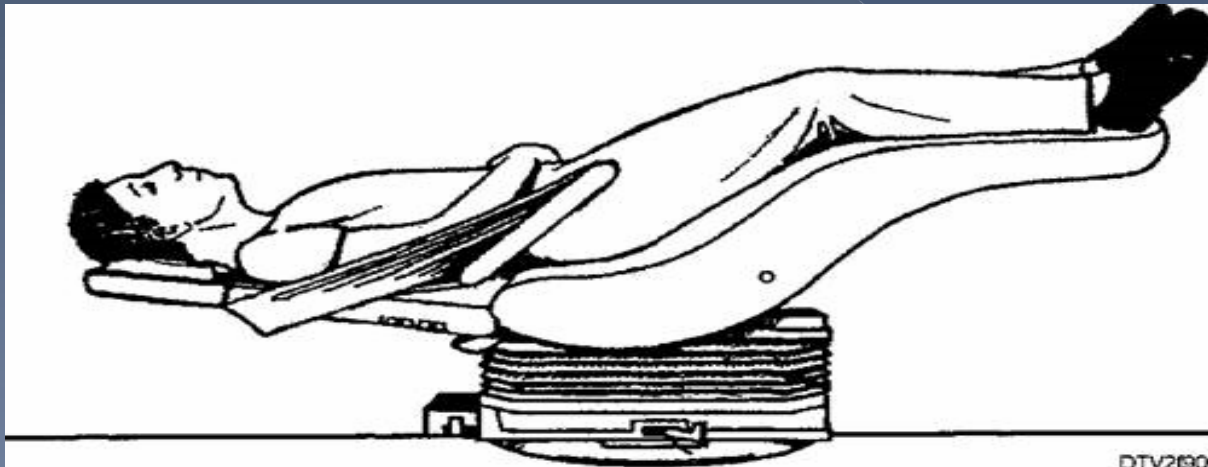


INTERNAL JUGULAR APPROACH

1. POSTIONING :

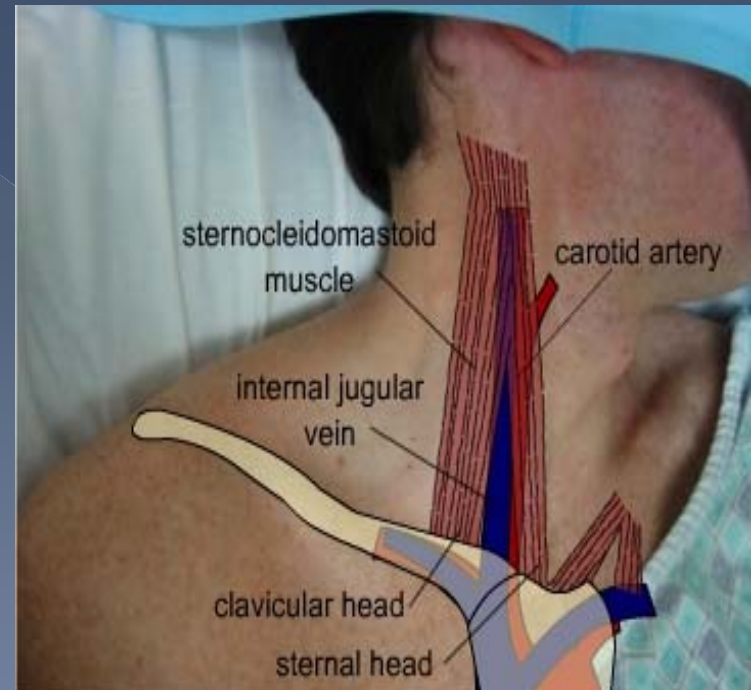
TRENDELENBURG POSITION

- Patient supine on surface inclined 45 degrees, head at the lower end and legs flexed over upper end.
(This distends the central veins and prevents air embolism)
- Head turned to opposite side of central venous line
- Stand at the head of the patient



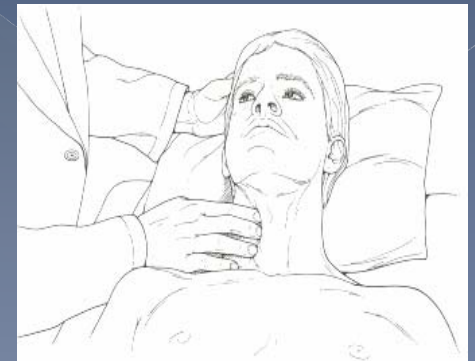LOCATING AND ACCESSING VEIN

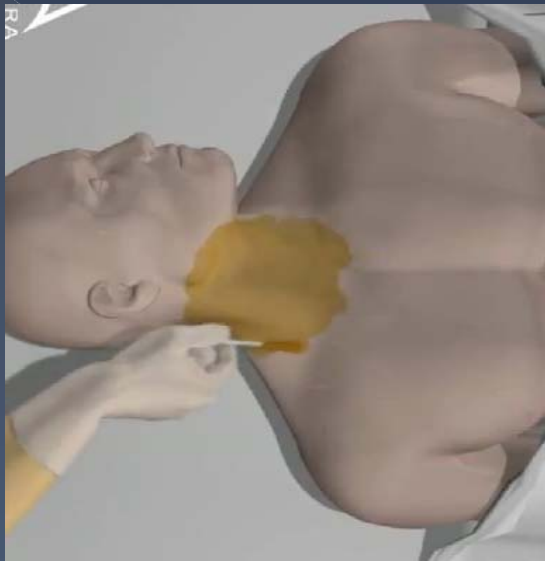
- Ultrasound and landmarks can be used
- IJV is between the clavicular and sternal heads of the sternocleidomastoid muscle
- Point of needle insertion is midway between sternal head of SCM and mastoid process behind ear



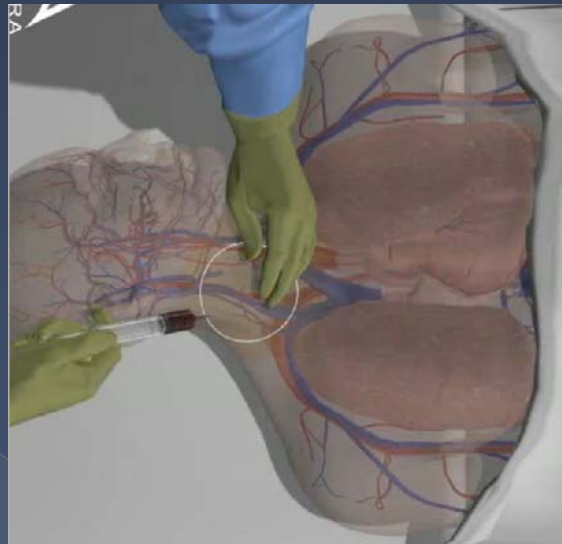
PROCEDURE

- Disinfect area , apply L.A and fenestrated drape
- Place three fingers on carotid artery
- Place needle about 45 degrees to the skin, lateral to the carotid artery
- Direct needle in sagittal plane angled towards feet
- Vein should be 1-1.5 cm deep, avoid deep probing in the neck
- Seldinger technique used

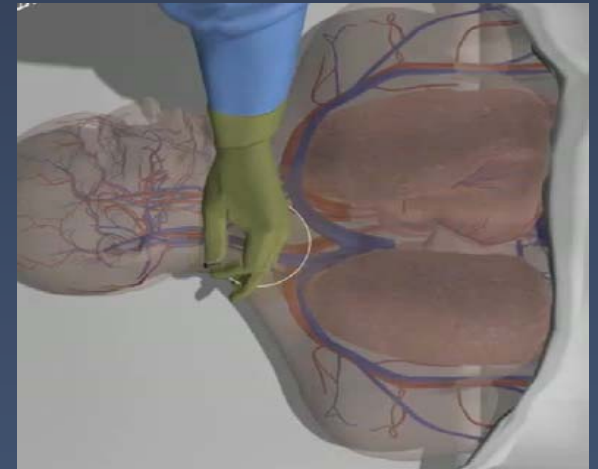




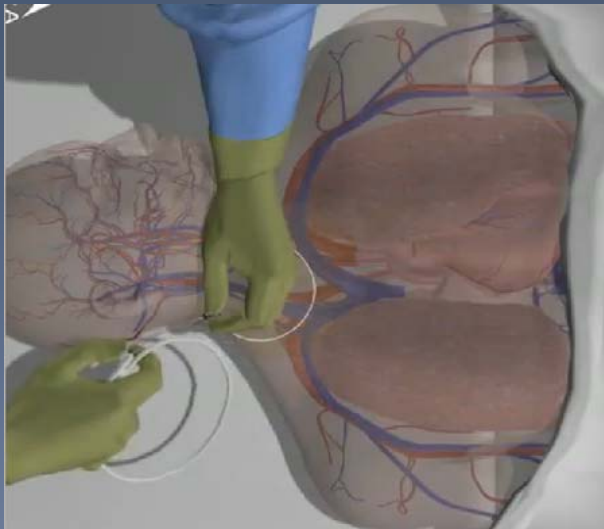
1. Disinfection, L.A and sterile drape



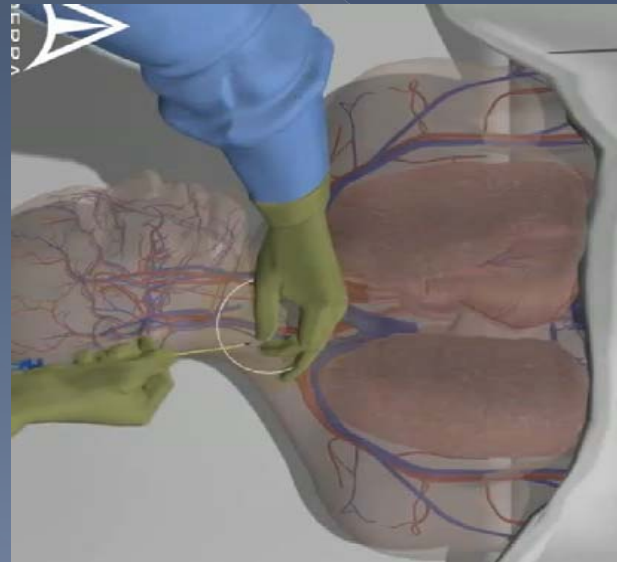
2. Insert needle into IJV and aspirate



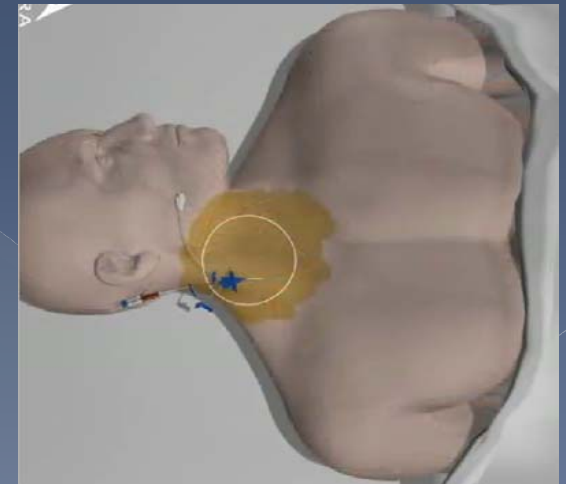
3. Hold tip of needle with one hand



4. Place wire through needle and remove needle



5. Insert catheter over wire then remove wire



6. Once catheter is in place, secure and apply dressing

SUBCLAVIAN APPROACH

POSITIONING

- Trendelenburg position (10-15 degrees)
- Supine position, head and shoulders neutral with arm slightly abducted
- Stand beside the patient at the side

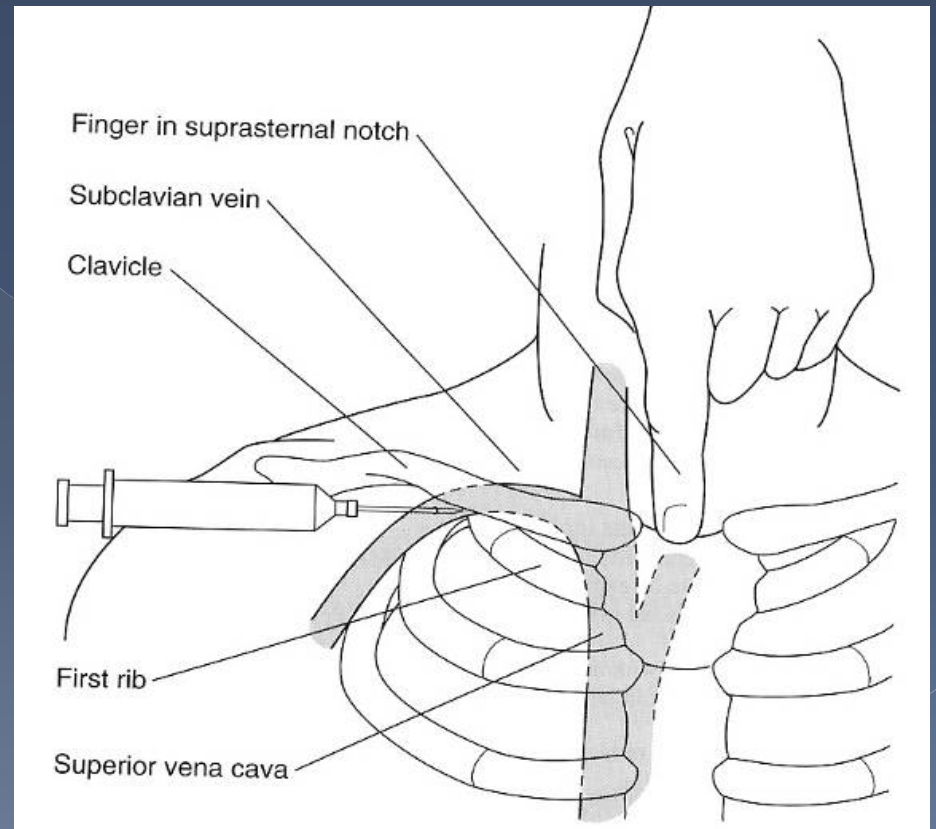
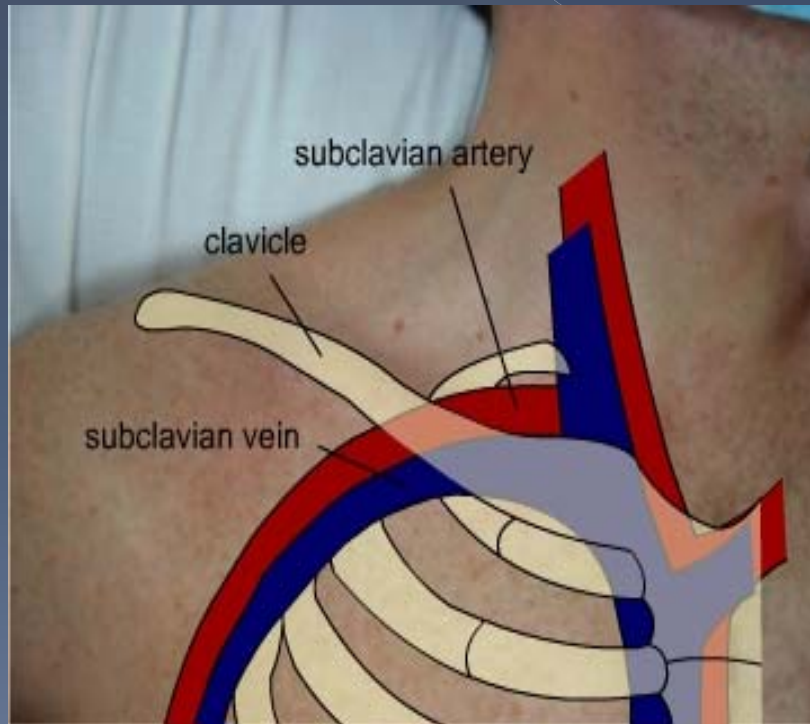
PROCEDURE

- Disinfect area and apply local anaesthetic
- Cover procedure area with fenestrated sterile drape
- Use seldinger technique

LOCATION AND ACCESS TO VEIN

- Identify the midclavicular point and sternal notch
- Insert needle into the skin 1cm below and lateral to the midclavicular point
- Direction of needle should be parallel to skin
- Advance posterior to the clavicle aiming for the sternal notch (Do not pass the needle further than the sternal head of the clavicle)

Location and insertion of needle

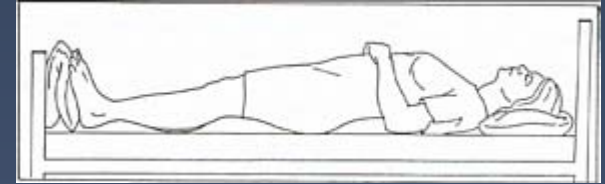


<http://video.google.com/videoplay?docid=2421324986948418582#>

FEMORAL VEIN APPROACH

POSITIONING

- Supine patient
- Extend the patient's leg and abduct slightly at the hip



PROCEDURE

- Disinfect area and apply local anaesthetic
- Cover procedure area with fenestrated sterile drape
- Use seldinger technique

LOCALISATION AND ACCESS TO VEIN

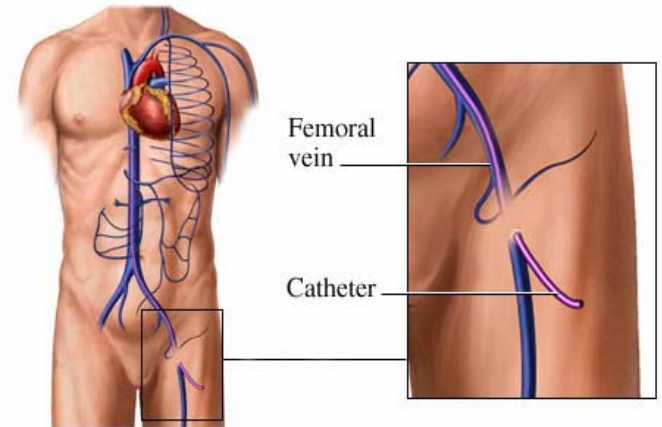
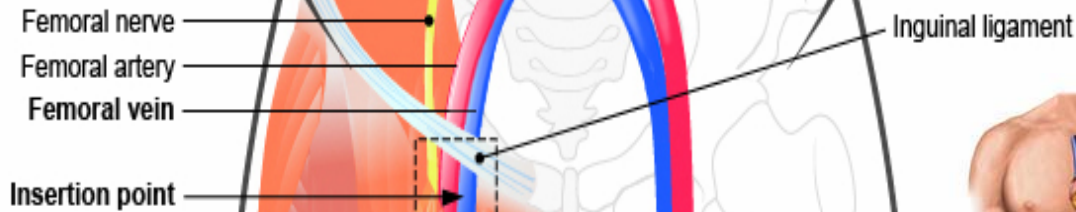
- Vein is medial to femoral artery
- Identify the pulsation of the femoral artery 1-2 cm below the inguinal ligament.
- Position needle at 45 degree angle and about 1cm medial to pulsation
- Needle inserted at skin about 2 cm below inguinal ligament
- Aiming towards the umbilicus

(In adults, the vein normally found 2-4cm from the skin. In small children reduce elevation on the needle to 10-15° as the vein is more superficial)



uOttawa


General anatomy of the right femoral vein



http://www.4shared.com/file/61538831/b1027127/Placement_of_a_Femoral_Venous_.html

POST CATHETER PLACEMENT

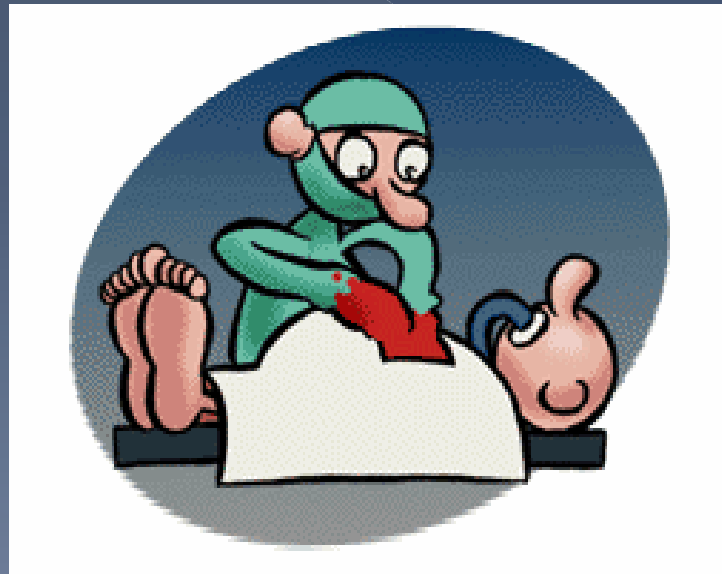- 1) Aspirate blood from each port
- 2) Flush with saline / sterile water
- 3) Secure the catheter with sutures
- 4) Apply sterile dressing
- 5) Dispose of used gloves, needles, syringe etc
- 6) Wash hands
- 7) Chest x-ray for IJ and SC lines



EVALUATION

LOCATION	BENEFITS	RISKS
INTERNAL JUGULAR VEIN	<ul style="list-style-type: none">•Bleeding can be seen and controlled•Decreased risk of pneumothorax	<ul style="list-style-type: none">•Risk of Carotid artery puncture•Pneumothorax
SUBCLAVIAN VEIN	<ul style="list-style-type: none">•Most comfortable for conscious patients	<ul style="list-style-type: none">•Increased risk of pneumothorax•Should not be done on less than 2yrs•Vein is non-compressible
FEMORAL VEIN	<ul style="list-style-type: none">•Easy to locate•Less bad complications•No risk of pneumothorax•Preffered in emergencies	<ul style="list-style-type: none">•Highest risk of infection•Risk of DVT

THANX FOR LISTENING!

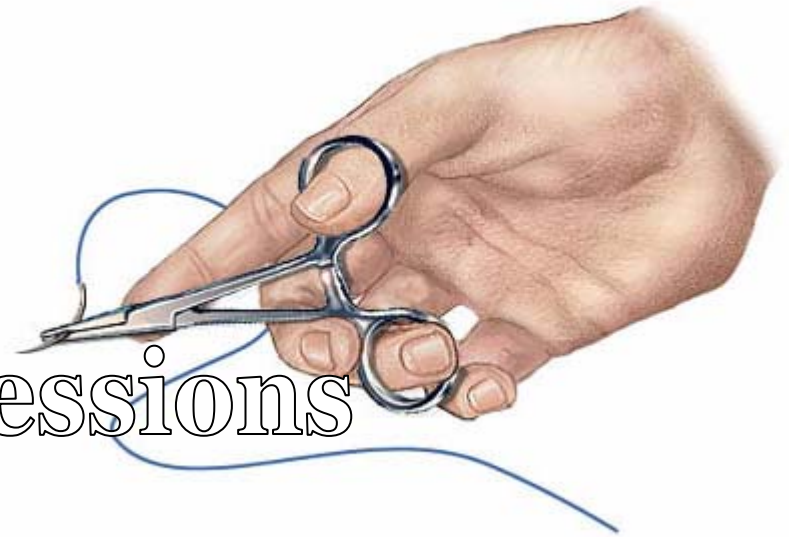


Masaryk University



Clinical Sessions


Sutures



Joao Marques de Oliveira

Main Points

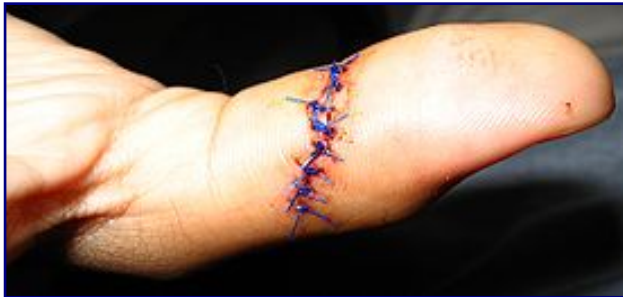- What's a suture?
- Why do I need to know how to do one?
- What instruments do I use for it?



- Can I tie a knot?
- What techniques shall I use?
- What types of sutures and materials do I know?

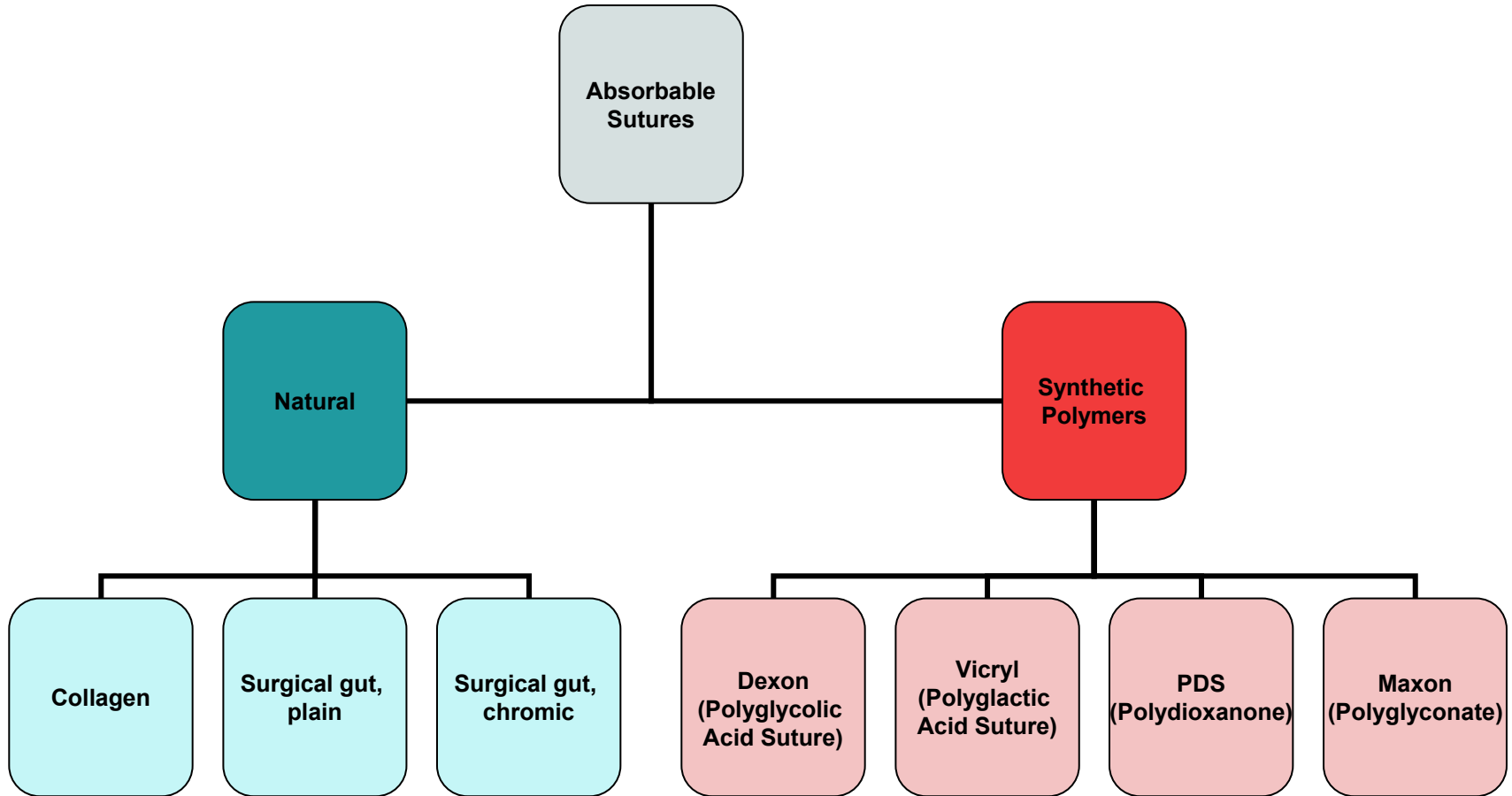
Definitions

- **Suture:** Is a medical device used to hold **body tissues** together after an injury or surgery. To stitch together, cut or torn edges of tissue with suture material.



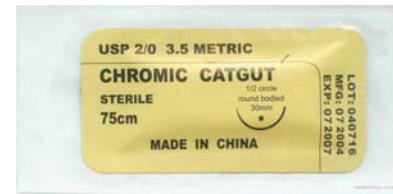
- **Tensile Strength :** The **resistance** of a material to a **force** tending to tear it apart, measured as the **maximum tension** the material can withstand **without tearing**

Suture Characteristics



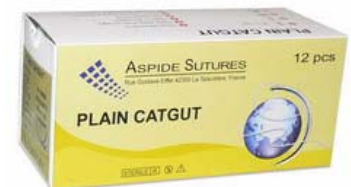
Suture Characteristics II

- Absorbable Suture: A suture that degrades and loses its tensile strength within 60 days under the skin

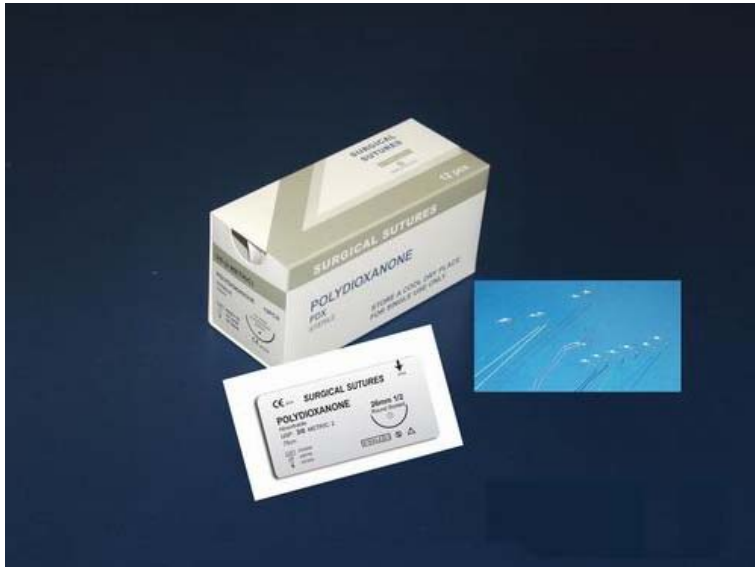

We use this sutures in patients who cannot return for suture removal, or in internal body tissues

- Natural Suture: Can be made of collagen from mammal intestines or from synthetic collagen (polymers)
- Synthetic: New technology in surgical stitches



Absorbable Sutures

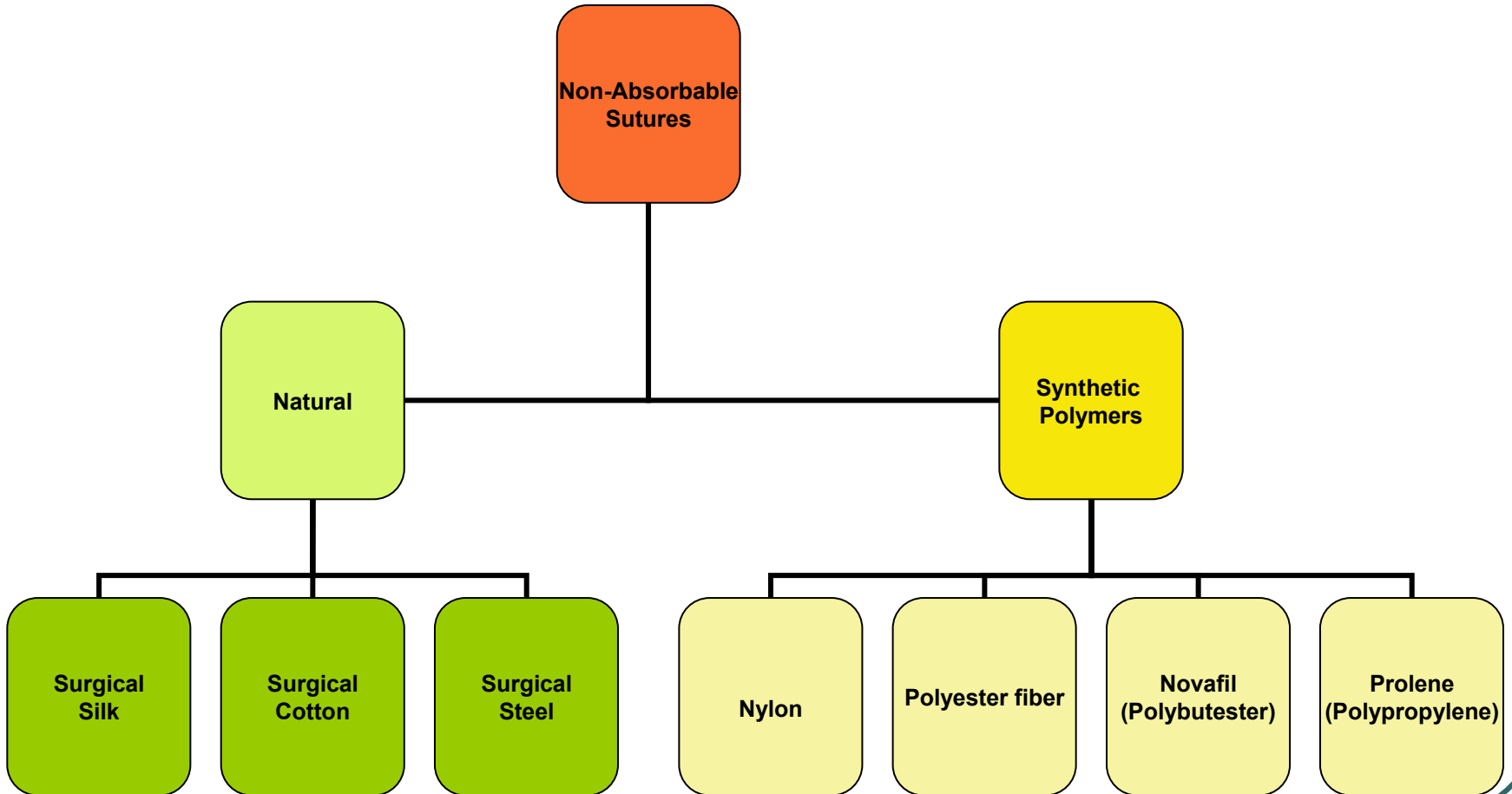


Monofilament vs Multifilament

Mono is made of a single strand, more resistant to microorganisms, less resistant to passage through tissue, needs great care in handling and tying because it crushes easily

1. **Catgut Suture:** Tensile strength is maintained for 7-10 days, absorption complete within 60 days. Used for ligating superficial blood vessels and for epidermal use
2. **Dexon and Vicryl:** Tensile strength is maintained for 14 days. Absorption completed in 56-70 days. Used in general soft tissues and vessel ligations
3. **PDS (Polydioxanone):** Polyester monofilament suture with tensile strength maximal for 14 days. Absorption completed within 6 months. Used for soft tissue approximation in pediatric, cardiovascular, gynecologic, ophthalmic, plastic and digestive situations.

Sutures Characteristics III



Non-Absorbable Sutures

- **Silk:** Many surgeons consider silk suture the standard of performance. Tensile strength decreases with moisture absorption and is lost by 1 year. The problem is the acute inflammatory reaction triggered by this material.

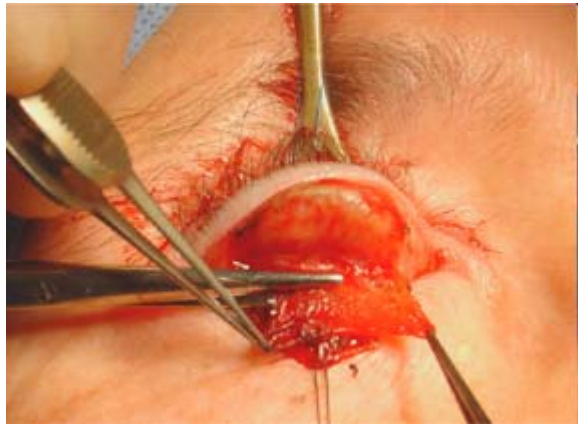

Fig.A - Correction of blepharoptosis

Prolene: Monofilament suture, useful in contaminated and infected wounds. Widely used in plastic, cardiovascular, orthopedic surgery. Ideal for use in continuous suture closure.

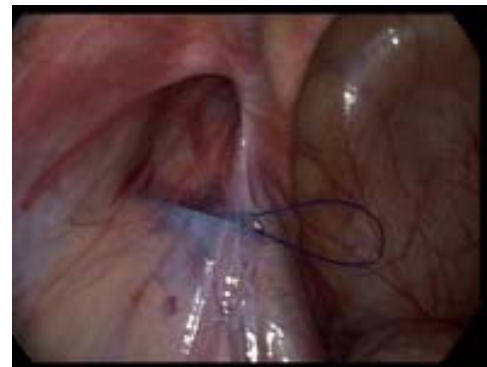
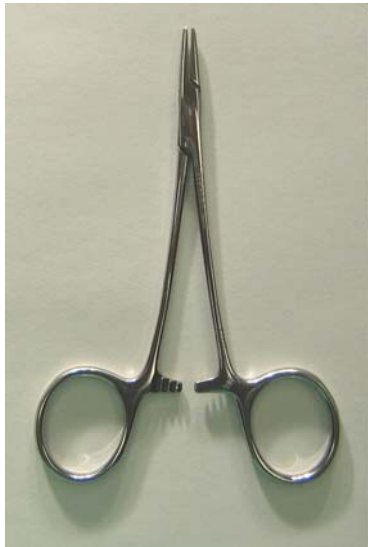
Fig.B - Repair of a left indirect inguinal hernia

Suture Material – Needle Holders



Mayo Hager Needle Holder

Mathieu Needle Holder



Suture Specifications

Needles

Traumatic needles: With holes or eyes which are supplied to the hospital, separate from their suture thread. Suture must be threaded on site as is done when sewing at home

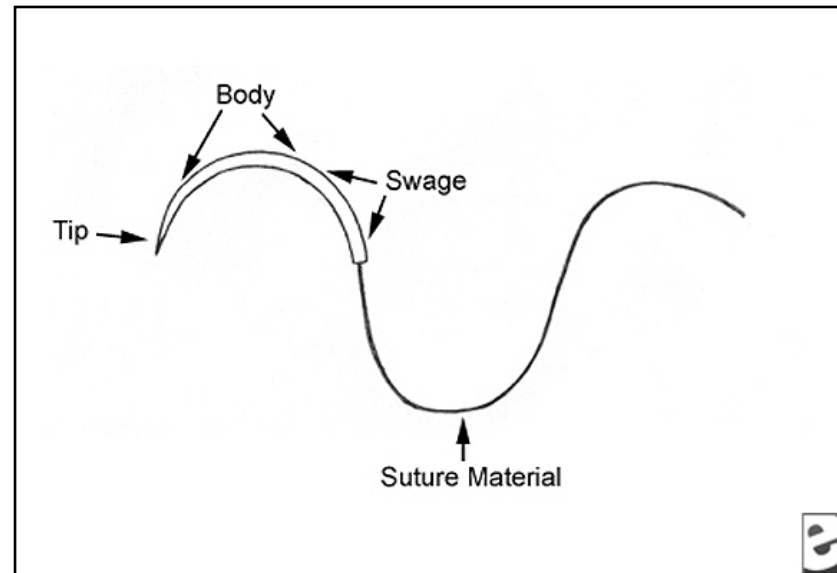
Atraumatic needles: With sutures comprise an eyeless needle attached to specific length suture thread

- **Curvature**

- Straight needle
- Curved 2/8 of circle
- Curved 3/8 of circle
- Curved 4/8 of circle
- Curved 5/8 of circle

- **Needle Tip**

1. Taper
2. Conventional cutting needle
3. Reverse cutting needle



Suture Material - Needles



Fig.C – Atraumatic Needle, Taper

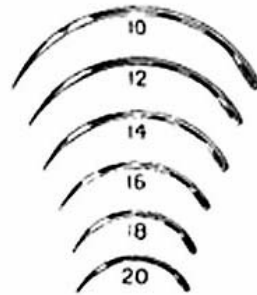

Fig.D – 3/8 circle needle, Cutting



Fig.D – Traumatic Needle, Reverse Cutting

NEEDLE CHART

Super Sharp Point Siliconized Needles

1/2 Circle Taper Point

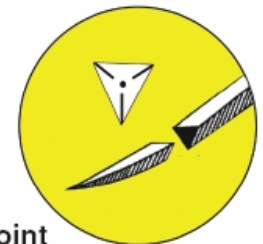Needle	Size
NSH-1	22mm
NSH	26mm
NCT-2	27mm
NCT-1	36mm



Taper Point

3/8 Circle Reverse Cutting

Needle	Size
NFS-2	19mm
NFS-1	24mm
NFS	26mm
NFSL	30mm



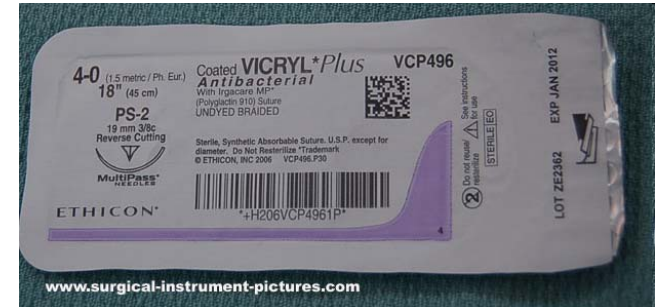Reverse Cutting

1/2 Circle Reverse Cutting Point

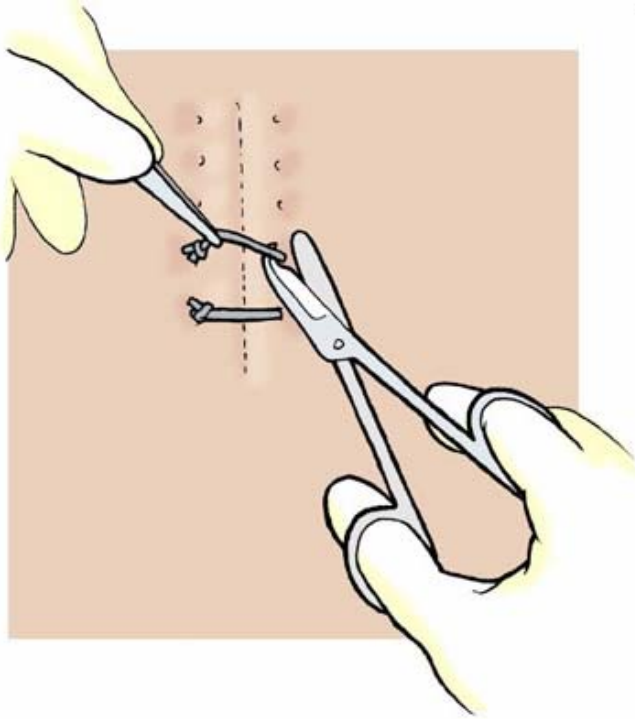
Needle	Size
NCP-2	27mm
NCP-1	36mm
NX-1	23mm

Suture Size

- **Size 0:** Largest suture
- **Size 2-0**
- **Size 3-0**
 - Skin: Foot or Sole
 - Deep: Chest, Abdomen, Back, Scalp
- **Size 4-0**
 - Skin: Scalp, Chest, Abdomen, Foot, Extremity
 - Deep: Scalp, Extremity, Foot
- **Size 5-0**
 - Skin: Scalp, Brow, Oral, Chest, Abdomen, Hand
 - Deep: Brow, Nose, Lip, Face, Hand
- **Size 6-0**
 - Skin: Ear, Lid, Brow, Nose, Lip, Face, Penis
- **Size 7-0:** Smallest Suture
 - Skin: Eyelid, Lip, Face



Suture Removal Timing



Condition **delaying** Wound Healing: 14 to 21 days
Chronic Corticosteroid use and Diabetes Mellitus

Scalp: 6-8 days

Face, Eyelid, Eyebrow, Nose, Lip: 3-5 days
.Follow with papertape or steristrips

Ear: 10-14 days

Chest and abdomen: 8-10 days

Back: 12-14 days

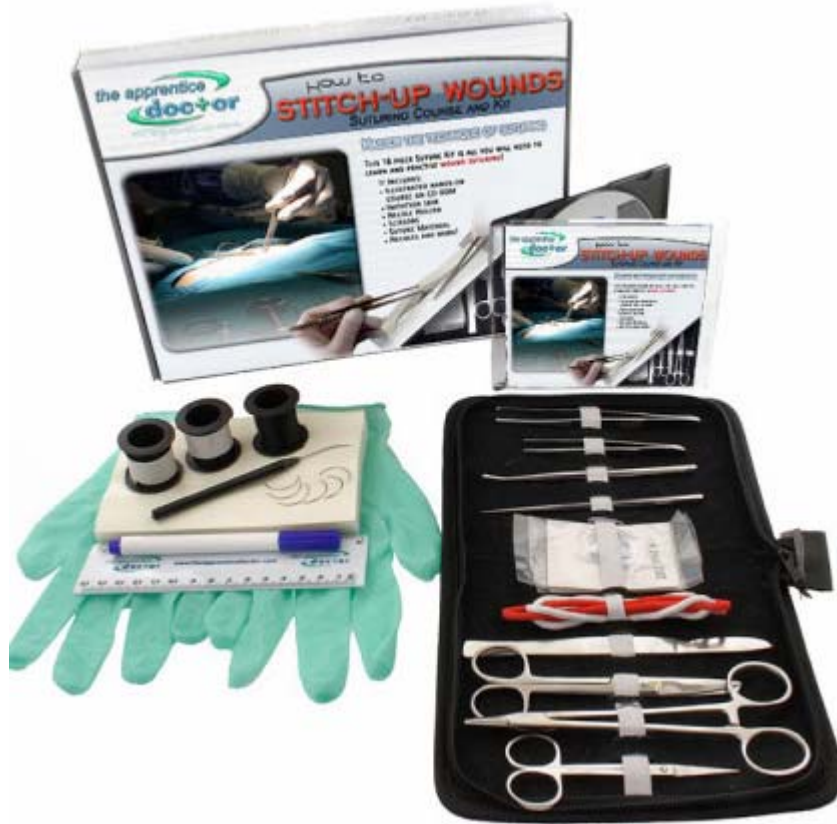Extremities: 12-14 days

Hand: 10-14 days

Foot and sole: 12-14 days

Penis: 8-10 days

Suture Technique



The aim of all these techniques is to approximate the wound edges without gaps and without tension.

Staples are an expensive alternative and glue may not be widely available. Suturing is the most versatile, least expensive and most widely used technique.

The choice of sutures and needles is determined by the location of the lesion, the thickness of the skin in that location, and the amount of tension exerted on the wound.

Pic.E - Suture Kit

<http://www.softwarecasa.com/apprentice-doctor-how-to-stitch-up-wounds.html>

List of Suture Techniques

:: Interrupted Suture

:: Continuous simple or Running Suture

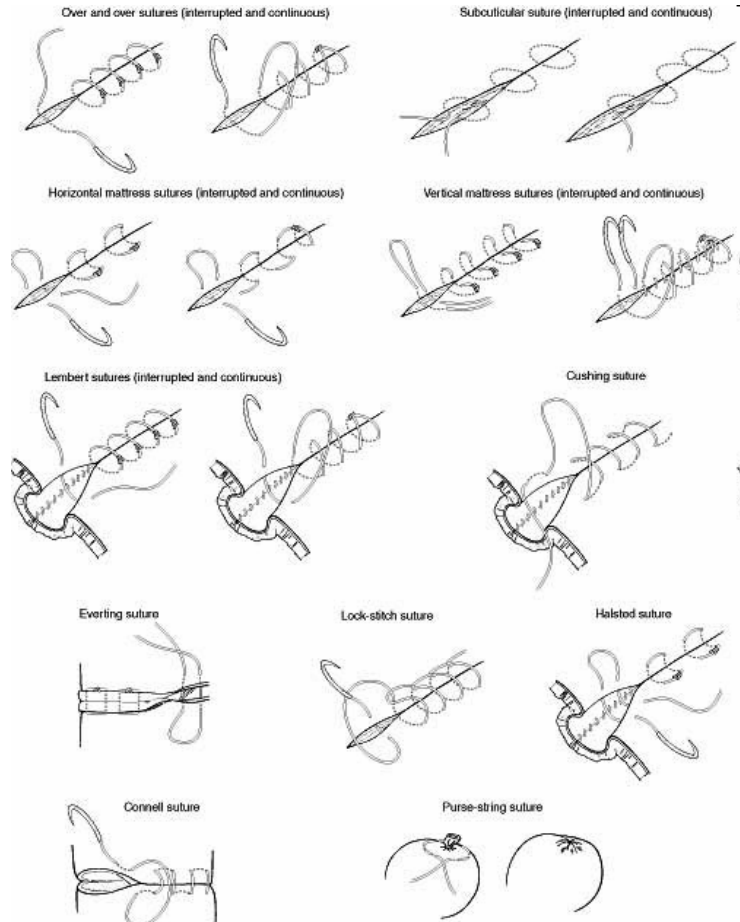
:: Vertical mattress

:: Horizontal mattress

:: Subcuticular Suture

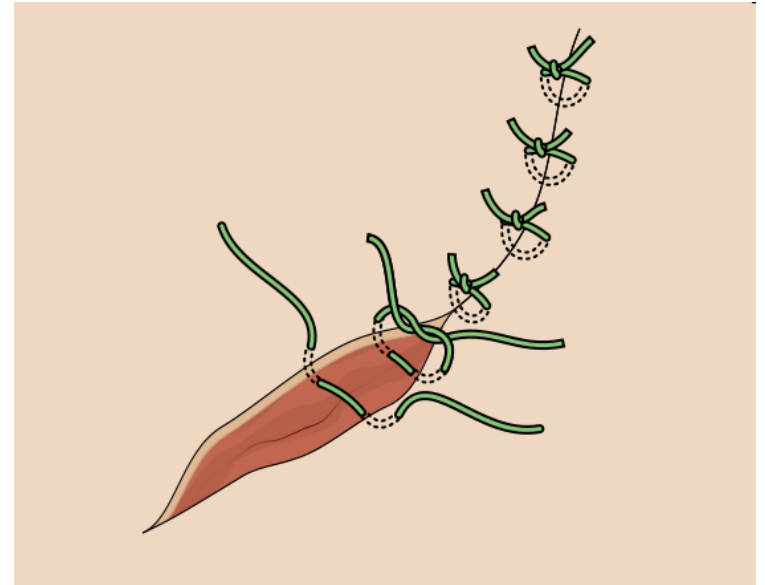
:: Purse string

:: Retention/tension



Simple Interrupted Suture


- The most commonly used and versatile suture in cutaneous surgery (i.e repair lacerations)
- This suture is placed by inserting the needle perpendicular to the epidermis, traversing the epidermis and the full thickness of the dermis, and exiting perpendicular to the epidermis on the opposite side of the wound



<http://www.youtube.com/watch?v=PoORW7pQs2M>

Continuous/Running Suture

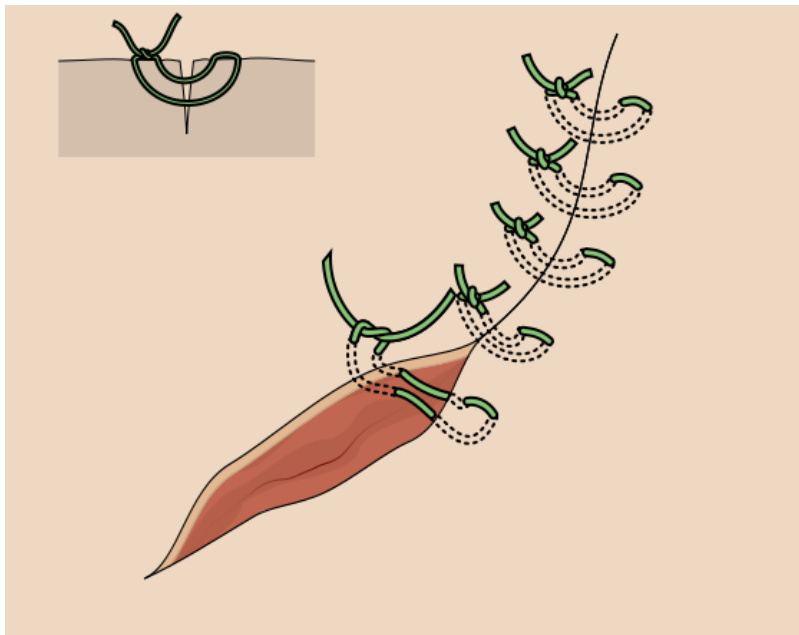
- Is an uninterrupted series of simple interrupted sutures
- Poor cosmetic result but less time/consuming



➤ Is started by placing a simple interrupted stitch, which is tied but not cut. A series of simple sutures are placed in succession without tying or cutting the suture material after each pass. The line of stitches is completed by tying a knot after the last pass at the end of the suture line

<http://www.youtube.com/watch?v=H1FmNevH2QE&feature=related>

Vertical Matress Suture



Is a variation of the simple interrupted suture.

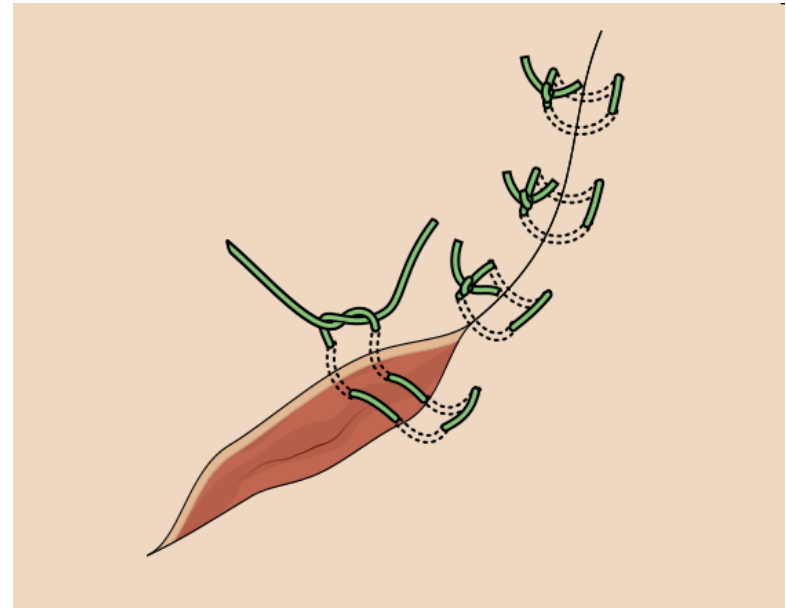
It consists of a simple interrupted stitch placed wide and deep into the wound edge and a second more superficial interrupted stitch placed closer to the wound edge and in the opposite direction.

Perfect apposition and great to relieve tension from skin edges

<http://www.youtube.com/watch?v=qNcM6D9OK0s>

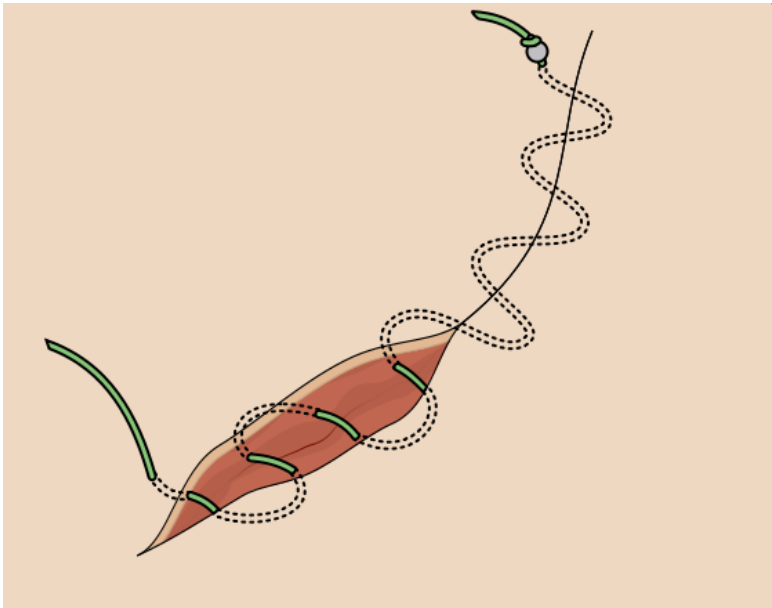
Horizontal Matress Suture

- Is placed by entering the skin 5 mm to 1 cm from the wound edge.
- The suture is passed deep in the dermis to the opposite side of the suture line and exits the skin equidistant from the wound edge.
- The stitch is passed deep to the opposite side of the wound where it exits the skin and the knot is tied



<http://www.youtube.com/watch?v=Svcau54Svyg&feature=related>

Subcuticular (Intradermal) Sutures



- Excellent cosmetic result
- It is placed by taking horizontal bites through the papillary dermis on alternating sides of the wound. No suture marks are visible, and the suture may be left in place for several weeks
- Useful in wounds with strong skin tension

<http://www.youtube.com/watch?v=-osbgWMXcFE>

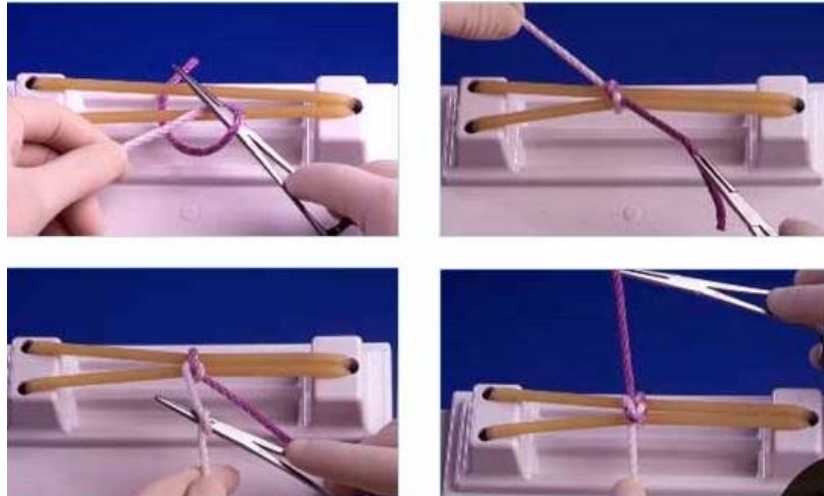
Knot Tying

- Essentially there are 3 basic techniques:

1. Instrumental tie

- This is the most straightforward and the most commonly used technique
- You must cross your hands to produce a square knot

Do not use instrument ties if the patient's life depends on the security of the knot

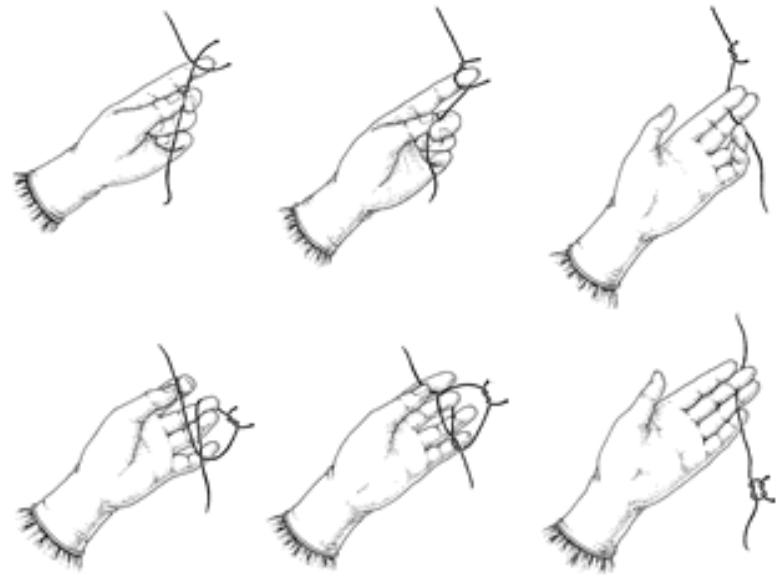


Knot Tying II

2. One handed knot

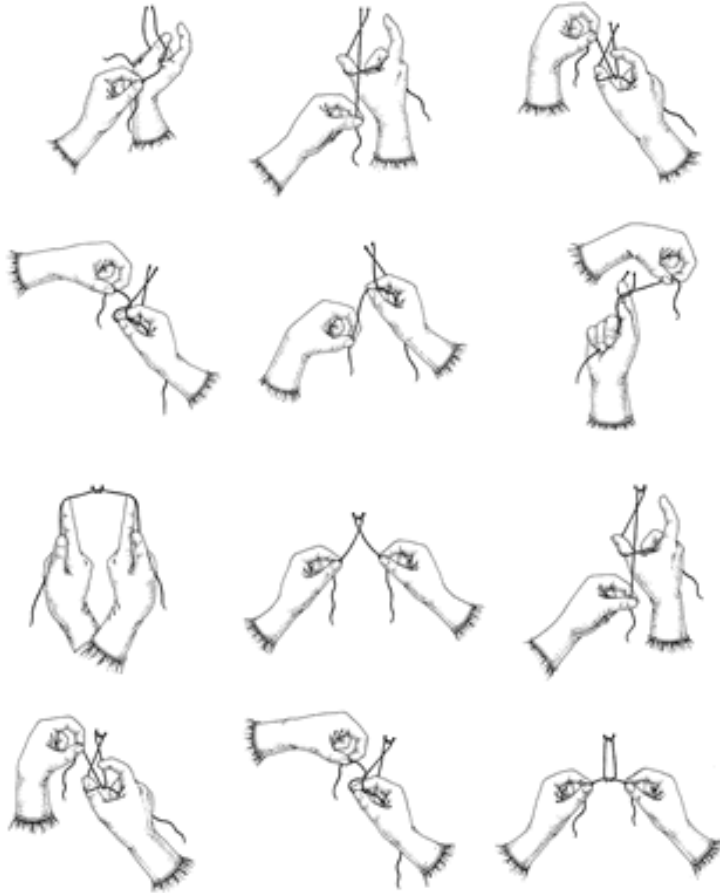Use the one handed technique to place deep seated knots and when one limb of the suture is immobilized by a needle or an instrument

Hand tying has the advantage of tactile sensations lost when using instruments; if you place the first throw of the knot twice, it will slide into place, but will have enough friction to hold while the next throw is placed



<http://www.youtube.com/watch?v=b8JEUd0C3Pw&feature=related>

Knot Tying III



3. Two handed knot

The two handed knot is the most secure. Both limbs of the suture are moved during its placement. A surgeon's knot is easily formed using a two handed technique

With **practice**, the feel of knot tying will begin to **seem automatic**. As with learning any motor skill, we develop "muscle memory". **Our brain teaches our hands how to tie the knots**, and eventually our hands tie knots so well, we are no longer consciously completing each step

Joao Marques de Oliveira

Thank you!
For your attention

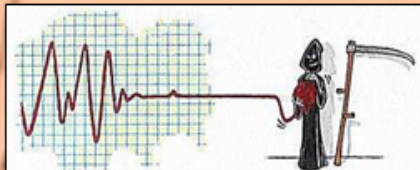


CHECK

GROUP

CLINICAL
SESSIONS
2010

Clinical
Session 4!



TUES 1830 - 1945

- Rectal examination
- Eye & Ear examination
- Urinary catheters
- ECG - signs of heart disease
& More...



Rectal Examination

Nikos Lymberopoulos



Anatomy I

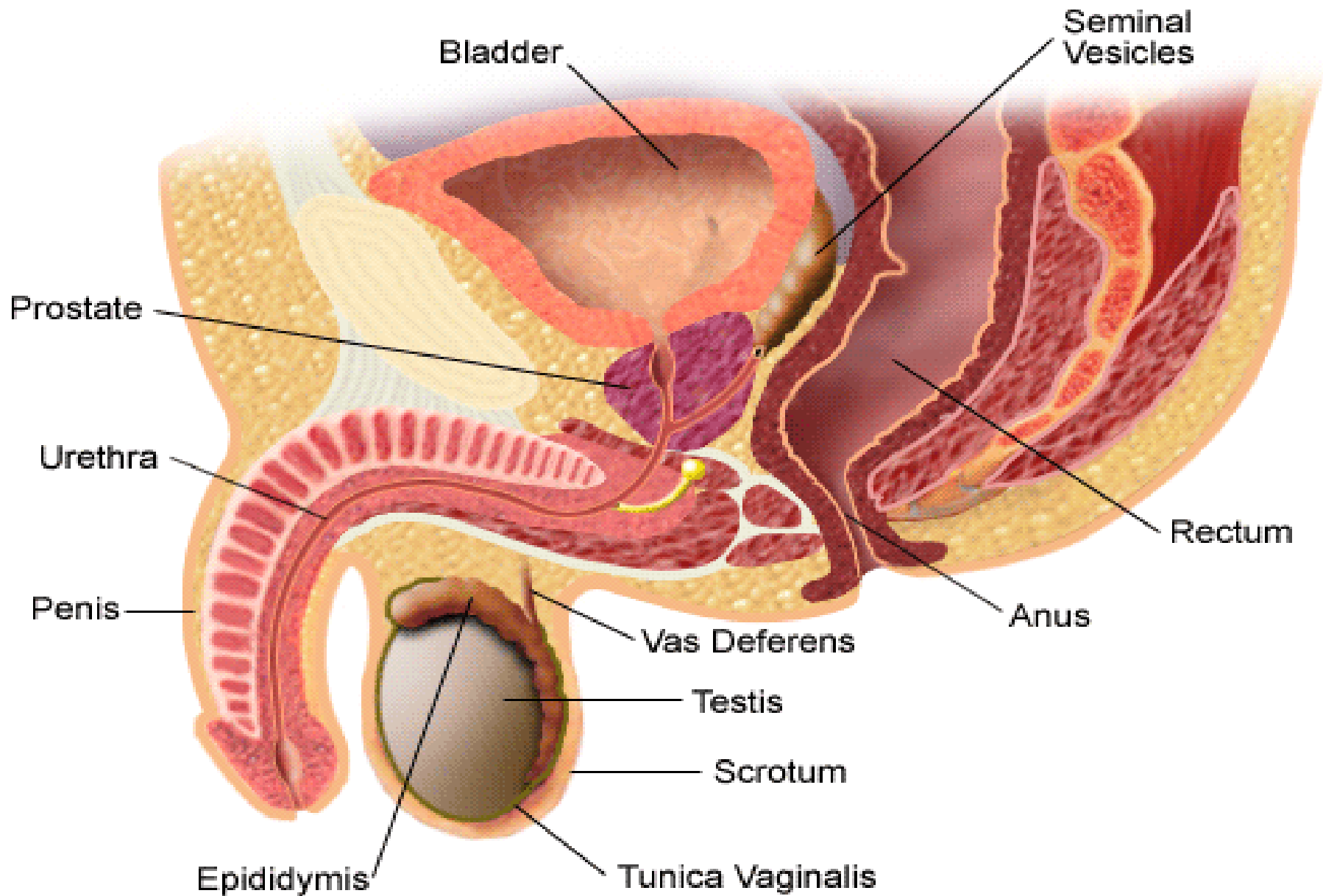
- The rectum is the curved lower, terminal segment of large bowel.
 - It is about 12 cms long and runs along the concavity of the sacrum.
 - Anterior to the lower 1/3 of the rectum lie different structures in men and women
-

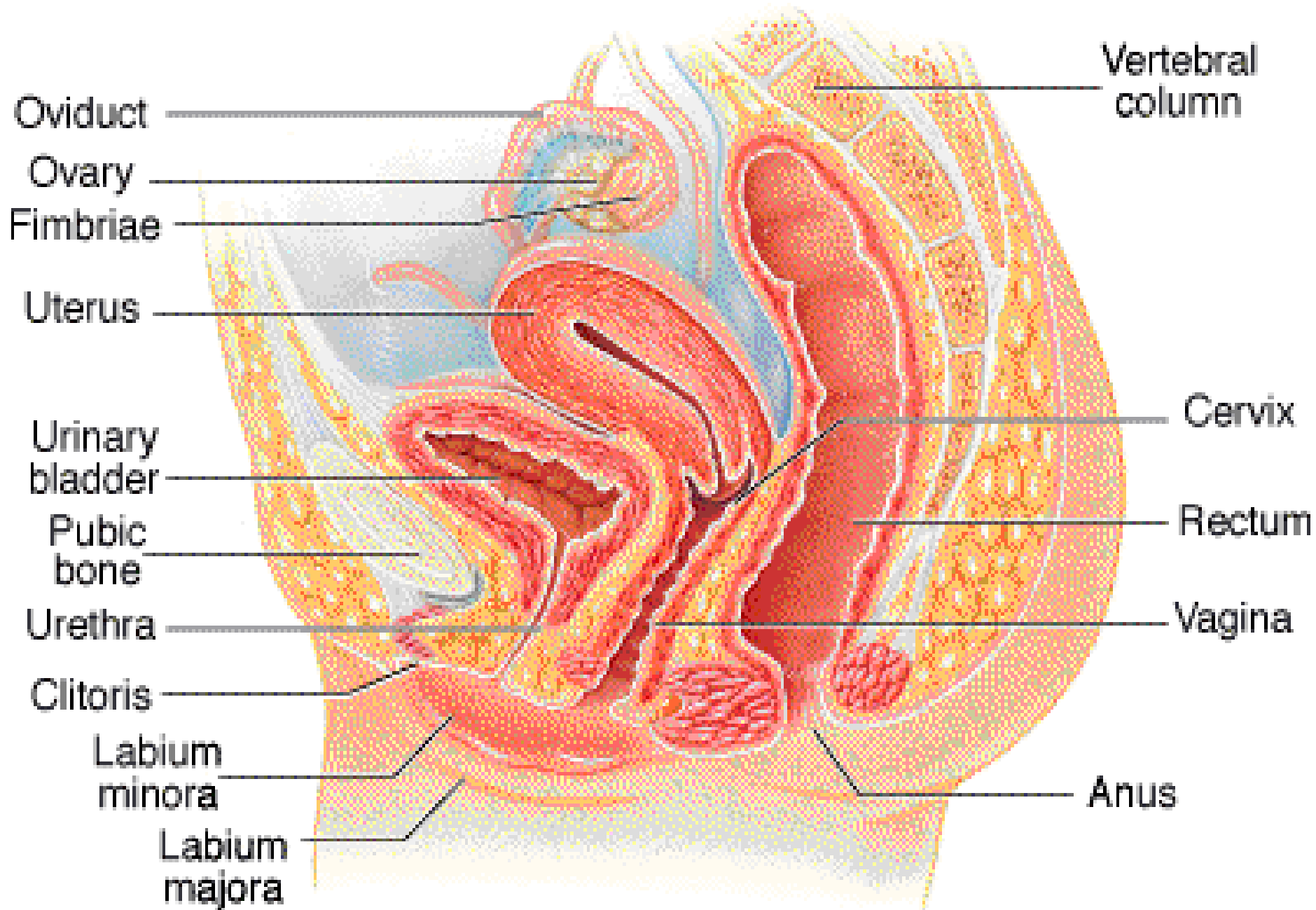


Anatomy II


- In men, anterior to the lower 1/3 of the rectum lie the prostate, bladder base and seminal vesicles.
 - In women, anterior to the lower 1/3 of the rectum lies the vagina. At the tip of the examining finger it may be possible to feel cervix and even a retroverted Uterus
-

Male Reproductive Tract






(a)



- This is an intimate and sometimes uncomfortable examination which is most often done when disease (usually gastrointestinal or genitourinary disease) is suspected or already identified. It may also be done as part of a screening examination when there is no suspicion or expectation of disease but the examination is performed as part of a thorough screening process. It is important in all cases to explain the reasons for the examination and to get verbal consent.

© Original Artist
Reproduction rights obtainable from
www.CartoonStock.com



"Honestly, if there was a virtual prostate exam, don't you think I'd want to be the first to know?"

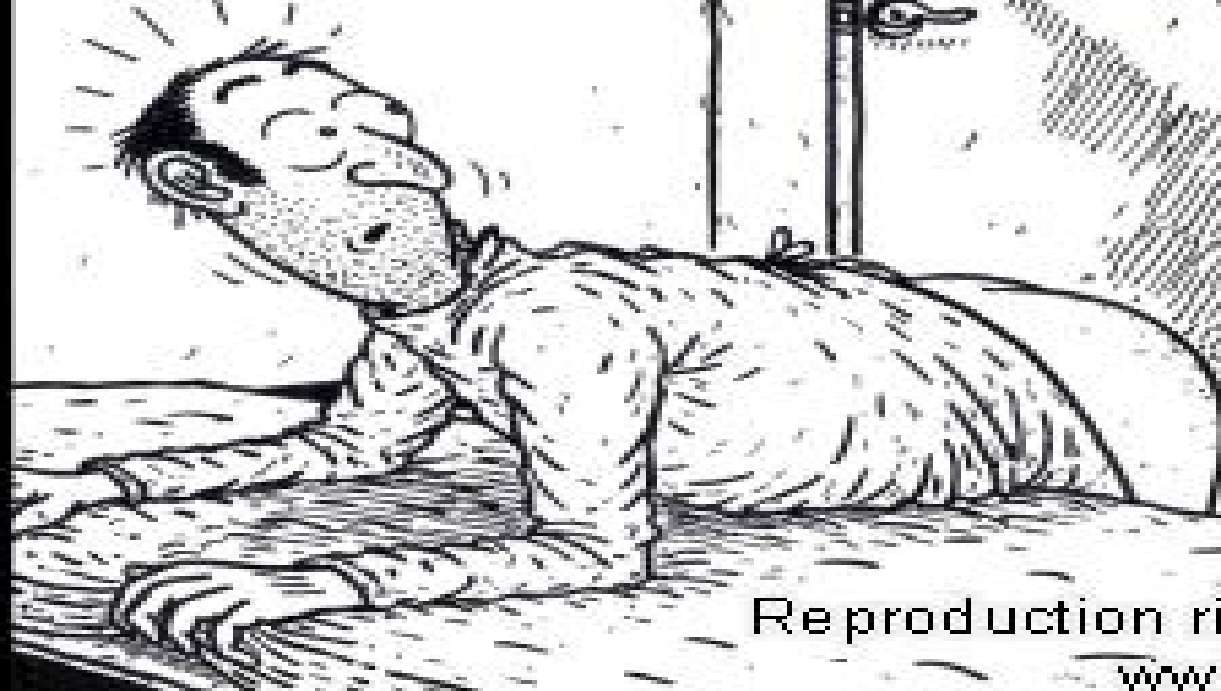



Indications for R.E.

- ❑ Assessment of the prostate (particularly symptoms of outflow obstruction).
 - ❑ When there has been rectal bleeding (prior to proctoscopy, sigmoidoscopy and colonoscopy).
 - ❑ Constipation.
 - ❑ Change of bowel habit.
 - ❑ Problems with urinary or faecal continence.
 - ❑ In exceptional circumstances to detect uterus and cervix (when vaginal examination is not possible).
-

ZWALTA

HELLO MURRY, I'M DR. ROSS,
YOUR PROCTOLOGIST.




searchID: z201966

© Original Artist
Reproduction rights obtainable from
www.CartoonStock.com



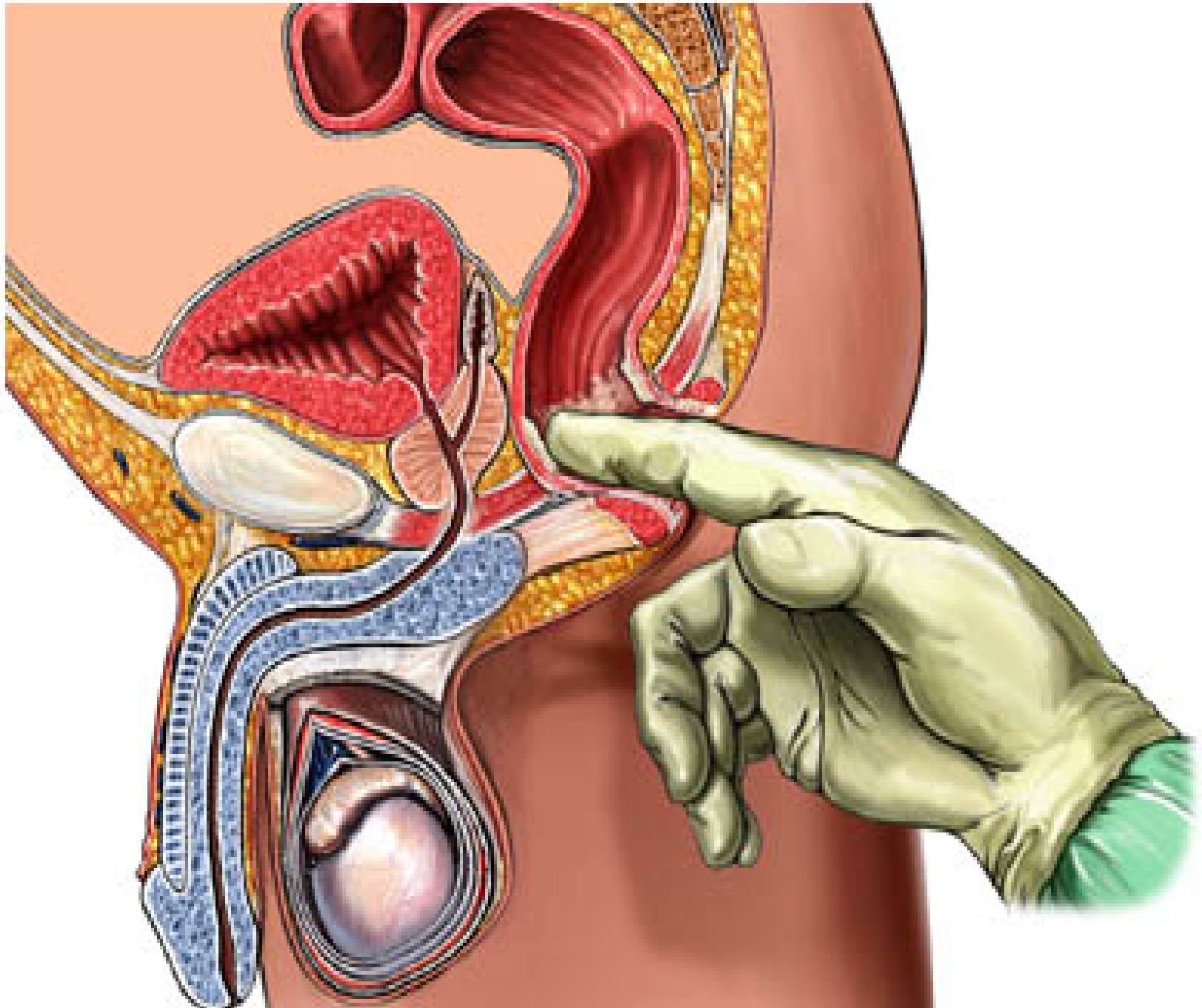
Procedure

- The finger is then moved through 180°, feeling the walls of the rectum. With the finger then rotated in the 12 o'clock position, helped usually by the examiner bending knees in a half crouched position and pronating the examining wrist, the anterior wall can be palpated. Rotation facilitates further examination of the opposing the walls of the rectum. In men, the prostate will be felt anteriorly. In women, the cervix and a retroverted uterus may be felt with the tip of the finger. It is important to feel the walls of the rectum throughout the 360°. Small rectal wall lesions may be missed if this is not done carefully.
-

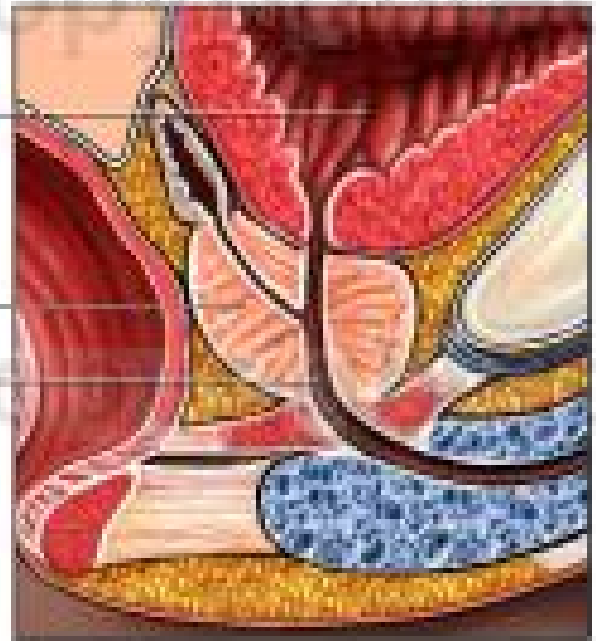

Examination of the Prostate Gland

- Normal size is 3.5 cms wide, protruding about 1 cm into the lumen of the rectum.
 - Consistency: it is normally rubbery and firm with a smooth surface and a palpable sulcus between right and left lobes.
 - There should not be any tenderness.
 - There should be no nodularity.
-



Normal Prostate Anatomy

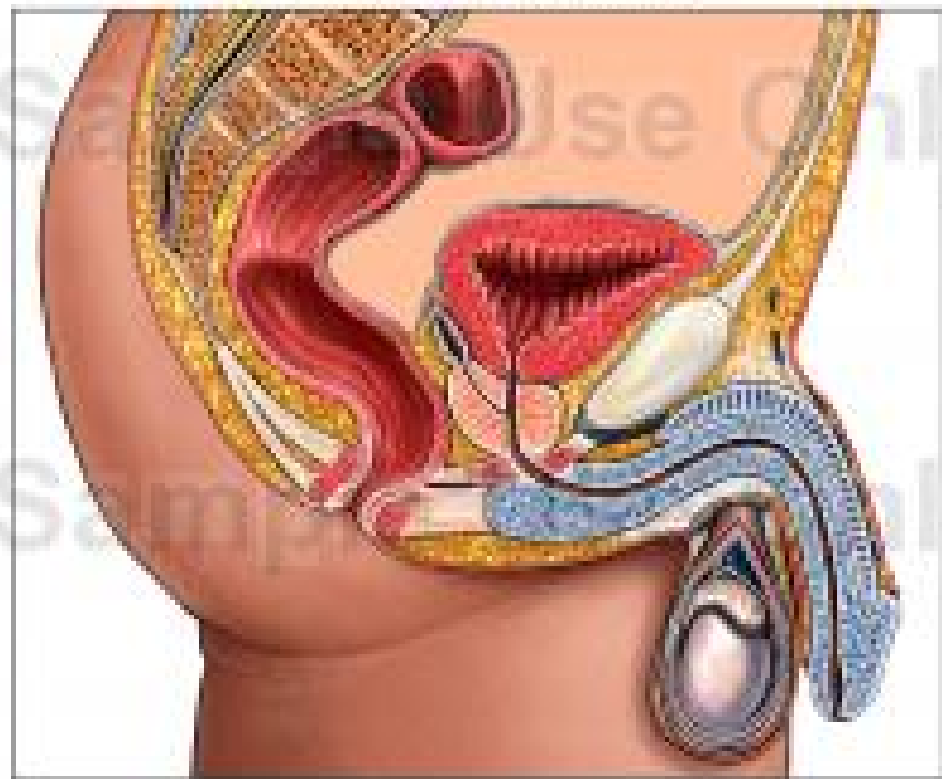


Bladder

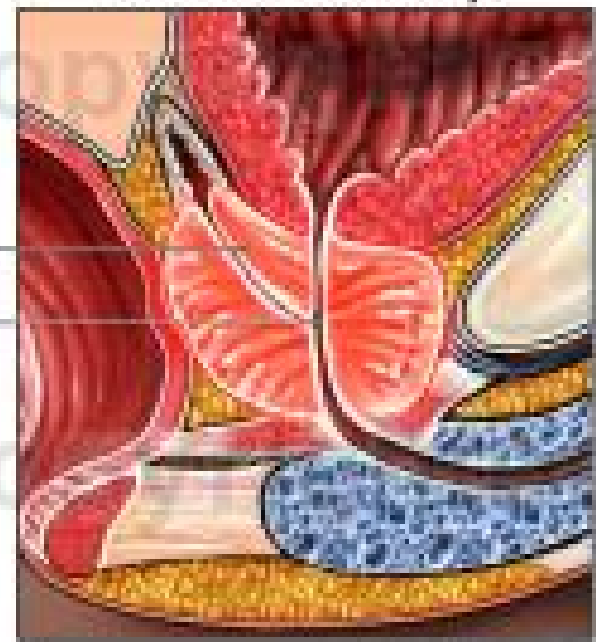
Prostate gland

Urethra

Normal Prostate Anatomy

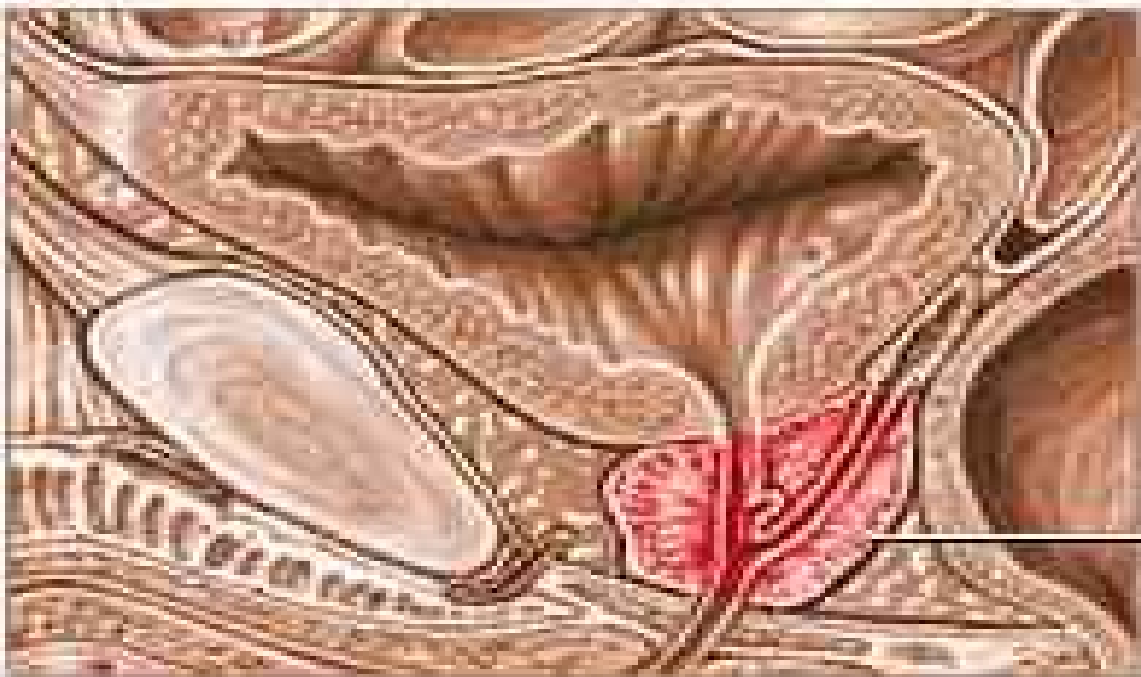

BPH Prostate Anatomy

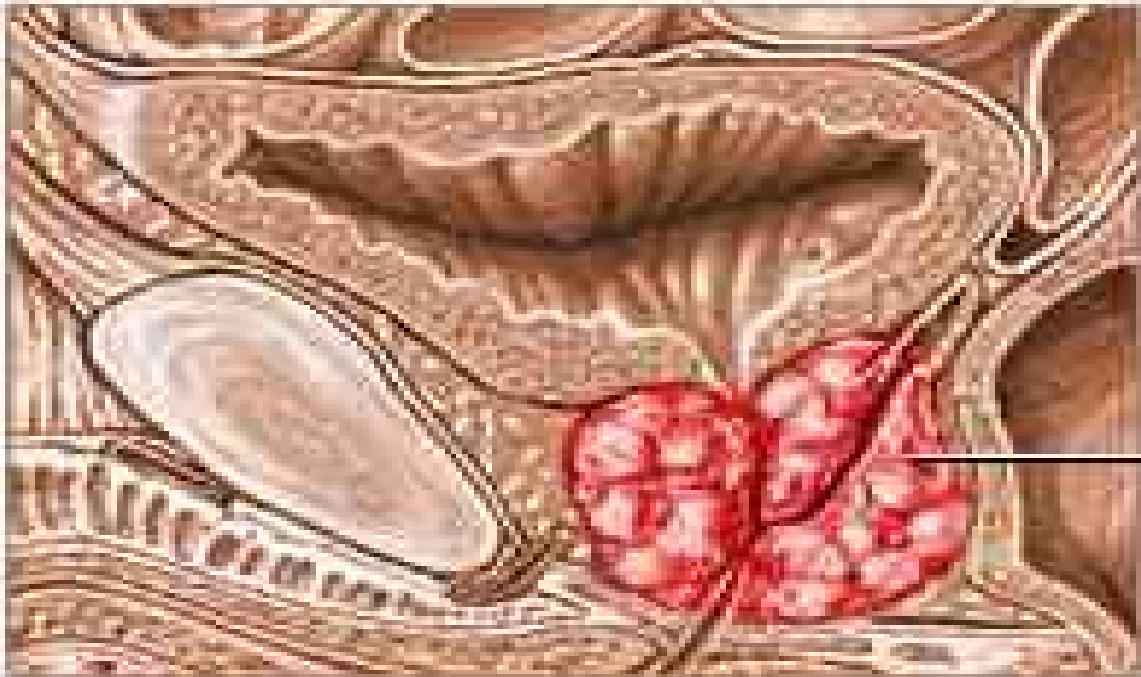


Enlarged prostate gland

Constricted urethra



Normal prostate



Prostate cancer



External Inspection

- ❑ Skin disease.
 - ❑ Skin tags
 - ❑ Genital warts
 - ❑ Anal fissures
 - ❑ Anal fistula
 - ❑ External haemorrhoids
 - ❑ Rectal prolapse
 - ❑ Skin discolouration with Crohn's disease
 - ❑ External thrombosed piles
-



Internal Inspection

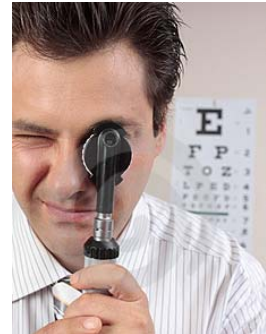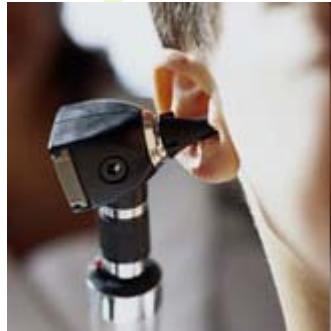- Simple piles (but best examined at proctoscopy)
 - Rectal carcinoma
 - Rectal polyps
 - Tenderness
 - Diseases of the prostate gland
 - Malignant or inflammatory conditions of the peritoneum (felt anteriorly)
-



Contraindications

- Imperforate Anus
 - Unwilling patient
 - Immunosuppressed patient
 - Absence of anus following surgical excision
 - Stricture
 - Moderate to severe anal pain
 - Prolapsed thrombosed internal hemorrhoids
-

OTOSCOPY & OPHTHALMOSCOPY



SHAN KESHRI
CLINICAL SESSIONS

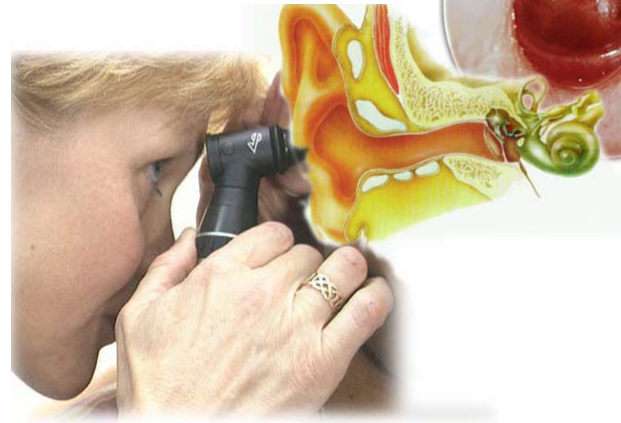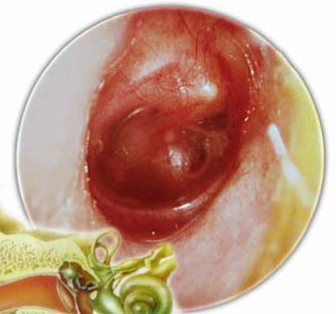


MASARYK UNIVERSITY
FACULTY OF MEDICINE

OTOSCOPY

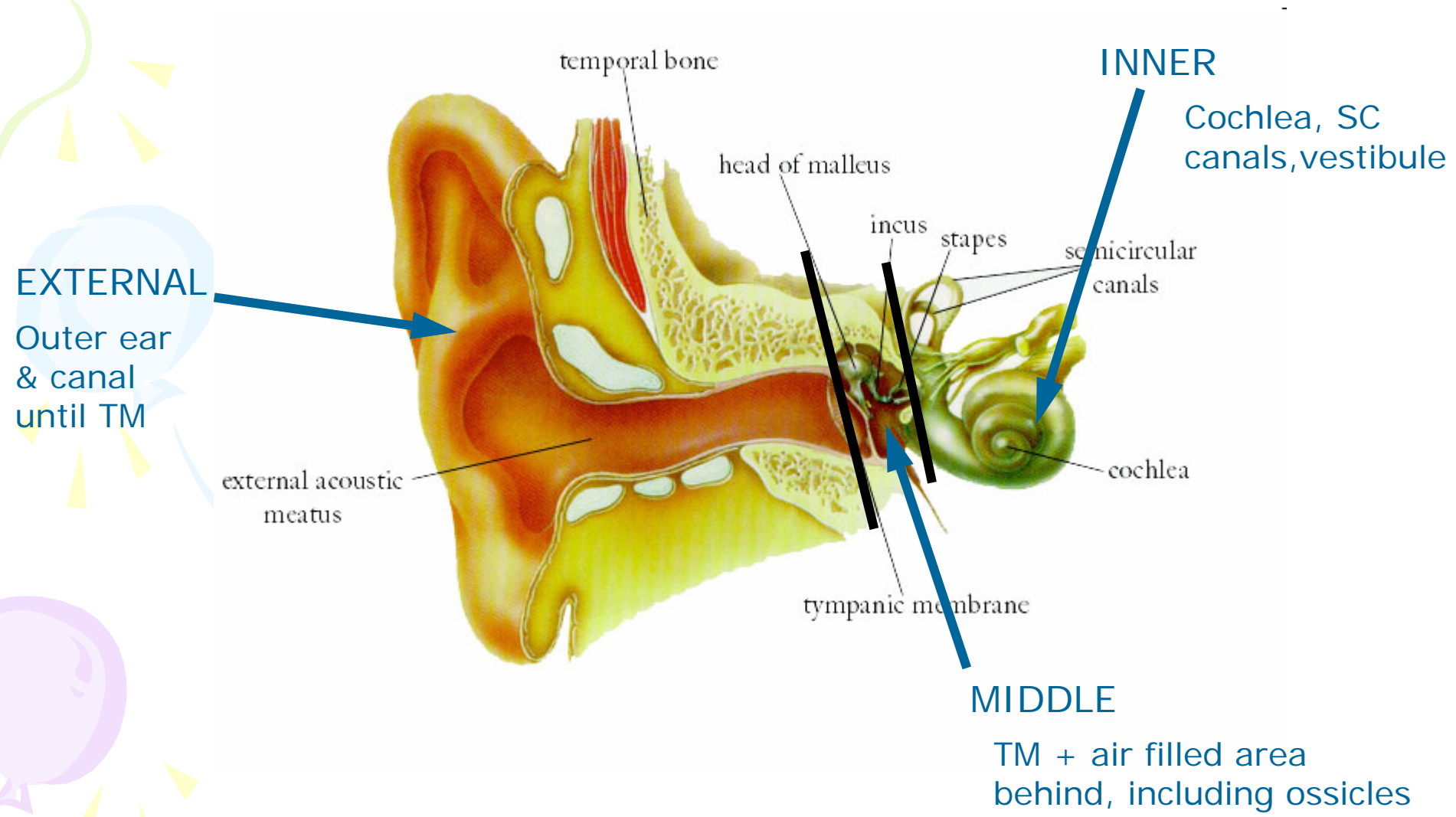


Examination of Ear

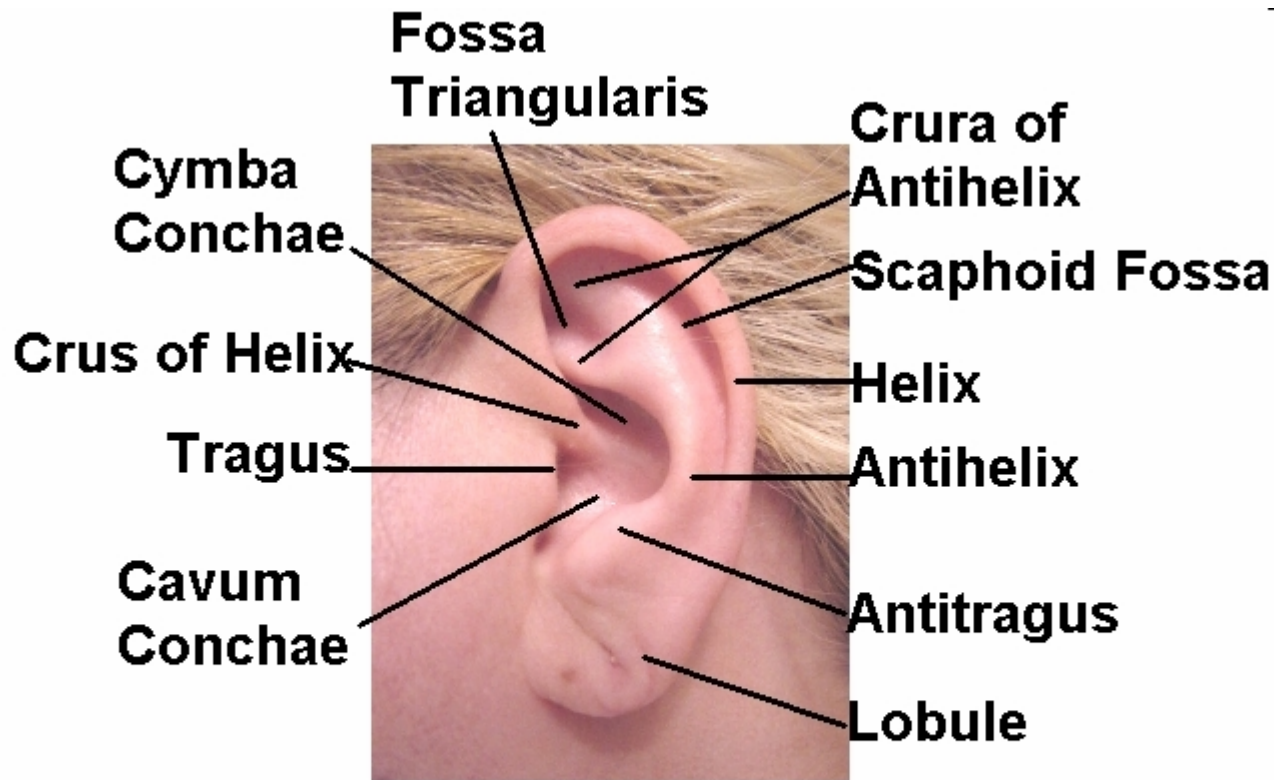


<http://medweb.cf.ac.uk/otoscopy/index.htm>

ANATOMY OF EAR

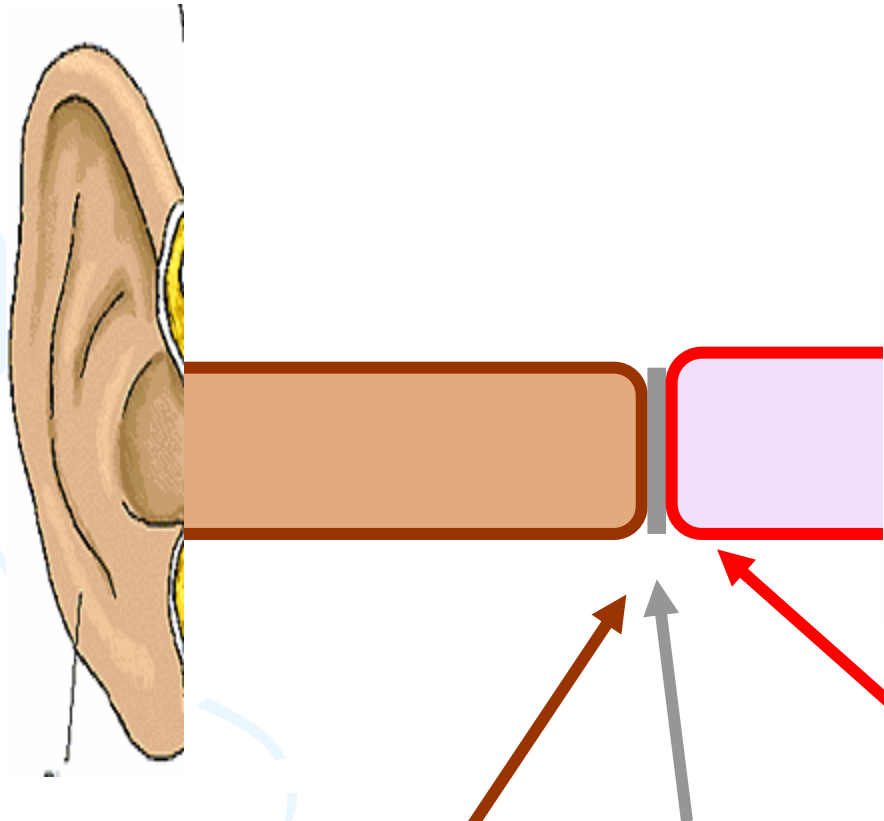


ANATOMY OF EXTERNAL EAR



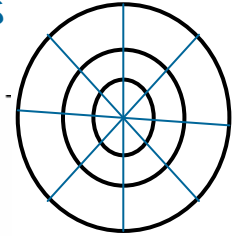
Anatomy of the Pinna

LAYERS OF TYMPANIC CAVITY

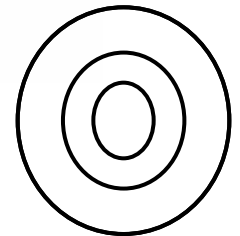


FIBROUS LAYER:

Pars Tensa: circular and radial fibres



Pars Flaccida: only circular fibres



SKIN OF EXT. CANAL

FIBROUS LAYER

MUCOSA



Safety & Communication

- Explain to patient what you are going to do.
 - May be some discomfort, but should be no pain.
- Clean & Disinfect speculum, and wash hands between patients

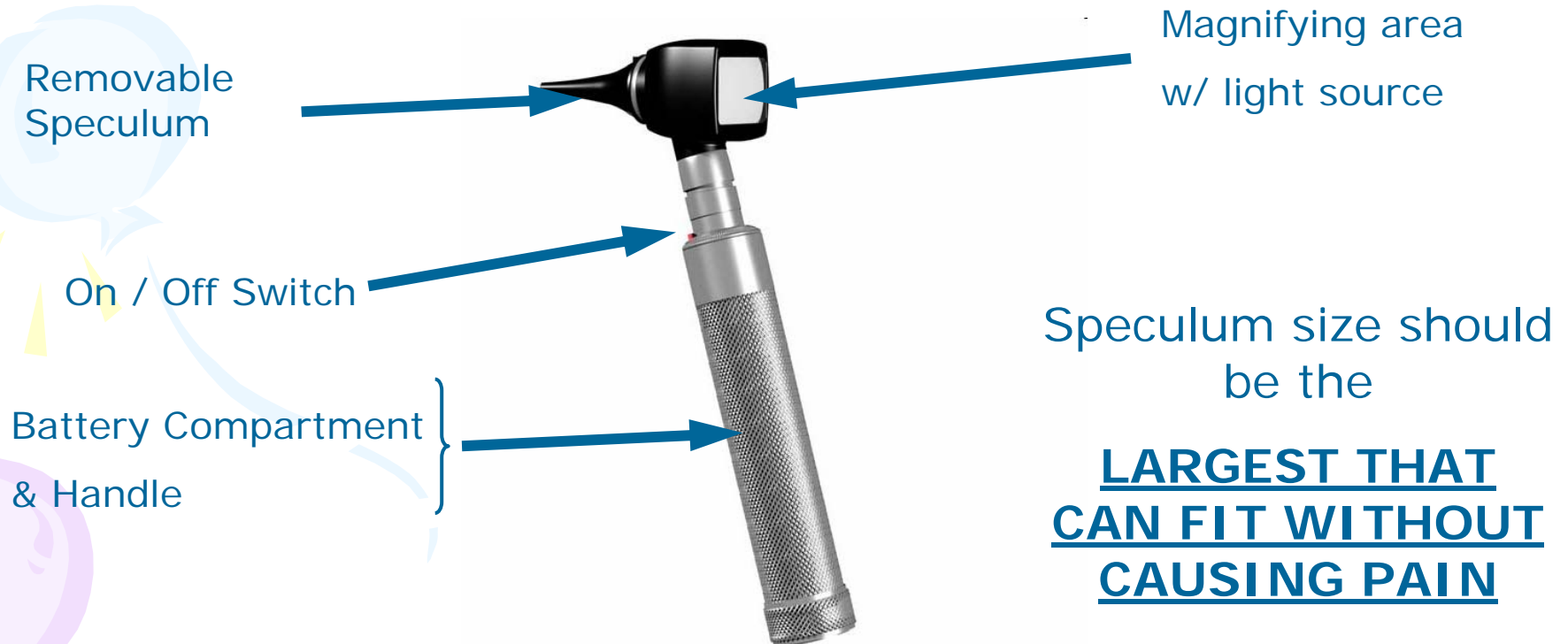


To Start...

- Clinical examination of the ear should begin with a general examination of the external ear, and of the lymph nodes of the head.
- Following this, we can use an otoscope to look inside the ear.

OTOSCOPE / AURISCOPE

- In primary care we use otoscope aka auroscope
 - Clean speculum & functioning batteries (BRIGHT light is important!!)

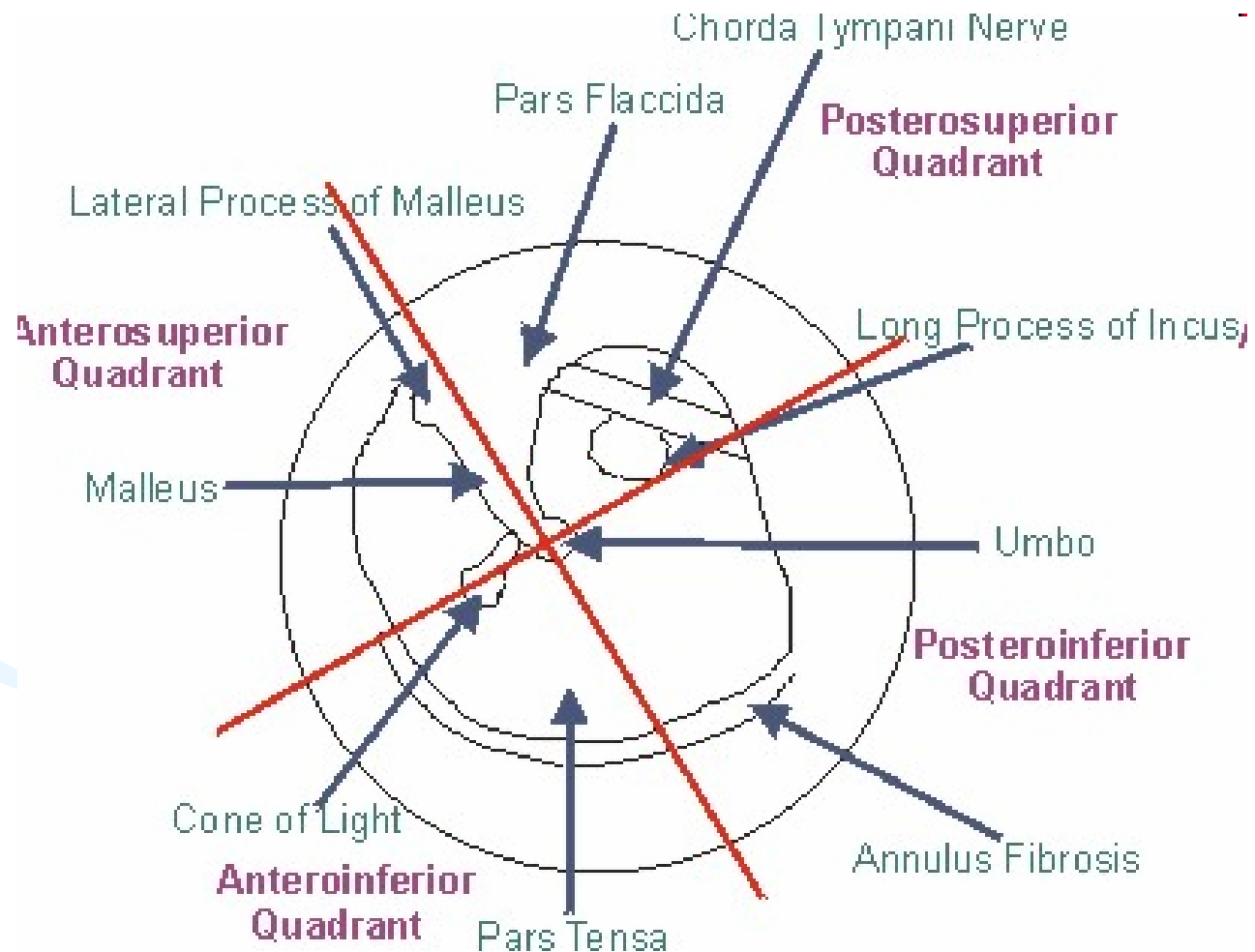


- Hold close to eyepiece for more control
 - Pencil (or hammer grip)
 - Right hand right ear, left hand left ear

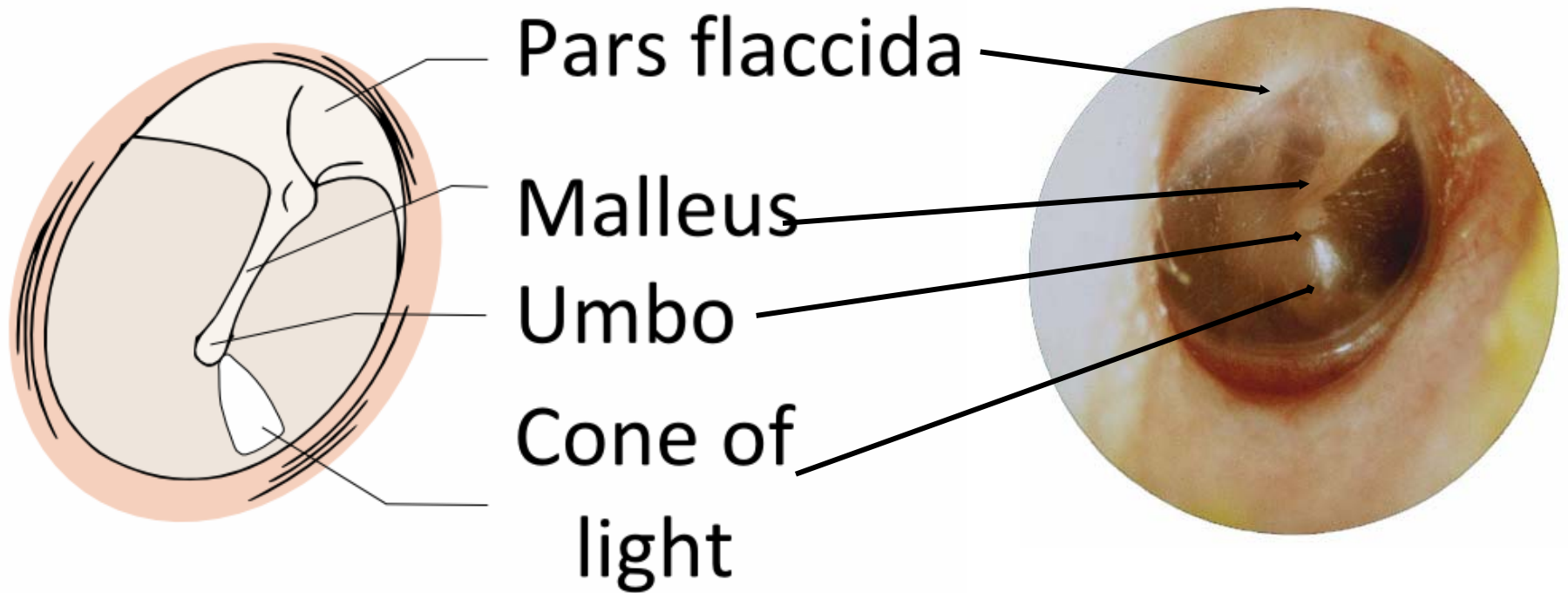


- Pull pinna back and up to straighten ear canal
 - To make speculum insertion easier
- Examine good ear first

QUADRANTS



NORMAL TYMPANIC MEMBRANE





WHAT TO LOOK FOR

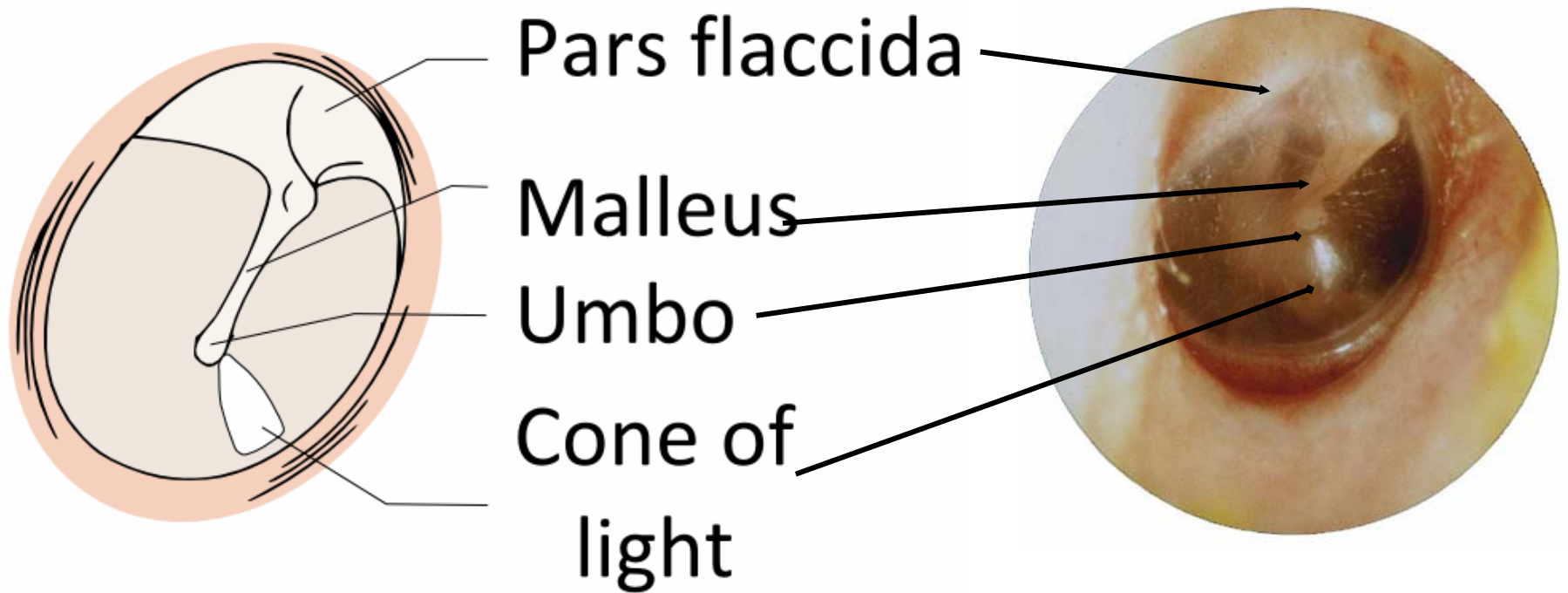
- External canal Wall
 - Skin (normal, inflammed?)
 - Debris?
- **Malleus HANDLE** (or lateral process) HUC
- **UMBO** (malleus stria)
- **CONE OF LIGHT** (triangle shape, with apex at umbo))
- Inspect Pars Tensa, starting in Posterior-Superior quadrant, clockwise
- Inspect Pars Flaccida
- Identify as many structures as you can



Ask Yourself

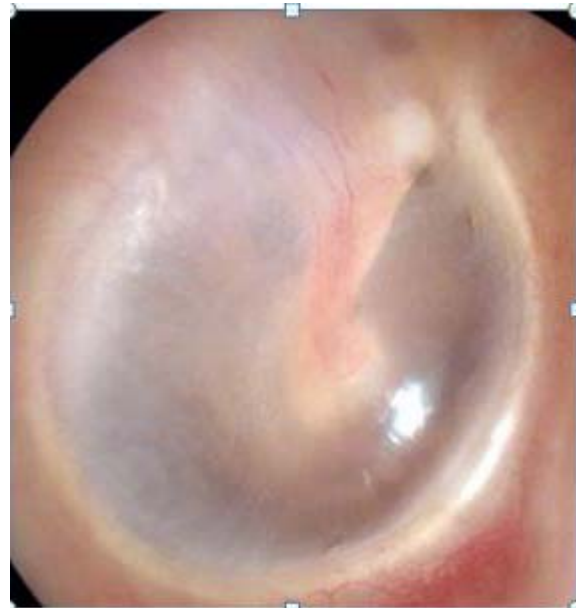- *Can I see **all** the external auditory canal?*
 - stenosis, foreign body, edema, blood, debris
- *Can I see the TM, or the handle of malleus, or both?*
- *Is the TM **intact**?*
 - retraction, perforation, blood vessels, clues about middle ear problems
- *Is the TM correct **colour and transparency**?*
 - Gold/blue/dull = fluid/blood in middle ear
 - White patches = tympanosclerosis (post-surgical?)
 - Pearly grey = Normal

NORMAL TYMPANIC MEMBRANE



NORMAL TYMPANIC MEMBRANE

- Thin
- Semi-transparent
- Pearly grey



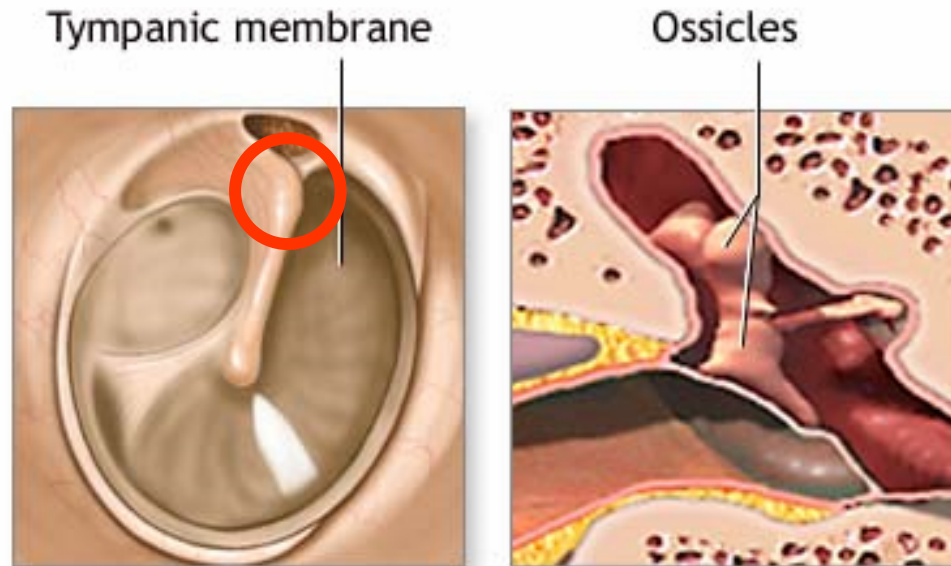


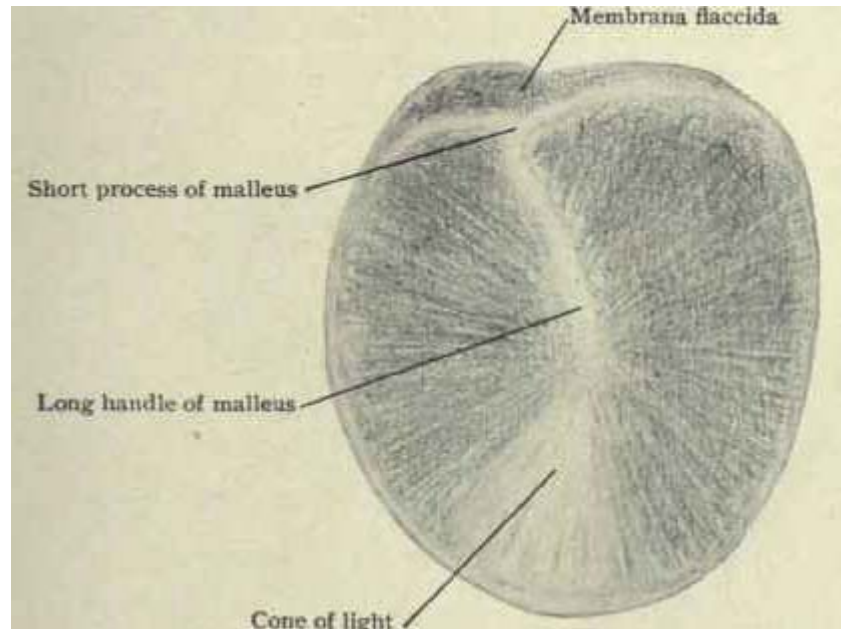
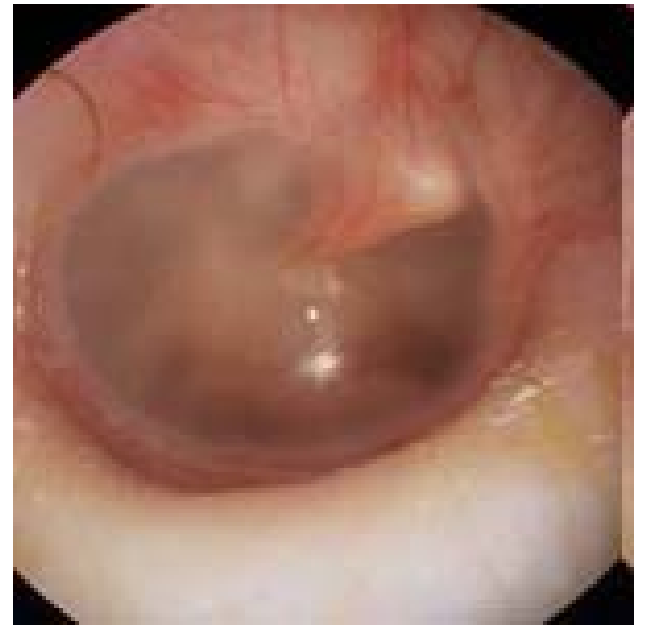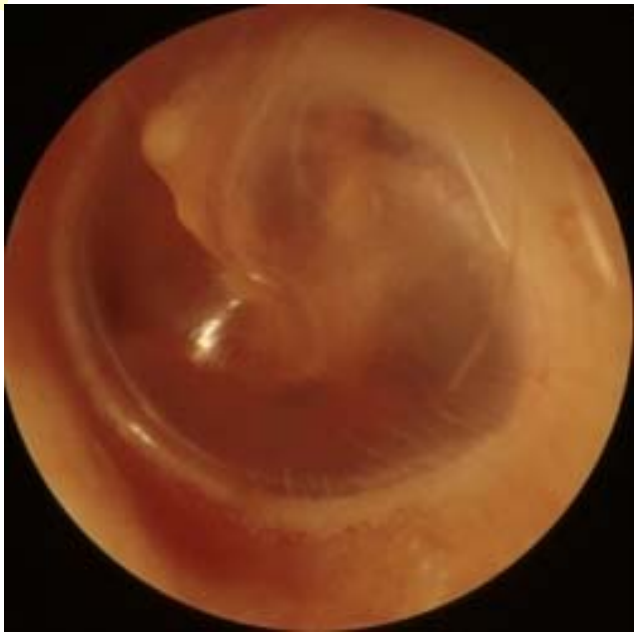INSUFFLATION

- Most otoscopes have a **small air vent connection** that allows the doctor to **puff air in to the canal**.
- Observing how much the eardrum moves with air pressure assesses its **mobility**, which **varies depending on the pressure within the middle ear**.

Can't work out what's what?

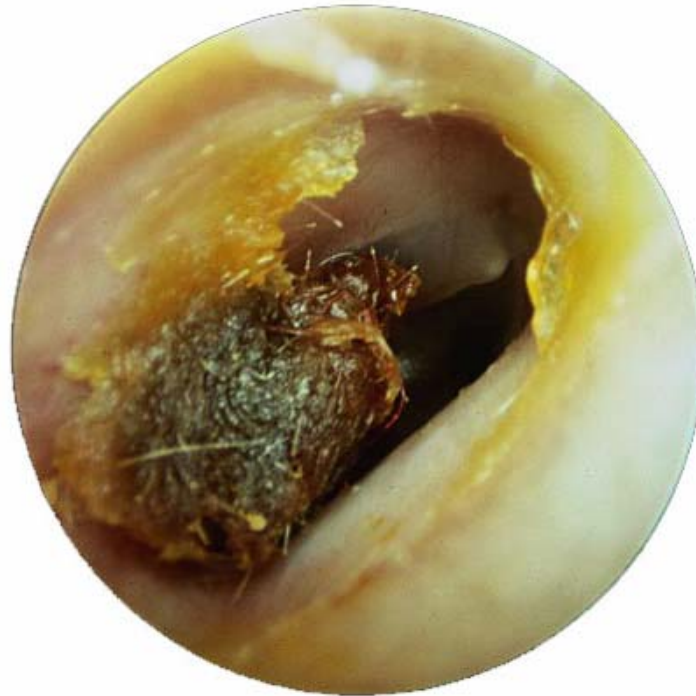- Look for the **lateral process of malleus** for orientation.
- Even when most other part have been destroyed, this is usually still visible.





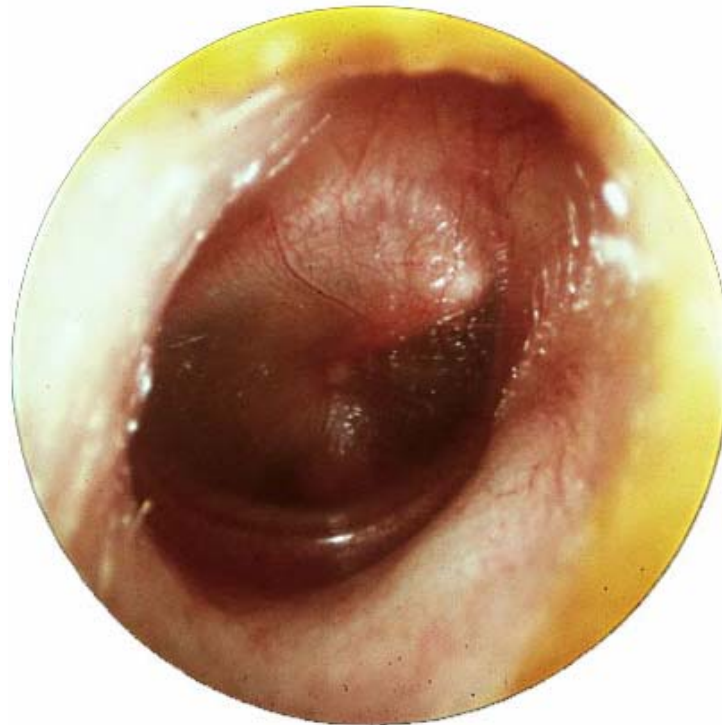WAX / CERUMEN

- Normal secretion of outer meatus
- Initially **semi liquid and colourless**, later oxidises to **yellow-brown harder** substance which can block passage of sound.

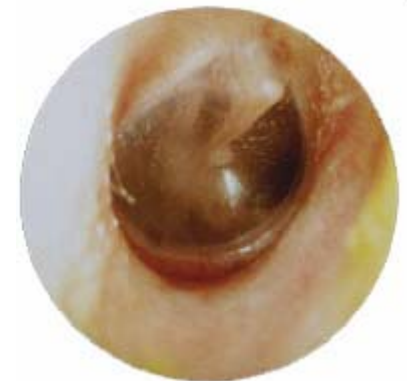


ACUTE OTITIS MEDIA (w/ effusion)

- Inflammation of middle ear (infection)
- Upper half:
 - Prominent blood vessels, Bulging, malleus prominence obscured (fluid)
- Lower half:
 - Dull

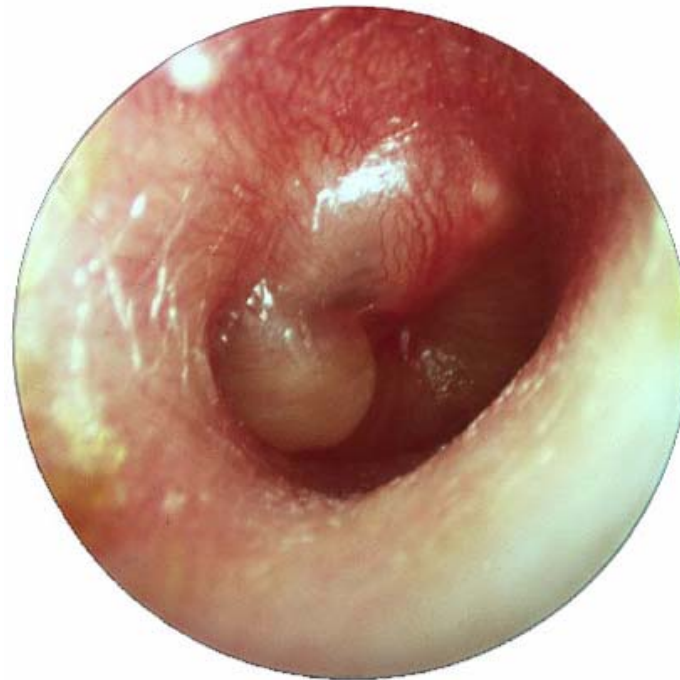

NORM

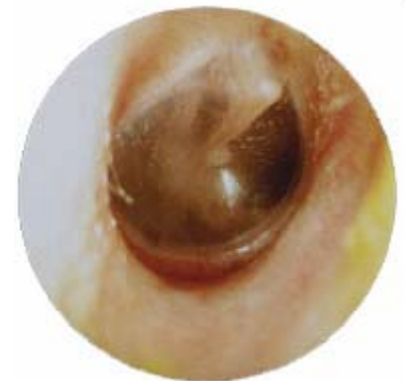


ACUTE OTITIS MEDIA (w/no definition)

- Inflammation of middle ear (infection)
- **Bulging** TM, with Purulent fluid behind a tense TM
- Risk of perforation – need to drain!

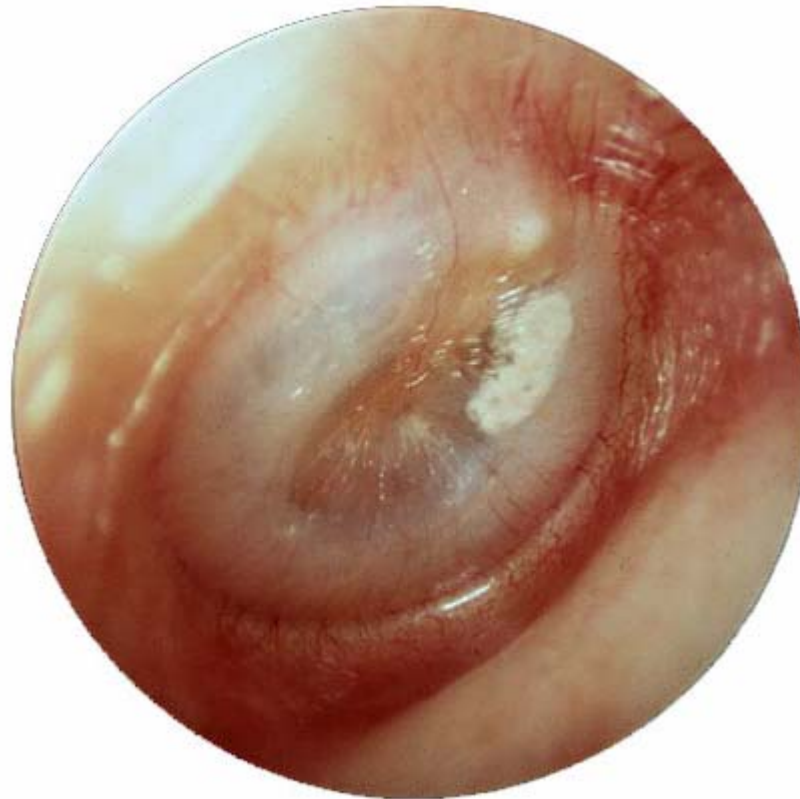

NORM



TYMPANO-SCLEROSIS

- **Incomplete healing of OM**
- Inflammatory process > Scar Tissue = **Calcified plaques on TM**

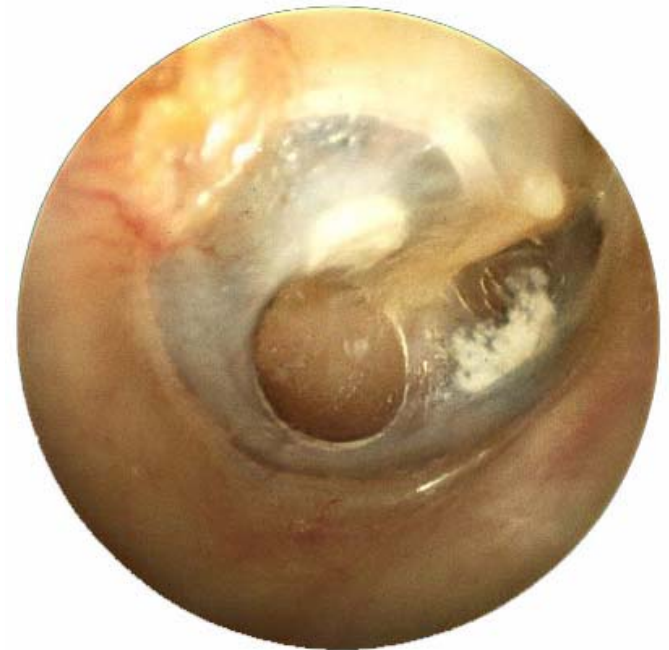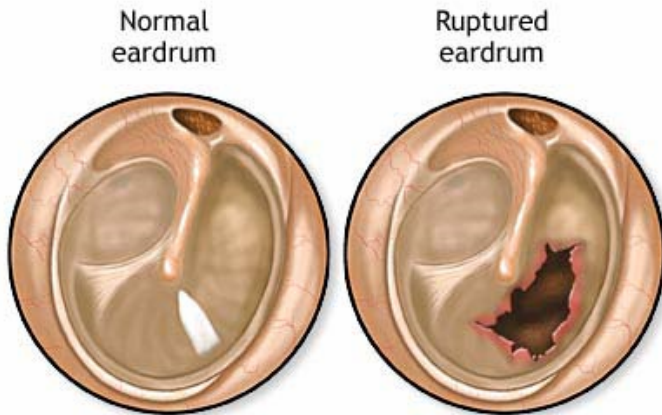


NORM



CENTRAL PERFORATION OF TM

- Causes include **Trauma to head**, Spontaneous perforation, Loud sounds, Middle ear fluid build up, kissing ear (negative pressure) etc
- Pressure related: circular
- Trauma related: cake shaped





OTHERS TO LOOK INTO

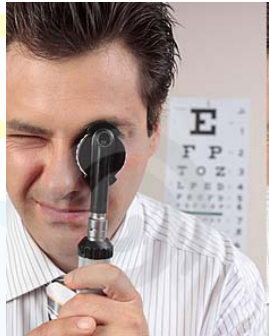- Acute Otitis Media with effusion
- Secretory Otitis Media
- Fluid behind eardrum
- Resolution of Middle Ear Infection
- Serous Otitis Media
- Grommet / Tympanostomy tube
- Otitis Externa



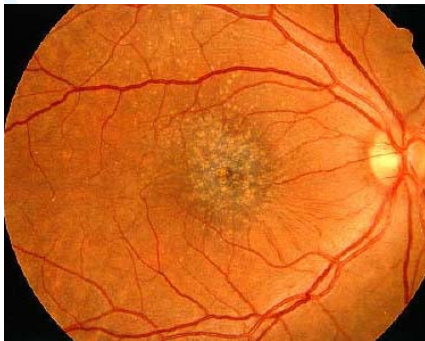
FURTHER READING

- Glue Ear (children)
 - Myringotomy
 - Retracted ear drum
 - Cholesteatoma
 - Grommets
 - Tuning Fork tests – Rhines & Webers
 - Tympanometry (Jerger classification)
 - Evoked Potentials
 - Vestibulo-ocular reflex (VOR)
 - Vestibulo-spinal reflex (VSR)
 - Audiometry
 - http://archive.student.bmj.com/back_issues/0795/7-otos.htm
 - <http://s818.photobucket.com/albums/zz101/bainiangudu168/video%20otoscope/?action=view¤t=002-2.flv>
- 

OPHTHALMOSCOPY

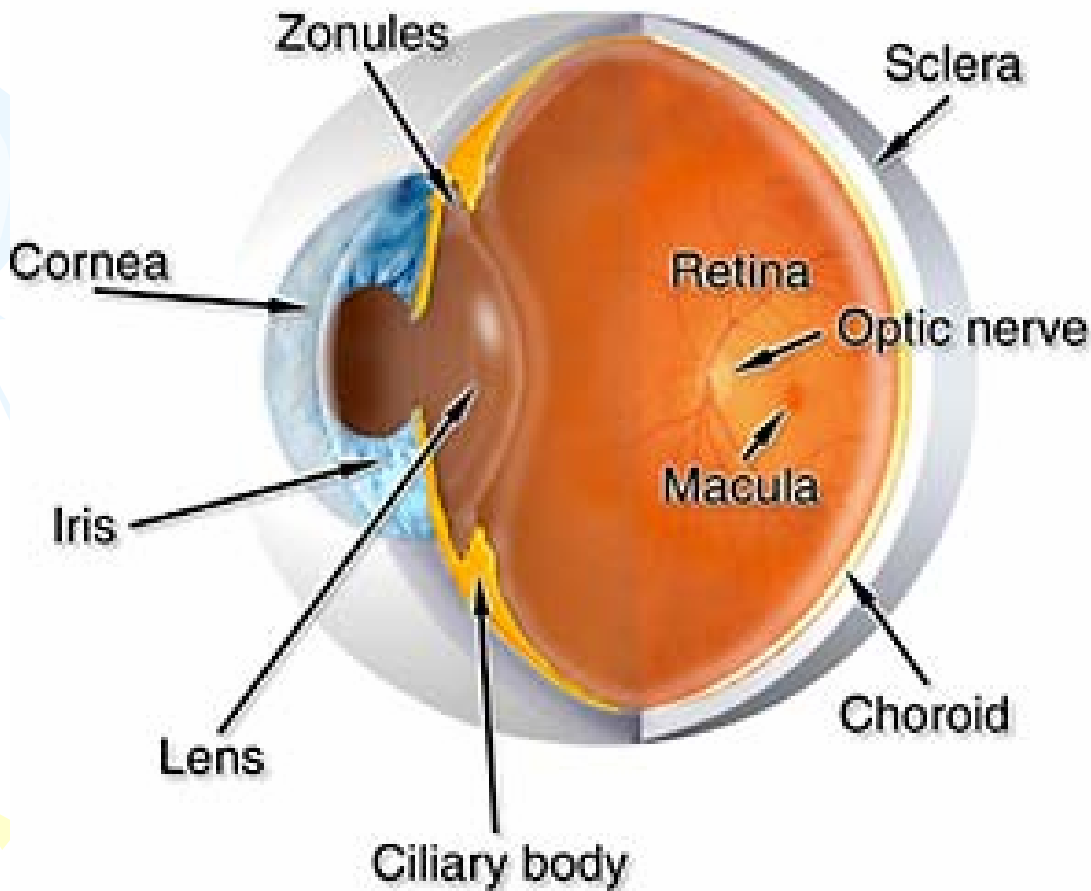


Examination of eye



ANATOMY OF EYE

Normal Eye Anatomy



Sclera

Vascular **Choroid**

Photosensitive

Retina

OPHTHALMOSCOPE

Look through here

Change magnification

Magnification number

Depress and rotate green button to turn on



**FACES
EXAMINER**

Lid

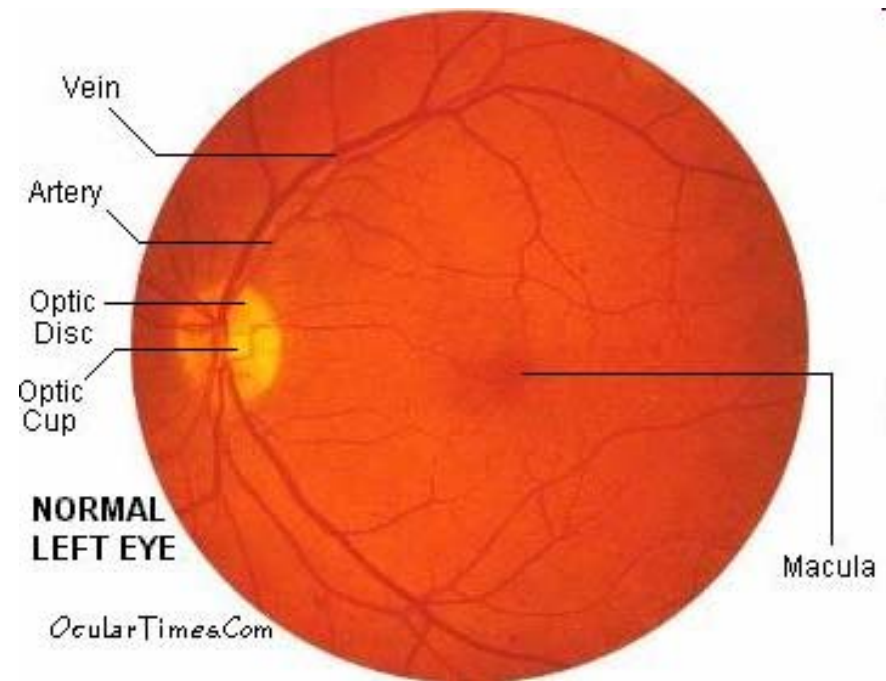
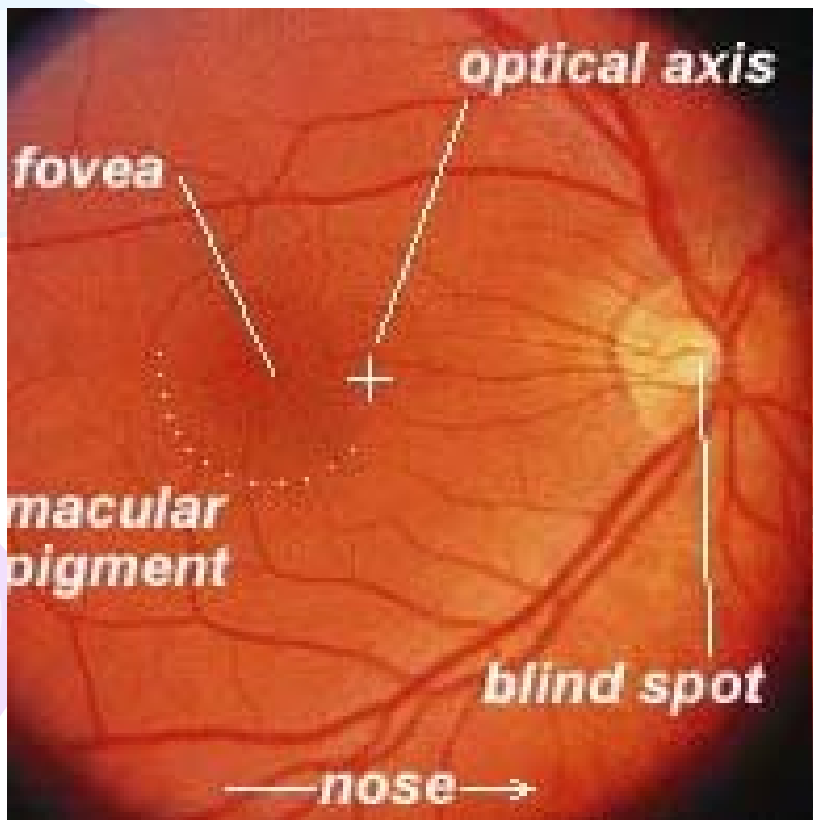


**FACES
PATIENTS
EYE**

OPHTHALMOSCOPE

- Examine Fundus

- Interior surface of the eye, opposite the lens, includes **retina, optic disc, macula** and **fovea**.



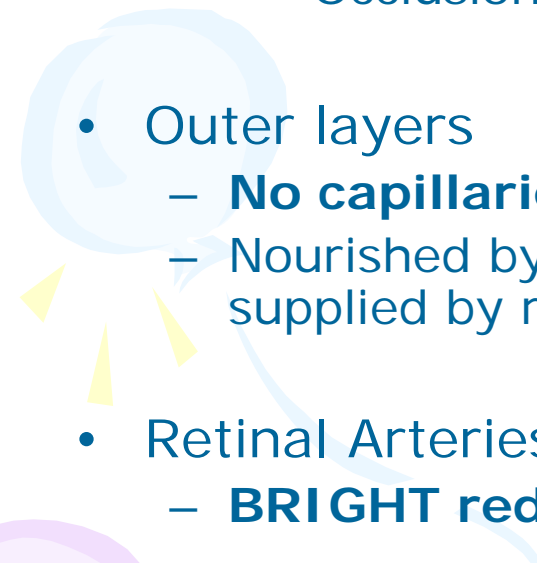



RETINA

- Innermost of 3 layers
 - Pars **optica** retina – **photoreceptive**
 - Pars **ceca** retina – **not photoreceptive**
- Review 11 histological layers of retina
- **Macula Lutea** : **flattened oval area in centre of retina**, slightly below optic disc.
 - In centre: Avascular **fovea centralis** : point of **sharpest visual acuity**; only cones, each with own nerve supply




RETINA: VASC SUPPLY

- Inner layers
 - **Central retinal arteries** (br. of ophthalmic)
 - Occlusion > retinal infarction
 - Outer layers
 - **No capillaries**
 - Nourished by diffusion from vascular choroid layer, which is supplied by retinal arteries
 - Retinal Arteries:
 - **BRIGHT red, BRIGHT reflex, NO PULSE, Paler with age,**
 - Retinal Veins:
 - **DARK red, NARROW reflex, SPONTANEOUS PULSE, 1.5x THICKER**
- 
- 



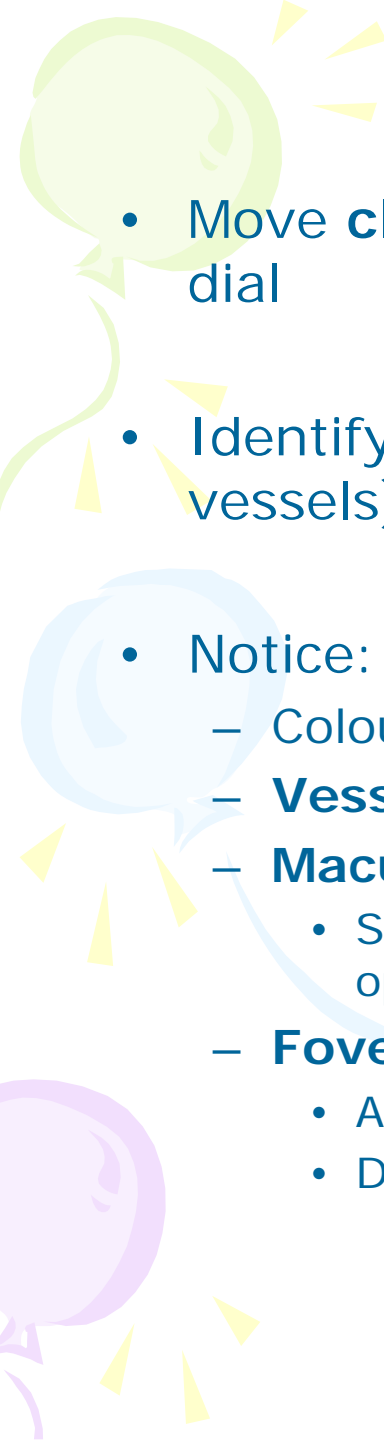
RETINA: NERVE SUPPLY

- No Sensory supply
- **Disorders of retina are painless!!**



METHOD

- Slightly **Dark** room (**dilated pupils** – can apply eye drops to help)
- Ask patient to keep looking straight ahead and **focus into distance**
- Check ophthalmoscope works and lid is open by **shining onto your hand**
- Hold ophthalmoscope **touching your eye, 30cm from patient**. Put **spare hand on patients head**
- From **lateral** side (holding ophthalmoscope in **right hand for right eye**), look into the patients eye, through the pupil
- Observe **red reflex**
 - **reddish-orange reflection from the eye's retina**
 - No? – cataract, retinoblastoma??

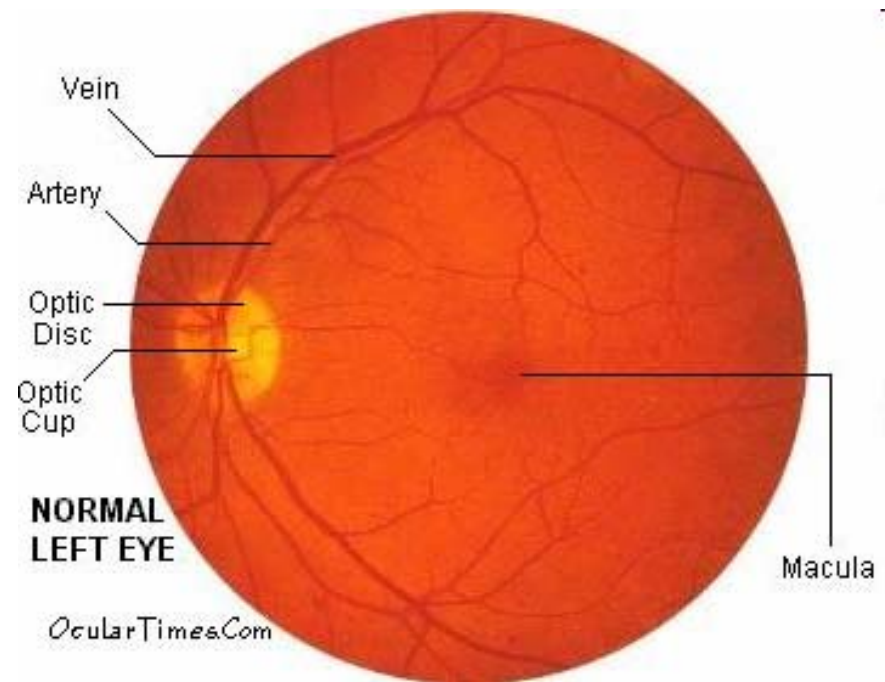
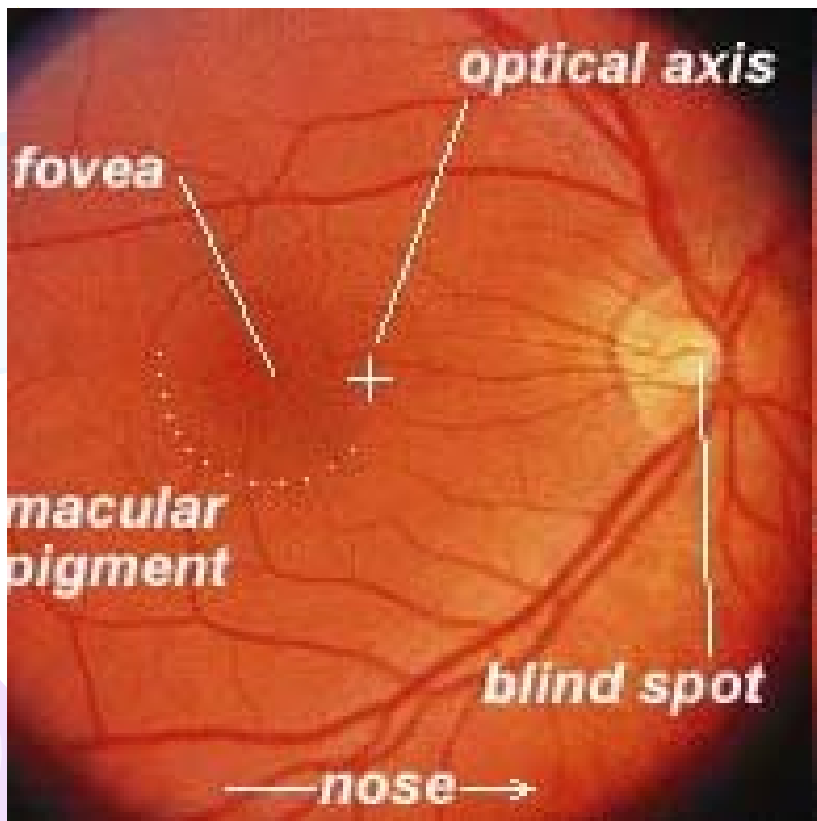
- 
- Move **closer** to eyes, **focusing** better using the focusing dial
 - Identify the **optic disc** (white circle / origin of all the blood vessels) and see the **fundus**.
 - Notice:
 - Colour size borders of **optic disc**
 - **Vessels** (of all quadrants)
 - **Macula**
 - Slightly darkened pigmented area, 2 optic disc widths from the optic disc
 - **Fovea**
 - Ask patient to looked directly into light, and you may see it
 - Do this last



NORMAL FUNDUS

- Completely **transparent retina**, with no intrinsic colour.
- **Uniform bright red coloration** from the choroid layer vessels
- Optic disc: sharply defined, **yellow-orange**
 - Younger people : pale pink optic disc
- Central Vein lies lateral to artery, **no crossing over**
- **Uniform diameter** of vessels
- Normal spontaneous **venous pulse**
- **NO arterial pulse**

NORMAL FUNDUS



A decorative graphic on the left side of the slide features three balloons in light green, light blue, and light purple, each with yellow streamers and triangular flags trailing behind them.

AGE RELATED CHANGES

- **Optic disc** turns pale **yellow** (from pink)
- **Fundus** turns dull, and **non reflective**
- **Drusen** visible
 - tiny yellow or white accumulations of extracellular material that build up in Bruch's membrane
- **Thick vascular walls** > less elastic
- **Meandering of venules**
 - Sclerotic changes can compress vessels



ABNORMAL CHANGES

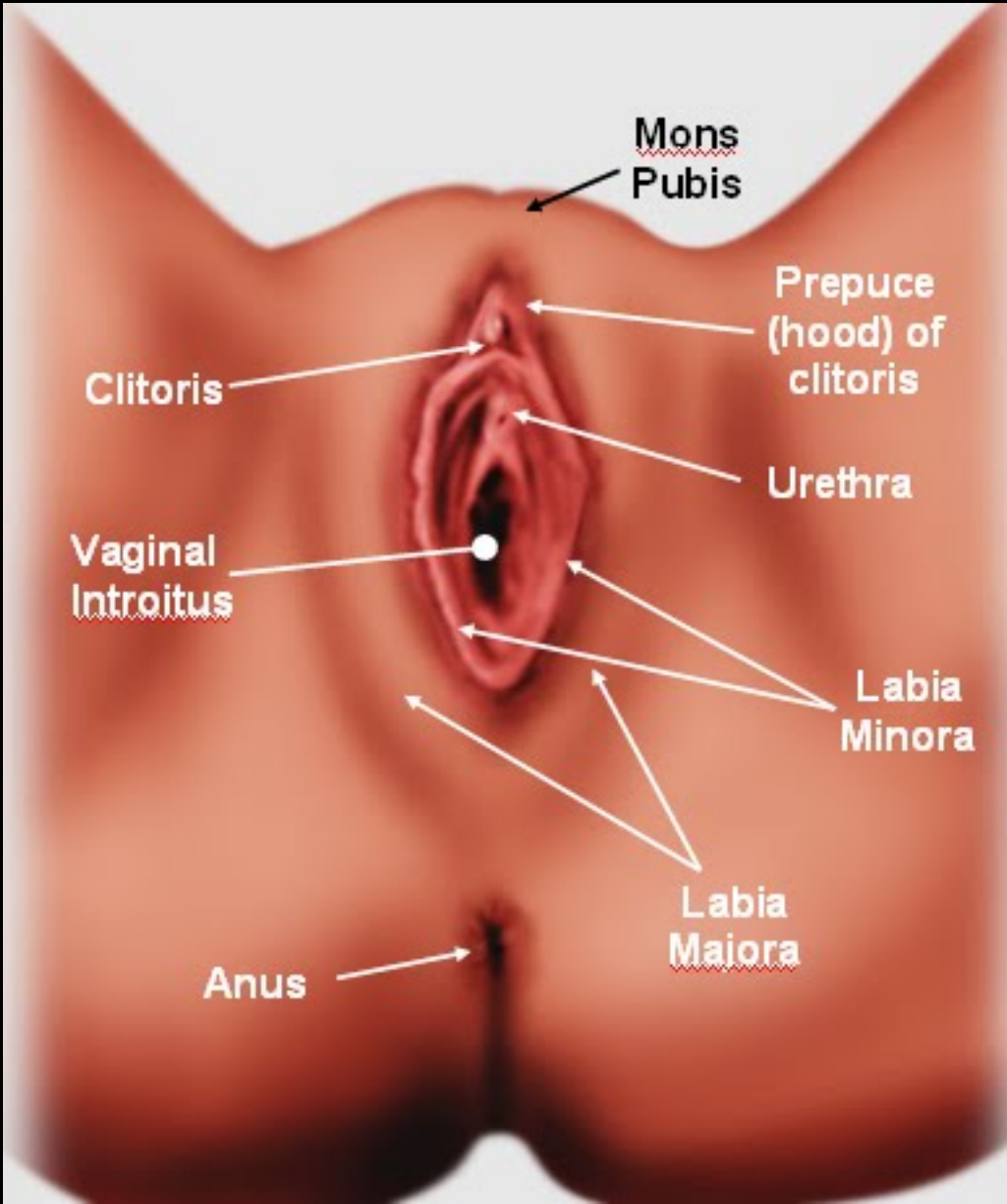
- Loss of transparency of retina
 - edema? – white/yellow
- Much more reading needed.

FURTHER READING

- Direct & indirect ophthalmoscope
- Ophthalmic history taking
- Tests of visual acuity (sharpness) : Snellens letter chart 20/20 / pictogram kids
- Ocular motility : 9 possible degrees of gaze
- Strabismus, paralysis of ocular muscles, gaze paresis
- Binocular alignment: cover test
- Eyelid and nasolacrimal duct examination
- Conjunctiva examination
- Cornea, and corneal sensitivity
- Examination of anterior chamber
- Lens examination : slit lamp, focused light
- Confrontational field testing
- Measure intraocular pressure
- Admin of eye drops, ointment, eye bandages

Urethral Catheterization

Diogo Forjaz
Clinical Sessions
Masaryk University




Urethral Catheterization

Is a routine medical procedure that facilitates direct drainage of the urinary bladder.

Catheters may be inserted as:

- ✓ an in-and-out procedure for **immediate drainage**,
- ✓ left in with a self-retaining device for **short-term drainage** (eg, during surgery)
- ✓ left indwelling for **long-term drainage** for patients with chronic urinary retention.

INDICATIONS



DIAGNOSTIC

THERAPY

DIAGNOSTIC PURPOSES:

- Determine the etiology of various genitourinary conditions
- Collection of urine specimen for microbiology testing
- Monitoring of urine output

THERAPEUTIC PURPOSES:

- Acute urinary retention (eg, blood clots)
- Chronic urinary retention (eg, obstruction that causes hydronephrosis and damage of kidney)
- Intermittent decompression for neurogenic bladder
- Hygienic care of bedridden patients
- Benign prostatic hyperplasia

BUT ALSO:

- On patients who are **anesthetized or sedated** for surgery or other medical care
- On **comatose** patients
- On some **incontinent** patients
- **Post orthopedic surgery** that may limit a patient's movement
- On patients who are unable due to **paralysis or physical injury** to use either standard toilet facilities or urinals.
- Sometimes before **Furosemide** administration

CONTRAINDICATIONS

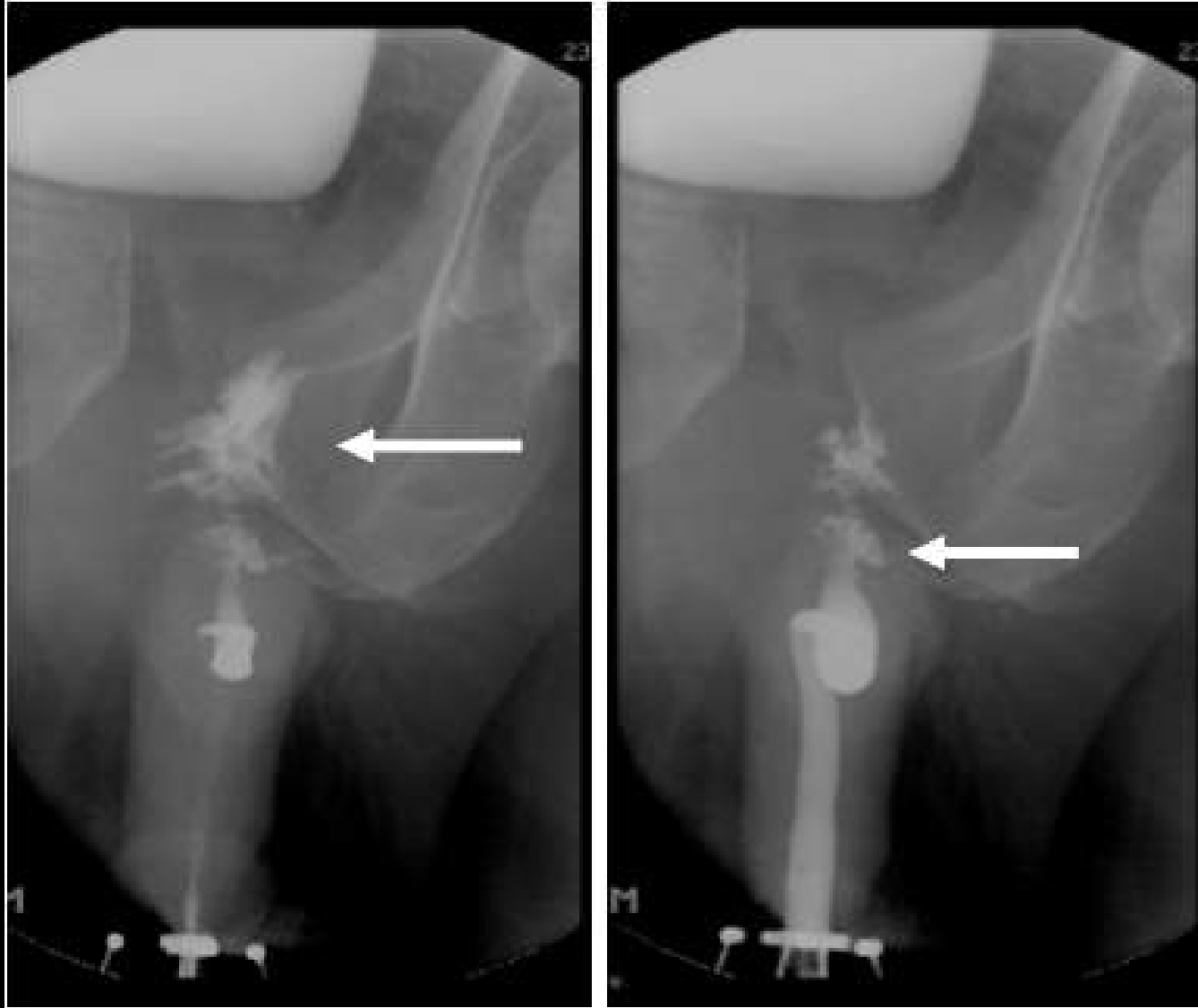
ABSOLUTE

traumatic injury in the lower urinary tract

Signs that increase suspicion for injury are:

- hematuria
- perineal hematoma
- blood at the meatus
- High riding prostate

a rectal exam, genital exam and a retrograde urethrogram should be performed to rule out prior to placing a catheter into the bladder.



injection of a radiopaque dye (**contrast agent**) into the urethral meatus in conjunction with **x-ray** imaging of the pelvic area.

CONTRAINDICATIONS

RELATIVE

- Urethral stricture
- Recent bladder or urethral surgery
- Combative or uncooperative pt.

EQUIPMENT

Sterile drapes and gloves

Antiseptic solution (povidone-iodine)

Cotton balls and forceps

Catheter – FOLEY

Sterile lubricant

Syringe with saline for balloon inflation

Drainage bag

Viscous Lidocaine 2%

Tape to secure the catheter to patient.


http://www.youtube.com/watch?v=o0DoftBJ1ew&feature=player_embedded

<http://www.youtube.com/watch?v=NLJ4vwaSOCE&feature=related>



The maximal recommended volume for urethral balloon inflation can be found on the inflation valve (usually, 10-30 mL).



Catheter Types



- 1) Straight tip;
- 2) Coude tip;
- 3) 3-way catheter irrigation



1) **Straight tip catheter** – 2 lumens:
urinary drainage

Inflate the balloon at distant end of catheter

2) **Coudé tip catheter** – 2 lumens and final semirigid curved end to facilitate in prostatic enlargement pt.

3) **3 way catheter irrigation** – addition lumen for drainage for post surgery bladder and prostatic patients, for hematuria and clots prevention.

CATHETER MATERIALS

✓ **Latex**

✓ **Silicone**

If the pt. is allergy/hypersensitivity

✓ **Silver**

prevent colonization of bacteria, use in recurrent urinary infections pt.

CATHETER SIZES

UNIT IS FRENCH

1 F is equivalent to 0.33 mm

Adults: Foley (straight tip) catheter (16-18F)

**Adult males with obstruction at the prostate -
Coudé tip (18 F)**

**Adults with gross hematuria - Foley catheter
(20-24F) or 3-way irrigation catheter (20-30F)**

**Children - Foley; to determine size, divide
child's age by 2 and then add 8**

**Infants younger than 6 months - Feeding tube
(5F) with tape**

COMPLICATIONS

- ✓ **INFECTIONS**

(Urethritis, Cystitis, Pyelonephritis, Transient bacteremia)

- ✓ **PARAPHIMOSIS**

(caused by failure to reduce the foreskin after catheterization)

- ✓ **Urethral STRICTURES**

- ✓ **Urethral PERFORATION**

- ✓ **BLEEDING**

LONG TERM COMPLICATIONS:


- ✓ Bladder spasm – due to inflated balloon
- ✓ Blood infections – sepsis
- ✓ Bladder stones
- ✓ Bladder cancer

THANK YOU FOR
YOUR ATTENTION

GALS


Gait, Arms, Legs and Spine Examination

by David Utulu

- 
- A GALS screen is an examination used by doctors and other healthcare professionals to detect locomotor abnormalities and functional disability relating to gait, arms, legs and the spine

Locomotors Examination

- G gait
- A arms
- L legs
- S spine

- 
- To describe a rapid screening examination of the musculoskeletal system - termed the 'GALS' screen
 - To overview how abnormal joints are assessed during the physical examination

GALS Screen – Gait, Arms, Legs, Spine

- The GALS screen aims to find out the following:
 - Are any of the joints abnormal?
 - What is the nature of the joint abnormality?
 - What is the extent (distribution) of the joint involvement?
 - Are any other features of diagnostic importance present?

The key questions

- Have you any pain or stiffness in your muscles, joints or back?
- Can you dress yourself completely without any difficulty? (dressing involves all joints)
- Can you walk up and down stairs without any difficulty? (assesses muscle wasting)

Gait

- *observe* patient walking, turning and walking back
- *look for*:
 - smoothness and symmetry of leg, pelvis and arm movements
 - normal stride length
 - ability to turn quickly
- NB: Parkinsonian patients have poor arm swing and cannot turn quickly

Arms

- Ask patient to stand in the anatomical position
- Check normal girdle muscle bulk and symmetry
- Check that elbows are straight and in full extension
- Attempt to place both hands behind the head, then push elbows back (look for glen humeral joint disease)
- Examine hands palms down, with fingers straight
- Observe normal supination and pronation (check for musculoskeletal dysfunction)
- Observe normal grip (reduced grip → arthritis)
- Place tip of each finger on to the tip of the thumb to assess normal dexterity and precision grip
- Squeeze across 2nd to 5th metacarpal (metacarpal 'squeeze' test) - discomfort suggests sinusitis

Legs

- Observe any knee or foot deformity
- Assess flexion of hip and knee, whilst supporting the knee
- Passively internally rotate each hip, in flexion
- Examine each knee for presence of fluid using 'bulge' sign and 'patella tap' sign
- Squeeze across the metatarsals to detect any synovitis
- Inspect soles of the feet for rashes and/or callosities (common in rheumatoid arthritis)

Spine

- Check par spinal and shoulder girdle muscle bulk and symmetry
- Look at straightness of spine (look for scoliosis)
- Check levels of iliac crest (look for hip pathology)
- Look for abnormal glutei muscle bulk (look for hip pathology)
- Check for political swellings (behind the knee)
- Check Achilles tendons (look for ethsopathy)
- Press over mid-point of each supraspinatus and squeeze skinfold over trapezius - tenderness suggests fibromyalgia.
- Note normal spine curvatures when standing, then ask patient to bend forward and assess lumbar and hip flexion – a straight spine and loss of lumbar flexion suggests enclosing spondylitis
- Try to place ear on the shoulder each side - tests lateral cervical flexion.

Joint Abnormality

Active Inflammation

- *Detailed* examination of abnormal joints:
- Inspection
 - Swelling, redness, deformity
- palpation
 - Warmth, crepitus, tenderness
- movement
 - Active, passive, against resistance
- Function
 - loss of function

Inflammation of joints

- **Arthritis** refers to definite **inflammation** of a joint(s) i.e. swelling, tenderness,
- warmth and loss of function of affected joints.
- **Arthralgia** refers to **pain** within a joint(s) without demonstrable inflammation by physical examination. Commonly occurs with SLE complaining of pain.
- The main signs of active inflammation include: *swelling, warmth, erythema, tenderness*, and *loss of function* of the joint.
-
- Site of swelling
- Tissue involved
- Indicative of...
- articular soft tissue
- joint synovium or effusion
- inflammatory joint disease

Inflammation of joints

- periarticular soft tissue
- subcutaneous tissue
- inflammatory joint disease
- non-articular synovial
- bursa/tendon sheath
- inflammation of structure
- bony areas
- articular ends of bone
- Osteoarthritis
- **Enthesopathy**: pathology or lesions of enthesis (the site where ligament or tendon inserts into bone) Examples include: *plantar fasciitis, Achilles tendonitis*.
- **Irreversible Joint Damage**

Joint deformity

- malalignment of two articulating bones
- Crepitus
 - audible and palpable sensation resulting from movement of one roughened surface on another
 - classic feature of osteoarthritis e.g. patellofemoral crepitus on flexing the knee
- Loss of joint range or abnormal movement
-
- **Dislocation:** articulating surfaces are displaced and no longer in contact
- **Subluxation:** partial dislocation
- **Valgus:** lower limb deformity whereby distal part is directed away from the midline e.g. hallux valgus

Joint deformity

- **Varus:** lower limb deformity whereby distal part is directed towards the midline e.g. varus knee with medial compartment OA
- These may be consequence of inflammation, degenerative arthritis or trauma:
- Identified by
- Painful restriction of motion in absence of features of inflammation
 - e.g. knee 'locking' due to meniscal tear or bone fragment
- Instability associated with abnormal movement or abnormal range of movement
 - e.g. side-to-side movement of tibia on femur due to ruptured collateral knee ligaments
-
- A spinal abnormality such as ankylosing spondylitis is a loss of the lordosis of cervical spine and lumbar spine. This pushes the head forwards, and means that a patient with this condition will be unable to look up.

Distribution of Joint Involvement

- Determine number of joints involved:
 - **polyarthritis** > 4 joints involved
 - **oligoarthritis** 2-4 joints involved
 - **monoarthritis** single affected joint
- Note if involvement is symmetrical

- Note the size of the involved joints
- Is there axial involvement?
-
- *Bilateral* and *symmetrical* involvement of *large* and *small* joints is typical of rheumatoid arthritis
- Lower limb *asymmetrical* oligoarthritis and *axial* involvement would be typical of reactive arthritis
- Exclusive inflammation of the distal interphalangeal joints of the fingers is highly suggestive of psoriatic arthritis

- The distribution of the polyarthritis is helpful in the differential diagnosis:
- Disease
- Joints involved
- Joints spared
- Rheumatoid arthritis
- PIP, MCP, wrist, elbow, shoulder, cervical spine, hip, knee, ankle, tarsal, MTP
- DIP, thoracic spine
- lumbar spine
- Osteoarthritis
- 1st CMC, DIP, PIP, cervical spine, thoracolumbar spine, hip, knee, 1st MTP, toe IP
- MCP, wrist, elbow, shoulder, ankle, tarsal joints
- Polyarticular gout
- 1st MTP, ankle, knee
- Axial

- Other Diagnostically Important Features
- Rheumatoid nodules: collection of normal cells including lymphocytes, and fibroblasts that surround a center of fibrinoid necrosis
- Tophi: deposit of crystallised monosodium urate in people with longstanding hyperuricemia
- Psoriasis: the characteristic skin condition may be present on various areas of the skin – commonly the elbows. In Psoriasis, patients commonly have nail “pitting” and also onycholysis – separation or loosening of part or all of a nail from its bed.
- Malar rash: red/purple scaly rash.

▪ **NEUROLOGICAL EXAMINATION**

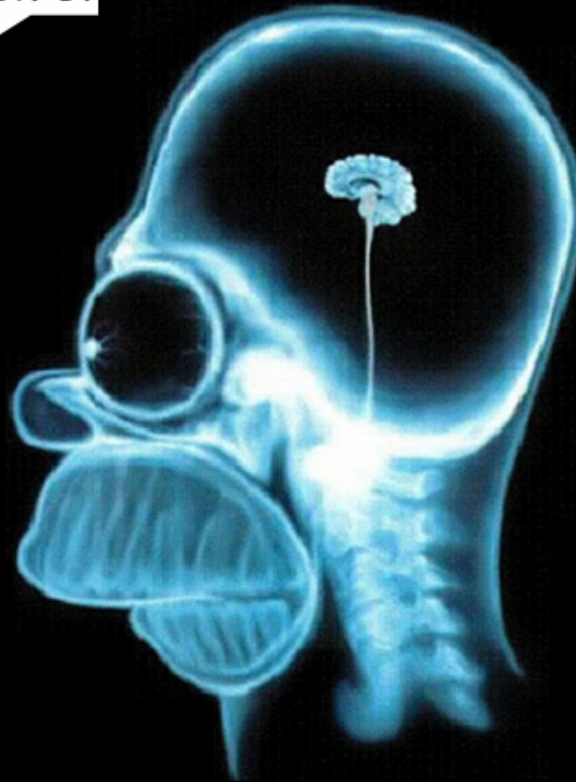
▪ **HOW TO READ A CHEST X-RAY**

▪ **CSF EXAMINATION (LP)**

▪ **CHEST DRAINS**

& More!

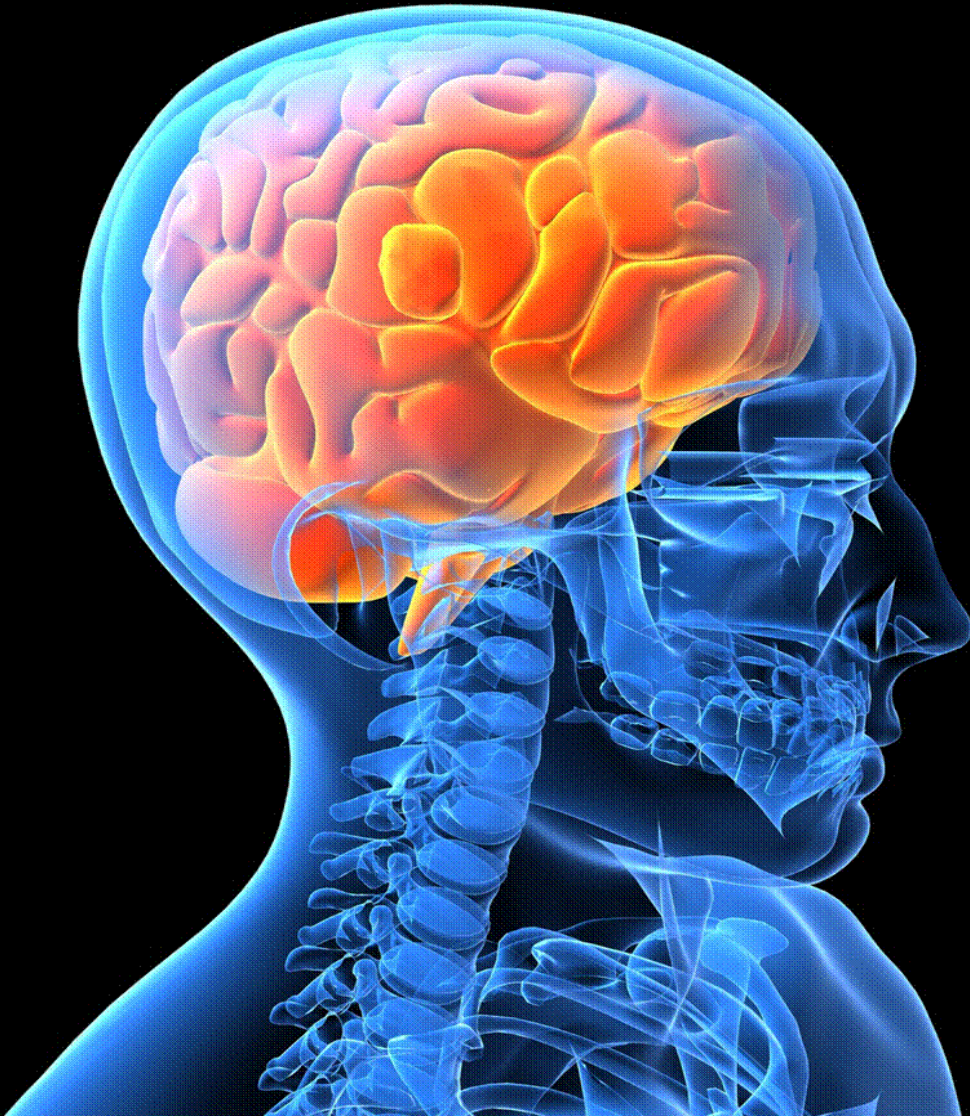**Clinical
Session 5!**



TUES 1830 - 1945



NEUROLOGICAL EXAMINATION



SHAN KESHRI
CLINICAL SESSIONS



MASARYK UNIVERSITY
FACULTY OF MEDICINE

HISTORY

- Presenting symptoms:
 - Headache
 - Weakness
 - Visual disturbance
 - Special senses (hearing, smell, taste etc)
 - Dizziness
 - Speech disturbance
 - Dysphasia
 - Fits, faints, involuntary movements
 - Tremor
 - Skin sensation disturbance (sensory loss)

HISTORY

- Cognitive State
 - Mini Mental State Exam
- Past Medical history
 - Meningitis, encephalitis, trauma, seizures
- Drug History
 - Anticonvulsant, antipsychotic, antidepressant, drugs with SE
- Social & Family History
 - Barthel Index Score

Wash hands

UPPER LIMB EXAMINATION

- **General Inspection**

- Posture, asymmetry, abnormal movements (fasciculation's, tremor), muscle wasting

UPPER LIMB EXAMINATION

- **Tone:**
 - Ask patient to relax
 - Passively **flex and extend limb**, & also **pronate and supinate**
 - Look for **SPASTICITY / RIDGIDITY**

UPPER LIMB EXAMINATION

- **Power:**

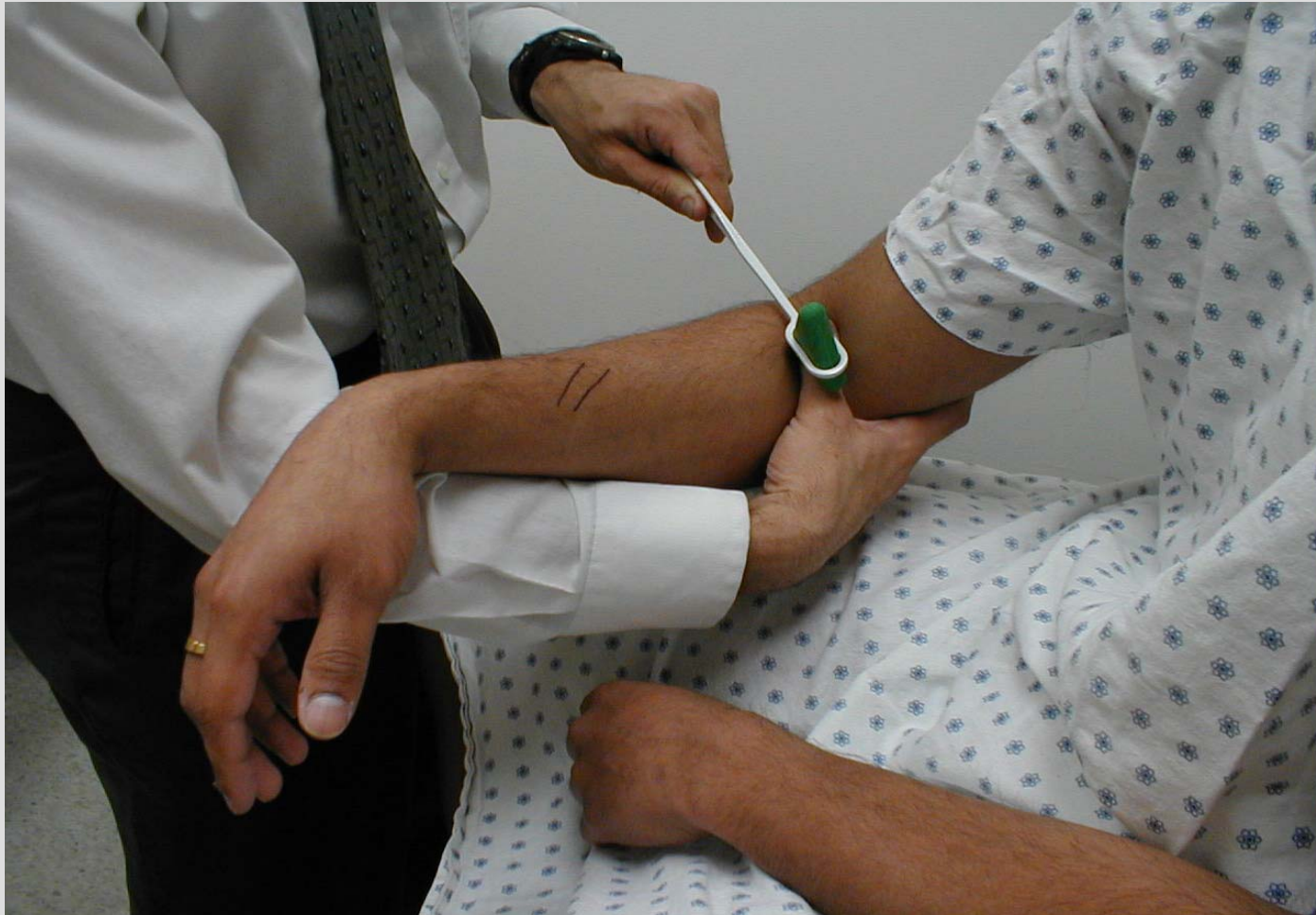- Resist movements as appropriate to grade power.
- Test each muscle group **bilaterally**.
 - Shoulder:
 - **“Shrug shoulders, don’t let me push down”**
 - **“Push arms out the side against me, try to pull them back in”**
 - Elbow:
 - **“Hold forearms up, and pull me towards you”**
 - Finger extension:
 - **“Hold your hand out, don’t let me push it down”**
 - **“Now don’t let me push it up”**
- Offer **two fingers** and ask patient to **squeeze**
- Ask to **spread fingers** and **resist you pushing them back**
- .

UPPER LIMB EXAMINATION

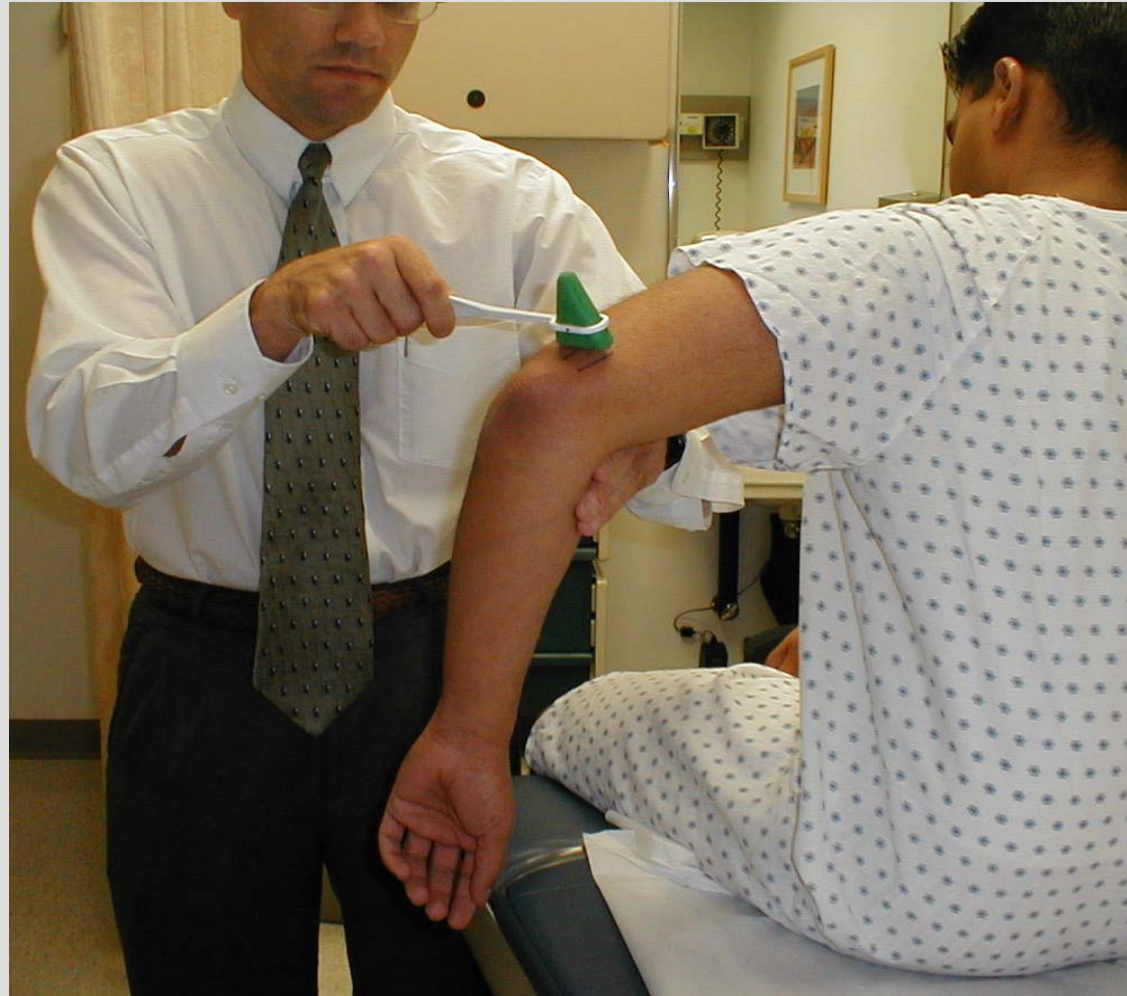- **Tendon Reflexes:**
 - Compare **left and right**
 - **Distract** patient e.g ask them to clasp hands tight
 - Assess reflex as **NORMAL, ABSENT, BRISK, EXAGGERATED**

 - Biceps: C5, C6
 - Triceps: C7
 - Supinator: C6

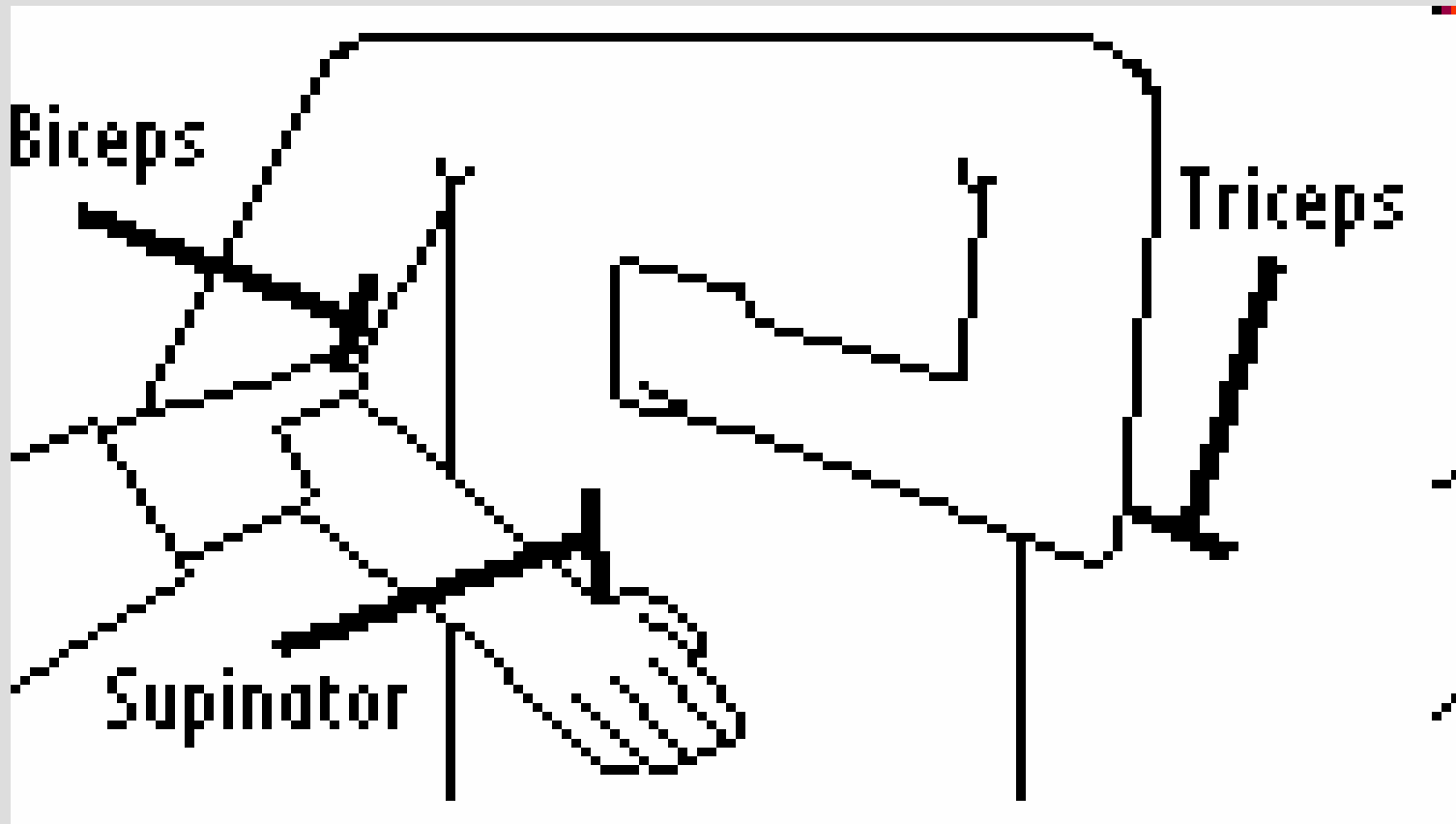
Biceps Reflex (C5,6)



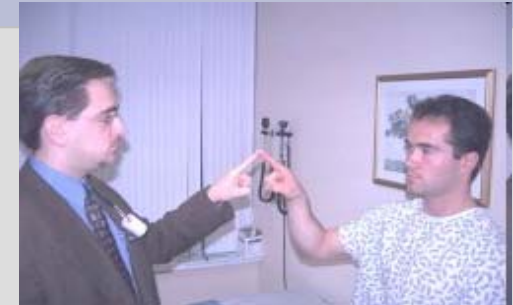Triceps Reflex (C7)



Supinator Reflex (C6)



UPPER LIMB EXAMINATION

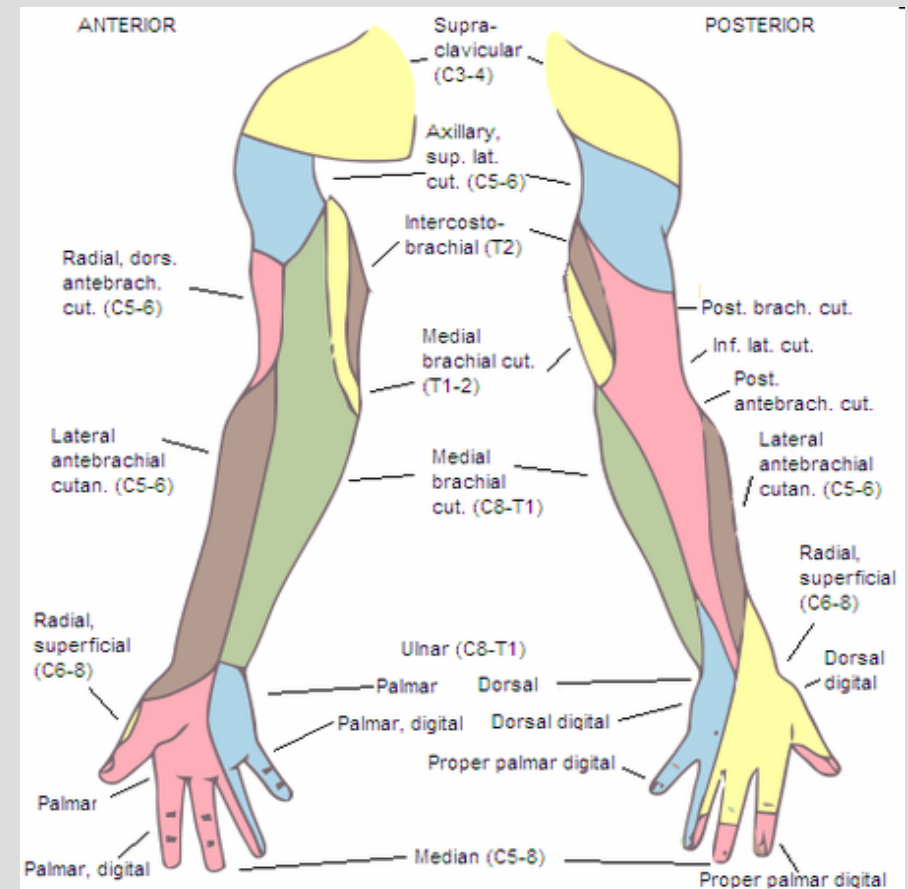


- **Co-ordination:**

- Finger Nose Test:
 - **“Touch my finger, and then your nose as fast as you can”**
 - Look for tremor or past pointing, or missing the targets
- Test for dysdiadokokinesia:
 - (failure to perform rapidly alternating movements)
 - Ask patient to repeatedly pronate and supinate hands together
- Test for pronator drift:
 - Patients eyes closed, arms outstretched palm up.
 - Tap down on palm and look for failure to maintain supination
 - .

UPPER LIMB EXAMINATION

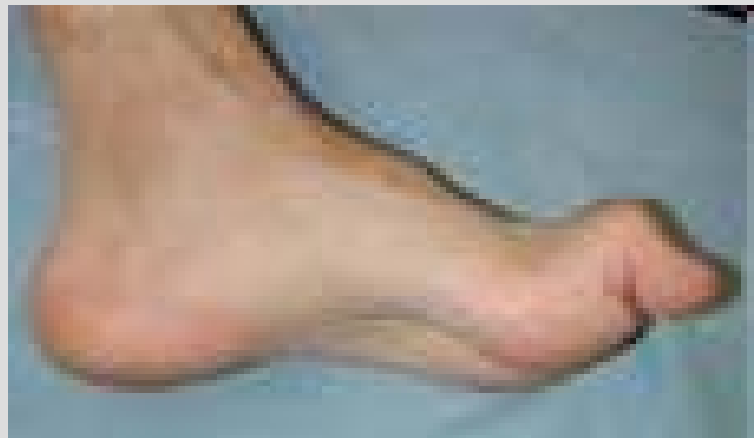- **Sensation:**
 - Light touch
 - Cotton wool- check dermatomes
 - Pin Prick
 - Temperature
 - Hot & cold probes



LOWER LIMB EXAMINATION

- **General Inspection**

- Posture, asymmetry, abnormal movements (fasciculation's, tremor), muscle wasting
- Deformities, Pes cavus (champagne bottle below)



LOWER LIMB EXAMINATION

- **Tone:**

- Ask patient to relax
- Passively **flex and extend at knees and hips and ankles, & also internally and externally rotate**
- Hold one hand on knee and rotate it
- Hold hand on back of knee and raise it quickly
 - Heel should lift slightly
- Test for clonus (involuntary contractions)
 - Plantar flex foot, the quickly dorsiflex.
 - .



LOWER LIMB EXAMINATION

- **Power:**

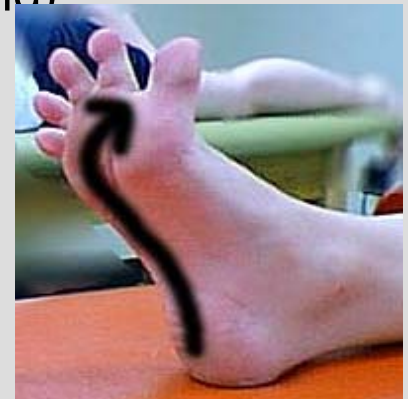- Resist movements as appropriate to grade power.
- Test each muscle group **bilaterally**.
 - Hip:
 - “Keeping your leg straight, can you lift your leg off the bed – don’t let me push it down”
 - “Using your leg, push my hand into the bed”
 - “With my hands on outer thighs, push legs out to sides”
 - “With my hands on inner thighs, push legs together”
 - Knee:
 - “Bend knee and bring you heel to your bottom – don’t let me pull it away”
 - “Now kick out against me”
 - Ankle:
 - “Bend foot down, pushing my hand down”
 - “Cock up your foot, point toes to ceiling, pushing my hand up”

LOWER LIMB EXAMINATION

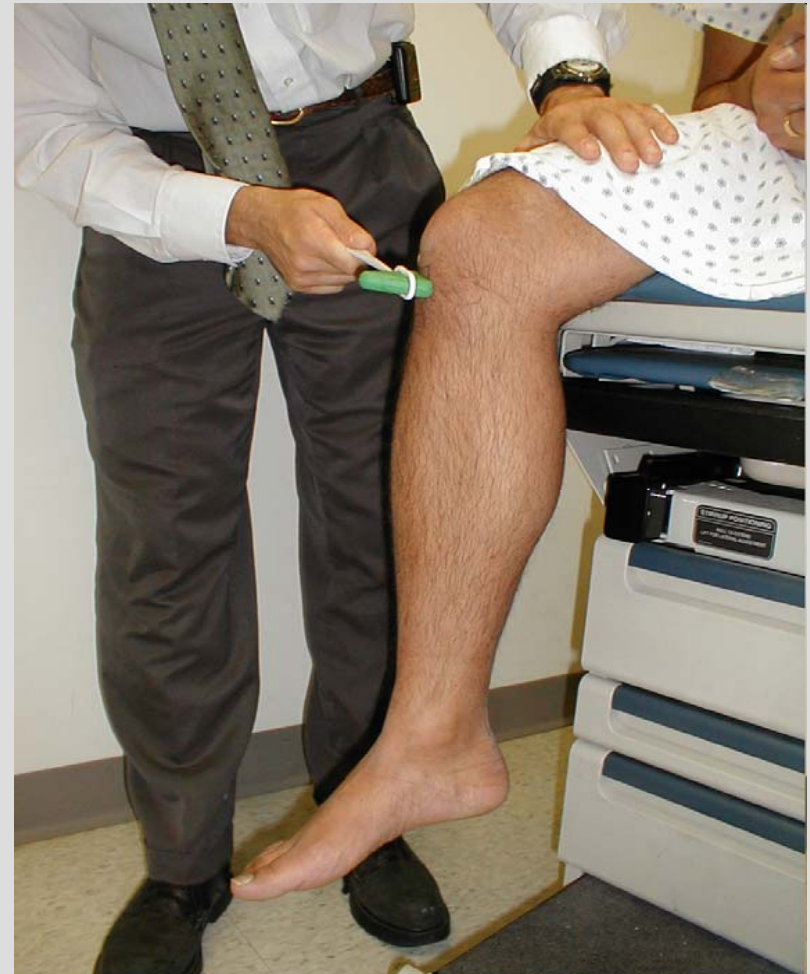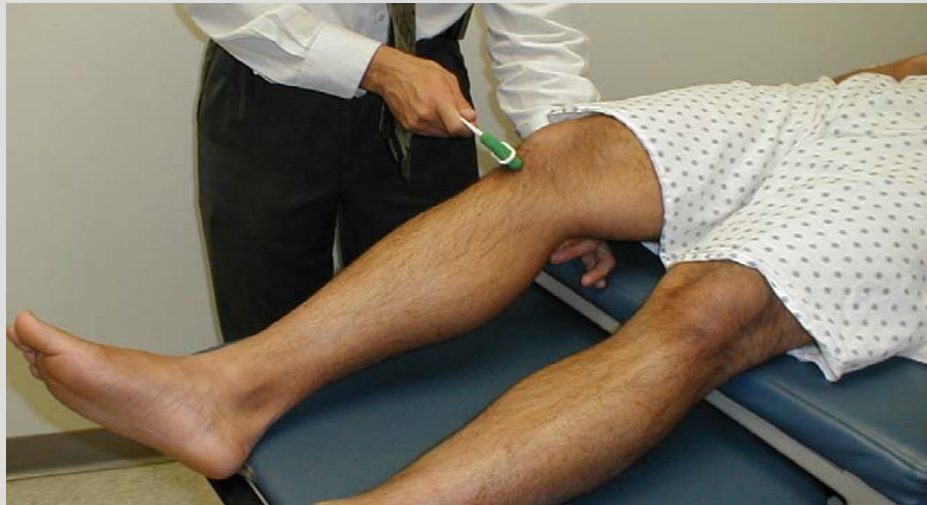- **Tendon Reflexes:**

- Compare **left and right**
- **Distract** patient e.g ask them to clasp hands tight, clench teeth
- Assess reflex as **NORMAL, ABSENT, BRISK, EXAGGERATED**

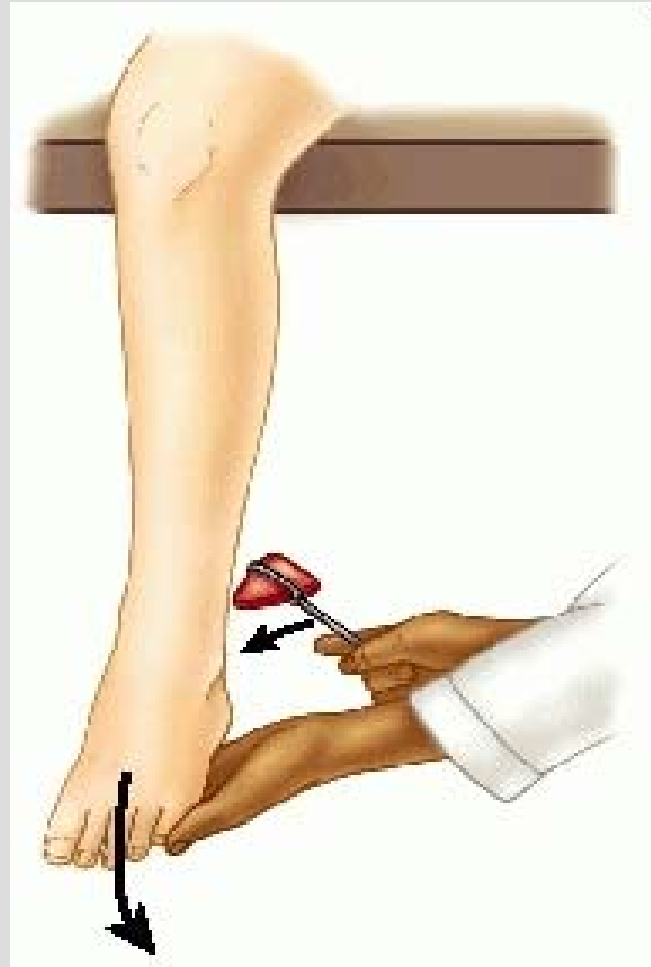- Knee: L3,4
- Ankle: L5, S1
- Extensor Plantar : L5, S1, S2
 - Stroke sole of foot
 - Positive Babinski : Dorsiflexion of great toe (Fanning)
 - Abnormal over rage of 6m (UMN Lesion)
 - .



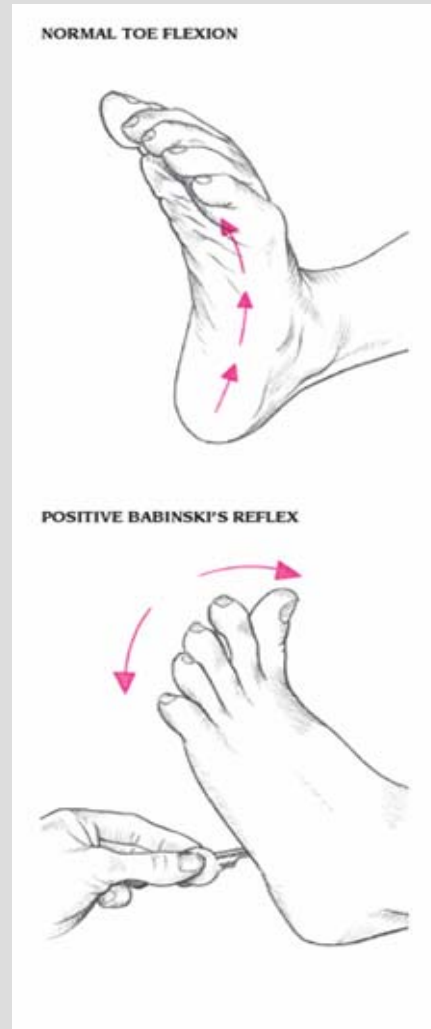Patellar Knee Reflex (L3,4)



Ankle Reflex (L5, S1)



Extensor Plantar Reflex (L5, S1, S2)



LOWER LIMB EXAMINATION

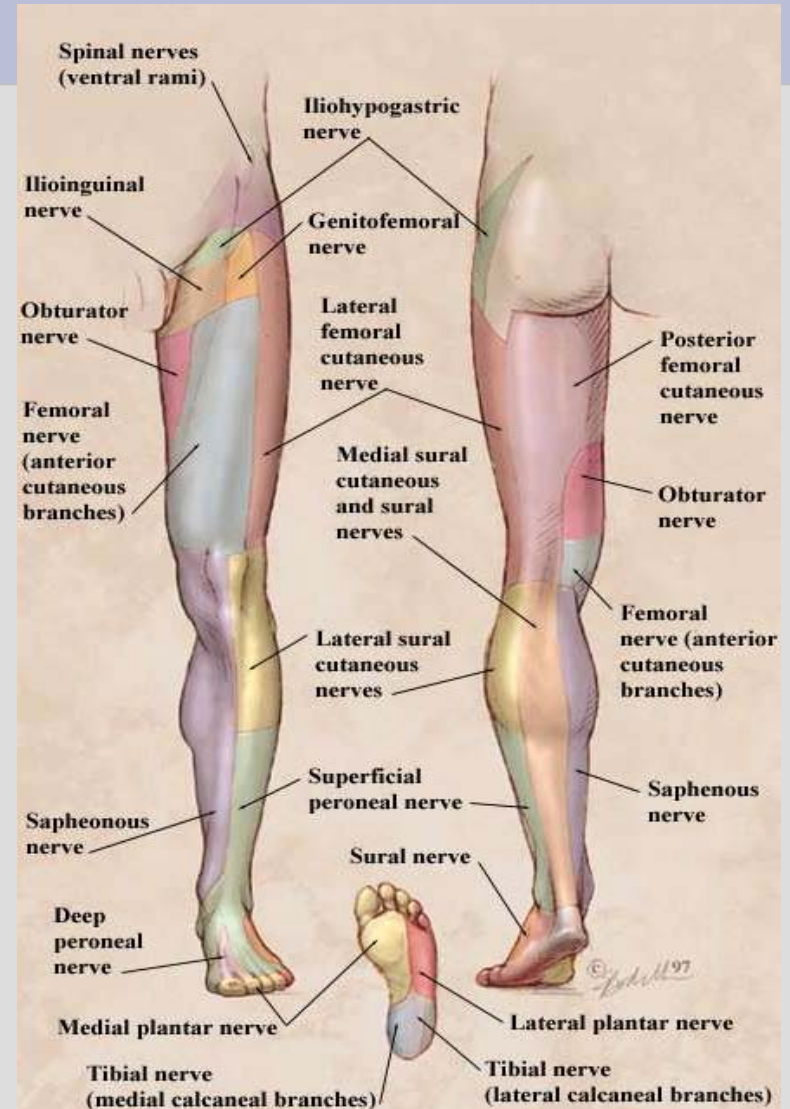
- **Co-ordination:**
 - Heel to Shin test
 - Put heel to shin and run heel up and down
 - Both sides



LOWER LIMB EXAMINATION

- **Sensation:**

- Light touch
 - Cotton wool- check dermatomes
- Pin Prick
- Temperature
 - Hot & cold probes

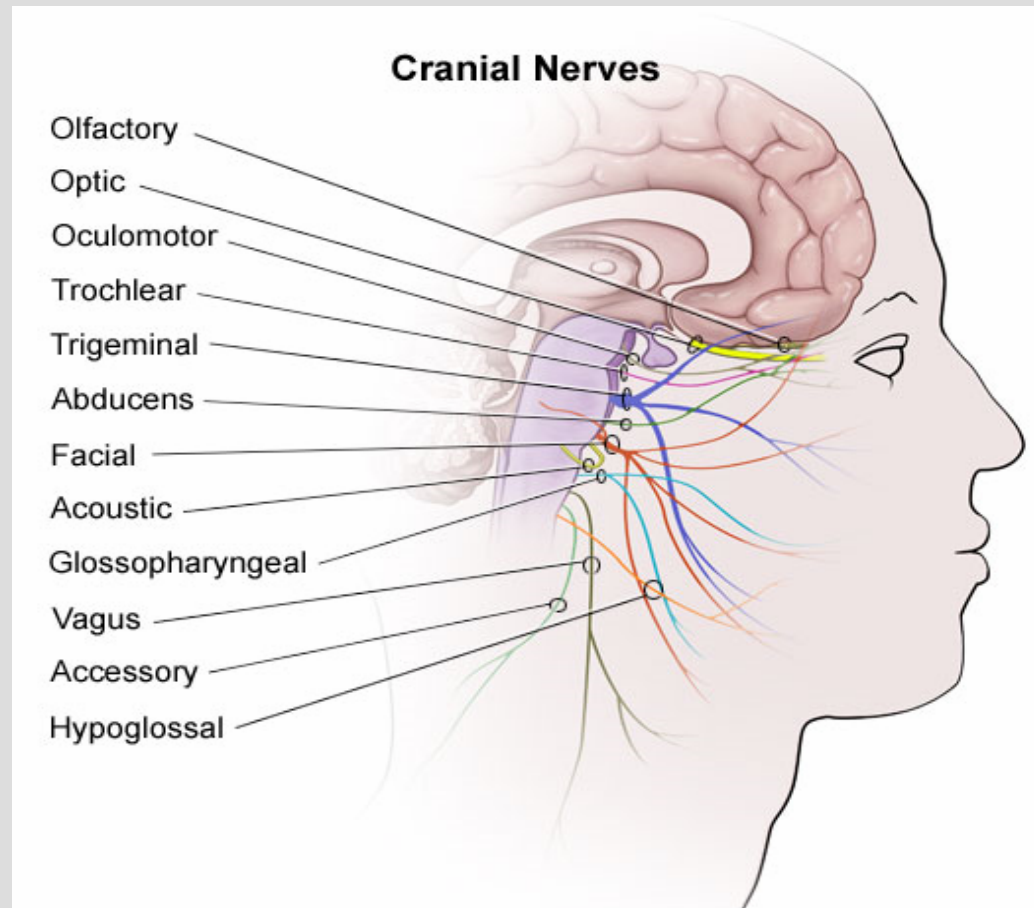


LOWER LIMB EXAMINATION

- **Gait:**

- Ask patient to walk a few metres, turn and walk back
 - Note use of walking aids, symmetry, size of pace, arm swing
- Ask patient to walk heel to toe (tightrope style)
 - This exaggerates instabilities
- Ask patient to walk on tiptoes (S1 lesion), then on heels (L4,5 lesion / foot drop)
- **ROMBERGS TEST:**
 - Ask patient to stand unaided, arms by sides, then close eyes.
 - Sway/loss of balance is positive
 - posterior column disease / sensory ataxia

CRANIAL NERVE EXAMINATION



CN I: Olfactory

- One nostril at a time
- Put non-irritating stimulus near nostril
 - Peppermint, lavender, coffee
- Detection of smell is more important than identification

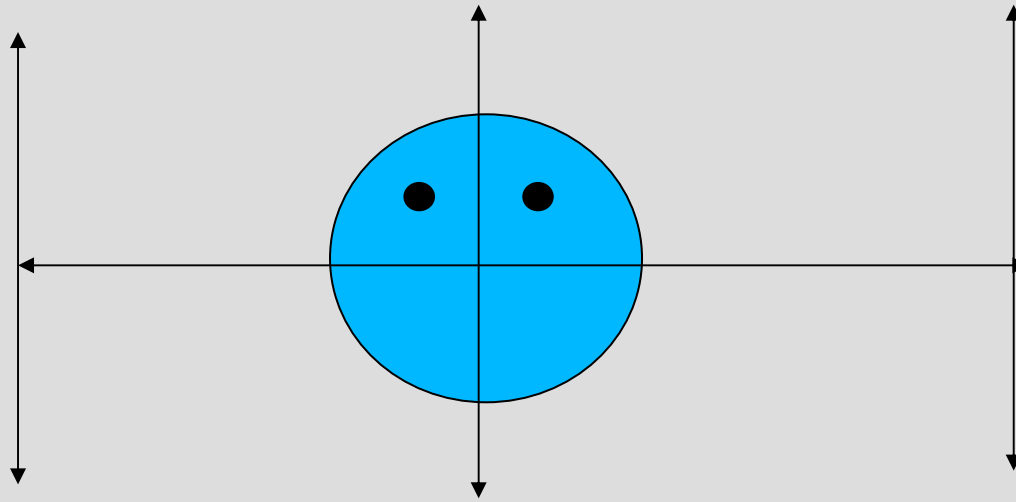
CN II: Optic

- One eye at a time, Cover the other
- Visual Acuity
 - Snellen Chart / pictogram

CN II: Optic

- Visual fields:
 - Central
 - Face to face
 - Tell patient stare at your nose
 - Wiggle finger left and right, up and down
 - Ask patient as you move can they see it
 - Compare your field with patients
 - Peripheral
 - Face to face
 - Tell patient to cover one eye
 - You cover same side eye
 - <http://www.youtube.com/watch?v=mtdBGOvj-No>

CN III, IV, V



Nystagmus?

CN V

- **Sensory**

- Cotton bud – close eyes, ask patient say where is the touch felt
- Forehead (ophthalmic), cheek (maxillary), chin (mandibular)

- **Motor**

- Open mouth against resistance

CN VII

- Raise eyebrows, smile, puff cheeks
- Muscles of facial expression!

CN VIII

- Eyes closed
- Rub fingers near ear
- Say which side!

- Webers, rhines test – tuning fork

CN IX

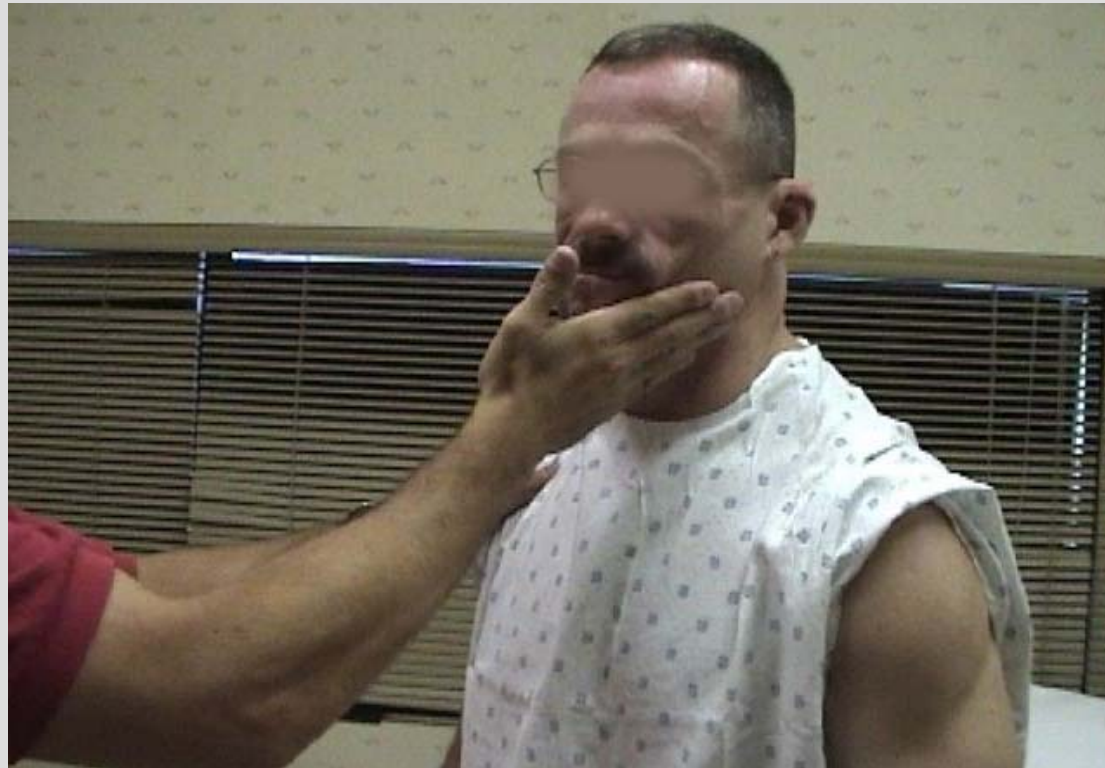- **Gag reflex**
 - Touch back of palate with spatula
 - Wretch

CN X

- Say “ahhhhhh” with mouth open and look with torch
 - Palate and uvula rise
- Cough
- Gag reflex


CN XI

- Turn head against resistance
- Shrug shoulders against resistance



CN XII

- Tongue protrusion (deviates to side of lesion?)



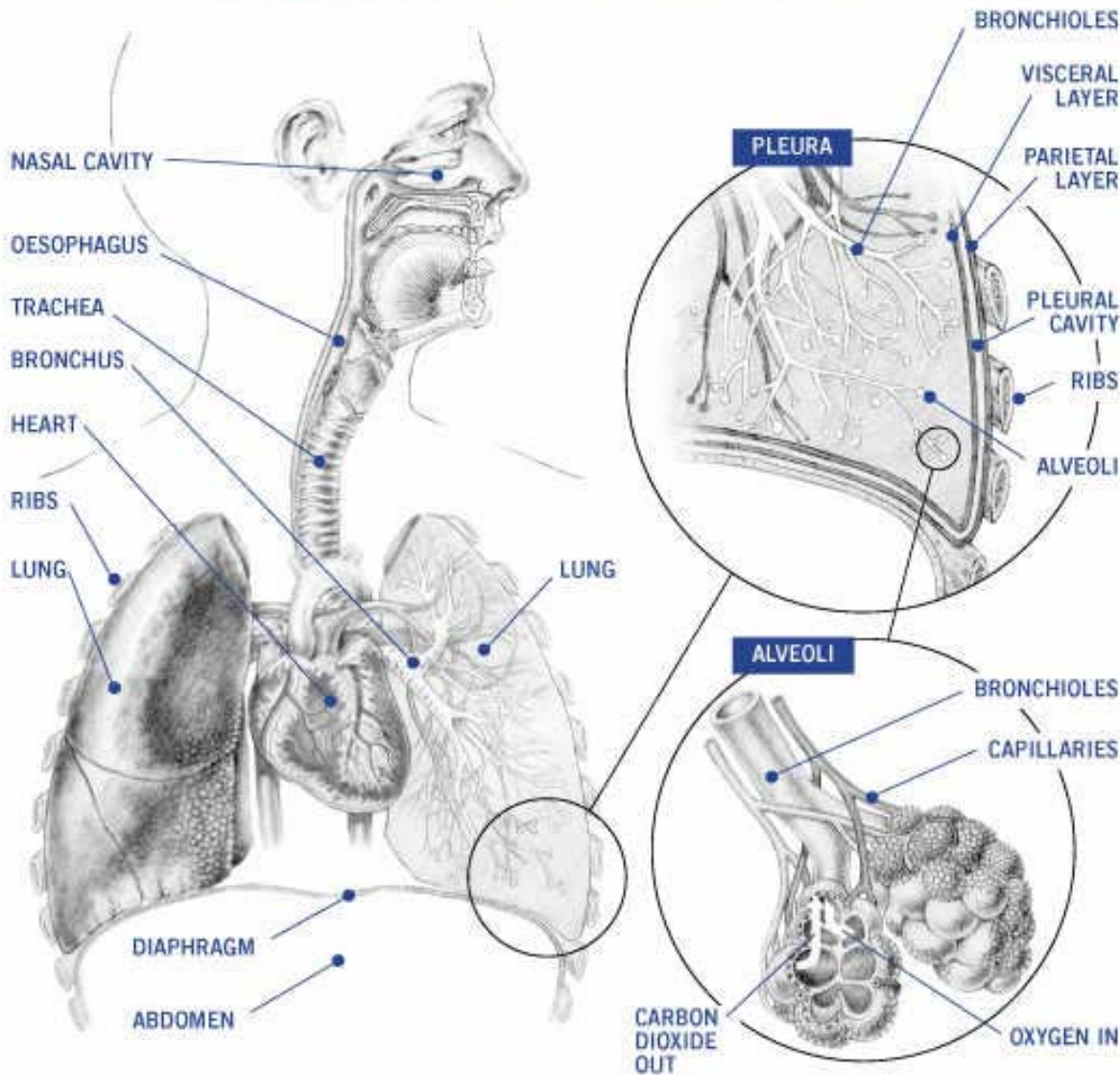
FURTHER READING

- Mingazinni
- Barres reflex
- Speech & higher mental function – aphasia (Broca, wernickes)
- UMN signs
- LMN signs
- Pyramidal signs
- Lassegues sign (and reverse)

Chest Drains

Anatomy review

THE LUNGS



How to remember the order at the hilum:

Right Lung:

Bronchiole

Artery

Vein

Left Lung:

Artery

Bronchiole

Vein

INDICATIONS

- Pneumothorax
- Pleural effusion (accumulation of fluid in the pleural space):
 - Malignant
 - Complicated parapneumonic
 - Traumatic haemopneumothorax
 - Chylothorax: a collection of lymphatic fluid in the pleural space
 - Empyema: a pyogenic infection of the pleural space
 - Hemothorax: accumulation of blood in the pleural space
 - Hydrothorax: accumulation of serous fluid in the pleural space
- Postoperative—Prevention of hydrothorax after cardiothoracic surgery

Pneumothorax

Definition:

- presence of air within the pleural space

Classification:

- Spontaneous (not caused by trauma)
- Traumatic
- Iatrogenic

Depending on the size:

- Small
- Large

presence of a visible rim of <2 cm or >2cm
between the lung margin and the chest wall

Spontaneous (not caused by trauma)

- **Primary (PSP)** - occurring in persons without clinically or radiologically apparent lung disease
 - Due subpleural bullae
 - Familial (genetics)
 - Cigarette smoking increases the risk of PSP

Clinical Signs:

- 90% of PSP occur while the patient is at **rest**
- Main symptoms are **chest pain** or **dyspnoea** either alone or in combination. Chest pain is more prominent and can be alone in 69%
- Symptoms usually resolve within 24 hours, even if the pneumothorax remains untreated and does not resolve

Spontaneous (not caused by trauma)

- **Secondary (SSP)**- in which lung disease is present and apparent
 - Diseases of the airways: COPD, cystic fibrosis, and status asthmaticus
 - Interstitial lung diseases: Langerhans cell histiocytosis, sarcoidosis, lymphangiomyomatosis, tuberous sclerosis, rheumatoid disease, idiopathic pulmonary fibrosis, and radiation fibrosis
 - Infectious diseases: Necrotizing gram-negative pneumonia, anaerobic pneumonia, staphylococcal pneumonia, AIDS with *P jiroveci* pneumonia, and *Mycobacterium tuberculosis*
 - Malignancies: Sarcoma, lung cancer
 - Pneumoconiosis: Silicoproteinosis, berylliosis, and bauxite pneumoconiosis

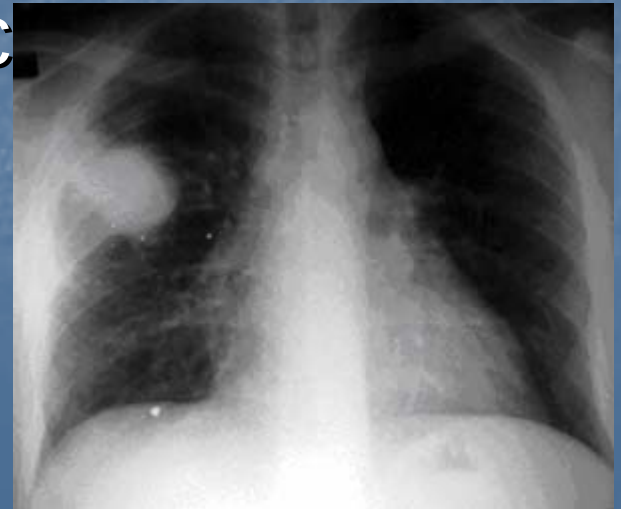Clinical Signs:

- Occurs during **acute exacerbation**. Should be suspected if the patient fails to respond to current treatment.
- **Dyspnoea** is more prominent than PSP
- **Chest pain** is less common but more severe than in PSP
- Symptoms of SSP don't resolve spontaneously

Traumatic

- Direct communication of the pleural space with the atmosphere → **penetrating injury**
- Disruption of the proximal tracheobronchial tree or viscera → **blunt chest trauma**

PA chest film demonstrates a right upper lobe mass abutting the pleural surface with associated metallic bullet fragments.



Pneumothorax: Signs

- Maybe minimal in small pneumothorax or in SSP.
- Decreased movement of the chest wall
- Hyperresonant percussion note with diminished tactile focal fremitus (palpable vibration) and resonance
- Decreased or absent breath sounds on the affected side.
- Haemodynamic instability (tachycardia, hypotension, and cyanosis) suggests tension pneumothorax.

Pneumothorax: Radiology

CT scan (which is very sensitive) should be obtained if a pneumothorax is suspected in case of :

- CXR of patient in a supine position and does not demonstrate a pneumothorax

OR

- It can not be differentiated from bullous disease

CONTRA-INDICATIONS

- Coagulopathy
- Small, stable pneumothorax (may spontaneously resolve)
- Empyema (collection of pus) caused by acid-fast organisms
- Fluid accumulation in small cavities (loculated fluid accum.)

COMPLICATIONS

Minor complications:

- subcutaneous hematoma or seroma
- anxiety
- shortness of breath (dyspnoea)
- cough (after removing large volume of fluid)

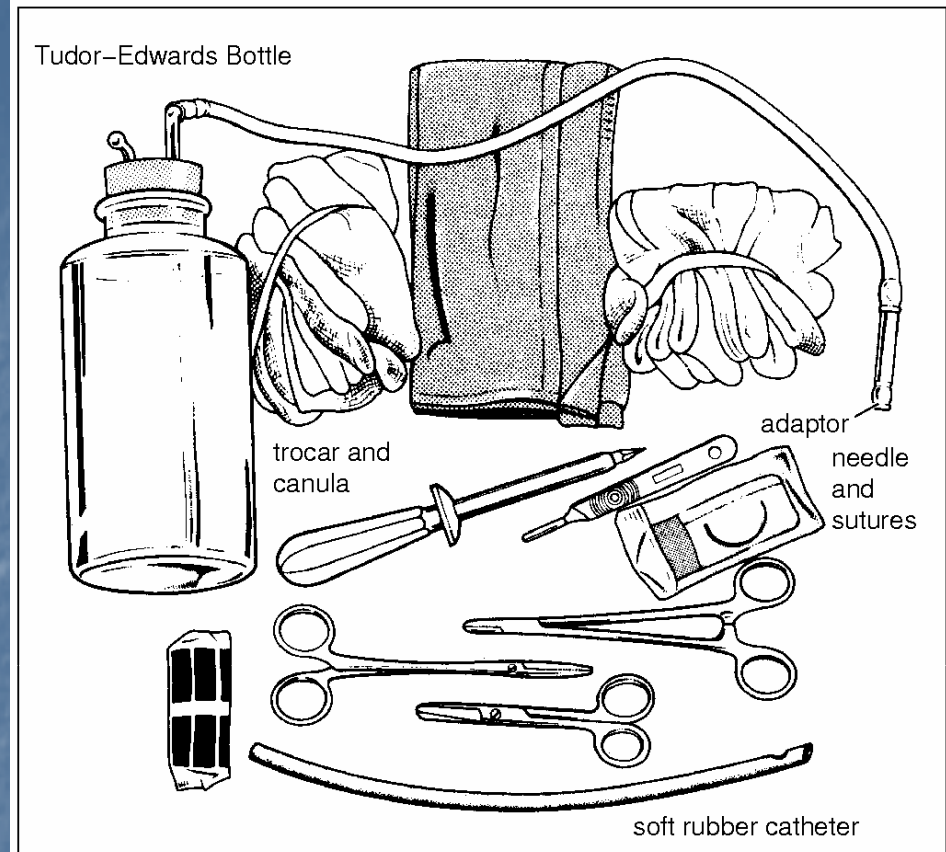
Others:

- Haemorrhage
- Infection
- Re-expansion pulmonary oedema.
- Chest tube clogging
- Injury to the liver, spleen or diaphragm is possible if the tube is placed inferior to the pleural cavity.
- Injuries to the thoracic aorta and heart

EQUIPMENT

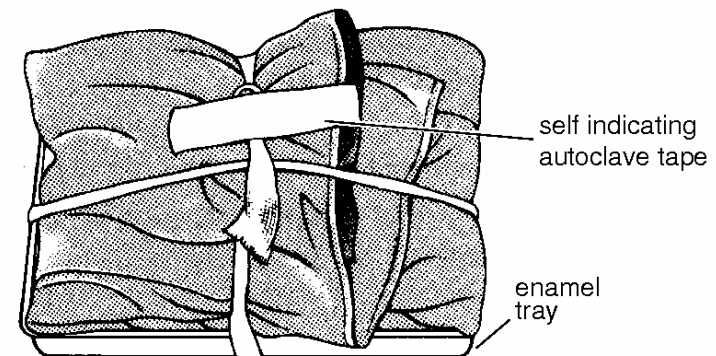
- ✓ Drapes
- ✓ An assistant
- ✓ Sterile gloves
- ✓ Suture kit
- ✓ Dressing pack
- ✓ Gauze pads
- ✓ Scalpel
- ✓ 1% or 2% lidocaine
- ✓ 2/0 silk suture on curved needle
- ✓ 10-ml syringe
- ✓ 21-gauge (green) needles
- ✓ 27-gauge (orange) needles
- ✓ Cleaning agent (e.g., iodine or chlorhexidine)
- ✓ Chest drain
- ✓ Chest drain bag (for pleural effusion) or water-tight bottle containing some normal saline or sterile water (for pneumothorax)

A CHEST SET



PACKED, AUTOCLAVED
AND INSTANTLY READY

This is essential
equipment in any
hospital



TECHNIQUE – in short

- Is drain really necessary?
- Consent patient
- Decide what size drain is needed
- Review imaging
- Make sure the tray has everything you need
- Sterile technique
- Have an assistant
- Chest x-ray after insertion

TECHNIQUE - detailed

- Make sure it is the correct patient and then tell them what you are going to do.
- Wash your hands and put drapes on.
- Confirm the position of the pneumothorax/effusion clinically and also with a chest x-ray.
- Sit the patient upright, legs over the side of bed, leaning over a high table so the arms are up, the back is straight, and you have access to the affected side of the chest. In an unwell patient, you might have to perform this with the patient sitting at a 45° angle.
- Prepare the underwater seal – fill a bottle one-third full with sterile water. The end of the tube should be 2–3 cm into the water.

- Choose the chest drain; tailor it to the patient by looking at how much rib space is available. Some chest physicians prefer larger drains, particularly for effusions and empyemas – as a guide, 24F is suitable for a pneumothorax; use 28–32F for effusions and empyemas.
- Put on your gloves and prepare your cart so that all of the items are within easy reach.
- Clean the patient's skin with chlorhexidine or iodine and perform pleural aspiration in the mid-axillary line at the 4th–5th intercostal space; aim above the rib.
- When pleural fluid has been located, insert more local anesthetic: Be generous – use up to 15 ml in the area around the aspiration site. Some patients might find this uncomfortable, so you can give a small dose of diamorphine IV with 10 mg metoclopramide IV.
- Make a 1–2 cm incision with the scalpel in line with the ribs, remaining just above the lower rib. When you are through the skin and into the subcutaneous fat, blunt-dissect down with forceps. Continue until you reach the pleura. This can be painful, so have remaining local anesthetic available and inject into pleura if necessary.

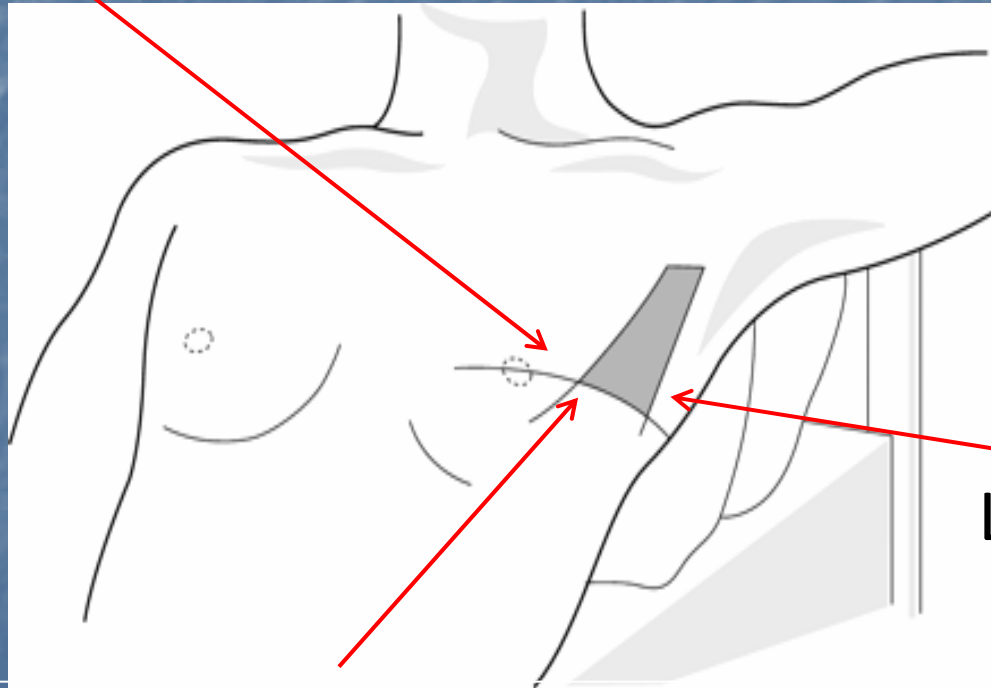
- Take the introducer out of the chest drain, so only the tubing remains. After you have blunt-dissected the pleura and fluid or air begins to escape, insert the drain into the hole. It should enter the pleural cavity easily, but keep a finger over the end of the drain until it is connected to the bag or underwater seal.
- Place a 1-mattress suture on either side of the drain and pull taut. Place another suture in the middle of incision around the drain. Tie the two side sutures, so the skin is pulled tight, then secure around the drain by coiling around several times. Leave the central suture free, to be tied when the drain is removed.
- Place pads of gauze around drain and secure with dressing. Secure the proximal part of the drain to the patient with tape.
- Ensure that the drain is draining/bubbling freely. Get a post-procedure chest x-ray to review the position.
- <http://www.youtube.com/watch?v=tSXQ7GR35E4>
- http://en.wikipedia.org/wiki/Seldinger_technique

SITE OF INSERTION

Pectoralis major

Semi-recumbent - "Safe triangle"

Triangle bordered by the anterior border of the latissimus dorsi, the lateral border of the pectoralis major muscle, a line superior to the horizontal level of the nipple, and an apex below the axilla



Latissimus dorsi

Superior Line to the horizontal level of the nipple

BE CAREFUL AS TO AVOID:

- Internal mammary artery
- Intra-abdominal insertion
- Damage to muscle
- Damage to breast tissue
- Unsightly scarring

REMOVAL

Explain the procedure to the patient

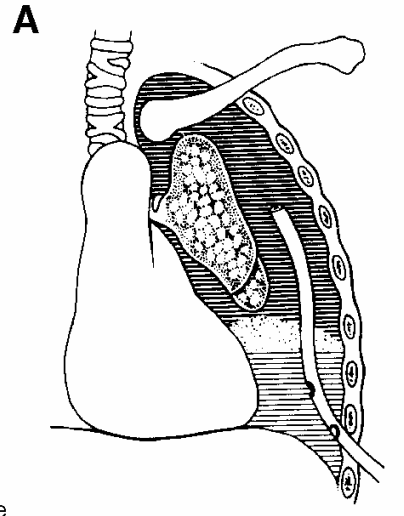
Remove dressing and stay sutures.

Cover the site of tube entry with sterile gauze.

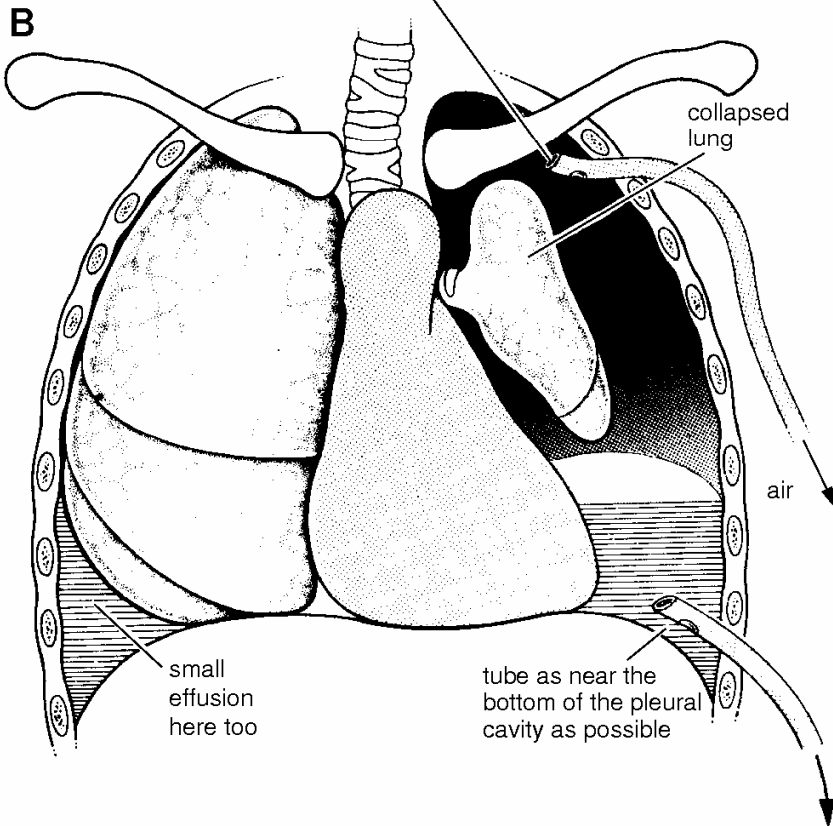
While patient performs Valsalva manoeuvre, remove the drain with a swift action and cover the wound with the gauze. Place a dressing on the gauze.

DRAINING AIR AND FLUID FROM THE CHEST

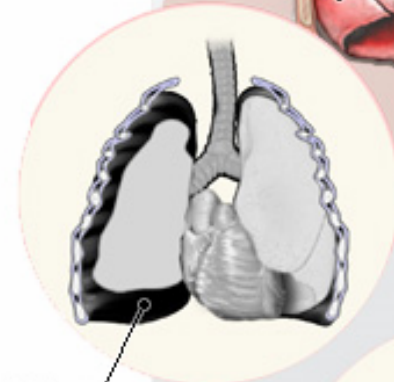
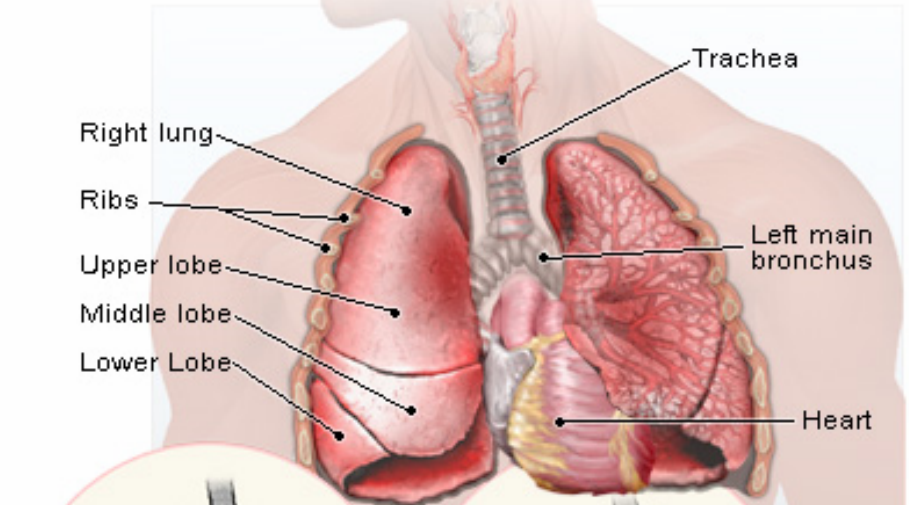
if you use one tube, insert it like this



tube as near the top of the pleural cavity as possible

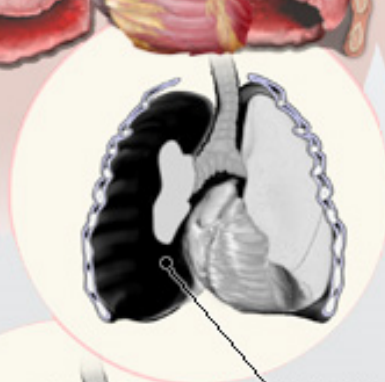

Pneumothorax



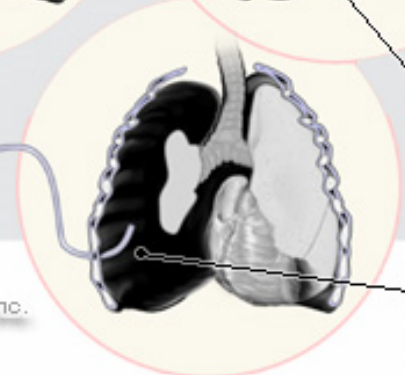Small pneumothorax

Air collects between the lung and the chest wall



Large pneumothorax

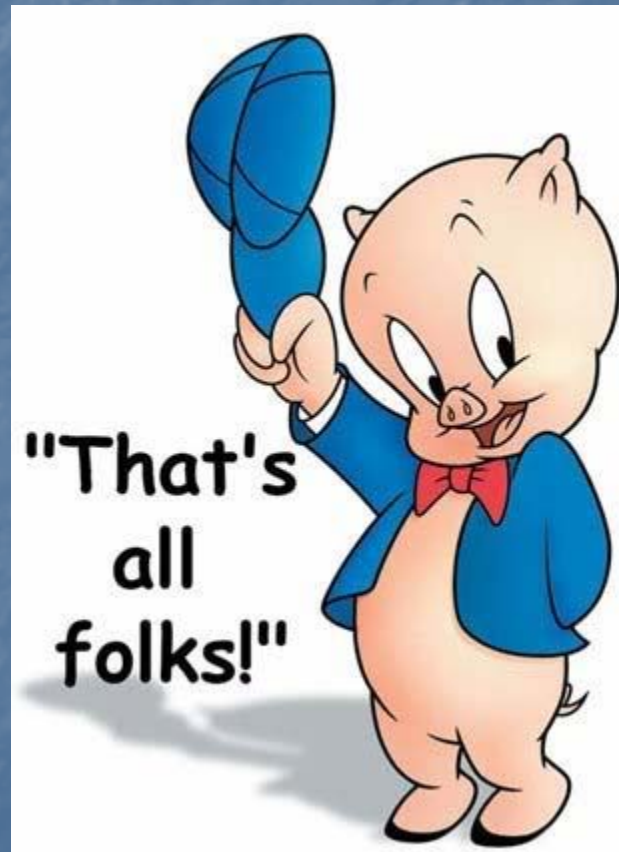A lot of air collects and pushes on the lung and heart



Treatment of a large pneumothorax

Trapped air is removed by using a chest tube

Thank You!


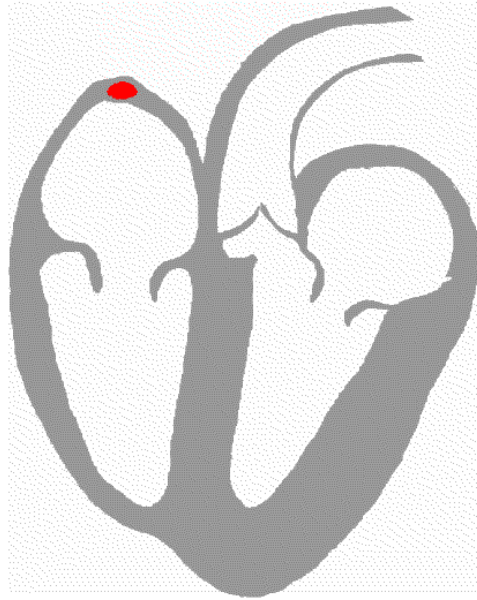


ECG {Electrocardiogram}

by

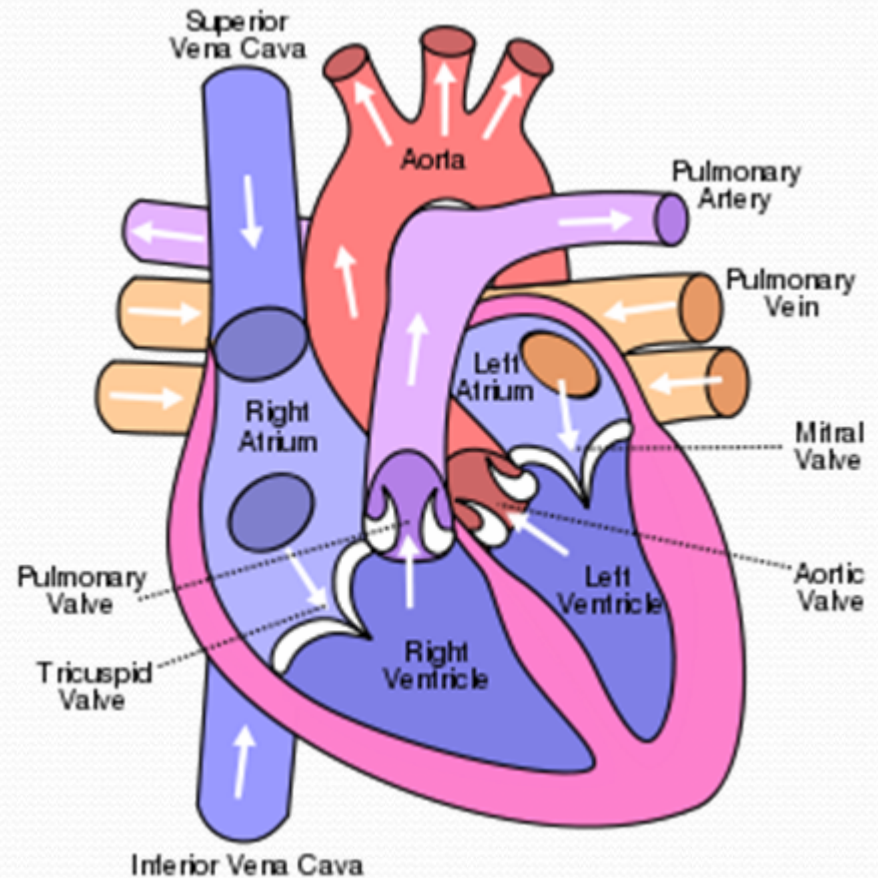
David Utulu

Introduction



The Heart

- The heart consists of four chambers
 - The right atrium and right ventricle: responsible for delivery of deoxygenated blood to lungs
 - The left atrium and left ventricle: responsible for delivery of oxygenated blood to the body



The Heart: Phases

- There are two phases of the cardiac cycle
- Systole: The ventricles are full of blood and begin to contract. The mitral and tricuspid valves close (between atria and ventricles). Blood is ejected through the pulmonary and aortic valves.
- Diastole: Blood flows into the atria and through the open mitral and tricuspid valves into the ventricles.

ECG

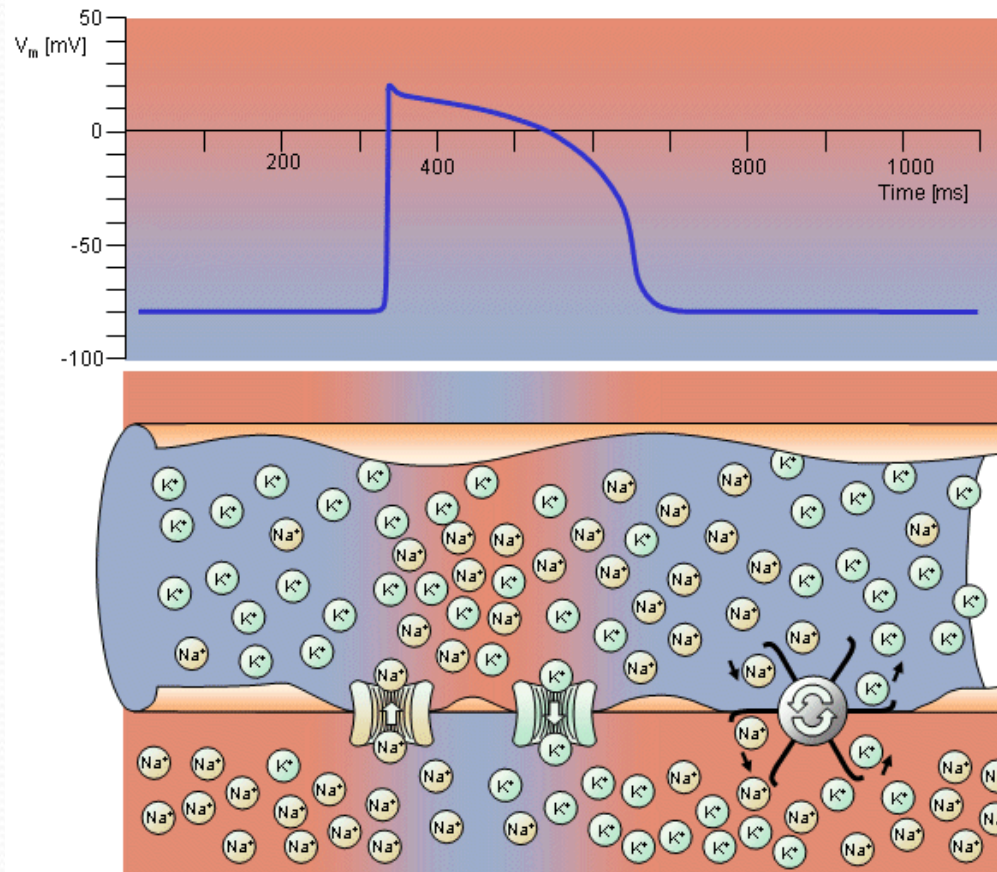
The ECG records the electrical signal of the heart as the muscle cells depolarize (contract) and repolarize.

Normally, the SA Node generates the initial electrical impulse and begins the cascade of events that results in a heart beat.

Recall that cells resting have a negative charge with respect to exterior and depolarization consists of positive ions rushing into the cell

Cell Depolarization

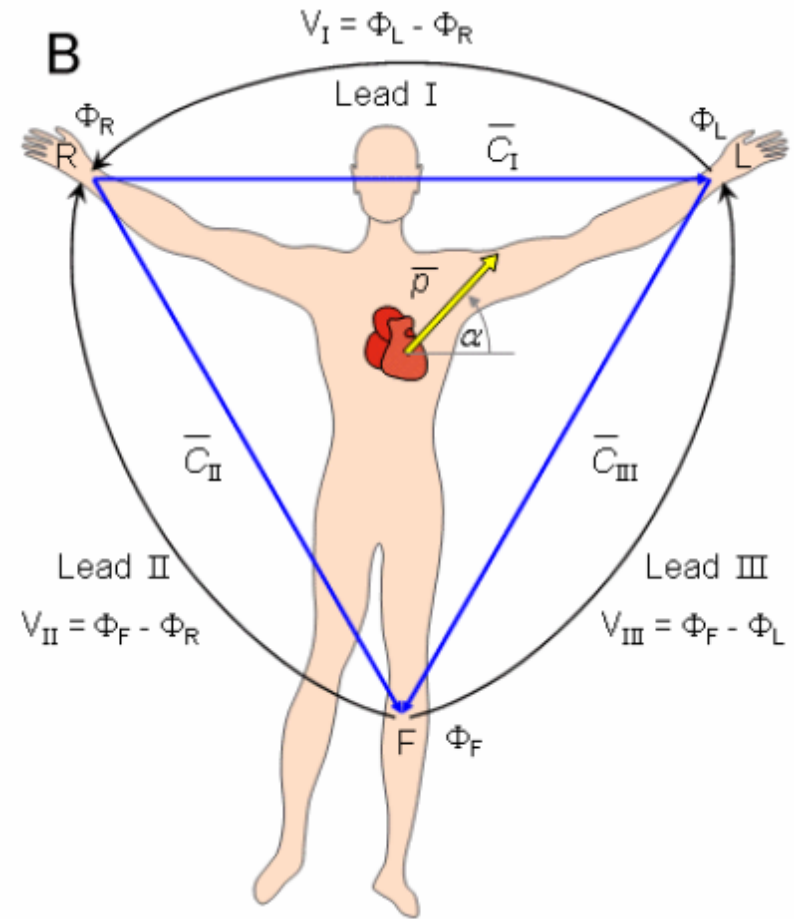
- Flow of sodium ions into cell during activation



Depol Repol. Restoration of
ionic balance

ECG Leads

- In 1908, Willem Einthoven developed a system capable of recording these small signals and recorded the first ECG.
- The leads were based on the Einthoven triangle associated with the limb leads.
- Leads put heart in the middle of a triangle



ECG Leads

- The basic values

V_I = the voltage of Lead I

V_{II} = the voltage of Lead II

V_{III} = the voltage of Lead III

Φ_L = potential at the left arm

Φ_R = potential at the right arm

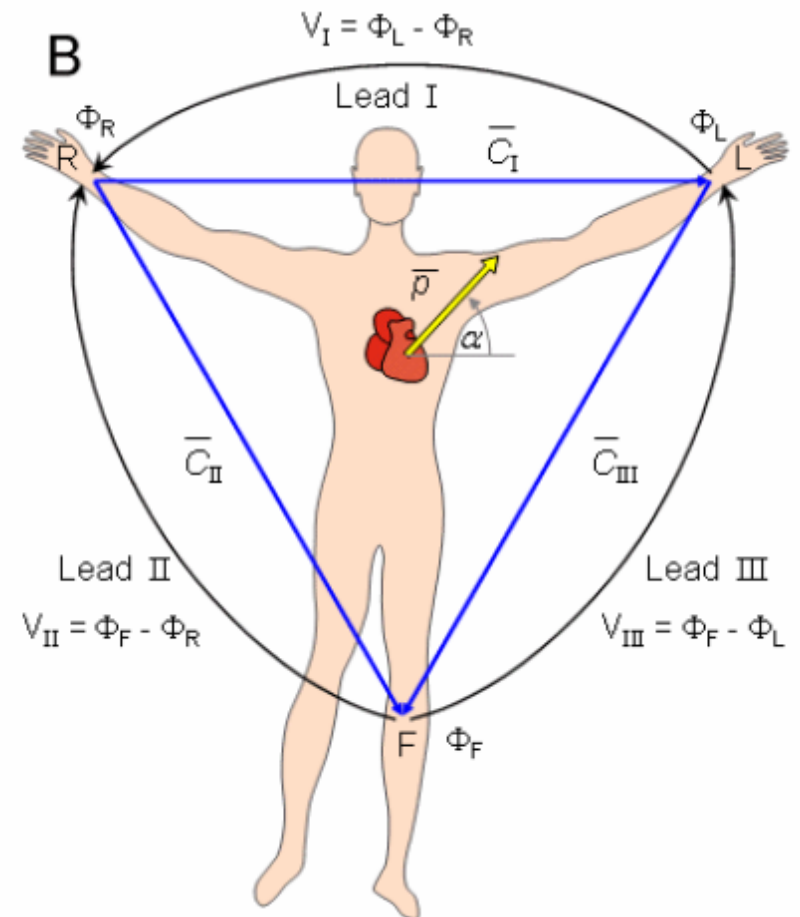
Φ_F = potential at the left foot

- The lead values

Lead I: $V_I = \Phi_L - \Phi_R$

Lead II: $V_{II} = \Phi_F - \Phi_R$

Lead III: $V_{III} = \Phi_F - \Phi_L$



Also note that by KVL:

$$V_I + V_{III} = V_{II}$$

ECG: Electric Signal

- Assumptions
 - Model cardiac source as a dipole producing an electric heart vector, p .
 - Model body as an infinite, homogeneous volume conductor
- The leads will pick up the projection of the electric heart vector, p , along the lead

$$V_I = p \cos \alpha = p_y$$

$$V_{II} = \frac{p}{2} \cos \alpha - \frac{\sqrt{3}}{2} p \sin \alpha = \frac{1}{2} p_y - \frac{\sqrt{3}}{2} p_z = -0.5 p_y - 0.87 p_z$$

$$V_{III} = -\frac{p}{2} \cos \alpha - \frac{\sqrt{3}}{2} p \sin \alpha = -\frac{1}{2} p_y - \frac{\sqrt{3}}{2} p_z = -0.5 p_y - 0.87 p_z$$

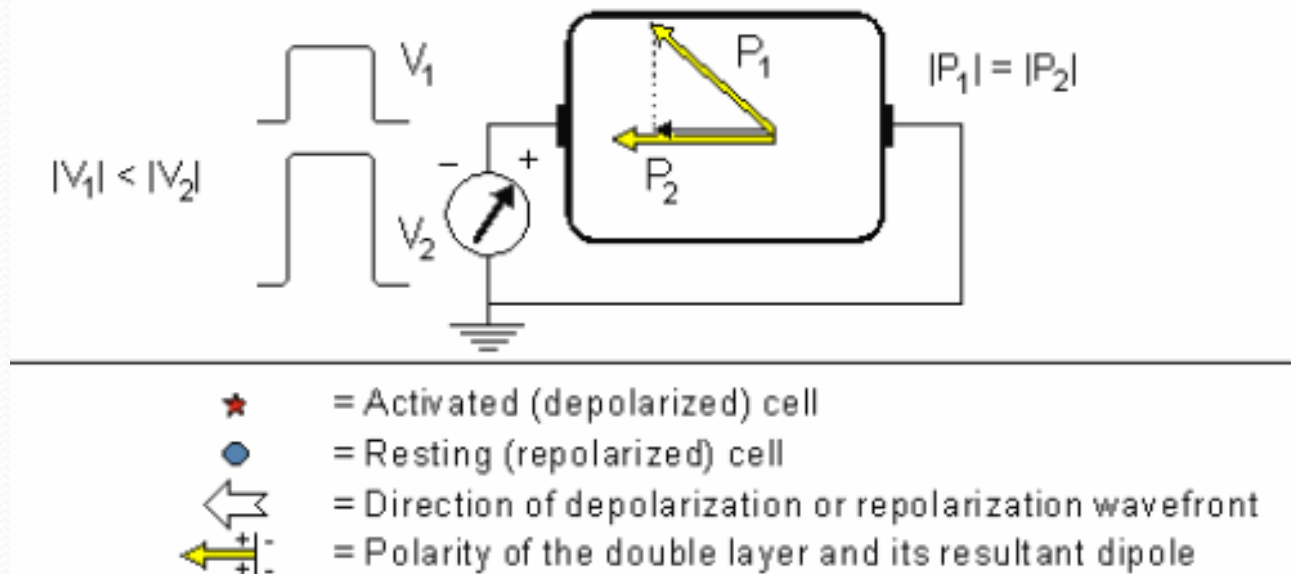
Propagating Activation

Wavefront

- When the cells are at rest, they have a negative transmembrane voltage – surrounding media is positive
- When the cells depolarize, they switch to a positive transmembrane voltage – surrounding media becomes negative
- This leads to a propagating electric vector (pointing from negative to positive)

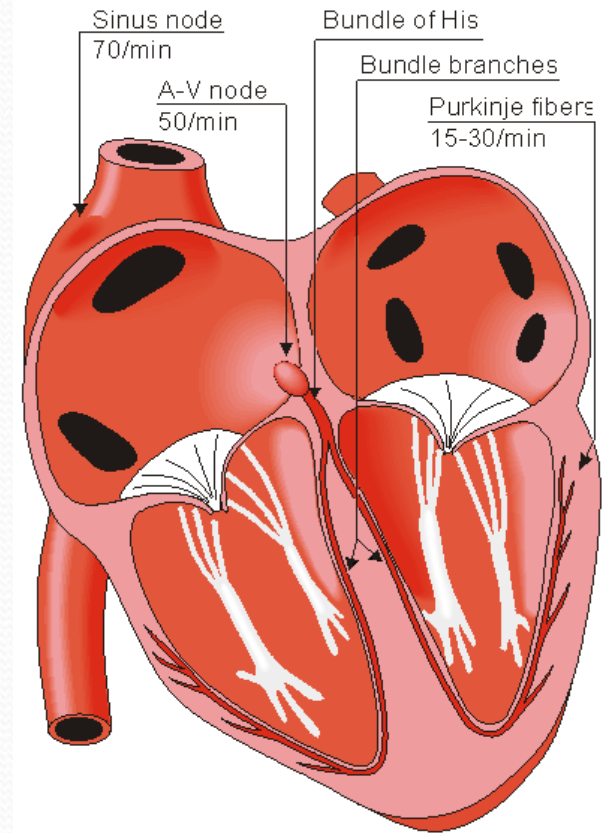
Propagating Activation Wavefront

- When the activation does not align directly with the lead (or propagate directly toward an electrode), the signal is proportional to the component of the activation direction along the lead direction.



ECG Signal

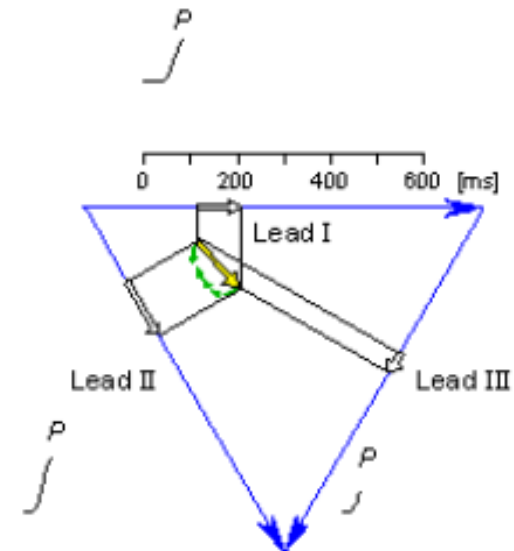
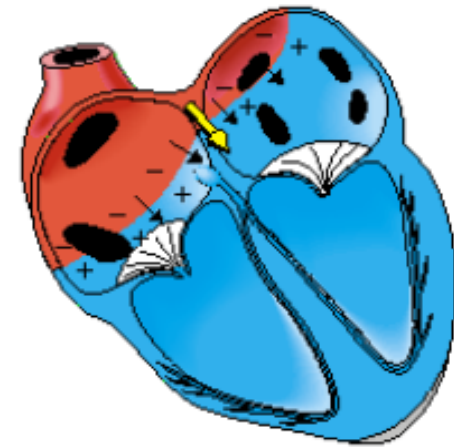
- Heart behaves as a syncytium: a propagating wave that once initiated continues to propagate uniformly into the region that is still at rest.
- The depolarization wavefront defines a dividing line between activated and resting cells.
- Elsewhere, the signal is zero
- Will propagate along conduction paths – sinus node – AV node – bundle branches – Purkinje fibers



ECG Signal

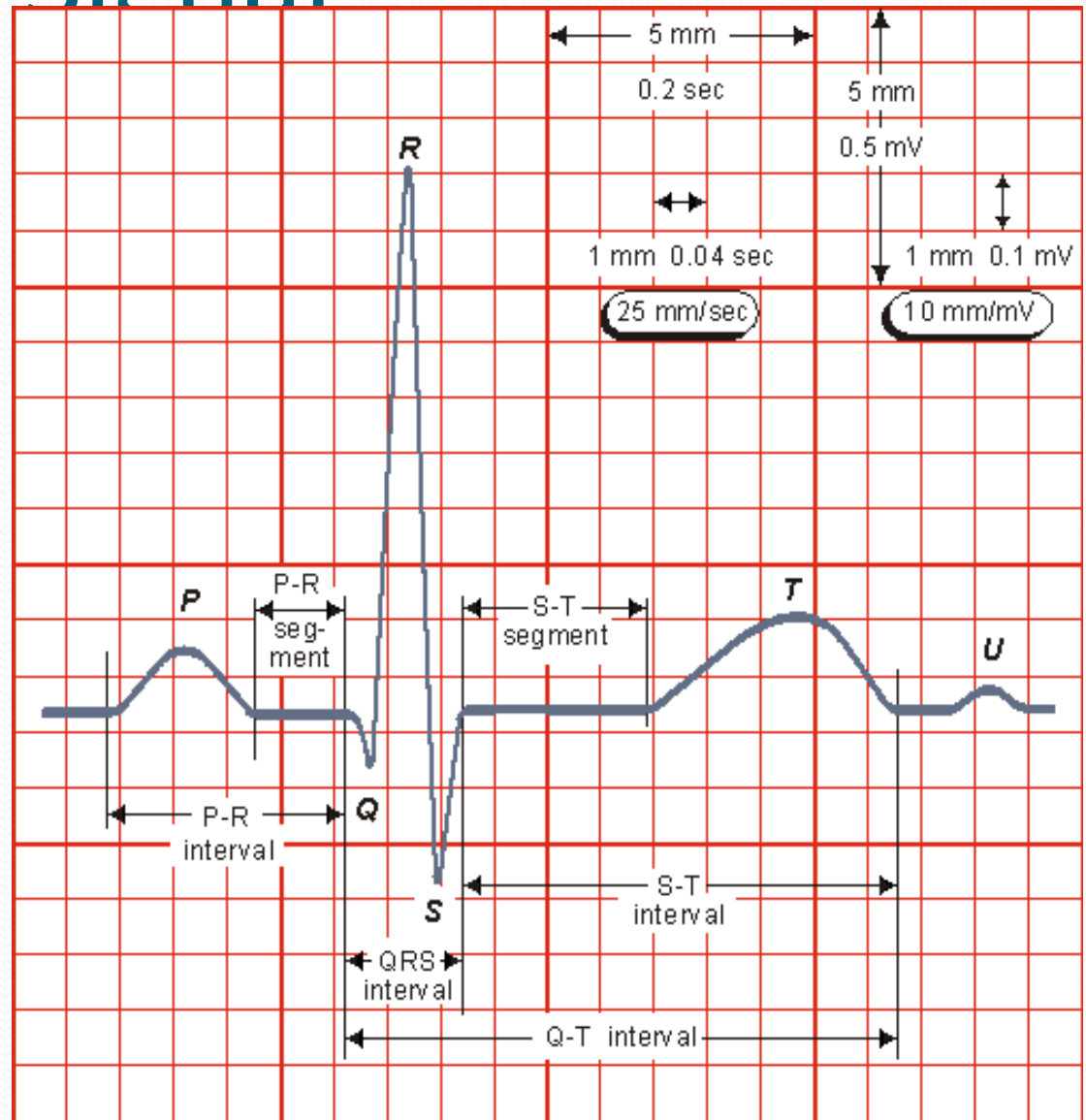
- The excitation begins at the sinus (SA) node and spreads along the atrial walls
- The resultant electric vector is shown in yellow
- Cannot propagate across the boundary between atria and ventricle
- The projections on Leads I, II and III are all positive

ATRIAL
DEPOLARIZATION
80 ms

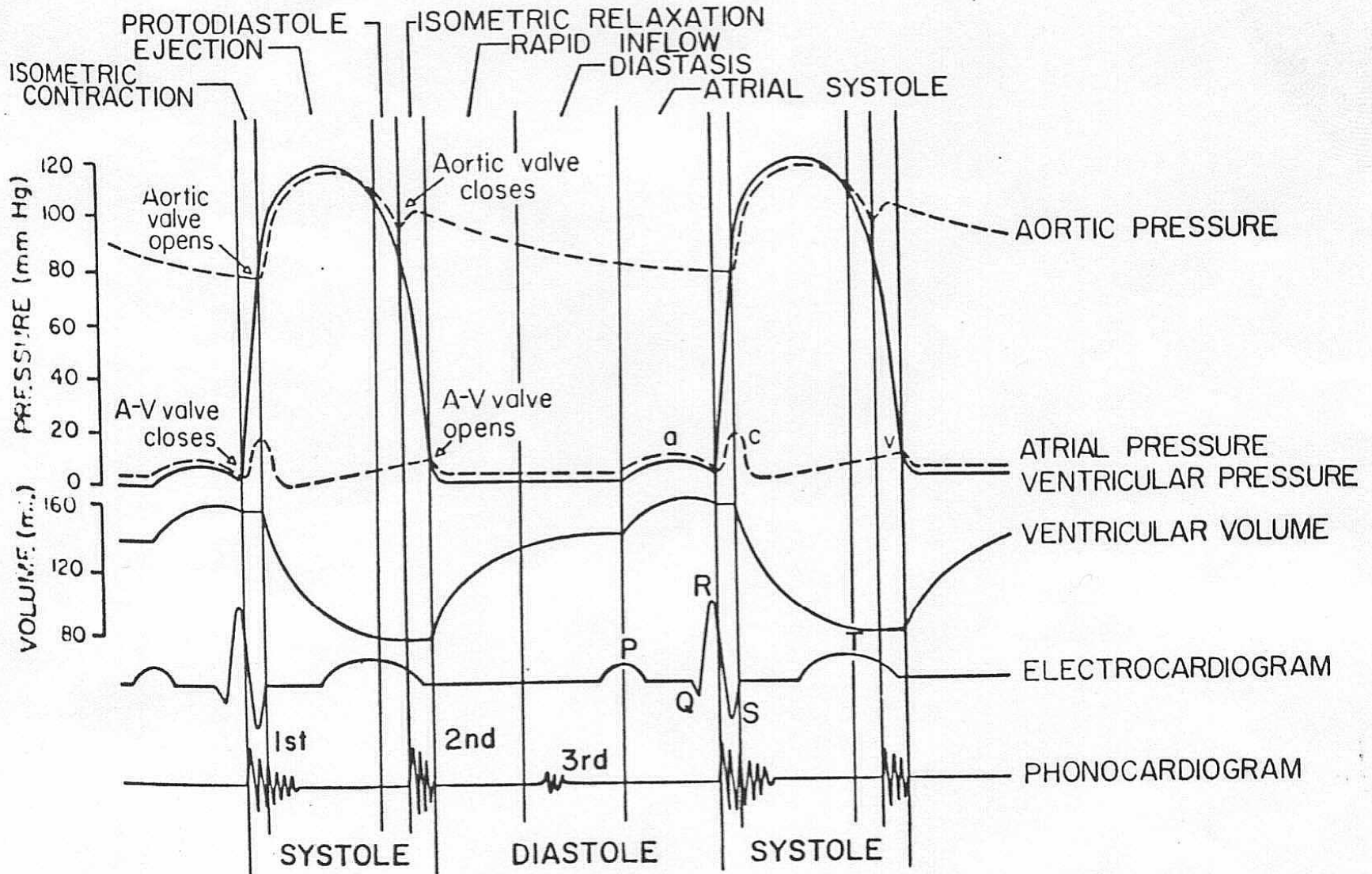


Normal ECG Signal

- P – atrial depolarization
- QRS complex – ventricular depolarization
- T – ventricular repolarization

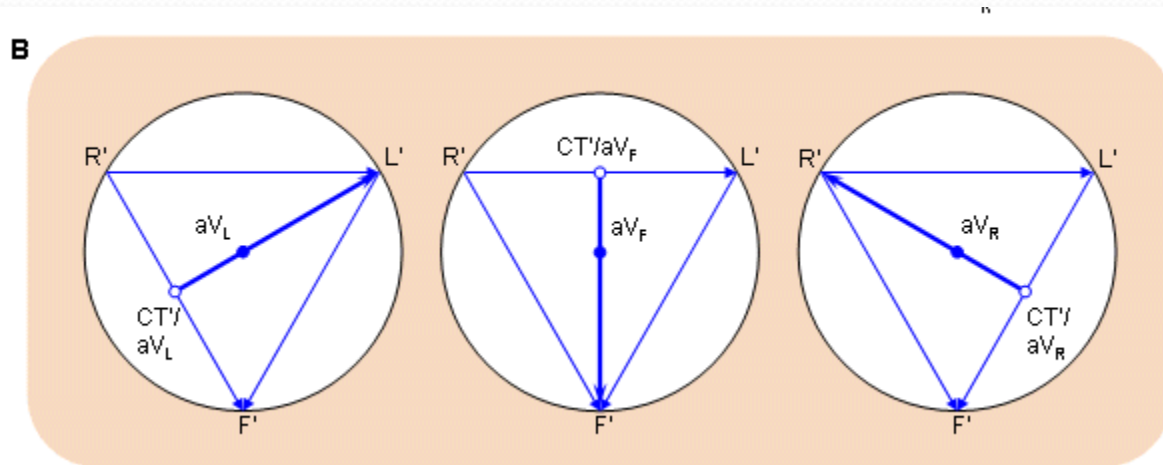


Cardiac Cycle



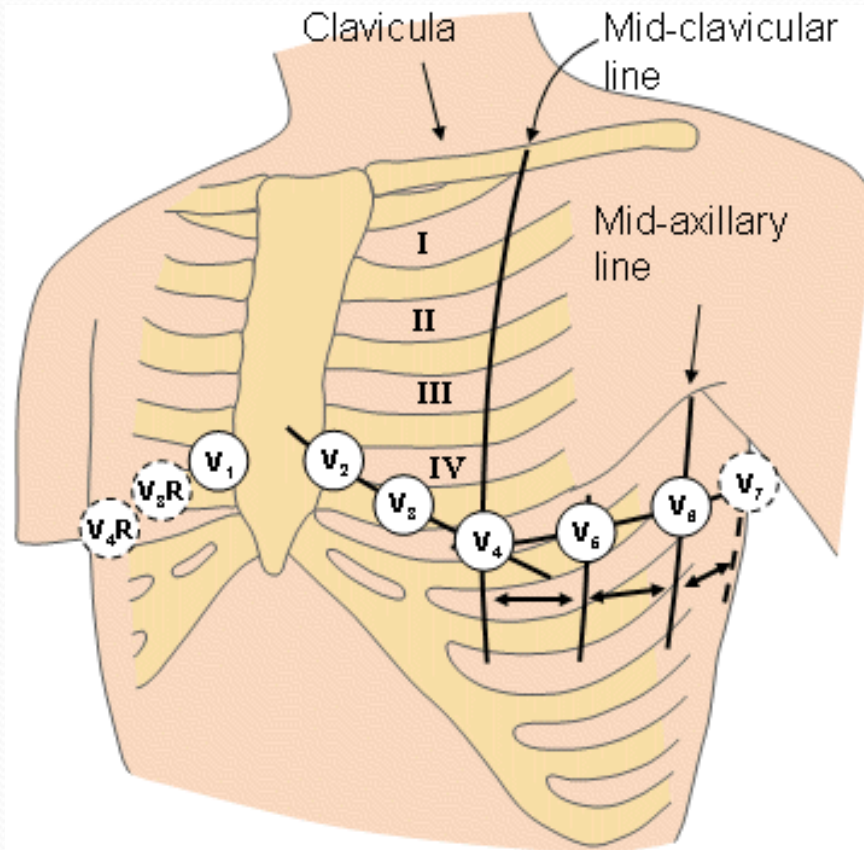
Augmented Leads

- Three additional limb leads are also used: aV_R , aV_L , and aV_F
- These are unipolar leads
- Each lead uses the average of the average of the other two leads as reference
 - $V_R = \Phi_R - (\Phi_L + \Phi_F)/2$



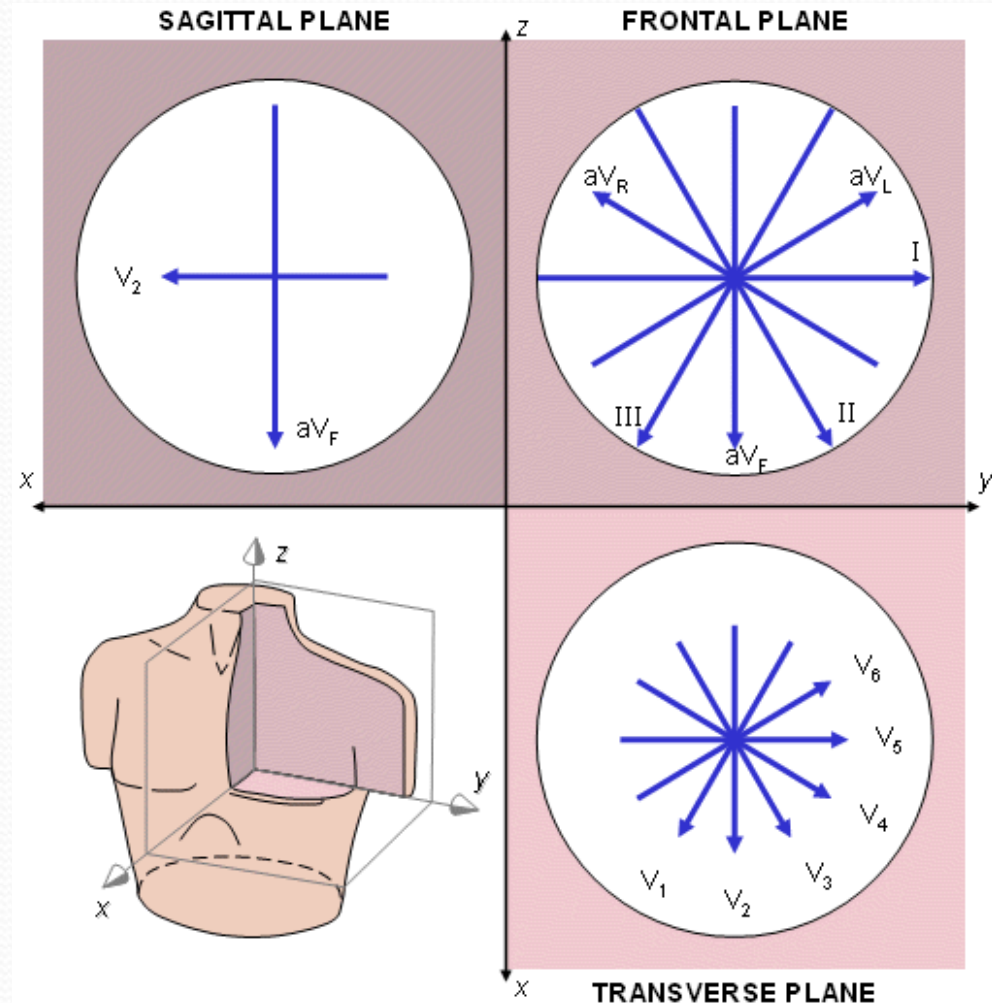
Precordial Leads

- Measure potentials close to the heart, V_1 - V_6
- Unipolar leads



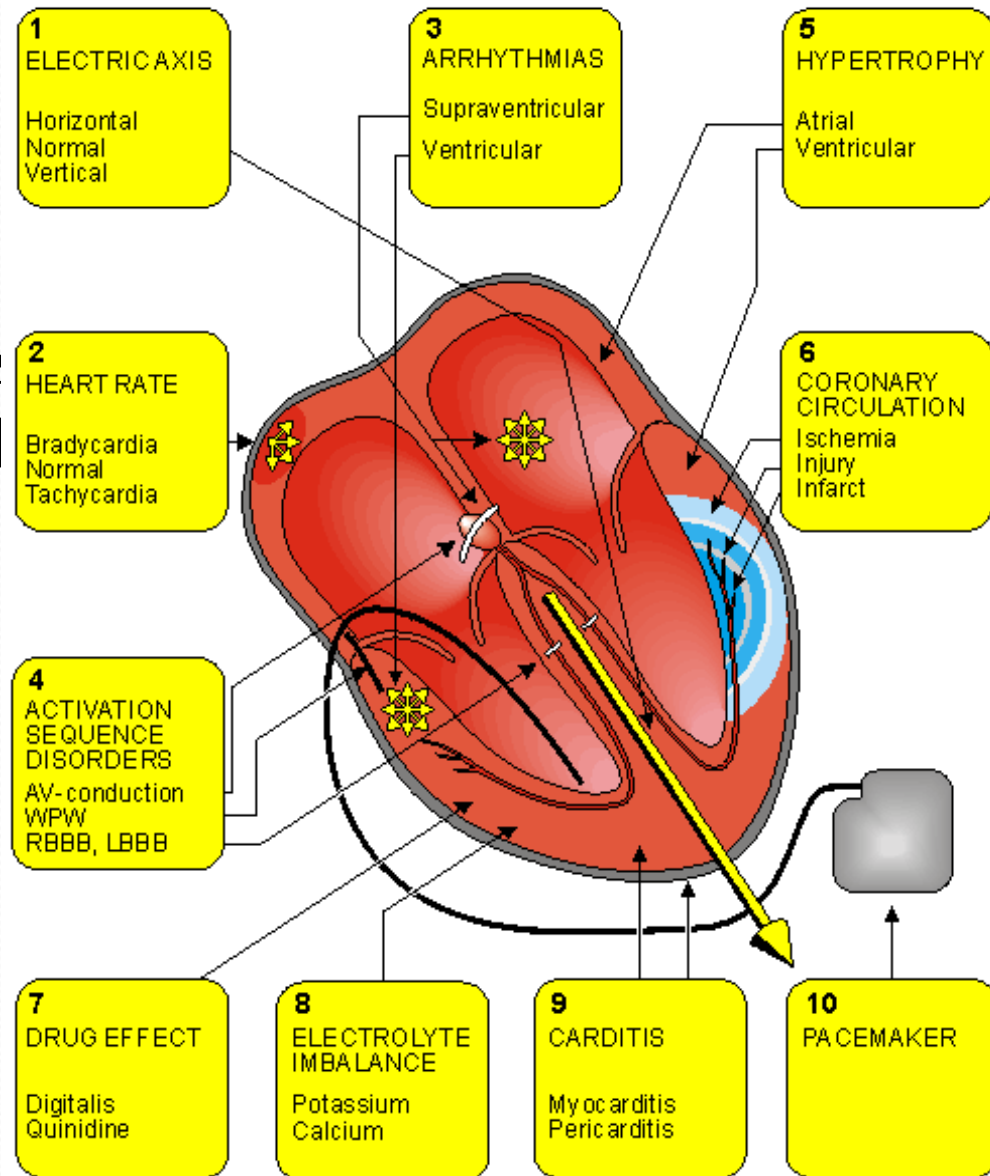
ECG Information

- The 12 leads allow tracing of electric vector in all three planes of interest
- Not all the leads are independent, but are recorded for redundant information



ECG Diagnosis

- The trajectory of the electric vector resulting from the propagating activation wavefront can be traced by the ECG and used to diagnose cardiac problems



Electric Axis of the Heart

This axis changes during cardiac cycle as shown earlier – generally lies between $+30^\circ$ and -110° in the frontal plane and $+30^\circ$ and -30° in the transverse plane

Clinically, it is generally taken where the QRS complex has the largest positive deflection

Note: Often use $-aV_R$

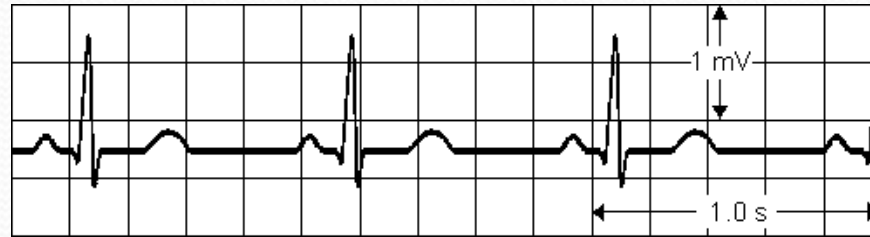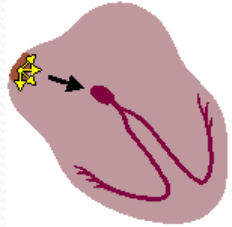
Deviation to R: increased activity in R vent. – obstruction in lung, pulmonary emboli, some heart disease

Deviation to L: increased activity in L vent. – hypertension, aortic stenosis, ischemic heart disease

Cardiac Rhythm: Supraventricular

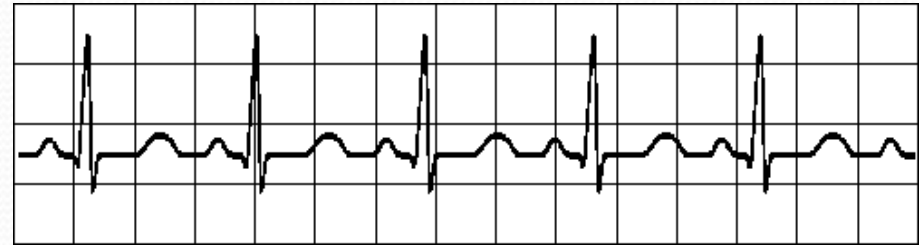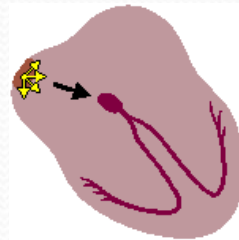
NORMAL SINUS RHYTHM

Impulses originate at S-A node at normal rate



SINUS TACHYCARDIA

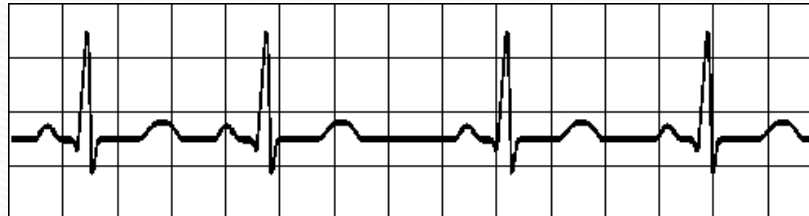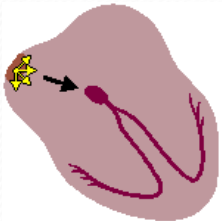
Impulses originate at S-A node at rapid rate



All complexes normal, evenly spaced
Rate > 100/min

SINUS BRADYCARDIA

Impulses originate at S-A node at rapid rate

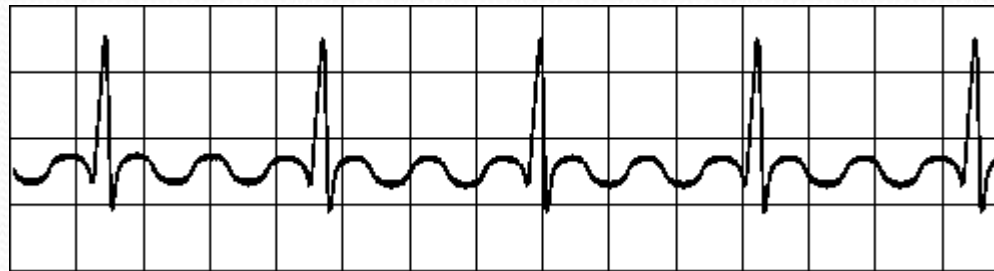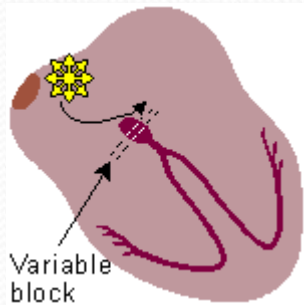


All complexes normal, rhythm is irregular
Longest R-R interval exceeds 0.16 s

Cardiac Rhythm: Supraventricular

ATRIAL FLUTTER

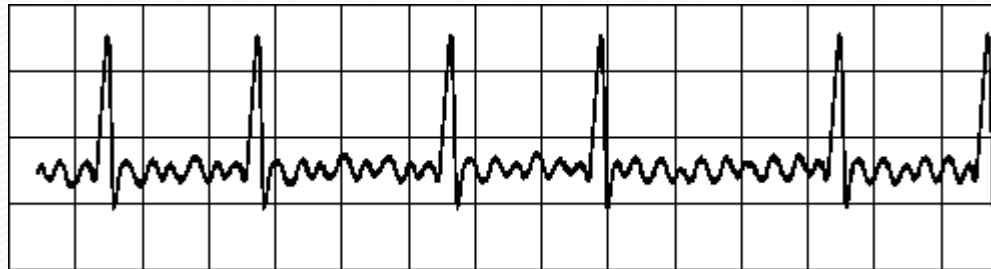
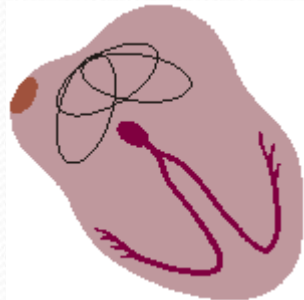
Impulses travel in circular course in atria – No interval between T and P



Rapid flutter waves, ventricular response irregular

ATRIAL FIBRILLATION

Impulses have chaotic, random pathways in atria

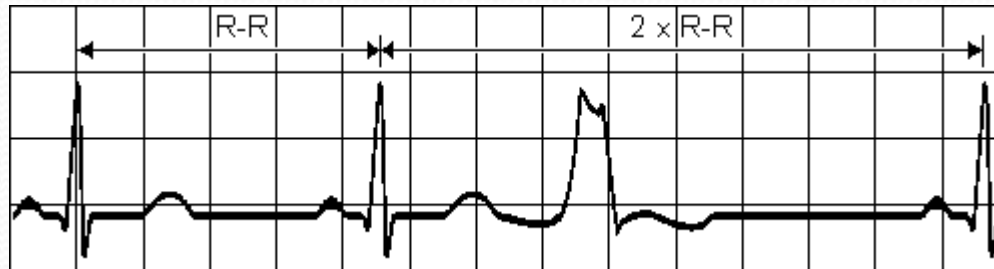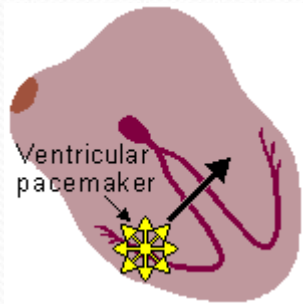


Baseline irregular, ventricular response irregular

Cardiac Rhythm: Ventricular

PREMATURE VENTRICULAR CONTRACTION

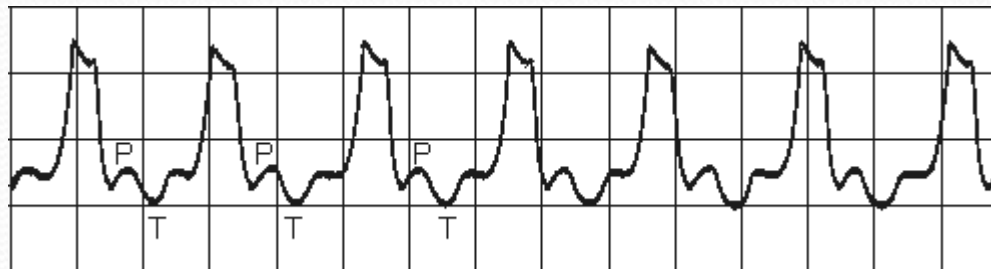
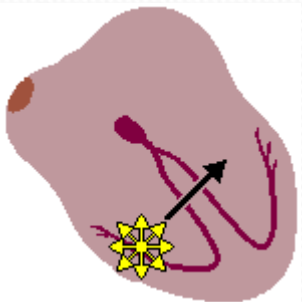
A single impulse originates at right ventricle



Time interval between normal R peaks
is a multiple of R-R intervals

VENTRICULAR TACHYCARDIA

Impulse originate at ventricular pacemaker – odd/wide QRS complex - often due to myocardial infarction

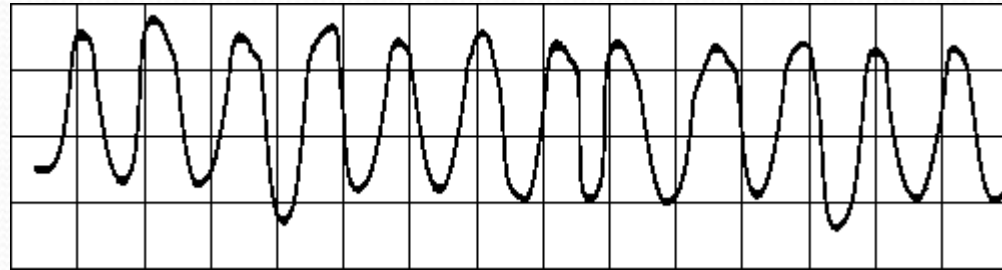
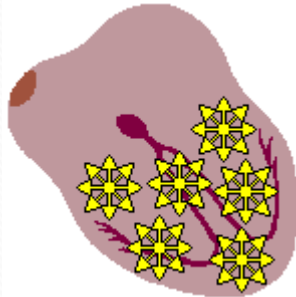


Wide ventricular complexes
Rate > 120/min

Cardiac Rhythm: Ventricular

VENTRICULAR FIBRILLATION

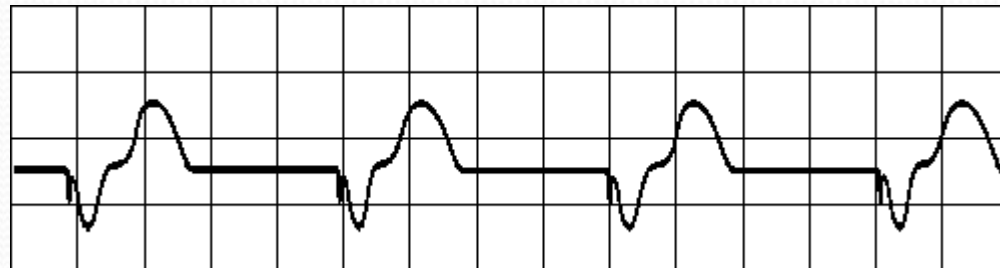

Chaotic ventricular depolarization – ineffective at pumping blood – death within minutes



Rapid, wide, irregular ventricular complexes

PACER RHYTHM

Impulses originate at transvenous pacemaker

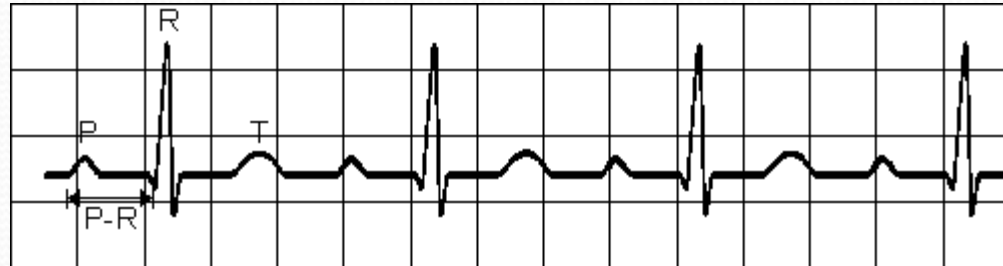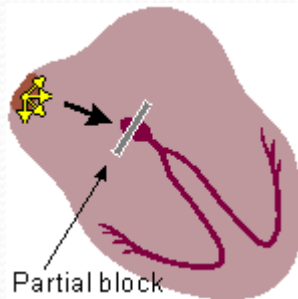


Wide ventricular complexes preceded by pacemaker spike
Rate is the pacer rhythm

Activation Sequence Disorders

A-V BLOCK, FIRST DEGREE

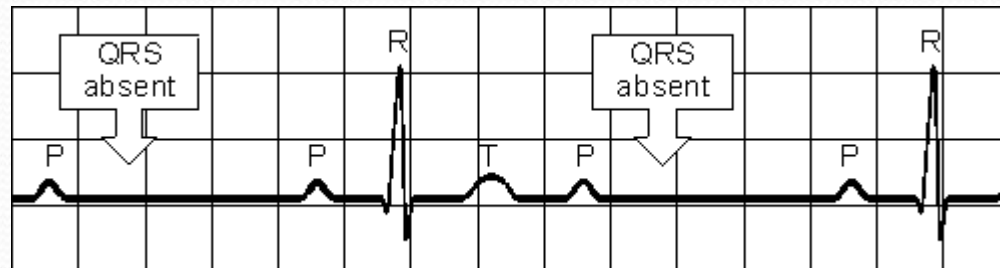
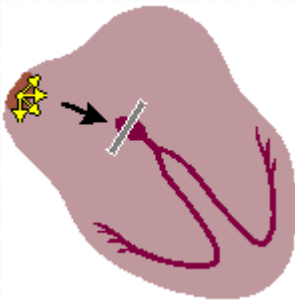
Atrio-ventricular conduction lengthened



P-wave precedes each QRS-complex but PR-interval is > 0.2 s

A-V BLOCK, SECOND DEGREE

Sudden dropped QRS-complex

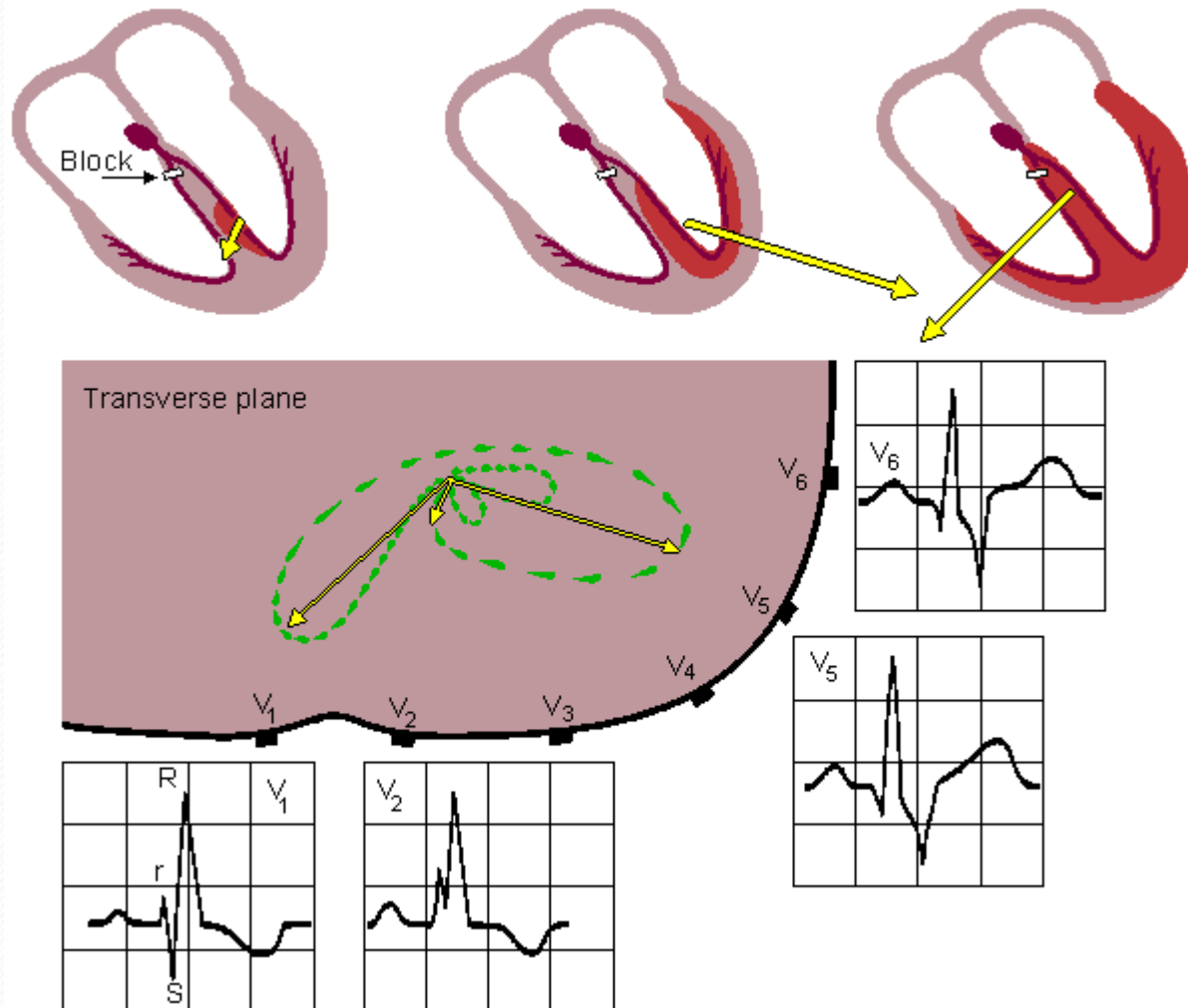


Intermittently skipped ventricular beat

Bundle-branch Block

RIGHT BUNDLE-BRANCH BLOCK

QRS duration greater than 0.12 s
Wide S wave in leads I, V₅ and V₆



Atrial Hypertrophy: Enlarged Atria

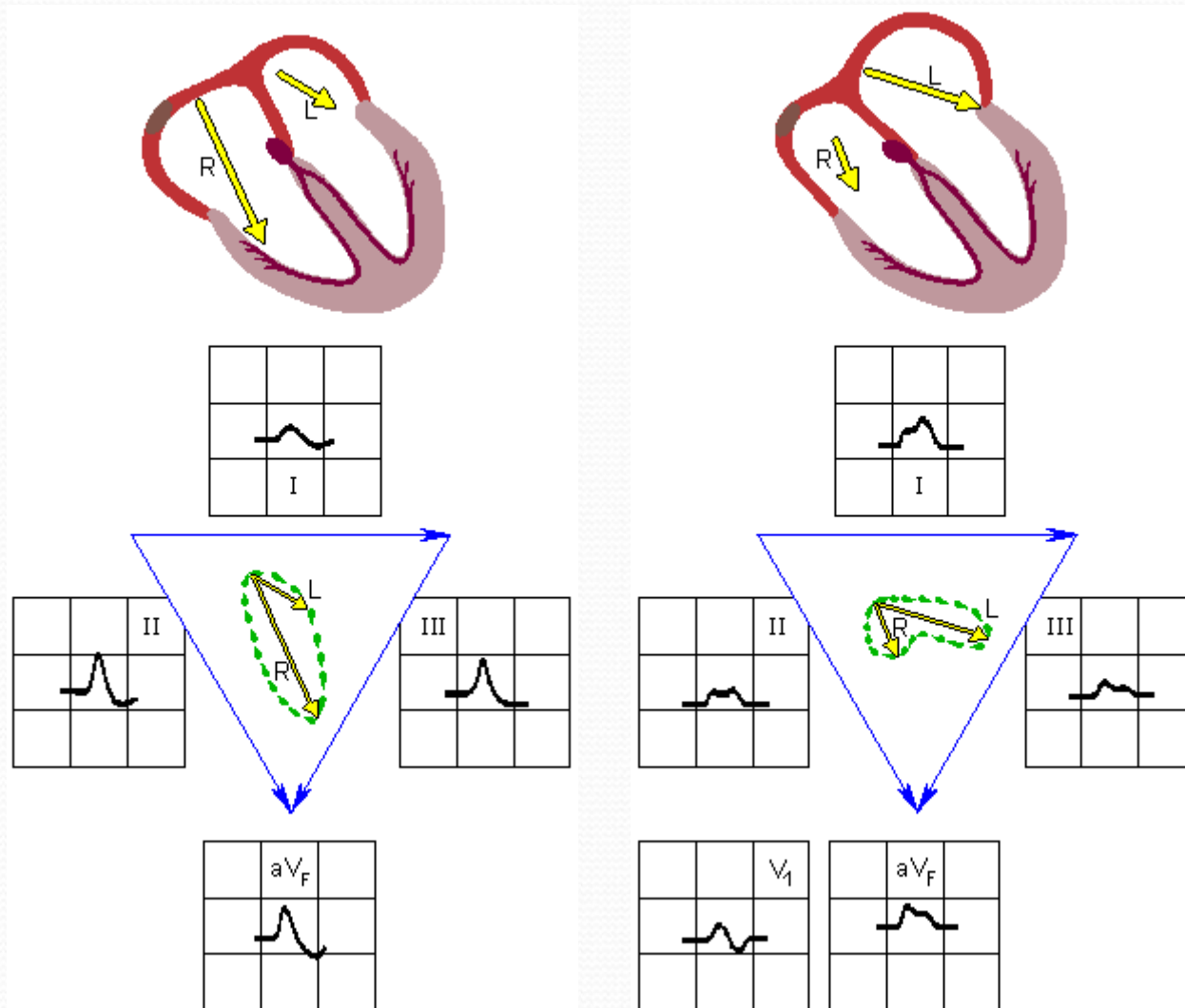
RIGHT ATRIAL HYPERTROPHY

Tall, peaked P wave in leads I and II

LEFT ATRIAL HYPERTROPHY

Wide, notched P wave in lead II

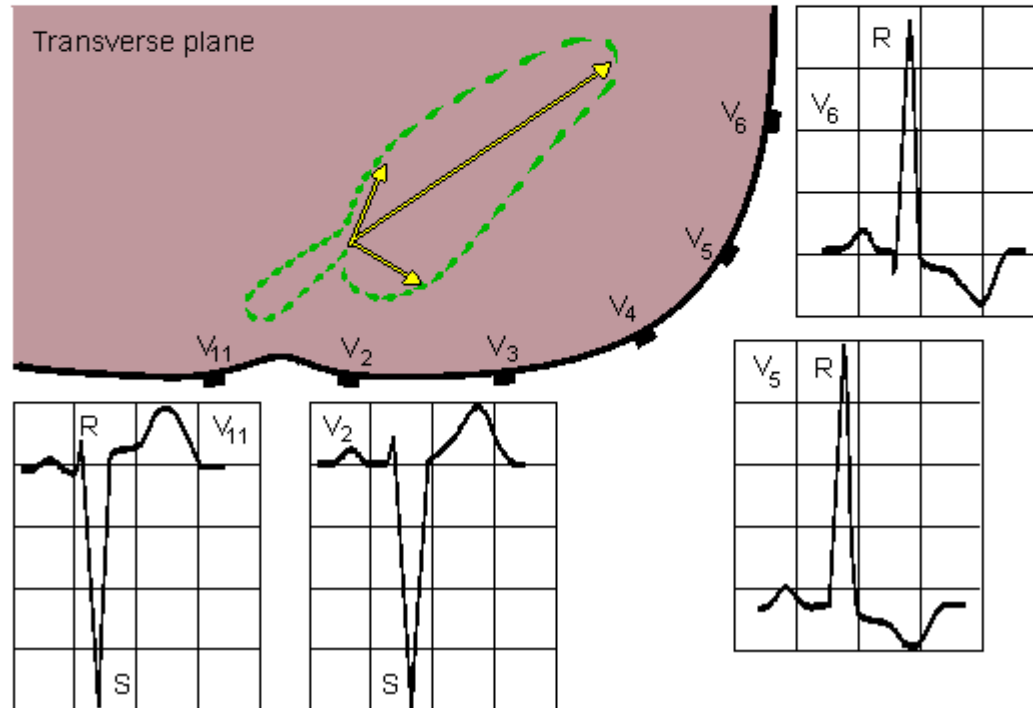
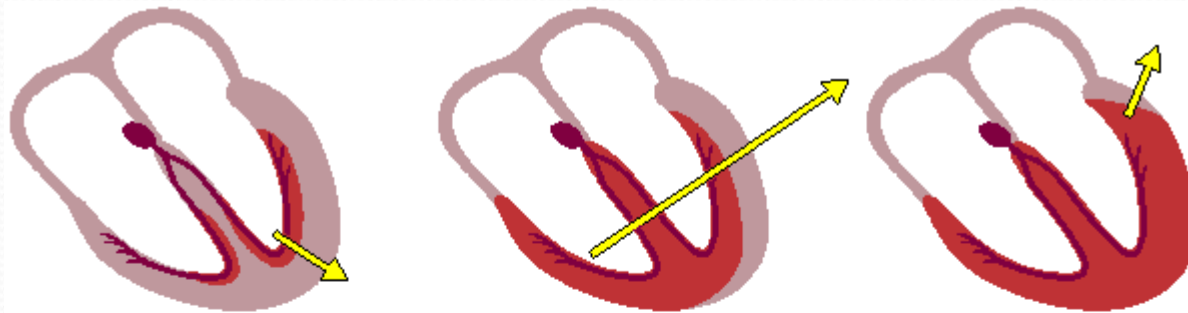
Diphasic P wave in V_1



Ventricular Hypertrophy: Enlarged Ventricle

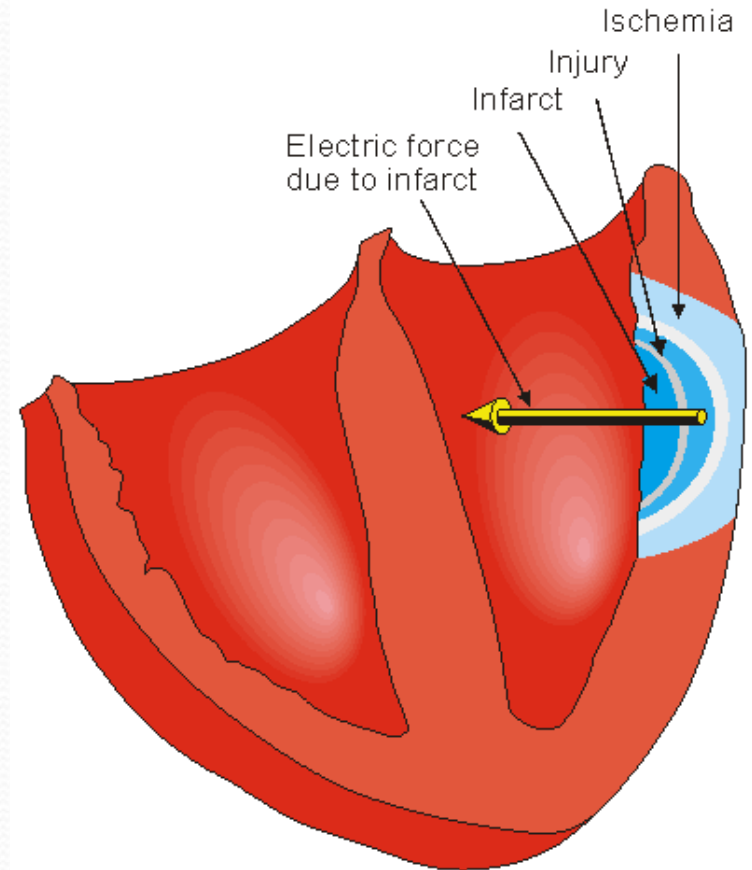
LEFT VENTRICULAR HYPERTROPHY

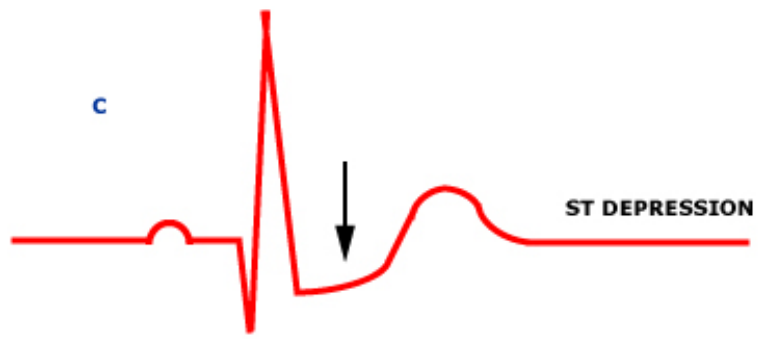
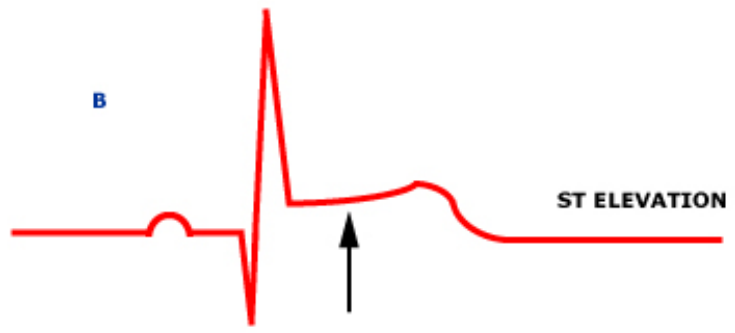
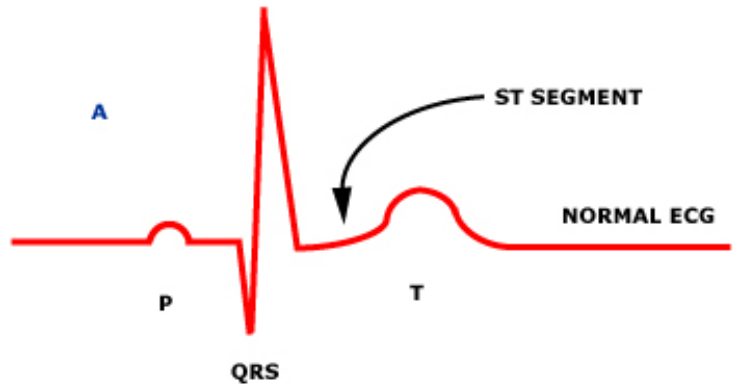
Large S wave in leads V_1 and V_2
Large R wave in leads V_5 and V_6



Myocardial Ischemia and Infarction

- Oxygen depletion to heart can cause an oxygen debt in the muscle (ischemia)
- If oxygen supply stops, the heart muscle dies (infarction)
- The infarct area is electrically silent and represents an inward facing electric vector...can locate with ECG





- The normal electrocardiogram (ECG) pattern consists of a P wave, a QRS complex, and a T wave (A). The portion of the ECG between the QRS complex and the T wave is called the ST segment. In patients who have an ST elevation most probably have myocardial infarction (MI), the ST segment is elevated above the baseline (B). In patients who have a non-ST elevation MI, the ST segment is not elevated, and instead other patterns are seen (for example, ST depression) (C).

- Thank you for your attention

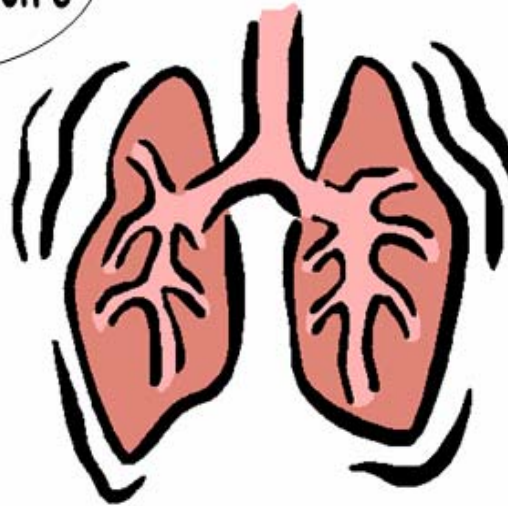




Practical & Clinical aspects of the :

RESPIRATORY SYSTEM!!

LAST
Clinical Session 6



- > Airway Intubation
- > How to use Nebulisers / Inhalers
- > How to administer oxygen & More...

TUES 1830 - 1945

Small Lecture Hall Med Fac!



Pulmonary Function Tests

Dave Utulu

Objectives

- Review basic pulmonary anatomy and physiology.
- Understand the reasons pulmonary function tests (PFTs) are performed.
- Understand the technique and basic interpretation of spirometry.
- Know the difference between obstructive and restrictive lung disease.
- Know how PFTs are clinically applied.

Before you can proceed, you need
to know a little about the lungs...

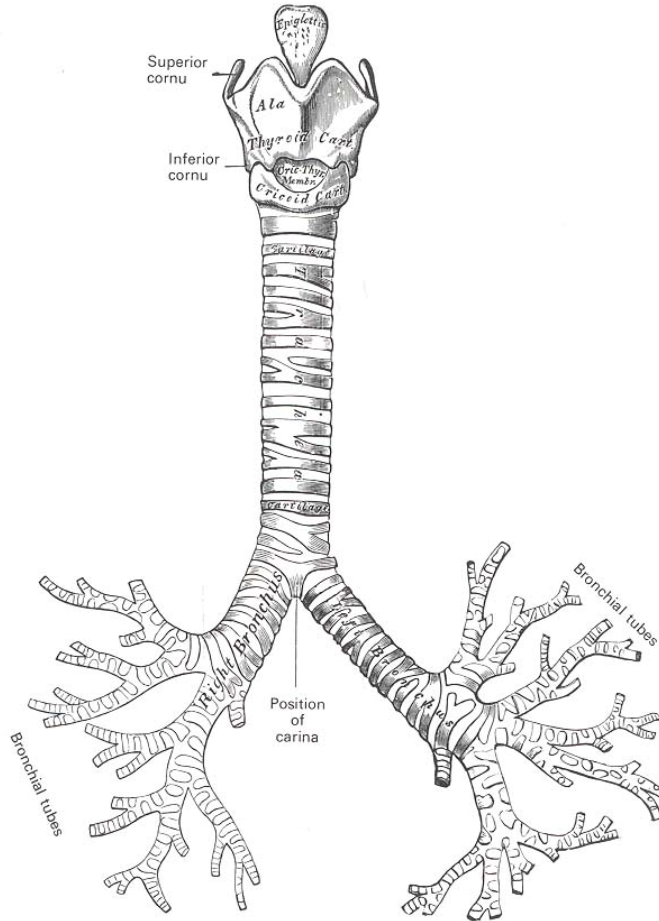
What do the lungs do?

- Primary function is gas exchange
- Let oxygen move in
- Let carbon dioxide move out

How do the lungs do this?

- First, air has to move to the region where gas exchange occurs.
- For this, you need a normal ribcage and respiratory muscles that work properly (among other things).

Conducting Airways



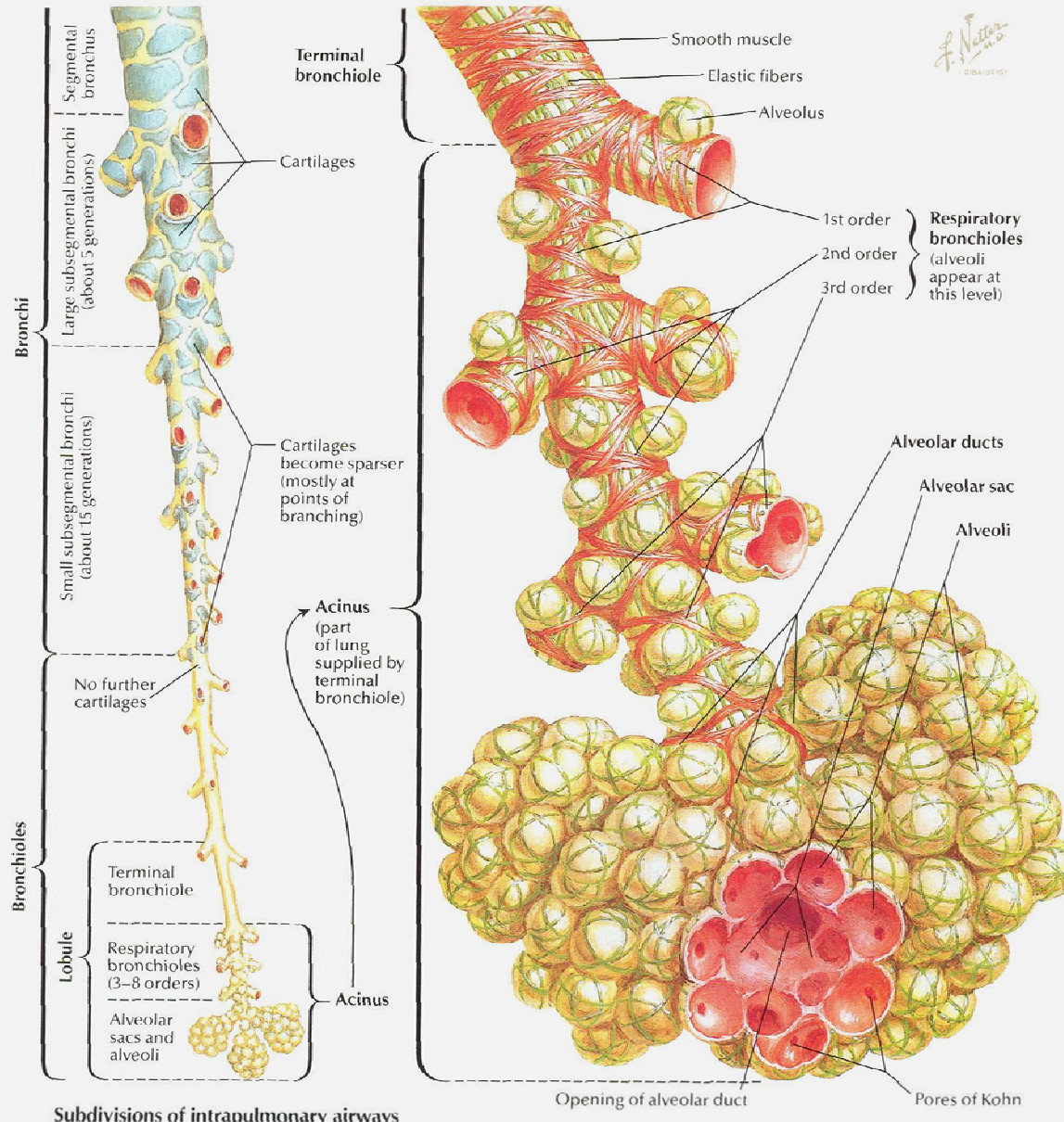
- Air travels via laminar flow through the conducting airways comprised of the following: trachea, lobar bronchi, segmental bronchi, subsegmental bronchi, small bronchi, bronchioles, and terminal bronchioles.

How do the lungs do this? (cont)

- The airways then branch further to become transitional/respiratory bronchioles.
- The transitional/respiratory zones are made up of respiratory bronchioles, alveolar ducts, and alveoli.

How do the lungs do this? (cont)

- Gas exchange takes place in the acinus.
- This is defined as an anatomical unit of the lung made of structures supplied by a terminal bronchiole.

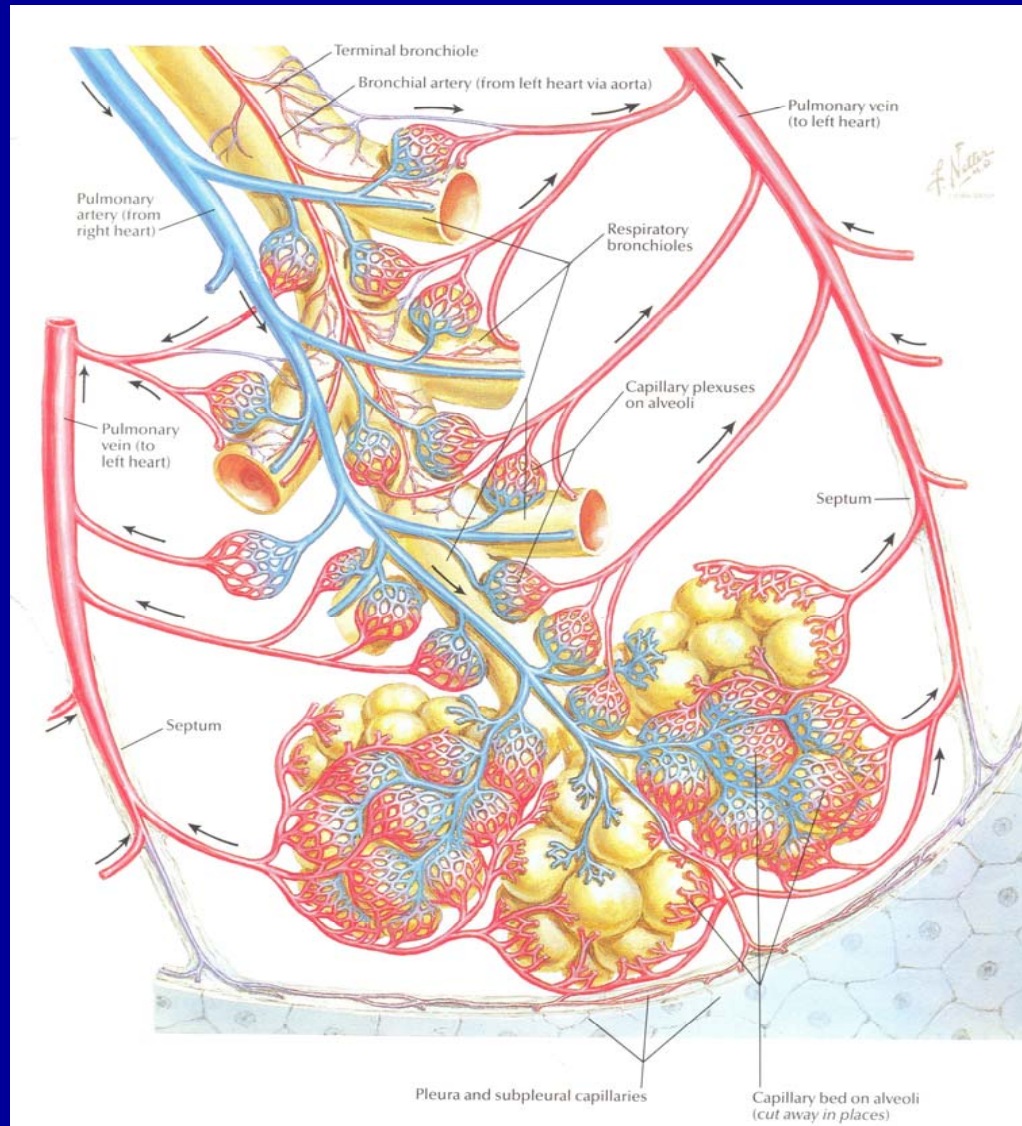


From Netter
 Atlas of
 Human
 Anatomy,
 1989

How does gas exchange occur?

- Numerous capillaries are wrapped around alveoli.
- Gas diffuses across this alveolar-capillary barrier.
- This barrier is as thin as $0.3 \mu\text{m}$ in some places and has a surface area of 50-100 square meters!

Gas Exchange



What exactly are PFTs?

- The term encompasses a wide variety of objective methods to assess lung function. (Remember that the primary function is gas exchange).
- Examples include:
 - Spirometry
 - Lung volumes by helium dilution or body plethysmography
 - Blood gases
 - Exercise tests
 - Diffusing capacity
 - Bronchial challenge testing
 - Pulse oximetry

Why do I care about PFTs?

- Add to diagnosis of disease (pulmonary and cardiac)
- May help guide management of a disease process
- Can help monitor progression of disease and effectiveness of treatment
- Aid in pre-operative assessment of certain patients

Yes, PFTs are really wonderful but...

- They do not act alone.
- They act only to support or exclude a diagnosis.
- A combination of a thorough history and physical exam, as well as supporting laboratory data and imaging will help establish a diagnosis.

Where would I perform PFTs?

- At home--peak expiratory flow meter/pulse ox
- Doctor's office
- Formal PFT laboratory

When would I order PFTs?

- **INDICATIONS FOR SPIROMETRY**

- **Diagnostic**
- To evaluate symptoms, signs, or abnormal laboratory tests
- -Symptoms: dyspnea, wheezing, orthopnea, cough, phlegm production, chest pain
- -Signs: diminished breath sounds, overinflation, expiratory slowing, cyanosis, chest deformity, unexplained crackles
- -Abnormal laboratory tests: hypoxemia, hypercapnia, polycythemia, abnormal chest radiographs
- To measure the effect of disease on pulmonary function
- To screen individuals at risk of having pulmonary diseases
- -Smokers
- -Individuals in occupations with exposures to injurious substances
- -Some routine physical examinations
- To assess preoperative risk
- To assess prognosis (lung transplant, etc.)
- To assess health status before enrollment in strenuous physical activity programs

- **Monitoring**
- To assess therapeutic interventions
 - -bronchodilator therapy
 - -Steroid treatment for asthma, interstitial lung disease, etc.
 - -Management of congestive heart failure
 - -Other (antibiotics in cystic fibrosis, etc.)
- To describe the course of diseases affecting lung function
 - -Pulmonary diseases
 - Obstructive airways diseases
 - Interstitial lung diseases
 - -Cardiac diseases
 - Congestive heart failure
 - -Neuromuscular diseases
 - Guillain-Barre Syndrome
- To monitor persons in occupations with exposure to injurious agents
- To monitor for adverse reactions to drugs with known pulmonary toxicity

(From ATS, 1994)

When would I order PFTs (cont)?

- **Disability/Impairment Evaluations**
- To assess patients as part of a rehabilitation program
 - -Medical
 - -Industrial
 - -Vocational
- To assess risks as part of an insurance evaluation
- To assess individuals for legal reasons
 - -Social Security or other government compensation programs
 - -Personal injury lawsuits
 - -Others
- **Public Health**
- Epidemiologic surveys
 - -Comparison of health status of populations living in different environments
 - -Validation of subjective complaints in occupational/environmental settings
- Derivation of reference equations

(From ATS, 1994)

Spirometry

Spirometry is a medical test that measures the volume of air an individual inhales or exhales as a function of time.

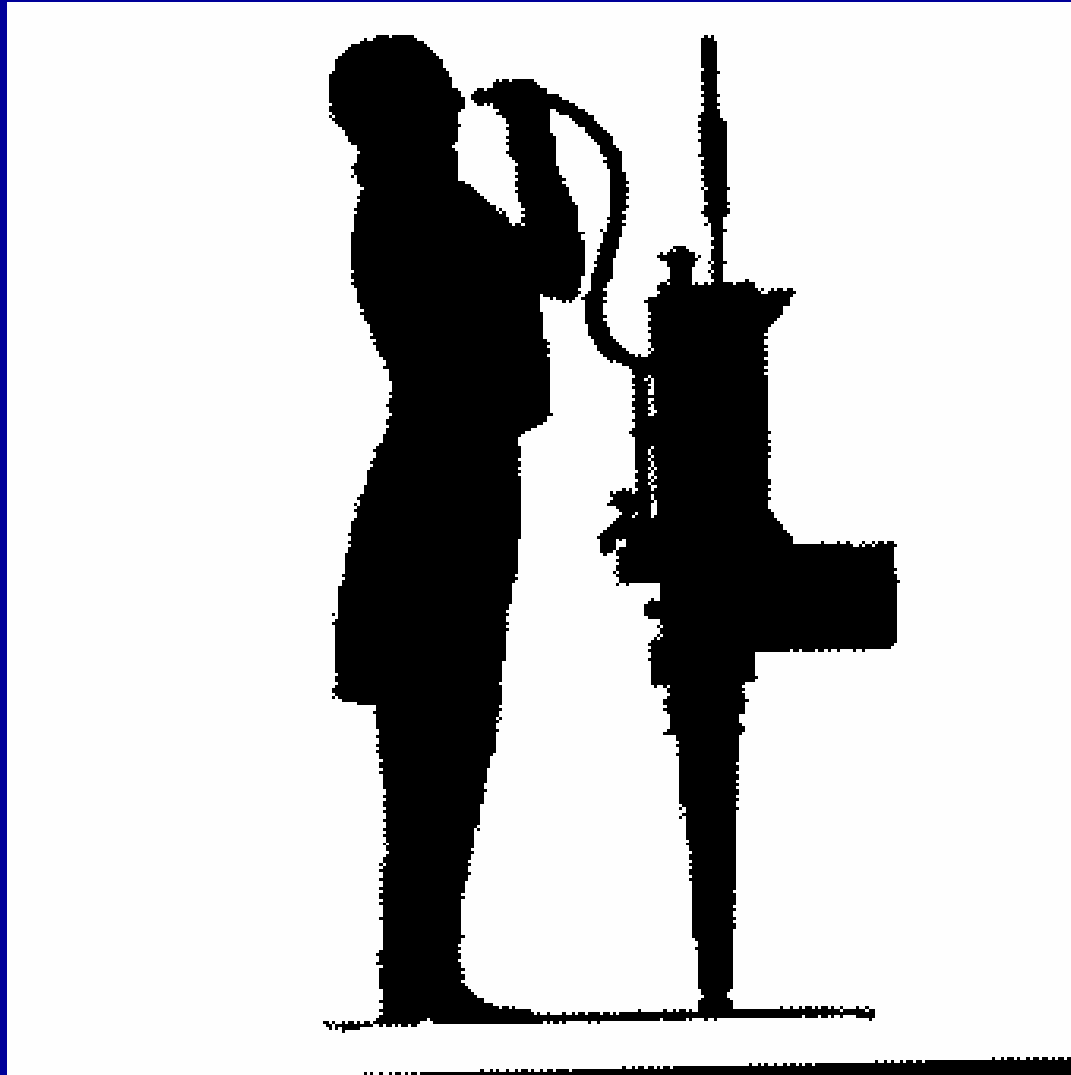
A Brief Aside on History

- John Hutchinson (1811-1861)—inventor of the spirometer and originator of the term vital capacity (VC).
- Original spirometer consisted of a calibrated bell turned upside down in water.
- Observed that VC was directly related to height and inversely related to age.
- Observations based on living and deceased subjects.

A Brief Aside on History

- Hutchinson thought it could apply to life insurance predictors.
- Not really used much during his time.
- Hutchinson moved to Australia and did not pursue any other work on spirometry.
- Eventually ended up in Fiji and died (possibly of murder.)

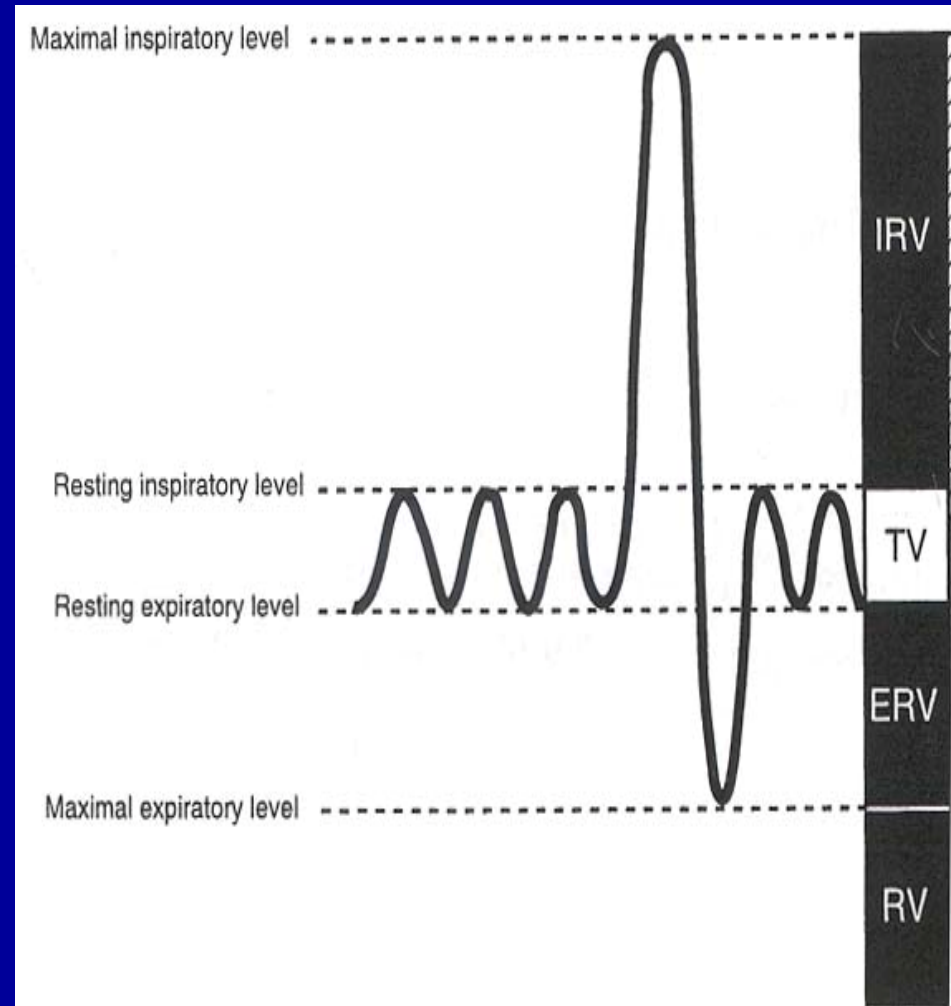
Silhouette of Hutchinson Performing Spirometry



From
Chest,
2002

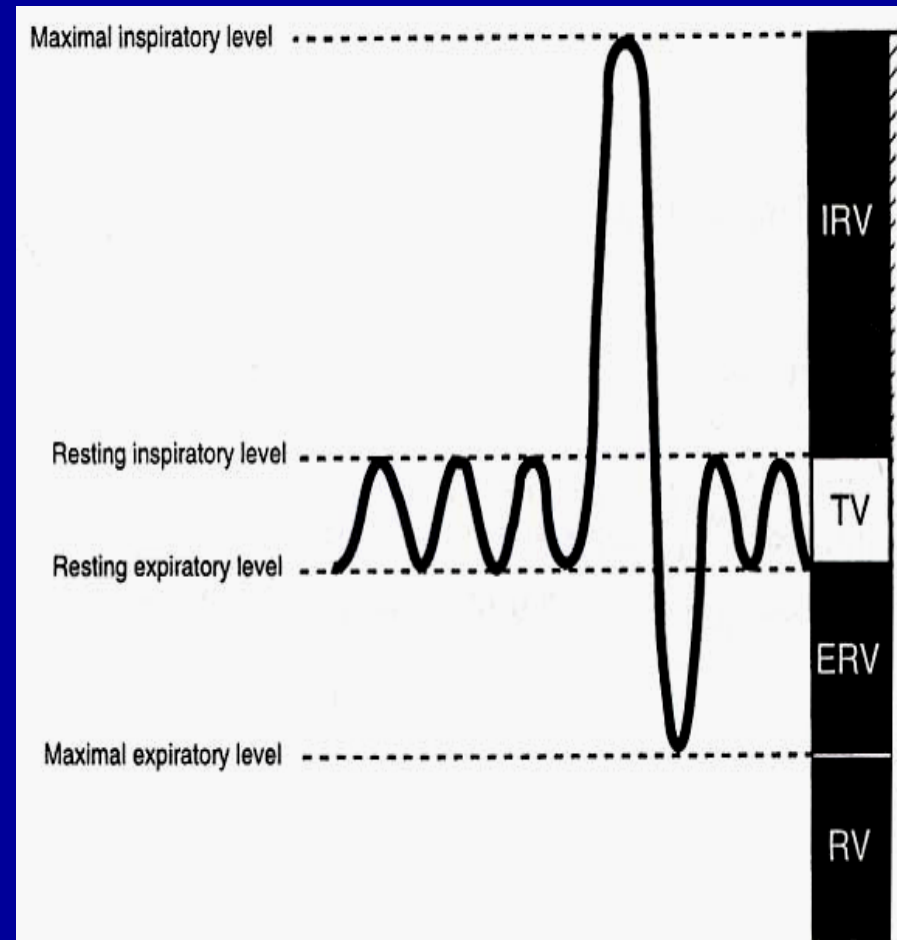
Lung Volumes

- *Tidal Volume (TV)*: volume of air inhaled or exhaled with each breath during quiet breathing
- *Inspiratory Reserve Volume (IRV)*: maximum volume of air inhaled from the end-inspiratory tidal position
- *Expiratory Reserve Volume (ERV)*: maximum volume of air that can be exhaled from resting end-expiratory tidal position



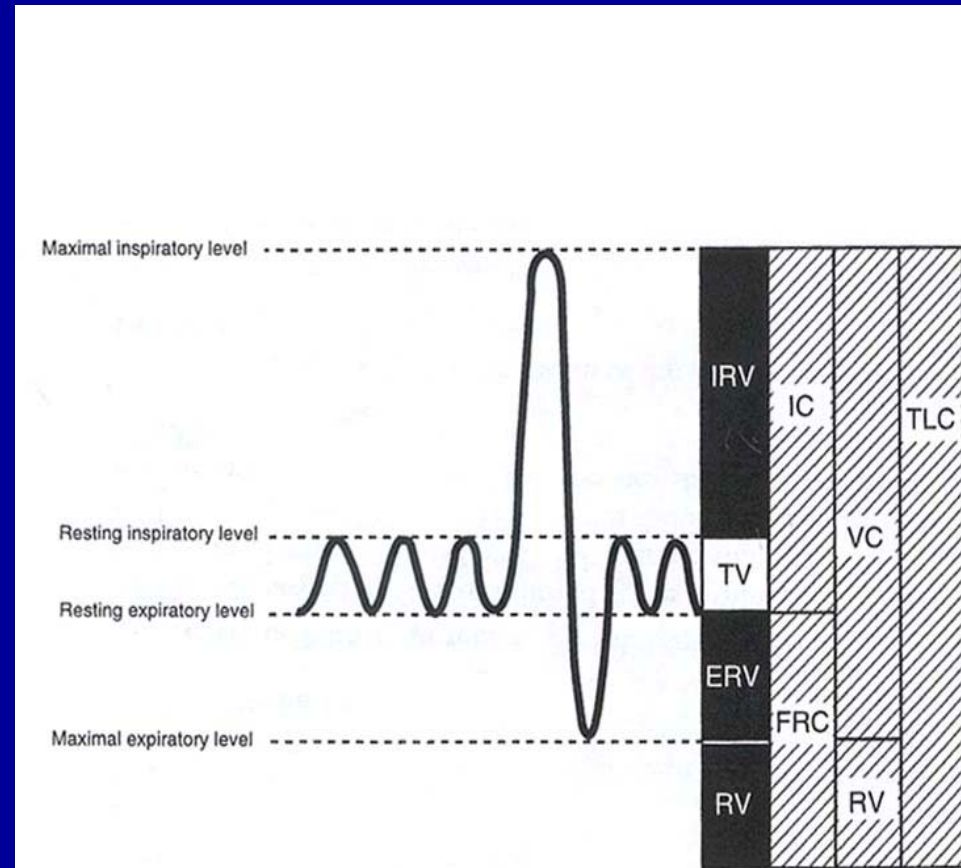
Lung Volumes

- *Residual Volume (RV)*:
 - Volume of air remaining in lungs after maximum exhalation
 - Indirectly measured (FRC-ERV) not by spirometry



Lung Capacities (cont.)

- *Functional Residual Capacity (FRC):*
 - Sum of RV and ERV or the volume of air in the lungs at end-expiratory tidal position
 - Measured with multiple-breath closed-circuit helium dilution, multiple-breath open-circuit nitrogen washout, or body plethysmography (not by spirometry)



What information does a spirometer yield?

- A spirometer can be used to measure the following:
 - FVC and its derivatives (such as FEV₁, FEF 25-75%)
 - Forced inspiratory vital capacity (FIVC)
 - Peak expiratory flow rate
 - Maximum voluntary ventilation (MVV)
 - Slow VC
 - IC, IRV, and ERV
 - Pre and post bronchodilator studies

Forced Expiratory Vital Capacity

- The volume exhaled after a subject inhales maximally then exhales as fast and hard as possible.
- Approximates vital capacity during slow expiration, except may be lower (than true VC) patients with obstructive disease

How is this done?

Performance of FVC maneuver

- Check spirometer calibration.
- Explain test.
- Prepare patient.
 - Ask about smoking, recent illness, medication use, etc.

(adapted from ATS,
1994)

Performance of FVC maneuver (continued)

- Give instructions and demonstrate:
 - Show nose clip and mouthpiece.
 - Demonstrate position of head with chin slightly elevated and neck somewhat extended.
 - Inhale as much as possible, put mouthpiece in mouth (open circuit), exhale as hard and fast as possible.
 - Give simple instructions.

(adapted from ATS,
1994)

Performance of FVC maneuver (continued)

- Patient performs the maneuver
 - Patient assumes the position
 - Puts nose clip on
 - Inhales maximally
 - Puts mouthpiece on mouth and closes lips around mouthpiece (open circuit)
 - Exhales as hard and fast and long as possible
 - Repeat instructions if necessary –be an effective coach
 - Repeat minimum of three times (check for reproducibility.)

(adapted from ATS, 1994)

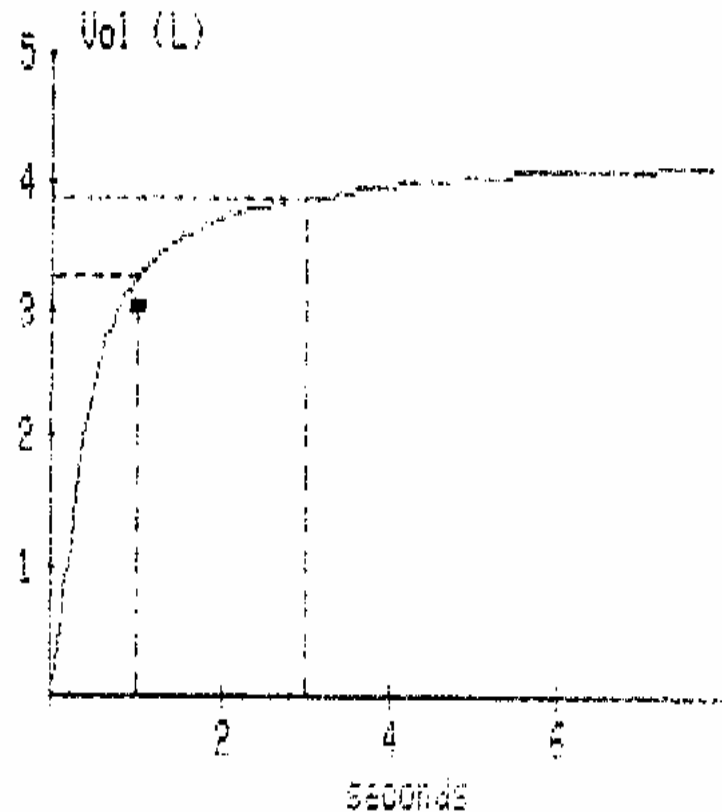
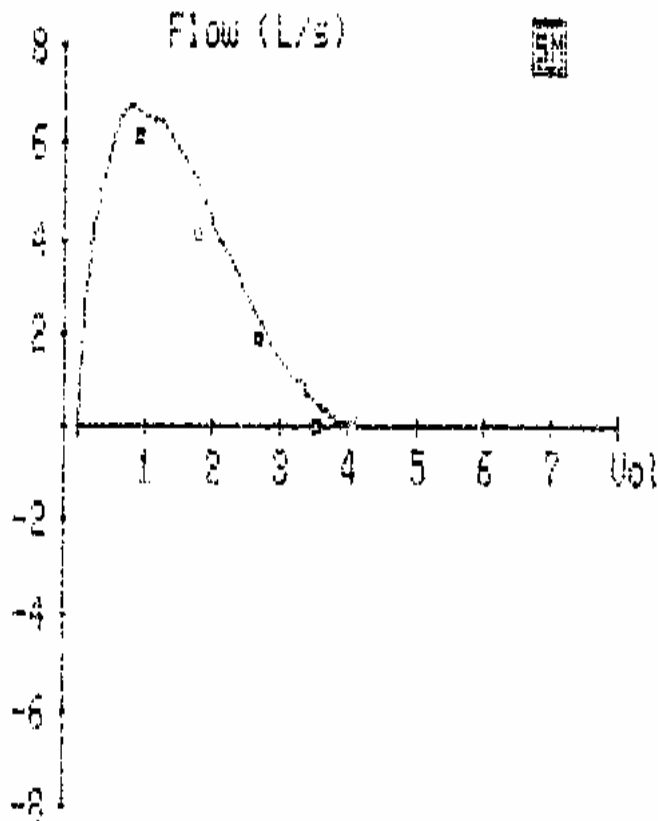
Special Considerations in Pediatric Patients

- Ability to perform spirometry dependent on developmental age of child, personality, and interest of the child.
- Patients need a calm, relaxed environment and good coaching. Patience is key.
- Even with the best of environments and coaching, a child may not be able to perform spirometry. (And that is OK.)

Flow-Volume Curves and Spirograms

- Two ways to record results of FVC maneuver:
 - Flow-volume curve---flow meter measures flow rate in L/s upon exhalation; flow plotted as function of volume
 - Classic spirogram---volume as a function of time

Normal Flow-Volume Curve and Spirogram



EU ERU IC Predicted

Spirometry Interpretation: So what constitutes normal?

- Normal values vary and depend on:
 - Height
 - Age
 - Gender
 - Ethnicity

Acceptable and Unacceptable Spirograms

(from ATS, 1994)

1124

AMERICAN JOURNAL OF RESPIRATORY AND CRITICAL CARE MEDICINE VOL 152 1995

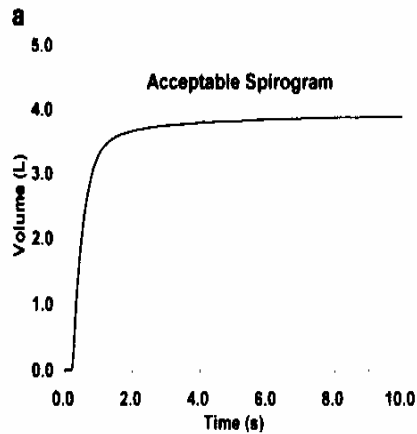


Figure A1a. Acceptable volume-time spirogram.

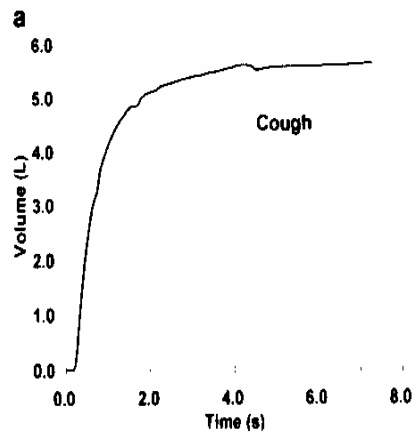


Figure A2a. Volume-time spirogram with a cough during the first second of exhalation.

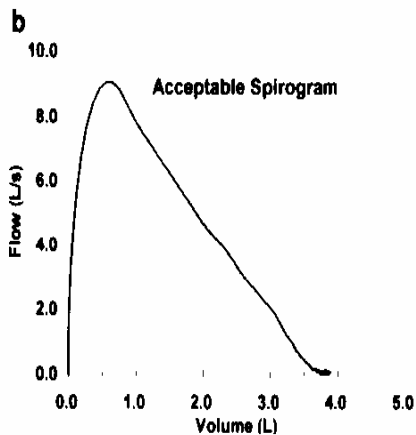


Figure A1b. Acceptable flow-volume spirogram.

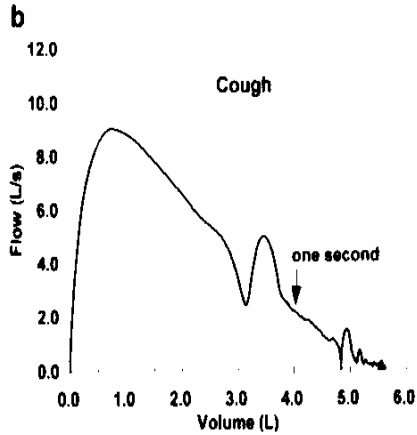


Figure A2b. Flow-volume spirogram with a cough during the first second of exhalation.

American Thoracic Society

1125

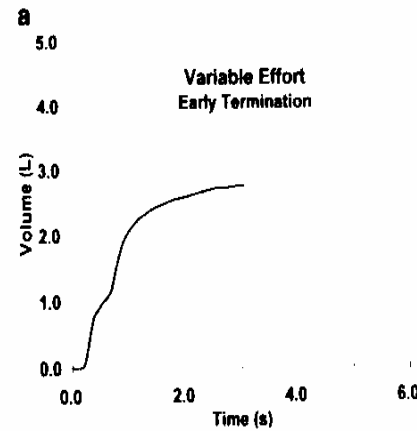


Figure A3a. Unacceptable volume-time spirogram due to variable effort and early termination.

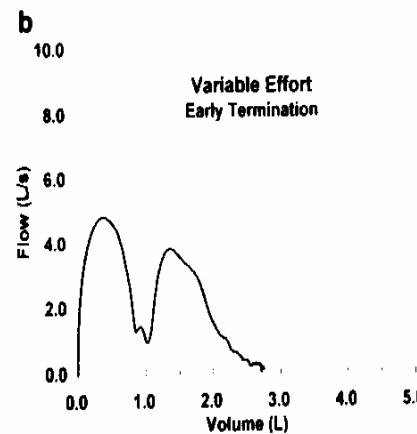


Figure A3b. Unacceptable flow-volume spirogram due to variable effort and early termination.

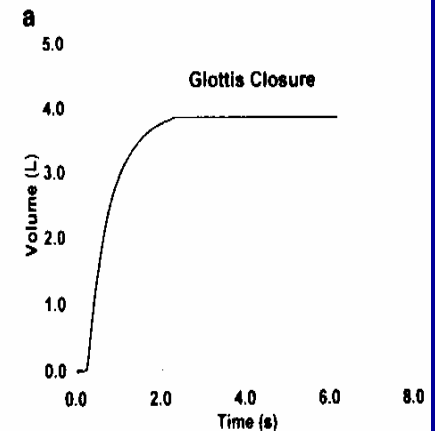


Figure A4a. Unacceptable volume-time spirogram due to possible glottis closure.

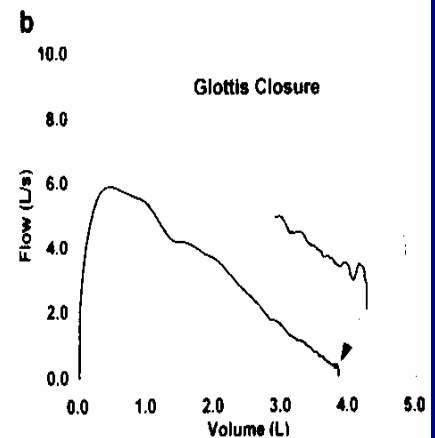


Figure A4b. Unacceptable flow-volume spirogram due to possible glottis closure.

Measurements Obtained from the FVC Curve

- FEV_1 ---the volume exhaled during the first second of the FVC maneuver
- FEF 25-75%---the mean expiratory flow during the middle half of the FVC maneuver; reflects flow through the small (<2 mm in diameter) airways
- FEV_1/FVC ---the ratio of FEV1 to FVC X 100 (expressed as a percent); an important value because a reduction of this ratio from expected values is specific for obstructive rather than restrictive diseases

Spirometry Interpretation: Obstructive vs. Restrictive Defect

- *Obstructive Disorders*

- Characterized by a limitation of expiratory airflow so that airways cannot empty as rapidly compared to normal (such as through narrowed airways from bronchospasm, inflammation, etc.)

Examples:

- Asthma
- Emphysema
- Cystic Fibrosis

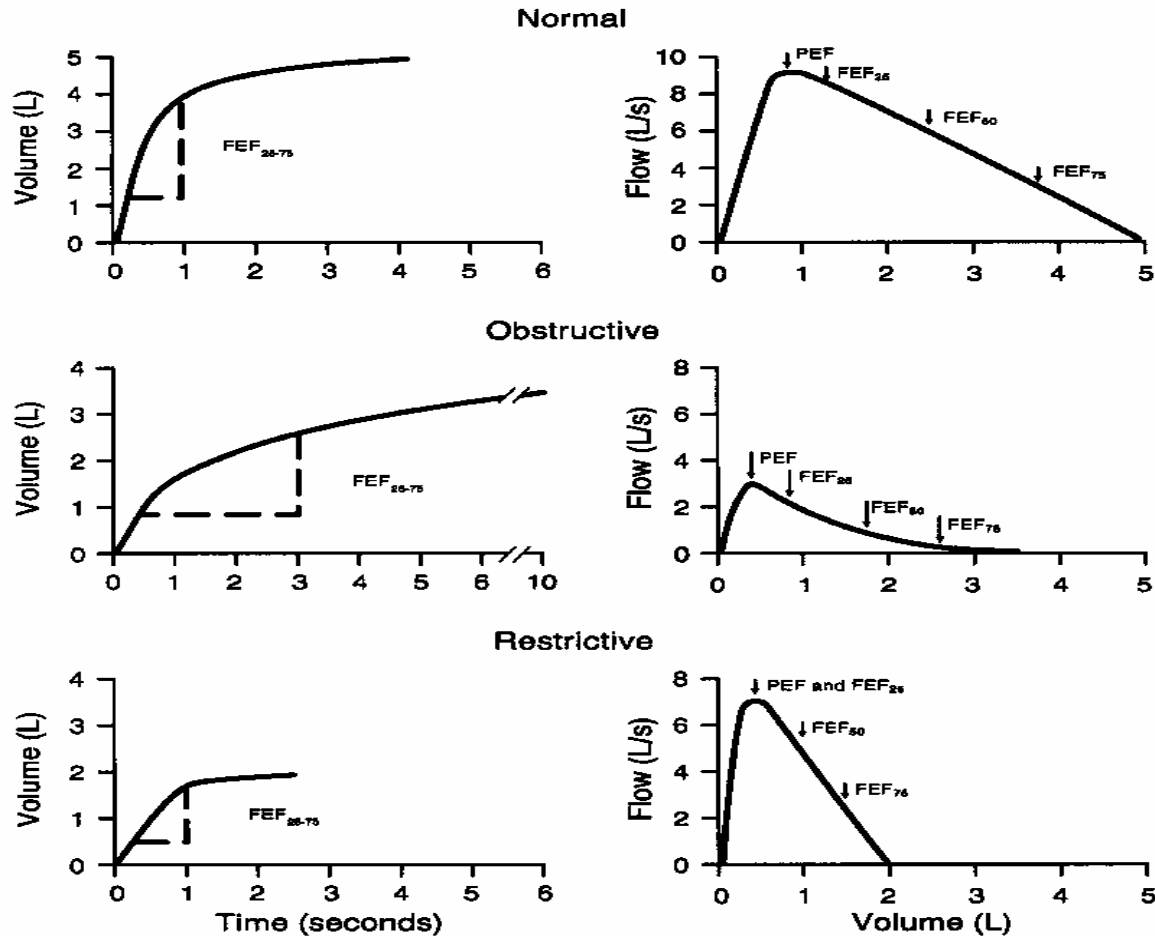
- *Restrictive Disorders*

- Characterized by reduced lung volumes/decreased lung compliance

Examples:

- Interstitial Fibrosis
- Scoliosis
- Obesity
- Lung Resection
- Neuromuscular diseases
- Cystic Fibrosis

Normal vs. Obstructive vs. Restrictive



(Hyatt, 2003)

Spirometry Interpretation: Obstructive vs. Restrictive Defect

- *Obstructive Disorders*
 - FVC nl or ↓
 - FEV1 ↓
 - FEF25-75% ↓
 - FEV1/FVC ↓
 - TLC nl or ↑
- *Restrictive Disorders*
 - FVC ↓
 - FEV1 ↓
 - FEF 25-75% nl to ↓
 - FEV1/FVC nl to ↑
 - TLC ↓

Spirometry Interpretation: What do the numbers mean?

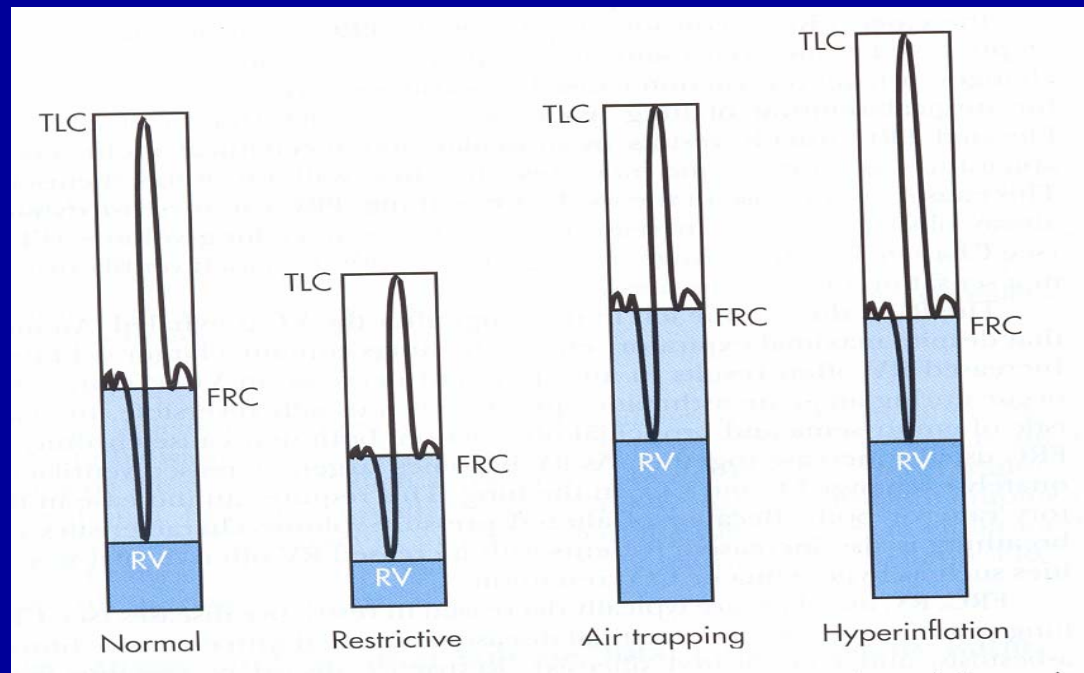
- FVC
- Interpretation of % predicted:
 - 80-120% Normal
 - 70-79% Mild reduction
 - 50%-69% Moderate reduction
 - <50% Severe reduction

- FEV1
- Interpretation of % predicted:
 - >75% Normal
 - 60%-75% Mild obstruction
 - 50-59% Moderate obstruction
 - <49% Severe obstruction
 - <25 y.o. add 5% and >60 y.o. subtract 5

Spirometry Interpretation: What do the numbers mean?

- FEF 25-75%
- Interpretation of % predicted:
 - >79% Normal
 - 60-79% Mild obstruction
 - 40-59% Moderate obstruction
 - <40% Severe obstruction
- FEV1/FVC
- Interpretation of *absolute* value:
 - 80 or higher Normal
 - 79 or lower Abnormal

What about lung volumes and obstructive and restrictive disease?

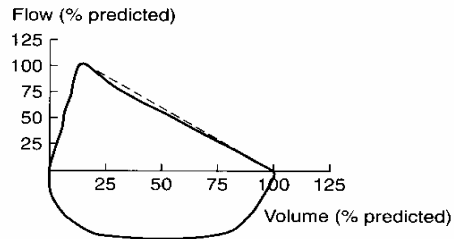


(From Ruppel, 2003)

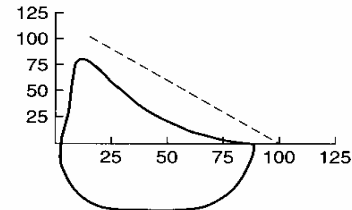
Maximal Inspiratory Flow

- Do FVC maneuver and then inhale as rapidly and as much as able.
- This makes an inspiratory curve.
- The expiratory and inspiratory flow volume curves put together make a flow volume loop.

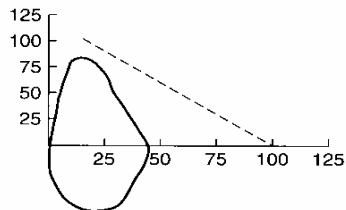
Flow-Volume Loops



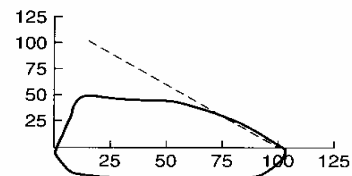
A. Normal



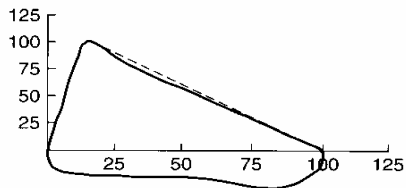
B. Obstructed Intrapulmonary Airways



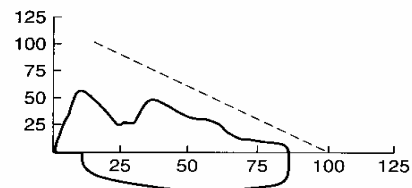
C. Restrictive Lung Disease



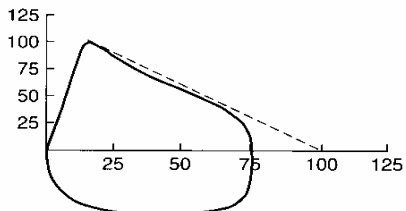
D. Fixed Central or Upper Airways Obstruction



E. Variable Upper Airway Obstruction



F. Inadequate Effort



G. Incomplete Exhalation

(Rudolph and Rudolph, 2003)

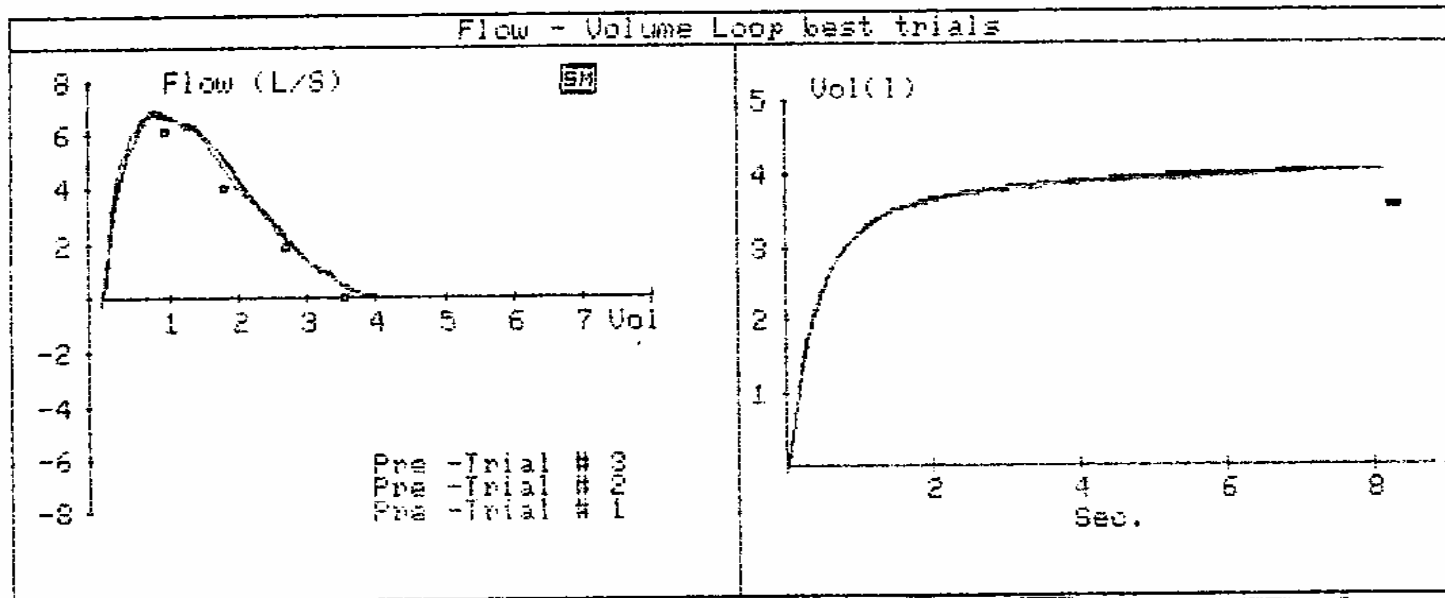
How is a flow-volume loop helpful?

- Helpful in evaluation of air flow limitation on inspiration and expiration
- In addition to obstructive and restrictive patterns, flow-volume loops can show provide information on upper airway obstruction:
 - Fixed obstruction: constant airflow limitation on inspiration and expiration—such as in tumor, tracheal stenosis
 - Variable extrathoracic obstruction: limitation of inspiratory flow, flattened inspiratory loop—such as in vocal cord dysfunction
 - Variable intrathoracic obstruction: flattening of expiratory limb; as in malignancy or tracheomalacia

Spirometry Pre and Post Bronchodilator

- Obtain a flow-volume loop.
- Administer a bronchodilator.
- Obtain the flow-volume loop again a minimum of 15 minutes after administration of the bronchodilator.
- Calculate percent change (FEV1 most commonly used---so % change FEV 1= $[(FEV1 \text{ Post}-FEV1 \text{ Pre})/FEV1 \text{ Pre}] \times 100$).
- Reversibility is with 12% or greater change.

Case #1



# Spirometry #	(BTPS)	Pre-BD		Post-BD		Normal Range	Pred
		Actual	%Pred	Actual	%Pred		
FVC	(L)	4.11	116			2.85	3.53
FEV1	(L)	3.28	108			2.46	3.02
FEV1/FVC	(%)	80	93			77	86
PEFR	(L/S)	6.94	107				6.50
FEF50	(L/S)	4.07	100				4.08
FEF75	(L/S)	1.24	65				1.91
FEF25-75	(L/S)	3.15	88			2.21	3.57

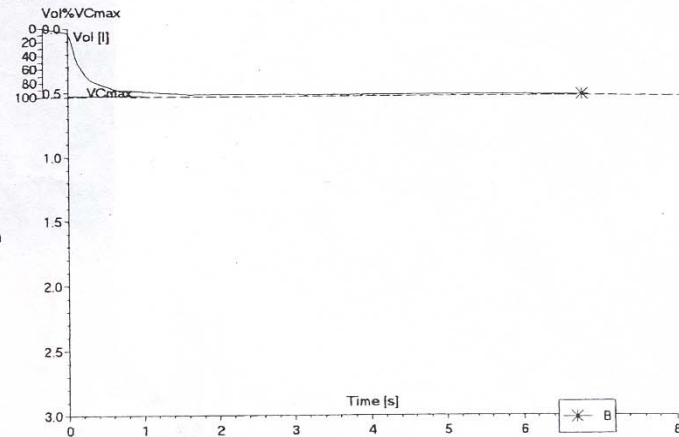
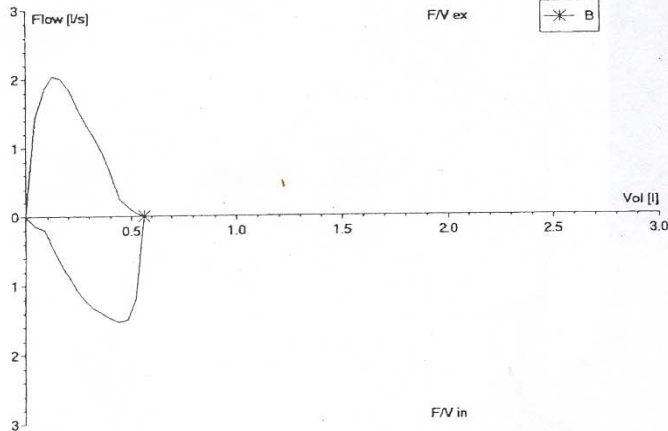
Case #2

SPIROMETRY

	Pred	Best	% Pred.
FVC.....[l]	2.63	0.53	20
FEV 1.....[l]	2.23	0.53	24
FEV 1 % FVC.....[%]	89.23	100.00	112
PEF.....[l/s]	5.41	2.04	38
FEF 50.....[l/s]	2.98	1.35	45
FEF 75.....[l/s]	1.44	0.59	41
MMEF 25/75.....[l/s]	2.59	1.18	45
FET.....[s]		6.83	

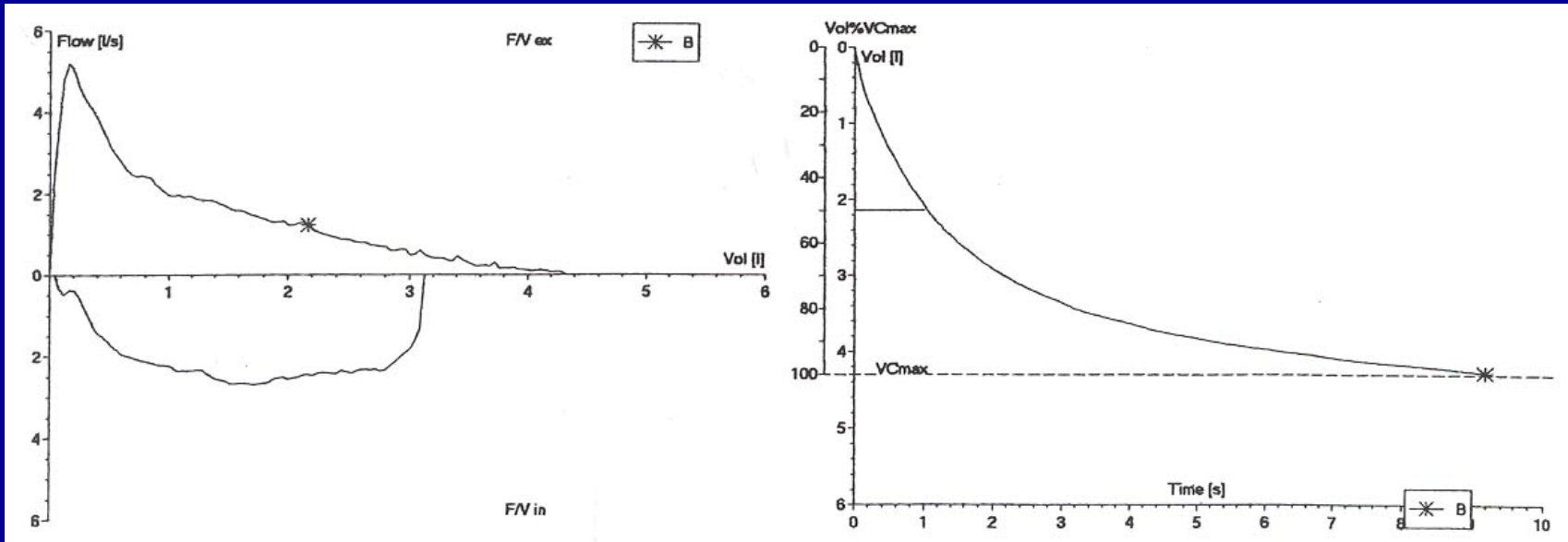
Date

09/19/2002



COMMENT: Muscular Dystrophy: GOOD EFFORT; NO MEDS PRIOR

Case #3



SPIROMETRY

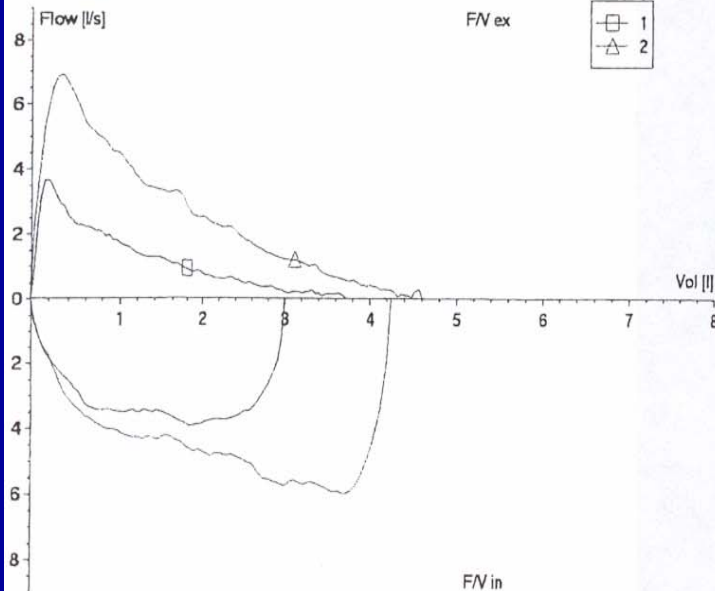
	Pred	Best	% Pred.
FVC.....[l]	4.44	4.31	97
FEV 1.....[l]	3.83	2.15	56
FEV 1 % FVC.....[%]	86.00	49.88	58
PEF.....[l/s]	8.01	5.23	65
FEF 50.....[l/s]	4.79	1.23	26
FEF 75.....[l/s]	2.50	0.41	16
MMEF 25/75.....[l/s]	4.27	0.93	22

Case #4

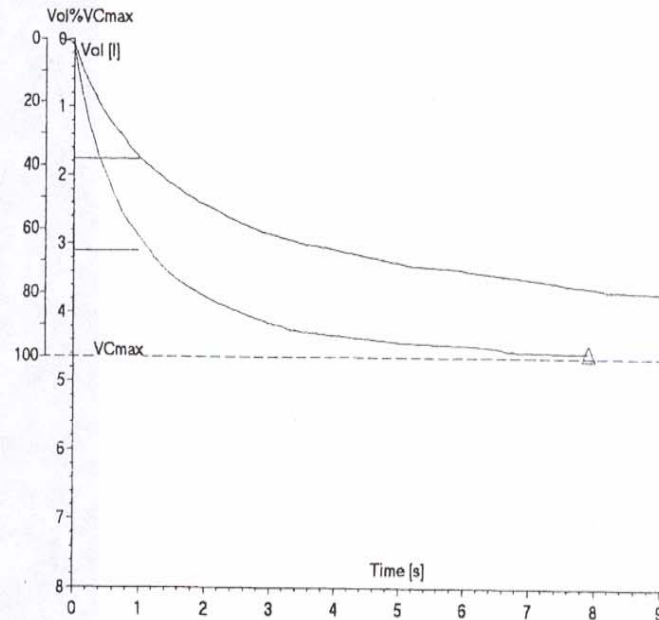
	Pred	Pre	% Pred	Post	% Pred	% Change
FVC.....[l]	3.88	3.77	97	4.66	120	23.38
FEV 1.....[l]	3.34	1.77	53	3.11	93	75.23
FEV 1 % FVC.....[%]	85.27	46.97	55	66.70	78	42.03
PEF.....[l/s]	8.03	3.65	45	6.92	86	89.72
FEF 50.....[l/s]	4.81	0.84	17	2.22	46	163.93
FEF 75.....[l/s]	2.69	0.36	13	0.81	30	124.17
MMEF 25/75.....[l/s]	4.36	0.77	18	1.82	42	137.47
FET.....[s]		9.21		7.97		-13.42

Date
Time

02/26/2004
09:43:48AM



02/26/2004
11:17:42AM



Comment: Asthma; Good effort; No meds prior

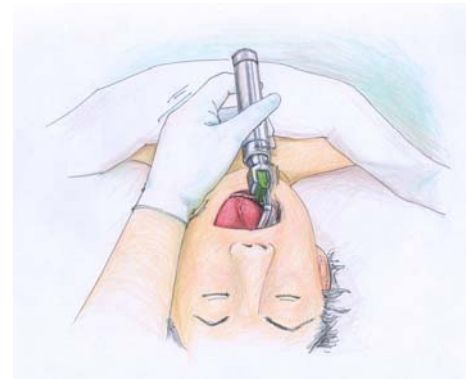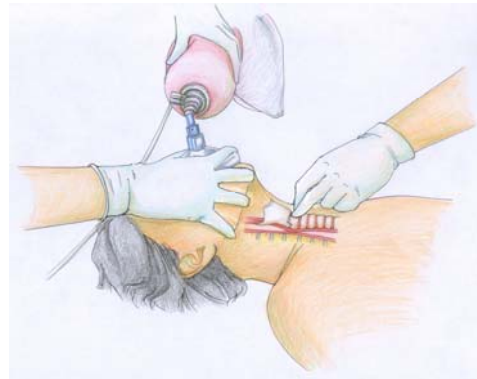
If you see a patient with cough and symptoms of breathing problems connected to airways and lungs, then this presentation will be very useful.

Thanks a lot for your time...
Goodluck everyone!!!



UNIVERSITY OF CAMBRIDGE
LIBRARY
Vito David Horta
12/12/2012

Airway Intubation



Joao Marques de Oliveira

Masaryk University

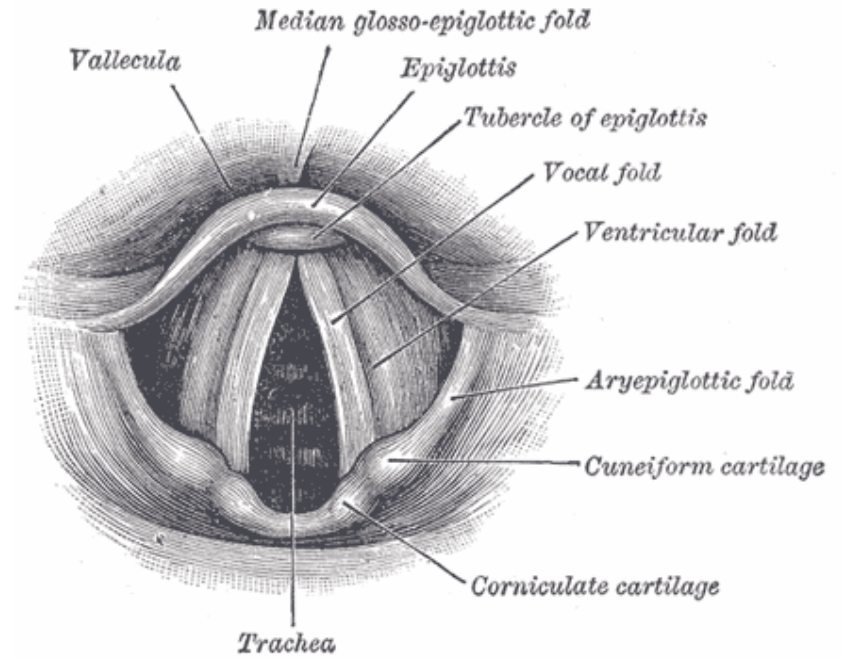
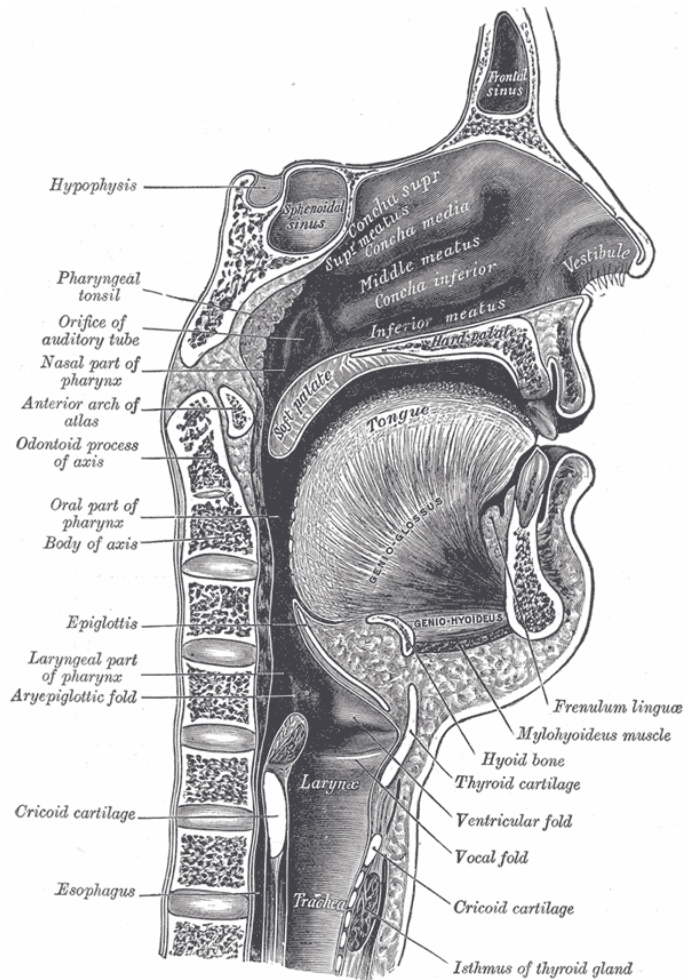
April 2010

Points of Discussion:

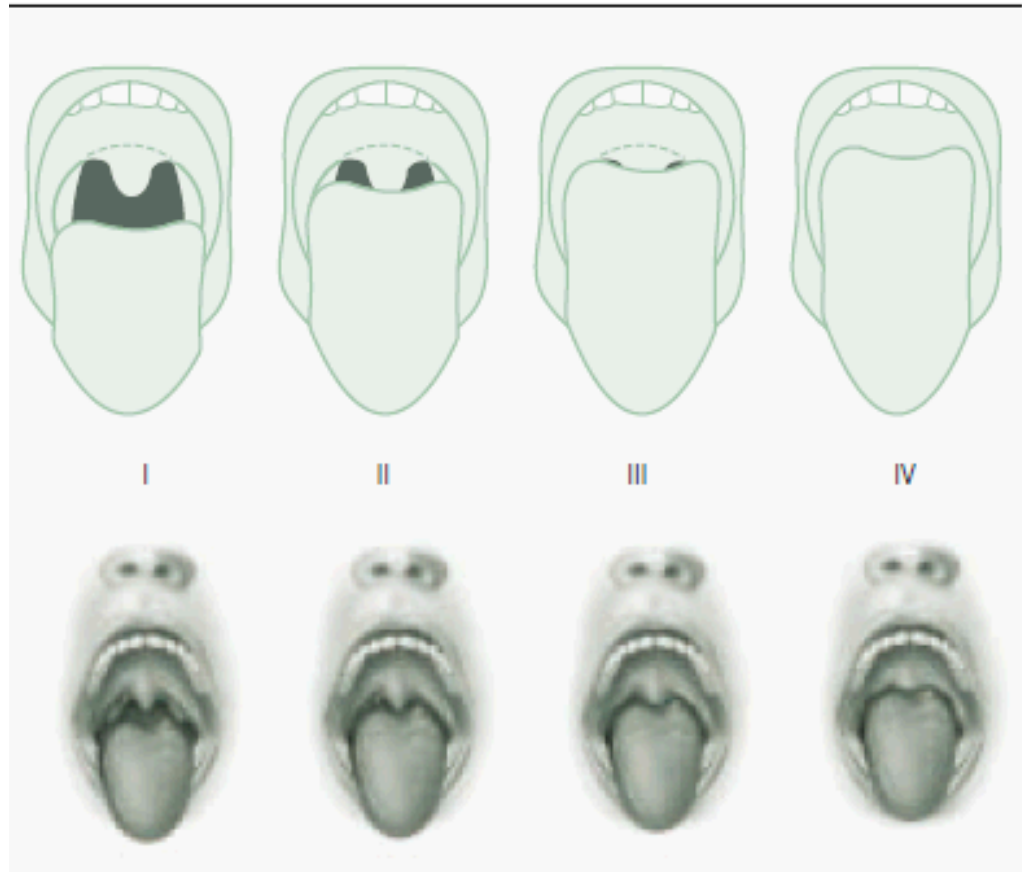
- **Revising Anatomy Structures**
- **What is intubation?**
- **What is the purpose of intubation?**
- **Is there more than one type of intubation?**
- **How's the correct technique?**
- **What kind of instruments are used?**
- **What are the main complications of intubation?**
- **Laryngeal Masks**



Anatomy



Mallampati Classification

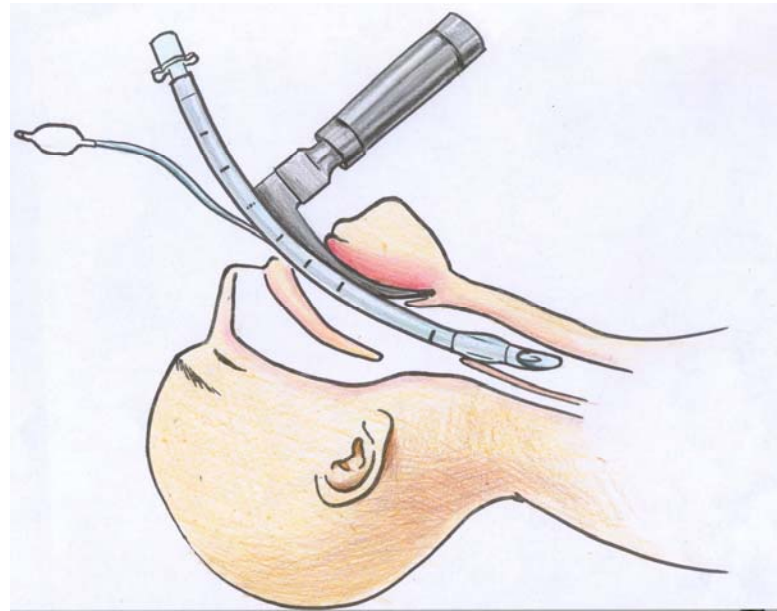


Definitions

What is endotracheal intubation?

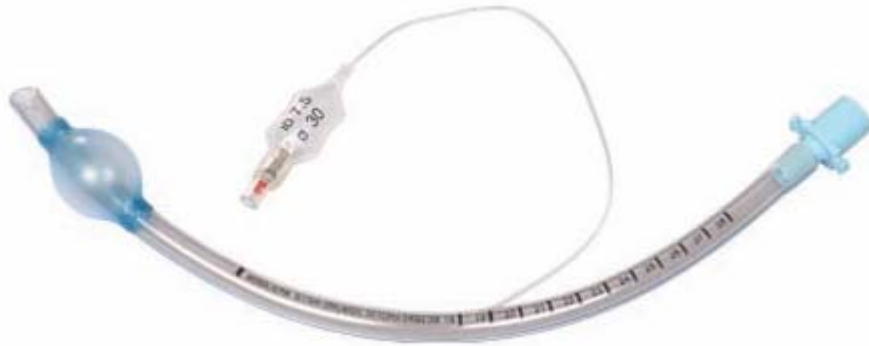Endotracheal intubation is a **procedure** by which a **tube is inserted** through the mouth down **into the trachea** (the large airway from the mouth to the lungs).

Before surgery, this is often done under **deep sedation**. In emergency situations, the patient is often **unconscious** at the time of this procedure.



Main Goal / Purpose of Endotracheal Intubation

- The endotracheal tube serves as an **open passage through the upper airway**.

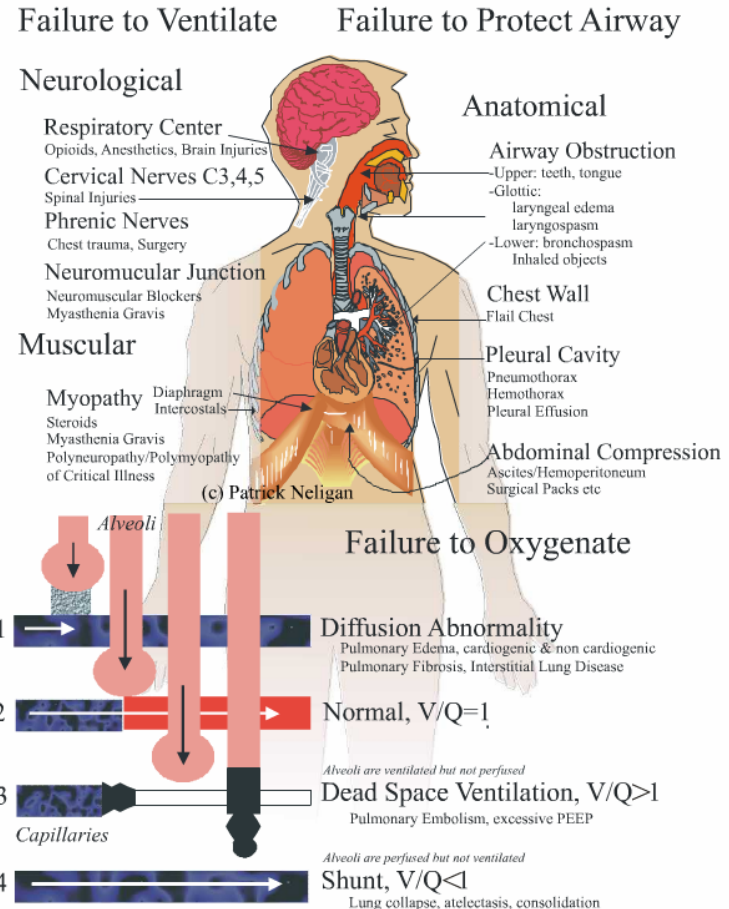


- The purpose of endotracheal intubation is to **permit air to pass freely to and from the lungs** in order to **ventilate** the lungs.
- Endotracheal tubes can be **connected to ventilator machines** to provide artificial respiration. This can help when a patient is unconscious and by maintaining a patent airway, especially during surgery.
- It is often used when patients are **critically ill** and **cannot maintain adequate respiratory function** to meet their needs.

How do i decide to Intubate? – Indications -

1. **Inadequate oxygenation** (decreased arterial PO₂, etc.) that is not corrected by supplemental oxygen supplied by mask
2. **Inadequate ventilation** (increased arterial PCO₂)
3. Need to **control and remove pulmonary secretions** (bronchial toilet)
4. Need to **provide airway protection** in a patient with a depressed gag reflex (for example during a general anesthesia).

Causes of Respiratory Failure



Do not Intubate... – Contraindications -



1. **Severe airway trauma or obstruction** that does not permit safe passage of an endotracheal tube.
2. **Cervical spine injury**, in which the need for complete immobilization of the cervical spine makes endotracheal intubation difficult.

Preparing the Procedure

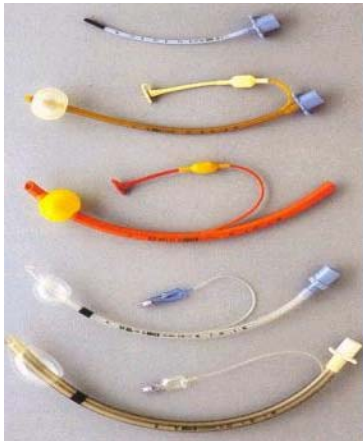
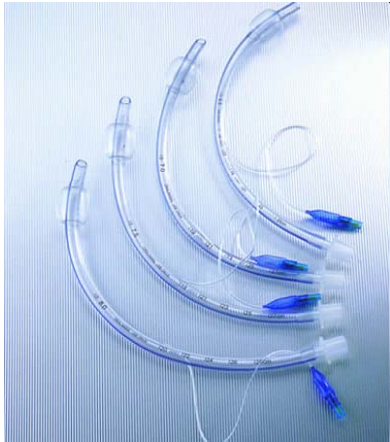Essentials that **must be present** to ensure a **safe intubation**.

They can be remembered by the mnemonic **SALT**

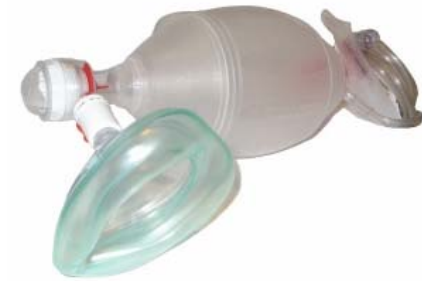

- **Suction**. This is extremely important. Often patients will have material in the pharynx, making visualization of the vocal cords difficult.
- **Airway**. the oral airway is a device that lifts the tongue off the posterior pharynx, often making it easier to mask ventilate a patient. The inability to ventilate a patient is bad. Also a source of O₂ with a delivery mechanism (ambu-bag and mask) must be available.
- **Laryngoscope**. This lighted tool is vital to placing an endotracheal tube.
- **Tube**. Endotracheal tubes come in many sizes. In the average adult a size 7.0 or 8.0 oral endotracheal tube will work just fine.

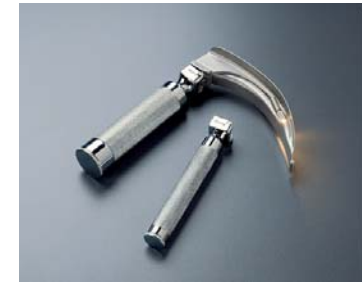Instruments used...



1. Self-refilling bag-valve combination (eg, **Ambu bag**) or bag-valve unit (Ayres bag), connector, tubing, and oxygen source. Assemble all items before attempting intubation.



2. **Laryngoscope** with curved (Macintosh type) and straight (Miller type) blades of a size appropriate for the patient.

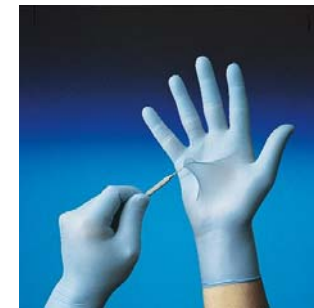
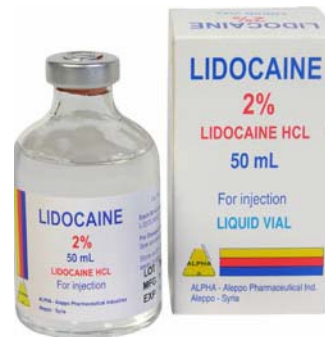
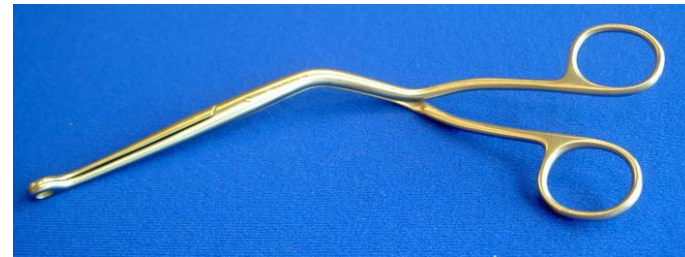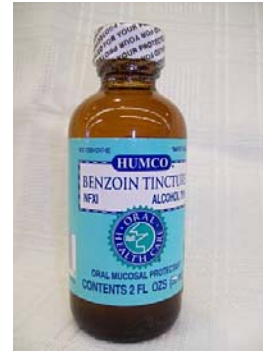3. **Endotracheal tubes** of several different sizes. Low-pressure, high-flow cuffed balloons are preferred.



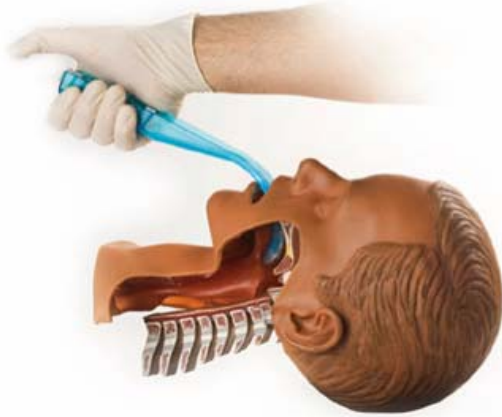Instruments used... (II)

5. Tincture of **benzoin** and precut **tape**.
6. Introducer (stylets or **Magill forceps**).
7. Suction apparatus (tonsil tip and catheter suction).
8. **Syringe**, 10-mL, to inflate the cuff.
9. **Mucosal anesthetics** (eg, 2% lidocaine)
10. Water-soluble sterile lubricant.
11. **Gloves**.

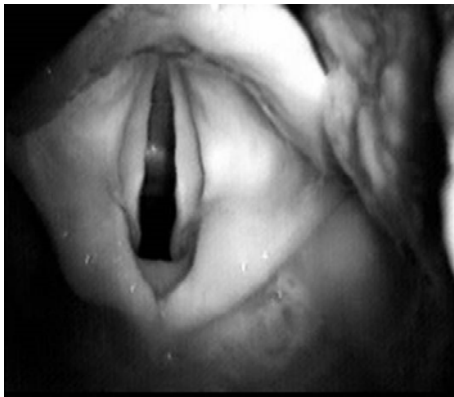




- **TECHNIQUE**



MADgicWand™ Mucosal Atomization Device
for atomizing topical solutions. With 5mL syringe



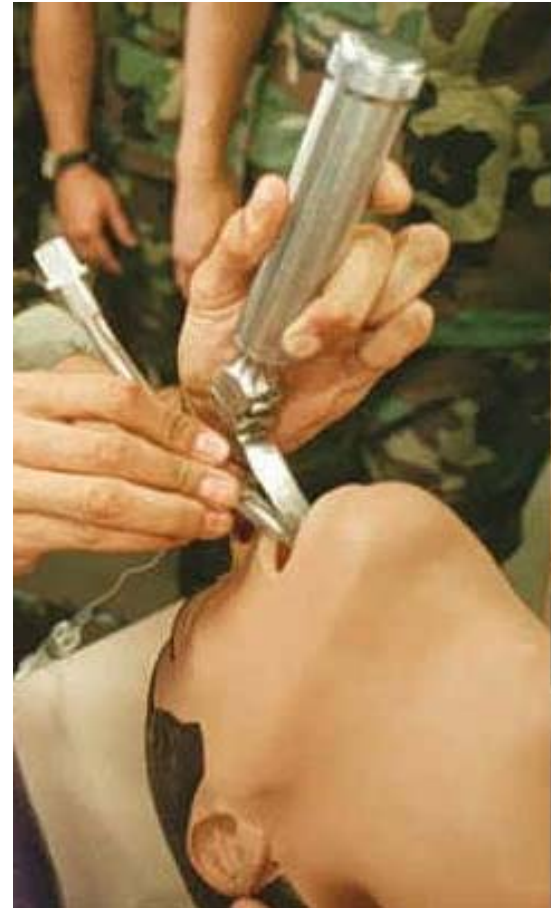Topical Anesthesia: Anesthetize the mucosa of the oropharynx, and upper airway with **lidocaine 2%**, if time permits and the patient is awake.

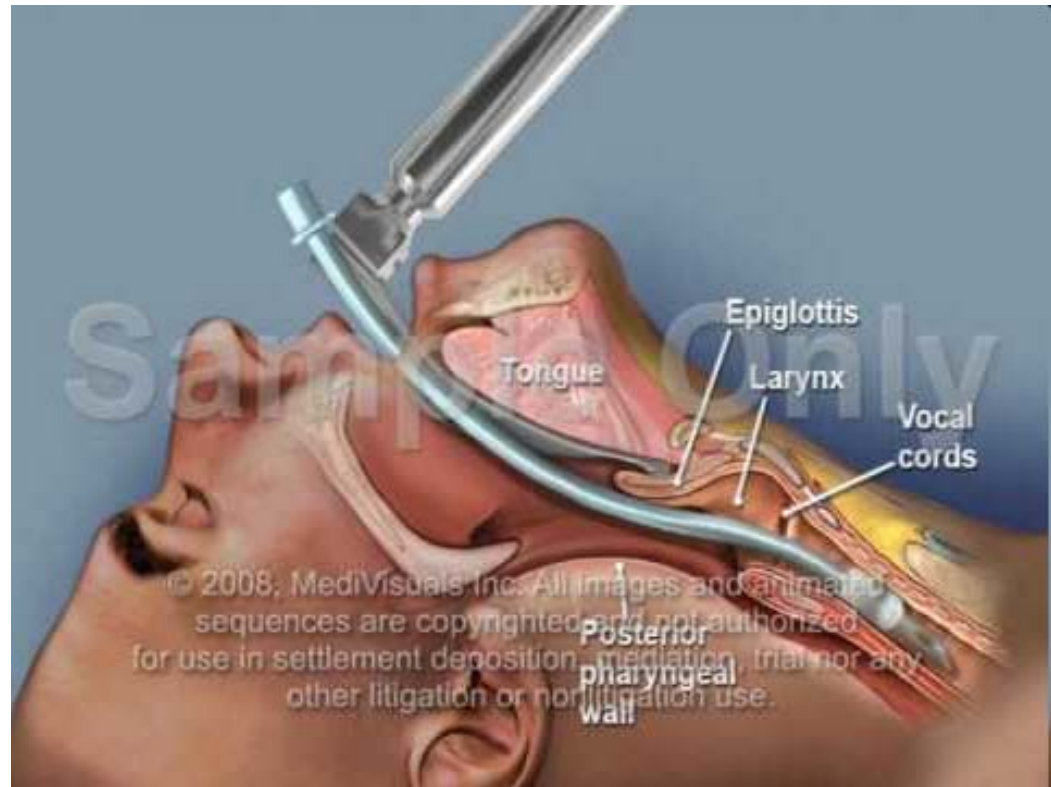
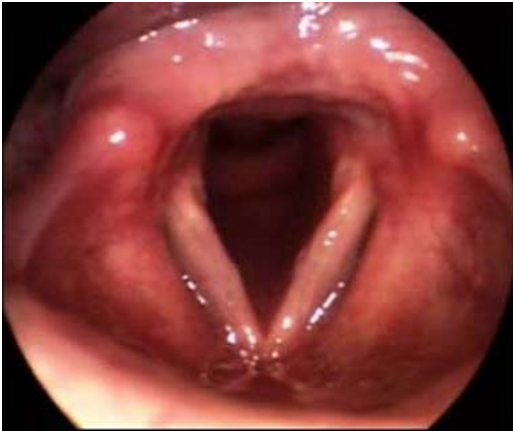Direct Laryngoscopy:

1. Place the patient in the sniffing position.
2. Check the laryngoscope and blade for proper fit, and make sure that the light works.
3. Make sure that all materials are assembled and close at hand.

Curved blade technique

- a) **Open the patient's mouth** with the right hand, and remove any dentures.
- b) Grasp the **laryngoscope in the left hand**
- c) Spread the patient's lips, and **insert the blade** between the teeth, being careful not to break a tooth.
- d) Pass the **blade to the right of the tongue**, and advance the blade **into the hypopharynx**, pushing the tongue to the left.
- e) **Lift the laryngoscope upward and forward**, without changing the angle of the blade, to expose the vocal cords.





Curved blade technique (II)

- f) The anesthesiologist then takes the **endotracheal tube**, made of flexible plastic, in the right hand and **starts inserting it through the mouth opening**.
- g) The tube is inserted **through the cords** to the point that the cuff rests just below the cords
- h) Finally, the **cuff is inflated** to provide a minimal leak when the bag is squeezed

Using a **stethoscope** , the anesthesiologist listens for breathing sounds to ensure correct placement of the tube

Document the view of the larynx obtained during laryngoscopy using the following criteria:

Grade I: full view of the cords

Grade II: partial view of the cords

Grade III: view of the epiglottis

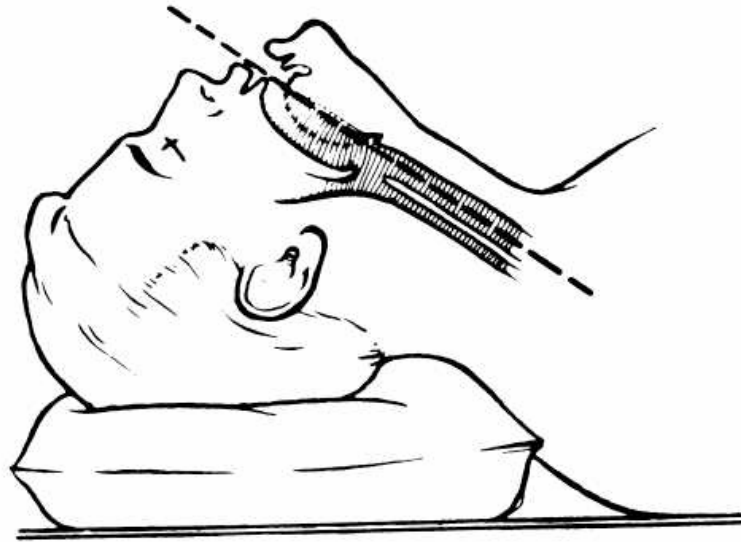
Grade IV: No view of the cords or epiglottis

<http://www.youtube.com/watch?v=eRkleyIji9U>

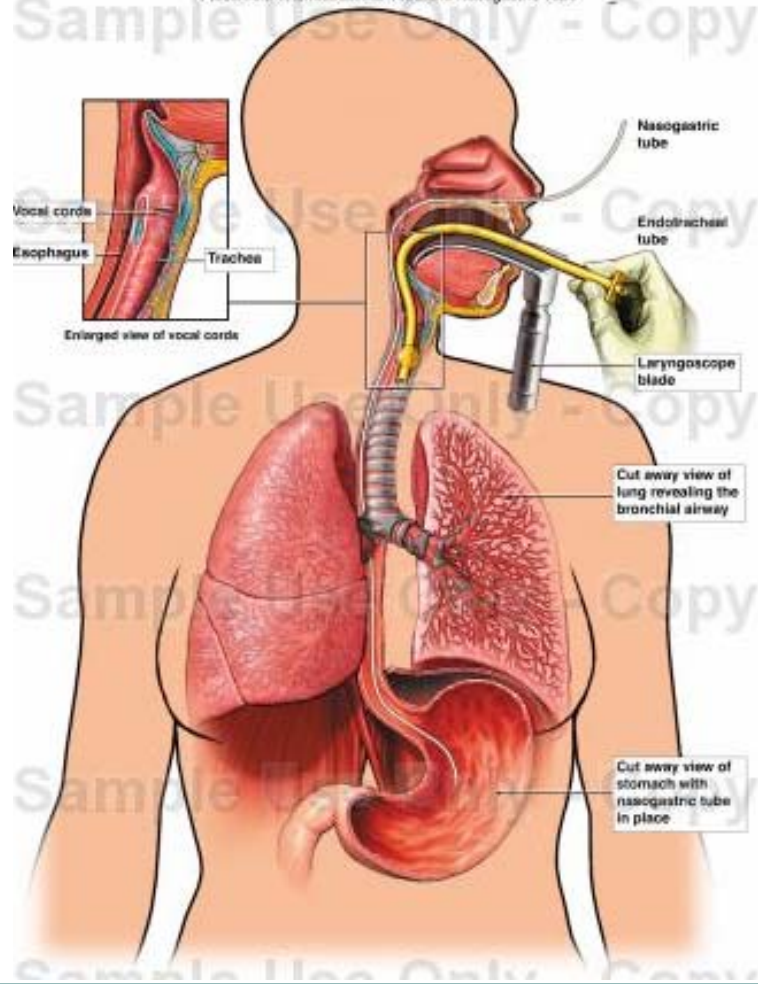
Straight blade technique

Follow the steps outlined for curved blade technique, but **advance the blade down the hypopharynx**, and **lift the epiglottis** with the tip of the blade to **expose the vocal cords**.

The tip of the laryngoscope **blade fits below the epiglottis**, which is no longer visible with the blade in position.



Placement of Endotracheal Tube and Nasogastric Tube



Complications

1. Tube **malpositioning** (esophageal intubation)
2. **Tube malfunction** or physiologic responses to airway instrumentation
3. Trauma such as **tooth damage**, lip/tongue/mucosal **laceration**, sore throat, dislocated mandible
4. **Mucosal inflammation** and **ulceration** and excoriation of nose can occur while the tube is in place
5. **Laryngeal malfunction** and aspiration, glottic, subglottic or tracheal **edema** and **stenosis**, vocal cord granuloma or **paralysis during extubation**

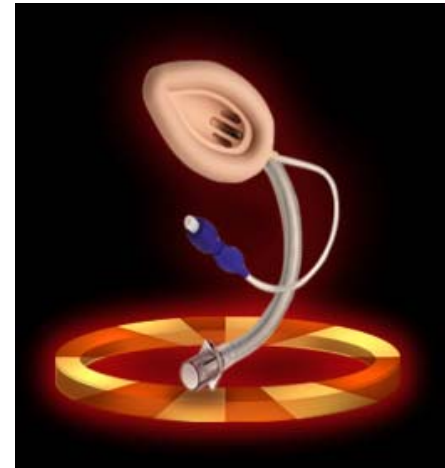
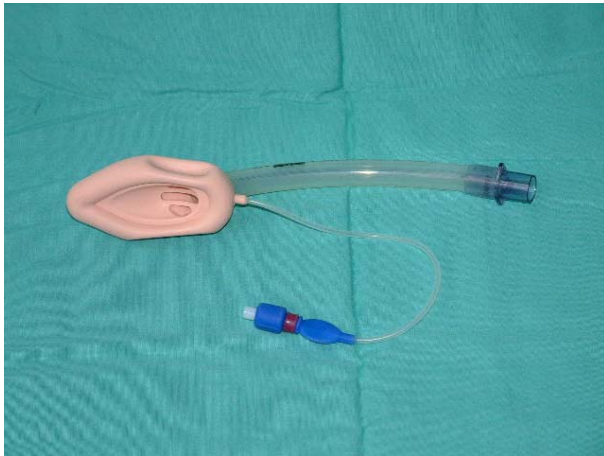
Physiologic responses to intubation include hypertension, tachycardia, intracranial hypertension, and laryngospasm

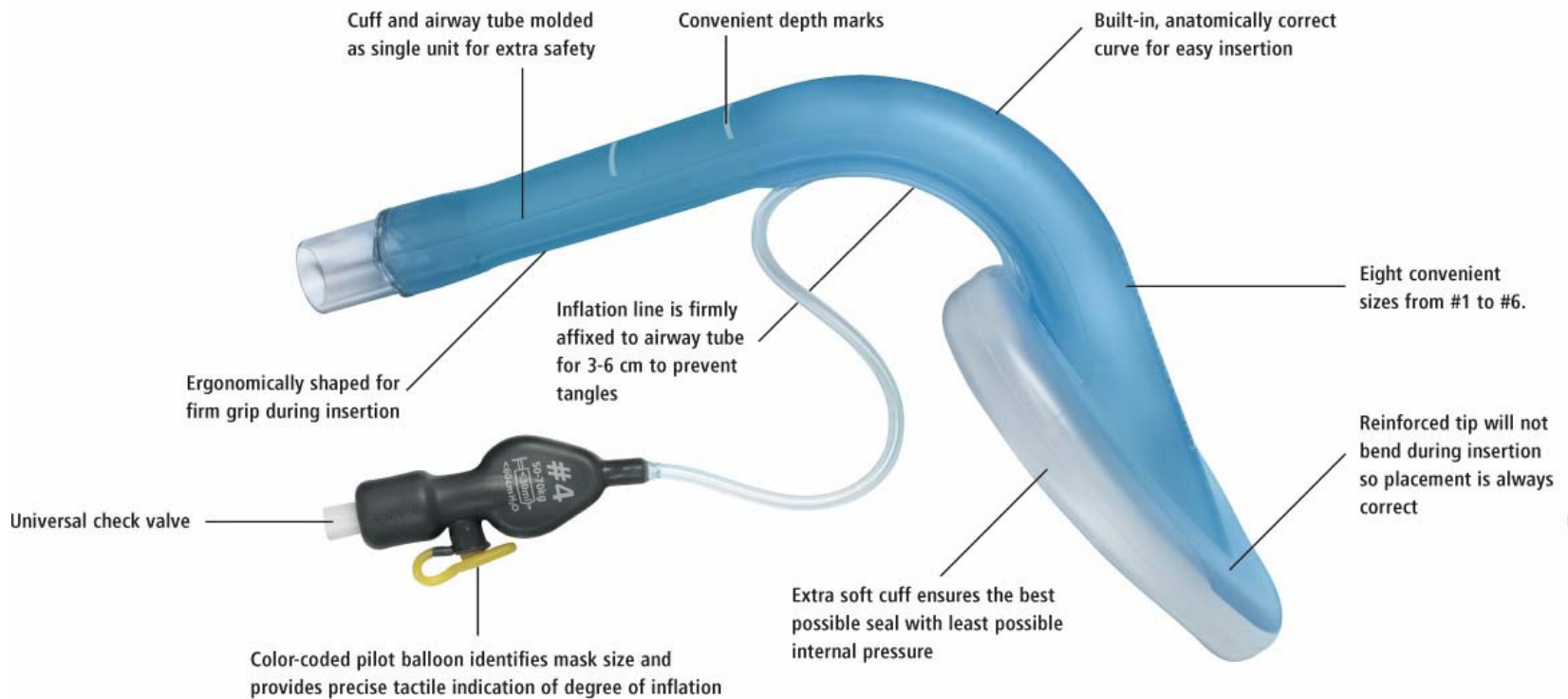
Laryngeal Masks (LMA)

The Laryngeal Mask Airway is an **alternative airway** device used for anesthesia and airway support.

- They cause **less pain** and coughing than an endotracheal tube, and are much **easier to insert**

It **consists of an inflatable silicone mask and rubber connecting tube**. It is inserted blindly into the **pharynx**, forming a low-pressure seal around the laryngeal inlet and permitting gentle **positive pressure ventilation**. All parts are latex-free





Laryngeal Masks (II)

Indications:

When **endotracheal intubation is not necessary** or it's difficult

Contraindications:

- Non-fasted patients
- Morbidly obese patients
- Obstructive or abnormal lesions of the oropharynx

Air entry is confirmed by listening for air entry into the lungs with a stethoscope

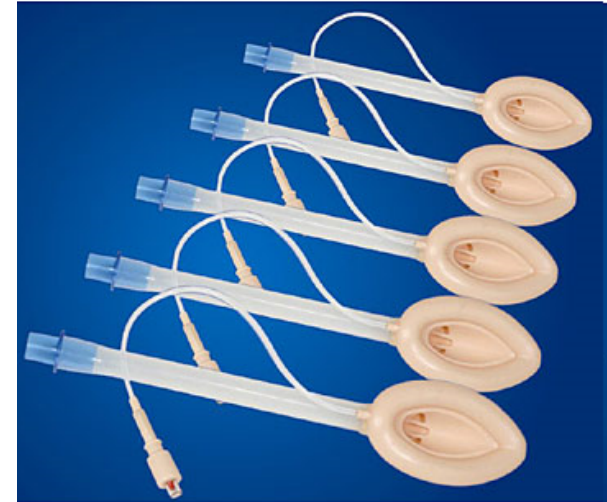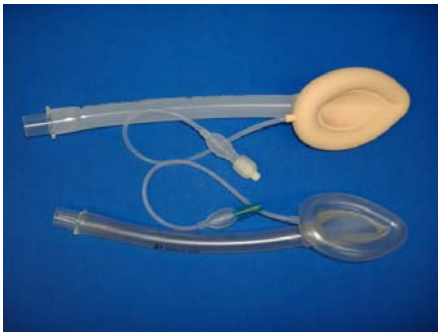Short Procedure:

1. The **cuff of the mask is deflated** before insertion and **lubricated**.
2. The patient is **sedated** or fully anaesthetized if conscious, and their neck is extended and their **mouth opened widely**.
3. The **apex** of the mask, with its open end pointing **downwards toward the tongue**, is pushed backwards towards the uvula.
4. The cuff follows the natural bend of the oropharynx, and its long walls come to **rest over the piriform fossa**.
5. Once placed, the cuff around the mask is **inflated** with air to create a tight seal.

Advantages vs. Disadvantages

Advantages:

- Allows rapid access
- Does not require laryngoscope
- Relaxants not needed
- Provides airway for spontaneous or controlled ventilation
- Tolerated at lighter anesthetic planes



Disadvantages:

- Does not fully protect against aspiration in the non-fasted patient
- Requires re-sterilization

THANK YOU!



Administration Of Oxygen Therapy



Richard Dolan

Oxygen Therapy.

- Oxygen therapy is the administration of oxygen as a medical intervention. For a variety of purposes in both acute and chronic patient care.
- Oxygen is essential for cell metabolism, and in turn, tissue oxygenation is essential for all normal physiological functions.
- Room air only contains 21% oxygen, and increasing the fraction of oxygen in the breathing gas increases the amount of oxygen in the blood.
- It is often only required to raise the fraction of oxygen delivered to 30–35% and this is done by use of a nasal cannula.



Oxygen Therapy.

- When 100% oxygen is needed, it may be delivered via a tight-fitting face mask, or by supplying 100% oxygen to an incubator in the case of infants.
- Oxygen can be administered in other ways, including specific treatments at raised air pressure, such as hyperbaric oxygen therapy.

Indications For Use.

- **Chronic conditions, patient with COPD, a common long term effect of smoking, patients need more oxygen to breathe during a temporary worsening of this condition or full time through day and night.**
- **Acute conditions, oxygen used in emergency medicine, like in resuscitations, major trauma, anaphylaxis, major haemorrhage, shock and hypothermia.**

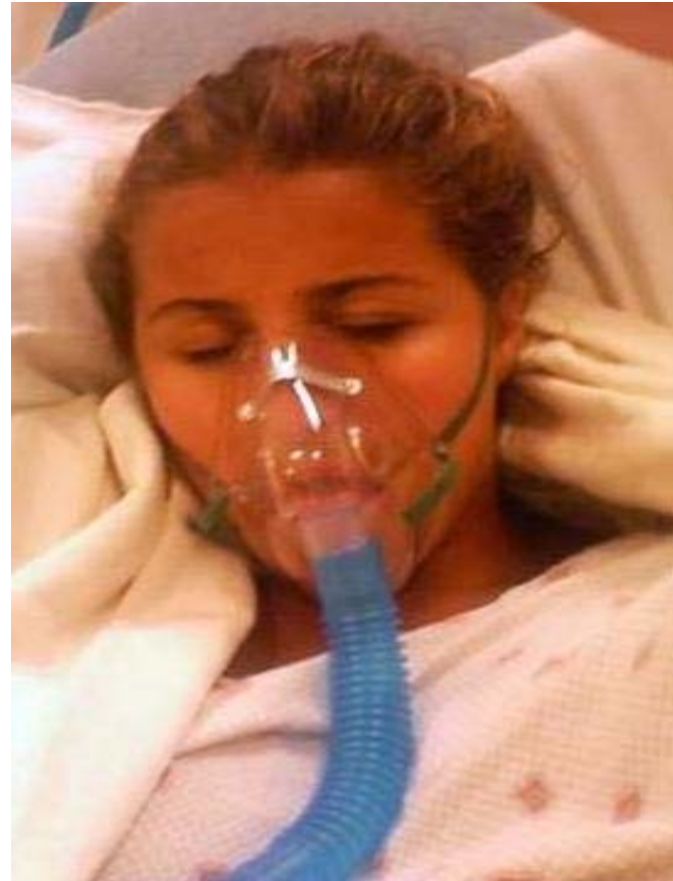

Delivery.

- Various devices are used for administration of oxygen.
- Most often, the oxygen will flow through a pressure regulator, used to control the high pressure of oxygen delivered from a cylinder, to a lower pressure.
- This lower pressure is then controlled by a flowmeter, which may be preset or selectable, and this controls the flow in a measure such as litres per minute (lpm).
- The typical flowmeter range for medical oxygen is between 0 and 15 lpm with some units able to obtain up to 25 liters per minute.

Supplemental oxygen.

- Majority of patients require only a supplementary level of oxygen in the room air they are breathing, rather than pure oxygen.
- A nasal cannula (NC) is a thin tube with two small nozzles that protrude into the patient's nostrils. It can only comfortably provide oxygen at low flow rates, 0.25-6 litres per minute (LPM), delivering a concentration of 24-40%. (pic on previous slide).
- Also, the face mask option, such as the simple face mask!
- Often used at between 5 and 15 LPM, with a concentration of oxygen to the patient of between 28% and 50%.
- Venturi masks, which can accurately deliver a predetermined oxygen concentration to the trachea up to 40%.



Supplemental oxygen.

- In some cases, oxygen can be delivered using a partial re breathing mask, based on a simple mask but has a reservoir bag, which increases the provided oxygen rate to 40 – 70% oxygen at 5 – 15 lpm.

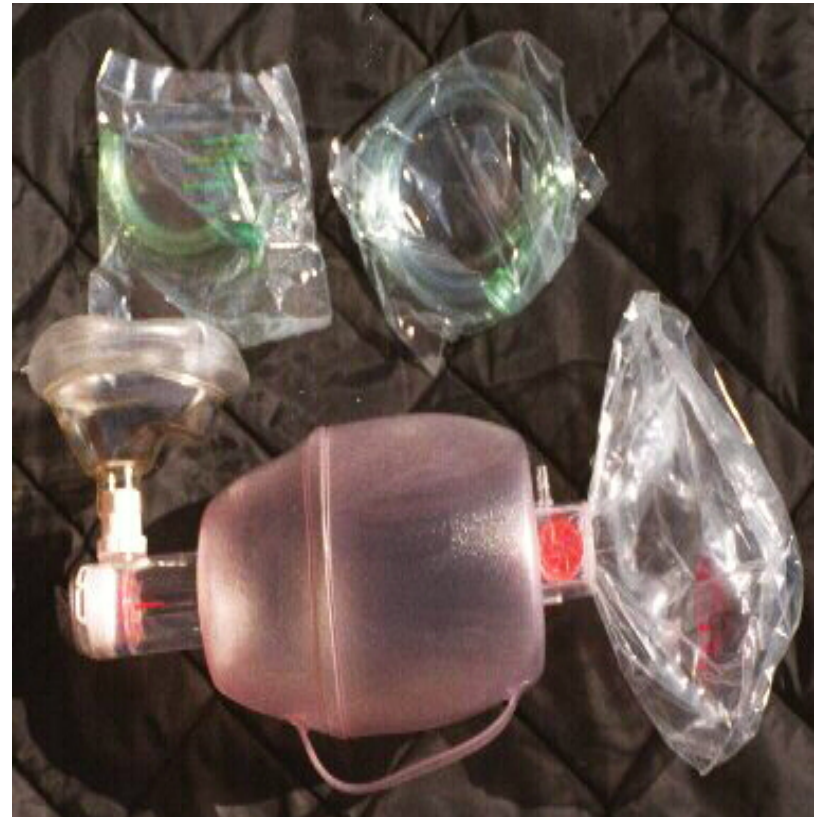

High flow oxygen delivery.

- In cases where the patient requires a flow of up to 100% oxygen, a number of devices are available, with the most common being the non-rebreather mask (or reservoir mask).
- This is similar to the partial rebreathing mask except it has a series of one-way valves preventing exhaled air from returning to the bag.
- There should be a minimum flow of 10 L/min.
- The delivered FIO₂ of this system is 60-80%, depending on the oxygen flow and breathing pattern.

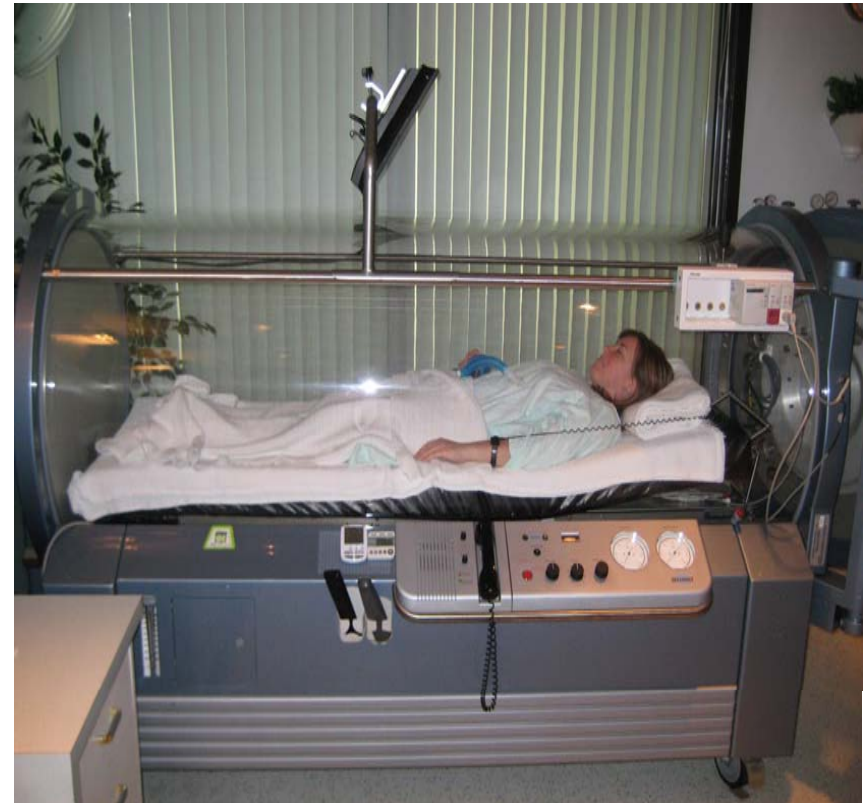Positive pressure delivery.

- Patients who are unable to breathe on their own will require positive pressure to move oxygen in to their lungs for gaseous exchange to take place.
- Systems for delivering this vary in complexity (and cost), starting with a basic pocket mask, which can be used by a basically trained first aider to manually deliver artificial respiration with supplemental oxygen delivered through a port in the mask.
- Many emergency medical service and first aid personnel, as well as hospitals, will use a bag-valve-mask (BVM), which is a malleable bag attached to a face mask, usually with a reservoir bag attached, which is manually manipulated by the healthcare professional to push oxygen (or air) in to the lungs.



Hyperbaric oxygen therapy.

- Therapeutic principle of HBOT lies in its ability to drastically increase partial pressure of oxygen in the tissues of the body. The oxygen partial pressures achievable using HBOT are much higher than those achievable while breathing pure oxygen at normobaric conditions (i.e. at normal atmospheric pressure);
- Hyperbaric oxygen therapy (HBOT), is the medical use of oxygen at a level higher than atmospheric pressure.
- The increased overall pressure is of therapeutic value when HBOT is used in the treatment of decompression sickness and air embolism. (Prevention of decompression syndrome is for the diver to make decompression stops on his way up to surface).



Indications for HBOT.

- Air or gas embolism.
- Carbon monoxide poisoning.
- Clostridial myositis and myonecrosis (gas gangrene)
- Decompression sickness.
- Intracranial abscess
- Big blood loss (anemia).

Oxygen Toxicity.

Symptoms of Oxygen toxicity

Eyes

- Visual field loss
- Near-sightedness
- Cataract formation
- Bleeding
- Fibrosis

Central

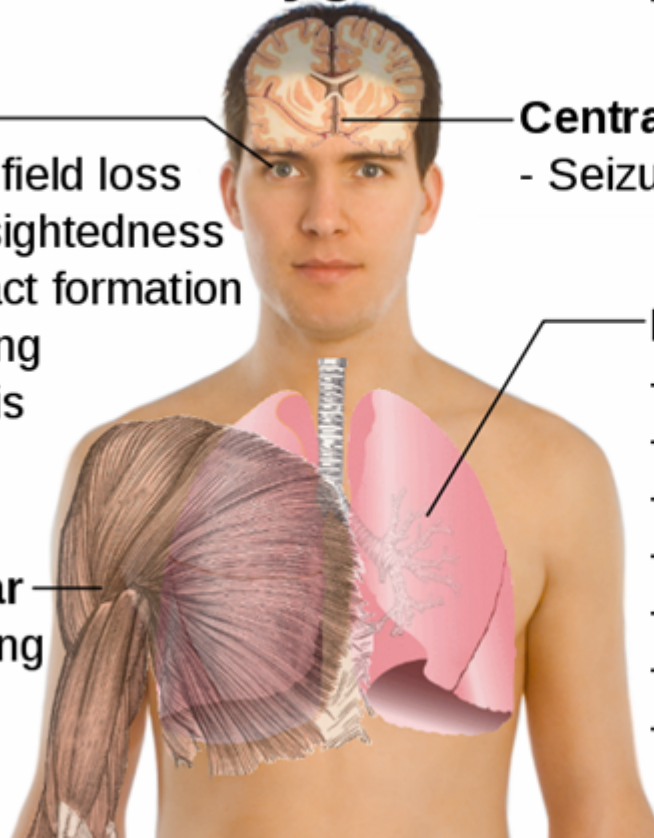
- Seizures

Respiratory

- Jerky breathing
- Irritation
- Coughing
- Pain
- Shortness of breath
- Tracheobronchitis
- Acute respiratory distress syndrome

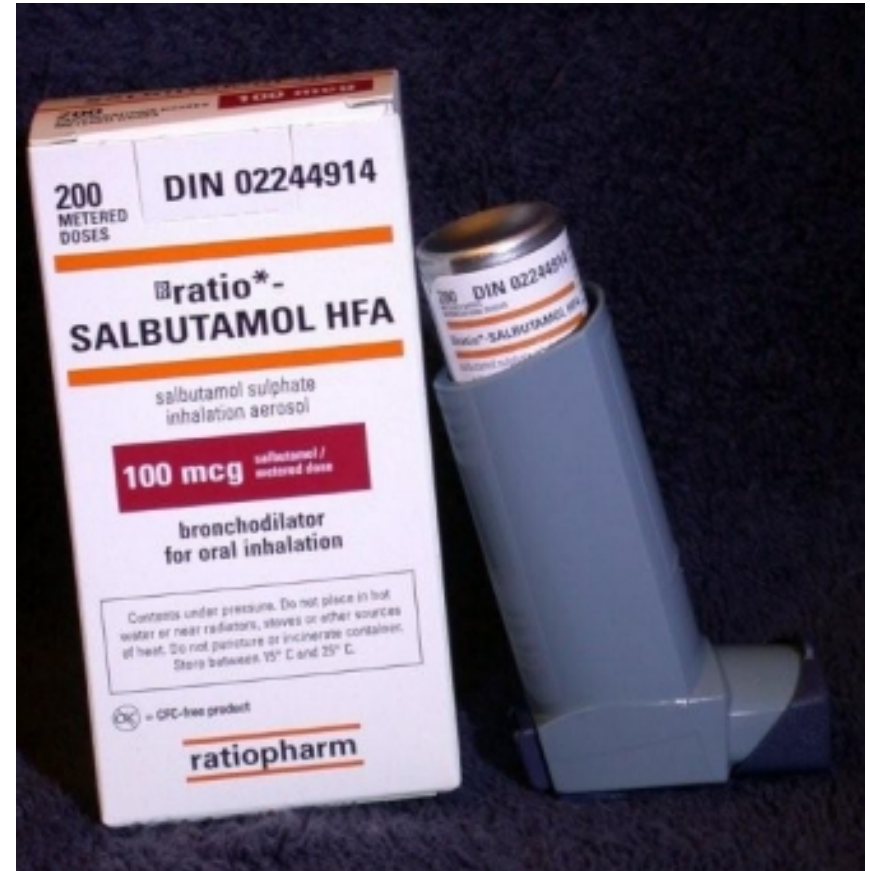Muscular

- Twitching



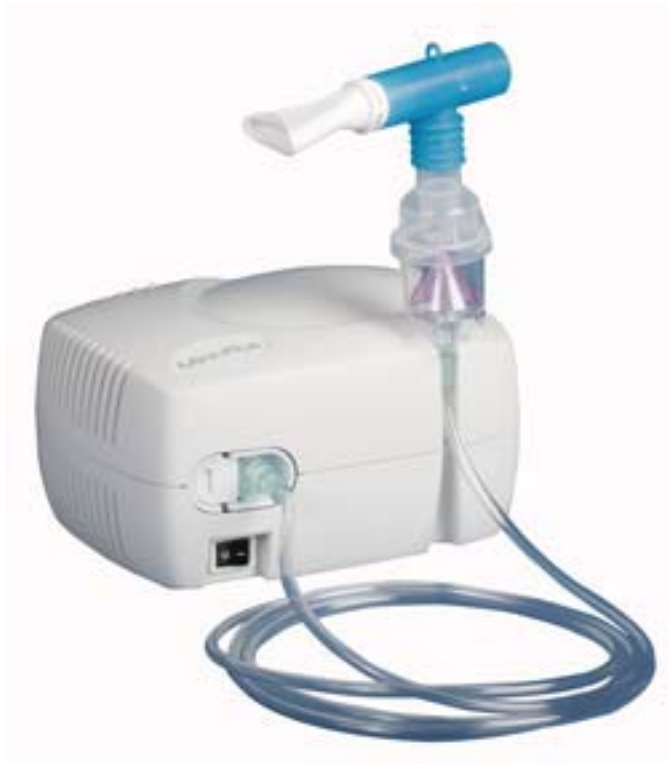As a drug delivery route

- Oxygen therapy can also be used as part of a strategy for delivering drugs to a patient.
- The usual example of this being through a nebulizer mask, which delivers nebulizable drugs such as salbutamol or epinephrine into the airways by creating a vapor-mist from the liquid form of the drug .



Thanks For Listening

Using a nebulizer and inhaler correctly.



Richard Dolan

Nebulizer.

- A Nebulizer is a device used to administer medication to people in the form of a mist inhaled into the lungs.
- Commonly used in treating cystic fibrosis, asthma, COPD and other respiratory diseases.
- The common technical principal for all nebulizers, is to either use oxygen, compressed air or ultrasonic power, as means to break up medical solutions/suspensions into small aerosol droplets, for direct inhalation from the mouthpiece of the device.

Use and attachments.

- Nebulizers accept their medicine in the form of a liquid solution, which is often loaded into the device upon use.
- Corticosteroids and Bronchodilators such as salbutamol are often used.
- The reason these pharmaceuticals are inhaled instead of ingested is in order to target their effect to the respiratory tract, which speeds onset of action and reduces side effects, compared to other alternative intake routes.



Nebulizer.

- The most commonly used nebulizers are the Jet Nebulizers.
- Jet nebulizers are connected by tubing to a compressor, that causes air or oxygen to blast at high velocity through a liquid medicine to turn it into an aerosol.
- Aerosol is then inhaled by the patient.



Inhalers.

- Instead of using nebulizers to deliver a medical liquid to the lungs in the form of aerosol droplets, its also possible to use inhalers for the same purpose.
- It is mainly used in the treatment of asthma and COPD.
- Pictured is the pressurised metered dose inhaler (MDI), the most common type of inhaler.



Use

- In MDI's, medication is most commonly stored in solution in a pressurized canister that contains a propellant.
- The MDI canister is attached to a plastic, hand-operated actuator.
- On activation, the metered-dose inhaler releases a fixed dose of medication in aerosol form.

Use

- The correct procedure for using an MDI is to first fully exhale, place the mouth-piece of the device into the mouth, and having just started to inhale at a moderate rate, depress the canister to release the medicine.
- The aerosolized medication is drawn into the lungs by continuing to inhale deeply before holding the breath for 10 seconds to allow the aerosol to settle onto the walls of the bronchial and other airways of the lung.



Categories

- Bronchodilator Inhalers: Short-Acting Beta-2 Adrenergic Bronchodilator Inhalers
- Daily Inhalers: Long-Acting Adrenergic Bronchodilator Inhalers
- Daily Inhalers: Anticholinergic Bronchodilators in COPD
- Daily Inhalers: Corticosteroids
- Combination Inhalers: Corticosteroid with LongActing Beta-2 Adrenergic Agonist



CLINICAL SESSIONS 2010

Feedback – 11 Q's



- 1) How would you rate clinical sessions out of 10? (0 = poor, 10 = best)
- 2) What did you find helpful about clinical sessions?
- 3) What were the bad parts of clinical sessions?
- 4) What other topics would you like to have seen?
- 5) Do you think the topics were covered in enough detail?
- 6) What improvements can be made to clinical sessions? (e.g. organization, structure, promotion and presentations)
- 7) Do you have any ideas for future educational projects? If so, what are they? What other areas of medicine would you like to see being explained? (e.g. ECG?, more clinical skills?, differential diagnoses?, case studies? etc?)

Use back of page if you need more space!

- 8) Do you think clinical sessions was promoted enough, so that it was accessible by all the international students?
- 9) Have you downloaded any of the presentations from the website yet? If not, what is the reason?
- 10) Would you prefer such courses to be organized, promoted and run through an official student university organization in future, or would you rather it stay independent?
- 11) If you have any more ideas to put forward or would like to actively participate in the running of future educational projects like clinical sessions, please write your name and email below, or make a mention on the facebook group page.

Thanks for your time and support!



Please turn over...

--- CLINICAL SESSIONS 2010 ---