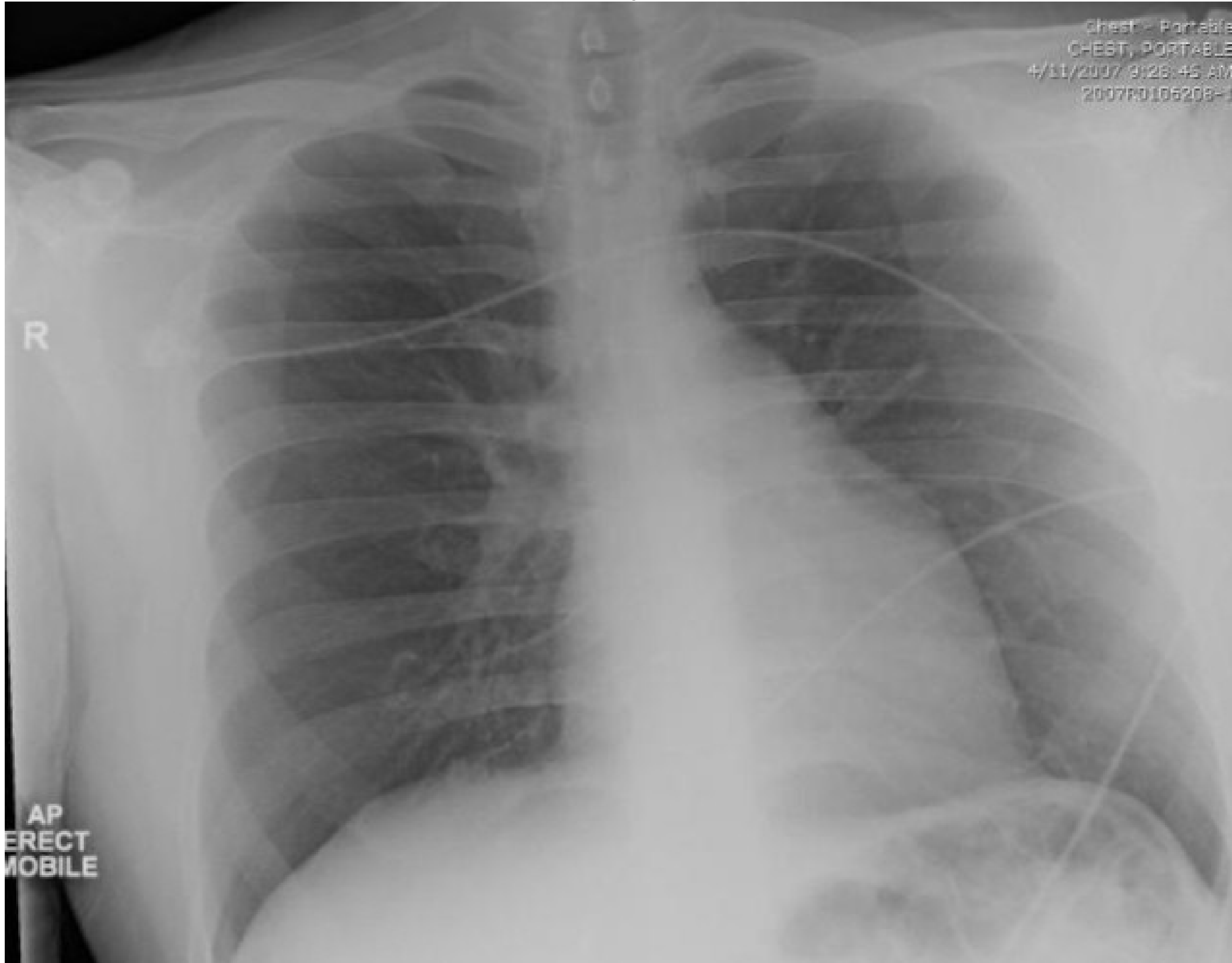


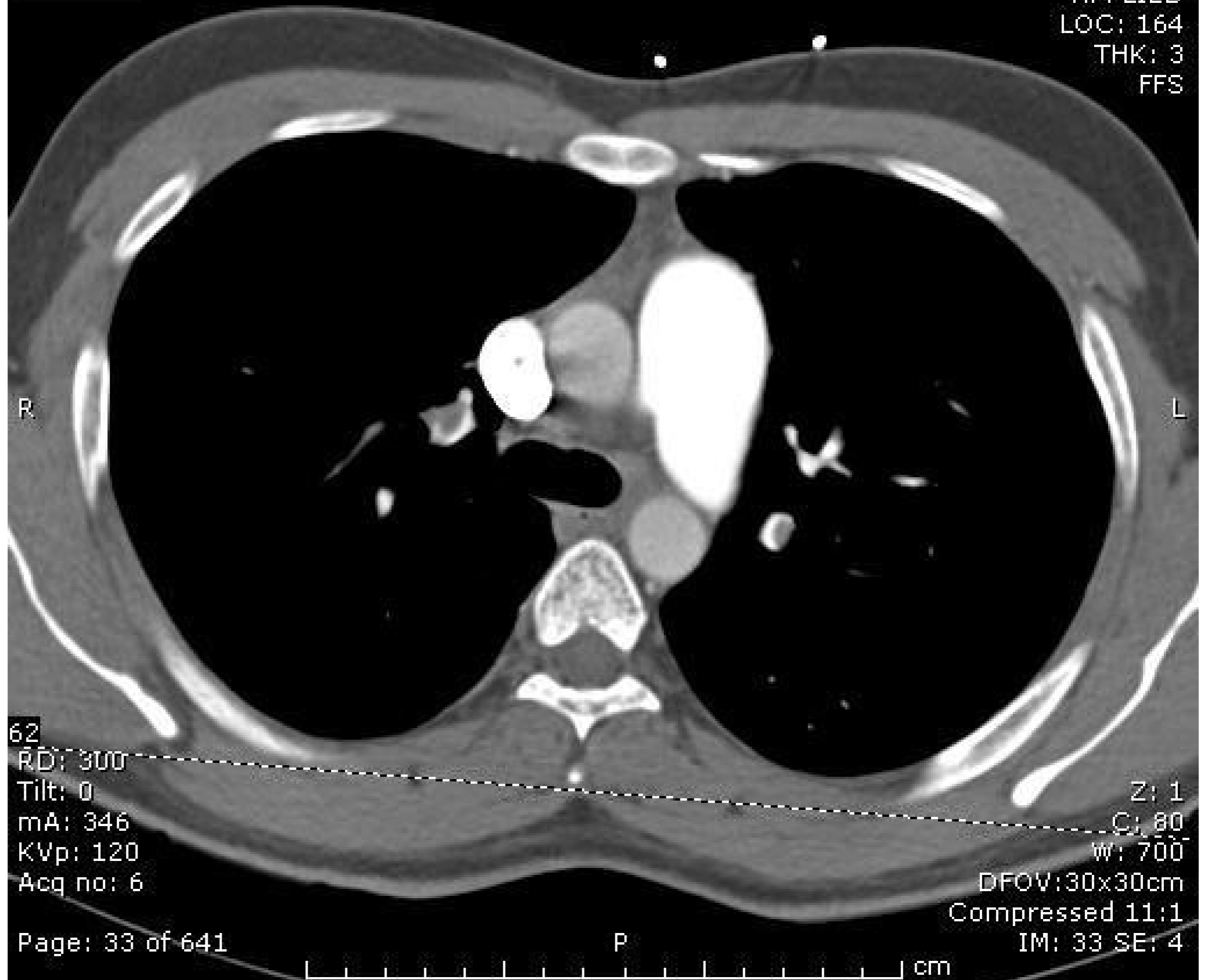
Life in the fast lane - pictures

Chest X-ray

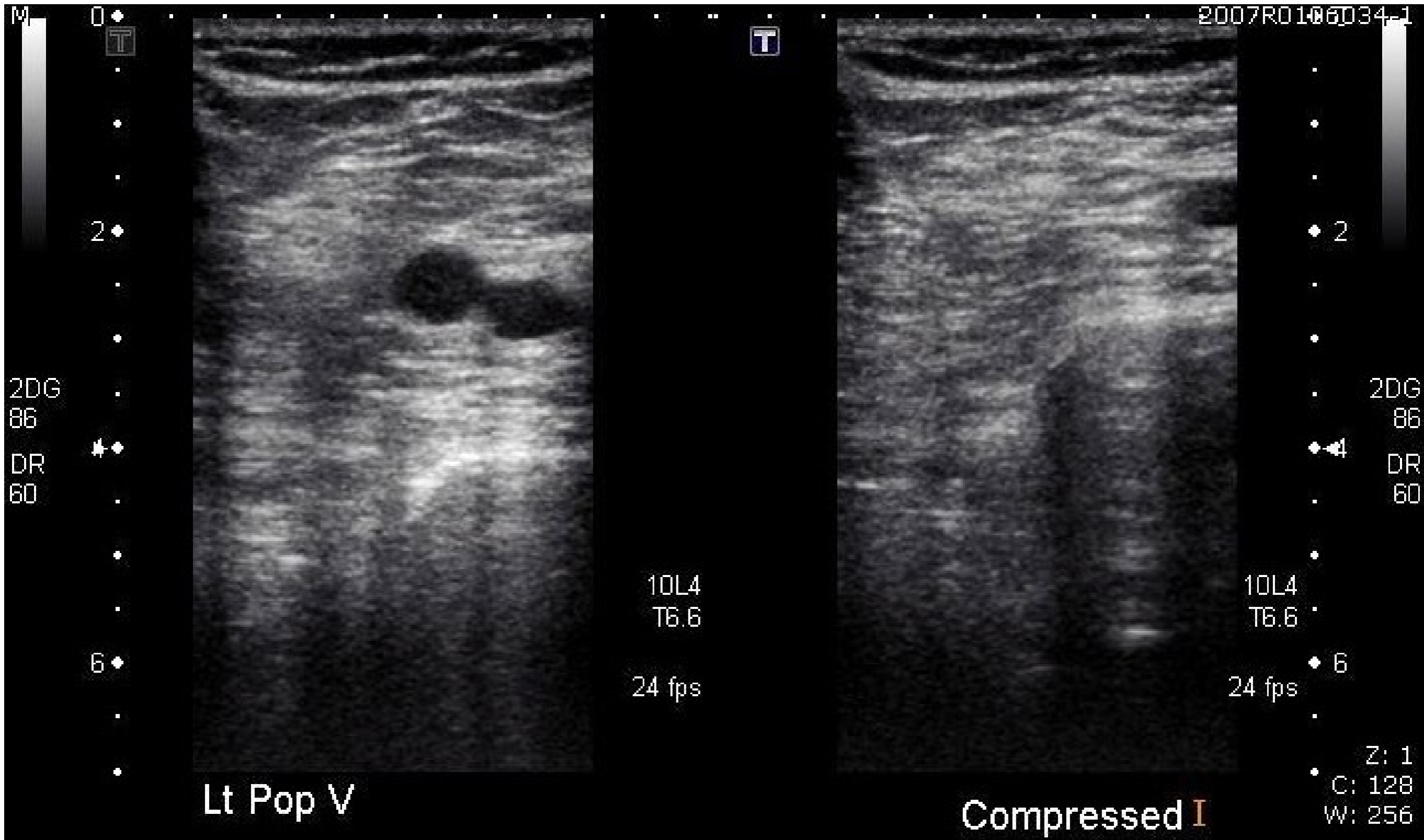


CTPA

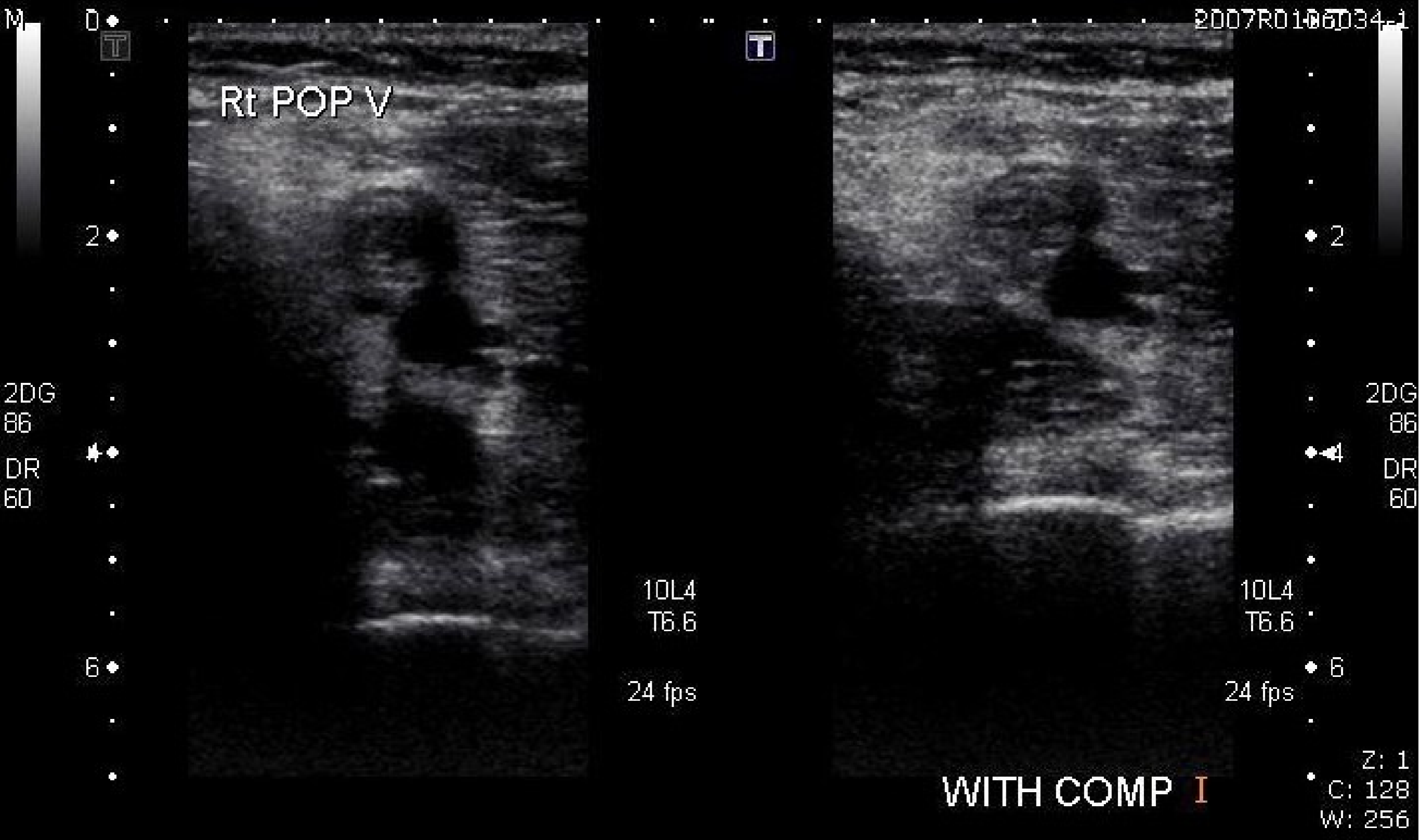
A
CT Angio Pulmonary Arteries/Veins - (Acute) (First 12 mths)
AXIAL THICK MEDIASTINUM
3/11/2007 12:47:58 AM
2007R0105947-1
APPLIED
LOC: 164
THK: 3
FFS



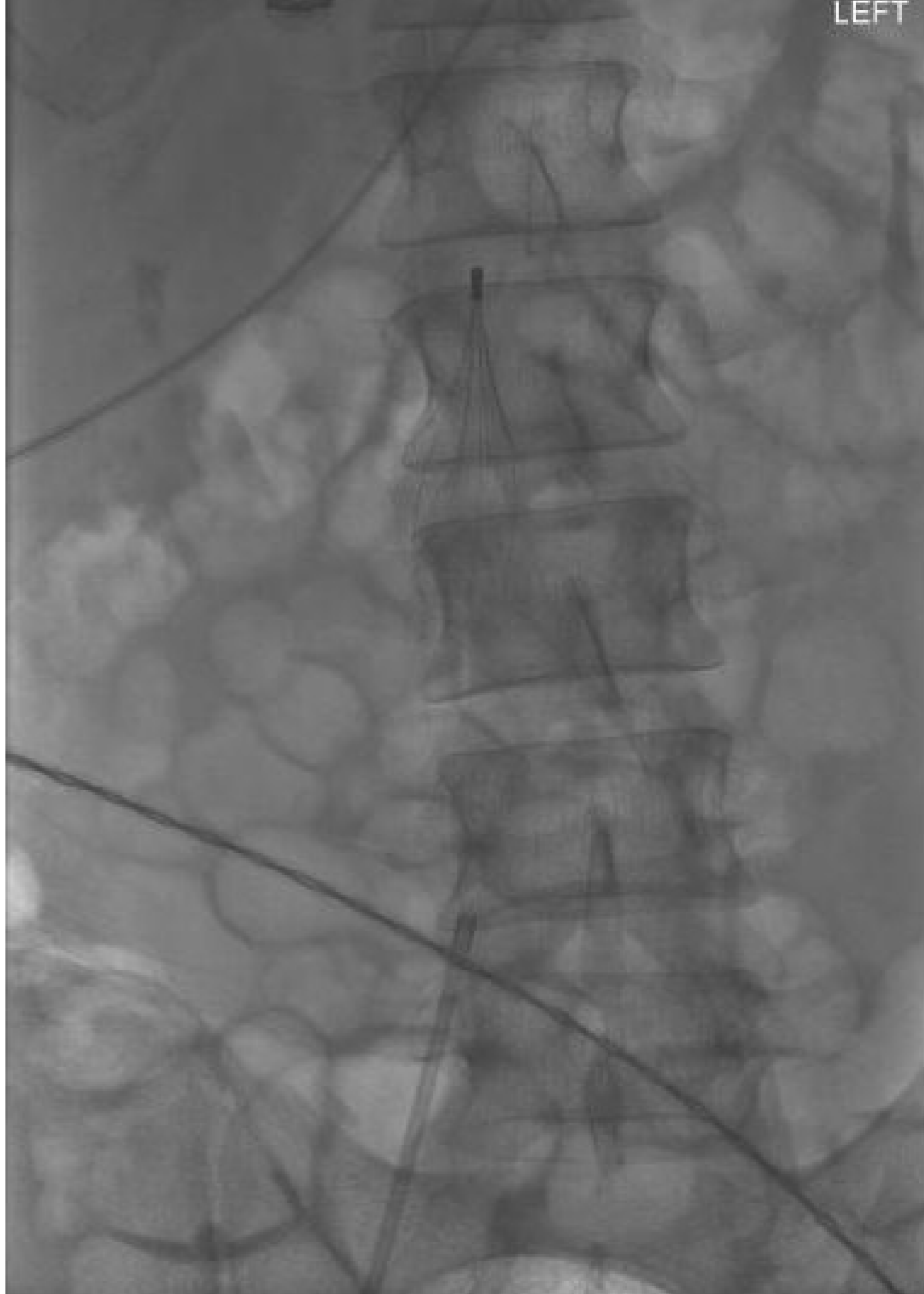Ultrasound - Left



Ultrasound - Right



What is this?



Admission ECG

