

Abdomen

Borders:

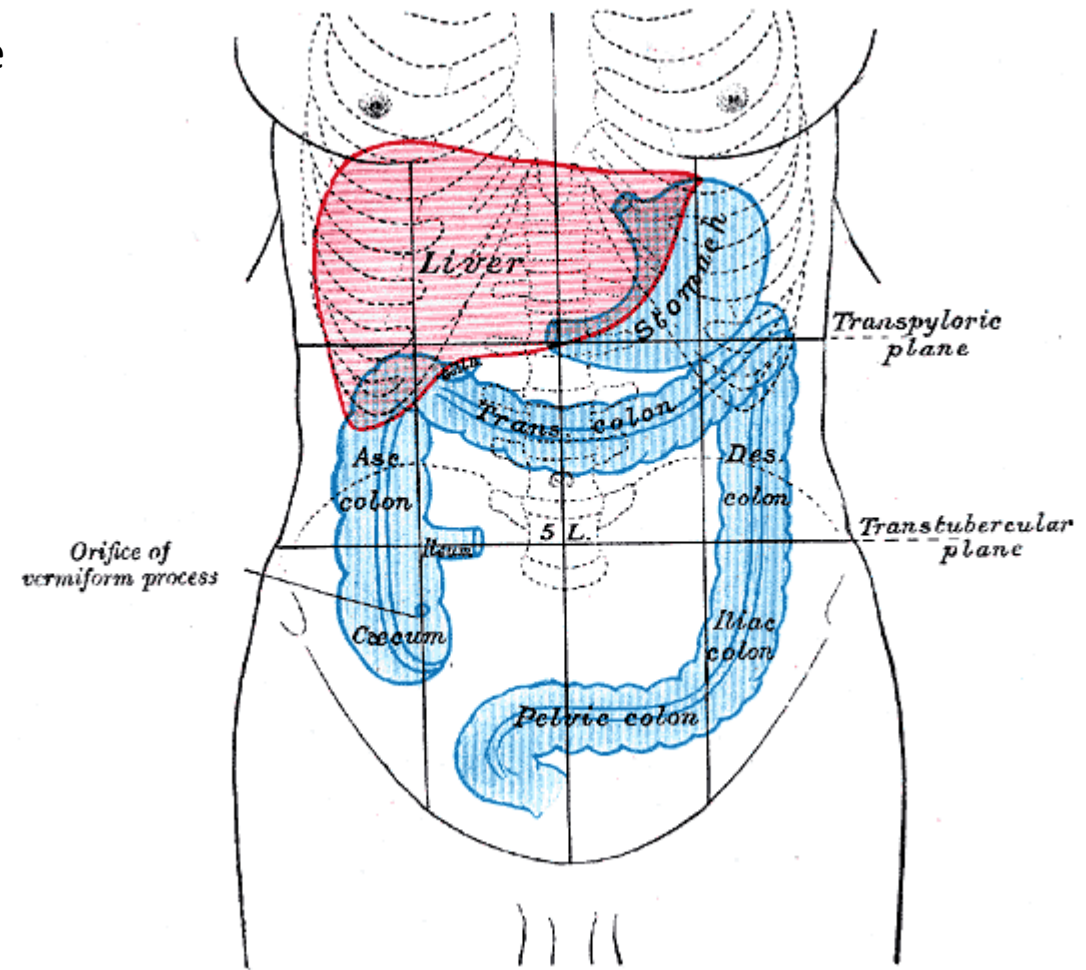
- Superiorly: xiphoid process, the lower six costal cartilages, and the anterior ends of the lower six ribs
- Inferiorly: pubic symphysis and the pubic crest, the anterior superior iliac spine, and the iliac crest.

Regions:

1. Epigastric
2. Hypochondriac (2)
3. Umpilical
4. Lumbar (2)
5. Hypogastric
6. Iliac (2)

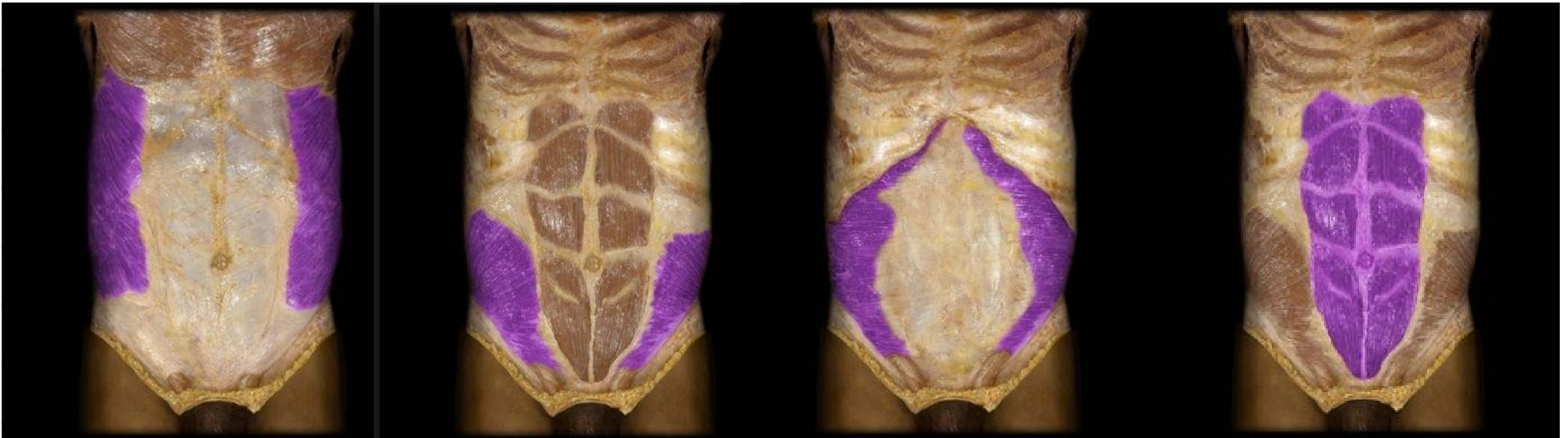These regions are devided by the following lines

- Mid clavicular lines
- Transpyloric line- 1/2 of the distance between the jugular notch and the pubic crest
- Intertubercular line

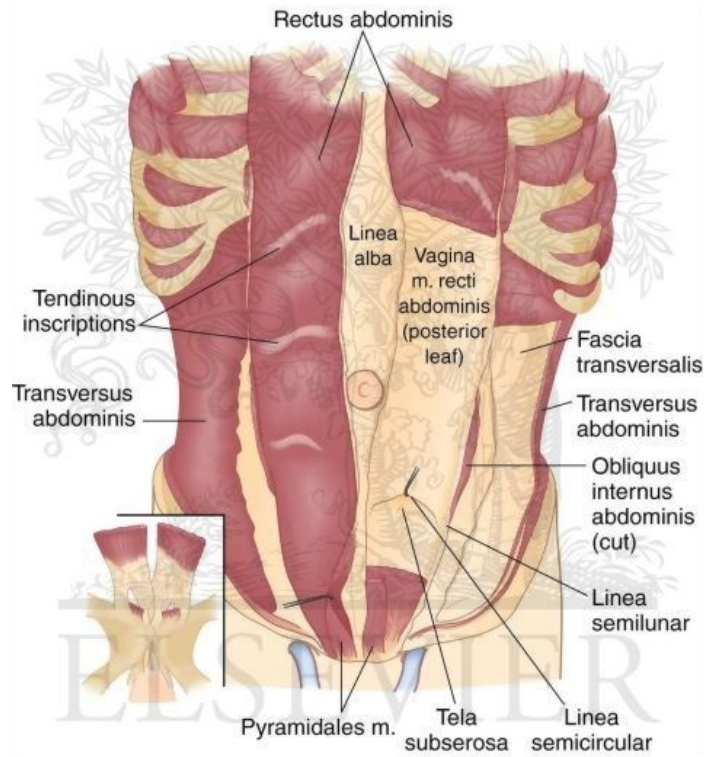


Muscles

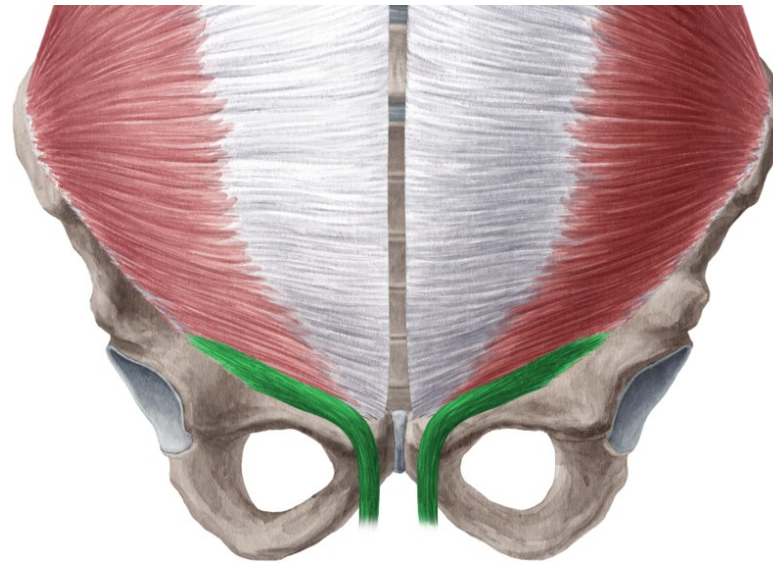
External Oblique M.	Internal Oblique M.	Transversus Abdominis M.	Rectus Abdominis M.
O:			
I:			
Inn:			
F:			



Pyramidalis M.	Cremaster M.	Quadratus Lumborum M.

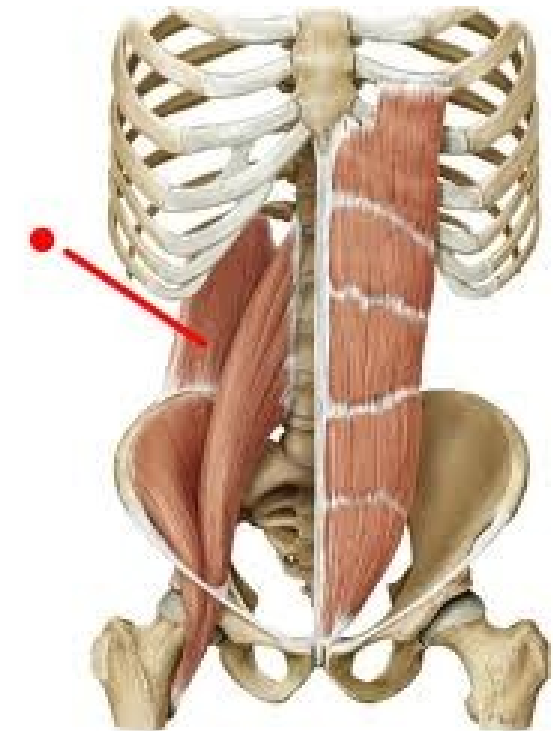



©ELSEVIER, INC. – ELSEVIERIMAGES.COM



www.kenhub.com

kenHub





Rectus Abdominis

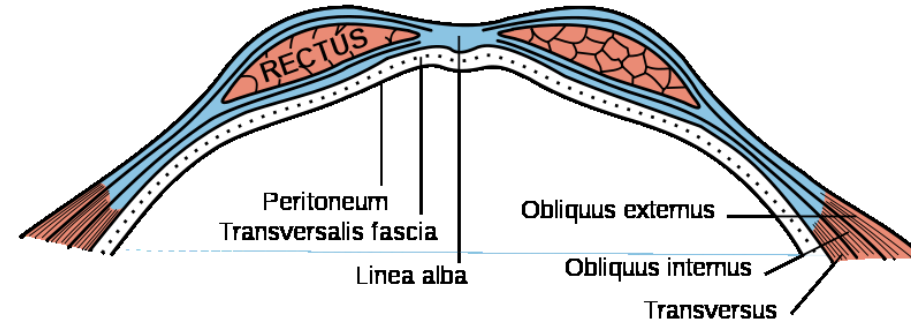
Sheath of Rectus Abdominis M.

Both Recti abdominis muscles are integrated into a fibrous sheath , vagina recti abdominis.

It is formed at the Superior 2/3 by

Anteriorly: External Oblique M. Aponeurosis and the one leaf of Internal Oblique M. Aponeurosis

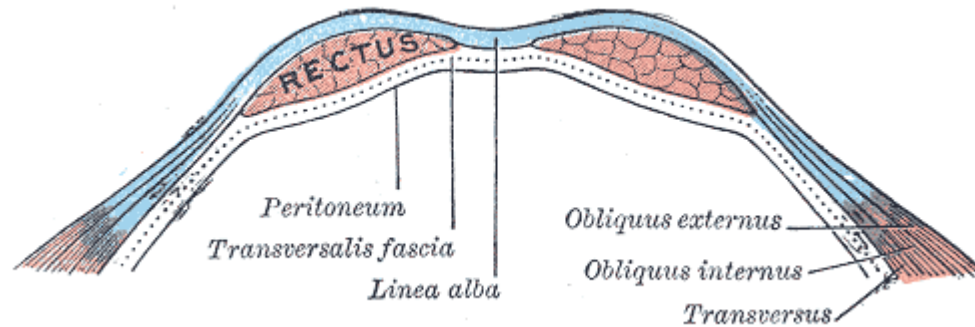
Posteriorly: One leaf of Internal Oblique M. Aponeurosis, Transverse abdominal M. Aponeurosis and Transversalis Fascia



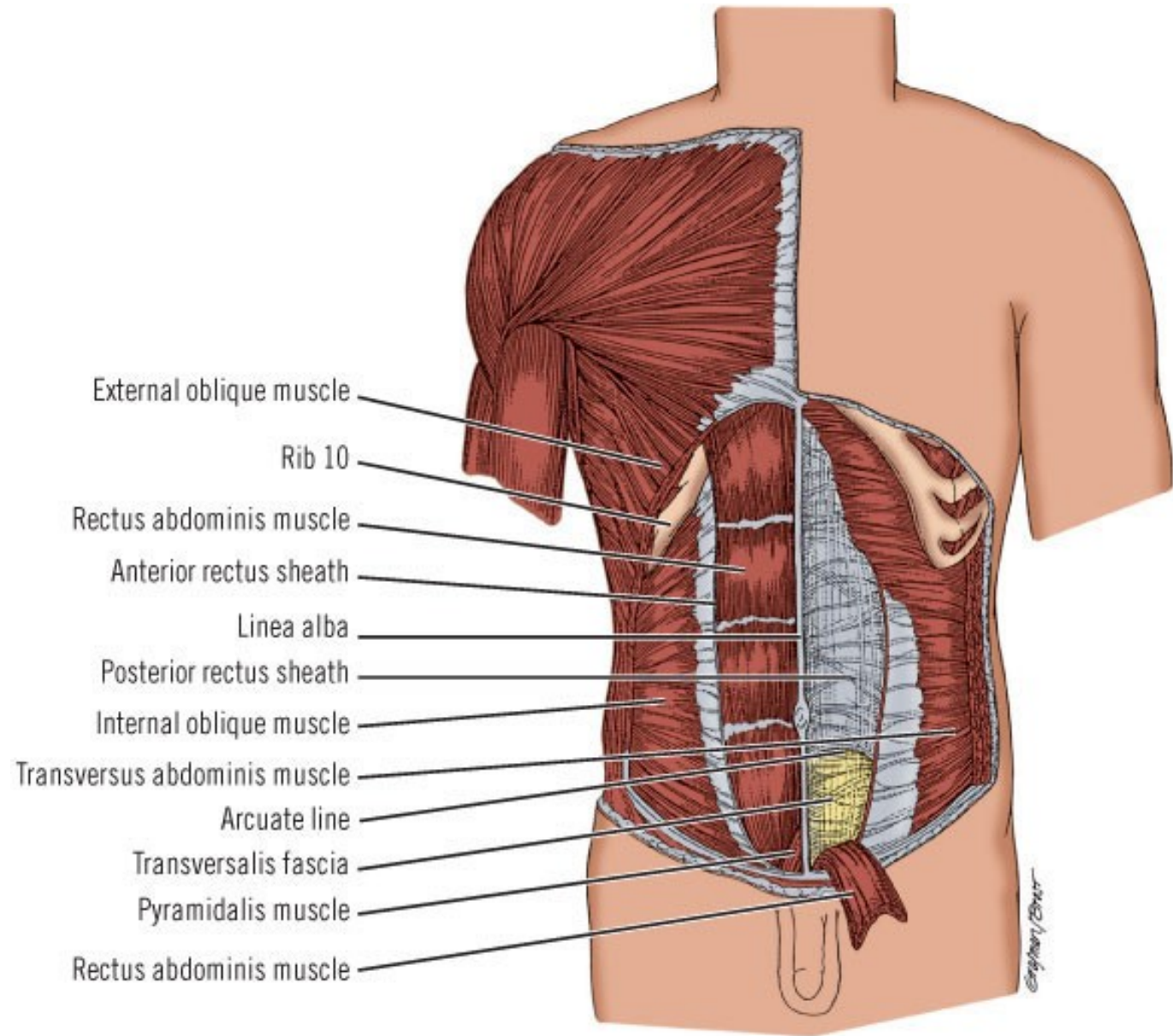
It is formed in at the Inferior 1/3 by

Anteriorly: External Oblique Aponeurosis , the whole Internal oblique Aponeurosis and Transverse abdominal M. aponeurosis

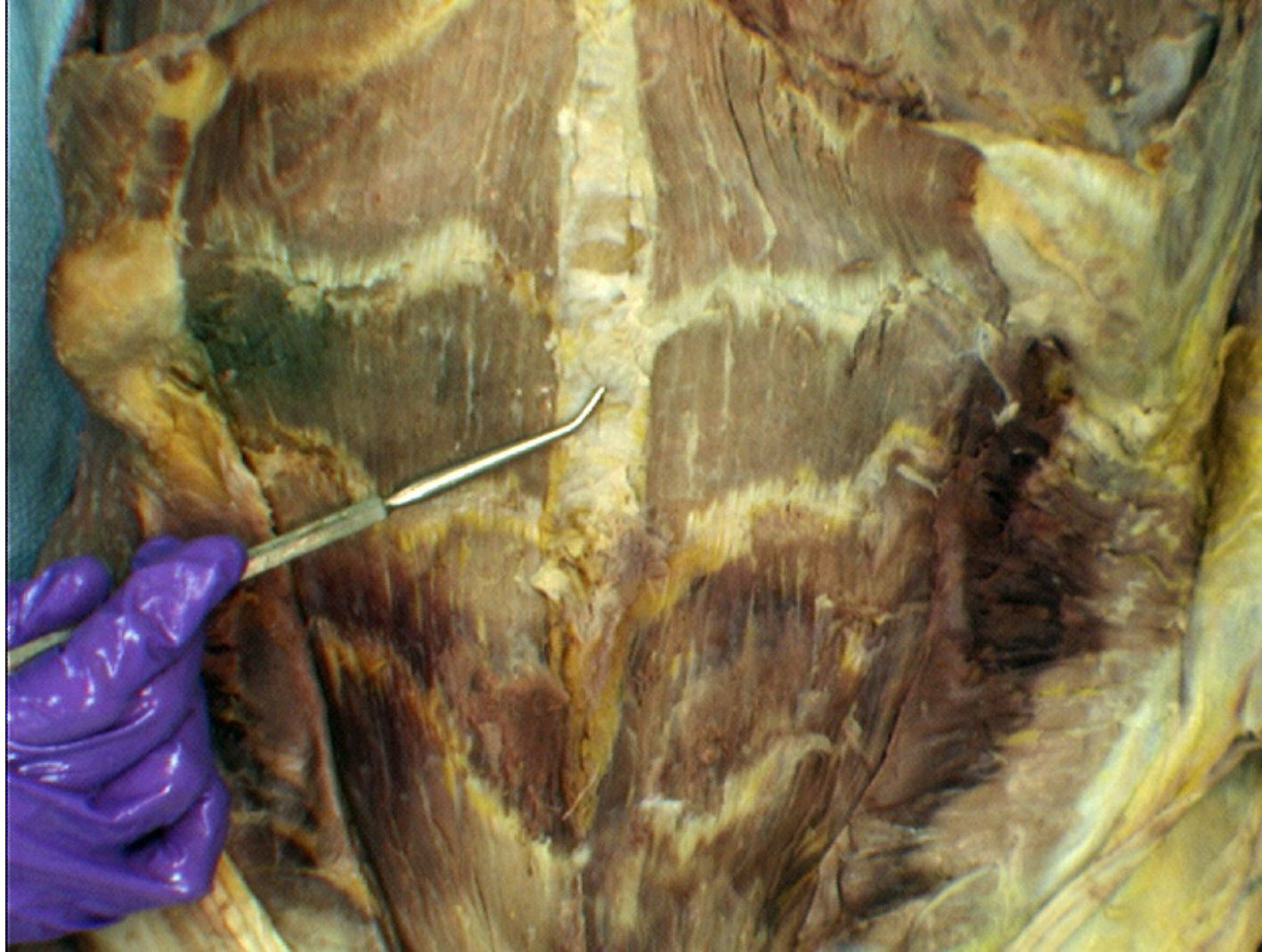
Posteriorly: Transversalis fascia



The superior and inferior part are divided by the arcuate line



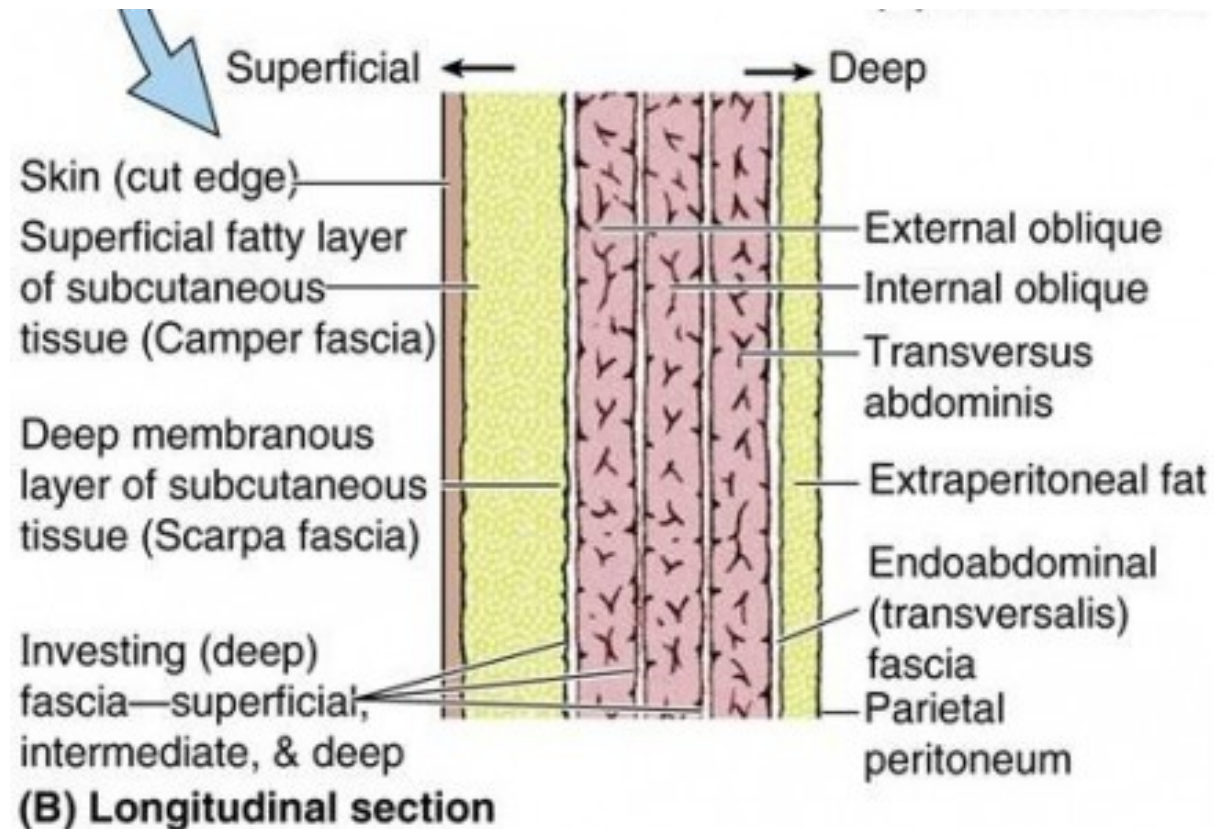
In the medial line both layers of vagina recti abdominis of both sides are connecting together and create a fibrous band – linea alba . This line runs from from xiphoid process to pubic symphysis. Approximately in the half of Linea Alba length there is an umbilical scar -umbilicus





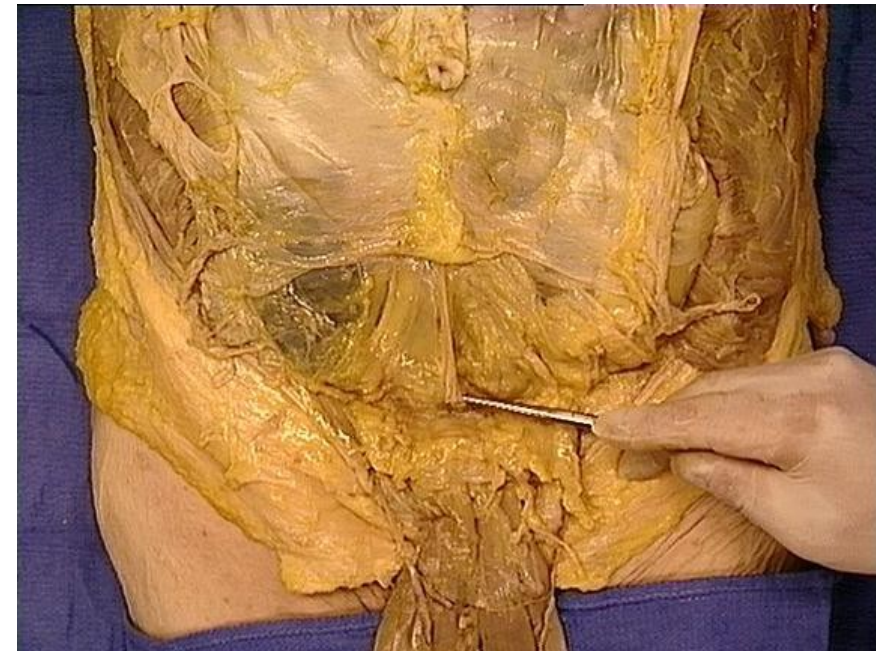
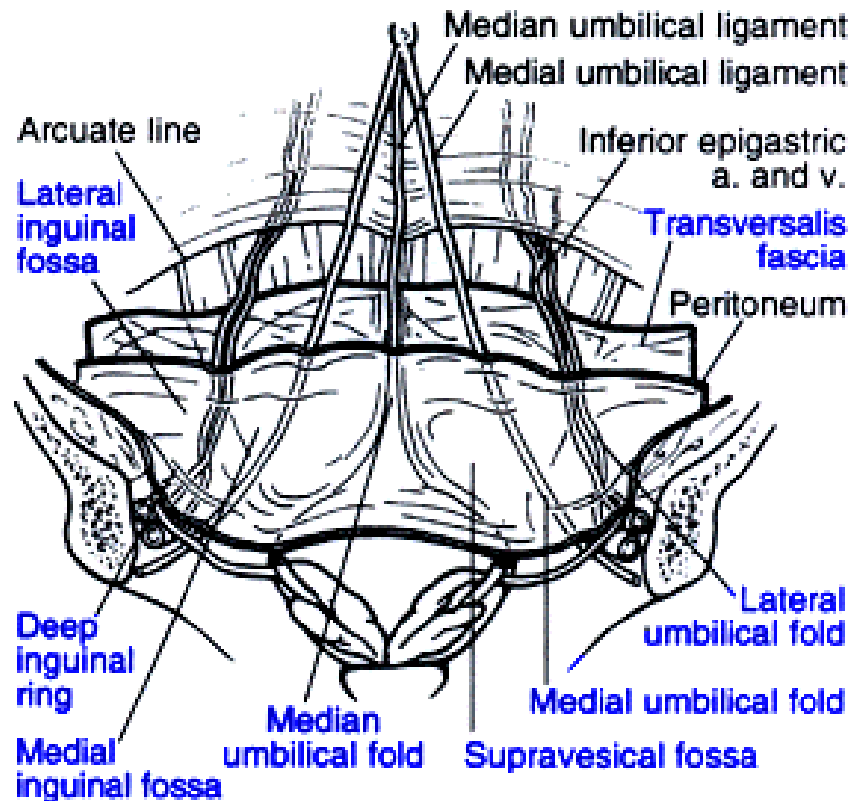
Fasciae

- Superficial abdominal Fascia: outer side of the abdominal wall= Camper's fascia - fatty superficial layer
- Subcutaneous Abdominal Fascia: Scarpa's fascia - deep fibrous layer.
- Fascia transversalis: inner side of abdominal wall



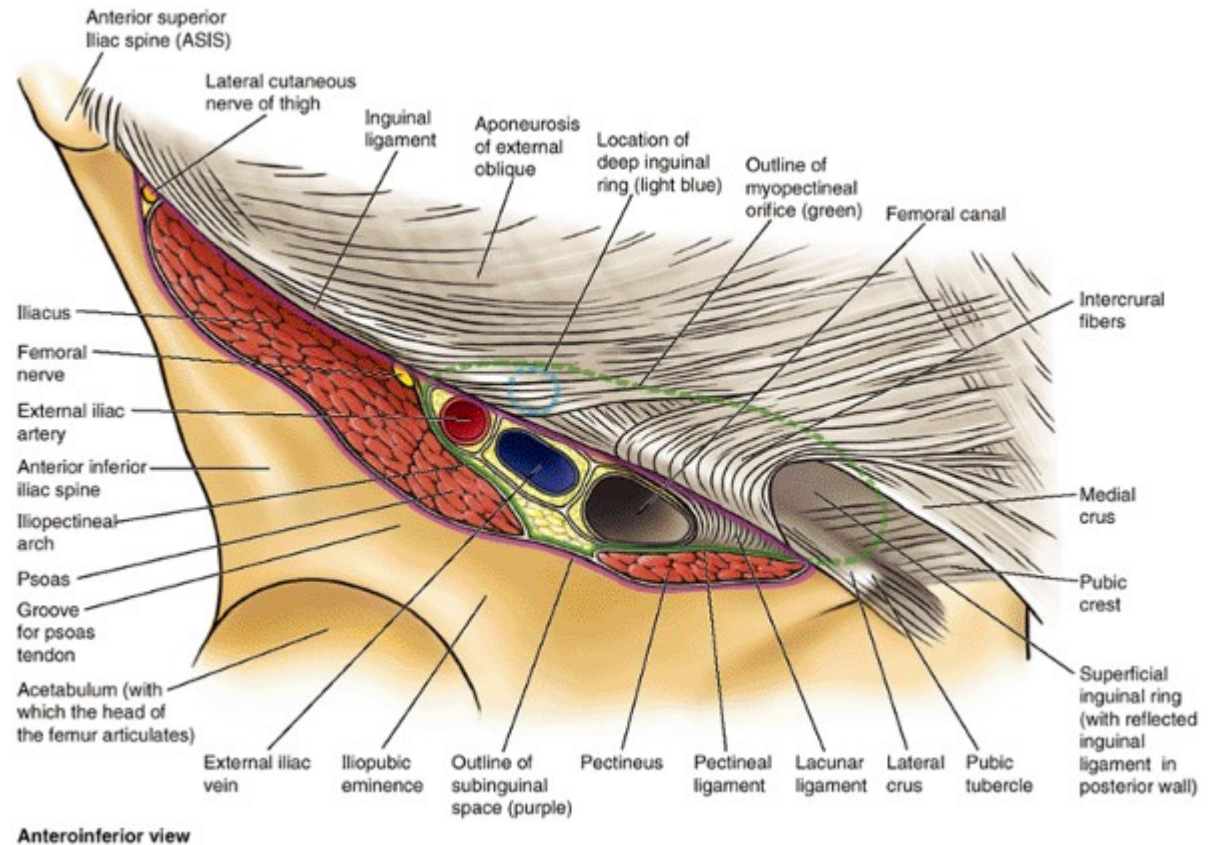
The inner surface of abdominal wall contains several ligaments separated by fossae:

Ligament/fold	Remnant of	Lateral fossa	Hernia
median umbilical ligament	urachus	supravesical fossa	-
medial umbilical ligament	umbilical artery	medial inguinal fossa	direct inguinal hernia
lateral umbilical fold	inferior epigastric vessels	lateral inguinal fossa	indirect inguinal hernia



Inguinal Canal

It opens medially under the abdominal skin as Superficial inguinal ring and laterally as deep inguinal ring which leads to peritoneal cavity. Superficial inguinal ring is in the aponeurosis of external oblique muscle and it is demarcated by crus mediale and crus laterale which are crossed by intercrural fibers. Deep inguinal ring is an opening located in aponeurosis of transversus abdominis muscle and internal oblique muscle. Its medial border is formed by interfoveolar ligament. It serves for passing of spermatic cord.

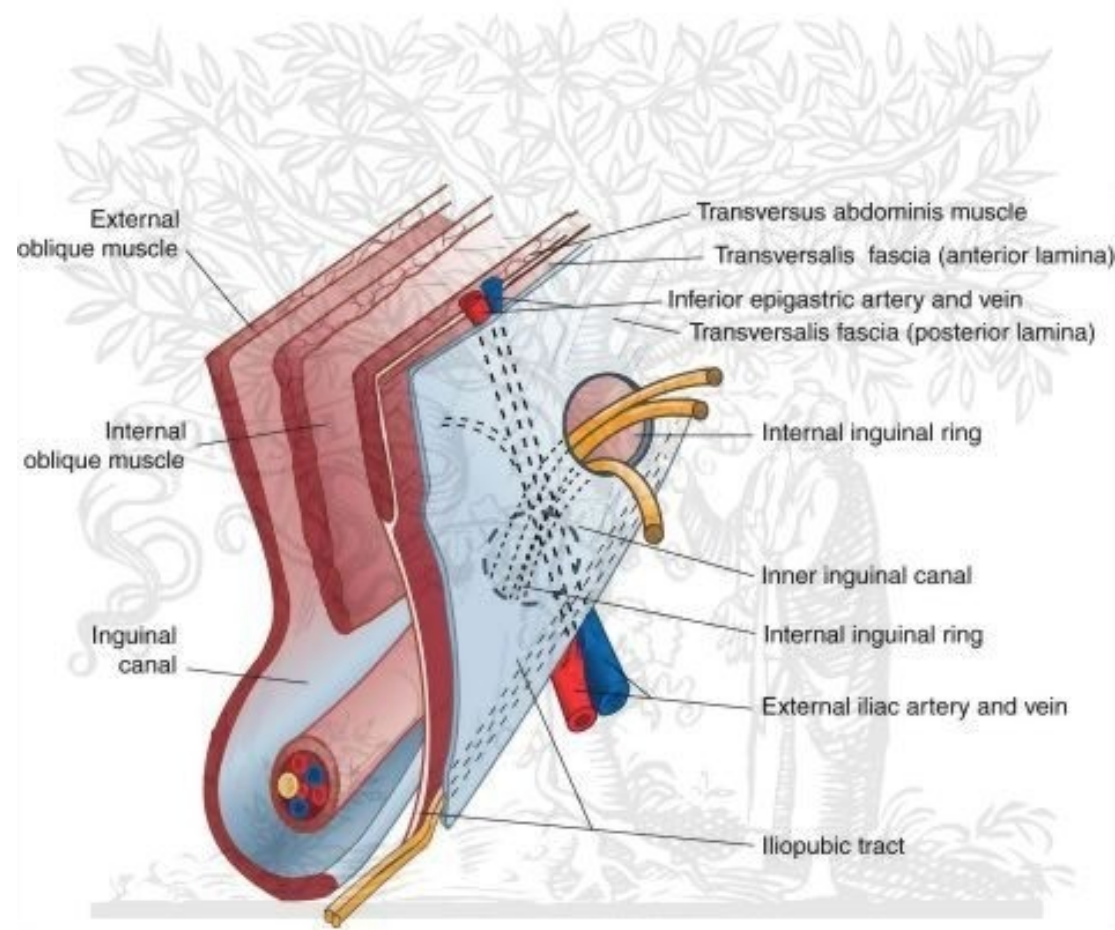
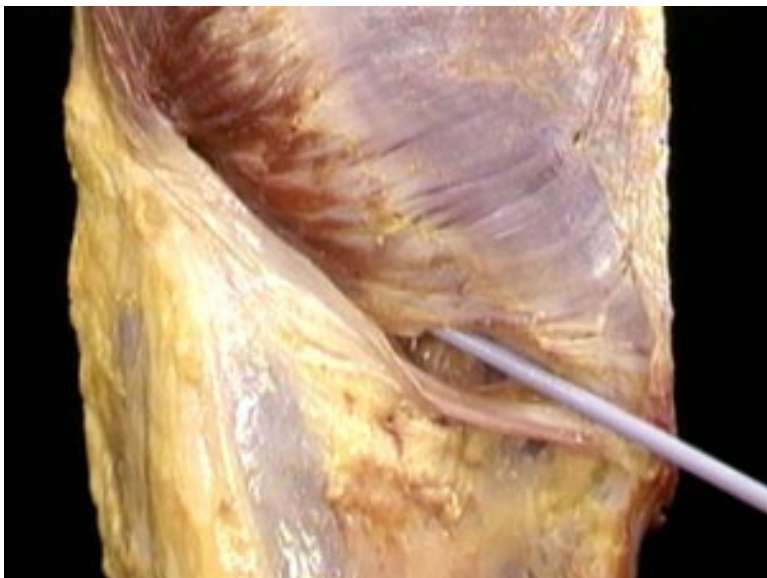

Inguinal Canal walls

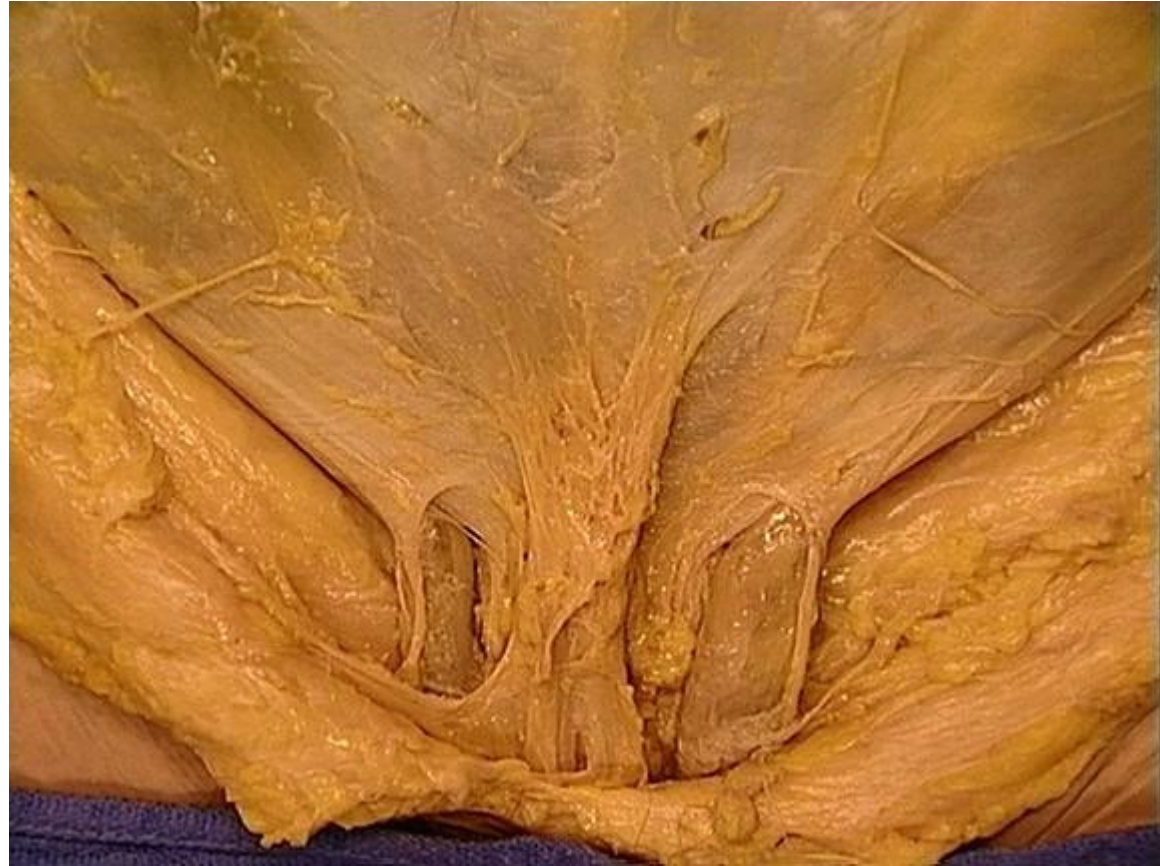Anterior: Aponeurosis of external oblique M.

Superior: Internal Oblique M. and Transversus abdominis M.

Inferior: Inguinal ligament



ELSEVIER



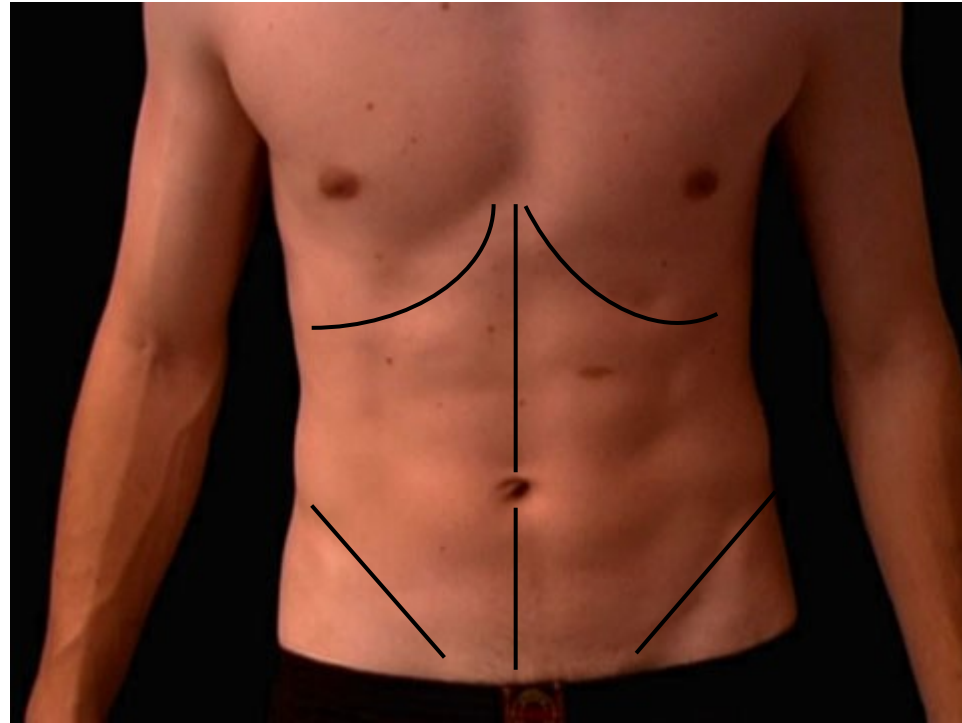






Dissection

Step 1
Skin incision



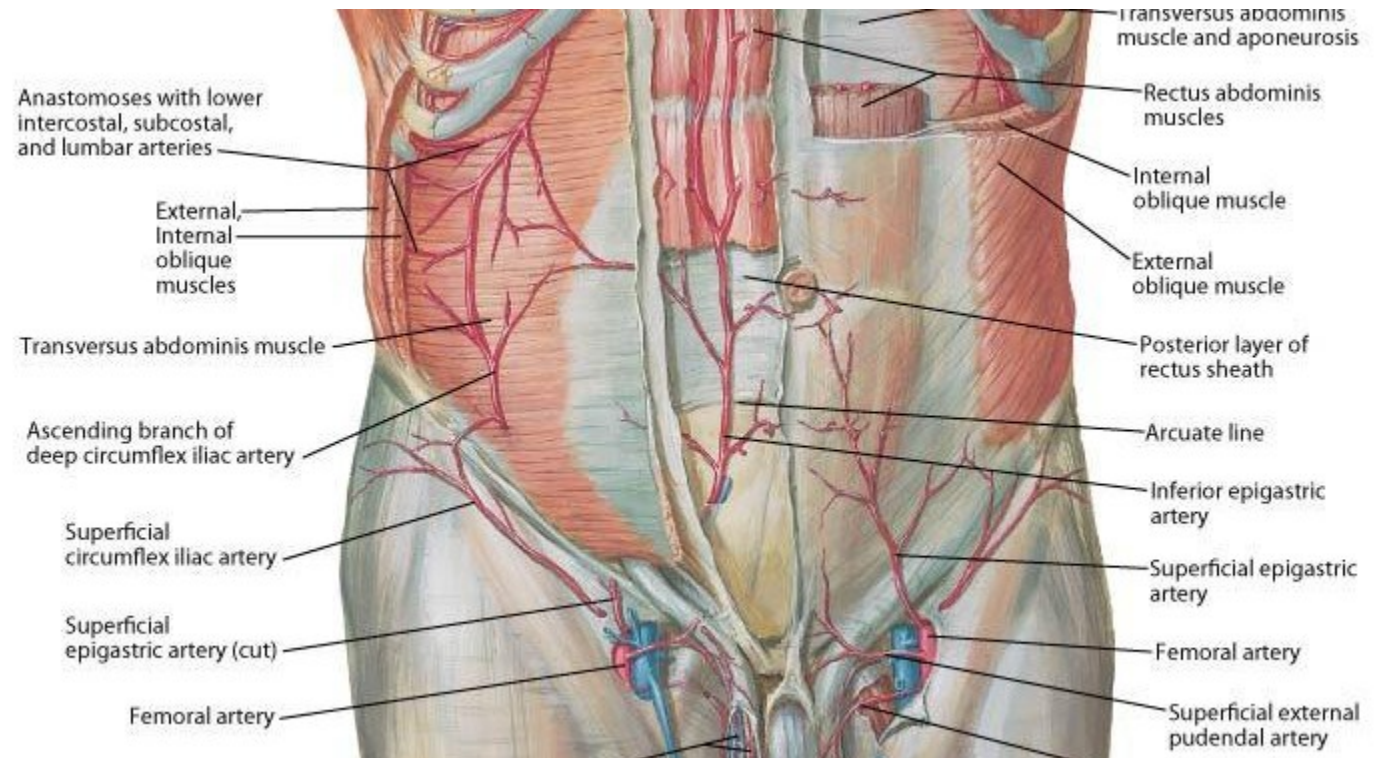
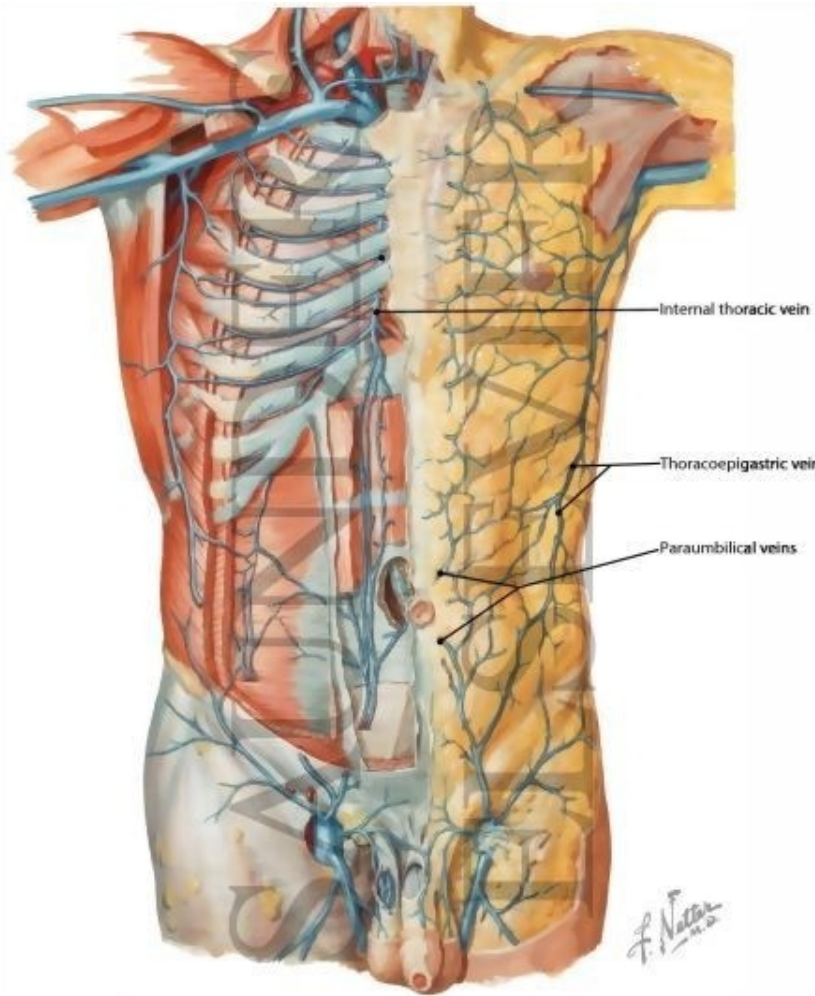
Step 2

Skin

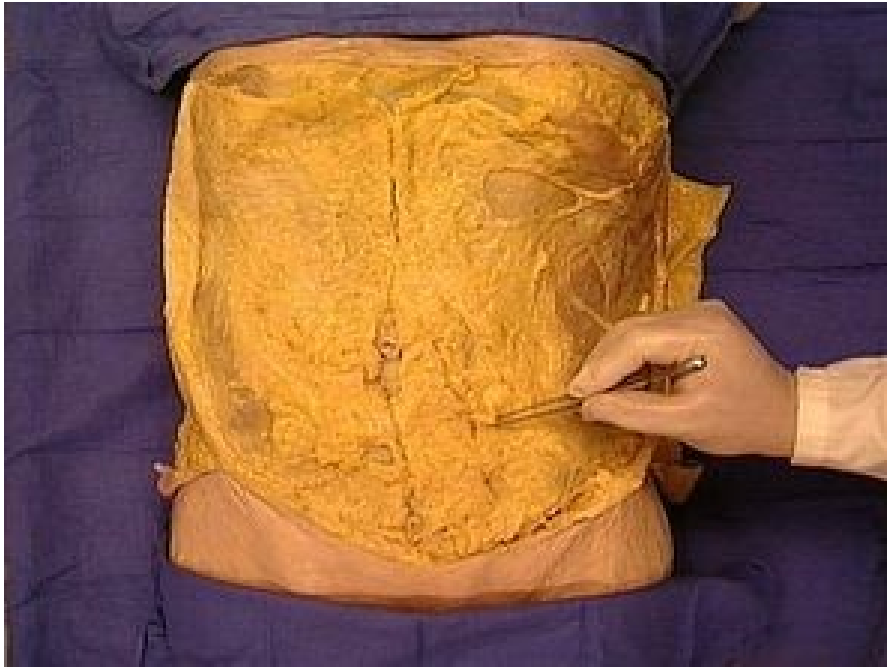
Subcutaneous Layer: Camper's and Scarpa's fascia

Find and clean anterior and lateral cutaneous nerves (<intercostal nerves)

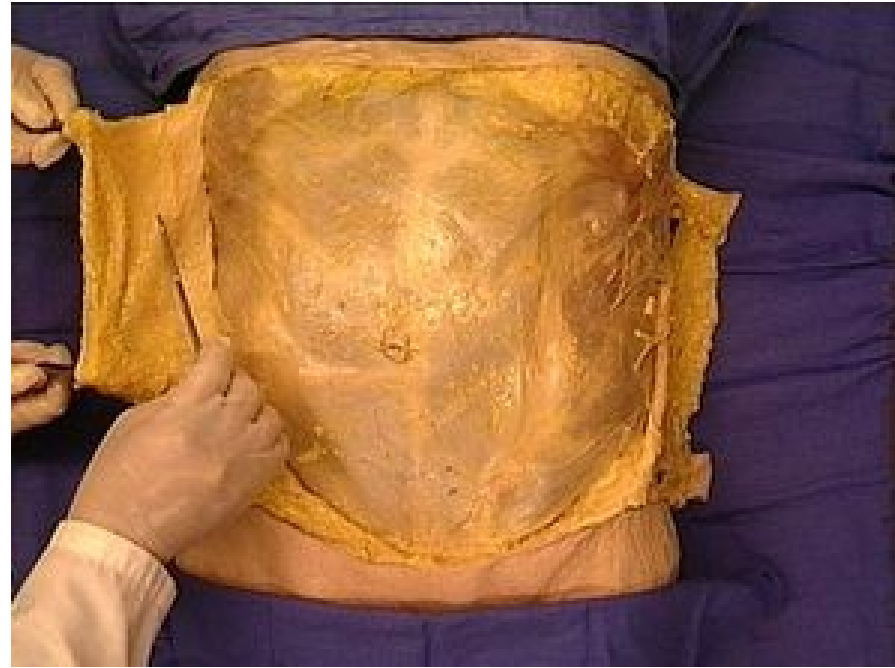
Find and clean Superficial epigastric vessels, Superficial iliac Circumflex vessels and External pudendal vessels



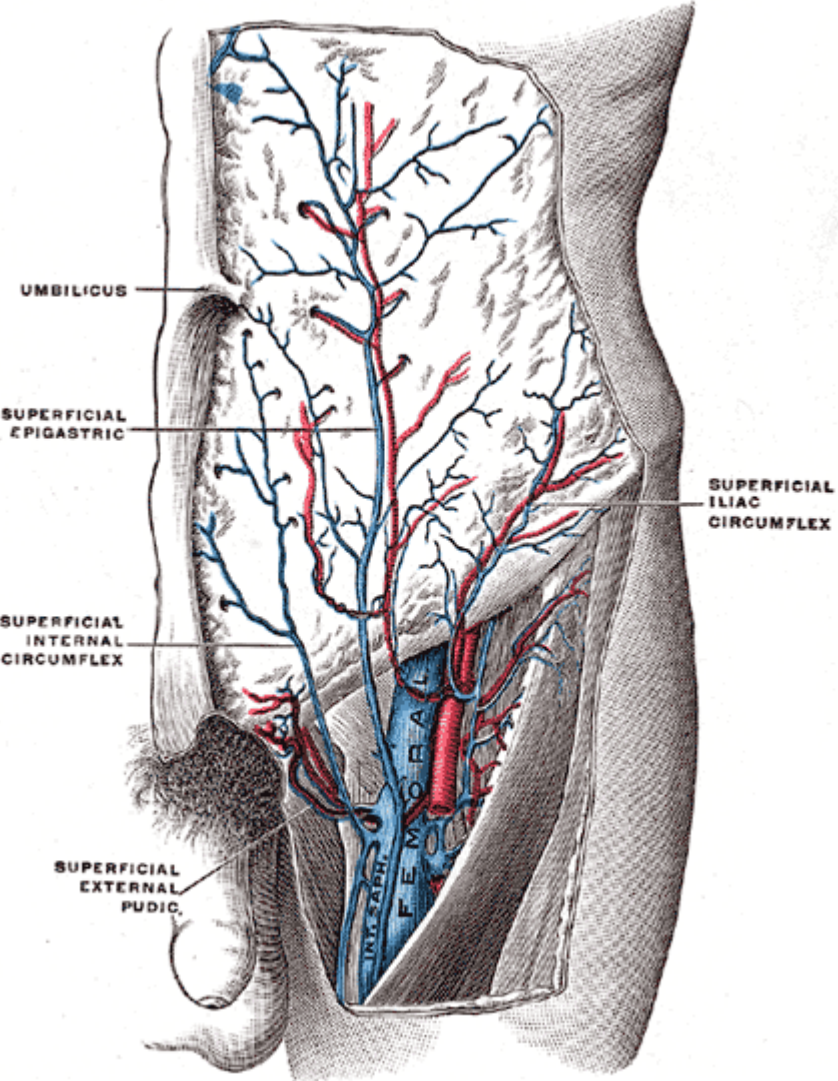
Camper's Fascia



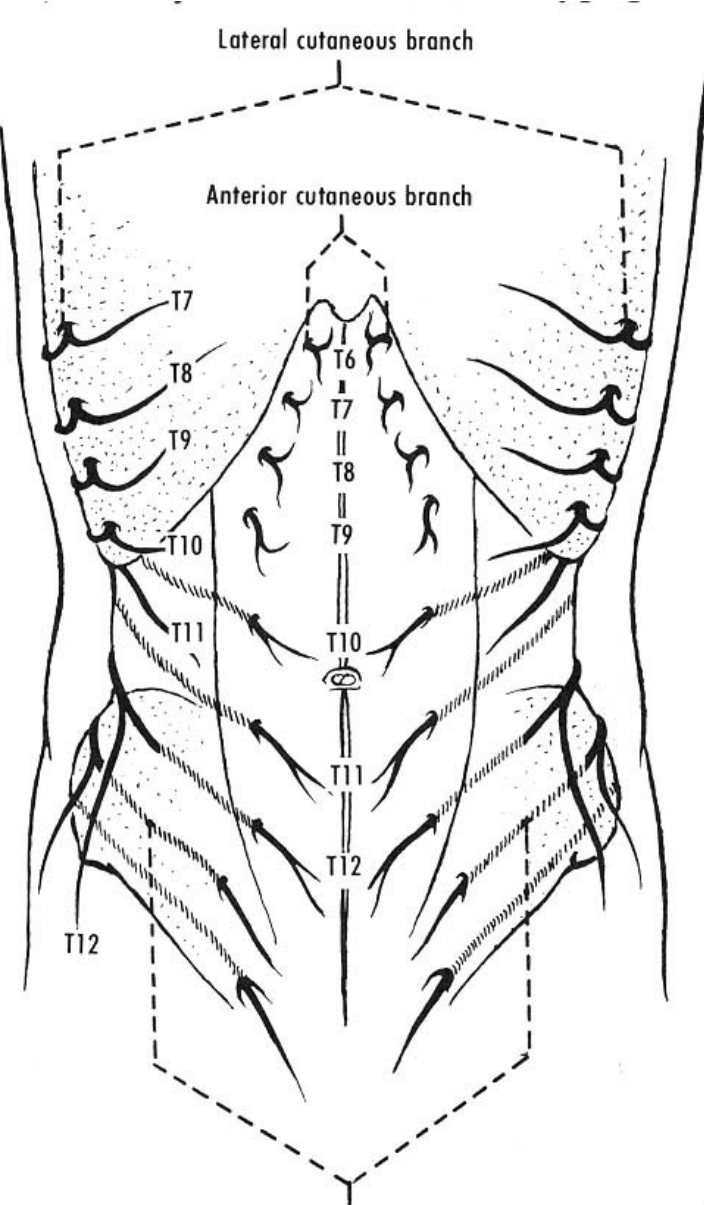
Scarpa's Fascia



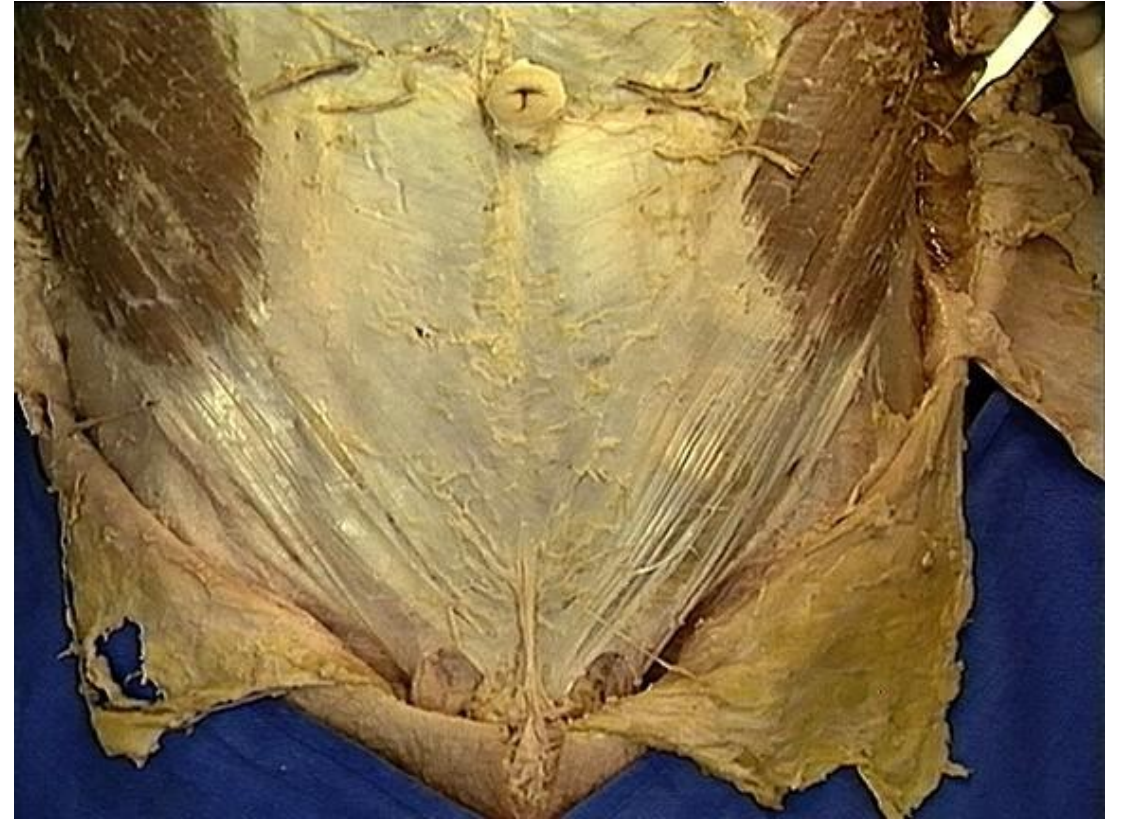
Superficial Epigastric artery and vein (<Femoral artery/vein)
 Superficial iliac circumflex artery and vein (< Femoral artery/vein)
 Superficial External Pudendal artery and vein (< Femoral artery/vein)



Anterior and Lateral Cutaneous nerves (<Intercostal Nerves)



Cutaneous branches



Step 3

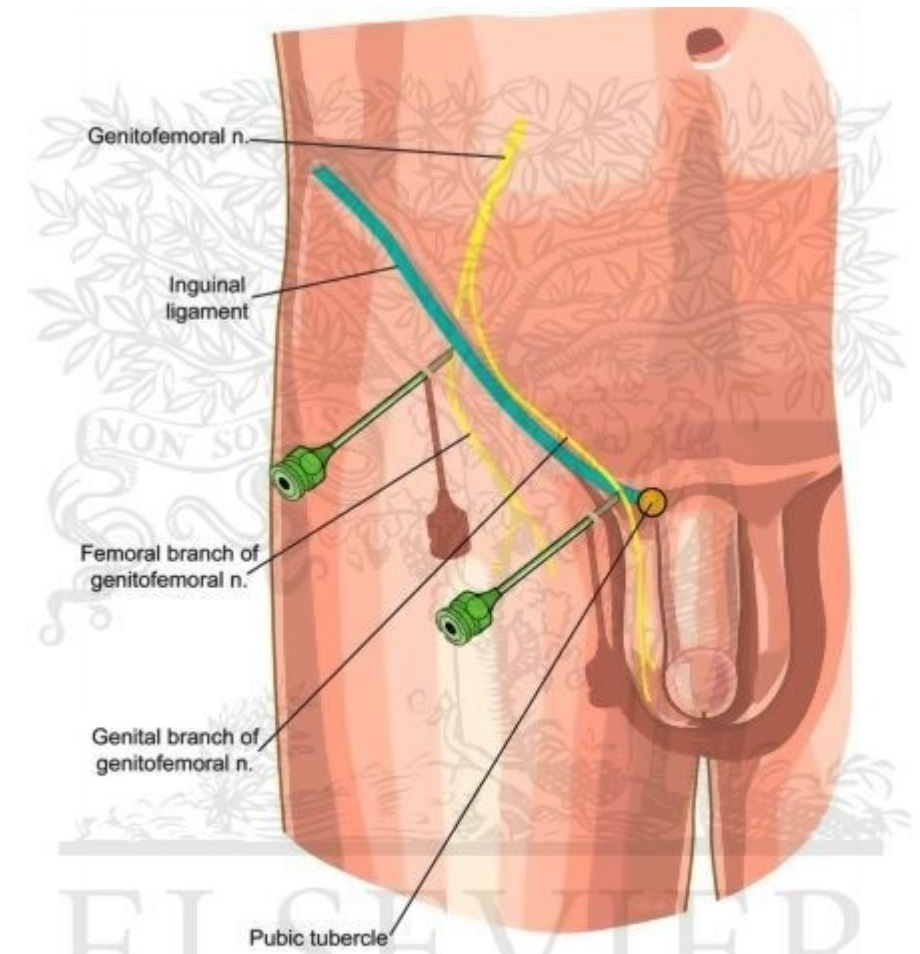
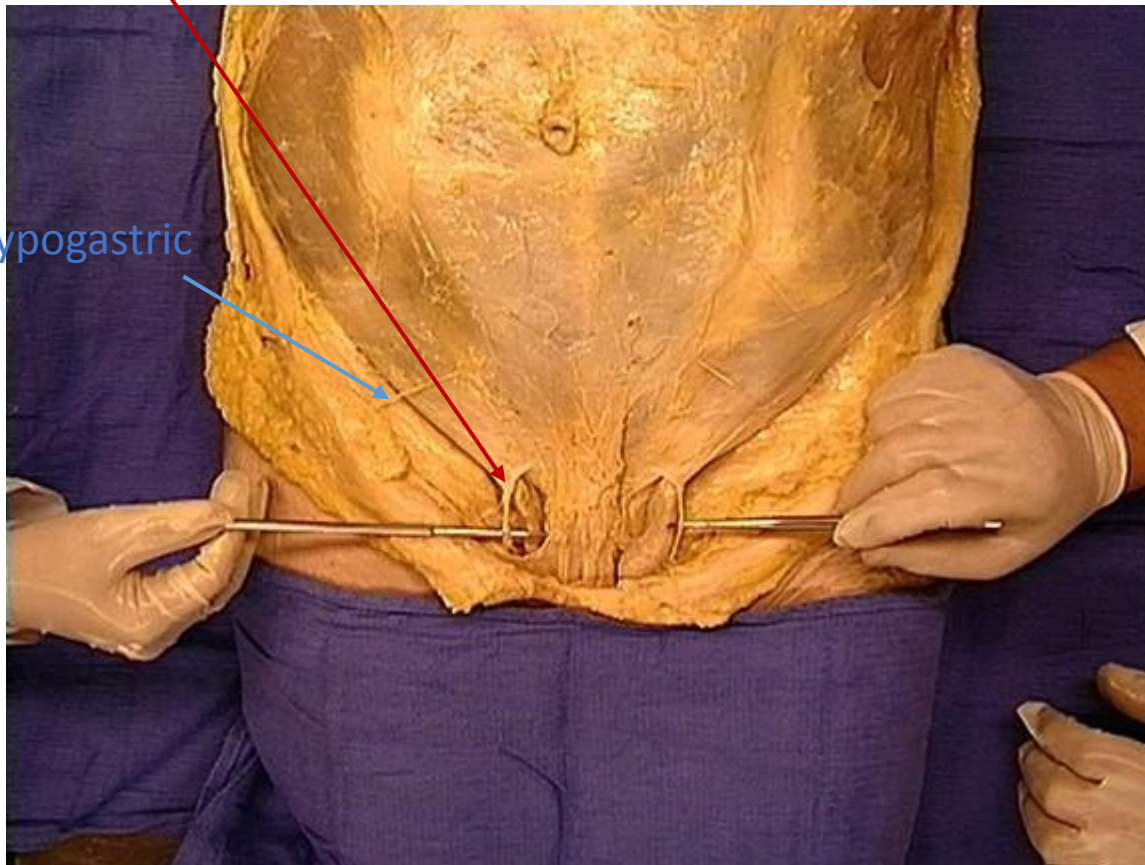
Clean the surface of external Oblique M.

Find and clean Superficial ring of inguinal canal

Identify the spermatic cord/ round ligament

Find and clean Ilioinguinal nerve (laterally of spermatic cord) and the genital branch of genitofemoral nerve(medially to spermatic cord)

Ilioinguinal Nerve



Correct needle placement for genitofemoral nerve block. (From Waldman SD: Atlas of Interventional Pain Management. Philadelphia, Saunders, 1998, p 365.)

©ELSEVIER, INC. – ELSEVIERIMAGES.COM

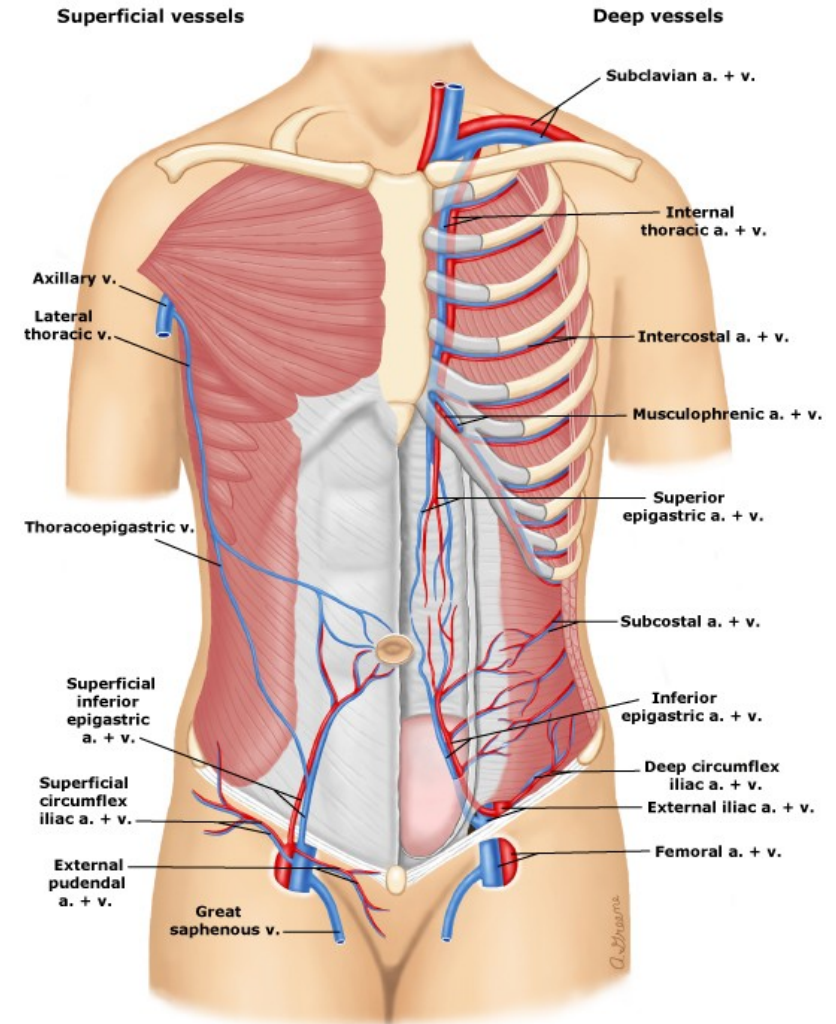
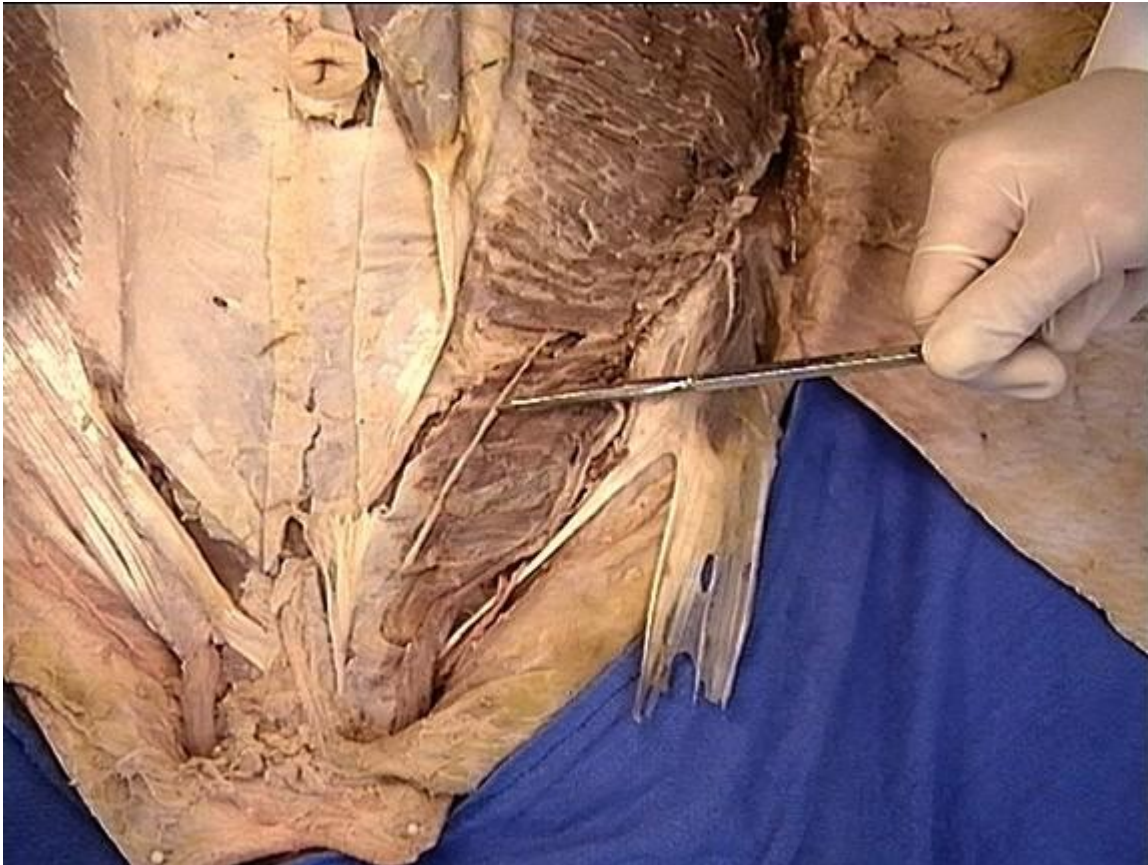
Step 4

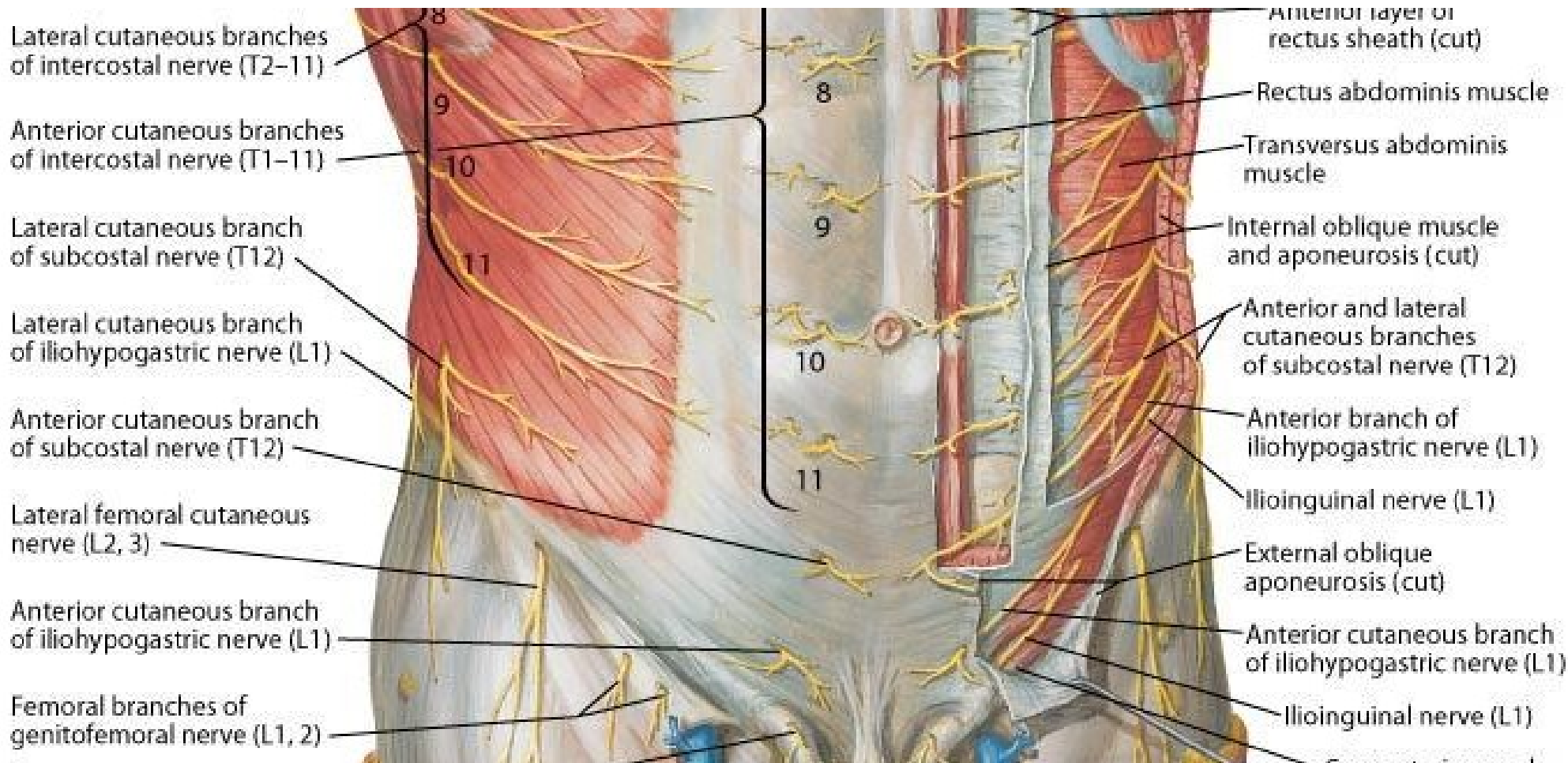
Cut the external Oblique M. in the mid axillary line to the anterior iliac spine

Separate the external oblique from the internal oblique with your fingers but preserve the nerves and the vessels

Find and clean the subcostal , ilioinguinal and iliohypogastric nerves and the deep iliac circumflex vessels

Iliohypogastric





Lateral cutaneous branches of intercostal nerve (T2-11)

Anterior cutaneous branches of intercostal nerve (T1-11)

Lateral cutaneous branch of subcostal nerve (T12)

Lateral cutaneous branch of iliohypogastric nerve (L1)

Anterior cutaneous branch of subcostal nerve (T12)

Lateral femoral cutaneous nerve (L2, 3)

Anterior cutaneous branch of iliohypogastric nerve (L1)

Femoral branches of genitofemoral nerve (L1, 2)

Anterior layer of rectus sheath (cut)

Rectus abdominis muscle

Transversus abdominis muscle

Internal oblique muscle and aponeurosis (cut)

Anterior and lateral cutaneous branches of subcostal nerve (T12)

Anterior branch of iliohypogastric nerve (L1)

Ilioinguinal nerve (L1)

External oblique aponeurosis (cut)

Anterior cutaneous branch of iliohypogastric nerve (L1)

Ilioinguinal nerve (L1)

Step 5

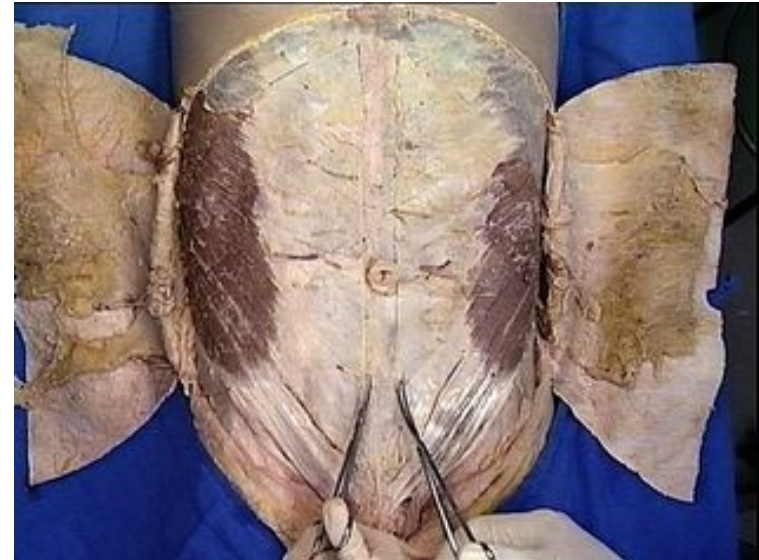
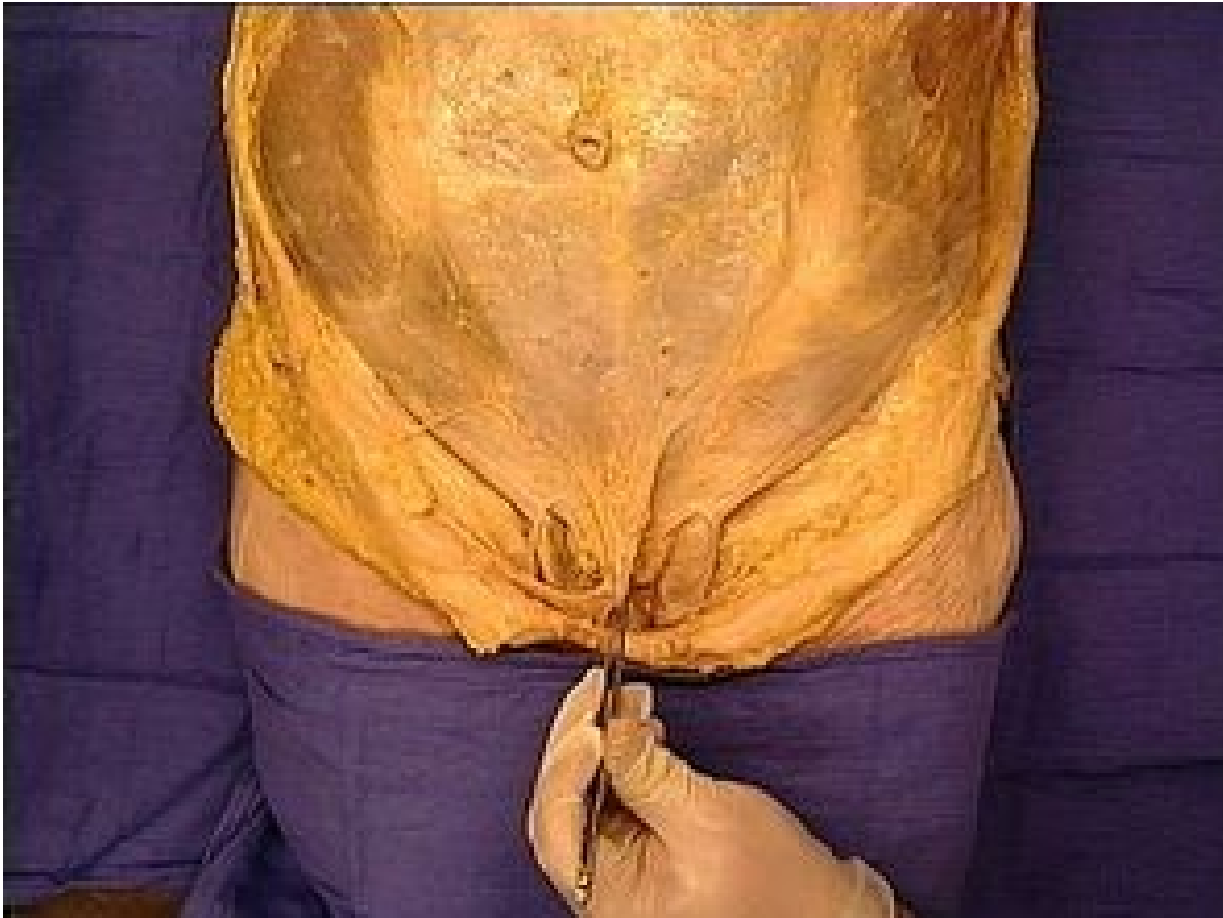Clean and cut the internal oblique in the same way as external oblique

Separate it with transversus abdominis by your fingers

Clean the rectus sheath

Identify the Fundiform ligament of the penis

Fundiform ligament: Scarpa's fascia contributes to formation of the fundiform ligament of the penis.

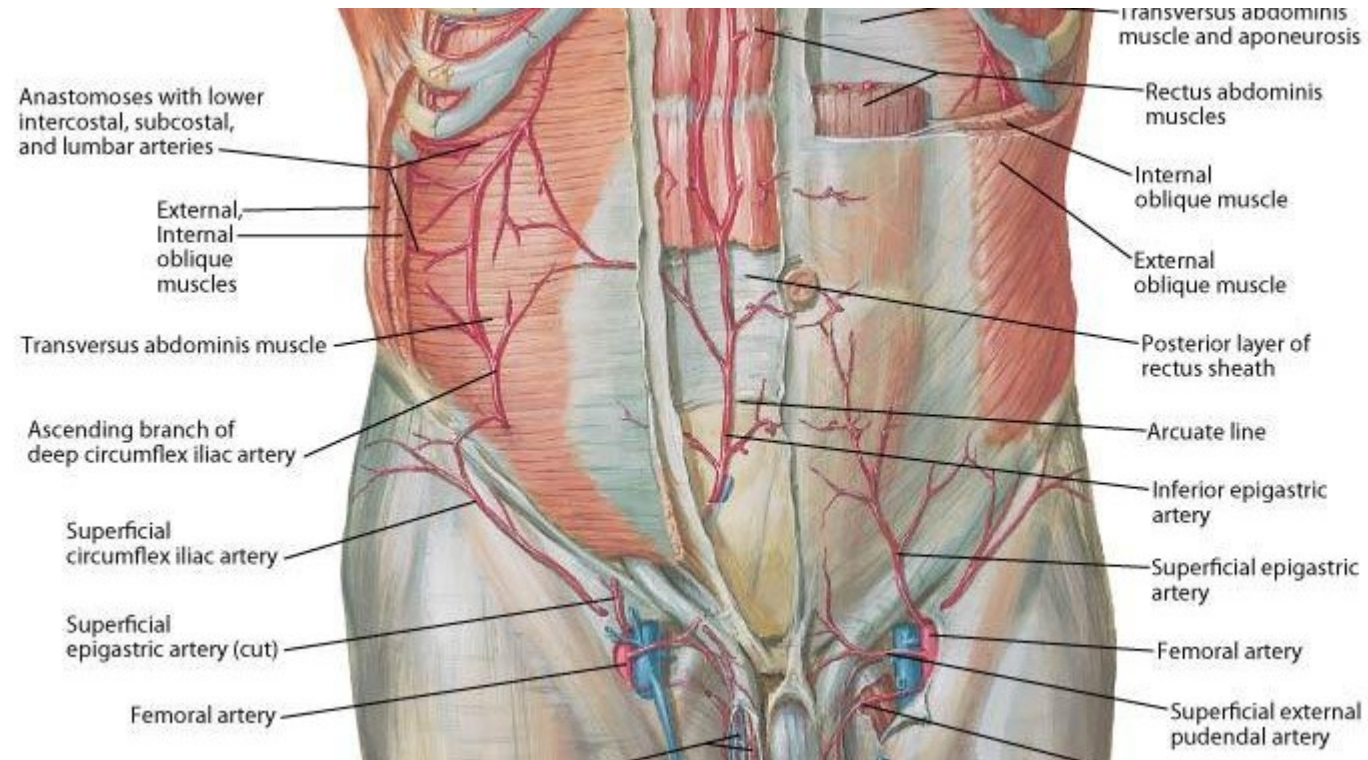


Step 6

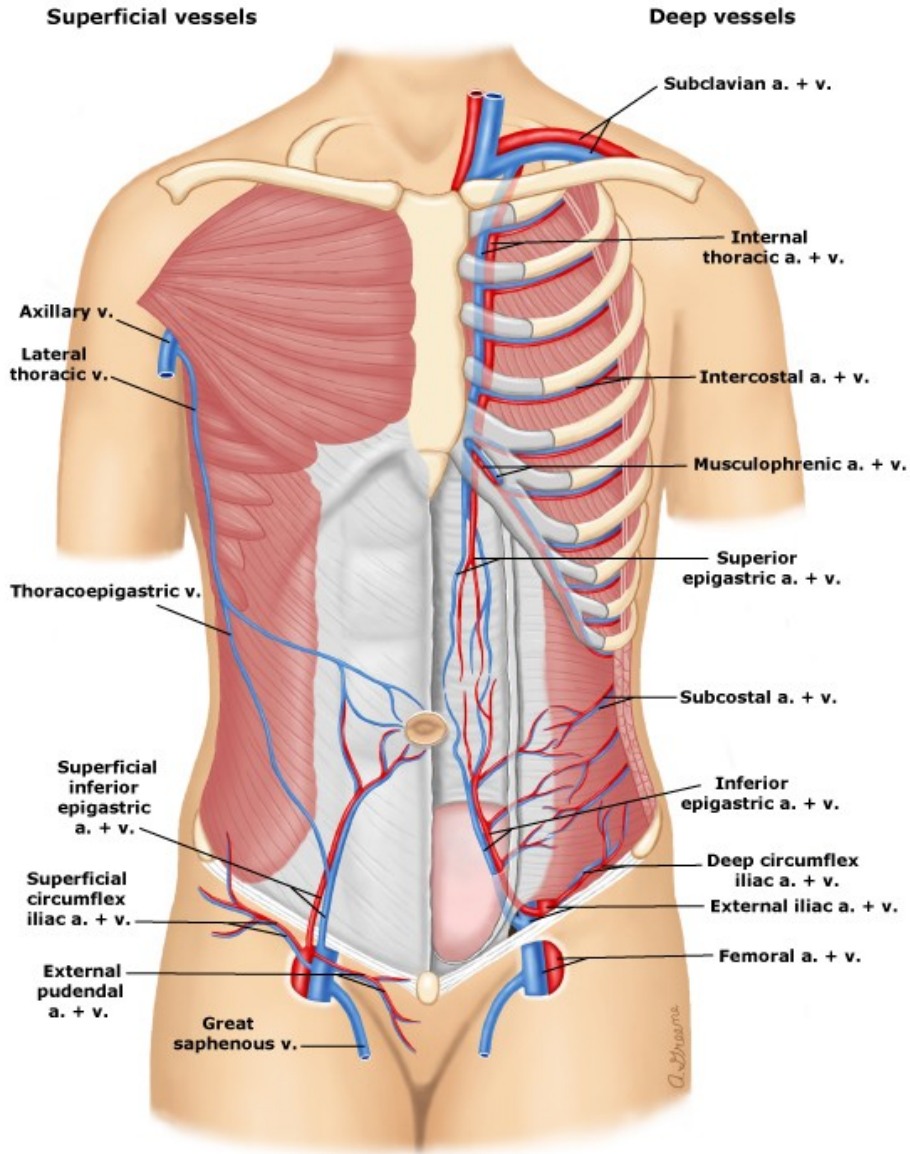
Open the rectus sheath by a median incision from the sternum to pubis symphysis

Reflect the sheath

Loose the rectus abdominis and identify the superior and inferior Epigastric vessels behind the rectus abdominis

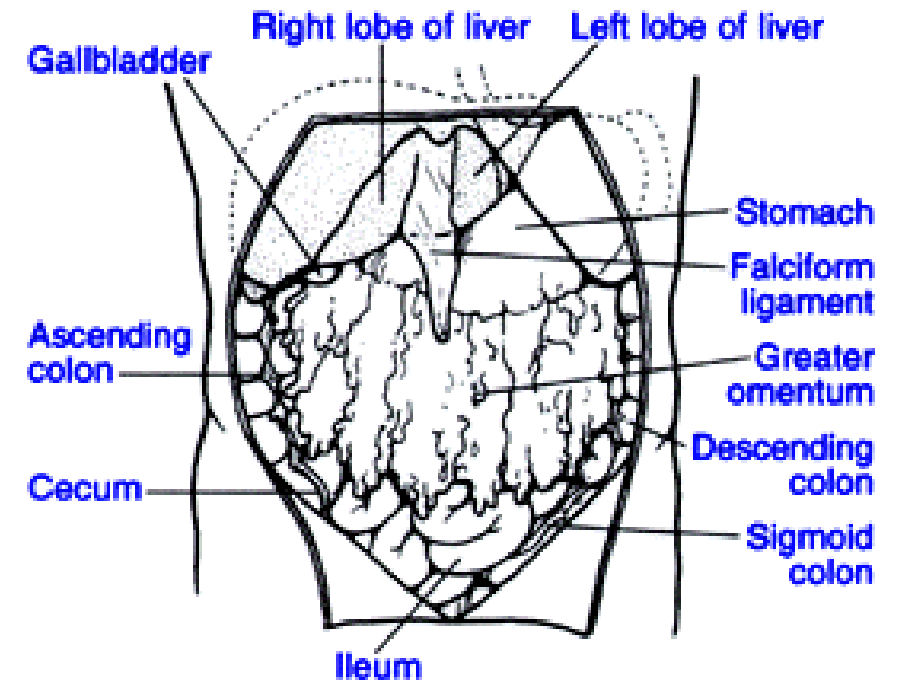
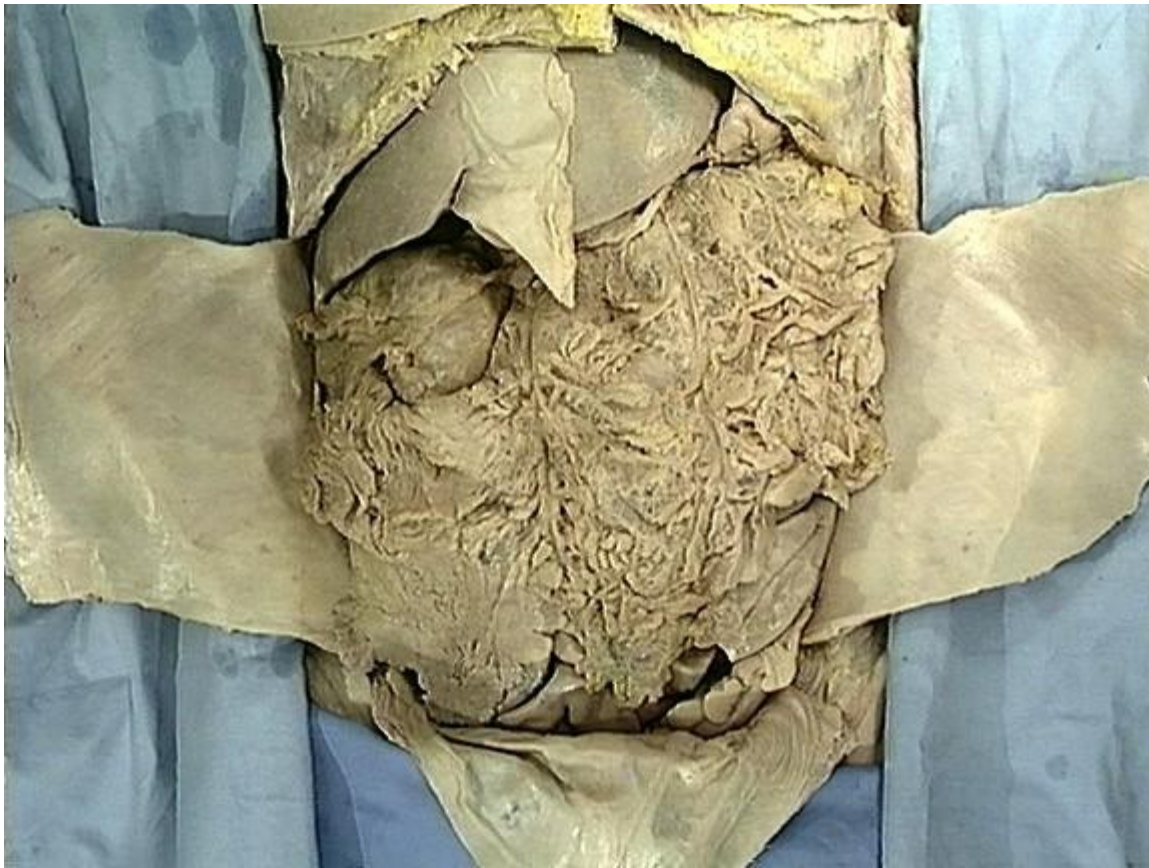

Superior Epigastric Artery and Vein (<Internal thoracic artery/vein)
 Inferior Epigastric Artery and Vein (<External Iliac artery/vein)
 Deep Circumflex Iliac Artery and vein (< External Iliac artery/vein)



The space that has been opened is the major portion of the peritoneal cavity, called the **greater peritoneal sac**. This space is located between the inner surface of the abdominal wall and the outer surface of the abdominal viscera. The greater peritoneal sac is bounded between the parietal and visceral peritoneum. It communicates through the epiploic foramen (of Winslow) with the smaller, **lesser peritoneal sac** (also called **omental bursa**). The lesser peritoneal sac is the largest recess of the peritoneal cavity and is located posterior to the stomach. Its boundaries will be described later.

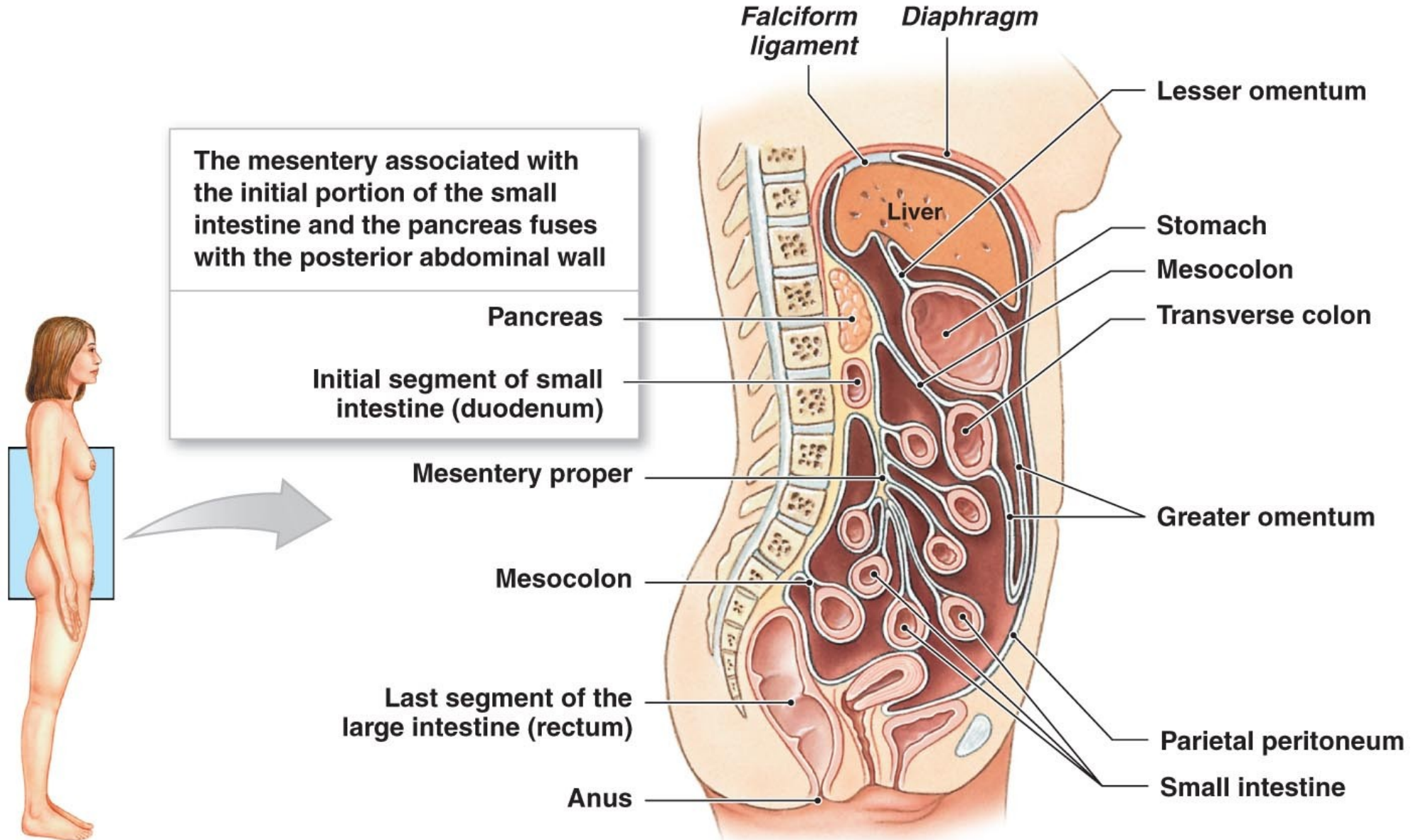
The **Falciform ligament of the liver** is formed as the visceral peritoneum that covers the liver and is reflected onto the internal surface of the anterior abdominal wall as ligamentum teres



The peritoneum is divided into two parts: the visceral peritoneum, which covers the surface of the visceral organs, and the parietal peritoneum, which lines the internal surface of the walls of the abdominal and pelvic cavity. Inside the abdominal cavity the peritoneum forms folds or reflections, referred to as mesenteries and peritoneal ligaments. Mesenteries attach organs to the posterior abdominal wall. Peritoneal ligaments generally attach one organ to another. Peritoneal ligaments and mesenteries hold abdominal organs in place, and serve as conduits through which nerves, blood and lymphatic vessels pass to and from the abdominal organs.

An organ, which is surrounded by the peritoneum and has a supporting mesentery, is defined as an **intraperitoneal organ** (e.g. **spleen, liver, and transverse colon**). An organ, which is only partially covered by the peritoneum and has no supporting mesentery, is defined as a **retroperitoneal** or **extraperitoneal organ** (e.g. **pancreas, kidney, ascending colon, and descending colon**).

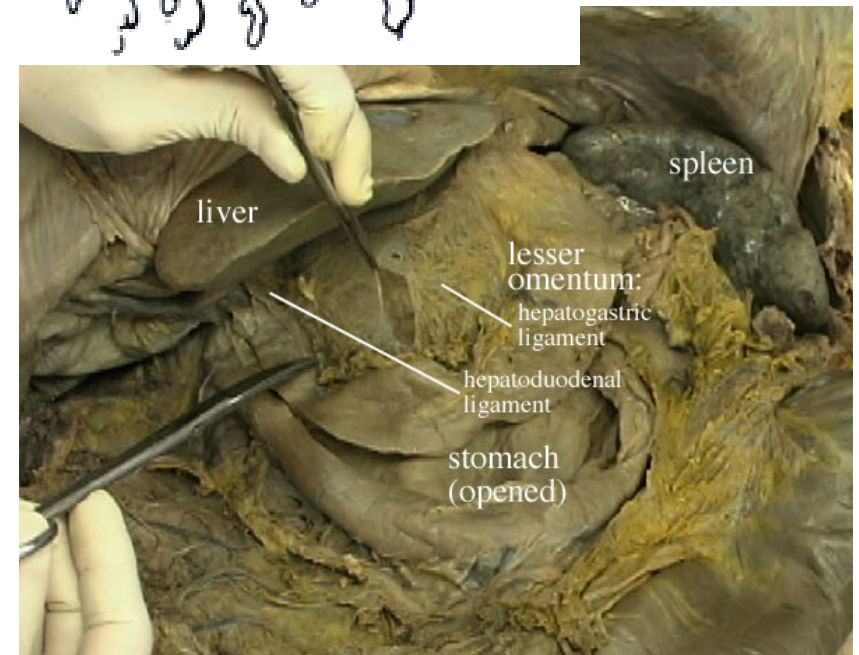
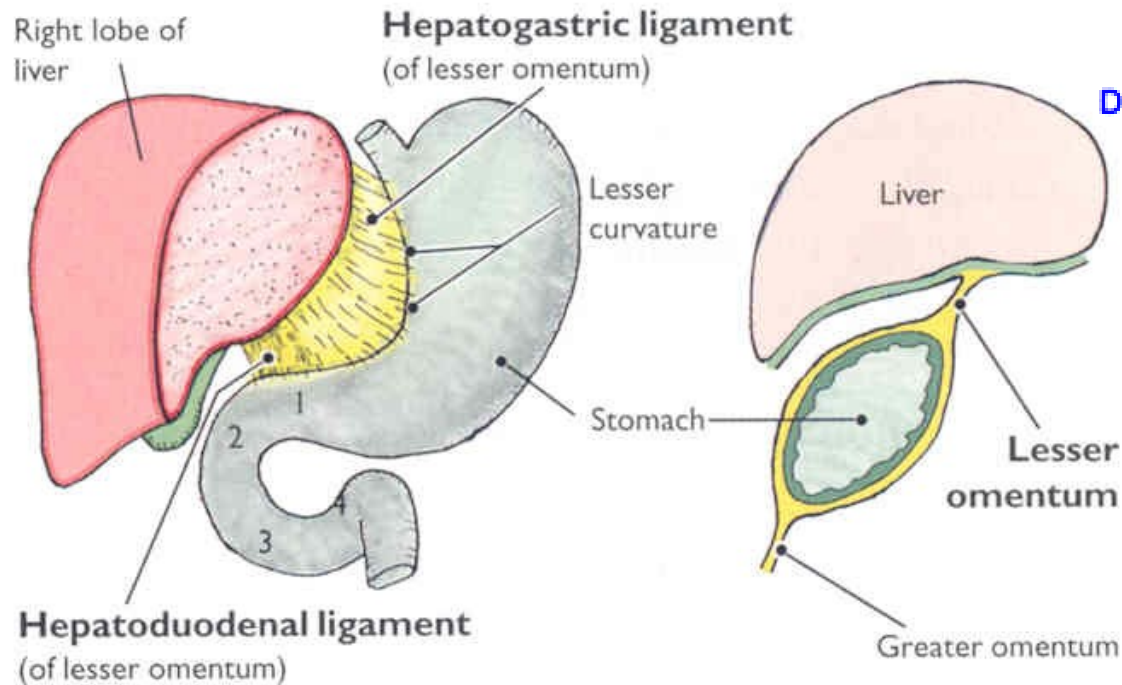
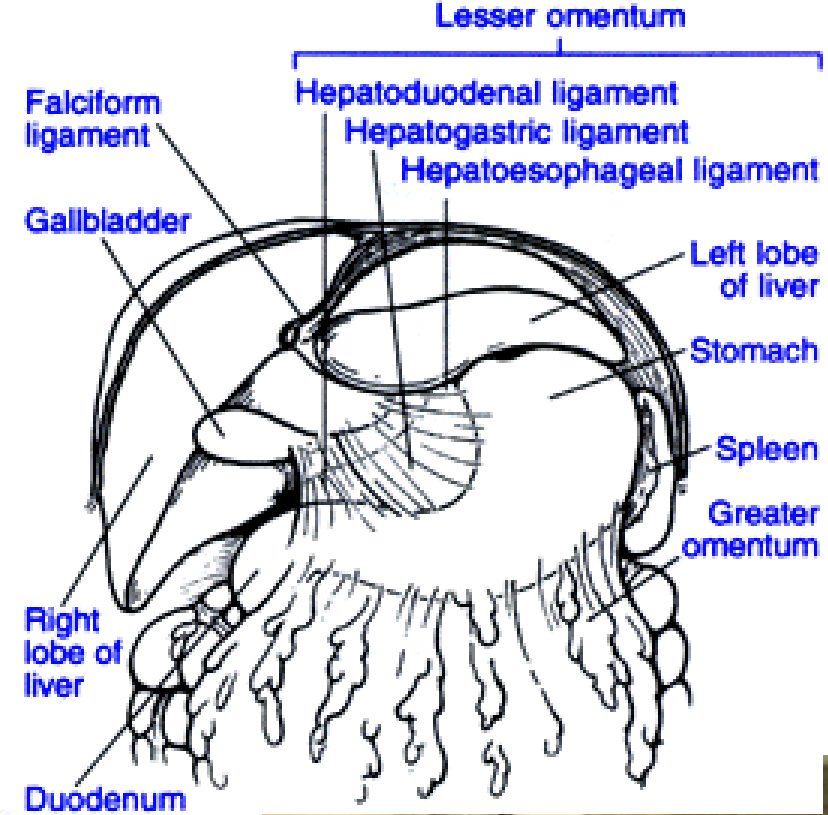
A sagittal section showing the orientation of the mesenteries in an adult



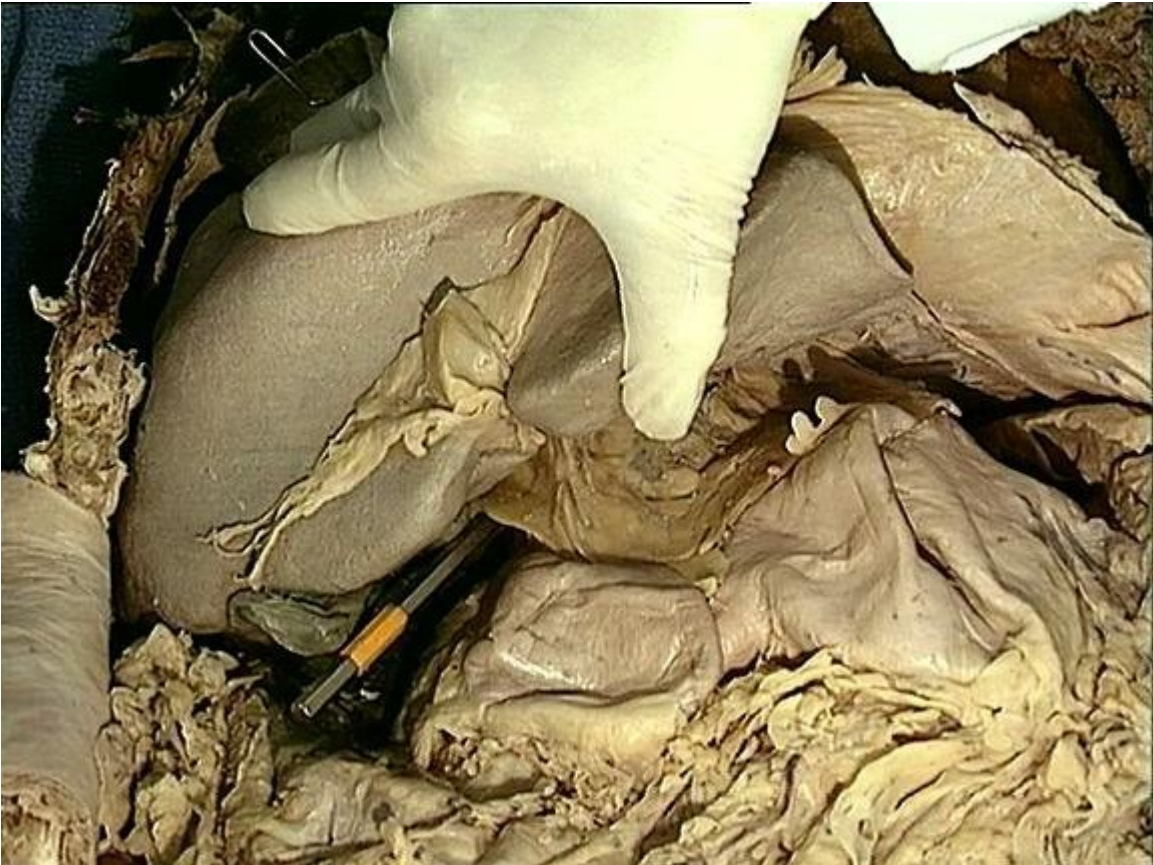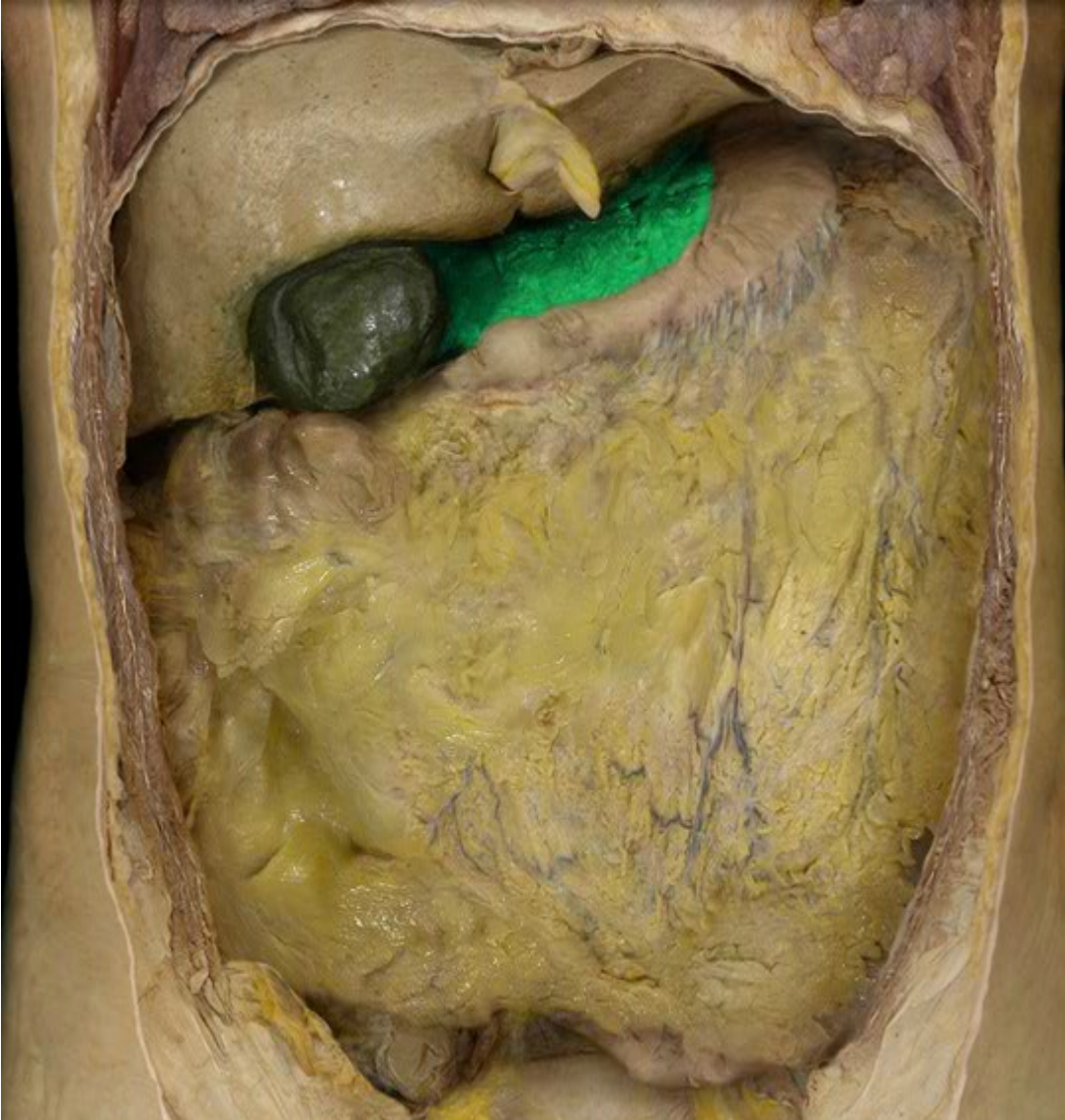The lesser omentum is actually a combination of three peritoneal ligaments:

- hepatoesophageal ligament
- hepatogastric ligament
- hepatoduodenal ligament

The hepatoduodenal ligament contains the proper hepatic artery, common bile duct, and portal vein. These three structures



the omental foramen (epiploic foramen, foramen of Winslow is the passage of communication, or foramen, between the greater sac (general cavity (of the abdomen)), and the lesser sac.

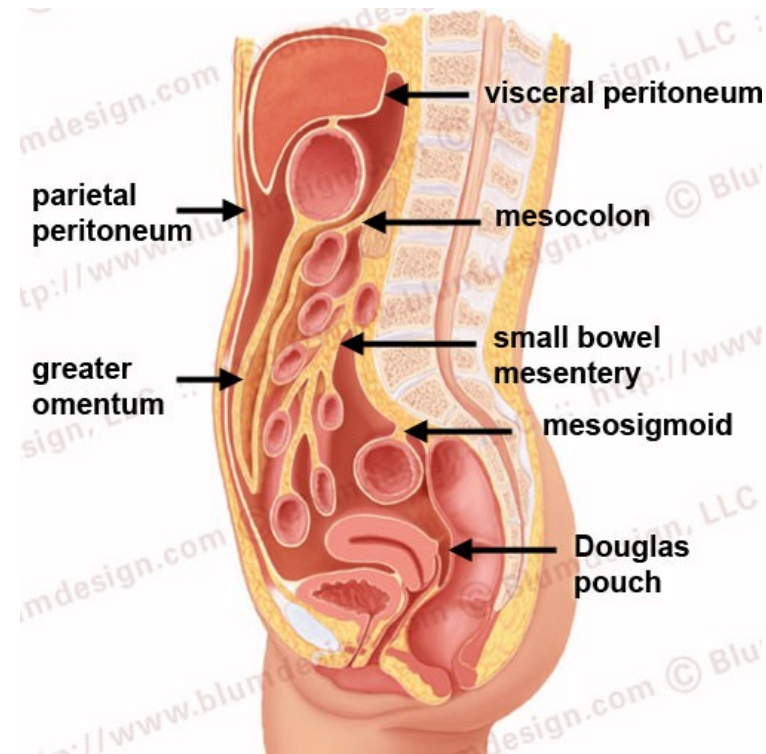
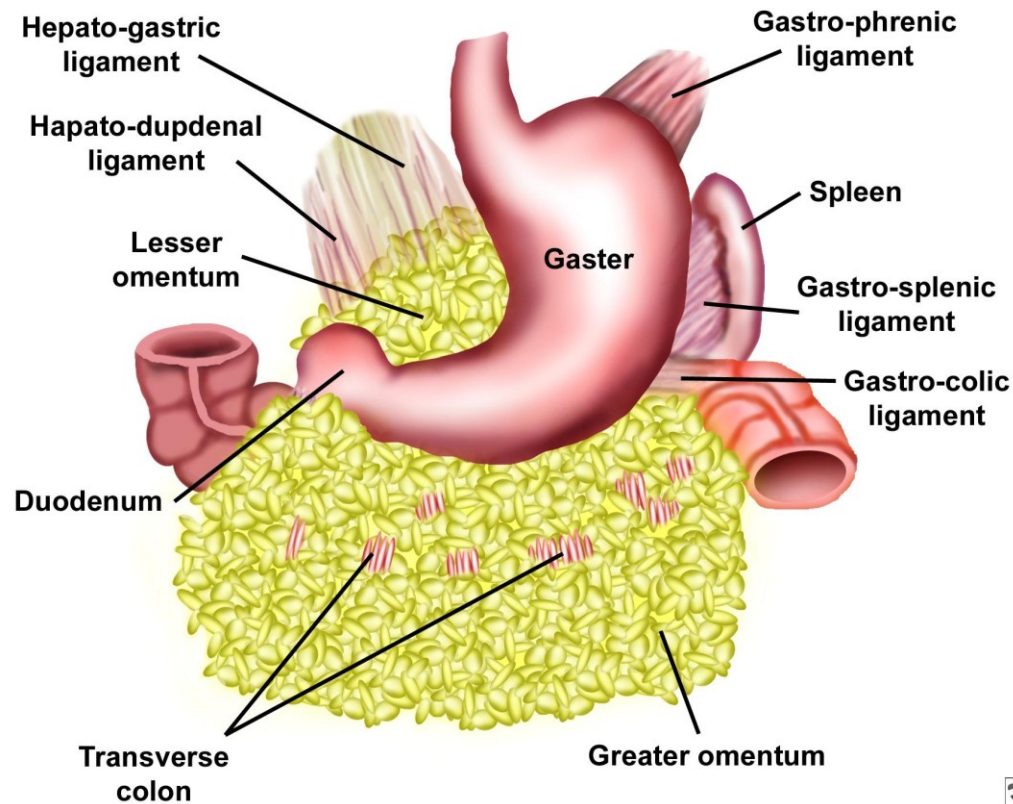


The greater omentum is the largest peritoneal fold. It consists of a double sheet of peritoneum. The two layers which descend from the greater curvature of the stomach and commencement of the duodenum pass in front of the small intestines, sometimes as low down as the pelvis; they then turn upon themselves, and ascend again as far as the transverse colon, where they separate and enclose that part of the intestine.

The left border of the greater omentum is continuous with the gastrosplenic ligament; its right border extends as far as the commencement of the duodenum. The greater omentum is often defined to encompass a variety of structures. Most sources include the following two

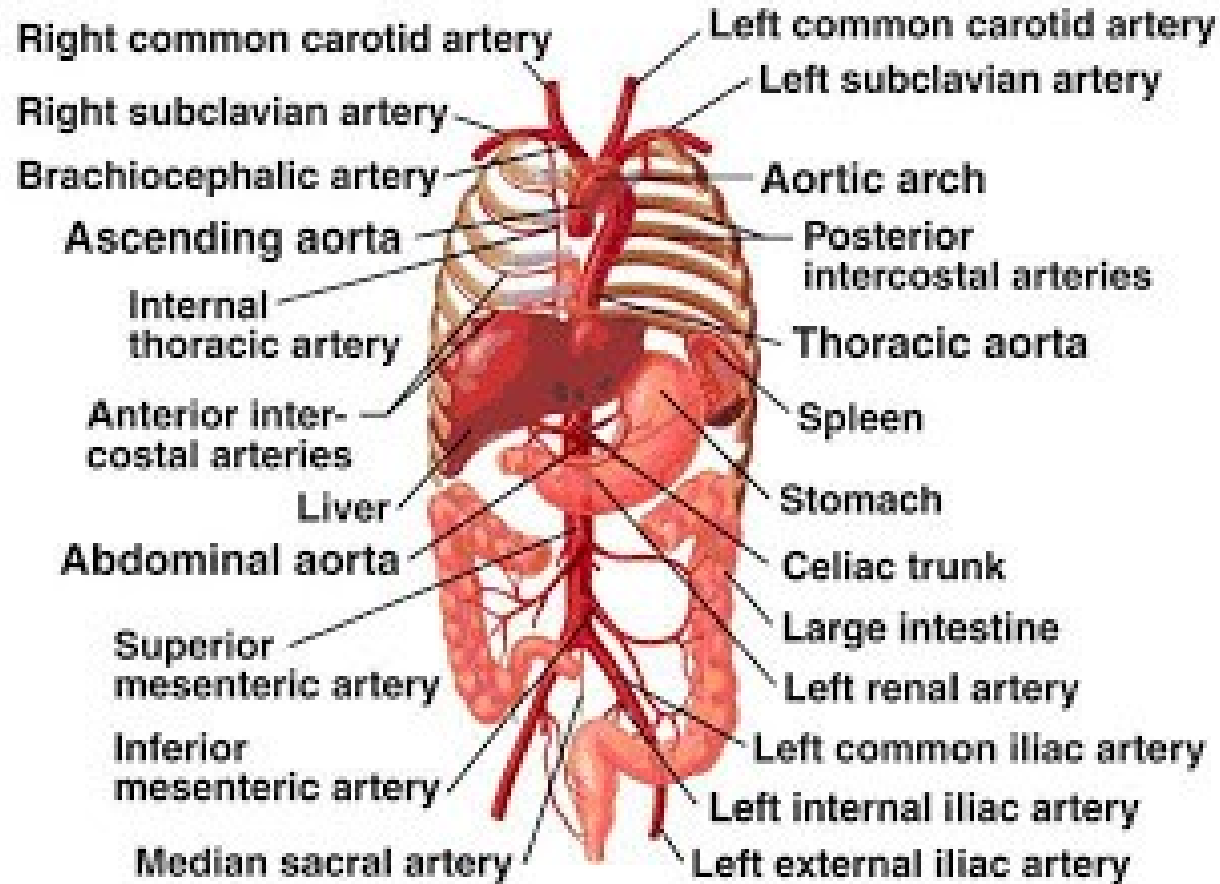
- Gastrocolic ligament - to transverse colon (occasionally on its own considered synonymous with "greater omentum")
- Gastrosplenic ligament - to spleen

The splenorenal ligament (from the left kidney to the spleen) is occasionally considered part of the greater omentum

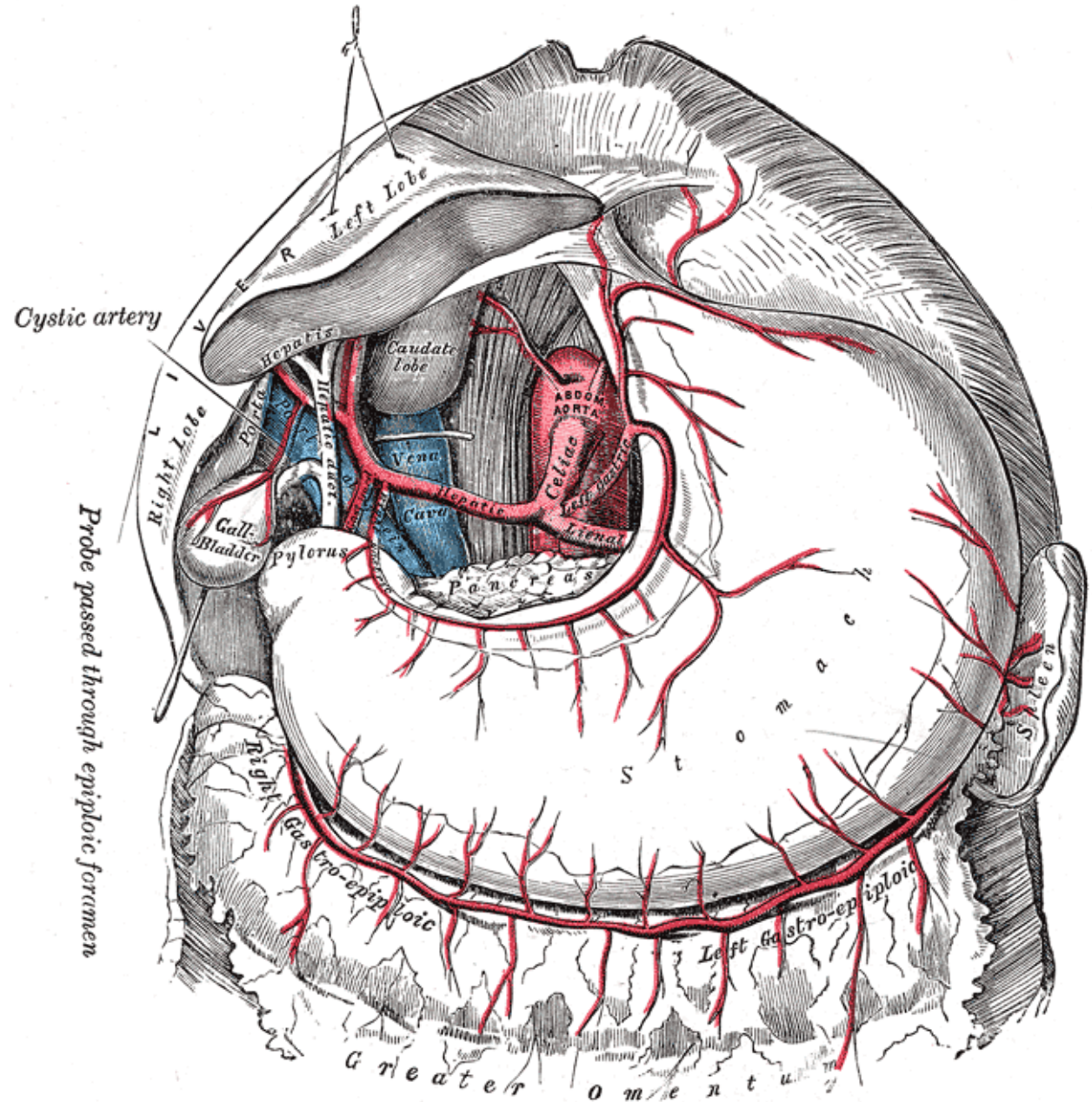


Blood Supply

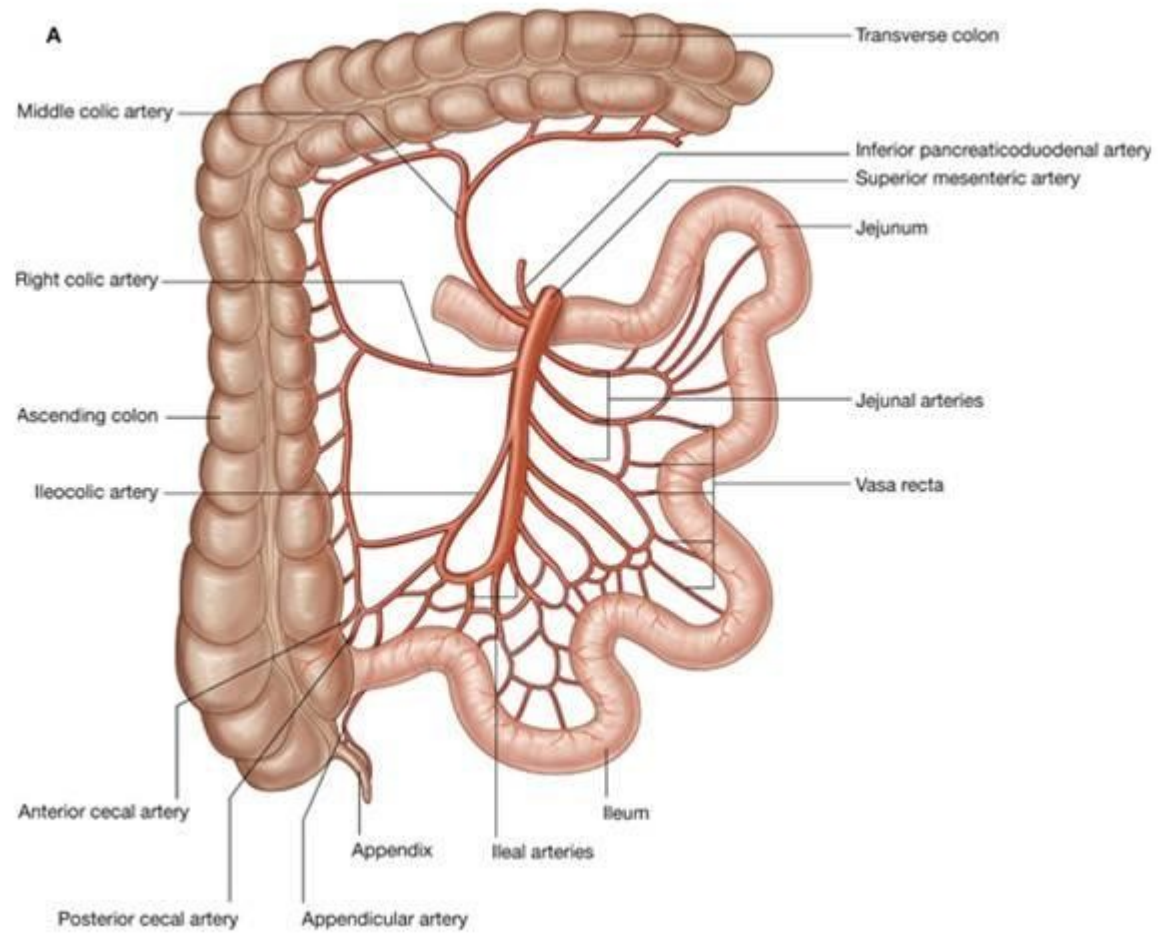
Copyright © The McGraw-Hill Companies, Inc. Permission required for reproduction or display.



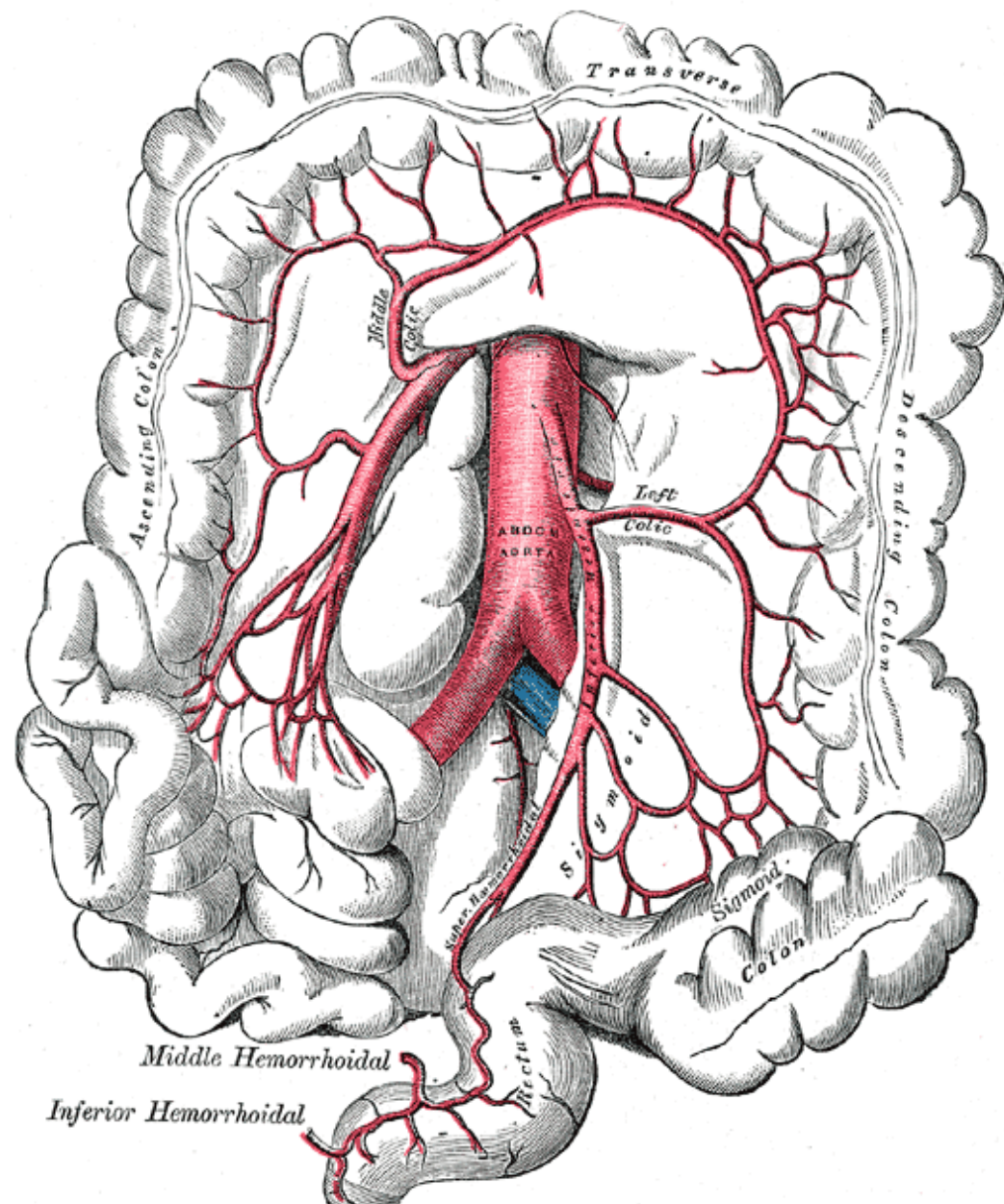
Coeliac Artery



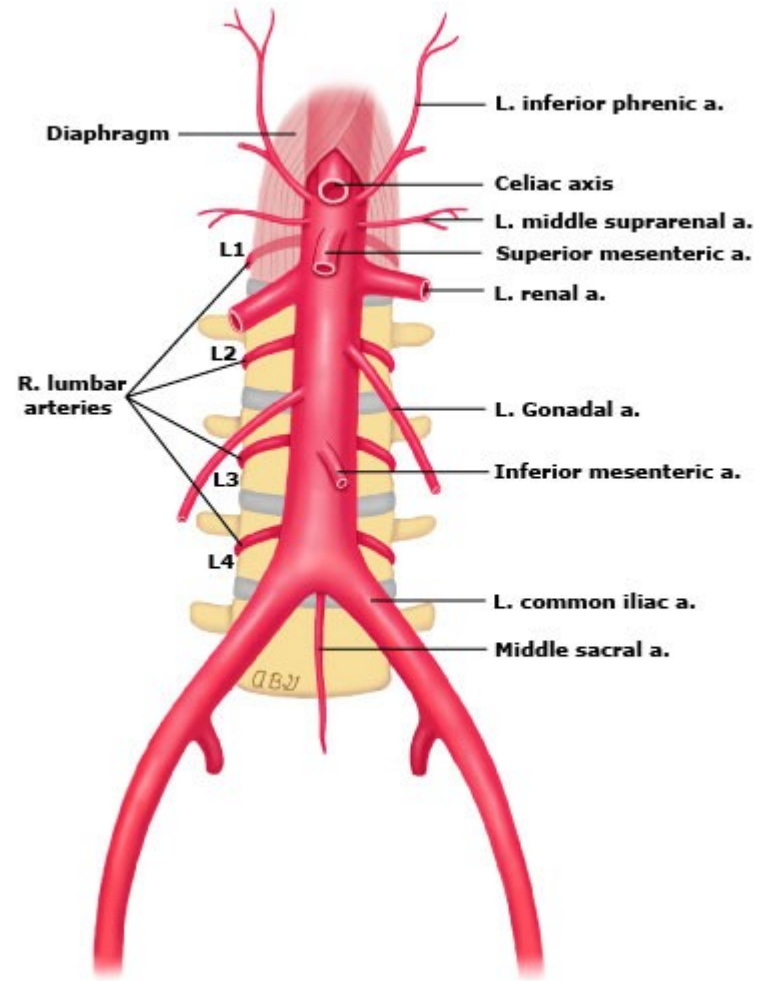
Superior Mesenteric Artery

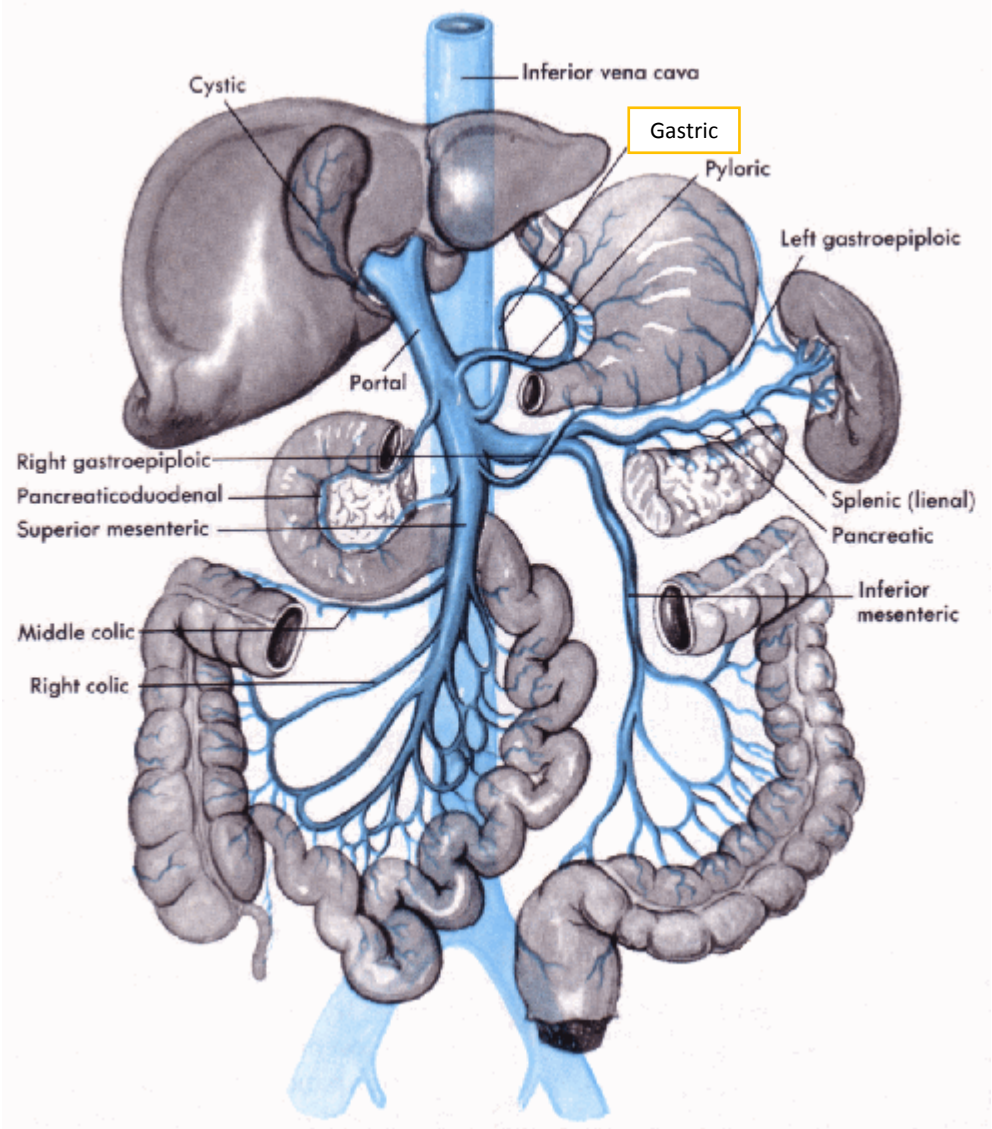


Inferior Mesenteric

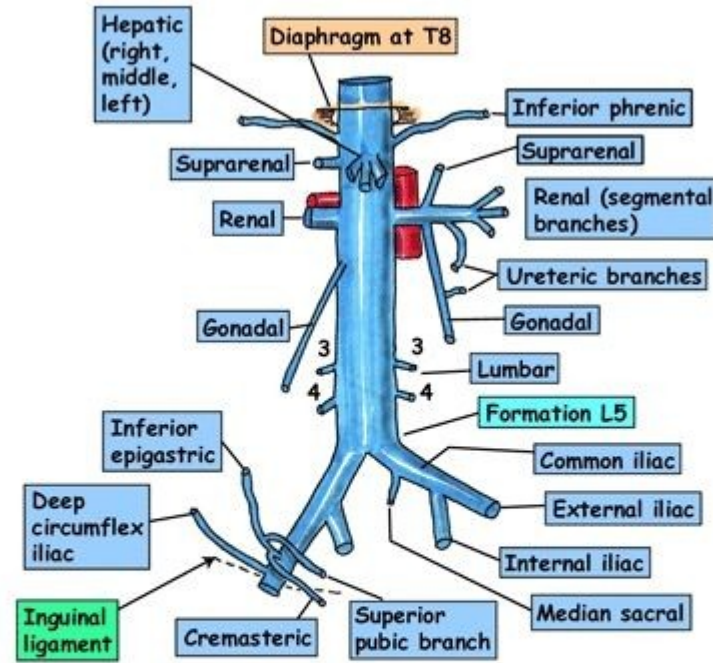


Abdominal aorta





INFERIOR VENA CAVA



Relations of IVC

Anterior: Bile duct, liver, opening of lesser sac, 1st/3rd parts of duodenum, head of pancreas, small bowel, right common iliac artery, root of mesentery, right gonadal artery, portal vein

Posterior: Right renal artery, lumbar arteries, right crus of diaphragm, right suprarenal & its artery, bodies of L3, 4, 5, right psoas, right sympathetic chain, right coeliac ganglion

Note: NO tributaries from gut

Stomach Shape

Most of the stomach projects to the **Left hypochondriac region**. The size of the stomach is variable, about 25 cm long. The volume is about 1 L, maximum capacity is about 2-3 L.

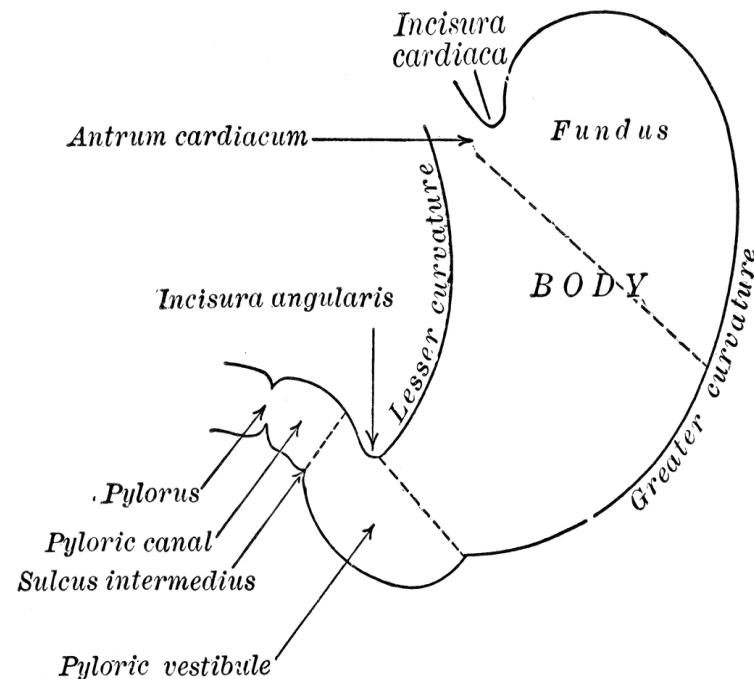
Cardia – surrounds the cardiac orifice, through which the stomach receives content through the oesophagus, left to the cardia there is a wide part that projects superiorly the fundus

Fundus ventriculi (fundus of stomach) – is separated from the oesophagus and cardia via the **incisura cardiaca**. Fundus continues downwards and to the right into the **corpus ventriculi (body of stomach)** which it turns to the right and horizontally verges into the **Pyloric Part**. **Pylorus** has a sphincter which opens only when if the content of the stomach is evacuated into the small intestine

ostium pyloricum – the opening through which the stomach communicates with the duodenum, and surrounded by the pylorus

Angular Notch(incisura angularis) - deeper notch in the lesser curvature that indicates the border between body of the stomach and its pyloric part

Cardiac Notch (incisura cardiaca)- separates the cardia from the fundus of the stomach

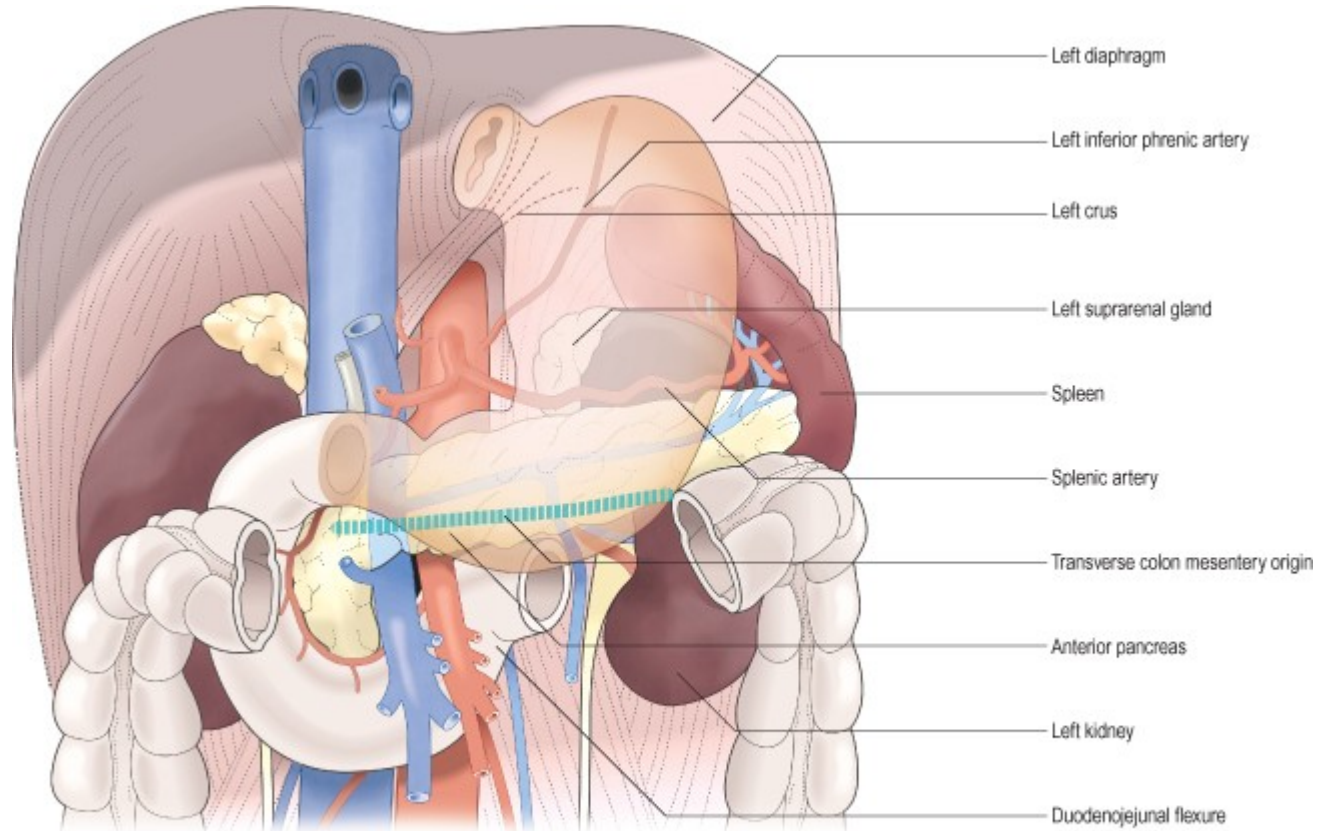


Anterior Part- Anterior wall of the stomach directs towards the liver, anterior abdominal wall in the range of epigastric region

Posterior Part- Posterior wall is directed towards diaphragm, left kidney, adrenal gland, spleen, pancreas and mesocolon transversum .

Lesser curvature - The smaller margin that directs superiorly and to the right

Greater curvature - the larger margin that directs posteriorly and to the left



The mucosa is folded into **Plicae gastricae (gastric folds)**, which are longitudinal or irregular. They disappear when the stomach is full but there are several constant folds along the lesser curvature that form **sulcus salivarius**.

There are 3 types of glands in the stomach.

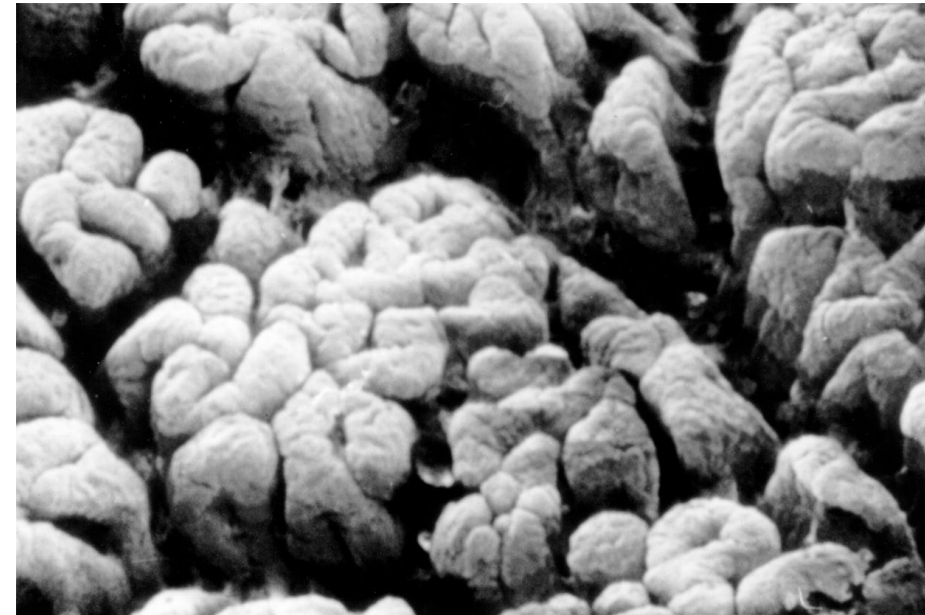
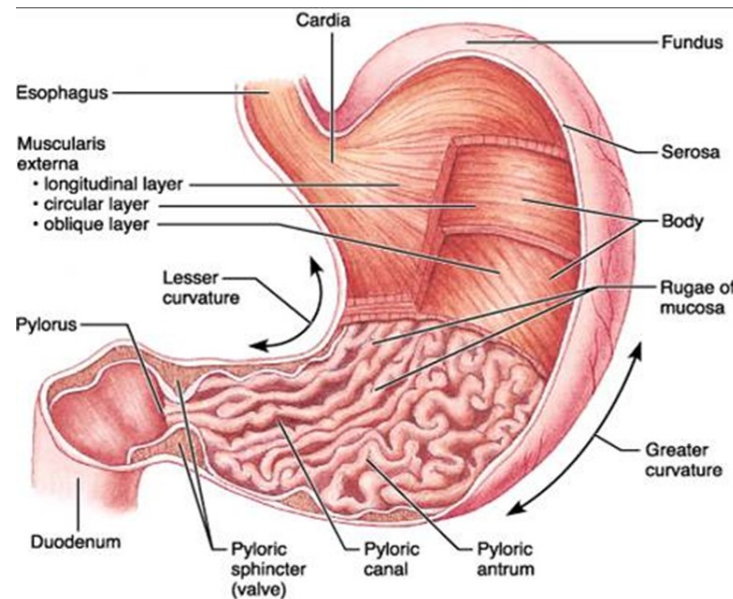
- cardiac gastric glands: glands in the beginning of the stomach, produce mucus.
- intermediate (**Tubulous glands**) gastric glands produce gastric juice, **succus gastricus**, containing HCl
- pyloric gastric glands: in the pyloric part, produce mucus .

All the gastric glands open into the orifices, **foveolae gastricae**, which are usually in the centers of small areas, about 2-6 mm in diameter, called **Areae gastricae**. This areas are surrounded by small grooves.

Endocrine cells in the pyloric mucosa produce the Gastrin hormone, that increases secretion of gastric juice.

Musculature – the musculature is formed by 3 layer.

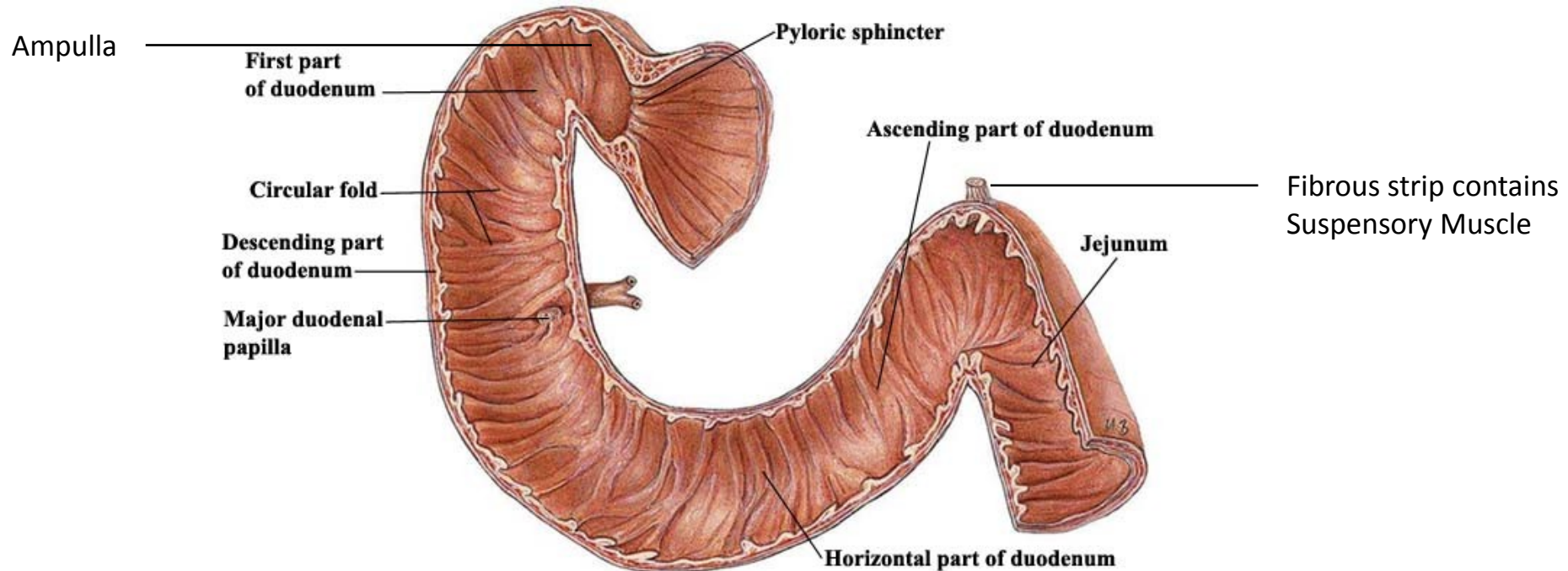
- Oblique fibers: direct from cardia towards greater curvature of the stomach.
- Circular layer– forms cardiac sphincter and m. sphincter pylori
- Longitudinal layer– the outer most layer of the musculature. Continue to the longitudinal musculature of the small intestine.



The duodenum

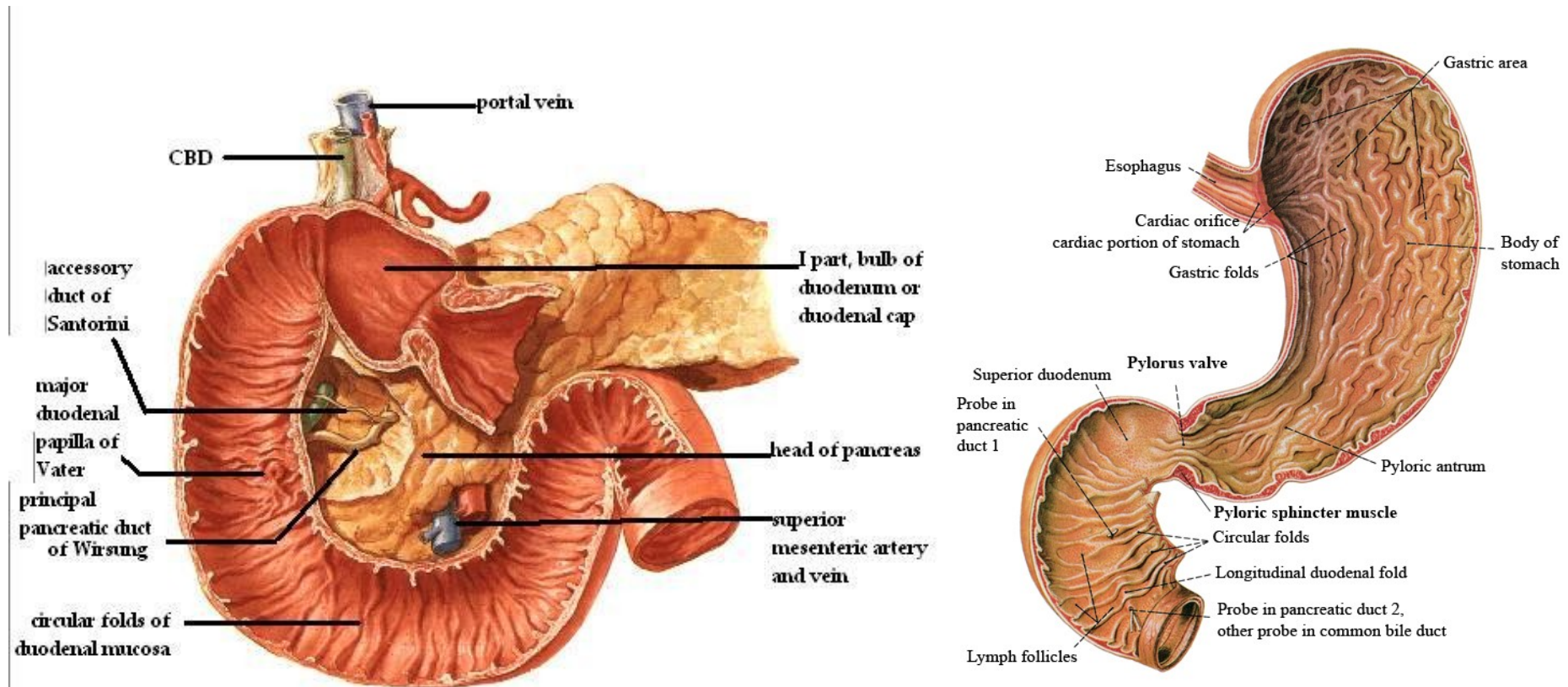
The duodenum is connected with the stomach through the **pyloric opening** and with the jejunum (small intestine) at **the duodenojejunal flexure**. The duodenum is 25-30 cm long and 3-4cm wide. It consists of **four parts**:

1. **Superior Part** (4-5cm): It is connected to the stomach at the level of L1 vertebra. It is enlarged at this level forming the ampulla of duodenum. **It is located intraperitoneally**. Then it turns caudally (superior duodenal flexure) and verges into descending part.
2. **Descending Part (6-10cm)**: it descends along the right margin of the lumbar vertebral column, L2-L3. Caudally at the right side of L3 and passes into the inferior/horizontal part forming the inferior duodenal flexure. **It is located retroperitoneally**.
3. **Horizontal (inferior) part** (7-8cm): It lies in front of L3 body. It is located retroperitoneally
4. **Ascending part**: Slowly turns upwards and then turns downwards and onto the right side of L2 verges into jejunum forming the duodenojejunal flexure. The position this flexure is provided by a fibrous strip (**Treitz's ligament**) which contains smooth muscles (**M suspensory of duodenum**) which starts from crus mediale sinistrum of diaphragm (Left Medial foot). **It is located retroperitoneally**.

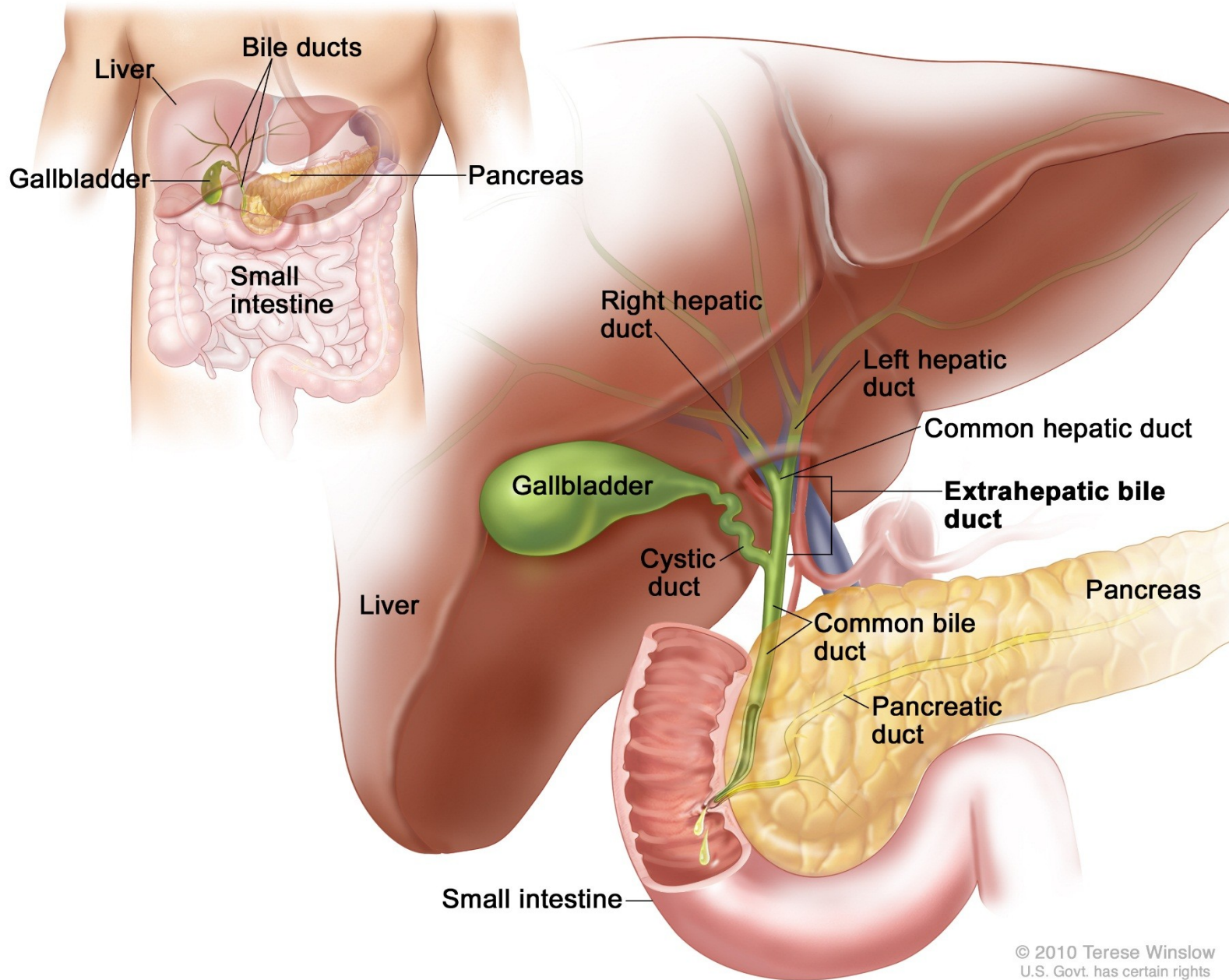


Structure of the duodenal wall

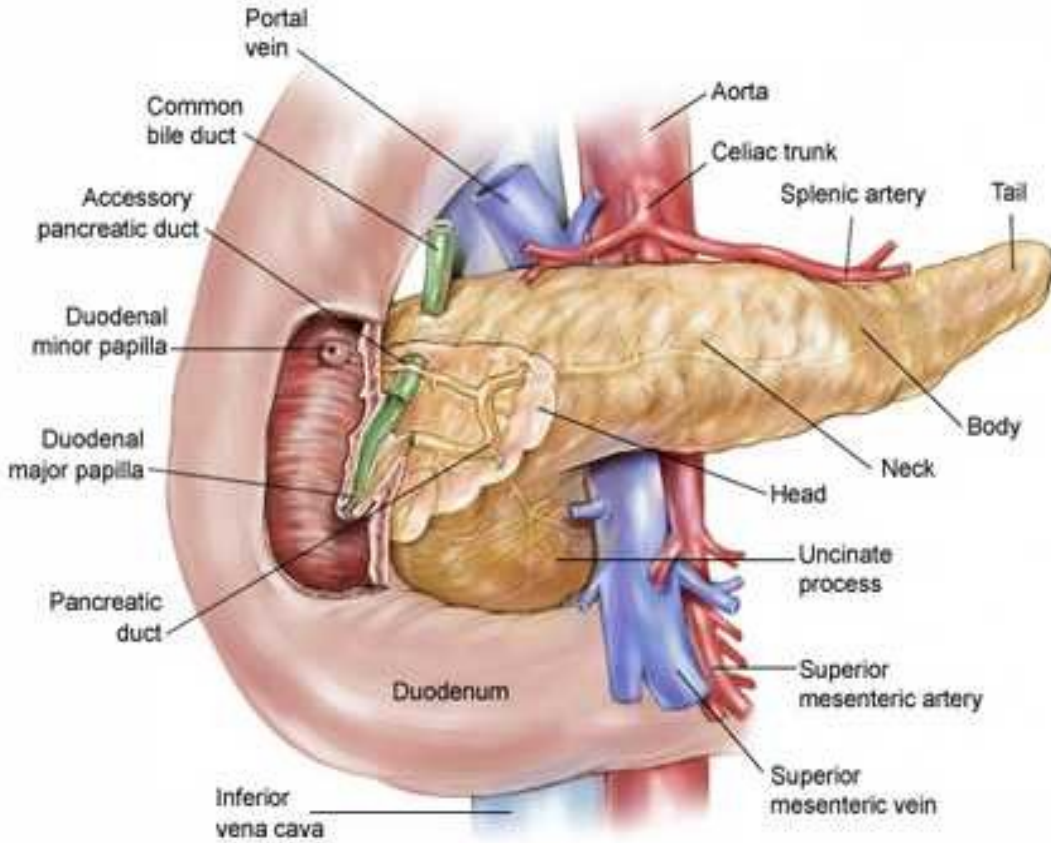
The duodenal mucosa is fitted with numerous **transverse circular folds** (plicae) which surfaces are covered **intestinal villi**. Inside the submucosa there are the **duodenal glands (Brunner's)** whose secretion is alkaline to neutralize with the acidic secretion of the stomach. On the posterior wall of descending part there is the **longitudinal duodenal fold** which is conditional on the course of ductus choledochus. This fold terminates distally on the **major duodenal papilla (pailla of Vater)** (10 cm from pylorus) onto which the **ductus choledochus and major pancreatic duct** opens out. The common section of these ducts is enlarged in **hepatopancreatic ampulla** and it against the duodenal lumen it is enclosed by the M. Sphincter of Oddi. Approximately 2 cm above major duodenal papilla is located the **minor duodenal papilla** onto which the minor pancreatic duct opens out



Biliary tract



Pancreas

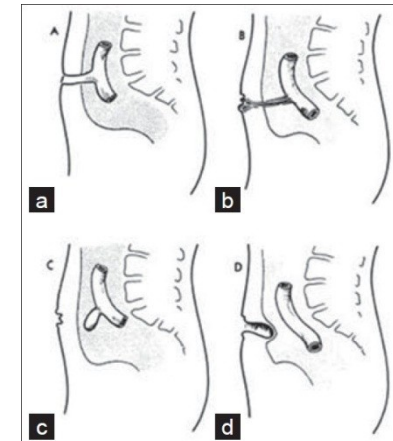
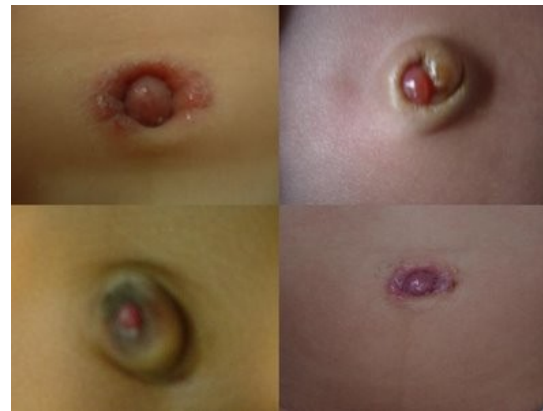
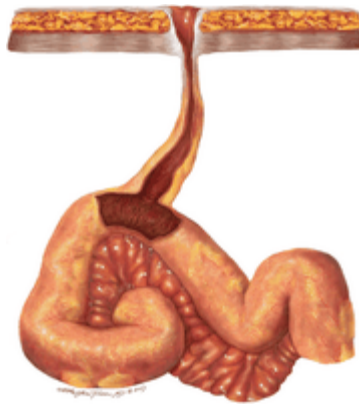
The small intestine; jejunum, ileum

The small intestine is hung by the mesenterium on the posterior wall of the peritoneal cavity. It is 3-5 meters long. It consists of the jejunum and the ileum. The jejunum joins the duodenum in the duodenojejunal flexure and the ileum opens into the lateral wall of the caecum (ileo-caecal opening) This opening is equipped with the ileocaecal valve which obstructs the retrograde passage of the large intestine's content into the small intestine. The junction between the jejunum and ileum is not quite distinct . Nevertheless there are numerous differences between both parts:

JEJUNUM	ILEUM
upper left part of the (inframesocolic space) Peritoneal cavity	lower right part of the (inframesocolic space) Peritoneal cavity
wider (3-4 cm)	narrower (2-3 cm)
more plicae circulares (circular folds)	fewer plicae circulares (circular folds)
1-2 arcades → Arteries of small intestine	2-3 arcades → Arteries of small intestine
folliculi lymph. Solitarii	folliculi lymph. Aggregati

In 2% of all cases there is a blind **diverticulum (Meckel's)** inside the intestinal wall . This is a remnant of ductus omphaloentericus .Rarely is open and can continue up to the umbilicus and then in newborn , the ileal content outflows on the body surface (umbilical fistula)



The large intestine (colon)

On the wall of large intestine there are small pouches which are called **haustra** and they are made by the sacculations of large intestine. There are also numerous small appendices which contain fatty tissue, **the epiploic appendices (appendices epiploicae)**. In the cavital side the large intestine has **semilunar folds (plicae semilunaris)** but **WITHOUT VILLI**.

The submucosa separates the mucosa from the musculature and contains vascular and nerve plexuses

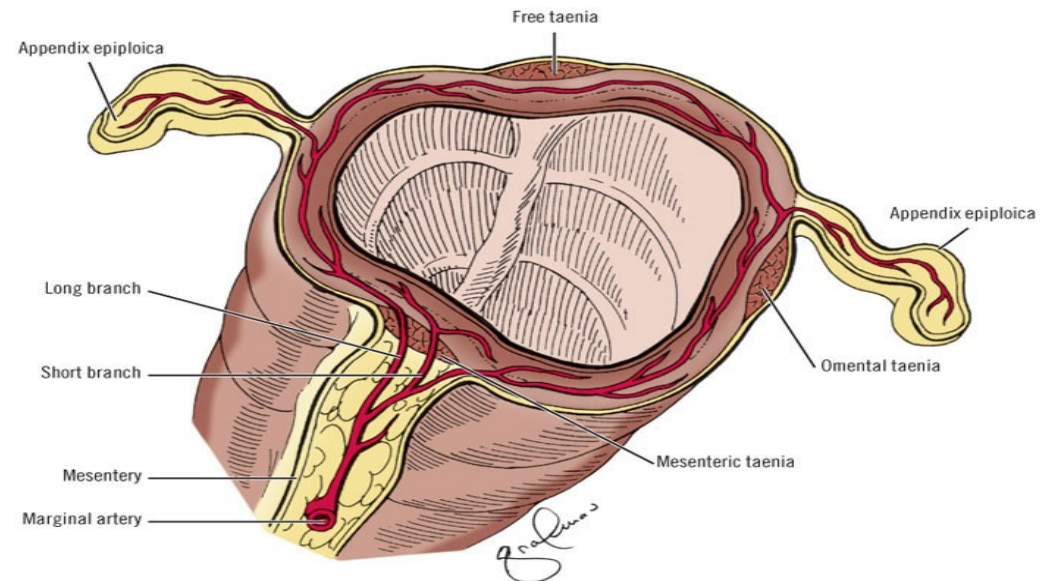
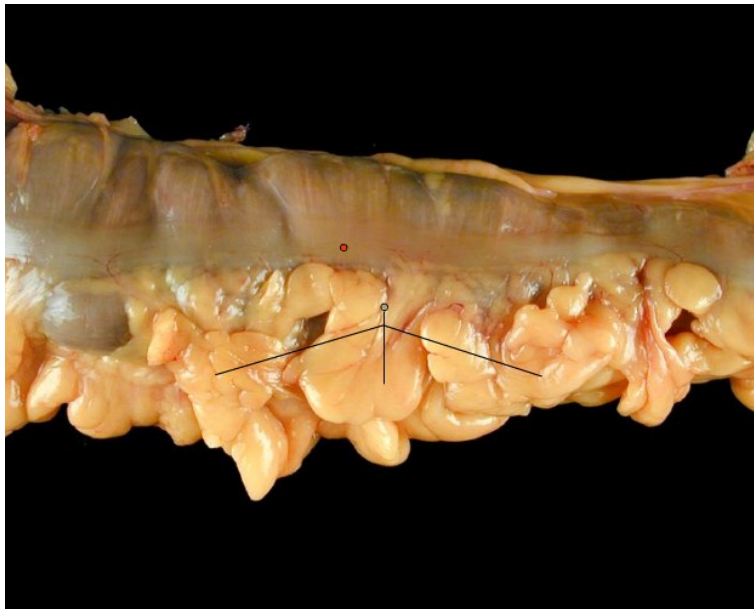Musculature has two layers:

- circular musculature – inner layer
- longitudinal musculature – outer layer, it is more developed in the three stripes called taeniae:

Omental taenia: attaches on the anterior side of the colon and it is also connected with greater omentum

Mesocolic taenia: attaches on the posterior side of the colon and it is also connected with the posterior abdominal wall

Free taenia (taenia libera): attaches on the inferior side of the colon and it is free



Copyright © 2006 by The McGraw-Hill Companies, Inc.
All rights reserved.

Taeniae are shorter than the large intestine and so they pull the large intestine and this is why the haustreae are formed

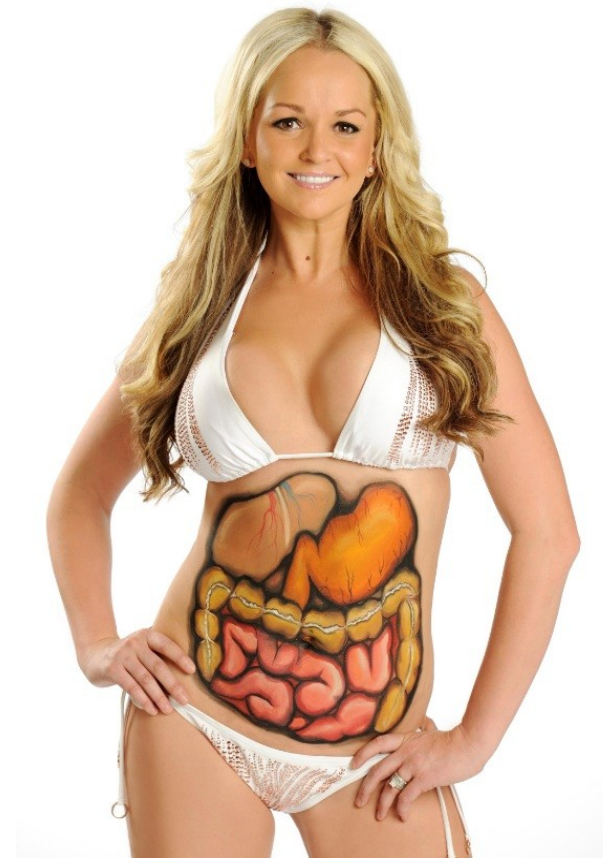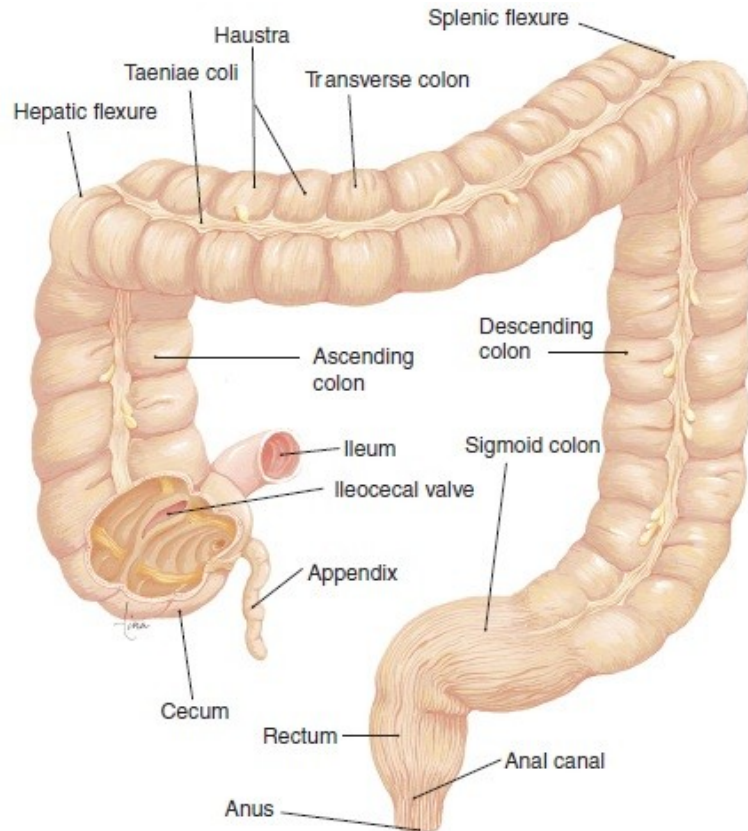
The large intestine (colon)

The large intestine consists of several parts:

- Caecum with the appendix vermiformis
- Ascending Colon → retroperitoneally
- Transverse Colon → intraperitoneally
- Descending Colon → retroperitoneally
- Sigmoid Colon → intraperitoneally
- Rectum

The ascending colon turns to the left, forming the right colic flexure (hepatic flexure)

The transverse colon turns caudally, forming the left colic flexure (splenic flexure)

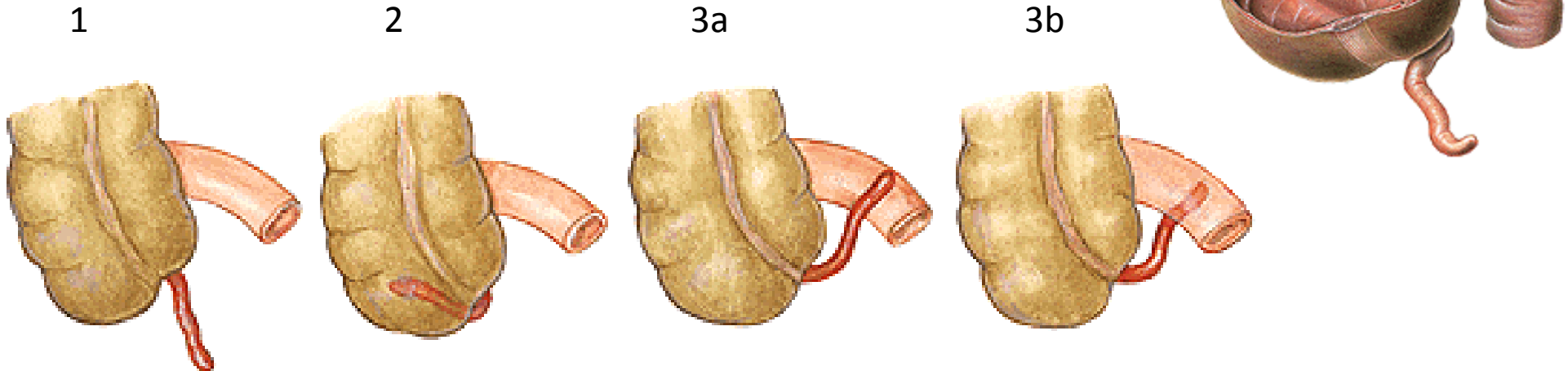


The caecum and the appendix

The caecum is an enlarged part of large intestine. Sometimes is free which means that is movable because it doesn't attach directly to the posterior abdominal wall but it hangs at its position by a peritoneal fold, which is called **mesocaecum**. The ileum opens on the medial side of caecum on the **ileocaecal opening (ostium)**. In the cavital side this structure appears as a papilla which works as a valve and is called **ileocaecal valve**. The ileocaecal valve has a superior and inferior lip. On the postero-inferior side of the caecum arise the **appendix vermiformis**. This point can be found during the surgery because is the intersection of the three taeniae. The appendix is hangs at its position by **the mesoappendix**. This peritoneal fold contains vessels which supply the appendix.

The appendix position is very variable:

1. **40%→pelvic position**: it passes the linea terminalis and it enters the small pelvis, often it attaches the right ovary and it can be connected with the ovary (appendiculoovarian ligament). This is important because appendicular inflammation can cause inflammation in the ovary and consecutive sterility
2. **10-15%→retrocaecal**: behind caecum
3. **~10%→ileocaecal, retroileal, subcaecal**
4. **2-5%→praecaecal**: in front of caecum



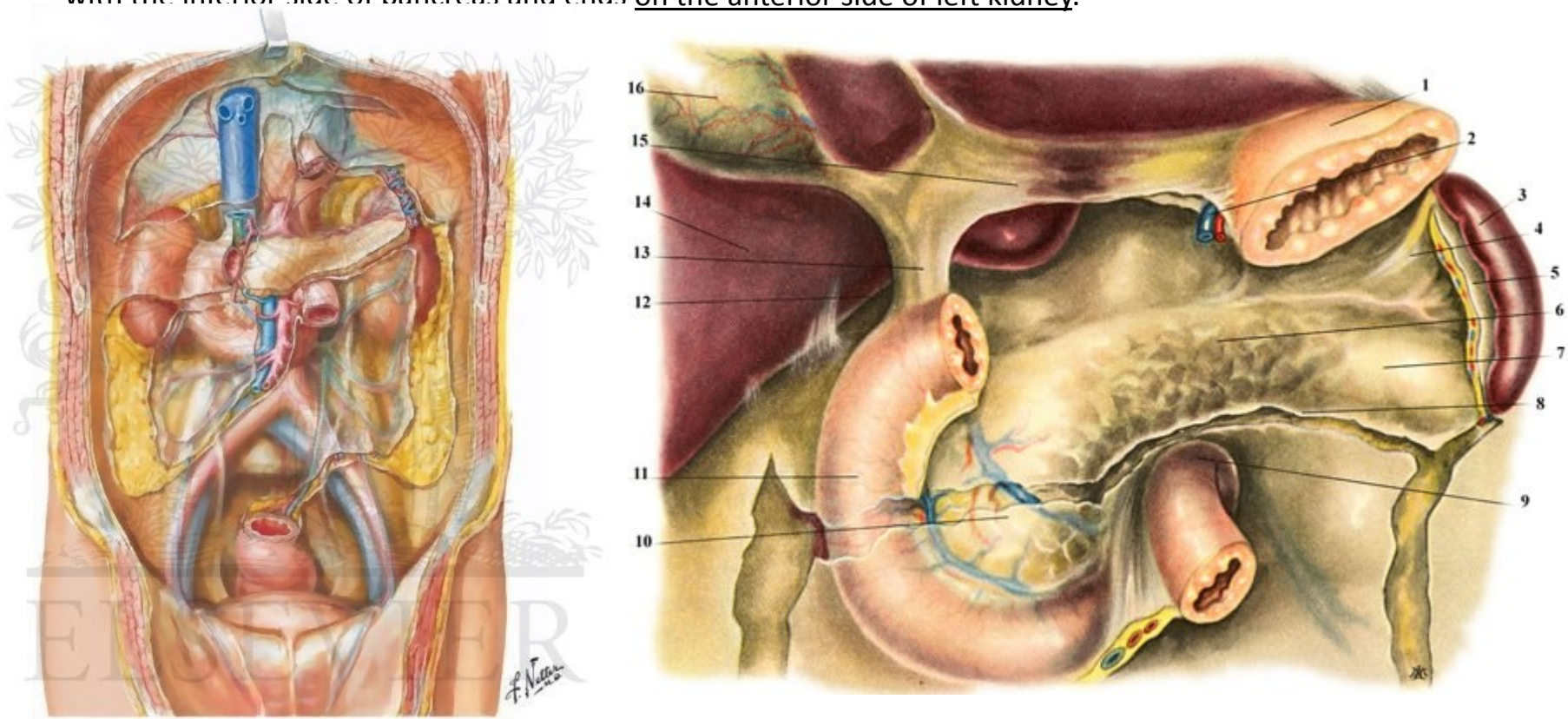
ASCENDING COLON

The ascending colon is located in the right plane of peritoneal cavity. It is about 20-30 cm long and it is the continuation of the caecum in the right plane of peritoneal cavity. Ascends towards visceral surface of the liver.

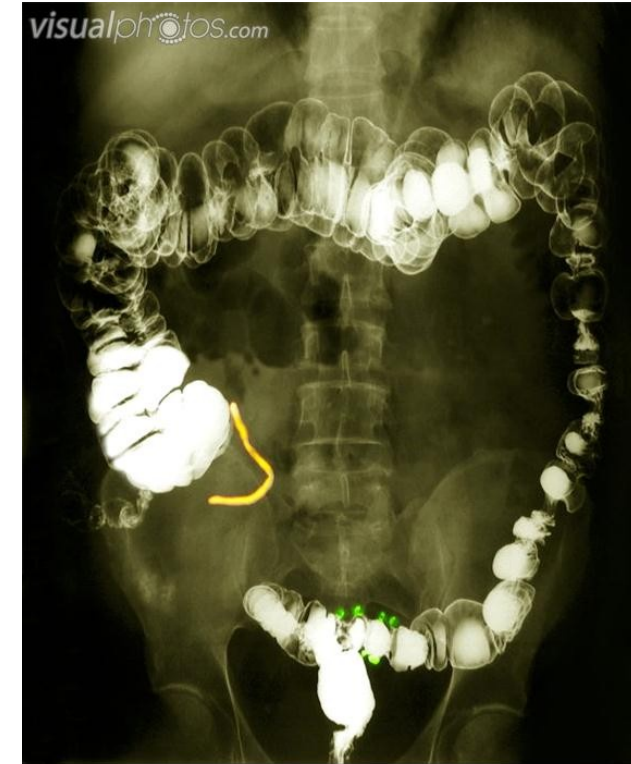
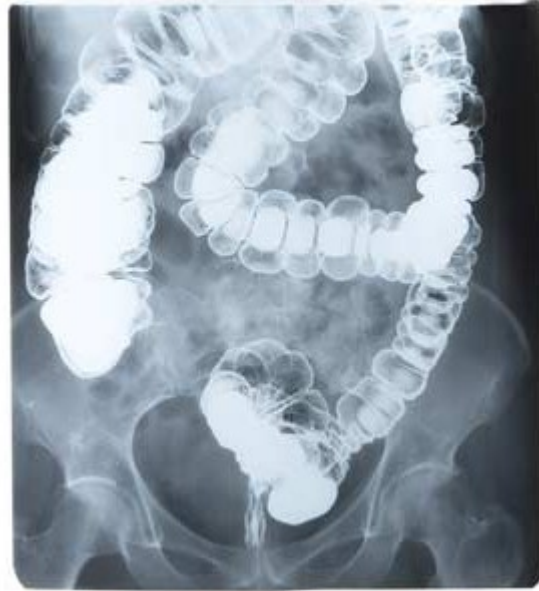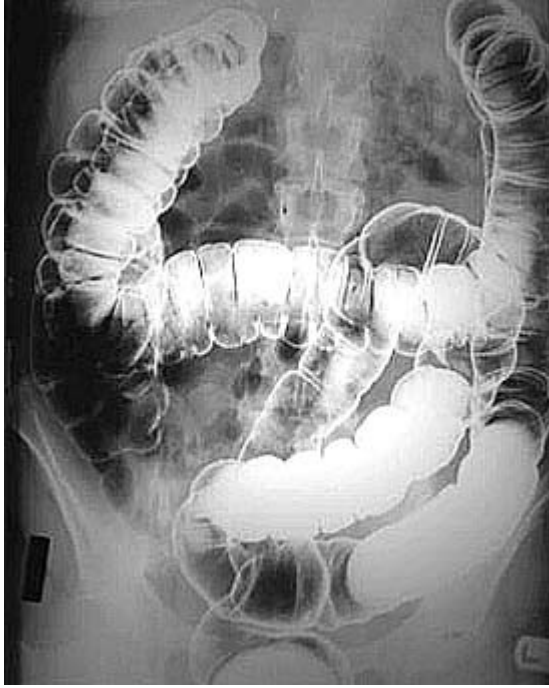TRANSVERSE COLON

The transverse colon is an **intrapertoneal portion** of the colon and it is mobile.

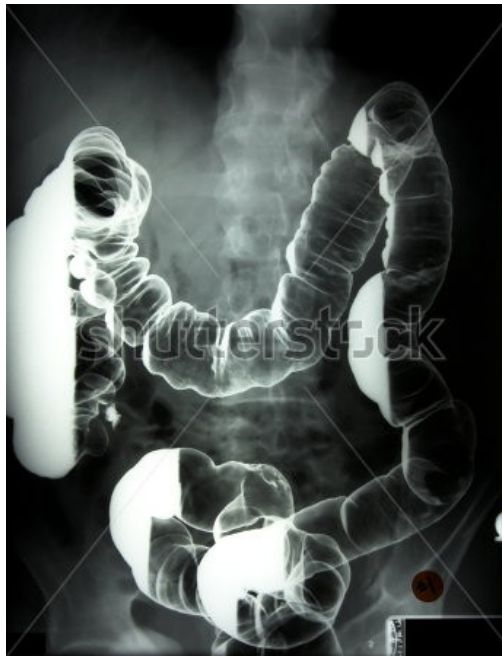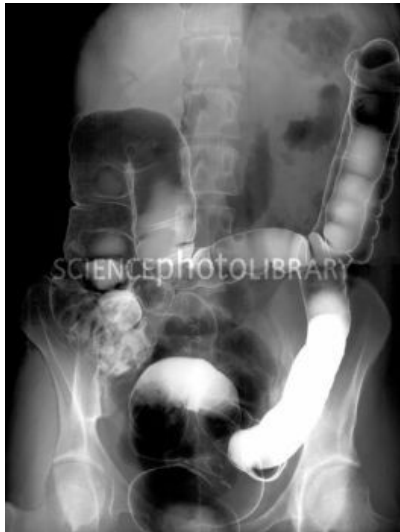It hangs at this position by the **mesocolon transversum**. This peritoneal fold attaches the transverse colon to posterior abdominal wall. It arises from the line on the posterior abdominal wall which passes from right renal hilus crosses the descending part of duodenum continues along with the inferior side of pancreas and ends on the anterior side of left kidney.



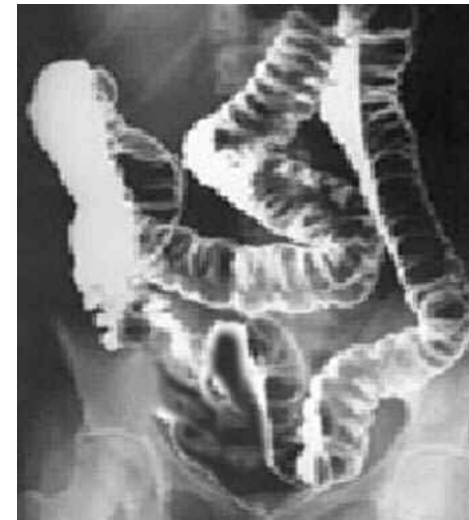The transverse colon is free!!!. It is mobile!!! It doesn't attach to posterior abdominal wall It hangs by the mesocolon transversum



BA2760 [RM] © www.visualphotos.com



www.shutterstock.com · 2165972

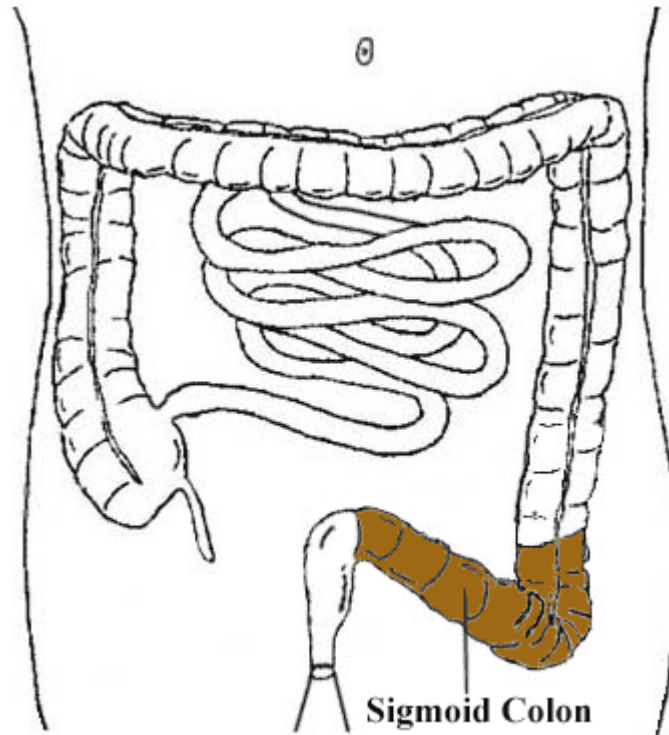


DESCENDING COLON

The descending colon is the continuation of the left colic flexure. It is longer than the ascending colon. It is located secondarily retroperitoneally. It descends to the left iliac fossa.

SIGMOID COLON



Sigmoid colon is the continuation of the descending colon, located in the left iliac fossa. It is S-shaped portion of large intestine. It is located **intraperitoneally and it is suspended on the peritoneal fold called the mesosigmoideum** that attaches the sigmoid colon to the posterior abdominal wall. Firstly, it directs downwards, then medially and finally over the terminal line between the greater and lesser pelvis. it descends to the lesser pelvis where it continues as the rectum.





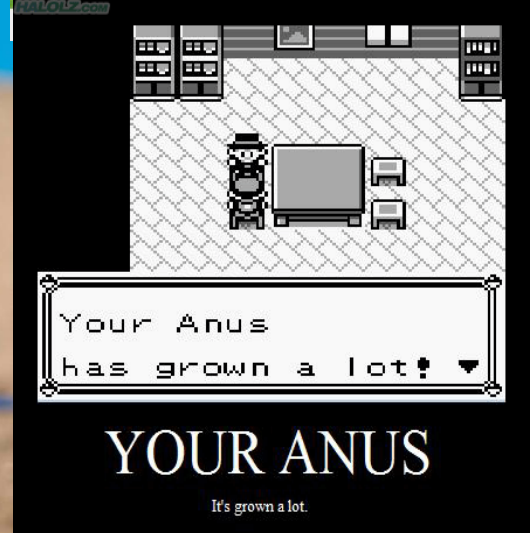
EEE

MEN.



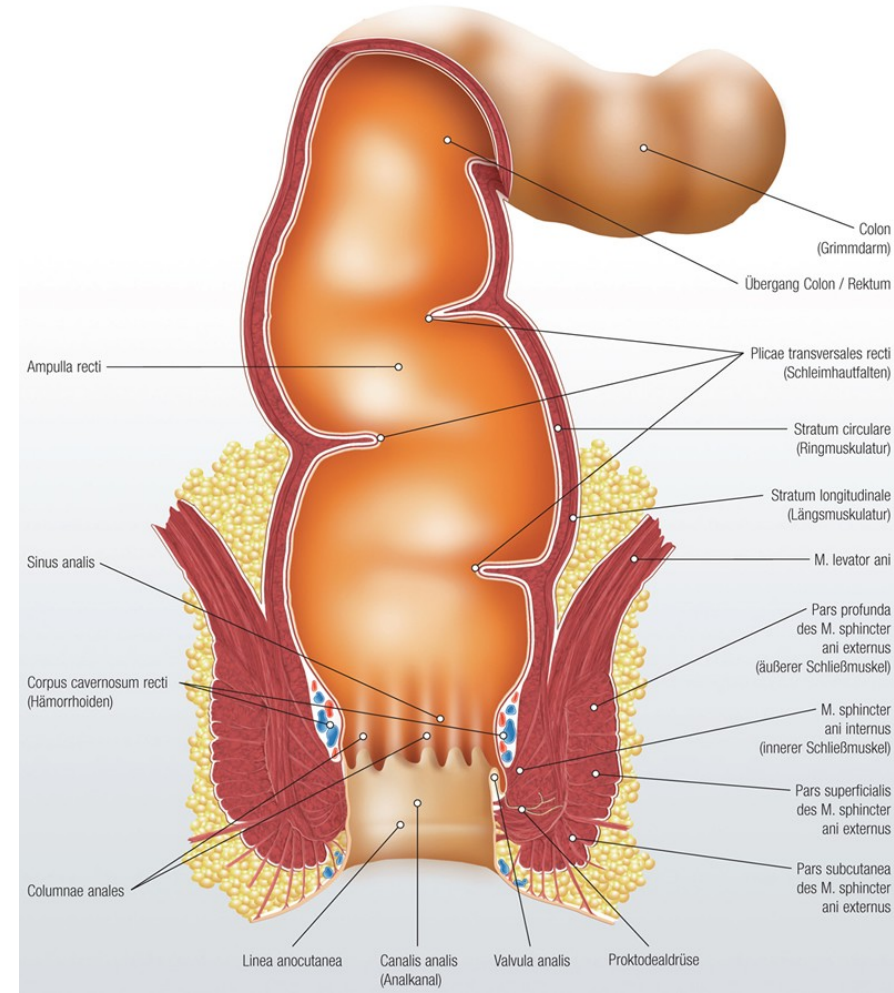
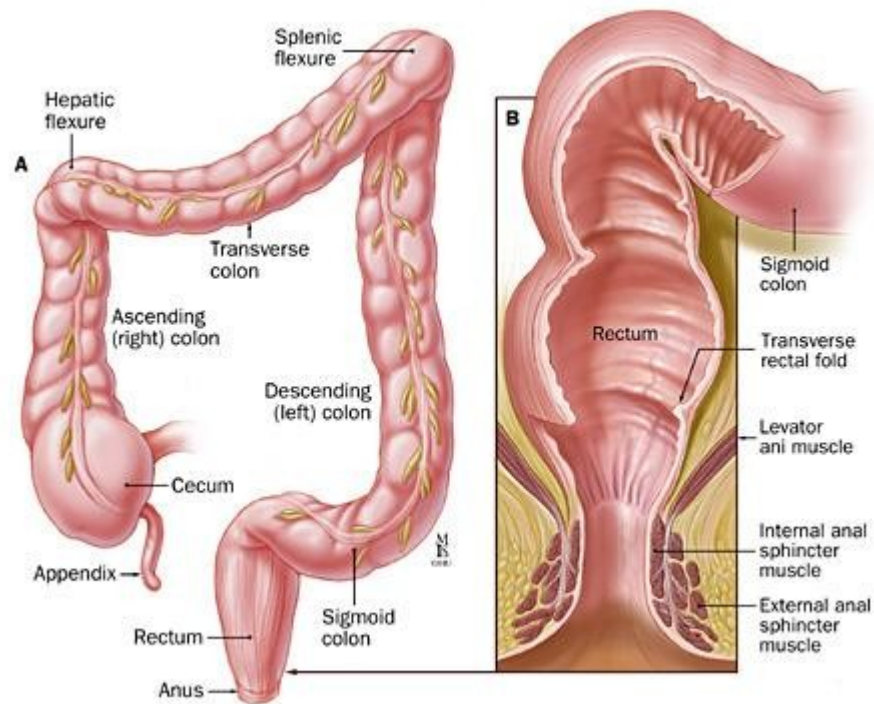
Why are you always in such a bad mood?

I have a nail in my anus.



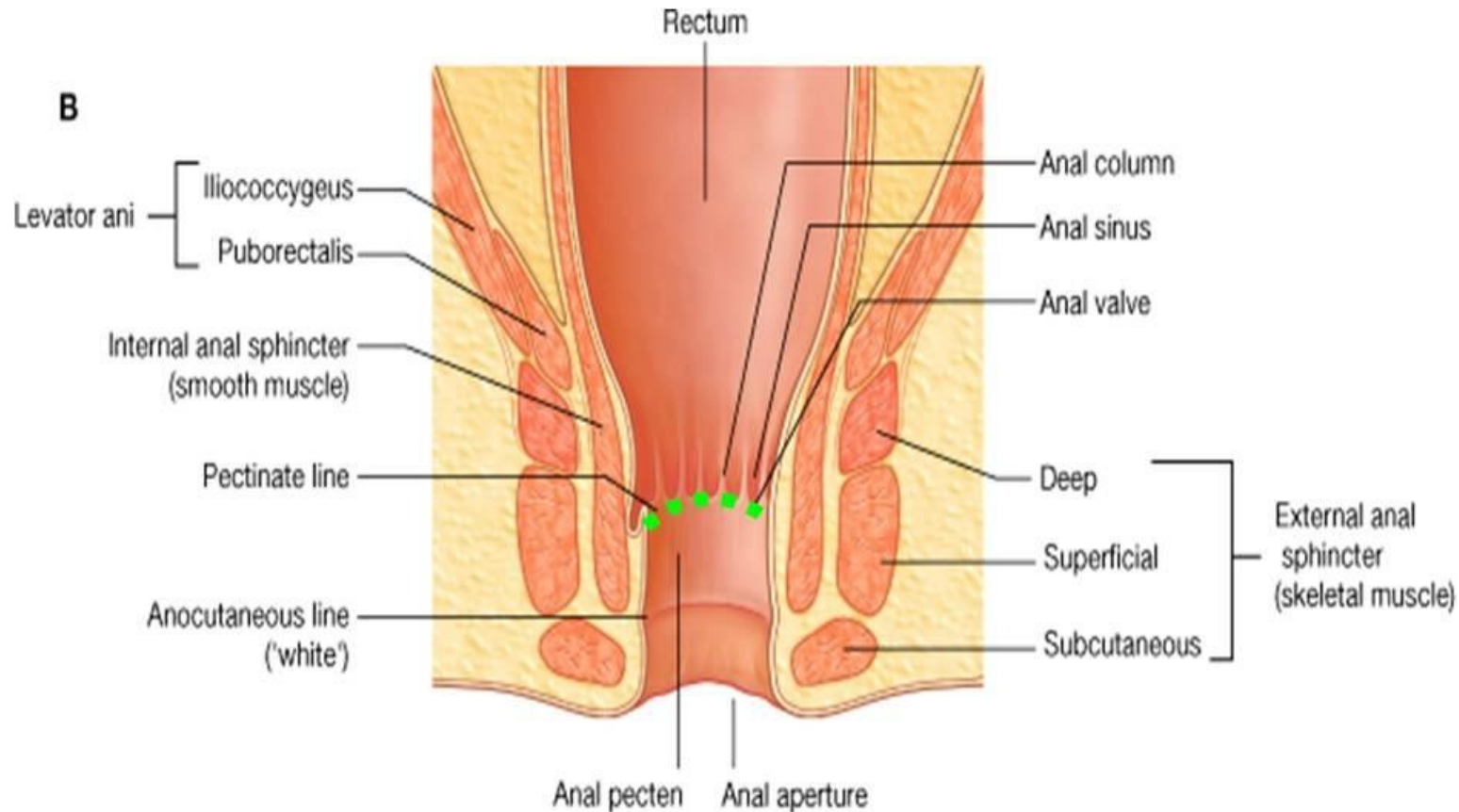
Rectum

The rectum is connected with the sigmoid loop at the level of S2-S3. Its length reaches up to 12-15 cm, its lumen varies between 4 till 8 cm. It consist of two parts **the ampulla** of the rectum and **the anal canal**. The ampulla vaults backwards as the sacral bone and it is also curved in frontal plane first rightwards then leftwards and finally rightwards. In the cavital side at the places of curvatures distinctive **transversal folds (plicae transversae recti)** are located. The most distinctive called **Kohlrausch fold(plica)** and it lies on the right side 6 cm away from the anus (it also called **plica transversa recti dextra**). **The rectum is located intraperitonially until the Kohlrausch Fold and then is located subperitonially.**



ANAL CANAL

The anal canal is shorter and represents the terminal part of the digestive tube. On the surface of rectum the border between the ampulla and the anal canal is created by the transversal incisure-notch ,**linea anorectalis (anorectal line)** which lies at the level of coccygeal apex.The anal canal opens on the body surface as anus.Inside the cranial part of anal canal the mucosa is organized up to **6 -10 longitudinal anal columns** which are underlined by venous plexuses and stripes of smooth muscles.In between these folds there are grooves which raise into blind recesses, **the sinus anales (anal sinuses)**.The particular sinuses enclose transversally **orientd valvulae anales(anal valves)** which are connected by a mucosal zone, **the pecten analis**, which is covered by the stratified squamous epithelium .The caudal boundary of pecten analis represents **linea anocutanea** .

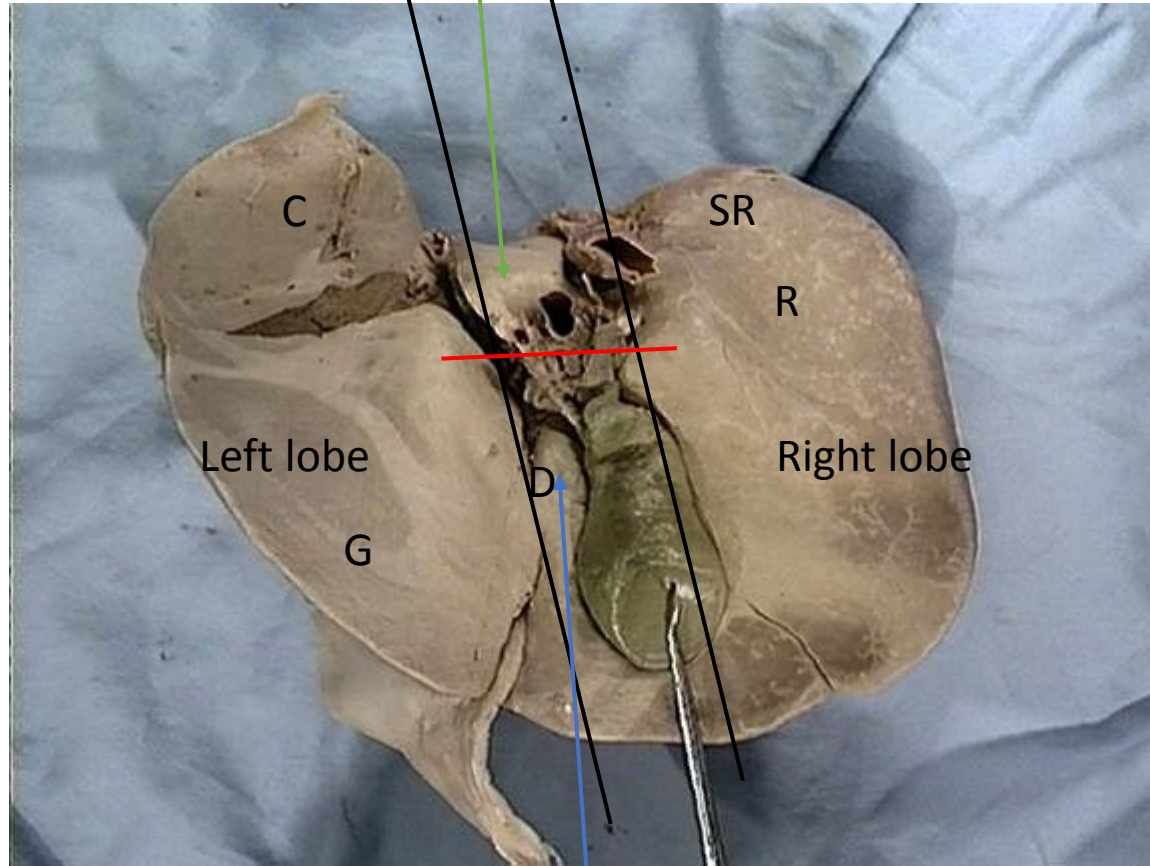


Liver

Left sagittal fissure:
Ligamentum venosum
Ligamentum teres

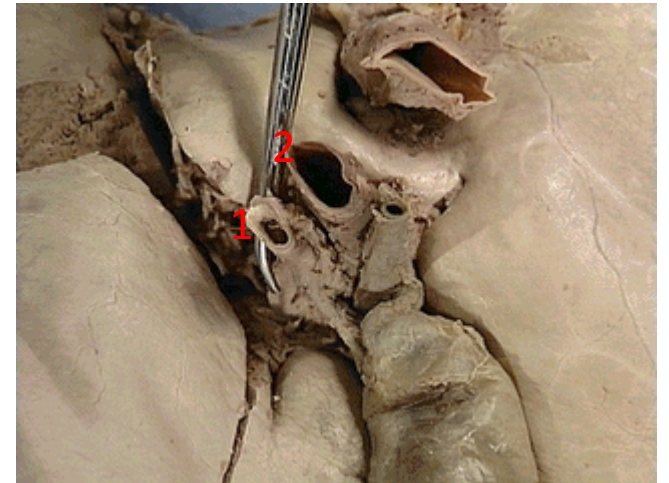
Caudate lobe

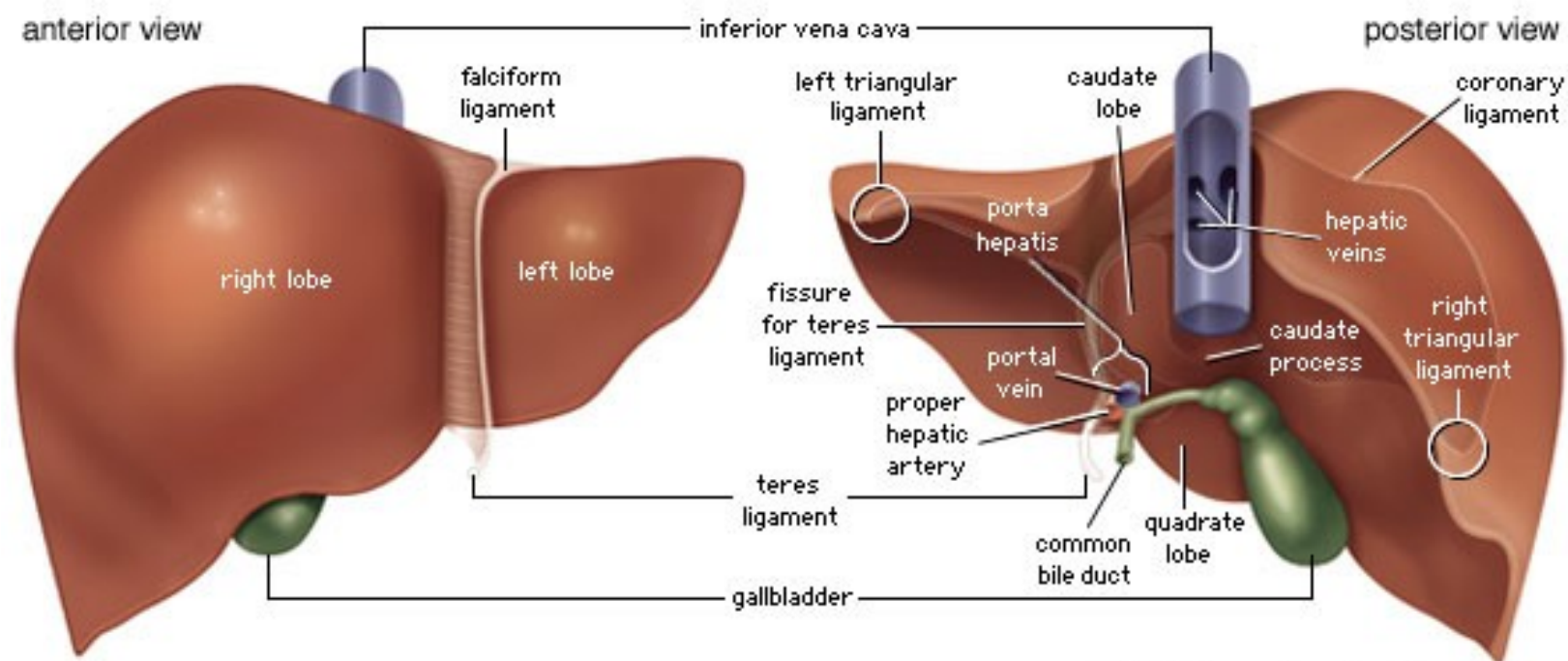
Right sagittal fissure : IVC gallbladder



Quadrate lobe

Transverse fissure:
1)Hepatic artery R/L
2)Portal vein





© 2003 Encyclopædia Britannica, Inc.

Kidneys