

Microscopic Analysis of Urine

Authors:

RNDr. Miroslava Beňovská, Ph.D.

Mgr. Ondřej Wiewiorka

MUDr. Jana Tůmová

Specimen selections:

Team of employees in Department of Clinical Biochemistry, University Hospital Brno

Faculty of Medicine, Masaryk University

Department of Laboratory Methods

University Hospital Brno

Department of Clinical biochemistry

Created in collaboration with Service Center for E-Learning at MU,

Faculty of Informatics, Masaryk University, Brno 2014–2015

Tiskový výstup publikace vydané na Elportále MU (<http://elportal.cz/>)

<http://is.muni.cz/elportal/?id=1231561>

Introduction

Semiquantitative urine analysis is one of the basic biochemical examinations. It consists of urine chemical properties determination by diagnostic strips and morphological examination of urinary elements. Both methods support each other in final determination of the result and both findings should correspond with each other. Urine analysis is required to be performed in one hour and is conducted from single sampling, preferably from the second urination in the morning. Nowadays, the analysis of urine is mostly automated. Manual microscopy is used only for determination of ambiguous or discrepant results.

The urine sediment for manual microscopy is prepared as follows: native urine sample is centrifuged in 2000 rpm and the supernatant is removed and the sediment resuspended to create a tenfold concentrated sample solution.

We use standardized staining (e.g. supravital staining) by Sternheimer for better recognition of elements. Staining reagent consists of 2 dyes (alcian blue and red pyronin B in 1:1 ratio). The staining reagent is added to the concentrated urine sample in 1:10 ratio.

In this database, we have sorted and described 3 variants of pictures.

1. Microscopic findings of stained sediment (10× concentrated urine sample with 400× magnification, Sternheimer staining)
2. Microscopic findings of native sediment (10× concentrated urine sample in 400× magnification)
3. Findings from automatic analyzer iQ 200 (Iris)

In the following links the database is prepared in a format suitable for print. For better recognition, some elements are magnified.

Erythrocytes

Erythrocytes are red blood cells without nucleus, with size about 10–12 μm and a disk-like shape. They count amongst the smallest and the most common elements in urine. Their presence in urine (hematuria) can be macroscopic or microscopic (without visible red color).

Causes for haematuria:

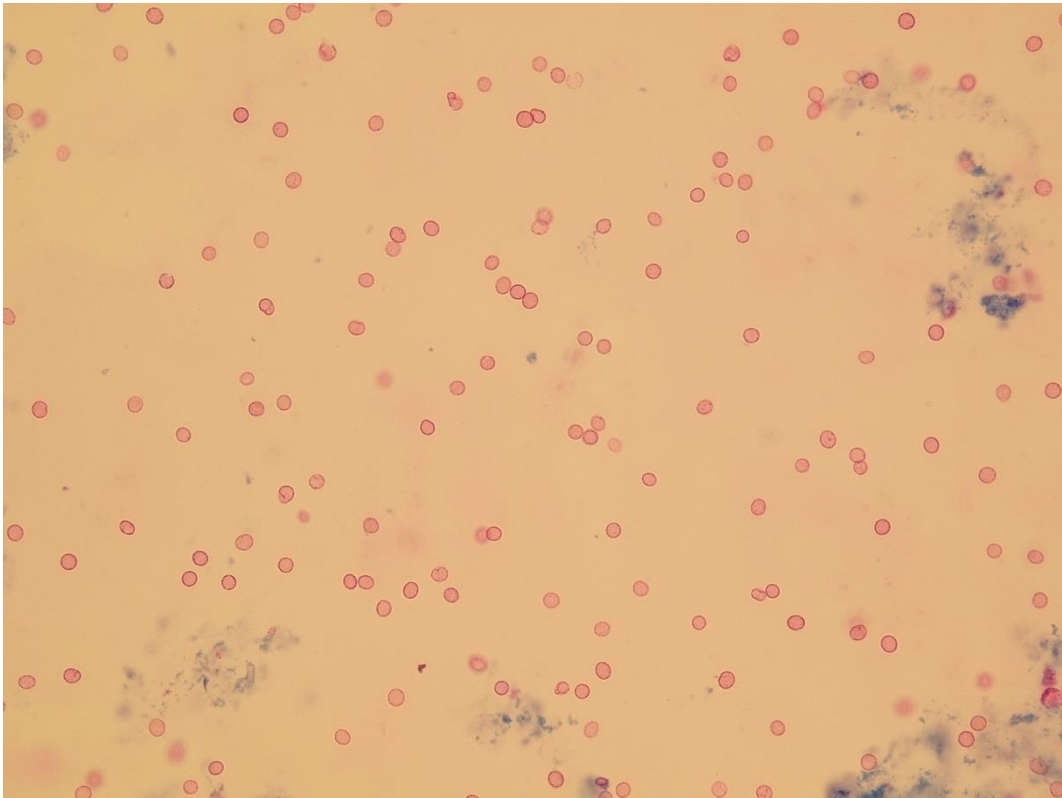
- Renal (glomerulonephritis, kidney cancer)
- Prerenal (hemocoagulation aberrations, muscle traumas, burns)
- Subrenal (bleeding in urinary tract – infection, kidney stones, carcinoma)
- Exertion (physical stress, cold)

If the erythrocytes have a normal biconcave shape with smooth surface, they are called eumorphic erythrocytes. Erythrocytes that passed to urine through glomerular membrane might be damaged and their shape is changed – we call them dysmorphic erythrocytes.

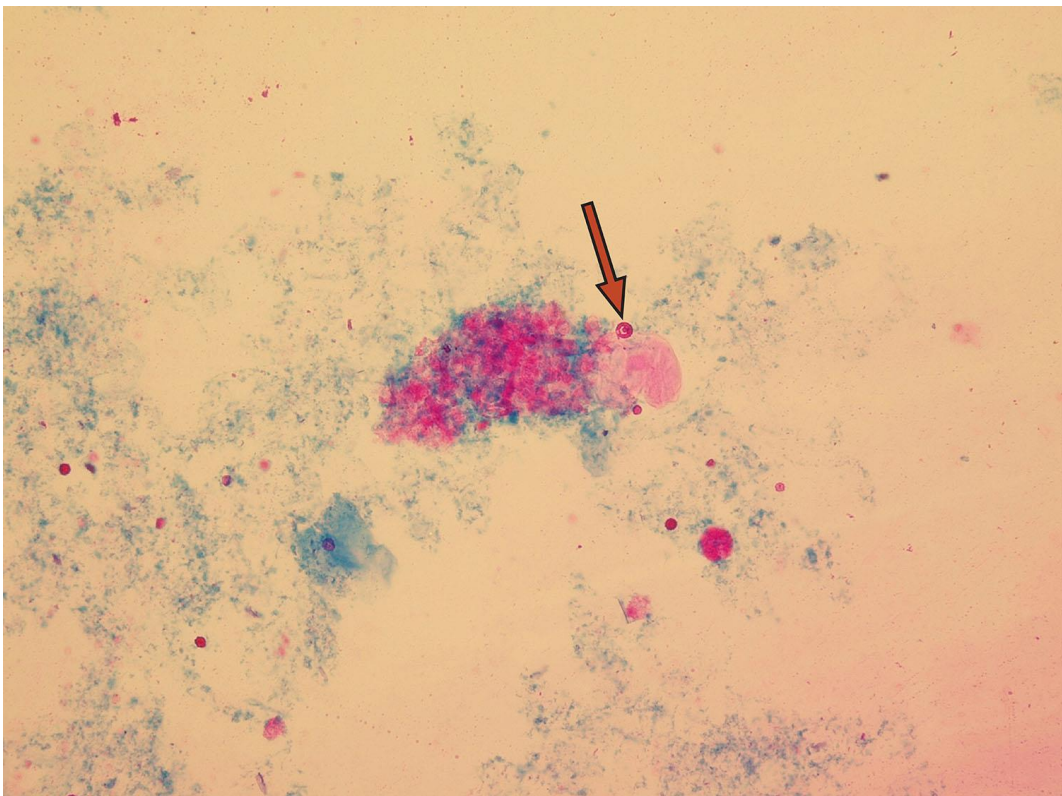
Dysmorphic erythrocytes may have a tire shape (codocytes) or the erythrocyte membrane may have protrusions (acanthocytes).

Hedgehog shaped or crenated erythrocytes (echinocytes) don't count among the dysmorphic erythrocytes. They are deformed by erythrocyte dehydration in urine with high osmolality.

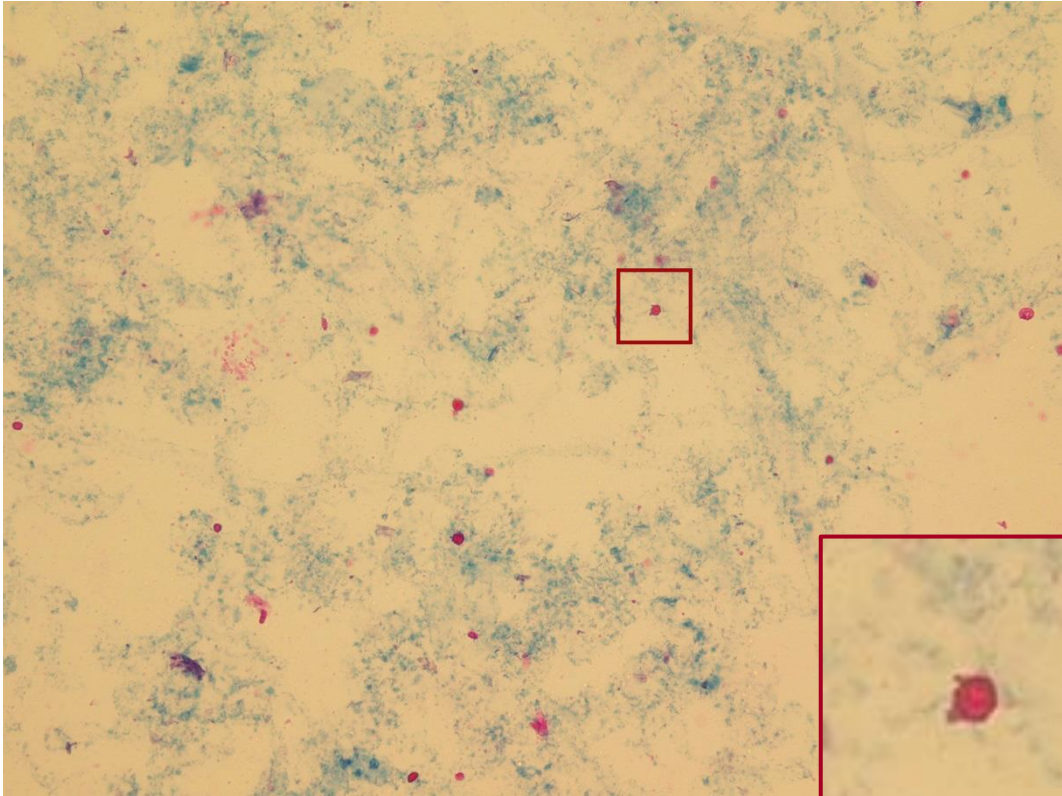
Stained sediment



Erythrocytes

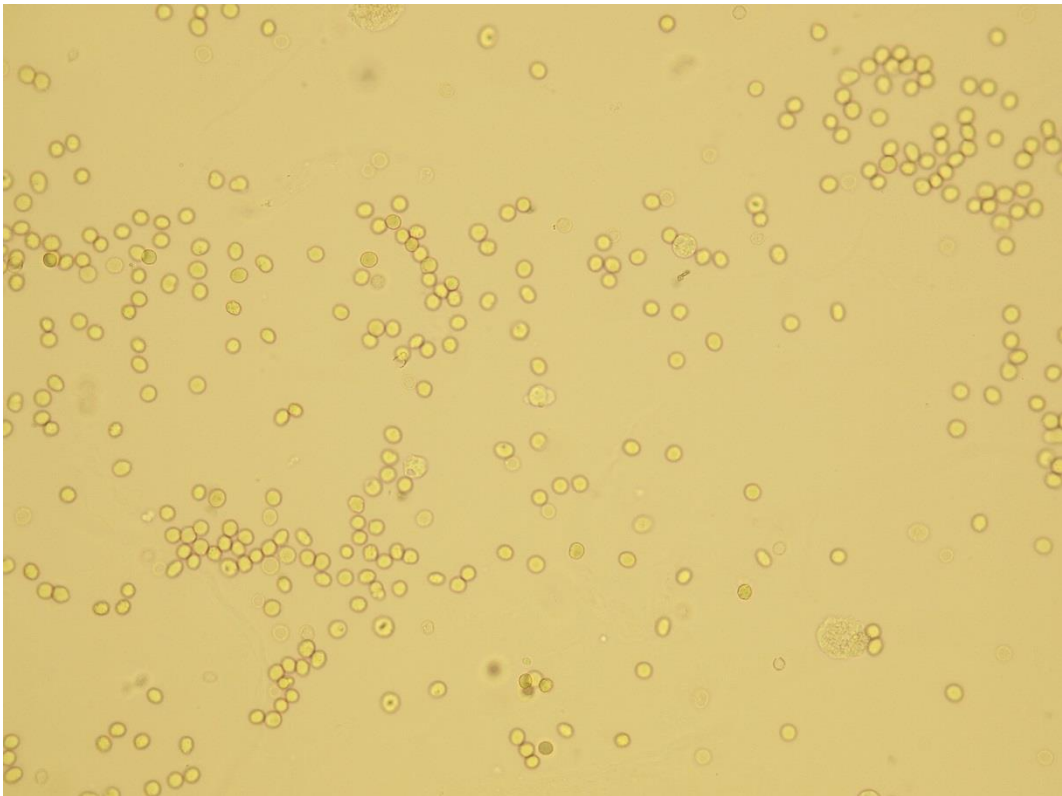


Dysmorphic erythrocyte – codocyte

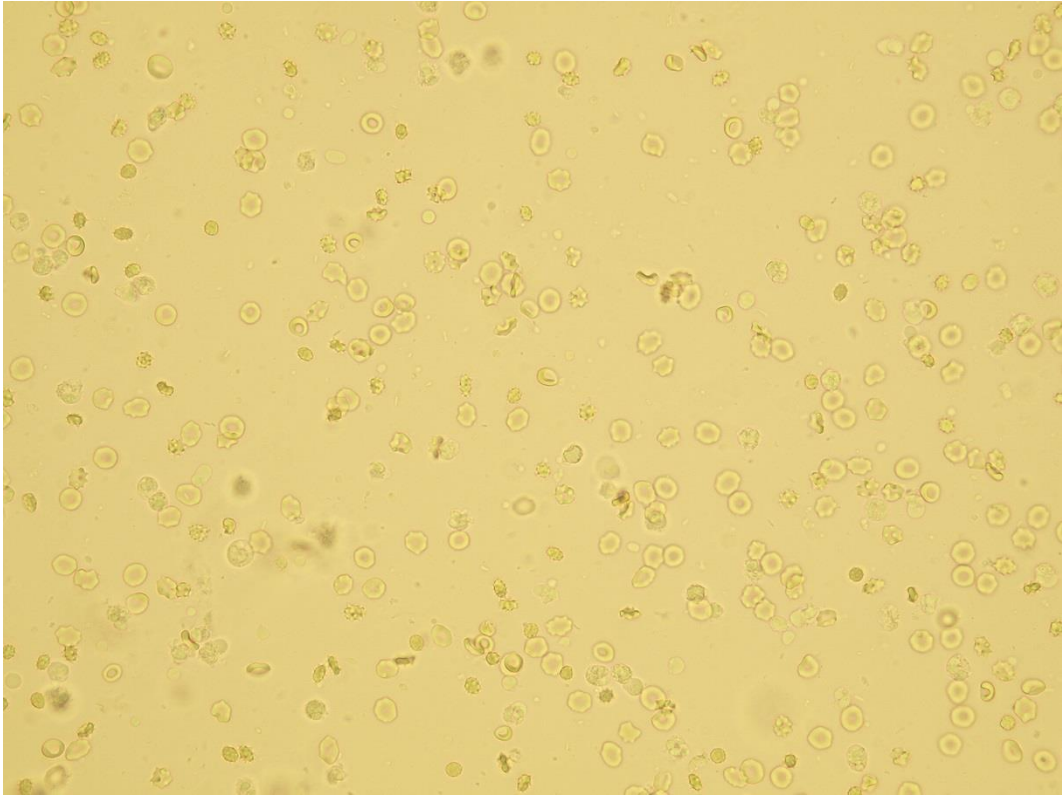


Dysmorphic erythrocytes – acanthocytes

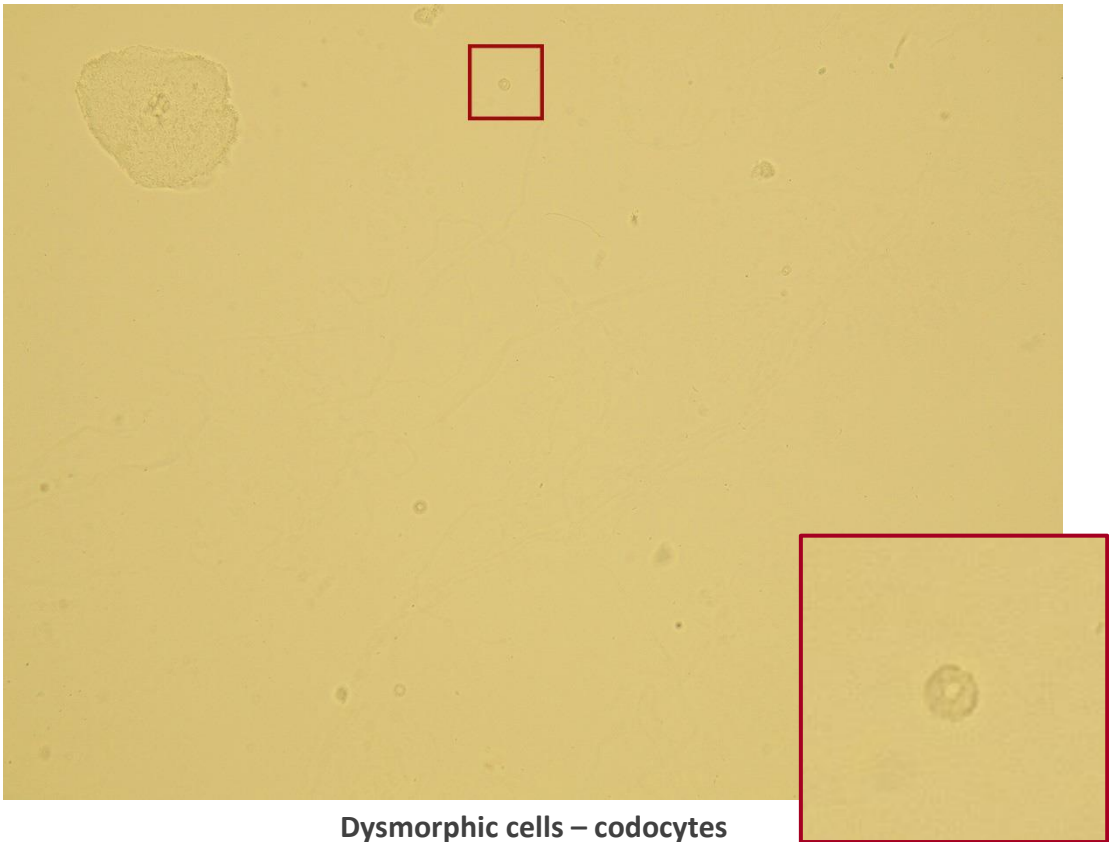
Native sediment



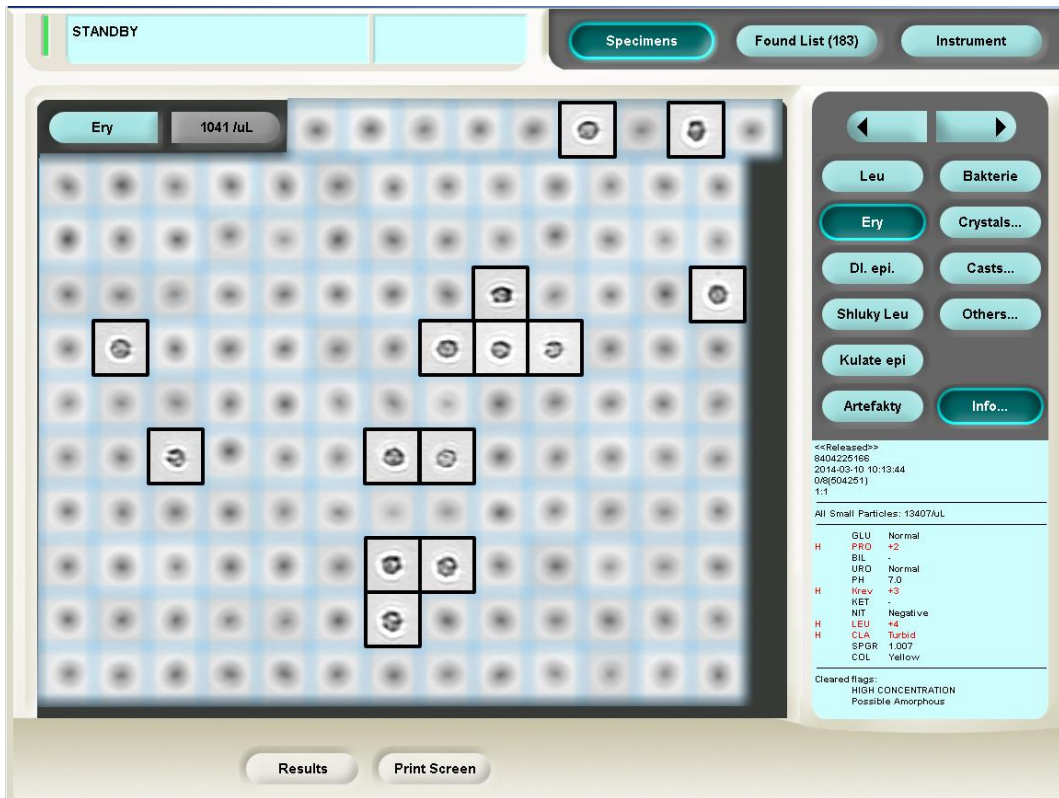
Erythrocytes



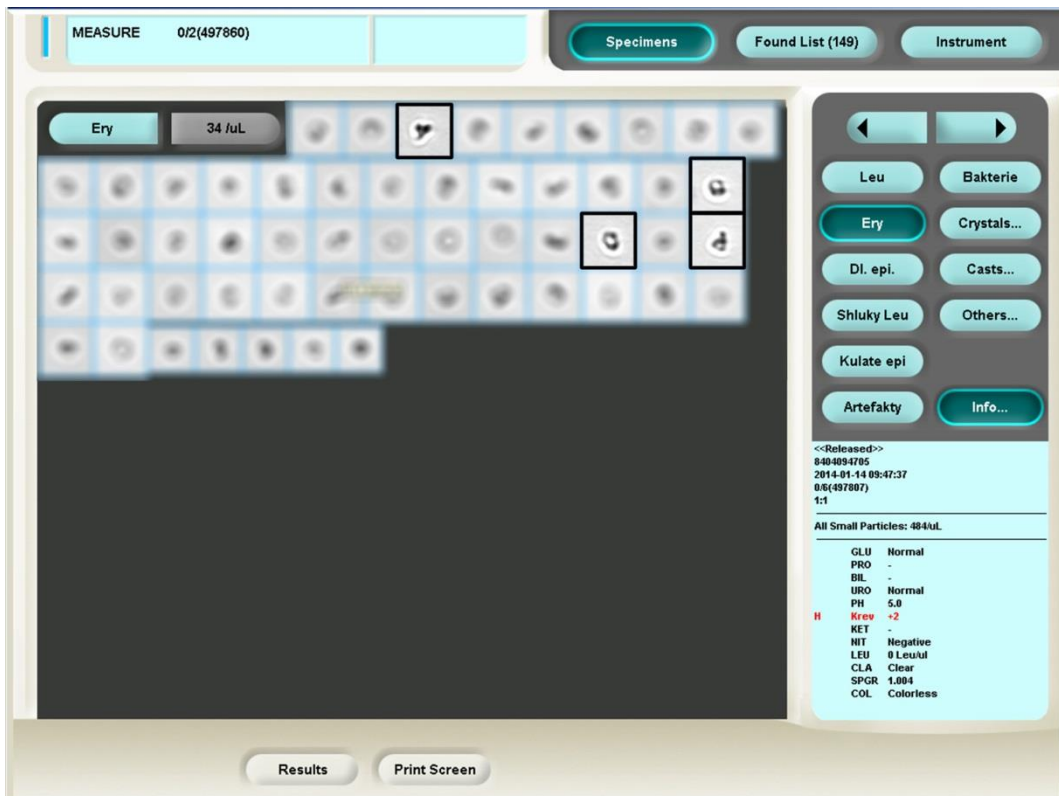
Erythrocytes deformed by high osmolality (the cells lose water)



Dysmorphic cells – codocytes



Erythrocytes deformed by high osmolality (the cells lose water)



Dysmorphic erythrocytes

Leukocytes

Neutrophil granulocytes are the most common leukocyte subcategory in urine. Their cells are round shaped with the size of 16–22 μm and with segmented nucleus in the center of the cell. The leukocyte nucleus may or may not be stained by the dye – vital leukocytes with undamaged membrane have colorless nucleus, cells with damaged membrane have their nucleus stained blue.

Other leukocyte types in urine such as **lymphocytes** (they have a large nucleus that fills almost the entire cell), **monocytes** (with nucleus in the shape of a horseshoe or a bean) and activated monocytes called **macrophages** can be rarely found. Diagnostic strip doesn't react with these leukocytes.

The granulocyte presence is typical especially for bacterial infections of urinary tract or kidneys. Semiquantitative detection with diagnostic strip is based on reaction with granulocyte esterase.

The presence of increased numbers of lymphocytes after renal transplantation is an important sign of kidney rejection.

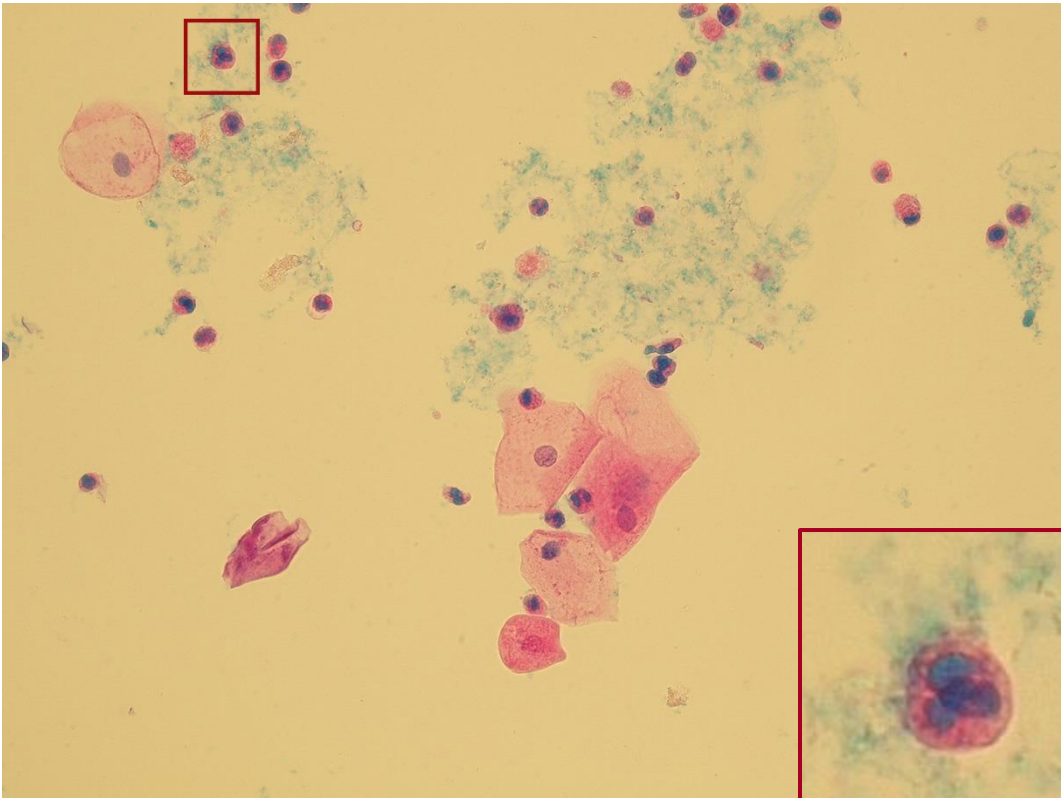
Macrophages

Macrophages play important role in immune reaction. Their primary function is phagocytosis – absorption of elements inside their cells. They belong among mononuclear leukocytes, meaning they have just one non-segmented nucleus. They evolve from monocytes in tissues. The macrophages have increased amount of lysosomes and vacuolated cytoplasm. They may be seen with phagocytosed erythrocytes (erythrophages), lipid droplets (lipophages) or crystals.

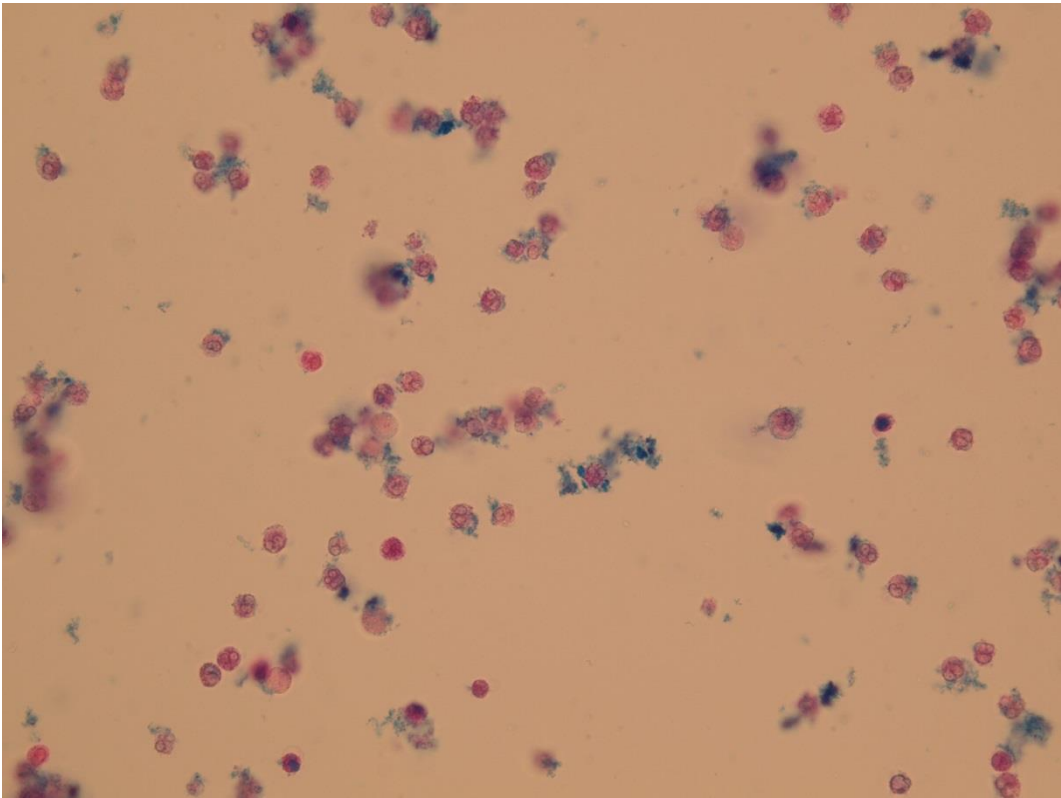
Glitter cells

Some leukocytes are in hypotonic urine particularly distinguishable by the Brownian movement of granules inside their cells. This gave these neutrophil granulocytes the name "glitter cells". In some cases, especially in hypotonic urine, the leukocyte membrane may rupture and spill some of the cytoplasm outside of cell. We may observe this in samples of patients with interstitial nephritis.

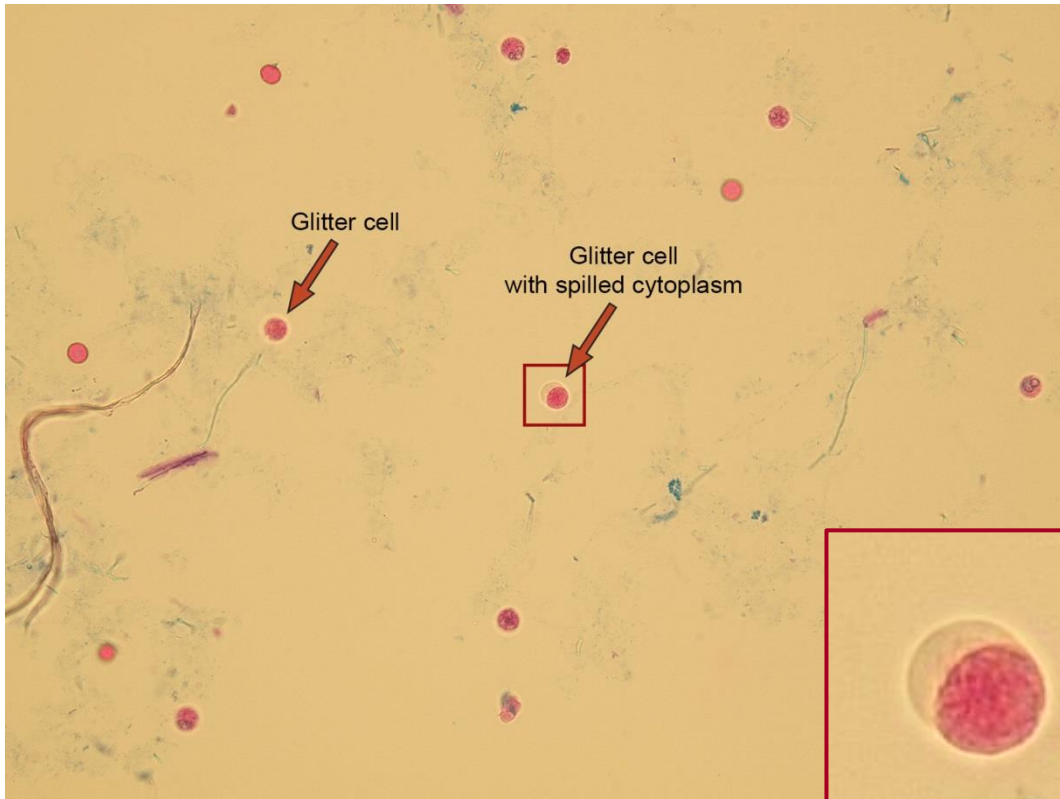
Stained sediment



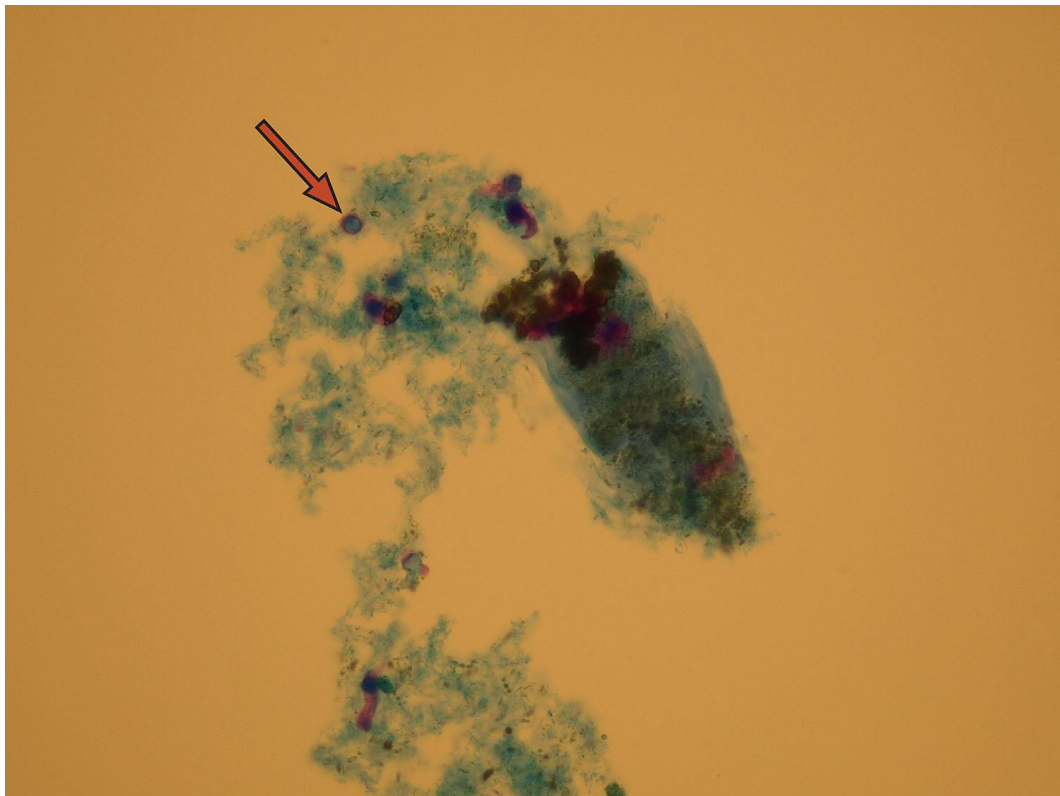
Leukocytes (granulocytes)



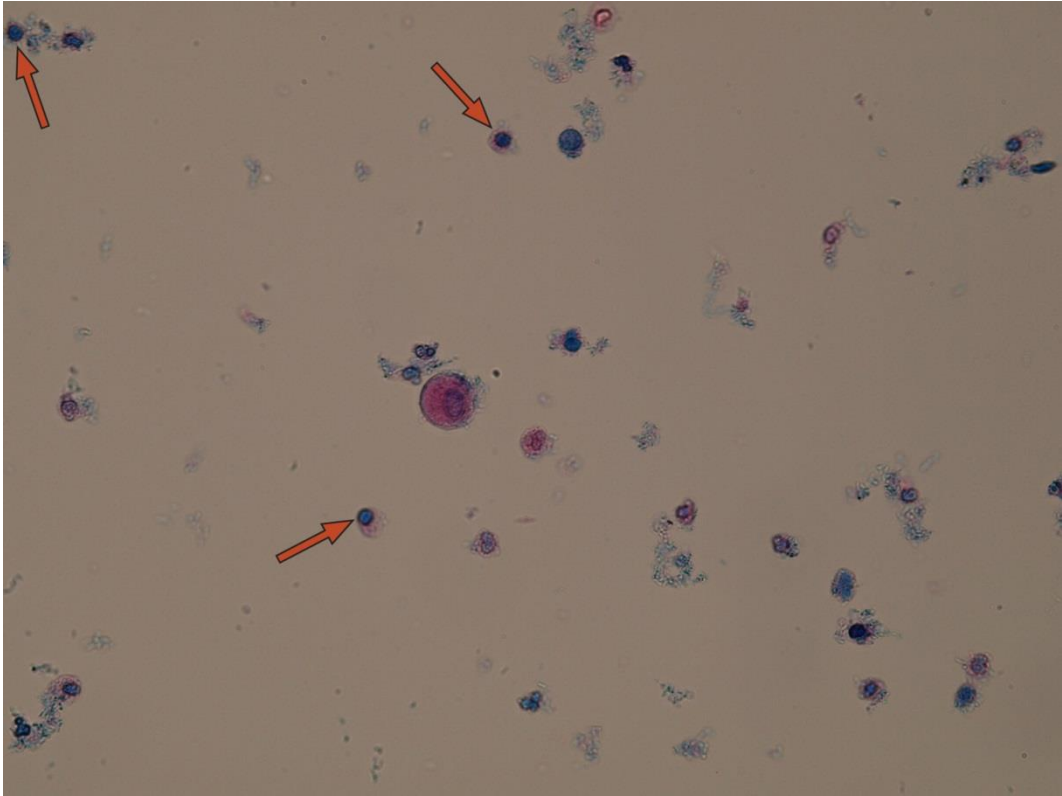
Leukocytes (granulocytes)



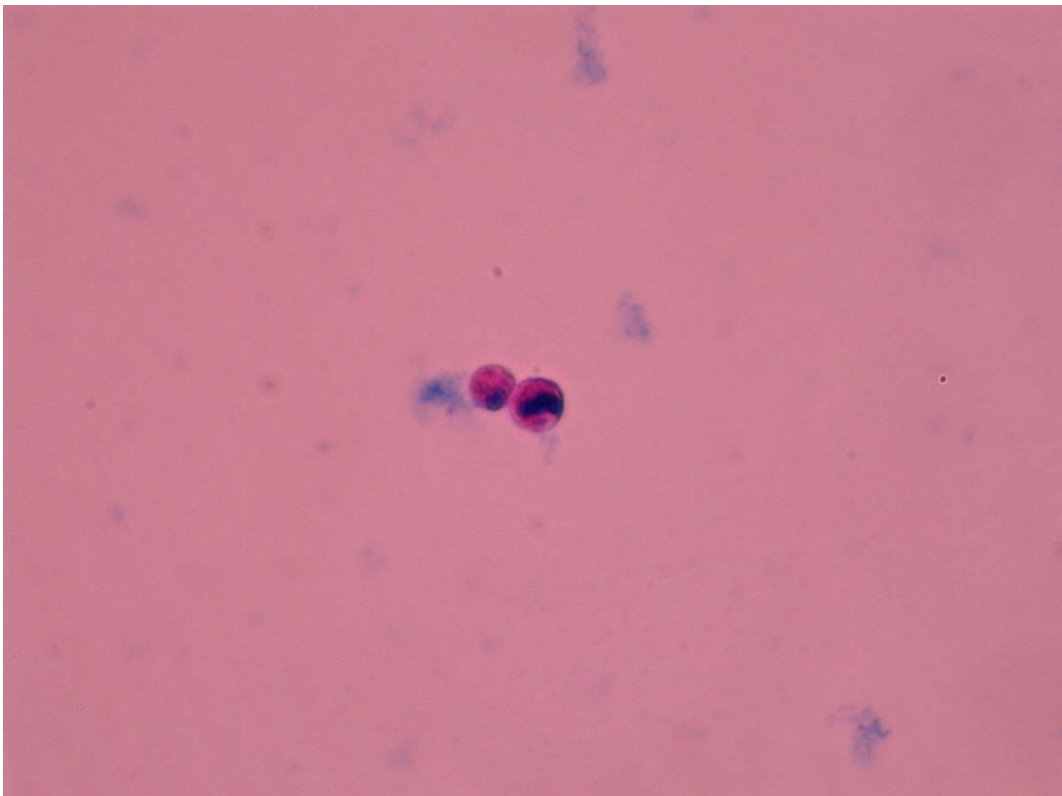
Granulocytes – glitter cells



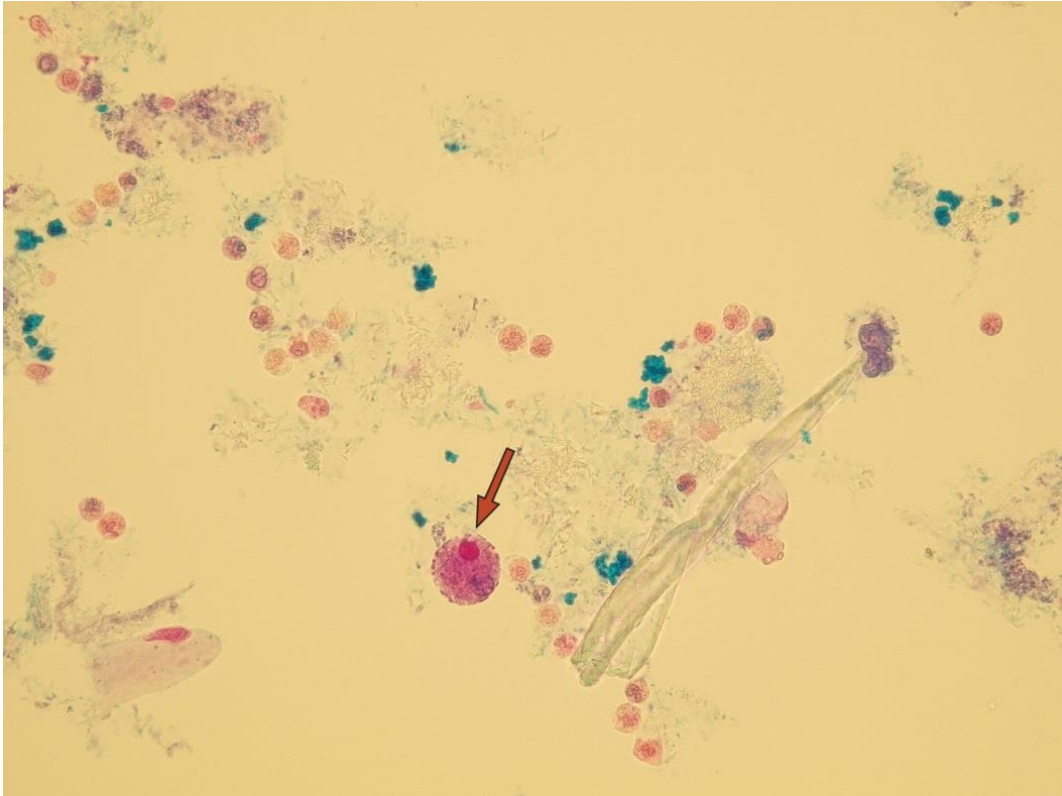
Leukocyte (lymphocyte)



Leukocytes (lymphocytes – arrows)

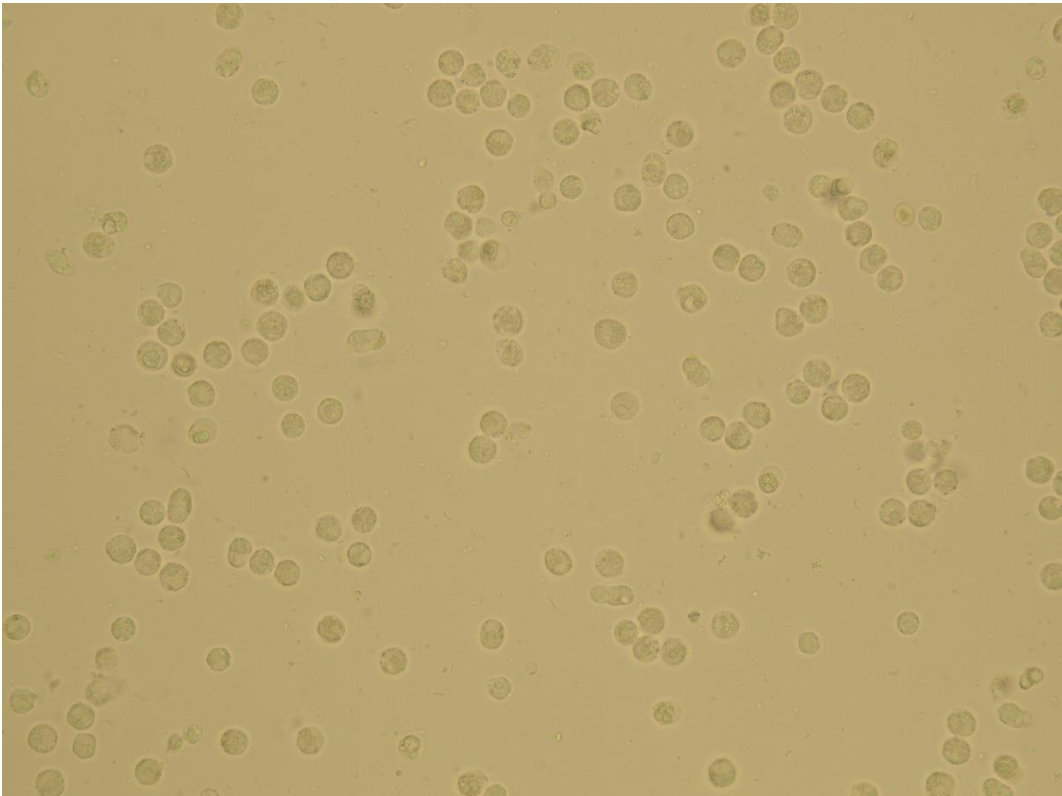


Leukocytes (monocytes), 1000× magnification

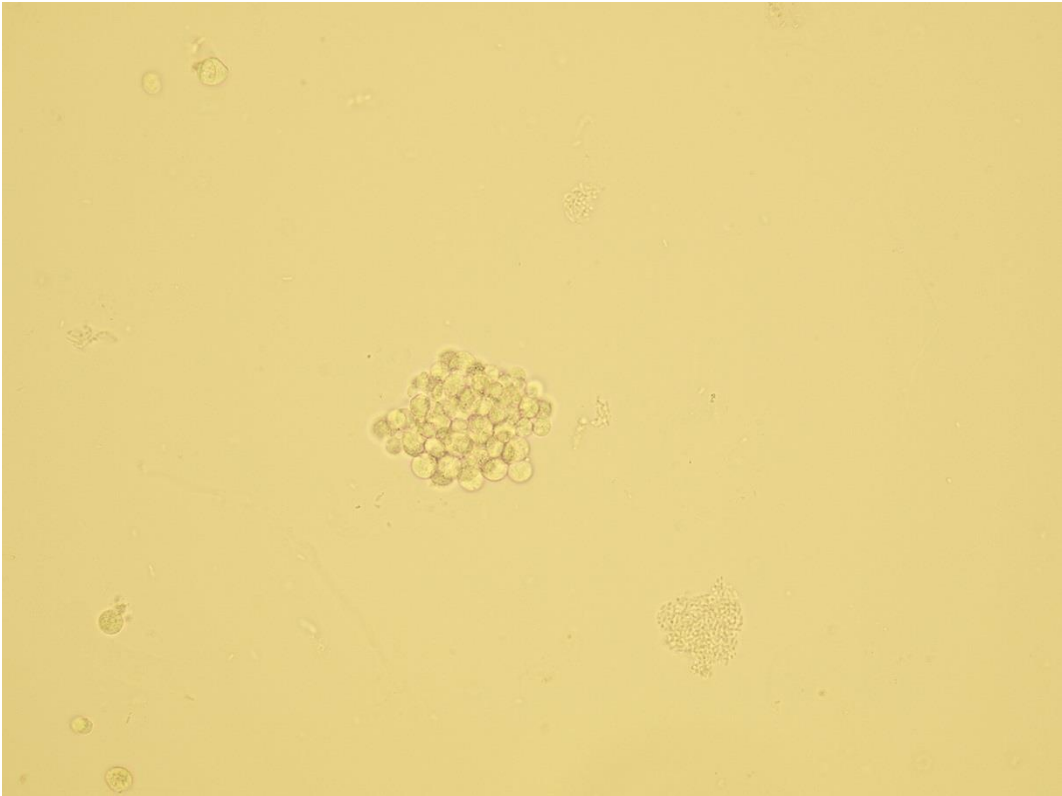


Leukocytes including macrophage with phagocytosed bacteria (arrow)

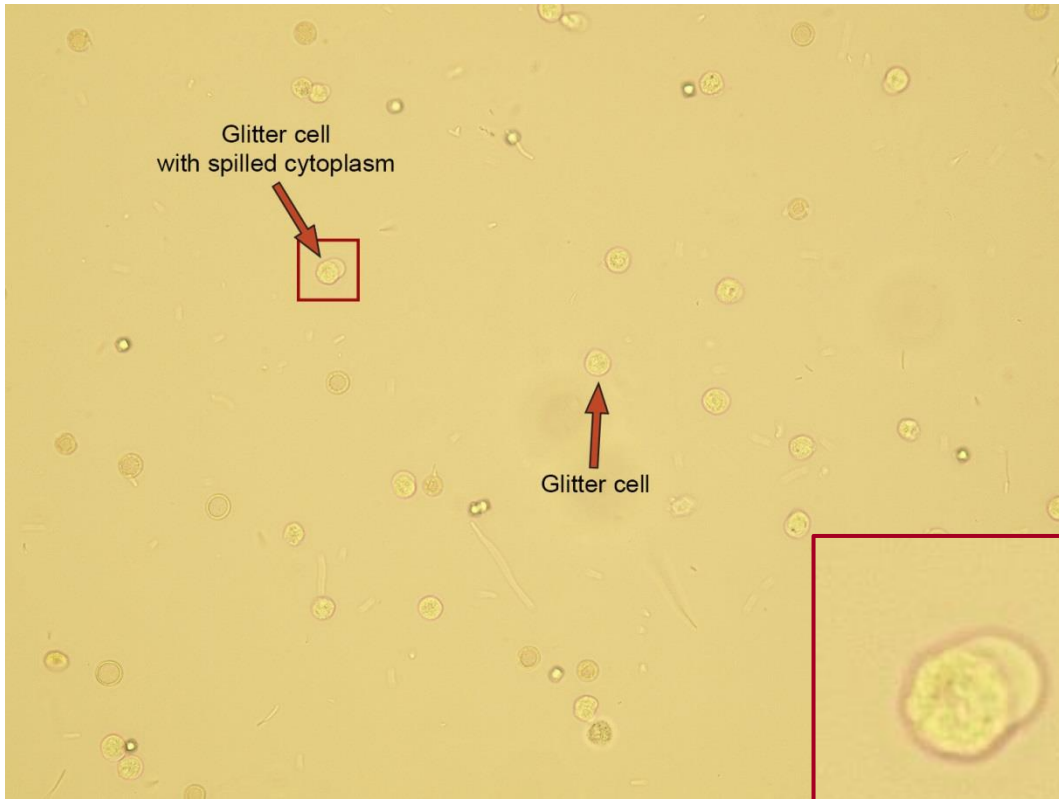
Native sediment



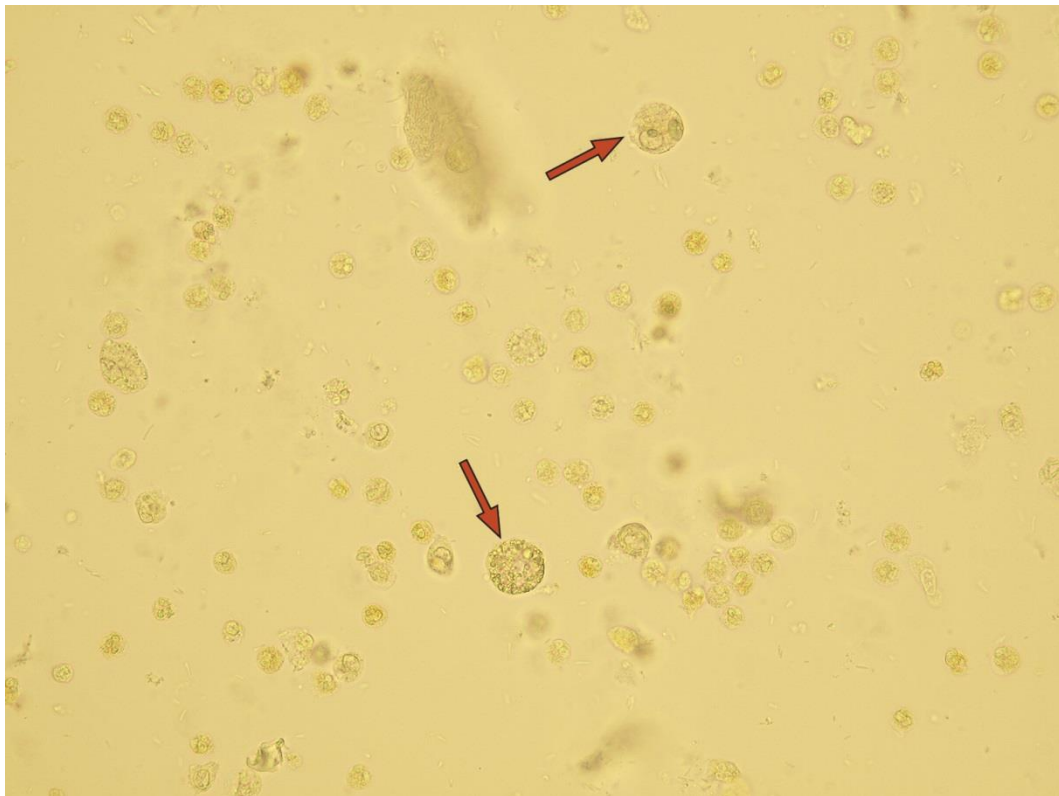Leukocytes



Group of leukocytes

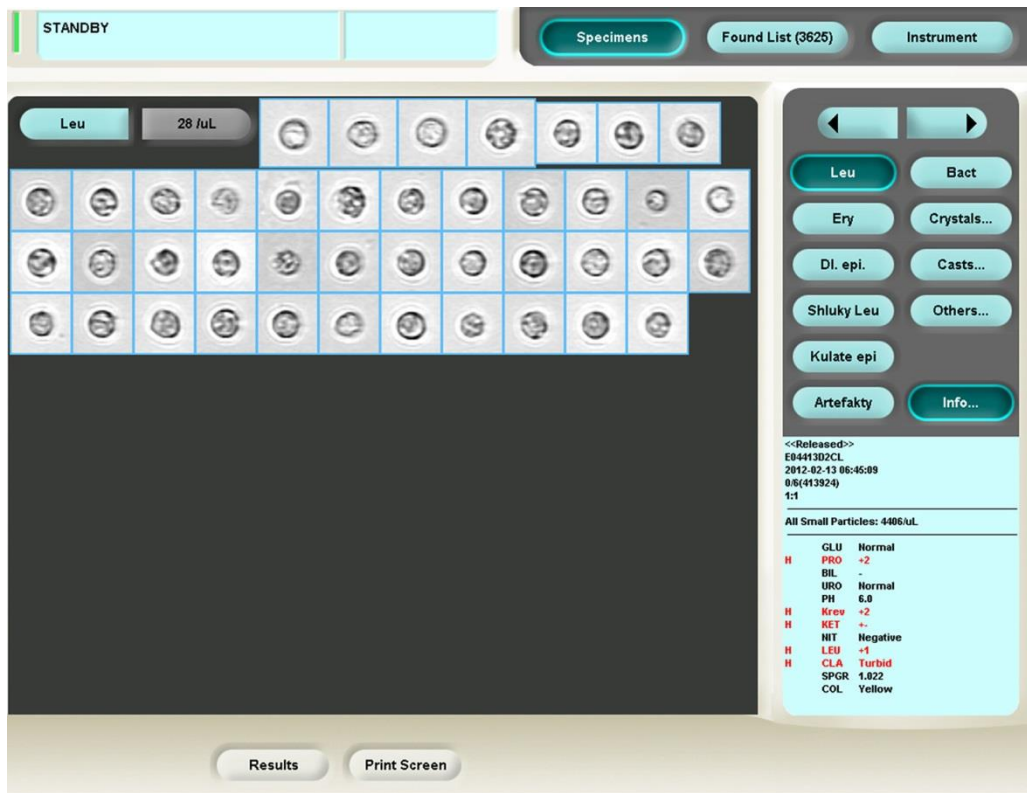


Granulocytes – glitter cells

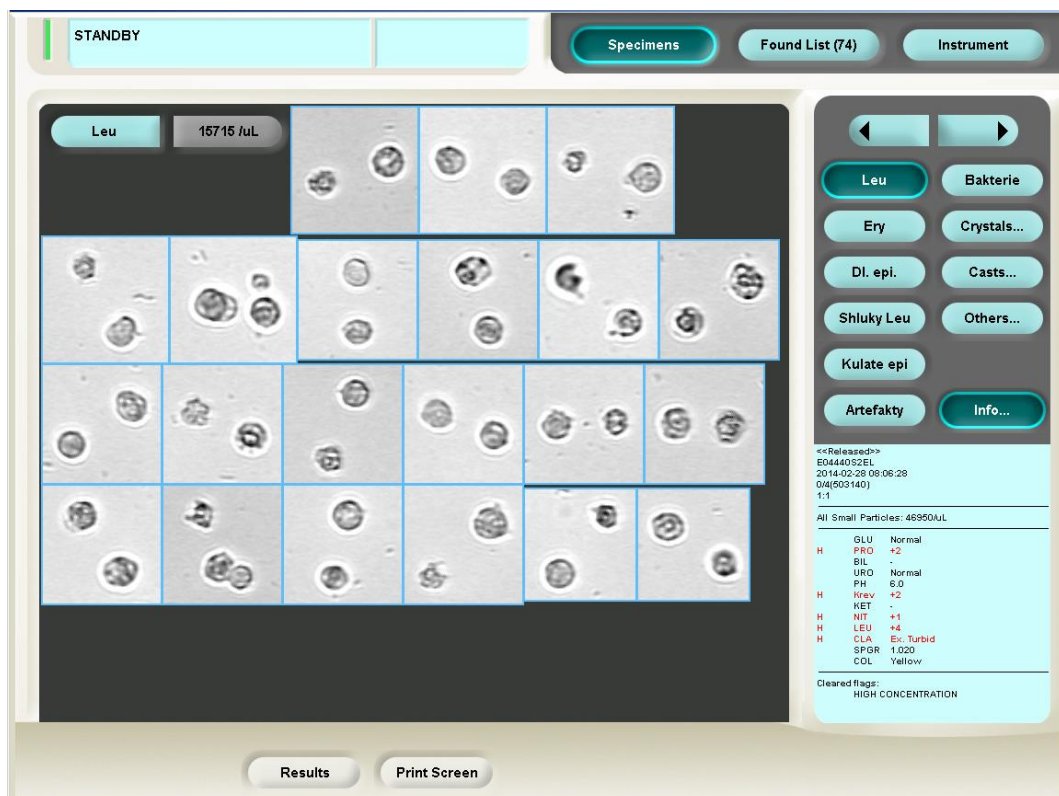


Leukocytes including macrophages (arrows)

Pictures from iQ 200 analyzer (IRIS)



Leukocytes (granulocytes)

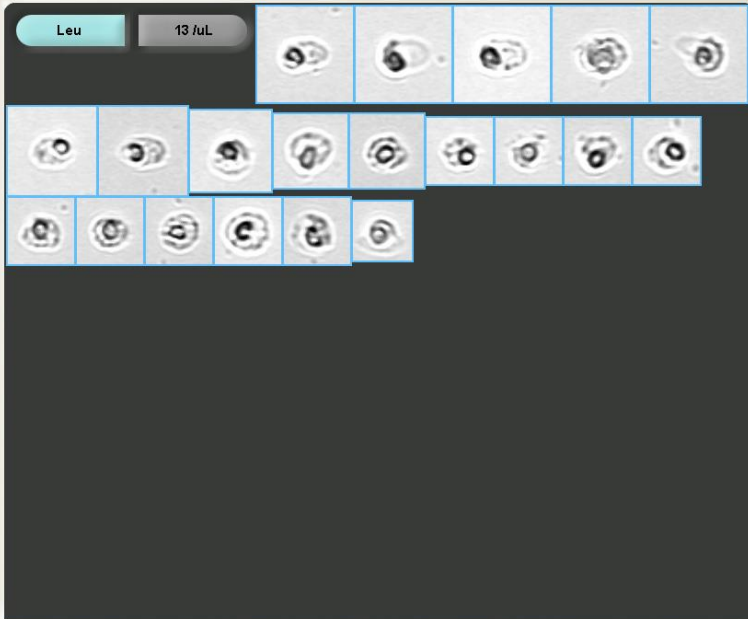


Leukocytes (monocytes and granulocytes)

STANDBY

Specimens Found List (122) Instrument

Leu 13 JuL



Leu Bakterie
Ery Crystals...
Dl. epi. Casts...
Shluky Leu Others...
Kulate epi
Artefakty Info...

<<Released>>
6404916896
2014-12-22 07:38:27
07(637172)
1:1

All Small Particles: 56006/uL

| | |
|-------|-----------|
| GLU | Normal |
| PRO | - |
| BIL | - |
| URO | Normal |
| PH | 6.0 |
| Krev | - |
| KET | - |
| H NIT | +2 |
| H LEU | +4 |
| H CLA | Turbid |
| SPGR | 1.006 |
| COL | Colorless |


Cleared flags:
Possible Amorphous

Results Print Screen

Leukocytes (lymphocytes)

MEASURE 231(631332)

Specimens Found List (201) Instrument



Leu Bakterie
Ery Crystals...
Dl. epi. Casts...
Shluky Leu Others...
Kulate epi
Artefakty Info...

<<Released>>
E044596AEL
2014-10-06 08:17:34
0/6(528284)
1:1

All Small Particles: 4539/uL

| | |
|--------|----------|
| GLU | Normal |
| PRO | +1 |
| BIL | - |
| URO | Normal |
| PH | 6.0 |
| H Krev | +2 |
| KET | - |
| NIT | Negative |
| H LEU | +1 |
| H CLA | Turbid |
| SPGR | 1.021 |
| COL | Yellow |

Results Print Screen

Macrophages

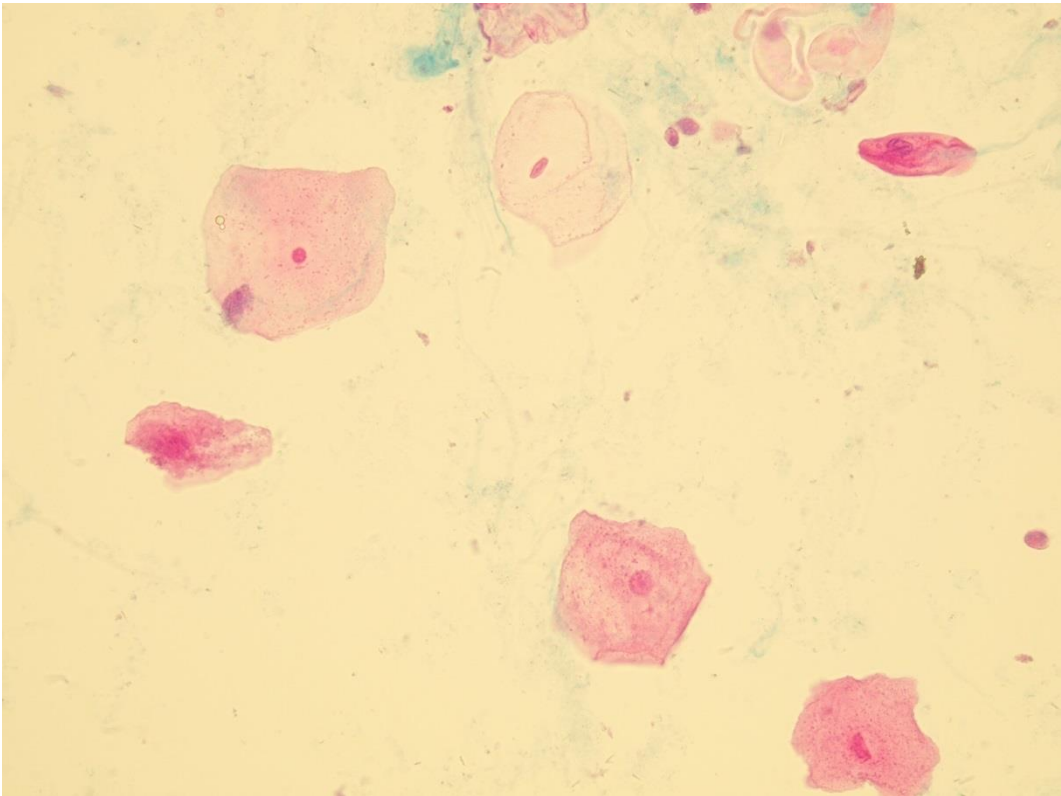
Epithelial cells

The outside or the inside of the organism surface is covered with epithelial cells. These cells can be found in urine and divided in several groups.

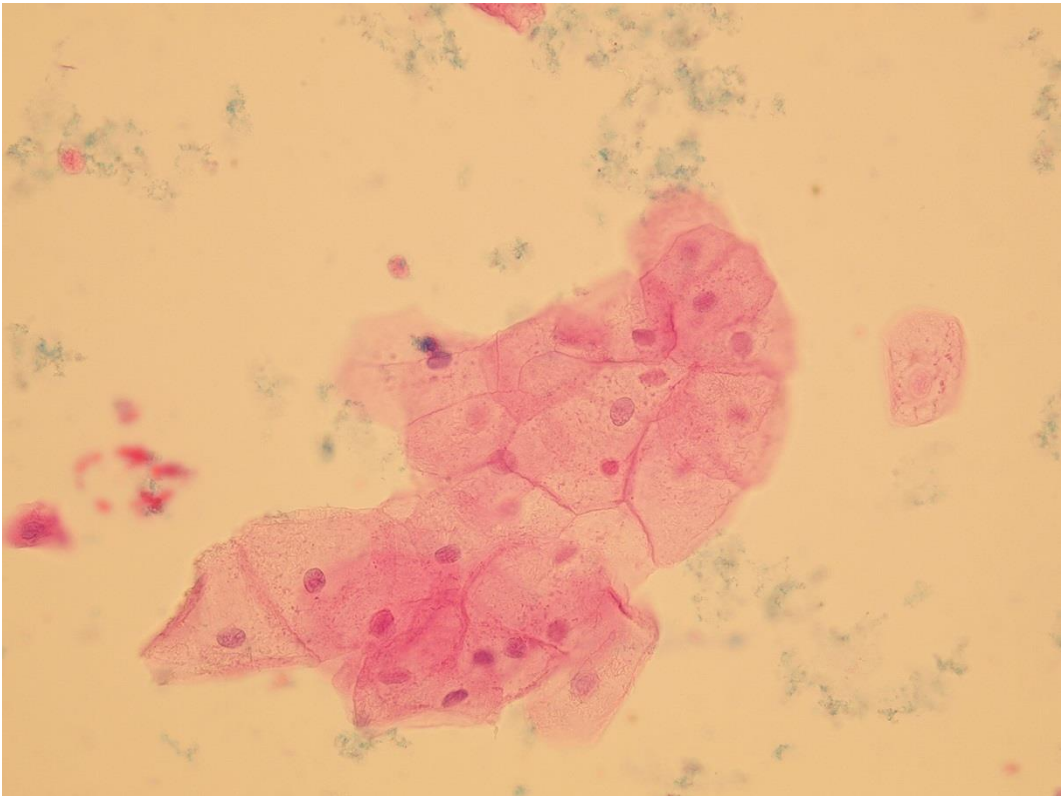
Squamous epithelial cells

These are very large unevenly shaped cells with easily visible nucleus inside. They originate from urethra or vagina. They are very common elements with minimal clinical impact.

Stained sediment

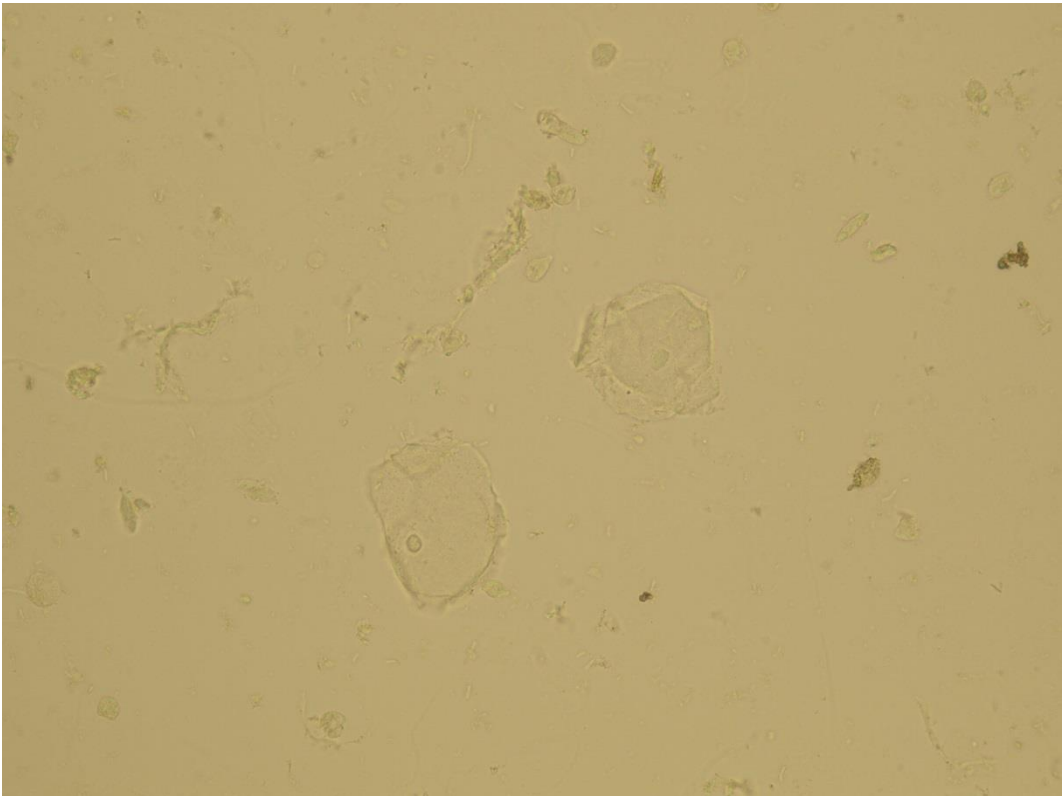


Squamous epithelial cells

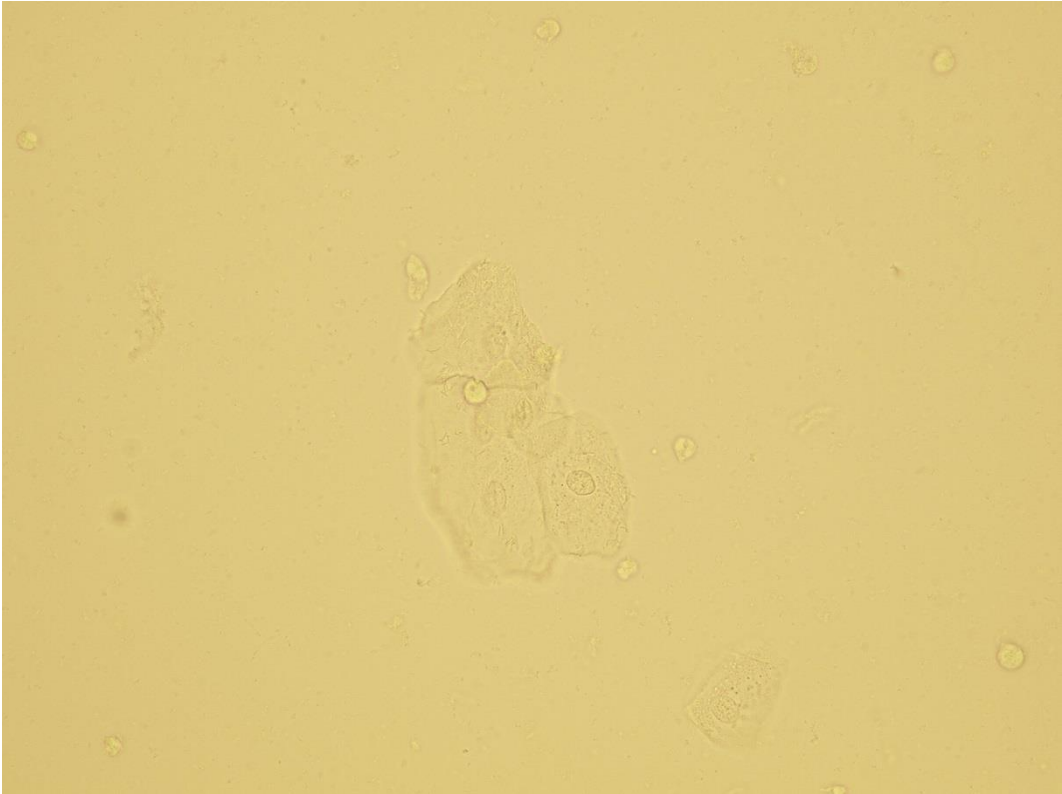


Squamous epithelial cells

Native sediment



Squamous epithelial cells



Squamous epithelial cells

Pictures from iQ 200 analyzer (IRIS)

STANDBY Specimens Found List (90) Instrument

DI. epi. 53 /uL

Leu Bakterie
Ery Crystals...
DI. epi. Casts...
Shluky Leu Others...
Kulate epi
Artefakty Info...

<<Released>>
8404043151
2013-12-19 10:19:04
0/8(495423)
1:1

All Small Particles: 3538/uL

| | | |
|---|------|----------|
| H | GLU | +- |
| H | PRO | +- |
| H | BIL | - |
| | URO | Normal |
| | PH | 6.0 |
| | Krev | - |
| | KET | - |
| | NIT | Negative |
| H | LEU | +1 |
| H | CLA | Turbid |
| | SPGR | 1.818 |
| | COL | Yellow |

Results Print Screen

Squamous epithelial cells

STANDBY Specimens Found List (226) Instrument

DI. epi. 38 /uL

Leu Bakterie
Ery Crystals...
DI. epi. Casts...
Shluky Leu Others...
Kulate epi
Artefakty Info...

<<Released>>
8404072089
2014-01-06 09:11:49
0/7(96668)
1:1

All Small Particles: 13004/uL

| | | |
|---|------|------------|
| H | GLU | Normal |
| H | PRO | +- |
| H | BIL | - |
| | URO | Normal |
| | PH | 6.0 |
| H | Krev | +- |
| H | KET | +1 |
| | NIT | Negative |
| H | LEU | +4 |
| H | CLA | Es. Turbid |
| | SPGR | 1.822 |
| | COL | Yellow |

Results Print Screen

Squamous epithelial cells

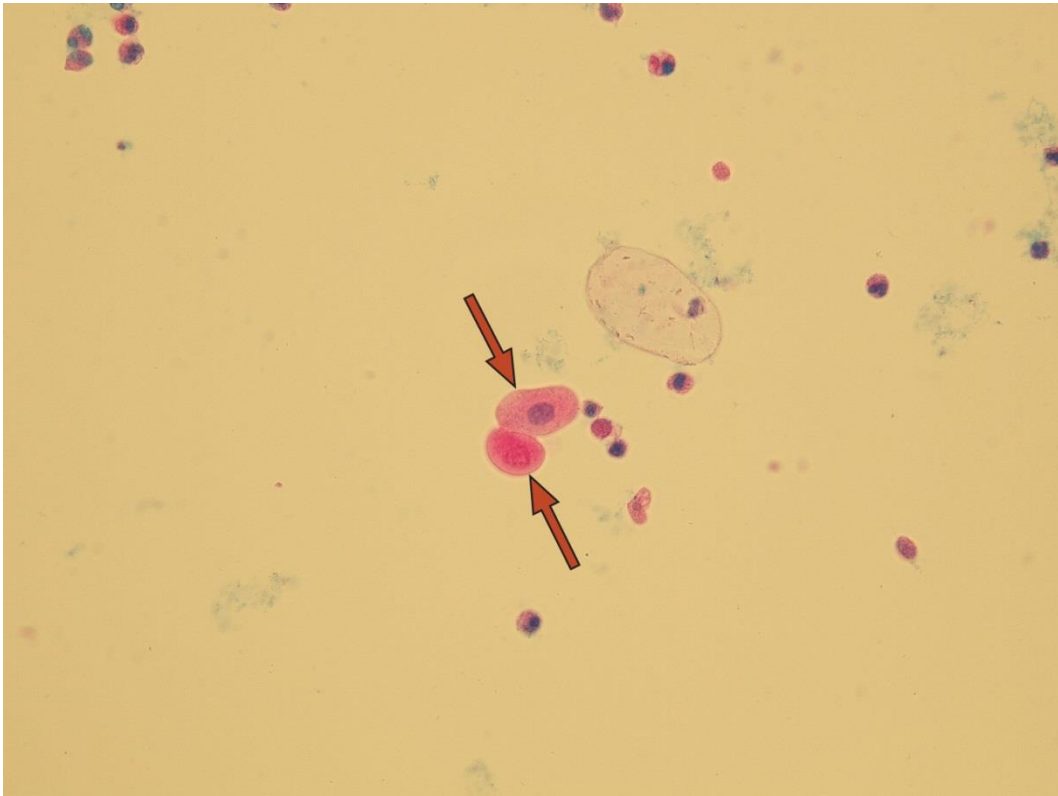
Transitional epithelial cells

These epithelial cells have different shapes and sizes depending on their origin. Round epithelial cells are most common. Their nucleus is in the middle of the cell, they are smaller than squamous epithelial cells and they come from the bladder or proximal segments of urethra in men. If they originate from deeper layers of epithelia or near the renal pelvis, they are smaller and more round.

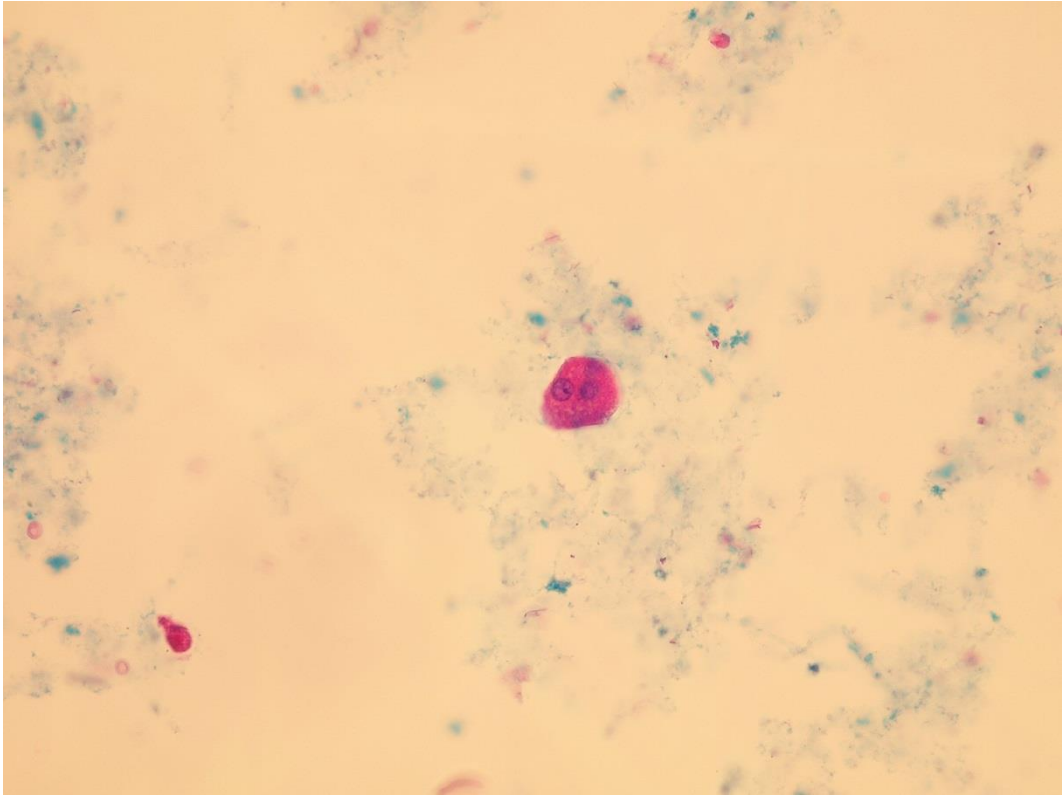
Limited amount of round transitional epithelial cells may be normal, large amount accounts to urinary tract infection.

Another subcategory is called caudate cells. They come from deep layers of a bladder. The cells with two nuclei are also categorized as transitional epithelial cells. Large number of cells with two nuclei or asymmetric cells can be found in urine from patients with transitional cell (urothelial) carcinomas.

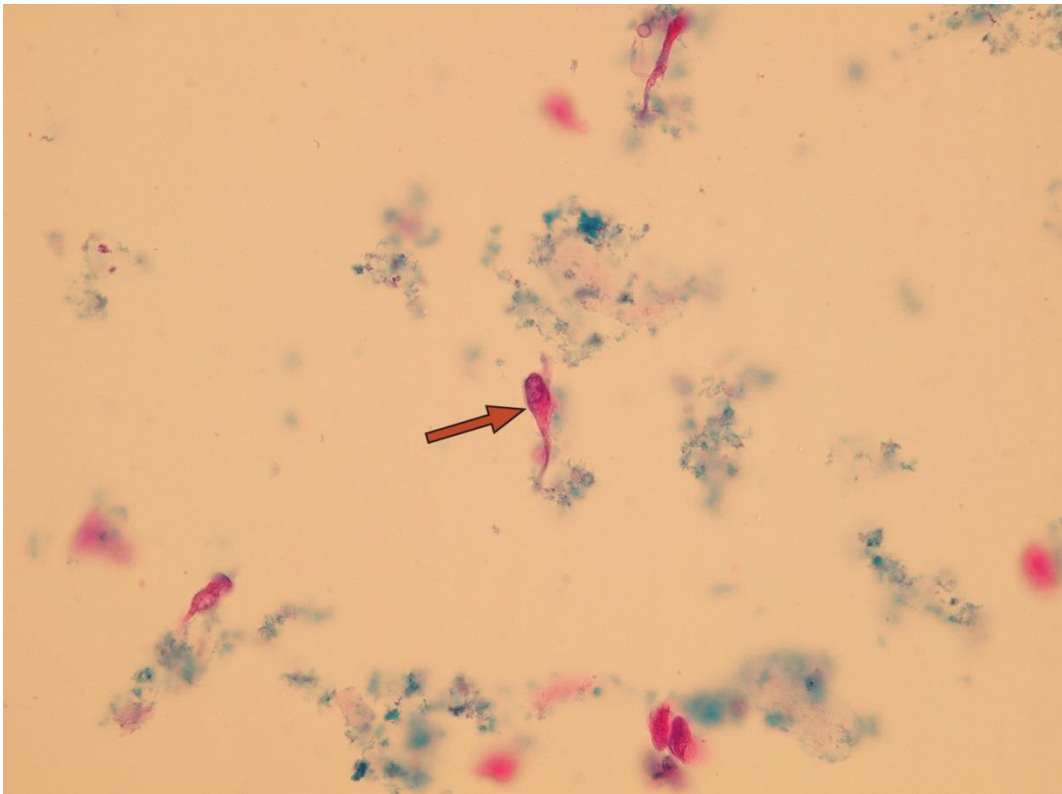
Stained sediment



Transitional epithelial cells

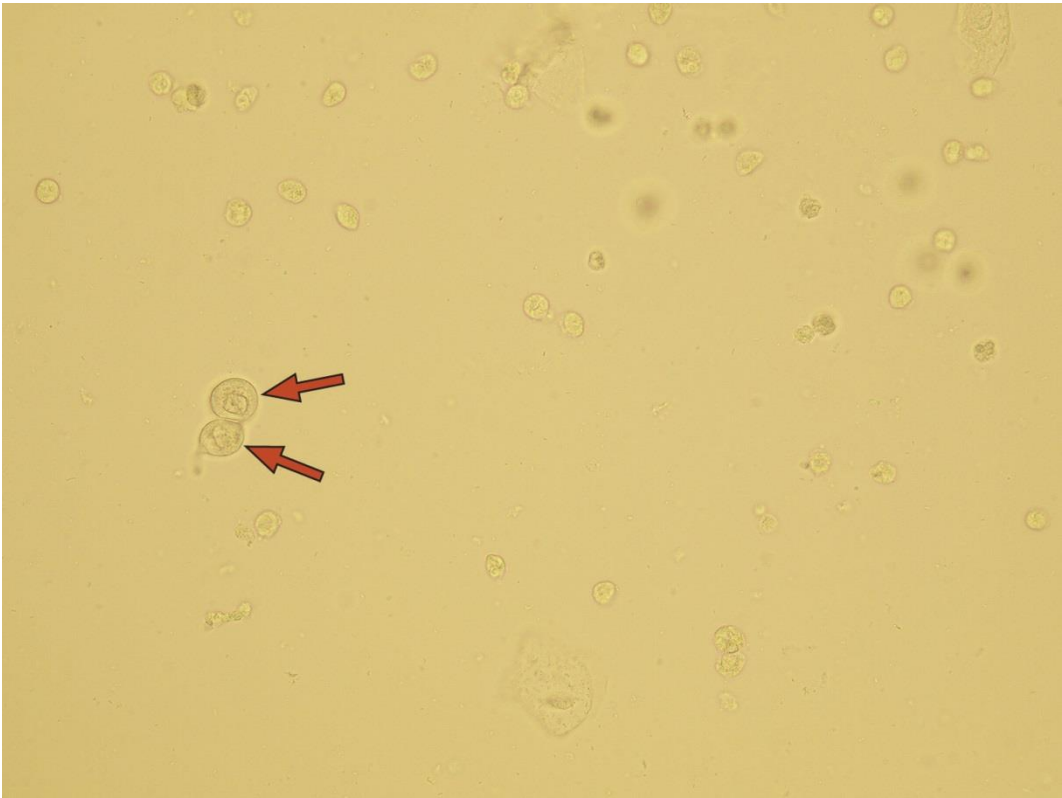


Transitional epithelial cell with two nuclei

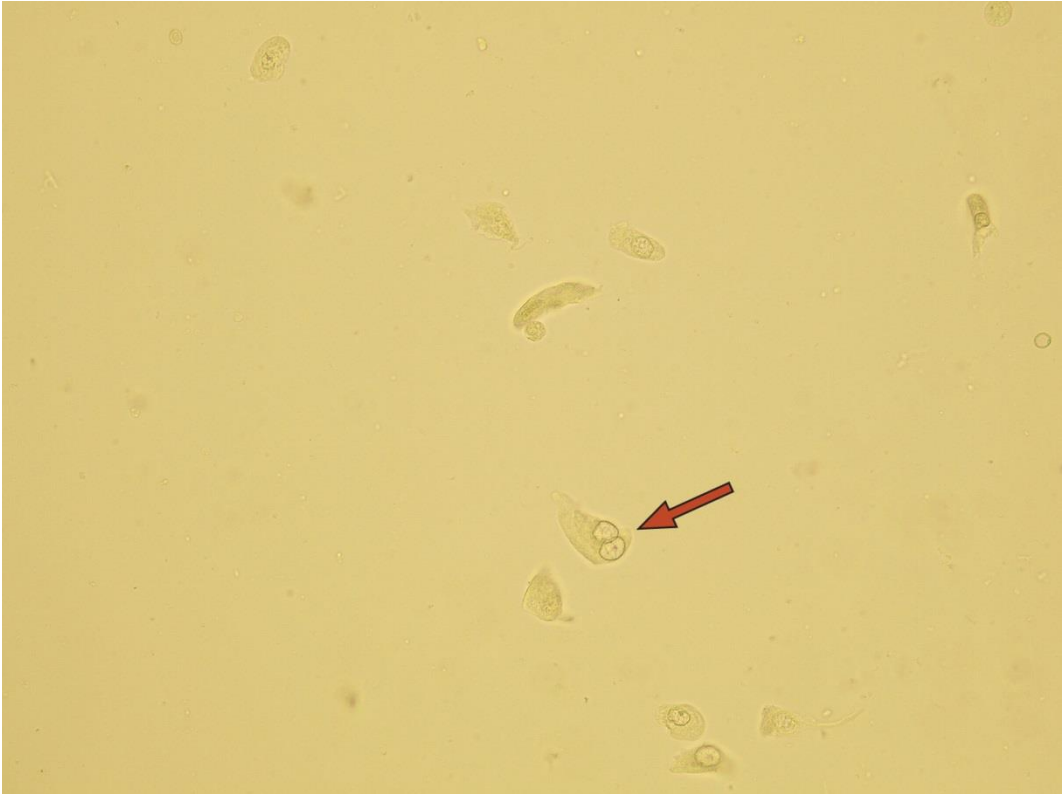

Caudate transitional epithelial cells


Native sediment



Transitional epithelial cells



Transitional epithelial cell with two nuclei

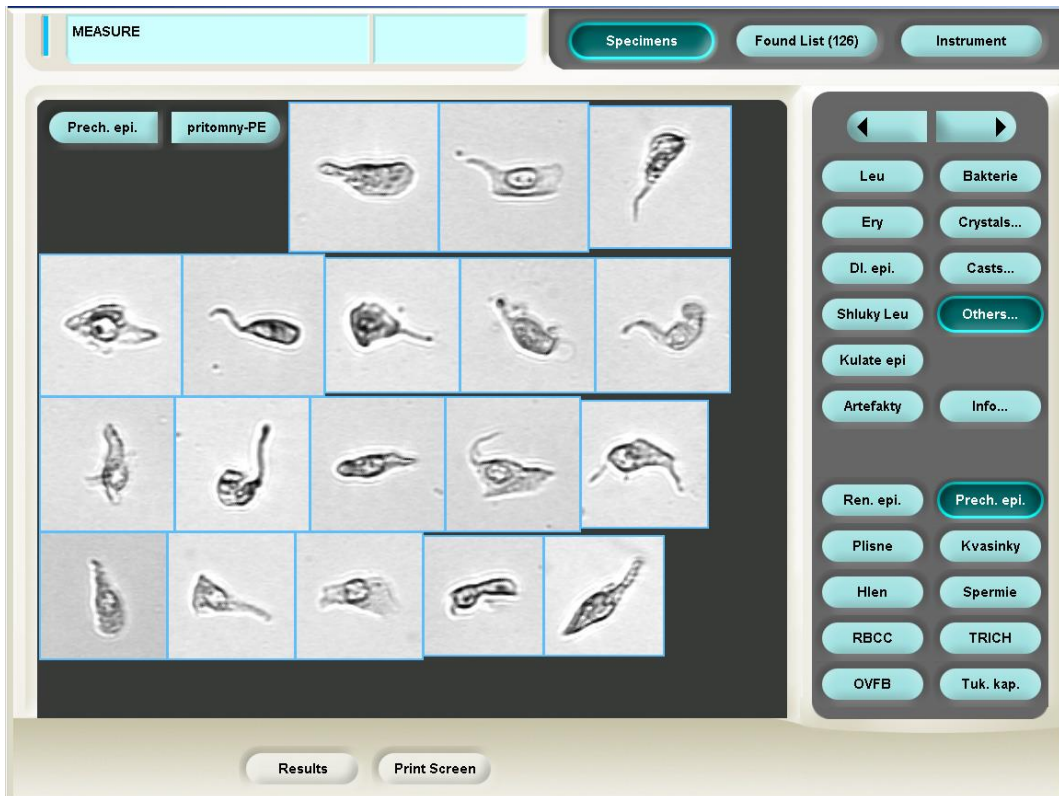


Caudate transitional epithelial cell

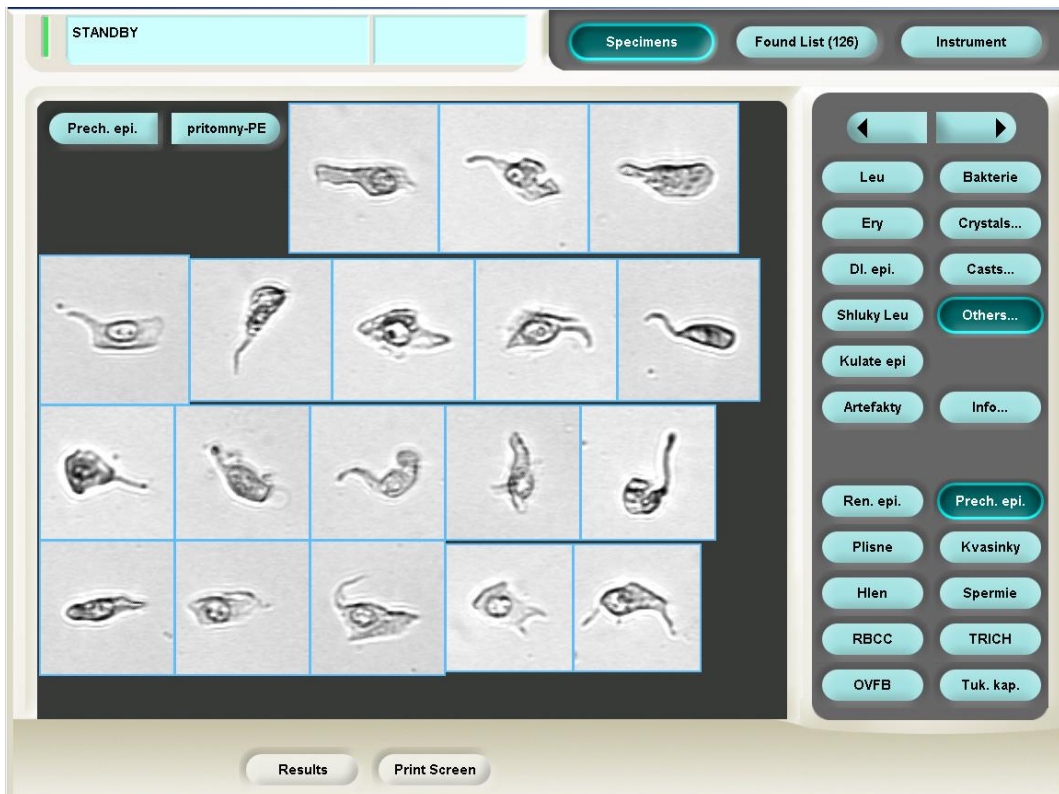
Pictures from iQ 200 analyzer (IRIS)

| | | |
|------------------------------|----------|--|
| All Small Particles: 6473/uL | | |
| GLU | Normal | |
| PRO | +1 | |
| BIL | - | |
| URO | Normal | |
| PH | 6.0 | |
| Krev | +2 | |
| KET | - | |
| NIT | Negative | |
| LEU | +4 | |
| CLA | Turbid | |
| SPGR | 1.015 | |
| COL | Yellow | |

Transitional epithelial cells



Caudate transitional epithelial cells – several of them with two nuclei



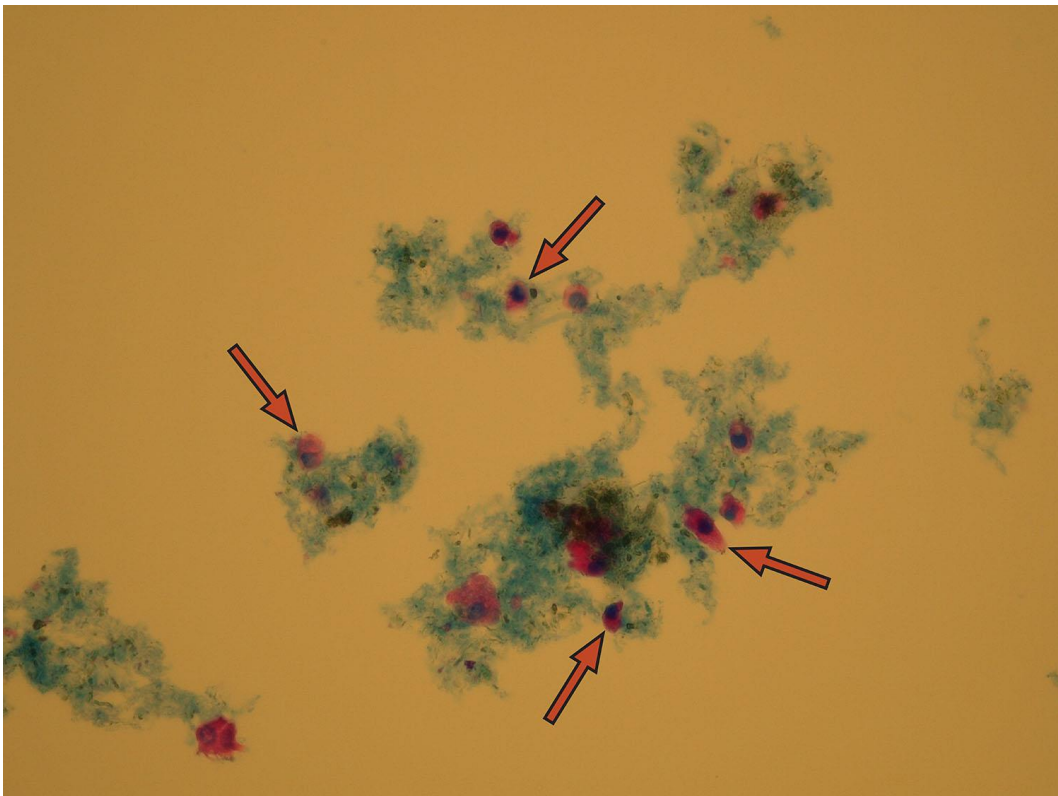
Caudate transitional epithelial cells

Renal epithelial cells

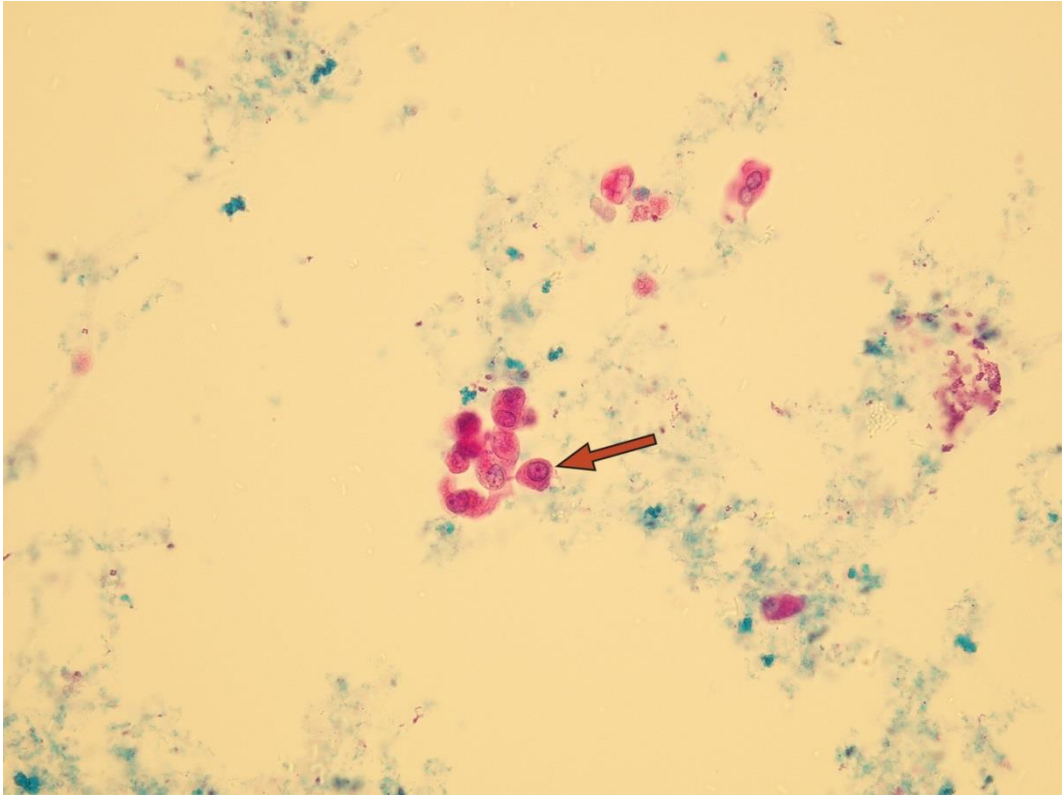
These cells have polyedric shape with non-segmented eccentric nucleus. They are the smallest epithelial cells, approximately twice the size of a leukocyte. They don't absorb water and swell, but keep their polyedric shape. Proximal tubular cells have granulated cytoplasm and sometimes may appear as small or fragmented granular casts. They are clinically significant elements in urine in cases of acute tubular necrosis or viral infection and drug or heavy metal toxicity.

Renal epithelial fragments constitute of several renal cells of collecting duct origin. Their presence in urine is considered to be clinically severe and indicates heavy renal tubular damage.

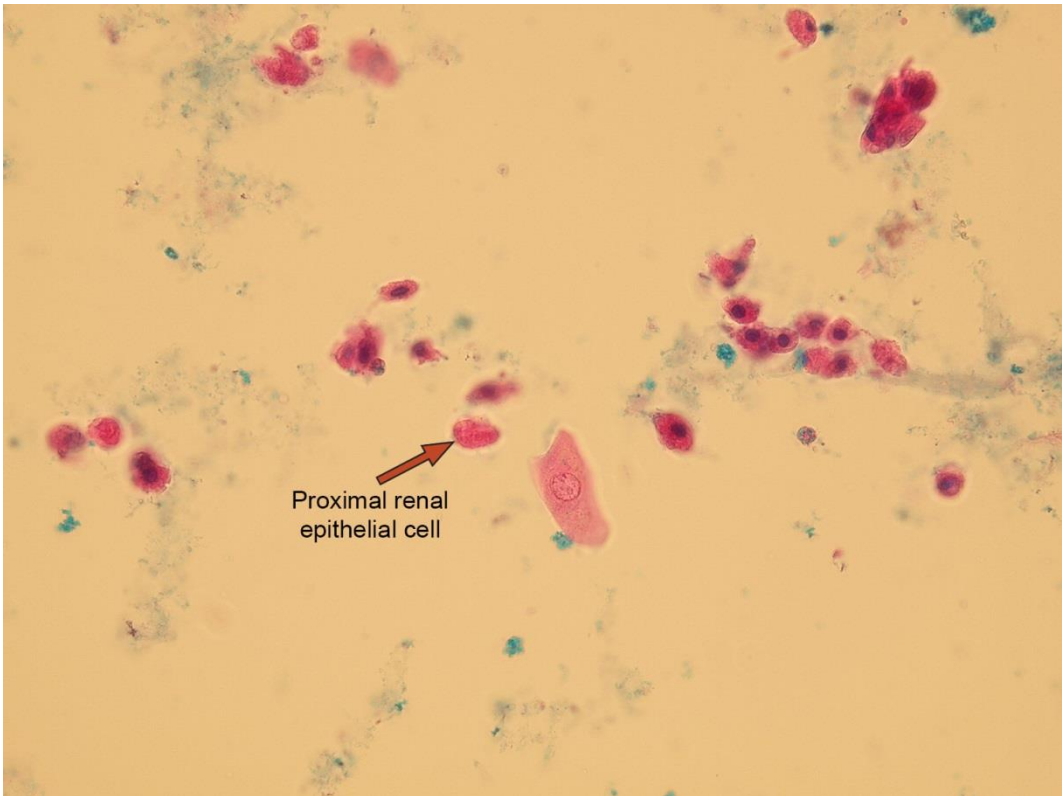
Stained sediment



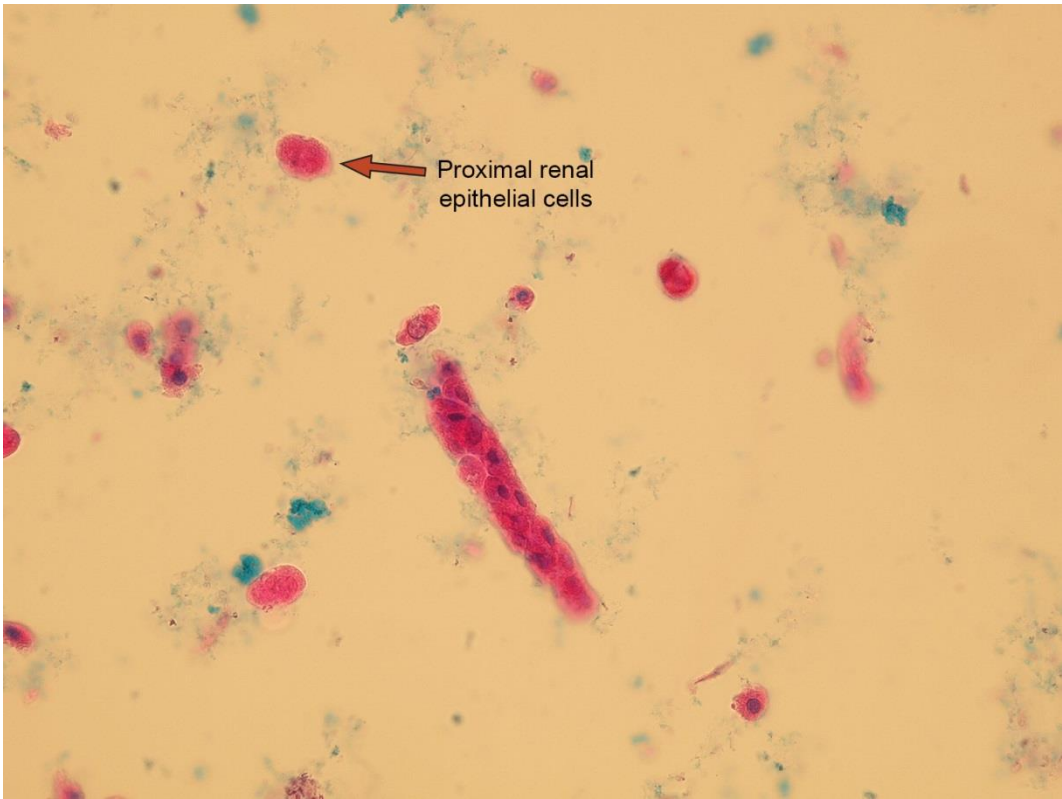
Renal epithelial cells



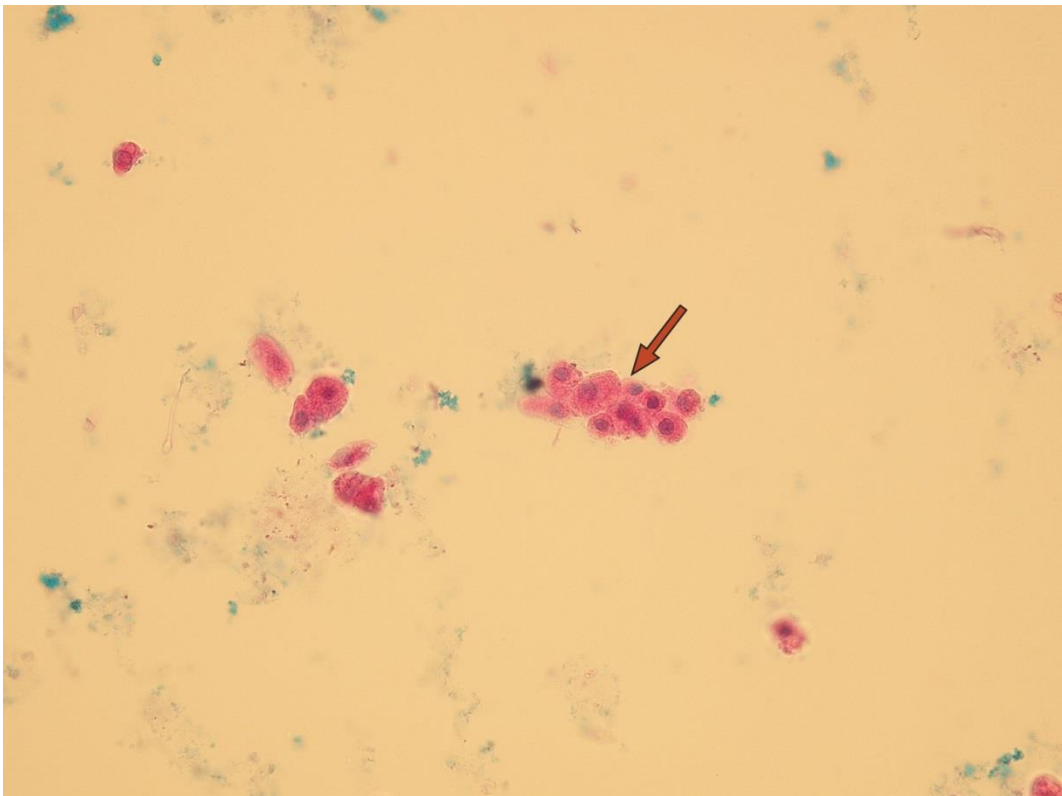
Renal epithelial cells



Renal tubular epithelia

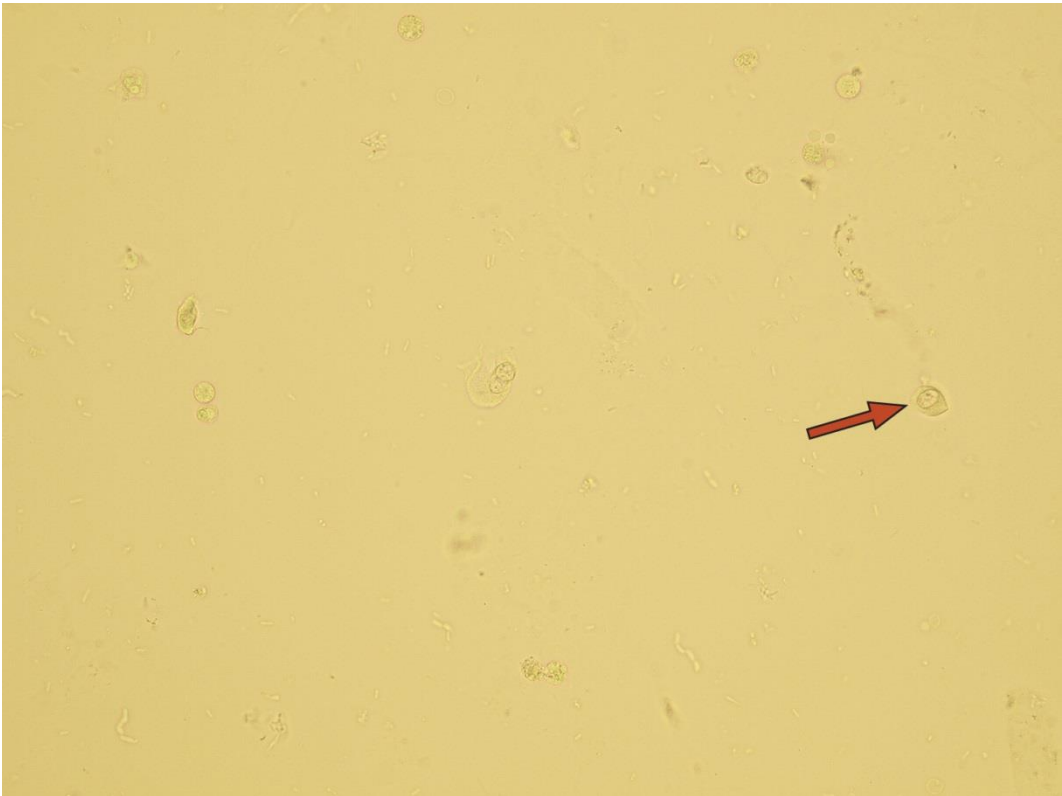


Renal tubular epithelia

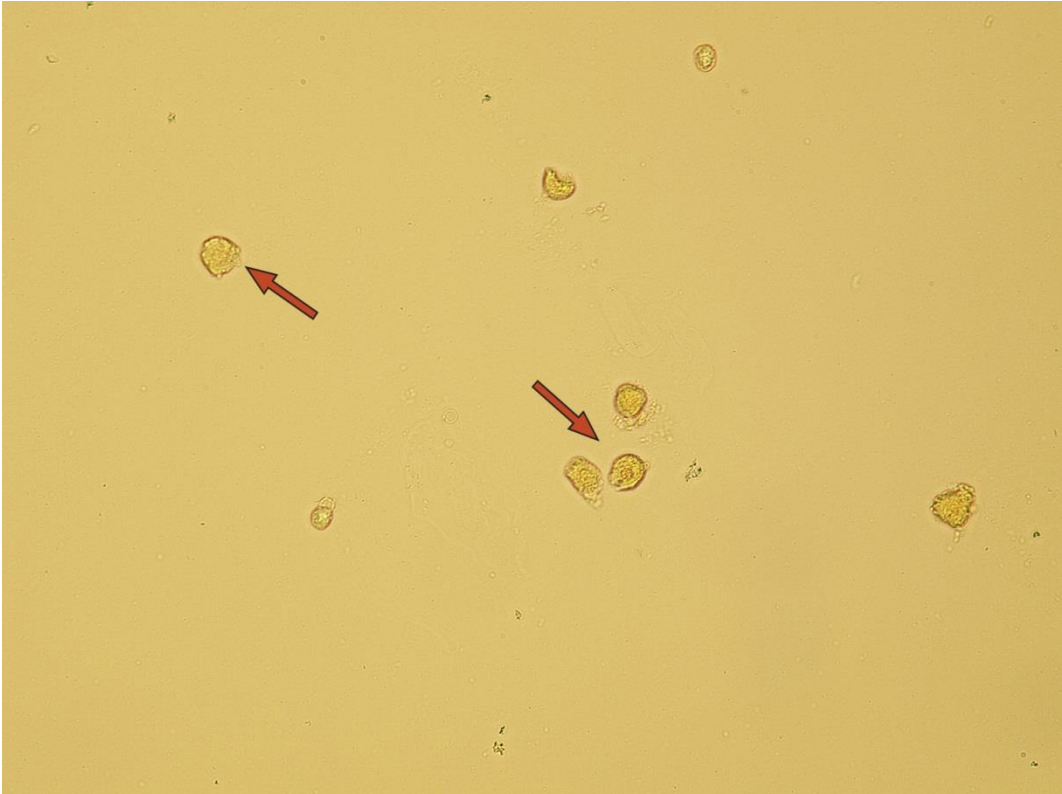


Fragments of renal tubular epithelia

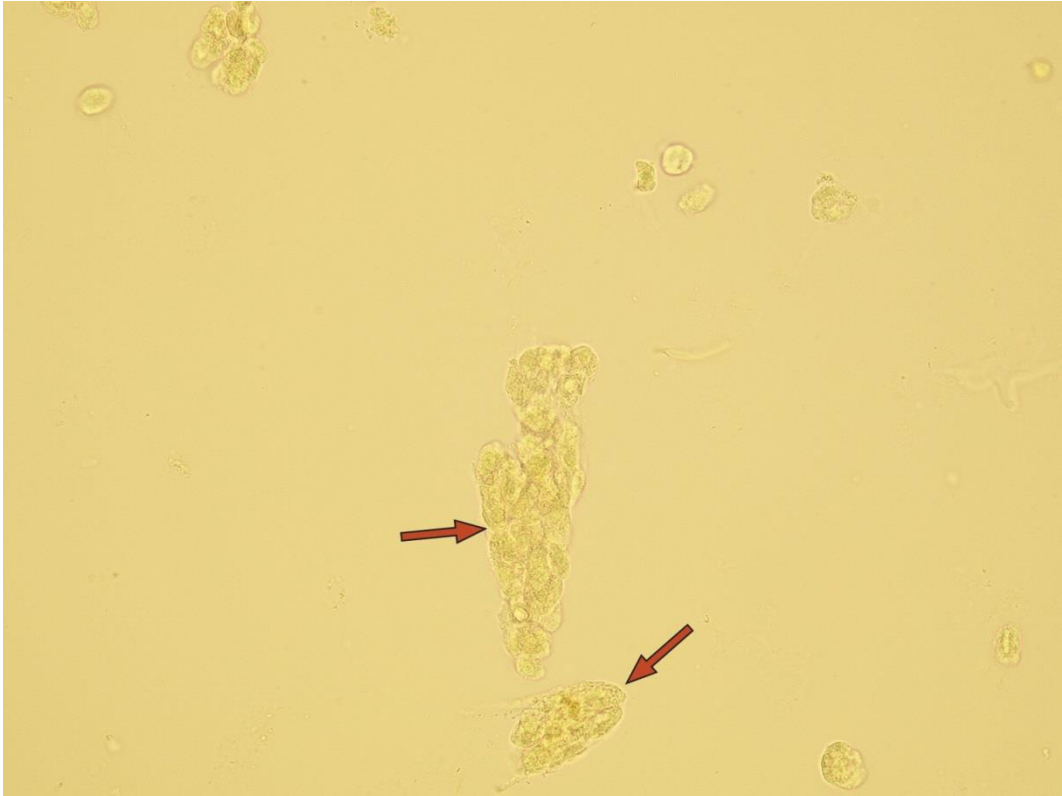
Native sediment



Renal epithelial cells

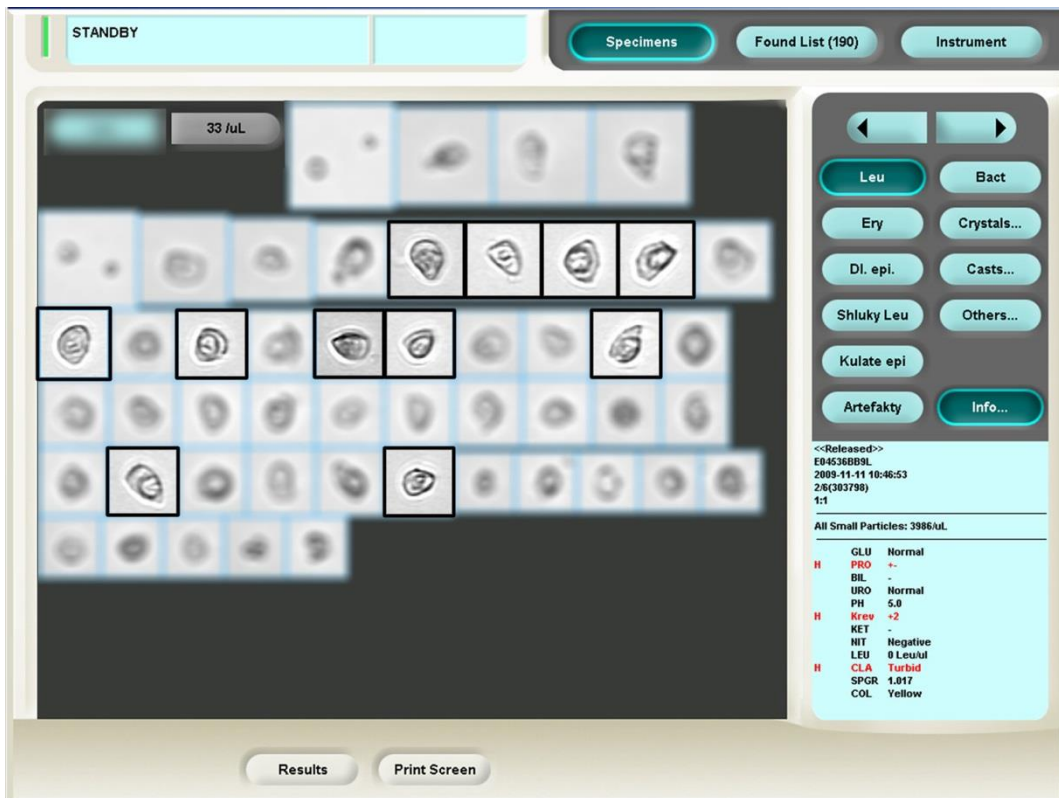


Renal tubular epithelia probably from proximal tubules

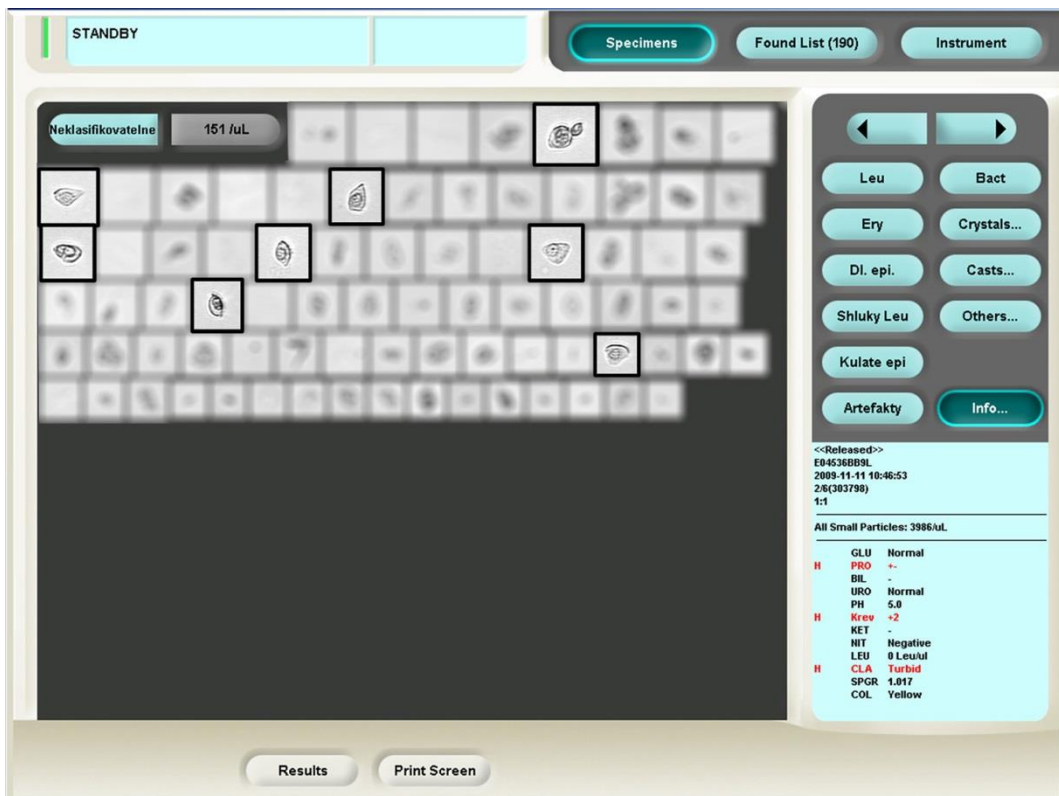


Fragments of renal tubular epithelia

Pictures from iQ 200 analyzer (IRIS)



Renal tubular epithelia



Renal tubular epithelia

Casts

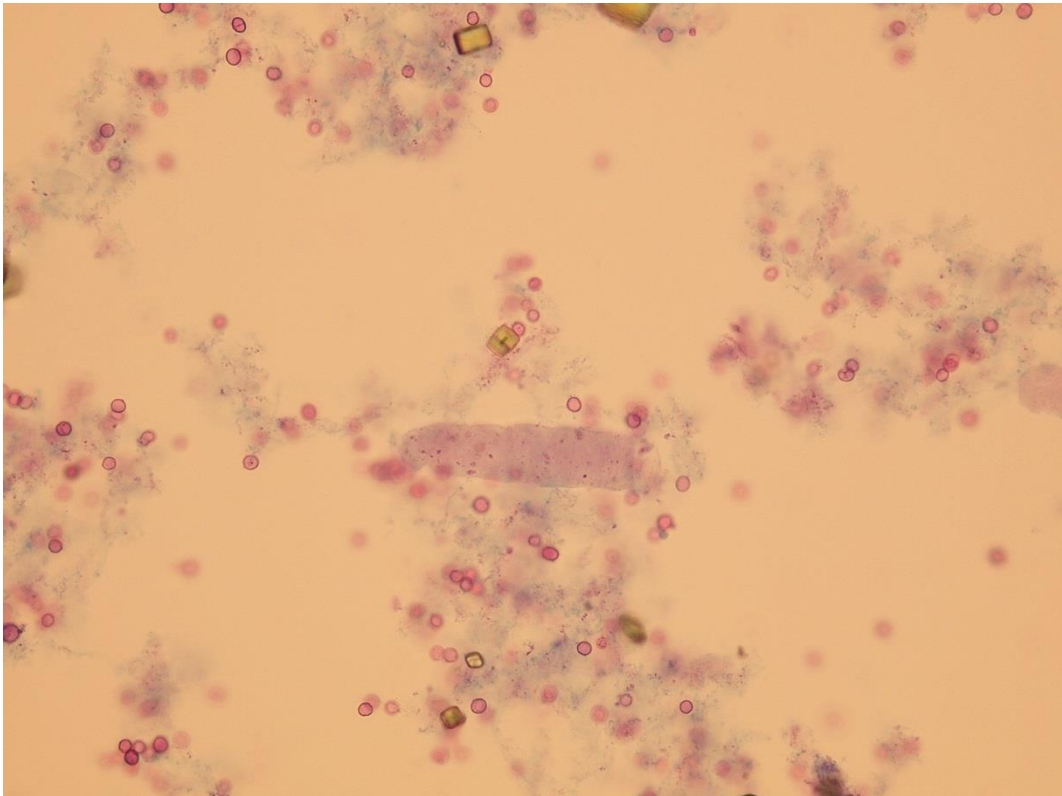
These elements are formed in the kidney tubules by Tamm-Horsfall mucoprotein precipitation. The mucoprotein is secreted from renal tubule cells. Their formation is reinforced by acidic pH in urine, higher concentration of plasmatic proteins, dehydration and excessive physical activity. Their shape copies the shape of a tubule with defined outer line, parallel sides and round ends.

We distinguish hyaline, cellular, granular, wax, lipid, bacterial and combined casts. The cast is classified as cellular or granular cast only if the amount of material inside takes up to 1/3 of its volume. Otherwise, it is called hyaline cast. The cast goes through different stages of development with increasing time in the kidney tubule: cell cast → granular cast → waxy cast.

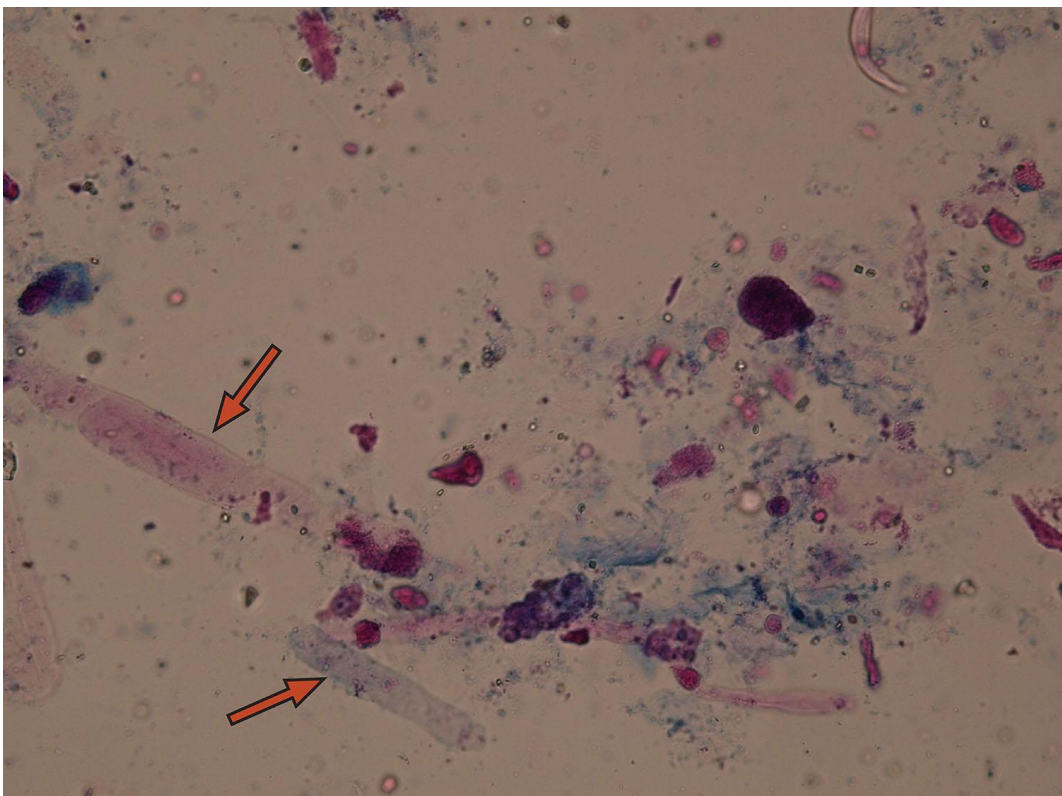
Hyaline casts

Hyaline casts are formed only by Tamm-Horsfall glycoprotein without any other elements or their fragments inside. Due to their composition, they are almost undetectable in native sediment.

Stained sediment




Hyaline cast


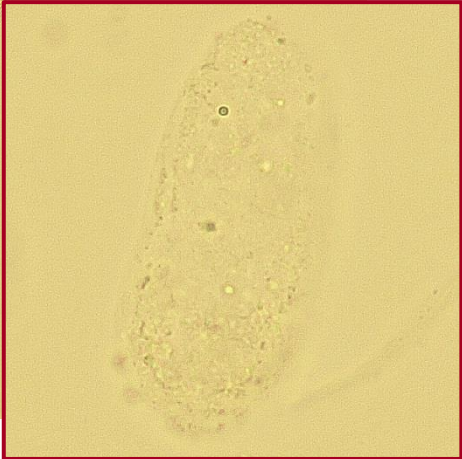


Hyaline casts

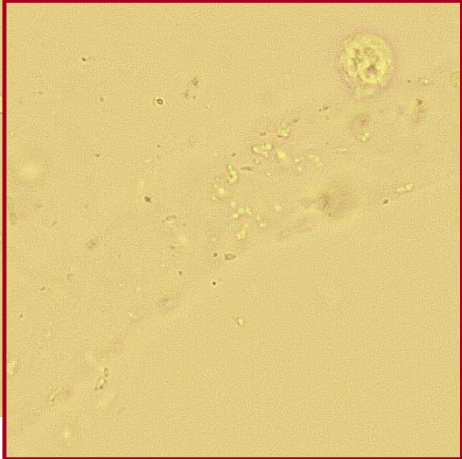
Native sediment



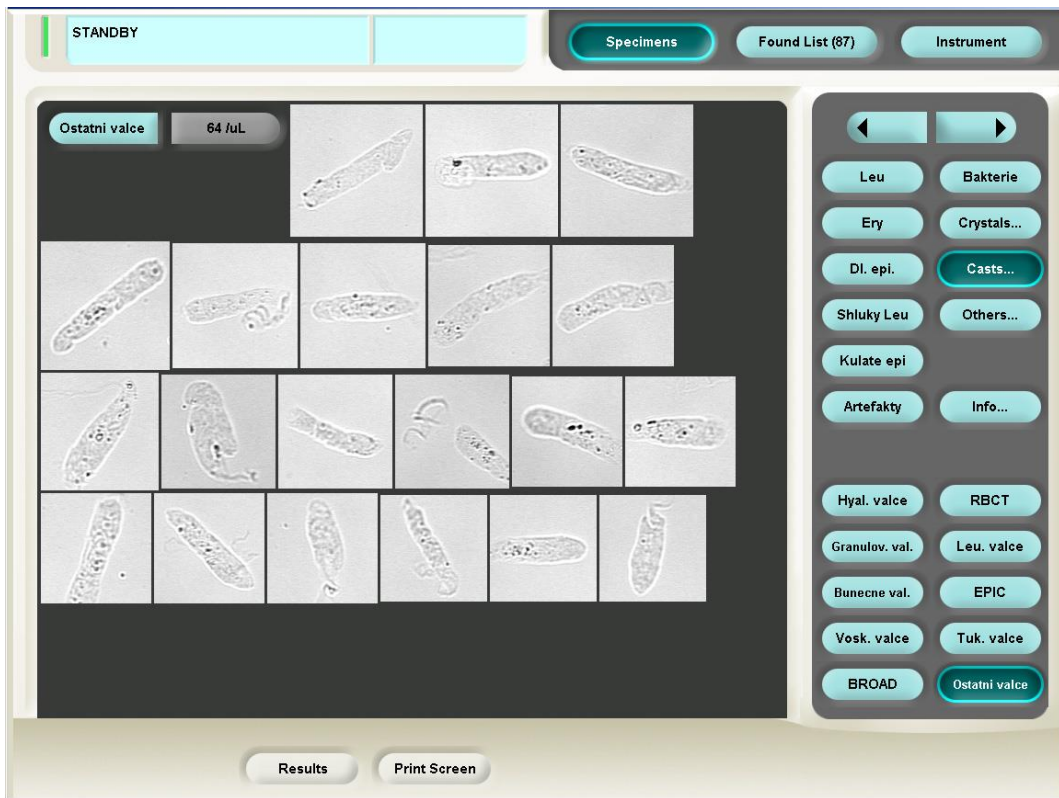
Hyaline cast



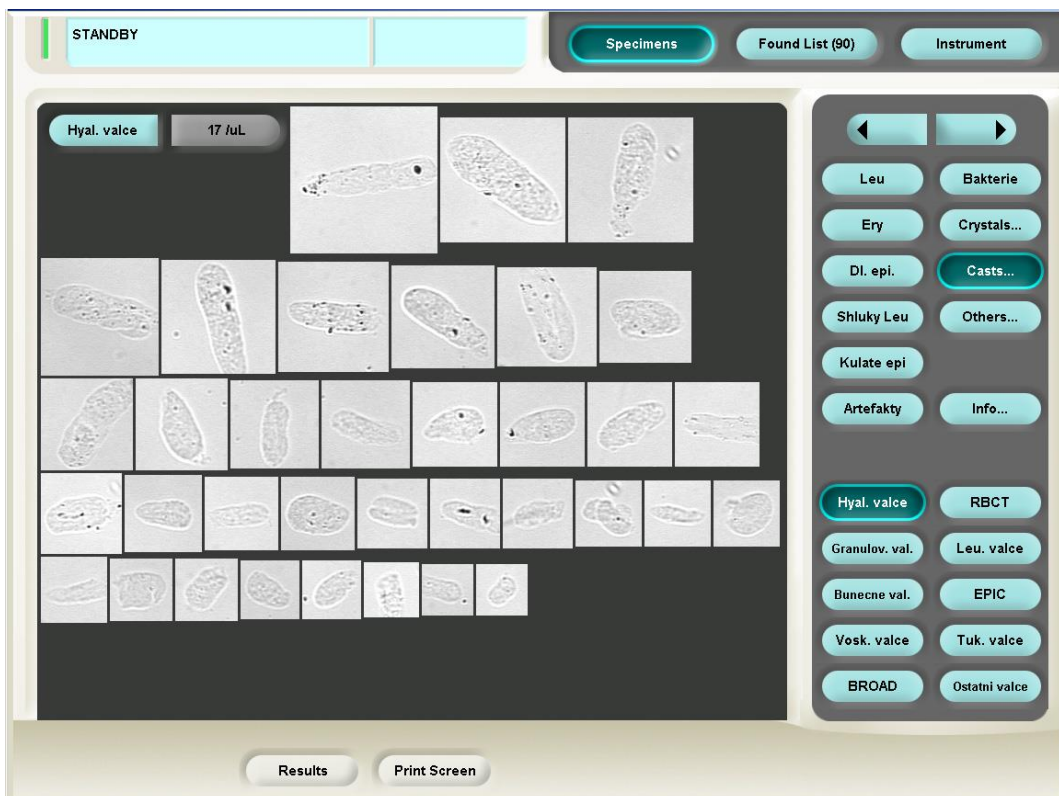
Hyaline cast



Pictures from iQ 200 analyzer (IRIS)



Hyaline casts

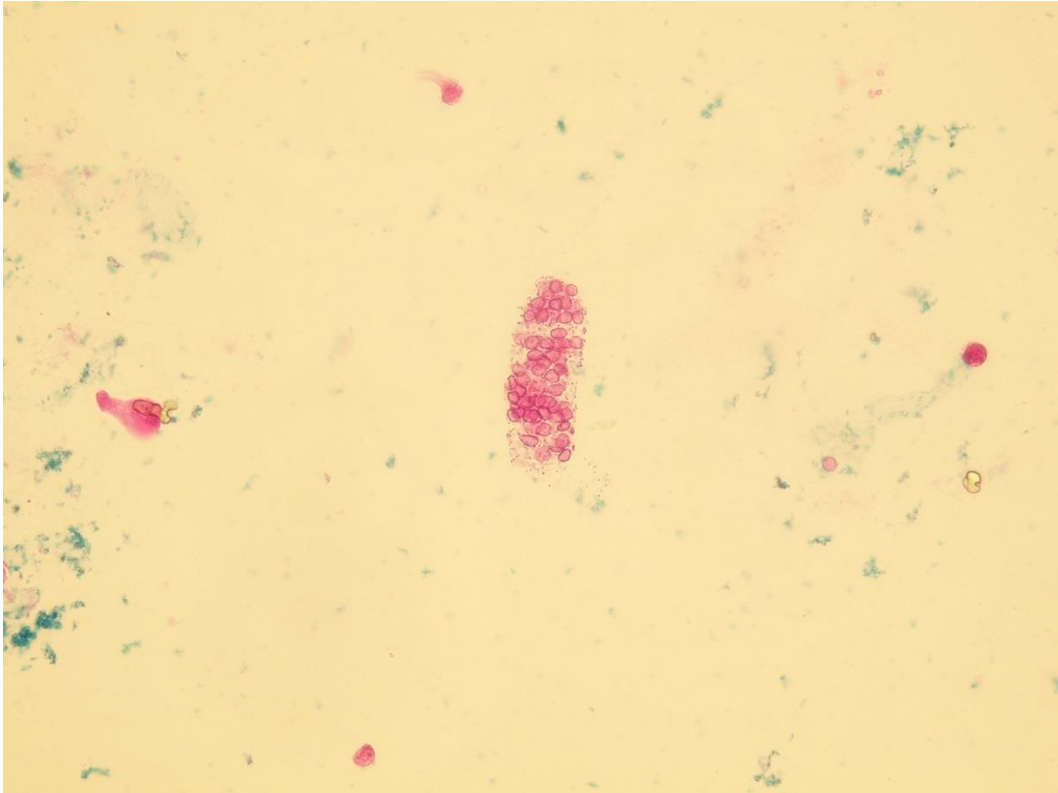


Hyaline cast

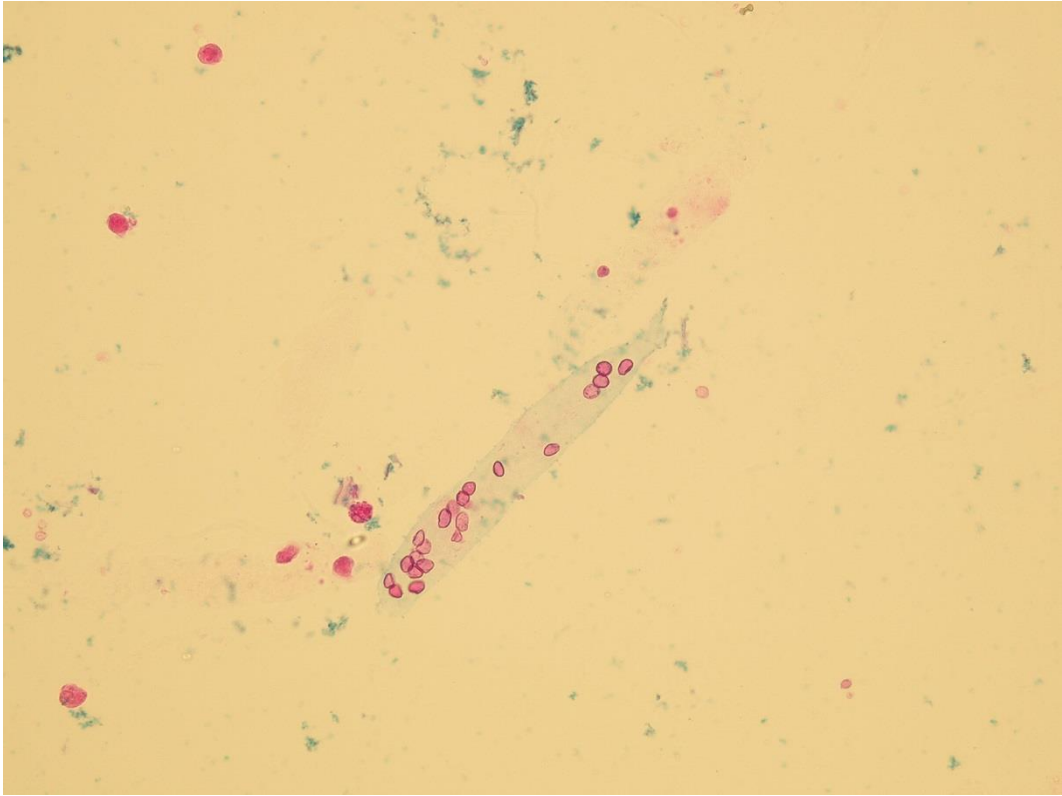
Cell casts

Cellular casts comprise of cells that may occur in renal tubules (leukocytes, erythrocytes and tubular epithelia) entrapped in Tamm-Horsfall mucoprotein matrix. We recognize leukocyte casts, erythrocyte casts and renal tubular epithelial cell casts. In some cases, the cells in the cast cannot be accurately determined and the cast is therefore categorized as cellular.

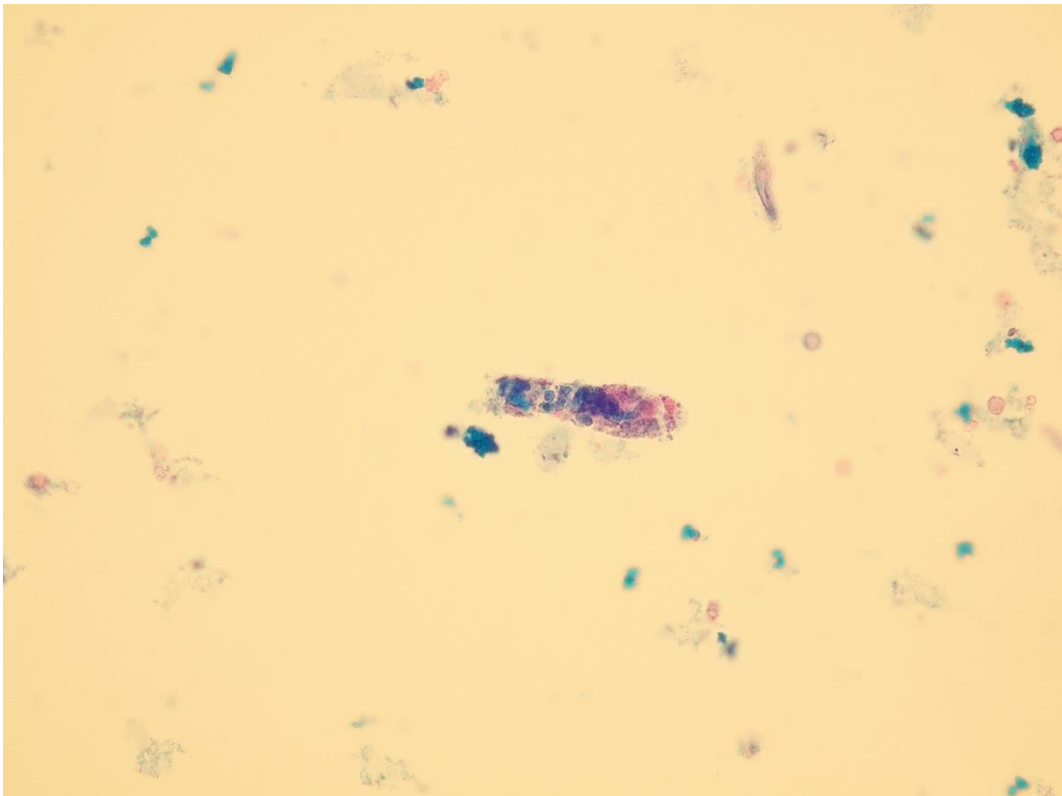Stained sediment



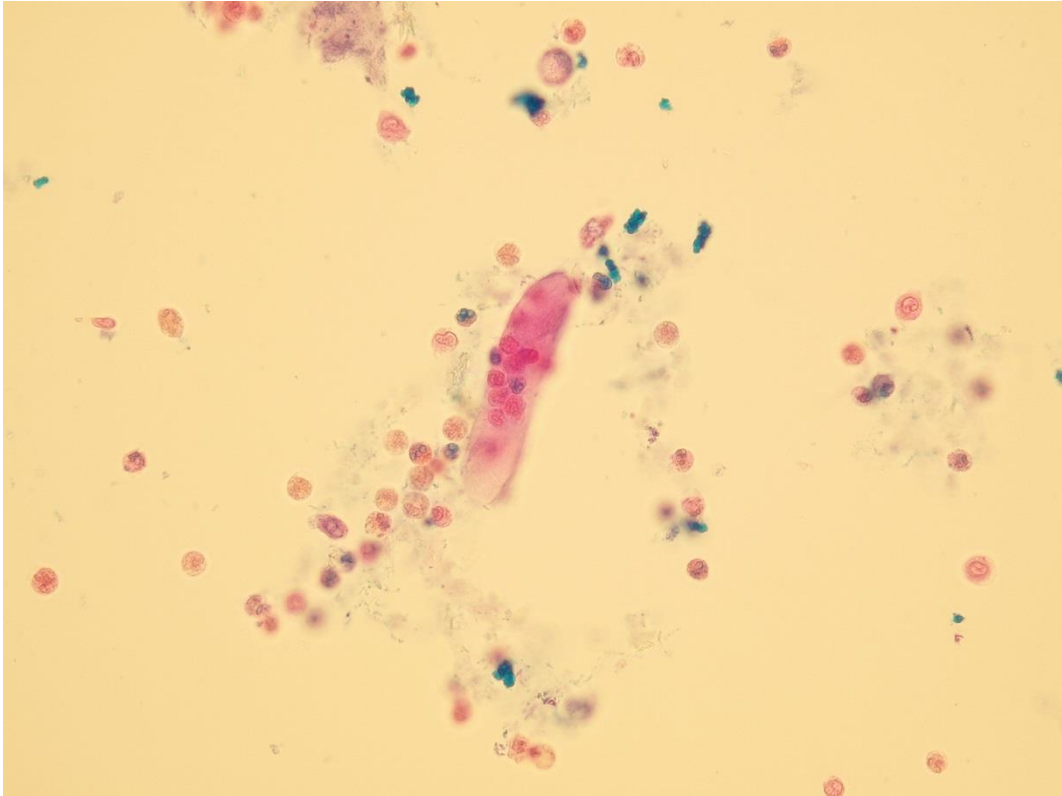
Erythrocyte cast



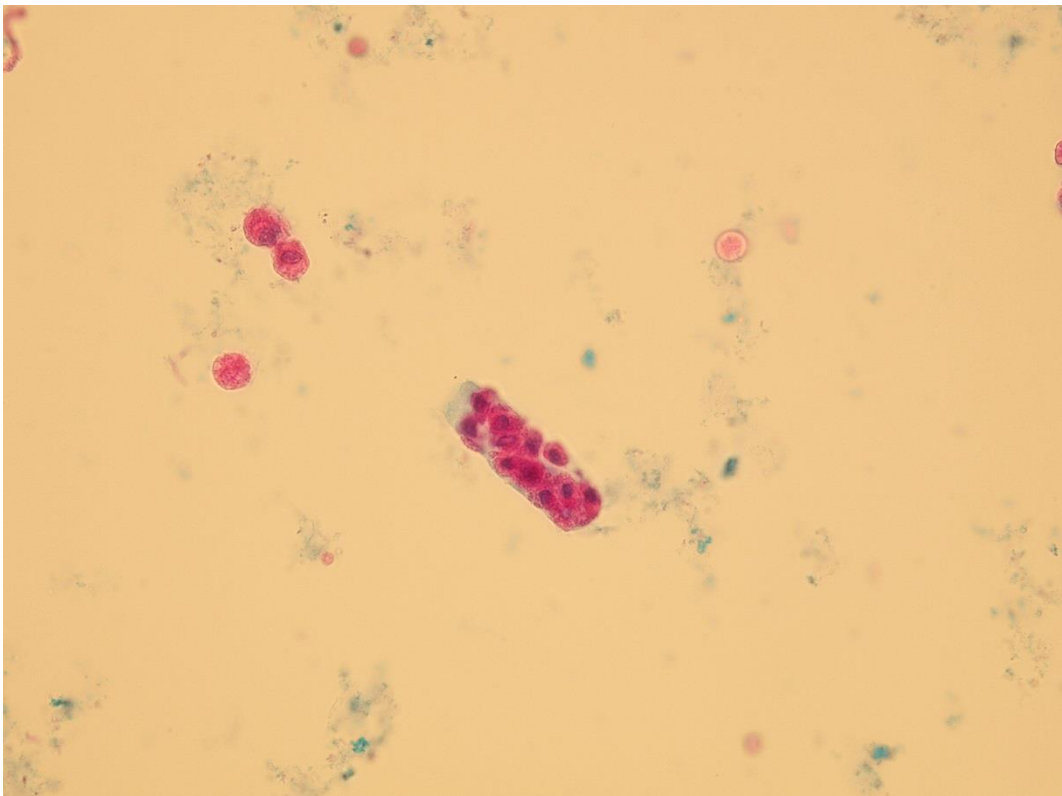
Hyaline cast with erythrocytes



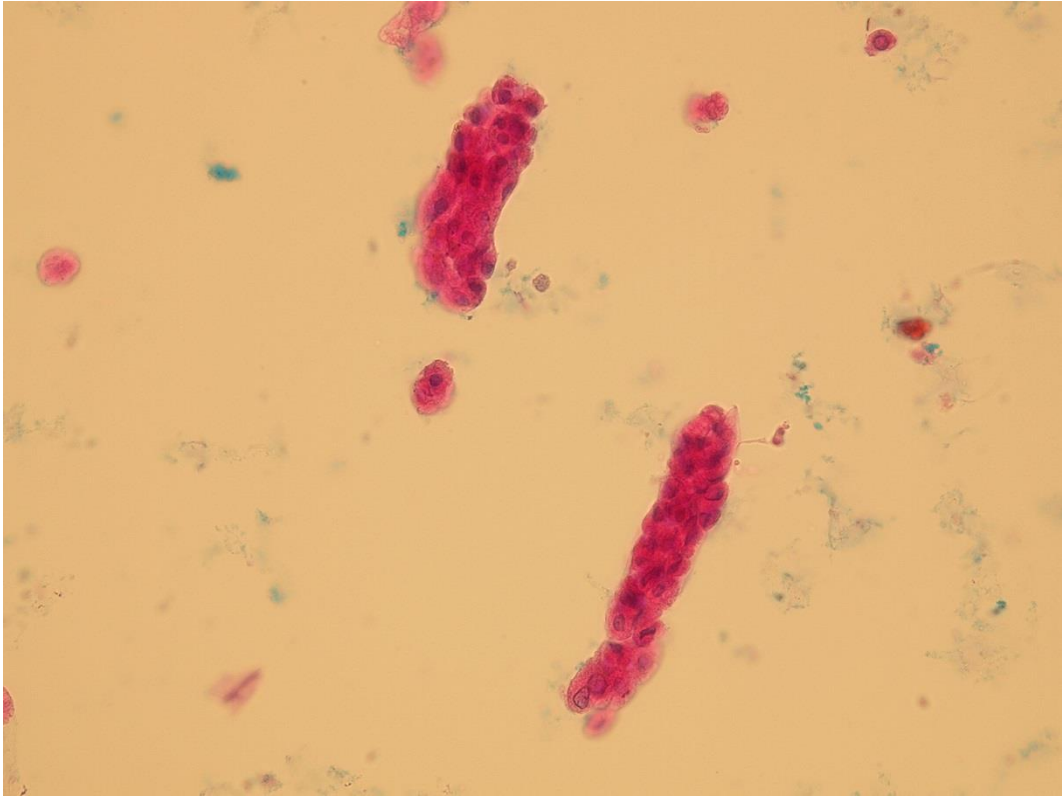
Leukocyte cast



Hyaline cast with leukocytes inside

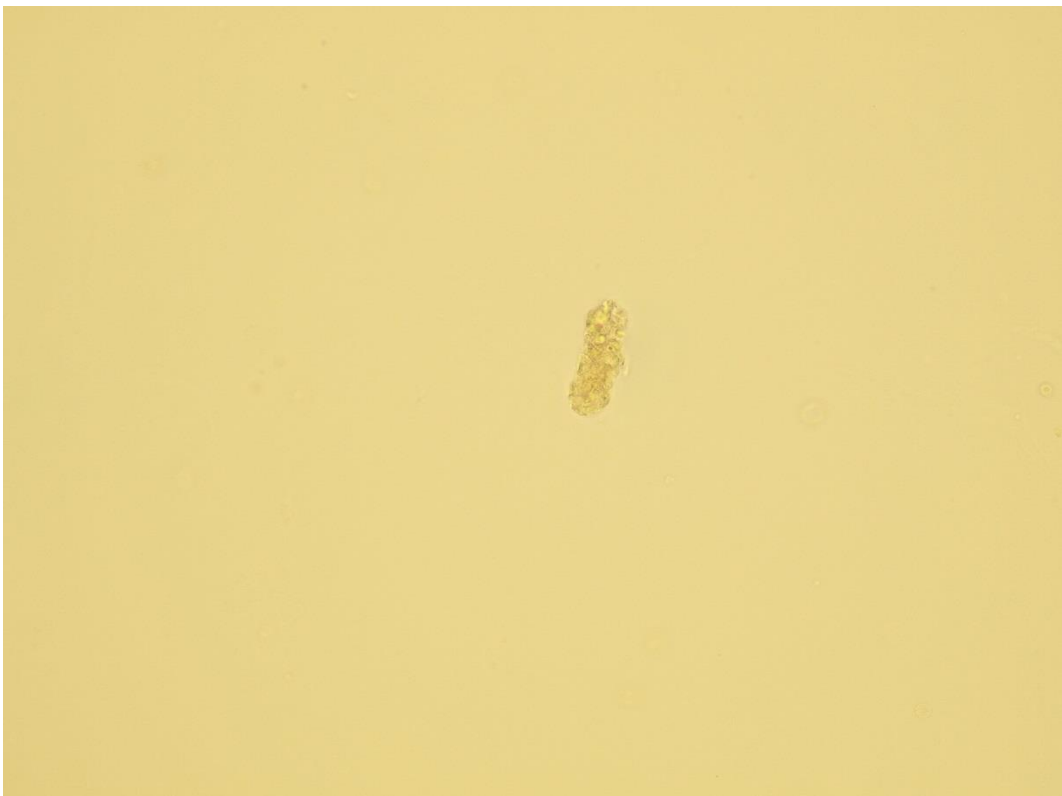

Renal epithelial cell cast

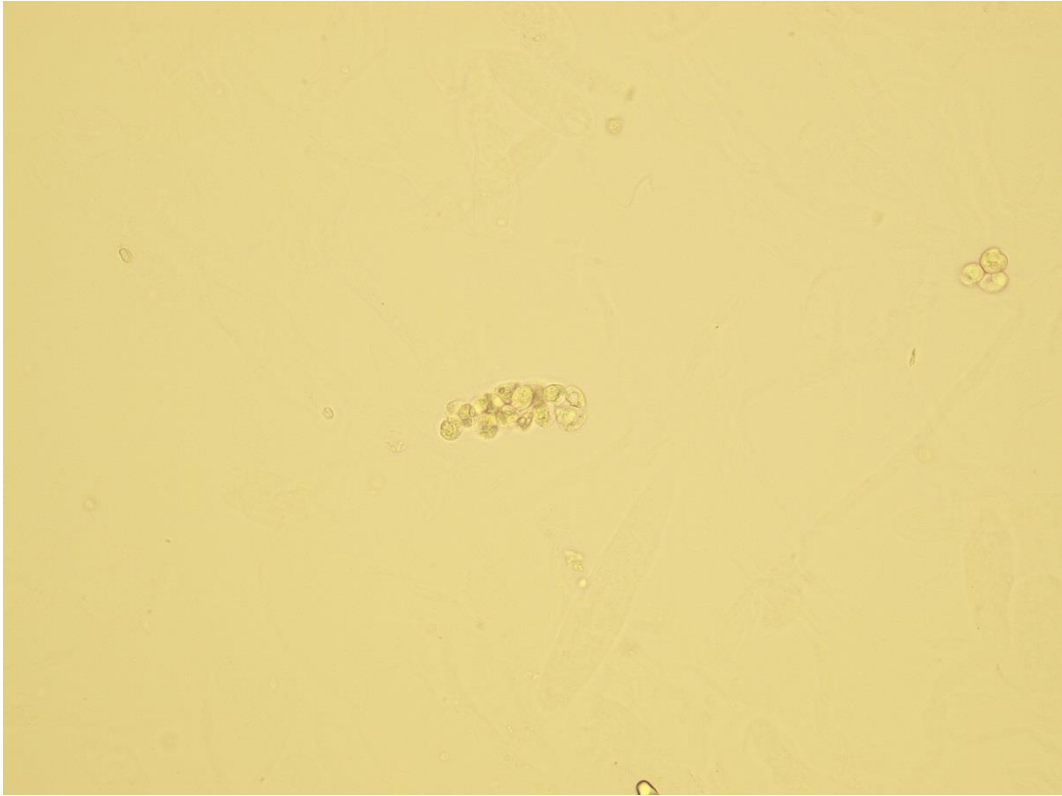


Renal epithelial cell casts

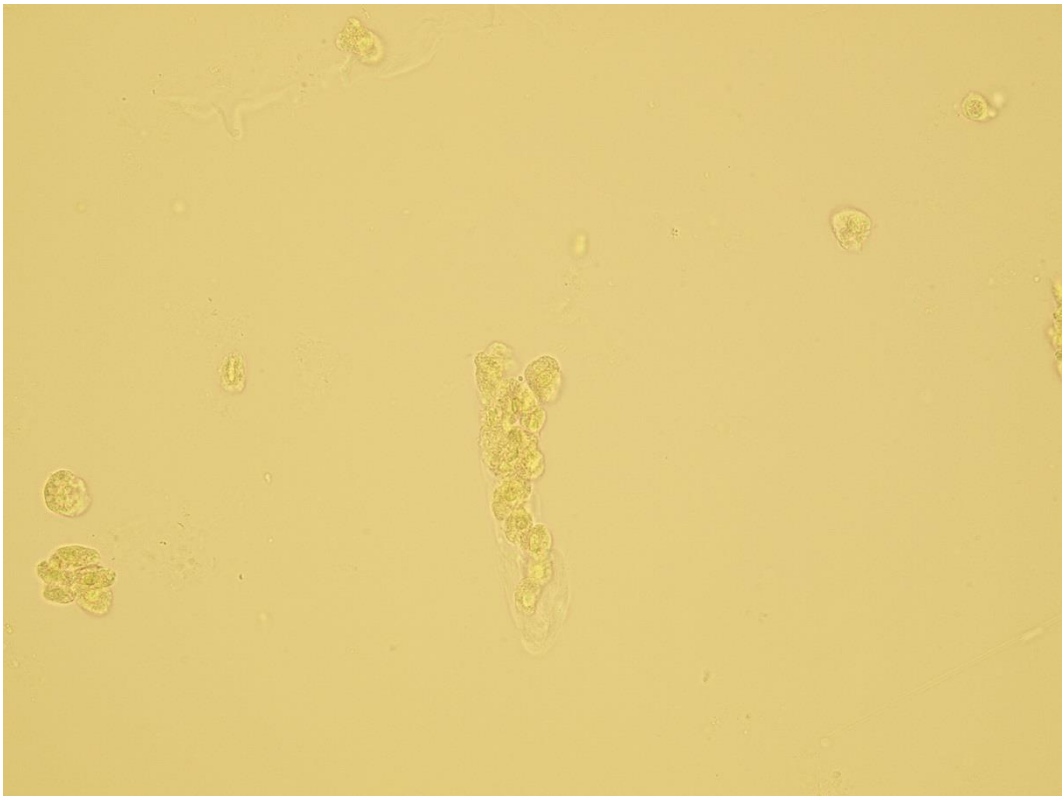Native sediment



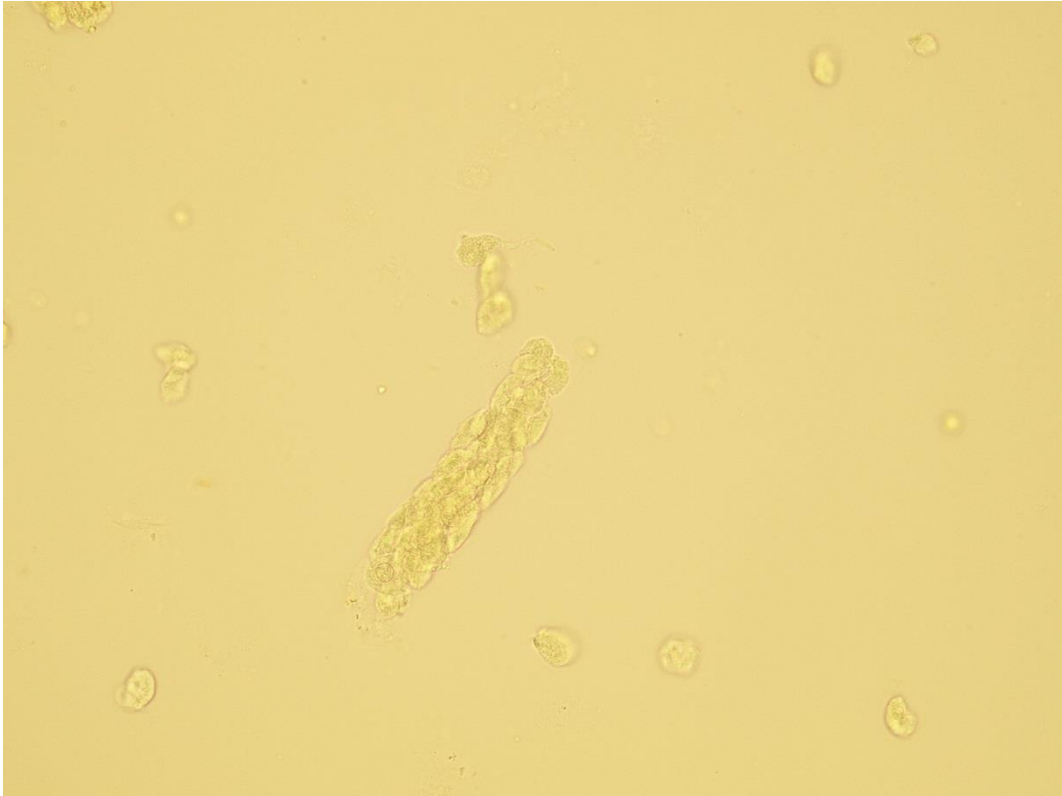
Erythrocyte cast



Leukocyte cast

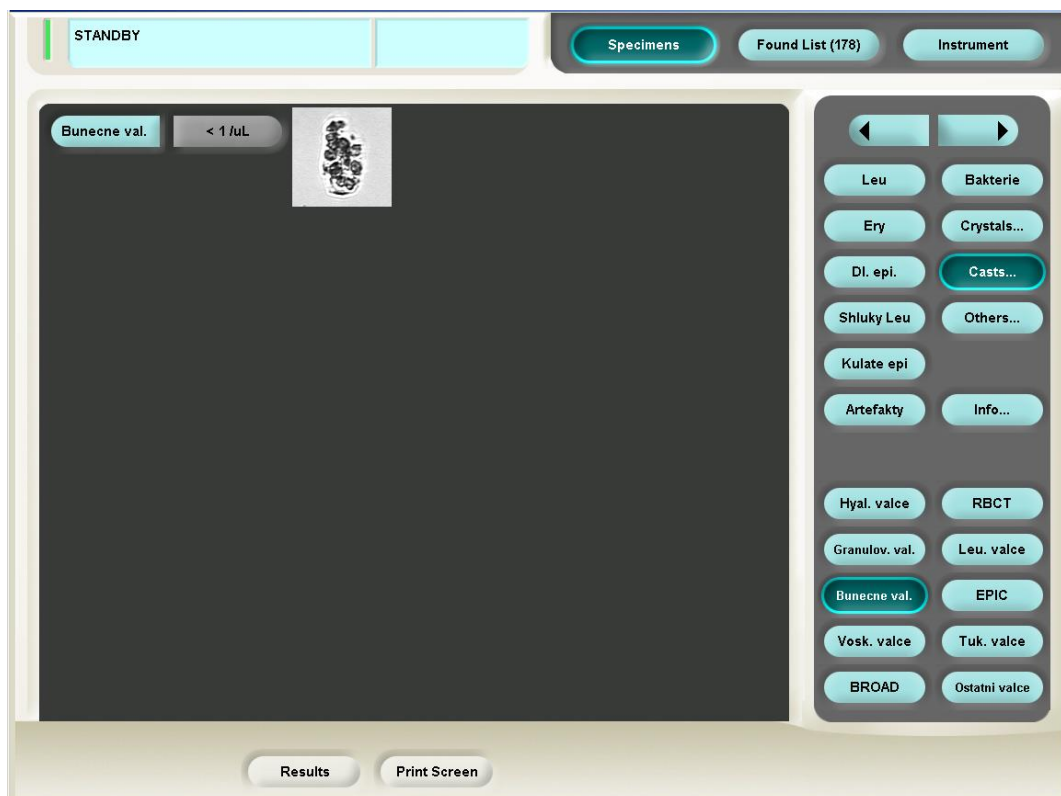


Renal epithelial cell cast

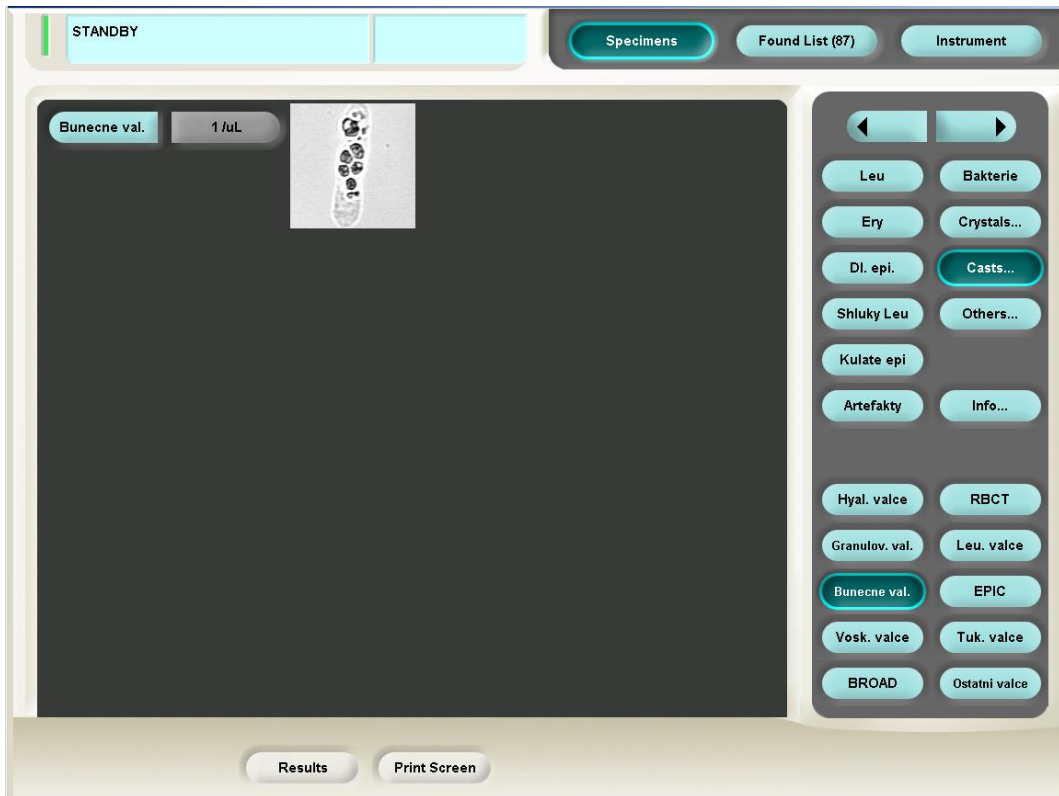


Renal epithelial cell cast

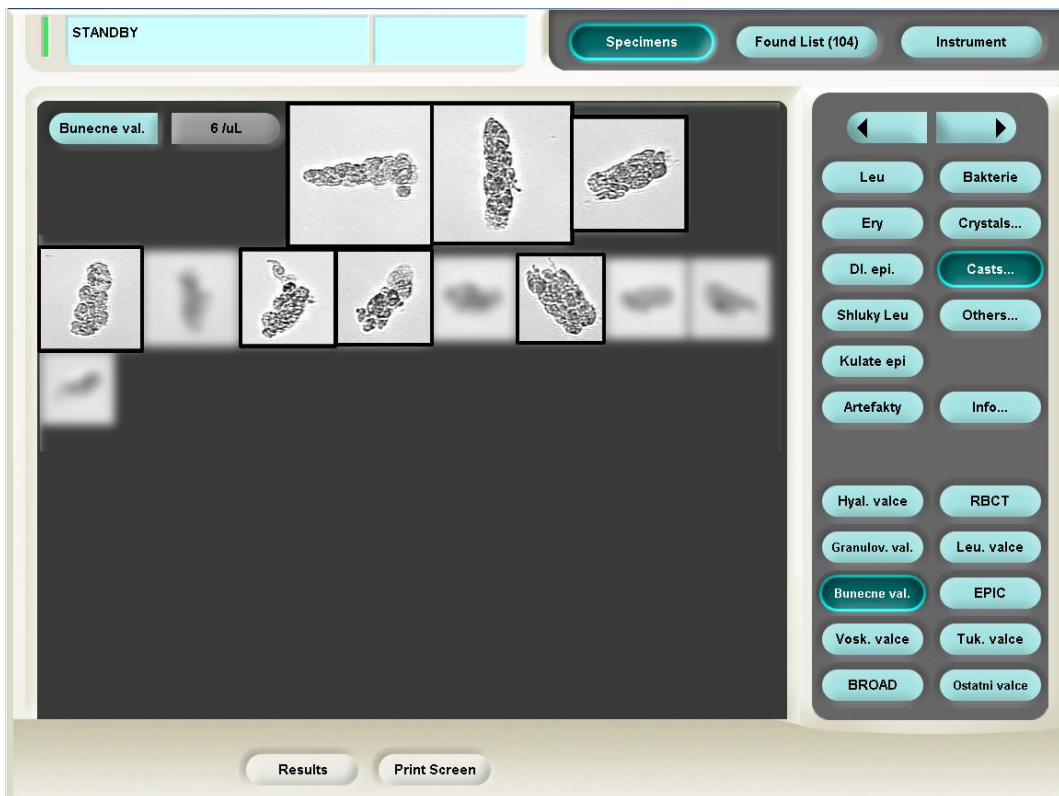
Pictures from iQ 200 analyzer (IRIS)



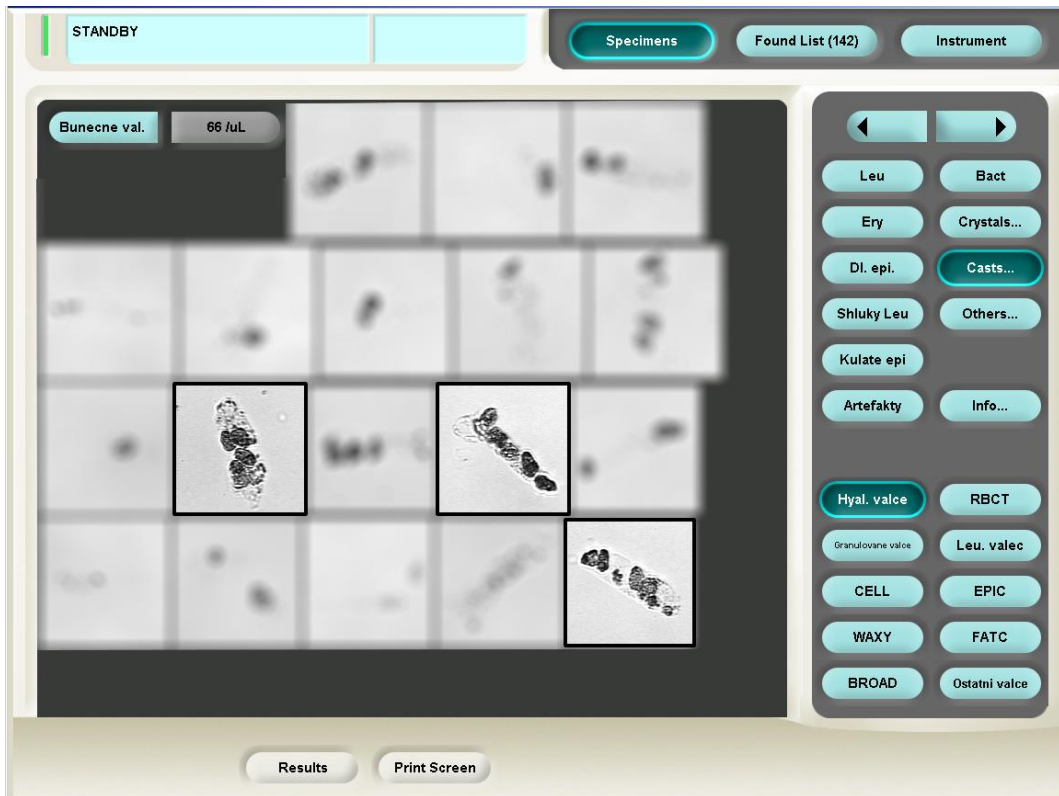
Erythrocyte cast



Leukocyte cast



Renal epithelial cast

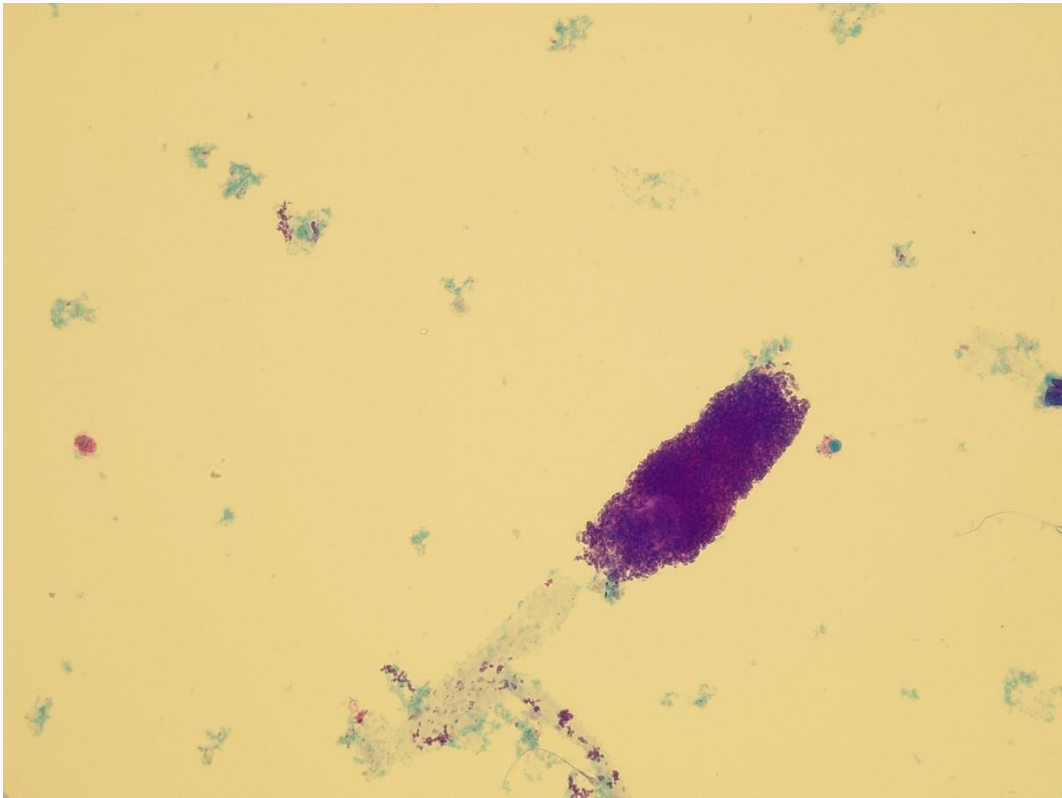


Renal epithelial cast

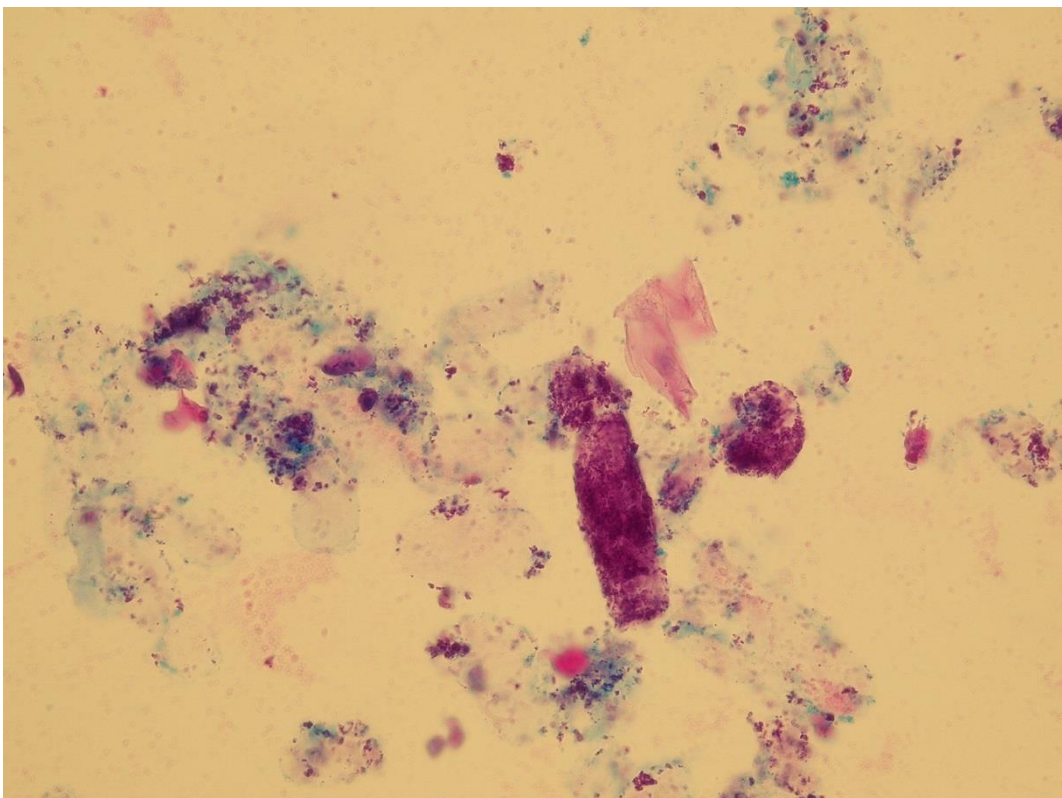
Granular casts

Granules inside these casts are formed after decomposition of cells in the cast or a tubule. Granular casts may vary from coarsely granular including cell particles to finely granular that are turning to waxy casts. Small number of these casts may occur after intensive physical activities (patients who were exposed to cold conditions or cold hardening). Increased concentration of granular casts is strongly pathological.

Stained sediment

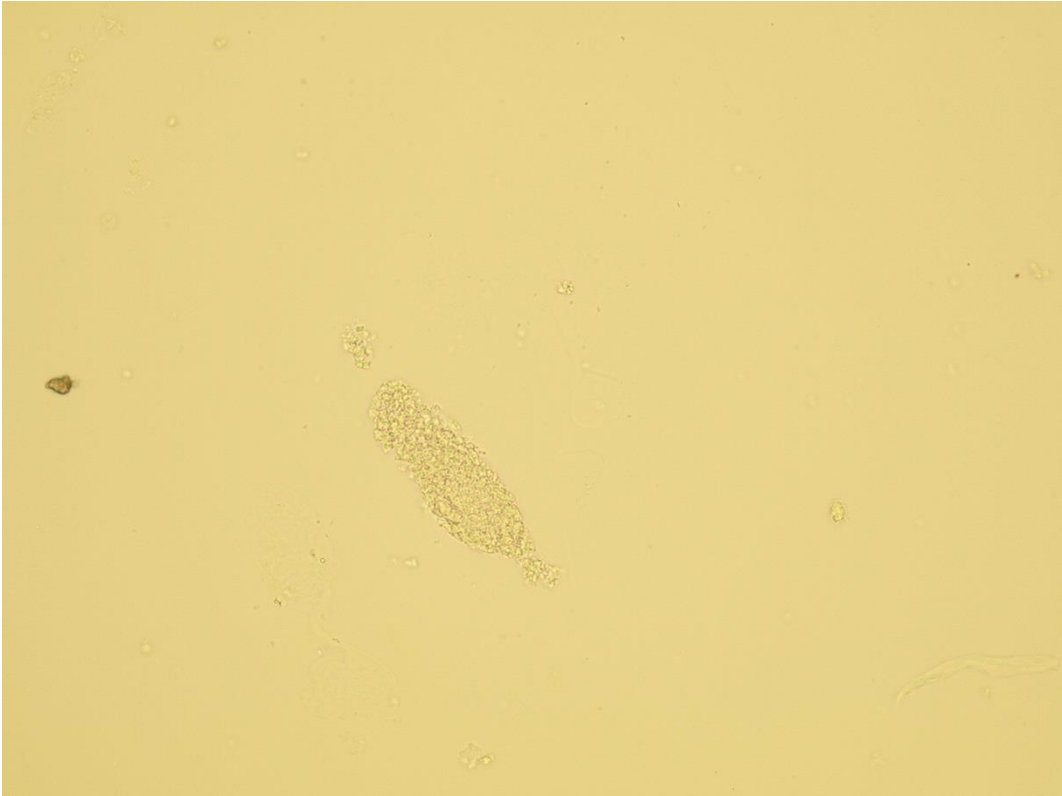


Granular cast

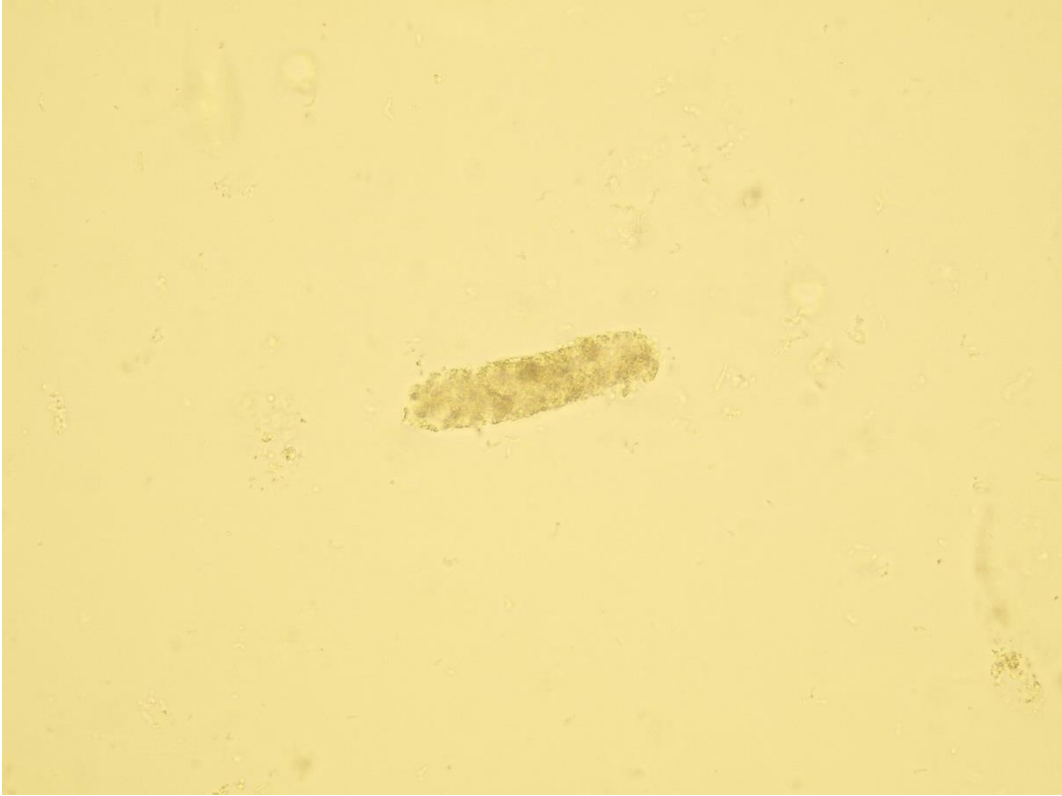


Granular cast

Native sediment

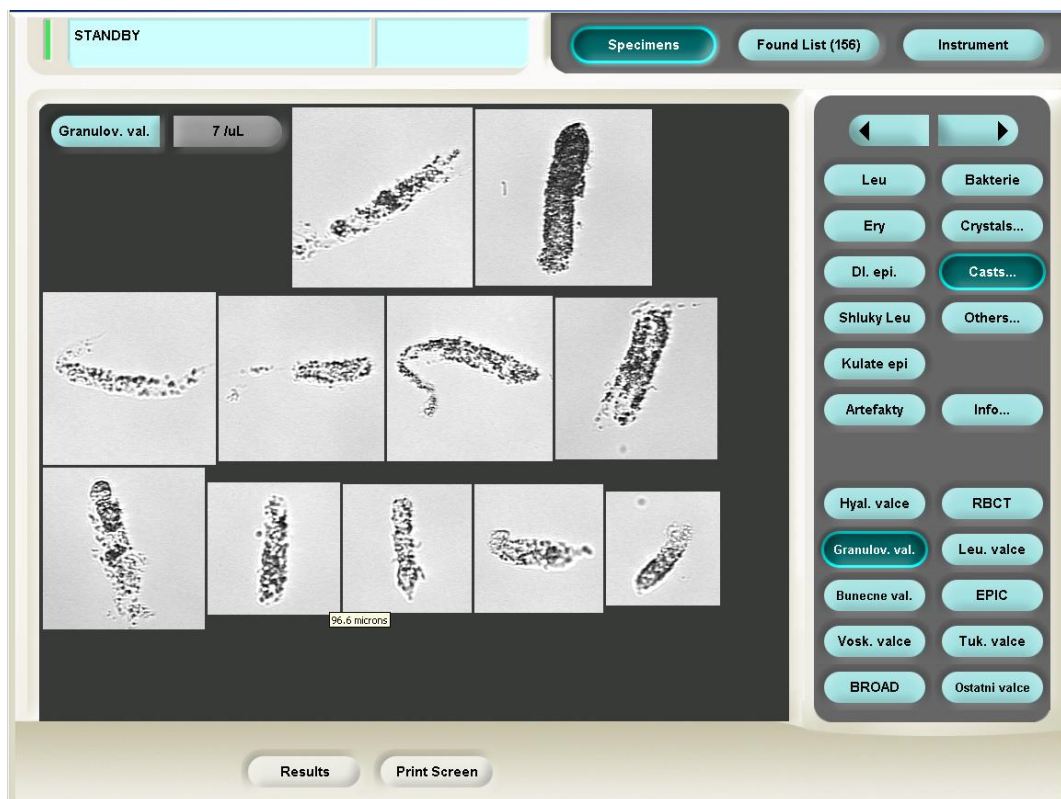


Granular cast

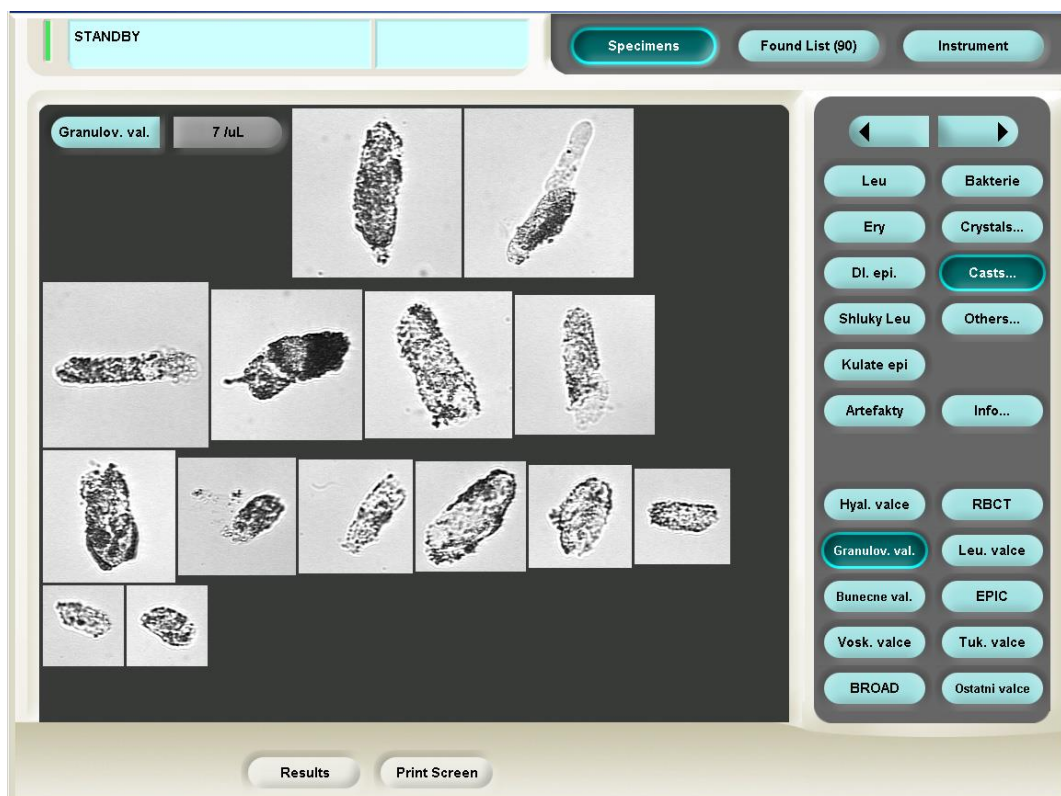


Granular cast

Pictures from iQ 200 analyzer (IRIS)



Granular casts

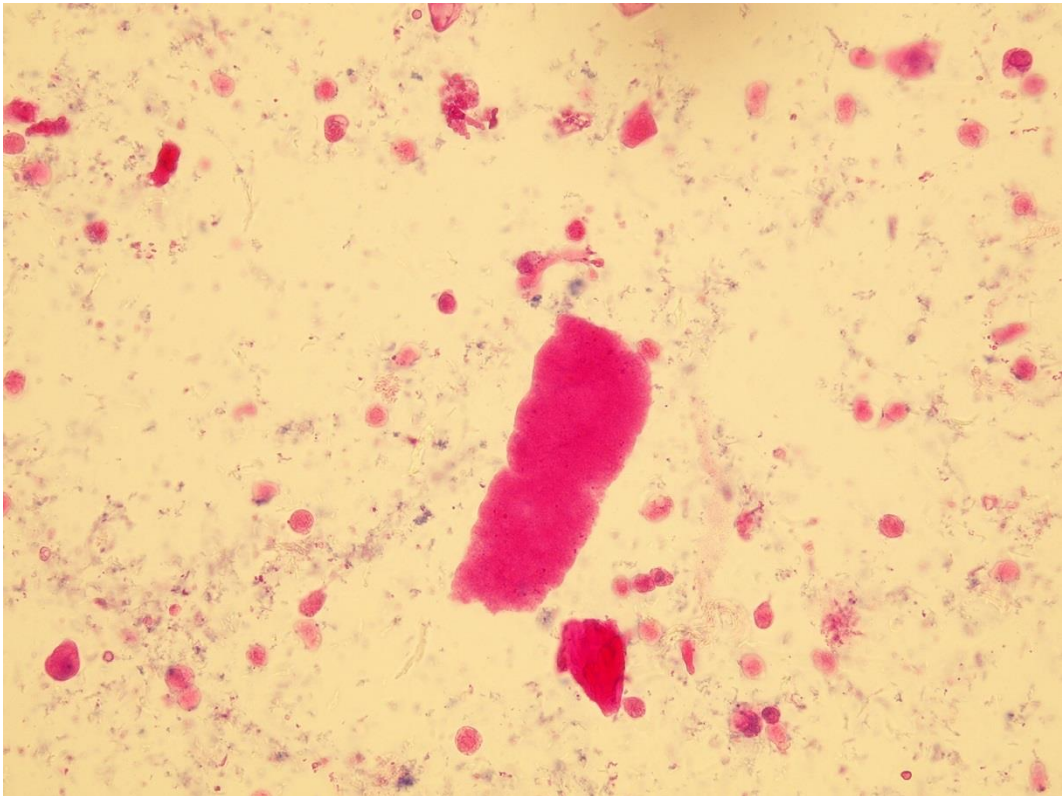


Granular casts

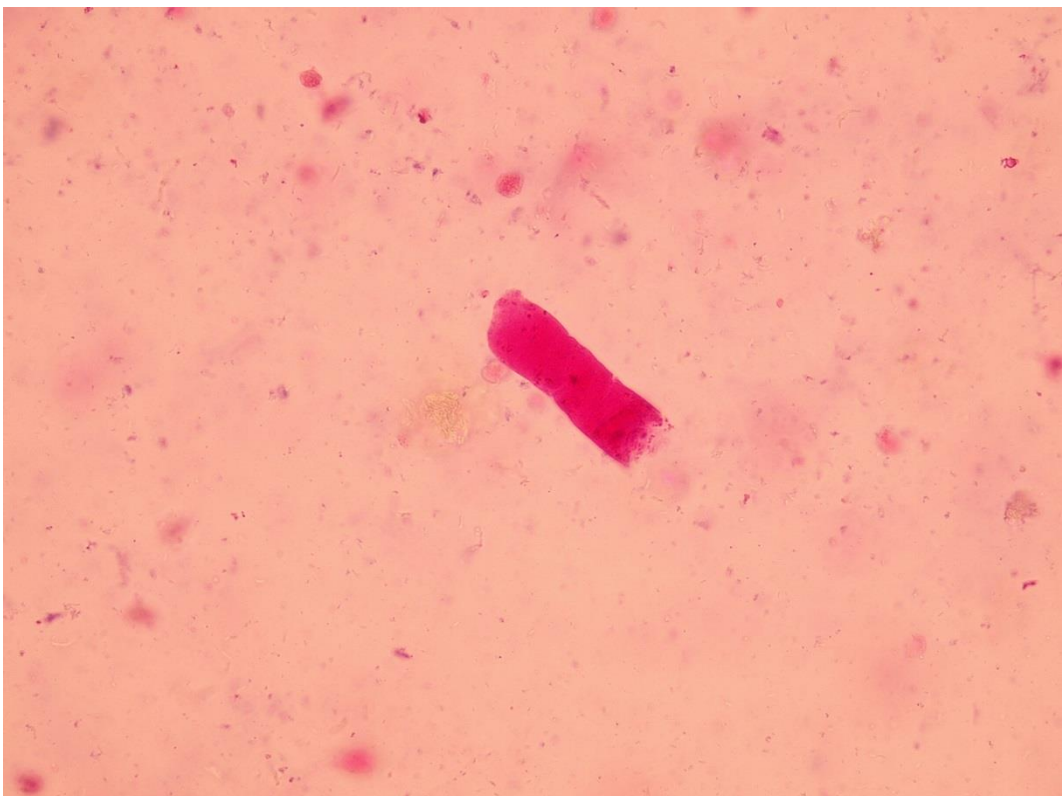
Waxy casts

Waxy casts are the clinically most serious type of casts and they are also called the casts of renal failure. They occur in patients with chronic kidney diseases. Their structure is homogenous, they have the biggest size and their endings are often broken. Sometimes they are partially made of granular matter. They indicate tubule damage.

Stained sediment

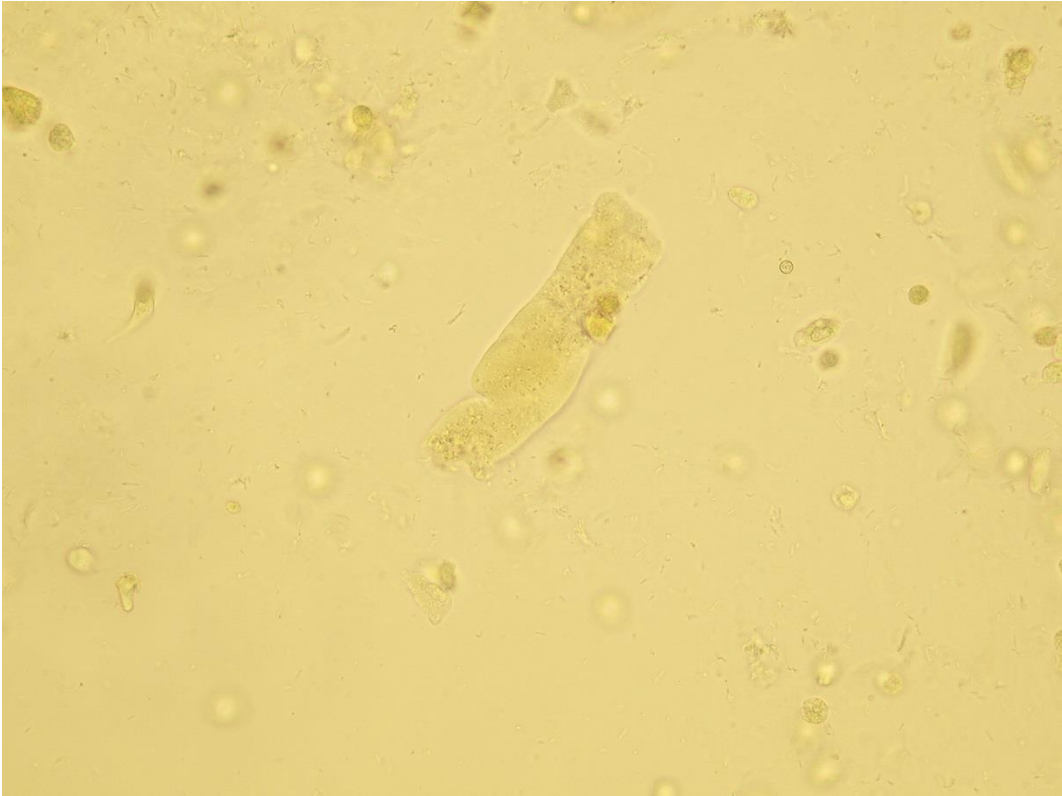

Waxy cast

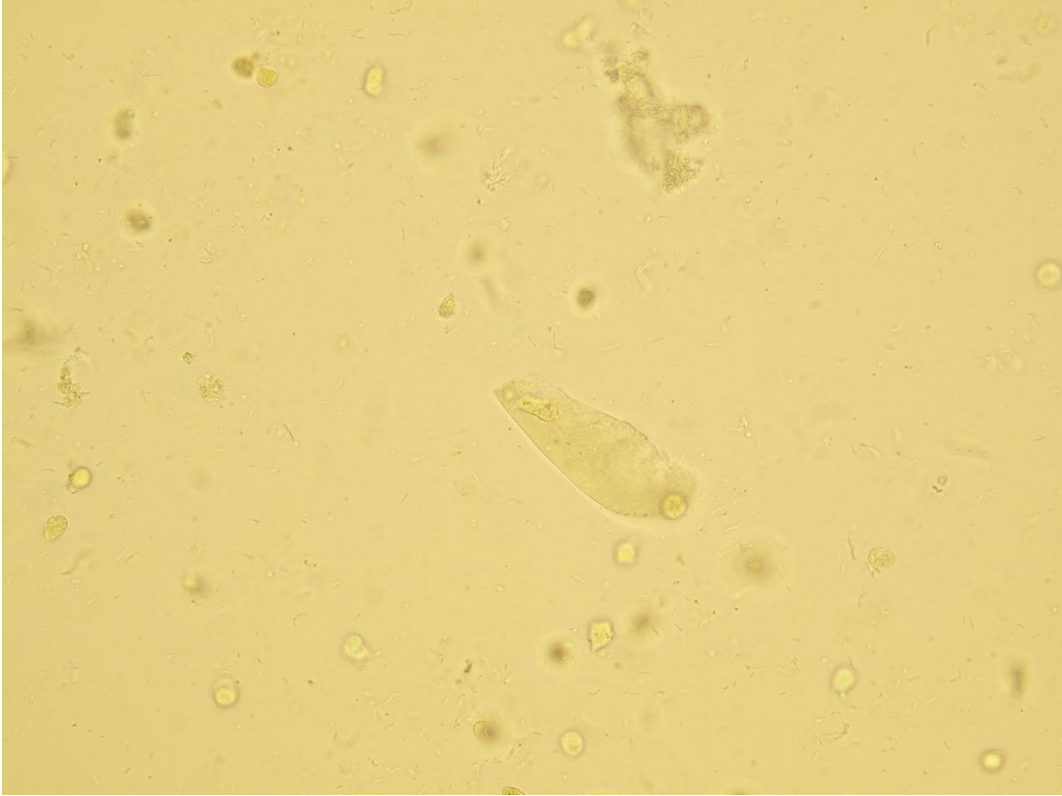

Waxy cast

Native sediment

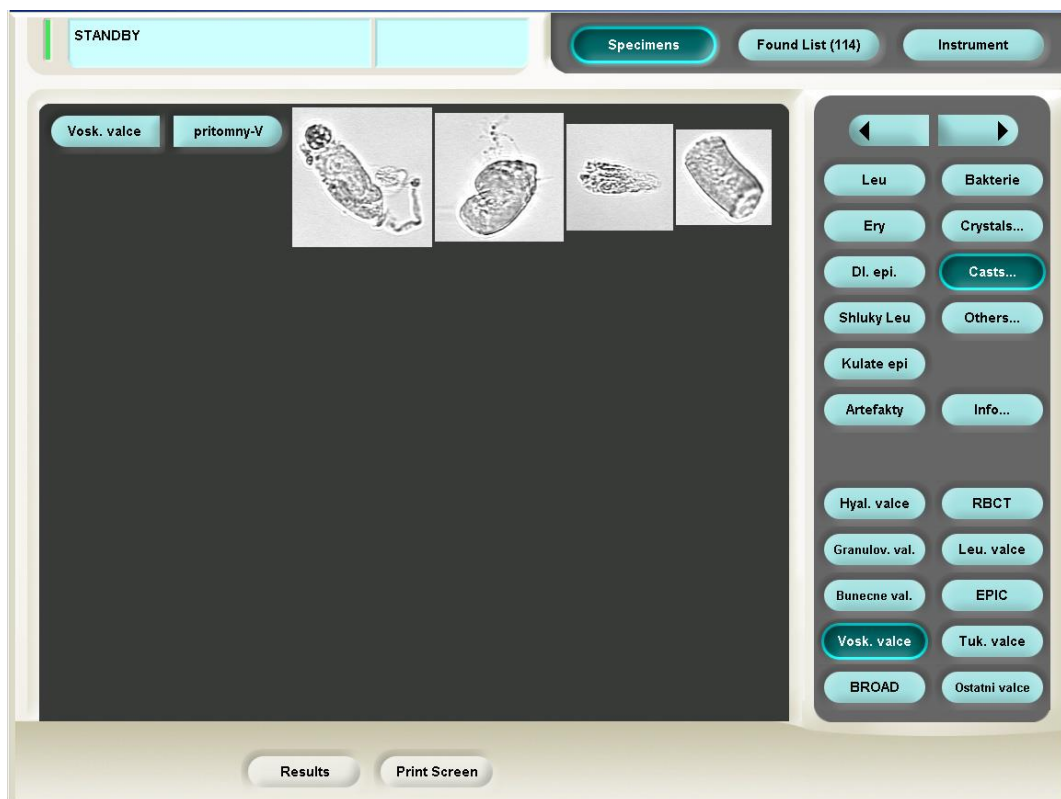


Waxy cast

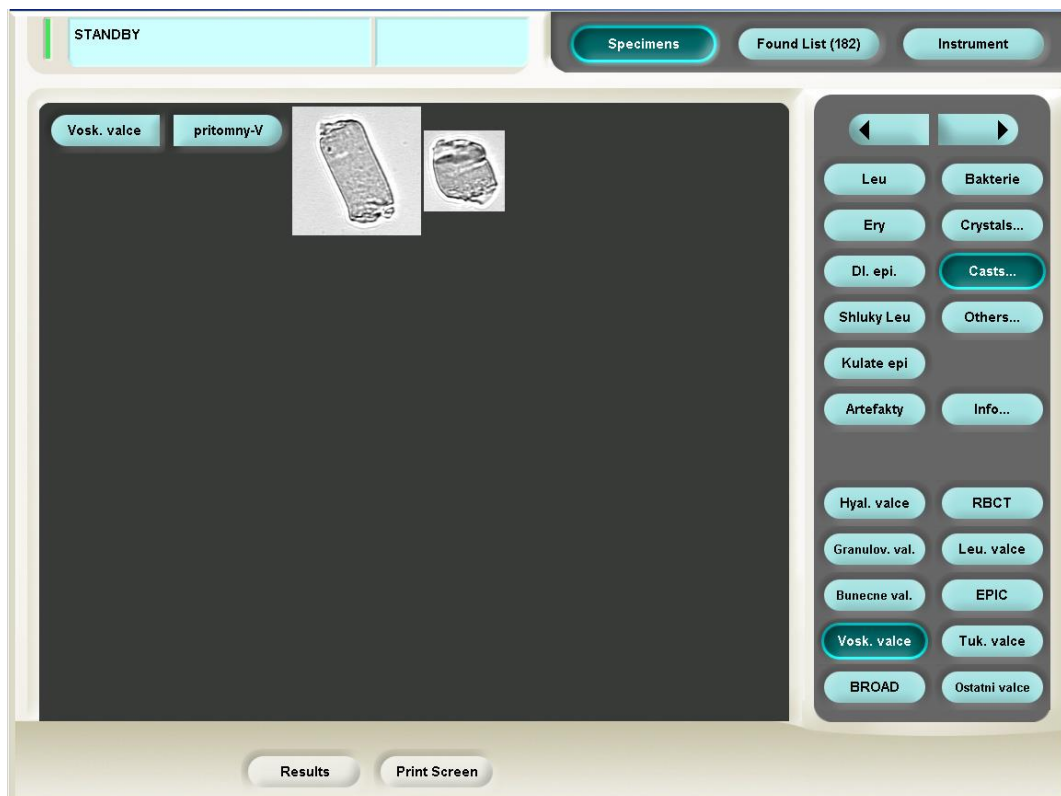


Waxy cast

Pictures from iQ 200 analyzer (IRIS)



Waxy casts

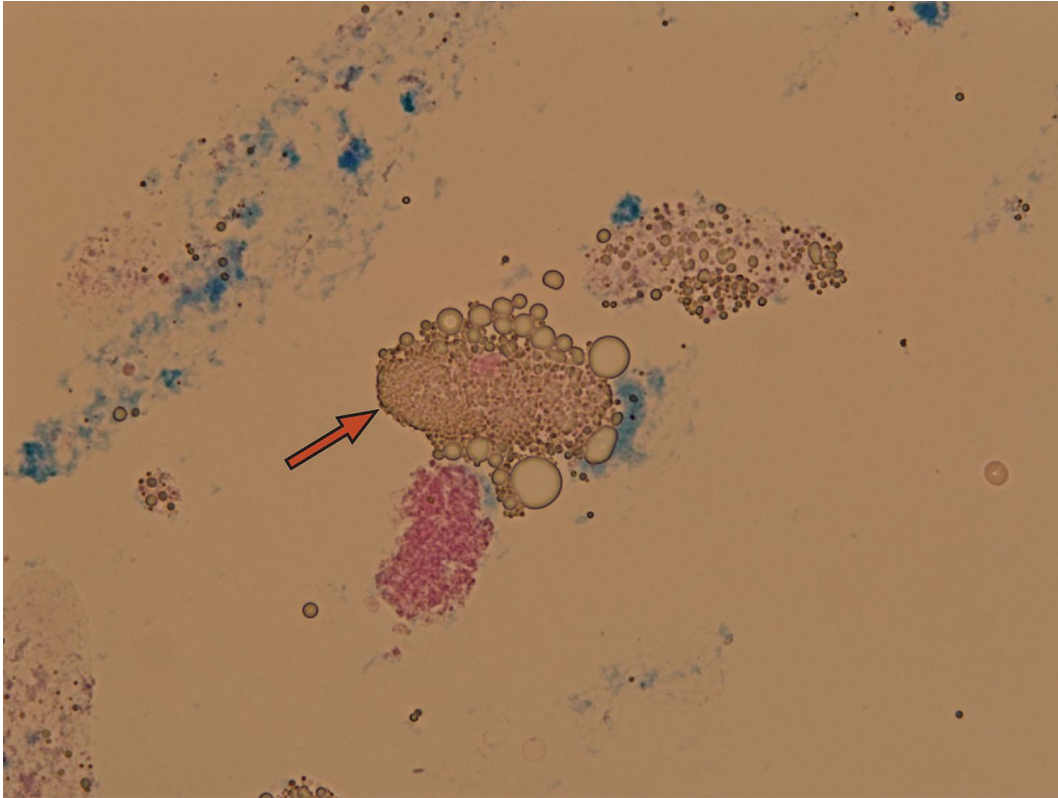


Waxy casts

Fatty casts

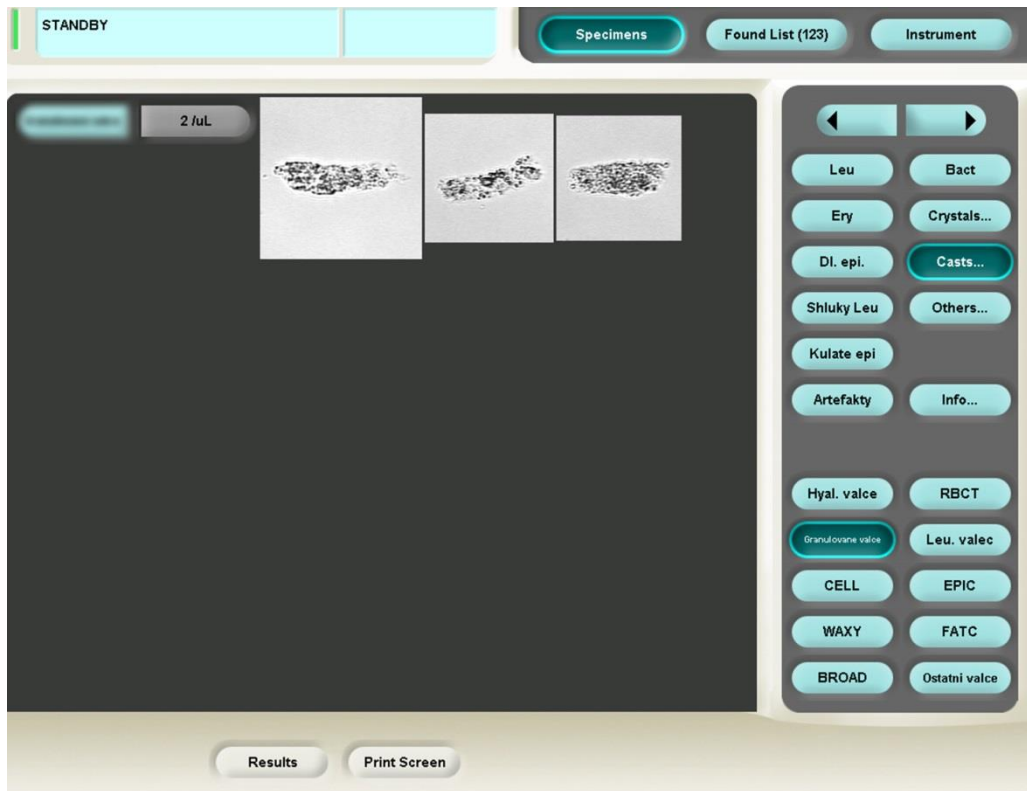
Fatty casts in protein matrix contain fat inclusions. They are related to strong insufficiency, nephritic syndrome, diabetics and mercury intoxication.

Stained sediment



Fatty cast

Pictures from iQ 200 analyzer (IRIS)

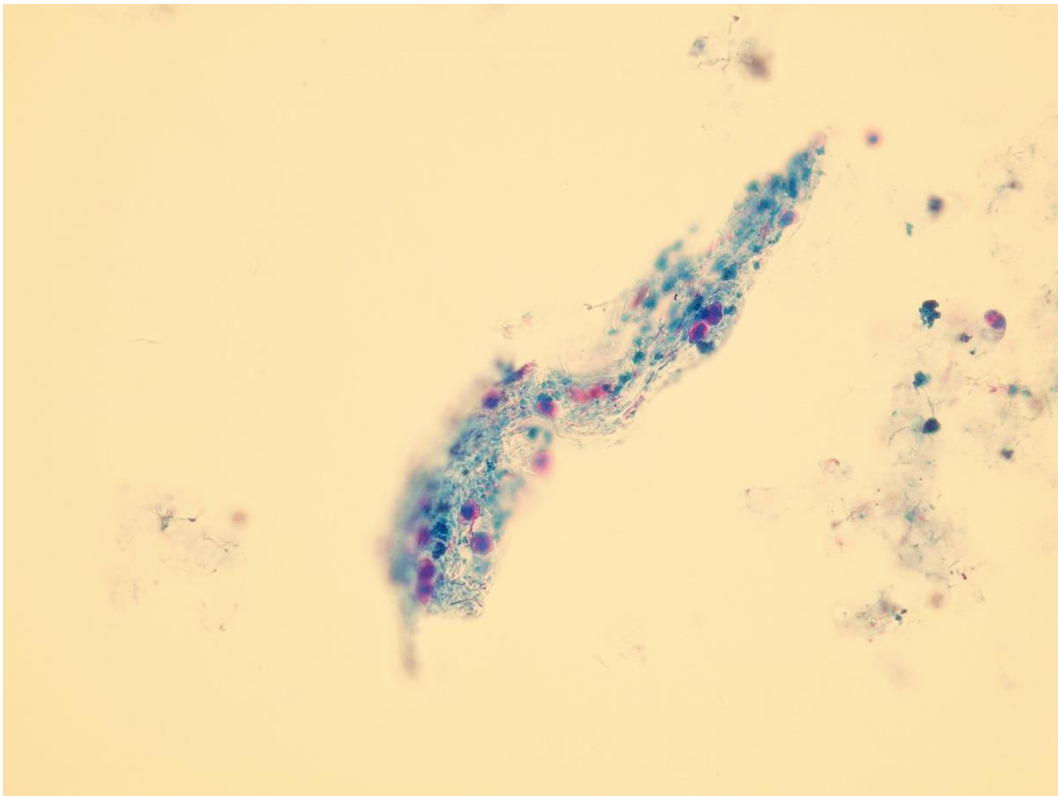


Fatty casts

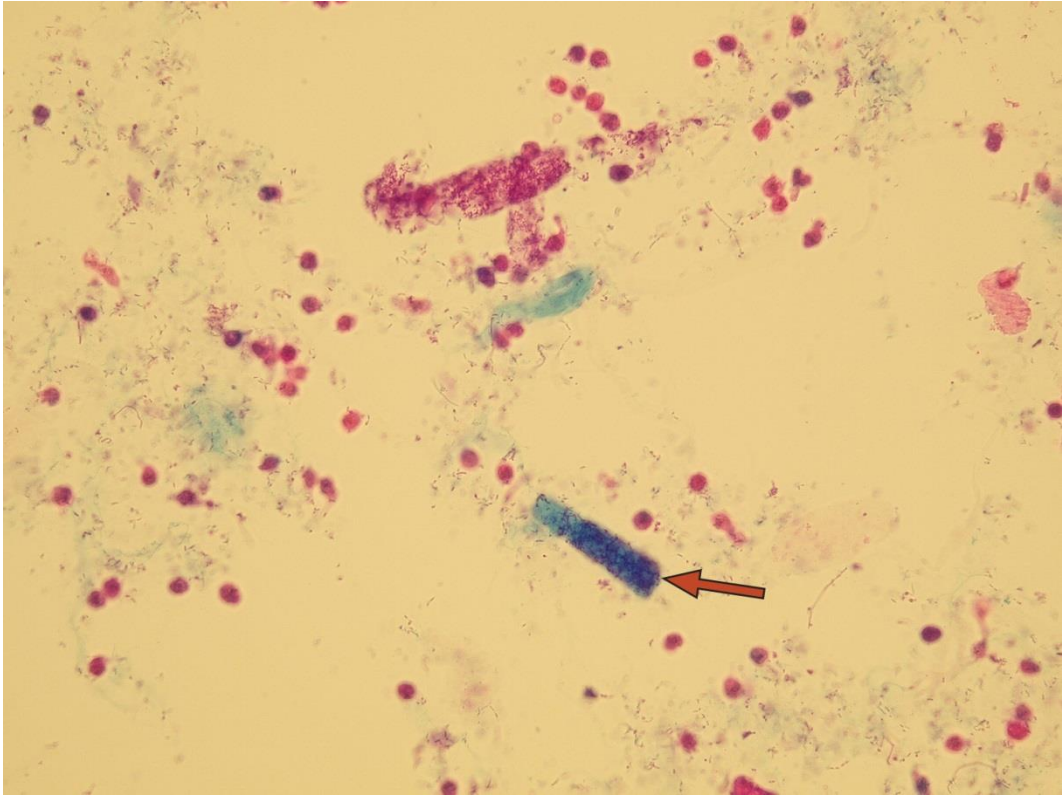
Bacterial casts

Bacterial casts are composed of bacteria in a protein matrix. They may be found in acute pyelonephritis or intrinsic renal infection. Bacterial casts should be seen in association with loose bacteria, leukocytes, and leukocyte casts. Their occurrence is extremely rare, due to their fragility and also commonly used antibiotic treatment.

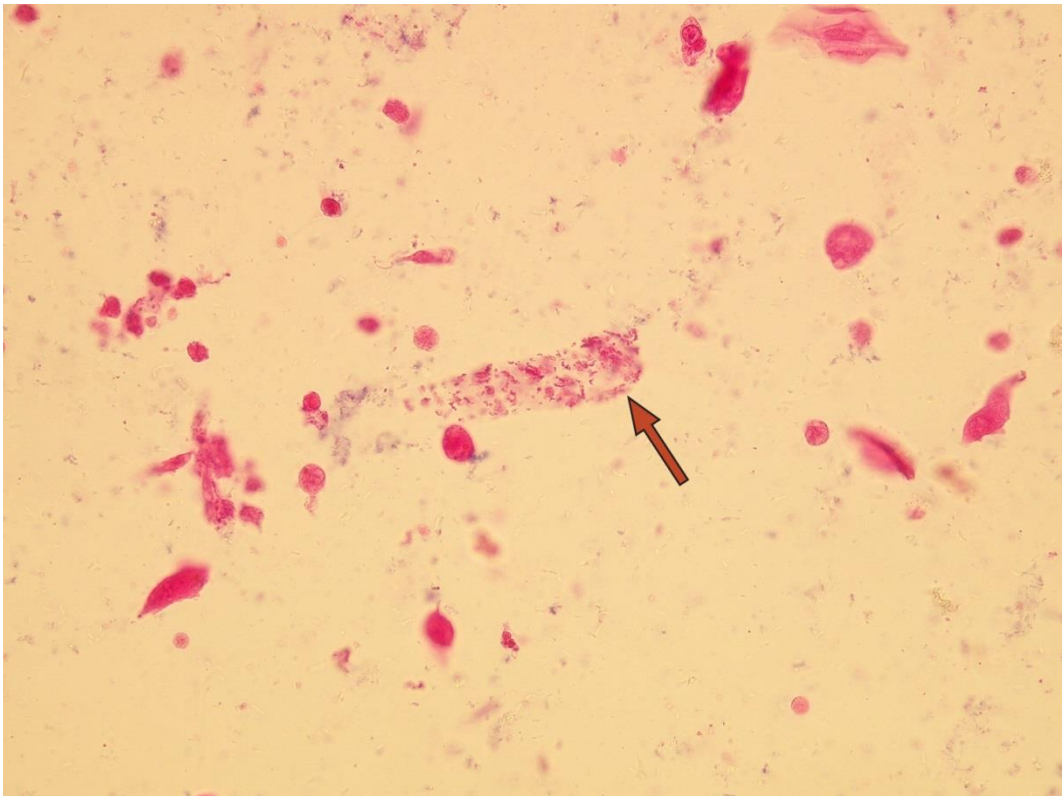
Stained sediment



Bacterial cast

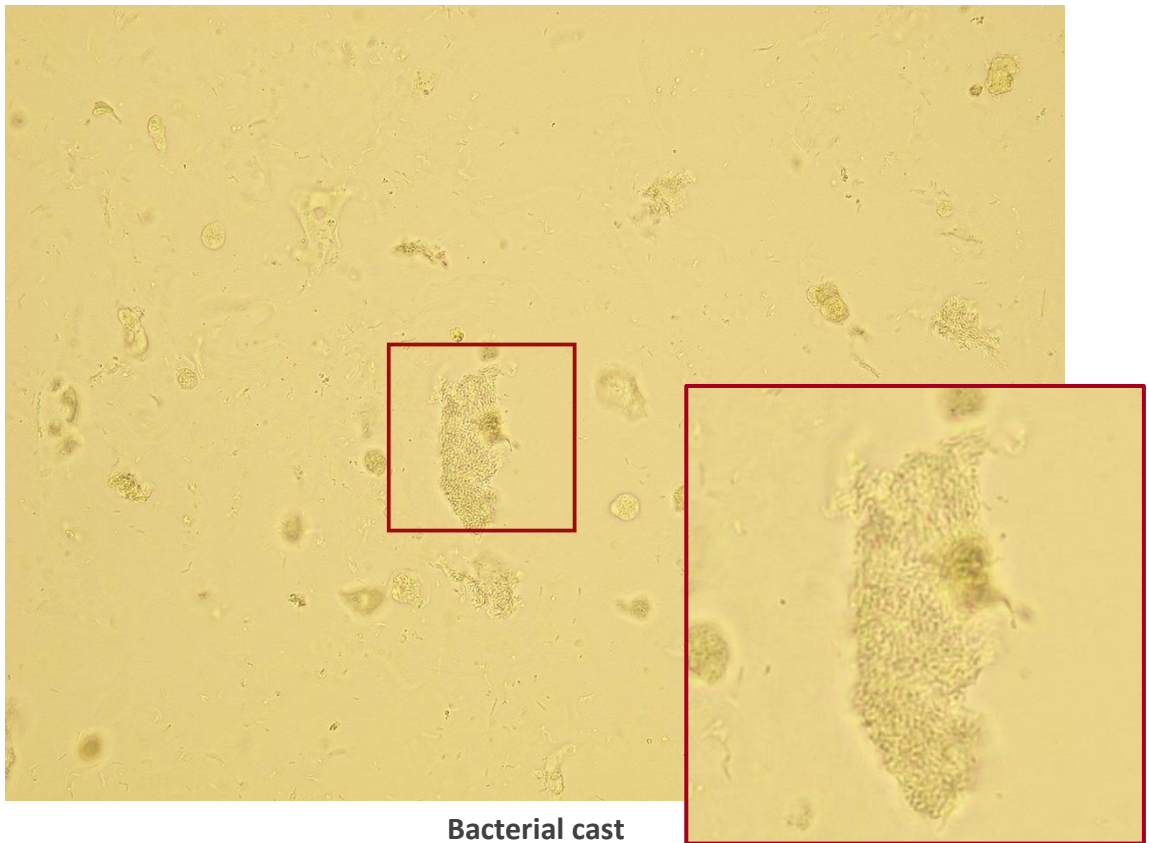


Bacterial cast

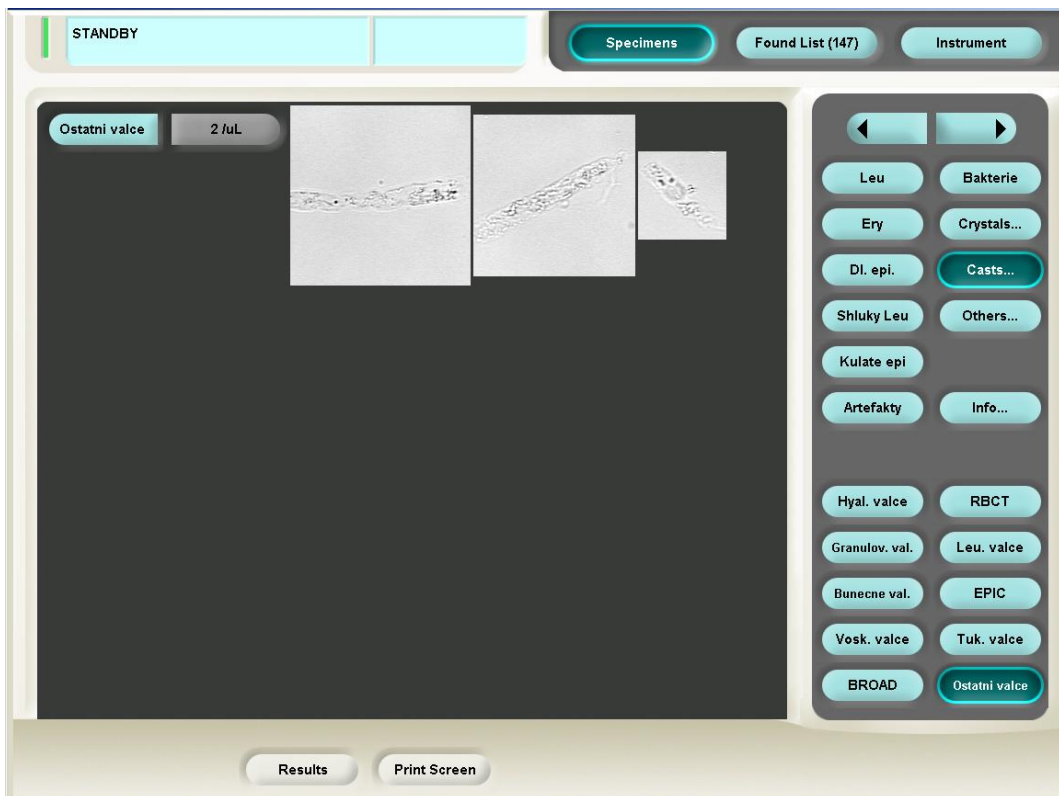


Bacterial cast

Native sediment



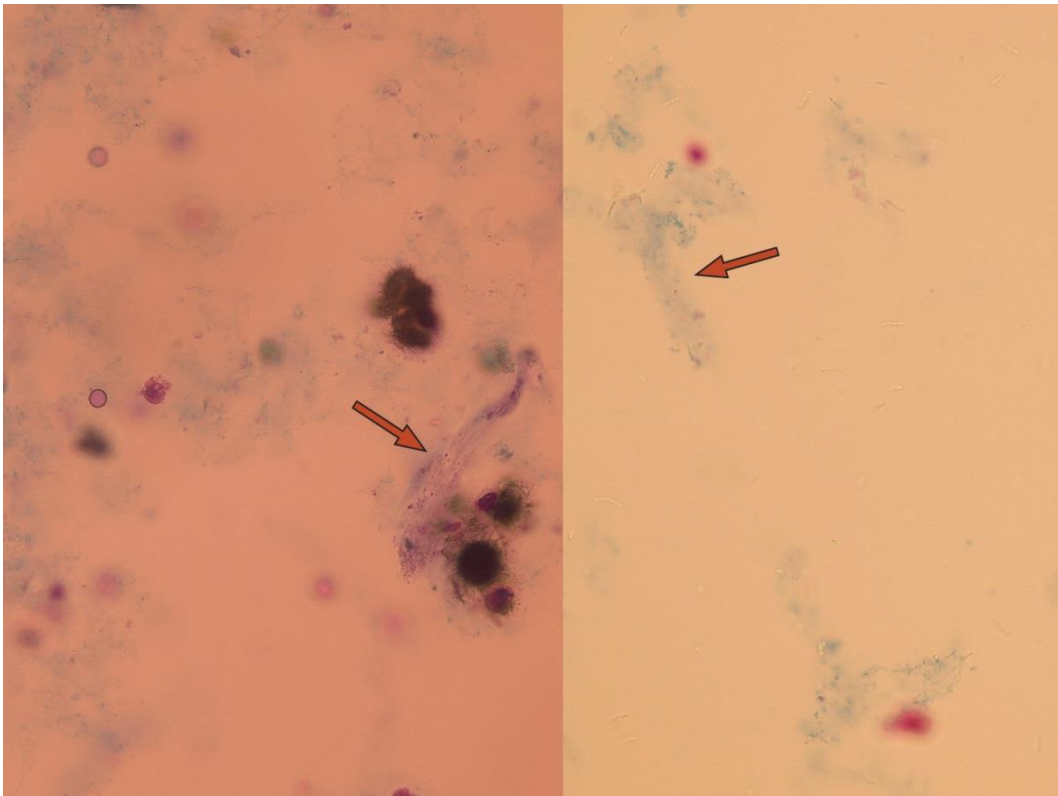
Pictures from iQ 200 analyzer (IRIS)



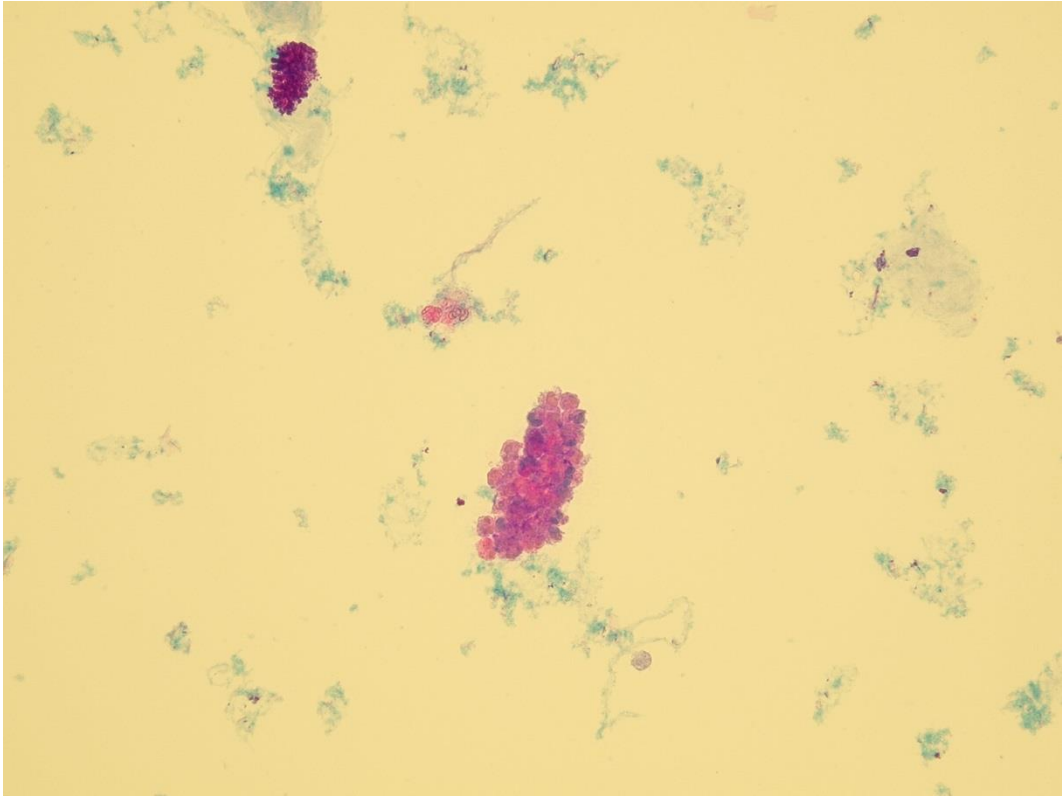
Pseudocasts

Pseudocasts are structures of aggregates that resemble and may be mistaken for casts because of their shape. They are without diagnostic significance. Such structures include mucus threads, leukocytes entrapped in mucus, rolled squamous epithelial cells, aggregates of amorphous urates, calcium oxalate crystals and so on. Artifacts don't belong in this category.

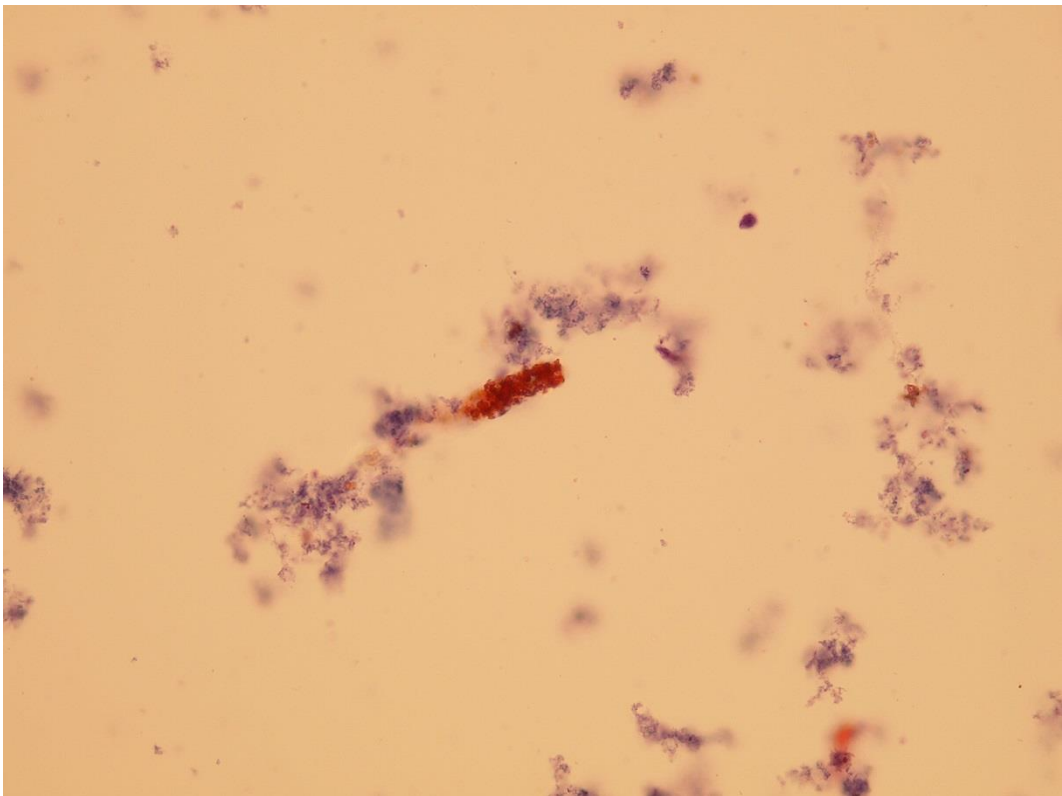
Stained sediment



Pseudocasts – mucus

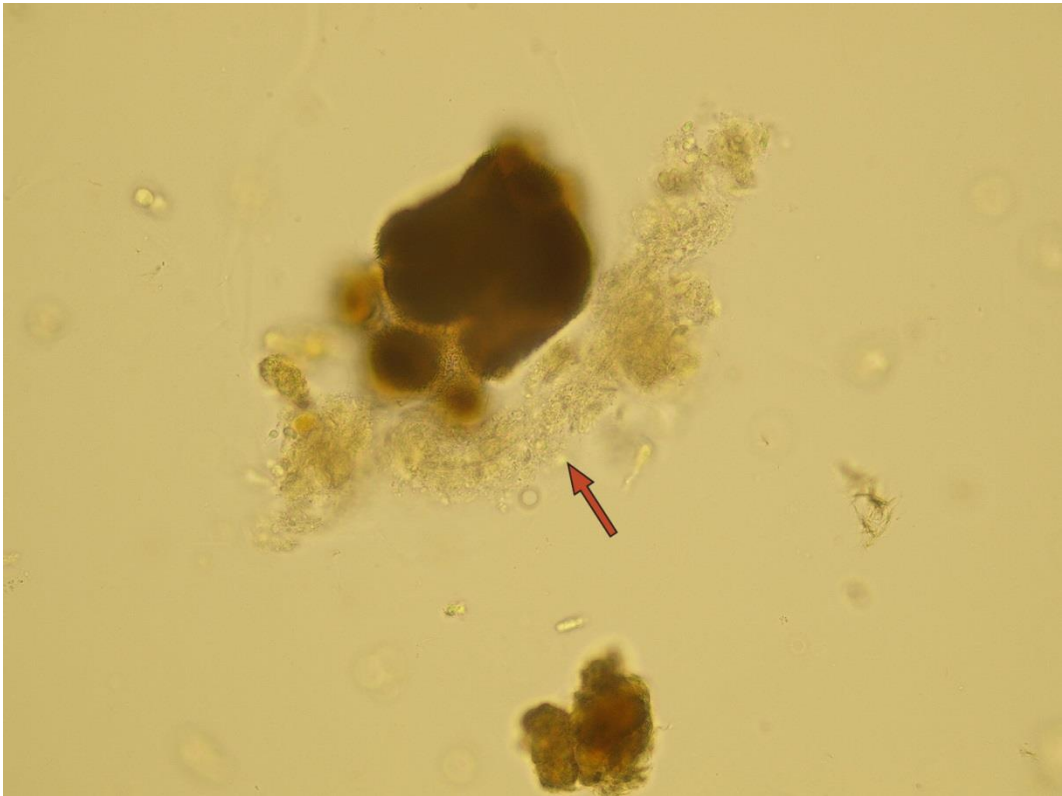


Pseudocasts – group of leukocytes



Pseudocast – bilirubin crystals

Native sediment



Pseudocast – ammonium urate crystals (arrow)

Pictures from iQ 200 analyzer (IRIS)

STANDBY

Specimens Found List (150) Instrument

Artefakty 1/μL

Leu Bakterie
Ery Crystals...
Dl. epi. Casts...
Shluky Leu Others...
Kulate epi
Artefakty Info...

<<Released>>
8404986073
2015-01-22 10:54:46
0/7(540625)
1:1

All Small Particles: 13992/μL

| | | |
|---|------|----------|
| H | GLU | Normal |
| | PRO | ++ |
| | BIL | - |
| | URO | Normal |
| | PH | 5.0 |
| H | Krev | +2 |
| | KET | - |
| | NIT | Negative |
| | LEU | 0 Leu/μl |
| H | CLA | Turbid |
| | SPGR | 1.025 |
| | COL | Yellow |

Results Print Screen

Pseudocasts – mucus

MEASURE 6/3(497108)

Specimens Found List (99) Instrument

Neklasifikovatelne 1420/μL

Leu Bakterie
Ery Crystals...
Dl. epi. Casts...
Shluky Leu Others...
Kulate epi
Artefakty Info...

<<Released>>
8404077228
2014-01-08 07:15:50
0/2(497028)
1:1

All Small Particles: 26014/μL

| | | |
|---|------|------------|
| H | GLU | Normal |
| | PRO | +1 |
| | BIL | - |
| H | URO | +1 |
| H | PH | 8.0 |
| | Krev | - |
| | KET | - |
| | NIT | Negative |
| H | LEU | +2 |
| H | CLA | Ex: Turbid |
| | SPGR | 1.012 |
| | COL | Yellow |

Cleared flags:
HIGH CONCENTRATION
Possible Amorphous

Results Print Screen

Pseudocasts – phosphate microcrystals

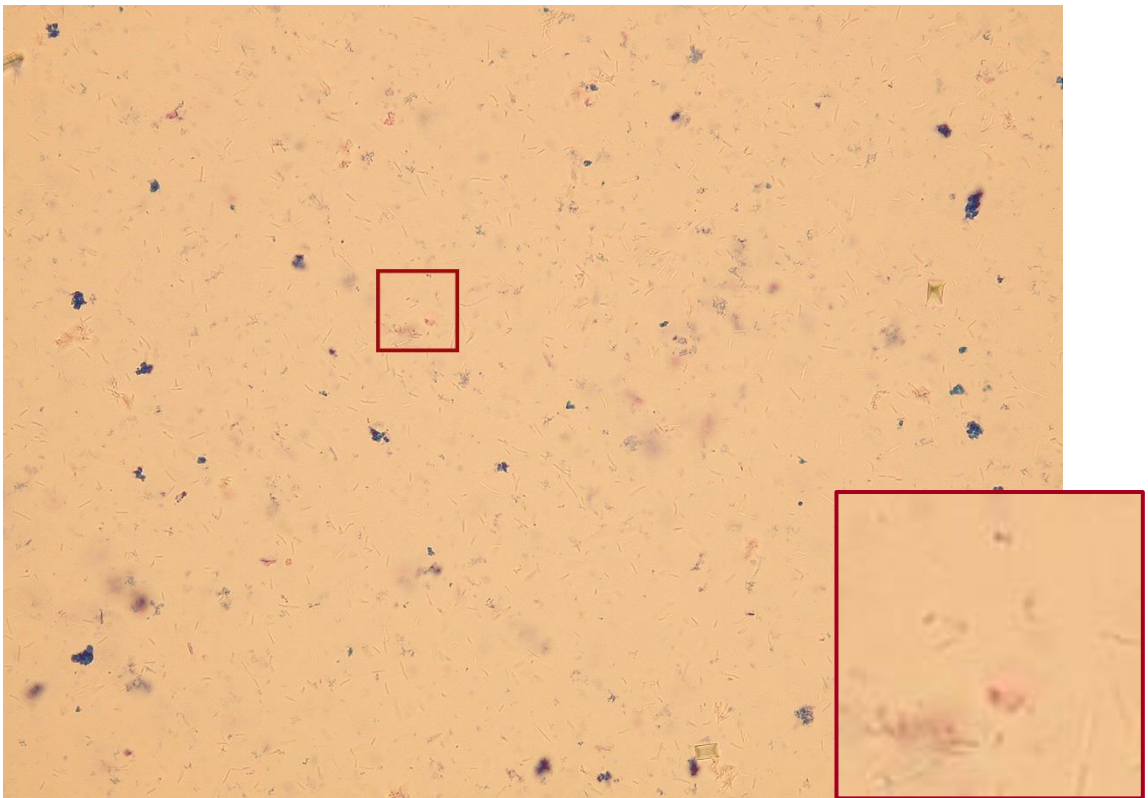
Microorganisms

Bacteria

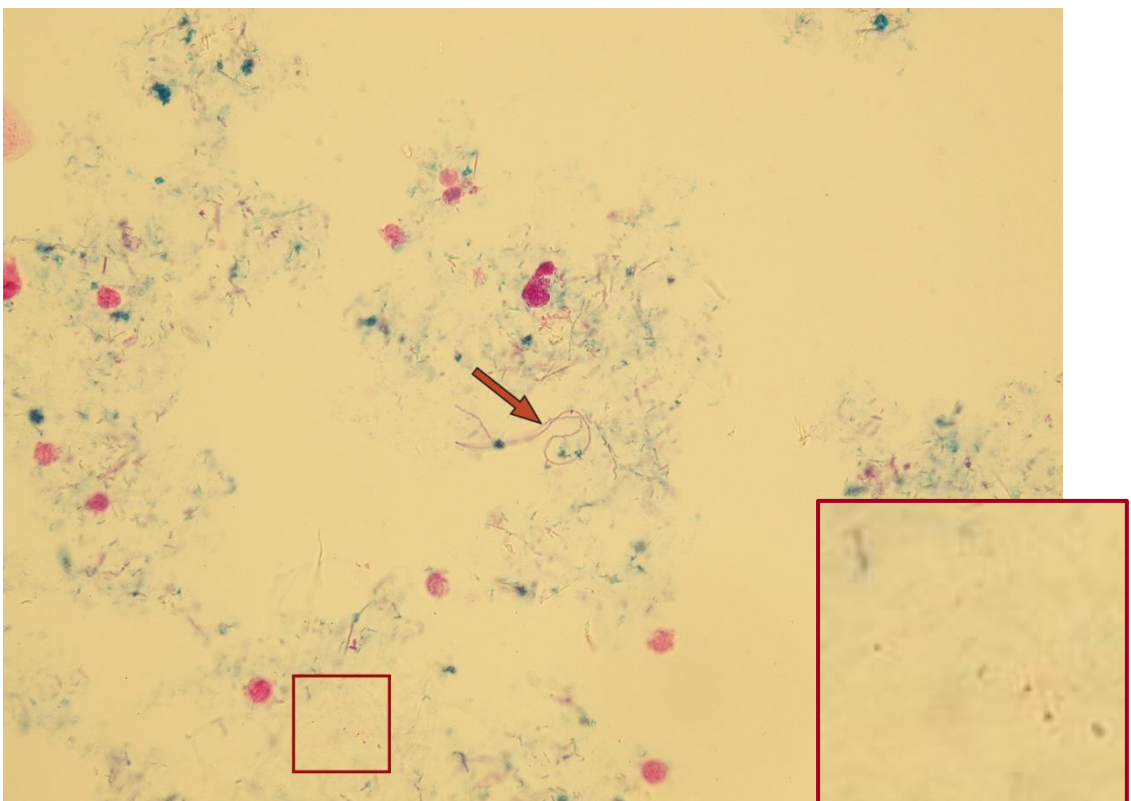
Bacteria are single celled organisms. They have shapes of spheres (cocci) or rods and usually reach size of a few micrometers.

Small amount of bacteria in urine is quite common finding. Urine should be analyzed within one hour, otherwise the bacteria multiply. They tend to form chains or occur as longer fibers. Antibiotic treatment may cause bacteria cell wall disintegration producing unusually long rod-shaped elements called bacteria protoplasts. Larger quantities of bacteria can often be found in pathological urine with leukocytes.

Stained sediment

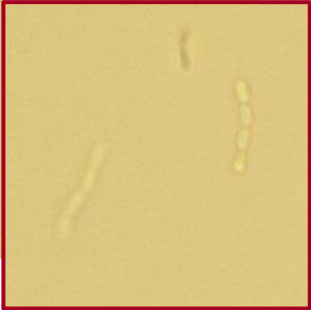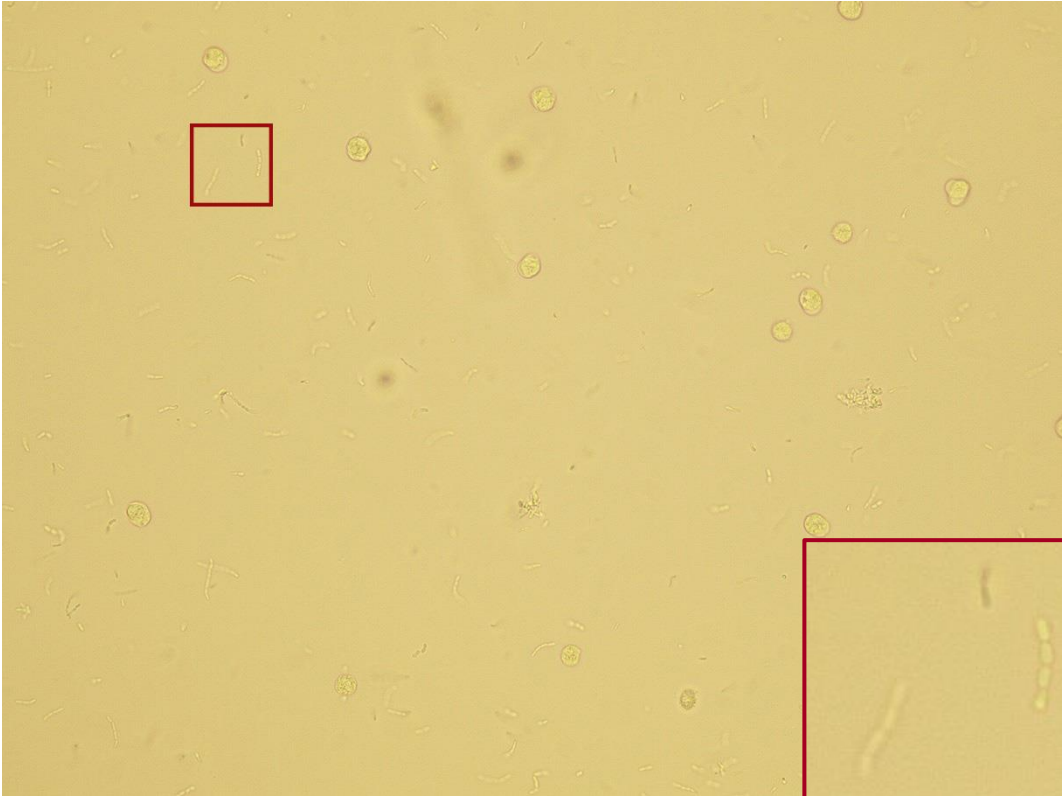


Rod-shaped bacteria that remained unstained after dyeing

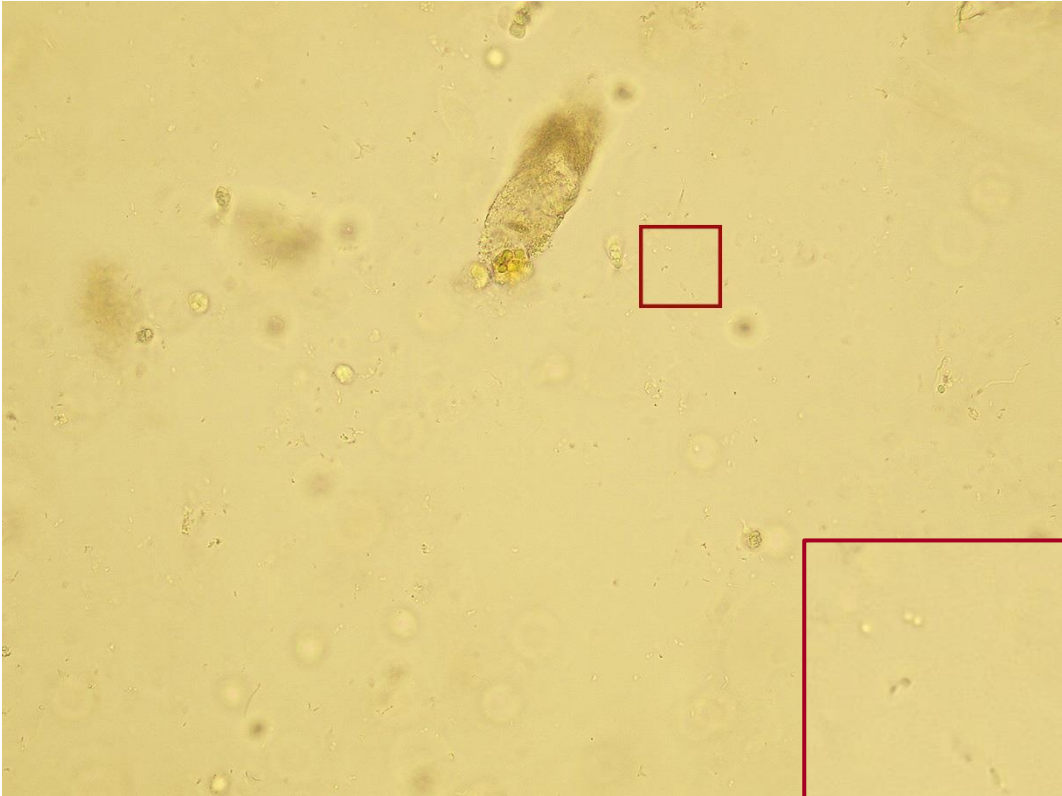


Cocci (detail) and protoplast bacteria (arrow) – stained after dyeing


Native sediment



Chained bacteria – cocci



Bacteria – cocci



Bacteria – rods

Pictures from iQ 200 analyzer (IRIS)

STANDBY Specimens Found List (179) Instrument

Bakterie zaplava-B

Leu **Bakterie**
Ery Crystals...
Dl. epi. Casts...
Shluky Leu Others...
Kulate epi
Artefakty **Info...**

<<Released>>
8404075849
2014-01-07 08:11:36
0/4(496853)
1:1

All Small Particles: 10074/uL

| | | |
|---|------|--------|
| H | GLU | Normal |
| | PRO | +- |
| | BIL | - |
| | URO | Normal |
| | PH | 5.0 |
| | Krev | - |
| | KET | - |
| H | NIT | +2 |
| H | LEU | +3 |
| H | CLA | Turbid |
| | SPGR | 1.013 |
| | COL | Yellow |

Results Print Screen

Bacteria

STANDBY Specimens Found List (147) Instrument

Neklasifikovane 420 /uL

Leu **Bakterie**
Ery Crystals...
Dl. epi. Casts...
Shluky Leu Others...
Kulate epi
Artefakty **Info...**

<<Released>>
8404134877
2014-01-30 09:21:49
1/8(499795)
1:1

All Small Particles: 18547/uL

| | | |
|---|------|----------|
| H | GLU | +3 |
| H | PRO | +- |
| | BIL | - |
| | URO | Normal |
| | PH | 5.0 |
| | Krev | - |
| | KET | - |
| | NIT | Negative |
| H | LEU | +4 |
| H | CLA | Turbid |
| | SPGR | 1.028 |
| | COL | Yellow |

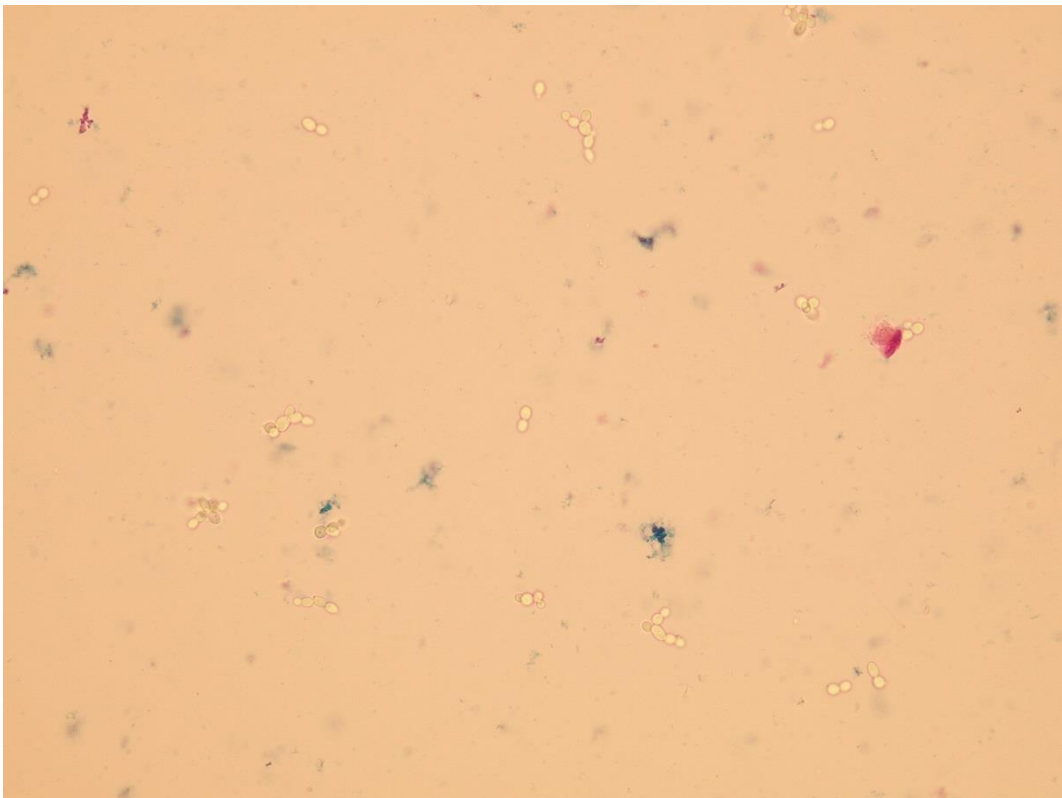
Results Print Screen

Fibers of bacteria; single cocci around

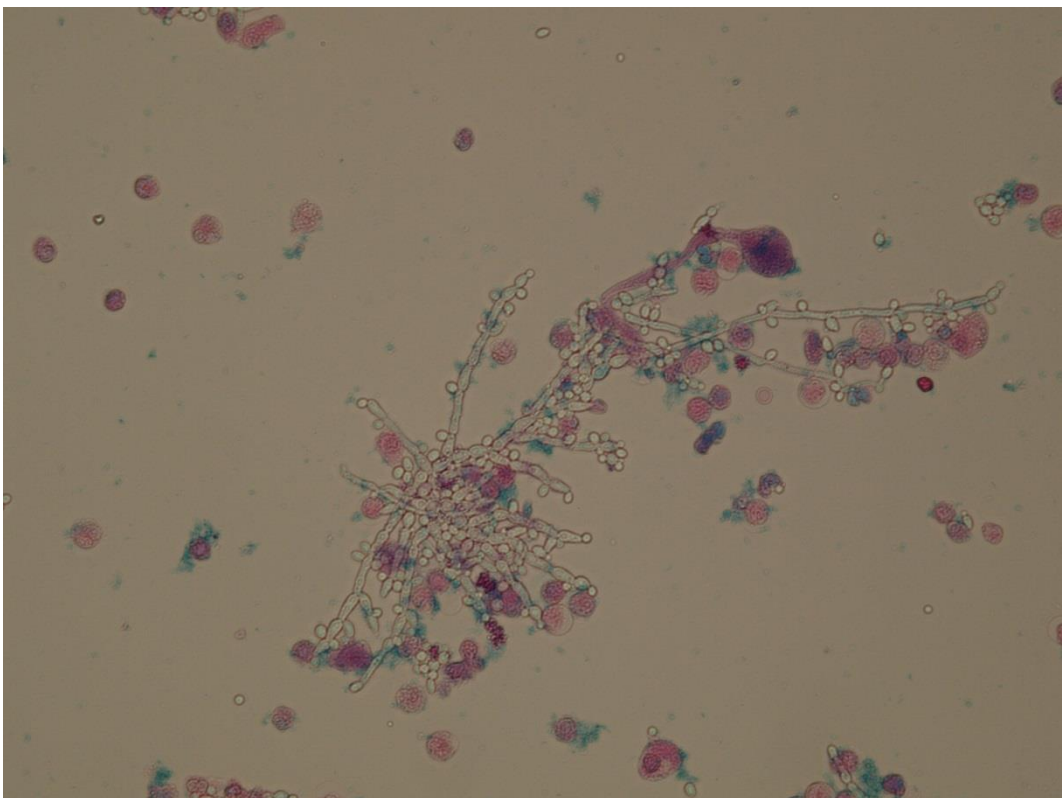
Yeasts

Yeasts are quite common pathological finding. They are unicellular microorganisms with typical round or oval shape. They multiply by budding and in some cases they form pseudomycelium (fibrous form of yeast). They may occur in urine of immunodeficient or immunosuppressed patients and may also be present in urine of diabetics, because glucose contributes to their growth. The most common species in urine is *Candida albicans*.

Stained sediment

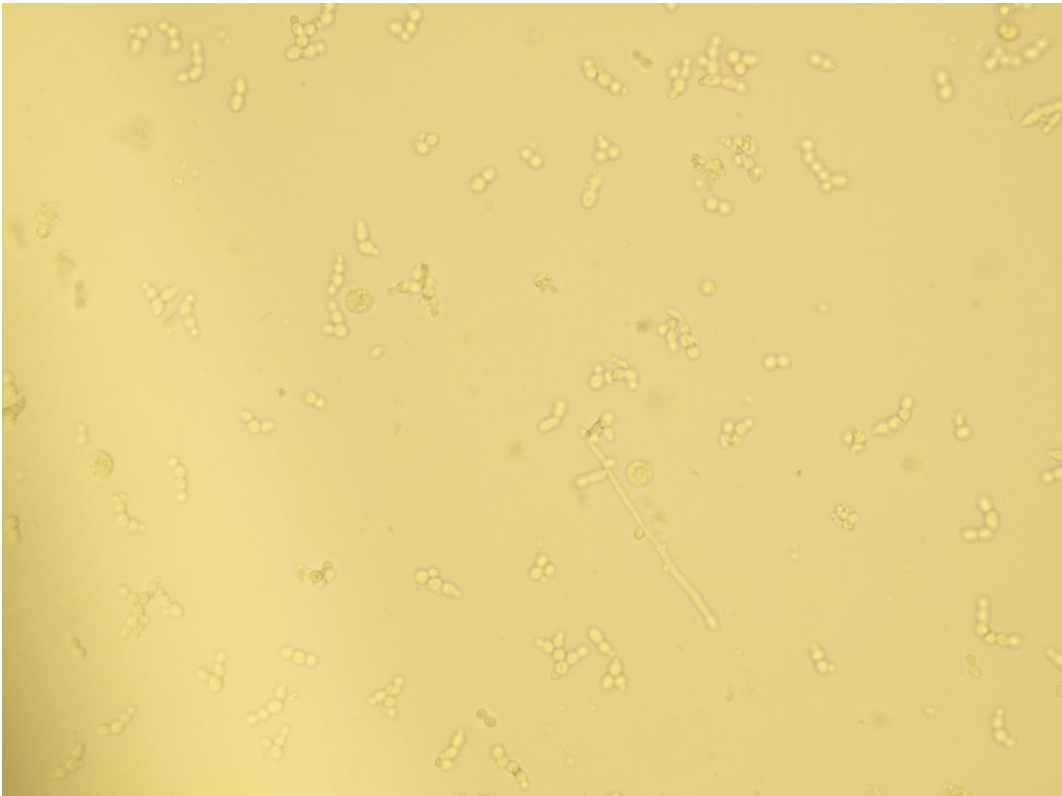


Yeast

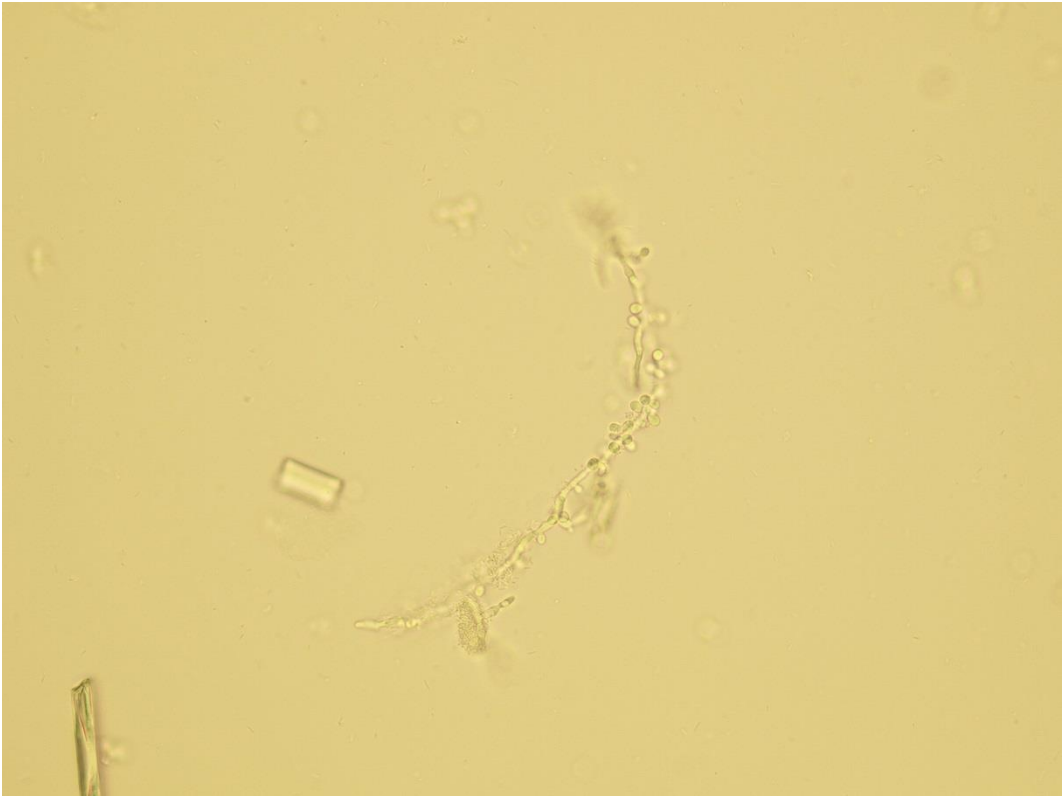


Yeast pseudomycelium

Native sediment

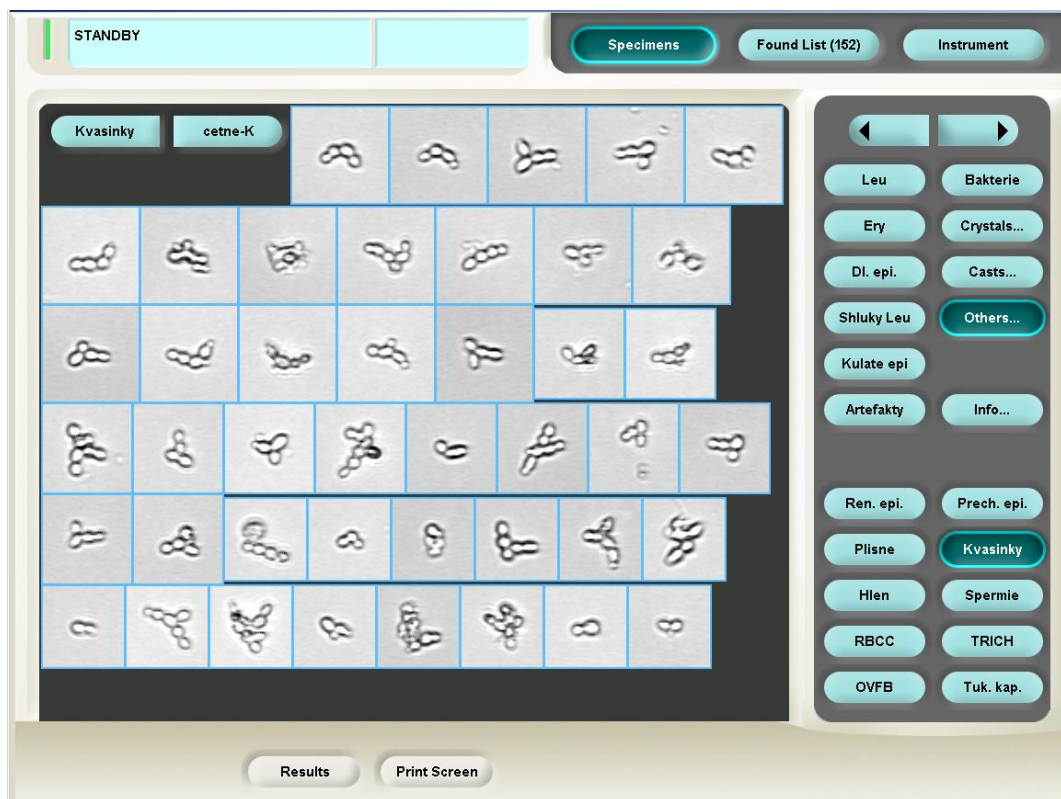


Yeast

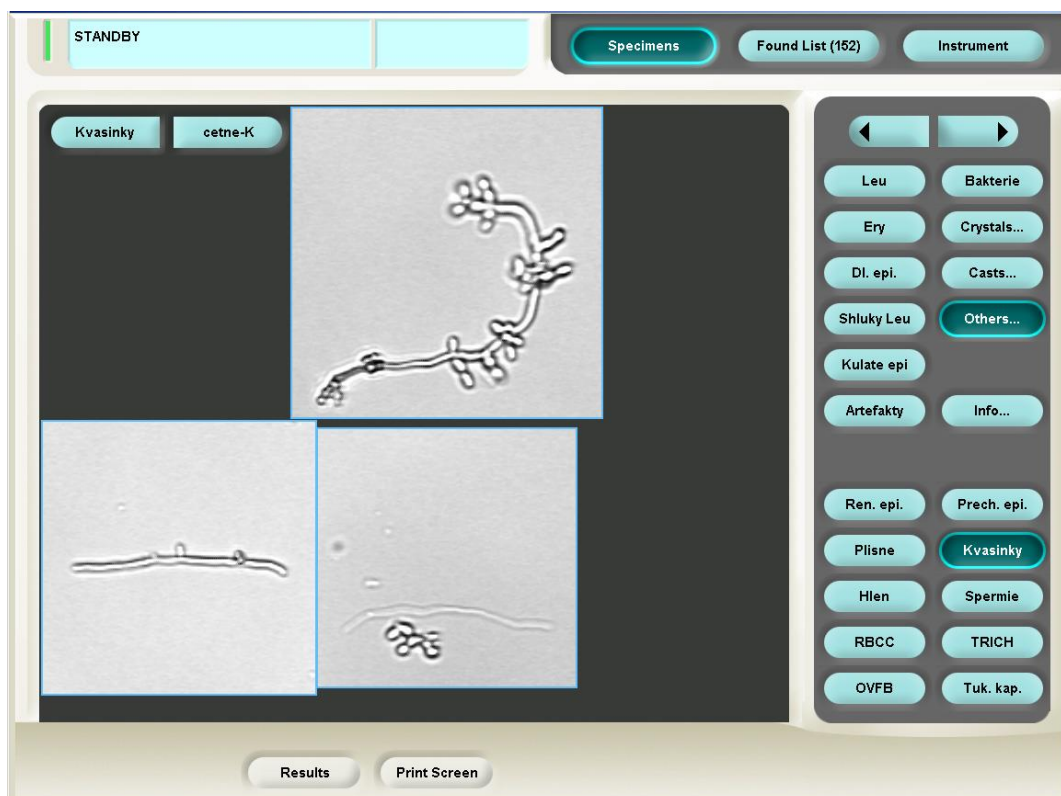


Yeast pseudomycelium

Pictures from iQ 200 analyzer (IRIS)



Yeast



Yeast pseudomycelium

Crystals

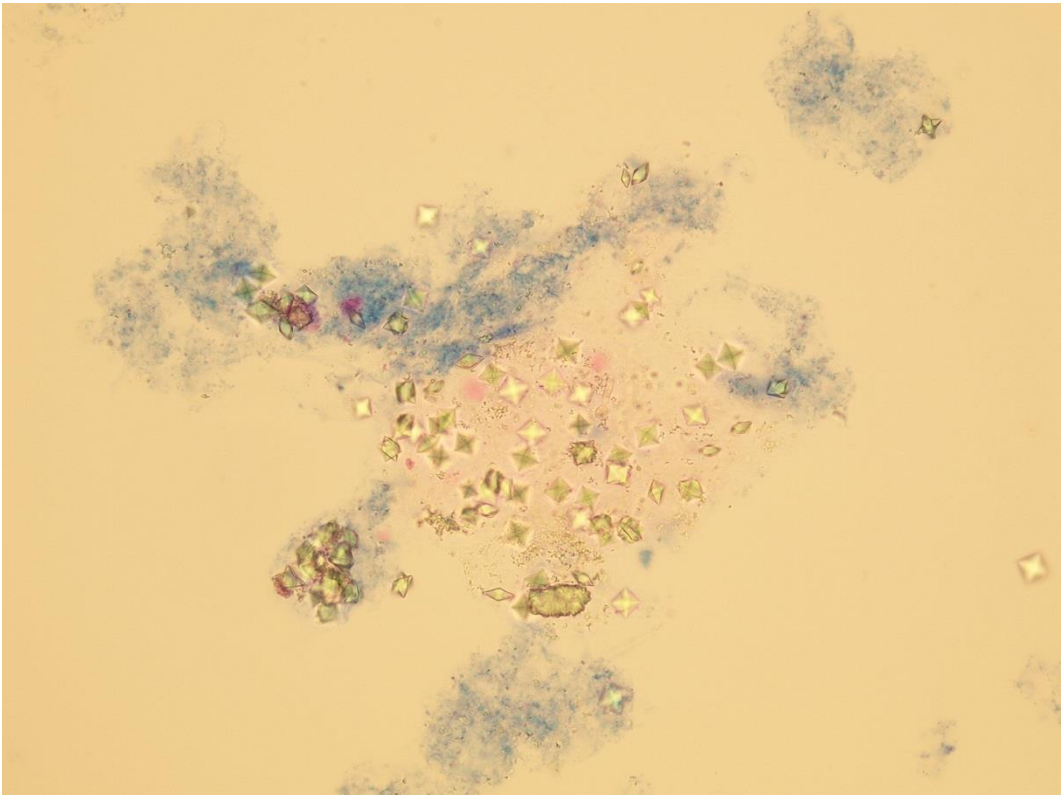
The presence of crystals and amorphous microcrystalline deposits in urine is not considered a significant clinical finding. However, both parameters are determined and their amount is evaluated.

Crystals have various crystalline structure and they occur in many forms. The pH of urine is important factor for their formation and structure, although it is sometimes difficult to distinguish them even then. In that case, the elements could be classified only as crystals - without further specification.

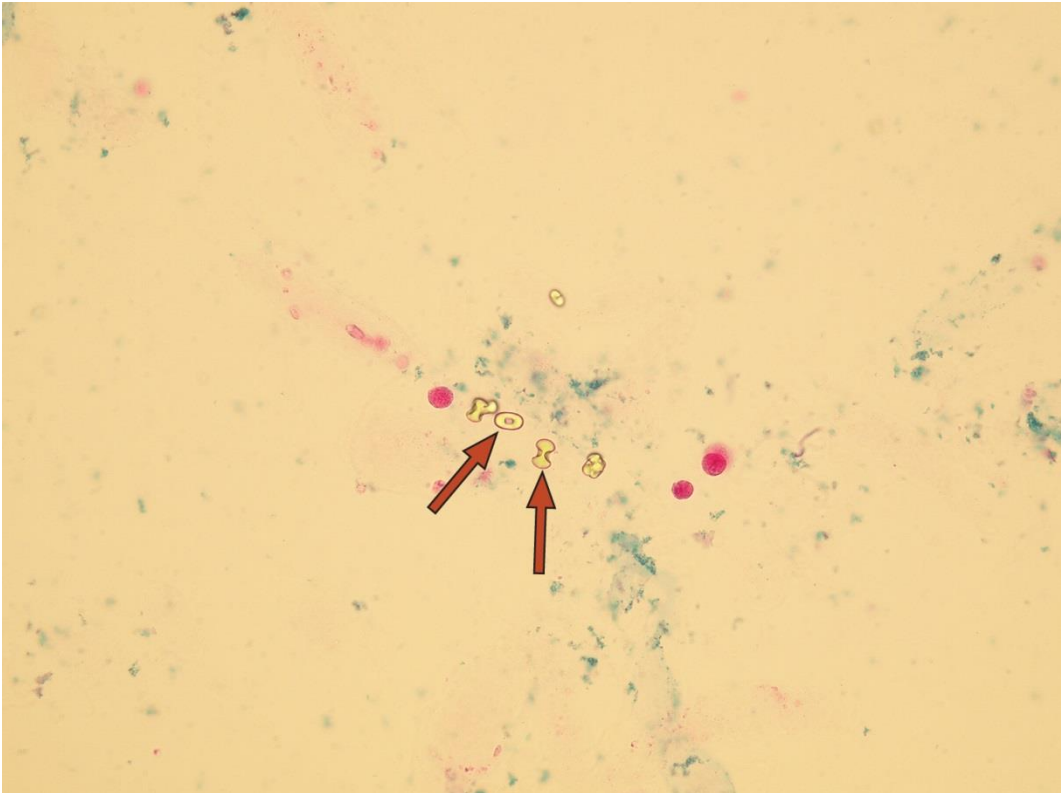
The most frequent crystals in urine are: oxalate and uric acid (in acidic urine) or phosphate (in alkaline urine). Rarely found crystals in urine: bilirubin, cysteine, leucine, tyrosine or drug. We distinguish two types of amorphous microcrystals – amorphous urates in acidic urine and amorphous phosphates in alkaline urine.

Oxalates

Stained sediment




Calcium oxalate dihydrate (envelope-shaped)

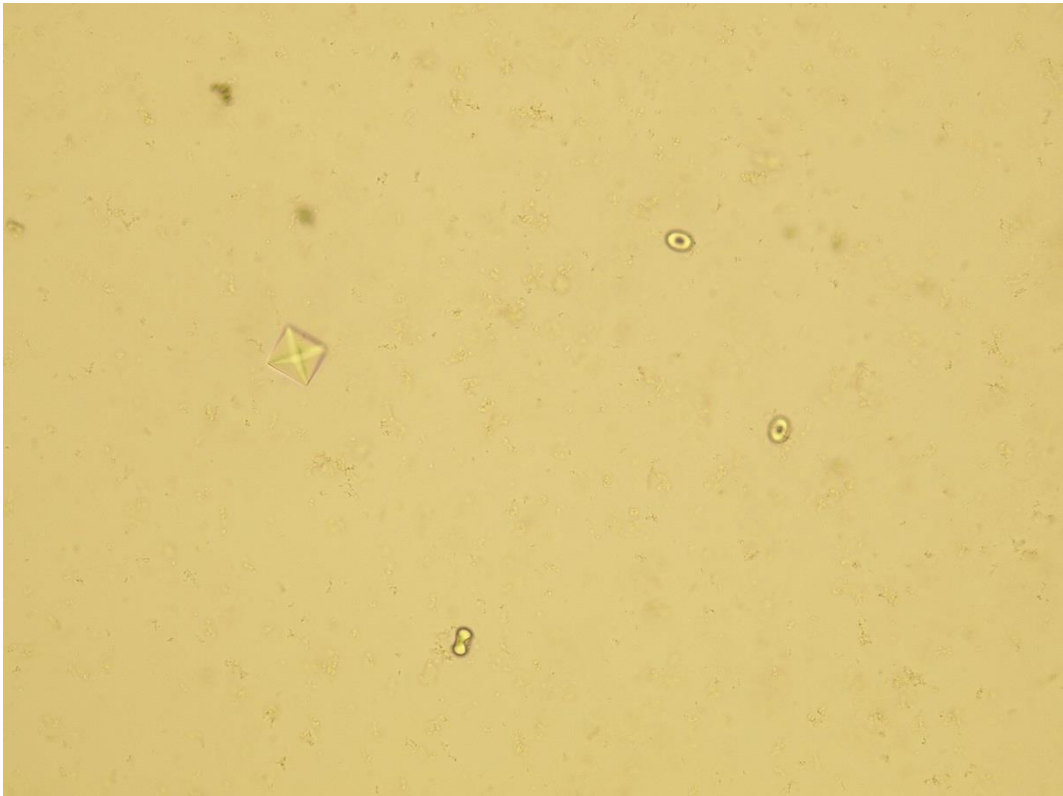


Calcium oxalate monohydrate (oval and biscuit-shaped)

Native sediment

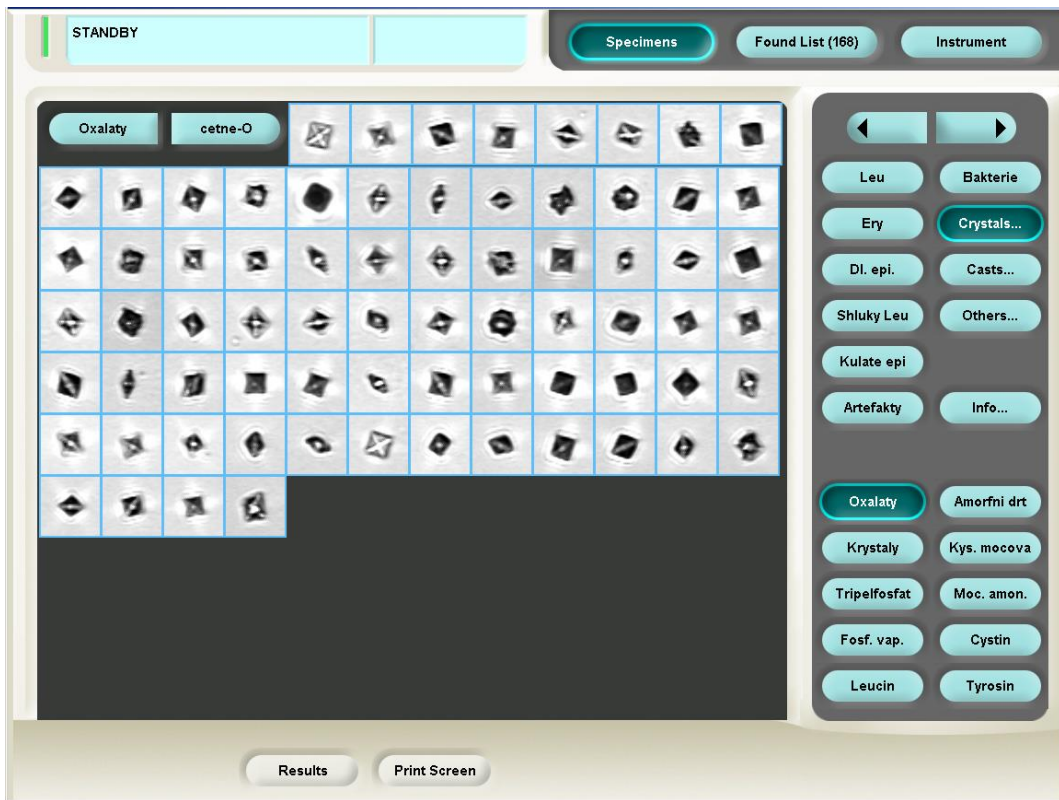


Calcium oxalate – monohydrate (oval form) and dihydrate

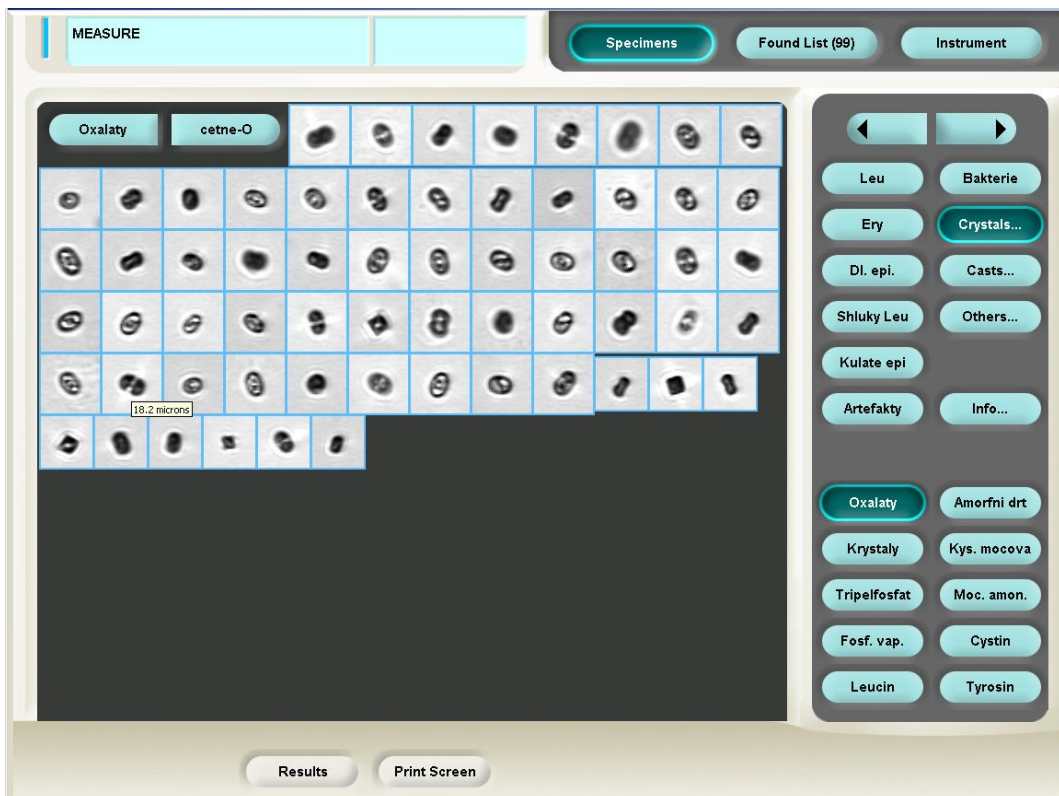


Calcium oxalate – monohydrate (oval form and biscuit-shaped) and dihydrate

Pictures from iQ 200 analyzer (IRIS)



Calcium oxalate dihydrate (envelope-shaped)

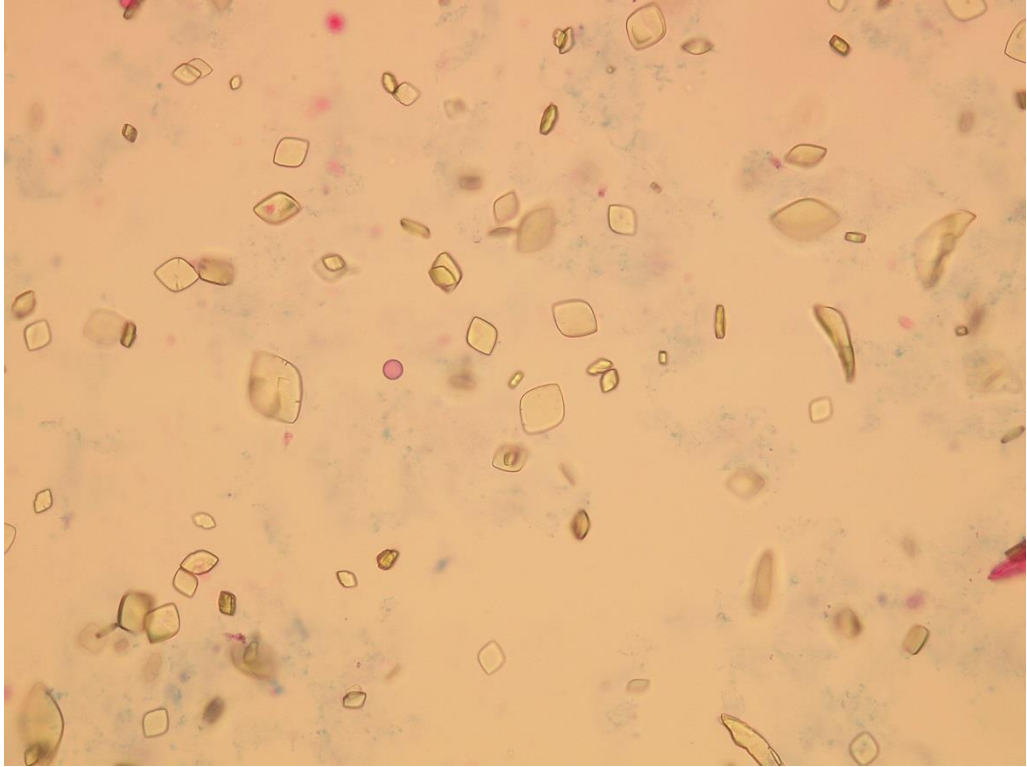


Calcium oxalate – monohydrate (oval and biscuit-shaped) and dihydrate

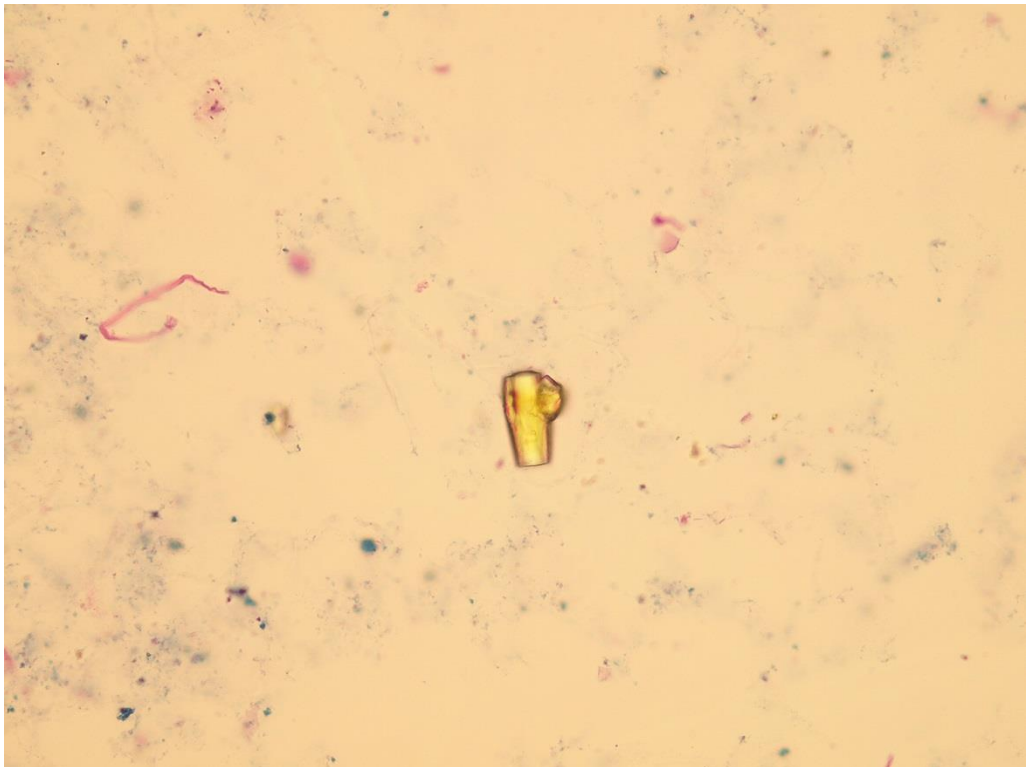
Uric acid

Various forms of crystals of uric acid

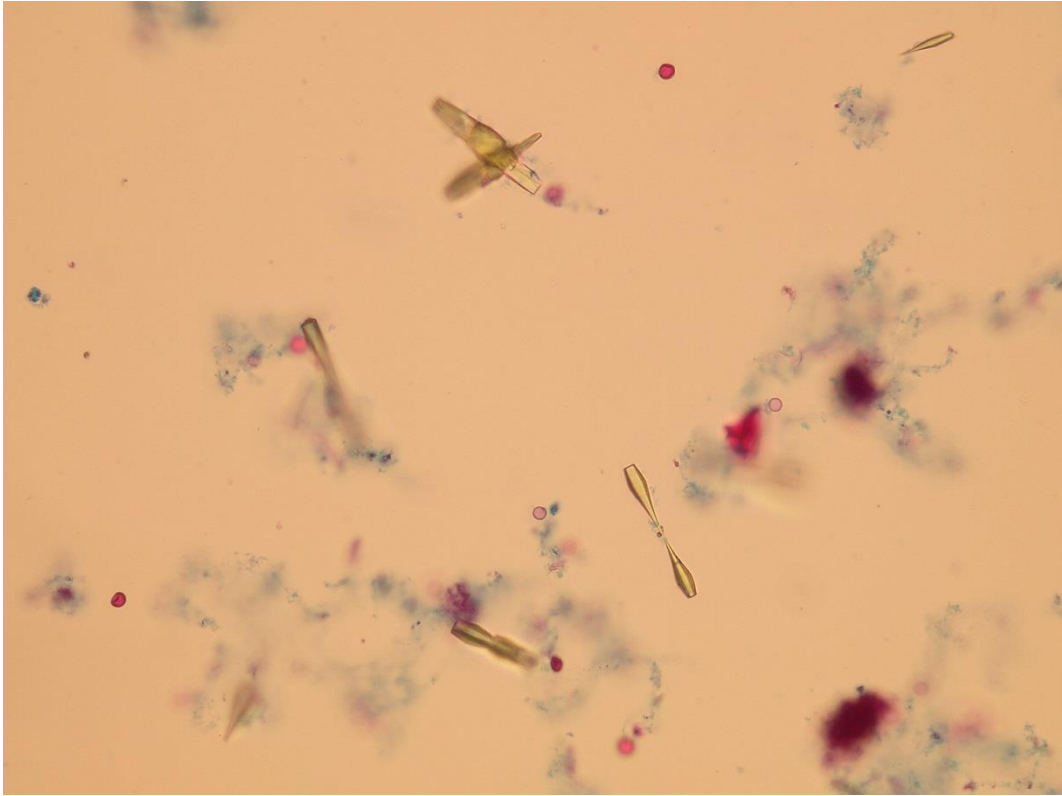
Stained sediment



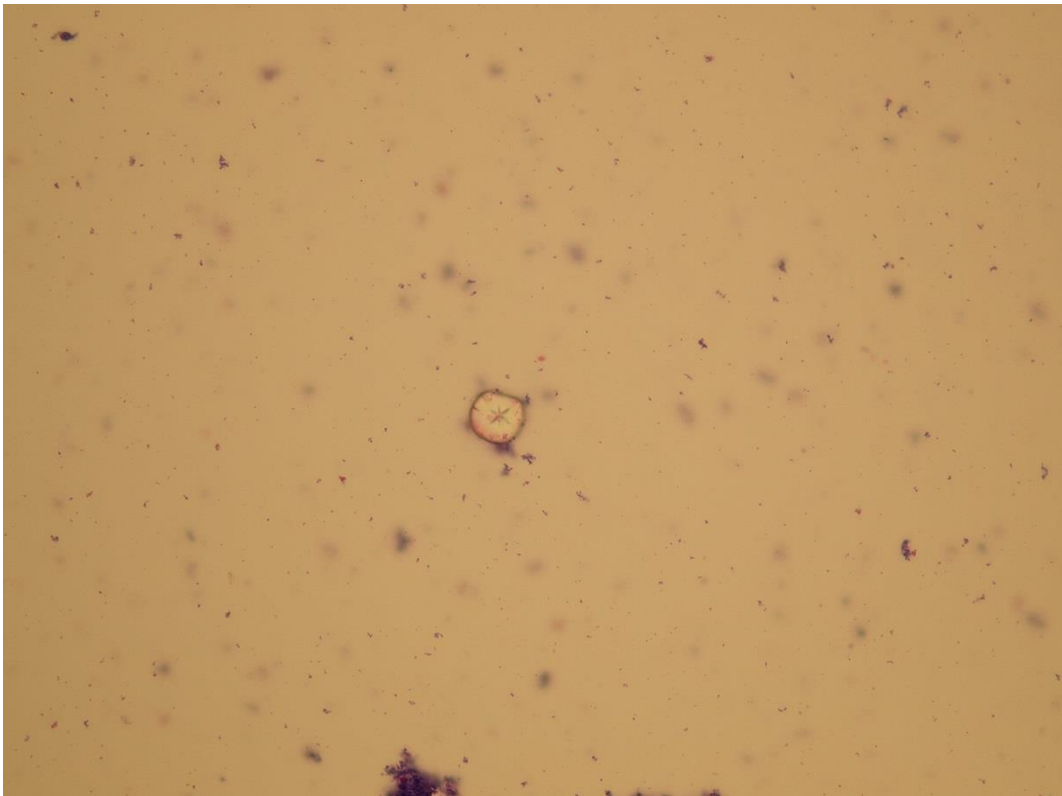
Uric acid (lemon-shaped)



Uric acid (barrel-shaped)




Uric acid (needle form)



Uric acid

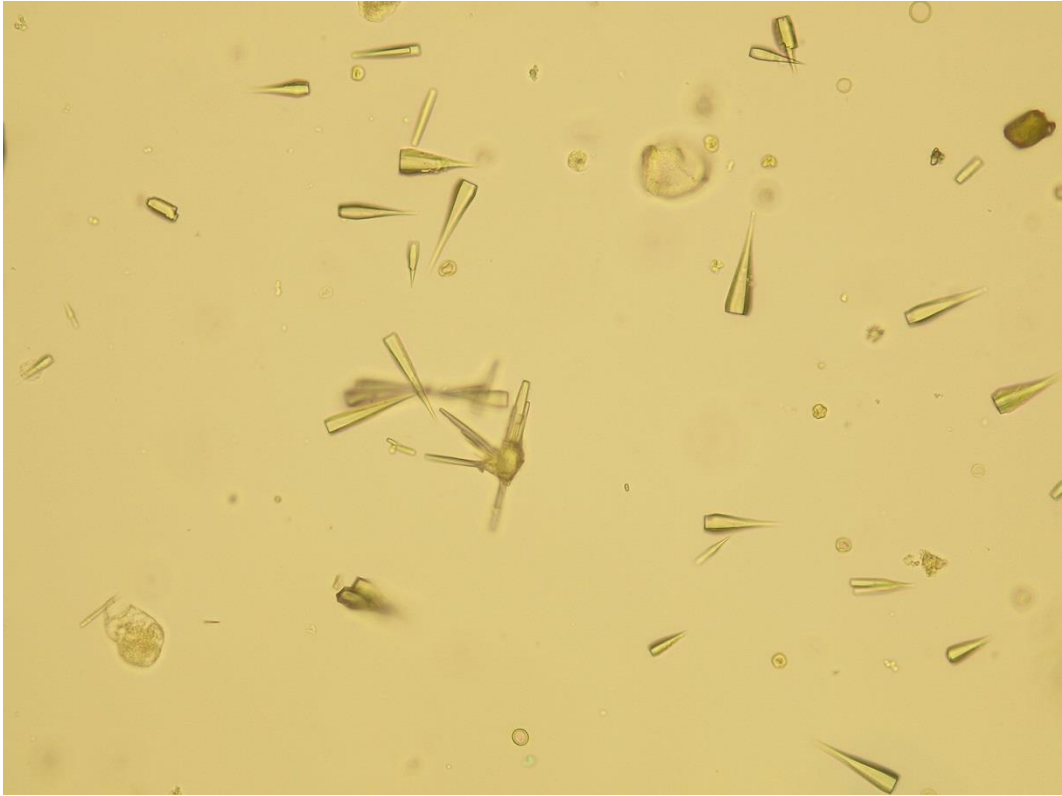Native sediment



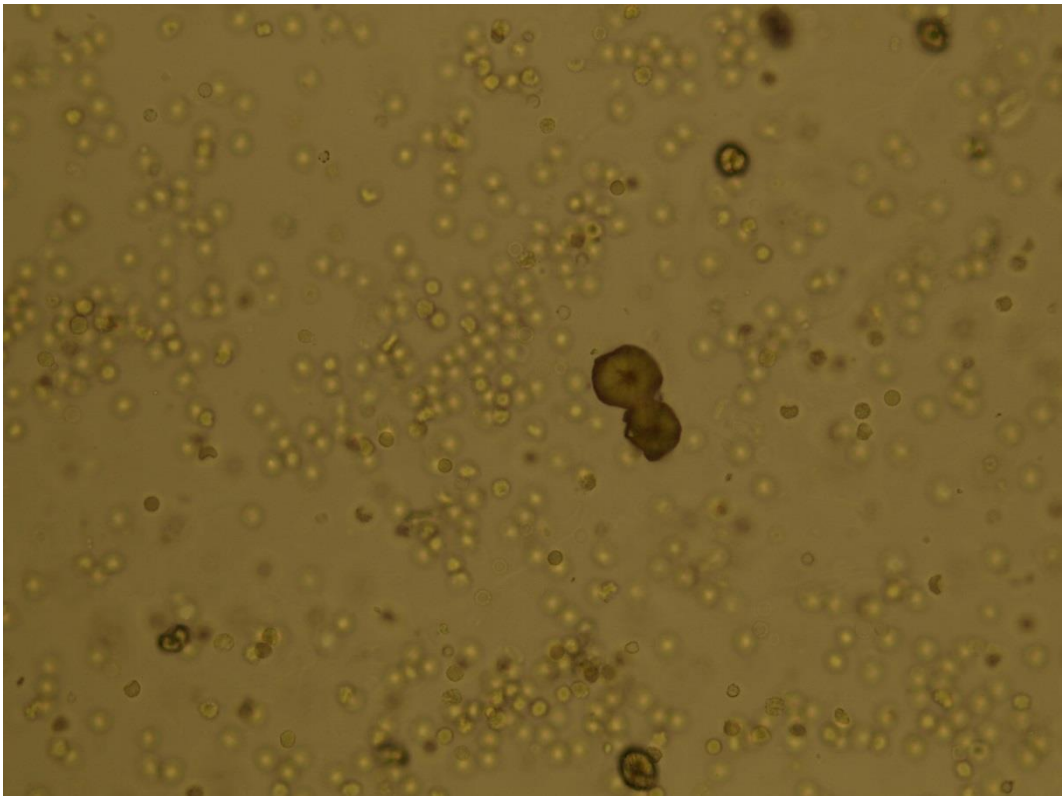
Uric acid (lemon-shaped)



Uric acid (barrel-shaped)

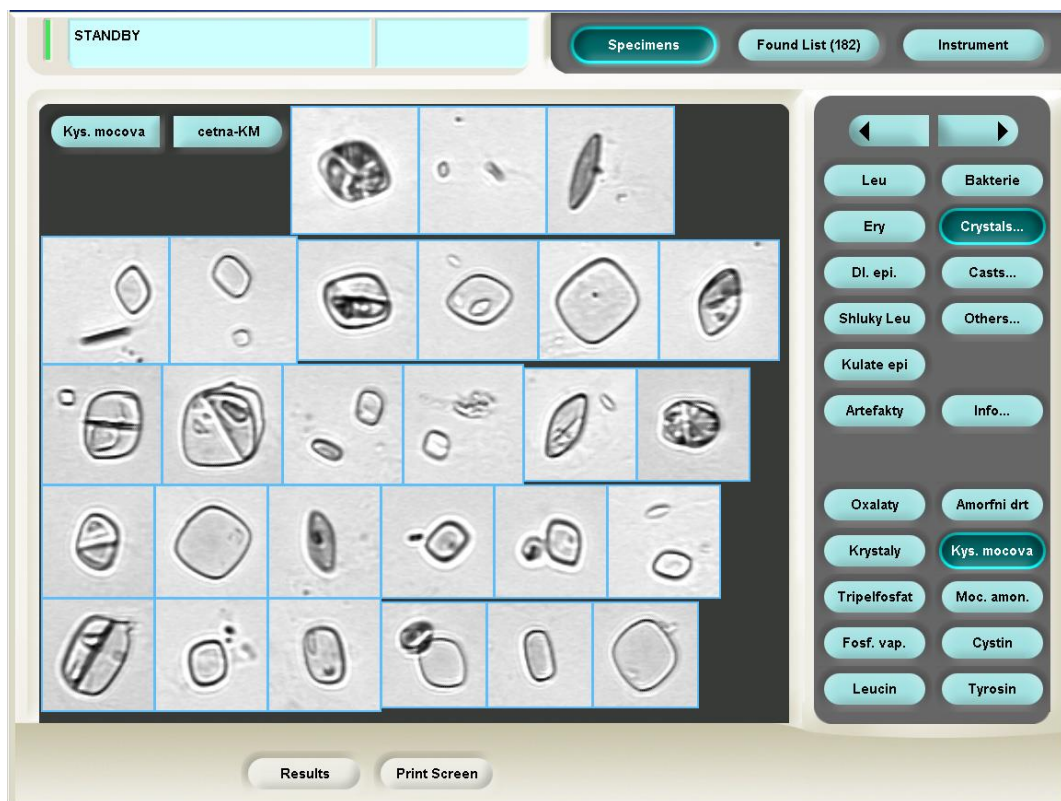


Uric acid (needle form)

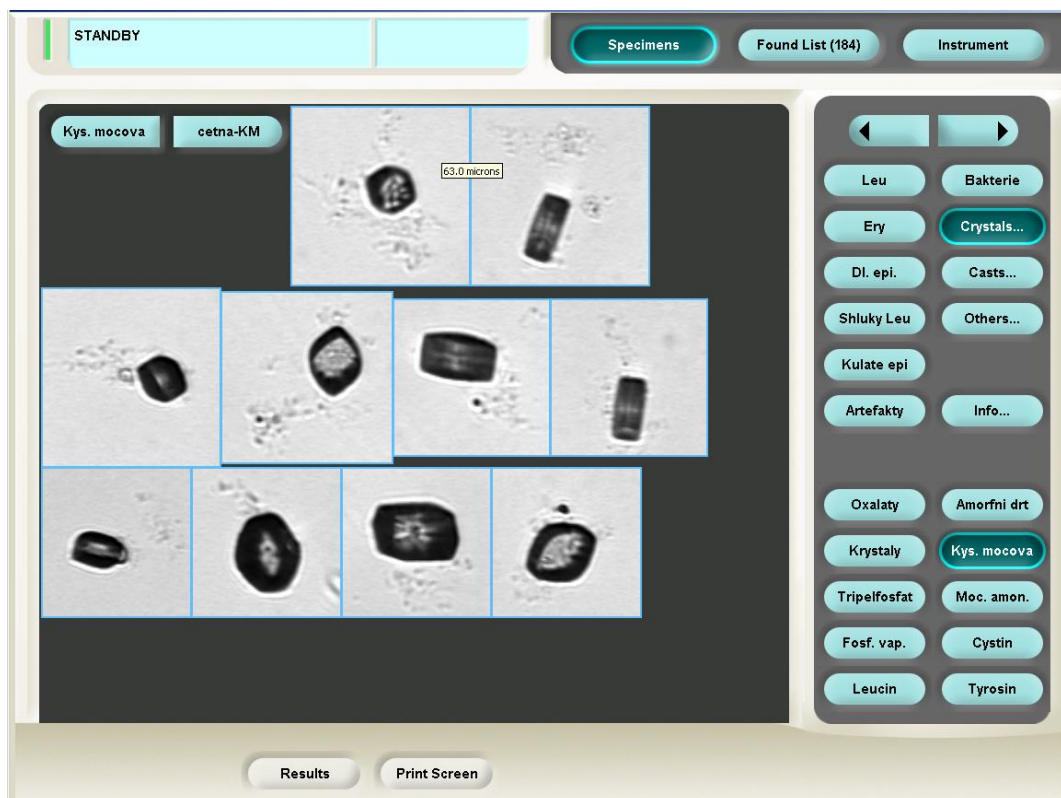


Uric acid

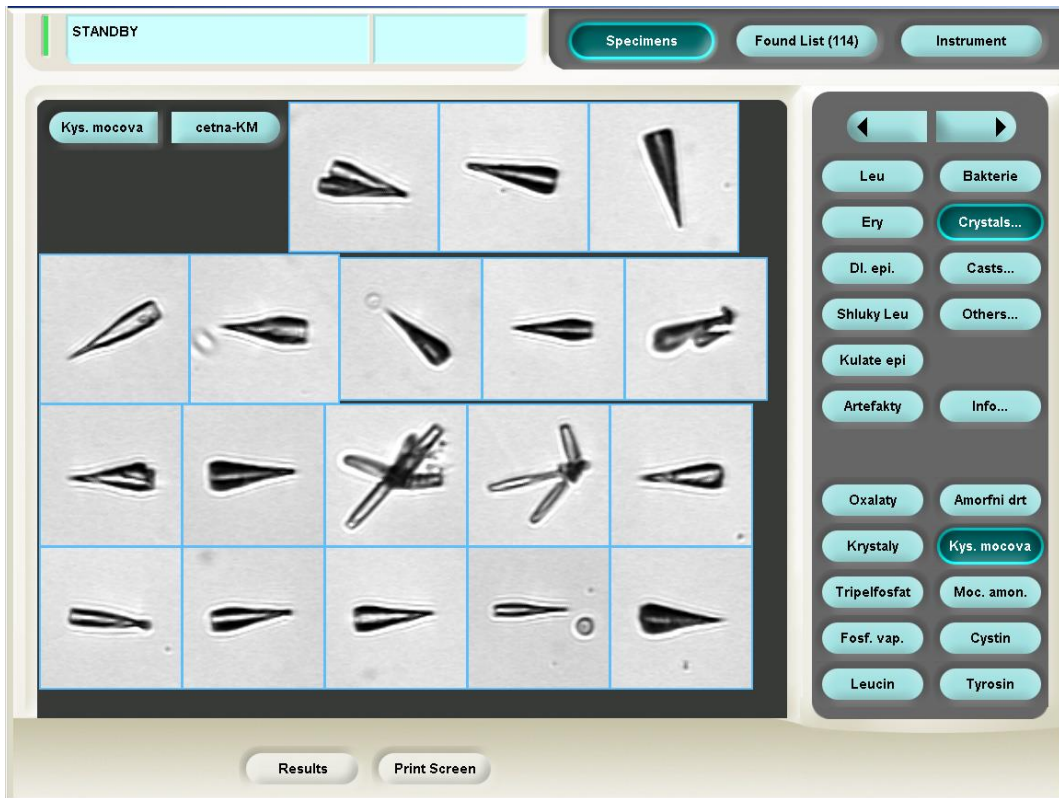
Pictures from iQ 200 analyzer (IRIS)



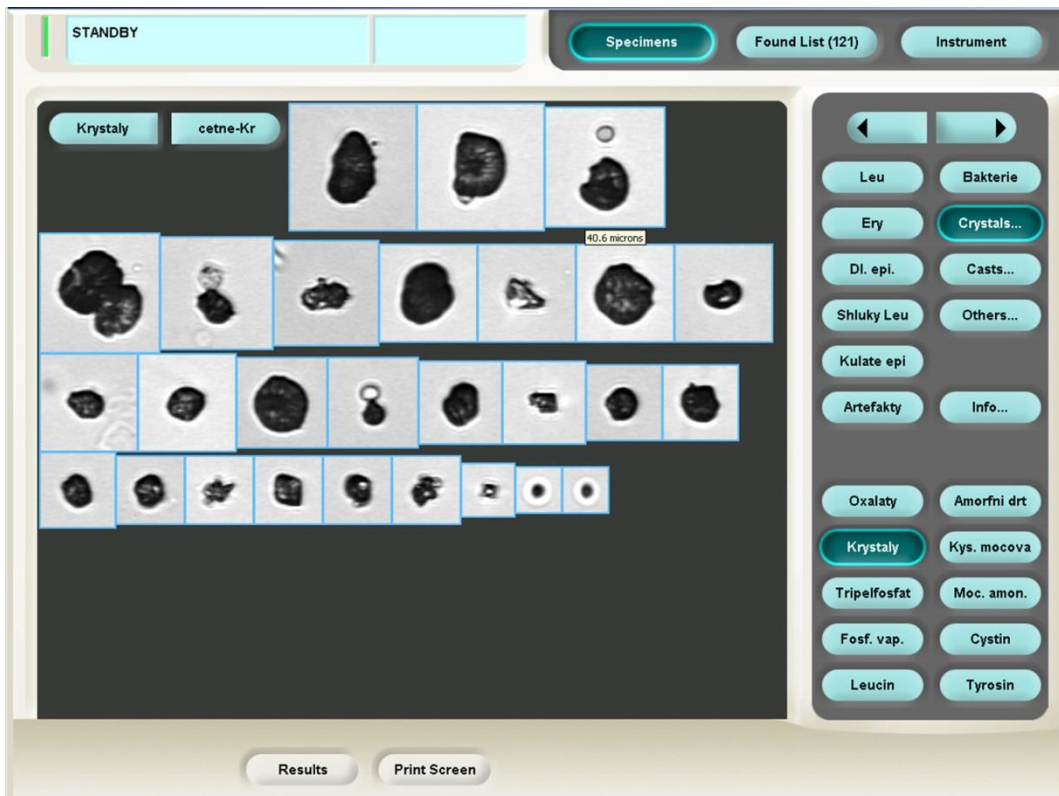
Uric acid (lemon-shaped)



Uric acid



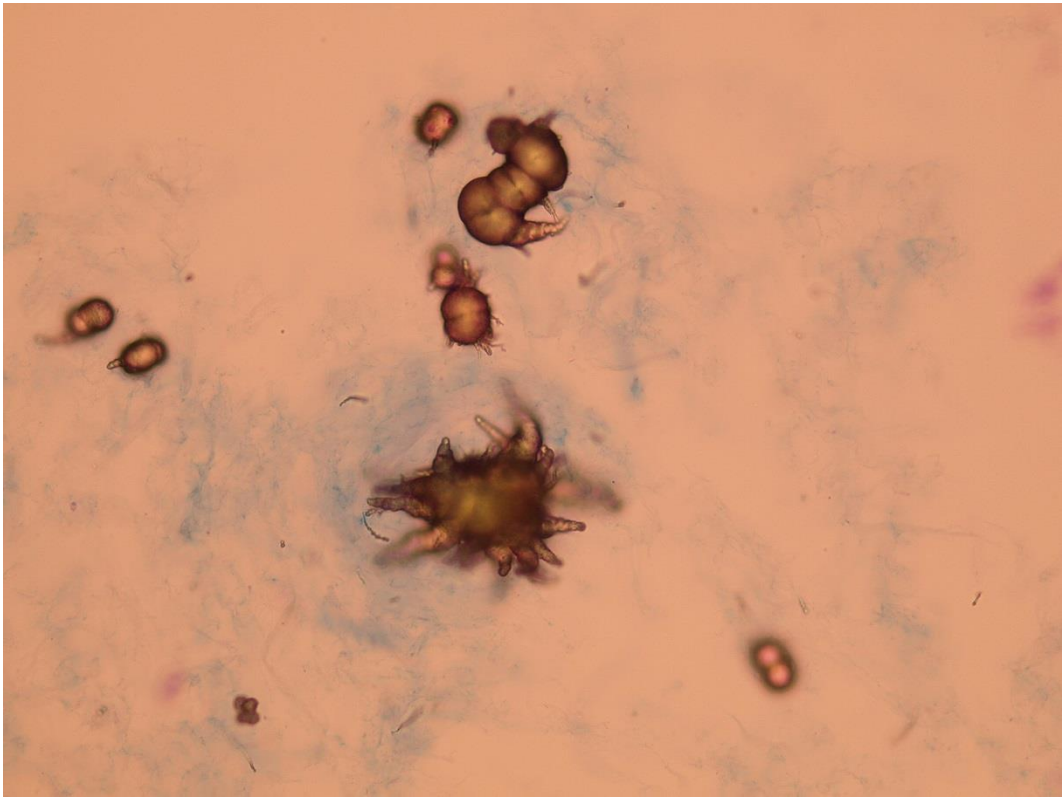
Uric acid (needle form)



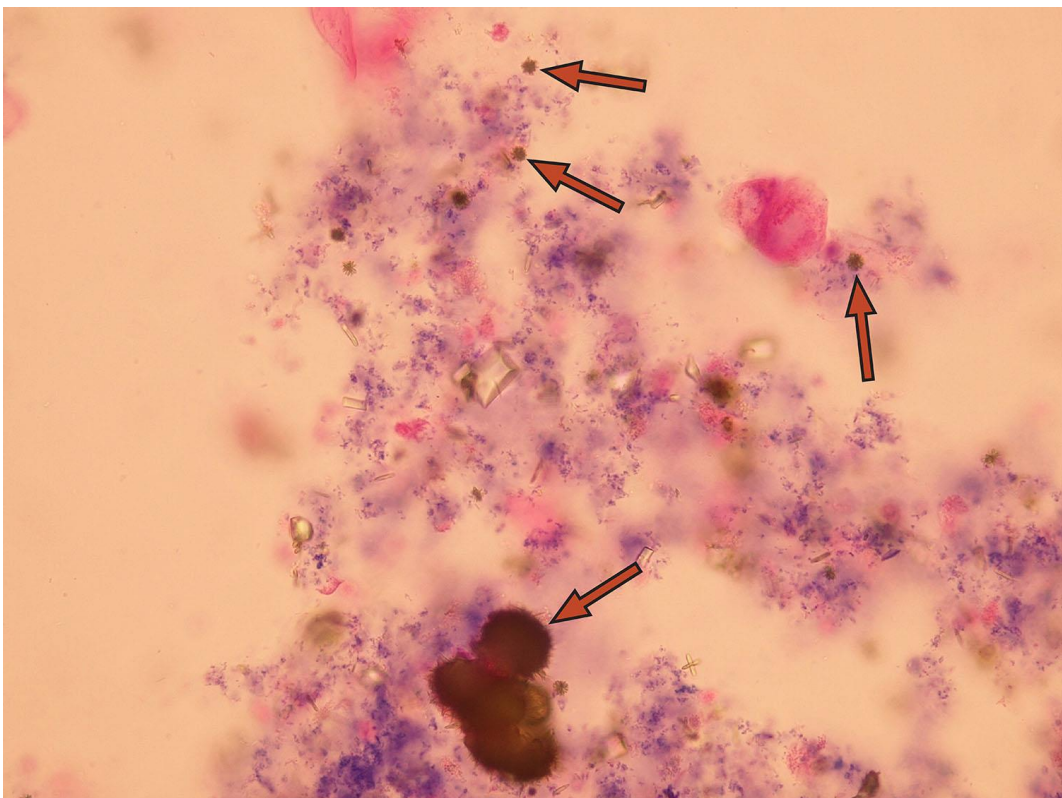
Uric acid

Ammonium urate

Stained sediment

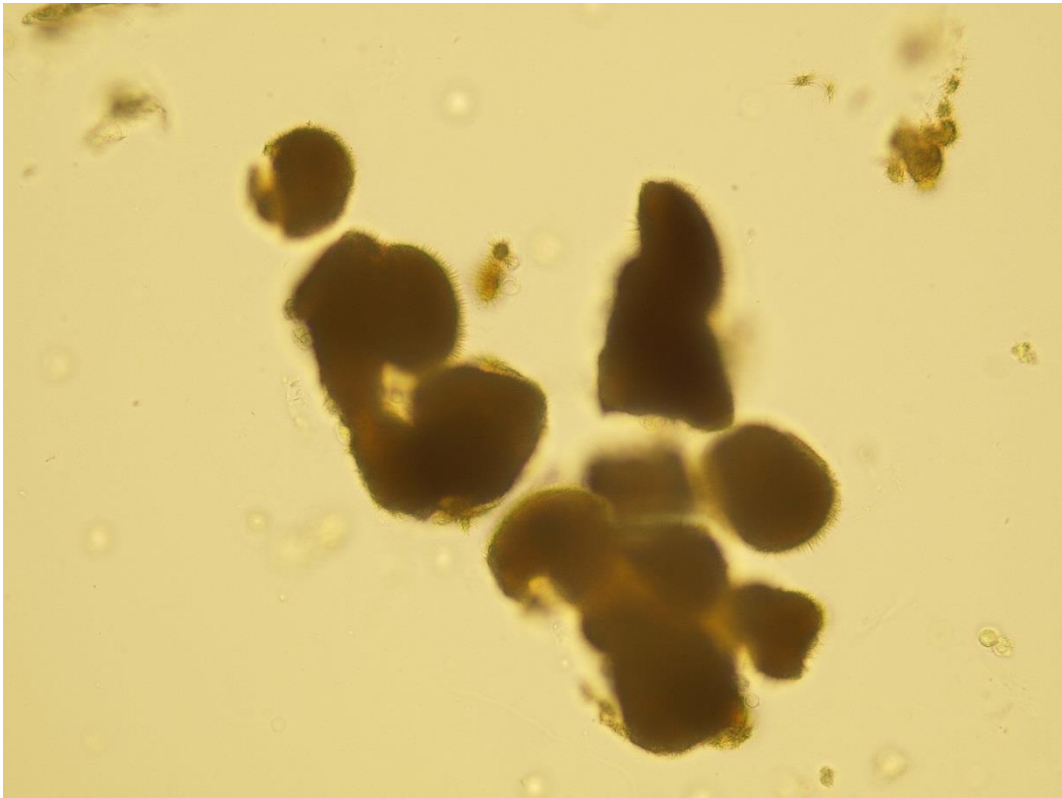


Ammonium urate



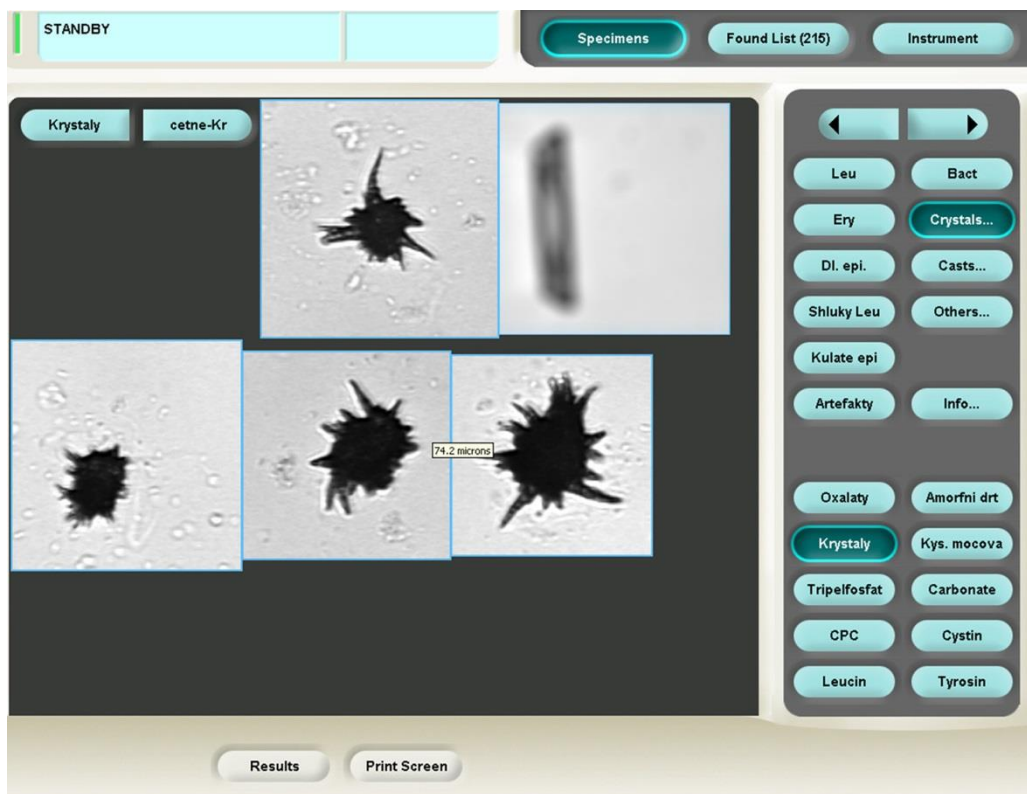
Ammonium urate

Native sediment

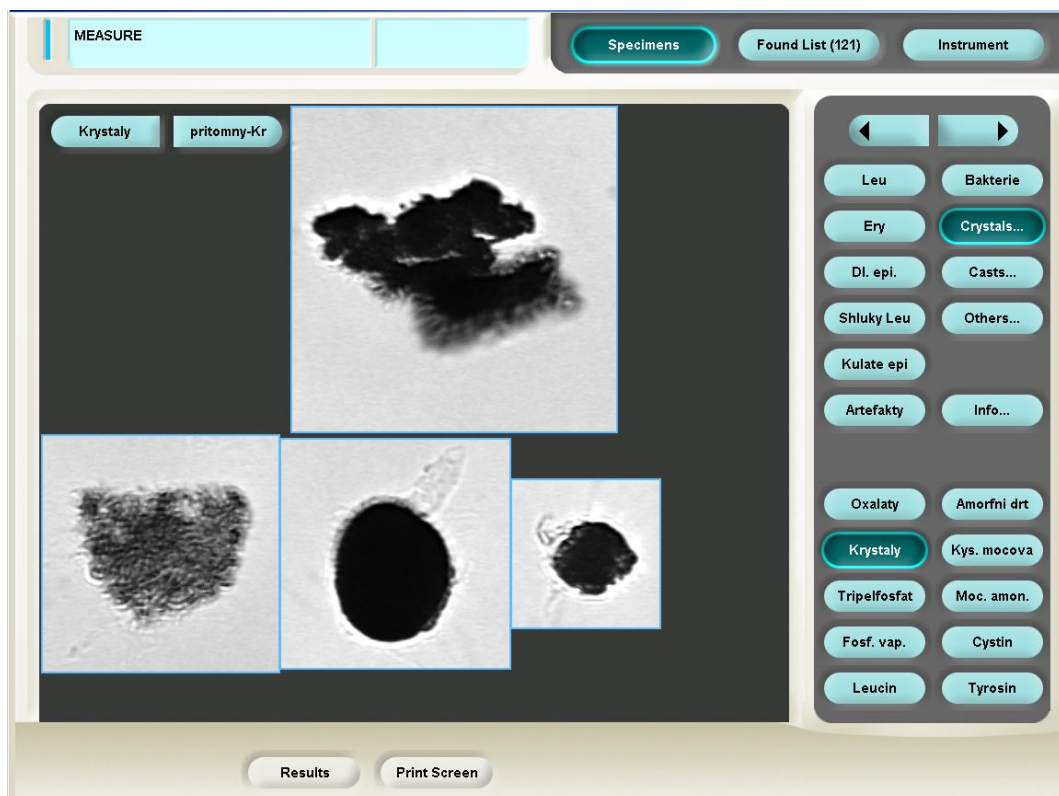


Ammonium urate

Pictures from iQ 200 analyzer (IRIS)



Ammonium urate

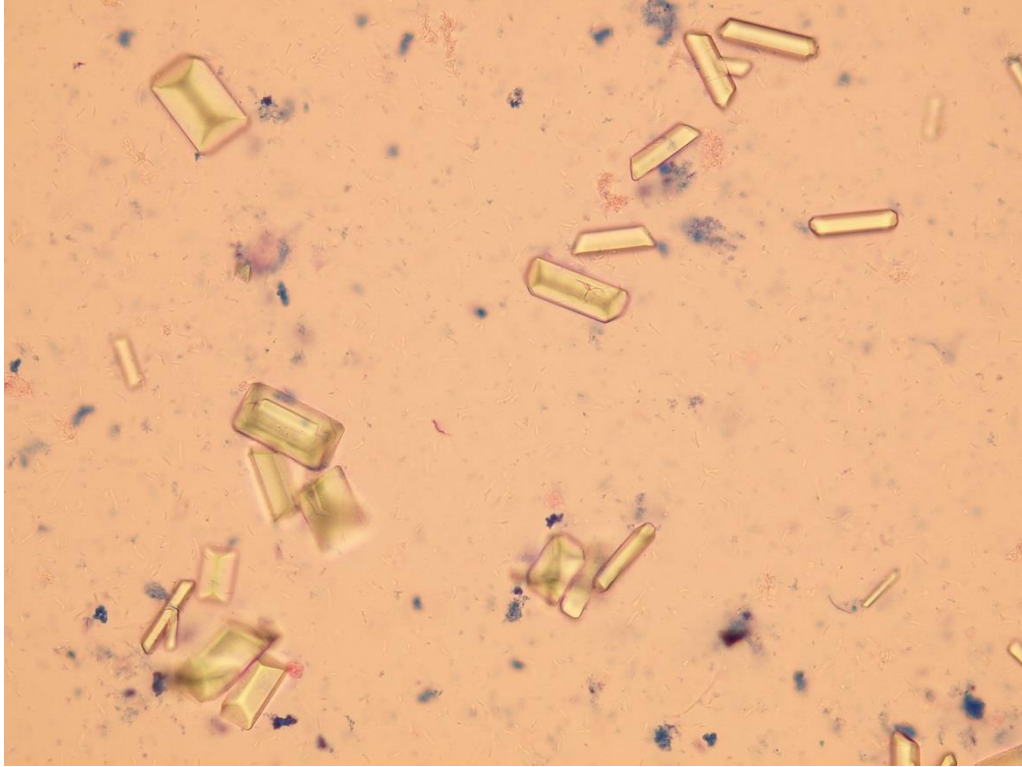


Ammonium urate


Triple phosphate

Ammonium magnesium phosphate crystals (Triple phosphate).

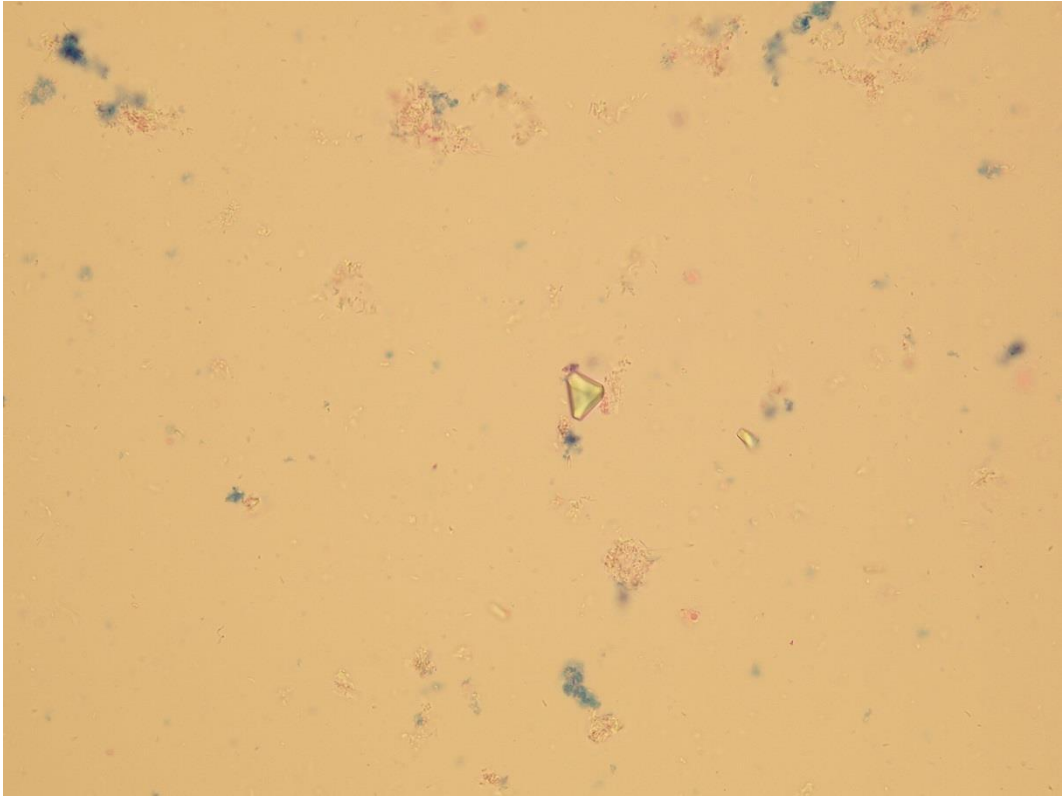
Stained sediment




Triple phosphate (coffin-shaped)



Triple phosphate

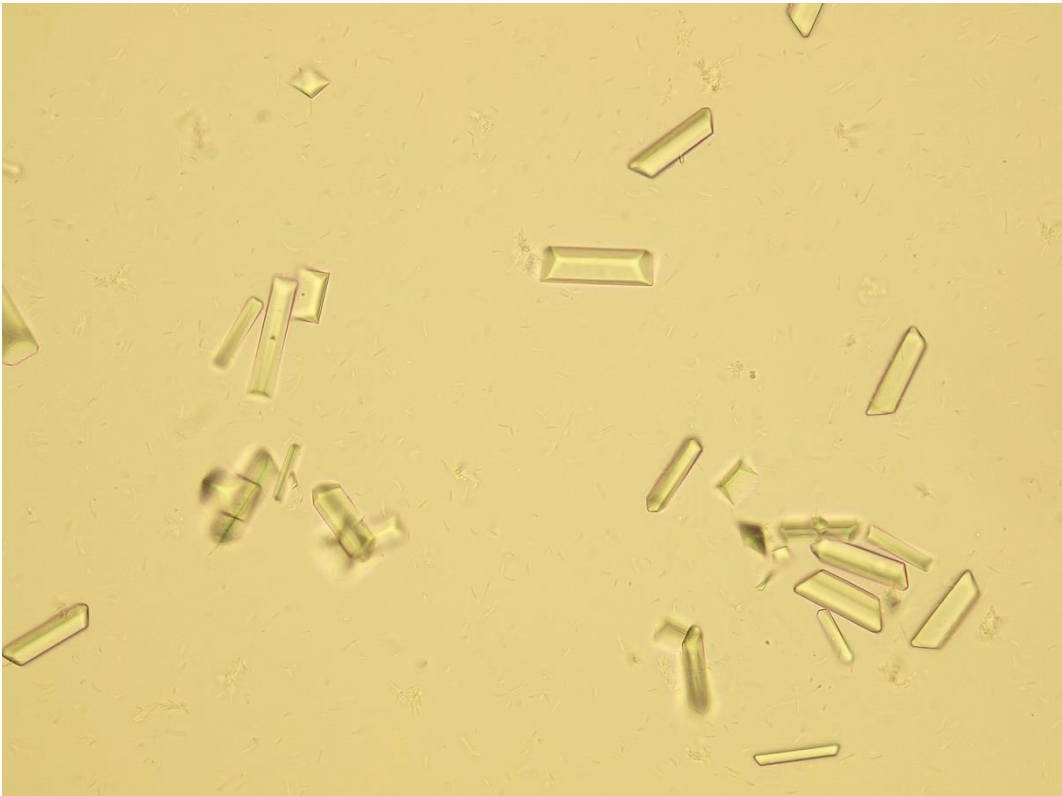

Triple phosphate crystal

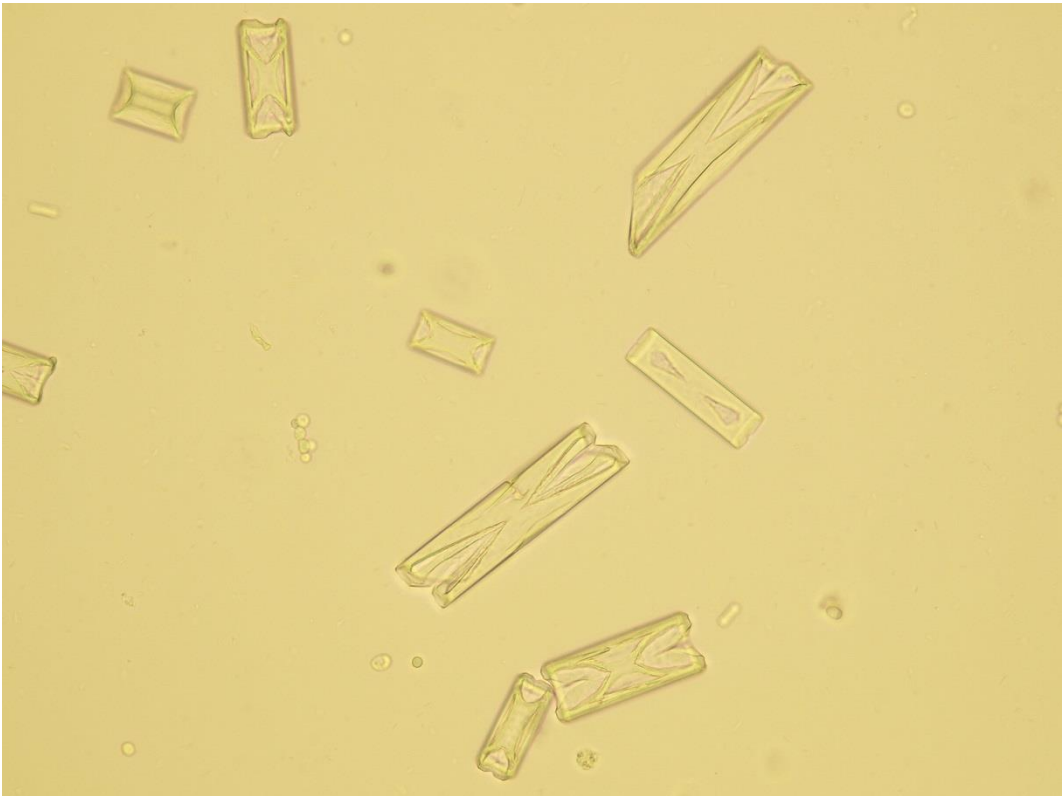


Triple phosphate (arrows)

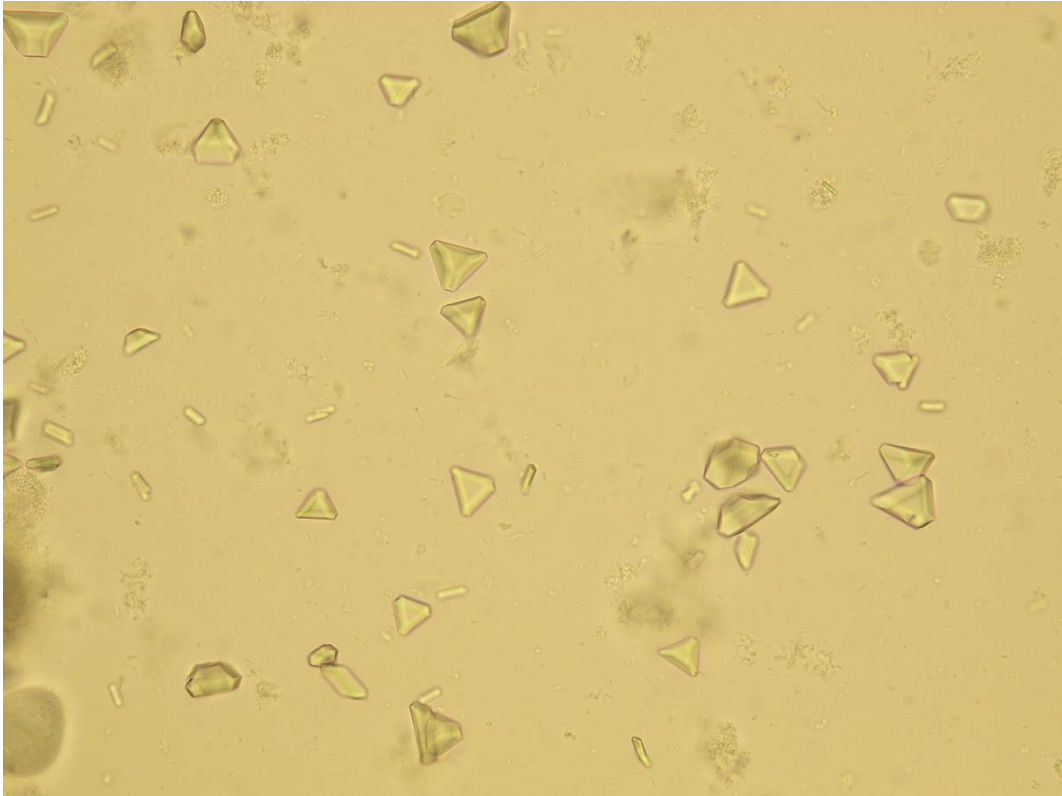
Native sediment




Triple phosphate (coffin-shaped)



Triple phosphate

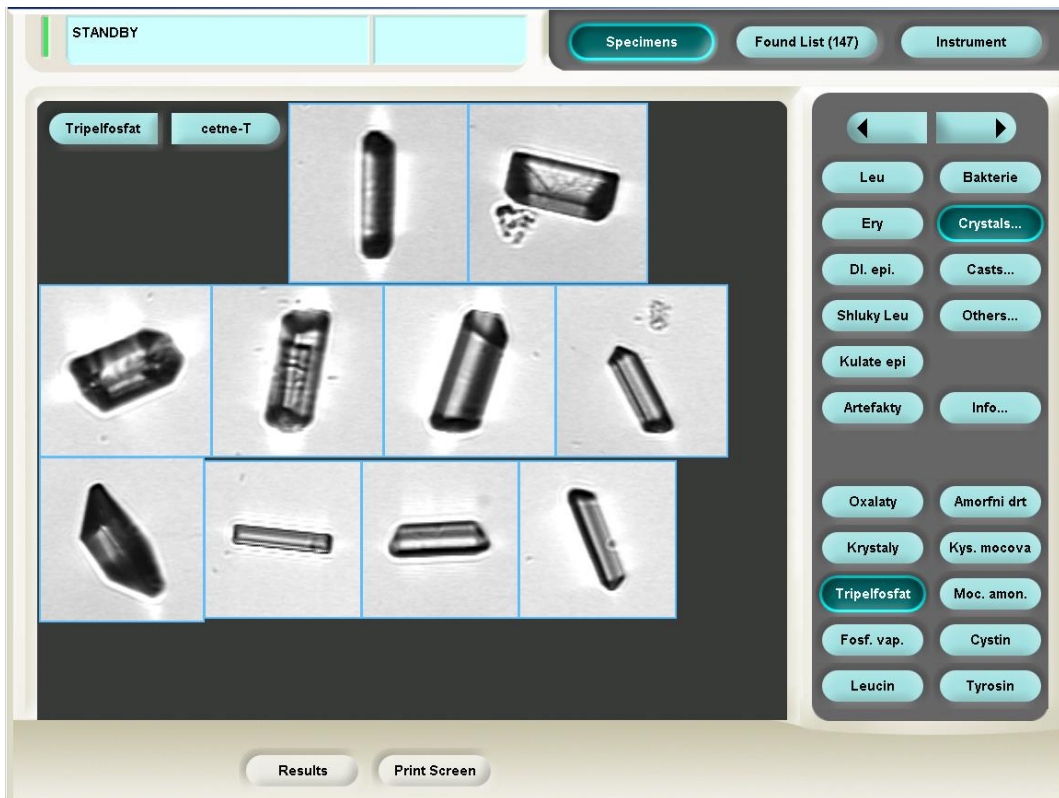


Triple phosphate

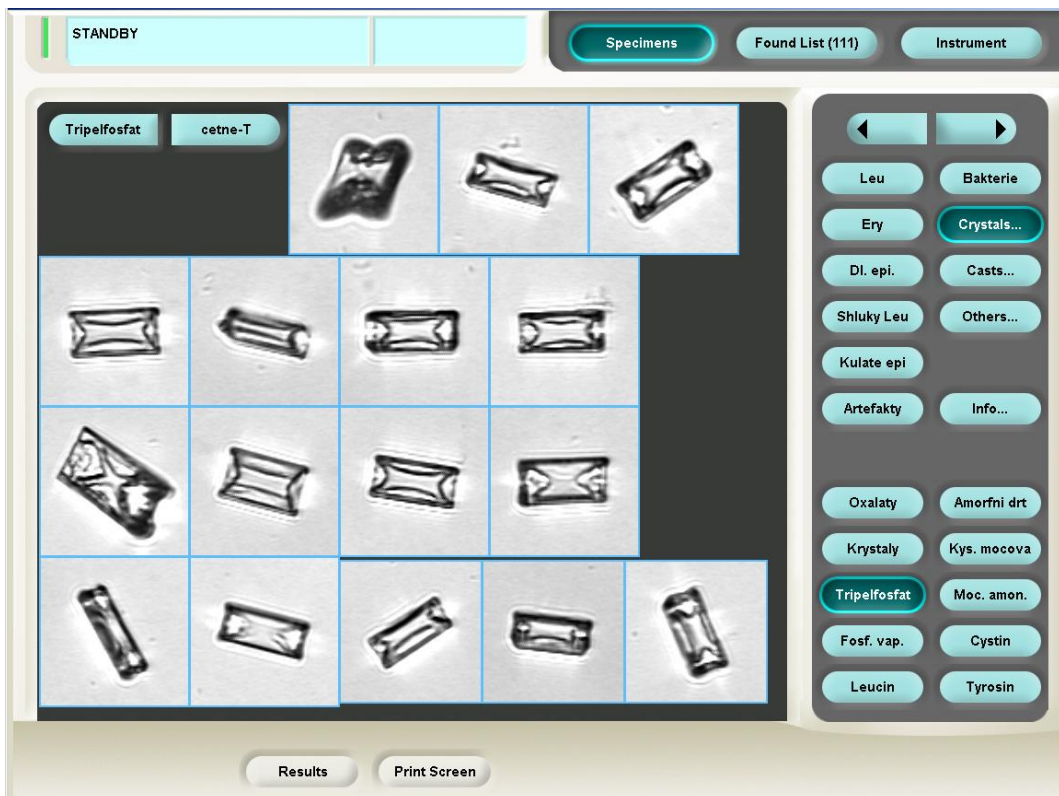


Triple phosphate (arrows)

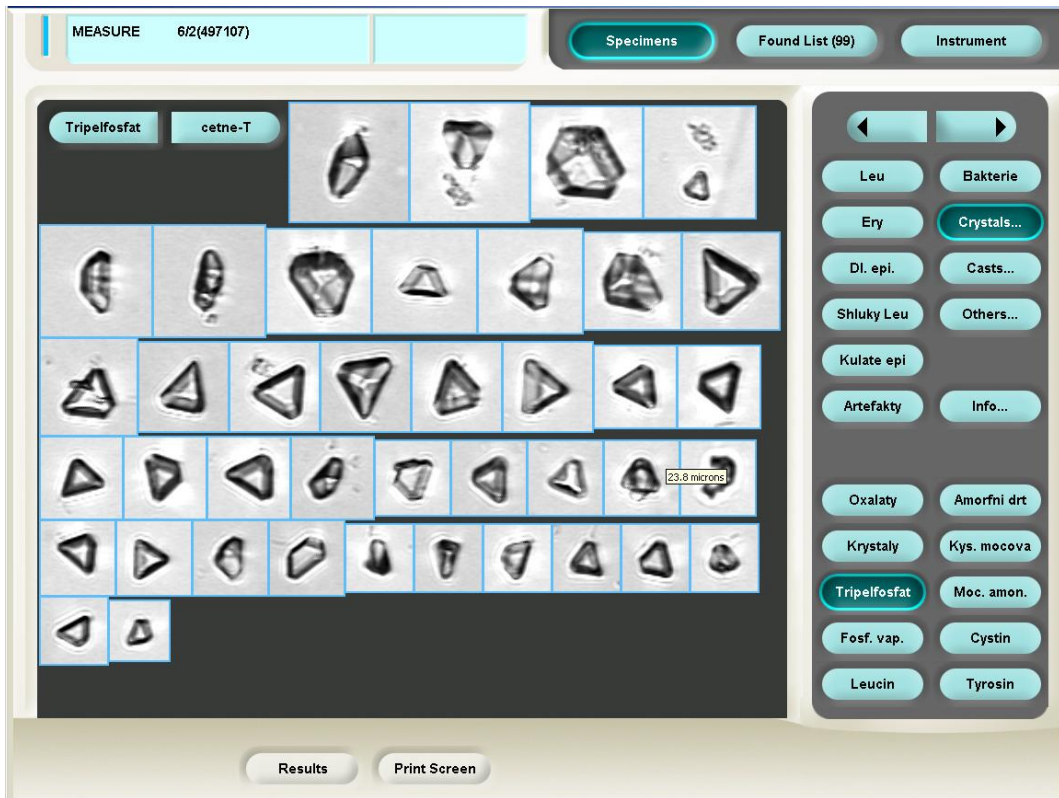
Pictures from iQ 200 analyzer (IRIS)



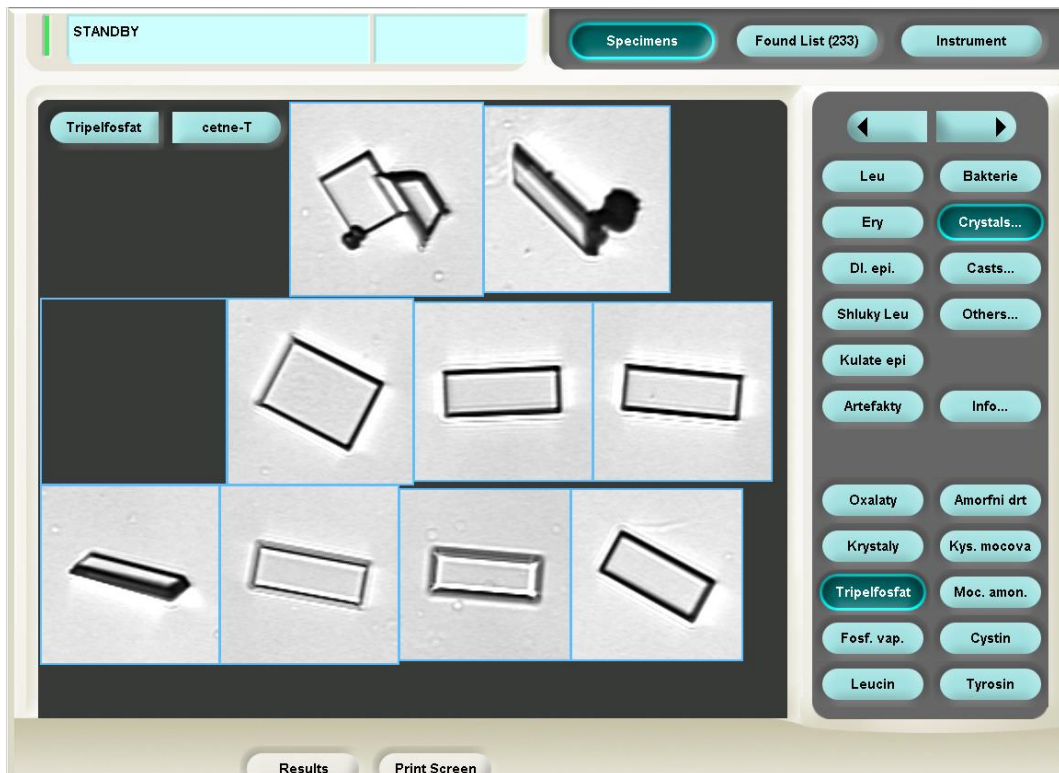
Triple phosphate (coffin-shaped)



Triple phosphate



Triple phosphate




Triple phosphate

STANDBY

Specimens Found List (233) Instrument

Tripelfosfat cetne-T



Leu Bakterie
 Ery Crystals...
 Dl. epi. Casts...
 Shluky Leu Others...
 Kulate epi
 Artefakty Info...
 Oxalaty Amorfni drt
 Krystaly Kys. mocova
 Tripelfosfat Moc. amon.
 Fosf. vap. Cystin
 Leucin Tyrosin

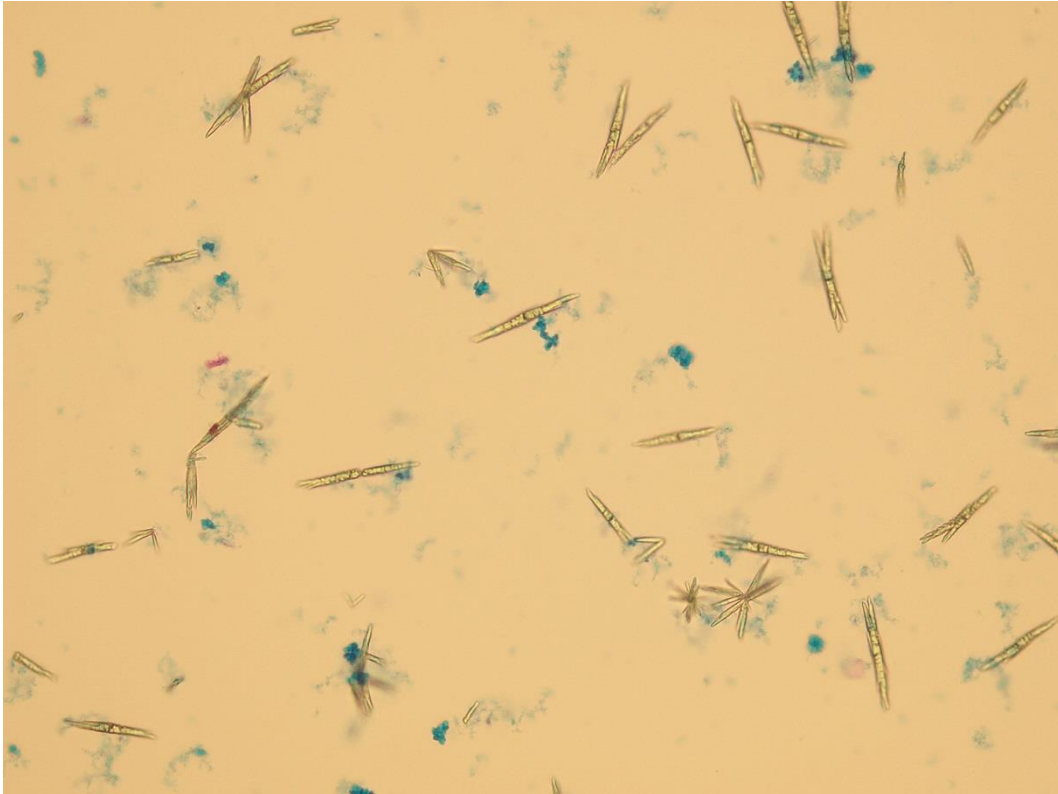
Results Print Screen

Massive triple phosphate

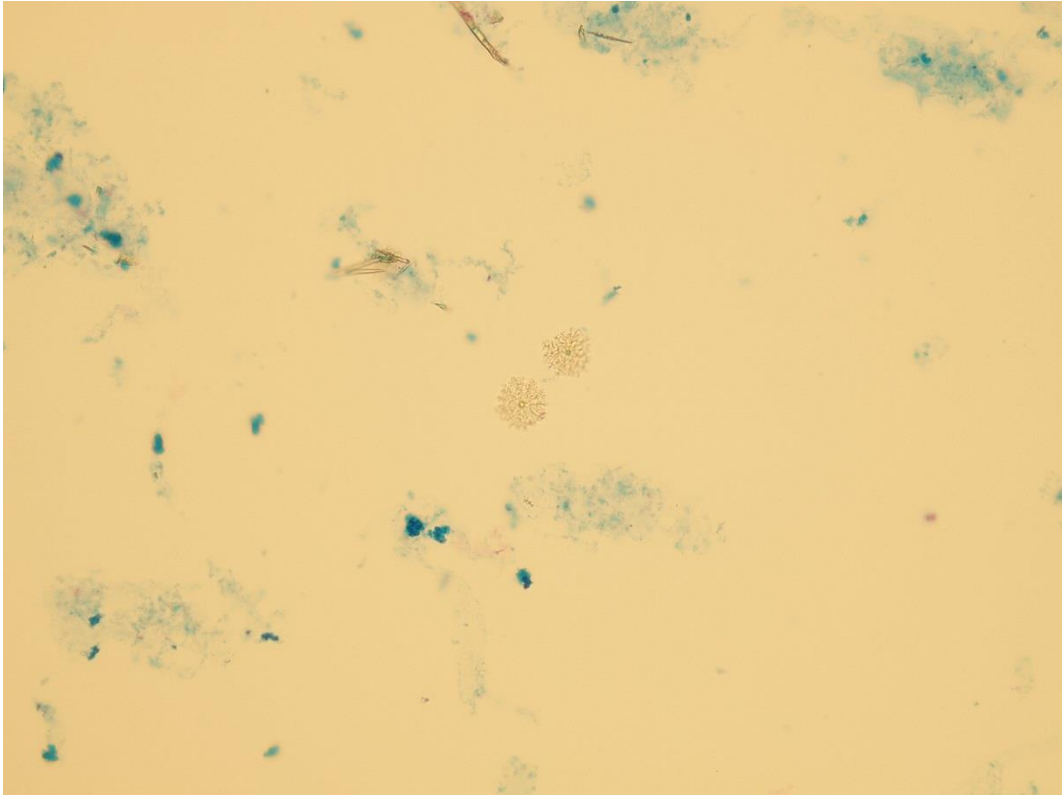
Calcium phosphate

These crystals can be differentiated from uric acid crystals by polarization microscopy. Unlike uric acid, calcium phosphate doesn't turn polarized light.

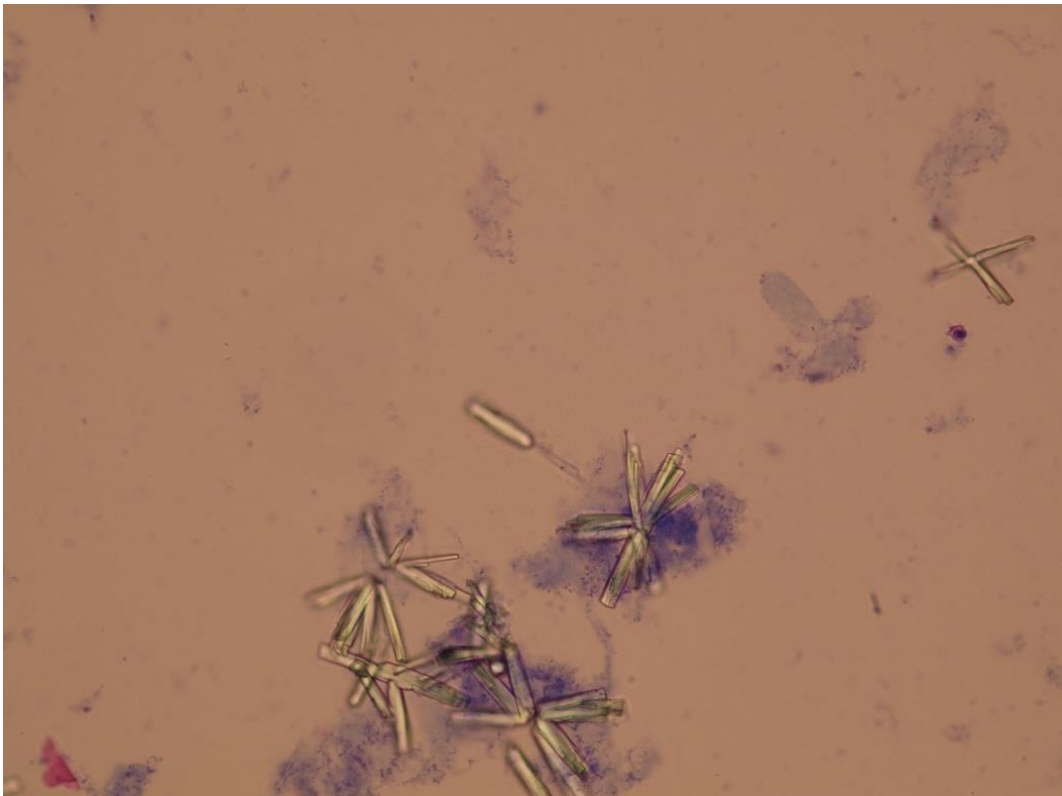
Stained sediment



Calcium phosphate

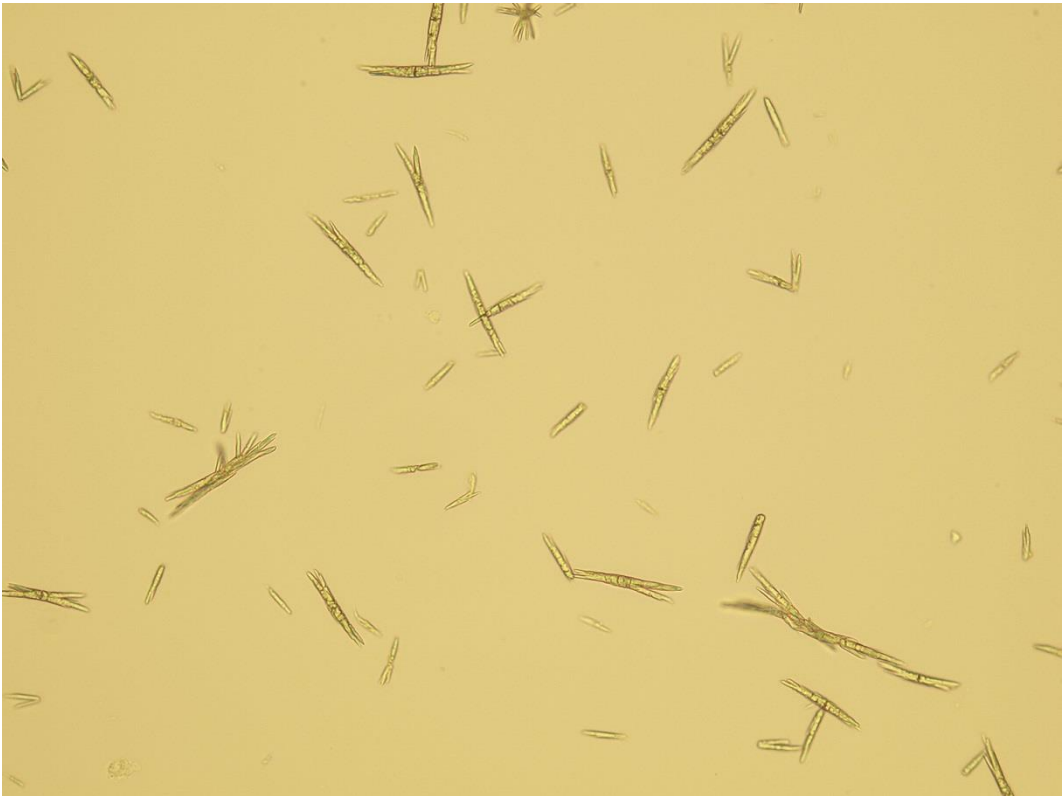


Calcium phosphate (needle-shaped and star-shaped druses)

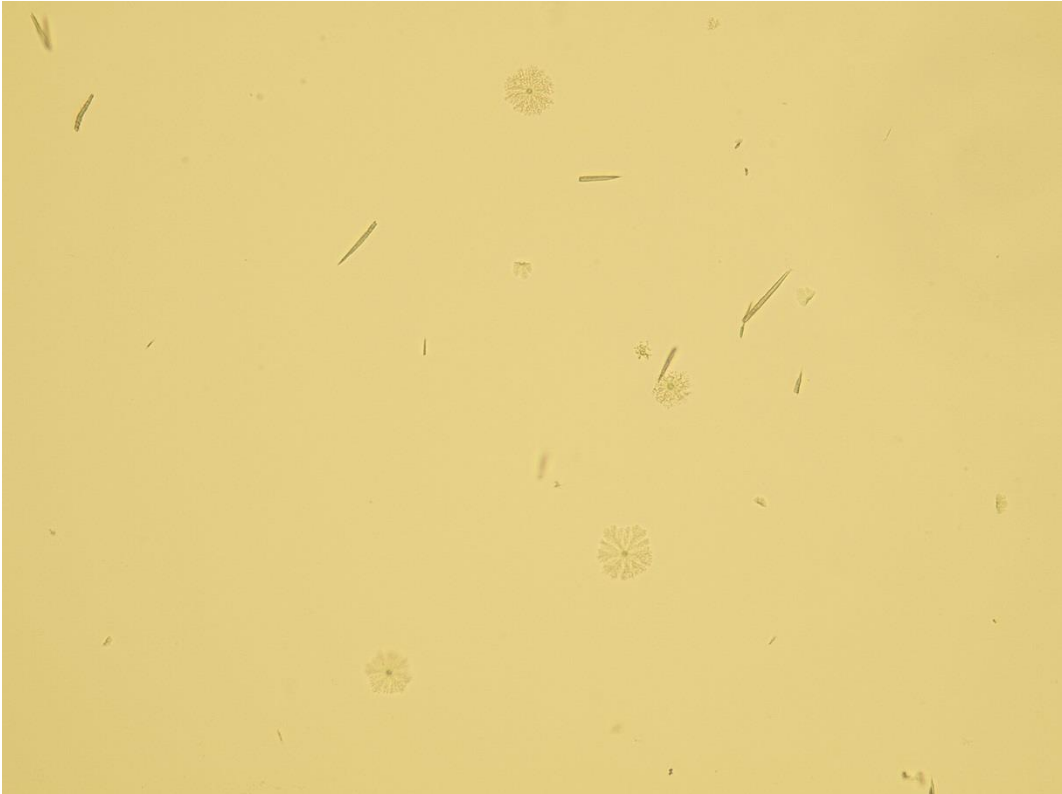

Calcium phosphate

Native sediment



Calcium phosphate

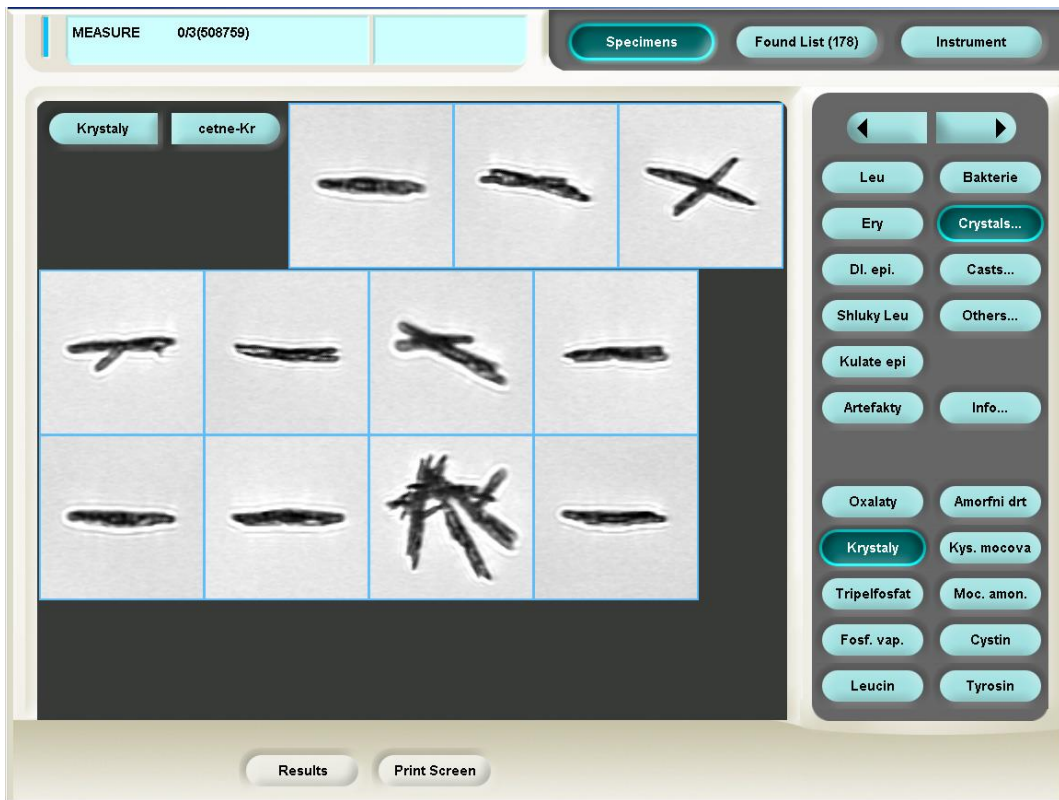


Calcium phosphate (needle-shaped and star-shaped druses)

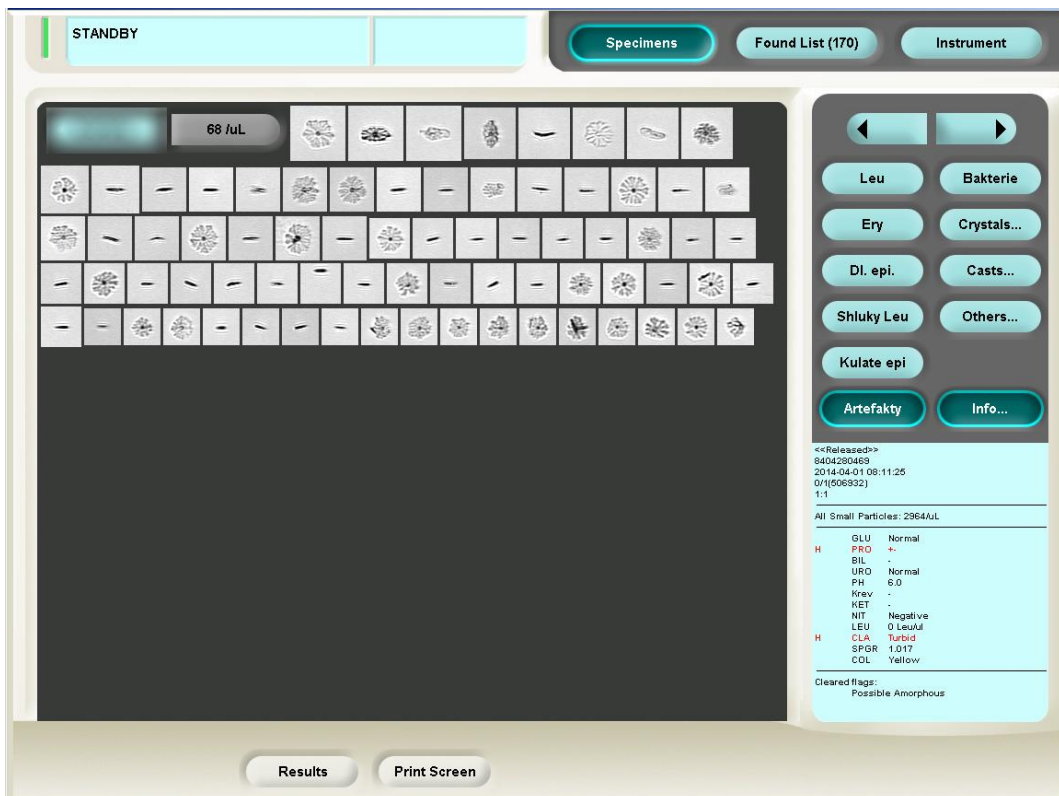


Calcium phosphate

Pictures from iQ 200 analyzer (IRIS)



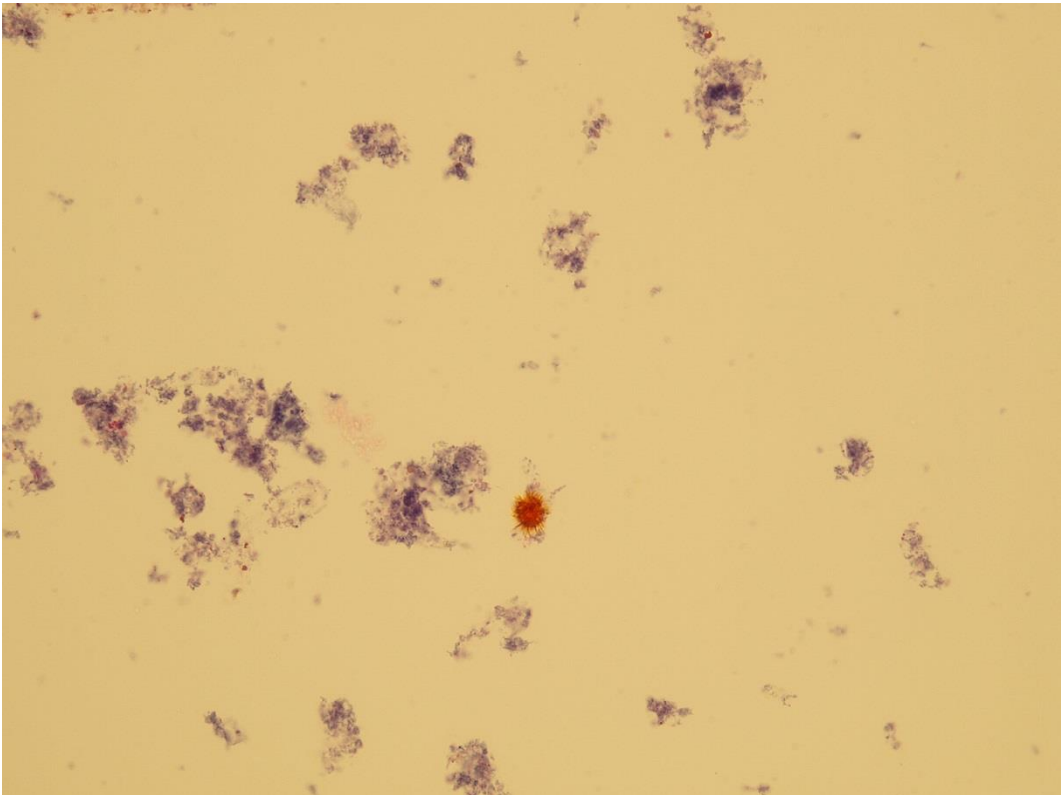
Calcium phosphate



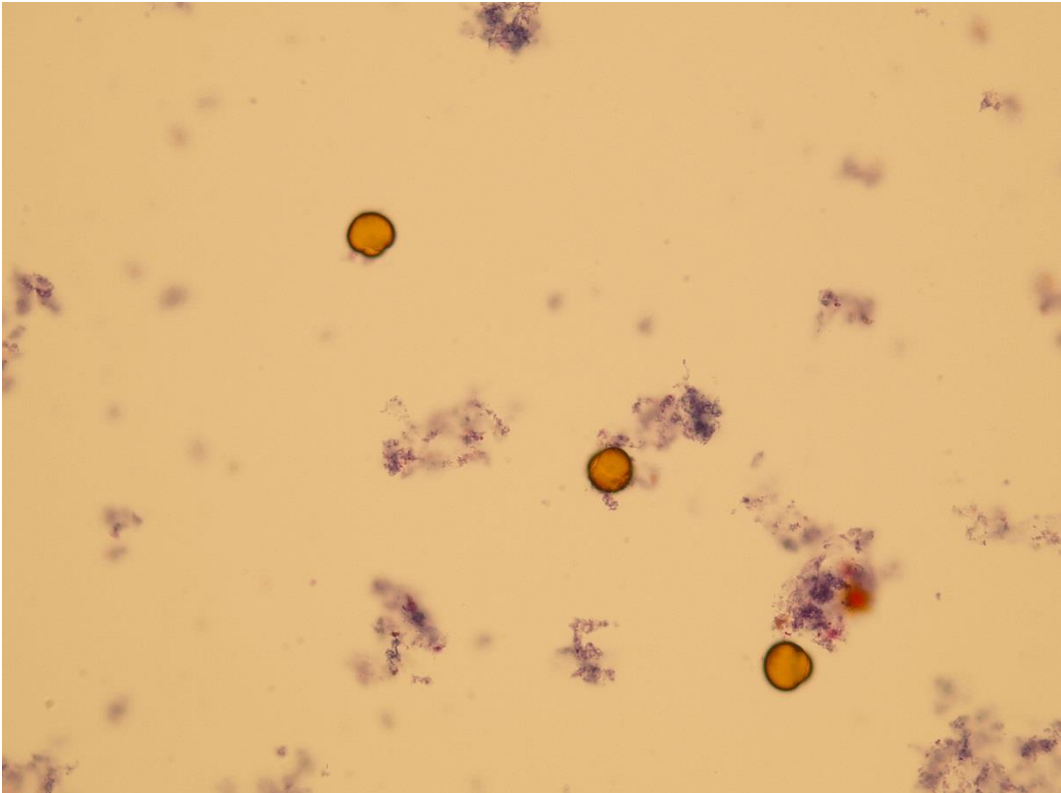
Calcium phosphate (needle-shaped and star-shaped druses)

Bilirubin

Stained sediment

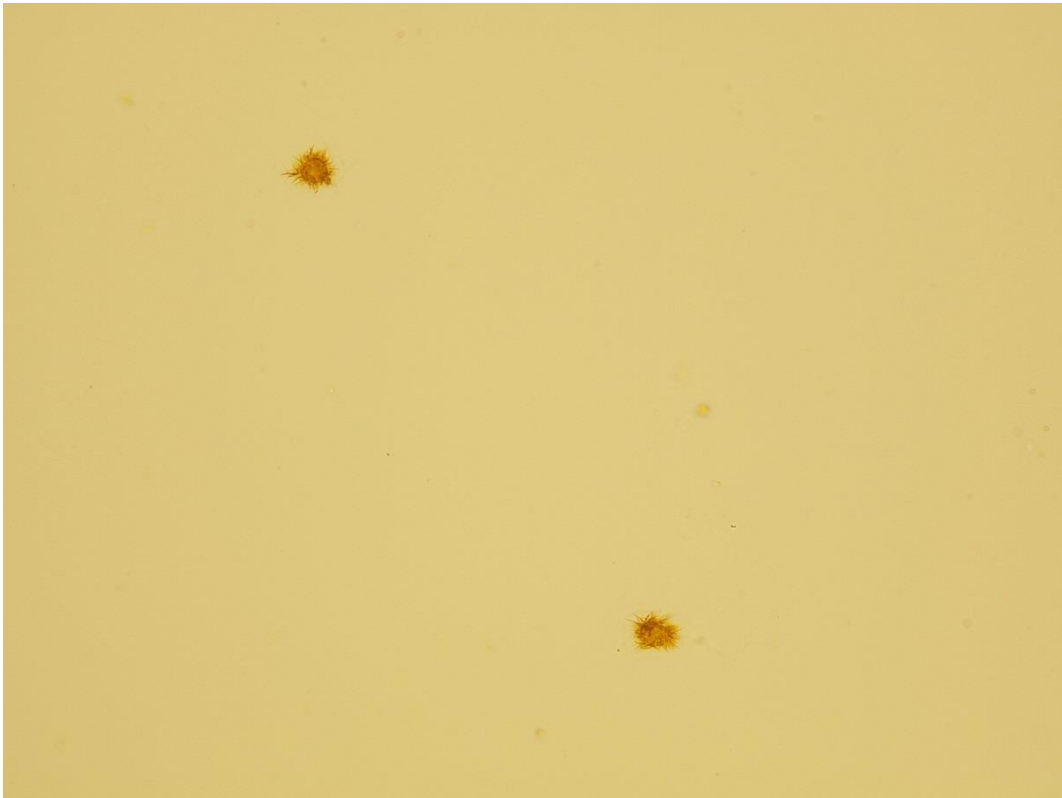


Bilirubin




Bilirubin

Native sediment

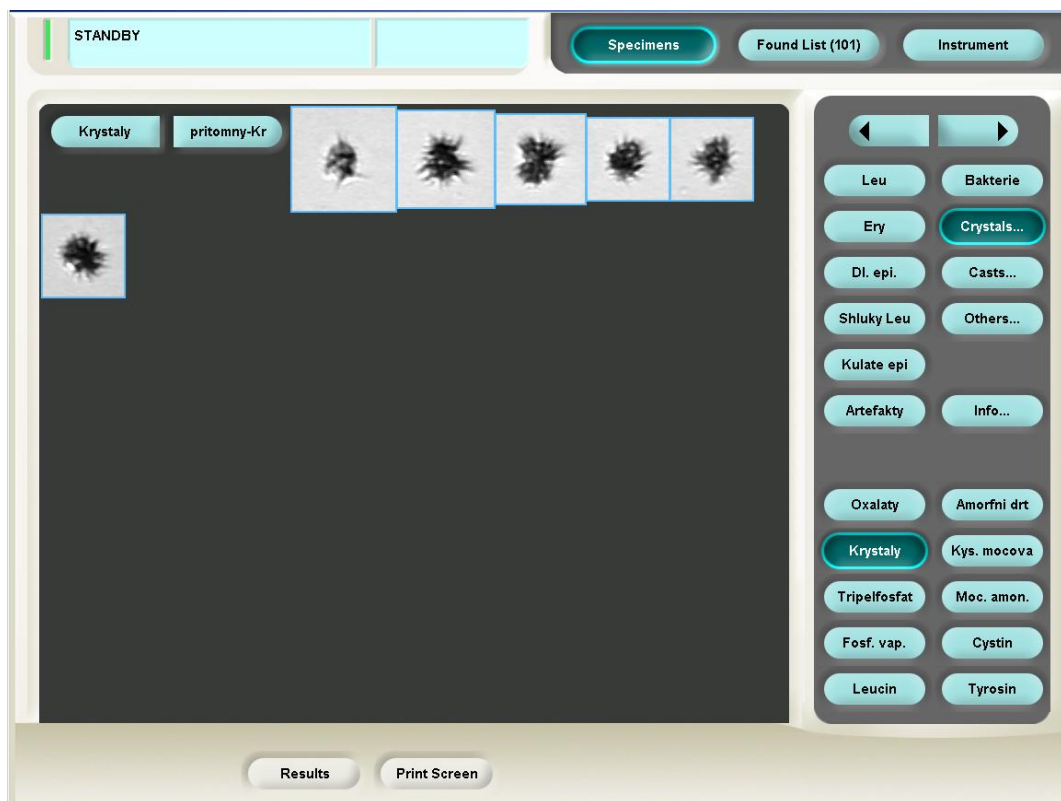


Bilirubin

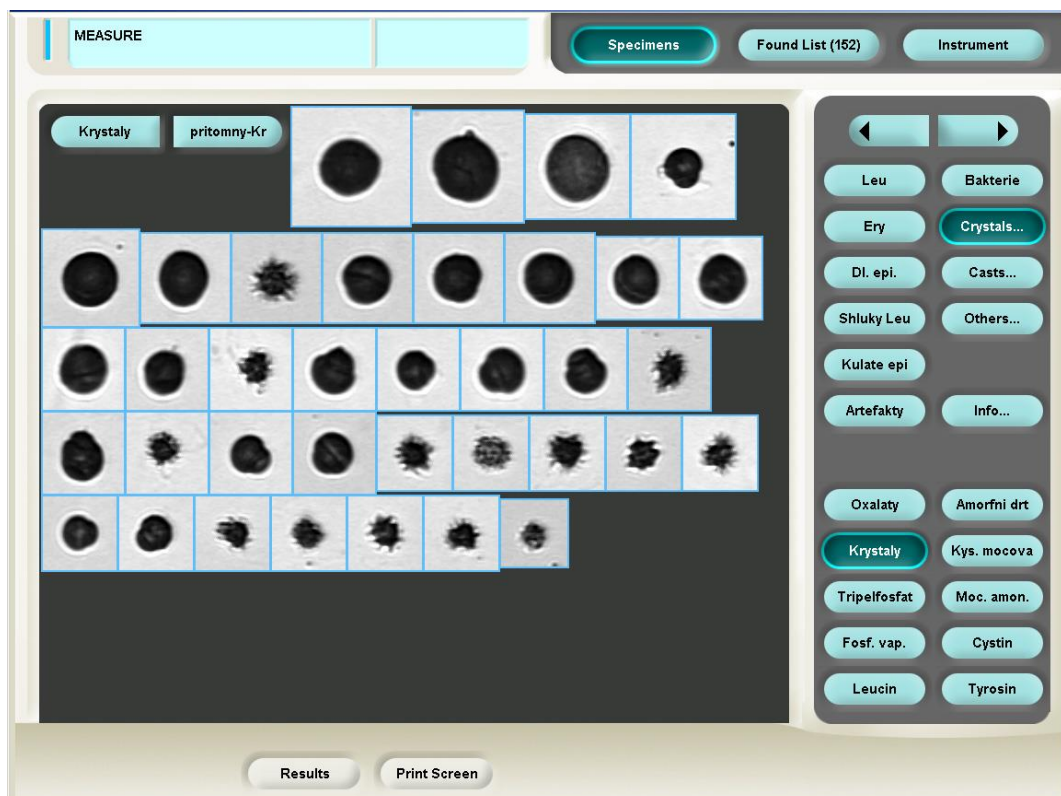


Bilirubin

Pictures from iQ 200 analyzer (IRIS)



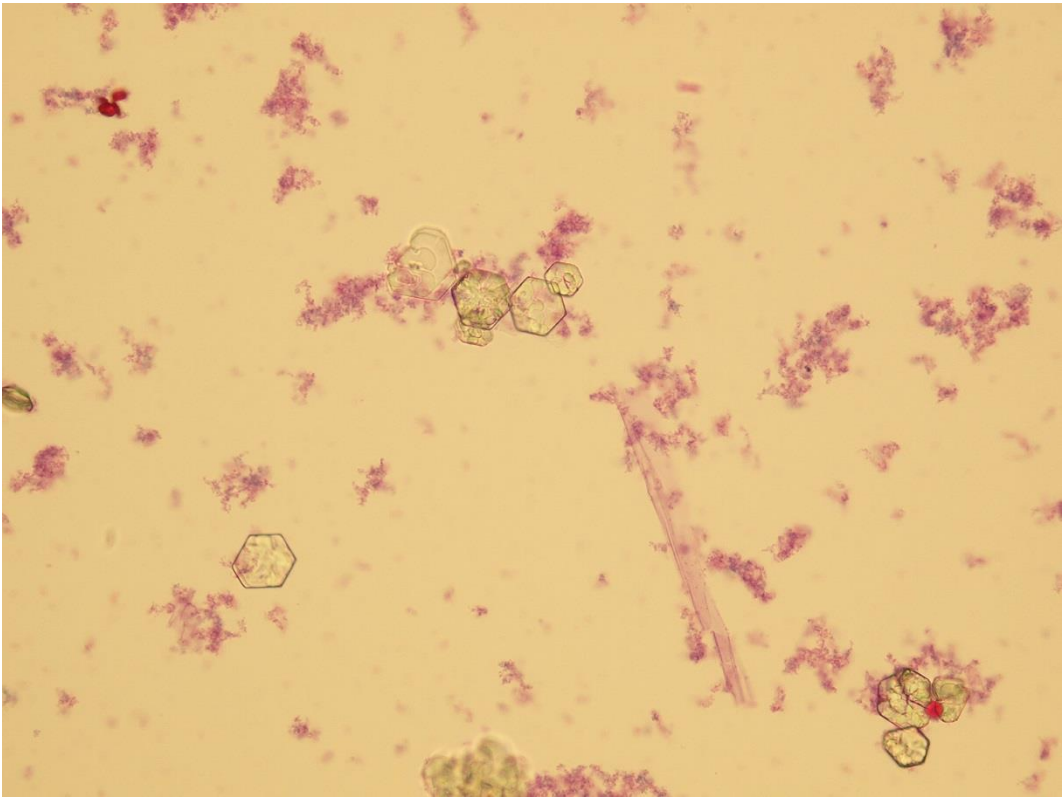
Bilirubin



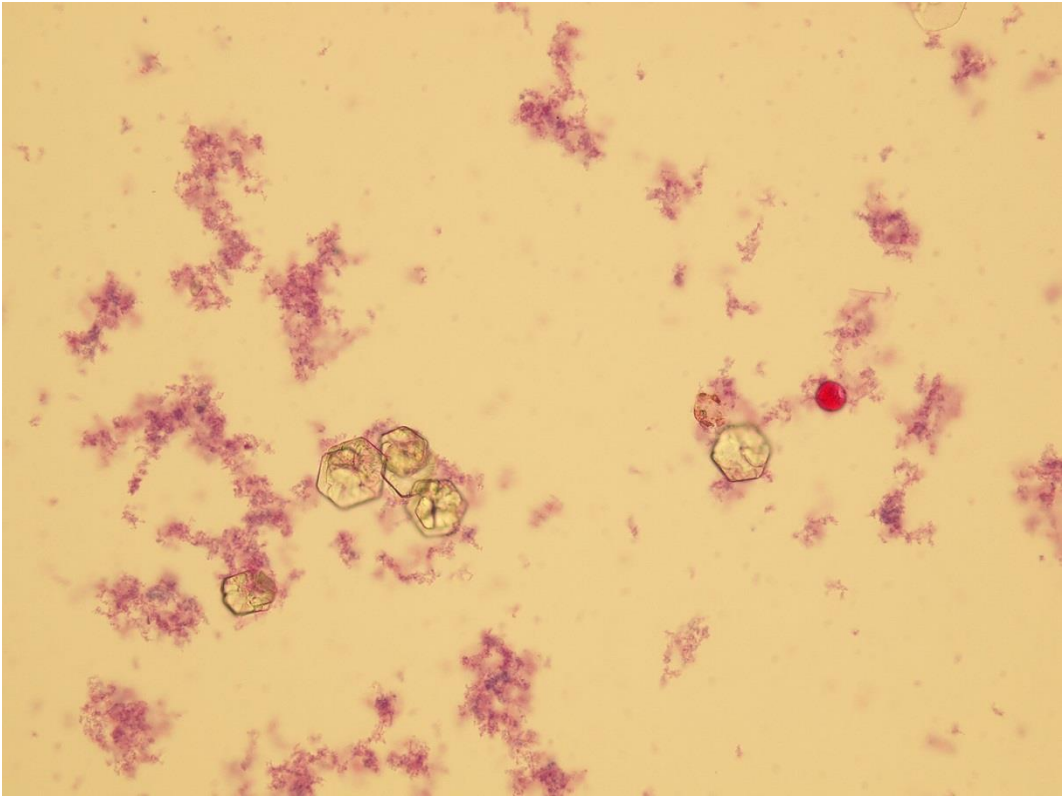
Bilirubin

Cystine

Stained sediment

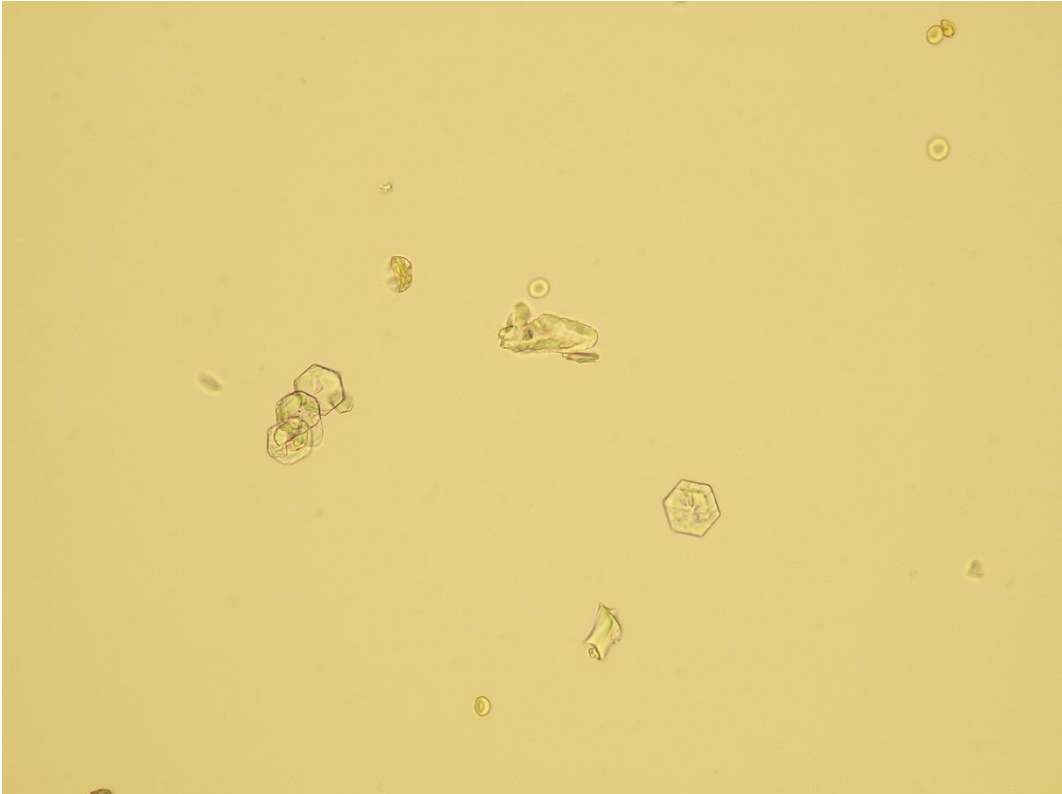


Cystine

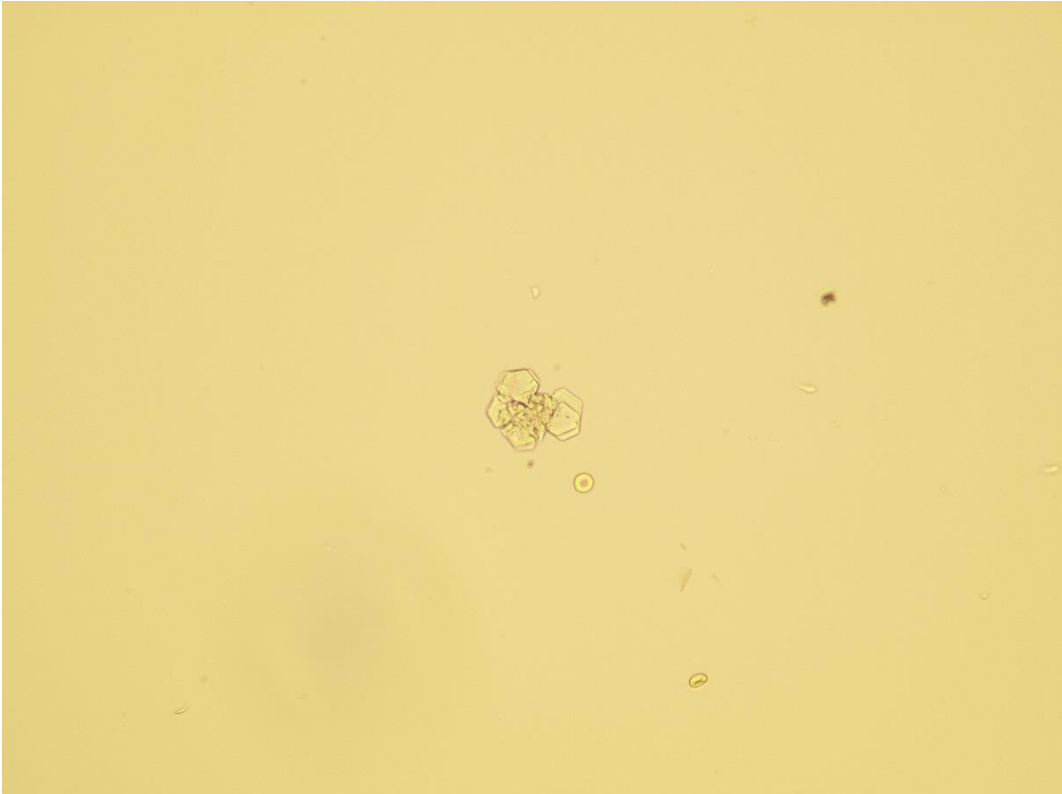


Cystine

Native sediment

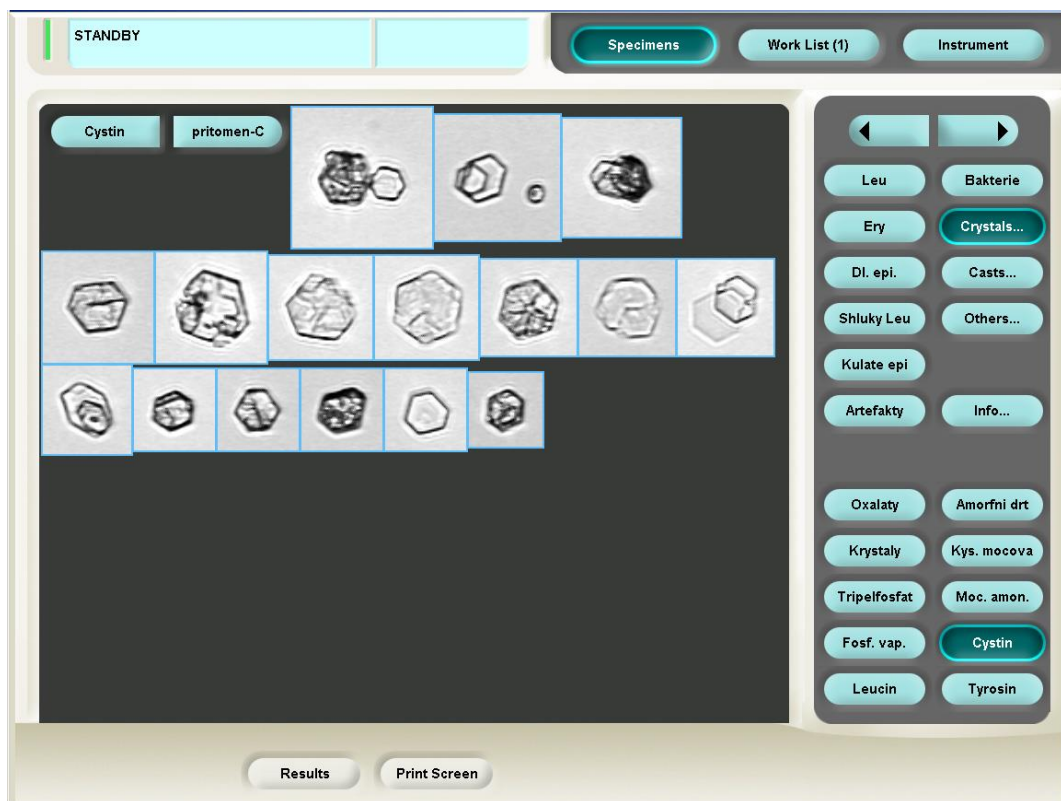


Cystine

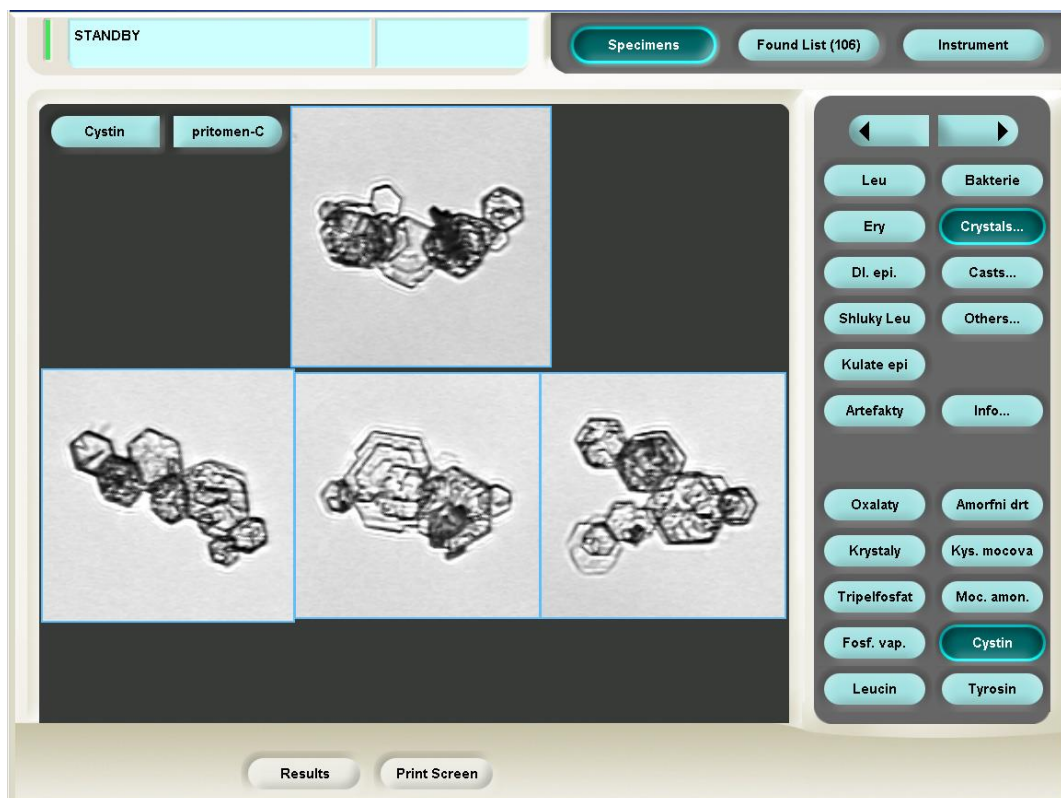


Cystine

Pictures from iQ 200 analyzer (IRIS)



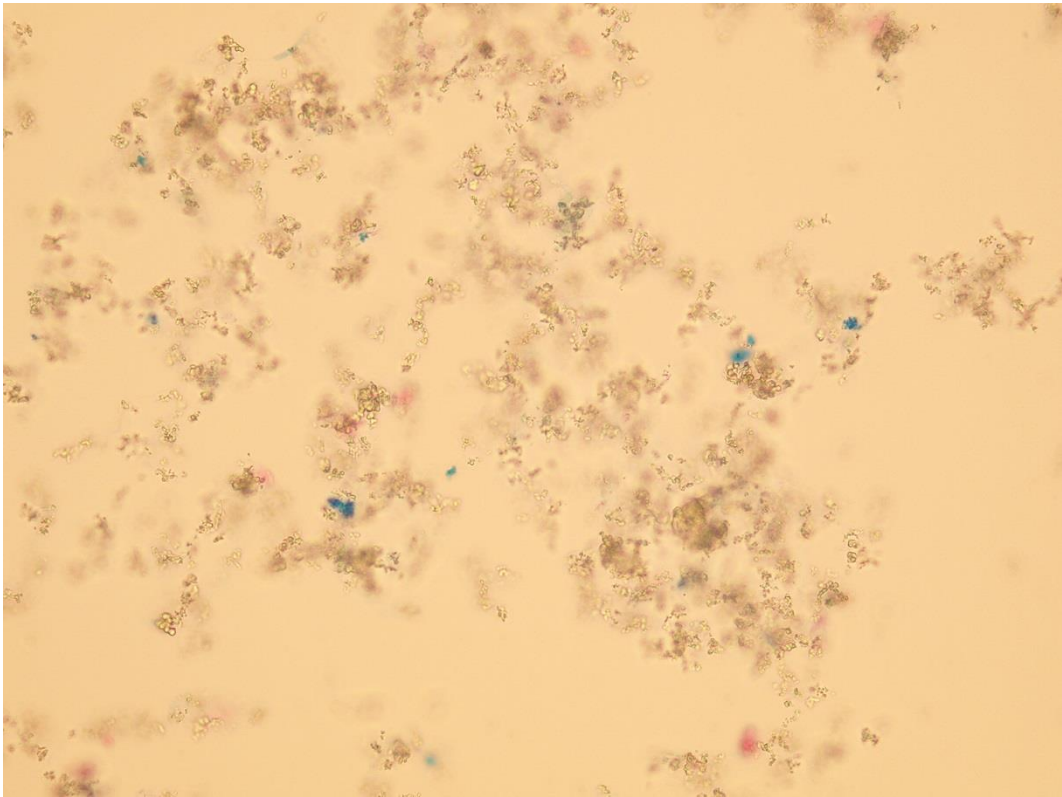
Cystine



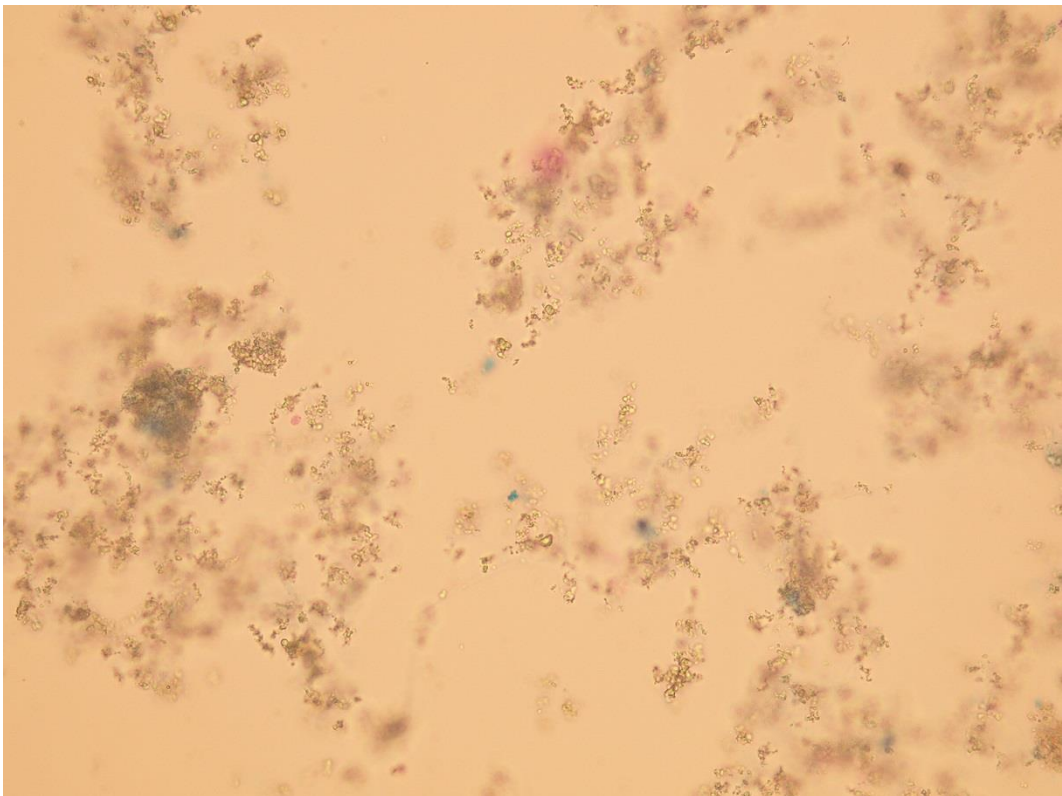
Cystine

Amorphous microcrystals

Stained sediment

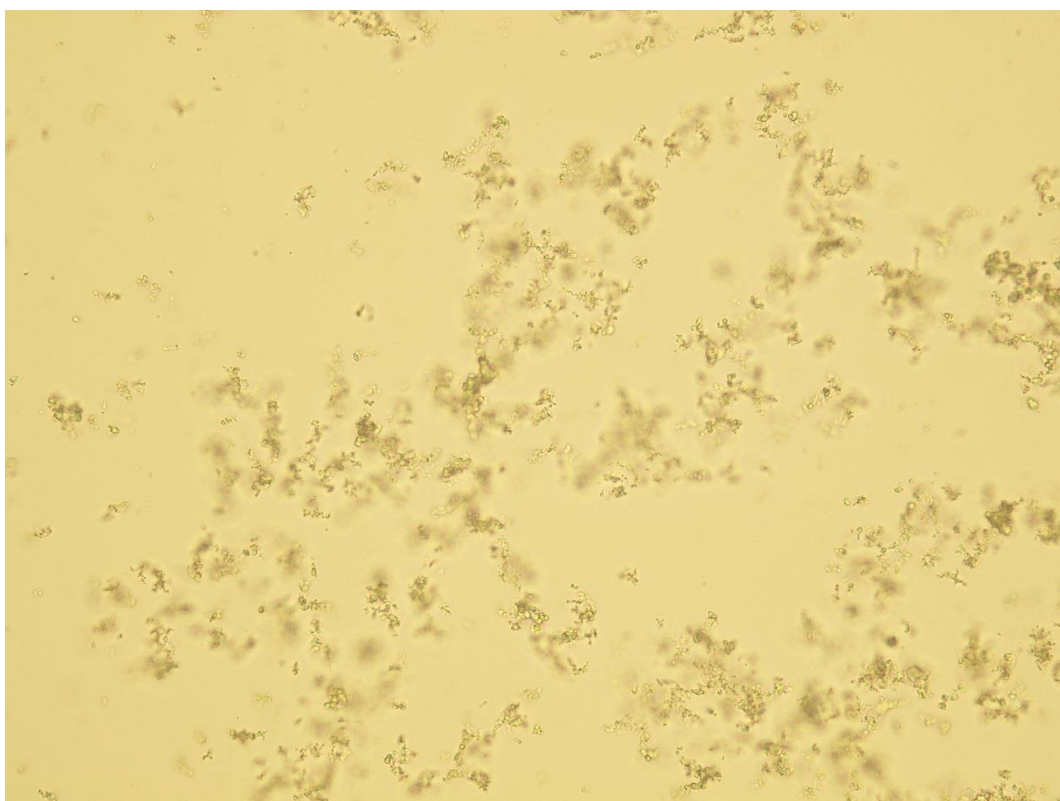


Amorphous microcrystals

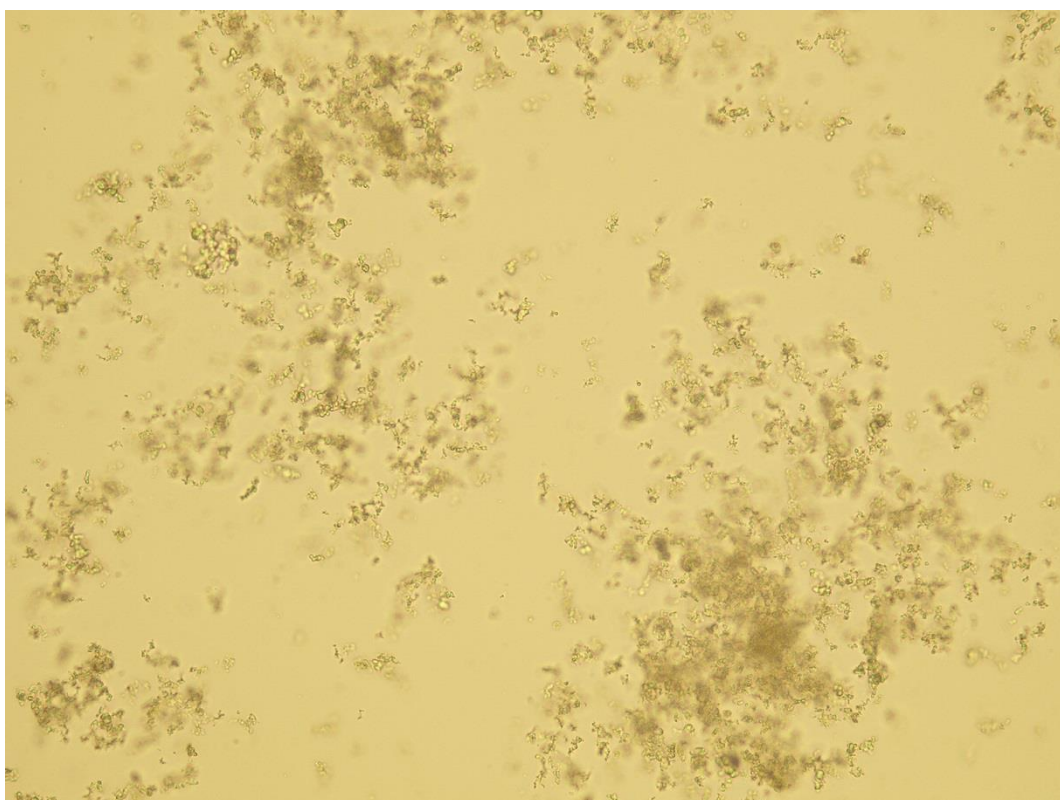


Amorphous microcrystals

Native sediment

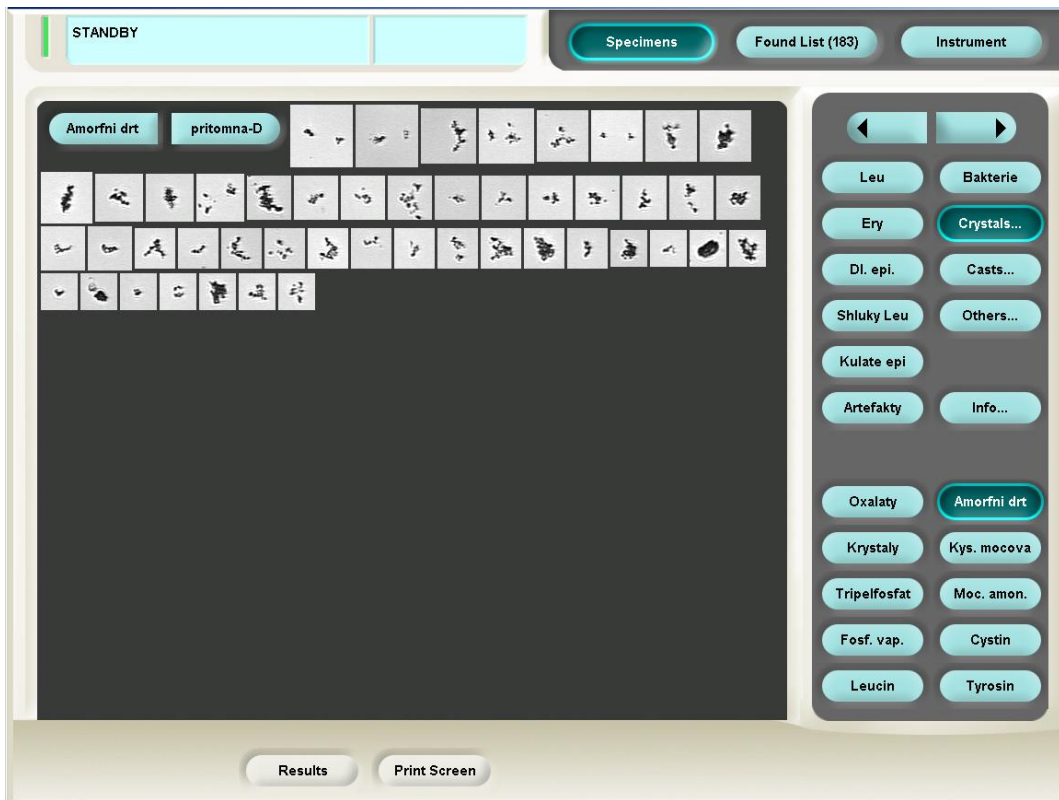


Amorphous microcrystals

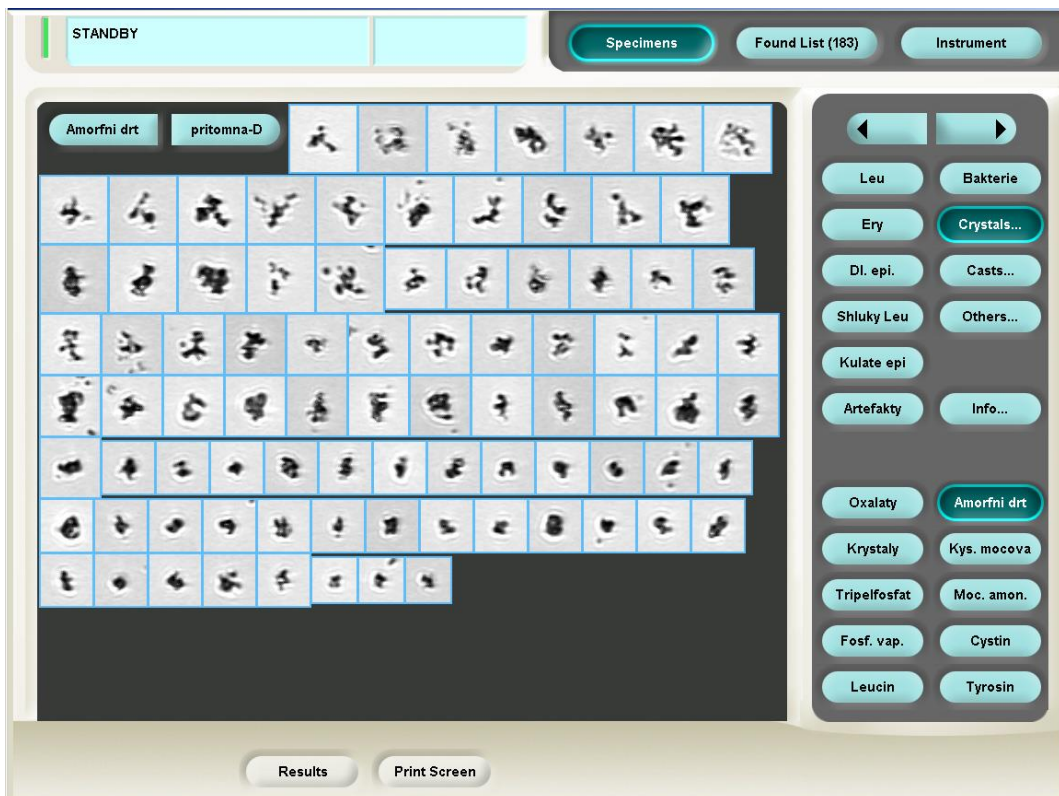


Amorphous microcrystals

Pictures from iQ 200 analyzer (IRIS)



Amorphous microcrystals



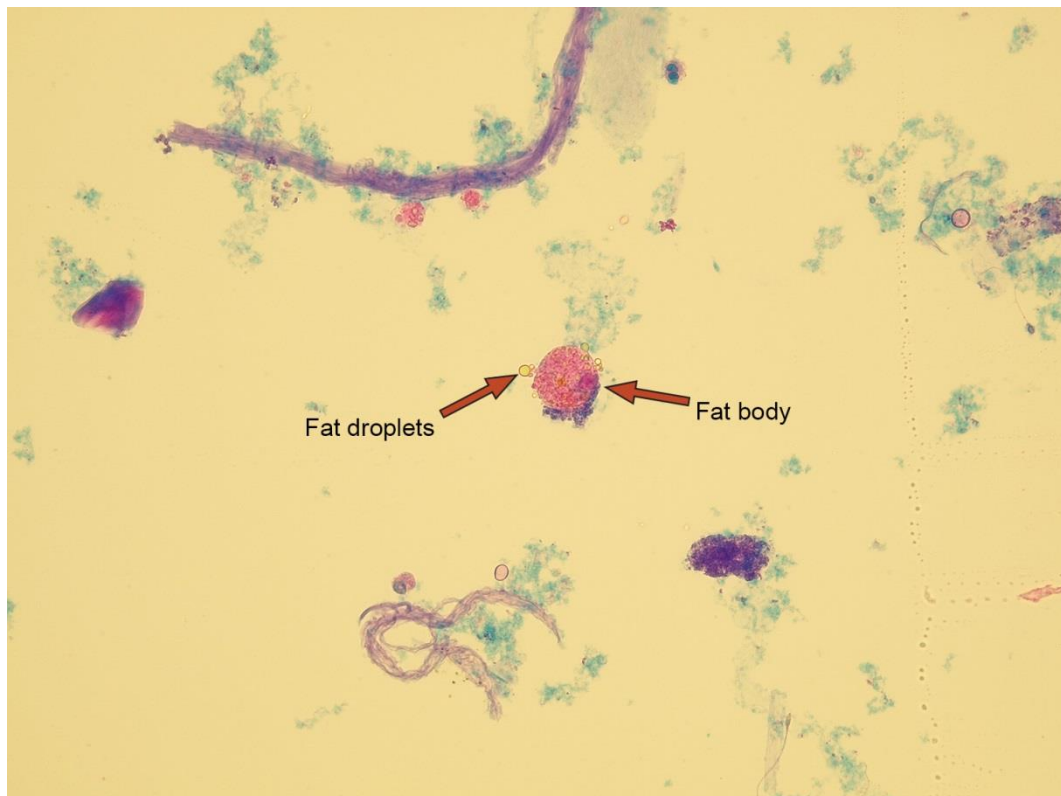
Amorphous microcrystals

Lipid particles

Oval fat bodies are renal tubular epithelial cells or macrophages filled with fat globules. The nuclei of these cells are barely visible. Fat bodies are accompanied by the presence of free fat droplets and possibly by hyaline casts with fat inclusions or fatty casts. Oval fat bodies and free fat droplets (globules) in urine are considered to be an exceptional and serious finding. The presence of fat with biological origin in urine is called lipiduria and indicates severe renal dysfunction. It is associated with serious damage and necrosis of renal epithelial cells as in nephrotic syndrome, advanced diabetes mellitus or some kinds of poisoning.

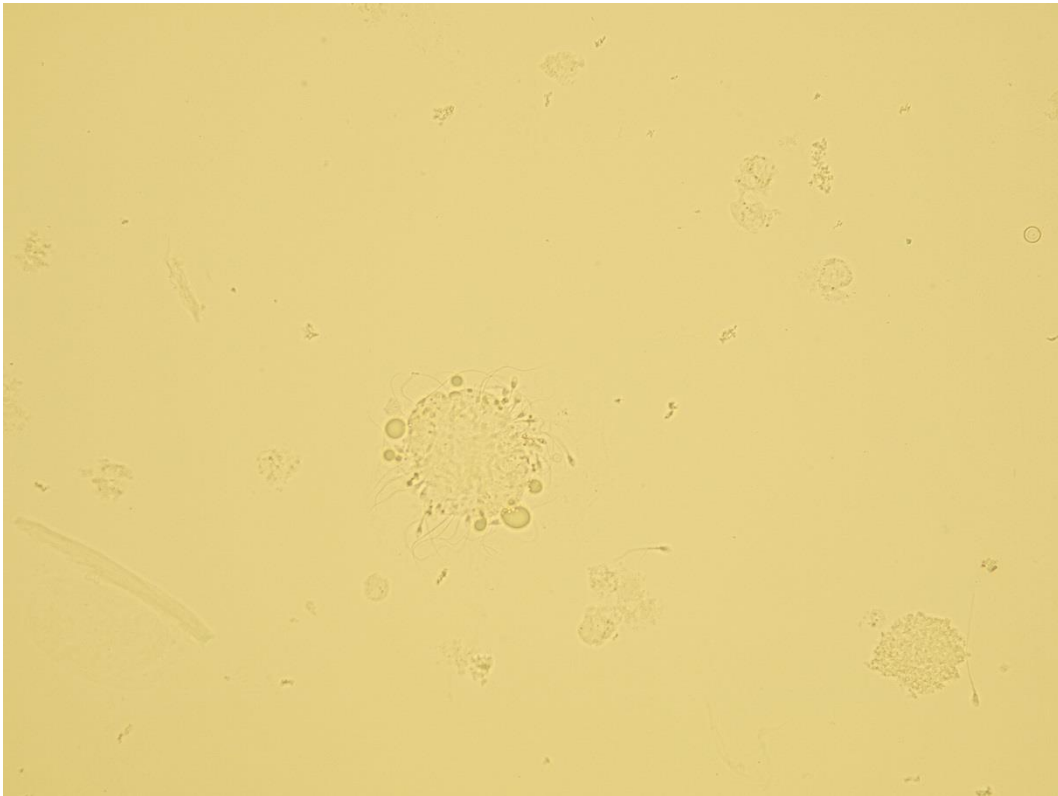
Fat globules may be seen in the urine as a contamination from oiled catheter or vaginal creams. There are no fat bodies and casts in sample in this case. Examples are shown in the Artifacts category.

Stained sediment



Macrophage and fat droplets

Native sediment



Macrophage with fat droplets and sperm

Pictures from iQ 200 analyzer (IRIS)

A screenshot of the iQ 200 analyzer (IRIS) interface. The top bar shows 'STANDBY' and navigation buttons for 'Specimens', 'Found List (123)', and 'Instrument'. The main area displays a grid of microscopic images of 'Kulate epi' at a concentration of '10 /uL'. The images show various cellular structures. On the right, there is a control panel with buttons for 'Leu', 'Bact', 'Ery', 'Crystals...', 'DI. epi.', 'Casts...', 'Shluky Leu', 'Others...', 'Kulate epi', 'Artefakty', and 'Info...'. Below the control panel, there is a data panel with the following information:

<<Released>>
8402730275
2012-02-01 09:19:10
632612619)
1:1

All Small Particles: 16673uL

| | | |
|---|------|----------|
| H | GLU | Normal |
| | PRD | +4 |
| | BIL | - |
| | URO | Normal |
| | PH | 6.5 |
| H | Krev | +3 |
| | KET | - |
| | NIT | Negative |
| H | LEU | +1 |
| H | CLA | Turbid |
| | SPGR | 1.017 |
| | CDL | Yellow |

Cleared flags:
HIGH CONCENTRATION
Possible Amorphous

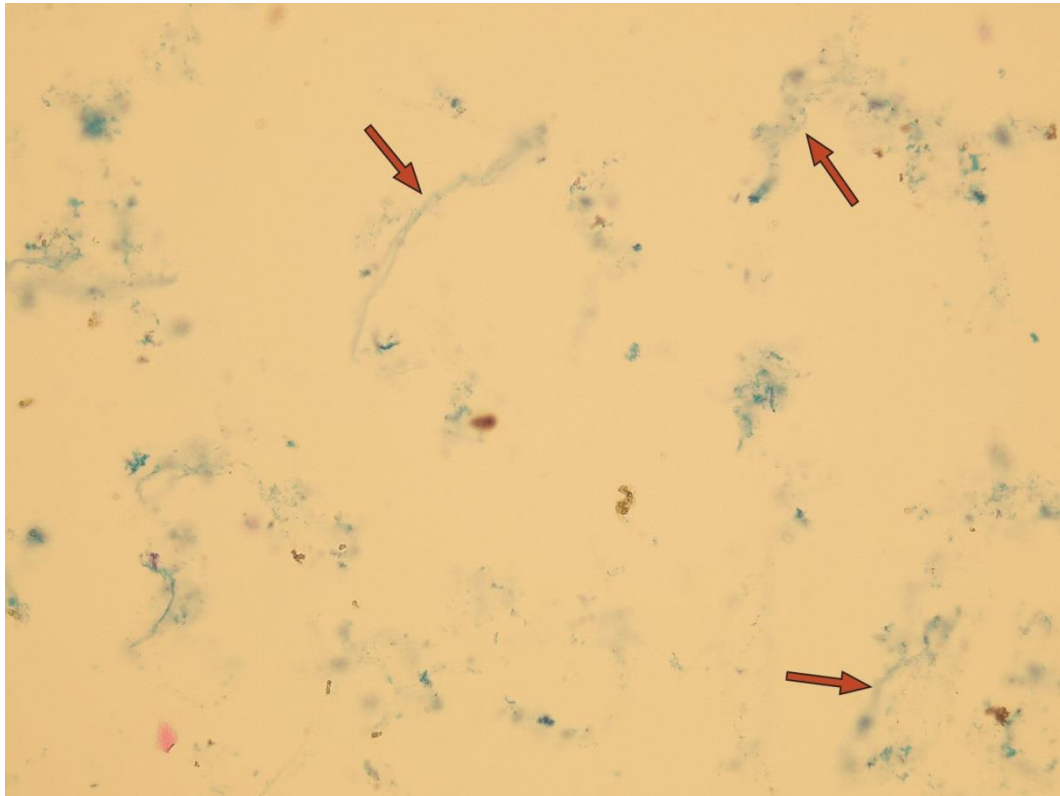
At the bottom, there are 'Results' and 'Print Screen' buttons.

Oval fat bodies

Mucus

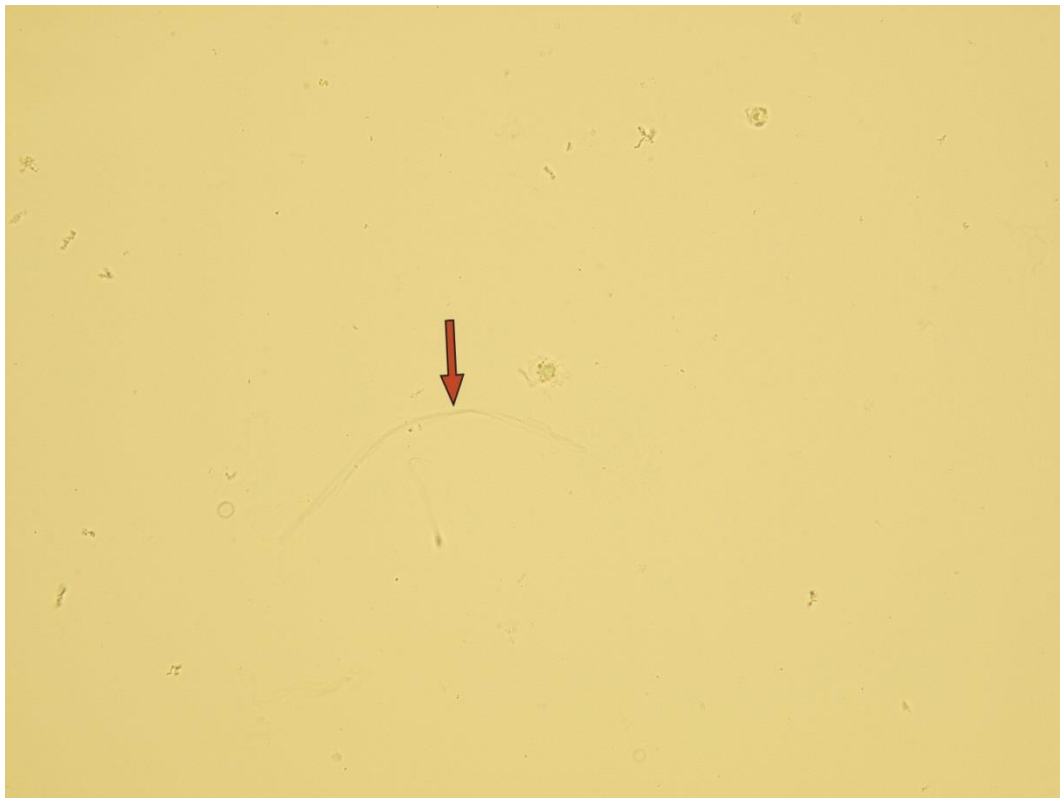
Mucus is secreted by glands in urinary tract and vagina. Its quantity could be increased with inflammatory conditions. It is common constituent in urine with no diagnostic significance.

Stained sediment



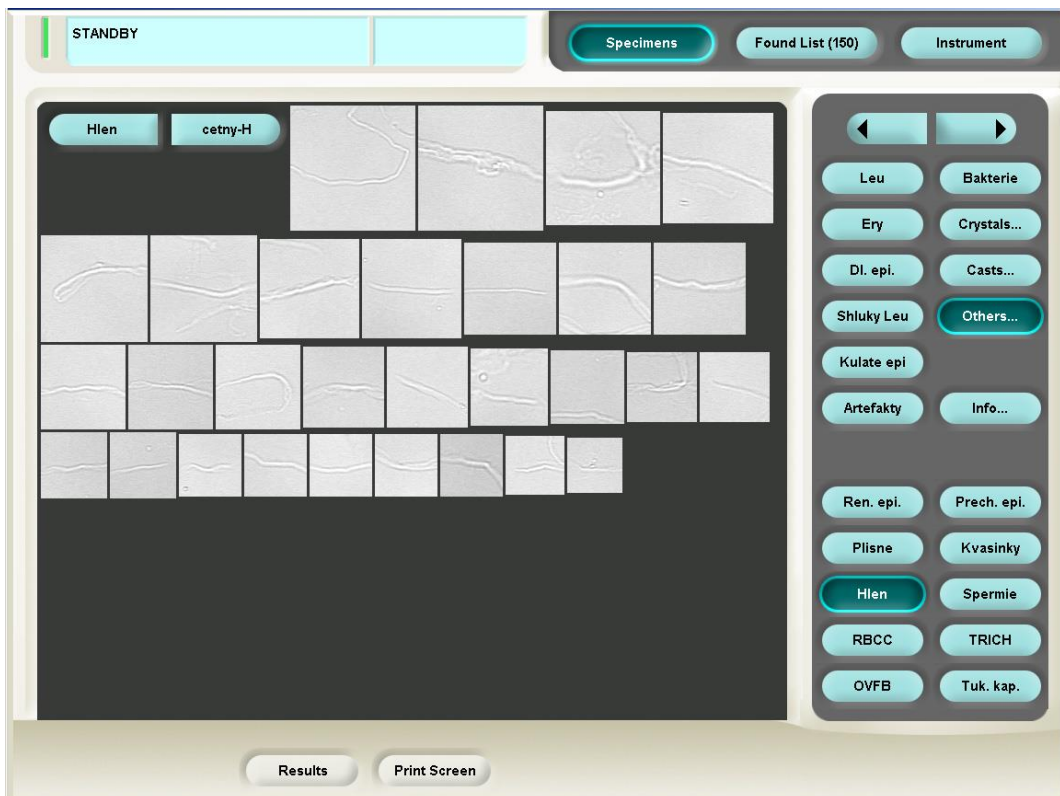
Mucus

Native sediment



Mucus

Pictures from iQ 200 analyzer (IRIS)

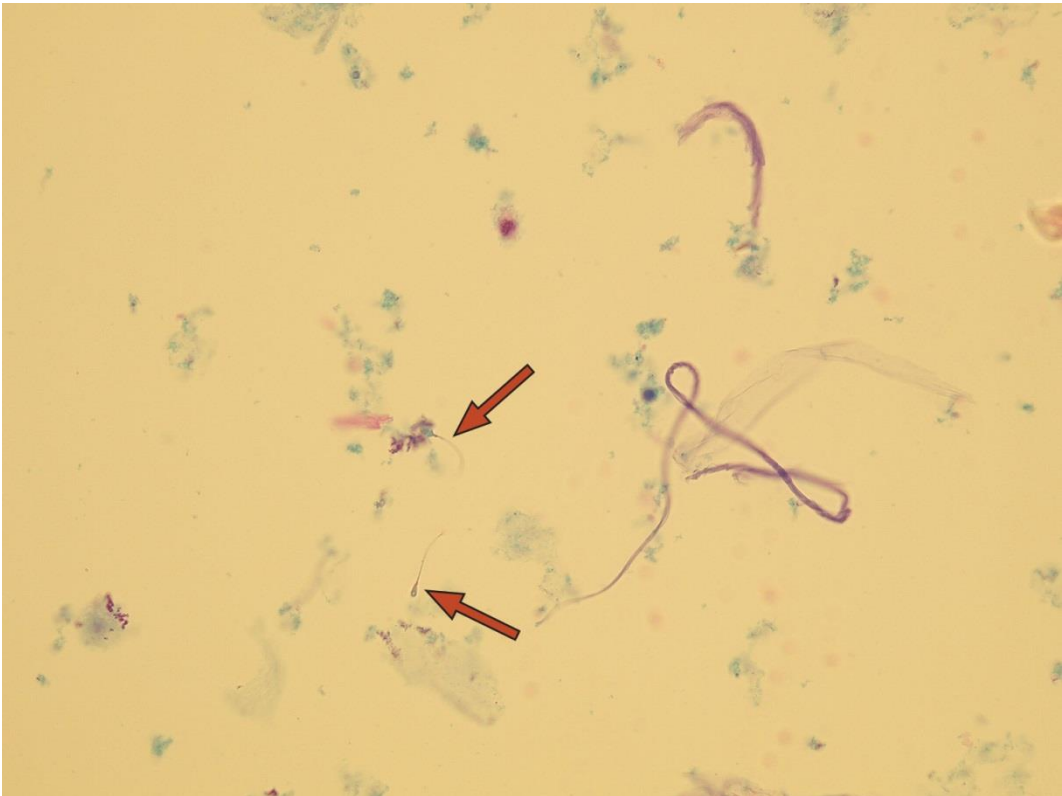


Mucus

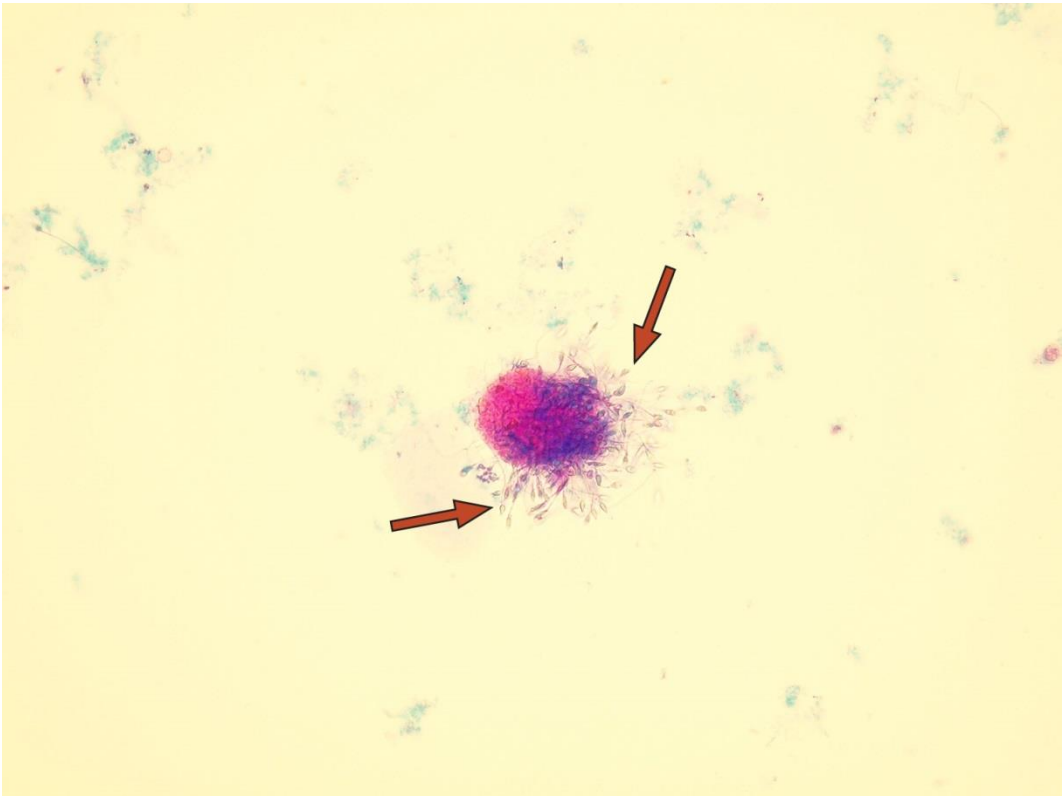
Sperms

The finding of sperms is common in man's urine. It is insignificant in women's samples as long as they are not underage girls.

Stained sediment

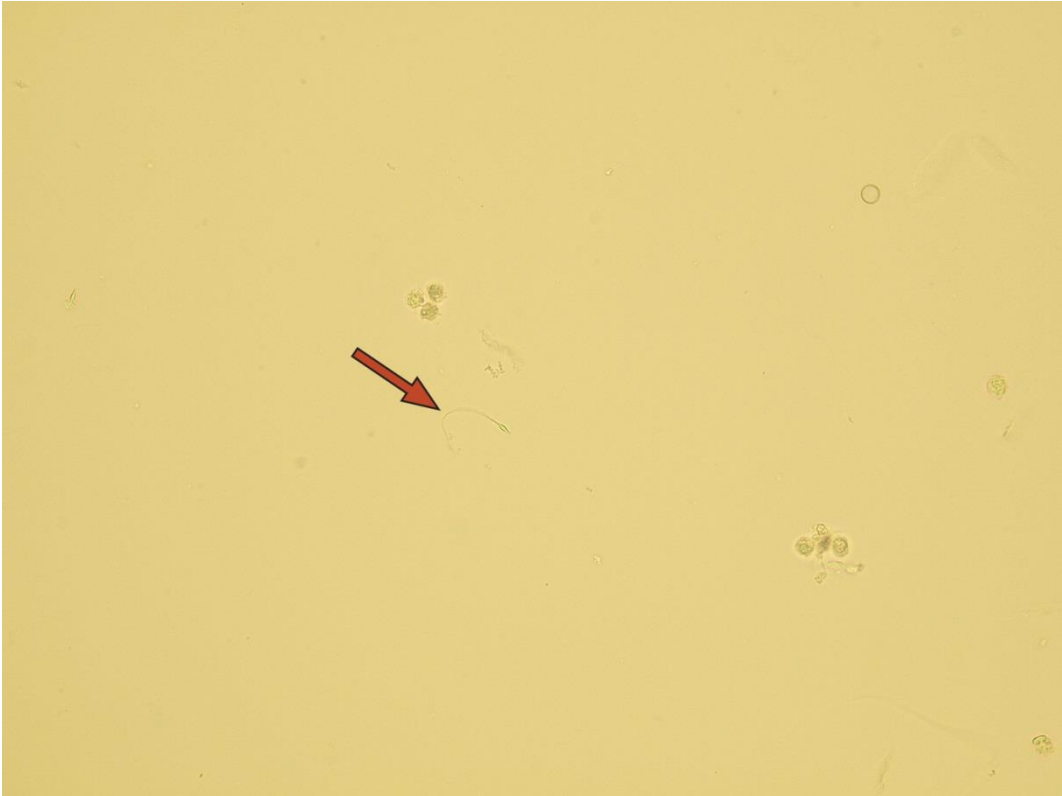


Sperms




Sperms

Native sediment

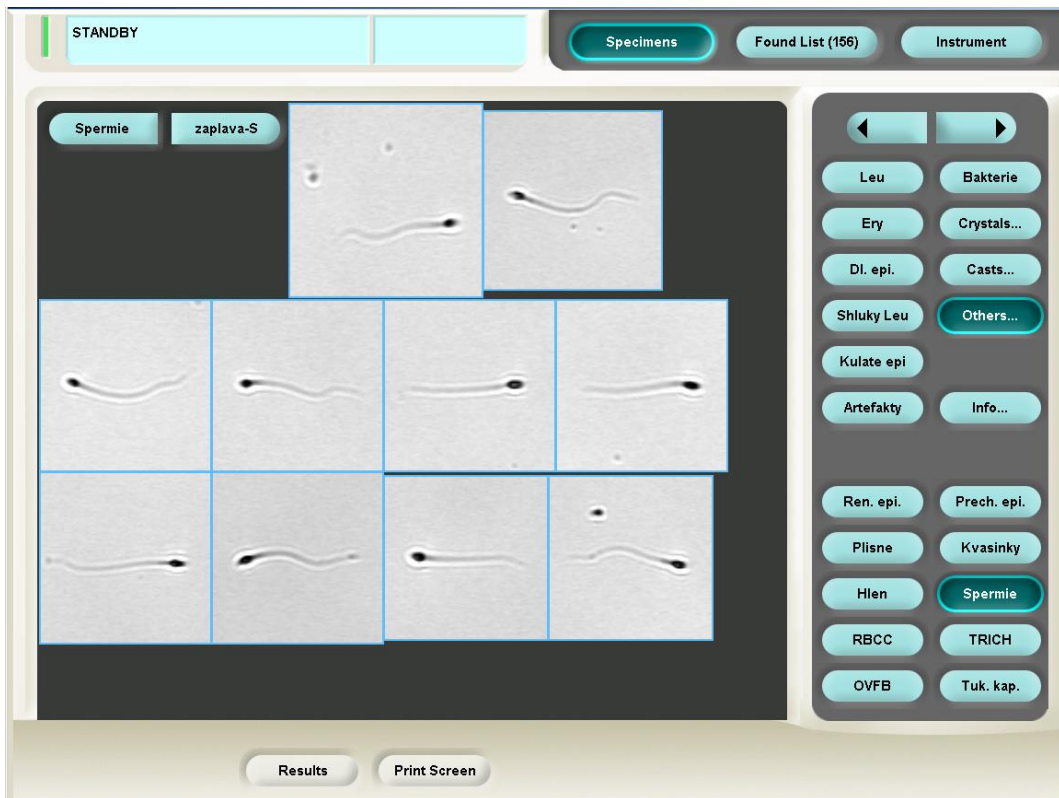


Sperms

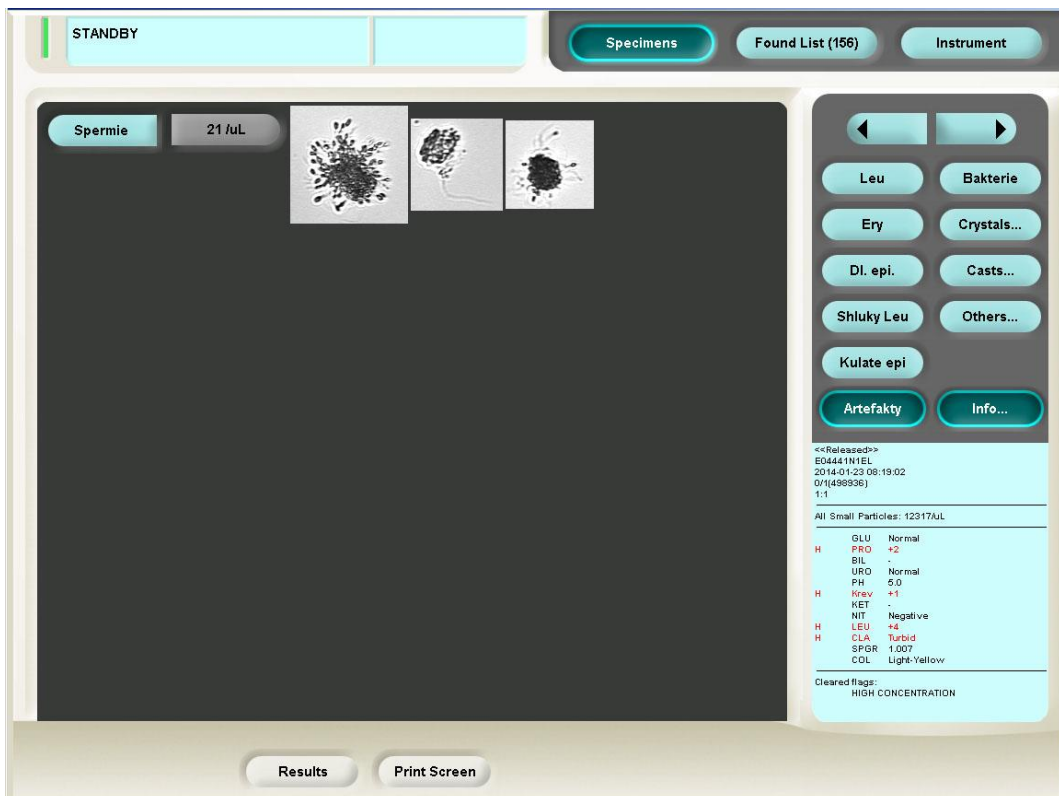


Sperms

Pictures from iQ 200 analyzer (IRIS)



Sperms

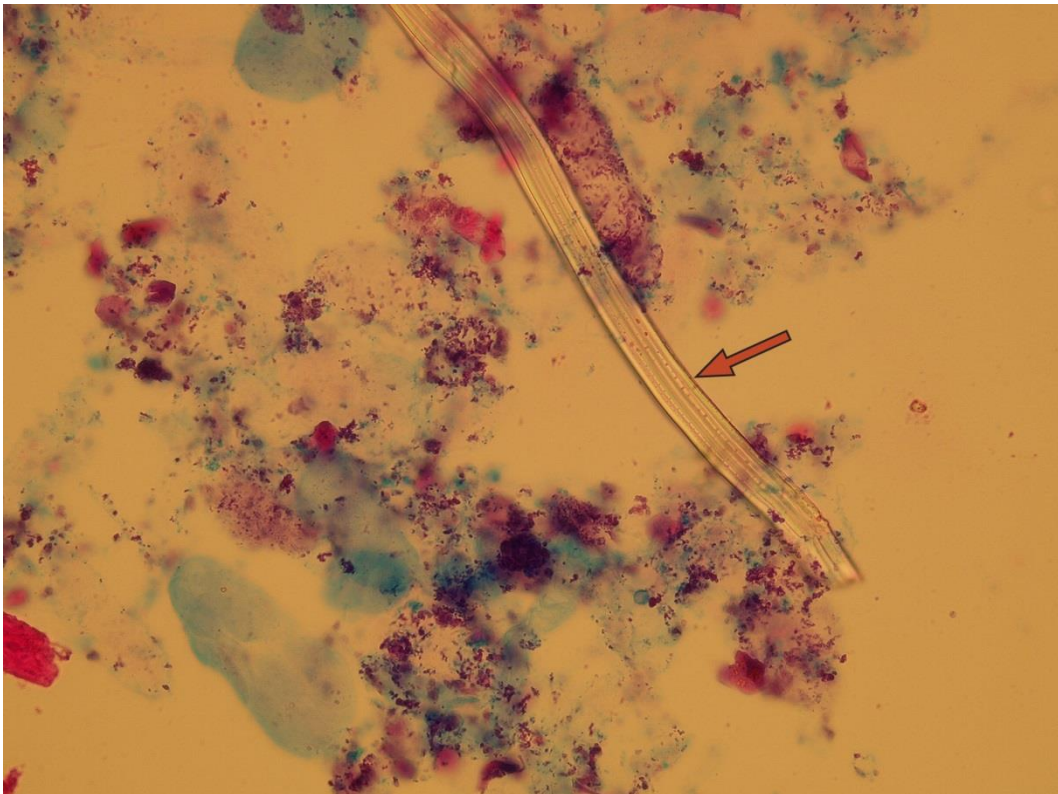


Sperms

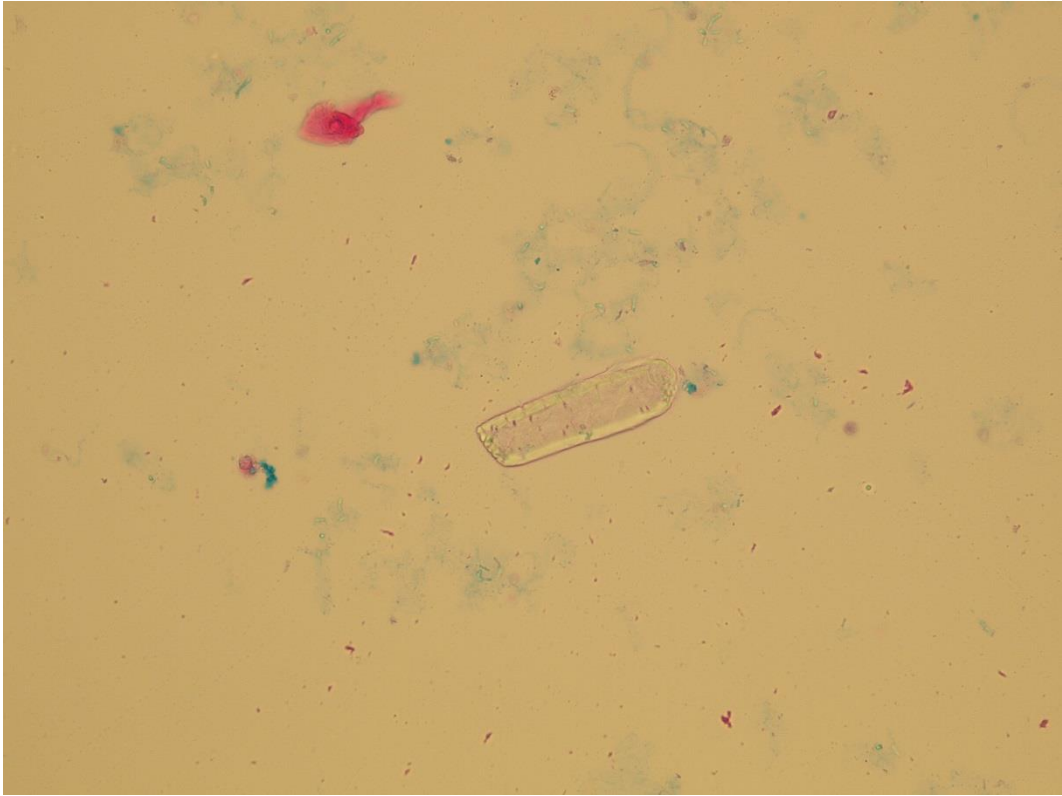
Artifacts

We can find some elements in urine that don't come from patient's body. They have no clinical significance, but it is important to recognize them to avoid confusion with another element. They can have various shapes. Textile and paper fibers and oil droplets are the most common artifacts.

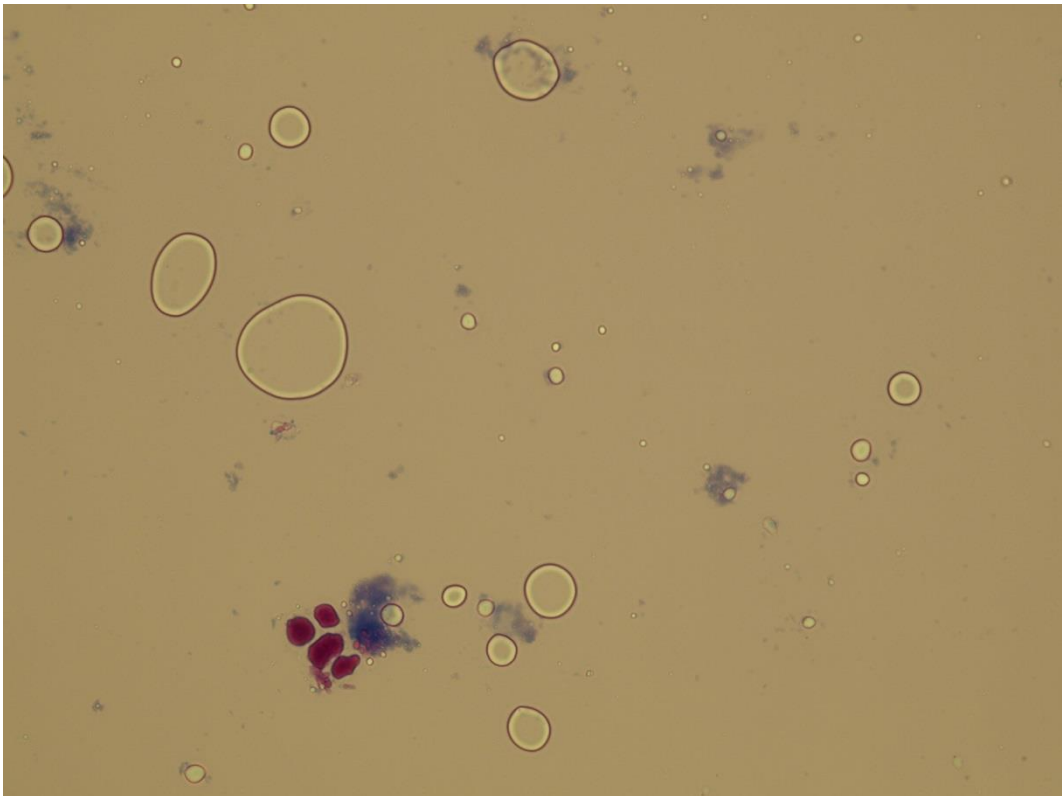
Stained sediment



Artifact

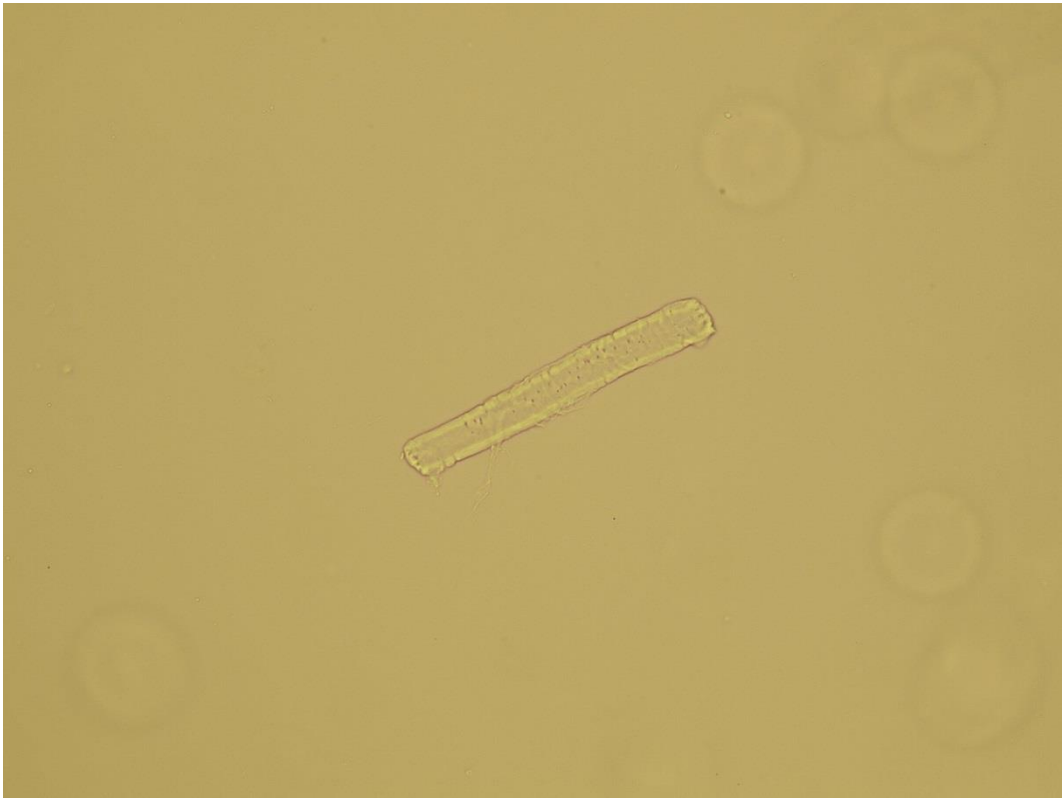


Artifact




Fat droplets (artificial contamination)

Native sediment

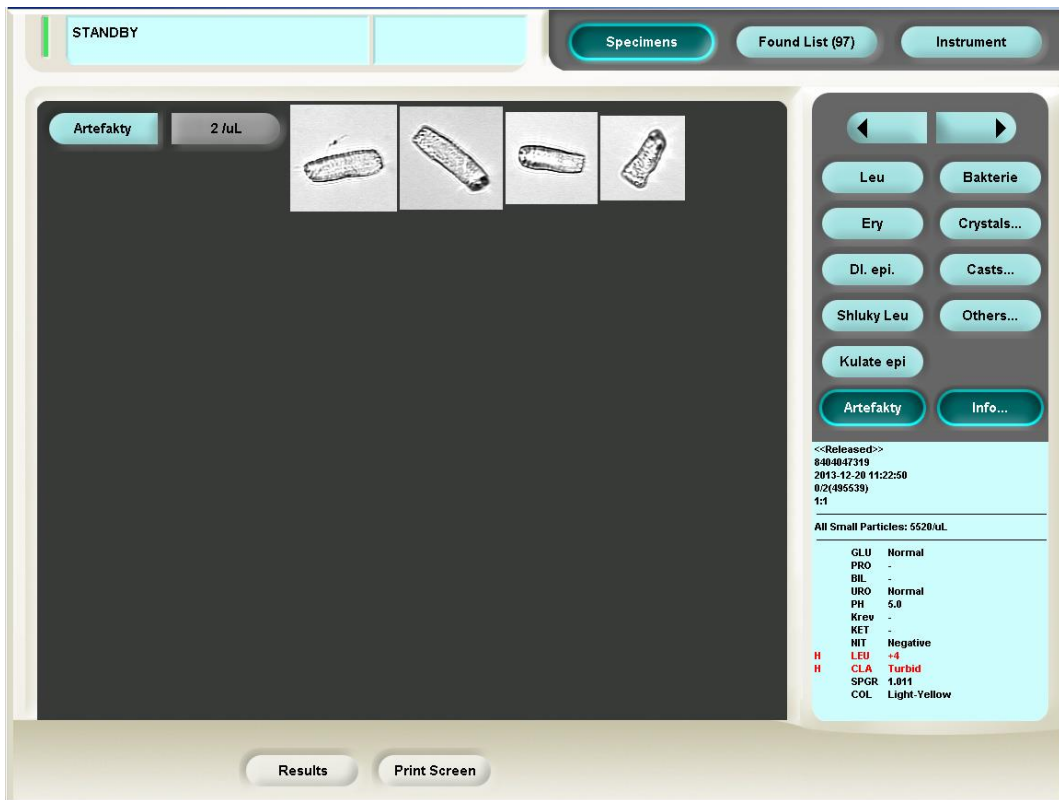


Artifact

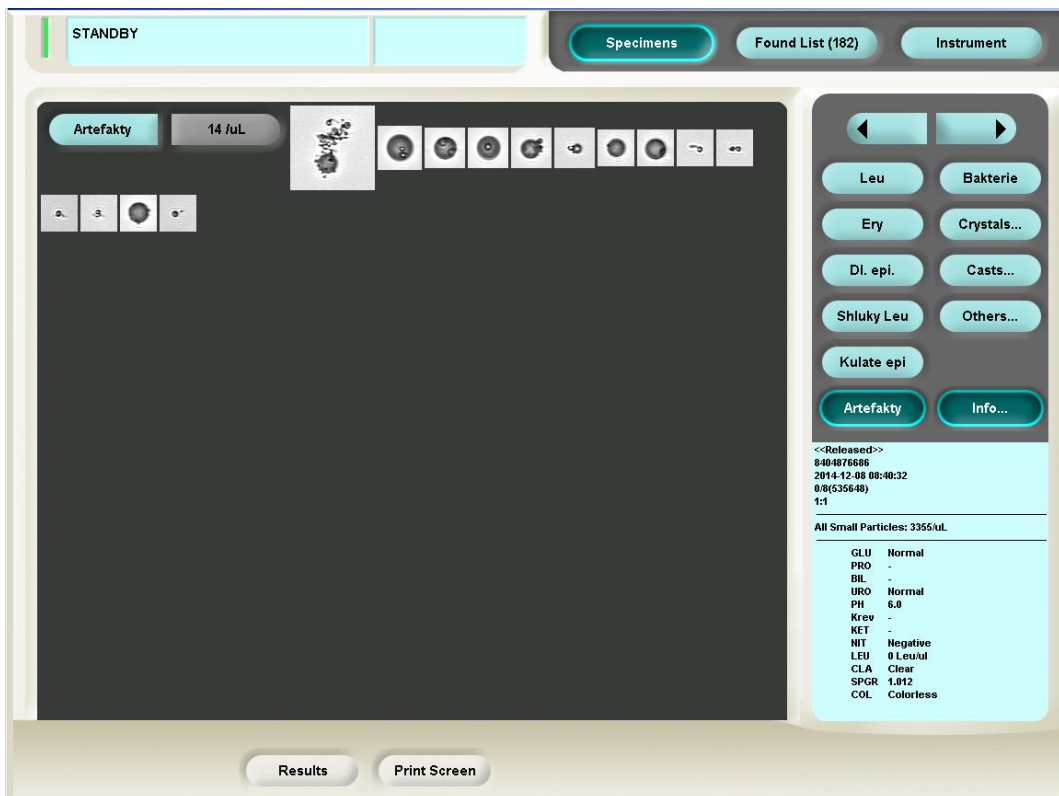


Fat droplets (artificial contamination)

Pictures from iQ 200 analyzer (IRIS)



Artifact



Fat droplets (artificial contamination)

Interesting findings

Erythrocytes x yeast

Occasionally, it is difficult to distinguish between single yeast and erythrocyte due to their similar shape and size in the pictures from automatic analyzer and in native sediment. The stained sediment can be used for determinative analysis, because erythrocytes are typically stained pink, but yeasts are colorless.

STANDBY

Specimens Found List (226) Instrument

Ery 412 /uL

Leu Bakterie
Ery Crystals...
Dl. epi. Casts...
Shluky Leu Others...
Kulate epi
Artefakty Info...

<<Released>>
8404071477
2014-01-06 10:01:08
6/5(496717)
1:1

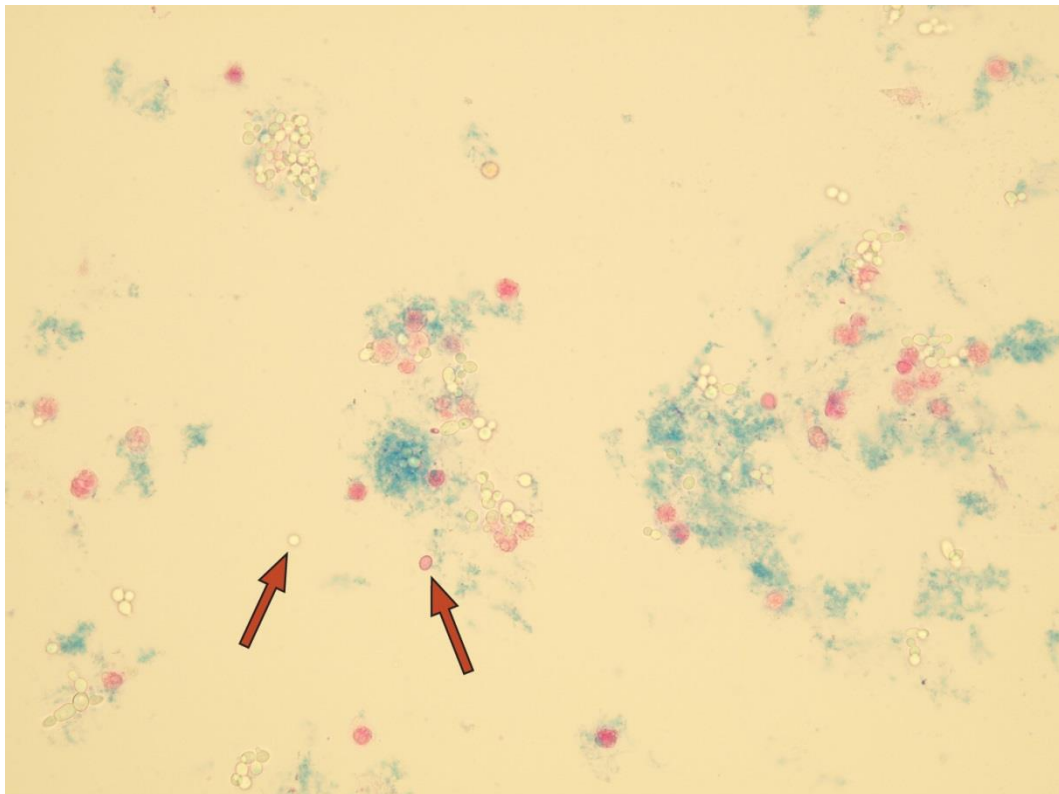
All Small Particles: 8226/uL

| | | |
|---|------|----------|
| H | GLU | Normal |
| | PRO | +2 |
| | BL | - |
| | URO | Normal |
| | PH | 6.0 |
| H | krev | +1 |
| | KET | - |
| | NIT | Negative |
| H | LEU | +6 |
| H | CLA | Turbid |
| | SPGR | 1.016 |
| | COL | Yellow |

Cleared flags:
HIGH CONCENTRATION
Possible Amorphous

Results Print Screen

Erythrocytes and yeast together



Erythrocytes and yeast together

Erythrocytes x oxalates

If erythrocytes and oxalates are both in urine, it is sometimes difficult to distinguish them in the automatic analyzer properly due to their similar size and shape. This applies particularly to calcium oxalate monohydrate (ovoid form). In the stained sediment on the other hand, the erythrocytes are pink and oxalates colorless.

MEASURE

Specimens Found List (191) Instrument

Ery 49 /uL

18.2 microns

Leu Bact
Ery Crystals...
DI. epi. Casts...
Shlucky Leu Others...
Kulate epi
Artefakty Info...

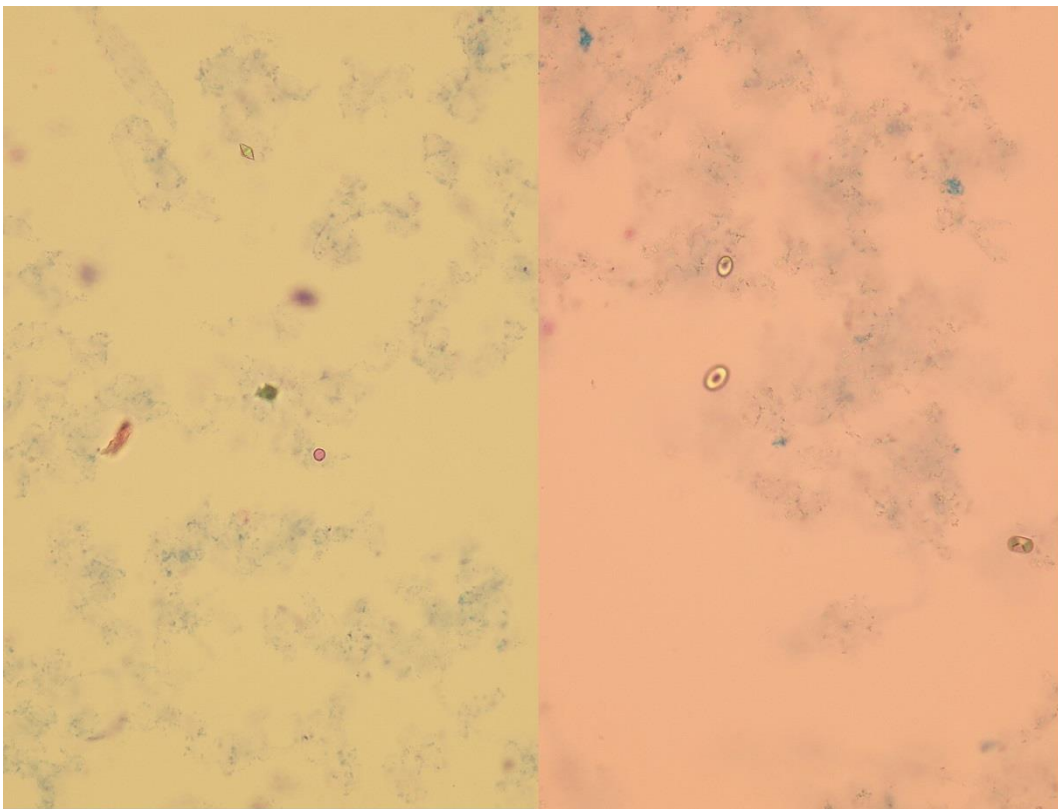
<<Released>>
E04457.HCL
2012-01-19 08:21:31
07(410910)
1:1

All Small Particles: 15091/uL

| | | |
|---|------|----------|
| H | GLU | Normal |
| | PRO | +- |
| | BIL | - |
| | URO | Normal |
| | PH | 6.8 |
| | Krev | - |
| | KET | - |
| | NIT | Negative |
| | LEU | 0 Leu/uL |
| H | CLA | Turbid |
| | SPGR | 1.029 |
| | COL | Yellow |

Results Print Screen

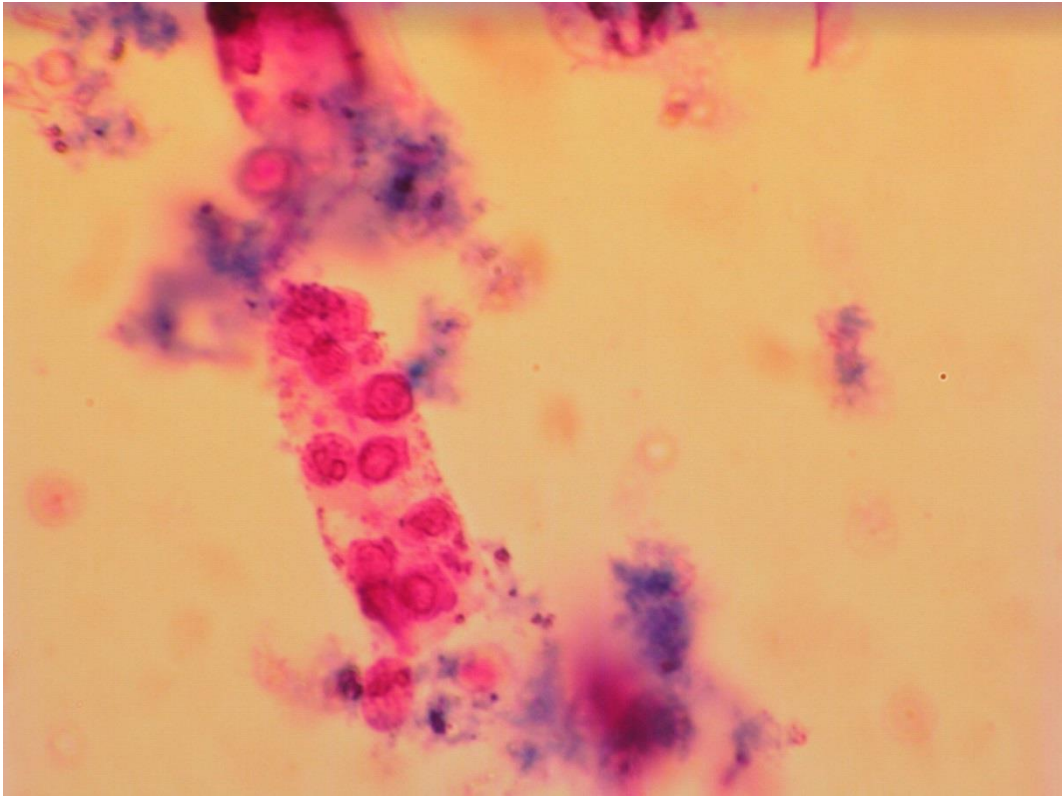
Calcium oxalate mono and dihydrate crystals next to erythrocytes automatically classified as erythrocytes in iQ 200



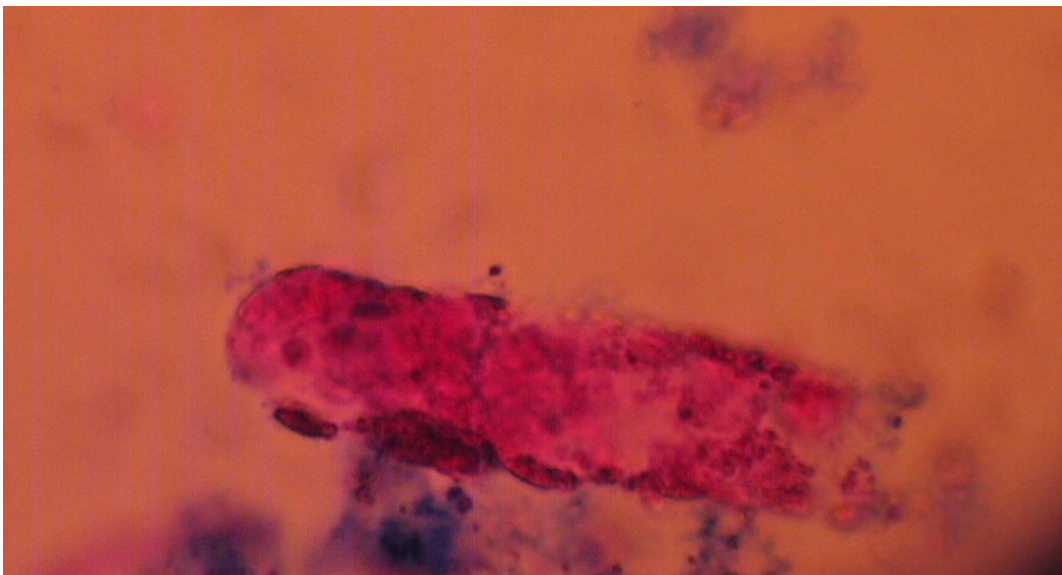Oxalate dihydrate crystals with an erythrocyte; oxalate crystals

The gradual transformation of pathological casts

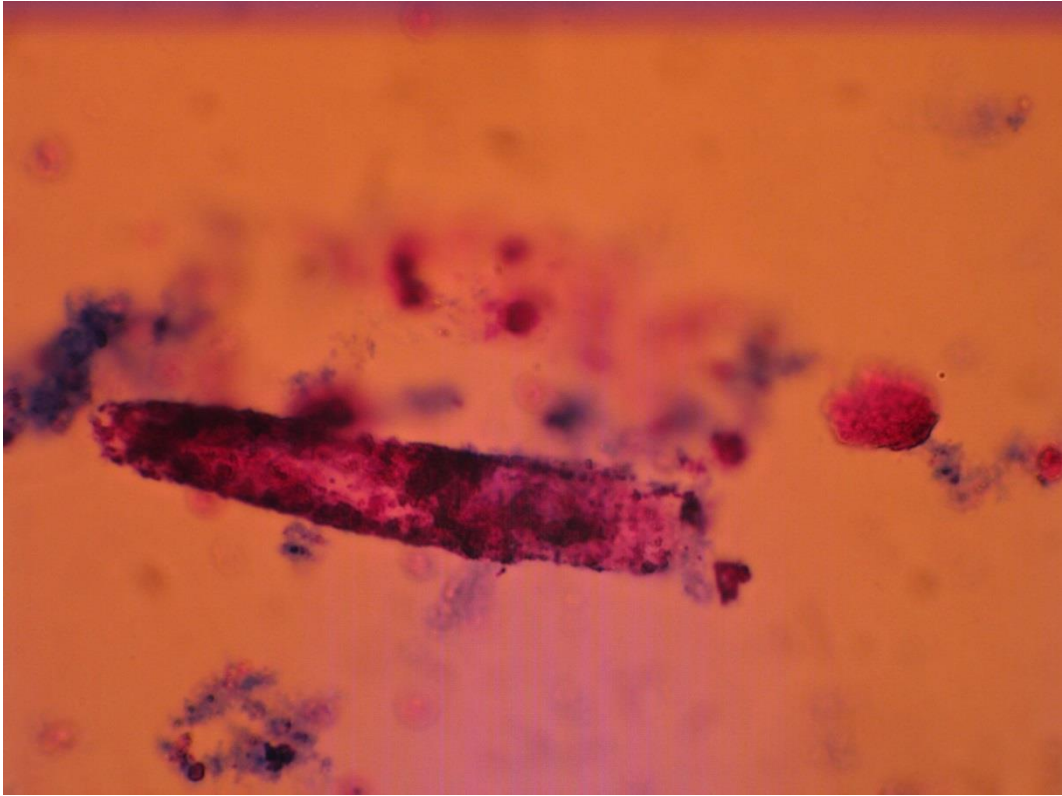
Exceptionally, all stages of cast transformations could be observed in one sample.



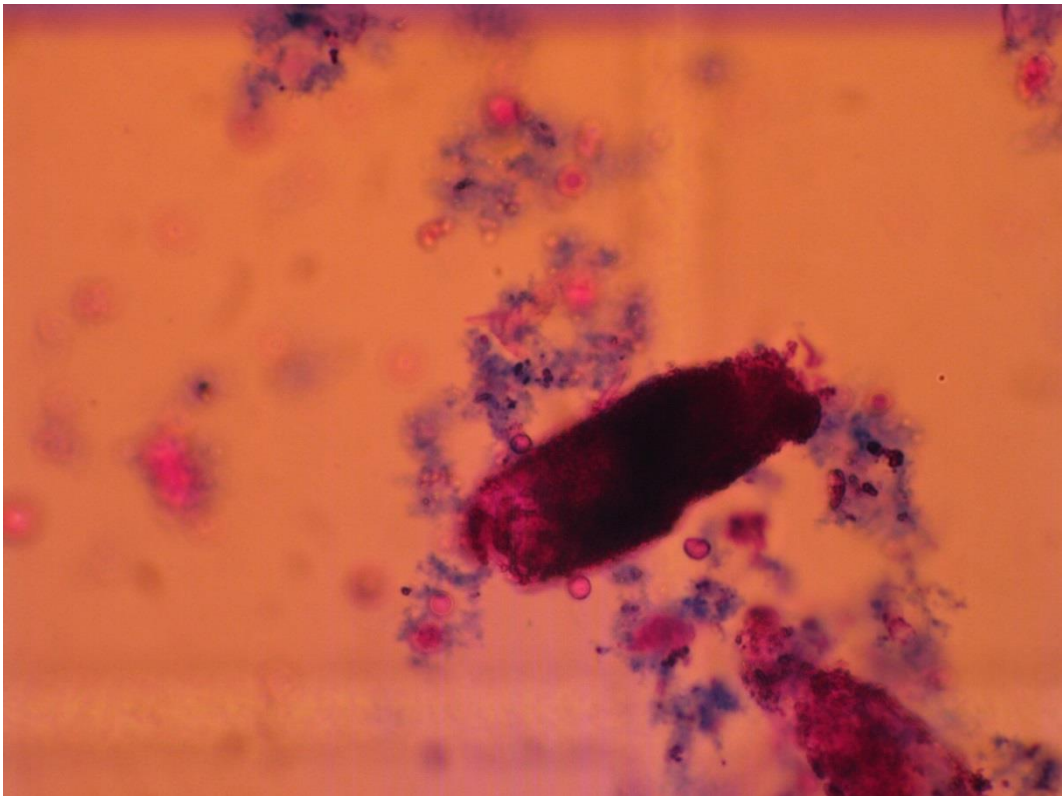
Cellular cast



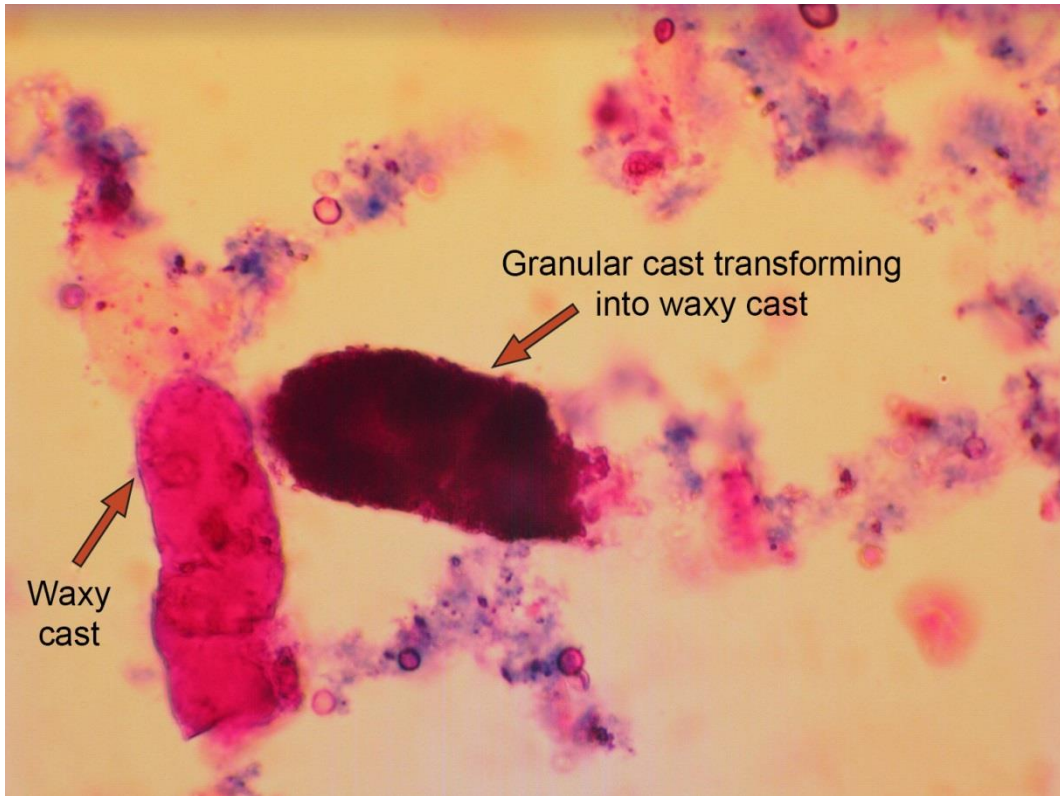
Transition phase of cast from cellular to granular (enlargement ×600)



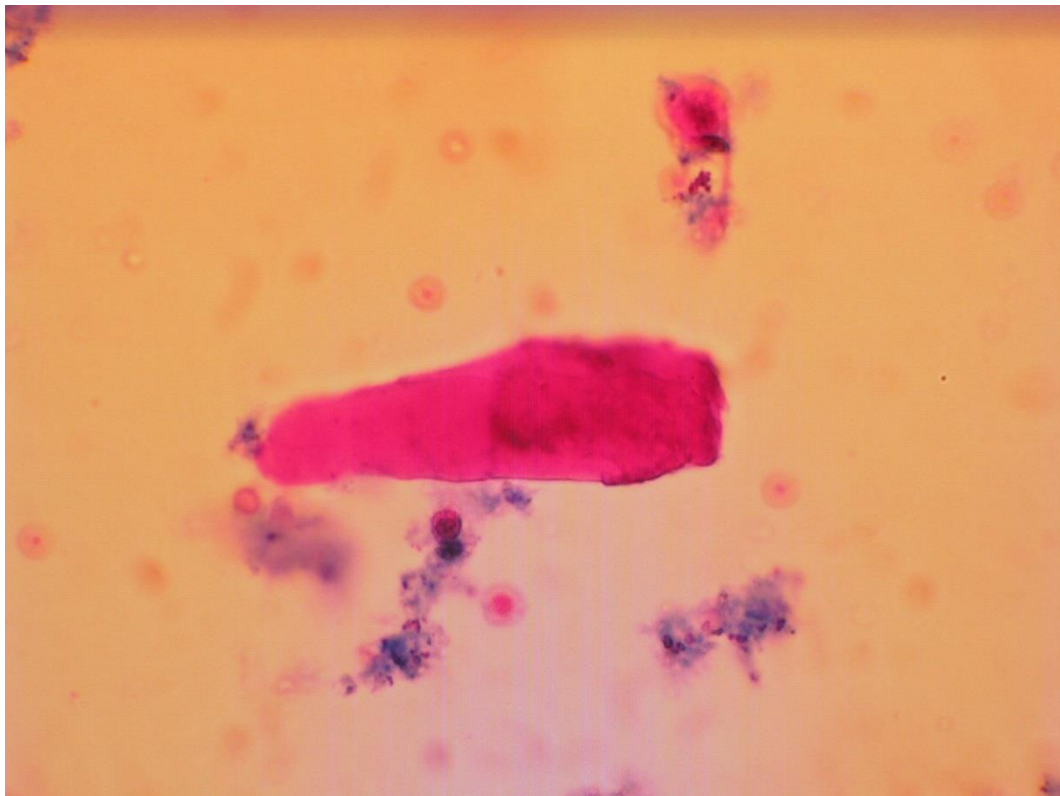
Transition phase of cast from cellular to granular



Granular cast



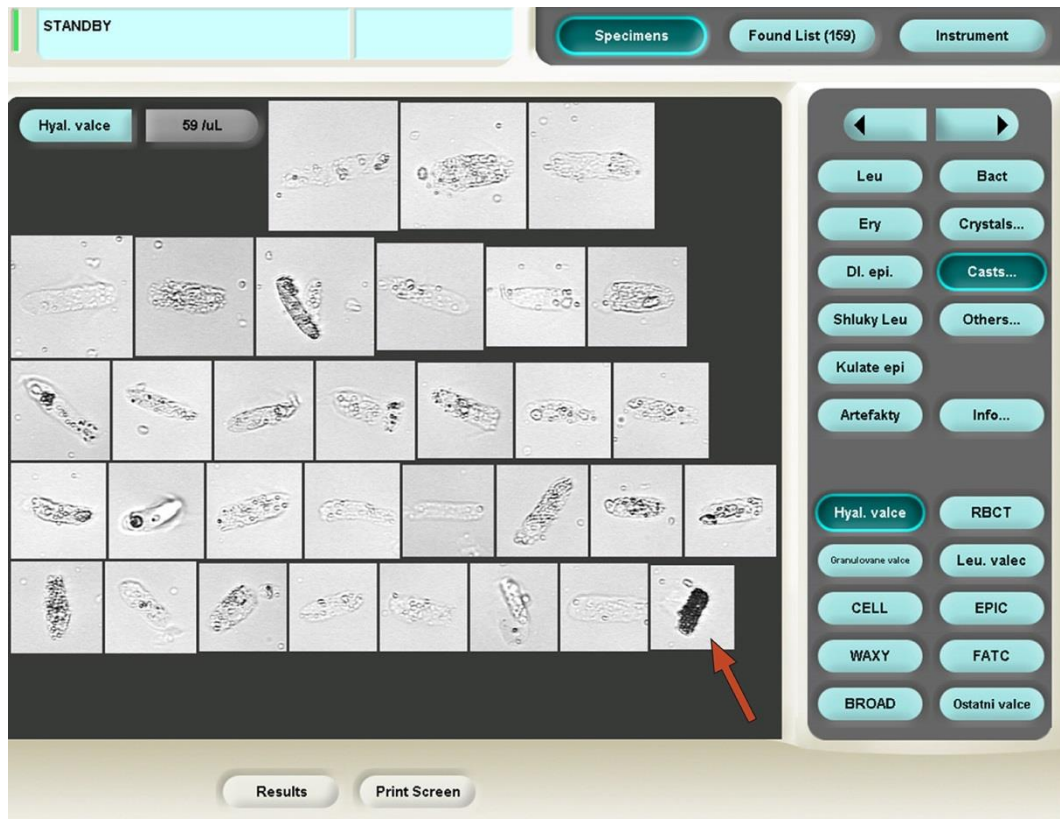
Transition phase of cast from granular to waxy and waxy cast



Waxy cast

The finding of fat particles in patient with nephrotic syndrome

The elements listed below were found in urine of patient with nephrotic syndrome.

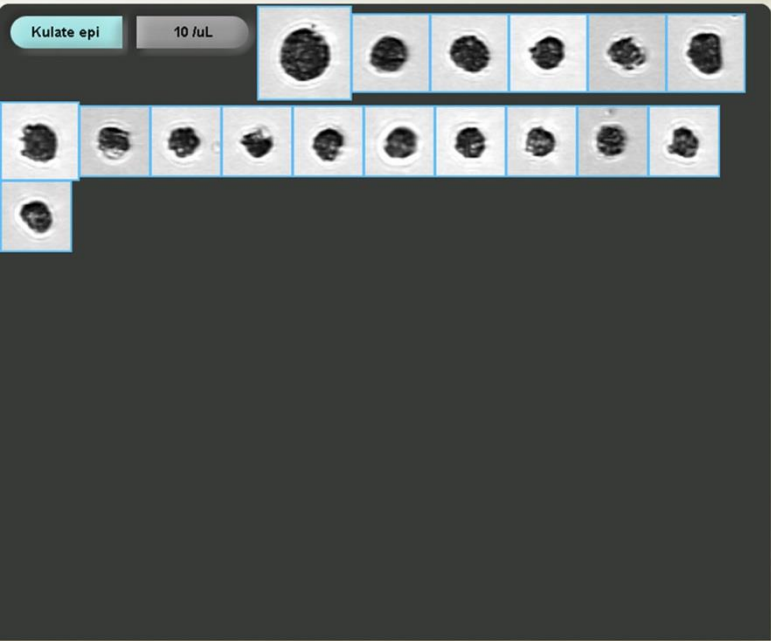


Hyaline casts with fat inclusions of fat droplets and fatty cast (arrow)

STANDBY

Specimens Found List (123) Instrument

Kulate epi 10 /uL



Leu Bact
Ery Crystals...
Dl. epi. Casts...
Shluky Leu Others...
Kulate epi
Artefakty Info...

<<Released>>
8402730275
2012-02-01 09:19:10
6/3(412618)
1:1

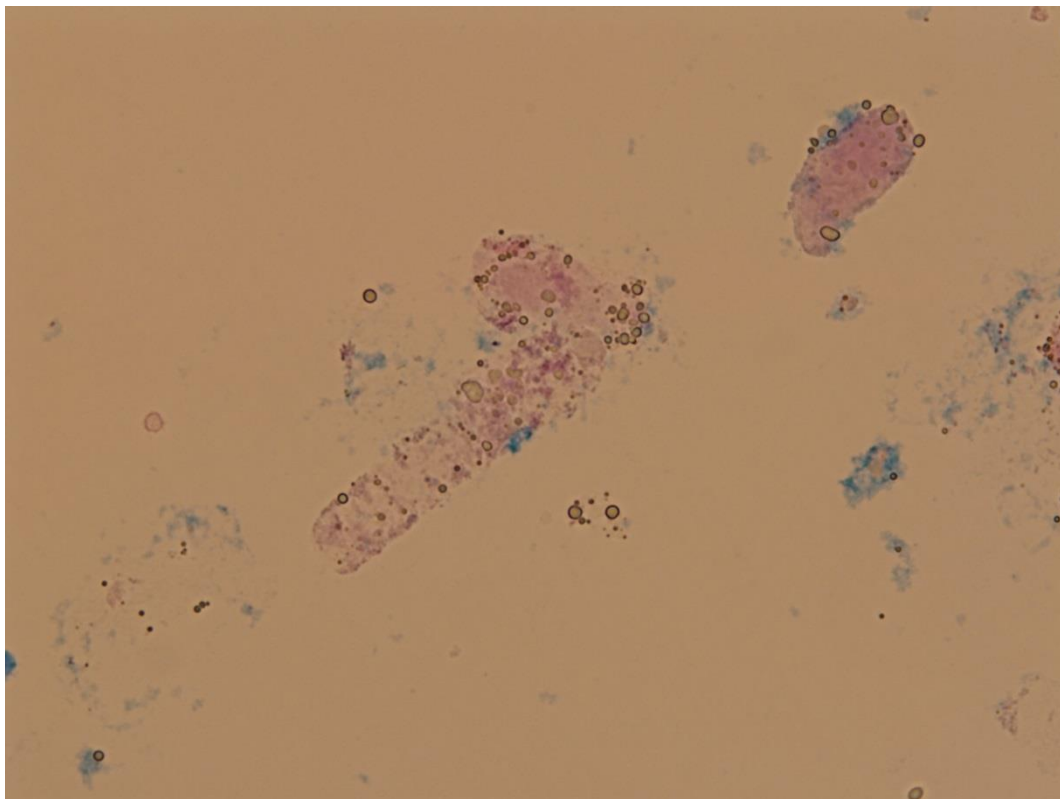
All Small Particles: 18673uL

| | | |
|---|------|----------|
| H | GLU | Normal |
| | PRO | +4 |
| | BIL | - |
| | URO | Normal |
| | PH | 6.5 |
| H | Krev | +3 |
| | HET | - |
| | NIT | Negative |
| H | LEU | +1 |
| H | CLA | Turbid |
| | SPGR | 1.017 |
| | COL | Yellow |

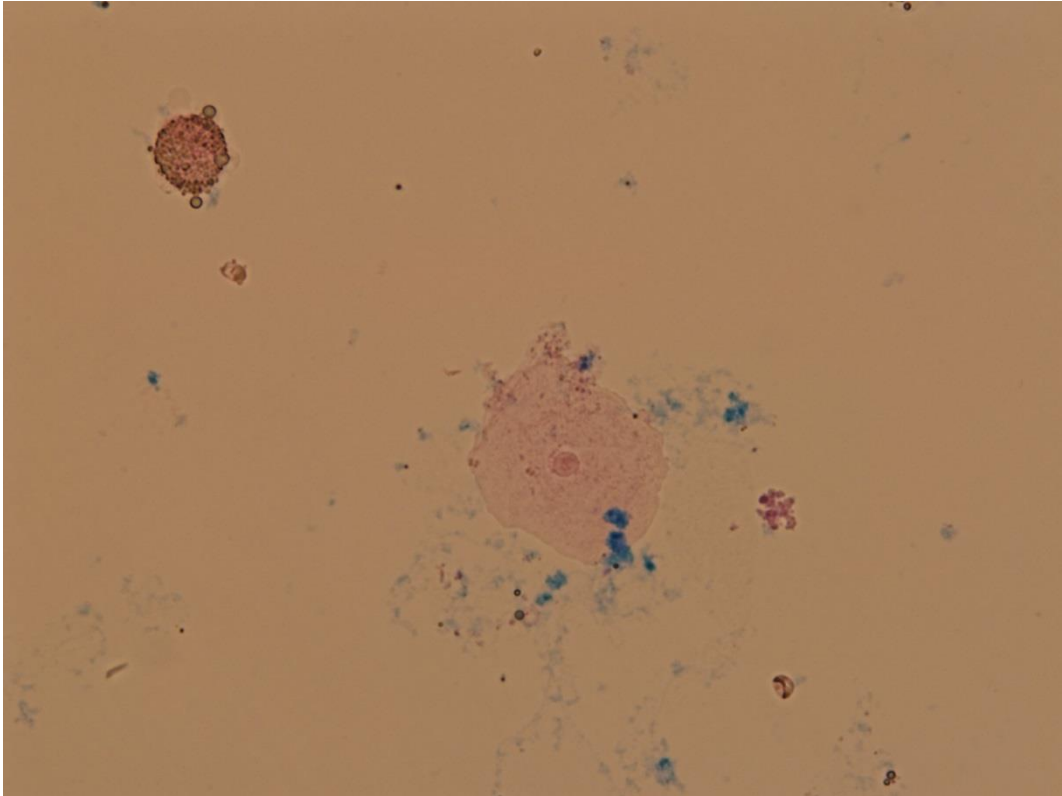
Cleared flags:
HIGH CONCENTRATION
Possible Amorphous

Results Print Screen

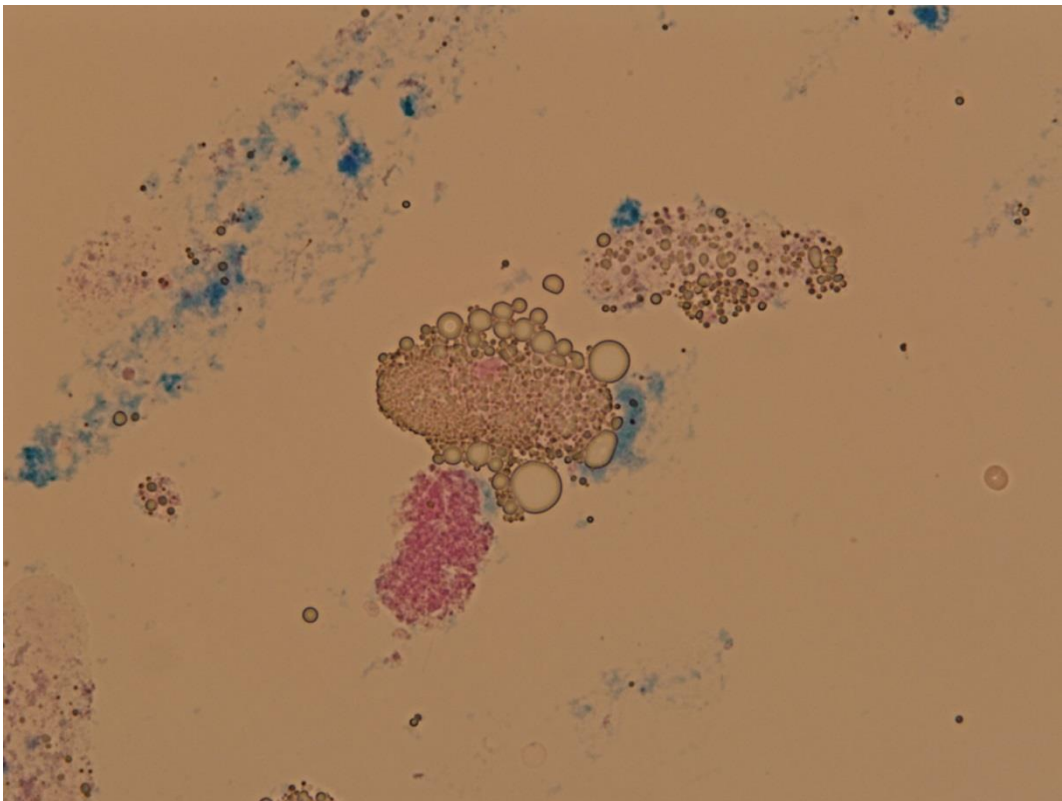
Oval fat bodies



Hyaline cast with fat inclusions of fat droplets



Squamous epithelial cell and oval fat body



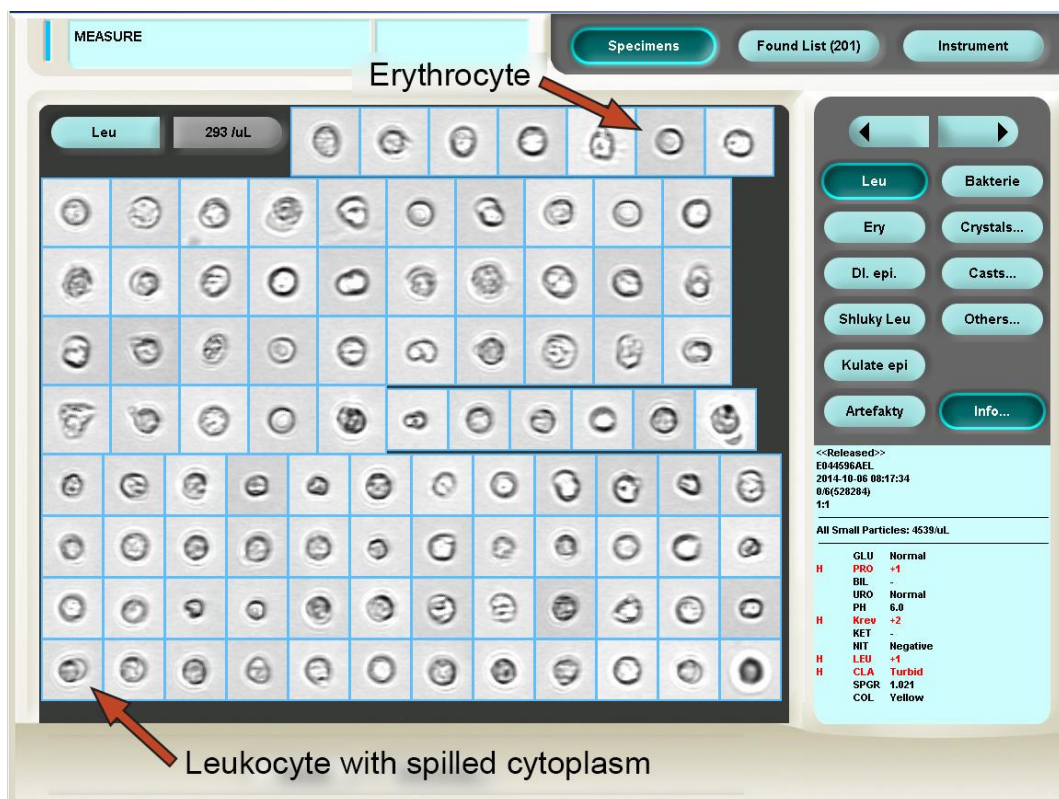
Fatty cast and free fat droplets

Elements in hypotonic urine

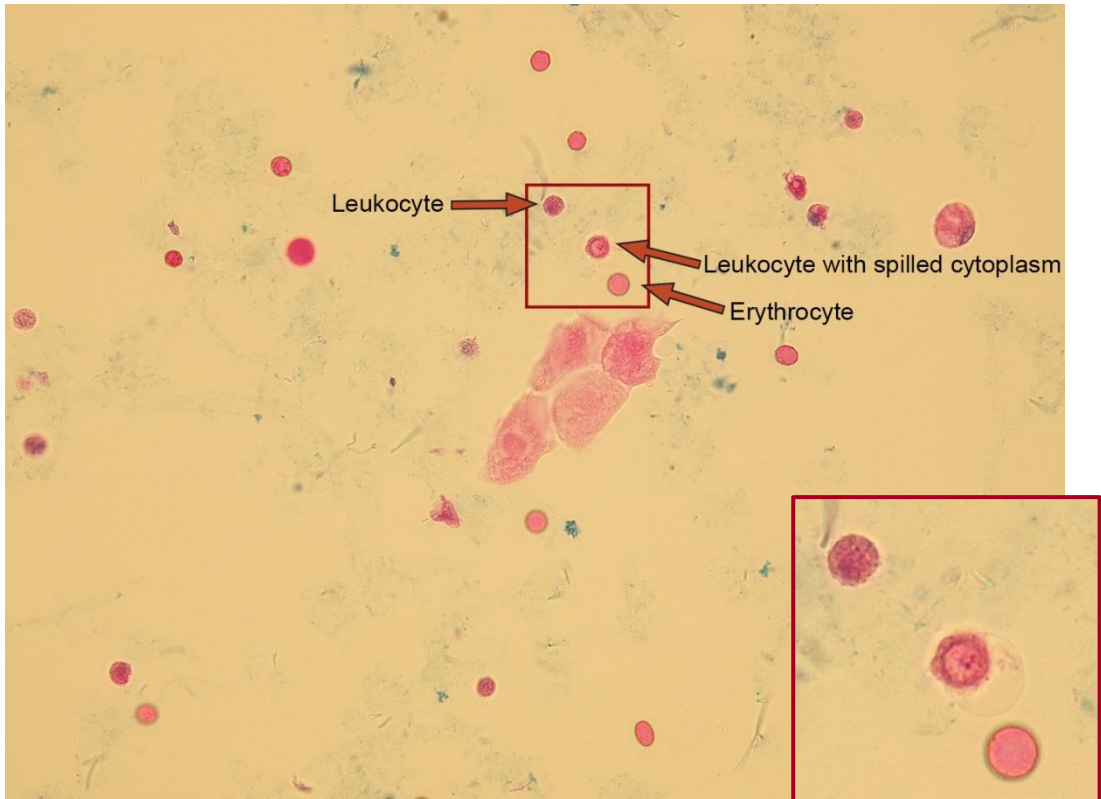
A patient with acute urine bladder inflammation was treated by hydration of the bladder, causing his urine to be hypotonic.

In the urine sample, we found neutrophil granulocytes which are called “glitter cells” because of the rapid Brownian movement of granules inside their cells. The low urine osmolality caused ruptures in the cell membranes of several of these leukocytes which resulted in cytoplasm spilling outside of the cells. These cells are sometimes called “winged leukocytes”.

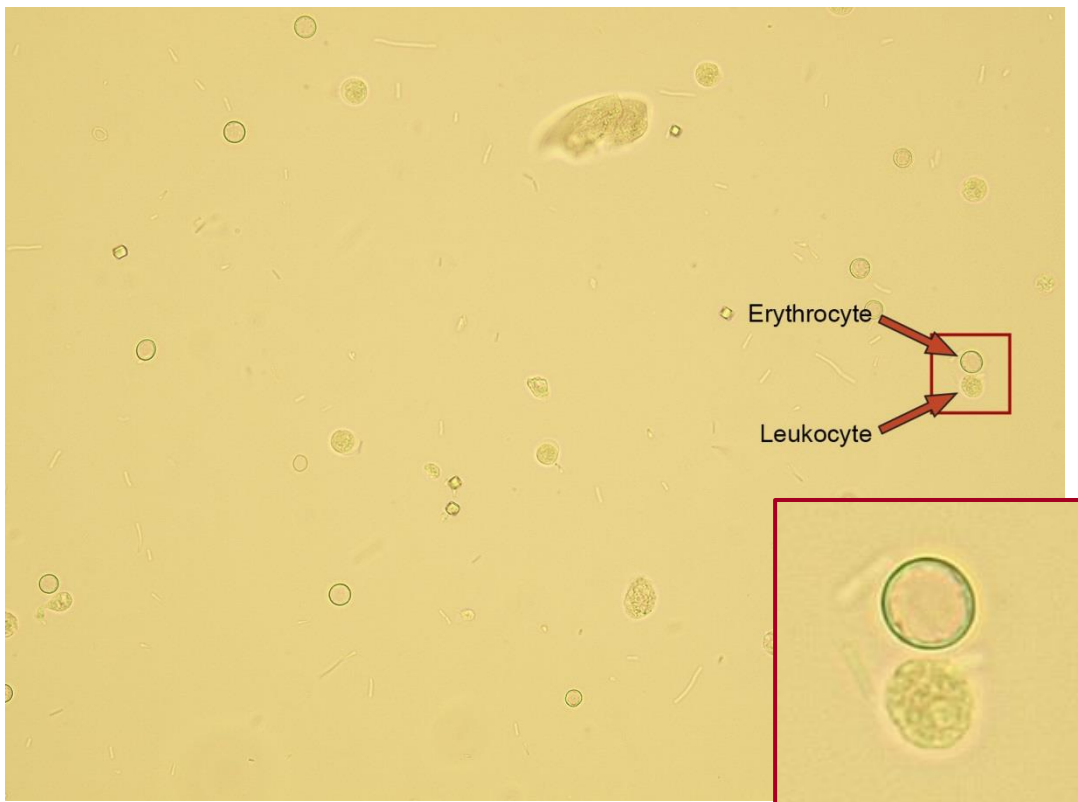
The hypotonic urine from the same patient also caused erythrocytes to swell and their size matched that of the leukocytes. The same size resulted in miscategorization of some erythrocytes in the leukocyte category by the iQ 200 analyzer software leading to a discrepant finding.



Leukocytes (glittering cells) mixed with erythrocytes in the leukocyte category



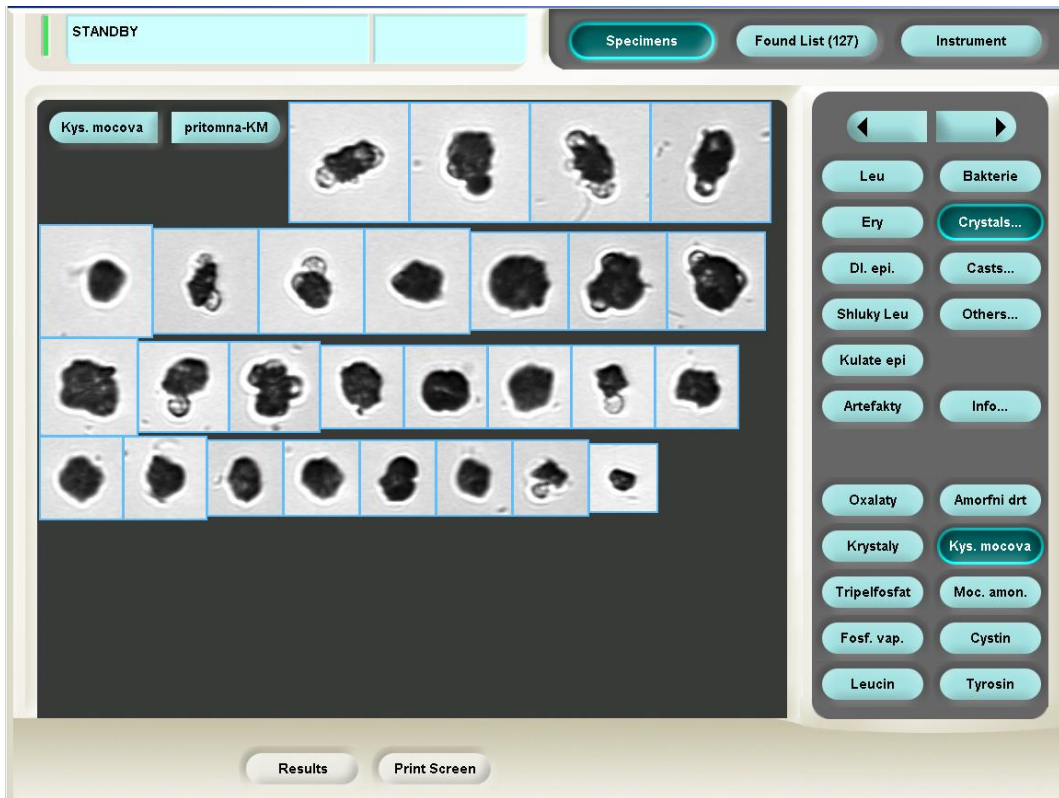
Leukocytes (glittering cells) with erythrocytes



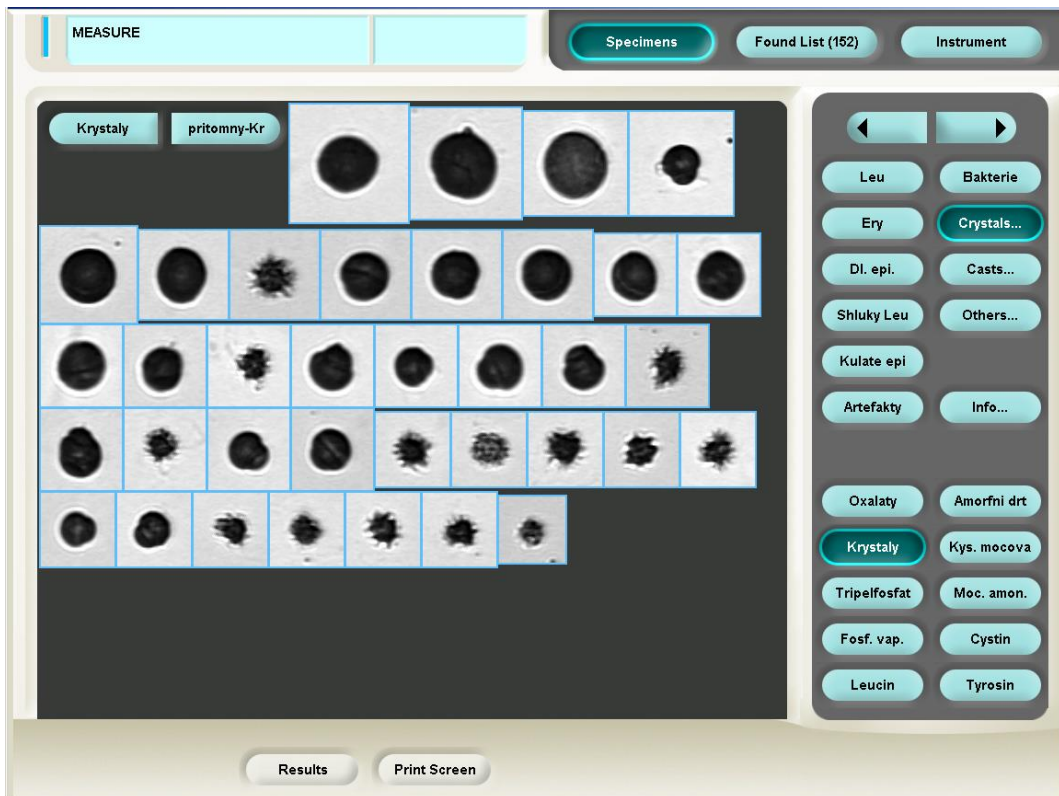
Leukocytes (glittering cells) with erythrocytes

Problematic spherical particles

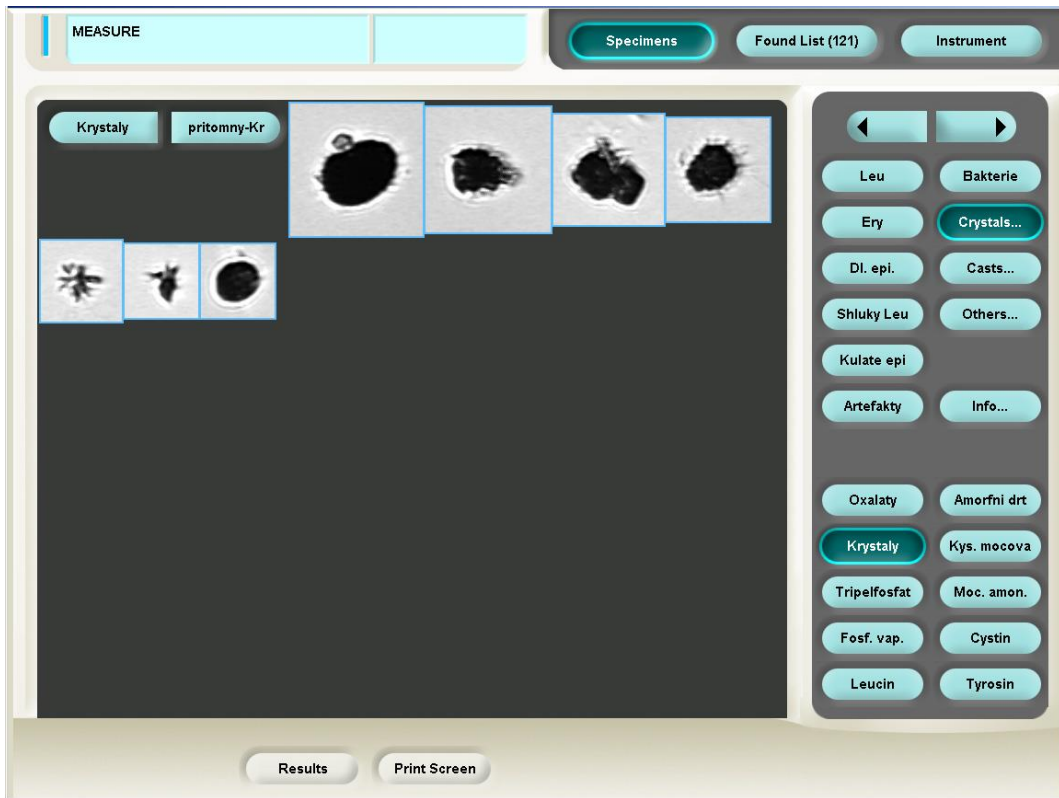
Automatic microscopic analysis may picture various elements resembling big black spheres. They may have various origin including crystals or other cells. Combination of chemical diagnostic strip analysis and microscopy of stained sediment is used to identify them.



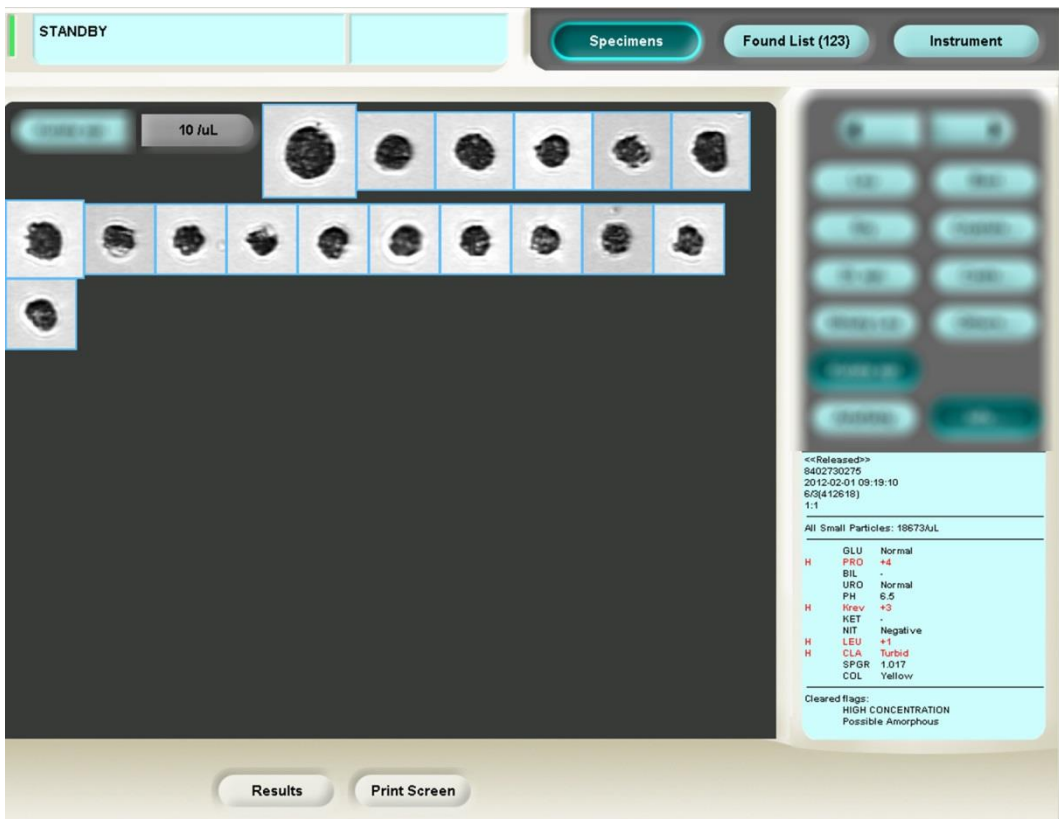
Uric acid



Bilirubin



Ammonium urate



Macrophages with fat bodies

Sample contaminated by feces

The urine analyzed with iQ 200 showed some dark asymmetric particles miscategorized as squamous epithelial cells. Further investigation with microscopy in stained and native sediment confirmed them to be stool particles. This rare contamination of feces may occur in patients with fistula of bladder.

STANDBY

Specimens Found List (117) Instrument

Dl. epi. 185 /uL

Leu Bakterie

Ery Crystals...

Dl. epi. Casts...

Shluky Leu Others...

Kulate epi

Artefakty Info...

<<Released>>
6404753392
2014-10-17 09:38:28
0/6(52801)
1:1

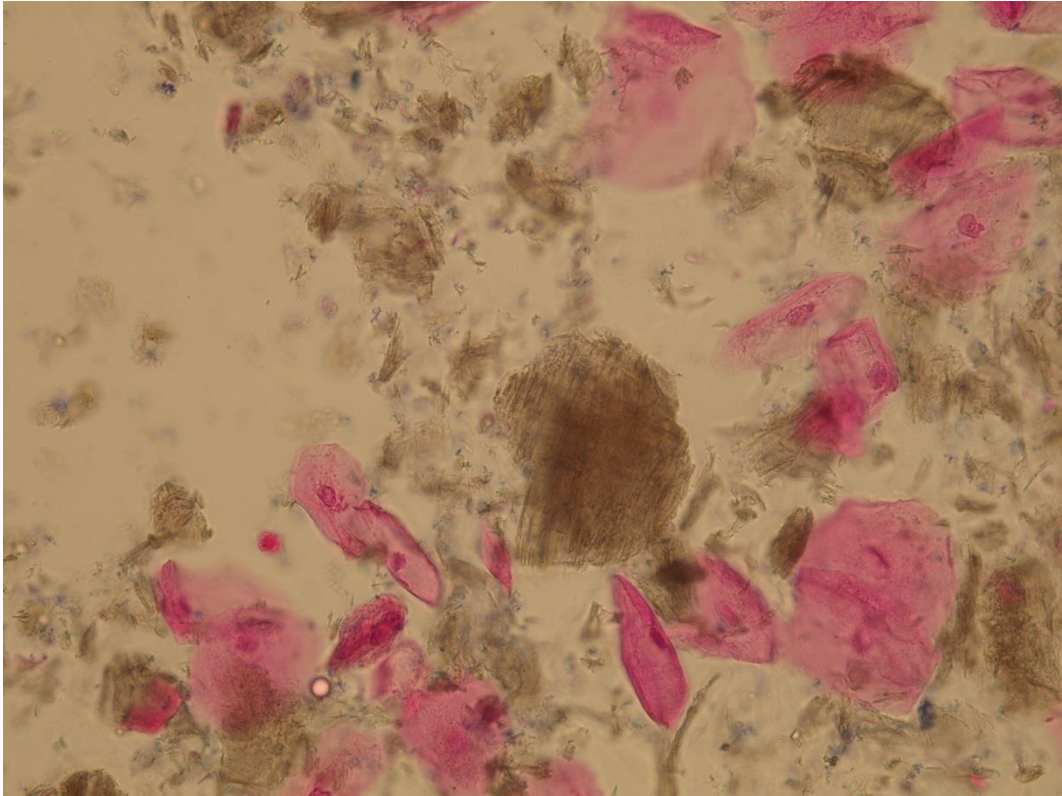
All Small Particles: 66515/uL

H GLU +
H PRO +1
BIL -
URO Normal
PH 6.0
H Ketv +
KET -
NIT Negative
LEU 0 Leu/uL
H CLA Eq. Turbid
H SPGR 1.033
COL Yellow

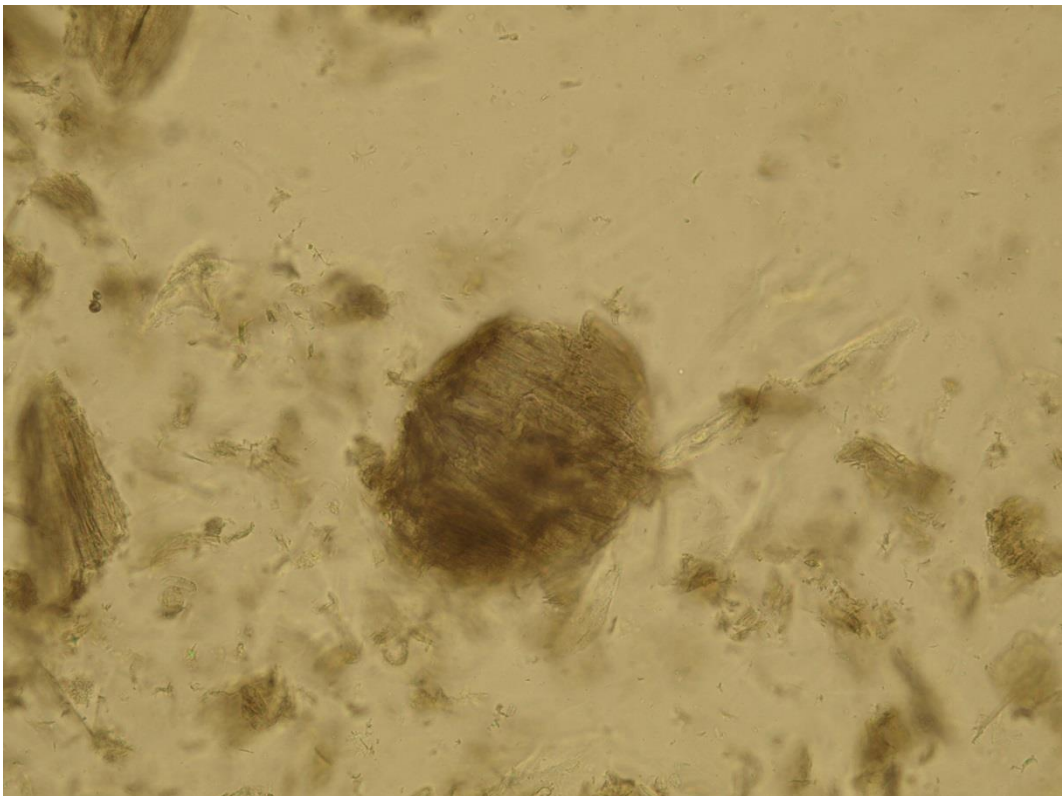
Cleared flags:
HIGH CONCENTRATION
Possible Amorphous

Results Print Screen

Fecal particles (black elements) miscategorized in squamous epithelia section



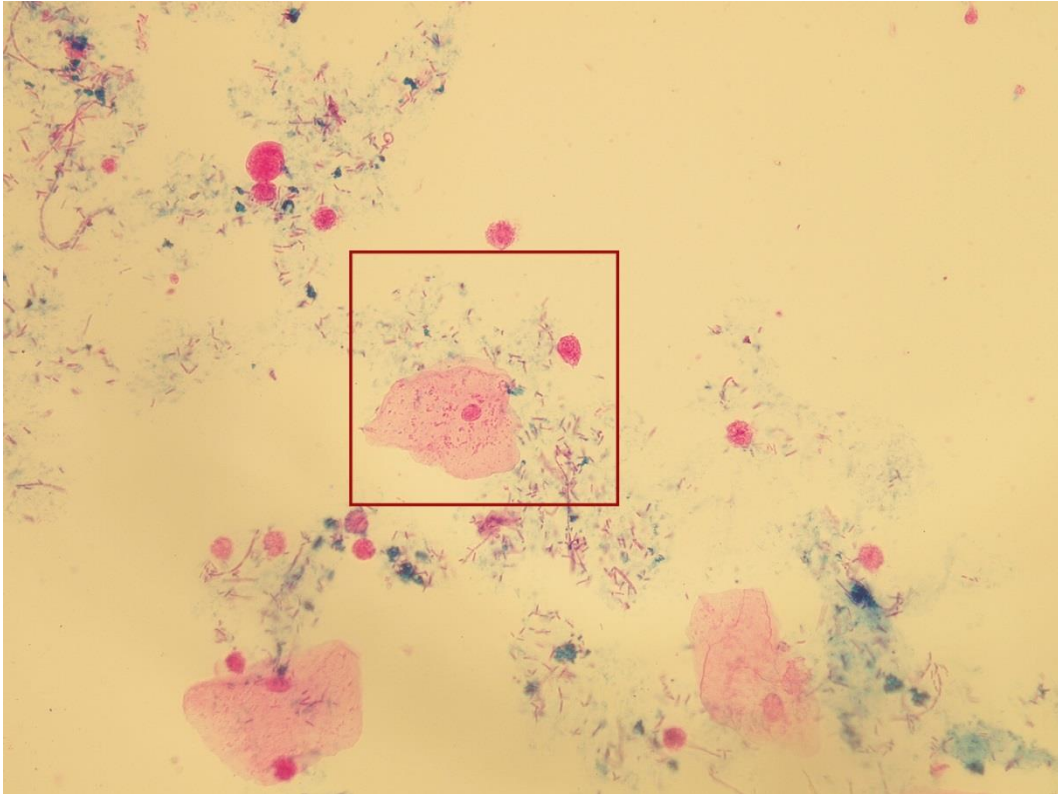
Fecal particles (brown elements) with squamous cells



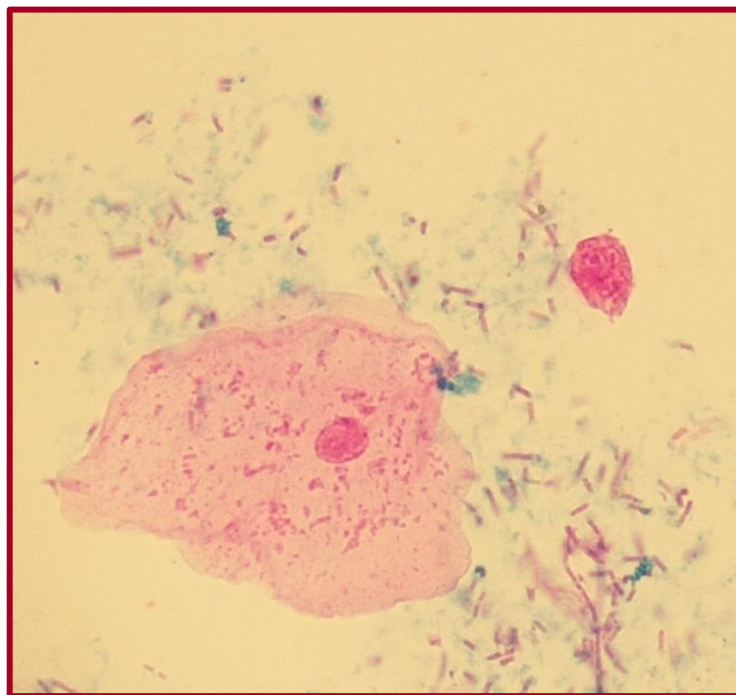
Fecal particles

Intracellular Bacteria

Bacteria, most commonly *E. coli*, may be sometimes observed inside epithelial cells of the bladder in samples of patients with urinary tract infection. Insufficient antibiotic treatment does not eradicate bacteria inside the cells and may cause future chronic infections.



Bacteria inside squamous and transitional epithelia



Bacteria inside squamous and transitional epithelia (cropped from the picture above)

Table of contents

| | |
|------------------------------------|-----|
| Introduction..... | 2 |
| Erythrocytes | 3 |
| Leukocytes..... | 9 |
| Epithelial cells..... | 18 |
| Squamous epithelial cells..... | 18 |
| Transitional epithelial cells..... | 22 |
| Renal epithelial cells..... | 27 |
| Casts | 33 |
| Hyaline casts..... | 33 |
| Cell casts..... | 37 |
| Granular casts..... | 45 |
| Waxy casts..... | 49 |
| Fatty casts..... | 53 |
| Bacterial casts..... | 55 |
| Pseudocasts..... | 58 |
| Microorganisms..... | 62 |
| Bacteria..... | 62 |
| Yeasts..... | 67 |
| Crystals | 71 |
| Oxalates..... | 72 |
| Uric acid..... | 75 |
| Ammonium urate | 81 |
| Triple phosphate | 84 |
| Calcium phosphate..... | 91 |
| Bilirubin | 96 |
| Cystine | 99 |
| Amorphous microcrystals | 102 |
| Lipid particles | 105 |
| Mucus..... | 107 |
| Sperms..... | 109 |

| | |
|---|-----|
| Artifacts | 113 |
| Interesting findings..... | 117 |
| Erythrocytes x yeast | 117 |
| Erythrocytes x oxalates | 119 |
| The gradual transformation of pathological casts | 121 |
| The finding of fat particles in patient with nephrotic syndrome | 124 |
| Elements in hypotonic urine | 127 |
| Problematic spherical particles | 129 |
| Sample contaminated by feces | 132 |
| Intracellular Bacteria | 134 |
| Table of contents..... | 135 |

CZ.1.07/2.2.00/28.0041

Centrum interaktivních a multimediálních studijních opor pro inovaci výuky a efektivní učení



INVESTICE DO ROZVOJE VZDĚLÁVÁNÍ