

MASARYK UNIVERSITY

Faculty of Medicine

Department of Paediatrics

**First Trimester Screening of Congenital Heart Defects
in Pregnancy: More Risk than Benefit?**

Habilitation Thesis

Commented Collection of Publications

MUDr. Hana Jičínská, Ph.D.

Brno 2020

Acknowledgements

I would like to thank prim. MUDr. Jan Škovránek CSc.; MUDr. Viktor Tomek Ph.D. (Children's Cardiac Centre, Prague); Professor Jan Marek M.D., Ph.D., FESC. (Great Ormond Street Hospital, London); prim. MUDr. Pavel Vlašín (Centre for Fetal Care, Brno); MUDr. Jiří Navrátil (University Hospital Brno) and MUDr. Zdeněk Jelínek (Paediatric Cardiology Clinic, Brno) who examined pregnant women and contributed clinical cases to the study.

I would also like to thank MUDr. Ilga Grochová who covered the genetic parts of the study.

In addition, I would like to thank Professor Jan Marek and MUDr. Pavel Vlašín for their support and help with the study.

Content

COMMENTARY.....	6
1. INTRODUCTION TO PAEDIATRIC AND PRENATAL CARDIOLOGY IN THE CZECH REPUBLIC.....	8
1.0.1 ANNEX 1. Jicinska H. Prenatal cardiology in the Czech Republic. Cesko-Slovenska Pediatrie. 2010;65(11):623-625.....	11
2. PRENATAL SCREENING AND PRENATAL DETECTION OF CONGENITAL HEART DEFECTS, ARRHYTHMIAS AND OTHER HEART DISEASE.....	15
2.0.1 ANNEX 2. Tomek V, Marek J, Jicinska H, Skovranek J. Fetal Cardiology in the Czech Republic: Current Management of Prenatally Diagnosed Congenital Heart Diseases and Arrhythmias. Physiological Research 2009;58(2):159-166.....	16
2.0.2 ANNEX 3. Tomek V, Jicinska H, Gilik J, Skovranek J, Navratil J, Janousek J. Prenatal diagnosis of congenital heart defects in the Czech Republic during the years 1986-2012. Actual Gyn 2014; 6:67-72.....	25
2.0.3 ANNEX 4. Tomek V, Gilik J, Jicinska H, Pavlicek J, Navratil J, Cutka D, Vlasin P, Lacinova M, Marek J, Skovranek J. Prenatal detection of congenital heart defects and its consequences. Cesko-Slovenska Pediatrie 2018;73(5):284-290.....	32
2.1 FIRST-TRIMESTER SCREENING.....	40
2.1.1 ANNEX 5. Jicinska H, Vlasin P, Jicinsky M, Grochova I, Tomek V, Volaufova J, Skovranek J, Marek J. Does First-Trimester Screening Modify the Natural History of Congenital Heart Disease? Analysis of Outcome of Regional Cardiac Screening at 2 Different Time Periods. Circulation 2017;135:1045-1055.....	40
3. LEFT HEART LESIONS.....	52
3.0.1 ANNEX 6. Gardiner H.M., Kovacevic A., Tulzer G., Sarkola T., Herberg U., Dangel J., Öhman A., Bartrons J., Carvalho J.S., Jicinska H., Fesslova V. Averiss I., Mellander M., Fetal Working Group of the AEPC. Natural history of 107 cases of fetal aortic stenosis from a European multicenter retrospective study. Ultrasound in Obstetrics and Gynecology 2016; 48:373-381.....	53
3.0.2 ANNEX 7. Kovacevic A, Öhman A, Tulzer G, Herberg U, Dangel J, Carvalho J S, Fesslova V, Jicinska H, Sarkola T, Pedroza C, Averiss I E, Mellander M, Gardiner H, the Fetal Working Group of the AEPC. Fetal hemodynamic response to aortic valvuloplasty and postnatal outcome: a European multicenter study. Ultrasound in Obstetrics and Gynecology; 2018, 52:221-229.....	63

3.0.3	ANNEX 8. Navratil J, Jicinska H, Jelinek Z. The incidence and the outcome of fetuses with hypoplastic left heart syndrome in the region of Morava and Silesia from 2002 to 2003. <i>Cesko-Slovenska Pediatrie</i> . 2005; 60(7):393-396.....	73
3.0.4	ANNEX 9. Matsui H, Mellander M, Roughton M, Jicinska H, Gardiner H. Morphological and Physiological Predictors of Fetal Aortic Coarctation. <i>Circulation</i> 2008;118: 1793-1801.....	78
3.0.5	ANNEX 10. Jowett V, Aparicio P, Santhakumaran S, Seale A, Jicinska H, Gardiner HM. Sonographic predictors of surgery in fetal coarctation of aorta. <i>Ultrasound in Obstetrics nad Gynecology</i> ; 2012; 40:47-54.....	88
4.	RARE MORPHOLOGICAL ABNORMALITIES.....	97
4.0.1	ANNEX 11. Jičínská H, Tax P, Pádr R, Jičínský M, Marek J. Rare congenital umbilical arteriovenous malformation. <i>European Heart Journal Cardiovascular Imaging</i> [online]. 2020; 21(10):1172. doi:10.1093/ehjci/jeaa102.....	97
4.0.2	ANNEX 12. Fotaki A, Novaes J, Jicinska H, Carvalho J S. Fetal aortopulmonary window: case series and review of the literature. <i>Ultrasound in Obstetrics & Gynecology</i> [online].2017; 49(4):533-539. ISSN 0960-7692. doi:10.1002/uog.15936.....	99
4.0.3	ANNEX 13. Krupickova S, Rigby M L, Jicinska H, Marais G, Rubens M, Carvalho J S. Total anomalous pulmonary venous connection to unroofed coronary sinus diagnosed in a fetus with spinal muscular atrophy Type I. <i>Ultrasound in Obstetrics& Gynecology</i> . [online]. 217;50(5):657+. ISSN 0960-7692. doi:10.1002/uog.17432.....	107
5.	FETAL ARRHYTHMIAS.....	110
5.0.1	ANNEX 14. Eliasson H, Sonesson S E, Sharland G, Granath F, Simpson M S, Carvalho J S, Jicinska H, Tomek V, Dangel J, Zelinsky P, Respondek-Liberska M, Freund M W, Mellander M, Bartoons J, Gardiner H M. Isolated Atrioventricular Block in the Fetus. A retrospective multinational, multicenter study of 175 patients. <i>Circulation</i> [online]. 2011;124(18):1919-1926. ISSN 0009-7322. doi:10.1161/CIRCULATIONaha.111.041970.....	110
6.	ASSOCIATED GENETIC ABNORMALITIES.....	120
6.0.1	ANNEX 15. Jicinska H, Marek J, Brysova V, Gaillyova R, Kuglik P, Tlaskal T, Litzman J, Tax P, Navratil J. Deletion of Chromosome 22q11 in Congenital Heart Disease. <i>Cesko-Slovenska Pediatrie</i> . 1998;53(11):650-664.....	120
7.	CONSENSUS STATEMENT AND RECCOMENDATION.....	127
7.0.1	ANNEX 16. Tomek V, Jicinska H, Klaskova E, Jehlicka P, Balatka P, Vit P, Hecht P, Reich O, Janousek J. Expert consensus statement on prenatal cardiology	

organization in the Czech Republic. Prepared by the Working Group on Pediatric Cardiology of the Czech Society of Cardiology.

Cor et Vasa 2020; 62(1): 60-63.....127

7.0.2 ANNEX 17. Zatocil T, Antonova P, Rubackova, Popelova J, Zakova D, Pokorna O, Chaloupecky V, Rohn V, Skalsky I, Jicinska H, Taborsky M, Kautzner J, Janousek J. Recommendations to organize care for adults with congenital heart disease in the Czech Republic. Cor et Vasa 2018;60(3): e331-e334.....131

8. CONCLUSIONS.....135

Cited literature is a part of the attached publications.

Commentary

Congenital heart defects (CHDs) are very common defects in fetuses and in children. The prevalence of CHDs varies from 6 to 10 per 1000 live births. 35% of CHDs are critical CHDs. Neonates born with critical CHDs often need to be treated immediately after birth: some of them need some medication, the others need to be treated by cardiac catheterization or by surgery. To be prepared to take care of such patients soon after birth, we need to diagnose critical CHDs prenatally.

In the Czech Republic, the nationwide prenatal cardiac screening program during the second trimester was introduced in 1986. This Habilitation Thesis is divided into 7 parts. After the introduction, the second part is focused on the organization and the results of the second trimester screening program in Czechoslovakia (later in the Czech Republic) from 1986. This part of the Habilitation Thesis also deals with first-trimester screening, and with the difficulties and limitations of screening during the first trimester.

The third part of the Thesis focuses on left heart lesions, severe CHDs, which can be detected by screening – aortic stenosis (AS), hypoplastic left heart syndrome (HLHS), and coarctation of the aorta (COA). Possible fetal interventions in this group of fetal patients are presented as well. Very rare congenital heart abnormalities are discussed in the fourth part of the Thesis, congenital complete heart block in the fifth part, and associated genetic abnormalities in the sixth part.

The main aim of the study was to assess the impact of first trimester screening on the spectrum of CHDs and the outcomes of fetuses with CHD later in pregnancy. The first trimester ultrasound screening program was implemented in the Southern Moravia region in most fetal medical centres by 2003. The spectrum of CHDs, associated comorbidities and outcome of fetuses, either diagnosed with CHD in the first or only in the second trimester in the South Moravian region of the Czech Republic, were compared retrospectively from 2007 to 2013. Fetuses diagnosed with CHD between 2007 and 2013 in the second trimester were also compared with fetuses diagnosed with CHD in the second trimester between 1996 to 2001, the period before first-trimester screening was introduced.

Our results confirmed the significant impact of first-trimester screening on the spectrum of CHDs later in pregnancy and on the outcomes of pregnancies with a CHD, in that more severe forms of cardiac abnormalities and higher comorbidities resulted in an increase in early termination of first-trimester pregnancies. In the second trimester, less severe forms of cardiac

abnormalities were diagnosed. These fetuses had better postnatal outcomes because of more frequent biventricular circulation and fewer associated comorbidities.

This Habilitation Thesis is designed as a commented collection of publications with the candidate being either the main author of five manuscripts, (in one case, the publication has two main authors who contributed equally), or the co-author significantly contributing to ten manuscripts. All manuscripts were published in their final version in the relevant medical journals or books. International medical journals where the manuscripts were published had an impact factor >18 in one case, IF >14 in two cases, IF >5 in three cases, and IF from 1.43 to 4.7 in four cases.

Keywords: prenatal cardiology, fetus, first-trimester screening, congenital heart defect, fetal arrhythmia

1. Introduction to paediatric and prenatal cardiology in the Czech Republic

Prenatal cardiology is a part of paediatric cardiology. Paediatric cardiology started to develop after World War II as the result of a high incidence of rheumatic carditis in rheumatic fever in children. Thanks to continuing treatment, the incidence of rheumatic fever decreased and congenital heart defects became the main area of interest for paediatric cardiologists. In the past, making a correct diagnosis of CHD was very difficult. The diagnosis was possible to be made only by clinical evaluation, chest X-ray and electrocardiogram. After implementation of cardiac catheterization to the diagnostic process in 1947, cardiac diagnosis became much easier. Since 1947, some treatment options in some CHDs improved — it was possible to surgically close a patent arterial duct from 1947, to perform a subclaviopulmonary anastomosis in Tetralogy of Fallot from 1949, and to repair coarctation of the aorta.

A fundamental change in paediatric cardiology in the Czech Republic occurred in 1977 when, thanks to professor Šamánek, the Children's Cardiac Centre in Prague was established. After some time, the Prague Children's Cardiac Centre experienced a unique accomplishment, in comparison to other units in Europe and in the world, involving the system of care for such serious paediatric morbidities. It was due to mutual cooperation between paediatric cardiologists and surgeons, and due to further specialization of paediatric cardiologists in different fields of paediatric cardiology — echocardiography, arrhythmology, cardiac catheterization, surgery, intensive postoperative care. It was also due to increased follow-up exams of cardiac outpatients in the Children's Cardiac Centre and subsequently in a network of paediatric cardiac outpatient clinics in the entire country. This organization of the system of care was unique in the world and this system guaranteed early diagnosis of CHD after birth, early transport to the Cardiac Centre, and early and necessary cardiac care after birth.

The development of echocardiography and the possibility of medical treatment keeping open a patent arterial duct in CHDs with duct-dependent circulation lead to further developments in paediatric cardiology. Echocardiography became “the gold standard” of the diagnostic process of CHDs. Cardiac catheterization became a more therapeutic method over time.

Thanks to the important development of ultrasound diagnostic methods and the effort to diagnose CHDs as soon as possible, prenatal cardiology as a new branch of paediatric cardiology was established. The first correlation of parallel imaging of a fetal heart was done by a pathologist (light photograph) and by cardiologist Lindsey Allan (ultrasound scan), who published the correlation in 1980. New possibilities of the evaluation of a fetal heart and making

the cardiac diagnosis in the early stages of pregnancy were opened up. Today, prenatal cardiology plays an important role in the diagnostic process of CHDs and other cardiac diseases. The Czech Republic was one of the first countries to start a prenatal cardiac screening program — the first ultrasound examination of a fetal heart was performed by Dr. Škovránek in 1981; a nationwide cardiac second-trimester screening program was started in 1986.

What is possible to be prenatally diagnosed in the fetus today? The majority of prenatal cardiac abnormalities are congenital heart defects, which are one of the most common structural abnormalities in the fetus. The prevalence of CHDs is 6.16/1000 live births in the Czech Republic (Šamánek). Fetal arrhythmias, cardiomyopathies, inflammatory heart disease, tumours and other heart diseases can be detected as well. It is also possible to detect the signs of heart failure or failure of the whole fetoplacental circulation as the result of other conditions having an effect on circulation, such as twin-to-twin transfusion syndrome, anemia, arteriovenous malformation and others.

What's possible to be treated in the fetus during pregnancy? For example, in severe aortic or severe pulmonary stenosis, it is possible to perform fetal balloon aortic or pulmonary valvuloplasty in order to protect the left or right ventricle from remodeling and progressing to hypoplastic left heart syndrome or to severe hypertrophy of the right ventricle, which, in the event of these consequences, could further progress to univentricular circulation with a very unfavourable prognosis. In some fetuses with hypoplastic left heart syndrome, the foramen ovale spontaneously will become restricted or completely closed. This leads to the development of pulmonary lymphangiectasia and increased pulmonary vascular resistance, which results in higher mortality after birth. In order to protect against this unfavourable outcome, it is possible to perform fetal balloon atrioseptostomy in the fetus and thereby improve the outcome of the fetus.

In fetuses with severe fetal arrhythmias (supraventricular or ventricular arrhythmias) it is possible to treat the fetus during pregnancy by giving an antiarrhythmic drug to the mother (transplacental administration) or to the fetus (direct fetal therapy). Using this treatment we can protect against or reduce the signs of heart failure and protect against the subsequent development of hydrops and fetal death.

When is it possible to perform an ultrasound examination of the fetal heart? An ultrasound examination of the fetal heart is a part of second-trimester screening from the 19th to the 22nd week of gestation. This scan is crucial for the detection of structural abnormalities in the fetus. At the end of the 20th century, in an effort to display, as soon as possible, morphologic structures including basic heart structures of the fetus, first-trimester screening arose. First-

trimester screening is performed between the 11th and the 13th (+ 6) weeks of gestation. In the first trimester it is not always possible to see all details of the fetal heart. It is also not possible to detect CHDs that will develop later in pregnancy. So it is necessary to know the limitations of first-trimester screening and to respect them.

If there is a suspicion of cardiac abnormality detected at the screening examination, the heart of the fetus is examined by a specialized fetal cardiologist and the final diagnosis is made. The finding of CHD is also a reason for a detailed specialized anomaly scan in order to detect additional extracardiac abnormalities. Genetic counselling and genetic evaluation is offered to the parents as well. The aim of these evaluations is to obtain as much information as possible in order to give parents complex information about the disease in the fetus, about possible developments of the disease, about possible interventions after birth, and about the most likely outcome after birth. Based on this information and on the character of the family, the parents make decisions about the outcome of the pregnancy. In cases where the pregnancy is continued, we follow up the fetus and monitor the development of CHD and the pregnancy. We arrange the pregnant woman to give birth close in the Cardiac Centre in order to take care of the baby immediately after birth, and in order to start with conservative treatment or to perform cardiac catheterization or heart surgery as soon as it is indicated. As is mentioned earlier herein, in some cases it is possible to treat fetuses before birth. In some cases with severe complex abnormalities and associated extracardiac or genetic abnormalities, the parents make the decision to terminate the pregnancy.

Commented publications

1.0.1 ANNEX 1

Jicinska H

Fetal Cardiology in the Czech Republic

Cesko-slovenska Pediatrie. 2010;65(11):623-625

Main points of the publication:

The paper is focused on the history of prenatal cardiology in the Czech Republic and on the main points of prenatal cardiology: screening of congenital heart defects, the detection rate of CHDs, management of pregnancy with CHD in the fetus, possible treatment in pregnancy and the first-trimester screening.

Prenatální kardiologie v České republice

Prenatal Cardiology in the Czech Republic

Jičínská H.

Dětská kardiologie Pediatrické kliniky FN Brno
přednosta prof. MUDr. Z. Doležel, CSc.
Lékařská fakulta Masarykovy univerzity Brno
Royal Brompton Hospital and St. George's Hospital London

Vrozené srdeční vady (VSV) jsou nejčastější vrozenou anomálií v prenatálním období (prevalence VSV je 6–7/1000 živě narozených dětí). Část VSV (kritické VSV 35 %) ohrožuje děti na životě bezprostředně po narození. Pokud kritickou VSV zjistíme až po narození, může v některých případech dojít k srdečnímu, poté multiorgánovému selhání a úmrtí dítěte. Zjistíme-li však kritickou VSV před narozením, můžeme léčebně zasáhnout ihned po narození a předejít tak srdečnímu selhání a následným závažným komplikacím.

Prenatální detekce VSV a dalších onemocnění srdce pomocí ultrazvukového (UZ) vyšetření srdce plodu je možná v posledních 30 letech. Díky prof. Milanu Šamánkovi [1, 2], zakladateli moderní československé dětské kardiologie, má prenatální kardiologie v České republice (ČR) dlouhou tradici. Československo patřilo k prvním zemím, ve kterých se začalo prenatální ultrazvukové vyšetření srdce provádět – první UZ vyšetření srdce plodu provedl prim. MUDr. Škovránek v roce 1981, který také vypracoval metodiku vyšetření fetálního srdce [3] a publikoval první výsledky [4, 5, 6, 7]. V roce 1986 bylo v celé republice zavedeno celoplošné screeningové vyšetření srdce plodu ve 2. trimestru těhotenství. O další rozvoj prenatální kardiologie a vzdělávání lékařů v této problematice se spolu s prim. MUDr. Škovránkem zasloužil také doc. MUDr. Jan Marek [8, 9, 10], který napsal také první českou monografii zabývající se touto problematikou [11]. Díky osobní aktivitě některých dětských kardiologů došlo k významnému zefektivnění prenatálního kardiologického screeningu v některých regionech (MUDr. J. Homola – Severočeský kraj, MUDr. Z. Jelínek, MUDr. J. Navrátil – Jihomoravský kraj).

Vyšetření srdce plodu je součástí třístupňového ultrazvukového vyšetření během těhotenství, které provádějí gynekologové. Při podezření na vrozenou srdeční vadu je těhotná odeslána na specia-

lizované pracoviště dětské kardiologie, kde je stanovena definitivní diagnóza. Při zjištění VSV u plodu je třeba poskytnout rodině co největší množství informací o charakteru VSV, jejím možném vývoji, možných léčebných postupech včetně předpokládaných intervencí po narození a o prognóze VSV. Rodině jsou také nabídnuta další vyšetření – podrobné UZ vyšetření plodu, které by mohlo odhalit možnou přítomnost přidružené extrakardiální anomálie, a genetická konzultace včetně vyšetření karyotypu plodu. Porod dítěte se závažnou VSV je směřován do zdravotnického centra, které je schopno zajistit po narození kvalifikovanou katetrizační a kardiochirurgickou léčbu. V případě velmi závažné VSV s infaustní nebo nejistou prognózou často s dalšími přidruženými extrakardiálními anomáliemi a genetickým postižením má těhotná možnost se rozhodnout pro umělé ukončení těhotenství.

V případech dalších onemocnění srdce – srdeční arytmie a kardiomyopatie – lze léčebně zasáhnout již prenatálně. Při zjištění závažné srdeční arytmie plodu lze medikamentózně (podáním antiarytmik matce nebo přímo plodu) ovlivnit rozvoj srdečního selhání nebo léčit již rozvinuté srdeční selhání plodu intrauterinně a příznivě tak ovlivnit osud plodu.

Česká republika patří k zemím s nejvyšší prenatální detekcí VSV v Evropě. Prenatální detekce všech VSV se zvýšila z 0,6 % v roce 1986 na 36,5 % v roce 2009 [12, 13] a prenatální detekce kritických VSV v ČR se pohybuje v posledních letech (2002–2009) od 70 do 83 %. Podobně vysoká prenatální detekce závažných VSV je v oblasti Paříže (80 %) a v Londýně (60 %). V letech 1986–2009 bylo v ČR detekováno celkem 2261 VSV prenatálně, 669 (33 %) těchto plodů mělo ještě další přidružené extrakardiální anomálie. U 55,5 % plodů s VSV bylo provedeno umělé ukončení těhotenství, u 6,8 % plodů došlo k intrauterinnímu úmrtí.

Příznivé výsledky jsou dosaženy také v managementu a léčbě závažných srdečních arytmií prenatálně. Supraventrikulární tachykardie byla v ČR diagnostikována u 87 plodů, 9 (10 %) z nich zemřelo. Z 62 léčených plodů byla léčba úspěšná u 85 %, došlo u nich ke konverzi tachykardie. Další závažná arytmie – kompletní atrioventrikulární blokáda – byla diagnostikována u 29 plodů. Tři těhotenství byla přerušena. Z 26 pokračujících těhotenství bylo 18 plodů léčeno, 16 z nich žije, dvě děti zemřely po narození. Z 8 neléčených plodů došlo u dvou k intrauterinnímu úmrtí.

Přímá léčebná intervence u plodu s VSV je prenatálně prováděna pouze v několika centrech na světě a zůstává stále otázkou k diskusi. Jednak připadá v úvahu pouze u velmi malého spektra prenatálně diagnostikovaných VSV a jednak rizikový zákrok ohrožuje kromě plodu i samotnou matku. U vrozené stenózy chlopně aorty a plicnice se provádí perkutánní balonková valvuloplastika (VLP) zúžené chlopně. U aortální stenózy je cílem valvuloplastiky zabránit regresi růstu levé srdeční komory a vývoji hypoplazie levého srdce. V dětské nemocnici v Bostonu, jediné nemocnici na světě, která se prenatálním srdečním intervencím věnuje ve větším rozsahu, provedli v letech 2000–2008 valvuloplastiku aortální chlopně celkem u 70 plodů, u 52 (74 %) z nich byla technicky úspěšná [14]. Příznivý vývoj levé srdeční komory a možnost dvoukomorové cirkulace po narození byl po VLP zachován u 17 (24 %) dětí. U 8 (12 %) plodů naopak došlo k intrauterinnímu úmrtí během těhotenství, žádná matka nebyla výkonem provedeným na tomto pracovišti ohrožena.

V budoucnu se bude prenatální diagnostika VSV posouvat do nižších týdnů gestace. Již dnes je standardní prenatální detekce VSV ve II. trimestru těhotenství (18.–22. týden) ovlivněna prenatálním screeningem v I. trimestru (11.–14. týden) zahrnujícím UZ vyšetření, měření nuchálního projasnění, detekci přítomnosti nosní kůstky a biochemický screening. Tímto kombinovaným screeningem jsou zachyceny vysoce rizikové plody a časné detekovány vrozené vývojové vady včetně VSV a chromozomálních postižení. Tato riziková těhotenství jsou často ukončována, bohužel dnes někdy i bez detailnějšího vyšetření srdce plodu. Úlohou prenatálních kardiologů je proto stanovit co nejpřesnější diagnózu VSV i v nízkém týdnu gestace a poskytnout rodině dostatek informací pro její rozhodnutí o osudu těhotenství.

Po více než dvaceti letech zkušeností s prenatální diagnostikou VSV je dnes často diskutován obecný význam jejího přínosu pro společnost. Ten jednoznačně najdeme v prenatální diagnostice závažných arytmií a jejich léčbě. Prenatální diagnostika a úspěšná léčba nejen za-

chrání život dítěte před narozením, ale uvádí do společnosti v drtivé většině člověka bez významnějšího postižení. Na druhou stranu včasný záhyt těchto prognosticky nejhorších postižení nabízí rodině včasným ukončením těhotenství alternativu, mnohdy akceptovatelnější, než je úmrtí dítěte po narození nebo jeho dlouhodobé strádání po mnoha paliativních operacích. Prenatální diagnostika snižuje v mnoha případech předoperační morbiditu a v některých případech má i vliv na lepší pooperační průběh. V budoucnu lze také očekávat další rozvoj přímých fetálních intervencí, i když jejich výsledky dnes nejsou jednoznačně přesvědčivé. Při srovnání osudu dětí s prenatálně a postnatálně diagnostikovanou srdeční vadou některá pracoviště uvádějí, že se osud těchto dětí příliš neliší, neboť skupina prenatálně diagnostikovaných VSV je skupinou závažnější. Prenatálně diagnostikované VSV byly detekovány právě proto, že jsou komplexnější povahy, mají často další přidružené extrakardiální anomálie a chromozomální postižení [15, 16, 17].

Hlavní úlohou prenatální kardiologie při nálezů VSV stále zůstává poskytnutí co nejpřesnějších informací rodině nezbytných pro její rozhodnutí o dalším osudu těhotenství a při pokračujícím těhotenství zajistit další management těhotenství tak, aby dítěti po narození byla poskytnuta co nejrychleji adekvátní péče.

Literatura

1. Šamánek M, Břešťák M, Škovránek J. Prenatální kardiologie. Čs. Pediat. 1986; 8: 475–480.
2. Šamánek M, Škovránek J. První výsledky prenatální detekce malformací a poruch funkce srdce „rizikových“ plodů. Čas. Lék. čes. 1988; 50: 1549–1551.
3. Škovránek J. Možnosti a způsob ultrazvukového vyšetření srdce plodu. Čas. Lék. čes. 1988; 127: 1380–1383.
4. Škovránek J. Screeningové ultrazvukové vyšetření srdce plodu. Čs. Gynekol. 1989; 5: 369–371.
5. Škovránek J. Prenatal development of the heart and the blood circulatory system. Physiol. Res. 1991; 40: 25–30.
6. Škovránek J, Marek J, Rázek V, et al. Spectrum, outcome and risk factors of fetal heart disease. Cardiol. Young 1993; 3(Suppl. 1): S366.
7. Škovránek J, Marek J, Povýšilová V. Prenatální kardiologie. Čes.-slov. Pediat. 1997; 52: 332–338.
8. Marek J, Škovránek J, Povýšilová V, Kulovány E. Prenatální diagnostika vrozených srdečních vad v České republice. Mod. Gyn. Porod. 2002; 11: 213–226.
9. Marek J, Škovránek J, Jičínská H, et al. Prenatální diagnostika a léčba supraventrikulární tachykardie plodu. Cor Vasa 2003; 45: 584–591.

10. **Marek J, Tomek V, Škovránek J, Povýšilová V, Šamánek M.** Prenatal ultrasound screening of congenital heart disease in an unselected national population: A 21-year experience. *Heart* 2010 (in print).
11. **Marek J.** *Pediatrická a prenatální echokardiografie.* Praha: Triton, 2003: 1–371.
12. **Tomek V, Marek J, Jičínská H, Škovránek J.** Fetal cardiology in the Czech Republic: Current management of prenatally diagnosed congenital heart diseases and arrhythmias. *Physiol. Res.* 2009; 58(Suppl. 2): S159–S166.
13. **Tomek V.** Dětské kardiocentrum FN Motol, Praha (nepublikovaná data).
14. **McElhinney DB, Marshall AC, Wilkins-Haug LE, et al.** Predictors of technical success and postnatal biventricular outcome after in utero aortic valvuloplasty for aortic stenosis with evolving hypoplastic left heart syndrome. *Circulation* 2009; 120: 1482–1490.
15. **Montana E, Khoury MJ, Cragan JD, et al.** Trends and outcomes after prenatal diagnosis of congenital cardiac malformations by fetal echocardiography in a well defined birth population. Atlanta, Georgia 1990–1994. *J. Am. Coll. Cardiol.* 1996; 28: 1805–1809.
16. **Fesslova V, Nava S, Villa L.** Evolution and long term outcome in cases with fetal diagnosis of congenital heart disease: Italian multicentre study. *Heart* 1999; 82: 594–599.
17. **Kim N, Friedberg MK, Silverman NH.** Diagnosis and prognosis of fetuses with double outlet right ventricle. *Prenat. Diagn.* 2006; 26(8): 740–745.

*MUDr. Hana Jičínská
Dětská nemocnice FN Brno
Černopolní 9
625 00 Brno
e-mail: hjicinska@seznam.cz*

2. Prenatal screening and prenatal detection of congenital heart defects, arrhythmias and other heart disease

In Czechoslovakia (later in the Czech Republic), a prenatal cardiology program developed very early. The nationwide prenatal second-trimester cardiac screening program was started in 1986. Screenings were performed by gynecologists, paediatric cardiologists and rentgenologists in the beginning. Thanks to the personal activities of some paediatric cardiologists (prof. Jan Marek, Dr. Jan Škovránek in Prague, prof. Jaroslav Homola in Ústí nad Labem, Dr. Zdeněk Jelínek and Dr. Jiří Navrátil in Brno), excellent results in the detection rate of CHDs and other heart diseases were achieved. Professor Jan Marek has contributed to further development of prenatal cardiology and education of prenatal cardiologists in Czechoslovakia and later in the Czech Republic.

First-trimester cardiac screening in the Czech Republic was implemented in fetal care in 2003. In the Czech Republic, two ultrasound screening scans are performed and financially supported by the government: one in the first trimester (from 11 to 13+6 weeks of gestation) and one in the second trimester (from 18 to 22 weeks of gestation) of pregnancy. To perform cardiac screening, it was necessary to image a four-chamber view in the fetus from 1986. Evaluations of both outflow tracts (from 1996), and 3-vessel views (from 2010) were implemented to the ultrasound screening protocol in the fetus.

The following publications include information about cardiac screening from 1986 to 2015, about the results of screening, about the improvement in detection rates in the Czech Republic, and about the outcomes of fetuses with CHDs.

2.0.1 ANNEX 2

Tomek V, Marek J, **Jicinska H**, Skovranek J

Fetal Cardiology in the Czech Republic: Current Management of Prenatally Diagnosed
Congenital Heart Diseases and Arrhythmias

Physiological Research 2009;58(2):159-166

Impact factor in 2009 = 1, 430

Main points of the publication:

The management of fetal cardiology and the results of this management in Czechoslovakia (later in the Czech Republic) are presented in this paper. The results of the screening of CHDs from 1986 to 2007, the detection rate of CHDs prenatally and postnatally, and the detection rate of individual CHDs are presented.

From 1986 to 2007, the detection rate of critical CHDs increased from 2.3% to 38% in the Czech Republic. There was a different detection rate of CHDs prenatally and postnatally, and a different detection rate of specific CHDs. The highest detection rate was in cases of double outlet right ventricle, hypoplastic left heart syndrome prenatally, and in ventricular septal defect and aortic stenosis postnatally.

In addition, the paper deals with the most important arrhythmias in the fetus: supraventricular tachycardia and complete atrioventricular block. The possibilities of prenatal treatment of these arrhythmias and the effect of medical treatment were evaluated.

The candidate contributed significantly to the manuscript.

Fetal Cardiology in the Czech Republic: Current Management of Prenatally Diagnosed Congenital Heart Diseases and Arrhythmias

V. TOMEK¹, J. MAREK¹, H. JIČÍNSKÁ², J. ŠKOVŘÁNEK¹

¹Center for Cardiovascular Research and Kardiocentrum, University Hospital Motol, Prague,

²Department of Pediatric Cardiology, University Hospital Brno, Czech Republic

Received May 29, 2009

Accepted October 30, 2009

Summary

Reliable diagnosis of congenital heart defects and arrhythmias *in utero* has been possible since the introduction of fetal echocardiography. The nation-wide prenatal ultrasound screening program in the Czech Republic enabled detection of cardiac abnormalities in 1/3 of patients born with any congenital heart disease and up to 83 % of those with critical forms. Prenatal frequency of individual heart anomalies significantly differed from the postnatal frequency. Fetal isolated complete atrioventricular block and supraventricular tachycardia may lead to heart failure and are important causes of fetal mortality. The regression of heart failure was achieved by a conversion to the sinus rhythm in the supraventricular tachycardia and by increase of ventricular rate in the complete atrioventricular block.

Key words

Prenatal • Echocardiography • Congenital heart defect • Arrhythmias • Heart failure

Corresponding author

V. Tomek, Kardiocentrum and Cardiovascular Research Centre, University Hospital Motol, V úvalu 84, 150 08 Prague 5, Czech Republic. Fax: +420 22443 2915. E-mail: viktor.tomek@fnmotol.cz

Introduction

Antenatal detection of congenital heart diseases by cross-sectional echocardiography has been possible for almost 20 years and has provided a new information

on the early evolution of cardiac malformations. Since 1980, the centralized healthcare system in the Czech Republic enabled the creation of a comprehensive registry of all the pediatric patients born with congenital heart disease in the territory. In 1986, a nation-wide echocardiographic prenatal screening has been established (Šamánek *et al.* 1986). The screening is performed between 18 to 21 weeks of gestation (government guaranteed second level prenatal ultrasound scan program) by a local obstetrician/gynecologist in every pregnant woman resident in the Czech Republic. A routine ultrasound scan is based on two-dimensional imaging to obtain a good quality four-chamber view and to visualize the crossing of the great arteries as well as to assess the heart rhythm and frequency.

The normal cardiac rhythm in fetuses is characterized by a regular heart rate ranging between 100 and 180 beats per min., depending on gestational age and degree of fetal activity, with a normal 1:1 atrioventricular conduction at each cardiac cycle. Based on that definition, fetal heart arrhythmias are defined as any irregularity in the heart rate or abnormally slow or fast heart rate. Fetal arrhythmias have been diagnosed in at least 2 % of pregnancies during screening ultrasound examination, but only less than 10 % of all cases are of a clinical relevance. Major clinically relevant fetal arrhythmias detected were supraventricular tachycardias (SVT), atrial flutter and complete atrioventricular block (CAVB). All of them should be referred to a specialized prenatal centre.

Congenital Heart Diseases (CHD)

Pregnancies suspected as having congenital heart disease are referred to the centre for final evaluation performed exclusively by an experienced prenatal (pediatric) cardiologist. Echocardiographic examination is completed by subsequent specialized gynecologic ultrasound investigation either to exclude or to specify extracardiac abnormality. A genetic examination including karyotyping is offered and a complete counseling is carried out. All fetuses born alive with significant CHD are delivered at an obstetric clinic adjacent to the pediatric cardiologic centre and are admitted to its intensive care unit immediately after the delivery. Prenatal diagnosis is confirmed within the first hour of life and necessary therapeutic measures are carried out without delay. In case of termination prior to 24th week of gestation, prenatal death, or an early postnatal death, the post mortem examination is performed by a fetopathologist experienced in cardiovascular system (Šamánek *et al.* 1985, 1986).

To assess the effectiveness and impact of fetal cardiac screening for each CHD, the number of antenatally diagnosed fetuses was compared to a hypothetical number estimated using the prevalence of the CHD in the Czech Republic between 1986 and 2007. The postnatal prevalence of individual heart lesions was calculated using the data of the nation-wide survey (Šamánek *et al.* 1999). Antenatal diagnosis was confirmed or modified by a post-mortem study in all the fetuses undergoing an early termination and in those who died "in utero" or postnatally whether treated or not. All live-born children with an abnormal antenatal scan were examined by experienced neonatologists and pediatric cardiologists.

Results

Prenatal echocardiographic examinations were performed in 10 027 fetuses between 13 to 41 weeks of gestation (median 23 weeks). In the entire cohort, a congenital heart disease was found in 1830 (18.3 %) fetuses (545 had additional extra cardiac anomalies).

Between 1986 and 2007, 2 380 909 children were live-born in the Czech Republic. Of these, 14 666 children have been estimated to be born with a congenital heart disease (6.16/1 000 livebirths). In total, 1 999 subjects estimated to be born with an atrial septal defect (prevalence 0.53/1 000 livebirths) and patent arterial duct (prevalence 0.31/1 000 livebirths) were excluded from the study protocol as the communications are physiological at this

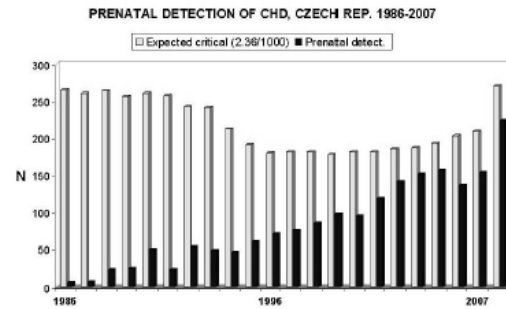


Fig. 1. Prenatal detection of congenital heart diseases compared to the calculated numbers of children expected to be born with critical forms of cardiac abnormalities.

fetal stage. Out of the remaining 12 667 children assumed to be born with CHD, 4 779 children were expected to be born with a "critical" form of CHD (35.1 % of all CHD, 2.3/1 000 livebirths).

Between 1986 and 2007, 1 830 fetal CHD have been diagnosed prenatally in Czech Republic, giving the overall prenatal detection rate of 14.1 %. Detection rate increased from 0.6 % in 1986 to 30.7 % in 2007. Detection rate of critical heart diseases in the whole period was 38.3 %, and increased from 2.3 % in 1986 to 83 % in 2007 (Fig. 1).

Most frequent prenatally detected lesions were atrioventricular septal defect occurring in 15.2 %, hypoplastic left heart syndrome in 15 %, ventricular septal defect in 9.1 % and double outlet right ventricle in 8.7 % fetuses.

Prenatal detection rate of individual heart lesions was compared to their estimated postnatal frequencies calculated from our epidemiological data (Šamánek *et al.* 1989). Prenatal detection rate was high in the double outlet right ventricle (77.3 %), hypoplastic left heart (50.6 %), Ebstein anomaly (50 %), atrioventricular septal defect (42.9 %) and a single ventricle (42.5 %). Prenatal detection rate was low in pulmonary stenosis (3.2 %), in ventricular (2.4 %) and atrial (0.8 %) septal defects. We have found only one case of an isolated total anomalous pulmonary venous drainage.

Prenatal frequency of individual heart anomalies significantly differed from the postnatal one. Postnatally, the most frequent cardiac lesion, ventricular septal defect (41.6 % of all CHD), was detected in only 9.1 % of all prenatally examined heart lesions, aortic stenosis (postnatal frequency 7.8 %) was prenatally diagnosed in 4.9 %. The proportion of postnatal and prenatal frequency of

Table 1. Outcome of pregnancies with prenatally diagnosed congenital heart diseases (associated extra cardiac anomalies in 545 fetuses [30 %]).

Year	CHD (n)	Termination (%)	Intrauterine death (%)	Live-born alive (%)
<1990	106	64.1	28.9	29.6
1991	21	76.2	20.0	50.0
1992	52	57.7	18.2	33.3
1993	47	59.6	5.3	50.0
1994	45	40.0	3.7	38.5
1995	60	70.0	16.7	40.0
1996	70	65.8	16.7	65.0
1997	75	61.3	17.2	75.0
1998	85	60.0	8.8	87.0
1999	97	68.0	6.5	75.9
2000	94	56.4	4.9	76.9
2001	118	54.2	16.7	68.9
2002	141	52.4	7.5	80.6
2003	151	60.3	3.3	86.2
2004	155	52.0	1.4	91.0
2005	136	59.0	7.1	92.0
2006	153	51.0	1.3	92.0
2007	224	54.0	1.0	94.0
<i>Total</i>	1830	58.0	7.7	78.0

transposition of the great arteries was equal (5.4 %). In hypoplastic left heart, atrioventricular septal defect and double outlet right ventricle prenatal frequency was higher (15.1 %, 15 %, 8.7 %) as compared to postnatal frequency (3.9 %, 3.9 %, and 1.1 % respectively).

The early termination was performed in 1040 (56.9 %) cases. Sixty fetuses (7.6 %) died *in utero*, and 728 (92.4 % of continuing pregnancy) were born alive. Survival of the live-born babies gradually increased and reached 94 % in 2007 (Table 1). Decreasing rate of intrauterine deaths in recent years is caused probably by the early termination of complex heart diseases associated with extracardiac malformations and chromosomal aberrations that diagnosed more frequently due to improvement of integrated prenatal screening in the Czech Republic.

Fetal Arrhythmias

Supraventricular tachycardias (SVT)

Most of all prenatally diagnosed tachyarrhythmias

are supraventricular. Fetal supraventricular tachycardia complicated by the myocardial dysfunction and hydrops fetalis carries a significant risk of morbidity and mortality (Simpson *et al.* 1998). Intrauterine conversion of SVT by antiarrhythmic drugs became standard approach to prevent development of the hydrops. The intrauterine treatment, however, may not always be successful either because of a low transplacental drug transfer (in both normal and edematous placenta), or because an inadequate response of the fetal myocardium (Naheed *et al.* 1996).

Re-entry tachycardias are the most common form, followed by the atrial flutter and the ectopic atrial tachycardia (van Engelen *et al.* 1994). Precise identification of the type of the arrhythmia using pulsed Doppler sampling of flow in the superior vena cava and the ascending aorta may contribute to good results of treatment (Fouron *et al.* 2003). The study goal is to distinguish between the tachycardia with a short ventriculoatrial time (usually atrioventricular re-entry) and the tachycardia with a long ventriculoatrial time (usually atrial ectopic tachycardia).

We use digoxin as the first choice drug in all the fetuses with SVT requiring a treatment. Sotalol (class III agent with a β -blocker activity) is added in the fetuses in whom a conversion to sinus rhythm could not be achieved despite a therapeutic maternal digoxinemia of 2-3 ng/ml or in those considered having an ectopic SVT. In one severely hydropic fetus in the 23rd week of gestation, an intraumbilical infusion of adenosine and cordarone was used with success.

The severity of heart failure in each fetus can be scored using the Fetal Heart Failure Score (Falkensammer *et al.* 2001). This multifactorial score combines assessment of direct and indirect markers of cardiovascular function. Presence of hydrops, umbilical venous Doppler, heart size, myocardial function, and arterial Doppler are all scored at a scale from 0 to 2 points. The score of 10 indicates a normal cardiovascular profile.

The cardiothoracic index in fetus may be measured from a standard transverse section of the chest showing the four chamber view. The heart area is compared to the area of the thorax. Normally, the ratio is less than 0.35. Ventricular shortening fraction (SF) can be measured using M-mode and its normal value is 0.28 to 0.46.

Our results

Eighty six fetuses with SVT (reentry tachycardia

in 59, ectopic in 14 and atrial flutter in 13 cases) have been examined in our centre, 9 of them died (10 %).

The hemodynamic measurement was performed in 35 fetuses with a supraventricular tachycardia. Out of those, 27 fetuses responded to the therapy by the conversion to the sinus rhythm and 8 fetuses did not respond. In the non-responders, the ECHO parameters of the heart failure did not change significantly whereas in the responders all the parameters improved significantly: cardiothoracic index changed from 0.34 ± 0.06 to 0.30 ± 0.06 ($p<0.001$), shortening fraction improved from 0.28 ± 0.06 to 0.36 ± 0.07 ($p=0.001$) and Fetal Heart Failure Score improved from 6.6 ± 2.0 to 9.7 ± 0.4 ($p<0.001$). To predict the effectiveness of the prenatal treatment, the ECHO indices prior to the initiation of the treatment were compared between the responding and the non-responding fetuses. Only the shortening fraction was significantly lower in the non-responders ($p<0.001$) as compared to the responding fetuses.

Isolated complete atrioventricular block (CAVB)

Isolated congenital complete atrioventricular block is caused predominantly by maternal anti-Ro and anti-La autoantibodies in a susceptible fetus typically between 20 and 24 weeks of gestation (Buyon *et al.* 1998). Prenatal CAVB develops in 1 % to 2 % of anti-Ro/La antibody positive pregnancies (Gladman *et al.* 2002, Brucato *et al.* 2001). The antibodies enter the fetal circulation and subsequently may lead to an immune-mediated tissue injury resulting in progressive destruction of the AV node, myocardial inflammation, and in severe cases in endocardial fibroelastosis and dilated cardiomyopathy (Moak *et al.* 2001).

The anti-Ro/La antibodies are typically found in systemic lupus erythematosus and Sjögren's syndrome (Schmidt *et al.* 1991), but often the fetal CAVB may be the first sign of an auto-immune disease in a pregnant woman having no clinical symptoms.

The compensatory cardiac mechanism in fetuses with complete atrioventricular block is increasing its stroke volume (Rudolph *et al.* 1976). If the heart fails to adapt, fetal hydrops develops subsequently with a high risk of fetal or neonatal death. The identified risk factors for adverse outcome are fetal hydrops, endocardial fibroelastosis, premature delivery and the fetal heart rate ≤ 55 bpm (Groves *et al.* 1996). Transplacental treatment may improve the outcome of prenatally diagnosed complete atrioventricular block without a structural heart disease.

To improve the pregnancy outcome, numerous preventive and therapeutic approaches have been used with a variable success. The treatment protocol published by Jaeggi *et al.* (2004) is used in our centre. According to this protocol, maternal peroral dexamethasone is initiated upon the diagnosis of the immune-mediated CAVB in the dose of 4 or 8 mg/d for initial 2 weeks, then followed by 4 mg/d up to the beginning of the third trimester when the dose is decreased to 2 mg/d. Beta-sympathomimetic maternal peroral therapy (salbutamol 3-4 x 10 mg) is added to increase the fetal cardiac output in fetuses with the average heart rate below 55 bpm. No serious adverse effects have been encountered so far. Oligohydramnios did occur in 20 % of cases after chronic steroid treatment and resulted in premature deliveries in some (Costedoat-Chalumeau *et al.* 2003).

Our results

Total of 24 fetuses with complete atrioventricular block with the mean ventricular rate of 58.6 ± 9.4 were diagnosed between the 19th and 32nd week of gestation (median 21 weeks). Anti-Ro and/or anti-La were detected in 18 mothers (75 %). Fetal heart failure was present in 15/20 (63 %) fetuses. Out of 22 ongoing pregnancies (two early terminations), all fetuses survived and 2 with intermittent complete atrioventricular block converted to sinus rhythm.

The same hemodynamic parameters as in the SVT protocol were analyzed in 12 fetuses with a diagnosis of the complete AV block to assess the effectiveness of the transplacental treatment. Echocardiographic signs of fetal heart failure were compared before and after the treatment (dexamethasone + salbutamol). Before to the treatment, 8 of 12 fetuses were hydropic (all of them had ventricular heart rate below 60 bpm). After the treatment, the shortening fraction increased from 0.34 ± 0.05 to 0.41 ± 0.06 ($p=0.03$). Cardiothoracic index decreased from 0.35 ± 0.09 to 0.31 ± 0.06 ($p=0.01$), and fetal heart failure score improved from 7.82 ± 1.72 to 9.27 ± 0.65 ($p=0.01$). Ventricular rate increased from 55.75 ± 7.36 to 63.25 ± 10.48 ($p=0.02$).

According to the obvious improvement in outcome and in agreement with the present state of knowledge (Jaeggi *et al.* 2005), we are convinced that there is no solid ground to deny the benefit of transplacental steroid treatment to the fetuses with the immune-mediated CAVB.

Ventricular tachycardia is rare prenatally,

contributing by less than 1 % to all the fetal arrhythmias. It may be present in association with a long QT syndrome. The fetal combination of sinus bradycardia, second degree atrioventricular block and transient ventricular tachycardia should raise a high suspicion of the long QT syndrome (Hofbeck *et al.* 1997). We have also suggested that an impaired ventricular relaxation documented by the short early deceleration time of the left ventricular filling can contribute to the final diagnosis of the long QT syndrome (Tomek *et al.* 2009).

Conclusions and perspectives

Reliable diagnosis of congenital heart defects and arrhythmias in utero has been possible since the introduction of fetal echocardiography. Prenatal echocardiography has the potential to improve postnatal survival in infants with critical heart defects, especially those with duct-dependent systemic or pulmonary circulations. If the diagnosis is known prenatally, the appropriate therapy avoiding the risk of circulatory collapse can be established immediately after the birth.

In the Czech Republic, a centralized health care system allowed for the creation of a nation-wide prenatal cardiac screening program (Šamánek *et al.* 1986). Referral for specialized fetal echocardiography is made on the basis of the risk factors for congenital heart defects or when obstetric screening raises a possibility of a fetal CHD or an arrhythmia. Data providing risk factors and proportion of individual heart anomalies and their postnatal outcome have been widely published (Allan *et al.* 1994, Cooper *et al.* 1995, Paladini *et al.* 2002). However, most infants with CHD are born to women without high-risk factors of heart anomalies (Simpson 2004). We know from our experience that more than 40 % of all the prenatally detected heart diseases did not carry any risk factor of CHD (Škovránek *et al.* 1997). The identification of fetuses with abnormal four-chamber views or with impossibility to visualize the crossing of the great arteries on screening examination improved detection of CHD prenatally. In recent years, the detection rate of cardiac abnormalities in the second trimester has also been influenced by the improved screening tests performed at the first trimester, such as the nuchal translucency measurement and biochemical screening tests (Makrydimas *et al.* 2005). Antenatal detection of complex heart diseases, along with a relatively high termination rate and the delivery of critical lesions in a specialized centre have had a positive impact

on the surgical outcome in the Czech Republic in accordance with the reported significantly improved morbidity and mortality (Bonnet *et al.* 1999, Yates 2004).

True prenatal incidence of CHD remains unknown as it is impossible to examine all the fetuses that die during the early development either naturally or through terminations for extracardiac/chromosomal lesions. Several studies proved that the increase of the prevalence of cardiac anomalies with the decreasing fetal age contributes to relatively high numbers of miscarriages (Gerlis 1985, Hoffman 1995). Our study has shown that the spectrum of prenatally diagnosed CHD differs significantly from the postnatal spectrum with markedly higher proportion of associated additional abnormalities. Small ventricular septal defects, mild aortic and pulmonary stenoses and total anomalous pulmonary venous connection are not usually detected on fetal echocardiographic screening. On the other hand, hypoplastic left heart syndromes, atrioventricular septal defects and double outlet right ventricles are more frequent prenatally as compared to their postnatal frequency.

The option for prenatal treatment of congenital heart diseases is challenging and at the same time controversial. The experience with a fetal aortic and pulmonary balloon valvuloplasty has been reported. The indication for a prenatal catheterization is based on the hypothesis that timely and effective intervention for severe aortic stenosis *in utero* may prevent the development of postnatal hypoplastic left heart syndrome. The Boston group (Tworetzky *et al.* 2004) revealed that only in 9 of 24 fetuses considered for the fetal balloon valvuloplasty a technically successful dilation was achieved and only two of those did not developed hypoplasia of the left ventricle and were postnatally capable of the biventricular circulation. However, some centers have reported successful pulmonary valve dilations and subsequent biventricular management of fetuses with pulmonary atresia and intact ventricular septum, but the outcome remains unknown (Tulzer *et al.* 2002).

Fetal tachycardia is an important cause of fetal morbidity and mortality (Simpson *et al.* 1998). The efficacy of transplacental pharmacological treatment has been well established in supraventricular tachycardia. Precise identification of the type of arrhythmia should influence the strategy of the therapy (Fouron *et al.* 2003). Supraventricular tachycardia without an appropriate treatment usually leads to fetal heart failure with hydrops and fetal death. Prenatal treatment may convert

supraventricular tachycardia to the sinus rhythm in most of the patients and prenatal ECHO allows for a reliable monitoring of the fetal heart and placental circulatory function. The probability of a successful treatment has been significantly lower in fetuses with hydrops. Altered systolic function prior to the treatment was a significant predictor of failure of the prenatal pharmacological treatment in our study.

Fetal isolated complete atrioventricular block is usually a result of damage to the fetal atrioventricular conduction tissue due to the placental transfer of maternal auto-antibodies. Attempts to reverse an already established complete atrioventricular block by the transplacental steroid treatment have been unsuccessful with few exceptions (Jaeggi *et al.* 2004). In our setting, 2 fetuses with an intermittent complete atrioventricular block converted to the sinus rhythm during the maternal steroid therapy.

To prevent the development of an isolated CAVB would be the ideal strategy of the prenatal management. However, markers predicting which fetus will in the presence of maternal anti-Ro/La antibodies develop a complete AV block are not yet identified.

General prophylactic steroid treatment on the basis of the presence of the auto-antibodies alone has not been recommended (Jaeggi *et al.* 2004). Nevertheless, fetuses with an isolated complete atrioventricular block have a significant intra-uterine mortality (Groves *et al.* 1996) and in spite of the irreversibility of the complete heart block, treatment with fluorinated steroids has been associated with an improved survival, probably because of a lower rate of the immune-mediated complications such as endocardial fibroelastosis, myocarditis and hepatitis (Jaeggi *et al.* 2004) and we therefore recommend maternal dexamethasone treatment in all the isolated fetal CAVB.

Conflict of Interest

There is no conflict of interest.

Acknowledgements

The publication was supported by the grant NR9451-3/2007, Internal Grant Agency, Ministry of Health, Czech Republic and 1MO510, Ministry of Education of the Czech Republic.

References

- ALLAN LD, SHARLAND GK, MILBURN A, LOCKHART SM, GROVES AMM, ANDERSON RH, COOK AC, FAGG NLK: Prospective diagnosis of 1,006 consecutive cases of congenital heart disease in the fetus. *J Am Coll Cardiol* 23: 1452-1458, 1994.
- BONNET D, COLTRI A, BUTERA G, FERMONTE L, LE BIDOIS J, KACHANER J, SIDI D: Detection of transposition of the great arteries in fetuses reduces neonatal morbidity and mortality. *Circulation* 99: 916-918, 1999.
- BRUCATO A, FRASSI M, FRANCESCHINI F, CIMAZ R, FADEN D, PISONI MP, MUSCARÁ M, VIGNATI G, STRAMBA-BADIALE M, CATELLI L: Risk of congenital complete heart block in newborns of mothers with anti-Ro/SSA antibodies detected by counterimmuno-electrophoresis: a prospective study of 100 women. *Arthritis Rheum* 44: 1832-1835, 2001.
- BUYON JR, HIEBERT R, COPEL J, CRAFT J, FRIEDMAN D, KATHOLI M, LEE LA, PROVOST TT, REICHLIN M, RIDER L, RUPEL A, SALEEB S, WESTON WL, SKOVRON ML: Autoimmune-associated congenital heart block: demographics, mortality, morbidity and recurrence rates obtained from the national lupus registry. *J Am Coll Cardiol* 31: 1658-1666, 1998.
- COOPER MJ, MARLENE AE, DYSON DC, ROGE CL, TARNOFF H: Fetal echocardiography: retrospective review of clinical experience and an evaluation of indications. *Obstet Gynecol* 86: 577-582, 1995.
- COSTEDOAT-CHALUMEAU N, AMOURA Z, LE THI HONG D, WECHSLER B, VAUTHIER D, GHILLANI P, PAPO T, FAIN O, MUSSET I, PIETTE JC: Questions about dexamethasone use for the prevention of anti-SSA related congenital heart block. *Ann Rheum Dis* 62: 1010-1012, 2003.
- FALKENSAMMER CB, HUHTA JC: Fetal congestive heart failure: correlation of Tei index and cardiovascular score. *J Perinat Med* 29: 390-398, 2001.

- FOURON JC, FOURNIER A, PROULX F, LAMARCHE J, BIGRAS JL, BOUTIN C, BRASSARD M, GAMACHE S: Management of fetal tachyarrhythmia based on superior vena cava/aorta Doppler flow recordings. *Heart* 89: 1211-1216, 2003.
- GERLIS LM: Cardiac malformations in spontaneous abortions. *Int J Cardiol* 7: 29-43, 1985.
- GLADMAN G, SILVERMAN ED, YUK-LAW, LUY L, BOUTIN C, LASKIN C, SMALLHORN JF: Fetal echocardiographic screening of pregnancies of mothers with anti-Ro and/or anti-La antibodies. *Am J Perinatol* 19: 73-80, 2002.
- GROVES AMM, ALLAN LD, ROSENTHAL E: Outcome of isolated congenital complete heart block diagnosed in utero. *Heart* 75: 190-194, 1996.
- HOFBECK M, ULMER H, BEINDER E, SIEBER E, SINGER H: Prenatal findings in patients with prolonged QT interval in the neonatal period. *Heart* 77: 198-204, 1997.
- HOFFMAN JI: Incidence of congenital heart disease. II. Prenatal Incidence. *Pediatr Cardiol* 16: 155-165, 1995.
- JAEGGI ET, NII M: Fetal brady- and tachyarrhythmias: new and accepted diagnostic and treatment methods. *Semin Fetal Neonatal Med* 10: 504-515, 2005.
- JAEGGI ET, FOURON JC, SILVERMAN ED, RYAN G, SMALLHORN J, HORNBERGER LK: Transplacental fetal treatment improves the outcome of prenatally diagnosed complete atrioventricular block without structural heart disease. *Circulation* 110: 1542-1548, 2004.
- MAKRYDIMAS G, SOTIRIADIS A, HUGGON IC, SIMPSON J, SHARLAND G, CARVALHO JS, DAUBENEY PE, IOANNIDIS JP: Nuchal translucency and fetal cardiac defects: a pooled analysis of major fetal echocardiography centres. *Am J Obstet Gynecol* 192: 89-95, 2005.
- MOAK JP, BARRON KS, HOUGEN TJ, WILES HB, BALAJI S, SREERAM N, COHEN MH, NORDENBERG A, VAN HARE GF, FRIEDMAN RA, PEREZ M, CECHIN F: Congenital heart block: development of late-onset cardiomyopathy, a previously underappreciated sequela. *J Am Coll Cardiol* 37: 238-242, 2001.
- NAHEED ZJ, NAHEED JF, STRASBURGER BJ, DEAL DW, BENSON JR, GIDDING SS: Fetal tachycardia: mechanisms and predictors of hydrops fetalis. *J Am Coll Cardiol* 27: 1736-1740, 1996.
- PALADINI D, RUSSO M, TEODORO A, PACILEO G, CAPOZZI G, MARTINELLI P, NAPPI C, CALABRO R: Prenatal diagnosis of congenital heart disease in the Naples area during the years 1994-1999 - the experience of a joint fetal-pediatric cardiology unit. *Prenat Diagn* 22: 545-552, 2002.
- RUDOLPH AM, HEYMAN MA: Cardiac output in the fetal lamb: the effects of spontaneous and induced changes of heart rate on right and left ventricular output. *Am J Obstet Gynecol* 124: 183-192, 1976.
- SCHMIDT KG, ULMER HE, SILVERMAN NH, KLEINMAN CS, COPEL JA: Perinatal outcome of fetal complete atrioventricular block: a multicenter experience. *J Am Coll Cardiol* 17: 1360-1366, 1991.
- SIMPSON JM, SHARLAND GK: Fetal tachycardias: management and outcome of 127 consecutive cases. *Heart* 79: 576-581, 1998.
- SIMPSON LL: Indications for fetal echocardiography from a tertiary-care obstetric sonography. *J Clin Ultrasound* 32: 123-128, 2004.
- ŠAMÁNEK M, GOETZOVÁ J, BENEŠOVÁ D: Distribution of congenital heart malformations in an autopsied child population. *Int J Cardiol* 8: 235-248, 1985.
- ŠAMÁNEK M, BŘEŠŤÁK M, ŠKOVŘÁNEK J: Prenatal cardiology. (in Czech) *Čs Pediatr* 41: 478-480, 1986.
- ŠAMÁNEK M, GOETZOVÁ J, BENEŠOVÁ D: Causes of death in neonates born with a heart malformation. *Int J Cardiol* 11: 63-74, 1986.
- ŠAMÁNEK M, VOŘÍŠKOVÁ M: Infants with critical heart disease in a territory with centralized care. *Int J Cardiol* 16: 75-91, 1987.
- ŠAMÁNEK M, SLAVÍK Z, ZBOŘILOVÁ B, HROBOŇOVÁ V, VOŘÍŠKOVÁ M, ŠKOVŘÁNEK J: Prevalence, treatment, and outcome of heart disease in live-born children: A prospective analysis of 91,823 live-born children. *Pediatr Cardiol* 10: 205-211, 1989.
- ŠAMÁNEK M, SLAVÍK Z, ZBOŘILOVÁ B, HROBOŇOVÁ V, VOŘÍŠKOVÁ M: Congenital heart disease among 815,569 children born between 1980 and 1990 and their 15-year survival: a prospective Bohemia survival study. *Pediatr Cardiol* 20: 411-417, 1999.
- ŠKOVŘÁNEK J, MAREK J, POVÝŠILOVÁ V: Prenatal cardiology. (in Czech) *Čs Pediatr* 52: 332-338, 1997.

-
- TOMEK V, ŠKOVŘÁNEK J, GEBAUER RA: Prenatal diagnosis and management of fetal Long QT syndrome. *Pediatr Cardiol* 30: 194-196, 2009.
- TULZER G, ARZT W, FRANKLIN RC, LOUGHNA PV, MAIR R, GARDINER HM: Fetal pulmonary valvuloplasty for critical pulmonary stenosis or atresia with intact septum. *Lancet* 16: 1567-1568, 2002.
- TWORETZKY W, WILKINS-HAUG L, JENNINGS RW, VAN DER VELDE ME, MARSHALL AC, MARX GR, COLAN SD, BENSON CB, LOCK JE, PERRY SB: Balloon dilation of severe aortic stenosis in the fetus: potential for prevention of hypoplastic left heart syndrome. Candidate selection, technique, and results of successful intervention. *Circulation* 110: 2125-2131, 2004.
- VAN ENGELEN AD, WEIJTENS O, BRENNER JI, KLEINMAN CS, COPEL JA, STOUTENBEEK P, MEIJBOOM EJ: Management, outcome and follow-up of fetal tachycardia. *J Am Coll Cardiol* 24: 1371-1375, 1994.
- YATES RS: The influence of prenatal diagnosis on postnatal outcome in patients with structural congenital heart disease. *Prenat Diagn* 24: 1143-1149, 2004.
-

2.0.2 ANNEX 3

Tomek V, **Jicinska H**, Gilik J, Skovranek J, Navratil J, Janousek J

Prenatal diagnosis of congenital heart defects in the Czech Republic during the years 1986 - 2012

Actual Gyn 2014;6:67-72

Main points of the publication:

The results of prenatal detection of congenital heart defects in fetuses in Czechoslovakia (later in the Czech Republic) from 1986 to 2012 and the improvement in the detection rate were published in this paper. The prenatal CHDs detection rate from 1986 to 2012 was compared to the postnatal prevalence of CHDs in accordance with the Bohemia Survival Study (BOSS), which is the study of postnatal prevalence of CHDs, published by professor Šamánek. The valid indication criteria for the specialized echocardiographic evaluation in the fetus, the spectrum of CHDs detected prenatally and the outcomes of fetuses with CHDs were presented as well.

From 1986 to 2012, in total 2996 fetuses with CHD in the Czech Republic were detected. Pregnancies were terminated in 54% of the total (there was additional extracardiac abnormality in 49% of terminated pregnancies). Intrauterine death occurred in 3% of the total; 43% of the total were born. Due to detection of CHDs prenatally and termination of pregnancy in some of them, there was a change in the spectrum of CHDs postnatally. The number of neonates born with hypoplastic left heart syndrome, atrioventricular septal defect, pulmonary atresia, persistent arterial trunk, single ventricle, and Ebstein anomaly decreased.

The candidate contributed to the manuscript and with cases to this study.

Prenatální diagnostika vrožených srdečních vad v České republice 1986–2012

Viktor Tomek¹, Hana Jičínská², Jiří Gilík¹, Jan Škovránek¹, Jiří Navrátil², Jan Janoušek¹

¹Dětské kardiocentrum FN v Motole, Praha

²Dětské kardiologické oddělení Pediatrické kliniky, FN Brno

Korespondenční adresa: MUDr. Viktor Tomek, Dětské kardiocentrum FN v Motole, V úvalu 84, 150 06 Praha 5, tel.: 224 432 963, e-mail: viktor.tomek@fnmotol.cz

Publikováno: 1. 9. 2014 Přijato: 12. 6. 2014 Akceptováno: 22. 8. 2014
Actual Gyn 2014, 6, 67-72 ISSN 1803-9588 © 2014, Aprofema s.r.o.
Článek lze stáhnout z www.actualgyn.com



Citujte tento článek jako: Tomek V, Jičínská H, Gilík J, Škovránek J, Navrátil J, Janoušek J. Prenatální diagnostika vrožených srdečních vad v České republice 1986-2012. Actual Gyn. 2014;6:67-72

PRENATAL DIAGNOSIS OF CONGENITAL HEART DEFECTS IN THE CZECH REPUBLIC DURING THE YEARS 1986-2012

Original article

Abstract

Introduction: Congenital heart defects (CHD) represents the most frequent congenital malformation. Prenatal detection of heart lesions is based on cooperation of screening and specialized echocardiographic examination.

Methods: To assess the success of prenatal detection of heart defects (CHD) we compared the number of prenatal diagnosis with a known prevalence of CHD at birth as determined by prospective Bohemian „BOSS” study. The study established prevalence of all CHD at birth 6.16 per 1 000 liveborn newborns and 2.36 of those with critical forms.

Results: Between 1986 and 2012 were evaluated 2 996 of fetuses with congenital heart defects. A detection rate of CHD reached 47% during recent five years and detection of critical forms exceeded 80%. 1 612 (54%) mothers of fetuses with CHD opted for termination of pregnancy, 49% of them had an extracardiac heart malformations. 1 296 (43%) newborns were born with prenatally detected heart lesion and 90 (3%) fetuses died in utero. Due to high termination rate of fetuses with CHD the number of children with several complexed heart lesions declined (hypoplastic left heart syndrome, pulmonary atresia, single ventricle, persistent arterial trunk, atrioventricular defect and Ebstein anomaly).

Conclusion: The nationwide prenatal ultrasound screening programme enabled detection of 43% of all CHD in recent years. Owing to severity of lesions and associated extracardiac malformations and cultural background, termination rate of fetuses with CHD remains high. High termination rate lead to significant decrease of postnatal incidence of several complex and severe CHD (such as hypoplastic left heart syndrome).

Key words: congenital heart disease, fetus, prenatal diagnosis, ultrasound

Původní práce

Abstrakt

Úvod: Vrozené srdeční vady jsou nejčastější vývojovou vadou plodu. Detekce vrozených srdečních vad u plodu je založena na propojení screeningového a specializovaného echokardiografického vyšetření.

Metodika: Pro posouzení úspěšnosti prenatalního záchytu srdečních vad používáme srovnání s prospektivní studií BOSS o postnatální prevalenci vad v ČR. Prevalence všech srdečních vad byla 6,16 na 1 000 živě narozených dětí a kritických 2,36/1 000 živě narozených dětí.

Výsledky: V České republice se v období 1986-2012 intrauterinně odhalilo 2 996 plodů se srdeční vadou. V posledních 5 letech se záchytnost vad srdce pohybuje v rozmezí 39-47 % a detekce kritických vad přesáhla 80 % z očekávaného počtu VSV. Z celkového počtu fetálně detekovaných VSV se 1 612 (54 %) těhotných rozhodlo pro ukončení gravidity, z nichž 49 % mělo další extrakardiální vadu. Narodilo se 1 296 dětí s prenatalní diagnózou VSV (43 %) a 90 plodů (3 %) zemřelo intrauterinně. Vzhledem k vysoké četnosti ukončení gravidity se mění postnatální spektrum srdečních vad. Snižuje se počet dětí s diagnózou syndromu hypoplázie levého srdce, atrioventrikulárním defektem, atrézií plicnice, společným arteriálním trunkem, společnou komorou a Ebsteinovou anomálií.

Závěr: Prenatální echokardiografie prováděná v celé České republice umožňuje v posledních letech detekci až 47 % všech a více než 80 % kritických srdečních vad. Vysoký počet ukončených těhotenství je nejspíše důsledkem závažnosti srdečních vad a četných přidružených vývojových abnormalit. Četnost ukončení gravidity má vliv na postnatální spektrum srdečních vad, kdy ubývá závažných nebo komplexních srdečních onemocnění (syndromu hypoplázie levého srdce a dalších).

Klíčová slova: vrozená srdeční vada, plod, prenatalní diagnostika, ultrazvuk

Úvod

Zavedení prenatalní diagnostiky srdečních vad a poruch srdečního rytmu souvisí s technologickým rozvojem ultrazvukových přístrojů v 80. letech 20. století. Od té doby se diagnostika srdečních onemocnění stala zcela rutinní součástí screeningového vyšetření ve 2. trimestru. V posledních letech se, byť v omezeném rozsahu, na vyšetření srdce zaměřujeme i při vyšetření v 1. trimestru. Cílem této práce je zhodnocení současného stavu prenatalní diagnostiky v České republice a ozřejmání optimálního postupu při vyšetření srdce plodu.

Organizace fetální echokardiografie

Organizace fetální echokardiografie spočívá v propojení screeningového a specializovaného echokardiografického vyšetření. **Screeningové vyšetření srdce** je součástí prenatalního ultrazvukového vyšetření, které je prováděno především gynekology. Jeho cílem je určení základní srdeční anatomie a funkce. Pro posouzení základní srdeční anatomie je důležité zejména zobrazení symetrických srdečních oddílů (4dutinová projekce) a správných odstupů velkých tepen (15). Není-li srdeční anatomie normální nebo je zachycena porucha srdečního rytmu (vyjma ojedinělých předčasných síňových stahů, které jsou obvykle benigní a vedou jen k nepravidelnosti srdeční akce), má být těhotná odeslána na podrobné vyšetření ke specialistovi v prenatalní kardiologii. Screeningový program, který je založen na multidisciplinární spolupráci, nyní existuje ve většině rozvinutých zemí a dále se prohlubuje. Z doporučení ISUOG (The International Society of Ultrasound in Obstetrics and Gynecology) pro ultrazvukové vyšetření plodu vyplývá, že k efektivnosti takového systému výrazně napomáhá nízký práh při doporučení k echokardiografickému vyšetření u specialisty na prenatalní kardiologii (7). Obdobný doporučující přístup zastává i AIUM (The American Institute of Ultrasound in Medicine) (8) a AEP (Association for European Paediatric Cardiology) (9).

Cílem **specializovaného vyšetření** je přesné určení srdeční vady nebo poruchy srdečního rytmu. Nedílnou a důležitou součástí vyšetření je adekvátní informování rodičů o povaze, léčebných možnostech a prognóze onemocnění s návrhem a zajištěním správné léčby včetně organizace porodu a následné postnatální léčby.

Indikace ke specializovanému prenatalnímu kardiologickému vyšetření

Vycházejí z doporučení ISUOG, AIUM a AEP a zohledňují rizikové faktory pro vznik vrozené srdeční vady (6,9,12,13).

A. Indikace ze strany matky a rodiny

- Metabolické vady matky (diabetes mellitus, fenyketonurie)
- Užívání léků v graviditě, (např. antiepileptika, antidepresiva, nesteroidní antiflogistika), teratogeny v graviditě (lithium, kys. retinová)
- In vitro fertilizace, vícečetné těhotenství
- Prodělané infekce v graviditě (dětské virové choroby, cytomegalovirus, parvovirus, toxoplasmosa event. další)
- Autoimunní onemocnění matky s přítomností autoprotilátek třídy SSA/antiRo a SSB/antiLa
- Přítomnost vrozených srdečních vad nebo kardiomyopatie u matky, otce, sourozenců a prarodičů
- Chromozomální aberace, syndromy a jiná genetická postižení, jako např. myopathie, Marfanův syndrom

B. Indikace ze strany plodu

- Abnormální nález při screeningu srdce (přítomná srdeční vada, podezření na srdeční vadu nebo nejasný nález na srdci)
- Srdeční arytmie nebo abnormální srdeční frekvence (< 100/min, > 180/min)
- Extrakardiální vrozená vývojová vada

- Chromozomální vada
- Hydrops
- Vícečetné těhotenství
- Nevysvětlitelný polyhydramnion
- Zvýšená nuchální translucence
- Absence ductus venosus
- Trikuspidální regurgitace v 1. trimestru
- Absence nosní kůstky

Absolutní indikací ke specializovanému echokardiografickému vyšetření dětským kardiologem je nepochybně nález srdeční vady nebo i podezření na ni. Falešná pozitivita srdeční vady rozhodně není při screeningovém vyšetření chybou. Je vždy lepší odeslat těhotnou ke specializovanému vyšetření „zbytečně“, než vadu přehlédnout nebo dokonce – v nehorším případě – indikovat ukončení gravidity při chybné diagnóze. Nehledě na to, že oprávnění lékaře doporučit ukončení těhotenství je přinejmenším velmi diskutabilní.

Rozhodnutí o dalším osudu plodu včetně eventuální úvahy o ukončení gravidity má být plně v kompetenci rodičů, kteří jsou zodpovědní za své dosud nenarozené dítě. Finální diagnostika a s ní související informování o možnostech léčby a prognóze srdeční vady má tedy zcela zásadní význam pro další osud těhotenství.

Metodika posouzení úspěšnosti záchytu srdečních vad (VSV)

Pro posouzení úspěšnosti prenatalního záchytu VSV používáme srovnání se známou prospektivní studií o postnatální incidenci vad v ČR - BOSS (BOhemia Survival Study) prof. Šamánka (14). V rámci této studie bylo vyšetřeno všech 815 569 živě narozených dětí v Čechách v období 1980-1990 a stanovena prevalence jednotlivých srdečních vad. Studie probíhala v době, kdy prenatalní selekce ještě neměla podstatnější vliv na spektrum dětí narozených se srdeční vadou. Prevalence všech srdečních vad byla stanovena 6,16 VSV na 1 000 živě narozených dětí (2). Za kritické VSV (celkem 35 % všech srdečních vad, 2,36/1 000 živě narozených dětí) považujeme ty vady, které ohrožují dítě po narození významnou hypoxémií, těžkým srdečním selháním nebo kombinací obou příznaků.

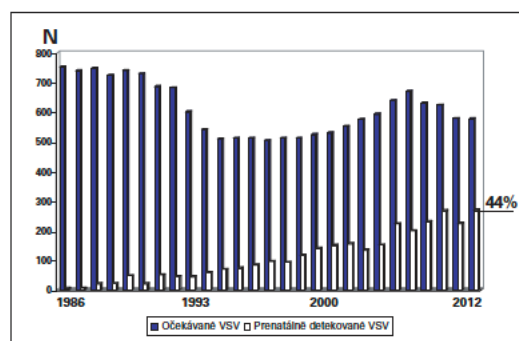
Statistická analýza

Pro analýzu jsme používali SigmaStat 3.5, Systat Software Inc. (San Jose, Kalifornie, USA). Soubory byly testovány na normalitu rozložení. Pro posouzení rozdílu v prenatalním a postnatálním spektru vad byl použit párový t-test nebo Mann-Whitney sum test. Za statisticky významné rozdíly byly považovány parametry s $P < 0,05$.

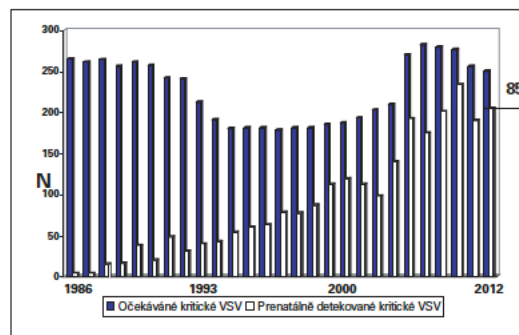
Výsledky prenatalní detekce VSV

V letech 1986-2012 se v ČR živě narodilo 2 953 229 dětí a intrauterinně byla odhalena srdeční vada celkem u 2 996 plodů v gestačním stádiu od 13. do 41. týdne (medián 20. týden). Pro srovnání prenatalního záchytu s postnatální prevalencí nebyly pro posouzení úspěšnosti detekce započítávány diagnózy, které jsou z povahy fetální cirkulace nemožné intrauterinně odhalit, a to tepenná dučež a sekundum defekt septa siní. Při známé postnatální prevalenci VSV byla celková úspěšnost intrauterinní detekce všech srdečních vad 19,7 % a kritických 47 %. Úspěš-

nost fetální detekce se průběžně zvyšovala a v posledních 5 letech se prenatalní záchyt všech VSV pohyboval v rozmezí 39-47 % (**Graf 1**) a detekce kritických vad (postnatální prevalence 2,36/1 000 živě narozených dětí) přesáhla 80 % z očekávaných srdečních vad v daném roce (**Graf 2**). Prenatálně nejčastěji detekovanou vadou byl atrioventrikulární defekt (419 plodů/13,9 %), syndrom hypoplázie levého srdce (387 plodů/12,9 %), defekt septa komor (323/10,8 %), dvojitá pravá komora (246/8,2 %), transpozice velkých tepen (185/6,2 %), Fallotova tetralogie (177/5,9 %) a atrézie plicnice (163/5,4 %) (**Tab. 1**). Nejméně často fetálně detekovanou vadou byl izolovaný totální anomální návrat plicních žil (4 případy).



Graf 1 Úspěšnost detekce všech vrozených srdečních vad



Graf 2 Úspěšnost detekce kritických vrozených srdečních vad

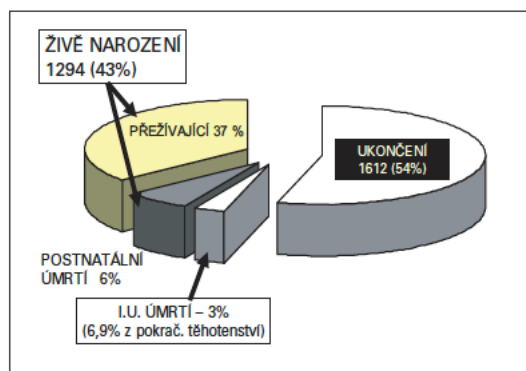
Z celkového počtu 2 996 fetálně detekovaných VSV se 1 612 (54 %) těhotných rozhodlo pro ukončení gravidity. Narodilo se 1 294 dětí s prenatalní diagnózou VSV (43 %), z nich 180 (6 % z odhalených VSV) zemřelo postnatálně (neléčené i léčené) a 90 plodů (3 %) zemřelo intrauterinně. Další extrakardiální vývojová vada byla přítomna u 49 % ukončených těhotenství. Nejčastěji ukončovanou srdeční vadou byl syndrom hypoplastického levého srdce (v 90,6 % případů), společný arteriální trunkus (86,5 %), atrézie plicnice (72,3 %) a dvojitá pravá komora (72,3 %). Vysoký počet ukončených těhotenství s VSV má významný dopad na jejich postnatální prevalenci (**Graf 3**). V období od roku 1986 (zejména však od 90. let) došlo k signifikantně významnému snížení řady diagnóz u dětí:

Tab. 1 Prenatální spektrum vrozeých srdečních vad

Vrozená srdeční vada	N	%	UUT	UUT %
Atrioventrikulární defekt septa	419	13,9	257	61,3
Syndrom hypoplázie levého srdce	387	12,9	351	90,6
Defekt septa komor	323	10,8	130	40,2*
Dvojvýtoková pravá komora	246	8,2	178	72,3
Transpozice velkých tepen	185	6,2	23	12,4
Fallotova tetralogie	177	5,9	43	24,3
Atrézie plicnice	163	5,4	118	72,3
Aortální stenóza	165	5,5	70	42,4
Společná komora	144	4,8	70	48,6
Koarktace aorty	141	4,7	22	15,6
Společný arteriální trunкус	104	3,4	90	86,5
Trikuspidální atrézie	93	3,1	47	50,5
Pulmonální stenóza	71	2,4	20	28,2
Ebsteinova anomálie	60	2	20	33,3
Ostatní	318	10,8	173	54,4

UUT – ukončení těhotenství

* UUT vždy z důvodu extrakardiální vady

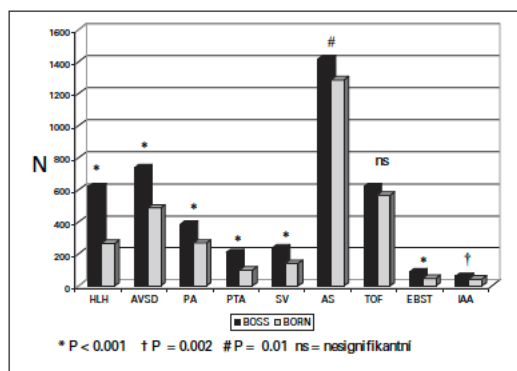


Graf 3 Osud prenatálně detekovaných vrozeých srdečních vad (VSV) 1986-2012 (n = 2 998)

syndromu hypoplastického levého srdce, atrioventrikulárního defektu, společného arteriálního trunकुs, atrézie plicnice, společné komory, aortální stenózy, Ebsteinově anomálie a interrupci aortálního oblouku.

Diskuze

Česká republika patří mezi první země, kde byl zahájen celoplošný prenatální screening srdečních vad. Centralizace péče, velmi dobrá kvalita primárního screeningu prováděného gynekology a spolupráce s dětskými kardiology specializujícími se na prenatální echokardiografii vede k vysoké záchytnosti VSV, která patří mezi nejvyšší v rámci celé Evropy (15-18). Spektrum fetálně detekovaných vad se významně liší od známé postnatální prevalence (2,6). Při porovnání s postnatální frekvencí jednotlivých vad jsou fetálně častěji zachyceny komplexní vady (syndrom hypoplázie levého srdce, atrézie plicnice, společná komora) a VSV, které jsou spojeny se závažnými extrakardiálními vadami včetně chromozomálních. Typicky se jedná o atrioventrikulární defekt nebo dvojvýtokovou pravou komoru (6). V posledních letech zaznamenáváme zvýšený počet VSV



Graf 4 Změna v postnatálním spektru VSV mezi očekávaným (BOSS) počtem vad a kalkulovaným počtem narozených dětí (BORN) po odečtení ukončených těhotenství

HLH – syndrom hypoplázie levého srdce, AVSD – defekt atrioventrikulárního septa, PA – atrézie plicnice, PTA – společný arteriální trunकुs, SV – společná komora, AS – aortální stenóza, TOF – Fallotova tetralogie, EBST – Ebsteinova anomálie trikuspidální chlopně, IAA – interrupce aortálního oblouku.

detekovaných v 1. trimestru (19-21). Známým faktem je, že prevalence VSV v nízkém gestačním stádiu je vyšší a přítomnost srdeční vady je častou příčinou intrauterinního úmrtí (26-27). Rovněž jsou zachyceny vady, se kterými se postnatálně téměř nesetkáváme (22). VSV jsou častou příčinou intrauterinního selhání a úmrtí v nízkém gestačním věku (23). V našem souboru byla intrauterinní úmrtnost 3 % respektive 6,9 % z pokračujících těhotenství. Nejčastěji se jednalo u dysplázií trikuspidální chlopně nebo komplexní vady s často přítomnou regurgitací některé atrioventrikulární chlopně. Úspěšnou detekcí vad v 1. trimestru se však může falešně zvyšovat záchytnost

vad u plodů, se kterými bychom se již při druhotrimestrálním vyšetření nesetkali. Na druhé straně se v 1. trimestru odhalí řada plodů s chromozomálními anomáliemi, na jejichž podkladě se gravidita ukončí (33). U nich předpokládáme zvýšený výskyt VSV, které nejsou většinou detekovány buď pro nemožnost nálezu vady v nízkém gestačním týdnu, nebo pro absenci důvodu po VSV dále pátrat (34). Ve 13.-14. týdnu je možné vcelku spolehlivě diagnostikovat některé typy vad, jako např. syndrom hypoplastického levého srdce, společnou komoru nebo atrioventrikulární defekt (24). Diagnóza VSV v 1. trimestru je následně indikací ke karyotypizaci a napomáhá efektivnějšímu záchytu chromozomálních aberací. U řady vad ale přesná diagnóza stanovit v 1. trimestru nelze a je nutná kontrola v další fázi těhotenství. Tím se ale zároveň dostáváme pod tlak ze strany rodičů, kteří naléhají na určení jasné diagnózy a prognózy, aby mohli co nejdříve rozhodnout o dalším osudu svého těhotenství (25). Tlak na brzké stanovení diagnózy může vést ke snaze nutit se do závěrů za každou cenu s rizikem závažných chyb.

Jeden z hlavních cílů prenatalní kardiologie spočívá v detekci kritické vady plodu s následným porodem dítěte s VSV ve specializovaném centru („transport in utero“). To umožní okamžitou péči o nemocného novorozence, který by byl při postnatální diagnóze a zdlouhavém transportu v bezprostředním ohrožení života a vede zároveň ke zlepšení celkové prognózy (28-29). Druhou možností při prenatalní diagnóze VSV je právo rodičů rozhodnout se pro ukončení gravidity z důvodu závažné diagnózy se špatnou nebo nejistou prognózou dítěte. V našem souboru se pro ukončení gravidity rozhodlo 54 % rodičů. Ukončování gravidity v ČR z důvodu srdeční vady plodu patří mezi nejvyšší v Evropě (30-32) a v procentech zůstává i v posledních letech stejně vysoké. Záchytnost VSV stále vzrůstá a diagnostikují se častěji i vady lehké, které nevyžadují žádné složité intervence po narození. Ukončování těhotenství z důvodu diagnózy závažné VSV vede ke změně spektra dětí se srdečními vadami, kde se významně snižují postnatální diagnózy závažnějších a/nebo komplexních vad (syndrom hypoplázie levého srdce, atrézie plicnice, společný arteriální trunkus a další). K ukončení gravidity při srdeční vadě nepochybně přispívá časté extrakardiální postižení plodu (v naší studii mělo 49 % ukončených těhotenství s VSV další vrozenou vývojovou vadu včetně chromozomální).

Závěr

Prenatální echokardiografie prováděná v celé České republice umožňuje v posledních letech detekci až 47 % všech a více než 80 % kritických srdečních vad. Vysoký počet ukončených těhotenství je nejspíše důsledkem závažnosti srdečních vad a četných přidružených vývojových abnormalit. Četnost ukončení gravidity má vliv na postnatální spektrum srdečních vad, kdy ubývá závažných nebo komplexních srdečních onemocnění (syndromu hypoplázie levého srdce a dalších).

Poděkování

Registr prenatalně detekovaných srdečních vad by nemohl vzniknout bez skvělé spolupráce řady kolegyně a kolegů – dětských kardiologů, gynekologů, genetiků a radiologů podílejících se na echokardiografických vyšetřeních v celé republice.

Registr prenatalně detekovaných VSV se opírá též o data každoročně zasílaná ze spolupracujících regionálních center fetální kardiologie v Ústí nad Labem (Jaroslav Homola) a FN v Ostravě (Jan Pavlíček, Tomáš Gruszka) a Centra lékařské genetiky v Českých Budějovicích (Karel a David Čutkové).

Literatura

1. Simpson LL. Screening for congenital heart disease. *Obstet Gynecol Clin North Am.* 2004;31:51-59
2. Šamánek M, Slavík Z, Zbořilová B, Hroboňová V, Voříšková M, Škovránek J. Prevalence, treatment, and outcome of heart disease in live-born children: a prospective analysis of 91,823 live-born children. *Pediatr Cardiol.* 1989;10:205-211
3. Cuneo BF, Curran LF, Davis N, Elrad H. Trends in prenatal diagnosis of critical cardiac defects in an integrated obstetric and pediatric cardiac imaging center. *J Perinatol.* 2004;24:674-678
4. Bonnet D, Coltri A, Butera G, et al. Detection of transposition of the great arteries in fetuses reduces neonatal morbidity and mortality. *Circulation.* 1999;99:916-918
5. Tworetzky W, McElhinney DB, Reddy VM, Brook MM, Hanley FL, Silverman NH. Improved surgical outcome after fetal diagnosis of hypoplastic left heart syndrome. *Circulation.* 2001;103:1269-1273
6. Marek J, Tomek V, Škovránek J, Povýšilová V, Šamánek M. Prenatal ultrasound screening of congenital heart disease in an unselected population: a 21-year experience. *Heart.* 2011 Jan;97(2):124-30
7. Carvalho JS, Allan LD, Chaoui R, Copel JA, DeVore GR, Hecher K, Lee W, Munoz H, Paladini D, Tutschek B, Yagel S. ISUOG Practice Guidelines (updated): sonographic screening examination of the fetal heart International Society of Ultrasound in Obstetrics and Gynecology. *Ultrasound Obstet Gynecol.* 2013 Mar;41(3):348-59
8. AIUM practice guideline for the performance of fetal echocardiography. *J Ultrasound Med.* 2011 Jan;30(1):127-31
9. Allan L, Dangel J, Fesslova V, Marek J, Mellander M, Oberhänsli I, Renate Oberhoffer R, Gurleen Sharland G, Simpson J, Sonesson SE. Recommendation of the AEPC. Recommendations for the practice of fetal cardiology in Europe. *Cardiol Young.* 2004;14:109-114
10. Novák P. Fyzikální principy a vyšetřovací technika. In: Calda P, Břešťák M, Fischerová D. *Ultrazvuková diagnostika v těhotenství a gynekologii.* 2. rozš. vydání. Aprofema, Praha, 2010, 35-52
11. Tomek V. Základní postupy vyšetření srdce. In: Calda P, Břešťák M, Fischerová D. *Ultrazvuková diagnostika v těhotenství a gynekologii.* 2. rozš. vydání. Aprofema, Praha, 2010, 273-277
12. Herskind AM, Almind Pedersen D, Christensen K. Increased prevalence of congenital heart defects in monozygotic and dizygotic twins. *Circulation.* 2013;128(11):1182-8
13. Tararbit K, Houyel L, Bonnet D, De Vigan C, Lelong N, Goffinet F, Khoshnood B. Risk of congenital heart defects associated with assisted reproductive technologies: a population-based evaluation. *European Heart Journal.* 2011;32:500-508

14. Šamánek M, Voříšková M. Congenital heart disease among 815,569 children born between 1980 and 1990 and their 15-year survival: a prospective Bohemia survival study. *Pediatr Cardiol.* 1999;20(6):411-417
15. Paladini D, Russo M, Teodoro A, et al. Prenatal diagnosis of congenital heart disease in the Naples area during the years 1994-1999-the experience of a joint fetal-pediatric cardiology unit. *Prenat Diagn.* 2002;22:545-52
16. Levy DJ, Pretorius DH, Rothman A, Gonzales M, Rao C, Nunes ME, Bendelstein J, Mehalek K, Thomas A, Nehlsen C, Ehr J, Burchette RJ, Sklansky MS. Improved Prenatal Detection of Congenital Heart Disease in an Integrated Health Care System. *Pediatric Cardiology.* 2013;34:670-9
17. Khoshnood B, De Vigan C, Vodovar V, Goujard J, Lhomme A, Bonnet D, Goffinet F. Trends in prenatal diagnosis, pregnancy termination, and perinatal mortality of newborns with congenital heart disease in France, 1983-2000: a population-based evaluation. *Pediatrics.* 2005;115:95-101
18. Garne E, Stoll C, Clementi M, Euroscan Group. Evaluation of prenatal diagnosis of congenital heart diseases by ultrasound: experience from 20 European registries. *Ultrasound Obstet Gynecol.* 2001;17(5):386-91
19. Timmerman E, Clur SA, Pajkt E, Bilardo CM. First-trimester measurement of the ductus venosus pulsatility index and the prediction of congenital heart defects. *Ultrasound Obstet Gynecol.* 2010;36:668-675
20. Huggon IC, Ghi T, Cook AC, Zosmer N, Allan LD, Nicolaides KH. Fetal cardiac abnormalities identified prior to 14 weeks' gestation. *Ultrasound Obstet Gynecol.* 2002;20:22-29
21. Carvalho JS. Screening for heart defects in the first trimester of pregnancy: food for thought. *Ultrasound Obstet Gynecol.* 2010;36:658-660
22. Marek J, Škovránek J, Povýšilová V. Congenital absence of aortic and pulmonary valve in a fetus with severe heart failure. *Heart.* 1996;75:98-100
23. Montana E, Khoury MJ, Cragan JD, et al. Trends and outcomes after prenatal diagnosis of congenital cardiac malformations by fetal echocardiography in well defined birth population, Atlanta, Georgia. *J Am Coll Cardiol.* 1996;28:1805-9
24. Bronshtein M, Zimmer EZ, Milo S, Ho SY, Lorber A, Gerlis LM. Fetal cardiac abnormalities detected by transvaginal sonography at 12-16 weeks' gestation. *Obstet Gynecol.* 1991;78:374-378
25. Larsson AK, Svalenius EC, Marsal K, Ekelin M, Nyberg P, Dykes AK. Parents' worried state of mind when fetal ultrasound shows an unexpected finding: a comparative study. *J Ultrasound Med.* 2009;28:1663-1670
26. Hoffman JIE. Incidence of congenital heart disease: II. Prenatal incidence. *Pediatr Cardiol.* 1995;16:155-65
27. Gerlis LM. Cardiac malformations in spontaneous abortions. *Int J Cardiol.* 1985;7:29-43
28. Galindo A, Nieto O, Villagrà S, Grañeras A, Herraiz I, Mendoza A. Hypoplastic left heart syndrome diagnosed in fetal life: associated findings, pregnancy outcome and results of palliative surgery. *Ultrasound Obstet Gynecol.* 2009;33:560-566
29. Yates RS. The influence of prenatal diagnosis on postnatal outcome in patients with structural congenital heart disease. *Prenat Diagn.* 2004;24:1143-9
30. Paladini D, Russo M, Teodoro A, et al. Prenatal diagnosis of congenital heart disease in the Naples area during the years 1994-1999-the experience of a joint fetal-pediatric cardiology unit. *Prenat Diagn.* 2002;22:545-52
31. Bull C. Current and potential impact of fetal diagnosis on prevalence and spectrum of serious congenital heart disease at term in the UK. *British Paediatric Cardiac Association. Lancet.* 1999;354:1242-7
32. Tararbit K, Bui TT, Lelong N, Thieulin AC, Goffinet F, Khoshnood B. Clinical and socioeconomic predictors of pregnancy termination for fetuses with congenital heart defects: a population-based evaluation. *Prenat Diagn.* 2013;33(2):179-86
33. Engelbrechtsen L, Brøndum-Nielsen K, Ekelund C, Tabor A, Skibsted L, Danish Fetal Medicine Study Group. Detection of triploidy at 11-14 weeks' gestation: a cohort study of 198 000 pregnant women. *Ultrasound Obstet Gynecol.* 2013;42(5):530-5
34. Wright D, Spencer K, Kagan K, Tørring N, Petersen OB, Christou A, Kallikas J, Nicolaides KH. First-trimester combined screening for trisomy 21 at 7-14 weeks' gestation. *Ultrasound Obstet Gynecol.* 2010;36:404-411

Podpořeno MZ ČR – RVO, FN v Motole 00064203.

2.0.3 ANNEX 4

Tomek V, Gilik J, **Jicinska H**, Pavlicek J, Navratil J, Cutka D, Vlasin P, Lacinova M, Marek J, Skovránek J

Prenatal diagnosis of congenital heart defects and its consequences

Cesko-slovenska Pediatrie 2018;73(5): 284-290

Main points/highlights of the publication:

In the study the detection rate of CHDs in the Czech Republic from 2006 to 2015 was assessed. In that period the detection rate of CHDs increased significantly and was very high in the CR: from 2006 to 2015, the prenatal detection rate was 39-49% of all CHDs and 80-90% of critical CHDs. The effectiveness of the prenatal detection rate of CHDs was assessed by the Bohemian Survival Study (BOSS study) published by professor Šamánek. The detection rates of individual CHDs and the very high detection rates of some CHDs (100% detection rate of single ventricle, atrioventricular septal defect and hypoplastic left heart syndrome) were presented. The very high termination rate of pregnancy in the Czech Republic (54%) and the impact of this termination rate was presented. The high prenatal termination rate of some CHDs changed the spectrum of CHDs postnatally.

The candidate contributed to the manuscript and with cases to this study.

Prenatální detekce srdečních vad a její důsledky

Tomek V.¹, Gilík J.¹, Jičínská H.^{2,5}, Pavlíček J.³, Navrátil J.², Čutka D.⁴, Vlašín P.⁵, Lacinová M.⁴, Marek J.¹, Škovránek J.¹

¹Dětské kardiocentrum FN Motol a 2. LF UK, Praha

²Dětská kardiologie Pediatrické kliniky FN Brno a LF Masarykovy univerzity, Brno

³Oddělení dětské a prenatální kardiologie, Klinika dětského lékařství FN Ostrava

⁴Centrum lékařské genetiky s.r.o., České Budějovice

⁵Centrum prenatální diagnostiky, Brno

Čes-slov Pediat 2018; 73 (5): 284–290

SOUHRN

Cíl studie: Posoudit úspěšnost prenatální diagnostiky vrozených srdečních vad a zjistit, jaký je důsledek ukončení těhotenství na změnu postnatálního spektra srdečních vad.

Metody: Počet prenatálně detekovaných srdečních vad jsme porovnávali se známou incidencí srdečních vad u dětí (studie M. Šamánek – BOSS). Obdobným způsobem jsme posuzovali úspěšnost záchytu jednotlivých srdečních vad v letech 2006–2015 a určili významnost změn v jejich počtu při ukončování gravidity.

Výsledky: Záchytnost srdečních vad se v posledních 5 letech v ČR pohybuje mezi 39–49 %. Z celkového počtu zjištěných 2358 srdečních vad se pro ukončení gravidity rozhodlo 1093 (46,3 %) těhotných, u nichž extrakardiální vadu mělo 526 (48,1 %) plodů. Fetálně jsme zachytili všechny plody se společnou komorou, atrioventrikulárním defektem a hypoplazií levého srdce. Celoplošně se zvyšuje i záchytnost kritických vad – transpozicí velkých tepen (48 %) a koarktací (35 %). Vzhledem k vysokému počtu ukončených těhotenství se významně snižuje počet většiny VSV postnatálně: kompletního atrioventrikulárního defektu, syndromu hypoplazie levého srdce, dvojitkové pravé komory, Fallotovy tetralogie, aortální stenózy, atrézie plicnice, arteriálního trunku, společné komory a Ebsteinovy anomálie.

Závěr: Prenatální detekce srdečních vad v České republice je díky vybudovanému propojení screeningu a specializovaného echokardiografického vyšetření vysoká. Ukončování těhotenství z důvodu diagnózy srdečního postižení vede ke změně spektra většiny srdečních vad u dětí. Signifikantně se snižují postnatální diagnózy závažnějších a/nebo komplexních vad s častými extrakardiálními defekty.

KLÍČOVÁ SLOVA

vrozená srdeční vada, prenatální diagnóza, echokardiografie, plod

SUMMARY

Prenatal detection of congenital heart defects and its consequences

Objective: The aim of the study was to assess an effectiveness of prenatal detection rate of congenital heart defects (CHD) and to analyse the impact of pregnancy termination on postnatal incidence of CHD.

Methods: Prenatal diagnosis rates for CHD were compared with known incidence of CHD in children (based on the study by M. Šamánek – BOSS).

Results: Prenatal detection rate of CHD varied between 39–49% in 2011–2015. Termination rate was 46.3% (1093 from 2358 fetuses) with high proportion of extracardiac lesion (526 fetuses, 48.1%). The highest detection rates (reaching 100%) were in single ventricle, atrioventricular defect and hypoplastic left heart syndrome. A detection rates of other critical heart lesions are increasing: transposition of great arteries (48%) and coarctation of the aorta (35%). Owing to high pregnancy terminations the postnatal rate of most CHD is declining: atrioventricular defect, hypoplastic left heart syndrome, pulmonary atresia, common arterial truncus and single ventricle.

Conclusion: The nationwide prenatal screening programme enabled detection of almost half fetuses with CHD. High pregnancy termination rate has an important impact on changing spectrum of postnatal incidence of heart lesions with significant lowering of severe and/or complex heart defects often combined with extra-cardiac defects.

KEY WORDS

congenital heart defect, prenatal diagnosis, echocardiography, fetus

ÚVOD

Hlavním smyslem prenatální detekce vrozených srdečních vad (VSV) je odhalení kritických vad ohrožujících zdraví nebo i život novorozenců a diagnostika komplexních onemocnění srdce, která mohou významně ovlivnit dlouhodobou morbiditu a mortalitu pacientů. Intrauterinní vyšetření tak díky včasné a přesné diagnóze zlepšuje přežívání dětí s VSV. Na druhé straně je ale příčinou jejich výrazné redukce díky častému ukončování těhotenství, což mění spektrum narozených dětí se srdečními vadami.

Organizace fetální kardiologie

Záchyt a diagnostika srdečních vad spočívá v návaznosti screeningového a specializovaného echokardiografického vyšetření. **Screeningové vyšetření srdce** je součástí prenatálního ultrazvukového vyšetření ve druhém a limitovaně i v prvním trimestru. Jeho cílem je odlišení fyziologického nálezu od patologie určením základní srdeční anatomie a funkce. Screeningové vyšetření je prováděno především gynekology, ale podílí se na něm i genetici, dětská kardiologové nebo také neonatologové. Pro posouzení základní srdeční anatomie je důležité zejména zobrazení symetrických srdečních oddílů (4-duťtinová projekce) a správné odstupky velkých tepen. Není-li srdeční anatomie normální, má být těhotná odeslána na podrobné vyšetření ke specialistovi v prenatální kardiologii. Logickou indikací specializovaného vyšetření tak je nejen přímo nálezu srdeční vady, ale i podezření na ni, nebo jen nejistota ohledně správné anatomie a funkce srdce.

Screeningový program, který je založený na multidisciplinární spolupráci, nyní existuje ve většině rozvinutých zemí. Z doporučení ISUOG (The International Society of Ultrasound in Obstetrics and Gynecology) pro ultrazvukové vyšetření plodu vyplývá, že k efektivnosti takového systému výrazně napomáhá nízký práh při doporučení k echokardiografickému vyšetření u specialisty na prenatální kardiologii [1]. Obdobný doporučující přístup zastává i AIUM (The American Institute of Ultrasound in Medicine) a AEP (Association for European Paediatric Cardiology) [2].

Etiologii vrozených srdečních vad přesně neznáme. Protože ani identifikace rizikových faktorů nevykloučí možnost přítomné srdeční vady u plodu, je screeningové vyšetření všech těhotných v prenatální diagnostice klíčové. Nález nebo podezření na vadu při screeningovém vyšetření je nejsilnějším „rizikovým faktorem“ přítomnosti srdeční vady. Existuje ale celá řada vlivů,

kteří riziko nálezu VSV u plodu dále zvyšují [3]. Rizikové faktory zahrnují vlivy ze strany matky, rodiny a plodu. Tato rizika, spadající do kategorie I a IIa (level of evidence) a zvyšující riziko VSV o $\geq 3\%$, jsou logicky indikacemi ke specializovanému prenatálnímu kardiologickému vyšetření tak, jak vycházejí z doporučení ISUOG, AIUM a AEP.

A. Riziko ze strany matky a rodiny

metabolické vady matky (diabetes mellitus, fenylketonurie), užívání léků v graviditě (např. antiepileptika, antidepresiva, nesteroidní kyselina retinová), *in vitro* fertilizace, vícečetné těhotenství, prodělané infekce v graviditě (dětské virové choroby, cytomegalovirus, parvovirus, toxoplazmóza, event. další), autoimunní onemocnění matky s přítomností autoprotilátek třídy SSA/antiRo a SSB/antiLa, přítomnost vrozených srdečních vad nebo kardiomyopatie u matky, otce, sourozenců a prarodičů, chromosomální aberace, syndromy a jiná genetická postižení, jako např. myopatie, Marfanův syndrom.

B. Rizikové faktory ze strany plodu

abnormální nález při screeningu srdce (přítomná srdeční vada, podezření na srdeční vadu nebo nejasný nález na srdci), srdeční arytmie nebo abnormální srdeční frekvence ($<100/\text{min}$, $>180/\text{min}$), extrakardiální vrozená vývojová vada, chromosomální vada, hydroops, zvýšená antiflogistika, teratogeny v graviditě (lithium, nuchální translucence, absence ductus venosus, vícečetné těhotenství, nevysvětlitelný polyhydramnion, trikuspidální regurgitace v 1. trimestru, syndrom fetu-fetální transfuze, absence nosní kůstky).

Cílem specializovaného vyšetření, prováděného erudovaným dětským kardiologem, je přesné určení srdeční vady. Její klíčovou součástí je adekvátní informování rodičů o povaze, léčebných možnostech a prognóze onemocnění s návrhem a zajištěním správné léčby včetně organizace porodu a následné postnatální léčby.

Specializované vyšetření dětským kardiologem a „counseling“

Za absolutní indikací ke specializovanému echokardiografickému vyšetření dětským kardiologem je nález srdeční vady nebo i podezření na ni. Falešná pozitivita srdeční vady rozhodně není při screeningovém vyšetření chybou. Je vždy lepší odeslat těhotnou ke specializovanému vyšetření „zbytečně“ než vadu přehlédnout. Ještě větší hrubou chybou je ale vytvářet mylné nebo dokonce

neexistující diagnózy srdečních vad a z nich plynoucí závěry, na jejichž chybném základě těhotné ženy mohou unáhleně volit možnost ukončení těhotenství.

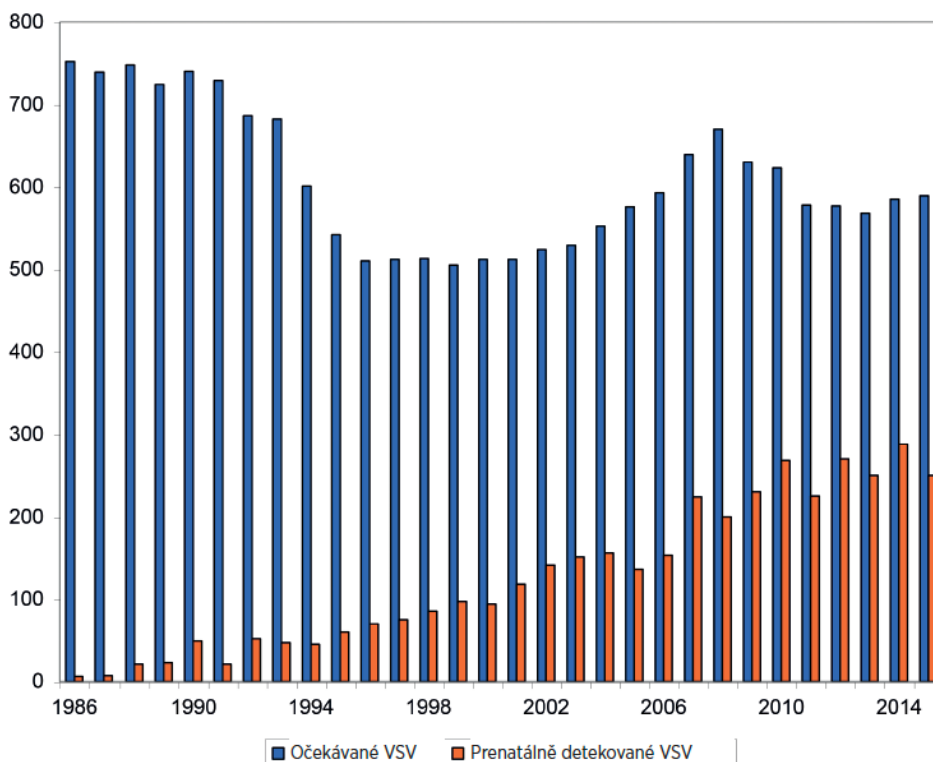
Správná diagnóza srdeční vady je pouze nezbytným předpokladem pro stanovení prognózy a následnou konzultaci s rodiči o dalším osudu těhotenství. Proto má být prováděna dětským kardiologem s adekvátními zkušenostmi v prenatalní diagnostice a léčbě dětí se srdečními vadami. Rozhodnutí o dalším osudu plodu včetně eventuelní úvahy o ukončení gravidity má být plně v kompetenci rodičů, kteří jsou zodpovědní za své dosud nenarozené dítě. Finální diagnostika a s ní související informování o možnostech léčby a prognóze srdeční vady má tedy zcela zásadní význam pro další osud těhotenství.

Diagnóza srdeční vady plodu je pro rodiče (zejména matku) velmi traumatizující a stresující záležitost. Je proto nutné při pohovoru s rodiči jednat citlivě a být připraven na to, že takový „*counseling*“ vyžaduje dostatek času, mnohdy opakované návštěvy a konzultace s dalšími lékaři a jinými zdravotnickými specialisty (kontaktní sestra, psycholog).

VÝSLEDKY PRENATÁLNÍ DIAGNOSTIKY SRDEČNÍCH VAD

Metodika posouzení úspěšnosti detekce srdečních vad a jejich vlivu na postnatální incidenci VSV

Pro posouzení úspěšnosti prenatalního zachytu VSV používáme srovnání se známou prospektivní studií o postnatální incidenci vad v ČR – BOSS (BOHemia Survival Study) prof. Šamánka [4]. V rámci této studie bylo vyšetřeno všech 815 569 živě narozených dětí v Čechách v období 1980–1990 a stanovena prevalence jednotlivých srdečních vad. Studie probíhala v době, kdy prenatalní selekce ještě neměla podstatnější vliv na spektrum dětí se srdeční vadou. Prevalence všech srdečních vad byla stanovena 6,16 VSV na 1000 živě narozených dětí. Za kritické VSV (celkem 35 % všech srdečních vad, 2,36/1000 živě narozených dětí) považujeme ty, které ohrožují dítě po narození významnou hypoxémií, těžkým srdečním selháním nebo kombinací obou příznaků.



Graf 1. Vývoj prenatalní detekce vrozených srdečních vad (VSV) v letech 1986–2015.

Tab. 1. Úspěšnost prenatalní detekce nejčastějších srdečních vad 2006–2015.

Typ VSV	Prenatálně detekované (n)	Extrakardiální vady (n)	UUT (n)	UUT (%)	Předpokládaný počet VSV	Úspěšnost detekce (%)
VSD	302	105	100	33,1	2867	10,5
AVSD	288	172	170	59,0	280	102,9
HLH	234	24	215	91,9	235	99,6
TGA	178	14	27	15,1	369	48,2
DORV	164	61	84	51,2	97	59,1
TOF	153	42	38	24,8	235	65,1
AS	135	4	61	45,2	537	25,1
COA	131	10	22	16,8	370	35,4
PA	115	41	89	77,4	145	79,3
SV	103	12	84	81,6	90	114,4
PTA	67	31	51	76,1	78	85,9
PS	75	4	19	25,3	403	18,6
EBST	25	3	14	56,0	34	73,5

Srdeční vady jsou řazeny podle frekvence jejich prenatalního výskytu. Předpokládaný počet VSV je vypočten podle jejich postnatální incidence (studie M. Šamánka - BOSS).

UUT - umělé ukončení těhotenství, VSD - defekt komorového septa, AVSD - atrioventrikulární defekt, HLH - syndrom hypoplazie levého srdce, TGA - transpozice velkých arterií, DORV - dvojitá pravá komora, TOF - Fallotova tetralogie, AS - aortální stenóza, COA - koarktace aorty, PA - atrézie plicnice, SV - společná komora, PTA - arteriální trunкус, PS - stenóza plicnice, EBST - Ebsteinova anomálie

Statistická analýza

Pro analýzu jsme používali SigmaStat 3.5, Systat Software Inc. (San Jose, Kalifornie, USA). Soubory byly testovány na normalitu rozložení. Pro posouzení rozdílů v prenatalním a postnatálním spektru vad byl použit párový t-test nebo Mannův-Whitneyho sum test. Za statisticky významné rozdíly byly považovány parametry s $p < 0,05$.

Celkové výsledky prenatalní detekce srdečních vad v České republice

V letech 1986–2015 se v ČR živě narodilo 3 280 604 dětí a intrauterinně byl dokumentován nález srdeční vady u celkem 3812 plodů v gestačním stádiu od 13. do 41. týdne (medián 20. týden). Pro srovnání prenatalního zachytu s postnatální prevalencí nebyly pro posouzení úspěšnosti detekce započítávány diagnózy, které je z povahy fetální cirkulace nemožné intrauterinně odhalit, a to tepenná dučej a sekundum defekt septa síní. Úspěšnost fetální detekce se průběžně zvyšovala a v posledních 5 letech se prenatalní zachyt všech VSV pohyboval v rozmezí 39–49 % (graf 1). Detekce kritických vad (postnatální prevalence 2,36/1000 živě narozených dětí) se pohybuje mezi 80–90 % z očekávaných srdečních vad v daném roce.

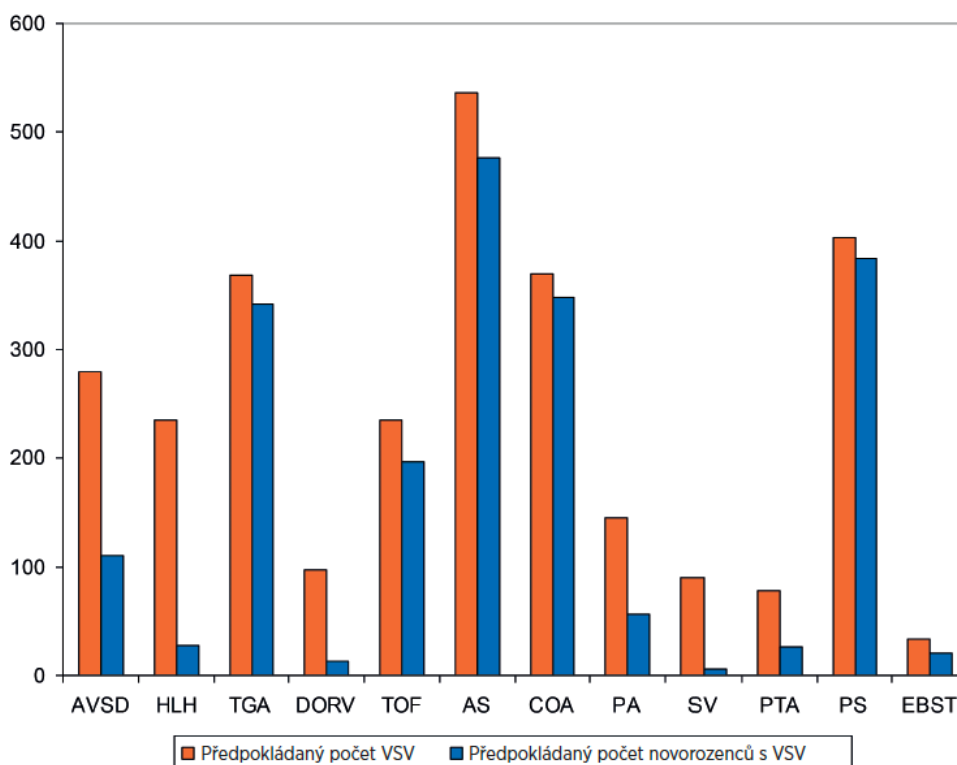
Úspěšnost prenatalní detekce VSV (2006–2015)

Porovnali jsme počty prenatalně detekovaných jednotlivých typů vad s předpokládaným počtem těchto vad u dětí narozených v daném roce v posledním analyzovaném 10letém období 2006–2015. Fetálně jsme

zachytili >100 % plodů se společnou komorou a atrioventrikulárním septálním defektem, 100 % plodů s hypoplazií levého srdce, 86 % arteriálních trunků, 73 % Ebsteinových anomálií, 65 % Fallotových tetralogií, 59 % plodů s dvojitou pravou komorou, 48 % plodů s transpozicí velkých arterií a 35 % s koarktací (tab. 1). V uvedeném období 2006–2015 byl prenatalně nejčastěji detekovanou vadou defekt komorového septa (302 plodů/12,8 %), atrioventrikulární defekt (288/12,2 %), syndrom hypoplazie levého srdce (234 plodů/8,9 %), transpozice velkých tepen (178/7,5 %), dvojitá pravá komora (164/7,0 %), Fallotova tetralogie (153/6,5 %) a aortální stenóza (163/5,7 %) (tab. 1). Nejméně často fetálně odhalenou vadou byl izolovaný totální anomální návrat plicních žil (3 případy).

Z celkového počtu 2358 srdečních vad byla u 576 (24,4 %) nalezena extrakardiální vada (genetická anomálie a/nebo orgánová vada). Pro ukončení gravidity se rozhodlo 1093 (46,3 %) těhotných, u 526 (48,1 %) z nich měl plod extrakardiální vadu. Z pokračujících těhotenství došlo k intrauterinnímu úmrtí u 67 plodů (2,8 %).

Vysoký počet umělé ukončených těhotenství (UUT) se srdeční vadou má významný dopad na jejich postnatální prevalenci (graf 2). V letech 2006–2015 tak došlo ke statisticky signifikantně významnému snížení výskytu většiny typů srdečních vad: kompletního atrioventrikulárního defektu, syndromu hypoplazie levého srdce, dvojitou pravé komory, Fallotovy tetralogie, aortální stenózy, atrézie plicnice, arteriálního trunku, společné komory a Ebsteinovy anomálie. Vliv ukončení těhotenství u defektu komorového septa, koarktace aorty, transpozice velkých tepen a stenózy plicnice neovlivnil významně



Graf 2. Změna v postnatálním spektru vrozených srdečních vad v letech 2006–2015. Statistická významnost (p) mezi předpokládaným počtem VSV a předpokládaným počtem novorozenců po odečtení ukončených těhotenství. AVSD (p <0,001) – atrioventrikulární defekt, HLH (p <0,001) – syndrom hypoplazie levého srdce, TGA (ns) – transpozice velkých arterií, DORV (p <0,001) – dvojitýtoková pravá komora, TOF (p = 0,02) – Fallotova tetralogie, AS (p <0,001) – aortální stenóza, COA (ns) – koarktace aorty, PA (p <0,001) – atrézie plicnice, SV (p <0,001) – společná komora, PTA (p <0,001) – arteriální trunкус, PS (ns) – stenóza plicnice, EBST (p <0,001) – Ebsteinova anomálie

jejich počet po narození. U těchto vad se jedná o dobře léčitelná onemocnění s obvykle dobrou prognózou.

Všechny případy ukončení těhotenství u defektu komorového septa byly z důvodů závažné extrakardiální vady a srdeční vada nebyla jejich primární příčinou. Nejčastěji byla těhotenství ukončována s vadou: syndrom hypoplastického levého srdce (UUT v 91,9 % případů), společná komora (81,6 %), atrézie plicnice (77,4 %), arteriální trunкус (76 %), atrioventrikulární defekt (59 %) a Ebsteinova anomálie (56 %).

DISKUSE

Jaký je důsledek prenatalní detekce srdečních vad?

Česká republika patří mezi první země, kde byl zahájen celoplošný prenatalní screening srdečních vad [5]. Centralizace péče, velmi dobrá kvalita primárního scree-

ningu prováděného gynekology a spolupráce s dětskými kardiology, specializujícími se na prenatalní echokardiografii, vede k vysoké záchytnosti VSV, která patří mezi nejvyšší v rámci celé Evropy [6, 7]. Proto vnímáme snahu části odborné gynekologické veřejnosti o absolutní autonomii při vyšetřování těhotných jako přímo ohrožující skvěle vybudovaný systém prenatalní detekce VSV. I když je pojmenována řada známých rizikových faktorů pro vznik srdeční vady, jejich absence možnost vzniku VSV u plodu vůbec nevylučuje. Např. různé metody *in vitro* fertilizace ale zvyšují, i přes prováděnou preimplantační diagnostiku, riziko srdeční vady 2–3násobně [8]. Při porovnání s postnatální frekvencí jednotlivých vad jsou fetálně častěji zachyceny komplexní vady (syndrom hypoplazie levého srdce, atrézie plicnice, společná komora) a VSV, které jsou spojeny se závažnými extrakardiálními vadami včetně chromosomálních, typicky se jedná o atrioventrikulární defekt nebo dvojitýtokovou pravou komoru [9].

Hlavním přínosem a smyslem prenatalní kardiologie je detekce kritické vady plodu s následným porodem dítěte s VSV ve specializovaném centru („transport *in utero*“). Tím je umožněna okamžitá péče o nemocného novorozence a odpadá prodlení vznikající oddálenou postnatální diagnostikou a transportem dítěte, které by mohlo být až v bezprostředním ohrožení života. Rada studií včasny přínos fetální diagnostiky na prognózu dítěte potvrdila [10, 11], zhruba obdobné množství studií takový prenatalní vliv popírá [12, 13] a argumentuje současnou dostupností kvalitní péče o novorozence. Druhou možností při prenatalní diagnostice VSV je právo rodičů rozhodnout se pro ukončení gravidity z důvodu závažné diagnózy se špatnou nebo nejistou prognózou dítěte. V našem souboru se pro ukončení gravidity rozhodlo 46 % rodičů.

Ukončování gravidity v ČR z důvodu srdeční vady plodu patří mezi nejvyšší v Evropě [14] a v procentech zůstává i v posledních letech stejně vysoké. Důvody pro vysoké ukončování gravidity jsou spekulativní: může jím být celkové naladění společnosti s nízkým prahem pro ukončení gravidity obecně, domnělá či skutečně chybějící zdravotnická a sociální podpora rodin s „postiženými“ dětmi, jejich nepřijetí společností a strach zejména matek z rozpadu manželského/partnerského vztahu. Často se i setkáváme s tím, že těhotné při screeningovém vyšetření dostávají nesprávné informace o povaze srdeční vady a je jim vyšetřujícími lékaři doporučeno ukončení těhotenství, buď na základě chybné diagnózy nebo nesprávné interpretaci závažnosti vady. A to i v případě léčitelné vady (kterých je naprostá většina) s dobrou prognózou. Nehledě na to, že oprávnění lékaře doporučit ukončení těhotenství je přinejmenším velmi diskutabilní. Prvotní informace o povaze srdeční vady je často klíčová pro rozhodování rodičů a dalším osudu těhotenství [15]. Je nesmírně složité následně vyvracet buď chybnou diagnózu VSV, nebo sice správně stanovenou diagnózu, ale prezentovanou s mylnou prognózou odvozenou četbou z mnoha let starých učebnic. Správná diagnóza srdeční vady je pouze nezbytným předpokladem pro stanovení prognózy a konzultaci s rodiči o dalším osudu těhotenství. Diagnóza srdeční vady musí být vždy potvrzena dětským kardiologem, který je plně erudován v prenatalní péči. Z našich zkušeností víme, že přesnost prenatalní diagnostiky je vysoká, ale určit přesný způsob postnatální léčby a prognózu je mnohdy obtížné [16].

Ukončování těhotenství z důvodu diagnózy závažné VSV vede ke změně spektra dětí se srdečními vadami, kde se významně snižují postnatální počty závažnějších a/nebo komplexních vad (syndrom hypoplazie levého srdce, atrézie plicnice, společný arteriální trunкус a další). K ukončení gravidity při srdeční vadě nepochybně přispívá časté extrakardiální postižení plodu [17]. V naší studii mělo 48 % ukončených těhotenství s VSV další vrozenou vývojovou vadu včetně chromosomální. Riziko genetického postižení je poměrně vysoké, u jednotlivých srdečních vad se liší. Některé vady riziko chromosomálních aberací nepředstavují (transpozice velkých arterií) a jiných je vysoké [18]: atrioventrikulární defekt (46–73 %), arteriální trunкус (19–78 %), dvojitá pravá komora (6–43 %).

V posledních letech zaznamenáváme zvýšený počet VSV detekovaných v prvním trimestru [19]. Známým faktem je, že prevalence VSV v nízkém gestačním stádiu je vyšší a přítomnost srdeční vady je i častou příči-

nou intrauterinního úmrtí [20]. Úspěšnou detekcí vad v 1. trimestru se však může falešně zvyšovat záchytnost vad u plodů, se kterými bychom se již při druhotrimestrálním vyšetření nesetkali. Typickým příkladem v našem souboru je „více než stoprocentní“ záchyt společné komory a atrioventrikulárního defektu v porovnání s jejich známou postnatální incidencí. Na druhé straně se v 1. trimestru odhalí řada plodů s chromosomálními anomáliemi, na jejichž podkladě se gravidita ukončí [21]. U nich předpokládáme zvýšený výskyt VSV, které nejsou vždy detekovány buď pro nemožnost nálezu vady v nízkém gestačním týdnu, nebo pro absenci důvodu po VSV dále pátrat [22]. Ve 13.–14. týdnu je možné vcelku spolehlivě diagnostikovat některé typy vad, jako např. syndrom hypoplastického levého srdce, společnou komoru nebo atrioventrikulární defekt [23].

U řady vad ale přesnou diagnózu stanovit v 1. trimestru nelze a je nutná kontrola v další fázi těhotenství. Tím se ale zároveň dostáváme pod tlak ze strany rodičů, kteří naléhají na určení jasné diagnózy a prognózy, aby mohli co nejdříve rozhodnout o dalším osudu svého těhotenství [24]. Tlak na brzké stanovení diagnózy může vést ke snaze nutit se do závěrů za každou cenu s rizikem závažných chyb.

Fetální intervence u srdečních vad – budoucnost nebo slepá cesta?

Úvahy o fetálních intervencích se týkají srdečních vad, jejichž přirozený vývoj vede k hypoplazii nebo ireverzibilní poruše srdeční komory, hypoplazii tepny a/nebo chlopně. Typicky se jedná o kritickou aortální stenózu, která může vést až k hypoplazii levého srdce (na principu „kde není adekvátní krevní průtok, není správný růst dané části srdce“) [25], nebo k dilataci dysfunkční levé komory s ischemickým postižením (endokardiální fibroelastóza). Smysl intrauterinní katetrizační balonkové valvuloplastiky aortální chlopně je v zachování růstu levé komory s možností biventrikulární postnatální korekce a zabrazení nezvratných změn levé komory vedoucích k její systolické a diastolické dysfunkci. Výsledky této fetální katetrizační intervence nejsou jednoznačné a jsou zatíženy vysokou mortalitou a morbiditou plodů i narozených dětí [26]. Zřejmě i proto, že kritická aortální stenóza s fibroelastózou dysfunkční a často malé komory je velmi závažné srdeční postižení, jejíž léčebné výsledky nejsou ani postnatálně povzbudivé. Fetální balonkové valvuloplastiky aortální stenózy se v ČR neprovádí. Od roku 2017 indikované případy referujeme na pracoviště v Linci, dosud se jedná o 4 těhotné. Intrauterinní katetrizační intervence vyžaduje další studie pro prokázání dlouhodobého efektu. Je ale příslibem toho, že existuje varianta ovlivnění nepříznivého vývoje srdeční vady již před narozením a není nutné čekat na porod dítěte s již hypoplastickou nebo dysfunkční dilatovanou komorou [27].

ZÁVĚR

Prenatální detekce srdečních vad v České republice je díky vybudovanému propojení screeningu a specializovaného echokardiografického vyšetření vysoká a patří mezi nejvyšší na světě vůbec. Ukončování těhotenství z důvodu

SYMPOZIUM: DĚTSKÁ KARDIOLOGIE

diagnózy srdečního postižení vede ke změně spektra většiny srdečních vad u dětí. Signifikantně se snižují postnatální diagnózy závažnějších a/nebo komplexních vad s častými extrakardiálními defekty.

Podpořeno MZ ČR – RVO, FN Motol 00064203.

LITERATURA

1. **Carvalho JS, Allan LD, Chaoui R, et al.** ISUOG Practice Guidelines (updated): sonographic screening examination of the fetal heart International Society of Ultrasound in Obstetrics and Gynecology, Ultrasound Obstet Gynecol 2013 Mar; 41 (3): 348–359.
2. **Donofrio MT, Moon-Grady AJ, Hornberger LK, et al.** Diagnosis and treatment of fetal cardiac disease: a scientific statement from the American Heart Association. Circulation 2014 May 27; 129 (21): 2183–2242.
3. **Pavlíček J, Klásková E, Procházka M, et al.** Congenital heart defects according to the types of the risk factors—a single center experience. J Matern-Fetal Neo M 2018, doi: 10.1080/14767058.2018.1468883.
4. **Šamánek M, Břešťák M, Škovránek J.** Prenatální kardiologie. Čs Pediatr 1986; 41:478–480.
5. **Šamánek M, Vofříšková M.** Congenital heart disease among 815,569 children born between 1980 and 1990 and their 15-year survival: A prospective Bohemia survival study. Pediatr Cardiol 1999; 20 (6): 411–417.
6. **Levy DJ, Pretorius DH, et al.** Improved prenatal detection of congenital heart disease in an Integrated Health Care System. Pediatr Cardiol 2013; 34: 670–679.
7. **Marek J, Tomek V, Škovránek J, et al.** Prenatal ultrasound screening of congenital heart disease in an unselected population: A 21-year experience. Heart 2011 Jan; 97 (2): 124–130.
8. **Tararbit K, Houyel L, Bonnet D, et al.** Risk of congenital heart defects associated with assisted reproductive technologies: a population-based evaluation. Eur Heart J 2011; 32, 500–508.
9. **Pavlíček J, Klásková E, Doležalková E, et al.** Vývoj prenatální diagnostiky vrozených srdečních vad, získ z jednotlivých ultrazvukových projekcí. Čes Gynek 2018; 83 (1): 17–23.
10. **Bonnet D, Coltri A, Butera G, et al.** Detection of transposition of the great arteries in fetuses reduces neonatal morbidity and mortality. Circulation 1999; 99: 916–918.
11. **Calderon J, Angeard N, Moutier S, et al.** Impact of prenatal diagnosis on neurocognitive outcomes in children with transposition of great arteries. J Pediatr 2012 Jul; 161 (1): 94–98.
12. **Landis BJ, Levey A, Levasseur SM, et al.** Prenatal diagnosis of congenital heart disease and birth outcomes. Pediatr Cardiol 2013 Mar; 34 (3): 597–605.
13. **Khoshnood B, Lelong N, Houyel L, et al.** Impact of prenatal diagnosis on survival of newborns with four congenital heart defects: a prospective, population-based cohort study in France (the EPICARD Study). BMJ Open 2017 Nov 8; 7 (11): e018285.
14. **Tararbit K, Bul TT, Lelong N, et al.** Clinical and socioeconomic predictors of pregnancy termination for fetuses with congenital heart defects: a population-based evaluation. Prenat Diagn 2013; 33 (2): 179–186.
15. **Carlsson T, Bergman G, Wadensten B, et al.** Experiences of informational needs and received information following a prenatal diagnosis of congenital heart defect. Prenat Diagn 2016 Jun; 36 (6): 515–522.
16. **Bensemlal M, Stirnemann J, Le Bidols J, et al.** Discordancies between pre-natal a post-natal diagnosis of congenital heart diseases and impact on care strategies. J Am Coll Cardiol 2016 Aug 30; 68 (9): 921–930.
17. **Ge Groote K, Vanhie E, Roets E, et al.** Outcome after prenatal and postnatal diagnosis of complex congenital heart defects and the influence of genetic anomalies. Prenat Diagn 2017 Oct; 37 (10): 983–991.
18. **Song MS, Hu A, Dyamenahalli U, et al.** Extracardiac lesions and chromosomal abnormalities associated with major fetal heart defects: comparison of intrauterine, postnatal and postmortem diagnoses. Ultrasound Obstet Gynecol 2009 May; 33 (5): 552–559.
19. **Carvalho JS.** Screening for heart defects in the first trimester of pregnancy: food for thought. Ultrasound Obstet Gynecol 2010; 36: 658–660.
20. **Gerlis LM.** Cardiac malformations in spontaneous abortions. Int J Cardiol 1985; 7: 29–43.
21. **Engelbrechtsen L, Brøndum-Nielsen K, Ekelund C, et al.** Detection of triploidy at 11–14 weeks' gestation: a cohort study of 198 000 pregnant women. Ultrasound Obstet Gynecol 2013; 42 (5): 530–535.
22. **Wright D, Spencer K, Kagan K, et al.** First-trimester combined screening for trisomy 21 at 7–14 weeks' gestation. Ultrasound Obstet Gynecol 2010; 36: 404–411.
23. **Jicinska H, Vlasin P, Jicinsky M, et al.** Does first trimester screening modify the natural history of congenital heart disease? Analysis of outcome of regional cardiac screening at 2 different time periods. Circulation 2017 Mar 14; 135 (11): 1045–1055.
24. **Larsson AK, Svalenlus EC, Marsal K, et al.** Parents' worried state of mind when fetal ultrasound shows an unexpected finding: a comparative study. J Ultrasound Med 2009; 28: 1663–1670.
25. **Sedmera D, Pexleder T, Rychterova V, et al.** Remodeling of chick embryonic ventricular myoarchitecture under experimentally changed loading conditions. Anat Rec 1999; 254: 238–252.
26. **Freud LR, McElhinney DB, Marshall AC, et al.** Fetal aortic valvuloplasty for evolving hypoplastic left heart syndrome: postnatal outcomes of the first 100 patients. Circulation 2014 Aug 19; 130 (8): 638–645.
27. **Gardiner HM, Kovacevic A, Tulzer G, et al.** Natural history of 107 cases of fetal aortic stenosis from a European multicenter retrospective study. Ultrasound Obstet Gynecol 2016 Sep; 48 (3): 373–381.

MUDr. Viktor Tomek, Ph.D.
Dětské kardiocentrum FN Motol
a 2. LF UK
V Úvalu 84
150 06 Praha 5
e-mail: viktor.tomek@fnmotol.cz

2.1 First-trimester screening

2.1.1 ANNEX 5

Jicinska H, Vlasin P, Jicinsky M, Grochova I, Tomek V, Volafova J, Skovranek J, Marek J. Does First-Trimester Screening Modify the Natural History of Congenital Heart Disease? Analysis of Outcome of Regional Cardiac Screening at 2 Different Time Periods. *Circulation* 2017;135:1045-1055
Impact factor in 2017 = 18.881

In this study we aimed to assess the impact of first-trimester screening on the spectrum of CHDs later in pregnancy, and on the outcome of fetuses and children with CHD. First-trimester screening was implemented to prenatal care by 2003 in the Czech Republic. The Spectrum of CHD, associated comorbidities and outcome of fetuses were compared between:

Group I (fetuses diagnosed with CHD in the first trimester from 2007 to 2013 and Group II (fetuses diagnosed with CHD in the second trimester from 2007 to 2013 Fetuses diagnosed with CHD only in the second trimester from 2007 to 2013 (Group IIb) were compared with Group III (fetuses with CHD diagnosed in the second trimester from 1996 to 2001 before first-trimester screening started).

The spectrum of CHDs diagnosed in the first and second trimesters in the same time period differed significantly, with a greater number of comorbidities, CHDs with univentricular outcome, intrauterine death and terminations of pregnancy in Group I compared with Group II. In Group III, significantly more cases with univentricular outcome, intrauterine demise, and early termination were identified compared with fetuses diagnosed with CHDs in the second trimester between 2007 and 2013.

Does First-Trimester Screening Modify the Natural History of Congenital Heart Disease?

Analysis of Outcome of Regional Cardiac Screening at 2 Different Time Periods

BACKGROUND: The study analyzed the impact of first-trimester screening on the spectrum of congenital heart defects (CHDs) later in pregnancy and on the outcome of fetuses and children born alive with a CHD.

METHODS: The spectrum of CHDs, associated comorbidities, and outcome of fetuses, either diagnosed with a CHD in the first trimester (Group I, 127 fetuses) or only in the second-trimester screening (Group II, 344 fetuses), were analyzed retrospectively between 2007 and 2013. Second-trimester fetuses diagnosed with a CHD between 2007 and 2013 were also compared with Group III (532 fetuses diagnosed with a CHD in the second trimester from 1996 to 2001, the period before first-trimester screening was introduced).

RESULTS: The spectrum of CHDs diagnosed in the first and second trimesters in the same time period differed significantly, with a greater number of comorbidities ($P < 0.0001$), CHDs with univentricular outcome ($P < 0.0001$), intrauterine deaths ($P = 0.01$), and terminations of pregnancy ($P < 0.0001$) in Group I compared with Group II. In Group III, significantly more cases of CHDs with univentricular outcome ($P < 0.0001$), intrauterine demise ($P = 0.036$), and early termination ($P < 0.0001$) were identified compared with fetuses diagnosed with CHDs in the second trimester between 2007 and 2013. The spectrum of CHDs seen in the second-trimester groups differed after first-trimester screening was implemented.

CONCLUSIONS: First-trimester screening had a significant impact on the spectrum of CHDs and the outcomes of pregnancies with CHDs diagnosed in the second trimester. Early detection of severe forms of CHDs and significant comorbidities resulted in an increased pregnancy termination rate in the first trimester.

Hana Jicinska, MD, PhD
Pavel Vlasin, MD
Michal Jicinsky, MD
Ilga Grochova, MD
Viktor Tomek, MD, PhD
Julia Volaufova, PhD
Jan Skovranek, MD, PhD
Jan Marek, MD, PhD

Downloaded from <http://ahajournals.org> by on April 18, 2020

Correspondence to: Hana Jicinska, MD, PhD, Destna 7, 644 00 Brno, Czech Republic. E-mail hjicinska@seznam.cz

Sources of Funding, see page 1054

Key Words: congenital heart defects ■ echocardiography ■ epidemiology ■ first-trimester screening ■ prenatal cardiology

© 2017 American Heart Association, Inc.

Clinical Perspective

What Is New?

- The implementation of first-trimester ultrasound screening programs has fundamentally changed prenatal care by moving the detection of major abnormalities, including cardiac abnormalities, to early stages of gestation.
- First-trimester screening changes the spectrum of congenital heart defects (CHDs) later in pregnancy.
- First-trimester screening has a major impact on the outcome of pregnancies with CHDs because early detection of more severe forms of cardiac abnormalities and a higher number of comorbidities lead to an increase in early termination of first-trimester pregnancies.

What Are the Clinical Implications?

- Moving prenatal cardiac ultrasound screening to early stages of pregnancy would, in some countries, reduce the numbers of children born with severe cardiac abnormalities and with associated comorbidities.
- To provide detailed echocardiographic evaluation and appropriate counseling, fetuses suspected of having CHDs in the first trimester should be referred to a fetal cardiology specialist.
- Because of diagnostic uncertainty in some first-trimester fetuses with CHDs and possible development of CHDs later in pregnancy, second-trimester screening should continue to be part of an integral screening program scheme in pregnancy.

First-trimester screening only recently started to play a pivotal role in the management of pregnancies. Through the combination of maternal age, serum biochemistry, ultrasound anomaly scan, and additional ultrasonographic markers, this screening can identify most fetal aneuploidies and structural abnormalities in the fetus.^{1,2} In addition, most congenital heart defects can be detected in the first trimester using a combination of increased nuchal translucency, reverse A wave after atrial contraction in ductus venosus, and tricuspid regurgitation on Doppler assessment. Increased nuchal translucency in euploid fetuses is associated with increased incidence of congenital heart defects (CHDs).³ This finding is supported by Chelemen,⁴ who claims that using increased nuchal translucency and reverse A wave in ductus venosus can detect CHD in the first trimester with a success rate of ≈40%. According to Huggon,⁵ an increased number of chromosomal abnormalities and CHDs appear in fetuses diagnosed with tricuspid regurgitation during first-trimester screening.

Samanek^{6,7} argues that the postnatal incidence of CHDs is roughly 1% (4.2–12.2 per 1000 live born in-

fants); however, the prenatal incidence is much higher. The highest incidence is in the earliest weeks of gestation, gradually decreasing (in later weeks) with increasing weeks of gestation.⁸ True prenatal incidence is unknown because of frequent intrauterine demise in the early postconceptional stages, particularly in fetuses with severe CHDs and associated comorbidities.

In this study, we aimed to compare the spectrum of CHDs, associated comorbidities, and the outcome of fetuses diagnosed with CHD in the first and second trimesters and to assess the impact of first-trimester screening on the spectrum of CHDs and the outcomes of fetuses with CHDs and associated comorbidity diagnosed in the second trimester before and after implementation of the first-trimester screening in the South Moravian region of the Czech Republic.

METHODS

In Southern Moravia, a region of the Czech Republic, 2 ultrasound screening scans are performed and financially supported by the government: 1 in the first trimester (from 11 to 13+6 weeks of gestation) and 1 in the second trimester (from 18 to 22 weeks of gestation) of pregnancy. The first-trimester ultrasound screening program was introduced in the Southern Moravian region in 2002 and formally implemented in most fetal medicine centers in the other regions of the Czech Republic by 2003.⁹ Both scans are performed by trained primary obstetricians (obstetrics and gynecology is recognized as a primary, first-line specialization in the Czech Republic) or by fetal medicine specialists if a primary obstetrician is unavailable to perform the scan. Specialist fetal echocardiography is performed by fetal cardiologists.

Study Group

From January 2007 to December 2013, 87901 fetuses (99% of all registered fetuses) from the Southern Moravian region underwent prenatal cardiac screening scans (92% in the first and second trimesters and 8% in the second trimester only). A total of 6145 fetuses (7.0% of all 87901 screened fetuses) were referred for specialist fetal echocardiography to the Fetal Medicine Center in Brno (the principal referring center for Southern Moravia; population 1.2 million) because of the presence of a risk factor for CHDs or heart anomaly suspected on the first- or second-trimester scan. Out of 6145 referred fetuses, 296 were referred for detailed fetal echocardiography in the first trimester. Of those 296 fetuses, 127 were subsequently confirmed with cardiac abnormalities. This group of fetuses is referred to as Group I (Figure 1). The remaining 5849 fetuses were referred for fetal echocardiography only in the second trimester. CHD was diagnosed in 344 of the 5849 fetuses referred for fetal echocardiography in the second trimester. These 344 fetuses constitute Group II. Group II was formed by 2 subgroups. Group IIa consisted of 112 fetuses screened in the first trimester but whose CHD was missed. They were later screened again and subsequently referred for fetal echocardiography and diagnosed with CHD in the second trimester. Group IIb consisted of 232 fetuses of women who declined or missed the first-trimester scan and were screened

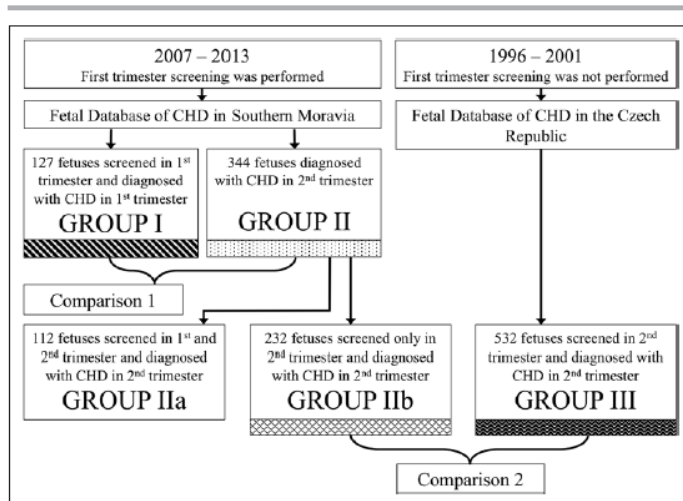


Figure 1. Study group.
CHD indicates congenital heart defect.

in the second trimester and subsequently referred for fetal echocardiography and diagnosed with CHD. Group III comprised 532 fetuses with CHD diagnosed prenatally in the Czech Republic in the second trimester from 1996 to 2001 before the first-trimester screening was introduced and after the implementation of outflow tracts evaluation to screening protocol (same screening protocols for Groups II and III). These data were obtained from the National Fetal Database of Congenital Heart Defects in the Czech Republic.¹⁰ Group III consisted of fetuses from the Southern Moravian region as well as the entire Czech Republic because a major region reorganization in 2001 changed the Southern Moravian population from 2.06 to 1.17 million inhabitants. Therefore, it was not possible to create a comparable study group of fetuses strictly from Southern Moravia from 1996 to 2001. The National Fetal Database of CHD in the Czech Republic was chosen as a data source to include more fetuses into the study group. This decision was fully justified because the Czech Republic population is rather homogenous both ethnically and socioeconomically.

The indications for specialist fetal echocardiography in the first trimester were abnormal fetal cardiac screening examination, presence of noncardiac or chromosomal abnormality, family history of CHD, increased nuchal translucency thickness, abnormal waveform in ductus venosus, and tricuspid regurgitation. In the second trimester, the indications were the same, plus maternal metabolic disease, maternal infection, maternal autoimmune disease, maternal exposure to teratogens, hydrops or arrhythmia in the fetus, conception through assisted reproductive technology, monozygotic twins, and abnormalities of umbilical cord, placental, or intraabdominal venous anatomy.^{11–13}

Study Protocol

These defined groups of fetuses were compared with regard to the spectrum of CHDs, associated comorbidities, type of circulation in CHD, and outcome of fetuses. Fetuses diagnosed with a CHD in the first trimester (Group I) were compared with fetuses diagnosed with a CHD in the second trimester in the

same period from 2007 to 2013 (Group II). Because Group II consists of two subgroups (Groups IIa and IIb), we compared the responses of the spectrum of CHDs, associated comorbidities, and outcome of fetuses between Groups IIa and IIb. Because our data, for almost all of the responses, do not indicate differences between Groups IIa and IIb, we used the combination of these 2 groups (which is the whole of Group II) for comparison with Group I.

To assess the impact of first-trimester screening on the second trimester, we compared fetuses screened and diagnosed with CHDs in the second trimester before 2001 (Group III), when first-trimester screening in our country was not routinely performed, with fetuses screened and diagnosed with CHDs only in the second trimester after 2007 (Group IIb), when first-trimester screening in our unit became available (Figure 1) because this group of fetuses is the only one that would be not confounded with other factors.

Classification of Cardiac Abnormalities

Complex cardiac abnormalities were classified according to the dominant heart lesion. For example, coarctation of the aorta with ventricular septal defect was classified as coarctation of the aorta. Atrioventricular septal defect, when it coexisted with double outlet right ventricle, was classified as atrioventricular septal defect. A single ventricle was classified as univentricular atrioventricular connection with double inlet or common atrioventricular valve. When an atrioventricular connection was absent, the diagnosis of tricuspid or mitral atresia was established. Hypoplastic left heart syndrome was defined as a heart with atrioventricular and ventriculoarterial concordance, small left ventricle, and reversed flow in the aortic arch. Cases with vascular rings (typically right aortic arch with aberrant left subclavian artery or double aortic arch) were included. Cases with isolated mirror imagery right aortic arch, left superior vena cava, and left aortic arch with aberrant right subclavian artery were not included.

CHDs with univentricular circulation, “functionally univentricular heart” unified different anatomic malformations, where

1 of the 2 ventricles was unable to sustain the pulmonary or systemic circulation because of diminutive size or deficiency in function.¹⁴ In these cases, the ventricles were not amenable to biventricular repair.

Assessment of Fetal Heart (First- and Second-Trimester Cardiac Scan) and Genetic Evaluation

In the Czech Republic, from 1996, fetal cardiac screening in the second trimester was performed by analyzing a 4-chamber view and outflow tracts relationship. From 2002, the first-trimester cardiac screening included a 4-chamber view as well as both arterial outflow tract views.

Similar fetal echocardiography protocols were used in the second-trimester scan (both periods 1996–2001 and 2007–2013) and in the first-trimester scan (2007–2013): examination of the viscerotracheal situs, cardiac axis, 4-chamber view, systemic venous connections, pulmonary venous return, evaluation of both arterial outflow tracts, 3 vessels and trachea view, and sagittal views of the aortic and ductal arches. Pulmonary veins were not consistently identified in every first-trimester scan.

The ultrasound machines used in the earlier and later eras differed in quality. In both periods, detailed fetal 2-dimensional, M-mode, color Doppler, and spectral Doppler echocardiograms were performed for detailed fetal cardiac assessment. In the earlier years, electronic phased array (convex and linear) probes operating on 3–7 MHz were used. In later years, multifrequency probes and matrix 2-dimensional/3-dimensional probes (4–8 MHz) were often used to assess cardiac structures in detail. Three-dimensional imaging (including Spatio-Temporal Image Correlation) was not routinely used to establish definitive cardiac diagnosis. In contrast, a high-definition power Doppler imaging was used routinely in all cases after 2007.

In all second-trimester and in the majority of first-trimester fetuses, the ultrasound examination was performed by transabdominal approach. Transvaginal approach was used in 7 of 127 (5.5%) first-trimester fetuses because of suboptimal quality of the transabdominal echocardiogram.

The diagnoses were verified through serial ultrasound examinations, a second examiner, midtrimester scans, postnatal echocardiography, or postmortems. Genetic consultation and karyotype were performed prenatally in all 127 fetuses diagnosed with CHDs in the first trimester. Out of the 876 fetuses diagnosed with CHDs in the second trimester (344 in Group II and 532 in Group III), in 656 fetuses (227 of 344 fetuses in Group II and 429 of 532 fetuses in Group III), genetic consultation and karyotype were performed prenatally. In the remaining 220 fetuses (117 of 344 fetuses in Group II and 103 of 532 fetuses in Group III), genetic evaluation (ie, clinical examination, genetic consultation, and, in some indicated cases, genetic testing) was performed postnatally. Prenatal cytogenetic and molecular genetic analyzes were performed on fetal cells obtained by chorionic villus sampling or amniocentesis.

Significant developments have occurred in prenatal genetic testing. From 1996 to 2001, karyotypes were done by cytogenetic analysis. In fetuses with suspected DiGeorge syndrome, the karyotype was completed by fluorescent in situ hybridization. From 2007 to 2013, quantitative fluorescence-polymerase chain reaction was performed as a first-line examination to exclude the most frequent chromosomal aneuploidies: trisomy

13, 18, and 21 and X chromosome monosomy. In cases of normal quantitative fluorescence-polymerase chain reaction, the karyotype was done by cytogenetic analysis or comparative genomic hybridization array. In fetuses with suspected DiGeorge syndrome, the karyotype was completed by fluorescent in situ hybridization, multiplex ligation-dependent probe, or comparative genomic hybridization array, if not done previously. In selected cases with a family history of CHDs where all mentioned techniques showed a normal result, targeted next-generation sequencing was performed.

Ethical Considerations

This study was discussed with the Institutional Review Board, but specific ethical approval was not necessary because the evaluation of fetuses was part of the management of pregnancies with CHDs in fetuses. Data analysis was assessed retrospectively.

Statistical Analysis

In the statistical analysis, dichotomous and multicategory response variables (congenital heart defect abnormalities, comorbidities, and outcomes) were investigated. All dichotomous response variables were analyzed by applying linear logistic regression model with logit transformation of probability of the event of interest with respect to group indicators, with reference-level parametrization. All response variables that allow for multiple categories in the response were analyzed using a multicategory logistic regression model with a generalized logit link with logarithms of ratios of probabilities of the category of interest and the reference category. In Tables 1–4, we present estimates of probabilities of outcome categories together with corresponding 95% confidence intervals (CIs) and *P*-values for group comparisons resulting from likelihood ratio tests. For multiple comparisons, we applied Tukey-Kramer adjustment to protect the probability of type I error. The analysis was carried out in SAS, Statistical Software System, Version 9.4.

RESULTS

Spectrum of Cardiac Abnormalities

From 2007 to 2013, 127 fetuses were diagnosed with CHDs in the first trimester (Group I) and 344 in the second trimester (112 fetuses with missed CHDs in the first trimester [Group IIa] and 232 fetuses with CHDs in pregnancies not attending first-trimester screening [Group IIb]). Within this period, in the first trimester (Group I), the most common diagnosed lesions were hypoplastic left heart syndrome in 27 cases (21.3%), atrioventricular septal defect in 26 cases (20.5%), pulmonary atresia in 10 cases (7.9%), and coarctation of the aorta (great vessels disproportion) in 9 cases (7.1%). In the second trimester, from 2007 to 2013 (Group II), the most common diagnosed lesions were atrioventricular septal defect in 45 cases (13.1%), transposition of great arteries in 31 cases (9.0%), coarctation of aorta in 30 cases (8.7%), and hypoplastic left heart syndrome and

Table 1. Spectrum of Congenital Heart Defects Diagnosed in First and Second Trimesters from 2007 to 2013 (Groups I and II)

Cardiac Abnormality	First Trimester (2007–2013) Group I			Second Trimester (2007–2013) Group II			Group I Versus Group II <i>P</i> value
	N=127	Frequency (%)	95% CI	N=344	Frequency (%)	95% CI	
Hypoplastic left heart	27	21.3	15.0–29.2	28	8.1	5.7–11.5	<0.001
Atrioventricular septal defect	26	20.5	14.3–28.4	45	13.1	9.9–17.1	0.053
Pulmonary atresia	10	7.9	4.3–14.0	7	2.0	1.0–4.2	0.005
Coarctation of the aorta	9	7.1	3.7–13.1	30	8.7	6.2–12.2	0.563
Tricuspid atresia	8	6.3	3.2–12.1	7	2.0	1.0–4.2	0.028
Tetralogy of Fallot	8	6.3	3.2–12.1	26	7.6	5.2–10.9	0.635
Ventricular septal defect	8	6.3	3.2–12.1	25	7.3	5.0–10.5	0.712
Aortic stenosis	5	3.9	1.6–9.1	27	7.8	5.4–11.2	0.115
Vascular rings	5	3.9	1.6–9.1	28	8.1	5.7–11.5	0.094
Double inlet ventricle	3	2.4	0.8–7.1	7	2.0	1.0–4.2	0.829
Double outlet ventricle	3	2.4	0.8–7.1	24	7.0	4.7–10.2	0.038
Persistent truncus arteriosus	2	1.6	0.4–6.1	8	2.3	1.2–4.6	0.605
Ebstein anomaly	2	1.6	0.4–6.1	3	0.9	0.3–2.7	0.526
Transposition of the great arteries	1	0.8	0.1–5.4	31	9.0	6.4–12.5	<0.001
Pulmonary stenosis	0	0.0	0–1	17	4.9	3.1–7.8	0.001
Others	10	7.9	4.3–14.0	31	9.0	6.4–12.5	0.695

CI indicates confidence interval.

vascular ring each in 28 cases (8.1%) fetuses. The frequency of hypoplastic left heart syndrome ($P<0.001$), pulmonary atresia ($P=0.005$), and tricuspid atresia ($P=0.028$) was significantly higher in the first trimester, whereas the detection of double outlet right ventricle ($P=0.038$), transposition of great arteries ($P<0.001$), and pulmonary stenosis ($P=0.001$) was higher in the second trimester during the same period. Furthermore, in the second trimester, more fetuses were diagnosed with aortic stenosis and vascular ring (Table 1).

In Group IIb, of 232 fetuses diagnosed with CHDs in the second trimester from 2007 to 2013, the most common lesions were atrioventricular septal defect in 36 cases (15.5%), hypoplastic left heart syndrome and coarctation of aorta each in 21 cases (9.1%), and transposition of great arteries in 20 cases (8.6%). In the second trimester, from 1996 to 2001 (Group III), 532 fetuses were diagnosed with CHDs. During this period, when first-trimester screening was not routinely performed, the most frequent cardiac abnormalities were atrioventricular septal defect in 101 cases (19.0%), hypoplastic left heart syndrome in 91 cases (17.1%), and double outlet right ventricle in 55 cases (10.3%). Before 2001, significantly more fetuses were diagnosed with hypoplastic left heart syndrome ($P=0.003$) and pulmonary atresia ($P=0.006$) compared with after 2007. In contrast, the detection of coarctation of aorta ($P=0.004$), Tetralogy of Fallot ($P=0.034$), vascular ring ($P<0.0001$), and pulmo-

nary stenosis ($P=0.008$) was significantly higher in the second trimester in Group IIb after 2007 (Table 2).

Associated Comorbidity and Outcome of Fetuses

Out of 127 fetuses detected with CHDs in the first trimester (Group I), any comorbidity (chromosomal or structural noncardiac anomalies) was found in 85 fetuses (66.9%, 95% CI, 58.3–74.5), whereas isolated cardiac abnormality was confirmed in 42 fetuses (33.1%). Chromosomal anomalies were found in 63 fetuses (49.6%, 95% CI, 41.0–58.2) and structural noncardiac anomalies in 58 fetuses (45.7%, 95% CI, 37.2–54.4). CHDs with univentricular circulation were identified in 54 fetuses (42.5%, 95% CI, 34.2–51.3) (Figure 2). Only 12 (9.5%, 95% CI, 5.4–15.9) of 127 fetuses diagnosed in the first trimester were born alive, and the diagnosis of CHD was confirmed postnatally in all. Seven fetuses (5.5%, 95% CI, 1.5–9.5) died in utero, and pregnancy was terminated in another 108 fetuses (85.0%, 95% CI, 78.8–91.2) (Figure 3).

In all terminated fetuses, the diagnosis was confirmed by a second examiner within 1 to 3 weeks after the first cardiac scan before termination of pregnancy. In the Czech Republic, postmortem is mandatory by law. Thus, of the 115 fetuses that were not born (7 intrauterine deaths + 108 terminations of pregnancy), in 47 (41.0%), the main diagnosis was confirmed by postmortem (from

Table 2. Spectrum of Congenital Heart Defects Diagnosed in Second Trimester From 2007 to 2013 (Group IIb) and in Second Trimester from 1996 to 2001 (Group III)

Cardiac Abnormality	Second Trimester (2007–2013) Group IIb			Second Trimester (1996–2001) Group III			Group IIb Versus Group III P value
	N=232	Frequency (%)	95% CI	N=532	Frequency (%)	95% CI	
Hypoplastic left heart	21	9.1	6.0–13.5	91	17.1	14.1–20.5	0.003
Atrioventricular septal defect	36	15.5	11.4–20.8	101	19.0	15.9–22.5	0.246
Pulmonary atresia	5	2.2	0.9–5.1	35	6.6	4.8–9.0	0.006
Coarctation of the aorta	21	9.1	6.0–13.5	20	3.8	2.4–5.8	0.004
Tricuspid atresia	5	2.2	0.9–5.1	19	3.6	2.3–5.5	0.285
Tetralogy of Fallot	18	7.8	4.9–12.0	21	3.9	2.6–6.0	0.034
Ventricular septal defect	18	7.8	4.9–12.0	46	8.6	6.5–11.4	0.682
Aortic stenosis	15	6.5	3.9–10.4	24	4.5	3.0–6.6	0.269
Vascular rings	15	6.5	3.9–10.4	0	<0.001	<0.001–1	<0.0001
Double inlet ventricle	6	2.6	1.2–5.6	30	5.6	4.0–8.0	0.053
Double outlet ventricle	19	8.2	5.3–12.5	55	10.3	8.0–13.2	0.349
Persistent truncus arteriosus	6	2.6	1.2–5.6	20	3.8	2.4–5.8	0.399
Ebstein anomaly	2	0.9	0.2–3.4	5	0.9	0.4–2.2	0.917
Transposition of the great arteries	20	8.6	5.6–13.0	33	6.2	4.4–8.6	0.235
Pulmonary stenosis	9	3.9	2.0–7.3	5	0.9	0.4–2.2	0.008
Others	16	6.9	4.3–11.0	27	5.1	3.5–7.3	0.324

CI indicates confidence interval.

13 to 23 weeks of gestation, median 16+3). In 46 fetuses (40.0%) who died or were terminated in the earlier weeks of pregnancy (from 12 to 14 weeks of gestation, median 12+5), the diagnosis was impossible to confirm postmortem because of fragmentation of the fetus. In the remaining 22 fetuses (19.0%), postmortem information was unavailable.

Similarly, of 344 fetuses (Group II) diagnosed with CHDs in the second trimester from 2007 to 2013, any comorbidity was found in 112 fetuses (32.6%, 95% CI, 27.8–37.7), and isolated cardiac abnormality was de-

tected in 232 fetuses (67.4%). Chromosomal anomalies were found in 57 cases (16.6%, 95% CI, 13.0–20.9), structural noncardiac anomalies were found in 84 cases (24.4%, 95% CI, 20.2–29.2), and CHDs with univentricular circulation in 50 cases (14.5%, 95% CI, 11.2–18.7) (Figure 2). Four fetuses (1.2%, 95% CI, 0.03–2.3) from Group II died in utero, pregnancy was terminated in 112 cases (32.5%, 95% CI, 27.6–37.5), and 228 fetuses (66.3%, 95% CI, 61.1–71.8) were born alive (Figure 3).

In all fetuses terminated in second trimester, the diagnosis was confirmed by a second examiner before

Downloaded from http://ahajournals.org by on April 18, 2020

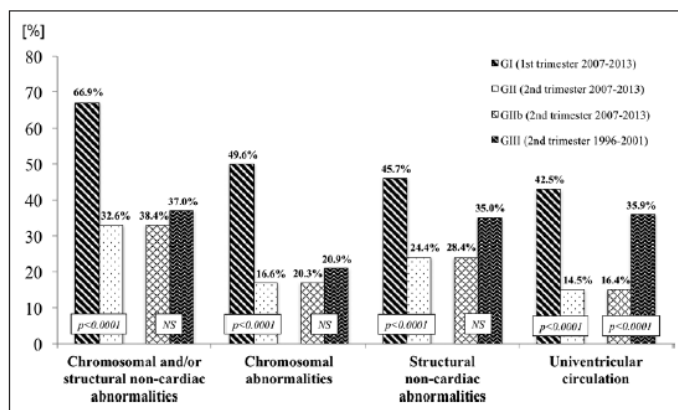


Figure 2. Associated comorbidity and type of circulation in first and second trimesters from 2007 to 2013 and in second trimester from 1996 to 2001. NS indicates not significant.

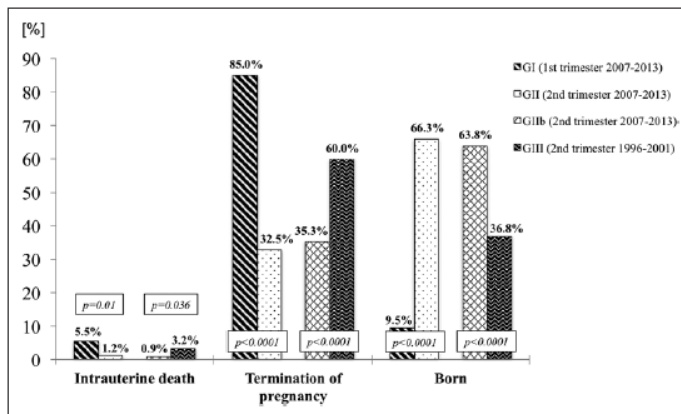


Figure 3. Outcome of fetuses with congenital heart defect diagnosed in the first and second trimesters from 2007 to 2013 and in the second trimester from 1996 to 2001.

termination of pregnancy. Out of 116 fetuses that were not born (4 intrauterine deaths + 112 terminations of pregnancy), the diagnosis was confirmed by postmortem in 114 cases (98.3%). Only 2 families declined postmortem. In 228 fetuses born alive, the CHD diagnosis was confirmed postnatally.

Our data indicate that significantly more comorbidities ($P<0.0001$), chromosomal abnormalities ($P<0.0001$), structural noncardiac abnormalities ($P<0.0001$), CHD with univentricular outcome ($P<0.0001$), intrauterine deaths ($P=0.01$), and terminations of pregnancy ($P<0.0001$) were identified in the group of CHD cases diagnosed within the first trimester (Group I) compared with the second trimester (Group II) from 2007 to 2013 (Figures 2 and 3).

Out of 232 fetuses from Group IIb (subgroup of Group II), comorbidity was found in 89 fetuses (38.4%, 95% CI, 32.3–44.8), whereas isolated cardiac abnormality was confirmed in 143 fetuses (61.6%). Chromosomal anomalies were found in 47 fetuses (20.3%, 95% CI, 15.6–25.9) and structural noncardiac anomalies in 66 fetuses (28.4%, 95% CI, 23.0–34.6). CHDs with univentricular circulation were identified in 38 fetuses (16.4%, 95% CI, 12.2–21.7) (Figure 2). Two fetuses (0.9%, 95% CI, 0.0–2.1) from Group IIb died in utero, pregnancy was terminated in 82 cases (35.3%, 95% CI, 29.2–41.5), and 148 fetuses were born (63.8%, 95% CI, 57.4–69.7) (Figure 3).

In 532 fetal CHD cases diagnosed in the second trimester from 1996 to 2001 (Group III), any comorbidity was detected in 197 cases (37.0%, 95% CI, 33.0–41.2) and isolated cardiac abnormality in 335 cases (63.0%). Chromosomal anomalies were detected in 111 cases (20.9%, 95% CI, 17.6–24.5), structural noncardiac anomalies in 186 cases (35.0%, 95% CI, 31.0–39.1), and CHDs with univentricular circulation in 191 cases (35.9%, 95% CI, 32.0–40.1) (Figure 2). Intrauterine death occurred in 17 fetuses (3.2%, 95% CI, 1.7–4.7),

pregnancy was terminated in 319 cases (60.0%, 95% CI, 55.8–64.1), and 196 fetuses were born (36.8%, 95% CI, 32.8–41.0) (Figure 3).

Lastly, we observed a significantly higher frequency of CHD cases with univentricular outcomes ($P<0.0001$), intrauterine deaths ($P=0.036$), and terminations of pregnancy ($P<0.0001$) in Group III compared with Group IIb (Figures 2 and 3).

Significantly more fetuses were detected with trisomy 21 ($P=0.0008$), trisomy 18 ($P=0.023$), trisomy 13 ($P<0.0001$), and X chromosome monosomy ($P<0.0001$) in the first trimester compared with the second trimester from 2007 to 2013 (Table 3). A higher detection of the other chromosomal abnormalities ($P=0.030$) was found in the second trimester in Group IIb from 2007 to 2013 compared with the second trimester from 1996 to 2001 in Group III (Table 4).

DISCUSSION

It has been confirmed by epidemiological and postmortem studies that the spectrum and frequency of the individual lesions found prenatally differ from those found postnatally.^{15–17} In this study, we confirmed that the spectrum of congenital heart abnormalities diagnosed in the first and second trimesters differed significantly as well with more comorbidities, conditions with univentricular outcomes, intrauterine deaths, and pregnancy terminations in the first trimester. Furthermore, we confirmed for the first time on a large group of fetuses in 2 time periods that first-trimester screening implementation as part of prenatal care changes the spectrum of congenital heart defects in later pregnancy and has a major impact on the postnatal outcome of children with CHDs.

Second-trimester cardiac screening programs were implemented and financially supported by governments in many developed countries back in 1980 to 1990.

Table 3. Chromosomal Abnormalities Diagnosed in First and Second Trimesters From 2007 to 2013 (Groups I and II)

Chromosomal Abnormalities	First Trimester (2007–2013) Group I			Second Trimester (2007–2013) Group II			Group I Versus Group II P value
	N	Frequency (%)	95% CI	N	Frequency (%)	95% CI	
Trisomy 21	18	14.2	(8.1–20.2)	16	4.7	(2.4–6.9)	0.0008
Trisomy 18	13	10.2	(5.0–15.5)	15	4.4	(2.2–6.5)	0.023
Trisomy 13	11	8.7	(3.8–13.6)	4	1.2	(0.02–2.3)	<0.0001
Monosomy X	13	10.2	(5.0–15.5)	5	1.5	(0.2–2.7)	<0.0001
Deletion 22q11	0	0.0	(0.0–0.0)	6	1.7	(0.4–3.1)	0.051
Others	8	6.3	(2.1–10.5)	11	3.2	(1.3–5.1)	0.150
Total	63	49.6	(41.0–58.2)	57	16.6	(13.0–20.9)	<0.0001

CI indicates confidence interval.

Several national and international recommendations and guidelines^{11–13} have helped to develop organizational, structural, and educational programs to offer standard quality of care to all patients in each country. These programs have been successfully supported by health organizers in almost all countries within the European Union. The implementation of first-trimester ultrasound screening programs at the beginning of the new millennium fundamentally changed prenatal care by moving the detection of major abnormalities to the early stages of gestation.¹ A recent review of published data in 13 centers indicated that first-trimester detection rates of major CHDs varied between 2.3% and 54.5% in euploid fetuses and between 36.8% and 82.1% in euploid and aneuploid fetuses.¹⁸

We documented that in the early weeks of gestation, the incidence of cardiac abnormalities was higher and more often associated with chromosomal abnormalities. In our study, 49.6% of heart abnormalities detected in the first trimester were associated with chromosomal abnormalities. A similar study, also performed in the first trimester, revealed chromosomal abnormalities in 72.9% of cases.¹⁹ Other published studies documented

that the frequency of chromosomal abnormalities in fetuses varied between 16% and 47% depending on the gestational age.^{20,21} The differences in outcomes of 2 screening programs in the 2 different time periods of our study are influenced by the tremendous progress in the detection of chromosomal abnormalities as several new techniques (quantitative fluorescent polymerase chain reaction, array comparative genomic hybridization, and noninvasive prenatal testing) have emerged, offering more detailed and rapid genetic qualitative evaluation. In our study, associated cumulative (first- and second-trimester) frequencies of chromosomal aberrations were 49.6% (first trimester) and 16.6% (second trimester) compared with only 20.9% aneuploidies detected during second-trimester screening between 1996 and 2001.

Although major structural abnormalities can be identified at 11 to 13 weeks of gestation, the accuracy of diagnosis in the first trimester depends on multiple factors, such as the expertise of the sonographer, time allocated for fetal examination, quality of the equipment, and presence of an easily detectable marker for CHD (increased NT, abnormal flow in the ductus venosus, and tricuspid regurgitation).^{3–5,18,22}

Table 4. Chromosomal Abnormalities Diagnosed in Second Trimester From 2007 to 2013 (Group IIb) and in Second Trimester From 1996 to 2001 (Group III)

Chromosomal Abnormalities	Second Trimester (2007–2013) Group IIb			Second Trimester (1996–2001) Group III			Group IIb Versus Group III P value
	N	Frequency (%)	95% CI*	N	Frequency (%)	95% CI	
Trisomy 21	13	5.6	(2.6–8.6)	47	8.8	(6.4–11.2)	0.116
Trisomy 18	14	6.0	(3.0–9.1)	34	6.4	(4.3–8.5)	0.844
Trisomy 13	2	0.9	(0.0–2.1)	5	0.9	(0.1–1.8)	0.911
Monosomy X	4	1.7	(0.0–3.4)	12	2.3	(1.0–3.5)	0.636
Deletion 22q11	4	1.7	(0.0–3.4)	5	0.9	(0.1–1.8)	0.376
Others	10	4.3	(1.7–6.9)	8	1.5	(0.5–2.5)	0.030
Total	47	20.3	(15.6–25.9)	111	20.9	(17.6–24.5)	0.849

CI indicates confidence interval.

Better quality ultrasound machines with more advanced technology were used in the latter period of our study (2007–2013) compared with the former period (1996–2001). We believe that the new advanced technology, such as high-definition imaging and high-definition power Doppler ultrasound in particular, may contribute to better detection of CHDs associated with vascular abnormalities such as vascular rings, aortopulmonary collaterals, coronary fistulae, and pulmonary vein abnormalities. The progress in cardiovascular imaging is documented by a higher number of detected vascular rings and anomalies of aortic arches and neck arteries in the latter period (2007–2013).

Also, the differences in detection of major structural cardiac abnormalities are related to the quality of training provided, the skills of individual colleagues, and improved technology over this period. Therefore, it is crucial to improve the technological aspects of ultrasound scanning as well as provide high-level training in first-trimester ultrasound screening for fetal sonographers and obstetricians. Introducing new training standards significantly helped improve detection rates of vascular abnormalities and great artery lesions.²³ The 3-vessels and trachea view has been implemented recently in fetal anomaly scans in the United Kingdom, and similar trends are seen in other countries as well.

Persico²⁴ suggested that the vast majority of major CHDs ($\leq 84\%$) can be detected during the first-trimester fetal ultrasound scan performed by experienced fetal sonographers and obstetricians. Moving prenatal cardiac ultrasound screening to the early stages of pregnancy would, in some countries, reduce the numbers of children born with severe cardiac abnormalities and with associated comorbidities. However, such first-trimester screening will possibly miss some heart conditions (eg, ventricular septal defects, total anomalous pulmonary venous connection, aortic and pulmonary stenosis).

Similarly, early termination might be considered in CHD cases that could have rather good postnatal outcomes (eg, typically in aortic coarctation, wrongly diagnosed as hypoplastic left heart syndrome). In addition, in the first trimester, it is not always possible to detect cardiac abnormalities in enough detail to provide the family with correct information about the natural progress of disease, the postnatal patient's management, and treatment options. Typical abnormalities falling under the category of likely incomplete diagnosis in the first trimester are common arterial trunk, pulmonary atresia with ventricular septal defect, and the majority of complex CHDs. Furthermore, some heart lesions are detectable or develop at later stages of pregnancy (eg, heart tumors [typically rhabdomyoma], aortic coarctation, and cardiomyopathy), whereas some heart abnormalities can progress throughout the pregnancy. It has been known that disproportion in the 4-chamber view may be caused by a variety of cardiac abnormalities (typically

aortic coarctation and arch hypoplasia)²⁵ and noncardiac abnormalities, including abnormal blood flow distribution (persistent left superior vena cava draining coronary sinus),²⁶ as well as the presence of chromosomal abnormalities.²⁷ The progression of aortic stenosis toward hypoplastic left heart syndrome is well known.^{28,29} In many of these cases, family counseling is extremely difficult because physicians are expected to predict as much as possible from little diagnostic information. Detection of heart abnormalities, which can develop into such a vast variety of conditions, causes uncertainty and significant stress for families.^{30,31}

In 2011, noninvasive prenatal testing of some chromosomal aneuploidies and submicroscopic chromosomal aberrations using cell-free DNA analysis was introduced into clinical practice.³² In some countries, this approach could potentially result in the diagnosis of fetuses with trisomies or other chromosomal abnormalities and subsequently increase the termination rate of pregnancies with chromosomal abnormalities without ultrasound screening. However, based on the recommendations of professional societies, noninvasive prenatal testing is not a diagnostic test, and confirmatory invasive testing (amniocentesis preferably) is required in case of any abnormal result.³³ However, direct-to-consumer noninvasive prenatal testing examinations (mostly those that are targeted on chromosomes 13, 18, and 21 only) without previous discussion with a health professional (gynecologist, obstetrician, geneticist, etc.) could lead to missed diagnoses of heart defects that are caused by submicroscopic aberrations (ie, DiGeorge syndrome) or germline mutations or have a nongenetic background.

We are in agreement with Persico's²⁴ recommendation for all fetuses with CHD detected in the first trimester to be referred for specialized fetal echocardiography to better evaluate the cardiac abnormality, confirm the correct diagnosis, and provide appropriate family counseling. We believe that the second-trimester cardiac screening program should be maintained to confirm normal cardiovascular structures or reassess fetuses with cardiac abnormalities detected in the first trimester; for all these reasons, we would not change the existing practice. Also, Nicolaides's¹ inverted pyramid model of prenatal investigations, which moves prenatal care into the first trimester, keeps second-trimester screening in the prenatal care process for all the pregnancies to re-evaluate fetal anatomy and growth. This approach is also recommended by the International Society of Ultrasound in Obstetrics and Gynecology consensus statement that a pregnant woman with family history of CHD, increased NT, or abnormal fetal cardiac screening evaluation in the fetus should be offered a fetal echocardiography scan at or before 14 weeks of gestation with a follow-up scan at 20 to 22 weeks.¹³ First-trimester counseling should be carried out with the parents made aware that a more detailed diagnosis and more accurate prediction of fetal

outcome should be achievable in the later stages of the pregnancy. Nevertheless, we still perceive first-trimester screening to be perilous because it could lead to more frequent terminations of pregnancies in euploid fetuses with CHDs that otherwise might have had favorable outcomes.

In addition, pre- and postnatal diagnostic protocols and follow-up data collection (including postmortem data) are necessary to assess the impact of prenatal diagnoses on postnatal outcomes and learn from the natural and unnatural histories of CHDs.

CONCLUSIONS

Our results from the Southern Moravian region confirmed the significant impact of first-trimester screening on the spectrum of CHDs later in pregnancy and on the outcomes of pregnancies with a CHD, in that more severe forms of cardiac abnormalities and higher comorbidities resulted in an increase in early termination of first-trimester pregnancies. In the second trimester, less severe forms of cardiac abnormalities were diagnosed. These fetuses had better postnatal outcomes because of more frequent biventricular circulation and fewer associated comorbidities. However, first-trimester screening was unable to detect some serious heart conditions with duct-dependent circulation, which have good long-term postnatal outcomes if treated appropriately. In addition, the early diagnostic ultrasound appearance does not allow the accurate prediction of later clinical outcomes. We believe that the second-trimester screening program has its place in an integral, multimodality screening program scheme in pregnancy. National healthcare providers should continue supporting these programs, including educational programs for specialized sonographers and doctors. The concept of the implementation of fetal medicine centers with specialized sonographers or doctors collaborating with first-line healthcare providers and tertiary experts in fetal/pediatric cardiology appears to be optimal for the Czech Republic as well as other countries.

LIMITATIONS

We are aware of a rather small screening population sample in our study. However, the prenatal cardiac screening program has been well organized, with 98% of pregnant women in the entire Czech Republic participating in prenatal screening. Not all children born alive in our geographical area had complete cross-section imaging confirming normal cardiac structures, and not all terminated fetuses, or those who died before reaching term, had a postmortem examination to confirm prenatal diagnosis. However, all children who died postnatally did have a postmortem examination (mandatory in children <18

years of age), and all those who presented with a heart murmur or any clinical symptoms suggestive of a heart condition did have comprehensive cardiology review, including detailed echocardiography.

ACKNOWLEDGMENTS

We are grateful for the support and input of Petra Ovesna, PhD, Institute of Biostatistics and Analyses of the Faculty of Medicine, Masaryk University Brno, Czech Republic; Marta Jezova, MD, PhD, Department of Pathology, Faculty of Medicine, Masaryk University Brno, Czech Republic; and Diana Grochova, PhD, Cytogenetic Laboratory Brno, Czech Republic.

SOURCES OF FUNDING

Drs Tomek, Skovranek, and Jicinsky were supported by the Ministry of Health, Czech Republic project for conceptual development of research organization 00064203 (University Hospital Motol, Prague, Czech Republic).

DISCLOSURES

None.

AFFILIATIONS

From Department of Pediatric Cardiology, University Hospital Brno and Faculty of Medicine, Masaryk University, Czech Republic (H.J.); Fetal Medicine Center, Brno, Czech Republic (H.J., P.V., I.G.); Children's Heart Center, 2nd Faculty of Medicine, Charles University and Motol University Hospital, Prague, Czech Republic (M.J., V.T., J.S., J.M.); University Hospital Sv. Anny, Brno, Czech Republic (I.G.); Louisiana State University Health–New Orleans, School of Public Health (J.V.); and Great Ormond Street Hospital for Children and Institute of Cardiovascular Sciences UCL, London, UK (J.M.).

FOOTNOTES

Received December 10, 2015; accepted January 13, 2017.
Circulation is available at <http://circ.ahajournals.org>.

REFERENCES

- Nicolaides KH. A model for a new pyramid of prenatal care based on 11 to 13 week's assessment. *Prenat Diagn*. 2011;31:3–6.
- Nicolaides KH. Screening for fetal aneuploidies at 11 to 13 weeks. *Prenat Diagn*. 2011;31:7–15. doi: 10.1002/pd.2637.
- Bahado-Singh RO, Wapner R, Thom E, Zachary J, Platt L, Mahoney MJ, Johnson A, Silver RK, Pergament E, Filkins K, Hogge WA, Wilson RD, Jackson LG; First Trimester Maternal Serum Biochemistry and Fetal Nuchal Translucency Screening Study Group. Elevated first-trimester nuchal translucency increases the risk of congenital heart defects. *Am J Obstet Gynecol*. 2005;192:1357–1361. doi: 10.1016/j.ajog.2004.12.086.
- Chelemen T, Syngelaki A, Maiz N, Allan L, Nicolaides KH. Contribution of ductus venosus Doppler in first-trimester screening for

- major cardiac defects. *Fetal Diagn Ther*. 2011;29:127–134. doi: 10.1159/000322138.
5. Huggon IC, DeFigueiredo DB, Allan LD. Tricuspid regurgitation in the diagnosis of chromosomal anomalies in the fetus at 11–14 weeks of gestation. *Heart*. 2003;89:1071–1073.
 6. Samánek M, Vorisková M. Congenital heart disease among 815,569 children born between 1980 and 1990 and their 15-year survival: a prospective Bohemia survival study. *Pediatr Cardiol*. 1999;20:411–417. doi: 10.1007/s002469900502.
 7. Samánek M, Slavík Z, Zborilová B, Hrobonová V, Vorisková M, Skovránek J. Prevalence, treatment, and outcome of heart disease in live-born children: a prospective analysis of 91,823 live-born children. *Pediatr Cardiol*. 1989;10:205–211. doi: 10.1007/BF02083294.
 8. Gerlis LM. Cardiac malformations in spontaneous abortions. *Int J Cardiol*. 1985;7:29–46.
 9. Calda P, Sipek A, Gregor V. Gradual implementation of first trimester screening in a population with a prior screening strategy: population based cohort study. *Acta Obstet Gynecol Scand*. 2010;89:1029–1033. doi: 10.3109/00016349.2010.489599.
 10. Marek J, Tomek V, Skovránek J, Povysilová V, Samánek M. Prenatal ultrasound screening of congenital heart disease in an unselected national population: a 21-year experience. *Heart*. 2011;97:124–130. doi: 10.1136/hrt.2010.206623.
 11. Allan L, Dangel J, Fesslova V, Marek J, Mellander M, Oberhansli I, Oberhoffer R, Sharland G, Simpson J, Sonesson SE; Fetal Cardiology Working Group; Association for European Paediatric Cardiology. Recommendations for the practice of fetal cardiology in Europe. *Cardiol Young*. 2004;14:109–114.
 12. Donofrio MT, Moon-Grady AJ, Hornberger LK, Copel JA, Sklansky MS, Abuhamad A, Cuneo BF, Huhta JC, Jonas RA, Krishnan A, Lacey S, Lee W, Michelfelder EC Sr, Rempel GR, Silverman NH, Spray TL, Strasburger JF, Tworetzky W, Rychik J; American Heart Association Adults With Congenital Heart Disease Joint Committee of the Council on Cardiovascular Disease in the Young and Council on Clinical Cardiology, Council on Cardiovascular Surgery and Anesthesia, and Council on Cardiovascular and Stroke Nursing. Diagnosis and treatment of fetal cardiac disease: a scientific statement from the American Heart Association. *Circulation*. 2014;129:2183–2242. doi: 10.1161/01.cir.0000437597.44550.5d.
 13. Lee W, Allan L, Carvalho JS, Chaoui R, Copel J, Devore G, Hecher K, Munoz H, Nelson T, Paladini D, Yagel S; ISUOG Fetal Echocardiography Task Force. ISUOG consensus statement: what constitutes a fetal echocardiogram? *Ultrasound Obstet Gynecol*. 2008;32:239–242. doi: 10.1002/uog.6115.
 14. Anderson RH, Cook AC. Morphology of the functionally univentricular heart. *Cardiol Young*. 2004;14(Suppl 1):3–12.
 15. Hoffman JL. Incidence of congenital heart disease: II. Prenatal incidence. *Pediatr Cardiol*. 1995;16:155–165. doi: 10.1007/BF00794186.
 16. Allan LD, Crawford DC, Anderson RH, Tynan M. Spectrum of congenital heart disease detected echocardiographically in prenatal life. *Br Heart J*. 1985;54:523–526.
 17. Tennstedt C, Chaoui R, Körner H, Dietel M. Spectrum of congenital heart defects and extracardiac malformations associated with chromosomal abnormalities: results of a seven year necropsy study. *Heart*. 1999;82:34–39.
 18. Khalil A, Nicolaides KH. Fetal heart defects: potential and pitfalls of first-trimester detection. *Semin Fetal Neonatal Med*. 2013;18:251–260. doi: 10.1016/j.siny.2013.05.004.
 19. Huggon IC, Ghi T, Cook AC, Zosmer N, Allan LD, Nicolaides KH. Fetal cardiac abnormalities identified prior to 14 weeks' gestation. *Ultrasound Obstet Gynecol*. 2002;20:22–29. doi: 10.1046/j.1469-0705.2002.00733.x.
 20. Helling KS, Chaoui R. Early Fetal echocardiography: results from the first trimester screening in a 3 year period. *Ultrasound Obstet Gynecol*. 2008;32:264.
 21. Allan LD, Sharland GK, Chita SK, Lockhart S, Maxwell DJ. Chromosomal anomalies in fetal congenital heart disease. *Ultrasound Obstet Gynecol*. 1991;1:8–11. doi: 10.1046/j.1469-0705.1991.01010008.x.
 22. Syngelaki A, Chelemen T, Dagklis T, Allan L, Nicolaides KH. Challenges in the diagnosis of fetal non-chromosomal abnormalities at 11–13 weeks. *Prenat Diagn*. 2011;31:90–102. doi: 10.1002/pd.2642.
 23. Levy DJ, Pretorius DH, Rothman A, Gonzales M, Rao C, Nunes ME, Bendelstein J, Mehalek K, Thomas A, Nehlsen C, Ehr J, Burchette RJ, Sklansky MS. Improved prenatal detection of congenital heart disease in an integrated health care system. *Pediatr Cardiol*. 2013;34:670–679. doi: 10.1007/s00246-012-0526-y.
 24. Persico N, Moratalla J, Lombardi CM, Zidere V, Allan L, Nicolaides KH. Fetal echocardiography at 11–13 weeks by transabdominal high-frequency ultrasound. *Ultrasound Obstet Gynecol*. 2011;37:296–301. doi: 10.1002/uog.8934.
 25. Matsui H, Mellander M, Roughton M, Jicinska H, Gardiner HM. Morphological and physiological predictors of fetal aortic coarctation. *Circulation*. 2008;118:1793–1801. doi: 10.1161/CIRCULATIONAHA.108.787598.
 26. Berg C, Knüppel M, Geipel A, Kohl T, Krapp M, Knöpfle G, Germer U, Hansmann M, Gembruch U. Prenatal diagnosis of persistent left superior vena cava and its associated congenital anomalies. *Ultrasound Obstet Gynecol*. 2006;27:274–280. doi: 10.1002/uog.2704.
 27. Bellotti M, Fesslova V, De Gasperi C, Rognoni G, Bee V, Zucca I, Cappellini A, Bulfamante G, Lombardi CM. Reliability of the first-trimester cardiac scan by ultrasound-trained obstetricians with high-frequency transabdominal probes in fetuses with increased nuchal translucency. *Ultrasound Obstet Gynecol*. 2010;36:272–278. doi: 10.1002/uog.7685.
 28. Simpson JM, Sharland GK. Natural history and outcome of aortic stenosis diagnosed prenatally. *Heart*. 1997;77:205–210.
 29. Axt-Fliedner R, Kreiselmaier P, Schwarze A, Krapp M, Gembruch U. Development of hypoplastic left heart syndrome after diagnosis of aortic stenosis in the first trimester by early echocardiography. *Ultrasound Obstet Gynecol*. 2006;28:106–109. doi: 10.1002/uog.2824.
 30. Carvalho JS. Screening for heart defects in the first trimester of pregnancy: food for thought. *Ultrasound Obstet Gynecol*. 2010;36:658–660. doi: 10.1002/uog.8874.
 31. Carvalho JS, Moscoso G, Tekay A, Campbell S, Thilaganathan B, Shinebourne EA. Clinical impact of first and early second trimester fetal echocardiography on high risk pregnancies. *Heart*. 2004;90:921–926. doi: 10.1136/hrt.2003.015065.
 32. Allyse M, Minear MA, Berson E, Sridhar S, Rote M, Hung A, Chandrasekharan S. Non-invasive prenatal testing: a review of international implementation and challenges. *Int J Womens Health*. 2015;7:113–126. doi: 10.2147/IJWH.S67124.
 33. Dondorp W, de Wert G, Bombard Y, Bianchi DW, Bergmann C, Borry P, Chitty LS, Fellmann F, Forzano F, Hall A, Henneman L, Howard HC, Lucassen A, Ormond K, Peterlin B, Radojkovic D, Rogowski W, Soller M, Tibben A, Tranebjærg L, van El CG, Cornel MC; European Society of Human Genetics; American Society of Human Genetics. Non-invasive prenatal testing for aneuploidy and beyond: challenges of responsible innovation in prenatal screening. *Eur J Hum Genet*. 2015;23:1438–1450. doi: 10.1038/ejhg.2015.57.

3. Left heart lesions

The aim of prenatal detection of CHDs is to detect severe CHDs, mainly critical CHDs, which present with signs of heart failure or with cyanosis soon after birth. CHD cases need to be treated by conservative treatment or by invasive procedures (cardiac catheterization or heart surgery) soon after birth.

Most left heart lesions (severe aortic stenosis, aortic atresia, mitral stenosis, mitral atresia, hypoplastic left heart syndrome) belong to the most severe CHDs. It is known that in some cases severe aortic stenosis detected during prenatal life can develop into hypoplastic left heart syndrome by the time of birth. In such cases it is impossible to use the left ventricle for circulation after birth and such cases result in CHD with univentricular circulation and with an uncertain prognosis. Prenatally in some cases, it is possible to perform fetal aortic balloon valvuloplasty and to protect the left ventricle from remodeling and progression to hypoplastic left heart syndrome. But it is very difficult to recognize which fetus, with aortic valve stenosis, will develop hypoplastic left heart syndrome and which fetus will profit from this invasive procedure. There are morphological and physiological parameters which should help to provide answers to these questions. Subsequent studies tested these parameters retrospectively and they looked into the natural history of fetuses with aortic valve stenosis and their outcomes, i.e., if the development of the left ventricle lead to univentricular or biventricular circulation. In addition, the studies looked into the outcomes of fetuses with and without fetal aortic balloon valvuloplasty.

Coarctation of the aorta definitely develops after arterial duct closure after birth. Because of this reason it is very difficult to predict the development of coarctation of the aorta before birth when the arterial duct is still open. Later publications tested and presented some parameters which can help to make the diagnosis of COA. If there is suspicion of COA or diagnosis of COA prenatally, we do follow up in such fetuses postnatally and we indicate surgery at the right time. There is mainly a very good prognosis for this CHD.

3.0.1 ANNEX 6

Gardiner H M, Kovacevic A, Tulzer G, Sarkola T, Herberg U, Dangel J, Öhman A, Bartrons J, Carvalho J S, **Jicinska H**, Fesslova V, Averiss I, Mellander M, Fetal Working Group of the AEPC

The natural history of 107 cases of fetal aortic stenosis from a European multicenter retrospective study

Ultrasound in Obstetrics and Gynecology 2016;48:373-381.

Impact factor in 2016 = 4.710

Main points of the publication:

In some fetuses fetal aortic valve stenosis progresses to hypoplastic left heart syndrome (HLHS), which results in postnatal univentricular (UV) circulation. Fetal aortic valvuloplasty aims to prevent the remodeling of the left ventricle and a univentricular circulation outcome.

The aim of the study was to describe the natural history of fetal aortic stenosis and to test previously published criteria designed to identify emerging HLHS cases with the potential for a biventricular (BV) outcome after fetal valvuloplasty (FV).

The main finding of this study: of 147 fetuses with Aortic Stenosis who did not undergo FV, 80 of them (54%) underwent a postnatal procedure, with 44 fetuses (55%) resulting in a BV outcome.

Our data show that a substantial proportion of fetuses meeting the criteria for emerging HLHS, with or without favorable selection criteria for FV, had a sustained BV circulation without fetal intervention. This indicates that further work is needed to refine the selection criteria to offer appropriate therapy to fetuses with aortic stenosis.

The candidate contributed to the manuscript and with cases to this international study.



Natural history of 107 cases of fetal aortic stenosis from a European multicenter retrospective study

H. M. GARDINER*, A. KOVACEVIC†, G. TULZER‡, T. SARKOLA§, U. HERBERG¶, J. DANGEL**, A. ÖHMAN††, J. BARTRONS‡‡, J. S. CARVALHO§§, H. JICINSKA¶¶, V. FESSLOVA***, I. AVERISS*, M. MELLANDER††† and the Fetal Working Group of the AEPG

*The Fetal Center at Children's Memorial Hermann Hospital, McGovern Medical School at The University of Texas Health Science Center at Houston (UTHealth), TX, USA; †Department of Paediatric and Congenital Cardiology, University of Heidelberg, Heidelberg, Germany; ‡Department of Paediatric Cardiology, Children's Heart Centre, Linz, Austria; §University of Helsinki and Helsinki University Hospital, Helsinki, Finland; ¶Department of Paediatric Cardiology, University Hospital Bonn, Bonn, Germany; **Perinatal Cardiology Clinic, 2nd Department of Obstetrics and Gynecology, Medical University of Warsaw, Warsaw, Poland; ††Department of Paediatric Cardiology, Queen Silvia Children's Hospital, Sahlgrenska University Hospital, Gothenburg, Sweden; †††Department of Paediatric Cardiology, Sant Joan de Déu, Barcelona, Spain; §§Department of Paediatric and Congenital Cardiology, Royal Brompton and Harefield Hospital, NHS Trust, and Fetal Medicine Unit, St George's Hospital NHS Trust, London, UK; ¶¶University Hospital and Masaryk University Brno, Brno, Czech Republic; ***Center of Fetal Cardiology, Policlinico San Donato IRCSS, Milan, Italy

KEYWORDS: aortic valve stenosis; fetal heart; natural history; valvuloplasty

ABSTRACT

Objectives Fetal aortic valvuloplasty (FV) aims to prevent fetal aortic valve stenosis progressing into hypoplastic left heart syndrome (HLHS), which results in postnatal univentricular (UV) circulation. Despite increasing numbers of FVs performed worldwide, the natural history of the disease in fetal life remains poorly defined. The primary aim of this study was to describe the natural history of fetal aortic stenosis, and a secondary aim was to test previously published criteria designed to identify cases of emerging HLHS with the potential for a biventricular (BV) outcome after FV.

Methods From a European multicenter retrospective study of 214 fetuses with aortic stenosis (2005–2012), 107 fetuses in ongoing pregnancies that did not undergo FV were included in this study and their natural history was reported. We examined longitudinal changes in Z-scores of aortic and mitral valve and left ventricular dimensions and documented direction of flow across the foramen ovale and aortic arch, and mitral valve inflow pattern and any gestational changes. Data were used to identify fetuses satisfying the Boston criteria for emerging HLHS and estimate the proportion of these that would have been ideal FV candidates. We applied the threshold score whereby a score of 1 was assigned to fetuses for each Z-score meeting the following criteria: left ventricular length and width > 0; mitral valve diameter > -2; aortic valve diameter > -3.5; and pressure gradient

across either the mitral or aortic valve > 20 mmHg. We compared the predicted circulation with known survival and final postnatal circulation (BV, UV or conversion from BV to UV).

Results Among the 107 ongoing pregnancies there were eight spontaneous fetal deaths and 99 livebirths. Five were lost to follow-up, five had comfort care and four had mild aortic stenosis not requiring intervention. There was intention-to-treat in these 85 newborns but five died prior to surgery, before circulation could be determined, and thus 80 underwent postnatal procedures with 44 BV, 29 UV and seven BV-to-UV circulatory outcomes. Of newborns with intention-to-treat, 69/85 (81%) survived ≥ 30 days. Survival at median 6 years was superior in cases with BV circulation ($P = 0.041$). Those with a postnatal UV circulation showed a trend towards smaller aortic valve diameters at first scan than did the BV cohort ($P = 0.076$), but aortic valve growth velocities were similar in both cohorts to term. In contrast, the mitral valve diameter was significantly smaller at first scan in those with postnatal UV outcomes ($P = 0.004$) and its growth velocity ($P = 0.008$), in common with the left ventricular inlet length ($P = 0.004$) and width ($P = 0.002$), were reduced significantly by term in fetuses with UV compared with BV outcome. Fetal data, recorded before 30 completed gestational weeks, from 70 treated neonates were evaluated to identify emerging HLHS. Forty-four had moderate or severe left ventricular depression and 38 of these had retrograde flow in the aortic arch and two

Correspondence to: Prof. H. M. Gardiner, The Fetal Center, UT Professional Building, 6410 Fannin, Suite 210, Houston, TX 77030, USA (e-mail: helena.m.gardiner@uth.tmc.edu)

Accepted: 30 January 2016

had left-to-right flow at atrial level and reversed a-waves in the pulmonary veins. Thus 40 neonates met the criteria for emerging HLHS and BV circulation was documented in 13 (33%). Of these 40 cases, 12 (30%) had a threshold score of 4 or 5, of which five (42%) had BV circulation without fetal intervention.

Conclusions The natural history in our cohort of fetuses with aortic stenosis and known outcomes shows that a substantial proportion of fetuses meeting the criteria for emerging HLHS, with or without favorable selection criteria for FV, had a sustained BV circulation without fetal intervention. This indicates that further work is needed to refine the selection criteria to offer appropriate therapy to fetuses with aortic stenosis. Copyright © 2016 ISUOG. Published by John Wiley & Sons Ltd.

INTRODUCTION

Prenatal diagnosis of aortic stenosis is relatively rare, occurring in less than 10% of newborns requiring neonatal intervention¹. Fetal aortic valvuloplasty (FV) is offered in the setting of significant aortic stenosis, with the intent to alter fetal left heart hemodynamics that might result in univentricular (UV) circulation after birth. However, the procedure is not without risk and experienced centers report a 10% procedure-related loss^{2,3}, with higher losses reported by multicenter registries with more varied experience⁴.

There are important challenges in conducting a randomized trial to assess risks and benefits of FV in this rare condition and natural history reports are limited by their sample size, quality of prenatal data and postnatal follow-up⁵⁻⁷. Knowledge of the natural history of fetal aortic stenosis is important for health professionals providing fetal counseling.

The primary aim of this study was to report the spectrum of fetal left heart morphology and physiology, pregnancy outcome, survival and final circulatory pathways in a natural history cohort of aortic stenosis, established by the Fetal Working Group of the Association for European Paediatric Cardiology. A secondary aim was to test previously published selection criteria for emerging hypoplastic left heart syndrome (HLHS) and identify ideal candidates for FV in this population of fetuses by comparing predicted with observed outcomes^{2,6}.

METHODS

The multicenter multinational study of fetal aortic stenosis was established by the Fetal Working Group of the Association for European Paediatric Cardiology and involved 23 centers in 12 European countries from January 2005 to May 2012. In total, 214 fetuses with a spectrum of aortic valve diseases were enrolled, 67 of which underwent FV and are not reported here (Figure 1). We present the natural history of 107 of these fetuses with aortic stenosis that did not undergo FV, with information obtained retrospectively.

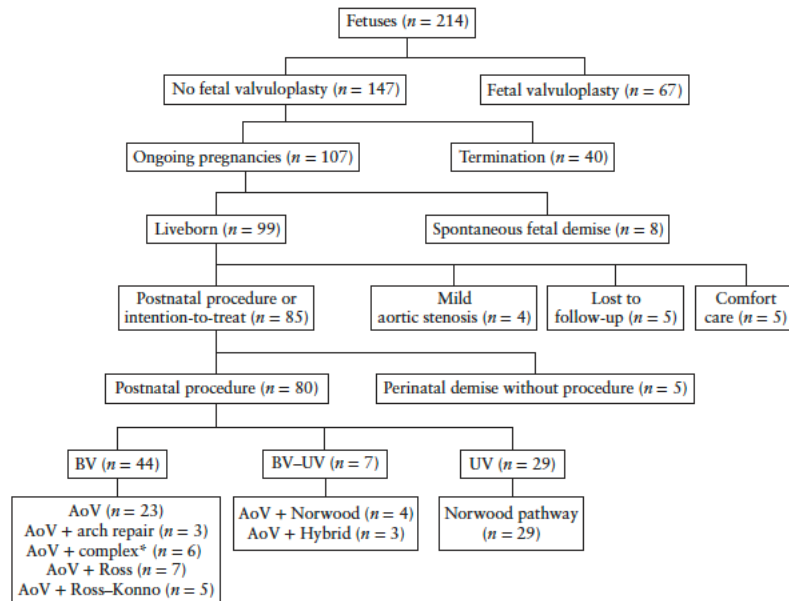


Figure 1 Outcomes of the natural history cohort of fetuses with aortic stenosis. *Complex includes a variety of mitral valve procedures, including its replacement. AoV, balloon valvuloplasty or surgical valvotomy of the aortic valve; BV, biventricular circulation; BV-UV, biventricular-to-univentricular conversion; UV, univentricular circulation.

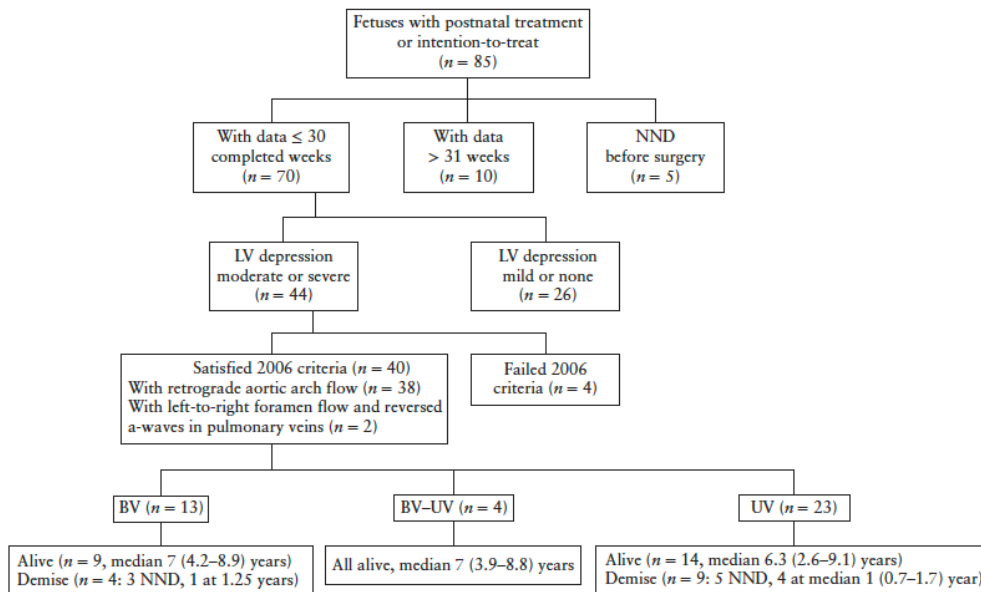


Figure 2 Selection process to determine proportion of fetuses with aortic stenosis that satisfied the Boston 2006 criteria for emerging hypoplastic left heart syndrome and their postnatal circulatory outcome. BV, biventricular circulation; BV-UV, biventricular-to-univentricular conversion; LV, left ventricular; NND, neonatal death; UV, univentricular circulation.

Cases suitable for inclusion in the study had usual atrial arrangements, concordant atrioventricular and ventriculoarterial connections with stenosed, but still patent, aortic valves. Associated findings of mitral valve hypoplasia, left ventricular fibroelastosis, coarctation and persistent left superior vena cava were accepted. The morphological and physiological data were collected prospectively and measured by the fetal cardiologists of the participating centers, and recorded on a standardized data collection form.

In order to facilitate data acquisition, the core investigators (A.K. and A.O.) offered to visit sites. In practice, most contributors sent completed data sheets to the core investigators, and 35% were visited by one coauthor (A.K.) who retrieved and documented the recorded measurements and added any missing measurements from available clips.

We documented right- and left-sided atrioventricular valve lateral diameters and ventricular sizes, Doppler velocities and waveform patterns through pulmonary veins, the ductus venosus, foramen ovale and both semilunar valves, and information about the aortic and ductal arches. The demographic data of the pregnancies and fetuses, and follow-up data were collated by A.K. and A.O., who also calculated Z-scores of the cardiac measurements based on gestational age⁸.

The analysis of circulatory outcome was confined to cases that underwent (or intended) a postnatal surgical or catheter procedure during the neonatal period. None had multiple congenital abnormalities or abnormal karyotype

and no maternal conditions or multiple pregnancies resulted in exclusion from the analysis. In ongoing pregnancies, Z-scores of aortic and mitral valves and left ventricular inlet length and width, and any change in physiological parameters recorded during the pregnancy at first and last echo were compared. We recorded mitral valve flow profile (biphasic, monophasic or absent), direction of flow in the aortic arch (forward or reversed including bidirectional) and across the atrial septum (right to left, left to right, restrictive or none) and the peak pressure gradient generated across the aortic and mitral valves. These variables were analyzed in relation to survival and circulatory outcome in the 80 liveborn neonates in which postnatal therapy was performed.

The postnatal surgical pathway was considered biventricular (BV) if the first procedure was balloon aortic valvuloplasty or surgical valvotomy, or if a Ross or Ross-Konno procedure was performed. The fetus followed a primary UV circulatory pathway when a primary Norwood or Hybrid procedure was performed and a BV-to-UV conversion if a BV procedure was followed by a Norwood or Hybrid procedure at any age. No children received a transplant and no UV circulation was later converted to BV using left ventricular rehabilitation strategies.

Previously published experience of the natural history of aortic stenosis from Boston in 2006⁶ describes fetuses with aortic stenosis that are likely to develop HLHS during pregnancy. In order to derive the proportion of our natural history cohort expected to progress to HLHS using the

Boston 2006 criteria, we took physiological data from the first fetal echocardiogram before 31 completed gestational weeks and combined this with the left ventricular inlet length (major axis) Z-scores (Figure 2).

We then included peak pressure gradients derived from mitral regurgitation jets and Doppler flow velocities across the aortic valve and applied the Boston 2009 threshold score to those selected previously as likely to develop HLHS according to Boston 2006 criteria. A threshold score of 4 or 5 defined the morphological dimensions and physiology necessary to permit a BV circulatory outcome following technically successful FV, thus defining the 'ideal FV candidate'. A score of 1 was awarded to fetuses for each Z-score meeting the following criteria: left ventricular inlet length and width > 0; mitral valve diameter > -2; aortic valve diameter > -3.5; and pressure gradient across either the mitral or aortic valve > 20 mmHg². This enabled us to determine the proportion of fetuses with emerging HLHS that also fulfilled the criteria for an ideal FV candidate, yet circulation remained BV without fetal therapy.

The Ethics Committee at Imperial College London considered the study audit of practice and no specific ethical approval was required. Data from the postnatal pre-intervention echocardiogram in 71 cases of this natural history cohort have been used and reported previously in a blinded study of postnatal surgical decision-making⁹.

Statistical analysis

Summary statistics of the natural history fetal cohort are presented. Logistic regression was used to assess change in Z-score during pregnancy and its effect on postnatal circulation. The categorical physiological data were dichotomized to code for whether individual parameters changed during pregnancy, and Fisher's exact test was used to compare the effect on postnatal circulation. The Mann-Whitney U-test was used to analyze the continuous variables of gestation and left ventricular morphology by circulatory outcome. Odds ratios (OR) of overall survival (for any circulation) in those meeting the fetal criteria for emerging HLHS compared with those that did not were calculated. The effects of first and final circulation on survival were assessed using Kaplan-Meier survival curves. Statistical significance was determined at $P < 0.05$. Statistical analysis was performed with Stata version 13 (StataCorp, College Station, TX, USA).

RESULTS

Overview

Figure 1 summarizes the outcomes of the 147 fetuses that did not undergo FV from the whole cohort of 214 fetuses enrolled in the multicenter study. The mean \pm SD gestational age at first fetal echocardiogram of these 147 fetuses with adequate data submitted to the

study was 23.5 ± 5 weeks. Termination of pregnancy was performed in 40 (27.2%) pregnancies. Pregnancies ending in termination in the whole cohort of 214 fetuses were not affected more severely than ongoing pregnancies, but were examined at an earlier gestational age (Table S1).

Circulation and survival outcomes in ongoing pregnancies

In the 107 ongoing natural history pregnancies, there were eight spontaneous fetal deaths (7.5%), resulting in 99 liveborn neonates. No postnatal aortic valve interventions were performed in 14 of the 99 liveborns. Four never required intervention on the aortic valve during the study period and were excluded: three with mild aortic valve stenosis after birth and one with a primary lesion of coarctation with moderate aortic stenosis (30 mmHg peak gradient). A further five were lost to follow-up and five received comfort care.

Therefore, there was intention-to-treat in 85 newborns with severe aortic stenosis. None had abnormal chromosomes and one was from a twin pregnancy. However, five died before surgery, including two that were born preterm (at 25 and 30 weeks, with the latter after attempts to open a closed atrial septum), and the circulation could not be determined. Ultimately, 80 neonates underwent postnatal procedures with 44 BV, 29 UV and seven BV-to-UV circulatory outcomes (Figure 1). Thirty-day survival was 81% (69/85) and survival at median 6 years was superior in cases with BV circulation ($P = 0.041$).

Hydrops

Twelve fetuses were hydropic; their age at presentation and pathophysiology are reported in Table S2. Three suffered spontaneous fetal demise and one pregnancy with intact atrial septum was terminated. Of the eight liveborns, six died: one following attempted balloon aortic valvuloplasty, one after Rashkind and Norwood, two had comfort care and two died before any procedure could be performed. Only two cases survived (one was delivered at 33 weeks); both developed restrictive atrial septum, had antegrade fetal arch flow and only required balloon aortic valvuloplasty after birth. At the time of writing, aged 9.1 and 6.6 years, they were alive with BV circulation.

Changes in morphology and physiology during pregnancy in relation to outcome

Table 1 compares fetal left heart Z-scores of 51 liveborns with data available before 30 gestational weeks and who survived for more than 3 months, according to their postnatal circulation. Children with BV circulation had better initial fetal Z-scores than did those with UV circulation, but the only significant variable was mitral valve diameter ($P = 0.004$).

In addition, Tables S3 and S4 show the Z-scores of variables at the first scan with sufficient data for all 80 children receiving treatment, grouped according to circulatory

Table 1 Gestational age and Z-scores of left-sided cardiac morphology in 51 liveborn fetuses with data ≤ 30 gestational weeks that survived for more than 3 months, according to whether they had biventricular (BV) or univentricular (UV) postnatal circulatory outcome

Variable	BV (n=27)	UV (n=24)	P
Gestational age (weeks)	24.0 (18.6 to 30.0)	23.0 (18.0 to 30.0)	0.383
Left heart Z-scores			
Aortic valve diameter	-0.76 (-5.14 to 2.28)	-1.20 (-6.70 to 0.29)	0.076
Mitral valve diameter	-1.06 (-7.77 to 0.87)	-3.90 (-8.70 to 1.39)	0.004
LV inlet length	-0.59 (-4.70 to 2.41)	-1.86 (-4.47 to 4.60)	0.167
LV width	-0.26 (-2.66 to 4.81)	0.64 (-4.94 to 3.76)	0.299

Data are given as median (range). LV, left ventricular.

outcome (Table S3) and according to the time of demise in those dying before 3 months old (Table S4). Logistic regression analysis of the 85 liveborns, treated or with intention-to-treat, demonstrated a four-fold increased risk of dying in cases classified as having evolving HLHS⁶ (OR, 3.98 (95% CI, 1.56–10.14); *P* = 0.0028).

Figure 3 shows the gestational changes in left-sided cardiac morphology for 69 fetuses with at least two examinations, the regression analysis of which is displayed in Table 2. The mean ± SD gestational age at first scan was 24.3 ± 4.2 weeks and at the last scan was 32.9 ± 3.0 weeks. The median Z-scores at first echo were as follows: mitral valve diameter -2.2 (range, -8.7 to

Table 2 Regression analysis demonstrating gestational changes in Z-scores of left-sided cardiac morphology in neonates assigned to a postnatal univentricular circulatory pathway, compared with those with biventricular circulatory outcome as the reference group

Variable	n	Coefficient (95% CI)	SE	P
Aortic valve diameter	48	-0.80 (-2.11 to 0.52)	0.65	0.229
Mitral valve diameter	45	-2.25 (-3.87 to -0.63)	0.80	0.008
LV inlet length	54	-1.79 (-2.99 to -0.59)	0.60	0.004
LV width	57	-1.77 (-2.84 to -0.69)	0.54	0.002

LV, left ventricular; SE, standard error.

4.0); aortic valve width -1.6 (range, -6.7 to 2.3); left ventricular inlet length -1.2 (range, -5.7 to 3.8); and left ventricular width 0.0 (range, -5.0 to 6.5). Those with postnatal UV circulation showed a significant decrease in growth velocity of the mitral valve (*P* = 0.008), left ventricular inlet length (*P* = 0.004) and width (*P* = 0.002), compared with those with postnatal BV circulation. However there was no difference in the growth velocity of Z-scores for aortic valve diameter (*P* = 0.229) between fetuses with different circulatory outcomes (Table 2).

Thirteen fetuses had an alteration in physiology during the second and third trimesters; two showed new left-to-right flow across the foramen ovale, one of which also had new reversal of aortic arch flow, while one fetus showed normalization of foramen flow. Six fetuses showed deterioration of mitral valve flow, three developing atresia and three developing short, monophasic mitral valve inflow, one of which also showed new

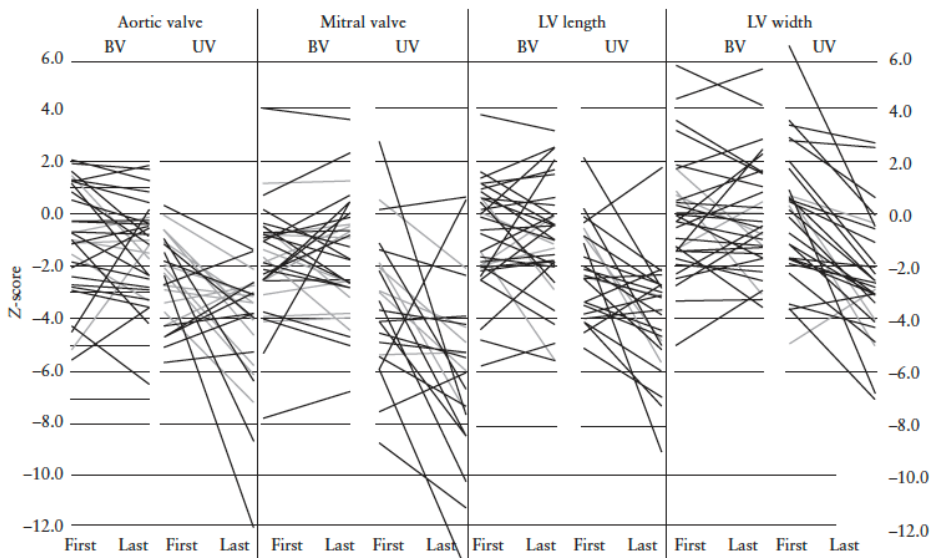


Figure 3 Comparison of Z-scores of aortic and mitral valve diameters and left ventricular (LV) inlet length and width at first-to-last echocardiogram in 69 fetuses with biventricular (BV) or univentricular (UV) postnatal circulation.

Table 3 Boston 2009 threshold scores in 40 fetuses with aortic stenosis that met the Boston 2006 criteria for emerging hypoplastic left heart syndrome, according to their postnatal outcome of biventricular (BV) or univentricular (UV) circulation

Threshold score	All cases (n=40)	BV (n=13)	UV (n=27)
0	4	2	2
1	6	1	5*
2	10	2	8
3	8	3	5*
4	7	1	6†
5	5	4	1

Data are given as n. *Includes one case of BV-to-UV conversion.

†Includes two cases of BV-to-UV conversion.

reversed flow in the transverse aortic arch. A further three fetuses showed new retrograde arch flow and one normalized during pregnancy. Although not statistically significant, 5/6 fetuses whose mitral valve became atretic or monophasic in pregnancy had UV circulation after birth ($P=0.069$), while the development of new retrograde arch flow alone was equally likely to result in a BV ($n=3$) as UV ($n=3$) postnatal circulation ($P=1.00$).

Published selection criteria

Figure 2 shows that 13/40 (33%) fetuses that satisfied the criteria for emerging HLHS⁶ had a BV circulation after birth, nine of which were alive at a median of 6.9 (range, 4.2–8.9) years.

Table 3 shows the proportion of these 40 fetuses with emerging HLHS that would have also been considered ideal candidates for FV using the threshold score². Twelve (30%) of the 40 fetuses had a threshold score of 4 or 5, thus satisfying the criteria for an FV. Five (42%) of these 12 had postnatal BV circulation without fetal intervention.

Postnatal management and survival analysis

Postnatal management was decided by the local teams and 51 neonates were assigned to a BV pathway initially,

seven of which required subsequent conversion to a UV pathway, and 29 followed an initial UV pathway. There were 11 early hospital deaths (13.8% 30-day mortality) after surgery or interventional catheter; seven following Norwood Stage 1 (one after Rashkind); two after aortic valvuloplasty (one was a 31-week premature baby and one had a giant right atrium with bronchial compression after lobectomy). Another died from septicemia at 13 days old after aortic valvuloplasty followed by stenting of the isthmus and duct, and one died at 30 days old following the Ross procedure for severe aortic regurgitation and LV dysfunction. Three of these had an intact atrial septum at delivery. Of all 85 neonates considered for treatment after birth (Figure 1), 16 died in the first 30 days (18.8% mortality). The median follow-up of the remaining 69 was 6 years (range, 46 days to 9.6 years). Survival from birth for those undergoing an initial BV route (balloon aortic valvuloplasty or surgery) was compared with those originally designated to UV using Kaplan–Meier analysis (Figure 4). In this analysis, the seven BV-to-UV conversions were treated as an event, removing them from the BV cohort at the time of conversion (Figure 4a). Hazard analysis showed no significant difference in survival between the groups (73.7% vs 54.5%, $P=0.058$). If these seven cases that changed circulatory designation are not included in the Kaplan–Meier analysis, those with a sustained BV circulation show a small but significant survival advantage over those with UV circulation (76.1% vs 54.5%, $P=0.041$, Figure 4b). The deaths were clustered in the first 2 years, with no further demises to almost 10 years.

Table S5 lists the number and type of interventions undergone by the 80 children who had postnatal treatment. There were a total of 200 catheter and surgical procedures: the 29 neonates that followed an initial UV pathway from birth had 67 procedures, with nine dying after Norwood Stage 1 and three after the Glenn procedure (59% survival). The 44 cases with a sustained BV circulation had a total of 92 procedures

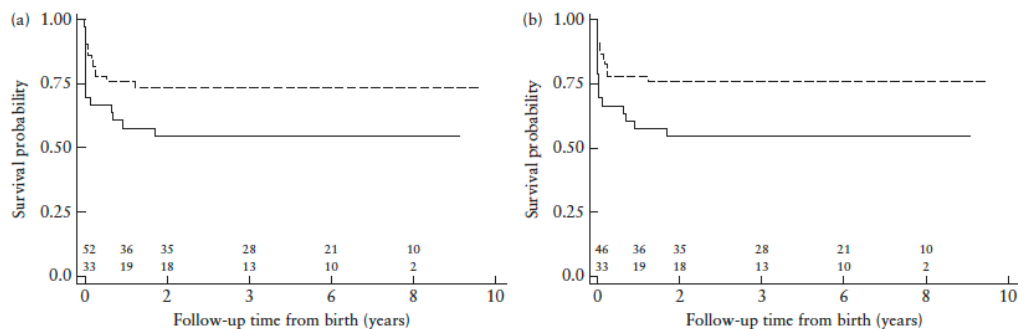


Figure 4 Kaplan–Meier survival curves for 85 liveborns with aortic stenosis and intention-to-treat, assigned to an initial biventricular (BV) circulatory pathway (dashed line) or a univentricular (UV) circulatory pathway (solid line). (a) Fetuses with BV-to-UV conversion are treated as an event and are removed from the BV cohort; $P=0.058$. (b) Fetuses with BV-to-UV conversion are excluded from analysis altogether; $P=0.041$.

and eight deaths occurred (82% survival). Seven children that required conversion from BV to UV pathway had a total of 41 procedures between them and two died (71% survival). They were converted at median age of 27 (8–286) days to a UV circulatory pathway and three had hybrid procedures that accounted for the majority of the interventions. Two infants died (at 2 months and at 1.7 years) following the hybrid pathway, one after 12 procedures, and the remaining five were alive at almost 10 years, with one child having had 10 procedures. The first procedure among the 51 neonates that followed an initial BV pathway was balloon aortic valvuloplasty in 48 and surgical valvotomy in three. Repeat balloon valvuloplasty was required in two cases, and was associated with aortic arch repair in two and arch stenting in one. Nine had a surgical valvotomy, three as their initial procedure. Seven had mitral valve stenting and dilation and another with Shone complex had four surgeries requiring coarctation repair and resection of subaortic membranes as well as supramitral valve surgery. Seven cases overall had Ross procedures, one with subaortic shelf resection and another had homograft replacement, and five underwent the Ross–Konno procedure. Two neonates were reported to have pulmonary hypertension: one with a giant left atrium compressing the bronchi died in the neonatal period after lobectomy and the other was alive at 7.5 years, not requiring medical or long-term oxygen therapy. Function is reported to be good in the surviving cohort with most in New York Heart Association (NYHA) Functional Classification 1.

DISCUSSION

Our study presents the natural history outcomes of 107 fetuses with aortic stenosis documented in the period 2005–2012. This is a large natural history series, particularly as fewer than 10% of neonates with critical aortic stenosis are reported to have had a prenatal diagnosis¹. The strength of this cohort is that it documents outcomes of fetuses with serial fetal morphology and physiology, followed-up to over 9 years (median, 6 years), and thus provides health professionals and parents with information on both the spectrum of the disease and the prognosis in relation to circulatory outcomes.

When we applied the threshold score² to the 40 fetuses characterized as having emerging HLHS, 12 scored ≥ 4 and could be considered as ideal FV candidates, yet a BV outcome was achieved in five of them (42%) without fetal therapy. Moreover 29% (8/28) of the remaining fetuses that would not have been chosen for fetal therapy because of a low threshold score also had a BV outcome. We cannot know if FV would have improved outcome further in this cohort, but the proportion of BV outcomes in those considered to have emerging HLHS⁶ is at least equal to that achieved following FV^{2–4}. We believe our

data imply that the threshold score² may not be specific or sensitive enough in its selection of cases for valvuloplasty when applied to different populations.

Previous natural history studies conclude that retrograde aortic arch flow is an important predictor of evolving HLHS^{6,7}. However, we observed it in one-third of our cohort satisfying the Boston 2006 criteria for emerging HLHS that had a postnatal BV circulation. Retrograde aortic arch flow is described in aortic coarctation with BV outcome¹⁰ and in normal fetal hearts near term¹¹. Therefore we interpreted this physiological parameter cautiously.

Those with a postnatal UV circulation showed a trend towards smaller aortic valve diameters at first scan than did the BV cohort, but aortic valve growth velocities were similar in both cohorts to term. In contrast, the mitral valve diameter was significantly smaller at first scan in those with postnatal UV outcomes and its growth velocity, in common with the left ventricular inlet length and width, were reduced significantly by term in fetuses with UV compared with BV outcome. Our findings are in line with the observations of left heart growth following successful FV, where no real improvement in ventricular growth during pregnancy could be observed, despite successful intervention^{2,3}. We also observed that development of mitral valve atresia or monophasic flow during pregnancy was associated with UV circulation. This is in agreement with the selection criteria for FV in Linz in which longer mitral valve inflow duration (corrected for cardiac cycle) was predictive of postnatal BV circulation³.

Neonatal mortality in aortic stenosis remains high compared with other cardiac lesions in Europe¹². Our natural history cohort was not super-selected as no differences in severity were demonstrated between the ongoing pregnancies and those terminated. Further demises occurred: spontaneous fetal demise of 7.5%, pre-surgical neonatal demise of 6% and a 10% neonatal post-procedural demise. Thus the 30-day survival of a newborn intending postnatal treatment was 69/85 (81%). This is higher than the rate of survival to hospital discharge of 57.5% following FV from the IF CIR multicenter registry⁴. The proportion of early survivors is influenced by disease severity, and between one-half and two-thirds of our neonates receiving postnatal therapy fulfilled the characteristics of evolving HLHS⁶. This increased their risk of dying during the study period four-fold compared with those with better anatomy and physiology at the first fetal scan.

Our natural history data show important similarities with the outcomes of the first 100 FV performed in Boston over a similar time period¹³. Both show similar survival of the BV and HLHS cohorts. Differences in survival become apparent only when cardiac deaths and conversions from UV to BV were included in the Boston analysis, whereas we demonstrated better BV survival when those requiring conversion from BV to UV circulations were not included in the analysis. However the final outcome depends not only on prenatal appearances but also on postnatal decision-making and

team ethos, including the skill to maintain a BV circulation^{9,13–17}. The choice of postnatal circulatory pathway depends on neonatal appearances, functional parameters and local preferences⁹ and our children with aortic stenosis required a median of three episodes of often complex surgery, in line with others, and some had multiple catheter interventions^{3,13–17}. In our cohort, worse outcomes were identified in children undergoing multiple interventional catheter procedures (Table S5). Hybrid procedures reported in the European Congenital Heart Surgeons Association (ECHSA) database have a 38% 30-day mortality with survival to hospital discharge of only 42%¹². This postnatal therapeutic choice may be one reason for poor survival in some registry reports⁴.

One major strength of this study is the multicenter design, which allowed us to collect a relatively large number of cases. However the multicenter retrospective nature comes with several important limitations when compared with the ideal prospective large single-center study. There was a lower degree of uniformity of data collection and although guidance was provided on how to perform all morphological measurements, we were not able to standardize and assess reproducibility of measurements as is possible in a core-lab. Moreover, postnatal management decision-making and surgical performance could not be considered uniform between centers. Other limitations of this study are common to other retrospective studies with incomplete data and inability to answer some questions. For example we do not know the decision-making behind referral for prenatal valvuloplasty or for termination of pregnancy, which lie beyond the scope of this study. The cohort has a small number that were followed-up to 10 years, which reduces the power to make firm conclusions but the event rate after 18 months was low. We might anticipate more events occurring in later adolescence in both cohorts.

In conclusion, our large natural history cohort of children diagnosed with aortic stenosis prenatally and known outcomes shows that a substantial proportion of fetuses that met the criteria for emerging HLHS and were ideal candidates for FV had a sustained BV circulation without fetal intervention. This indicates that further work is needed to refine selection criteria to offer appropriate therapy to fetuses with aortic stenosis.

ACKNOWLEDGMENTS

This study was devised by the Fetal Working Group of the Association for European Paediatric Cardiology (AEPIC). Financial support for site visits by Dr Kovacevic and some statistical assistance was provided by the Fetal Working Group of the AEPIC. Dr Kovacevic was supported by a grant from the Department of Paediatric Cardiology, Heinrich Heine University Duesseldorf, Germany. Drs Mellander and Öhman were supported by the Swedish Heart-Lung Foundation (Grant numbers 20130635, 20100362 and 20090225).

CONTRIBUTORS TO THE STUDY INCLUDING MEMBERS OF THE FETAL WORKING GROUP OF THE AEPIC

Frances Bullock and Suhair Shebani, *Congenital and Paediatric Cardiac Service, Glenfield Hospital, Leicester, UK*;
Sally Ann Clur, *Academic Medical Center, Amsterdam, The Netherlands*;
Ingo Daehnert, *Clinic for Pediatric Cardiology, Heart Centre, University of Leipzig, Leipzig, Germany*;
Giovanni Di Salvo, *Department of Pediatric Cardiology, Second University of Naples, Monaldi Hospital, Naples, Italy*;
Ruth Heying and Marc Gewillig, *Department of Congenital and Pediatric Cardiology, University Hospital Gasthuisberg, Leuven, Belgium*;
Els Grijseels and Laurens Koopmann, *Departments of Prenatal Medicine and Pediatric Cardiology, Erasmus MC/Sophia Children's Hospital Rotterdam, Rotterdam, The Netherlands*;
Kaarin Makikallio, Aydin Tekay and Markku Leskinen, *Departments of Obstetrics and Gynaecology and Pediatrics, Oulu University Hospital, Oulu, Finland*;
Nicky Manning and Nick Archer, *Paediatric and Fetal Cardiology Service, John Radcliffe Hospital, Oxford, UK*;
Renate Oberhoffer, *The German Heart Centre, Munich, Germany*;
Cristina Romeo, *Department of Cardiology, Azienda Ospedaliera Bolzano, Bolzano, Italy*;
Keld Ejvind Sørensen, *Skejby University Hospital, Aarhus, Denmark*;
Trevor Richens, *Department of Cardiology, Royal Hospital for Sick Children, Yorkhill Division, Glasgow, Scotland, UK*;
Klaus Schmidt, *Department of Paediatric Cardiology, Heinrich Heine University Duesseldorf, Duesseldorf, Germany*;
Anna Seale and Victoria Jowett, *Queen Charlotte's Hospital and Department of Paediatric and Congenital Cardiology, Royal Brompton and Harefield Hospital, NHS Trust London, London, UK*;
Cecile Tissot, *Pediatric Cardiology Unit, The Children's University Hospital of Geneva, Geneva, Switzerland*;
Viktor Tomek, *University Motol Hospital, Prague, Czech Republic*;
Frank Uhlemann, *Department of Pediatric Cardiology and Pediatric Intensive Care, Olgahospital, Stuttgart, Germany*;
Niels Vejlstrop, *Department of Cardiology, Rigshospitalet, Copenhagen, Denmark*;
Jochen Weil, *Clinic for Paediatric Cardiology, University Heart Centre Hamburg, Hamburg, Germany*.


REFERENCES

1. Freud LR, Moon-Grady A, Escobar-Diaz MC, Gotteiner NL, Young LT, McElhinney DB, Tworetzky W. Low rate of prenatal diagnosis among neonates with critical aortic stenosis: insight into the natural history in utero. *Ultrasound Obstet Gynecol* 2014; 45: 326–332.
2. McElhinney DB, Marshall AC, Wilkins-Haug LE, Brown DW, Benson CB, Silva V, Marx GR, Mizrahi-Arnaud A, Lock JE, Tworetzky W. Predictors of technical

- success and postnatal biventricular outcome after in utero aortic valvuloplasty for aortic stenosis with evolving hypoplastic left heart syndrome. *Circulation* 2009; 120: 1482–1490.
3. Arzt W, Wertaschnigg D, Veit I, Klement F, Gitter R, Tulzer G. Intrauterine aortic valvuloplasty in fetuses with critical aortic stenosis: experience and results of 24 procedures. *Ultrasound Obstet Gynecol* 2011; 37: 689–695.
 4. Moon-Grady AJ, Morris SA, Belfort M, Chmait R, Dangel J, Devlieger R, Emery S, Frommelt M, Galindo A, Gelehrter S, Gembruch U, Grinenco S, Habli M, Herberg U, Jaeggi E, Kilby M, Kontopoulos E, Marantz P, Miller O, Otaño L, Pedra C, Pedra S, Pruetz J, Quintero R, Ryan G, Sharland G, Simpson J, Vlastos E, Tworetzky W, Wilkins-Haug L, Oepkes D. International Fetal Cardiac Intervention Registry: A worldwide collaborative description and preliminary outcomes. *J Am Coll Cardiol* 2015; 66: 388–399.
 5. Simpson JM, Sharland GK. Natural history and outcome of aortic stenosis diagnosed prenatally. *Heart* 1997; 77: 205–210.
 6. Mäkilä K, McElhinney DB, Levine JC, Marx GR, Colan SD, Marshall AC, Lock JE, Marcus EN, Tworetzky W. Fetal aortic valve stenosis and the evolution of hypoplastic left heart syndrome: patient selection for fetal intervention. *Circulation* 2006; 113: 1401–1405.
 7. Hunter LE, Chubb H, Miller O, Sharland G, Simpson JM. Fetal aortic valve stenosis: a critique of case selection criteria for fetal intervention. *Prenat Diagn* 2015; 35: 1176–1181.
 8. Schneider C, McCrindle BW, Carvalho JS, Hornberger LK, McCarthy KP, Daubeney PE. Development of Z-scores for fetal cardiac dimensions from echocardiography. *Ultrasound Obstet Gynecol* 2005; 26: 599–605.
 9. Kovacic A, Roughton M, Mellander M, Ohman A, Tulzer G, Dangel J, Magee AG, Mair R, Ghez O, Schmidt KG, Gardiner HM. Fetal aortic valvuloplasty: investigating institutional bias in surgical decision-making. *Ultrasound Obstet Gynecol* 2014; 44: 538–544.
 10. Yamamoto Y, Khoo NS, Brooks PA, Savard W, Hirose A, Hornberger LK. Severe left heart obstruction with retrograde arch flow influences fetal cerebral and placental blood flow. *Ultrasound Obstet Gynecol* 2013; 42: 294–299.
 11. Chabaneix J, Fouron JC, Sosa-Olavarria A, Gendron R, Dahdah N, Berger A, Brisebois S. Profiling left and right ventricular proportional output during fetal life with a novel systolic index in the aortic isthmus. *Ultrasound Obstet Gynecol* 2014; 44: 176–181.
 12. European Congenital Heart Surgeons Association (ECHSA) Congenital Database. http://www.echsacongenitaldb.org/mvp_report/ [Accessed 8 December 2015].
 13. Freud LR, McElhinney DB, Marshall AC, Marx GR, Friedman KG, del Nido PJ, Emani SM, Lafranchi T, Silva V, Wilkins-Haug LE, Benson CB, Lock JE, Tworetzky W. Fetal aortic valvuloplasty for evolving hypoplastic left heart syndrome: postnatal outcomes of the first 100 patients. *Circulation* 2014; 130: 638–645.
 14. Colan SD, McElhinney DB, Crawford EC, Keane JF, Lock JE. Validation and re-evaluation of a discriminant model predicting anatomic suitability for biventricular repair in neonates with aortic stenosis. *J Am Coll Cardiol* 2006; 47: 1858–1865.
 15. Hickey EJ, Caldarone CA, Blackstone EH, Lofland GK, Yeh T Jr, Pizarro C, Tchervenkov CI, Pigula F, Overman DM, Jacobs ML, McCrindle BW; Congenital Heart Surgeons' Society. Critical left ventricular outflow tract obstruction: The disproportionate impact of biventricular repair in borderline cases. *J Thorac Cardiovasc Surg* 2007; 134: 1429–1436; discussion 1436–1437.
 16. Emani SM, Racha EA, McElhinney DB, Marx GR, Tworetzky W, Pigula FA, del Nido PJ. Primary left ventricular rehabilitation is effective in maintaining two-ventricle physiology in the borderline left heart. *J Thorac Cardiovasc Surg* 2009; 138: 1276–1282.
 17. Perez-Negueruela C, Mayol J, Prada F, Caffarena-Calvar JM. Neonatal Ross-Konno operation and endocardial fibroelastosis resection after foetal percutaneous aortic valve balloon valvuloplasty: a complex approach to rescue the left heart. *Eur J Cardiothorac Surg* 2014; 46: 498–499.

SUPPORTING INFORMATION ON THE INTERNET

The following supporting information may be found in the online version of this article:

-  **Table S1** Continuous fetal variables measured at first scan for entire study population (including fetal demises) separated into termination of pregnancy (TOP) and ongoing pregnancies, whether or not there was subsequent fetal demise
- Table S2** Details of age at first examination, pathophysiology and left ventricular and aortic valve size and outcomes in the 12 hydropic fetuses
- Table S3** Comparison of Z-scores of variables at first scan by outcome for all 80 liveborn fetuses with known outcome
- Table S4** Comparison of Z-scores of variables at first scan by outcome for all 80 liveborn fetuses with known outcome that died early. This combines all circulatory pathways
- Table S5** Type of procedures, frequency and survival for each circulatory pathway in the 80 neonates undergoing postnatal therapy

3.0.2 ANNEX 7

Kovacevic A, Ohman A, Tulzer G, Herberg U, Dangel J, Carvalho J S, Fesslova V, **Jicinska H**, Sarkola T, Pedroza C, Averiss I E, Mellander M, Gardiner H, the Fetal Working Group of the AEPC

Fetal hemodynamic response to aortic valvuloplasty and postnatal outcome: a European multicenter study

Ultrasound in Obstetrics and Gynecology; 2018; 52:221-229

Impact factor in 2018 = 5.654

Main points of the publication:

Fetal aortic stenosis may progress to hypoplastic left heart syndrome. Fetal valvuloplasty (FV) has been proposed to improve left heart hemodynamics and maintain biventricular (BV) circulation. The aim of this study was to assess FV efficacy by comparing survival and postnatal circulation between fetuses that underwent FV and those that did not.

Similar proportions of fetuses had BV circulation (36% for the FV cohort and 38% for the NH cohort). Successful FV cases showed improved hemodynamic response and less deterioration of left heart growth compared with natural history (NH) cases ($P \leq 0.01$).

FV survivors showed improved survival. However, FV is associated with a 10% procedure-related loss and therefore the risk-to-benefit ratio remains uncertain.

The candidate contributed to the manuscript and with cases to this international study.



Fetal hemodynamic response to aortic valvuloplasty and postnatal outcome: a European multicenter study

A. KOVACEVIC¹, A. ÖHMAN², G. TULZER³, U. HERBERG⁴, J. DANGEL⁵,
J. S. CARVALHO⁶, V. FESSLOVA⁷, H. JICINSKA⁸, T. SARKOLA⁹, C. PEDROZA¹⁰,
I. E. AVERISS¹¹, M. MELLANDER² and H. M. GARDINER¹¹

¹Royal Brompton NHS Foundation Trust, London, UK; and Department of General Paediatrics, Neonatology and Paediatric Cardiology, Heinrich Heine University Duesseldorf, Duesseldorf, Germany; ²Department of Paediatric Cardiology, Queen Silvia Children's Hospital, Sahlgrenska University Hospital, Gothenburg, Sweden; ³Department of Paediatric Cardiology, Children's Heart Center Linz, Kepler University Hospital, Linz, Austria; ⁴Department of Paediatric Cardiology, University Hospital Bonn, Bonn, Germany; ⁵Perinatal Cardiology Department, The Center of Postgraduate Medical Education, Warsaw, Poland; ⁶Brompton Centre for Fetal Cardiology, Royal Brompton NHS Foundation Trust, London, UK; and Fetal Medicine Unit, St George's University Hospital NHS Trust and Molecular & Clinical Sciences Research Institute, St George's University of London, London, UK; ⁷Center of Fetal Cardiology, Policlinico San Donato IRCSS, Milan, Italy; ⁸University Hospital Brno, Faculty of Medicine, Masaryk University Brno, Czech Republic; ⁹University of Helsinki and Helsinki University Central Hospital/Children's Hospital, Helsinki, Finland; ¹⁰Center for Clinical Research and Evidence-Based Medicine, McGovern Medical School at University of Texas Health Sciences Center at Houston, Houston, TX, USA; ¹¹The Fetal Center, McGovern Medical School at University of Texas Health Sciences Center at Houston, Houston, TX, USA

KEYWORDS: aortic stenosis; fetal therapy; fetus; Norwood procedure

ABSTRACT

Objective Fetal aortic stenosis may progress to hypoplastic left heart syndrome. Fetal valvuloplasty (FV) has been proposed to improve left heart hemodynamics and maintain biventricular (BV) circulation. The aim of this study was to assess FV efficacy by comparing survival and postnatal circulation between fetuses that underwent FV and those that did not.

Methods This was a retrospective multicenter study of fetuses with aortic stenosis that underwent FV between 2005 and 2012, compared with contemporaneously enrolled natural history (NH) cases sharing similar characteristics at presentation but not undergoing FV. Main outcome measures were overall survival, BV-circulation survival and survival after birth. Secondary outcomes were hemodynamic change and left heart growth. A propensity score model was created including 54/67 FV and 60/147 NH fetuses. Analyses were performed using logistic, Cox or linear regression models with inverse probability of treatment weighting (IPTW) restricted to fetuses with a propensity score of 0.14–0.9, to create a final cohort for analysis of 42 FV and 29 NH cases.

Results FV was technically successful in 59/67 fetuses at a median age of 26 (21–34) weeks. There were 7/72

(10%) procedure-related losses, and 22/53 (42%) FV babies were delivered at < 37 weeks. IPTW demonstrated improved survival of liveborn infants following FV (hazard ratio, 0.38; 95% CI, 0.23–0.64; $P = 0.0001$), after adjusting for circulation and postnatal surgical center. Similar proportions had BV circulation (36% for the FV cohort and 38% for the NH cohort) and survival was similar between final circulations. Successful FV cases showed improved hemodynamic response and less deterioration of left heart growth compared with NH cases ($P \leq 0.01$).

Conclusions We report improvements in fetal hemodynamics and preservation of left heart growth following successful FV compared with NH. While the proportion of those achieving a BV circulation outcome was similar in both cohorts, FV survivors showed improved survival independent of final circulation to 10 years' follow-up. However, FV is associated with a 10% procedure-related loss and increased prematurity compared with the NH cohort, and therefore the risk-to-benefit ratio remains uncertain. We recommend a carefully designed trial incorporating appropriate and integrated fetal and postnatal management strategies to account for center-specific practices, so that the benefits achieved by fetal therapy vs surgical strategy can be demonstrated clearly. Copyright © 2017 ISUOG. Published by John Wiley & Sons Ltd.

Correspondence to: Prof. H. M. Gardiner, 6410 Fannin, Suite 700, Houston, TX 77030, USA (e-mail: helena.m.gardiner@uth.tmc.edu)

Accepted: 8 September 2017

INTRODUCTION

A proportion of fetuses with aortic valve stenosis (AoS) will develop hypoplastic left heart syndrome before birth, requiring postnatal univentricular (UV) palliation^{1–3}. Fetal aortic valvuloplasty (FV) has been developed for the treatment of AoS during the past 15 years, with the intention of improving fetal left heart hemodynamics and promoting growth to achieve biventricular (BV) circulation.

Single-center studies have reported BV circulation outcome in one-third to two-thirds of fetuses with AoS undergoing FV^{4,5}, and an international anonymized registry reported 43% of such cases as having BV circulation compared with 20% of those untreated⁶. In our previous study on the natural history (NH) of 147 fetuses with AoS, 33% of those fulfilling hypothetical FV selection criteria had BV circulation².

The Fetal Working Group of the Association for European Paediatric and Congenital Cardiology established a retrospective European study to assess the benefits of FV.

In the current study, we present survival and circulation following FV and, uniquely, compare these with contemporaneously enrolled NH cases sharing similar characteristics at presentation but not undergoing FV.

METHODS

Six centers performing FV in Europe submitted their outcome data on fetal AoS and on their NH cases collected contemporaneously from January 2005 to May 2012, with follow-up until April 2017. A further 17 fetal centers in 13 countries submitted NH data over the same time period and the live-born children were treated at one of 16 postnatal centers. Inclusion criteria were usual atrial arrangement, concordant atrioventricular and ventriculoarterial connections, and stenosed, but still patent, aortic valve. No fetuses with non-cardiac congenital malformations were enrolled. No maternal conditions or multiple pregnancies were excluded.

NH data reported here were published recently² and pre-intervention echocardiograms from 109 neonates were reported in a blinded study of surgical decision making⁷.

The Ethics Committee at Imperial College London considered the study as audit of practice and no ethical approval was required.

Morphological and physiological data were entered into a standardized form by fetal cardiologists in participating centers, as described previously². A.K. added missing measurements from available clips. Data included right- and left-sided valve and ventricular dimensions, and cardiac Doppler, including aortic and mitral valve pressure drop. Doppler waveforms of systemic and pulmonary veins, the ductus venosus, across the foramen ovale and the aortic and ductal arches were assessed, and fetuses with bidirectional or retrograde flow along most of the transverse aortic arch were classified as having retrograde flow. Demographic data, technical

procedures and follow-up data were collated by A.K. and A.O., who calculated gestational age Z-scores for cardiac dimensions⁸.

All analyzed FV fetuses had AoS as the major lesion, defined as stenotic, but patent, aortic valves with qualitatively depressed left ventricular function, and all but one had retrograde arch flow. Primary outcome measures were survival and circulation. Secondary outcome measures were changes in fetal hemodynamics and left heart growth.

All centers performed FV percutaneously under ultrasound guidance using needles of 15–20 cm in length and 18–16 gauge, and coronary artery balloons of 2.0–4.0 mm in diameter with balloon to aortic valve ratio of 0.7–1.3. Technically successful FV (successful FV) was defined as balloon inflation resulting in increased flow when a balloon is placed across the aortic valve, with or without new regurgitation^{4,5}. Procedure-related events were defined as demise, or delivery resulting in death within 24 h of FV. Appendix S1 provides further procedural and technical details and Table S1 includes outcomes for FV cases in chronological order, according to FV center with outcomes reported up to April 2017.

Propensity score

Propensity score was used to assess the likelihood of a fetus with AoS receiving FV, enabling retrospective pseudorandomization of enrolled cases in a two-stage process. First, propensity score was derived from clinically important variables. Eligible FV cases included successful FV, unsuccessful FV and FV-related demise. All liveborn cases were required to have had postnatal intervention for AoS and known outcome with adequate data. We excluded spontaneous intrauterine fetal demise (sIUFD) and termination of pregnancy. Propensity score selected 54/67 FV (43 successful FVs, five unsuccessful FVs and six FV-related demises) and 60/80 NH cases. Second, propensity score cases were weighted and restricted to those with a propensity score within designated limits (0.14–0.9) to provide comparative cohorts⁹ using inverse probability of treatment weighting (IPTW) analyses. The final (IPTW) cohort for analysis was 42 FV and 29 NH⁹.

We tracked physiological changes and growth from first or immediate pre-FV echocardiograms to delivery. Hemodynamic changes of Doppler profiles through the foramen ovale, mitral valve and aortic arch were documented. Table S2 describes the relative weighting assigned to each Doppler flow based on clinical consensus of the authors. This enabled a comparison of hemodynamic changes during pregnancy; these, as well as changes in left heart Z-scores, were compared between three propensity score cohorts: successful FV, unsuccessful FV and NH.

The postnatal surgical pathway was considered UV if the first surgery was a Norwood or hybrid procedure and it was considered BV if the first surgery was aortic valvuloplasty (balloon or surgical) or a Ross/Ross–Konno procedure. BV–UV conversion was initial BV circulation intent followed by subsequent UV surgery (Norwood or

hybrid), independent of its timing. There were no UV–BV circulation conversions. Survival was compared for final BV and UV pathways.

Data analysis

Frequencies and descriptive statistics were used to summarize baseline characteristics for each cohort. We developed a propensity score for IPTW analyses to compute the average treatment effect of FV (whether FV was successful or not), accounting for potential confounding by observed baseline characteristics. Logistic model predictors used to calculate the propensity score included: gestational age at first scan; restrictive foramen ovale; aortic arch and foramen ovale flow directions; aortic and mitral valve diameter Z-scores; mitral valve inflow Doppler pattern; left ventricular inlet length Z-score; left–right ventricular inlet-length ratio; hydrops; and large-center effect for fetal and postnatal treatment. A large center was defined as one contributing to the study data on 10 or more of both FV and postnatal procedures. The aortic valve pressure gradient at presentation was left out of the propensity score model since it did not improve the balance of baseline covariates.

Weights were calculated as the inverse of the propensity score. To obtain acceptable balance in baseline covariates, we restricted all IPTW analyses to observations with a propensity score of 0.14–0.90⁹.

Overall survival and BV circulation survival (from fetal therapy to successful surgery) were compared between the FV and NH cohorts, using an IPTW logistic regression model with cohort as a covariate. Estimated odds ratios (ORs) and 95% CI are reported. Secondary analyses

were performed, adjusted for a subset of six covariates: gestational age at first scan; mitral valve inflow Doppler; mitral and aortic valve Z-scores; left–right ventricular inlet-length ratio; and hydrops.

Liveborn survival was compared between the FV and NH cohorts using Kaplan–Meier survival curves and Cox regression with IPTW, adjusting for circulatory type and clustering of postnatal surgical center. Similarly, we compared survival in four groups for final circulation, including only successful FV: FV–BV, FV–UV, NH–BV and NH–UV.

Differences between the pre-FV and last fetal echocardiograms in left heart growth and hemodynamics were compared among successful FV, unsuccessful FV and NH cohorts using linear regression with IPTW. Statistical significance was defined as $P < 0.05$. All analyses were conducted in Stata 14.2 (Stata Corp, College Station, TX, USA).

RESULTS

Entire FV cohort

Sixty-seven fetuses undergoing FV were reported from six centers. Median gestational age at referral for FV was 25 (range, 15–33) weeks, and the procedure was performed at median gestational age of 26 (21–34) weeks. There were 72 procedures performed: three had repeat FV, one was unsuccessful on both occasions and one repeat FV had been thought successful initially, 1 month previously. Interatrial-septum ballooning/stenting was performed in two cases after FV (repeated in one). Figure 1 shows outcomes for the entire FV cohort and Table S1 shows

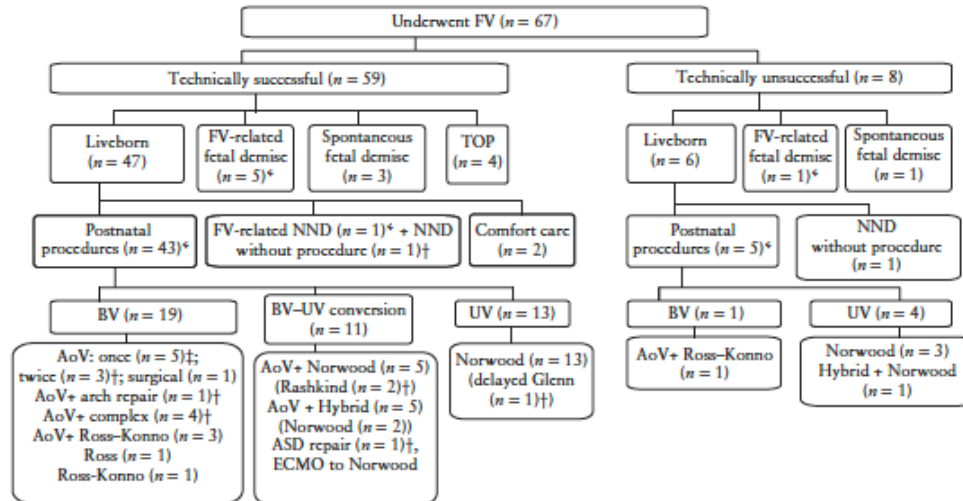


Figure 1 Outcomes of fetuses with aortic stenosis that underwent fetal valvuloplasty (FV). *Data used in propensity score. †Pulmonary hypertension ($n = 1$). ‡Pulmonary hypertension ($n = 2$). AoV, aortic valvuloplasty or surgical valvotomy; ASD, atrial septal defect; BV, biventricular circulation; ECMO, extracorporeal membrane oxygenation; Hybrid, hybrid procedure; NND, neonatal death; Norwood, Norwood procedure; Rashkind, Rashkind procedure; Ross, Ross procedure; Ross–Konno, Ross–Konno procedure; TOP, termination of pregnancy; UV, univentricular circulation.

Table 1 Details and outcomes of fetuses that presented with hydrops at or after first fetal echocardiogram and underwent technically successful fetal valvuloplasty (FV) for aortic valve stenosis, according to whether their hydrops resolved

GA at FV (weeks)	GA at birth (weeks)	Circulatory outcome	Follow-up age (years)
Presented at first echocardiogram, resolved (n = 9)			
23	41.4	CC	
21	36.4	UV dead	0.003
22	39.0	UV alive	3.7
26 ^c	40.0 ^c	UV alive ^c	6.5 ^c
25	34.7	BV alive	10.1
26	39.1	BV alive	5.7
27	32.9	BV alive	6.7
28	34.4	BV alive	11.5
33	36.9	BV alive	11.4
Developed after first echocardiogram, not resolved (n = 7)			
21	—	sIUID	
23	—	sIUID	
25	—	TOP	
26, 30	—	CC	
30 ^c	40.0 ^c	UV alive ^c	6.7 ^c
24	40.0	BV alive	4.9
30 ^c	33.6 ^c	BV alive ^c	7.5 ^c
Presented at first echocardiogram, not resolved (n = 8)			
28	—	sIUID	
29	—	sIUID	
25	25.0	FV-NND	0.003
27	39.0	NND (presurgery)	0.027
26, 27	36.6	BV-UV dead	0.014
24 ^c	37.1 ^c	BV dead ^c	0.125 ^c
31 ^c	39.0 ^c	BV dead ^c	0.25 ^c
30 ^c	36.0 ^c	BV-UV alive ^c	5.5 ^c

^cCase included in inverse probability of treatment weighting cohort. BV, biventricular circulation; BV-UV, biventricular to univentricular conversion; CC, comfort care; FV-NND, neonatal death related to FV; GA, gestational age; NND, neonatal death; sIUID, spontaneous intrauterine death; TOP, termination of pregnancy; UV, univentricular circulation.

outcome data reported up to April 2017 in chronological order of procedure.

FV-related death occurred in 7/72 (10%) procedures, including six considered successful FV. Rare adverse events included left ventricular thrombus formation and balloon rupture. One serious maternal complication (placental abruption) resulted in delivery at 25 weeks' gestation. Fifty-nine fetuses had successful FV and 19/43 (44%) treated neonates had BV circulation.

Eight fetuses had unsuccessful FV (1/8 developed intact atrial septum resulting in fetal demise), of which 4/5 survivors were UV, and 1/5 with retrograde arch flow and monophasic mitral valve inflow had BV circulation and was alive at age 5.7 years (at the time of writing) without pulmonary hypertension.

Hydrops was present in 24/59 successful FV cases and resolved in 9/24 affected fetuses. The course and outcomes are presented in Table 1. One additional case presented with hydrops that did not resolve after unsuccessful FV at 21 gestational weeks and resulted in sIUID.

Sustained hemodynamic improvement was documented in 29/43 (67%) successful FV cases undergoing postnatal procedures, with temporary improvement in another five (12%). One fetus with BV outcome improved initially, but subsequently developed an intact atrial septum and hydrops. Four with UV outcome showed no hemodynamic improvement, or deteriorated following FV; one had inadequate follow-up data to evaluate change. Seven out of eleven (64%) fetuses with subsequent BV-UV conversions showed sustained hemodynamic improvement after FV and two showed temporary improvement. Following unsuccessful FV, the five liveborns demonstrated no fetal hemodynamic improvement and only one achieved BV circulation.

Median gestational age at delivery in the FV cohort was 38.0 (range, 25.0–41.4) weeks, but 22/53 (42%) were delivered before 37 + 0 weeks, compared with 22/85

Table 2 Baseline characteristics at first scan of fetuses that underwent fetal valvuloplasty (FV) for aortic stenosis and those that did not (natural history (NH) group), used to derive propensity score model and inverse probability of treatment weighting cohort

Characteristic	Whole cohort (with sufficient data)			Inverse probability of treatment weighting cohort		
	FV (n = 55)	NH (n = 80)	Standardized difference	FV ^c (n = 42)	NH ^c (n = 29)	Standardized difference
Gestational age at scan (weeks)	25.7 ± 3.7	25.4 ± 4.7	0.08	25.7 ± 3.7	25.5 ± 4.8	0.06
Aortic valve diameter Z-score	-1.3 ± 1.34	-1.62 ± 2.15	0.17	-1.64 ± 1.32	-1.51 ± 2.07	-0.08
Mitral valve diameter Z-score	-0.97 ± 1.96	-2.21 ± 2.43	0.54	-1.85 ± 1.99	-2.00 ± 1.93	0.08
LV:RV length ratio	1.03 ± 0.23	0.97 ± 0.22	0.26	0.99 ± 0.23	0.99 ± 0.20	0.01
FO right-to-left flow	1/54 (2)	26/72 (36)	-0.97	1 (4)	1 (4)	-0.01
AoA retrograde flow	54/55 (98)	42/80 (53)	1.25	34 (97)	35 (98)	-0.08
Mitral valve biphasic flow	17/55 (31)	39/68 (57)	-0.55	7 (20)	7 (19)	0.02
Hydrops	12/55 (22)	3/80 (4)	0.56	2 (7)	1 (4)	0.14
LV inlet length Z-score	-0.47 ± 1.55	-1.04 ± 2.03	0.30	-0.80 ± 1.74	-0.69 ± 1.88	-0.06
Large center†				15 (44)	14 (38)	0.11
AoVPG (mmHg)‡				16.2 ± 14.3	15.0 ± 11.8	0.09

Data are presented as mean ± SD, n/N (%) or n (%). ^cNumbers weighted by inverse probability. †Number of cases presenting for FV and/or postnatal surgery at one or more large center. ‡Not included in propensity score model. AoA, aortic arch; AoVPG, aortic valve pressure gradient; FO, foramen ovale; LV, left ventricle; RV, right ventricle.

(26%) of the NH cohort². Outcomes following premature delivery were similar in both cohorts, with two-thirds surviving (70% of which had BV circulation). Birth weight was <10th centile in 11 in each cohort, but all but one of these delivered at term. The children underwent a median of three (range, 1–12) procedures. Six neonates had persistent pulmonary hypertension (one died from multiorgan failure before the procedure and five had BV procedures with one surviving to 3 years). Three children had late-onset pulmonary hypertension, in one case after a Norwood procedure, delaying the Glenn procedure, but the Fontan procedure was completed and the child was alive at age 5 years (at the time of writing), treated with sildenafil. The two others were BV–UV conversions (one early and one aged 18 months); both died. Seven of these nine were included in the weighted analysis.

Table 3 Final postnatal circulation for liveborn fetuses with aortic stenosis included in inverse probability of treatment weighted cohort, in those that underwent fetal valvuloplasty (FV) and those that did not (natural history (NH) group)

Final circulation	FV	NH	Total
BV	13 (36.1)	11 (37.9)	24
BV–UV conversion	10 (27.8)	4 (13.8)	14
UV	13 (36.1)	14 (48.3)	27
Total	36	29	65

Data are given as n (%) or n. BV, biventricular; UV, univentricular.

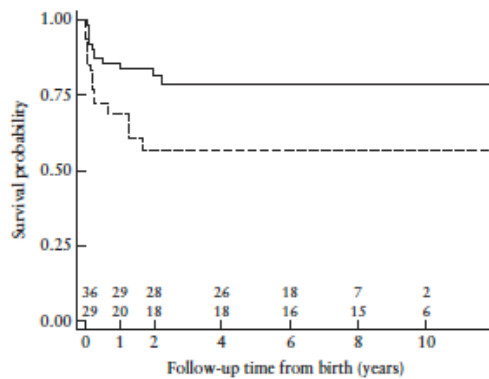


Figure 2 Kaplan–Meier curves comparing survival of fetuses with aortic stenosis included in inverse probability of treatment weighting (IPTW) cohort, in those that underwent fetal valvuloplasty (FV; —) and those that did not (---). FV group includes both technically successful and unsuccessful FV cases on intention-to-treat basis. Six procedure-related fetal deaths were removed to create survival analyses of live births. Actual number of included individuals at each time period is documented below curves (although weighted values were used in analysis and curves). Time zero represents birth. IPTW Cox-regression analysis, adjusting for clustering due to surgical center, showed FV conferred survival advantage after birth (hazard ratio, 0.38; 95% CI, 0.23–0.64; $P = 0.0001$), even after adjusting for circulation and postnatal treatment center.

Propensity score modeling and IPTW analysis

Table 2 compares the baseline characteristics of the first scan used to derive the propensity score model and IPTW cohort used in the weighted analyses, resulting in between-group balance on baseline characteristics with standardized differences of 0.14 or less. The postnatal circulatory outcomes for the liveborn weighted cohorts were similar (36% and 38%) (Table 3).

Survival and circulatory outcomes

Overall survival was similar in FV and NH cohorts (OR, 1.57; 95% CI, 0.72–3.41; $P = 0.25$), as was BV circulation survival (OR, 1.31; 95% CI, 0.23–7.48; $P = 0.76$). Secondary analyses adjusting for additional covariates gave similar results (not shown).

The six procedure-related fetal deaths were removed to create survival analyses of livebirths. The age at which the first postnatal procedure was performed was similar in both cohorts; median age was 6 (range, 1–56) days for FV and 4 (range, 1–74) days for NH. IPTW Cox-regression analysis, adjusting for clustering due to surgical center, showed that FV conferred postnatal survival advantage after adjusting for circulation (hazard ratio (HR), 0.38; 95% CI, 0.23–0.64; $P = 0.0001$; Figure 2). The final circulations were compared for each cohort (after removing unsuccessful FV cases) and survival over 10 years’ follow-up was similar (HR, 0.54; 95% CI, 0.14–2.08; $P = 0.37$; Figure 3). Pairwise comparisons of the marginal linear predictions are included in Table S3.

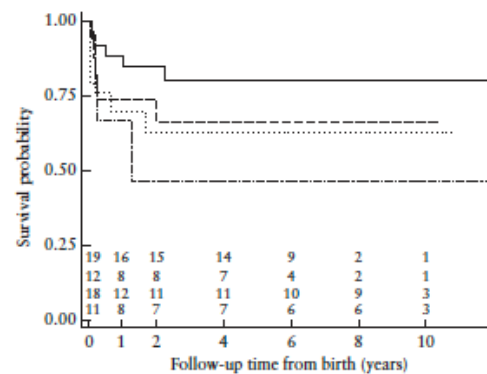


Figure 3 Kaplan–Meier curves comparing survival of fetuses with aortic stenosis included in inverse probability of treatment weighting (IPTW) cohort, in those that underwent fetal valvuloplasty (FV) and those that did not (NH), according to final circulation (univentricular (UV) or biventricular (BV)): FV-UV (—); FV-BV (---); NH-UV (.....); NH-BV (— · —). FV group comprises only technically successful FV cases. Actual number of individuals included at each time period is documented below curves. Time zero represents birth. IPTW Cox-regression analysis, adjusting for clustering due to surgical center, showed no difference in survival between postnatal circulations in FV cohort (hazard ratio, 0.54; 95% CI, 0.14–2.08; $P = 0.37$), after adjusting for postnatal treatment center.

Table 4 Change in fetal hemodynamics and left heart growth from first to last fetal echocardiogram in fetuses included in inverse probability of treatment weighting (IPTW) cohort that underwent fetal valvuloplasty (FV) and those that did not (natural history group)

Parameter	FV technically successful				FV technically unsuccessful				Natural history					
	n	First	Last	Δ	n	First	Last	Δ	n	First	Last	Δ	p*	
Aortic valve diameter Z-score	32	-1.29 ± 1.17	-1.5 ± 1.55	-0.21 ± 1.53	6	-1.78 ± 1.75	-3.04 ± 1.02	-1.26 ± 1.68	0.09	19	-2.38 ± 2.22	-3.12 ± 2.40	-0.74 ± 3.06	0.01
Mitral valve diameter Z-score	32	-1.25 ± 1.91	-1.24 ± 1.55	0.01 ± 1.98	5	-2.07 ± 1.16	-3.42 ± 1.46	-1.35 ± 1.18	0.04	17	-2.48 ± 1.60	-3.41 ± 2.37	-0.93 ± 2.78	0.02
LV inlet length Z-score	31	-0.46 ± 1.67	-1.14 ± 1.97	-0.69 ± 1.33	6	-1.63 ± 1.35	-2.3 ± 2.01	-0.67 ± 1.05	0.83	20	-1.21 ± 1.73	-3.21 ± 2.63	-2.01 ± 2.38	0.002
LV-EDD Z-score	31	0.96 ± 1.92	0.36 ± 2.23	-0.61 ± 2.01	5	-0.86 ± 1.23	-0.34 ± 1.34	0.52 ± 1.22	0.11	19	0.34 ± 1.70	-1.64 ± 2.74	-1.99 ± 2.64	0.006
Hemodynamics weighted score	26	14.15 ± 2.92	11.15 ± 4.88	3.00 ± 4.72	6	16.67 ± 2.04	16.25 ± 1.37	0.42 ± 1.02	0.04	16	14.03 ± 3.44	12.72 ± 4.32	1.31 ± 2.73	0.09
Composite hemodynamic score		15 (12.5–15)	10.25 (9.5–15)	2.75 (0–5)		16.25 (15–17.5)	16.25 (15–17.5)	0 (0–0)		15 (14.5–15)	14.5 (10–15)	0 (0–3.5)		

Data are presented as mean ± SD or median (interquartile range). *Comparison of difference between scans (Δ) with that in FV technically successful cases, calculated from IPTW regression. EDD, end-diastolic diameter; LV, left ventricle.

Fetal hemodynamics and left heart growth

The IPTW analysis shows hemodynamic improvement was significantly better following successful FV than following a failed attempt, but did not differ significantly from the NH group. However, left heart growth was significantly worse in the NH than in the successful FV group (Table 4). The small number of technically unsuccessful cases appeared to show similar left ventricular and aortic valve growth to those of the successful FV cohort, but had a significantly reduced mitral valve size by delivery. The hemodynamic and left heart growth data used to create the propensity score are included in Table S4.

DISCUSSION

During the study period, the selection of cases for FV was evolving worldwide. Initially, fetal cardiologists hoped that FV could achieve BV circulation in fetuses with short left ventricles and endocardial fibroelastosis, compared with NH. Subsequent experience has shown that only selected fetuses appear to benefit; however, selection criteria remain elusive.

As a prospective randomized controlled trial was not feasible, we used the propensity score to provide pseudorandomization of our retrospective data. We observed similar proportions with BV circulation outcome in our IPTW intention-to-treat cohorts (36% for the FV and 38% for the NH cohort). IPTW logistic analysis showed that FV did not confer survival or circulatory benefits but, when procedure-related deaths were removed and Cox regression was adjusted for circulation and surgical center, FV reduced the risk of early postnatal death by two-thirds. Survival to 10 years' follow-up in this cohort was similar for those with final BV circulation and those with final UV circulation, with no deaths after 2.3 years.

FV was introduced into clinical practice without a trial, and many centers performed procedures without reporting outcomes. An international, anonymized registry was established recently to collect multicenter data, but currently lacks independent audit, making data validation difficult⁶. Contemporaneously matched controls (rather than choosing those with unsuccessful FV) and treatment randomization are missing from FV publications^{1,4–6,10,11}, providing only Level-3 evidence of treatment efficacy⁷.

Our study contributes to the global experience of FV and is strengthened by contemporaneously collected NH controls. Several important observations can be drawn. Firstly, our 10% procedure-related loss was similar to that found in single-center studies^{4,5,9} and less than the 17% reported in the anonymized registry⁶, highlighting the importance of experienced teams mentoring new FV centers. Secondly, fetal Z-scores demonstrated favorable anatomy for FV, indicating good case selection. Thirdly, the operators' evaluation of FV success was accompanied by objective changes in fetal

hemodynamics; hydrops resolved in over one-third of affected fetuses, and two-thirds of all successful FV showed sustained hemodynamic improvement, including reversal of previously retrograde arch and foramen flow and new biphasic ventricular filling. These individuals had BV circulation outcomes more commonly.

The prevalence of premature delivery (< 37 + 0 weeks) has not been reported following FV. Premature delivery occurred in 42% of FV cases compared with 26% (22/85) of NH cases. From the limited maternity data that were collected, growth restriction (estimated fetal weight < 10th centile) was found not to be responsible for early delivery as it occurred almost exclusively in those delivering > 37 weeks. Early delivery may represent institutional practice (unsubstantiated by evidence) to avoid worsening left heart function and aortic valve closure and, in this study, was more frequent following fetal intervention. Delivery was not centralized to the site performing the FV and lack of familiarity in disease assessment may be a contributing factor.

Recognition that left heart growth remains suboptimal following successful FV has resulted in modifications to selection criteria. Although important in long-term ventricular function, the diagnosis and grading of endocardial fibroelastosis by ultrasound remains elusive due to poor accuracy in comparison with histology¹². Although it was originally included as a predictive variable¹³, it has been removed recently due to the qualitative nature of grading and only modest interobserver reliability^{12,14}. Newer selection criteria include left ventricular inlet length Z-score > 0 at presentation and pressure generation ≥ 20 mmHg^{4,5}. While one group applied the 2010 criteria hypothetically to a small series and described it as predictive of outcome³, our larger dataset suggests otherwise. Of the 40 NH fetuses satisfying criteria for emerging hypoplastic left heart syndrome, 13 (33%) had BV circulation despite eight falling below the threshold score to be theoretically offered FV². Importantly, our hemodynamic and left heart growth data suggest that outcomes following unsuccessful FV are not similar to NH, making unsuccessful FV cases unsuitable as controls.

Prospective fetal therapy trials for open meningocele surgery and laser therapy for twin-to-twin transfusion syndrome^{15,16} demonstrate that successful fetal procedures rely on case selection, technical prowess and integrated postnatal management. Therefore, refinement of FV selection criteria, unsupported by a trial, may increase the chance that FV is offered to those who would achieve BV circulation without fetal therapy, with the associated risks of procedure-related mortality and fetal and/or maternal morbidity.

We have previously discussed postnatal selection bias and its effects, which touches upon the ethos and ability of the entire pre- and postnatal team in decision making⁷. We note that BV circulation survival is relatively low in our study, similar to survival to hospital discharge of 58% (irrespective of FV) reported in a recent multicenter registry report, and less than

that reported in a single center report^{6,11}. Poor outcome may be associated with the complexity of congenital AoS resulting in multiple procedures in addition to premature delivery.

Even though we accounted for surgical center variability in our analyses, unrecognized center-specific differences in delivering affected babies preterm to initiate earlier treatment, decision-making regarding postnatal management, skill and practice may potentially confound our results. The postnatal treatment centers had different postnatal strategies, in part because the range of surgical options was not available in all cardiac surgical centers in this study^{17–21}. An aggressive approach may preclude later conversion to UV and result in early mortality and the risk of later pulmonary hypertension^{11,17–22}.

Limitations of the current study include its retrospective multicenter design with a limited cohort size. Low rates of prenatal diagnosis of AoS²³ make a prospective, randomized FV trial challenging; therefore, we used IPTW in our study to minimize the deficiencies in our dataset. Although the number of postnatal cardiac centers may have introduced unrecognized confounding and bias into the assessment of the efficacy of FV in this study, the statistical model we used adjusted for clustering due to center influence.

In conclusion, we report improvements in fetal hemodynamics and preservation of left heart growth following successful FV compared to NH. While the proportion of those achieving a BV circulation outcome was similar in both cohorts, FV survivors showed improved survival, independent of final circulation, to 10 years' follow-up. However, FV is associated with a 10% procedure-related loss and increased prematurity compared with NH, and therefore the risk–benefit ratio remains uncertain.

We recommend a carefully designed trial, incorporating appropriate and integrated fetal and postnatal management strategies to account for center-specific practices, so that the benefits achieved by fetal therapy *vs* surgical strategy can be demonstrated clearly.

ACKNOWLEDGMENTS

This study was devised by the Fetal Working Group of the Association for European Paediatric Cardiology. Financial support for site visits by A.K. and some statistical assistance was provided by the Fetal Working Group of the AEPC. Additional funding for statistical analysis was provided by Children's Heart Unit Fund (CHUF), Royal Brompton Hospital Charities (Registered Charity No: 1053584); Oberösterreichische Spitals AG; donations to The Fetal Center at Children's Memorial Hermann Hospital, University of Texas, Houston; and from the coauthors' private funds. A.K. was supported by a grant from the Department of Paediatric Cardiology, Heinrich Heine University Duesseldorf, Germany. M.M. and A.Ö. were supported by the Swedish Heart and Lung Foundation.

CONTRIBUTORS TO THE STUDY INCLUDING MEMBERS OF THE FETAL WORKING GROUP OF THE AEPIC

Joaquim Bartrons, *Department of Paediatric Cardiology, Hospital Clinic of Barcelona, Sant Joan de Déu, Barcelona, Spain*;
 Frances Bullock and Suhair Shebani, *Congenital and Paediatric Cardiac Service, Glenfield Hospital, Leicester, UK*;
 Sally Ann Clur, *Academic Medical Center, Amsterdam, The Netherlands*;
 Ingo Daehner, *Clinic for Pediatric Cardiology, Heart Centre, University of Leipzig, Germany*;
 Giovanni Di Salvo, *Department of Pediatric Cardiology, Second University of Naples, Monaldi Hospital, Naples, Italy*;
 Ruth Heying and Marc Gewillig, *Department of Congenital and Pediatric Cardiology, University Hospital Gasthuisberg, Leuven, Belgium*;
 Els Grijseels and Laurens Koopmann, *Departments of Prenatal Medicine and Pediatric Cardiology, Erasmus MC/Sophia Children's Hospital Rotterdam, The Netherlands*;
 Kaarin Makikallio, Aydin Tekay and Markku Leskinen, *Departments of Obstetrics and Gynaecology and of Pediatrics, Oulu University Hospital, Oulu, Finland*;
 Nicky Manning and Nick Archer, *Paediatric and Fetal Cardiology Service, John Radcliffe Hospital, Oxford, UK*;
 Renate Oberhoffer, *The German Heart Centre, Munich, Germany*;
 Cristina Romeo, *Department of Cardiology, Azienda Ospedaliera Bolzano, Bolzano, Italy*;
 Keld Ejvind Sørensen, *Skejby University Hospital, Aarhus, Denmark*;
 Trevor Richens, *Department of Cardiology, Royal Hospital for Sick Children, Yorkhill Division, Glasgow, UK*;
 Klaus Schmidt, *Department of Paediatric Cardiology, Heinrich Heine University Duesseldorf, Germany*;
 Anna Seale and Victoria Jowett, *Queen Charlotte's Hospital and Royal Brompton Hospital, London, UK*;
 Cecile Tissot, *Pediatric Cardiology Unit, The Children's University Hospital of Geneva, Geneva, Switzerland*;
 Viktor Tomek, *University Motol Hospital, Prague, Czech Republic*;
 Frank Uhlemann, *Department of Pediatric Cardiology and Pediatric Intensive Care, Olgahospital, Stuttgart, Germany*;
 Niels Vejstrup, *Department of Cardiology, Rigshospitalet, Copenhagen, Denmark*;
 Jochen Weil, *Clinic for Paediatric Cardiology, University Heart Centre Hamburg, Germany*;
 Adam Kolešnik, *The Children's Memorial Health Institute, Cardiology Department, Warsaw, Poland*;
 Marzena Dębska, *The 2nd Department of Obstetrics and Gynecology, The Center of Medical Postgraduate Education, Warsaw, Poland*;
 Agata Włoch, *Department of Obstetrics and Gynecology, Medical University of Silesia, Katowice, Poland*;

Paweł Dryżek, *Department of Cardiology, Polish Mother Memorial Hospital Research Institute, Lodz, Poland*;
 Maciej Chojnicki, *Department of Pediatric Cardiac Surgery, Mikolaj Kopernik Hospital, Gdansk, Poland*.

REFERENCES

- Makikallio K, McElhinney DB, Levine JC, Marx GR, Colan SD, Marshall AC, Lock JE, Marcus EN, Tworetzky W. Fetal aortic valve stenosis and the evolution of hypoplastic left heart syndrome: patient selection for fetal intervention. *Circulation* 2006; 113: 1401–1405.
- Gardiner HM, Kovacevic A, Tulzer G, Sarkola T, Herberg U, Dangel J, Ohman A, Bartrons J, Carvalho JS, Jicinska H, Feslova V, Averis I, Mellander M; Fetal Working Group of the AEPIC. Natural history of 107 cases of fetal aortic stenosis from a European multicenter retrospective study. *Ultrasound Obstet Gynecol* 2016; 48: 373–381.
- Hunter LE, Chubb H, Miller O, Sharland G, Simpson JM. Fetal aortic valve stenosis: a critique of case selection criteria for fetal intervention. *Prenat Diagn* 2015; 35: 1176–1181.
- Arzt W, Wertaschnigg D, Veit I, Klement F, Gitter R, Tulzer G. Intrauterine aortic valvuloplasty in fetuses with critical aortic stenosis: experience and results of 24 procedures. *Ultrasound Obstet Gynecol* 2011; 37: 689–695.
- McElhinney DB, Marshall AC, Wilkins-Haug LE, Brown DW, Benson CB, Silva V, Marx GR, Mirzali-Arnaud A, Lock JE, Tworetzky W. Predictors of technical success and postnatal biventricular outcome after in utero aortic valvuloplasty for aortic stenosis with evolving hypoplastic left heart syndrome. *Circulation* 2009; 120: 1482–1490.
- Moon-Grady AJ, Morris SA, Belfort M, Chmait R, Dangel J, Devlieger R, Emery S, Frommelt M, Galindo A, Gelehrter S, Gembruch U, Grinenco S, Habli M, Herberg U, Jaeggi E, Kilby M, Kontopoulos E, Marantz P, Miller O, Otaño L, Pedra C, Pedra S, Pruetz J, Quintero R, Ryan G, Sharland G, Simpson J, Vlastos E, Tworetzky W, Wilkins-Haug L, Oepkes D. International Fetal Cardiac Intervention Registry: a worldwide collaborative description and preliminary outcomes. *J Am Coll Cardiol* 2015; 66: 388–399.
- Kovacevic A, Roughton M, Mellander M, Ohman A, Tulzer G, Dangel J, Magee AG, Mair R, Ghez O, Schmidt KG, Gardiner HM. Fetal aortic valvuloplasty: investigating institutional bias in surgical decision-making. *Ultrasound Obstet Gynecol* 2014; 44: 538–544.
- Schneider C, McCrindle BW, Carvalho JS, Hornberger LK, McCarthy KP, Daueney PE. Development of Z-scores for fetal cardiac dimensions from echocardiography. *Ultrasound Obstet Gynecol* 2005; 26: 599–605.
- Crump RK, Hotz VJ, Imbens GW, Matinik OA. Dealing with limited overlap in estimation of average treatment effects. *Biometrika* 2009; 96: 187–199.
- McElhinney DB, Tworetzky W, Lock JE. Current status of fetal cardiac intervention. *Circulation* 2010; 121: 1256–1263.
- Freud LR, McElhinney DB, Marshall AC, Marx GR, Friedman KG, del Nido PJ, Emami SM, Lafranchi T, Silva V, Wilkins-Haug LE, Benson CB, Lock JE, Tworetzky W. Fetal aortic valvuloplasty for evolving hypoplastic left heart syndrome: postnatal outcomes of the first 100 patients. *Circulation* 2014; 130: 638–645.
- Mahle WT, Weinberg PM, Rychik J. Can echocardiography predict the presence or absence of endocardial fibroelastosis in infants <1 year of age with left ventricular outflow obstruction? *Am J Cardiol* 1998; 82: 122–124.
- McElhinney DB, Vogel M, Benson CB, Marshall AC, Wilkins-Haug LE, Silva V, Tworetzky W. Assessment of left ventricular endocardial fibroelastosis in fetuses with aortic stenosis and evolving hypoplastic left heart syndrome. *Am J Cardiol* 2010; 106: 1792–1797.
- Friedman KG, Sleeper LA, Freud LR, Marshall AC, Godfrey ME, Drogoz M, Lafranchi T, Benson CB, Wilkins-Haug LE, Tworetzky W. Improved technical success, postnatal outcome and refined predictors of outcome for fetal aortic valvuloplasty. *Ultrasound Obstet Gynecol* 2018; 52: 212–220.
- Adzick NS, Thom EA, Spong CY, Brock JW 3rd, Burrows PK, Johnson MP, Howell LJ, Farrell JA, Dabrowski ME, Sutton LN, Gupta N, Tulpan NB, D'Alton ME, Farmer DL; MOMS Investigators. A randomized trial of prenatal versus postnatal repair of myelomeningocele. *N Engl J Med* 2011; 364: 993–1004.
- Senat MV, Deprest J, Boulvain M, Paupe A, Winer N, Ville Y. Endoscopic laser surgery versus serial amnioreduction for severe twin-to-twin transfusion syndrome. *N Engl J Med* 2004; 351: 136–144.
- Emami SM, Bacha EA, McElhinney DB, Marx GR, Tworetzky W, Pigula FA, del Nido PJ. Primary left ventricular rehabilitation is effective in maintaining two-ventricle physiology in the borderline left heart. *J Thorac Cardiovasc Surg* 2009; 138: 1276–1282.
- Perez-Negruela C, Mayol J, Prada F, Caffarena-Calvar JM. Neonatal Ross-Konno operation and endocardial fibroelastosis resection after foetal percutaneous aortic valve balloon valvuloplasty: a complex approach to rescue the left heart. *Eur J Cardiothorac Surg* 2014; 46: 498–499.
- Hickey EJ, Caldaroni CA, Blackstone EH, Lofland GK, Yeh T Jr, Pizarro C, Tchervenkov CI, Pigula F, Overman DM, Jacobs ML, McCrindle BW; Congenital Heart Surgeons' Society. Critical left ventricular outflow tract obstruction: The disproportionate impact of biventricular repair in borderline cases. *J Thorac Cardiovasc Surg* 2007; 134: 1429–1436; discussion 1436–1437.

20. Hickey EJ, Caldarone CA, McCrindle BW. Left ventricular hypoplasia: a spectrum of disease involving the left ventricular outflow tract, aortic valve, and aorta. *J Am Coll Cardiol* 2012; 59 (1 Suppl): S43–S54.
21. Moon-Grady AJ, Moore P, Azakie A. Ross-Konno and endocardial fibroelastosis resection after hybrid stage I palliation in infancy: successful staged left-ventricular rehabilitation and conversion to biventricular circulation after fetal diagnosis of aortic stenosis. *Pediatr Cardiol* 2011; 32: 211–214.
22. Burch M, Kaufman L, Archer N, Sullivan I. Persistent pulmonary hypertension late after neonatal aortic valvotomy: a consequence of an expanded surgical cohort. *Heart* 2004; 90: 918–920.
23. Freud LR, Moon-Grady A, Escobar-Diaz MC, Gotteiner NL, Young LT, McElhinney DB, Tworetzky W. Low rate of prenatal diagnosis among neonates with critical aortic stenosis: insight into the natural history *in utero*. *Ultrasound Obstet Gynecol* 2014; 45: 326–332.

SUPPORTING INFORMATION ON THE INTERNET

The following supporting information may be found in the online version of this article:



Appendix S1 Procedural and technical details used in study and center-specific details

Table S1 Technical success, circulatory outcome and survival by procedure in chronological order (with follow-up up to April 2017)

Table S2 Weighted scores for hemodynamic variables thought to have greatest impact on circulatory outcome. These parameters should normalize if fetal hemodynamics improves following a successful fetal valvuloplasty

Table S3 Pairwise comparisons of marginal linear predictions

Table S4 Change in fetal hemodynamics and left heart growth during pregnancy in whole propensity score cohort

3.0.3 ANNEX 8

Navratil J, **Jicinska H**, Jelinek Z

The incidence and the outcome of fetuses diagnosed with hypoplastic left heart syndrome in the region of Moravia and Silesia in 2002 and 2003

Cesko-slovenska Pediatrie. 2005; 60(7): 393-396

Main points of the publication:

The authors monitored the occurrence and the outcome of fetuses diagnosed with severe congenital heart defect (hypoplastic left heart syndrome) in the region of Moravia and Silesia prenatally. They looked for the risk factors associated with the incidence and with the detection of hypoplastic left heart syndrome prenatally. In conclusion, the ultrasonographic examination of the fetal heart is the only reliable method to detect HLHS prenatally.

Výskyt a osudy plodů se syndromem hypoplastického levého srdce na území Moravy a Slezska v letech 2002 a 2003

Navrátil J., Jičínská H., Jelínek Z.¹

II. dětská klinika LF MU a FN Brno
přednosta prof. MUDr. Z. Doležel, CSc.
Ambulance dětské kardiologie, Brno¹

Souhrn

Syndrom hypoplazie levého srdce (HLHS) je vrozená srdeční vada se závažnou prognózou. Přes velký rozvoj dětské kardiologie má stále vysokou mortalitu. Prenatální diagnóza HLHS má vliv na další osud těchto plodů. Na spádovém území Moravy a Slezska dosud nebyl zjišťován výskyt a osudy pacientů s HLHS, epidemiologická studie Bohemian Survival Study zahrnovala jen české země.

V letech 2002 a 2003 bylo na našem pracovišti, které zahrnuje spádovou oblast Moravy a Slezska, vyšetřeno 4667 plodů, u 108 z nich byla zjištěna vrozená srdeční vada. Ve stejném období se na uvedeném území narodilo 69 623 novorozenců, 478 z nich mělo vrozenou srdeční vadu. HLHS se vyskytl celkem u 24 z nich, což je 5 % ze všech vrozených srdečních vad. V 21 případech (87,5 %) byla diagnóza HLHS známa prenatálně, ve třech až postnatálně. HLHS představoval 19,5 % ze všech prenatálně diagnostikovaných srdečních vad. Z 21 prenatálně diagnostikovaných HLHS se v 17 případech (81 %) rozhodli rodiče pro ukončení gravidity, ve 4 případech (19 %) její pokračování.

Autoři hodnotili prenatálně zjistitelné rizikové faktory, které byly zaznamenány u 12 plodů, 9 plodů bylo bez rizikového faktoru. Vyšetření karyotypu u prenatálně zjištěných HLHS bylo v 62 % normální, v 9,5 % patologické a u 28,5 % nebylo provedeno.

Výskyt HLHS na našem spádovém území je srovnatelný s literárními údaji. Autorům se nepodařilo najít jinou metodu než ultrazukové vyšetření, která by upozornila na výskyt HLHS a tak toto vyšetření zůstává i nadále rozhodující pro prenatální diagnostiku HLHS.

Klíčová slova: syndrom hypoplazie levého srdce, prenatální diagnóza, rizikové faktory

Summary

Occurrence and Fate of Fetuses with Hypoplastic Left Heart in the Region of Moravia and Silesia during 2002 and 2003

The syndrome of hypoplasia of the left heart (HLHS) is an inborn heart defect with severe prognosis. In spite of the great development of the child cardiosurgery there is still a high mortality. Prenatal diagnosis of HLHS significantly influences further fate of the fetuses. The incidence and fate of patients with HLHS have not been so far investigated in the area of Moravia and Silesia, since the epidemiological Bohemian Survival Study included only the Czech countries (Bohemia).

In the years 2002 and 2003, our workplace which takes care of the Moravia and Silesia region, examined 4,667 fetuses, 108 of them suffering from inborn heart defect. In the same period of time 69,623 newborns were born in this area, 478 of them having inborn heart defect. HLHS occurred in 24 of them, i.e., 5% of all inborn heart defects. In 21 cases (87.5%) the HLHS diagnosis was established before birth, whereas in three of them after birth. HLHS represented 19.5% of all heart defects diagnosed before birth. In 21 HLHS, where the diagnosis was established before birth, the parents decided to end the pregnancy in 17 cases (81%), in four cases they decided the pregnancy to continue.

The authors evaluated the detectable risk factors before birth and established them in 12 fetuses, whereas no risk factor was found in 9 fetuses. The examination of karyotype in HLHS established in prenatal period revealed normal picture in 62% of cases, 9.5% being pathological and 28.5% and it was not determined in 28.5% at all.

The occurrence of HLHS in our region proved to be comparable with data in literature. Authors have not been able to find a method other than ultrasonography, which would draw attention to HLHS and this method therefore remains to be the decisive method for prenatal diagnostics of HLHS.

Key words: syndrome of left heart hypoplasia, prenatal diagnosis, risk factors

G.

Úvod

Vrozené srdeční anomálie, které vznikají chyb-
ným vývojem jednotlivých částí levého srdce (tj.
levé síně, mitrální chlopně, levé komory, aortální
chlopně a aortálního oblouku) a vedou k nedosta-
tečné funkci tohoto srdečního oddílu, se souhrnně
nazývají syndrom hypoplastického levého srdce
(HLHS). Přes veškerý rozvoj dětské kardiochi-
rurgie od 90. let 20. století zůstává HLHS vadou
s nejvyšším operačním rizikem a nejistou dlouho-
dobou prognózou. Všechny modifikace kardiochi-
rurgického řešení HLHS představují úpravu
krevního oběhu na jednodukovou cirkulaci.
Druhou variantu léčby HLHS představuje trans-
plantace srdce.

Před narozením nevede HLHS k růstové retar-
daci plodu a nebývá ani příčinou předčasného
porodu. Po porodu se však hned v prvních dnech
projevuje známkami srdeční nedostatečnosti se
všemi nepříznivými důsledky kritické srdeční
vady. Vada HLHS vzniká v raných fázích gravidity
a lze ji prenatálně diagnostikovat. Včasná
informace o této diagnóze umožňuje zlepšit,
zrychlit a zlevnit péči o novorozence s HLHS.
Zatím monopolní metodou, kterou lze HLHS
detekovat ještě před narozením, je ultrazvukové
vyšetření (USV) srdce plodu.

Materiál a metodika

V letech 2002 a 2003 jsme vyšetřili srdce plo-
du u 4667 gravidních žen. V hodnoceném období
se na území Moravy a Slezska narodilo 69 623
novorozenců, z nichž 478 mělo vrozenou srdeční
vadu. USV srdce plodu jsme prováděli v rozme-
zí 20.–34. týdne gravidity přístrojem Vivid 7 fir-
my GE Medical systems sondou M3S a 3,5C
a přístrojem Sonos 100 firmy Hewlett Packard
sondou 3 a 5 MHz. Prenatálně stanovená diag-
nóza HLHS byla ověřena buď sekci srdce plodu,
nebo vyšetřením novorozence. Všichni novoro-
zenci měli provedenou klinickou vyšetření, EKG
a USV.

Cílem naší práce bylo:

1. Zjistit, jaký je celkový výskyt a podíl prena-
tálně diagnostikovaných HLHS na našem spádo-
vém území (kraje Jihomoravský, Vysočina, Zlín-
ský, Olomoucký, Moravskoslezský).

2. Vyhodnotit možnosti stratifikace rizika vzni-
ku a možnosti predikce výskytu HLHS v analyzo-
vaném souboru.

Výsledky

Z námi vyšetřených 4667 plodů byla v hodno-
ceném období prenatálně zjištěna vrozená srdeč-
ní vada u 108 z nich. Z 69 623 živě narozených
novorozenců v oblasti Moravy a Slezska byla
potvrzena vrozená srdeční vada u 478 z nich.

Na území Moravy a Slezska byl v letech 2002
a 2003 diagnostikován HLHS ve 24 případech,
z toho prenatálně u 21 (87,5 %) z nich; teprve
postnatálně byl HLHS diagnostikován u tří novo-
rozenců. Ze všech prenatálně diagnostikovaných
vrozených srdečních vad představoval HLHS
19,5 %. V našem souboru vyšetřených plodů byl
HLHS nejčastějším typem vrozené srdeční vady.
Pět z 24 pacientů (21 %) s HLHS mělo přidruže-
nou extrakardiální anomálii (2krát hygroma coli
cysticum, 1krát gastroschisis, 1krát solitární
umbilikální arterii, 1krát střevní malrotaci),
u ostatních 19 (79 %) se vyskytoval HLHS izolo-
vaně.

Prevalence HLHS na našem spádovém území
v hodnoceném období byla 1:2900, tj. 0,34/1000
živě narozených novorozenců. Z 69 623 živě naro-
zených novorozenců mělo vrozenou srdeční vadu
478 z nich a zastoupení HLHS tak bylo 5 % ze
všech vrozených srdečních vad.

Téměř všechny těhotné ženy v České republice
procházejí během gravidity screeningovým vyšet-
řením laboratorním a ultrazvukovým. Zvýšená
pozornost a prenatální péče se věnuje těm z nich,
které mají známé rizikové faktory pro vznik vro-
zených vývojových vad, tj. věk matky nad 35 let,
přítomnost jiné vrozené vady u plodu nebo v rodi-
ně, patologický laboratorní screening, výskyt
předchozích spontánních abortů a intrauterin-
ních úmrtí, proběhlá infekce/jiná choroba v těho-
tenství, chronické onemocnění matky. V našem
souboru 21 plodů s HLHS byly u 12 z nich (57 %)
přítomny některé z uvedených rizikových fakto-
rů, 9 (43 %) plodů bylo bez rizikového faktoru.
U 12 plodů (57 %) s HLHS mohla tedy být predi-
kci rizika výskytu HLHS přítomnost jednoho nebo
více rizikových faktorů, u 9 (43 %) nebyl žádný
rizikový faktor nebo další údaj, který by upozor-
nil na možnost výskytu HLHS.

V případech zjištění HLHS indikujeme vyšetření
karyotypu plodu vyšetřením plodové vody, pupeč-
níkové krve nebo krve novorozence. Výsledky
vyšetření karyotypu v námi hodnoceném souboru
uvádí tabulka 2. Oba plody s HLHS a patologic-
kým karyotypem měly i další přidružené extra-
kardiální anomálie, které byly známy již před
kardiologickým vyšetřením. Ze 13 plodů s nor-
málním karyotypem měly přidružené extrakar-
diální anomálie tři z nich. Jen jeden plod, který

Tab. 1. Spektrum rizikových faktorů v souboru 21 prenatalně diagnostikovaných HLHS.

Rizikový faktor	Počet	Senzitivita (%)	Specifita (%)
Věk nad 35 let	0	0	84
Chronická nemoc matky	0	0	95
Viroza v 1. trimestru	1	5	98
Kombinace dvou faktorů	2	9,5	95
Spontánní aborty	2	9,5	96
Patologický triple test	2	9,5	78
Extrakardiální anomálie	5	24	98
Bez rizikového faktoru	9	43	84
Součet všech rizikových faktorů	12	57	54

HLHS – syndrom hypoplazie levého srdce

Tab. 2. Karyotyp plodů s HLHS.

Karyotyp	Počet	%
Normální	13	62
Patologický (47XY+13,45 X0)	2	9,5
Nevyšetřen	6	28,5

HLHS – syndrom hypoplazie levého srdce

neměl vyšetřen karyotyp, měl znám jeden rizikový faktor (diabetes mellitus matky). Všechny ostatní plody, u nichž nebyl vyšetřen karyotyp, neměly přidružené extrakardiální anomálie ani žádné ze sledovaných rizikových faktorů. Z těchto souvislostí lze usuzovat, že podíl plodů s HLHS a normálním karyotypem byl ještě vyšší.

Z 21 prenatalně diagnostikovaných HLHS se rodiče rozhodli v 17 případech (81 %) pro ukončení gravidity, ve 4 případech (19 %) pro pokračování těhotenství. Ze tří novorozenců s HLHS, u kterých nebyla srdeční vada známa prenatalně, se jednou rodiče rozhodli pro konzervativní postup a dvakrát pro kardiologické řešení. Dítě bez operace zemřelo, další dvě děti po kardiologickém zákroku žijí.

Diskuse

Výskyt HLHS podle jednotlivých autorů kolísá. Šamáněk ve své studii Bohemian Survival Study – BOSS [10] uvádí výskyt HLHS 3,5 % ze všech vrozených srdečních vad, autoři Freedom a spol. udávají výskyt této vady 9 % [3]. Námí zjištěný výskyt 5 % je tak v literárně udávaném rozmezí.

Podíl prenatalně diagnostikovaných HLHS závisí především na úrovni provádění USV v graviditě. V práci autorů Mahle a kol. z pracoviště ve Philadelphii [6] je uváděn podíl prenatalně diagnostikovaných HLHS 36,6 %, Kumar a kol. [5] uvádí 18 %, Reis a kol. [9] 37 %. V našem souboru zjištěný záchyt prenatalního HLHS 87,5 % je tedy hodnotou mimořádně vysokou.

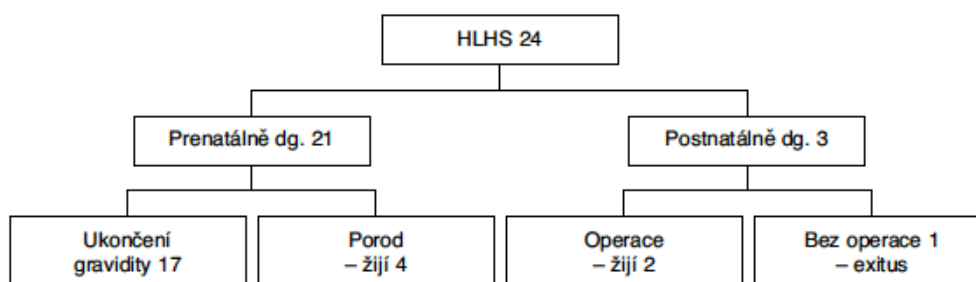
Přirozený průběh HLHS je fatální. Chirurgické řešení v podobě trístupňové Norwoodovy

korekce je možné pouze u části pacientů a její kumulativní mortalita je 35–50 % [8].

Další léčebnou možností je ortotopická transplantace srdce, která je v Evropě pro nedostatek vhodných dárců realizována jen ojediněle. V případě zjištění HLHS prenatalně do 24. týdne gravidity je tak možno buď nechat těhotenství pokračovat a směřovat porod novorozence do specializovaného centra, kde může být zajištěna následná péče, nebo těhotenství na přání rodičů ukončit. V našem souboru 21 prenatalně diagnostikovaných HLHS se pro ukončení těhotenství rozhodlo 81 % rodičů, což je významně více, než uvádějí některé přehledné práce ze Spojených států amerických. V práci L. D. Allana a kol. [1] se pro ukončení gravidity rozhodlo 33 % těhotných. Tento rozdíl je jistě ovlivněn tím, že v autorčině souboru byla diagnóza HLHS stanovena v pozdějším prenatalním období – do 24. týdne těhotenství bylo prenatalně diagnostikováno 40 % HLHS, zatímco v našem souboru to bylo 95 %. Rozdíl v obou souborech může také souviset s odlišnými zdravotními systémy, včetně jiné organizace prenatalní péče ve Spojených státech amerických a v České republice. Lze také předpokládat, že pokud by byl podíl prenatalně diagnostikovaných plodů s HLHS do 24. týdne těhotenství u nás nižší, byl by také nižší podíl ukončených gravidit. Pro ukončení gravidity se často rodiče rozhodují z toho důvodu, že by jejich dítě muselo podstoupit opakované kardiologické výkony s vysokou mortalitou a nejistou prognózou.

HLHS jako jedna z nejzávažnějších vrozených srdečních vad se vyskytuje ve vysokém podílu jako vada izolovaná [7]. V našem souboru 21 prenatalně diagnostikovaných HLHS mělo 5 (21 %) plodů přidruženou extrakardiální anomálii, u 16 (79 %) se vyskytoval HLHS izolovaně. Z dalších rizikových faktorů byly přítomny u dvou předcházející spontánní aborty v anamnéze, u dalších

Schéma 1. Přehled osudů plodů a novorozenců s HLHS.



HLHS – syndrom hypoplazie levého srdce

dvou viróza v prvním trimestru gravidity a pozitivní biochemický screening také u dvou těhotných. Přítomnost jednoho nebo více rizikových faktorů celkem u 12 (57 %) plodů s HLHS může být predikcí rizika výskytu HLHS, ovšem se senzitivitou pouze 57 %. Jednotlivé rizikové faktory se v našem souboru neukázaly jako signifikantní, neboť se jednalo o malý soubor. U 9 (43 %) těhotných nebyl nalezen žádný rizikový faktor, což potvrzuje správnost a nezbytnost provádění prenatálního USV screeningu vrozených srdečních vad.

Závěr

Námi zjištěné údaje lze uzavřít:

1. Výskyt HLHS na spádovém území Moravy a Slezska není odlišný od českých zemí a je srovnatelný s literárními údaji z jiných geografických oblastí. Osud plodů/novorozenců s HLHS v našem souboru uvádí schéma 1.

2. Prenatální záchyt HLHS na sledovaném území je mimořádně vysoký a je tak dokladem odpovídající spolupráce gynekologů a dětských kardiologů.

3. Kvalifikované USV srdce plodu zůstává stěžejní metodou pro stratifikaci rizika výskytu HLHS.

Poděkování

Autoři sdělení děkují spolupracovníkům z oblasti gynekologie, genetiky, dětské kardiologie, kardiochirurgie a všem ostatním, kteří se na péči o pacienty s HLHS, resp. o těhotné ženy a příslušné rodiny, podíleli.

Práce byla podpořena Výzkumným záměrem MZ ČR č. 00065269705: Komplexní program prenatální kardiologie ve FN Brno.

Literatura

- Allan, L. D., Apofel, H. D., Printz, B. F. Outcome after prenatal diagnosis of the hypoplastic left heart syndrome. *Heart*, 1998, 79, s. 371–373.
- Anderson, R. H., Baker, E. J., Macartney, F. J. *Pediatric Cardiology*. 2nd ed. Churchill Livingstone, 2002, s. 1191–1211.
- Emmanouilides, G. C., Allen, H. D. *Moss and Adams Heart Disease in Infants, Children and Adolescents*. 5th ed. Williams and Wilkins, 1995, s. 1133–1153.
- Grobman, W., Pergament, E. Isolated hypoplastic left heart syndrome in three siblings. *Obstetrics and Gynecology*, 1996, 88, s. 673–675.
- Kumar, R. K., Newburger, J. W., Gauvreau, K., Kamenir, S. A., Horberger, L. K. Comparison and outcome when hypoplastic left heart syndrome and transposition of the great arteries are diagnosed prenatally versus when diagnosis of these two conditions is made postnatally. *American Journal of Cardiology*, 1999, 83, s. 1649–1653.
- Mahle, W. T., Clancy, R. R., McGaurn, S. P., Goin, J. E., Clark, B. J. Impact of prenatal diagnosis on survival and early neurologic morbidity in neonates with the hypoplastic left heart syndrome. *Pediatrics*, 2001, 107, s. 1277–1282.
- Moller, J., Hoffman, J. *Pediatric Cardiovascular Medicine*. Churchill Livingstone, 2000, s. 594–605.
- Niederle, P., Marek, J. *Echokardiografie, 2. díl – Pediatrická a prenatální echokardiografie*. Praha: Triton, 2003, s. 285–295.
- Reis, P. M., Punch, M. R., Bove, E. L., van de Ven, C. J. Obstetric management of 219 infants with hypoplastic left heart syndrome. *Amer. J. Obstet. Gynecol.*, 1998, 179, s. 1150–1154.
- Šamánek, M., Voříšková, M. Prežívání dětí narozených se srdeční vadou v Čechách (Bohemian Survival Study – BOSS). *Ces.-slov. Pediat.*, 1997, 52, s. 403–407.

Došlo: 14. 3. 2005

MUDr. Jiří Navrátil
FN Brno – II. dětská klinika
Černopolní 9
625 00 Brno

3.0.4 ANNEX 9

Matsui H, Mellander M, Roughton M, Jicinska H, Gardiner H

Morphological and Physiological Predictors of Fetal Aortic Coarctation

Circulation 2008;118:1793-1801

Impact factor in 2008:14.816

Main points of the publication:

The study tested the applicability of previously published aortic arch and ductal Z scores and their ratios. Secondly, the study tested the ability of serial Z scores to distinguish fetuses with coarctation of aorta within a cohort of fetuses with right-to-left disproportion on a ventricular and/or arterial level. Finally, the study evaluated the diagnostic significance of associated cardiac lesions and coarctation shelf and isthmus flow disturbance.

In conclusion, isthmus Z scores and isthmus-to-duct ratios < 0.75 are sensitive indicators of fetal coarctation. Serial measurements and abnormal isthmus flow patterns improve diagnostic specificity and may reduce false positive cases.

The candidate contributed to the manuscript and with cases to this study.

Morphological and Physiological Predictors of Fetal Aortic Coarctation

Hikoro Matsui, MD; Mats Mellander, PhD, MD; Michael Roughton, PhD; Hana Jicinska, MD; Helena M. Gardiner, PhD, MD

Background—Prenatal diagnosis of aortic coarctation suffers from high false-negative rates at screening and poor specificity.

Methods and Results—This retrospective study tested the applicability of published aortic arch and ductal Z scores (measured just before the descending aorta in the 3-vessel and tracheal view) and their ratio on 200 consecutive normal controls at a median of 22 ± 0 gestational weeks (range, 15 ± 4 to 38 ± 4 weeks). Second, this study tested the ability of serial Z scores to distinguish fetuses with coarctation within a cohort with ventricular and/or great arterial disproportion detected at screening or fetal echocardiography. Third, it evaluated the diagnostic significance of associated cardiac lesions, coarctation shelf, and isthmal flow disturbance. We studied 44 fetuses with suspected coarctation at 24 ± 0 weeks (range, 17 ± 3 to 37 ± 4 weeks). Receiver-operating characteristic curves were created. Logistic regression tested the association between z scores, additional cardiac diagnoses, and coarctation. Good separation was found of isthmal Z scores for cases requiring surgery from controls and false-positive cases, and receiver-operating characteristic curves showed an excellent area under the curve for isthmal Z score (0.963) and isthmal-to-ductal ratio (0.969). Serial isthmal Z scores improved to > -2 in suspected cases with normal outcomes; those requiring surveillance or surgery remained < -2 . Minor lesions did not increase the diagnostic specificity of coarctation, but isthmal flow disturbance increased the odds ratio of true coarctation versus arch hypoplasia 16-fold.

Conclusions—Isthmal Z scores and isthmal-to-ductal ratio are sensitive indicators of fetal coarctation. Serial measurements and abnormal isthmal flow patterns improve diagnostic specificity and may reduce false positives. (*Circulation*. 2008; 118:1793-1801.)

Key Words: coarctation ■ fetus ■ pediatrics

Coarctation of the aorta is the most common duct-dependent cardiac defect missed at routine physical screening of the neonate.¹ An estimated 60% to 80% of newborns with isolated coarctation are sent home as “healthy” babies,¹⁻³ to face circulatory collapse and death as the duct closes or, if closure is gradual, prostaglandin rescue and surgery.

Clinical Perspective p 1801

Diagnostic difficulties occur at antenatal screening, where a high false-negative rate is present, and at the hands of the fetal cardiologist. Current echocardiographic methods seem unable to reduce the high false-positive rate of diagnoses among those referred from screening programs.

Prenatal diagnosis improves survival and reduces morbidity^{4,5} by allowing planned delivery in a tertiary center and early institution of prostaglandin treatment to prevent ductal constriction, but this ideal is rarely achieved, and only 19% of

admissions to a large cardiac center for left-sided obstruction have had an antenatal diagnosis.⁶ More comprehensive information is obtained from unselected populations. In 1 regional study, only 6% of babies born with arch obstruction had an antenatal diagnosis, and half of the neonates requiring cardiac surgery for all types of malformations were diagnosed only after discharge from hospital when they became symptomatic.³ It is recognized that not all cases of arch obstruction develop in the neonatal period and that, in an unknown proportion, hypoplasia of the arch may progress to coarctation of the aorta, requiring surgery or interventional catheter in infancy or childhood. Thus, coarctation is one of the most difficult cardiac defects to screen for and diagnose before birth. Suspicion of coarctation is raised by the finding of disproportion at the 4-chamber and/or 3-vessel and tracheal views at screening. Although coarctation of the aorta is high in the differential diagnosis of cardiac disproportion, the sensitivity and positive predictive power of ventricular dis-

Received November 18, 2007; accepted August 27, 2008.

From the Faculty of Medicine, Imperial College at Queen Charlotte's and Chelsea Hospital (H.M., H.M.G.); Brompton Fetal Cardiology, Royal Brompton Hospital (H.M., M.M., H.J., H.M.G.); and Royal Brompton Hospital NHS Trust (M.R.), London, UK. Dr Mellander is now at the Department of Paediatric Cardiology, The Queen Silvia Children's Hospital, Gothenburg, Sweden.

Correspondence to Dr Helena M Gardiner, PhD, MD, FRCP, FRCPCH, DCH, Institute of Reproductive and Developmental Biology, Faculty of Medicine, Imperial College, Queen Charlotte's and Chelsea Hospital, Du Cane Rd, London, W12 0HS, UK. E-mail helena.gardiner@imperial.ac.uk

© 2008 American Heart Association, Inc.

Circulation is available at <http://circ.ahajournals.org>

DOI: 10.1161/CIRCULATIONAHA.108.787598

proportion recognized at screening are low, at ~62% and 33%, respectively.^{7,8} The differential diagnosis of isolated 4-chamber cardiac disproportion is varied but includes cardiovascular diagnoses such as vein of Galen aneurysm and noncardiac diagnoses such as aneuploidy, anemia, and growth restriction caused by placental insufficiency. These noncardiac causes should be investigated by fetal medicine specialists. Once a cardiac diagnosis is suspected and the fetus is referred to a fetal cardiologist, the false-positive rate is 20% to 30%, rising to 80% in 1 report.⁷⁻⁹

In view of the devastating perinatal course following a missed diagnosis of coarctation of the aorta, it is important to improve detection at obstetric screening and to reduce the number of false-negative cases.¹⁰ To achieve this objective, we have trained sonographers to incorporate the 3-vessel and tracheal view into their routine screening so that they can visually recognize great arterial disproportion, which is an abnormal finding in the first- and second-trimester fetus.¹¹ To enable serial objective quantification of the degree of hypoplasia present in the aortic arch, we have published Z scores for the normal diameters of the distal aortic isthmus and arterial duct measured in the 3-vessel and tracheal view.¹²

The purpose of this study was first to test the applicability of our Z scores to the general population and second to see whether serial measurement would increase the specificity of the diagnosis of fetal coarctation by the specialist once a referral had been made. Third, we describe the ability of associated cardiac findings (such as ventricular septal defect, bicuspid aortic valve, and persistent left superior caval vein) and of visualization of a shelf or flow disturbance at the isthmus to increase the specificity of the diagnosis of coarctation of the aorta requiring neonatal surgery.

Methods

Control Group

The first 200 consecutive singleton fetuses referred during 2004 for cardiac scan and found to have normal cardiac anatomy were chosen to test the applicability of our Z scores to the general fetal population. The fetuses were scanned at a median of 22±0 gestational weeks (range, 15±4 to 38±4 weeks). We checked for these fetuses in the national Congenital Cardiac Audit Database, which lists all cardiac surgical and catheter interventions; none had developed coarctation of the aorta during the year after delivery. The measurements were made by a single investigator (H.M.) from the archived recordings of the fetal echocardiograms. The diameters of the aortic isthmus and duct were measured in the 3-vessel and tracheal view immediately before their entry into the descending aorta, and the Z scores and isthmal-to-ductal-diameter ratio were

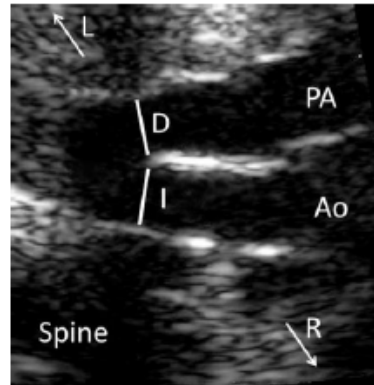


Figure 1. Magnification of the 3-vessel and trachea view showing the pulmonary trunk (PA) leading into the arterial duct (D). The isthmus (I) is measured as shown by the line just before it enters the descending aorta and the duct measured opposite it (line). L indicates left; R, right; and Ao, aorta.

calculated as previously described by our group¹² (Figure 1). In our original report, the results were presented as Z scores related to gestational age and femoral length. In the present study, we used gestational-age Z scores because we found no significant difference between these and femoral-length Z scores, and their use allowed comparison with our retrospective normal cases in whom femoral length was not necessarily available on the same day.

Study Group

All pregnant women referred for specialist fetal echocardiography and found to have ventricular and/or arch disproportion during the period of January 2000 to December 2005 were eligible for inclusion in the study. Their echocardiograms were analyzed retrospectively by an investigator (H.M. or H.J.) blinded to outcome.

The diagnosis of disproportion was subjective and suspected visually. No chamber sizes were measured. In practice, disproportion was noticeable when an ~20% difference was found in ventricular widths or in the transverse portion of the ductal and aortic arches.

Only fetuses suspected of having isolated coarctation (ie, normal situs, concordant atrioventricular and ventriculoarterial connections, and a biventricular atrioventricular connection) were included. Forty-eight fetuses fulfilled these inclusion criteria. Two were excluded because of incomplete outcome data, and another 2 were enrolled but later excluded because the pregnancy was terminated. Thus, the study comprised 44 fetuses with suspicion of coarctation in whom outcome was known until at least 1 year of age. Minor secondary diagnoses of atrial or ventricular septal defect, bicuspid aortic valve, and persistent left superior caval vein to coronary sinus were identified; their frequency is presented in Table 1. The arch

Table 1. Secondary Diagnoses in Fetuses Referred With Suspected Aortic Coarctation

Factor	Surgery (n=20), n (%)	Surveillance (n=7), n (%)	Postnatal Normal (n=17), n (%)	P
Shelf	9 (45)	0 (0)	1 (6)	0.005
Flow disturbance	13 (65)	1 (14)	0 (0)	<0.001
Shelf and flow disturbance	6 (30)	0 (0)	0 (0)	0.015
Flow disturbance, no shelf	7 (35)	1 (14)	0 (0)	0.022
VSD	10 (50)	3 (43)	2 (12)	0.044
LSVC	4 (20)	4 (57)	7 (41)	0.149
Bicuspid AoV	5 (25)	0 (0)	1 (6)	0.125

VSD indicates ventricular septal defect; LSVC, left superior vena cava; and AoV, aortic valve.

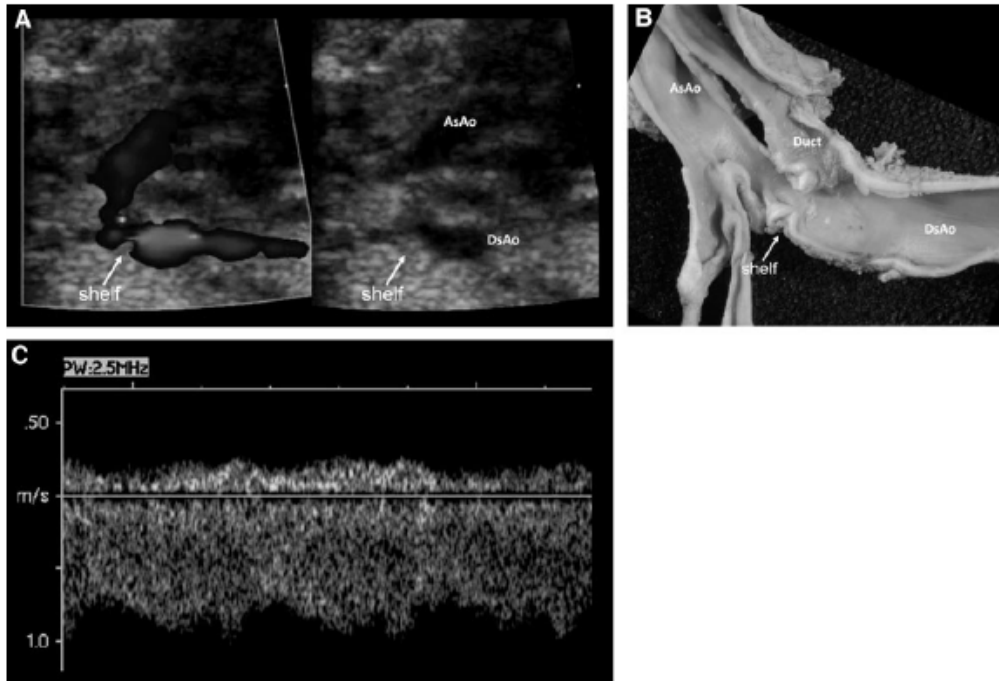


Figure 2. A, Discrete coarctation shelf seen in the aorta of a 27-week-gestation fetus. B, Postmortem specimen of the same fetus born at 38 weeks demonstrating coarctation shelf (baby died of laryngeal atresia with tracheoesophageal fistula). C, Continuous low-velocity Doppler waveform resulting from the obstruction of flow at the isthmus. AsAo indicates ascending aorta; DsAo, descending aorta.

views were examined for the presence of tissue in the posterior part of the arch on sagittal view (a coarctation shelf) (Figure 2A and 2B) and the presence of continuous flow at the isthmus on either the 3-vessel and tracheal or sagittal view (Figure 2C).¹³ The median age at referral was 24 ± 0 gestational weeks (range, 17 ± 3 to 37 ± 4 weeks).

From the case notes, we reviewed our opinion (written at the first examination) and classified the case as highly likely, possibly, or unlikely to have coarctation. Because this is a retrospective study, the postnatal outcome is known, and each case is classified as "surgery" (requiring surgery for coarctation), "surveillance" (because arch hypoplasia was present and coarctation could not be definitely excluded), or "postnatal normal" (antenatally suspected at screening but a definitely normal arch after ductal closure). Because none of the cases in the surveillance group developed arch obstruction requiring surgery, we have considered them to be false-positive diagnoses of coarctation in our subsequent analyses.

Ethical Considerations

We discussed this study with the institutional review board, but specific ethical approval was not necessary because the sonographic measurements were performed as an integral part of routine clinical visits for which informed consent from the patients is a part.

Statistical Analysis

Z scores were created using natural logarithms in a 2-stage process as described previously.¹² We assigned gestational age on the basis of completed weeks of gestation: predicted isthmal or ductal diameter = $\ln(\text{predicted isthmal or ductal diameter}) = m \ln(\text{gestational age}) + c$, and Z score = $[\ln(\text{measured isthmal or ductal diameter}) - \ln(\text{predicted isthmal or ductal diameter})] / \text{root MSE}$,

where m and c are the slope and intercept, respectively, of the regression equations used to predict the cardiac dimensions on the basis of the measured values of gestational age and MSE is mean squared error.

Cross-sectional scores were calculated from the 200 control fetuses and serial Z scores for all but 3 cases of suspected coarctation that attended only once. Receiver-operating characteristic curves were created for measurements of the isthmal and ductal diameters and their ratio from the first examination. Logistic regression was used to test the association between the Z scores, additional cardiac diagnoses, and coarctation. When serial scans were used from the same fetus, a multilevel logistic regression model was used, with the fetus declared as a random effect. Within the multilevel model, an independent variance structure was used, with a unique variance estimate associated with each subject and no between-subject covariances. Multivariable analysis was used to assess the interdependence of significant variables. All analyses were repeated using only scans taken in the third trimester (from >26 weeks' gestation) to see whether their use improved prediction of the requirement for postnatal surgery. The κ value was used to test agreement between the clinical impression (assigned without making measurements) and postnatal outcome.

The authors had full access to and take full responsibility for the integrity of the data. All authors have read and agree to the manuscript as written.

Results

Study Group

One of the 44 babies had an extracardiac malformation (multicystic kidney), and 3 had a chromosomal defect (Turner

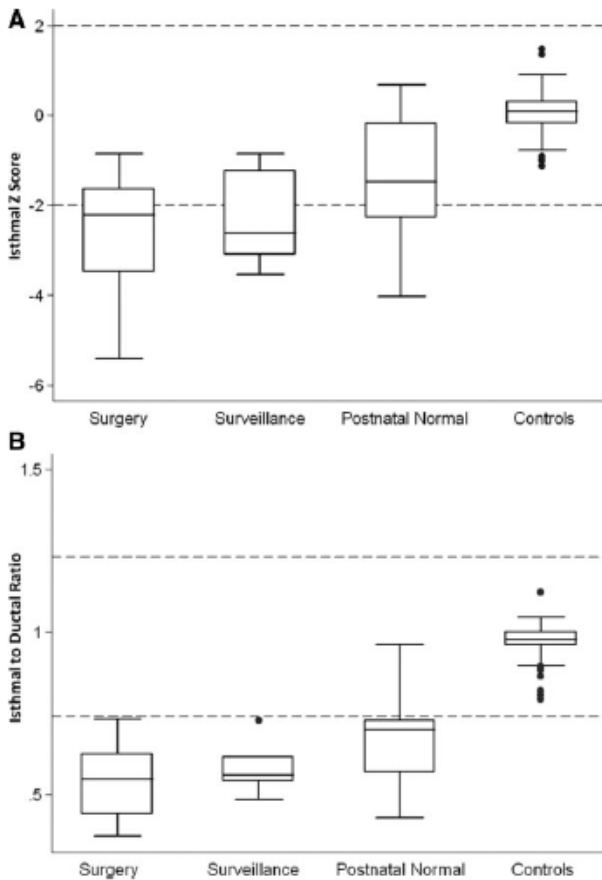


Figure 3. Box-and-whisker plots of the isthmal Z scores (A) and isthmal-to-ductal ratio (B) of cases and controls measured at the first examination and compared by postnatal outcome.

syndrome, 45XO in 2 diagnosed antenatally; trisomy 13 in 1 confirmed after preterm delivery). Twenty of the 44 fetuses with ventricular or great arterial disproportion had coarctation of the aorta; 19 had surgery. The diagnosis of coarctation was confirmed at postmortem for the baby with trisomy 13. Seven babies had long-segment arch hypoplasia and were kept under surveillance to exclude the development of coarctation during the first year; they are considered false-positive diagnoses. The remaining 17 infants had sonographically normal appearances of the aortic arch and were discharged home only after the duct had closed in accordance with our usual practice for management of cases suspected antenatally to be at risk for coarctation. No case has required surgery later than the perinatal period.

Identification of Abnormality

The aortic arch Z scores and the isthmal-to-ductal ratio enabled good separation between the 200 fetuses in the control group and those with disproportion suspected to have coarctation at the first scan (Figure 3A and 3B). The Z scores demonstrated less variance in our control population than in

the population used to derive the scores, which may be explained by the use of a single examiner in this study. We have described that the normal isthmal-to-ductal ratio approaches 1 with a 95% reference range of 0.74 to 1.23 and does not change significantly in the normal fetal population during the second and third trimesters.¹² Of the 44 fetuses in the study group, 40 had an isthmal-to-ductal ratio at first examination <0.74 , and this included all 27 fetuses who required postnatal surgery or surveillance. In contrast, the 4 fetuses with ratios in the normal range were all normal after delivery.

Receiver-operating characteristic curves were used to test the ability of isthmal and ductal Z scores and the isthmal-to-ductal ratio to differentiate between normal outcomes (controls, postnatal normal, and surveillance groups; $n=224$) and cases requiring surgery (20 babies). The isthmal and ductal Z scores showed an excellent area under the curve for the first scan of 0.963 (95% confidence interval [CI], 0.940 to 0.985) and 0.969 (95% CI, 0.949 to 0.990), respectively, whereas measurements of the ductal-diameter Z scores alone were less powerful at 0.726 (95% CI, 0.571 to 0.881; Figure 4).

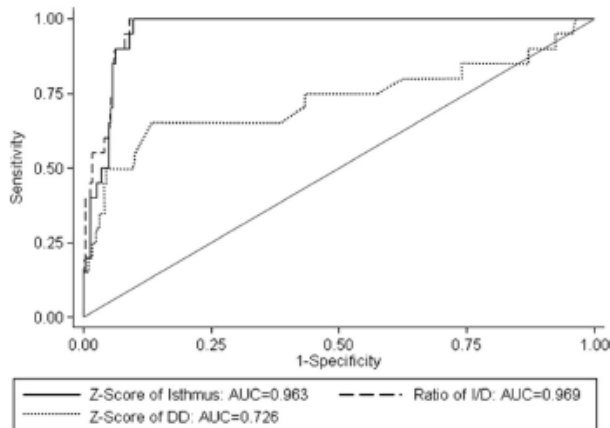


Figure 4. Receiver-operating characteristic curves of the Z scores of the isthmus and ductal diameter and their ratio in 244 fetuses assessing their ability to distinguish those that required surgery at the first examination.

Refining the Diagnosis: Serial Measurements, Isthmal Morphology, and Flow Disturbance

At the first scan, the isthmal-to-ductal ratio of 4 cases of suspected coarctation lay above the lower 95% CI. All proved to be normal after delivery (Figure 5A). The isthmal Z scores of 21 fetuses with disproportion were >-2 and thus lay within the normal range (Figure 5B). Eight required surgery for coarctation of the aorta; 2 were kept under surveillance; and 11 were considered normal after the duct closed. The serial isthmal-to-ductal ratios and isthmal Z scores are shown in Figure 6A and 6B. Those who proved normal postnatally showed an improvement in the ratio or Z score to within the normal ranges during pregnancy but remained below the lower limit of normal or worsened for both parameters in all but 2 of those requiring surgery and 3 kept under surveillance after birth; their isthmal Z scores remained in the low-normal range (Figure 6B). Thus, serial isthmal Z scores and isthmus-to-ductal ratios could distinguish those who would require surgery from those requiring surveillance with odds ratios

(ORs) of 0.52 (95% CI, 0.320 to 0.847) and 0.92 (95% CI, 0.869 to 0.1.052), respectively (Table 2). The higher (less negative) the scores were, the less likely it was that a true coarctation of the aorta existed.

The correlation of the within-subject measurements was reasonably high. Of the 44 patients with suspected coarctation of the aorta, the intraclass correlation coefficient for the isthmus Z scores, ductal Z scores, and isthmal-to-ductal ratio were 0.75, 0.44, and 0.71, respectively. For the cases with confirmed coarctation of the aorta, the intraclass correlation coefficient values were 0.65, 0.50, and 0.63.

Very little difference was found in the area under the receiver-operating characteristic curves created using the first scan only against using all available serial scans. The serial scans showed a marginal decrease in the area under the curve: Isthmal Z scores decreased from 0.963 to 0.958 ($P=0.93$); the isthmal-to-ductal ratio decreased from 0.969 to 0.965 ($P=0.94$); and ductal Z scores decreased from 0.726 to 0.654 ($P=0.25$).

Downloaded from <http://ahajournals.org> by on April 13, 2020

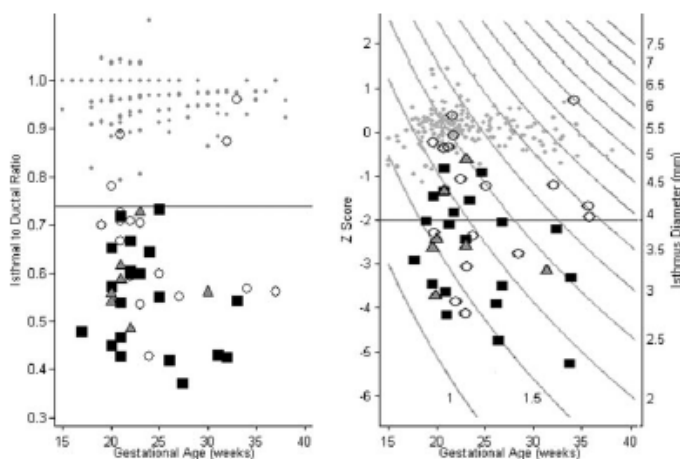


Figure 5. Isthmal-to-ductal ratios (A) and isthmal Z scores (B) of suspected cases of coarctation (n=44) and controls (n=200) measured at the first examination categorized by outcome. Line represents lower 95% CI for reference ranges from cohort studied in Reference 12. ● Indicates controls; ■, surgery; ▲, surveillance; and ○, postnatal normal.

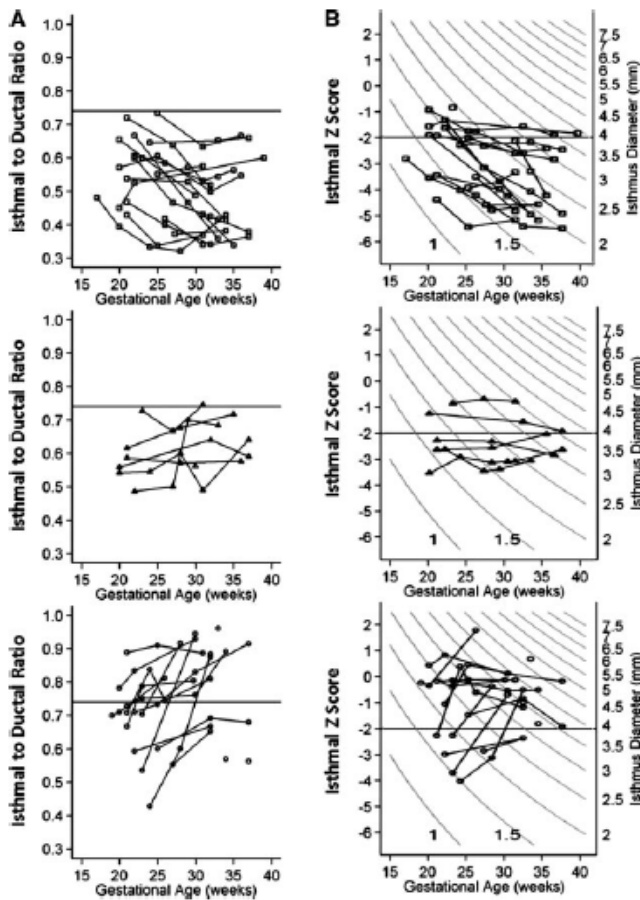


Figure 6. Serial isthmal-to-ductal ratios (A) and isthmal Z scores (B) of the 44 fetuses referred with suspected coarctation. Line represents lower 95% CI for reference range from cohort studied in Reference 12. Upper panels show fetuses requiring postnatal surgery (□); middle panels, those with arch hypoplasia undergoing surveillance (▲); and bottom panels, those who were normal after birth (○).

Downloaded from <http://ahajournals.org> by on April 13, 2020

In addition to growth of the aortic and ductal arches, we analyzed whether visualization of a posterior shelf and/or flow disturbance at the isthmus could increase the cardiologist's ability to predict whether a fetus would require surgery for coarctation of the aorta in the neonatal period (Table 3). All were independent predictors of surgery. Multivariable logistic regression showed that the presence of flow disturbance at the isthmus increased the chances of a true coarctation 15.8-fold in this fetal cohort with cardiac disproportion.

Identification of Abnormality Using Scans at >26 Weeks' Gestation Only

Because serial scans seemed to help distinguish suspicious cases that proved normal after birth from those requiring surgery or surveillance, we analyzed separately the measurements made in the third trimester after 26 weeks. These measurements were as good in separating control cases from those requiring surgery and were useful in separating those

requiring surgery from those requiring surveillance (isthmal Z scores: OR, 0.312; 95% CI, 0.138 to 0.706; $P=0.005$; isthmal-to-ductal ratio: OR, 0.894; 95% CI, 0.826 to 0.967; $P=0.005$).

Likelihood of Coarctation of the Aorta: Additional Echocardiographic Features

The frequency of minor secondary diagnoses such as ventricular septal defect, bicuspid aortic valve, and persistent left superior caval vein to coronary sinus, as well as the presence of a coarctation shelf and flow disturbance in the isthmus, also was documented prospectively (Table 1). Logistic regression showed that the presence of flow disturbance increased the OR for coarctation 22-fold (95% CI, 4.5 to 103; $P<0.001$), a ventricular septal defect increased it slightly to 1.4 (95% CI, 0.5 to 4; $P=0.52$), and the presence of a left superior caval vein reduced the OR to 0.3 (95% CI, 0.1 to 1.0; $P=0.05$). When a shelf was visualized, surgery was required in all but 1, who proved normal postnatally.

Table 2. ORs for Coarctation Using Z Scores of Aortic Isthmus, Arterial Duct, and Ratio of Isthmal to Ductal Diameters for All Gestational Ages

	Measurement	OR	95% CI	P
Surgical cases vs controls and false-positive cases				
All scans used	Isthmal Z score (GA)	0.008	0.000–0.170	0.002
	Ductal Z score (GA)	2.434	1.624–3.648	<0.001
	Isthmal-to-ductal ratio×100	0.792	0.724–0.866	<0.001
Only first scan used	Isthmal Z score (GA)	0.234	0.148–0.369	<0.001
	Ductal Z score (GA)	4.709	2.416–9.177	<0.001
	Isthmal-to-ductal ratio×100	0.876	0.836–0.917	<0.001
Need for surgery vs surveillance				
All scans used	Isthmal Z score (GA)	0.521	0.320–0.847	0.009
	Ductal Z score (GA)	1.258	0.711–2.224	0.430
	Isthmal-to-ductal ratio×100	0.920	0.869–0.973	0.004
Only first scan used	Isthmal Z score (GA)	0.781	0.362–1.685	0.529
	Ductal Z score (GA)	1.101	0.440–2.757	0.837
	Isthmal-to-ductal ratio×100	0.962	0.878–1.052	0.395

GA indicates gestational age.

Likelihood of Coarctation of the Aorta: Clinical Impression

The degree of agreement between the fetal cardiologist’s first clinical impression and outcome was 77%, with a κ value of 0.63 (Table 4). Nineteen of the 24 classified as highly likely to have coarctation of the aorta at the first scan required surgery, and all 12 thought unlikely to have coarctation were normal. The remaining 8 fetuses classified as possibly having coarctation had a mixed outcome: 1 had surgery for coarctation, 3 required surveillance for arch hypoplasia; and 4 were normal.

Discussion

Aortic coarctation is one of the most poorly detected lesions at routine prenatal and postnatal screening and is life-threatening if undiagnosed.^{1–3,6,14} It is important to develop better screening methods both before and after birth. Arch obstruction occurs in the fetus; it is not a postnatal event but a dynamic situation in the fetus.¹⁰ In this unselected series of fetuses with disproportion, we have demonstrated a posterior

shelf and flow disturbance at the isthmus in 45% and 65% cases of true coarctation of the aorta, respectively. Moreover, these were specific signs of coarctation, each occurring in only 1 case that did not require neonatal surgery, giving a specificity of 90% and 94%, respectively. Fetuses who had flow obstruction were 15.8-fold more likely to require surgery for coarctation of the aorta after birth than those with arch hypoplasia. Because all but 1 with a shelf required surgery, we could not calculate an OR to distinguish those requiring surgery from surveillance.

Redistribution of flow at the atrial level from left to right is 1 explanation for disproportion at the 4-chamber and arch views, but growth velocities may alter during gestation and permit sufficient arch growth to avoid surgery. These babies are often born with arch hypoplasia, and late coarctation has been described.¹⁵ Four-chamber disproportion may be subtle, and disproportion may be visible only at the arch views. Therefore, screening using the 3-vessel and tracheal view is important to avoid false-negative results. We also recommend this view to fetal cardiologists because color velocity and energy enhance disproportion and may reveal a holdup of flow at the isthmus, which further increases specificity of diagnosis. Current specificity of diagnosis is poor, and the high false-positive rates of up to 81% reported by fetal cardiologists reviewing suspected cases in tertiary referral centers reflect the cautious postnatal management plan insti-

Table 3. Factors Predictive of Surgery for Aortic Coarctation

Measurement	OR	95% CI	P
Need for surgery vs surveillance			
Isthmal Z score (GA)	0.521	0.320–0.847	0.009
Ductal Z score (GA)	1.258	0.711–2.224	0.430
Isthmal-to-ductal ratio×100	0.920	0.869–0.973	0.004
Flow disturbance	21.706	...	<0.001
VSD	1.407	0.490–4.043	0.526
LSVC	0.349	0.121–1.002	0.050
Multivariable analysis			
Isthmal-to-ductal ratio×100	0.946	0.888–1.008	0.085
Flow disturbance	15.860	...	0.001

VSD indicates ventricular septal defect; LSVC, left superior vena cava.

Table 4. Agreement Between the Clinical Impression of the Fetal Cardiologist After the First Scan and the Postnatal Outcome

Clinical Grading	Outcome		
	Surgery	Surveillance	Postnatal Normal
Highly likely coarctation	19	4	1
Possibly coarctation	1	3	4
Unlikely coarctation	0	0	12

Observed agreement, 77.3%. κ=0.63 (95% CI, 0.42 to 0.85).

Downloaded from http://ahajournals.org by on April 13, 2020

tuted in most centers once antenatal suspicion is raised.⁷⁻⁹ Although this is warranted in view of the severity of the disease if undiagnosed, transfer of place of delivery to a tertiary center and admission to a cardiac unit for surveillance pending closure of the arterial duct are expensive and may be difficult for the family. Poor specificity was confirmed in our study, in which the accuracy of our clinical impression in predicting the need for postnatal arch repair or surveillance was 77% for cases thought either highly likely or highly unlikely to be coarctation but only 50% in borderline cases referred with disproportion. If one considers a true positive to be a case requiring surgery in the perinatal period and not to include those requiring surveillance for arch hypoplasia (cases we believe are important to identify and monitor), the true-positive rate (based on our usual observations and not these study measurements) was 62.5%. We believe this study has identified more objective measurements that will assist us in risk stratification of those suspected to have coarctation at screening in the future.

Screening for Fetal Coarctation

The proportion of neonates admitted to our pediatric cardiac surgical unit last year with coarctation of the aorta requiring surgery who had an antenatal diagnosis of isolated coarctation (as defined in Methods) was 32%, which is better than the 19% reported from other cardiac centers⁶ or the 6% antenatal detection rate described in a regional UK study.³ This is similar to the proportion admitted for surgery with an antenatal detection of ventriculoarterial discordance (simple transposition of the great arteries, 38%) and tetralogy of Fallot (35%). This suggests that our training strategy is beginning to achieve success in reducing the false-negative rate within the screening programs in our referral area. Most referring obstetric units now screen the fetal heart in 5 transverse views, including the 3-vessel and tracheal view,¹¹ in the second trimester. They form a visual appreciation of the relative sizes of the aortic and ductal arches (without making measurements) and refer if the arches are not equivalent in size, if the aortic arch is right sided, or if a persistent left superior caval vein is identified. Disproportion of the arch vessels identifies a population of fetuses at risk of coarctation (or interrupted aortic arch), and increased detection of isolated coarctation is reported in some screening programs as a result of similar training initiatives.¹⁶

Incorporation of the 3-vessel and tracheal view into screening will identify more cases of persistent left superior caval vein with or without 4-chamber disproportion. We and others have published our early observations on the coexistence of a persistent left superior caval vein and congenital heart disease and extracardiac malformations in the fetus. In our previous study, we found that it increased the odds of congenital heart disease to 8.43 and was seen in half of the cases of coarctation requiring surgery.¹⁷⁻¹⁹ We have included the fetuses from this early experience in this study. In this current cohort, half of the fetuses with a persistent left superior caval vein did not have coarctation or arch hypoplasia after birth, and its detection decreased the likelihood of requiring surgery for coarctation to 0.35. This is in agreement with the findings of others who have reported that, although it is seen more

commonly in association with congenital heart disease and important extracardiac malformations such as the CHARGE syndrome or esophageal atresia than in the normal population, the enlarged coronary sinus may lead to 4-chamber disproportion and may increase false-positive diagnoses of coarctation at screening.¹⁵

Applicability of Z Scores to the General Fetal Population

In the present study, we tested our previously developed Z scores derived from measurements of the diameters of the distal aortic isthmus and arterial duct¹² in another population of normal fetuses to assess its general applicability and then in a cohort at risk of coarctation resulting from ventricular or great arterial disproportion. These measurements achieved good separation of the cohort with true coarctation of the aorta from the normal population at the first scan.

Gestational Age at Screening

Earlier gestational age at first examination is known to improve the specificity of diagnosis of coarctation.^{7,8} This was confirmed in our study in which 3 fetuses seen for the first time after 32 gestational weeks (and on only 1 occasion) showed lack of agreement between clinical impression and outcome. However, the predictive power of our serial Z scores and ratios was as good when data recorded only after 26 weeks were analyzed (Table 2). The use of serial isthmal Z scores and the absence of a shelf or flow disturbance in the isthmus would have been helpful in deciding that these 3 cases were true negatives.¹⁰

Study Limitations

Our study was not designed to test the sensitivity and specificity of the measurement of isthmus diameter (alone or related to duct diameter) in a large unselected population of fetuses as part of a screening program but to explore factors that might improve specificity once a diagnosis was suspected. Although these measurements are relatively simple and reproducible in the hands of an experienced fetal cardiologist, we are not recommending their routine use at screening of the low-risk population by sonographers because of time constraints. We believe that the 3-vessel and tracheal view can be used to visually identify fetuses with arch disproportion, thus increasing the sensitivity of screening.

Although 5 of 6 fetuses with proven bicuspid aortic valve had true coarctation of the aorta, we could not confirm a predictive association statistically because of insufficient power in the study. A larger series may confirm this, but antenatal diagnosis of bicuspid aortic valve is not always reliable. The CIs for multivariable logistic regression of flow disturbance at the isthmus were wide, reflecting the small sample size, and have been omitted from Table 3.

In late gestation, the isthmal-to-ductal ratio may be low as a result of ductal dilatation owing to a restrictive oval foramen that causes right-sided enlargement and may reduce the utility of this ratio used in isolation in advanced gestational age.²⁰

Conclusions

Fetal arch obstruction is a dynamic process in which obstruction exists in the setting of rapid fetal growth. Improved

sensitivity of coarctation at screening is possible by including transverse views of the aortic and ductal arches routinely and referring if disproportion is seen. Our first arch Z scores and the isthmal-to-ductal diameter ratio were able to separate fetuses at risk of coarctation from normal fetuses but could not reduce false-positive diagnoses. However, diagnostic specificity was improved by serial Z score and ratio measurements; it was improved 15.8-fold if a flow disturbance in the isthmus was detected. The presence of a shelf also was an excellent indicator of coarctation. We recommend early postnatal surveillance until the duct has closed, even in cases exhibiting good prenatal growth of the isthmus, until more experience has been gained with these indices.

Source of Funding

Dr Matsui is supported by TinyTickers, the fetal heart charity (www.tinytickers.org).

Disclosures

None.

References

- Mellander M, Sunnegårdh J. Failure to diagnose critical heart malformations in newborns before discharge: an increasing problem? *Acta Paediatr*. 2006;95:407–413.
- Abu-Harb M, Hey E, Wren C. Death in infancy from unrecognized congenital heart disease. *Arch Dis Child*. 1994;71:3–7.
- Wren C, Reinhardt Z, Khawaja K. Twenty-year trends in diagnosis of life-threatening neonatal cardiovascular malformations. *Arch Dis Child Fetal Neonatal Ed*. 2008;93:F33–F35.
- Franklin O, Burch M, Manning N, Sleeman K, Gould S, Archer N. Prenatal diagnosis of coarctation of the aorta improves survival and reduces morbidity. *Heart*. 2002;87:67–69.
- Eapen RS, Rowland DG, Franklin WH. Effect of prenatal diagnosis of critical left heart obstruction on perinatal morbidity and mortality. *Am J Perinatol*. 1998;15:237–242.
- Brown KL, Ridout DA, Hoskote A, Verhulst L, Ricci M, Bull C. Delayed diagnosis of congenital heart disease worsens preoperative condition and outcome of congenital heart disease surgery in neonates. *Heart*. 2006;92:1298–1302.
- Sharland GK, Chan KY, Allan LD. Coarctation of the aorta: difficulties in prenatal diagnosis. *Br Heart J*. 1994;71:70–75.
- Brown DL, Durfee SM, Hornberger LK. Ventricular discrepancy as a sonographic sign of coarctation of the fetal aorta: how reliable is it? *J Ultrasound Med*. 1997;16:95–99.
- Stos B, Le Bidois J, Fermont L, Bonnet D. Is antenatal diagnosis of coarctation of the aorta possible [in French]? *Arch Mal Coeur Vaiss*. 2007;100:428–432.
- Hornberger LK, Sahn DJ, Kleinman CS, Copel J, Silverman NH. Antenatal diagnosis of coarctation of the aorta: a multicenter experience. *J Am Coll Cardiol*. 1994;23:417–423.
- Yagel S, Cohen SM, Achiron R. Examination of the fetal heart by five short-axis views: a proposed screening method for comprehensive cardiac evaluation. *Ultrasound Obstet Gynecol*. 2001;17:367–369.
- Pasquini L, Mellander M, Seale A, Matsui H, Roughton M, Ho SY, Gardiner HM. Z-scores of the fetal aortic isthmus and duct: an aid to assessing arch hypoplasia. *Ultrasound Obstet Gynecol*. 2007;29:628–633.
- Gardiner H. *The Influence of Intrauterine Environment on Cardiovascular Development During Fetal Life and After Birth* [thesis]. Lund, Sweden: Lund University; 2002:80.
- Abu-Harb M, Wyllie J, Hey E, Richmond S, Wren C. Presentation of obstructive left heart malformations in infancy. *Arch Dis Child*. 1994;71:F179–F183.
- Head CE, Jowett VC, Sharland GK, Simpson JM. Timing of presentation and postnatal outcome of infants suspected of having coarctation of the aorta during fetal life. *Heart*. 2005;91:1070–1074.
- Tegnander E, Williams W, Johansen OJ, Blaas HG, Eik-Nes SH. Prenatal detection of heart defects in a non-selected population of 30,149 fetuses: detection rates and outcome. *Ultrasound Obstet Gynecol*. 2006;27:252–265.
- Pasquini L, Fichera A, Tan T, Ho SY, Gardiner H. Left superior caval vein: a powerful indicator of fetal coarctation. *Heart*. 2005;91:539–540.
- Berg C, Knappel M, Geipel A, Kohl T, Krapp M, Knopfle G, Germer U, Hansmann M, Gembruch U. Prenatal diagnosis of persistent left superior vena cava and its associated congenital anomalies. *Ultrasound Obstet Gynecol*. 2006;27:274–280.
- Postema PG, Rammeloo LAJ, van Litsenburg R, Rothuis EGM, Hrudu J. Left superior vena cava in pediatric cardiology associated with extra-cardiac anomalies. *Int J Cardiol*. 2008;123:302–306.
- Hagen A, Albig M, Schmitz L, Hopp H, van Baalen A, Becker R, Entezamia M. Prenatal diagnosis of isolated foramen ovale obstruction. *Fetal Diagn Ther*. 2005;20:70–73.

CLINICAL PERSPECTIVE

Undiagnosed coarctation can cause neonatal circulatory collapse and death, but morbidity is reduced by antenatal detection and appropriate perinatal management. Identification of isolated coarctation at obstetric screening is notoriously difficult; one 20-year regional series reported that only 6% of isolated coarctation was detected antenatally. Fetal coarctation is suspected sonographically from disproportion at 4-chamber or great arterial views. Incorporating the 3-vessel and tracheal view into obstetric screening programs enables assessment of the relative sizes of aortic and ductal arches and may reduce false-negative diagnoses, but surveillance of false-positives cases, estimated at ~30%, incurs hospital costs. This article analyzes the ability of measurements and Doppler in the arches to improve diagnostic specificity. We report that the receiver-operating characteristic curves of isthmal Z scores and the isthmal-to-ductal ratio can identify cases requiring surgery at first examination and that serial measurements allow separation of normal arches from those requiring surgery or observation during infancy. Continuous isthmal Doppler flow increased the likelihood ratio of coarctation 16-fold, and visualization of a coarctation shelf was specific for those requiring surgery. Ventricular septal defect and bicuspid aortic valve were seen in 50% and 25% of true coarctation, respectively, but did not increase the specificity of diagnosis, and left superior vena cava generated false-positive cases. False-negative diagnoses of coarctation may be reduced by appreciating arch disproportion at obstetric screening using the 3-vessel and tracheal view, and false-positive diagnoses can be reduced in the tertiary center by serial measurements and detection of isthmal flow disturbance or coarctation shelf.

3.0.5 ANNEX 10

Jowett V, Aparicio P, Santhakumaran S, Seale A, **Jicinska H**, Gardiner H M

Sonographic predictors of surgery in fetal coarctation of the aorta

Ultrasound in Obstetrics and Gynecology 2012; 40:47-54

Impact factor is 2012 = 3.557

Main points of the publication:

The aim of the study was to determine whether within a group of cases prenatally diagnosed with COA, four sonographic features — the isthmus diameter Z-scores, the ratio of isthmus to duct diameters, the visualization of coarctation of the aortic shelf, and the isthmus flow disturbance — could differentiate cases that would require neonatal surgery.

An isthmus diameter score < -2 was the most powerful predictor for surgery. An isthmus to duct ratio < 0.74 on the last scan required surgery in all patients, the aortic shelf was identified in 66% of cases, and isthmus flow disturbance was present in 50% of fetuses with COA. In this study the combination of these four parameters allowed us to predict COA correctly in 81% of cases at the first assessment and in 86% of cases using serial measurements. The incorporation of these four parameters into the prenatal assessment of fetal COA in tertiary centres was proposed by the authors.

The candidate contributed to the manuscript and with cases to this study.

Sonographic predictors of surgery in fetal coarctation of the aorta

V. JOWETT*†, P. APARICIO†, S. SANTHAKUMARAN‡, A. SEALE†, H. JICINSKA§
and H. M. GARDINER*†

*Institute of Reproductive and Developmental Biology, Faculty of Medicine, Imperial College at Queen Charlotte's and Chelsea Hospital, London, UK; †Royal Brompton and Harefield Foundation NHS Trust, London, UK; ‡Department of Medicine, Faculty of Medicine, Imperial College London, London, UK; §University Hospital and Masaryk University, Brno, Czech Republic

KEYWORDS: aortic coarctation; coarctation shelf; fetus; surgery

ABSTRACT

Objectives Isolated fetal coarctation of the aorta (CoA) has high false-positive diagnostic rates by cardiologists in tertiary centers. Isthmal diameter Z-scores (I), ratio of isthmus to duct diameters (I:D), and visualization of CoA shelf (Shelf) and isthmal flow disturbance (Flow) distinguish hypoplastic from normal aortic arches in retrospective studies, but their ability to predict a need for perinatal surgery is unknown. The aim of this study was to determine whether these four sonographic features could differentiate prenatally cases which would require neonatal surgery in a prospective cohort diagnosed with CoA by a cardiologist.

Methods From 83 referrals with cardiac disproportion (January 2006 to August 2010), we identified 37 consecutive fetuses diagnosed with CoA. Measurements of I and I:D were made and the presence of Shelf or Flow recorded. Sensitivity, specificity and areas under receiver–operating characteristics curves, using previously reported limits of $I < -2$ and $I:D < 0.74$, as well as Shelf and Flow were compared at first and final scan. Associations between surgery and predictors were compared using multivariable logistic regression and changes in measurements using ANCOVA.

Results Among the 37 fetuses, 30 (81.1%) required surgery and two with an initial diagnosis of CoA were revised to normal following isthmal growth, giving an 86% diagnostic accuracy at term. The median age at first scan was 22.4 (range, 16.6–7.0) weeks and the median number of scans per fetus was three (range, one to five). $I < -2$ at final scan was the most powerful predictor (odds ratio, 3.6 (95% CI, 0.47–27.3)). Shelf was identified in 66% and Flow in 50% of fetuses with CoA.

Conclusion Incorporation of these four sonographic parameters in the assessment of fetuses with suspected CoA at a tertiary center resulted in better diagnostic precision regarding which cases would require neonatal surgery than has been reported previously. Copyright © 2012 ISUOG. Published by John Wiley & Sons, Ltd.

INTRODUCTION

Antenatal diagnosis of isolated coarctation of the aorta (CoA), even by experts, lacks sensitivity at screening and specificity¹. This leads to increased morbidity and mortality in affected neonates without a prenatal diagnosis, who often collapse and require resuscitation before surgery². In the tertiary fetal cardiology setting there is a high false-positive rate, resulting in a significant proportion of fetuses which do not eventually require surgery being scanned throughout pregnancy and transferred and assessed at a cardiac unit following delivery.

We have previously published a method that compared the diameters of the aortic and ductal arches in a normal fetal population and derived reference ranges³, reporting that Z-scores of the aortic isthmus diameter and the isthmal to duct diameters ratio of raw measurements could be used at screening to select for further evaluation those lying below the normal range, thus potentially increasing the sensitivity of screening for CoA. We used these measurements retrospectively in a cohort of fetuses referred with suspected CoA and in whom we knew the outcome, to assess the diagnostic ability of this approach compared with subjective assessment of disproportion⁴, reporting that only 62.5% of those thought to have CoA by the cardiologist actually required surgery in the neonatal period.

In this prospective study we analyzed whether four sonographic parameters ('predictors': isthmal Z-scores (I);

Correspondence to: Dr H. M. Gardiner, Institute of Reproductive and Developmental Biology, Faculty of Medicine, Imperial College, Du Cane Road, London, W12 0HS, UK (e-mail: helena.gardiner@imperial.ac.uk)

Accepted: 13 March 2012

ratio of isthmus to duct (I:D); visualization of CoA shelf (Shelf); and visualization of continuous diastolic flow at the isthmus (Flow) could predict at three time points in pregnancy (before 24 weeks; at first scan after 24 weeks; and at final scan) the need for postnatal surgery in fetuses thought by a fetal cardiologist to have CoA because of disproportion detected at screening in the four-chamber and/or three vessels and trachea view.

METHODS

This study was performed at Queen Charlotte's and Chelsea Hospital, Imperial College London, UK and University Hospital and Masaryk University, Brno, Czech Republic. We recruited 43 fetuses which had been referred sequentially between January 2006 and August 2010, with a primary diagnosis of CoA made by a cardiologist at one of two tertiary centers. Indication for referral was suspected congenital heart disease ($n=39$), family history ($n=2$), increased nuchal translucency thickness ($n=1$) and diabetes mellitus type 1 ($n=1$). During the same time interval an additional 40 fetuses were referred with suspected CoA on obstetric ultrasound, but assessment by the fetal cardiologist showed arch measurements within the normal range³ and neither Shelf nor Flow. These were therefore not felt to have CoA and were excluded from the study, but their postnatal outcome was checked on the national Central Cardiac Audit Database (www.ccad.org/congenital) to ensure that they did not undergo surgery for CoA during the first year after delivery. A postnatal echo was not recommended routinely but postnatal evaluation was offered in a report generated following the fetal consultation if there were any postnatal concerns.

CoA was defined as concordant atrioventricular and ventriculoarterial connection with hypoplasia of the isthmus $< Z$ -score -2 , presence of a CoA shelf (Shelf) or presence of continuous diastolic flow at the isthmus (Flow). The diagnosis of likely CoA was made if any one of the four predictors assessed in this study was present, i.e. I or I:D below the lower limit of normal or if there was evidence of Shelf or Flow. We included fetuses with associated ventricular septal defect, bicuspid aortic valve and persistent left superior caval vein⁴, but not those with other cardiac abnormalities. We did not exclude fetuses with aneuploidy or extracardiac malformations, but five cases which suffered intrauterine death or termination of pregnancy without confirmed outcome at postmortem were excluded from analysis and one with diaphragmatic hernia was excluded as the disproportion was thought to be secondary to the extracardiac abnormality rather than a marker of CoA. Therefore, 37 fetuses with a fetal diagnosis of CoA were enrolled into the study.

The institutional review board considered ethical approval unnecessary because the sonographic measurements were performed as an integral part of routine clinical visits, for which informed consent had been obtained from the women.

Echocardiography

Fetal echocardiography was performed on a GE Voluson E8 (GE Medical Systems, Zipf, Austria) ultrasound machine using a 4-8-D RAB probe. The four predictors comprised serial arch diameter measurements in the three vessels and trachea view, and presence of Shelf and Flow. Z-scores of the isthmus were calculated based on gestational age as described previously³. Sagittal views of the aortic arch were examined for Shelf (Figure 1) and both views were examined with color and power Doppler to detect Flow. No alteration from routine settings was required to detect Flow. If detected, Flow was confirmed on pulsed Doppler (Figure 2). Fetuses were examined at approximately monthly intervals and perinatal management was informed by objective data from the four predictors.

Outcome measures

The primary outcome measure was the requirement for CoA surgery perinatally.

Statistical analysis

All analyses were carried out using Stata version 11.1 (Stata Statistical Software; StataCorp, College Station, TX, USA). Mean and standard deviation of I, I:D and gestational age at scan were calculated for neonates who required surgery and those who did not, and differences compared using *t*-tests for first and last scan. Median and range were determined and Mann-Whitney *U*-tests were used if variables were not normally distributed. For the binary predictors (Shelf, Flow, $I < -2$, $I:D < 0.74$)³ the percentages in each group were calculated and the chi-square test, or Fisher's exact test for cell counts < 5 , was used to test for differences.

The relationship between predictors at first and last scan and outcome was assessed by calculating sensitivity, specificity and area under the receiver-operating characteristics (ROC) curves (AUC) using previously defined cut-offs³ of < -2 for I and < 0.74 for I:D, as well as for the binary variables (Shelf and Flow).

Differences in predictive power at first and last scan were tested using McNemar's test. Differences in AUC were tested using the *roccomp* procedure in Stata Statistical Software version 11 (StataCorp LP, 2009, College Station, TX, USA)⁵. Logistic regression was used to test and compare associations between outcome and predictors at first and last scan.

We investigated whether the change in measurements made over time was associated with the need for surgery. The change in I and I:D as continuous variables from first to last scan was compared using ANCOVA, with last scan measurement as the dependent variable, need for surgery as the independent variable and adjusting for measurement at first scan as this is preferable to using change as an outcome⁶. For fetuses that were

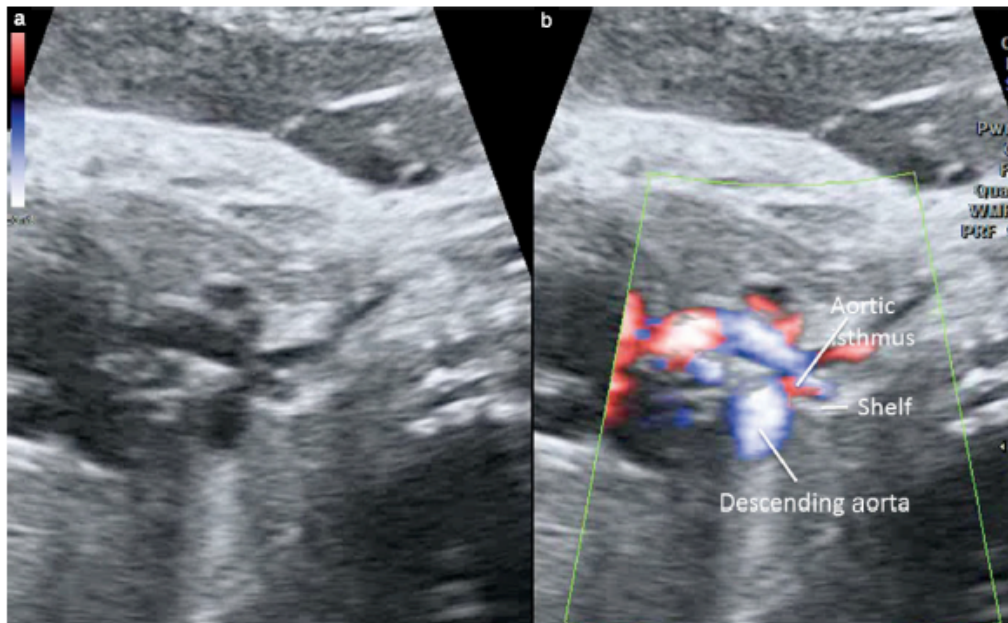


Figure 1 Sagittal view of the aortic arch in a fetus showing a posterior shelf on two-dimensional ultrasound (a) and color flow mapping (b).

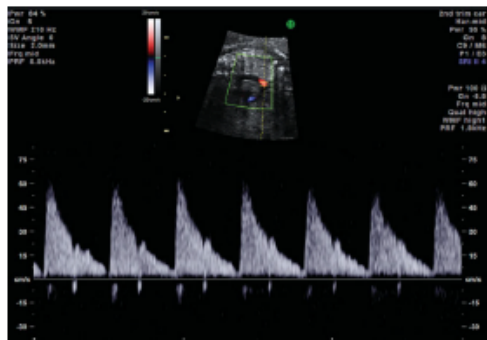


Figure 2 Doppler flow profile from the isthmus (sagittal view), showing continuous flow throughout systole and diastole.

scanned before 24 weeks, the results of the first scan before 24 weeks and the first scan after 24 weeks were compared to determine whether diagnostic properties improved.

Reproducibility of measurements was assessed by calculating the limits of agreement⁷, i.e. the range in which 95% of the differences between pairs of measurements on the same subject carried out by two different observers were expected to lie. Based on 10 pairs of measurements carried out by V.J. and H.M.G., the interobserver variability showed a mean difference of 0.06 (95% limits of agreement, -0.68 to 0.56).

RESULTS

Of the 37 fetuses enrolled into the study, at a median (range) gestational age of 22.4 (16.6–37.1) weeks, 30 (81%) required surgery and seven were false-positive. A median of three (range, one to five) scans was performed per fetus. Two fetuses did not have I:D measured at the first scan and one did not have Shelf recorded.

Twenty-three of the 30 (77%) requiring surgery were assessed before 24 weeks, compared with two of the seven (29%) that did not ($P = 0.03$). Overall, eight fetuses had persistent left superior vena cava (LSVC) (three in cases false-positive for CoA) and nine had small ventricular septal defects (VSD) (four in false-positive group; an additional one was undetected prenatally), while six of the 30 cases of true CoA had an associated bicuspid valve reported.

A comparison of measurements for I and I:D and the percentage lying below the lower limit of normal at the first scan and the last scan before delivery is shown in Table 1. All patients requiring surgery had an I:D ratio < 0.74 on the final scan. Shelf was detected in 19/29 (65.5%) fetuses requiring surgery and in 3/7 (43%) that did not ($P = 0.4$). Flow was seen in half of those requiring surgery (15/30, 50%) and in three of the seven (43%) that did not ($P > 0.9$).

Predictive power of echocardiographic parameters

Table 2 shows the predictive properties of Shelf, Flow, I and I:D. There was no significant difference in the

Table 1 Comparison of measurements at first and last scan in those requiring surgery with those thought normal after delivery

Measurement	No surgery (n=7)	Surgery (n=30)	P
First scan			
Gestational age (weeks)	24.3 (19.6–30)	22.0 (16.6–37.1)	0.14
Isthmal Z-score	-2.67 ± 0.57	-2.78 ± 1.7	0.87
Isthmal Z-score < -2	86 (6/7)	77 (23/30)	0.6
Isthmus to duct ratio	0.57 ± 0.11	0.57 ± 0.18	0.95
Isthmus to duct ratio < 0.74	100 (6/6)	90 (26/29)	0.68
Last scan			
Gestational age (weeks)	34.4 (26.9–36.7)	35.0 (22.4–38.4)	0.91
Isthmal Z-score	-2.89 ± 1.5	-3.44 ± 1.8	0.46
Isthmal Z-score < -2	71 (5/7)	90 (27/30)	0.20
Isthmus to duct ratio	0.57 ± 0.16	0.52 ± 0.12	0.28
Isthmus to duct ratio < 0.74	80 (6/7)	100 (29/29) ^a	N/A

Data presented as median (interquartile range), mean ± SD or % (n). ^aAll fetuses requiring surgery had isthmus to duct ratio < 0.74 by the last scan. N/A, not applicable.

Table 2 Predictive properties of sonographic features at first and last scan

Predictor	Sensitivity (% (95% CI))	Specificity (% (95% CI))	AUC (95% CI)
Presence of shelf (Shelf)			
Any scan	65.5 (45.7–82.1)	57.1 (18.4–90.1)	0.61 (0.40–0.83)
Presence of continuous flow (Flow)			
Any scan	50.0 (31.3–68.7)	57.1 (18.4–90.1)	0.54 (0.32–0.75)
Isthmal Z-score			
First scan	76.7 (57.7–90.1)	14.3 (0.4–57.9)	0.45 (0.3–0.61)
Last scan	90.0 (73.5–97.9)	28.6 (3.7–71.0)	0.59 (0.40–0.78)
P	0.29	> 0.99	0.32
Isthmus to duct ratio			
First scan	89.7 (72.6–97.8)	0 (0–45.9)	0.45 (0.39–0.50)
Last scan	100 (88.1–100)	14.3 (0.4–57.9)	0.57 (0.43–0.71)
P	0.25	> 0.99	0.5

AUC, area under the receiver–operating characteristics curve.

predictive ability of I and I:D between the first and last fetal scans. Table 3 presents the odds ratios (OR) for the four predictors. The OR for all predictors except for I at first scan was > 1; however, none was significant and the confidence intervals were very wide.

Predictive power of serial measurements

While there was an improvement in sensitivity of I:D on serial scans, with 100% sensitivity on the final scan, ANCOVA analysis showed that there was no difference in the change in I and I:D between fetuses who required surgery and those who did not (difference in I at last scan, adjusting for first scan = -0.50 (95% CI, -1.9 to 0.9), $P = 0.48$; difference in I:D at last scan, adjusting for first scan = -0.02 (95% CI, -0.14 to 0.10), $P = 0.75$).

Predictive accuracy of combinations of factors

The incremental value of combinations of factors was examined (Table 4). Alone, Shelf had the highest AUC (0.61). By combining this with I there was a modest increase in AUC, to 0.64 (95% CI, 0.44–0.84).

Table 3 Association between need for surgery and the four predictors at first and last scans

Predictor	Univariable regression: OR (95% CI)	P
Shelf	2.53 (0.47–13.6)	0.28
Flow	1.33 (0.25–7.01)	0.73
Isthmal Z-score < -2		
First scan	0.55 (0.56–5.35)	0.61
Last scan	3.6 (0.47–27.3)	0.22
Isthmus to duct ratio < 0.74		
First scan	N/A ^a	0.12
Last scan	N/A ^a	

^aAll fetuses requiring surgery had isthmus to duct ratio < 0.74 by the last scan. N/A, not applicable; OR, odds ratio.

Predictive accuracy before 24 weeks

Of the 25 fetuses scanned before 24 weeks, only two (8%) did not require surgery, so estimates of specificity and ROC were not reliable. Although the sensitivity of I and I:D increased between the first and last scans

Table 4 Predictive accuracy of combinations of echocardiographic signs at first scan

Combination of predictors	Sensitivity (% (95% CI))	Specificity % (95% CI))	AUC (95% CI)
Two signs			
Shelf + Flow	36.7 (19.9–56.1)	57.1 (18.4–90.1)	0.47 (0.25–0.69)
Shelf + I	56.7 (37.4–74.5)	71.4 (6.3–29.0)	0.64 (0.44–0.84)
Shelf + I:D	60.0 (40.6–77.3)	57.1 (18.4–90.1)	0.59 (0.37–0.80)
Flow + I	50.0 (31.3–68.7)	71.4 (0.3–29.0)	0.61 (0.40–0.81)
Flow + I:D	43.3 (25.5–62.6)	57.1 (18.4–90.1)	0.50 (0.28–0.72)
I + I:D	70.0 (50.6–85.3)	28.6 (3.7–71.0)	0.49 (0.29–0.69)
Three signs			
Shelf + Flow + I	36.7 (19.9–56.1)	71.4 (29.0–96.3)	0.54 (0.34–0.74)
Shelf + Flow + I:D	33.3 (17.3–52.8)	57.1 (18.4–90.1)	0.45 (0.24–0.67)
Shelf + I + I:D	53.3 (34.3–71.7)	71.4 (29.0–96.3)	0.62 (0.42–0.83)
Flow + I + I:D	43.3 (25.5–62.6)	71.4 (29–96.3)	0.57 (0.37–0.78)
Four signs			
Shelf + Flow + I + I:D	33.3 (17.3–52.8)	71.4 (29–96.3)	0.52 (0.32–0.72)

AUC, area under receiver–operating characteristics curve; Flow, presence of continuous flow; I, isthmal Z-score; I:D, isthmus to duct ratio; Shelf, presence of shelf.

(I from 73.9% (95% CI, 51.6–89.8) to 81.8% (95% CI, 59.7–94.8) and I:D from 86.4% (95% CI, 65.1–97.1) to 95.2% (95% CI, 76.2–99.9)), these increases were not significant ($P = 0.73$ for I, $P = 0.63$ for I:D).

Presence of abnormal karyotype and extracardiac abnormalities

Fourteen of the 37 (37.8%) women accepted prenatal karyotype testing. All results were normal. Among those declining prenatal testing was one case of trisomy 13 (with CoA) and one case of trisomy 21 (without CoA, with VSD) diagnosed postnatally. All children undergoing surgery had normal karyotype.

Seven of the 37 (18.9%) fetuses had additional sonographic findings detected prenatally, including increased nuchal translucency, single umbilical artery, two-vessel cord and cerebellar hypoplasia or cerebral ventriculomegaly. Three chromosomally normal fetuses had extracardiac abnormalities confirmed postnatally: one with duodenal atresia, one with tracheo-esophageal fistula and one with multiple abnormalities including scoliosis and coloboma. Two fetuses had brain abnormalities confirmed on fetal magnetic resonance imaging, associated with trisomy 21 and trisomy 13.

Characteristics of those not requiring surgery

Table 5 details the characteristics of the seven fetuses that did not require surgery postnatally. Six fetuses had a tapering or hypoplastic arch and one did not. Of these six, two showed improved growth on serial scans, reaching an isthmal Z-score within the normal range by term and so were thought unlikely to have CoA. Four had bilateral superior caval veins and five had a VSD identified prenatally (four of which were confirmed postnatally). Two fetuses had trisomies (21 and 13). The only fetus without an additional finding on prenatal ultrasound was found to have a small ventricular septal defect (not seen

on fetal echo) after birth. The postnatal echo showed a normal arch in four babies, two had arch hypoplasia and one had an area of isthmal narrowing without CoA. All children were reviewed in a cardiac clinic until they were 1 year old.

DISCUSSION

Making a prenatal diagnosis of CoA requires the combination of high sensitivity at screening (due to the serious consequences of not detecting this lesion before birth⁸) and high specificity following referral to a tertiary center. Currently, neither of these is satisfactory, with less than one third of cases of CoA being detected at screening² and a high rate of false-positive diagnosis (low specificity) by fetal cardiologists. False-positive diagnosis can cause unnecessary parental anxiety, alteration of perinatal plans that are disruptive to the family and unnecessary investigations and hospital stay for the baby in a tertiary cardiac center¹, incurring costs.

In this prospective study we have demonstrated that the use of four parameters (I, I:D, Shelf and Flow) in combination achieves superior diagnostic precision (86%) in the detection of true fetal CoA requiring perinatal surgery compared with our previously published clinical estimate of 62.5%⁴. Shelf, Flow and I had ORs > 1 at the final scan and all patients with CoA postnatally had an I:D ratio below the lower limit of normal. Application of these sonographic criteria by the fetal cardiologist during serial review may increase diagnostic specificity and improve clinical management. Furthermore, we confirmed that we could safely exclude from further review approximately half of the original prenatal referrals with suspected CoA using these sonographic parameters as none had CoA diagnosed during infancy. Statistical analysis could not define a single 'best predictor' of CoA; however, measurement of the isthmus and duct allow comparison of serial Z-scores (measurements corrected for gestation or size)

Table 5 Characteristics of the seven fetuses with unobstructed aortic arch postnatally

Fetus	Prenatal echo: arch morphology	Shelf	Diastolic flow	Additional prenatal features	Isthmal Z-score (first scan; last scan)	Postnatal features
1	No arch hypoplasia	No	No	Left SVC, bicuspid AoV	-2.5; -1.4	Normal arch, left SVC to coronary sinus
2	Tapering arch	Yes	Yes	Left SVC, multiple VSD, extracardiac abnormalities	-3.5; -2.8	Normal arch, left SVC to coronary sinus, multiple VSD, dysmorphic features
3	Tapering arch on early scans, improved growth on later scans	Yes	Yes	Left SVC, VSD	-3.26; -1.72	Mild narrowing at isthmus but no CoA, left SVC to coronary sinus, perimembranous outlet VSD
4	Tapering arch on later scans	Yes	Yes	VSD	-1.98; -5.98	Mild arch hypoplasia without CoA, apical muscular VSD, trisomy 21
5	No tapering and improved growth of arch	No	No	VSD (on early scan; not seen on later scan or postnatally)	-2.2; -2.2*	Normal arch, no VSD
6	Arch hypoplasia	No	No	Left SVC, VSD	-2.9; -3.4	Normal arch, malaligned VSD, trisomy 13
7	Arch hypoplasia	No	No	None	-2.3; -2.7	Hypoplastic arch without CoA, VSD, premature delivery at 28 weeks

*Z-scores measured between these time points were more negative. AoV, aortic valve; CoA, coarctation of the aorta; SVC, superior vena cava; VSD, ventricular septal defect.

and in two fetuses we correctly revised our opinion to their being at low risk of CoA because of improvement of isthmal measurements by term.

Previous studies have used sagittal or coronal views of the aortic arch and focused on measurements of the arch^{9,10} or on the ratio of transverse arch diameter to diameter of head and neck vessels¹¹. The diagnostic accuracy in our study (86%) was higher than the 62%¹ and 30%¹² reported previously. We preferred the three vessels and trachea view in our examination protocol because it is the ideal plane in which to compare aortic and ductal arches and measure I and I:D (Figures 3a and 4a). However, Shelf and Flow are best identified in the sagittal view of the aortic arch (Figures 3b and 4b) and in this study in two-thirds of cases of true CoA we observed Shelf and in 50% we observed Flow on at least one examination.

The high level of false-positive diagnoses reported in most series and the finding of Shelf in only two-thirds of our current series of true CoA cases is not surprising as tubular hypoplasia is the most common morphology in neonatal CoA, although a shelf may co-exist. Tubular hypoplasia may also occur without obstruction^{4,12}. We did not recognize Shelf in one case with CoA that had an aneurysmal duct covering the isthmus in all sonographic planes. There seems to be a learning curve in the examination of the fetal arch, as in our previous report we recognized a smaller proportion (45%) of fetuses with true CoA to have Shelf⁴. Conversely, identification of Shelf in three of our cases that did not require surgery is interesting. One was diagnosed with trisomy 21 postnatally (an unusual association with CoA) (Figure 1). This fetus had an apical muscular VSD on postnatal scan and isthmal narrowing without CoA; the second had Shelf described

on the initial scan, followed by improvement in measurements to within the normal range as the pregnancy progressed, with Shelf not visible in later scans; the third had multiple abnormalities, including abnormalities of the thoracic spine compatible with CHARGE syndrome.

Pitfalls in the correct diagnosis of fetal CoA in previous studies included fetuses having additional sonographic findings, such as VSD and persistent LSVC that may be a cause of ventricular disproportion particularly in the early fetus because dilatation of the coronary sinus impairs left ventricular filling^{13,14}. In this study, persistent LSVC was seen as commonly in those with as in those without CoA, as we have reported previously⁴. Bicuspid aortic valve was diagnosed more frequently in true CoA; however, difficulty in confirmation may make this well-recognized association less helpful prenatally.

The rate of karyotypic abnormalities in this study was lower than that in other published reports¹⁵, likely due to the majority of fetuses being referred following first-trimester screening; chromosomally abnormal pregnancies may already have been terminated.

While statistical analysis of serial arch measurements did not show improved diagnostic accuracy, two fetuses had good aortic arch growth and our counseling was altered to reflect this; neither required postnatal surgery, giving an overall diagnostic accuracy of 86%. This is in accord with our previous retrospective study in which those not requiring surgery tended to show improved growth of the aortic arch by term⁴. We arrange serial follow-up for any fetus found to have any one of the four sonographic parameters outside the normal range and determine perinatal management (place of delivery and postnatal assessment) if abnormality of any of the four

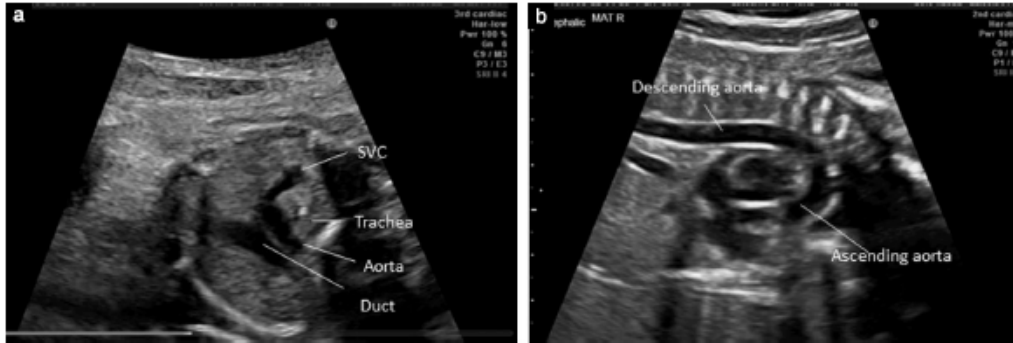


Figure 3 Appearance in a normal fetus: (a) three vessels and trachea view, with aorta and duct passing to the left of the trachea and a single right superior caval vein (SVC); (b) sagittal view of aortic arch.

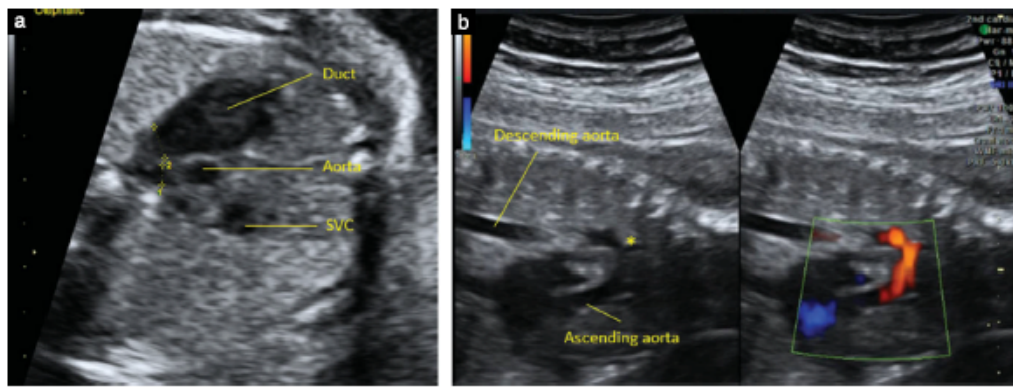


Figure 4 Appearance in a fetus with coarctation of the aorta: (a) three vessels and trachea view, showing marked disproportion of the great arteries; (b) two-dimensional ultrasound and power Doppler sagittal view of aortic arch, showing hypoplasia of the transverse arch with a posterior shelf at the isthmus (*). SVC, superior vena cava. Calipers in (a) show measurement of aortic isthmus and ductal arch diameters.

predictors persists. If the parameters normalize during follow-up we arrange local delivery and postnatal assessment, provided that there is appropriate local expertise to assess the neonate safely until the duct has closed.

Limitations

The accuracy of measurements must be interpreted with caution when arch views are suboptimal, particularly in the very small fetus or when the arch is very narrow, although in the latter case CoA is more likely. Use of the I:D may be misleading in late gestation due to ductal dilatation and tortuosity. Augmented diastolic isthmal flow can be identified using standard machine settings, and recognition that it might be present is important. Ultrasound manufacturers commit to a measurement accuracy of 1 mm for small structures (GE Healthcare, pers. comm.), so accuracy may be reduced in early pregnancy. The lack of statistical confirmation of what we believe to be a true clinical scenario is likely due to the limited size of this study; there was limited power to

examine the change in predictive power with gestational age at scan due to the small number of babies and the variation in the number and timing of scans.

Conclusions

We propose incorporation into the prenatal assessment of fetal CoA in the tertiary setting the following four sonographic parameters: $I:D < 0.74$, $I < -2$ and presence of Shelf and/or Flow. In our study this combination allowed us to predict CoA correctly in 81% of cases at first assessment and serial measurements enabled us to revise our assessment in two cases, resulting in an accuracy of 86% overall.

ACKNOWLEDGMENTS

This work was supported by the Richard and Jack Wiseman Trust, Tiny Tickers charity (www.tinytickers.org), the NIHR Biomedical Research Centre funding scheme

and the Genesis Research Trust, Institute of Reproductive Biology, Queen Charlotte's and Chelsea Hospital, London, UK.

REFERENCES

1. Sharland GK, Chan KY, Allan LD. Coarctation of the aorta: difficulties in prenatal diagnosis. *Br Heart J* 1994; 71: 70–75.
2. Brown KL, Ridout DA, Hoskote A, Verhulst L, Ricci M, Bull C. Delayed diagnosis of congenital heart disease worsens preoperative condition and outcome of surgery in neonates. *Heart* 2006; 92: 1298–1302.
3. Pasquini L, Mellander M, Seale A, Matsui H, Roughton M, Ho SY, Gardiner HM. Z-scores of the fetal aortic isthmus and duct: an aid to assessing arch hypoplasia. *Ultrasound Obstet Gynecol* 2007; 29: 628–633.
4. Matsui H, Mellander M, Roughton M, Jicinska H, Gardiner HM. Morphological and physiological predictors of fetal aortic coarctation. *Circulation* 2008; 118: 1793–1801.
5. DeLong ER, DeLong DM, Clarke-Pearson DL. Comparing the areas under two or more correlated receiver operating characteristic curves: a nonparametric approach. *Biometrics* 1988; 44: 837–845.
6. Vickers AJ, Altman DG. Statistics notes: Analysing controlled trials with baseline and follow up measurements. *BMJ* 2001; 323: 1123–1124.
7. Bland MJ, Altman D. Statistical methods for assessing agreement between two methods of clinical measurement. *The Lancet* 1986; 327: 307–310.
8. Abu-Harb M, Hey E, Wren C. Death in infancy from unrecognized congenital heart disease. *Arch Dis Child* 1994; 71: 3–7.
9. Hornberger LK, Sahn DJ, Kleinman CS, Copel J, Silverman NH. Antenatal diagnosis of coarctation of the aorta: a multicenter experience. *J Am Coll Cardiol* 1994; 23: 417–423.
10. Head CE, Jowett VC, Sharland GK, Simpson JM. Timing of presentation and postnatal outcome of infants suspected of having coarctation of the aorta during fetal life. *Heart* 2005; 91: 1070–1074.
11. Tegnander E, Williams W, Johansen OJ, Blaas HG, Eik-Nes SH. Prenatal detection of heart defects in a non-selected population of 30,149 fetuses—detection rates and outcome. *Ultrasound Obstet Gynecol* 2006; 27: 252–265.
12. Matsui H, Gardiner HM. Coarctation of the aorta: fetal and postnatal diagnosis and outcome. *Expert Rev Obstet Gynecol* 2009; 4: 191–200.
13. Hornung TS, Heads A, Hunter AS. Right ventricular dilatation in the fetus: a study of associated features and outcome. *Pediatr Cardiol* 2001; 22: 215–217.
14. Pasquini L, Fichera A, Tan T, Ho SY, Gardiner H. Left superior caval vein: a powerful indicator of fetal coarctation. *Heart* 2005; 91: 539–540.
15. Tennstedt C, Chaoui R, Korner H, Dietel M. Spectrum of congenital heart defects and extracardiac malformations associated with chromosomal abnormalities: results of a seven year necropsy study. *Heart* 1999; 82: 34–39.

4. Rare morphological abnormalities

Thanks to the development of new ultrasound methods, we occasionally detect very rare and unusual structural abnormalities in the fetus. In this part, some of them are presented.

4.0.1 ANNEX 11

Jicinska H, Tax P, Padr R, Jicinsky M, Marek J

Rare congenital umbilical arteriovenous malformation

European Heart Journal Cardiovascular Imaging [online]. 2020; 21(10):1172.

doi:10.1093/ehjci/jeaa102

Impact factor in 2020 = 5.26

Main points of the publication:

A very rare case with arteriovenous malformation involving the umbilical vein was presented. This unique case of vascular abnormality was detected at a very early prenatal stage (at the 16th week of gestation), confirmed postnatally, and successfully treated by coil embolization at the age of three months.

IMAGE FOCUS

doi:10.1093/ehj/ehj102
Online published ahead of print 15 May 2020

Rare congenital umbilical arteriovenous malformation

Hana Jicinska^{1*}, Petr Tax², Radek Padr³, Michal Jicinsky², and Jan Marek⁴¹Department of Pediatrics, University Hospital Brno; Faculty of Medicine, Masaryk University Brno, Cernopolni 9, 662 63 Brno, Czech Republic; ²Children's Heart Centre, 2nd Faculty of Medicine, Charles University and Motol University Hospital, Prague, V Uvalu 84, 150 06 Prague, Czech Republic; ³Department of Radiology, 2nd Faculty of Medicine, Charles University in Prague and Motol University Hospital, V Uvalu 84, 150 06 Prague, Czech Republic; and ⁴Great Ormond Street Hospital for Children and Institute of Cardiovascular Sciences UCL, London, UK

* Corresponding author. Tel: +420 736 605 806. E-mail: h.jicinska@seznam.cz

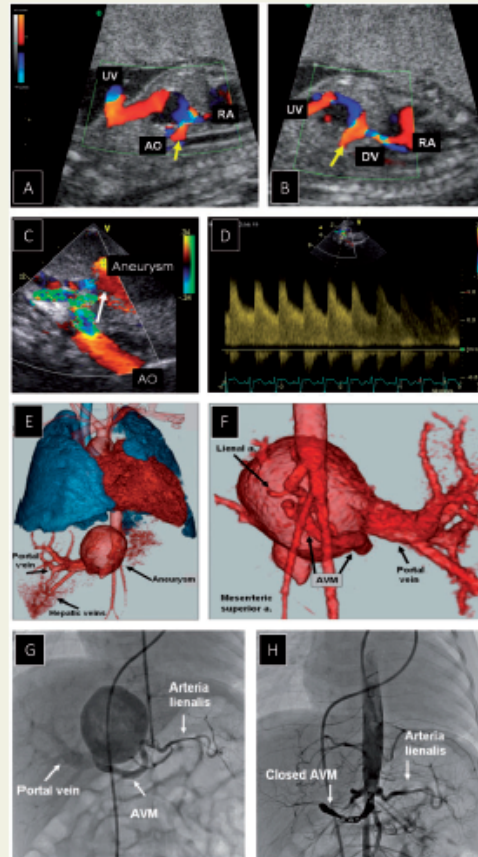
A 23-year-old pregnant woman (in vitro fertilization) was referred to an early foetal echocardiogram for an enlarged right atrium (RA) and tricuspid valve regurgitation (TR). These findings were confirmed at 16 weeks of gestation with otherwise normal cardiac anatomy. Colour flow mapping used during foetal echocardiogram at 21st week of gestation revealed intra-hepatic arteriovenous malformation (AVM)—a communication between abdominal aorta (AO) and a cystic enlargement of the umbilical vein (UV) proximal to the ductus venosus (DV) (Panels A and B, Supplementary data online, Videos S1A and S1B). Apart from RA enlargement, there was no other sign of foetoplacental circulatory impairment.

A postnatal echocardiogram confirmed persistent AVM (Panel C, arrow) with systolic–diastolic flow in the supply vessel on pulsed Doppler echocardiogram (Panels C and D). The DV was closed completely. Apart from AVM, significant left-to-right shunt across patent arterial duct was detected.

A 3D reconstruction of contrast computerized tomography at 11 weeks of age confirmed a cystic aneurysm of the former UV connected to the hepatic and portal veins and communicating with AO (Panel E). Three feeding vessels arising from the AO were found: one just below the diaphragm, and two arising from the area of the celiac trunk; only the largest of these vessels remaining patent at that time (Panel F, posterior view).

At the age of 3 months, the feeding artery of the AVM was successfully closed by three coils (Panels G and H, Supplementary data online, Videos S1G and S1H). Arterial duct was closed at the same time. A follow-up review confirmed an excellent outcome.

Supplementary data are available at *European Heart Journal - Cardiovascular Imaging* online.



Published on behalf of the European Society of Cardiology. All rights reserved. © The Author(s) 2020. For permissions, please email: journal.permissions@oup.com.

4.0.2 ANNEX 12

Fotaki A, Novaes J, **Jicinska H**, Carvalho J S.

Fetal aortopulmonary window: case series and review of the literature.

Ultrasound in Obstetrics & Gynecology[online].2017; 49(4):533-539. ISSN 0960-7692.

doi:10.1002/uog.15936

Impact factor in 2017 = 5.654

Main points of the publication:

Aortopulmonary window (APW) is a rare congenital cardiac anomaly characterized by communication between the pulmonary artery and the aorta. Prenatal diagnosis of this lesion is rare. Only isolated case reports have been reported so far.

In this paper four cases with aortopulmonary window were reported. The diagnosis of APW was made prenatally in two of them: in the first case with atrioventricular (AV) and ventriculoarterial (VA) concordance and no additional cardiac or extracardiac anomalies, and in the second case with atrioventricular and ventriculoarterial concordance and interrupted aortic arch.

The diagnosis of APW was made postnatally in the third case with transposition of the great arteries. Similarly in the fourth case, diagnosis of APW was made with a criss-cross relationship of the ventricles, and with a superoinferior relationship of the great vessels. There were no additional extracardiac or chromosomal abnormalities in any of them.

In cases with APW and normal cardiac connections, the diagnosis can be made prenatally with a standard three-vessel view. However, when there are associated abnormalities affecting the spacial orientation of the great arteries, the diagnosis of APW can be challenging. In APW cases, additional cardiac defects are common, while extracardiac and genetic abnormalities are uncommon.

The candidate contributed to the manuscript and with a case to this study.

Fetal aortopulmonary window: case series and review of the literature

A. FOTAKI*†, J. NOVAES*†, H. JICINSKA*†‡ and J. S. CARVALHO*†§

*Brompton Centre for Fetal Cardiology, Royal Brompton Hospital, London, UK; †Fetal Medicine Unit, St George's University of London & St George's University Hospitals NHS Foundation Trust, Molecular and Clinical Sciences Research Institute, London, UK; ‡University Hospital and Masaryk University Brno, Brno, Czech Republic; §Institute of Cardiovascular and Cell Sciences, St George's University of London, London, UK

KEYWORDS: aortopulmonary window; congenital heart defects; echocardiography; fetus; prenatal diagnosis

ABSTRACT

Aortopulmonary window is a rare congenital cardiac anomaly characterized by communication between the aorta and the pulmonary artery above the semilunar valves. Prenatal diagnosis is rare. We report four fetuses with aortopulmonary window and review the relevant literature. Approximately half of the reported cases had additional cardiac defects. None had chromosomal abnormalities. In cases with normal cardiac connections, the diagnosis can be made prenatally on the standard three-vessel view, as seen in two of our cases. In one fetus with complete transposition of the great arteries, the diagnosis was made retrospectively on sagittal views. In the remaining case, the window was seen postnatally but could not be identified retrospectively due to the abnormal superior/inferior relationship of the ventricles and vessels. Copyright © 2016 ISUOG. Published by John Wiley & Sons Ltd.

CASE SERIES

Between January 1997 and July 2015, fetal echocardiography was performed in 11 727 fetuses at our tertiary pediatric cardiology center. Among these, we identified four with a diagnosis of aortopulmonary window (APW), two of which were diagnosed prenatally. The diagnosis was made postnatally in the other two cases, and could be diagnosed retrospectively in one of these.

Case 1

Prenatal findings

A 33-year-old woman (gravida 3 para 1) was referred for fetal echocardiography at 34 weeks' gestation due to the presence of a cystic mass located behind the left atrium. The patient's family history was unremarkable.

First-trimester nuchal translucency (NT) thickness was 1.6 mm. Fetal anatomical survey at 21 weeks' gestation was normal apart from the presence of a hypoechoic lesion in the upper mediastinum, thought to represent an intrathoracic cyst. As the pregnancy advanced and the mediastinal lesion persisted, the woman was referred for fetal cardiac assessment. Fetal echocardiography showed abdominal situs solitus and the heart was positioned normally in the chest. The atrioventricular and ventriculoarterial connections were concordant. At the level of the four-chamber view, a relatively small cystic mass (measuring 10 × 10 × 9 mm) was depicted behind the left atrium, with no distortion of the cardiac structures. Intracardiac anatomy appeared normal. The three-vessel view demonstrated normal relationship of the pulmonary artery, aorta and superior vena cava. However, cross-sectional views showed a large communication (8 mm) between the ascending aorta and the pulmonary artery (Figure 1). Both branches of the pulmonary artery were identified separately and appeared normal. The arterial wall defect was proximal and separate from the origin of the right pulmonary artery (APW Type 1 according to classification of Richardson *et al.*¹). Color-flow mapping showed bidirectional shunting across the defect, confirming the presence of the APW (Figure 1b). The family was informed of the diagnosis, the need for postnatal open-heart surgery and the likelihood of good long-term outcome.

A three-dimensional ultrasound examination was performed at 37 + 4 weeks' gestation (Prestige V20, Medison, Seoul, South Korea). Static, rather than spatiotemporal image correlation, volumes were obtained due to frequent fetal body and breathing movements and the limitation posed by the advanced gestational age. Volumes were analyzed offline using dedicated computer software (Sonoview Pro, version 1.6.2, Medison). Rendered images of the fetal APW are shown in Figure 1c and d.

Correspondence to: Dr J. S. Carvalho, Royal Brompton Hospital, Sydney Street, London SW3 6NP, UK (e-mail: j.carvalho@rbht.nhs.uk)

Accepted: 27 March 2016

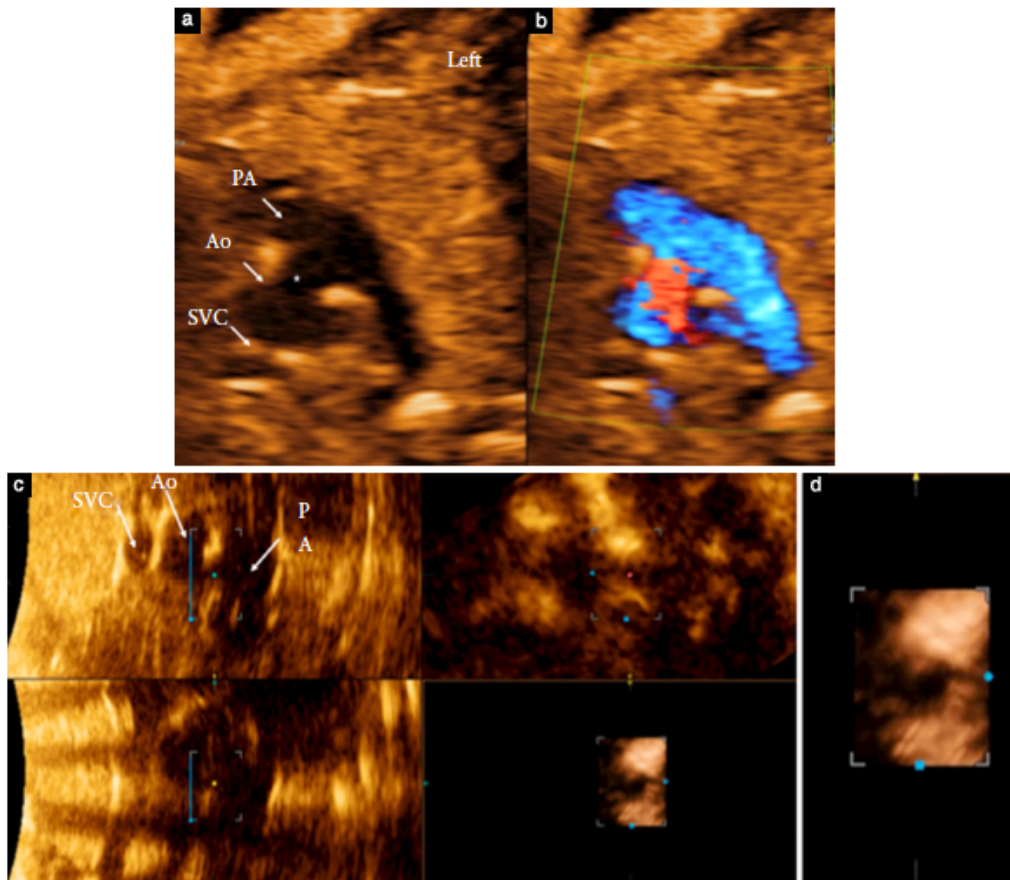


Figure 1 Fetal echocardiography at 28 + 1 weeks' gestation in Case 1, showing aortopulmonary window (APW, *) in standard three-vessel view without (a) and with (b) color mapping. Multiplanar (c) and rendered (d) images in same case at 37 + 4 weeks' gestation, showing APW in the three planes (c) and in en-face view as seen from aortic side (d). Ao, aorta; PA, pulmonary artery; SVC, superior vena cava.

Postnatal follow-up

A male neonate (3550 g) was born at 37 + 6 weeks' gestation by spontaneous vaginal delivery with no complications. Postnatal echocardiography at 5 days postpartum confirmed the diagnosis of isolated APW (Type 1, measuring 8 mm). Karyotype was normal and excluded 22q11 microdeletion. The neonate was treated initially with diuretics and surgical repair was performed 36 days after delivery. The APW was repaired through the aorta; the wall of the ascending aorta was closed with a pulmonary artery wall flap and autologous pericardium was used to reconstruct the pulmonary trunk. The postoperative course was uneventful and the baby was discharged without complications 8 days after the surgery. The infant was well on clinical follow-up at 4 years. There has been no need for further intervention.

Case 2

Prenatal findings

A 28-year-old woman (gravida 3 para 1) was referred to our fetal medicine unit due to abnormal three-vessel view during the anomaly scan. The patient's family history was unremarkable. First-trimester NT thickness was 2.7 mm (>95th centile) and risk from the combined screening test was low. Fetal echocardiography at 22 + 5 weeks' gestation showed abdominal situs solitus with atrioventricular concordance and normal intracardiac anatomy. There was ventriculoarterial discordance in keeping with the diagnosis of complete transposition of the great arteries. The great vessels were otherwise normal with no outflow tract obstruction. No other abnormality was found prenatally and fetal anatomical assessment showed no extracardiac abnormality. The arterial switch procedure was explained to the family and they were informed of the likely good

outcome. A female neonate was delivered vaginally at 38 + 5 weeks' gestation following induction of labor.

Postnatal follow-up

The neonate was born in good condition. No resuscitation was required and elective infusion of prostaglandin E was commenced. Postnatal echocardiography confirmed the prenatal diagnosis of simple transposition with a wide patent foramen ovale and a large ductus arteriosus. The neonate underwent an arterial switch operation 7 days after delivery, during which the APW was identified and repaired. The arterial duct was identified and ligated and the atrial septal defect was closed. Based on the surgical description, the APW was Type 1. Postsurgical course was uneventful and the neonate was discharged 15 days after the operation. Stored images from fetal echocardiography were reviewed. The APW was identified retrospectively on sagittal views (Figure 2) but could not be seen on the three-vessel view due to the abnormal relationship of the great arteries. At 3-year follow-up, echocardiography showed increased velocity across both pulmonary arteries associated with the arterial switch operation (right pulmonary artery velocity, 3 m/s; left pulmonary artery velocity, 3.2 m/s). The infant was clinically well and had no further intervention.

Case 3

Prenatal findings

A 36-year-old woman (gravida 2 para 1) was referred for fetal echocardiography at 20 + 4 weeks' gestation due to inability to obtain the four-chamber view. The patient's family history was unremarkable except for gestational diabetes in her previous pregnancy. The first-trimester ultrasound examination was normal, NT thickness was 1.9 mm and risk from the combined test was low. Fetal echocardiography demonstrated normal abdominal situs solitus. The heart was on the left side of the fetal chest and normal in size; however, the four-chamber view could not be obtained in any axial plane through the fetal chest. There was abnormal spatial orientation of the ventricles, which were in a superoinferior position, resembling a criss-cross relationship of the ventricular inlets. The atrioventricular connection was concordant. The two ventricles were symmetrical and normal in size. Frame-by-frame review of the recorded ultrasound images appeared to show a large inlet ventricular septal defect with straddling of the tricuspid valve. The great vessels were also in an unusual position but the ventriculoarterial connection was concordant. There was no obvious outflow tract obstruction, although the left pulmonary artery could not be visualized well in any of the antenatal scans. Both semilunar valves were normal in size. There was normal systemic and pulmonary venous return. Due to the abnormal spatial orientation of the arteries, which also had a superoinferior relationship, a standard three-vessel view could not be obtained. The crossover of

the great vessels and their unusual course within the chest could only be seen in parasagittal views (Figure 3). The aorta appeared normal with no evidence of obstruction.

No extracardiac abnormality was identified. The findings and likelihood of univentricular palliation based on the presence of a straddling tricuspid valve were explained to the family. The parents opted for amniocentesis, which was performed at 20 + 4 weeks' gestation. Polymerase chain reaction and array comparative genomic hybridization analyses were normal. At approximately 29 weeks' gestation, the patient developed gestational diabetes. A male neonate (2180 g) was born in good condition after spontaneous vaginal delivery at 37 + 3 weeks' gestation.

Postnatal follow-up

The neonate was admitted in good health to our tertiary pediatric cardiology hospital 2 days postpartum for further investigations due to complex anatomy. Echocardiography confirmed situs solitus with concordant atrioventricular and ventriculoarterial connections, with the right ventricle positioned superiorly in relation to the left ventricle. The foramen ovale was widely patent but there was no ventricular septal defect or straddling of mitral or tricuspid valves, and therefore no obvious need for univentricular palliation. The main pulmonary artery was shown to arise from the superior aspect of the right ventricle, being to the left of the aortic root. The aorta ascended from the inferior left ventricle, with the aortic valve situated more caudally. There was a large communication between the aorta and the main pulmonary artery, indicating the presence of an APW. The left pulmonary artery was confirmed to be smaller than the right. The aortic arch could not be imaged by any standard transthoracic echocardiographic view. A computed tomography scan confirmed the echocardiographic findings and showed no obstruction in the aortic arch. The arch was positioned very low within the chest with the origin of the aortic branches almost at the level of the diaphragm. This was also seen retrospectively on the prenatal ultrasound images (Figure 3). The left main bronchus was found to be unusually long and the left upper lobe bronchus could not be identified. The neonate was discharged and administered diuretics. Due to the increased effort of breathing and oxygen saturation of around 80%, cardiac catheterization was performed 4 days postpartum. The APW was described as 'not classic', mainly due to its large size and superoinferior relationship with the vessels. However, from the available images and surgical report, the APW did not seem to extend into the right pulmonary artery (Type 1). The consensus was for the neonate to undergo biventricular repair on cardiopulmonary bypass, which would require weight gain. Alternatively, banding of the right pulmonary artery was to be considered if he became symptomatic or failed to gain weight. The neonate remained well and thrived for the first 4 months following delivery. Surgery to close the APW and augment the left pulmonary artery was performed at 5 months. At 1-year follow-up, the infant was well from a cardiac perspective

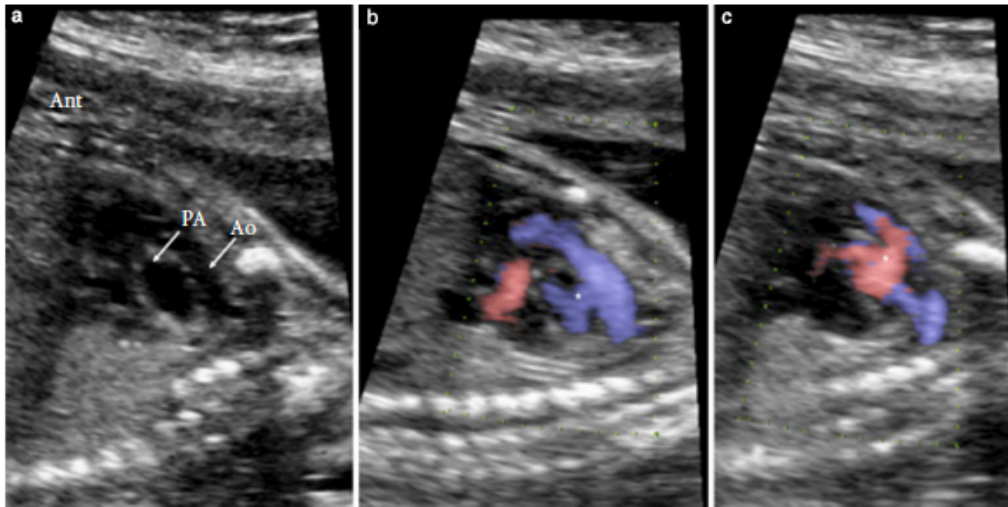


Figure 2 Fetal echocardiography (sagittal view) at 22 + 5 weeks' gestation in Case 2, showing aortopulmonary window (APW) and complete transposition of arteries. (a) With B-mode, APW could not be shown with certainty. (b,c) With e-flow mapping, APW (*) can be seen between aorta (Ao) and pulmonary artery (PA), consistent with postnatal diagnosis. Ant, anterior.

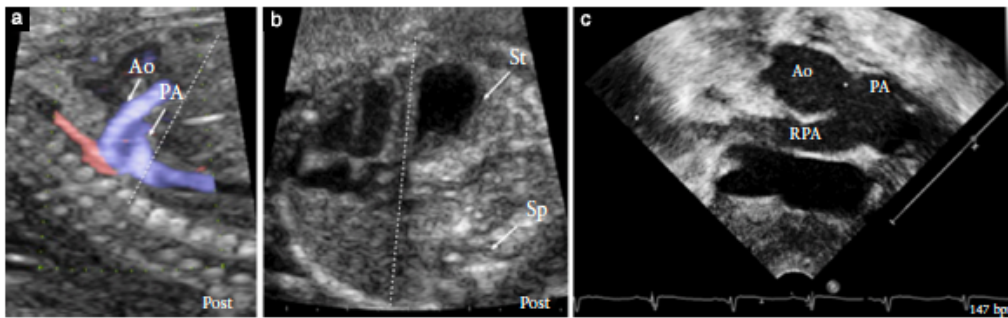


Figure 3 Fetal echocardiography at 20 + 4 weeks' gestation in Case 3, showing aortopulmonary window (APW) in: (a) parasagittal plane, showing abnormal position of great vessels close to diaphragm (dotted line) and (b) oblique view, showing four-chamber view and stomach (St) in same plane. (c) Postnatal echocardiography in same case showing APW (*) in subcostal position. Ao, aorta; PA, pulmonary artery; Post, posterior; RPA, right pulmonary artery; Sp, spine.

but continued to receive ongoing treatment for lung and airway problems.

Case 4

Prenatal findings

A 30-year-old woman (gravida 1 para 0) was referred to our unit because of an abnormal four-chamber view during the routine anomaly scan. The patient's family history was unremarkable. First-trimester combined screening was normal. Fetal echocardiography at 20 + 3 weeks' gestation showed situs solitus with concordant atrioventricular and ventriculoarterial connections. The fetal heart was normal in size but occupied a central position with an

anteroposterior axis. There was no structural intracardiac abnormality. The coronary sinus was dilated due to a persistent left superior vena cava. There was no outflow tract obstruction. At the level of the three-vessel view, there was a wide communication between the aorta and the main pulmonary artery (Figure 4). Color-flow mapping showed bidirectional shunting, confirming the presence of an APW. Both branches of the pulmonary artery were identified separately and appeared normal (Type 1). At the level of the three-vessel trachea view, the transverse arch was smaller than the ductal arch. On sagittal views, a diagnosis of an associated interrupted aortic arch was suspected. Assessment of extracardiac structures showed a single umbilical artery. The right kidney could not be imaged. The parents opted for amniocentesis. Polymerase

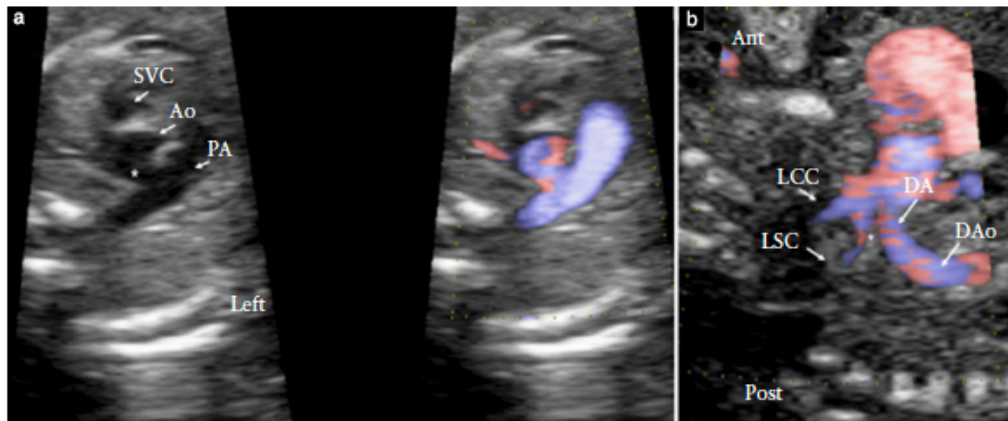


Figure 4 Fetal echocardiography at 21 + 3 weeks' gestation in Case 4, showing: (a) aortopulmonary window (*) at level of three-vessel view, with and without color mapping; and (b) site of interruption of aortic arch (*) in sagittal view. Ant, anterior; Ao, aorta; DA, ductal arch; DAo, descending aorta; LCC, left common carotid artery; LSC, left subclavian artery; PA, pulmonary artery; Post, posterior; SVC, superior vena cava.

chain reaction and array comparative genomic hybridization analyses were normal. Follow-up scans confirmed the diagnosis of interrupted aortic arch after the left subclavian artery (Figure 4). A female neonate was delivered vaginally at 39 + 6 weeks' gestation.

Postnatal follow-up

The neonate was born in good condition and no resuscitation was required. Elective infusion of prostaglandin E was administered. Postnatal echocardiography confirmed the prenatal cardiac diagnosis and showed a widely patent foramen ovale and ductus arteriosus. The right kidney was identified on ultrasound examination in an ectopic position. The neonate underwent surgery 7 days after delivery. The aortic arch was reconstructed and the aortic and pulmonary aspects of the APW were repaired with pulmonary homograft. The arterial duct was ligated and the atrial septal defect closed. The postsurgical course was uneventful. At 3-month follow-up, the infant was well with no need for further intervention.

DISCUSSION

Review of this case series and previous reports of APW show that prenatal diagnosis is feasible. The communication between the aorta and pulmonary artery can be identified using the standard three-vessel view and therefore can be suspected during routine mid-trimester screening. However, when there are associated abnormalities affecting the spatial orientation of the great arteries, the diagnosis of an APW can be challenging and overlooked even with specialist fetal echocardiography.

An APW, also called aortopulmonary septal defect, is a rare congenital heart malformation. It refers to

a communication between the ascending aorta and pulmonary artery in the presence of separate semilunar valves². It accounts for 0.1–0.2% of all cardiac defects in live births³, with a female: male ratio of 1 : 3⁴. Richardson *et al.* classified APW into three types¹. In Type 1, there is a simple defect located between the aorta and the main pulmonary artery, immediately above the sinuses of Valsalva. In Type 2, the defect is located more distally between the ascending aorta and the pulmonary trunk with extension into the origin of the right pulmonary artery. In Type 3, there is anomalous origin of the right pulmonary artery from the ascending aorta. The most frequent form of APW is Type 1⁵. APW can occur in isolation or associated with other cardiac defects². Kutsche and Van Mierop reported additional malformations in 52% of a series of 188 cases⁶. These included simple lesions, such as ventricular and atrial septal defects, patent arterial duct, aortic and pulmonary stenosis, as well as more complex abnormalities, such as interrupted aortic arch, coarctation of the aorta, aortic valve atresia, tetralogy of Fallot and transposition of the great arteries. If untreated, isolated APW can lead to heart failure and pulmonary hypertension with irreversible pulmonary vascular disease⁷. Therefore, early diagnosis is important to optimize medical and surgical treatment. In cases with associated malformations, clinical presentation and time of intervention will depend on the nature of the additional abnormalities.

Previous publications on prenatal diagnosis of APW are restricted to case reports, either isolated or with coexisting abnormalities (Table 1). In six of the seven previous reports, the diagnosis was made prenatally^{2,4,8–11}. In all six cases, the APW could be seen at the level of the three-vessel view. In the remaining case with associated pulmonary atresia and ventricular septal defect, APW was identified only postnatally¹². The authors argued

Table 1 Summary of cases with prenatal diagnosis of aortopulmonary window (APW) reported in our series and in the literature

Study	Time of diagnosis	Additional cardiac finding	Extracardiac finding	Karyotype/phenotype	NT (mm)	Classification of APW*
Our series	34 GW	None	Thoracic cyst	Normal†	1.6	Type 1
	Postnatal	TGA	None	Normal	2.7	Type 1
	Postnatal	Superoinferior ventricles, hypoplastic LPA	Airway abnormalities	Normal†	1.9	Type 1
Hayashi (2010) ⁸	20 GW	IAA, LSVC	SUA, renal agenesis	Normal†	1.3	Type 1
	29 GW	IAA	None	Normal	Unknown	Type 1
Aslan (2012) ¹⁰	33 GW	PAPVD	Subdural hematoma, hydrocephaly	Unknown	Unknown	Type 1
Collinet (2002) ⁴	23 GW	VSD, secundum ASD	None	Unknown	Unknown	Type 1
Kuehn (2004) ¹²	Postnatal	Pulmonary atresia, VSD, LSVC, aberrant RSA	None	Normal†	Unknown	Type 1
Alvarez (2011) ²	26 GW	None	None	Normal†	Unknown	Type 3
Kadohira (2013) ¹¹	29 GW	IAA	None	Unknown	Unknown	Unknown
Valsangiacomo (2002) ⁹	32 GW	RAA	None	Unknown	Unknown	Unknown

Only first author of each study is given. *According to Richardson classification¹. †Includes 22q11 analysis. ASD, atrial septal defect; GW, gestational weeks; IAA, interrupted aortic arch; LPA, left pulmonary artery; LSVC, left superior vena cava; NT, nuchal translucency thickness; PAPVD, partial anomalous pulmonary venous drainage; RAA, right aortic arch; RSA, right subclavian artery; SUA, single umbilical artery; TGA, transposition of the great arteries; VSD, ventricular septal defect.

that abnormal flow conditions with reversed flow in the pulmonary artery contributed to the failure to identify the APW prenatally.

In our series of four cases, the APW was accurately diagnosed prenatally in two, when it was clearly demonstrated in the three-vessel view. In the other two cases, the standard three-vessel view could not be obtained due to associated diagnosis of complete transposition in one and superoinferior relationship of the vessels in the other. After retrospectively reviewing the fetal echocardiogram in the case with transposition of the arteries, we were able to identify the APW on sagittal views. However, we could not demonstrate the APW in the other case despite it being a large defect on postnatal scans. Although this is a small series, it highlights the importance of associated cardiac malformations, in keeping with postnatal literature⁶. The three-vessel view is the most useful cross-sectional plane in which to suspect an APW during routine screening and is also a diagnostic view for the fetal cardiologist. The APW may be best demonstrated with a plane perpendicular to the plane of the hole itself, i.e. through the side of the fetal chest rather than straight through the front or back as seen in Figures 1 and 4. This plane of insonation also allows better demonstration of the flow through the defect, an orientation that is parallel to flow. It is less likely that the APW will be identified at the level of the three-vessel view in cases with associated cardiac abnormalities that, *per se*, will not allow the simultaneous imaging of the aorta and pulmonary artery in the three-vessel view. In some instances, sagittal views may be diagnostic, as in our case of transposition of the great arteries.

Embryologically, the beginning of the formation of the aortopulmonary septum can be traced to the fifth week of development, when pairs of opposing ridges appear in the truncus, called cushions or truncus swellings. They grow towards the aortic sac, twisting counter-clockwise around each other, foreshadowing the spiral course of the future septum¹³. After complete fusion, the ridges form the aortopulmonary septum, dividing the truncus into separate aortic and pulmonary channels. Neural crest cells migrate to the outflow region of the heart contributing to the formation of the aortopulmonary septum. There are many proposed mechanisms explaining outflow tract defects, including direct insults to the truncus swellings, insults to neural crest cells that disrupt signaling to truncus swellings or insults to neural crest cells that disrupt their contribution to fusion. All proposed mechanisms can potentially disrupt the whole process of outflow tract formation. Abnormalities in neural crest migration and signaling are linked to velocardiofacial syndrome, because neural crest cells also contribute to the craniofacial development. Although APW can be considered a conotruncal defect, we were unable to identify any report of its association with 22q11 microdeletion (DiGeorge syndrome) or other genetic syndromes including the velocardiofacial syndromes. Unlike other conotruncal malformations, such as truncus arteriosus or interrupted aortic arch, the risk of associated chromosomal abnormalities in APW, including 22q11 deletion, seems low⁶. In our series, all fetuses except one had normal NT thickness at first-trimester screening and all pregnancies had low risk from the combined test. The

karyotype, including 22q11 assessment, or phenotype was normal in all cases. This is relevant for family counseling.

The outcome for isolated APW is excellent¹⁴ and operative mortality is low; there was no surgical death among all cases operated in the UK in 2013–2014¹⁵. The prognosis depends mainly on the presence of associated cardiac malformations and whether surgery is performed early^{5,14,16}. Associated complex congenital heart disease can be a bad prognostic factor¹⁶. An interrupted aortic arch, for instance, was associated independently with increased mortality in one series¹⁴.

Patients with complex associated lesions are also at greater risk of late death. Reintervention is sometimes indicated for stenosis in both the pulmonary artery and the aorta, as well as being associated with the specific associated lesions^{14,16}. On follow-up, residual lesions are more frequently observed in patients with APW Type 3, and may require early reintervention¹⁷.

Without prenatal diagnosis, death can occur before repair is performed in cases of critical left heart obstruction. Typically, an isolated APW is large, allows a large left-to-right shunt leading to heart failure and is associated with high pulmonary artery systolic pressure. If postnatal diagnosis is delayed, there is a risk of development of pulmonary vascular disease with increased morbidity and mortality. Once postnatal diagnosis is made, the APW should be repaired as early as possible, even in the presence of associated cardiovascular anomalies¹⁷. If the diagnosis is known prenatally and there is no associated critical lesion, surgery is not required shortly after birth but should still be planned and performed early.

In conclusion, although rare, APW can be diagnosed prenatally, usually at the level of the three-vessel view. Additional cardiac defects are common and extracardiac abnormalities are uncommon. The risk of genetic or chromosomal abnormalities is low. Surgical outcome is favorable even in the presence of associated cardiac defects.

ACKNOWLEDGMENTS

A.F. was supported by a Training Grant from the European Society of Cardiology and J.N. was supported by the Children's Heart Unit Fund, Royal Brompton & Harefield Hospitals Charity (charity no. 1053584).

REFERENCES

- Richardson JV, Doty DB, Rossi NP, Ehrenhaft JL. The spectrum of anomalies of aortopulmonary septation. *J Thorac Cardiovasc Surg* 1979; 78: 21–27.
- Alvarez R, Garcia-Diaz I, Coserria F, Housseinpour R, Antinolo G. Aortopulmonary window with atrial septal defect: prenatal diagnosis, management and outcome. *Fetal Diagn Ther* 2011; 30: 306–308.
- Alborino D, Guccione P, Di Donato R, Marino B. Aortopulmonary window coexisting with tetralogy of Fallot. *J Cardiovasc Surg* 2001; 42: 197–199.
- Collinet P, Chatelet-Cheront C, Houze de l'Aulnoit D, Rey C. Prenatal diagnosis of an aortopulmonary window by fetal echocardiography. *Fetal Diagn Ther* 2002; 17: 302–307.
- Tkebuchava T, von Segesser LK, Vogt PR, Bauersfeld U, Jenni R, Kunzli A, Lachat M, Turina M. Congenital aortopulmonary window: diagnosis, surgical technique and long-term results. *Eur J Cardiothorac Surg* 1997; 11: 293–297.
- Kutsche LM, Van Mierop LH. Anatomy and pathogenesis of aortopulmonary septal defect. *Am J Cardiol* 1987; 59: 443–447.
- Santos W, Rossi R, Abecassis M, Neves JP, Rodrigues R, Nunes M, Teixeira A, Ferreira R, Anjos R, Menezes I, Martins FM. Aortopulmonary window – a review of nine cases. *Rev Port Cardiol* 2008; 27: 1453–1462.
- Hayashi G, Inamura N, Kayatani F, Kawazu Y, Hamamichi Y. Prenatal diagnosis of aortopulmonary window with interrupted aortic arch by fetal echocardiography. *Fetal Diagn Ther* 2010; 27: 97–100.
- Valsangiacomo ER, Smallhorn JF. Images in cardiovascular medicine. Prenatal diagnosis of aortopulmonary window by fetal echocardiography. *Circulation* 2002; 105: E192.
- Aslan H, Corbacioglu A, Yildirim G, Ceylan Y. Prenatal diagnosis of aortopulmonary window. *J Clin Ultrasound* 2012; 40: 598–599.
- Kadobira I, Miyakoshi K, Yoshimura Y. Prenatal images of the aortopulmonary window with an interrupted aortic arch. *Pediatr Cardiol* 2013; 34: 1288–1289.
- Kuehn A, Oberhoffer R, Vogt M, Lange R, Hess J. Aortopulmonary window with ventricular septal defect and pulmonary atresia: prenatal diagnosis and successful early surgical correction. *Ultrasound Obstet Gynecol* 2004; 24: 793–796.
- Sadler TW, Langman J. Cardiovascular system. In *Langman's Medical Embryology*. Wolters Kluwer Health/Lippincott Williams & Wilkins: Philadelphia, USA, 2012.
- Bagharia R, Trivedi KR, Burkhart HM, Williams WG, Freedom RM, Van Arsdell GS, McCrindle BW. Outcomes for patients with an aortopulmonary window, and the impact of associated cardiovascular lesions. *Cardiol Young* 2004; 14: 473–480.
- National Institute for Cardiovascular Outcomes Research: NICOR. Specific procedures national data. <https://nicor5.nicor.org.uk/CHD/an&uscore=paeds.msf/WBenchmarkYears?openview&RestrictToCategory=2013&start=1&count=500> [Accessed 10 Feb 2016].
- Gangana CS, Malheiros AF, Alves EV, de Azevedo MA, Bernardes RM, Simoes LC. Aortopulmonary window – impact of associated lesions on surgical results. *Arq Bras Cardiol* 2007; 88: 402–407.
- Chen CA, Chiu SN, Wu ET, Lin MT, Wang JK, Chang CI, Chiu IS, Wu MH. Surgical outcome of aortopulmonary window repair in early infancy. *J Formos Med Assoc* 2006; 105: 813–820.

4.0.3 ANNEX 13

Krupickova S, Rigby M L, **Jicinska H**, Marais G, Rubens M, Carvalho J S. Total anomalous pulmonary venous connection to unroofed coronary sinus diagnosed in a fetus with spinal muscular atrophy Type I. *Ultrasound in Obstetrics & Gynecology*. [online]. 2017;50(5):657+. ISSN 0960-7692. doi:10.1002/uog.17432

Impact factor in 2017 = 5.654

Main points of the publication:

A totally anomalous pulmonary venous connection (TAPVC) to an unroofed coronary sinus is a very rare condition. In this paper the first case of prenatal diagnosis of TAPVC to an unroofed coronary sinus was reported. In addition, due to generalized hypotonia and pathological reflexes in the patient postnatally, genetic testing was carried out which revealed a homozygous mutation in the SMN1 gene confirming the diagnosis of spinal muscular atrophy in the patient.

The candidate contributed to the manuscript and with a case to this study.



Letters to the Editor

Total anomalous pulmonary venous connection to unroofed coronary sinus diagnosed in a fetus with spinal muscular atrophy Type I

Total anomalous pulmonary venous connection (TAPVC) to unroofed coronary sinus is a rare cardiac condition. We report here the first case of antenatal diagnosis of TAPVC to unroofed coronary sinus, which had a rapid and fatal neonatal course due to associated spinal muscular atrophy (SMA) Type I (Werdnig-Hoffmann disease).

A 23-year-old primigravida, with a non-consanguineous relationship, was referred for fetal echocardiography at 23 weeks' gestation with a dilated abdominal aorta. The initial scan showed dilatation of the inferior vena cava at its entrance to the right atrium. Follow-up scan at 26 weeks revealed abnormal pulmonary venous connection to a confluence posteroinferior to the left atrium. From the confluence, pulmonary venous return

was directed towards the region of the coronary sinus, although the roof could not be visualized fully. Pulmonary venous return appeared to enter the left atrium but, in addition, color flow mapping showed streaming of pulmonary venous flow towards the inferior vena cava, in keeping with the observations made at the first fetal cardiac scan (Figure 1a). The diagnosis of TAPVC with unroofed coronary sinus was made (Figure 1b,c). There was also increased nuchal thickening, prenatal edema and single umbilical artery. Invasive testing was declined by the family.

A male neonate was delivered at 37 + 3 weeks. Postnatal echocardiographic assessment and computed tomography confirmed the prenatal findings and additionally demonstrated a superior sinus venosus defect (Figures 2 and S1). Due to generalized hypotonia and pathological reflexes, genetic testing was carried out which revealed a homozygous mutation in the SMN1 gene confirming the presumptive diagnosis of SMA. Only one copy of the

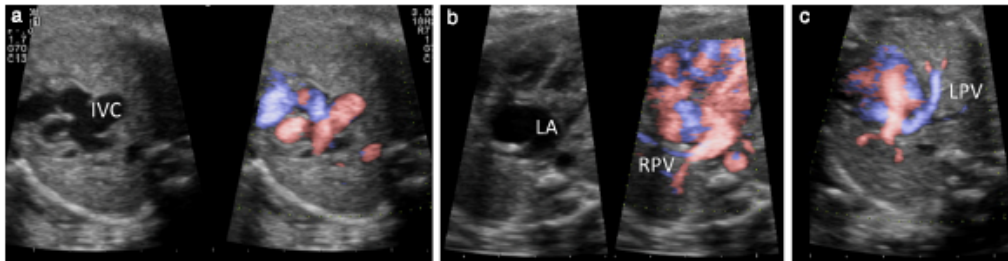


Figure 1 Fetal echocardiography with and without high-definition color imaging, at 26 weeks' gestation, showing: (a) significant dilatation of inferior vena cava (IVC) at its entrance to right atrium and (b,c) abnormal pulmonary venous connection to unroofed coronary sinus. LA, left atrium; LPV, left pulmonary vein; RPV, right pulmonary vein.

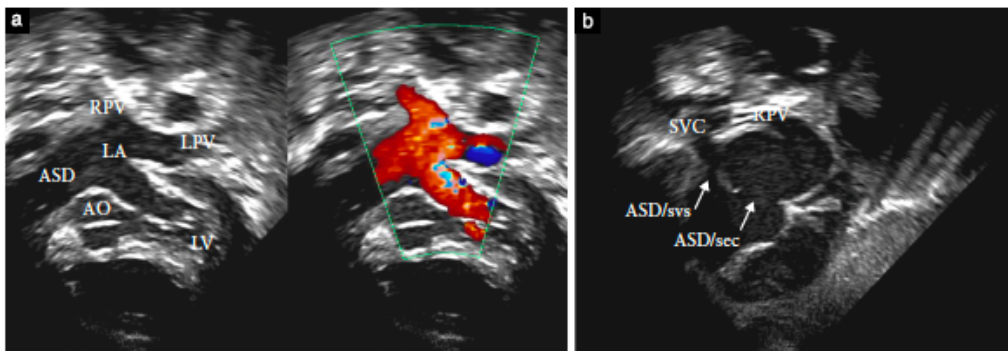



Figure 2 Postnatal echocardiogram showing abnormal connection of right (RPV) and left (LPV) pulmonary veins to posteroinferior aspect of left atrium (LA) (a) and large atrial septal defect (ASD) (a,b). AO, aorta; ASD/sec, secundum ASD; ASD/svs, sinus venosus superior ASD; LV, left ventricle; SVC, superior vena cava.

SMN2 gene was present. The infant deteriorated rapidly and became dependent on mechanical ventilatory support, failing extubation on several occasions. Following discussion with the family, the infant was extubated and died soon after, at the age of 6 weeks.

Prenatal diagnosis of TAPVC is rare, with only eight out of 424 cases identified prenatally in a recent multicenter study^{1,2}. To our knowledge, this is the first case of TAPVC to unroofed coronary sinus reported in a fetus, while published data on postnatal diagnosis are sparse³. The diagnosis is usually an incidental finding with concomitant congenital cardiac anomalies. The condition leads to right-to-left shunt at the atrial level (Figure S2) and, similar to all interatrial communications, it may cause symptoms of right heart failure, atrial arrhythmia and pulmonary hypertension in late adulthood.

Our patient was also diagnosed with SMA Type I. SMA is a rare autosomal recessive neurodegenerative disorder that affects motor neurons in the spinal cord and causes postnatal degeneration and subsequent weakness of skeletal muscles, leading to feeding and breathing difficulties. SMA Type I represents the most severe form of the disorder, appearing within 3 months of age and being associated with early mortality. The SMN2 gene encodes a protein that is identical to that of the SMN1 gene, the survival motor neuron (SMN) protein, but with impaired function. The number of copies of the SMN2 gene influences the amount of fully functional SMN protein, and thus, the severity of the disease. The most severe types of SMA are associated with the presence of only one copy of SMN2 gene, as was observed in our case, and there is a strong association of this disorder with congenital heart defects⁴. Simultaneous presentation of TAPVC to unroofed coronary sinus and SMA Type I has not been reported previously. It is interesting to speculate that the SMN2 gene may be involved in cardiogenesis in these patients.

S. Krupickova¹, M. L. Rigby¹, H. Jicinska^{1,2},
G. Marais³, M. Rubens^{1,4} and J. S. Carvalho^{1,2,5*} 

¹Department of Paediatric Cardiology,
Royal Brompton Hospital, London, UK;

²Fetal Medicine Unit,
St George's Hospital, London, UK;

³Department of Paediatrics,
Croydon Hospital, Croydon, UK;

⁴Department of Radiology,
Royal Brompton Hospital, London, UK;

⁵Molecular & Clinical Sciences Research Institute,
St George's University of London, London, UK

*Correspondence.

(e-mail: j.carvalho@rbht.nhs.uk)

DOI: 10.1002/uog.17432

References

1. Seale AN, Carvalho JS, Gardiner HM, Mellander M, Roughton M, Simpson J, Tometzi A, Uzun O, Webber SA, Daubeney PE; British Congenital Cardiac Association. Total anomalous pulmonary venous connection: impact of prenatal diagnosis. *Ultrasound Obstet Gynecol* 2012; 40: 310–318.

2. Karl K, Kainer F, Knabl J, Chaoui R. Prenatal diagnosis of total anomalous pulmonary venous connection into the coronary sinus. *Ultrasound Obstet Gynecol* 2011; 38: 729–731.
3. Laux D, Houyel L, Bajolle F, Bonnet D. Total anomalous pulmonary venous connection to the unroofed coronary sinus in a neonate. *Pediatr Cardiol* 2013; 34: 2006–2008.
4. Shababi M, Lorson CL, Rudnik-Schöneborn SS. Spinal muscular atrophy: a motor neuron disorder or a multi-organ disease? *J Anat* 2014; 224: 15–28.

SUPPORTING INFORMATION ON THE INTERNET

The following supporting information may be found in the online version of this article:


 **Figure S1** Postnatal echocardiogram showing abnormal connection of right (RPV) and left (LPV) pulmonary veins to posteroinferior aspect of left atrium.

Figure S2 Schematic images of: (a) normal cardiac anatomy, (b) total anomalous venous connection to coronary sinus (CS) and (c) total anomalous venous connection to unroofed CS. IVC, inferior vena cava; LA, left atrium; PVC, pulmonary venous confluence; RA, right atrium; SVC, superior vena cava.

5. Fetal arrhythmias

Fetal arrhythmias can be detected during a prenatal ultrasound examination. The most severe fetal arrhythmias are supraventricular and ventricular tachycardias and congenital complete atrioventricular block in the fetus. It is necessary to detect and to assess signs of heart failure in the fetus and in the whole fetoplacental circulation during fetal examination.

5.0.1 ANNEX 14

Eliasson H, Sonesson S E, Sharland G, Granath F, Simpson M S, Carvalho J S, **Jicinska H**, Tomek V, Dangel J, Zelinsky P, Respondek-Liberska M, Freund M W, Mellander M, Bartroons J, Gardiner H M

Isolated Atrioventricular Block in the Fetus. A retrospective multinational, multicenter study of 175 patients.

Circulation [online]. 2011;124(18):1919-1926. ISSN 0009-7322

doi:10.1161/CIRCULATIONaha.111.041970

Impact factor in 2011 = 14.739

Main points of the publication:

Isolated congenital complete heart block in the fetus is one of the most severe fetal arrhythmias and can cause heart failure and fetal death. The aim of this multicenter study was to find risk factors associated with fetal death and the influence of steroid therapy. 175 fetuses diagnosed with second or third degree atrioventricular block from 2000 to 2007 were studied. Of 175 fetuses, 80% were anti-Ro and 59% anti-La positive. 67 fetuses (38%) were treated with transplacental steroids and 41 fetuses (23%) were treated with betamimetics. Of 175 fetuses, 26 died before birth or in the neonatal period, 11 were lost to follow-up. In steroid treated groups and non-steroid treated groups of fetuses, there was the same survival rate of 91%. Neonatal survival was 95% in the steroid treated group and 82% in the non-treated group.

10 fetuses with AV block second degree were exposed to maternal anti-Ro antibodies. Seven of them were treated with steroids. In 3 of the 7 treated fetuses, AV block converted to sinus rhythm, but only one of these three fetuses was known to stably remain in sinus rhythm by the age of 12 months. Eight fetuses developed cardiomyopathy and pacemakers were implanted in 69% of the fetuses within one year.

A gestational age < 20 weeks of gestation, a ventricular rate < 50 bpm, a presence of hydrops, and impaired left ventricle function are risk factors for intrauterine death.

The candidate contributed to the manuscript and with cases to this international study.

Isolated Atrioventricular Block in the Fetus A Retrospective, Multinational, Multicenter Study of 175 Patients

Håkan Eliasson, MD; Sven-Erik Sonesson, PhD, MD; Gurleen Sharland, MD;
Fredrik Granath, PhD, MD; John M. Simpson, MD; Julene S. Carvalho, PhD, MD; Hana Jicinska, MD;
Viktor Tomek, MD; Joanna Dangel, PhD, MD; Paulo Zielinsky, PhD, MD;
Maria Respondek-Liberska, PhD, MD; Matthias W. Freund, MD; Mats Mellander, PhD, MD;
Joaquim Bartrons, MD; Helena M. Gardiner, PhD, MD; for the Fetal Working Group of the European
Association of Pediatric Cardiology

Background—Isolated complete atrioventricular block in the fetus is a rare but potentially lethal condition in which the effect of steroid treatment on outcome is unclear. The objective of this work was to study risk factors associated with death and the influence of steroid treatment on outcome.

Methods and Results—We studied 175 fetuses diagnosed with second- or third-degree atrioventricular block (2000–2007) retrospectively in a multinational, multicenter setting. In 80% of 162 pregnancies with documented antibody status, atrioventricular block was associated with maternal anti-Ro/SSA antibodies. Sixty-seven cases (38%) were treated with fluorinated corticosteroids for a median of 10 weeks (1–21 weeks). Ninety-one percent were alive at birth, and survival in the neonatal period was 93%, similar in steroid-treated and untreated fetuses, regardless of degree of block and/or presence of anti-Ro/SSA. Variables associated with death were gestational age <20 weeks, ventricular rate ≤ 50 bpm, fetal hydrops, and impaired left ventricular function at diagnosis. The presence of ≥ 1 of these variables was associated with a 10-fold increase in mortality before birth and a 6-fold increase in the neonatal period independently of treatment. Except for a lower gestational age at diagnosis in treated than untreated (23.4 ± 2.9 versus 24.9 ± 4.9 weeks; $P=0.02$), risk factors were distributed equally between treatment groups. Two-thirds of survivors had a pacemaker by 1 year of age; 8 children developed cardiomyopathy.

Conclusions—Risk factors associated with a poor outcome were gestation <20 weeks, ventricular rate ≤ 50 bpm, hydrops, and impaired left ventricular function. No significant effect of treatment with fluorinated corticosteroids was seen. (*Circulation*. 2011;124:1919–1926.)

Key Words: atrioventricular block ■ fetal heart ■ lupus erythematosus, systemic ■ therapeutics

Congenital complete atrioventricular block (AVB III) without associated cardiac malformation is a rare disease with an incidence in newborn babies of 1 in 15 000 to 1 in 20 000.¹ Some studies have suggested that maternal administration of high-dose steroids that cross the placenta can inhibit the progression or even reverse second-degree AVB (AVB II) to sinus rhythm.^{2–5} Treatment with fluorinated steroids and betamimetics has been proposed to improve outcome in AVB III,⁶ but repeated doses of steroids have potentially serious side effects in the fetus, including alteration of brain development.^{7–10} Thus, fetal cardiologists lack consensus on treatment¹¹; many are not supportive of universal steroid treatment for fetal AVB III but may use steroids if the fetus presents with or develops hydrops because there is some evidence that steroids promote the resolution of hy-

drops. Maternal betamimetic therapy for fetuses with ventricular rates <55 bpm has also been given, with minimal benefit in most reports.^{6,12–14}

Editorial see p 1905 Clinical Perspective on p 1926

After a previous unsuccessful attempt to start a prospective therapeutic study in 1995, the Fetal Working Group of the European Association for Pediatric Cardiology recognized that the rarity of isolated AVB III contributed to the difficulties in providing an evidence base for the management of heart block diagnosed in the fetus. This retrospective, multinational, multicenter observational study was therefore initiated to provide a review of current practice and outcomes. All members of the Fetal Working Group of the European

Received November 22, 2010; accepted July 21, 2011.

With the exception of Dr Granath, all of the authors are members of the Fetal Working Group of the European Association of Pediatric Cardiology. Dr Granath is affiliated with the Clinical Epidemiology Unit, Karolinska University Hospital and Karolinska Institutet, Stockholm, Sweden. In addition, for a full list of contributors to the Fetal Working Group of the European Association of Pediatric Cardiology, please see the acknowledgments.

Correspondence to Håkan Eliasson, MD, Pediatric Cardiology Q1:03, Astrid Lindgren Children's Hospital, Karolinska University Hospital, S-171 76 Stockholm, Sweden. E-mail hakan.eliasson@karolinska.se

© 2011 American Heart Association, Inc.

Circulation is available at <http://circ.ahajournals.org>

DOI: 10.1161/CIRCULATIONAHA.111.041970

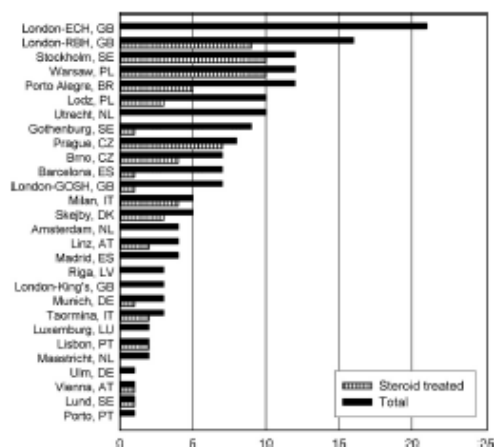


Figure 1. Number of patients (total and steroid treated) from each participating center.

Association of Pediatric Cardiology were invited to contribute data to a communal database of fetuses diagnosed with isolated AVB II and III between 2000 and 2007.

The objectives of this study were to identify risk factors predictive of a poor outcome, to describe current practice regarding steroid treatment of isolated AVB II and III in the contributing centers, and to compare the outcome in fetuses treated with fluorinated glucocorticoids with untreated fetuses in respect to morbidity and mortality.

Methods

Patient Selection

Data on 189 fetuses were submitted from 28 centers, 27 in Europe and 1 in Brazil. The contributing institutions are listed in the Acknowledgments, and the number of cases per center is shown in Figure 1. Fourteen fetuses were excluded after data evaluation; no birth outcome data were available in 10, and another 4 fetuses were thought to have reverted from AVB II or III. However, in 2 of these 4 fetuses, review was not possible because of lack of documentation, and in the other 2 fetuses, initial diagnosis of AVB could not be retrospectively confirmed. The resulting final study population consisted of 175 fetuses (174 pregnancies) of 172 women diagnosed with isolated AVB II or III (2000–2007) and a minimum follow-up time from diagnosis until birth or intrauterine death. Two women had 2 separate affected pregnancies with fetal AVB III, and a third woman had a twin pregnancy in which both babies developed AVB III.

Methods

The project was evaluated by the National Research Ethics Service (Hammersmith and Queen Charlotte's and Chelsea Research Ethics Committee, 2007) and considered to not require review by a National Health Service Research Ethics Committee. All cases were diagnosed by a fetal cardiologist at each center using standard fetal echocardiographic techniques. The examination excluded cardiac structural malformations, diagnosed the arrhythmia, and evaluated cardiac function and hemodynamics. Observational data were collected retrospectively by review of the clinical charts and echocardiographic examinations at each of the participating centers, and the data were sent to the study coordinator. Data were collected on the mother (age, presence of autoimmune disease, maternal antibodies, steroid treatment at time of conception, parity, previous fetuses with

AVB); the fetus at presentation (gestational age, degree of AVB, atrial and ventricular rate, left ventricular function [impaired or normal], mitral or tricuspid regurgitation [present or absent], ascites, pleural and/or pericardial effusion, skin edema); pharmacological treatment used (steroids [type, dose, duration], betamimetics [type, dose, duration] and documented fetal and/or maternal complications); fetal outcome, including intrauterine death; and the child at birth/follow-up (date of birth, gestational age, birth weight, degree of AVB, ventricular rate, age at last follow-up or death). Pacing and development of cardiomyopathy were documented.

Cases of AVB demonstrating improved atrioventricular conduction were included only if accompanied by M-mode or Doppler recordings confirming the diagnosis. Transplacental steroid treatment was considered only when the pregnant mothers were given fluorinated steroids. Hydrops was defined as serous effusions in at least 2 compartments.

Statistical Analysis

Cases were divided into groups based on placental treatment (steroid treated or untreated) and outcome at birth and 1 month of age (survival or death). Comparisons of frequencies with respect to categorical variables were performed by Fisher exact tests or an exact counterpart for $R \times C$ tables. Comparisons with respect to quantitative variables were performed by 2-sample t tests assuming equal variances for all variables except parity, for which the Wilcoxon 2-sample test was used. Descriptive data are presented as counts, frequencies, mean \pm SD, or median with range. Intrauterine mortality and neonatal mortality with respect to steroid treatment were analyzed separately; all patients were assessed for intrauterine mortality. All patients alive at birth, except 11 patients lost to follow-up, were assessed for neonatal mortality. Both of these outcomes were analyzed by exact logistic regression including only steroid treatment and an adjusted model conditioned on gestational age at diagnosis (categorized as <20 , 20 to 24, 25 to 29, ≥ 30 weeks). These analyses were also performed on the subgroups of patients defined by a positive anti-Ro/SSA and/or anti-Ro/SSB test and a positive test further restricted to AVB II–III/III. Results of the logistic regressions are presented as odds ratios with exact 95% confidence limits. We describe the effect of betamimetics on heart rate, including only patients with data on ventricular rate before and within 2 weeks after treatment was initiated. Follow-up of the cohort beyond the neonatal period is incomplete with missing information on the time points when the patients were lost to follow-up. Therefore, data on long-term outcomes and characteristics are purely descriptive. All analyses were performed with SAS 9.2 software (SAS Institute, Inc, Cary, NC) or Statistica 10.0 (Stat Soft, Tulsa, OK).

Results

Baseline Characteristics

Table 1 details the clinical characteristics. To summarize the available data, approximately half of the women were diagnosed with collagen disease, and 80% were anti-Ro/SSA positive and 59% anti-La/SSB positive. Two tested negative for anti-Ro/SSA but positive for anti-La/SSB. Fifteen fetuses (9%) were diagnosed with AVB II, 14 (8%) with AVB II to III, and 146 (83%) with AVB III. The average ventricular rate of the whole cohort was 60 bpm, and 21% had a ventricular rate ≤ 50 bpm; 9% were hydropic.

Transplacental Treatment

Sixty-seven fetuses (38%) were treated with transplacental steroids starting at 23.5 gestational weeks (range, 19–31 weeks; Table 1). Fifty-two received dexamethasone beginning with 4 mg/d (range, 2–12 mg/d) and 15 betamethasone at 4 mg/d (range, 3–5 mg/d). In 2 pregnancies, fluorinated steroids were given in combination with prednisolone. The

Table 1. Clinical Characteristics at the Time of Diagnosis and Transplacental Treatment of 175 Fetuses of 172 Women With Second- or Third-Degree Atrioventricular Block

	All Cases (n=175)	Steroid		P
		Treated (n=67)	Untreated (n=108)	
Maternal age, y	30.3±5.9	31.0±5.7	29.9±6.0	0.18
Parity	1.0±1.0	1.1±1.0	0.9±1.0	0.20
Collagen disease, n (%)	77/167 (46)	33/63 (52)	44/104 (42)	0.26
Sjögren syndrome	18	11	7	
SLE	11	5	6	
Unspecified	48	17	31	
Previous history of AVB, n (%)	9/172 (5)	7/66 (11)	2/106 (2)	0.03
Anti-Ro/SSA positive	129/162 (80)	55/64 (86)	74/98 (76)	0.25
Anti-La/SSB positive	85/144 (59)	38/61 (62)	47/83 (57)	0.61
GA at diagnosis, wk	24.3±4.3	23.4±2.9	24.9±4.9	0.02
AVB I, II–III, III, n (%)	15, 14, 146 (9, 8, 83)	7, 6, 54 (10, 9, 81)	8, 8, 92 (7, 7, 86)	0.48, 0.71, 0.43
Ventricular rate, bpm	59.8±11.4	61.3±11.3	58.9±11.5	0.19
Ventricular rate ≤50 bpm, n (%)	36/173 (21)	13/66 (20)	23/107 (21)	0.77
Isolated ascites, pericardial or pleural effusion, n (%)	32/154 (21)	11/62 (18)	21/92 (23)	0.45
Hydrops, n (%)	16/175 (9)	5/67 (7)	11/108 (10)	0.54
Impaired LV function, n (%)	17/141 (12)	7/55 (13)	10/86 (12)	0.84
Steroid treatment, n (%)	67/175 (38)			
Dexamethasone	52	52		
Betamethasone	15	15		
Betamimetics	41/175 (23)	23/67 (34)	18/108 (17)	0.01

SLE indicates systemic lupus erythematosus; AVB, atrioventricular block; GA, gestational age; and LV, left ventricular. Cases are divided into groups based on transplacental steroid treatment. Values are mean±SD when appropriate. Comparisons are untreated versus steroid-treated fetuses.

duration of treatment was 10 weeks (range, 1–21 weeks), and in most cases, the dose remained unchanged. Side effects were reported in 11 pregnancies (6%), mainly oligohydramnios, growth restriction, and constriction of the arterial duct. One mother developed diabetes mellitus, adrenal insufficiency, and psychosis.

Forty-one fetuses (23%) were treated with betamimetics, usually salbutamol, from 25 gestational weeks (range, 19–33 weeks) for 8 weeks (range, 2–18 weeks). Betamimetics were more frequently combined with steroid administration than given alone (23 of 67 versus 18 of 108; $P=0.01$). Ventricular rate increased from 50.1 ± 3.8 to 55.1 ± 3.7 bpm ($P=0.001$) in 15 patients with data before and after initiation of treatment.

Two mothers from the same center received prophylactic treatment with plasmapheresis twice a week for 9 and 14 weeks. Their fetuses had AVB III at the time of diagnosis, were treated with steroids (1 with dexamethasone, 1 with prednisolone followed by dexamethasone), were born in AVB III, and were alive at 0.9 and 2.2 years. A third woman with a previous history of fetal AVB III was given 1 g/kg immunoglobulin intravenously at 14 and 18 weeks of gestation to minimize the risk of having a second child with AVB. The fetus was diagnosed with AVB II at 19 weeks that reverted after 1 week of treatment with betamethasone and remained in sinus rhythm at 0.9 years of age.

Baseline Characteristics and Neonatal Survival

Sixteen of the 175 fetuses with AVB II or AVB III died in utero (Figure 2). This included 1 pregnancy terminated at 23 weeks of gestation because the fetus was not responding to treatment with steroids and betamimetics. Of 159 live-born babies, 10 died during the first month (neonatal deaths), 138 were reported alive at 1 month, and 11 were lost to follow-up.

Baseline characteristics for the groups based on intrauterine and neonatal survival outcome are presented in Tables 2 and 3. Fetuses with a poor outcome were diagnosed ~3 to 4 weeks earlier than survivors. Hydrops and impaired left

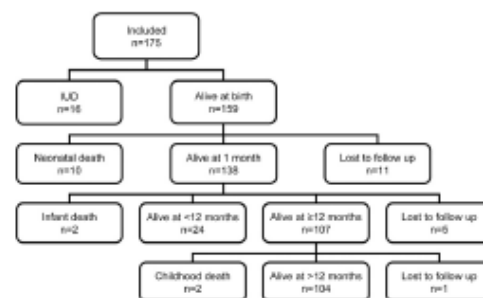


Figure 2. Outcome of all 175 fetuses with second- or third-degree atrioventricular block at diagnosis. IUD indicates intrauterine death.

Table 2. Clinical Characteristics at the Time of Diagnosis and Transplacental Treatment Among Survivors at Birth Versus Intrauterine Death and Survivors at 1 Month Versus Neonatal Death

	Survivors at Birth (n=159)	Intrauterine Death (n=16)	P	Survivors at 1 mo (n=138)	Neonatal Death (n=10)	P
Maternal age, y	30.6±6.0	27.4±3.3	0.02	31.0±6.0	29.7±6.4	0.54
Anti-Ro/SSA positive, n (%)	117/148 (79)	12/14 (86)	0.84	102/127 (80)	4/10 (40)	0.28
Anti-La/SSB positive, n (%)	74/131 (56)	11/13 (85)	0.38	63/113 (56)	5/9 (56)	1.0
GA at diagnosis, wk	24.6±4.3	21.6±3.3	0.01	24.8±4.2	20.6±3.3	0.004
Ventricular rate, bpm	60.8±10.9	49.9±11.8	0.0002	61.0±10.8	59.6±14.6	0.70
Treatment, n (%)						
Steroids	61/159 (38)	6/16 (38)	1.00	53/138 (38)	3/10 (30)	0.74
Betamimetics	35/159 (22)	6/16 (38)	0.21	27/138 (20)	3/10 (30)	0.42

GA indicates gestational age. Values are mean±SD when appropriate.

ventricular function were observed more frequently in fetuses not surviving to 1 month of age, whereas a ventricular rate ≤ 50 bpm was associated only with intrauterine mortality. The effects of gestational age, ventricular rate, and the presence of hydrops at diagnosis on survival outcome are also more directly illustrated in Figure 3. Intrauterine mortality rate was >4 times higher in fetuses diagnosed with AVB before 20 weeks of gestation compared with those diagnosed after 23 weeks. Fetuses with a ventricular rate ≤ 50 bpm had 5 times higher intrauterine mortality than those with a ventricular rate >55 bpm. The presence of hydrops and impaired left ventricular function increased both intrauterine mortality and neonatal mortality by a factor of

6 and 4, respectively. Considering a gestational age <20 weeks, ventricular rate ≤ 50 bpm, and the presence of hydrops and impaired left ventricular function as risk factors, intrauterine mortality was 11 times higher in fetuses with at least 1 risk factor, and neonatal mortality was 6 times higher when at least 1 risk factor was present at time of diagnosis (Table 3).

Steroid Treatment and Survival to 1 Month of Age

Transplacental treatment with steroids and betamimetics was given in the same proportion to survivors and nonsurvivors (Table 2). The logistic regression model (Table 4) could not demonstrate any effect of transplacental steroid treatment on intrauterine or neonatal survival. In steroid-treated fetuses, intrauterine survival was 91%, the same as in those not treated; neonatal survival among the 148 children alive at birth was 95% in the steroid-treated group and 92% in the untreated group. Adjusting for effects of gestational age at diagnosis had only a minor influence on the model without demonstrating any treatment effect (Table 4). Table 1 shows that the steroid-treated and untreated cohorts had similar ventricular rates, frequency of hydrops, rates of impaired left ventricular function, and rates of incomplete AVB and only a

Table 3. Intrauterine Mortality Related to Clinical Observations Made at the Time of Diagnosis in 175 Fetuses With Known Outcome at Birth and Neonatal Mortality in 148 Newborns With Known Outcome at 1 Month of Age

	Intrauterine Death (n=16), % (n)	P	Neonatal Death (n=10), % (n)	P
GA at diagnosis, wk		0.001		0.10
<20	38 (5/13)		13 (1/8)	
20–23	10 (7/73)		11 (7/61)	
>23	8 (4/86)		3 (2/76)	
Ventricular rate, bpm		0.0019		0.50
≤ 50	25 (9/36)		13 (3/24)	
51–55	6 (2/31)		7 (2/28)	
>55	5 (5/106)		5 (5/95)	
Hydrops		0.001		0.02
Yes	38 (6/16)		30 (3/10)	
No	6 (10/159)		5 (7/138)	
Impaired LV function		0.04		0.04
Yes	24 (4/17)		23 (3/13)	
No	6 (8/124)		5 (5/111)	
Any risk factor		0.0001		0.009
≥ 1	22 (12/55)		18 (7/40)	
No	2 (2/101)		3 (3/92)	

GA indicates gestational age; LV, left ventricular. Risk factor denotes presence of hydrops, impaired LV function, ventricular rate ≤ 50 bpm, and/or a GA <20 wk.

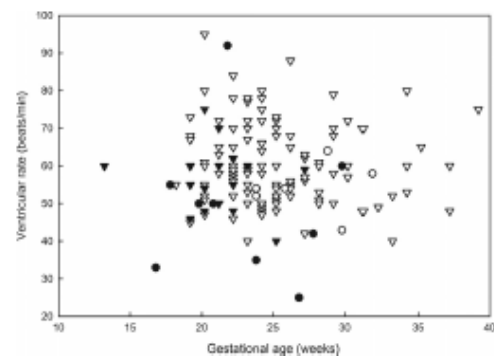


Figure 3. Fetal ventricular rate vs gestational age at diagnosis in cases with a known outcome at 1 month of age. Circles and triangles represent fetuses with and without hydrops, respectively. Open symbols denote survivors; filled symbols, cases of intrauterine or neonatal death.

Table 4. Transplacental Steroid Treatment and Outcome of All 175 Included Fetuses (at Birth) and the 148 Live-Born Neonates With Known Outcome at 1 Month of Age

Categories	All Patients, % (n)	Steroid Treated, % (n)	Untreated, % (n)	Crude OR	Adjusted OR
Survival at birth					
All fetuses (n=175)	91 (159/175)	91 (61/67)	91 (98/108)	0.96 (0.27–3.10)	0.79 (0.21–2.67)
Anti-Ro/SSA and/or La/SSB positive (n=131)	91 (119/131)	91 (51/56)	91 (68/75)	0.95 (0.22–3.72)	0.85 (0.20–3.41)
Anti-Ro/SSA and/or La/SSB positive and AVB III (n=121)	90 (109/121)	90 (44/49)	90 (65/72)	1.05 (0.25–4.15)	0.97 (0.22–3.96)
Survival at 1 mo					
All neonates (n=148)	93 (138/148)	95 (53/56)	92 (85/92)	0.69 (0.11–3.18)	0.58 (0.23–1.79)
Anti-Ro/SSA and/or La/SSB positive (n=108)	95 (103/108)	96 (44/46)	95 (59/62)	0.89 (0.07–8.16)	1.00 (0.08–10.2)
Anti-Ro/SSA and/or La/SSB positive and AVB III (n=101)	95 (96/101)	95 (39/41)	95 (57/60)	0.97 (0.08–8.92)	1.04 (0.08–10.7)

Crude OR indicates unadjusted odds ratio; Adjusted OR, odds ratio adjusted for gestational age (categorized as <20, 20–24, 25–29, and ≥30 wk) at diagnosis. OR is presented with 95% confidence limits.

small difference in gestational age at diagnosis. Pregnancies with a previous history of fetal AVB were more often treated, but no relationship between the size of the center and the proportion of steroid-treated cases could be demonstrated (Figure 1). Limiting the analysis to antibody-exposed fetuses in whom steroid treatment theoretically might have the best effect, survival was similar without any positive treatment effect (Table 4). If the presence of at least 1 risk factor was included, it was still not possible to detect any significant effect of steroid treatment on survival at birth or at 1 month of age (Figure 4).

Steroid Treatment and Atrioventricular Conduction

Fifteen fetuses (9%) had AVB II diagnosed at a gestation of 22 weeks (range, 19–29 weeks; Figure 5). Exposure to maternal anti-Ro/SSA and/or anti-La/SSB antibodies was established in 10 cases, seven of whom were treated with

steroids, and in 3 fetuses, treated from 19, 22, and 23 weeks of gestation, the rhythm converted to 1:1 conduction within 1 to 2 weeks after the start of treatment. All 3 fetuses were in sinus rhythm at birth, but only 1 was known to remain so at a year of age; the second had reverted to AVB I to II at 5 years of age, and no information was available for the third. The remaining 12 fetuses remained in AVB II (n=2), progressed to AVB III (n=8), or were lost to follow-up after birth (n=2).

Fourteen fetuses were reported to have AVB II–III, 12 of whom progressed to AVB III by birth. Of the remaining 2 fetuses, 1 was diagnosed at 20 weeks and showed reversion to 1:1 atrioventricular conduction after initiation of steroid treatment but had AVB III by 4 years of age. This fetus was exposed to maternal antibodies. The other fetus was diagnosed at 21 weeks to an antibody-negative woman and was in sinus rhythm at birth and at 2.7 years.

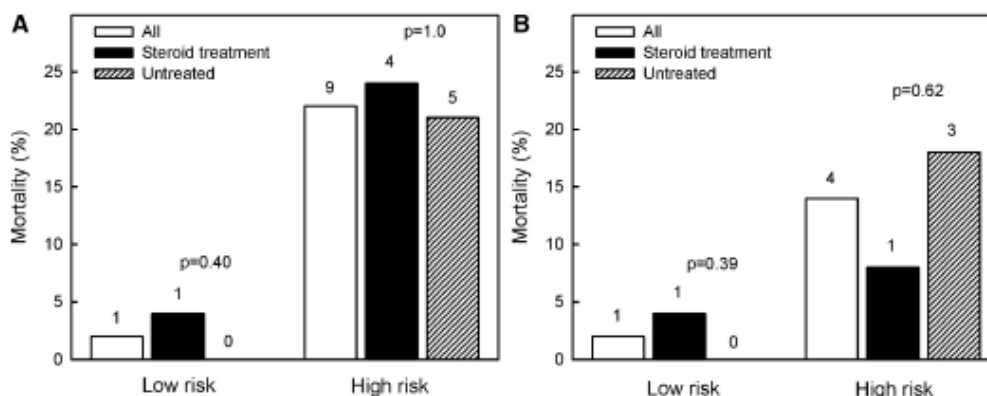


Figure 4. Intrauterine (A; n=107) and neonatal (B; n=90) mortality in fetuses with known presence or absence of risk factors at diagnosis, second- and third-degree atrioventricular block, and fetal exposure to maternal anti-Ro/SSA and/or anti-La/SSB antibodies. Mortality is shown by treatment group. High risk denotes the presence of at least 1 risk factor: gestational age <20 weeks, ventricular rate ≤50 bpm, presence of hydrops, or impaired left ventricular function. Low risk denotes those without any risk factors. Numbers on top of bars are numbers of cases. Comparisons are between treated and untreated patients.

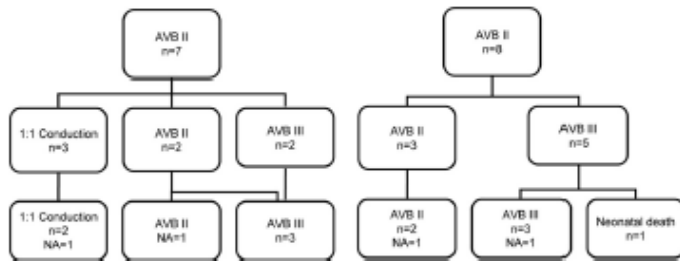


Figure 5. Outcome of 15 fetuses with second-degree atrioventricular block (AVB II) at diagnosis. Seven steroid-treated patients are presented on the left; 8 untreated patients are presented on the right. Middle row shows numbers at birth; bottom row, numbers at follow-up. NA indicates not available; AVB III, third-degree AVB.

Postnatal Outcome

Of 175 fetuses originally enrolled in the study, 26 died before birth or during the neonatal period and 11 were lost to follow-up (Figure 2). The remaining 138 infants were followed up for an average of 3.2 years (range, 1 month–8.1 years; Table 5). Two infants died before and another 2 died after 1 year of age. Twenty-four had not reached the age of 1 year within the time limit of the study, and 6 were lost to follow-up (Figure 2). One child's death was due to a pacemaker complication. Eight patients developed cardiomyopathy, which resulted in the death of 1 infant. All but 1 mother were antibody positive (6/8 Ro positive; one LA positive), and in 3, the diagnosis of cardiomyopathy was made before birth. Fetuses receiving transplacental steroids were delivered somewhat earlier (gestational age, 36.6 ± 2.7 versus 37.4 ± 2.4 weeks; $P=0.04$) with no significant difference in birth weight (2.7 ± 0.6 versus 2.9 ± 0.6 kg; $P=0.08$).

In this study, 31 pregnancies were reported to be antibody negative. If these pregnancies are considered to be truly antibody negative, then fetal mortality and neonatal mortality did not differ significantly between antibody-positive and -negative pregnancies (17 of 120 [14%] versus 7 of 31 [23%]; $P=0.27$) in those with known outcome at 1 month of age.

Pacing

A permanent pacemaker was implanted in 102 children. Sixty of the children (43%) alive at 1 month were paced, and 69%

Table 5. Outcome of 148 Children With Atrioventricular Block and Known Outcome at 1 Month of Age

	All Cases	Steroid Treated	Untreated
Follow up time of survivors at 1 mo of age (n=138), y	3.3 (0.1–8.1)	2.6 (0.1–7.8)	3.7 (0.2–8.1)
Age at pacing	10 d (1 d–7.9 y)	7 d (1 d–5.2 y)	10 d (1 d–7.9 y)
Pacemaker (at 1 mo of age), n (%)	60/138 (43)	25/53 (47)	35/85 (41)
Pacemaker (at 1 y of age), n (%)	74/107 (69)	32/42 (76)	42/65 (65)
Cardiomyopathy, n (%)	8/120 (7)	4/52 (8)	4/68 (6)
Infant death (≤ 1 y), n (%)	2/109 (2)	0/42	2/67 (3)
Childhood death (> 1 y), n	2	1	1

Values are given as median with range when appropriate. Cases are divided into groups based on transplacental steroid treatment.

were paced by 1 year (Table 5). An epicardial approach was used in the majority (81%) at a median age of 10 days (range, 1 day–7.9 years), and a transvenous approach was used in 19% (median, 2 months; range, 1 day–2.2 years). Fifty-nine had a dual-chamber pacemaker as the initial pacing mode with 1 death at 8 days of age from septicemia after pacemaker implantation and 1 in childhood from cardiac strangulation by the pacing wire.

Discussion

In this retrospective multicenter study, we describe the current treatment practices and outcomes in the largest reported data set of fetuses diagnosed with isolated AVB II and III. Our results confirm that there is no consensus regarding treatment with steroids. At some centers, no patients were treated, whatever the fetal status, whereas at others, almost all were treated. There was no correlation between the number of cases submitted from a center and the proportion treated.

In contrast to what might have been expected, the sicker fetuses were not more likely to be offered therapy. Because the groups were comparable at the time of diagnosis, except for a lower gestational age at diagnosis in the treated group, we could compare outcomes between the treated and untreated cohorts. We detected no significant differences in fetal or neonatal mortality, even when adjusting for earlier gestation at diagnosis in the treated group. Our results contrast with those of Jaeggi and colleagues,⁶ who described a lower mortality rate in fetuses treated with steroids compared with their untreated historical control subjects. The most striking difference was a mortality rate close to 50% in the control subjects, whereas the 1-month survival during the later treatment period was similar to the results of the present study. An examination of the Jaeggi et al data demonstrates that risk factors shown in our study to be associated with a poor early outcome were present in half of the 16 historical control subjects compared with one third of the 21 cases reported from the later period. Our survival experience in untreated cases is more comparable to that published in a more recent study,¹⁵ the largest single-center study so far in which 51 of 57 (89%) of fetuses with isolated AVB II or III not receiving steroid treatment had a 1-month survival of 80%. However, in contrast to our study, mortality was high in the steroid-treated fetuses, with only 3 of 6 surviving to 1 month of age.

We found a clear correlation between gestational age at diagnosis and the risk of intrauterine or neonatal death, with a better outcome in those diagnosed after 23 weeks, when 92% were alive at birth. Patients in the Jaeggi et al⁶ study were approximately the same gestational age at diagnosis as in ours, without any significant difference in nonsurvivors compared with those who survived (median, 26.5 versus 25 weeks). Fetuses in the Lopes et al study¹³ were diagnosed at a median gestation of 29 weeks. Caution must be exercised, however, because the time interval between onset of disease and age at diagnosis may depend on the frequency and timing of midwife surveillance and ultrasound screening programs, which may differ between countries.

In agreement with others, we report reversion of incomplete heart block in 5 steroid-treated fetuses with AVB II (3 of 5) or AVB II to III (2 of 5), but only two of these children (with known outcome) remained in sinus rhythm at a follow-up of 1 and 2.7 years. Permanent reversal of fetal AVB II in anti-Ro/SSA- and/or anti-La/SSB-positive mothers is a rare finding,¹⁶ and to the best of our knowledge, no cases of spontaneous resolution of verified AVB II in fetuses of antibody-positive mothers have been reported, whereas cases of reversal after steroid treatment have been described before.^{2,4,17} This indicates a possible effect of early steroid treatment in some of our cases.

Fetal hydrops is associated with a high risk of intrauterine death unless a treatable cause is identified^{13,18,19} and left ventricular function are also bad prognostic signs,¹⁹ but the impact of having at least one of these risk factors, including early gestational age at time of diagnosis, has, to the best of our knowledge, not been studied before.

In our study, intrauterine mortality and neonatal mortality were 22% and 18% in the groups with risk factors compared with 2% and 3% in those without risk factors. We think these findings support risk stratification of cases and enable more appropriate counseling and management.

Morbidity outcome in terms of requirement for pacing or prevalence of cardiomyopathy could not be evaluated adequately owing to a substantial variation in follow-up time and loss to follow-up. However, the incidence of cardiomyopathy may be underestimated in those with shorter periods of follow-up. Villain and colleagues²⁰ compared outcomes in children with AVB III and found that 28% of the antibody-positive children developed cardiomyopathy compared with none in the antibody-negative group; the mean age at follow-up was 4.6 years (range, 0.6 to 23 years). Only a few centers in our study reported side effects of steroids in the fetus; 5 of 11 reported cases came from 1 center, which suggests universal underreporting and is perhaps more common when fetal cardiology is practiced independently from a fetal medicine unit. Even fewer maternal side effects were described: in one case, managed in a fetal medicine center, serious side effects were recognized, including diabetes mellitus, adrenal insufficiency, and psychosis.

Study Limitations

The limitations of retrospective studies are well known, especially those with a multicenter design, in which it is more difficult to verify or check data. Consequently, our results

cannot rule out the possibility that some patients or groups of patients may benefit from steroid treatment. Moreover, AVB II to III was difficult to verify from the limited traces available. This can frequently be very difficult to distinguish from sustained complete AV block with a seemingly constant time relationship between atrial and ventricular activation, therefore resembling AVB II. Fetuses were considered to have no risk factors only if confirmation was provided for all 4 variables; thus, we have potentially underreported the absolute numbers of the cohort without risk factors, which accounts for the missing data in Table 3 and Figure 4.

Conclusions

The results of our study do not support a therapeutic strategy of universal treatment with steroids for fetuses of anti-Ro/SSA- or anti-La/SSB-positive women with AVB III. However, it is important to emphasize that because of the retrospective design, we cannot rule out a possibly beneficial, or even harmful, effect of steroids. Our results in the subgroup with AVB II indicate that in this situation, steroids might be beneficial in decreasing the risk of progression to AVB III.

Because our data do not point to a clearly beneficial or harmful effect of steroids on the fetus with isolated AVB II or III, a randomized trial would, in our opinion, be ethical. However, because the observed mortality in this report was 16%, 253 patients would be required in each arm (treated versus untreated) to detect a 50% reduction in mortality from steroid treatment at a 5% significance level with 80% power. An alternative study would be to include only fetuses with AVB II in a randomized study with the hypothesis that steroids decrease the risk of progression to AVB III, but recognition of such cases is even rarer. The difficulty in recruiting large numbers of fetuses with such a rare condition is likely to make such studies impossible to conduct.

Acknowledgments

The Fetal Working Group of the European Association of Pediatric Cardiology would like to acknowledge the following members who contributed cases to this study: G. Sharland and J.M. Simpson, Evelina Children's Hospital, London, UK; H.M. Gardiner and J.S. Carvalho, Royal Brompton Hospital, London, UK; J. Marek and V. Tomek, University Motol Hospital, Prague, Czech Republic; H. Jicinska, University Hospital and Masaryk University Brno, Czech Republic; H. Eliasson and S.-E. Sonesson, Karolinska University Hospital, Stockholm, Sweden; J. Dangel and A. Hamela-Olkowska, Medical University of Warsaw, Warsaw, Poland; P. Zielinsky, L. Nicoloso, and M. Moraes, Institute of Cardiology, Porto Alegre, Brazil; M.W. Freund, University Hospital Utrecht, Utrecht, the Netherlands; M. Respondek-Liberska, Institute Polish Mother's Memorial Hospital, Lodz, Poland; M. Mellander, Queen Silvia Children's Hospital, Gothenburg, Sweden; S. Sridharan, Great Ormond St Hospital for Children, London, UK; J. Bartrons, Hospital Clinic, Sant Joan de Déu, Barcelona, Spain; B. Ostergaard Cristensen, Skejby University Hospital, Aarhus, Denmark; V. Fesslova, Centro Cardiovascolare San Donato, Policlinico San Donato IRCCS, Milan, Italy; S.A. Clur, Academic Medical Center, Amsterdam, Netherlands; A. Galindo, Hospital Universitario 12 de Octubre, Madrid, Spain; G. Tulzer, Kinderherzzentrum, Linz, Austria; I. Bianca and A. di Pino, San Vincenzo Hospital, Taormina, Italy; V. Zidere, Children's Hospital Gailezers, Riga, Latvia; R. Oberhoffer, The German Heart Centre, Munich, Germany; L. Allan, King's College Hospital, London, UK; G. Nogueira, Santa Marta's Hospital, Lisbon, Portugal;

K. Wagner, Centre Hospitalier, Luxembourg; K. van Loo, University Hospital, Maastricht, the Netherlands; J.C. Areias and A. Carrico, Hospital de Sao João, Porto, Portugal; U. Doblanzki, Universitätsklinik für Kinder- und Jugendmedizin, Ulm, Germany; U. Salzer and E. Mlczoch, General Hospital, Vienna, Austria; and K. Hanséus, Skåne University Hospital, Lund, Sweden.

Sources of Funding

This study was devised by the Fetal Working Group of the European Association of Pediatric Cardiology, and financial support for site visits by Dr Eliasson was provided by the Fetal Working Group. Financial support for Drs Eliasson and Sonesson was provided through the regional agreement on medical training and clinical research (ALF) between Stockholm County Council and Karolinska Institutet, the Swedish Heart Lung Foundation, and Karolinska Institutet Research Foundations. Dr Eliasson was also supported by Freemason's in Stockholm Foundation for Children's Welfare and Samaritan Foundation.

Disclosures

None.

References

1. Michaelsson M, Engle MA. Congenital complete heart block: an international study of the natural history. *Cardiovasc Clin*. 1972;4:85-101.
2. Saleeb S, Copel J, Friedman D, Buyon JP. Comparison of treatment with fluorinated glucocorticoids to the natural history of autoantibody-associated congenital heart block: retrospective review of the Research Registry for Neonatal Lupus. *Arthritis Rheum*. 1999;42:2335-2345.
3. Raboisson MJ, Fouron JC, Sonesson SE, Nyman M, Proulx F, Garmache S. Fetal Doppler echocardiographic diagnosis and successful steroid therapy of Luciani-Wenckebach phenomenon and endocardial fibroelastosis related to maternal anti-Ro and anti-La antibodies. *J Am Soc Echocardiogr*. 2005;18:375-380.
4. Theander E, Brucato A, Gudmundsson S, Salomonsson S, Wahren-Herlenius M, Manthorpe R. Primary Sjogren's syndrome: treatment of fetal incomplete atrioventricular block with dexamethasone. *J Rheumatol*. 2001;28:373-376.
5. Gerosa M, Cimaz R, Stramba-Badiale M, Goulene K, Meregalli E, Trespidi L, Acaia B, Cattaneo R, Tincani A, Motta M, Doria A, Zulian F, Milanese O, Brucato A, Riboldi P, Meroni PL. Electrocardiographic abnormalities in infants born from mothers with autoimmune diseases: a multicentre prospective study. *Rheumatology*. 2007;46:1285-1289.
6. Jaeggi ET, Fouron JC, Silverman ED, Ryan G, Smallhorn J, Hornberger LK. Transplacental fetal treatment improves the outcome of prenatally diagnosed complete atrioventricular block without structural heart disease. *Circulation*. 2004;110:1542-1548.
7. Breur JM, Visser GH, Kruijze AA, Stoutenbeek P, Meijboom EJ. Treatment of fetal heart block with maternal steroid therapy: case report and review of the literature. *Ultrasound Obstet Gynecol*. 2004;24:467-472.
8. Costedout-Chalumeau N, Amoura Z, Le Thi Hong D, Wechsler B, Vauthier D, Ghillani P, Papo T, Fain O, Musset L, Piette JC. Questions about dexamethasone use for the prevention of anti-SSA related congenital heart block. *Ann Rheum Dis*. 2003;62:1010-1012.
9. Whitelaw A, Thorsen M. Antenatal steroids and the developing brain. *Arch Dis Child Fetal Neonatal Ed*. 2000;83:F154-F157.
10. Modi N, Lewis H, Al-Naqeeb N, Ajayi-Obe M, Dore CJ, Rutherford M. The effects of repeated antenatal glucocorticoid therapy on the developing brain. *Pediatr Res*. 2001;50:581-585.
11. Rosenthal E, Gordon PA, Simpson JM, Sharland GK. Letter regarding article by Jaeggi et al, "transplacental fetal treatment improves the outcome of prenatally diagnosed complete atrioventricular block without structural heart disease." *Circulation*. 2005;111:e287-e288.
12. Groves AM, Allan LD, Rosenthal E. Therapeutic trial of sympathomimetics in three cases of complete heart block in the fetus. *Circulation*. 1995;92:3394-3396.
13. Berg C, Geipel A, Kohl T, Breuer J, Germer U, Krapp M, Baschat AA, Hansmann M, Gembruch U. Atrioventricular block detected in fetal life: associated anomalies and potential prognostic markers. *Ultrasound Obstet Gynecol*. 2005;26:4-15.
14. Cuneo BF, Zhao H, Strasburger JF, Ovadia M, Huhta JC, Wakai RT. Atrial and ventricular rate response and patterns of heart rate acceleration during maternal-fetal terbutaline treatment of fetal complete heart block. *Am J Cardiol*. 2007;100:661-665.
15. Lopes LM, Tavares GM, Damiano AP, Lopes MA, Aiello VD, Schultz R, Zugaib M. Perinatal outcome of fetal atrioventricular block: one-hundred-sixteen cases from a single institution. *Circulation*. 2008;118:1268-1275.
16. Askanase AD, Friedman DM, Copel J, Dische MR, Dubin A, Starc TJ, Katholi MC, Buyon JP. Spectrum and progression of conduction abnormalities in infants born to mothers with anti-SSA/Ro-SSB/La antibodies. *Lupus*. 2002;11:145-151.
17. Copel JA, Buyon JP, Kleinman CS. Successful in utero therapy of fetal heart block. *Am J Obstet Gynecol*. 1995;173:1384-1390.
18. Ismail KM, Martin WL, Ghosh S, Whittle MJ, Kilby MD. Etiology and outcome of hydrops fetalis. *J Matern Fetal Med*. 2001;10:175-181.
19. Jaeggi ET, Hamilton RM, Silverman ED, Zamora SA, Hornberger LK. Outcome of children with fetal, neonatal or childhood diagnosis of isolated congenital atrioventricular block: a single institution's experience of 30 years. *J Am Coll Cardiol*. 2002;39:130-137.
20. Villain E, Costedout-Chalumeau N, Marijon E, Boudjemline Y, Piette JC, Bonnet D. Presentation and prognosis of complete atrioventricular block in childhood, according to maternal antibody status. *J Am Coll Cardiol*. 2006;48:1682-1687.

CLINICAL PERSPECTIVE

Isolated congenital complete atrioventricular block in the fetus is a rare but potentially lethal condition, most frequently associated with transplacental passage of maternal anti-Ro/SSA autoantibodies. With the assumption that this triggers an inflammatory reaction and subsequent fibrosis in the atrioventricular node, transplacental steroid treatment has been used with the aim to mitigate cardiac damage, but the effect of steroid treatment on outcome is still unclear. In this retrospective multicenter study of 175 fetuses with second- or third-degree atrioventricular block, 38% were treated with fluorinated steroids. Ninety-one percent were alive at birth, and survival in the neonatal period was 93%, without any difference between steroid-treated and untreated patients. A gestational age <20 weeks, a ventricular rate \leq 50 bpm, the presence of fetal hydrops, and impaired left ventricular function at diagnosis were associated with an increased risk of death. The presence of \geq 1 of these risk factors was associated with a 10-fold increase in mortality before birth and a 6-fold increase in the neonatal period independently of treatment. Except for a slightly lower gestational age at diagnosis in treated than untreated patients, risk factors were equally distributed between groups. Reversion of incomplete atrioventricular block was seen in 5 steroid-treated patients, but only 2 of them remained in sinus rhythm at 1 and 2.7 years of age. Our results do not support universal treatment with steroids for antibody-exposed fetuses with complete atrioventricular block, but because of the retrospective design, we cannot rule out a possibly beneficial, or even harmful, effect of steroids.

6. Associated genetic abnormalities

In cases with cardiac abnormalities, it is also necessary to find possible additional structural extracardiac or genetic abnormalities, because these additional findings can change the prognosis and the outcome of the fetus.

Recently, new genetic methods have been developed and new associations between cardiac abnormalities and genetic disease have been found.

6.0.1 ANNEX 15

Jicinska H, Marek J, Brysova V, Gaillyova R, Kuglik P, Tlaskal T, Litzman J, Tax P, Navratil
Deletion of Chromosome 22q11 in Congenital Heart Disease.

Cesko-Slovenska Pediatrie. 1998;53(11):650-664

Main points of the publication:

The development of new genetic methods and genetic testing recently shows that the proportion of genetic congenital heart defects is higher than previously assumed. At the end of the 20th century, the etiology of some congenital heart defects called “conotruncal malformations” was discovered. It was after the implementation of the “fluorescence in situ hybridization” (FISH) method to the diagnostic process. It was found that some conotruncal malformations are associated with a 22q11 deletion.

The Genetic Department in the University Hospital Brno started with FISH examinations very early. The aim of our study was to present the early results of FISH examinations in patients with conotruncal malformations. From 1996 to 1998, in total 27 children and 5 fetuses with CHD were examined using the FISH method. The 22q11 deletion was found in 5 children (18%) and in 1 fetus (20%). In total, 22q11 deletions were diagnosed in 6 patients (26%) with conotruncal malformation. Thymus aplasia was found in 3 patients, a low level of T lymphocytes was found in 5 patients, and face dysmorphism was found in 3 patients. In 4 fetuses parents decided to terminate pregnancy. In total, 5 children died.

Delece chromozomu 22q11 u vrozených srdečních vad

H. Jičínská¹, J. Marek², V. Bryšová³, R. Gaillyová³, P. Kuglík⁴, T. Tláskal²,
J. Litzman⁵, P. Tax², J. Navrátil¹

Oddělení dětské kardiologie II. dětské interní kliniky FDN J. G. Mendela, Brno,¹

primář MUDr. J. Navrátil

Dětské kardiocentrum, FNŠP v Motole, Praha,²

přednosta MUDr. J. Škvránek, CSc.

Oddělení lékařské genetiky FDN J. G. Mendela, Brno,³

primářka MUDr. R. Gaillyová

Katedra genetiky a molekulární biologie Přirodovědecké fakulty Masarykovy univerzity, Brno,⁴

vedoucí prof. RNDr. J. Belichová, CSc.

Ústav klinické imunologie a alergologie, FN U Sv. Anny, Brno,⁵

přednosta prof. MUDr. J. Lokaj, CSc.

Souhrn

Stále dokonalejší genetické vyšetřovací metody prokazují, že z hlediska etiologie je podíl geneticky podmíněných vrozených srdečních vad (VSV) vyšší, než se předpokládalo. V poslední době se do popředí zájmu kardiologů dostává - díky metodě fluorescein in situ hybridizace (FISH) - delece chromozomu 22q11, která je podkladem onemocnění nazývaného souhrnně CATCH 22 (cardiac defects, abnormal facies, thymic hypoplasia, cleft palate, hypocalcemia), jehož součástí je i syndrom di Georgeův (DGS). I když je fenotyp tohoto syndromu vysoce variabilní, jsou pro DGS charakteristické aplazie nebo hypoplazie thymu, aplazie nebo hypoplazie příštítných tělísek, vrozené srdeční vady, dysmorfie obličeje a rozštěp patra. Vedle postižení imunologického a hormonálního systému jsou dominantním klinickým projevem DGS vrozené srdeční vady, nejčastěji konotrunkální malformace: interrupce aortálního oblouku, Fallotova tetralogie, atřezie plicnice s defektem komorového septa, společný arteriální trunкус a další.

Cílem této práce bylo zhodnotit první výsledky pre- a postnatálního stanovení delece 22q11 u pacientů s prokázanou VSV. Od roku 1996 bylo ve Fakultní dětské nemocnici v Brně vyšetřeno 27 dětí a 5 plodů s vrozenou srdeční vadou na přítomnost mikrolece chromozomu 22q11. Z tohoto souboru vyšetřených bylo celkem 23 konotrunkálních malformací. Chromozomální mikrolece 22q11 byla prokázána FISH metodou u 5 (18 %) ze všech vyšetřených dětí a u jednoho z 5 (20 %) plodů s jakoukoli VSV. Ve skupině 23 konotrunkálních malformací byla mikrolece 22q11 prokázána celkem v 6 případech (26 %). U poloviny pacientů nebyl vyvinut tymus, u všech 5 vyšetřených dětí byl prokázán snížený počet T lymfocytů, dysmorfie obličeje byla nalezena u 3 z 5 dětí. U dvou byla prokázána snížená hladina kalcia v séru a u jednoho i snížená hladina parathormonu.

Včasná diagnostika specifické konotrunkální VSV u dítěte s dysmorfii obličeje by měla být indikací FISH vyšetření pro možnou přítomnost delece 22q11. Pacienti s anomálním vývojem aortálního oblouku (zejména s jeho interrupcí) by měli být vyšetřeni bez ohledu na přítomnost či absenci dysmorfie obličeje. Včasné odhalení delece 22q11 zjednoduší a urychlí způsob péče o přidružená postižení související s možným imunitním defektem a postižením systému metabolismu kalcia. Prenatální průkaz delece 22q11 je důležitým ukazatelem v rozhodování o osudu gravidity a má zásadní význam pro další prekoncepční poradenství.

Klíčová slova: delece chromozomu 22q11, syndrom di Georgeův, vrozená srdeční vada, konotrunkální srdeční malformace

Summary

Deletion of Chromosome 22q11 in Congenital Heart Disease

Ever more perfect genetic examination methods provide evidence that from the etiological aspect the ratio of genetically conditioned congenital heart disease (CHD) is higher than assumed. Recently, due to the method of fluorescein in situ hybridization (FISH), is in the foreground of cardiologists interest the deletion of chromosome 22q11 which is the basis of a disease included under the term of CATCH 22 (cardiac defects, abnormal facies, thymic hypoplasia, cleft palate, hypocalcaemia), part of which is also di George's syndrome (DGS). Although the phenotype of this syndrome is highly variable, characteristic features of DGS are aplasia or hypoplasia of the thymus, aplasia or hypoplasia of the parathyroid glands, congenital heart disease, facial dysmorphism and cleft palate. In addition to affections of the immunological and hormonal system dominant clinical manifestations of DGS are congenital heart diseases, most frequently conotruncal malformations: interruption of the aortic arch, Fallot's tetralogy, atresia of the pulmonary artery with ventricular septal defect, a common arterial trunk etc.

The objective of the present work was to evaluate the initial results of pre- and postnatal assessment of deletion of 22q11 in patients with confirmed CHD. Since 1996 in the University Children's Hospital in Brno 27 children and 5 fetuses with congenital heart disease were examined for the presence of microdeletion of chromosome 22q11. This group comprised a total of 23 conotruncal malformations. Chromosomal microdeletion of 22q11 was proved

by the FISH method in 5 (18%) of all examined children and in one of 5 (20%) fetuses with CHD. In the group of 23 conotruncal malformations microdeletion of 22q11 was proved in a total of 6 cases (26%). In half the patients the thymus was not developed, in all 5 examined children there was a reduced number of T lymphocytes, facial dysmorphism was found in three of five children. In two a reduced serum calcium level was recorded and in one a reduced level of parathormone.

Early diagnosis of specific conotruncal CHD in children with facial dysmorphism should be an indication for FISH examination because of the possible presence of 22q11 deletion. Patients with an abnormal development of the aortic arch (in particular its interruption) should be examined regardless of the presence or absence of facial dysmorphism. Early detection of 22q11 deletion will simplify and hasten the care of associated affections associated with a possible immune defect and affection of the calcium metabolism. Prenatal evidence of 22q11 deletion is an important indicator for decision on the fate of pregnancy and should be of basic importance for further preconception counseling.

Key words: deletion of chromosome 22q11, di George's syndrome, congenital heart disease, conotruncal cardiac malformation

O.

Úvod

Etiologie vrozených srdečních vad (VSV) je multifaktoriální. Doposud všeobecně uznávaná schémata (8) udávají asi 80% podíl vlivu zevního prostředí (kardiotropní viry, diabetes mellitus matky, expozice teratogeny, alkohol a další), podíl chromozomálních abercií (10%) a mutace genů (5-10%) v etiologii VSV jsou významně nižší. Avšak podle výsledků genetických výzkumů prováděných v posledních letech je patrné, že podíl geneticky podmíněných VSV se zvyšuje přímo úměrně s objevem nových chromozomálních odchylek, podmiňujících vznik často specifických srdečních malformací. Mezi doposud nejčastěji se vyskytující chromozomální abercií sdruženými s vrozenými srdečními vadami patří především trizomie 21., 13., 15. a 18. chromozomu, známé jsou i syndromy s abercími vázanými na pohlavní chromozomy, sdruženými s VSV (Turnerův, Klinefelterův apod.). Delece chromozomů, například 5q-, 11q-, jako původců vzniku VSV byly prokazovány víceméně sporadicky.

V roce 1981 poprvé de la Chapelle a spol. (2) popsali rodinu s translokací zahrnující chromozom 20 a 22 na 20q11 a 22q11 -t(20,22), (q11, q11), ve které čtyři její členové s nebalancovanou formou měli syndrom di Georgeův (zahrnující aplazii nebo hypoplazii tymu, aplazii nebo hypoplazii předstítných tělísek, konotrunkální srdeční malformace, dysmorfii obličeje a rozštěp patra). Od začátku 90. let se objevují stále častěji práce prokazující delecí nebo mikrodelecí na dlouhém raménku 22. chromozomu u fenotypicky daleko širšího a variabilnějšího spektra pacientů, souborně řazených pod syndrom označovaný CATCH 22 (cardiac defects, abnormal facies, thymic hypoplasia, cleft palate, hypocalcemia). Kromě DGS je pod CATCH 22 řazen i velo-kardio-faciální a Sprintzenův syndrom.

Vzhledem k vysoce variabilnímu fenotypu dysmorfie obličeje a často i velmi omezené mimosrdeční symptomatice manifestaci je postižení kardiovaskulárního systému s klinickým nálezem odpovídajícím příslušné specifické vrozené srdeční vadě často hlavním projevem jinak velmi komplexní nemoci, postihující kromě srdce a oběhového systému i systém imunitní a hormonální.

Cílem této práce je uvést první zkušenosti s pre- a postnatálními diagnostickými možnostmi syndromu di Georgeova (DGS), s analýzou postižení kardiovaskulárního a imunitního systému a využitím nových poznatků pro další osud postižených dětí, včetně prenatálního období.

Soubor pacientů a metody


Od roku 1996 bylo na kardiologickém oddělení II. dětské interní kliniky Fakultní dětské nemocnice (FDN) ve spolupráci s oddělením lékařské genetiky FDN a Přírodovědecké fakulty Masarykovy univerzity v Brně indikováno genetické vyšetření delecí 22. chromozomu u 27 dětí a 5 plodů s prokázanou vrozenou srdeční vadou. Pro delecí 22q11, typickou tzv. konotrunkální malformaci srdce, bylo genetické vyšetření provedeno u 19 z 27 dětí (u zbývajících 8 dětí bylo vyšetření indikováno pro klinické podezření na DGS: dysmorfii obličeje nebo imunodefekt). Dominantní věkovou skupinou byli novorozenci (n = 18), věk zbývajících 9 dětí se pohyboval od 4 měsíců do 12 let.

Při prenatálním genetickém vyšetření pěti plodů byla vyšetřena fetální pupečnicková krev (kordocentéza) ve II. trimestru gravidity. Indikací vyšetření byl průkaz VSV při screeningovém prenatálním echokardiografickém (ECHO) vyšetření, provedeném mezi 20. a 22. gestačním týdnem. Indikací genetického vyšetření u dětí byl průkaz vrozené srdeční vady. Celkem ve 23 případech VSV dětí a plodů byla prokázána pro DGS typická konotrunkální VSV, v 9 případech byl typ VSV odlišný. Diagnóza vrozené srdeční vady všech 27 dětí byla stanovena echokardiografickým, klinickým, rtg a EKG vyšetřením. Ve 3 případech byla indikována doplňující srdeční katetrizace s angiografií. U 14 dětí operovaných pro VSV byla diagnóza ověřena peroperačně.

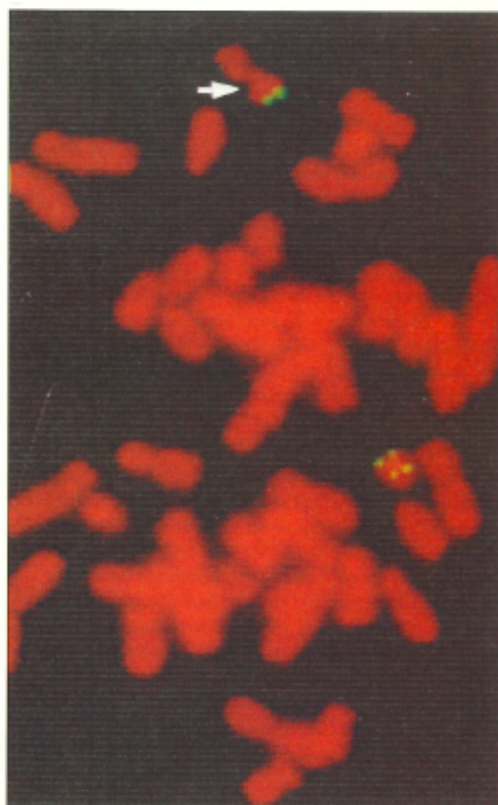Čtyři z pěti těhotenství s prokázanou VSV byla rozhodnutím rodičů předčasně ukončena a prenatální ECHO diagnóza byla ověřena sekčním vyšetřením, stejně tak jako u 5 zemřelých dětí (dvě děti s operovanou VSV zemřely z jiné příčiny, ze tří novorozenců dvě zemřely pro inoperabilní VSV a jedno pro nemožnost chirurgické korekce z důvodu nízké porodní hmotnosti). Jedno těhotenství s prokázanou VSV u plodu pokračovalo, prenatální diagnóza Fallotovy tetralogie byla postnatálně ověřena echokardiografií.

Pro detekci přítomnosti mikrodelece chromozomu 22q11.2 byla použita technika fluorescenční in situ hybridizace (FISH) s použitím sond firmy Oncor značených digoxigenem a následně detekovaných protilátkami konjugovanými s fluoresceinem. Celková DNA byla při tom barvena propilum jodidem. Preparáty byly prohlíženy pomocí fluorescenčního mikroskopu (Olympus BX-60) s obrazem snímaným barevnou CCD kamerou (COHU), který byl dále analyzován pomocí systému analýzy obrazu LUCIA M. Ve FISH testu byly

testovací a kontrolní sondy hybridizovány do metafáze chromozomů (obr. 1). Kontrolní sonda (D 22S39), která se hybridizuje do distálního konce 22q, byla použita k potvrzení správnosti přítomnosti dvou kopií dlouhého raménka chromozomu 22. Testovací sonda (D 22S75) mapovala proximální konec chromozomálního regionu di George. U normálního jedince byly přítomny 2 signály z každé sondy. Absence signálu testovací sondy na homologním chromozomu odpovídala mikrodeleci tohoto lokusu (obr. 2).



Obr. 1. K detekci syndromu Di Georgeova byly použity 2 sondy pro 22. chromozom. Testovací sonda (D 22S75) mapuje proximální konec chromozomálního regionu di George. Kontrolní sonda (D 22S39) se hybridizuje do distálního konce 22q.



Obr. 2. Defekce syndromu di Georgeova pomocí fluorescenční in situ hybridizace (FISH). Absence signálu testovací sondy na homologním chromozomu odpovídá mikrodeleci lokusu 22q11.2.

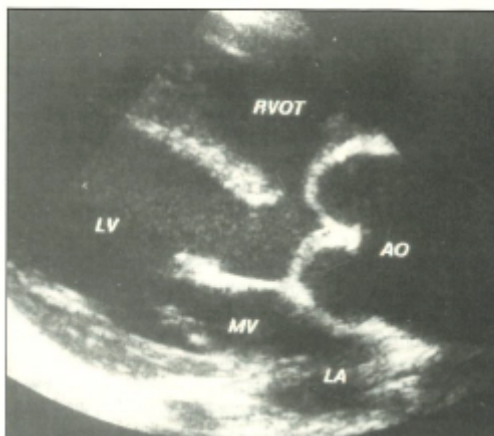
Fig. 2. Detection of di George's syndrome by in situ hybridization (FISH). Absence of signal of testing probe on homologous chromosome corresponds to microdeletion of locus 22q11.2.

Lymfocytární subpopulace byly zjišťovány pomocí přímé imunofluorescence za použití monoklonálních protilátek (firmy Becton Dickinson). Pozitivní buňky byly stanoveny na průtokovém cytometru (Coulter EPICS XL). Jako referenční byly použity tyto hodnoty lymfocytárních subpopulací: CD3+ (pan-T lymfocyty): 58 - 85 %, CD4+ (pomocné T lymfocyty): 35 - 60 %, CD8+ (tlumivé/cytotoxické T lymfocyty): 15 - 35 %. Hladiny imunoglobulinů byly stanoveny laserovým nefelometrem (Behring BN II) za použití antisér firmy Behring.

Funkce přštítných tělísek byla sledována laboratorním biochemickým vyšetřením hodnot vápníku v séru a hladin parathormonu v séru. Za hypokalcémií byla považována hladina celkového nebo ionizovaného kalcia v séru nižší než referenční hodnoty: celkové kalcium 2,2 - 2,7 mmol/l, ionizované kalcium 1,12 - 1,23 mmol/l, hladina parathormonu: 0,9 - 6,2 pmol/l.

Výsledky vyšetření a sledování osudu pacientů

V souboru 27 vyšetřených dětských pacientů mělo 9 dětí Fallotovu tetralogii (obr. 3). Ze 4 dětí s dvojitou pravou komorou byl normální vztah velkých arterií u dvou a transpozici vztah také u dvou. Tři děti měly společný arteriální truněk. U dvou dalších byla prokázána interrupce aortálního oblouku s defektem komorového septa, další dva pacienti měli izolovaný defekt komorového septa a rovněž u dvou dětí byl prokázán syndrom hypoplazie levého srdce. Nekorigova-



Obr. 3. Dvourozměrná echokardiografie. Vyšetření v parasternální dlouhé ose srdeční dokumentuje nasedání aorty (AO) nad defekt komorového septa u pacienta s Fallotovou tetralogií. Stejný nálezn lze získat u pacientů s dalšími konotrunkálními vrozenými srdečními vadami, například atrézií plicnice s defektem komorového septa nebo společným arteriálním truněkem. LA = levá síň, LV = levá komora, MV = mitrální chlopeč, RVOT = výtokový trakt pravé komory.

Fig. 3. Two-dimensional echocardiography. Examination in parasternal long cardiac axis indicates insertion of the aorta (AO) above the ventricular septal defect in a patient with Fallot's tetralogy. The same finding can be obtained in patients with other conotruncal congenital heart disease, e.g. atresia of the pulmonary artery with a ventricular septal defect or common arterial trunk. LA = left atrium, LV = left ventricle, MV = mitral valve, RVOT = right ventricular outflow tract.

Tab. 1. Charakteristika pacientů a výsledky vyšetření u případů s prokázanou delecí chromozomu 22q11.

Pacient	Věk při diagnóze vrozené srdeční vady	Sex	Typ vrozené srdeční vady	Tymus	Relativní počet T lymfocytů Hladina imunoglobulinů	Hladina celkového kalcia v séru	Dysmorfie obličeje	Další osud
1	Prenatálně ve 20. týdnu gravidity	M	Fallotova tetralogie (TOF)	normální	CD3 44-47 % ↓ CD4 19-22 % ↓ CD8 24-29 % n IgG n IgA n IgM n	2,5 mmol/l n	ano + rozštěp měkkého patra	Po operaci srdce ve velmi dobrém stavu
2	14 dní	F	Cévní prstenec se zdvojením aortálního oblouku, interrupcí levostranného a hypoplazií pravostranného aortálního oblouku, defekt komorového septa (DAA, IAA, VSD)	aplazie	CD3 24-40 % ↓ CD4 17-30 % ↓ CD8 7-9 % ↓ IgG n IgA n IgM n	2,57 mmol/l n	ano	Po operaci srdce ve velmi dobrém stavu
3	4 dny	F	Fallotova tetralogie (TOF)	aplazie	CD3 33-38 % ↓ CD4 20-24 % ↓ CD8 10-15 % ↓ IgG n IgA n IgM n	1,85 mmol/l ↓	ano	Po operaci srdce ve velmi dobrém stavu
4	4 dny	M	Interrupce aortálního oblouku typ B (IAA)	aplazie	CD3 26-39 % ↓ CD4 24-26 % ↓ CD8 10-11 % ↓ IgG ↓ IgA ↓ IgM n	1,9 mmol/l ↓	ne	Po operaci srdce ve velmi dobrém stavu
5	5 dnů	F	Společný arteriální trunkus (PTA)	normální	CD3 50 % ↓ CD4 28 % ↓ CD8 17 % n IgG n IgA n IgM n	2,5 mmol/l n	ne	Po operaci srdce ve velmi dobrém stavu
6	Prenatálně ve 22. týdnu gravidity	F	Dvojvýtoková pravá komora atrézie plicnice d-malpozice velkých tepen (DORV, PA, d-MGA)	normální	ne	ne	ne + klinodaktylie III. a IV. prstu levé ruky	Přerušeni gravidity ve 24. týdnu

F = ženské pohlaví, M = mužské pohlaví

ná transpozice velkých arterií, defekt komorového septa s pulmonální stenózou, koarktace aorty s defektem komorového septa, trikuspidální atrézie s pulmonální stenózou a mitrální atrézie s transpozicí velkých arterií a stenózou plicnice byly nalezeny v jednotlivých případech.

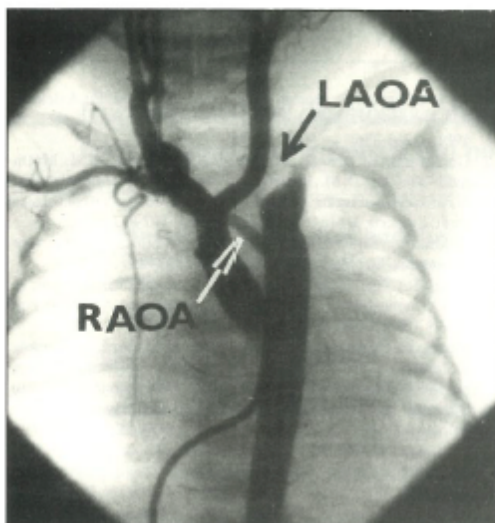
U 2 z 5 plodů byla prenatálně diagnostikována dvojvýtoková pravá komora, jednou s hypoplazií levé komory a normálním vztahem velkých arterií, jednou s atrézií plicnice a malpozicí velkých tepen. Jeden plod měl Fallotovu tetralogii, jeden společný arteriální trunkus a jeden hypoplazii levého srdce.

Z celkového spektra všech přítomných VSV u 27 dětí a 5 plodů patřilo mezi klasické konotrunkální VSV 23 srdečních malformací.

Chromozomální mikrodelece 22q11 byla prokázána u 5 (18 %) ze všech 27 vyšetřených dětí a u jednoho z 5 (20 %) plodů s jakoukoli VSV. Ve skupině 23 konotrunkálních malformací (19 dětí a 4 plody) byla mikrodelece 22q11 prokázána v 6 případech (26 %). Charakteristika pacientů a výsledky vyšetření u všech 6 případů (5 dětských pacientů a jeden plod) s prokázanou delecí 22q11 jsou shrnuty v tabulce 1.

U dvou pacientů s prokázanou mikrodelecí 22q11 byla diagnostikována Fallotova tetralogie, jednou již prenatálně ve 20. týdnu gravidity. U pacientky č. 2 byl diagnostikován cévní prstenec se zdvojením aortálního oblouku a defektem komorového septa (obr. 4). Levostranný oblouk byl za odstupem levé arteria carotis communis úplně přerušen (interrupce aortálního oblouku typu B), pravostranný oblouk byl za odstupem pravostranné arteria subclavia hypoplastický. Přítomen byl typický defekt komorového septa s posteriorní deviací infundibulárního septa, které zužovalo výtokový trakt levé komory. Pacient č. 4 měl interrupci aortálního oblouku mezi levou arteria carotis communis a arteria subclavia (typ B) s defektem komorového septa. U pacienta č. 5 byl nalezen společný arteriální trunkus II. typu s defektem komorového septa se samostatným odstupem obou větví plicnice z trunku.

Všech pět narozených dětí s prokázanou mikrodelecí 22q11 a konotrunkální vrozenou srdeční vadou je po radikální korekci VSV, provedené v Dětském kardiocentru ve FNŠP v Praze - Motole ve věku 5 dnů až 3,5 let. U pacienta č. 1 předcházela radikální korekci paliativní operace ve věku 1,5



Obr. 4. Angiokardiografické záznamy cévního prstence se zdvojením aortálního oblouku, interupcí levostranného (LAOA) a hypoplazií pravostřanného aortálního oblouku (RAOA) u pacienta č. 2.

Fig. 4. Angiokardiographic visualization of the vascular ring with duplication of the aortic arch, interruption of the left (LAOA) and hypoplasia of the right aortic arch (RAOA) in patient no. 2.

roku. U dvou pacientů byla nutná reoperace pro následné komplikace. U pacienta č. 2 byla nutná plikace kmene plicnice a angiopexie aortálního oblouku pro uzávěr levého bronchu. U pacienta č. 5 byla za 9 týdnů po operaci nutná exstirpace kalcifikovaného trombu z pravé síně. Všichni pacienti žijí, výsledek operace je ve dvou případech výborný, ve třech případech velmi příznivý. Dva pacienti mají lehkou psychomotorickou retardaci, další tři se vyvíjejí normálně.

U plodu s dvojvýtokovou pravou komorou s atrézií plicnice byla VSV zjištěna ve 22. týdnu gravidity prenatalním ECHO vyšetřením. Plod byl vyšetřen v rámci screeningového programu, matka neměla žádný rizikový faktor. U tohoto plodu bylo těhotenství na přání rodičů uměle ukončeno ve 24. týdnu gravidity a diagnóza VSV byla ověřena sekčním vyšetřením. Kromě srdeční vady mělo dítě ještě klinodaktylii 3. a 4. prstu levé ruky.

Přítomnost nebo chybění tymu byly ověřovány u 5 dětí peroperačně, u potraceného plodu sekčně. U tří pacientů byla zjištěna aplazie tymu, u dvou pacientů a plodu byl tymus vyvinut (tab. 1).

Imunologické vyšetření prokázalo u všech pacientů sníženou počtu T lymfocytů (CD3+), vždy byly sníženy i CD4+ (pomocné) T lymfocyty a u 3 pacientů i CD8+ (tlumivé/cytotoxické) T lymfocyty. U pacienta č. 4 jsme našli snížení hladin IgG a IgA. Po jednom roce života u něho došlo k normalizaci hladin imunoglobulinů. U pacienta č. 5 došlo k přechodnému snížení hladin imunoglobulinů v pooperačním období. U ostatních pacientů byly hladiny imunoglobulinů vždy normální (tab. 1).

Z těchto pěti pacientů dostává profylaxi co-trimoxazolem pacient č. 4, při této terapii je bez vážnějších infekcí. Tymové hormony byly opakovaně aplikovány u pacientů č. 1 a 3. Po této aplikaci nebyly prokázány výraznější změny subpopulací

T lymfocytů, zdravotní stav obou pacientů je však natolik uspokojivý, že nevyžadoval nasazení profylaktické terapie antibiotiky. Pacienti č. 2 a 5 jsou bez terapie.

U dvou pacientů byla zaznamenána hypokalcémie v novorozeneckém věku bez klinických projevů, později se hladina kalcia normalizovala. U tří pacientů byla vždy normokalcémie (tab. 1). U 4. pacienta byla zjištěna snížená hladina parathormonu.

Jeden nebo více rysů dysmorfie obličeje (hypertelorismus, krátké a rovné oční štěrby, prominence širokého kořene nosu, krátké filtrum, úzké rty, malá ústa, dysplastické, níže posazené boltce rotované dozadu) měli 3 pacienti, pacient č. 1 měl i rozštěp měkkého patra, pacient č. 5 byl bez stigmatizace.

Diskuse

Etiologie DGS je heterogenní, fenotyp DGS je výsledkem genetického podkladu a působení vlivů prostředí. Defekty v mnoha orgánových systémech, které vznikly během embryogeneze, nabízejí vysvětlení, že DGS je geneticky determinovaný defekt na vývojovém podkladě. Vzniká poruchou vývoje morfogenetické reaktivní jednotky, za kterou je považována hlavová a kranální část neurální lišty, ze které se formuje mezenchym třetího a čtvrtého žaberního oblouku. Třetí a čtvrtý žaberní oblouk tvoří základ pro tymus, příštítná tělíska, aorta a cévy hlavy a krku. Buňky z této oblasti neurální lišty také migrují do výtokového traktu srdce a jsou nezbytné pro normální septaci aorty a plicnice, proto porucha v době vývoje této části embrya vede k fenotypu DGS, včetně konotrunkálních malformací. Fenotyp DGS je charakterizován dysmorfii obličeje, rozštěpem patra, hypoplazií nebo aplazií tymu a příštítných tělísek. Další součástí DGS jsou specifické vrozené srdeční vady postihující vývoj dvou posledních segmentů primární srdeční trubice: srdeční konus, výtokový trakt pravé a levé komory a srdeční trunкус, arteriální konec srdeční trubice, z něhož se diferencují obě velké arterie, aorta a plicnice. Poruchou vývoje těchto segmentů pak vznikají konotrunkální VSV, typické pro DGS: společný arteriální trunкус, interupce aortálního oblouku, Fallotova tetralogie, dvojvýtoková pravá komora, pulmonální atrézie s defektem komorového septa, transpozice velkých arterií, tzv. malalignment typ subaortického defektu komorového septa.

I přes variabilitu fenotypu má převážná část pacientů podobnou rozsáhlou delecí dlouhého raménka chromozomu 22 rozsahu dvou megabází, která byla stanovena molekulární analýzou. Později se podařilo v rámci společného místa delecce definovat minimální kritické místo (MDGCR) pro nemoc - submikroskopickou delecí, což demonstrovalo DGS jako mikrodeleční syndrom. Moderní molekulární studie ukazují, že téměř 90 % pacientů s DGS má submikroskopickou delecí jedné kopie regionu 22q11.21 - q11.23 (2).

Standardní analýza karyotypu, dokonce s vysoce rozlišovací schopností, detekuje pouze 10 - 20 % delecí 22q11. Pro detekci mikrodelece 22q11 jsme použili FISH metodu, která je v současné době metodou volby pro toto vyšetření. Dvacet šest procent detekovaných mikrodelecí 22q11 v našem souboru 23 konotrunkálních VSV je v přibližném souladu s literárními údaji. Webber (9) udává přítomnost mikrodelece 22q11 u 15 - 20 % pacientů s konotrunkálními srdečními malformacemi, Goldmuntzová (4) prokázala DGS syndrom

u 29 % konotrunkálních VSV. Nejčastěji prokázanými konotrunkálními malformacemi jsou Fallotova tetralogie, atrézie plicnice s defektem komorového septa a interrupce aortálního oblouku. U pacientů s prokázanou delecí 22q11 a Fallotovou tetralogií bývá častější výskyt pravostranného aortálního oblouku s aberantní levostrannou arteria subclavia, u pacientů s delecí 22q11 a atrézií plicnice je častější výskyt aortopulmonálních kolaterál (6). Ve dvou případech jsme vyšetření indikovali u HLH, ačkoli tato VSV nepatří mezi konotrunkální malformace. Důvodem vyšetření je sporadický průkaz delecce 22q11 i u této anomálie (10).

Včasná identifikace pacientů s delecí 22q11 ulehčí diagnózu a zjednoduší a urychlí způsob péče o přidružená postižení. Nejčastějšími jsou poruchy imunity, hypokalcémie, opoždění růstu, neschopnost učení, porucha řeči, anomálie ledvin, respirační obtíže (časté bronchospazmy), poruchy psychiky a zraku. Z tohoto pohledu zaujímá prenatalní kardiologie významné místo při vyhledávání delecí 22q11. Při nálezů srdeční vady charakteristické pro delecí 22q11 v rámci screeningu VSV kontaktuje kardiolog genetika, který kromě karyotypizace zajistí vyšetření plodu na přítomnost delecce 22q11. Základní význam má i genetické poradenství zahrnující rodinu postiženého dítěte a vyšetření rodičů. Dosud provedené studie ukazují, že delecce se vyskytuje u 25 % párů rodičů, kteří mají dítě s delecí (9, 10). Pro tyto páry je samozřejmě riziko delecce 22q11 v dalším těhotenství 50%, což potvrzuje význam včasné prenatalní diagnostiky. U ostatních postižených se asi jedná o nově vzniklou mikrodelecí, která pak bude probandem dále přenášena.

Podezření na přítomnost DGS v prenatalním období lze vyslovit pouze na základě spolehlivé prenatalní echokardiografické diagnostiky. Vzhledem k poměrně dobře vytvořené struktuře prenatalního ultrazvukového screeningu vrozených srdečních vad v České republice (5, 8) lze ve spolupráci s genetikou ovlivnit další osud těhotenství, včetně možnosti časného ukončení těhotenství u plodu s komplexní VSV a prokázaným DGS, nebo s kontrolovaným těhotenstvím se zajištěním perinatální péče v centru, schopném provést operaci kritické VSV v novorozeneckém věku v optimálních podmínkách.

Literatura

1. De la Chapelle, A., Herva, R., Koivisto, M., Aula, P.: A deletion of chromosome 22 can cause di George syndrome. *Hum. Genet.*, 57, 1981, s. 253-256.
2. Goldmuntz, E., Driscoll, D., Budarf, M. L., Zackai, E. H., McDonald-McCinn, D. M., Biegel, J. A., Emanuel, B. S.: Microdeletions of chromosomal region 22q11 in patients with congenital conotruncal cardiac defects. *J. Med. Genet.*, 30, 1993, s. 807-812.
3. Goldmuntz, E., Emanuel, B. S.: Genetic disorders of cardiac morphogenesis. *Circ. Res.*, 80, 1997, č. 4, s. 437-443.
4. Hong, R.: The Di George anomaly. In: Rosen, F. S., Sellman, M. (eds.): *Immunodeficiencies*. Switzerland, Harwood Academic Publishers 1993, s. 167-176.
5. Marek, J., Škovránek, J., Šamánek, M., Povýšilová, V., Homola, J., Jelínek, Z., Navrátil, J.: Prenatal ultrasound screening of congenital heart disease in the Czech Republic: 10 year experience (v tisku).
6. Momma, K., Kondo, Ch., Matsuoka, R.: Tetralogy of Fallot with pulmonary atresia associated with chromosome 22q11 deletion. *J. Amer. Coll. Cardiol.*, 27, 1996, č. 1, s. 198-202.
7. Nora, J. J.: Causes of congenital heart diseases: Old and new modes mechanisms and models. *Amer. J. Cardiol.*, 5, 1993, č. 125, s. 1409-1419.
8. Škovránek, J., Marek, J., Povýšilová, V.: Prenatal kardiologie. *Čs. Pediat.*, 52, 1997, č. 6, s. 332-338.
9. Webber, S. A., Hatchwell, E., Barber, J. C. K., Daubency, P. E. F., Crolla, J. A., Salmon, A. P., Keeton, B. R., Temple, I. K., Dennis, N. R.: Importance of microdeletions of chromosomal region 22q11 as a cause of selected malformations of the ventricular outflow tracts and aortic arch: A three-year prospective study. *J. Pediatr.*, 129, 1996, č. 1, s. 26-32.
10. Wilson, D. L., Burn, J., Scambler, P., Goodship, J.: Di George syndrome: part of CATCH 22. *J. Med. Genet.*, 30, 1993, s. 852-856.

Došlo: 12. 6. 1998

MUDr. Hana Jelínková,
Oddělení dětské kardiologie
II. dětské interní kliniky,
FDN J. G. Menděla,
Černopolská 9,
662 63 Brno

REFERÁT

Battin, M. R. et al.: *Magnetic Resonance Imaging of the Brain in Very Preterm Infants: Visualisation of the Germinal Matrix, Early Myelination, and Cortical Folding (Zobrazování magnetickou rezonancí mozku u dětí velmi předčasně narozených: viditelnost zárodečné matrix, časná myelinizace a záhyby kůry)*. *Pediatrics*, 101, 1998, č. 6, s. 957-962.

Autofi zobrazovali mozek u dětí narozených před termínem v 25. až 32. týdnu gestačního věku s použitím novorozeneckého systému MR pomocí konvenčního spin echa (doba opakování 600, doba echa 20 ms), inverzního rychlého spin echa (TR 3530, efektivní doba echa 30, inverzní doba 950 ms) a T2-váženého rychlého spin echa (TR 3500, efektivní doba echa 208 ms). Zobrazili MR 17 dětí s mediánem 28 týdnů

gestačního věku (rozsah 24 až 31 týdnů) celkem 53krát mezi porodem a termínem. Medián počtu obrazů byl 2 (rozsah 1 až 9). U dětí s gestačním věkem pod 30 týdnů se zárodečná matrix zobrazila na okrajích postranních komor. Měla krátký T1 a krátký T2 a největší část se svinula mezi 30. a 32. týdnem GA. Bílá hmota měla relativně homogenní nízký signál až na pruhy změněného signálu (pravděpodobně z oblastí, které obsahovaly radiální glii a migrující buňky); byly nejzřetelnější v anterolaterálních a posterolaterálních oblastech u postranních komor. Myelinizace byla patrná v zadním mozgovém kmeni, mozečku a ve ventrolaterálních jádrech talamu. Děti měly v 25 týdnech GA velmi málo záhybů kůry, ale později se vyvinuly řádně.

Svatý, Praha

7. Consensus Statement and Recommendation

Both documents were prepared in accordance with international recommendations and in accordance with the need of specialized care in the Czech Republic.

7.0.1 ANNEX 16

Tomek V, **Jicinska H**, Klaskova E, Jehlicka P, Balatka P, Vít P, Hecht P, Reich O, Janousek J
An expert consensus statement on prenatal cardiology organization in the Czech Republic was prepared by the Working Group on Pediatric Cardiology of the Czech Society of Cardiology
Cor et Vasa 2020; 62(1):60-63

Main points of the publication:

The consensus statement was prepared by the Working Group on Pediatric Cardiology of the Czech Society of Cardiology. The aims of fetal cardiology, the screening program, and the connection between screening and specialized echocardiographic evaluation in the Czech Republic, and the indications for such evaluation were presented. The document defines who should perform specialized echocardiographic evaluations in the fetus, and who should counsel parents and other family members as may be necessary. Professor Jan Marek's experience in prenatal cardiology, especially regarding family counselling, was used in this consensus statement as well.

The publication has two main authors who contributed equally to the manuscript.

Odborné stanovisko k organizaci prenatální kardiologie v České republice.

Vypracované Pracovní skupinou dětské kardiologie České kardiologické společnosti

(Expert consensus statement on prenatal cardiology organization in the Czech Republic. Prepared by the Working Group on Pediatric Cardiology of the Czech Society of Cardiology)

Viktor Tomek^a, Hana Jičínská^b, Eva Klásková^c, Petr Jehlička^d, Pavel Balatka^e, Pavel Vít^b, Petr Hecht^a, Oleg Reich^a, Jan Janoušek^a

^a Dětské kardiocentrum, 2. lékařská fakulta Univerzity Karlovy a Fakultní nemocnice v Motole, Praha

^b Dětská kardiologie Pediatrické kliniky, Lékařská fakulta Masarykovy univerzity a Fakultní nemocnice Brno

^c Dětská klinika, Lékařská fakulta Univerzity Palackého a Fakultní nemocnice Olomouc

^d Dětská kardiologická ordinace, Plzeň

^e Dětská kardiologie a prenatální echokardiografie, Most

INFORMACE O ČLÁNKU

Historie článku:

Vložen do systému: 15. 8. 2019

Přepřacován: 11. 11. 2019

Přijat: 5. 12. 2019

Dostupný online: 20. 1. 2020

Klíčová slova:

Plod
Prenatální echokardiografie
Vrozená srdeční vada

Keywords:

Congenital heart defects
Fetus
Prenatal echocardiography

Úvod

Vrozená srdeční vada je nejčastější vrozenou vadou vedoucí k úmrtí v dětském věku.^{1,2} Její prevalence se udává mezi 4–13 na 1 000 živě narozených dětí. Strukturální vady srdce jsou nejčastěji nerozpoznanou vrozenou vadou v prenatálním screeningu vůbec.³ Správná prenatální detekce může zlepšit prognózu řady vrozených srdečních vad.^{4–6} Program prenatální kardiologie má i významné ekonomické dopady, ať již v důsledku ukončování těhotenství s komplexně postiženými plody, nebo pro výrazně nižší výskyt komplikací u pacientů s včas diagnostikovaným onemocněním a včas léčených.⁵ Screeningový program založený na multidisciplinární spolupráci nyní existuje ve většině rozvinutých zemí a dále se rozvíjí. Z doporučení ISUOG (International Society of Ultrasound in Obstetrics and Gynecology) pro ultrazvukové vyšetření plodu vyplý-

vá, že k efektivnosti takového systému výrazně napomáhá nízký práh při doporučení k echokardiografickému vyšetření u specialisty na prenatální kardiologii.⁷ Obdobný doporučující přístup zastává i AIUM (American Institute of Ultrasound in Medicine),⁸ AEPC (Association for European Paediatric and Congenital Cardiology)⁹ a American Heart Association.¹⁰

Cíl prenatální kardiologie

- Diagnostika srdečních abnormalit (vrozených srdečních vad, poruch srdečního rytmu a funkčních poruch fetoplacentární cirkulace), zejména kritických, jež vedou k ohrožení zdraví a života dítěte
- Seznámení rodičů s diagnostikovanou srdeční abnormalitou, možnostmi její léčby a prognózou tak,

Adresa pro korespondenci: MUDr. Viktor Tomek, Ph.D., Dětské kardiocentrum, 2. lékařská fakulta Univerzity Karlovy a Fakultní nemocnice v Motole, V Úvalu 84, 150 06 Praha 5, e-mail: viktor.tomek@fmotol.cz

© 2020, ČKS

DOI: 10.33678/cox.2019.085

Tento článek prosím citujte takto: Tomek V, Jičínská H, Klásková E, et al. Odborné stanovisko k organizaci prenatální kardiologie v České republice. Vypracované Pracovní skupinou dětské kardiologie České kardiologické společnosti. *Cox Vasa* 2020;62:60–62.

aby rodiče byli schopni rozhodnout o dalším osudu těhotenství

- Péče o těhotenství s diagnostikovanou srdeční abnormalitou ve spolupráci s gynekologem, genetikou a neonatologem
- Zahájení prenatální léčby v indikovaných případech
- Vytváření databáze s informacemi o prenatálně diagnostikovaných srdečních onemocněních a jejich dalším osudu

Organizace prenatální echokardiografie

Je založena na propojení screeningového a specializovaného echokardiografického vyšetření.

Screeningové vyšetření srdce plodu je součástí prenatálního ultrazvukového vyšetření, které provádí gynekolog. V případech, kdy vyšetření srdce není možné provést (z bezpečí) gynekologem, může být srdce vyšetřeno dětským kardiologem a vyšetření vykázáno jako screeningové.

Náplní screeningového vyšetření je základní zhodnocení anatomie, funkce a rytmu srdce.^{11,12} Cílem screeningového vyšetření je odlišení fyziologického nálezu od srdečních abnormalit a následně zajištění další péče o plod s diagnózou srdeční abnormality nebo podezření na ni.

Specializované vyšetření srdce plodu je prováděno lékařem s odbornou způsobilostí v oboru „dětská kardiologie“ (dále také dětský kardiolog) a je indikováno na základě jasných indikačních kritérií.

Indikace ke specializovanému prenatálnímu echokardiografickému vyšetření

Vycházejí z doporučení ISUOG, AIUM a AEPC a zohledňují přítomnost rizikových faktorů pro vznik vrozené srdeční vady^{4,9,10,11,14} a významnost rizika (nižší – riziko srdeční abnormality 1–3 %, vyšší – riziko srdeční abnormality > 3 %).¹⁰

Indikace ze strany matky a rodiny:

- Metabolické vady matky: pregestační diabetes mellitus, fenylketonurie (vyšší riziko), gestační diabetes mellitus se špatnou kompenzací ve III. trimestru těhotenství (nižší riziko)
- Užívání léků v graviditě
- Inhibitory angiotenzin konvertujícího enzymu (ACEI), kyselina retinová, nesteroidní antiflogistika ve III. trimestru (vyšší riziko)
- Antiepileptika, lithium, antidepresiva, nesteroidní antiflogistika v I. a II. trimestru (nižší riziko)
- Těhotenství po „in vitro fertilizaci“ (nižší riziko)
- Infekce v těhotenství (toxoplazmóza, cytomegalovirus, parvovirus, coxsackie virus, adenovirus, rubeola, další viry při prokázané sérokonverzi, eventuálně horečnaté onemocnění v I. trimestru těhotenství) (nižší riziko)
- Autoimunitní onemocnění matky s přítomností autoprotilátek třídy SSA/antiRo a SSB/antiLa (vyšší riziko)

- Přítomnost vrozených srdečních vad, kardiomyopatie u matky, otce, sourozenců a prarodičů (vyšší riziko), u jiných příbuzných než 1. a 2. stupně (nižší riziko)
- Chromosomální aberace, syndromy a jiná genetická postižení u matky nebo v rodině, jako např. myopatie, Marfanův syndrom (vyšší riziko)

Indikace ze strany plodu:

- Abnormální nálezy při screeningovém vyšetření srdce plodu: přítomná srdeční vada, podezření na srdeční vadu nebo nejasný nálezy na srdci (vyšší riziko)
- Bradykardie (srdeční frekvence < 100/min) nebo tachykardie (srdeční frekvence > 180/min) nebo častá nebo trvale nepravidelná srdeční frekvence u plodu (vyšší riziko)
- Extrakardiální vrozená vada (vyšší riziko)
- Chromosomální vada (vyšší riziko)
- Přítomnost výpotku nebo hydrospu u plodu (vyšší riziko)
- Monochoriální vícečetné těhotenství (vyšší riziko)
- Nevysvětlitelný polyhydramnion (nižší riziko)
- Zvýšená nuchální translucence > 95. percentil (vyšší riziko)
- Pulsatilní Index v ductus venosus v I. trimestru těhotenství > 95. percentil nebo absence ductus venosus (vyšší riziko)
- Trikuspidální regurgitace v I. trimestru těhotenství (vyšší riziko)
- Absence nosní kůstky (vyšší riziko)
- Abnormalita pupečníku („single umbilical artery“) nebo placenty (abnormální cévní spojky v placentě) (nižší riziko)
- Arteriovenózní cévní malformace zjištěné u plodu (nižší riziko)

Absolutní indikací ke specializovanému vyšetření srdce plodu dětským kardiologem představuje nálezy srdeční vady nebo podezření na ní při screeningovém vyšetření.

Cílem specializovaného vyšetření je přesné určení srdeční vady nebo poruchy srdečního rytmu, adekvátní konzultace pacientky o povaze a prognóze onemocnění a léčebných možnostech se znalostí jejich výsledků, návrh a zajištění správné léčby v indikovaných případech, organizace porodu a následně postnatální léčby. Dětský kardiolog provádí finální diagnostiku srdeční vady a poskytuje informace o prognóze. Bez této konzultace by neměla být stanovena indikace k „umělému přerušení těhotenství po uplynutí 12 týdnů délky těhotenství“.

Specializované echokardiografické vyšetření srdce plodu provádí dětský kardiolog s atestací z dětské kardiologie. Finální diagnózu vrozené srdeční vady a konzultaci o možnostech léčby dané vady a její prognóze provádí dětský kardiolog, který je vysoce erudován v oblasti prenatální kardiologie a který provádí nejméně 500 prenatálních echokardiografických vyšetření za rok a diagnostikuje nebo reviduje nejméně 30 závažných vrozených srdečních vad ročně.

Závěr

Možnosti léčby dětí s vrozenými srdečními vadami se neustále rozvíjejí. Jejich důsledkem je zlepšení prognózy u většiny srdečních vad a léčba těch, které byly donedávna považovány za neléčitelné. Finální diagnostika vrozené srdeční vady plodu a s ní související informace o způsobu léčby a prognóze dané vady má zásadní význam pro rozhodování rodičů o osudu těhotenství. Informace musejí být rodičům srozumitelně předány odborníkem erudovaným v oboru dětské kardiologie a kardiochirurgie, který je seznámen s novými diagnostickými a léčebnými postupy u dětí s vrozenou srdeční vadou. Rozhodnutí o dalším osudu těhotenství má být plně v kompetenci rodičů, kteří jsou zodpovědní za své dosud nenarozené dítě.

Prohlášení

Na vypracování rukopisu se stejnou měrou podíleli dva hlavní autoři MUDr. Viktor Tomek, Ph.D., a MUDr. Hana Jičínská, Ph.D.

Literatura

1. Simpson LL. Screening for congenital heart disease. *Obstet Gynecol Clin North Am* 2004;31:51–59.
2. Samánek M, Slavík Z, Zborilová B, et al. Prevalence, treatment, and outcome of heart disease in live-born children: a prospective analysis of 91,823 live-born children. *Pediatr Cardiol* 1989;10:205–211.
3. Cuneo BF, Curran LF, Davis N, et al. Trends in prenatal diagnosis of critical cardiac defects in an integrated obstetric and pediatric cardiac imaging center. *J Perinatol* 2004;24:674–678.
4. Bonnet D, Coltri A, Butera G, et al. Detection of transposition of the great arteries in fetuses reduces neonatal morbidity and mortality. *Circulation* 1999;99:916–918.
5. Tworetzky W, McElhinney DB, Reddy VM, et al. Improved surgical outcome after fetal diagnosis of hypoplastic left heart syndrome. *Circulation* 2001;103:1269–1273.
6. Marek J, Tomek V, Škovránek J, et al. Prenatal ultrasound screening of congenital heart disease in an unselected population: A 21-year experience. *Heart* 2011;97:124–130.
7. International Society of Ultrasound in Obstetrics and Gynecology, Carvalho JS, Allan LD, Chaoui R, et al. ISUOG Practice Guidelines (updated): sonographic screening examination of the fetal heart. *Ultrasound Obstet Gynecol* 2013;41:348–359.
8. AIUM practice guideline for the performance of fetal echocardiography. *J Ultrasound Med* 2011;30:127–131.
9. Allan L, Dangel J, Fesslova V, et al. Recommendation of the AEPG. Recommendations for the practice of fetal cardiology in Europe. *Cardiol Young* 2004;14:109–114.
10. Donofrio MT, Moon-Grady AJ, Hornberger LK, et al; American Heart Association Adults With Congenital Heart Disease Joint Committee of the Council on Cardiovascular Disease in the Young and Council on Clinical Cardiology, Council on Cardiovascular Surgery and Anesthesia, and Council on Cardiovascular and Stroke Nursing, Diagnosis and Treatment of Fetal Cardiac Disease: A Scientific Statement From the American Heart Association. *Circulation* 2014;129:2183–2242.
11. Novák P. Fyzikální principy a vyšetřovací technika. In: Calda P, Břešťák M, Fischerová D. *Ultrazvuková diagnostika v těhotenství a gynekologii*. Aprofema 2010;35–52.
12. Tomek V. Základní postupy vyšetření srdce. In: Calda P, Břešťák M, Fischerová D. *Ultrazvuková diagnostika v těhotenství a gynekologii*. Aprofema 2010;273–277.
13. Herskind AM, Almind Pedersen D, Christensen K. Increased prevalence of congenital heart defects in monozygotic and dizygotic twins. *Circulation* 2013;128:1182–1188.
14. Tararbit K, Houyel L, Bonnet D, et al. Risk of congenital heart defects associated with assisted reproductive technologies: a population-based evaluation. *Eur Heart J* 2011;32:500–508.

7.0.2 ANNEX 17

Zatocil T, Antonova P, Rubackova, Popelova J, Zakova D, Pokorna O, Chaloupecky V, Rohn V, Skalsky I, **Jicinska H**, Taborsky M, Kautzner J, Janousek J

Recommendations to organize care for adults with congenital heart disease in the Czech Republic.

Cor et Vasa 2018; Cor60(3): e331-e334

Main points of the publication:

This document was written by the Expertise committee of the Czech Society of Cardiology for adults with CHD based on the recommendations for organization of care for adults with congenital heart disease, and for training in the subspecialty of “Grown-up Congenital Heart Disease” in Europe, which is a position paper of the Working Group on Grow-up Congenital Heart Disease of the European Society of Cardiology.

The number of adults with CHD and survivals with CHD increased significantly in accordance with the development of paediatric cardiology and paediatric heart surgery. The prevalence of CHDs in adults is around 5 per 1000 adults. So there was a need to publish a study discussing the care of adults with congenital heart defects.

The care of adults with CHDs should follow the care of children with CHDs. Severe and complex CHDs should be followed up in specialized centres for adults with CHDs with appropriate personal and technical equipment. Currently there are three specialized centres for adults with CHD in the Czech Republic: the Hospital Na Homolce, the University Hospital Motol in Prague, and the Centre for complex care of CHDs in adults in Brno.



ELSEVIER

Available online at www.sciencedirect.com

ScienceDirect

Journal homepage: www.elsevier.com/locate/crvasa

Doporučení pro... | Guidelines

Doporučení pro organizaci péče o vrozené srdeční vady v dospělosti v České republice

(Recommendations to organize care for adults with congenital heart disease in the Czech Republic)

Tomáš Zatočil^a, Petra Antonová^b, Jana Rubáčková Popelová^c, Daniela Žáková^d, Olga Pokorná^d, Václav Chaloupecký^e, Vilém Rohn^b, Ivo Skalský^c, Hana Jičínská^f, Miloš Táborský^g, Josef Kautzner^h, Jan Janoušek^e

^a Interní kardiologická klinika, Lékařská fakulta Masarykovy univerzity a Fakultní nemocnice Brno, Brno, Česká republika^b Klinika kardiiovaskulární chirurgie, 2. lékařská fakulta Univerzity Karlovy a Fakultní nemocnice v Motole, Praha, Česká republika^c Kardiologické oddělení, Nemocnice Na Homolce, Praha, Česká republika^d Centrum kardiiovaskulární a transplantační chirurgie, Brno, Česká republika^e Dětské kardiocentrum, 2. lékařská fakulta Univerzity Karlovy a Fakultní nemocnice v Motole, Praha, Česká republika^f Pediatrická klinika, Lékařská fakulta Masarykovy univerzity a Fakultní nemocnice Brno; Centrum prenatální diagnostiky, Brno, Česká republika^g I. interní klinika – kardiologická, Lékařská fakulta Univerzity Palackého a Fakultní nemocnice Olomouc, Olomouc, Česká republika^h Klinika kardiologie, Institut klinické a experimentální medicíny, Praha, Česká republika

Tento dokument vypracovala Expertní komise pro vrozené srdeční vady (VSV) v dospělosti České kardiologické společnosti (ČKS) jako doplnění *Národního kardiiovaskulárního programu ČKS z roku 2013* v oblasti problematiky vrozených srdečních vad v dospělosti na podkladě *Recommendations for organization of care for adults with congenital heart disease and for training in the subspecialty of "Grown-up Congenital Heart Disease" in Europe: a position paper of the Working Group on Grown-up Congenital Heart Disease of the European Society of Cardiology* z roku 2014 [1] s ohledem na aktuální podmínky v České republice. Cílem dokumentu je optimalizovat poskytování péče dospělým s VSV v České republice v celé šíři, usnadnit jejich přechod z dětského věku do dospělosti, umožnit výzkum v oboru (populace je malá a unikátní) a výuku i trénink všech zúčastněných profesí i regionálních kardiologů podílejících se na sledování s cílem poskytovat péči založenou na důkazech („evidence-based care“), zastupovat zájmy oboru ve vztahu ke státním institucím, poskytovat informace lékařské veřejnosti a pacientům, konsolidovat zdroje.

Úvod

Incidence vrozených srdečních vad u novorozenců je 6–8/1 000 narozených dětí. S rozvojem pediatrické kardiologie a kardiologie od sedmdesátých let dvacátého století došlo k výraznému nárůstu přežití do dospělosti, které se v současné době pohybuje okolo 90 % [2]. Prevalence všech vrozených srdečních vad se odhaduje na 12/1 000 dětí a 5/1 000 dospělých a závažných VSV na 1,45/1 000 dětí a 0,38/1 000 dospělých [3], přičemž každoročně dochází k nárůstu počtu dospělých s VSV o 5 % [4]. Odhaduje se, že v současné době je v Evropské unii přibližně 2,3 milionu dospělých s VSV (ve srovnání s ischemickou chorobou srdeční, kde je počet 24 milionů) [5].

Pokud použijeme extrapolaci údajů uvedených výše, mělo by v České republice žít přibližně 53 000 dospělých nemocných s VSV (včetně defektů síňového septa a bikuspidální aortální chlopně), z toho cca 4 000 pacientů se závažnými VSV. Počet nemocných sledovaných v současné době třemi komplexními centry v ČR čítá podle jejich databází přibližně 9 000. Hospitalizace dospělých s VSV narostly od roku 2003

Adresa: MUDr. Tomáš Zatočil, Interní kardiologická klinika, Lékařská fakulta Masarykovy univerzity a Fakultní nemocnice Brno, Jihlavská 20, 625 00 Brno,

e-mail: zatočil@centrum.cz

DOI: 10.1016/j.crvasa.2018.03.009

Tento článek prosím citujte takto: T. Zatočil, et al., Recommendations to organize care for adults with congenital heart disease in the Czech Republic, *Cor et Vasa* 60 (2018) e331–e334, jak vyšel v online verzi *Cor et Vasa* na <https://www.sciencedirect.com/science/article/pii/S0010865018300237>

do roku 2010 o 81,5 % a průměrný věk při přijetí se také zvýšil z 53, 5 na 57,5 roku [6]. Popisovaný dramatický nárůst dokonce předčil hospitalizace dětských pacientů s VSV [7].

Díky poklesu časné mortality u těchto nemocných se moderní medicína nyní setkává s dlouhodobými komplikacemi vrozených srdečních vad, jako jsou chronické srdeční selhání, zvýšené riziko infekční endokarditidy, zvýšená zátěž arytmiemi, plicní hypertenze, chlopenní vady a komplikace v těhotenství. Celou řadu z VSV můžeme navíc zařadit mezi vzácná onemocnění, tzn. že postihují méně než pět osob z každých 10 000 [8]. Populace s VSV v dospělosti je a bude stále relativně malá, ale zároveň velmi heterogenní co do jednotlivých VSV i jejich komplikací a přístupu k nim. Toto doporučení využitím superspecializované multioborové péče v centrech pro VSV v dospělosti je v souladu s Národní strategií pro vzácná onemocnění na léta 2010–2020, tzn. že umožňuje zefektivnit diagnostiku a léčbu vzácných onemocnění a zajistit všem pacientům se vzácným onemocněním přístup k indikované a vysoce kvalitní zdravotní péči a následně sociální začlenění [9].

Organizace péče

Péče o VSV v dospělosti v ČR by měla navázat na dobře fungující systém péče o VSV v dětském věku. Péči v dětském věku pokrývá jedno specializované komplexní kardiologické centrum (Dětské kardiocentrum, Fakultní nemocnice v Motole) s dlouhodobě vykazovaným ročním počtem chirurgických výkonů mezi 400–500. Toto centrum má přímou návaznost na celostátní síť dětských kardiologů a úzce spolupracuje s neonatologickými a pediatrickými odděleními v celé ČR [10].

V dalším sledování VSV v dospělosti se obdobně využívá fungující síť mezi specializovanými centry pro VSV v dospělosti (dále VSV centra), komplexními kardiologickými centry (v každém by měla být specializovaná poradna pro dospělé s VSV s jedním až dvěma proškolenými lékaři), kardiologickými a interními pracovišti v regionech a síti ambulantních kardiologů a praktických lékařů. Centra VSV musejí aktivně pracovat na této síti, vytvořit fungující zpětnou vazbu, zpřístupnit konzultace a spoluvytvářet opatření společné péče.

Současná evropská doporučení [11] striktně nestanovují, které VSV vyžadují péči ve specializovaných centrech pro VSV v dospělosti a které ne. Za optimální model je nicméně

považováno alespoň jednorázové vyšetření pacienta s VSV po dosažení 18. roku věku v centru VSV, které na individuální bázi stanoví další režim a četnost sledování. Podrobná lékařská zpráva z centra VSV by měla shrnout dosavadní průběh onemocnění, včetně původní diagnózy, všech léčebných zásahů, komplikací a současného klinického stavu a stanovení další prognózy a způsobu sledování. V případech vysoké složitosti může být žádoucí při předávání z kardiologie dětského věku současná přítomnost pediatrického kardiologa a kardiologa pro dospělé centra VSV.

Rozdělení VSV dle komplexity ICHS lze použít i pro to, abychom správně rozhodli, kteří pacienti by měli být sledováni v centru VSV [12]. Všichni pacienti se středně a vysoce komplexními VSV mají být sledováni ve spolupráci s centry VSV. Pouze pacienti s jednoduchými VSV (tabulka 1) mohou být sledováni na ostatních kardiologických pracovištích s tím, že v případě diagnostické či terapeutické nejistoty či komplikace lze odeslat do centra VSV pacienta s jakoukoliv VSV.

Status specializovaných center pro VSV v dospělosti

Nadregionální centrum poskytuje superspecializovanou multioborovou péči o pacienty s VSV v dospělosti na nejvyšší úrovni, taktéž provádí školicí akce v oblasti VSV.

Tomu musí odpovídat personální, technické vybavení a zkušenosti s problematikou.

Personální vybavení

Kardiolog s odpovídající zkušeností s VSV (včetně echokardiografie)	≥ 2
Specialista na zobrazovací metody (MR, CT) s odpovídající zkušeností s VSV	≥ 1
Intravenózní kardiolog s odpovídající zkušeností s VSV	≥ 2
Kardiochirurg s odpovídající zkušeností s VSV	≥ 2
Anesteziolog s odpovídající zkušeností s VSV	≥ 2
Elektrofyzikolog s odpovídající zkušeností s VSV	≥ 1
Psycholog	≥ 1

Za odpovídající zkušenost personálu s VSV lze považovat atestaci z příslušného specializačního oboru (kardiologie, kardiochirurgie, radiologie a zobrazovací metody, anesteziologie a intenzivní medicína) a alespoň dvouletý intenzivní trénink v centru VSV. Je tak zajištěna dostatečná erudice personálu v místech s odpovídající koncentrací VSV a jejich komplikací.

Technické vybavení

EKG
Holterovské monitorování EKG
Zátěžové EKG
Holterovské monitorování TK
Epizodní záznamníky arytmií
Spiroergometrie
Echokardiografie (včetně jícnové, 3D)
MR srdce
CT srdce

Tabulka 1 – Jednoduché vrozené srdeční vady [12]

Bez korekčního výkonu
Izolované VSV aortální chlopně
Izolované VSV mitrální chlopně (vyjma padákové deformity, rozštěpu)
Malý defekt síňového septa
Malý defekt komorového septa bez asociovaných lézí
Lehká stenóza pulmonální chlopně
Malá otevřená tepenná dužej
Po korekčním výkonu
Tepenná dužej
Defekt síňového septa typu secundum či sinus venosus bez reziduí
Defekt komorového septa bez reziduí

Katetrizační sál
Elektrofyzilogický sál
Implantace PM/ICD
Zařízení pro kontrolu funkce PM/ICD včetně dedikované kardiostimulační ambulance
Kardiologický operační sál

Dále musí centrum zajistit návaznost na porodnické pracoviště pro péči o těhotné s VSV, stejně jako návaznost na další obory, zejména interní (hematologie, hepatologie, nefrologie, neurologie), chirurgické (nekardiální operace) a na transplantologii včetně programu dlouhodobé mechanické podpory oběhu, na specializovaná centra pro plícní hypertenzi. Nezbytná je také rozvinutá spolupráce s genetiky, mikrobiologií, sociálními pracovníky, sportovními lékaři a paliativní péčí.

Musí být zajištěna plynulá spolupráce mezi ambulancím a lůžkovým provozem pro pacienty s VSV, musí být zřízen nonstop servis pro urgentní stavy u VSV.

Zkušenosti

Expertní komise pro VSV v dospělosti ČKS doporučuje 2 000 pacientů jako minimální počet, který by centrum VSV mělo mít ve sledování, a to včetně středně a vysoce komplexních vad (tj. vady s funkčně jednou komorou, transpozice velkých tepen, Fallotova tetralogie, Ebsteinova anomálie aj.). Tento počet odráží odhadovanou nízkou prevalenci [3,13] komplexních VSV v populaci, a tudíž jedině koncentrování těchto pacientů do specializovaných center zajistí dostatečnou zkušenost a erudici centra v oblasti péče o nemocné se středně a vysoce komplexními vadami, ale i se vzácnými VSV. Taková koncentrace péče vytvoří předpoklady pro řešení široké škály možných situací a komplikací u heterogenní populace s VSV.

Dále musí mít centrum VSV zajištěný přísun nových pacientů s VSV (dětského věku a z regionů od spolupracujících kardiologů). Centrum VSV s využitím veškerého personálního, technického vybavení a zkušeností musí být schopno poskytnout veškeré potřebné spektrum výkonů pro tyto pacienty.

Do budoucna je vhodná strukturovaná certifikace specializovaného vzdělávání pro VSV v dospělosti.

Dle informací expertní komise tyto podmínky pro specializovaná centra pro VSV v dospělosti (včetně operací komplexních VSV v dospělosti) v současnosti splňují tato pracoviště:

- **Centrum pro dospělé s vrozenou srdeční vadou v rámci Kardiocentra Nemocnice Na Homolce [14],**
- **Centrum pro dospělé s vrozenou srdeční vadou ve Fakultní nemocnici v Motole (Klinika kardiologická chirurgie, Kardiologická klinika, Dětské kardiocentrum, 2. lékařská fakulta Univerzity Karlovy a Fakultní nemocnice v Motole), obě pražská pracoviště s návazností na superspecializovanou péči v oblasti srdečního selhání, dlouhodobých mechanických podpor a transplantací, komplexní léčbě srdečních arytmií v Institutu klinické a experimentální medicíny,**

- **Centrum komplexní péče o vrozené srdeční vady v dospělosti BRNO v rámci Fakultní nemocnice Brno (Bohunice) a Centra kardiologické a transplantční chirurgie Brno.**

Literatura

- [1] H. Baumgartner, W. Budts, M. Chessa, et al., Recommendations for organization of care for adults with congenital heart disease and for training in the subspecialty of "Grown-up Congenital Heart Disease" in Europe: a position paper of the Working Group on Grown-up Congenital Heart Disease of the European Society of Cardiology, *European Heart Journal* 35 (2014) 686–690.
- [2] P. Pillutla, K.D. Shetty, E. Foster, Mortality associated with adult congenital heart disease: Trends in the US population from 1979 to 2005, *American Heart Journal* 158 (2009) 874–879.
- [3] A.J. Marelli, A.S. Mackie, R. Ionescu-Ittu, et al., Congenital Heart Disease in the General Population: Changing Prevalence and Age Distribution, *Circulation* 115 (2006) 163–172.
- [4] P.C. Helm, H. Kaemmerer, G. Breithardt, et al., Transition in Patients with Congenital Heart Disease in Germany: Results of a Nationwide Patient Survey, *Frontiers in Pediatrics* 5 (2017) 115.
- [5] H. Baumgartner, An important attempt to improve the outcome of congenital heart disease in Europe, *European Heart Journal* 35 (2014) 674–675.
- [6] S. Agarwal, K. Sud, V. Menon, Nationwide Hospitalization Trends in Adult Congenital Heart Disease Across 2003–2012, *Journal of the American Heart Association* 5 (2016). doi: 10.1161/JAHA.115.002330.
- [7] J.M. O'Leary, O.K. Siddiqi, S. de Ferranti, et al., The Changing Demographics of Congenital Heart Disease Hospitalizations in the United States, 1998 Through 2010, *JAMA* 309 (2013) 984–986.
- [8] S. Baldovino, A.M. Moliner, D. Taruscio, et al., Rare Diseases in Europe: from a Wide to a Local Perspective, *Israel Medical Association Journal* 18 (2016) 359–363.
- [9] Národní strategie pro vzácná onemocnění 2010–2020 I Databáze strategií – portál pro strategické řízení, (n.d.). <https://www.databaze-strategie.cz/cz/mzd/strategie/narodni-strategie-pro-vzacna-onemocneni-naleta-2010-2020> (navštíveno 14. 1. 2018).
- [10] www.kardio-cz.cz/data/clanek/504/dokumenty/narodni-kardiovaskularni-program.pdf, (n.d.). <http://www.kardio-cz.cz/data/clanek/504/dokumenty/narodni-kardiovaskularni-program.pdf> (navštíveno 14. 1. 2018).
- [11] H. Baumgartner, P. Bonhoeffer, N.M.S. De Groot, et al., Task Force on the Management of Grown-up Congenital Heart Disease of the European Society of Cardiology (ESC), Association for European Paediatric Cardiology (AEPIC), ESC Committee for Practice Guidelines (CPG), ESC Guidelines for the management of grown-up congenital heart disease (new version 2010), *European Heart Journal* 31 (2010) 2915–2957.
- [12] C.A. Warnes, R.G. Williams, T.M. Bashore, et al., ACC/AHA 2008 guidelines for the management of adults with congenital heart disease: Executive summary – A report of the American College of Cardiology/American Heart Association Task Force on practice guidelines (writing committee to develop guidelines for the management of adults with congenital heart disease), *Circulation* 118 (2008) 2395–2451.
- [13] M. Šamánek, M. Vofisková, Congenital heart disease among 815,569 children born between 1980 and 1990 and their 15-year survival: a prospective Bohemia survival study, *Pediatric Cardiology* 20 (1999) 411–417.
- [14] J.R. Popelová, R. Gebauer, Š. Černý, et al., Operations of adults with congenital heart disease – Single center experience with 10 years results, *Cor et Vasa* 58 (2016) e317–e327.

Z anglického originálu online verze článku přeložil autor.

8. Conclusions

In the last 40 years, the outcome of children born with CHD became significantly better due to important developments of paediatric cardiology, heart surgery, imaging methods, extracorporeal circulation and specialized postoperative care. Since 1999, the mortality in children with CHD is below 1% in the Prague Children's Cardiac Centre. The development of prenatal cardiology in the last 35 years, including the implementation of second-trimester and later first-trimester screening into the complex care protocol of pregnancy, contributed, as well, to these excellent results. Because of important developments in ultrasound technology, more and more structures were included to the screening protocol of the fetal heart. For example, a 4-chamber view became available in 1986, evaluation of outflow tracts in 1996, and a 3-vessel view in 2010. At the end of the 20th century, first-trimester screening was implemented to fetal care in most countries and in most fetal medical centres (4-chamber view and outflow tracts imaging). Also "risk factors" of CHD – increased nuchal translucency, tricuspid regurgitation and abnormal flow in the ductus venosus — were found and examined. This development and the increased detection rate of CHD are possible not only because of new ultrasound methods, but also because of the development of other new imaging methods. Recently, fetal magnetic resonance imaging is playing a more and more important role in the imaging of fetal structures. It must also be mentioned that the training of physicians and technicians who perform screening scans in pregnant women has been an important factor in the detection rate of CHDs. Recently, the detection rate of all CHDs is about 45% prenatally, and the detection rate of critical CHDs, which can cause heart failure immediately after birth, is about 80 – 85%. It would not be possible to achieve such excellent results without the optimal management of pregnancies with CHDs. Nor would it be possible without reciprocal cooperation by all participating fields — obstetrics and gynecology, genetics, surgery and pathology. On the other hand, the Czech Republic has one of the highest percentages of terminations of pregnancy in Europe (54%) because of CHD. Many factors play a role in the decision-making process of parents about the outcome of pregnancy. From the cardiology point of view, it is important that a fetus with CHD must be examined by a paediatric cardiologist specialized in prenatal cardiology in order to make the correct diagnosis in all details, to inform parents about the possible development of CHD, the available options of invasive procedures, and the possible prognoses of CHD in an infant after birth.

In our study, we confirmed that first-trimester fetuses are mostly diagnosed with CHD with univentricular circulation, which is often associated with additional extracardiac and chromosomal abnormalities and has a very poor prognosis. Therefore most parents with such fetuses (85%) decided for termination of pregnancy in the first trimester. In the second trimester, CHDs mostly exhibit with biventricular circulation and less associated comorbidities allowing a better prognosis. Therefore fewer parents decided to terminate pregnancy (32%). In addition, we confirmed that first-trimester screening changed the spectrum of CHDs in the second trimester in comparison to first trimester during the same time period (2007 to 2013), and also in comparison to the time period before the implementation of first-trimester screening in fetal care (1996 to 2001).

In the study, we also showed the pitfalls and limitations of first-trimester screening. In some cases of first-trimester screening, it was impossible to detect some serious heart conditions with duct-dependent circulation, to detect all details of some particular type of CHD, or to detect CHD which will develop later in pregnancy. Similarly, it was not always possible to predict the development and the outcome of CHD in the first trimester, because a first-trimester fetus is, of course, only in the earliest stage of pregnancy and we know that CHD can later develop into the wider spectrum of CHD. In such cases we unfortunately create quite a lot of stress for the family by saying, *“The heart of the baby is not all right.”* We are able to discuss main information about CHD with the parents, but then we must tell them that, *“CHD has such a huge spectrum of possible development that we are only able to predict the outcome of the baby in greater detail later in the pregnancy.”*

So there is still the question of whether or not, in some cases, first-trimester screening produces more risk than benefit for some families. In view of all these facts, we think that the second-trimester screening program still has its place as an integral diagnostic component in a multimodality screening program in pregnancy.