

POHYBY HLAVY A TRUPU



POHYBY PÁNVE A LOPATEK

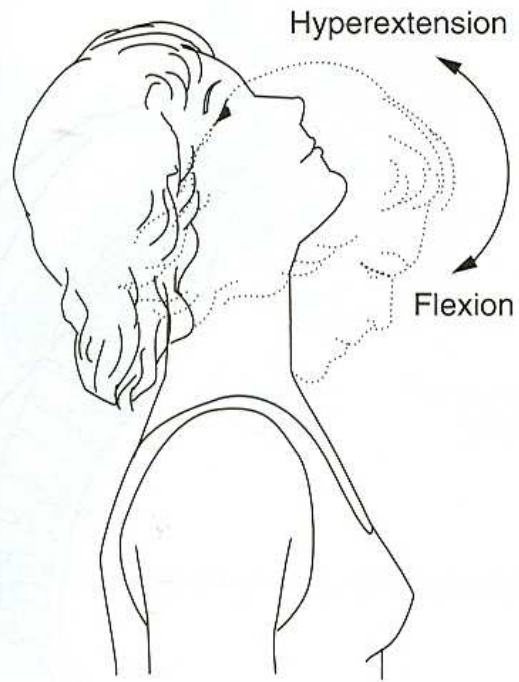
POHYBY HLAVY

FLEXE - PŘEDKLON

EXTENZE - ZÁKLON

LATEROFLEXE - ÚKLON

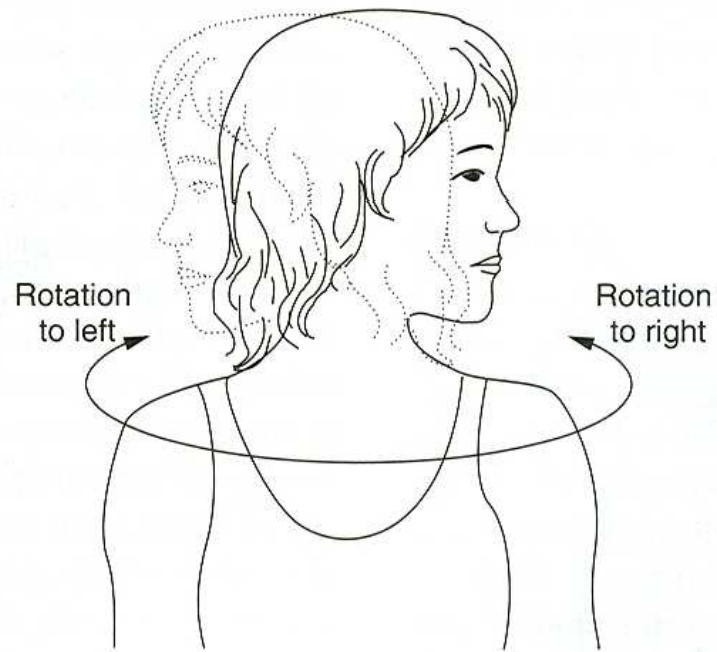
ROTACE - OTÁČENÍ



a.

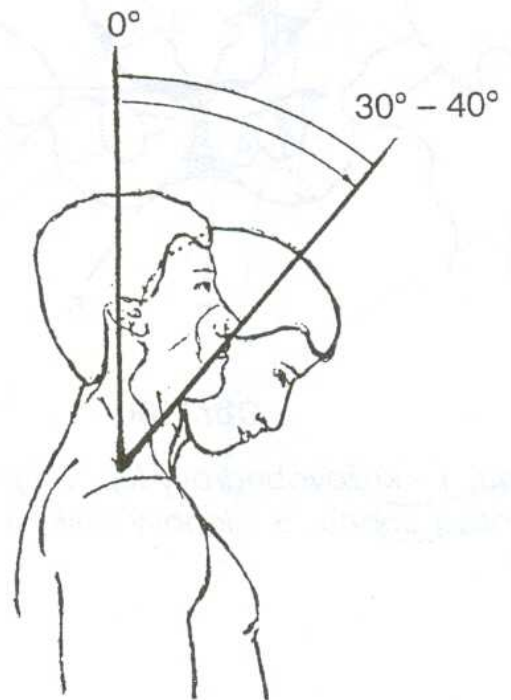


b.

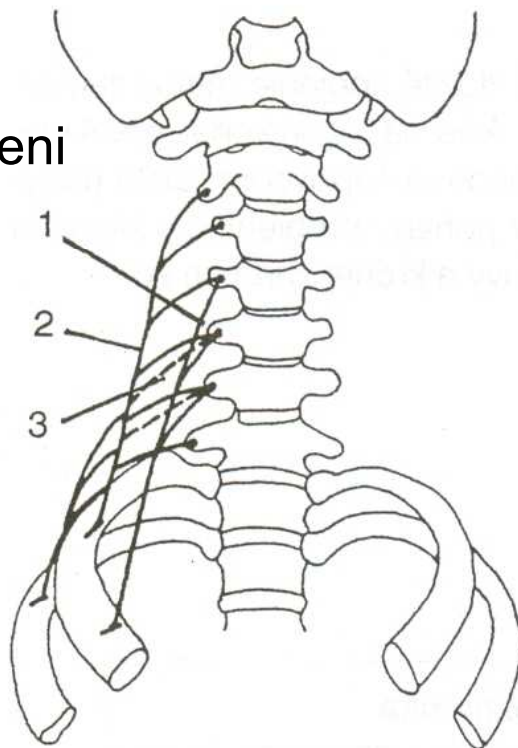


c.

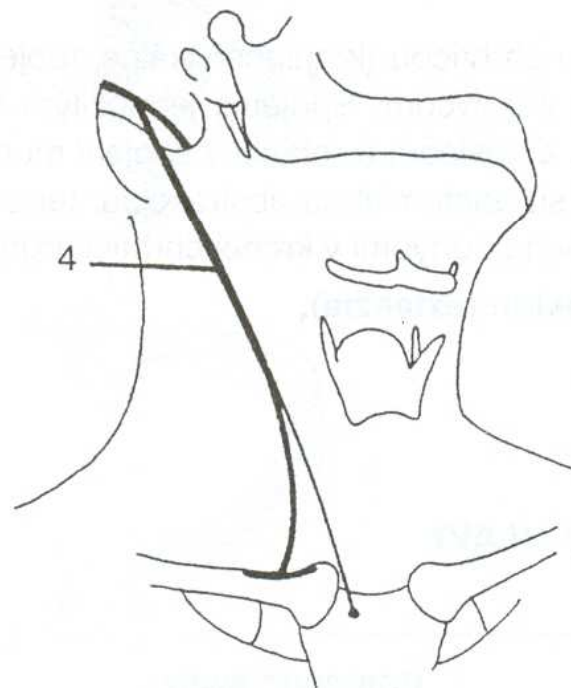
FLEXE - PŘEDKLON



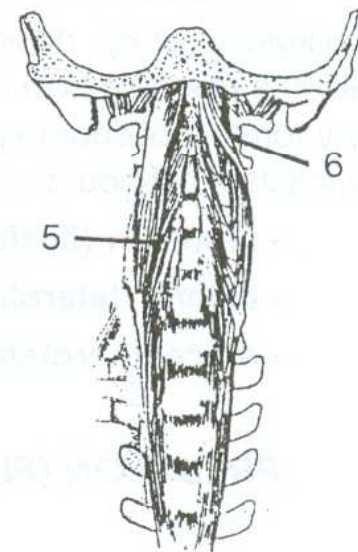
mm. scaleni



m. longus colli



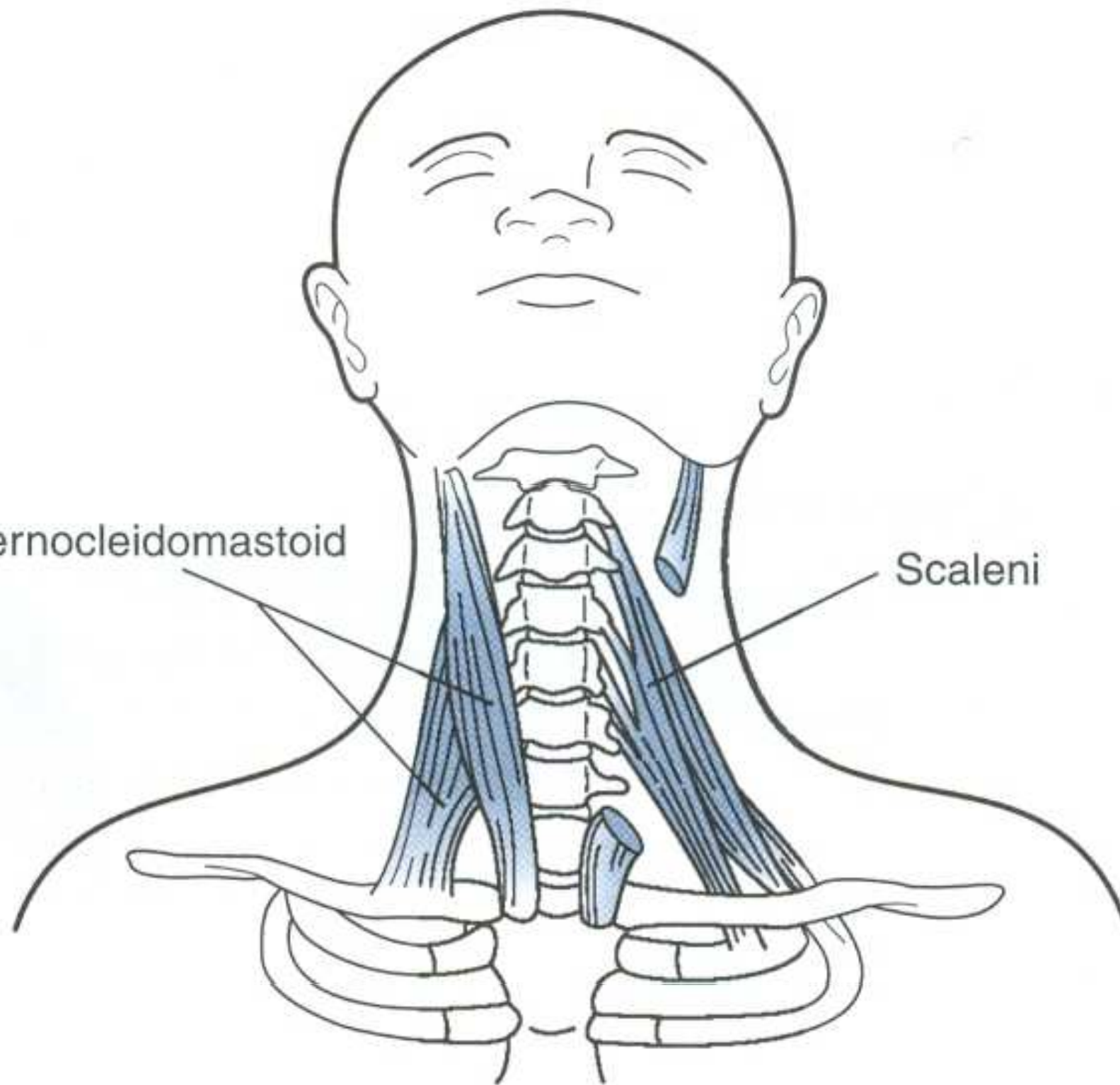
m. sternocleidomastoideus



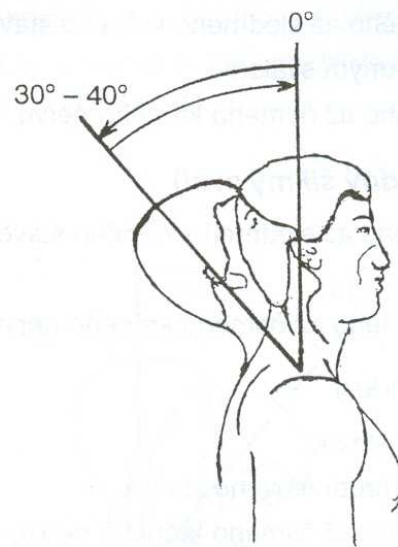
m. longus capitis

Sternocleidomastoid

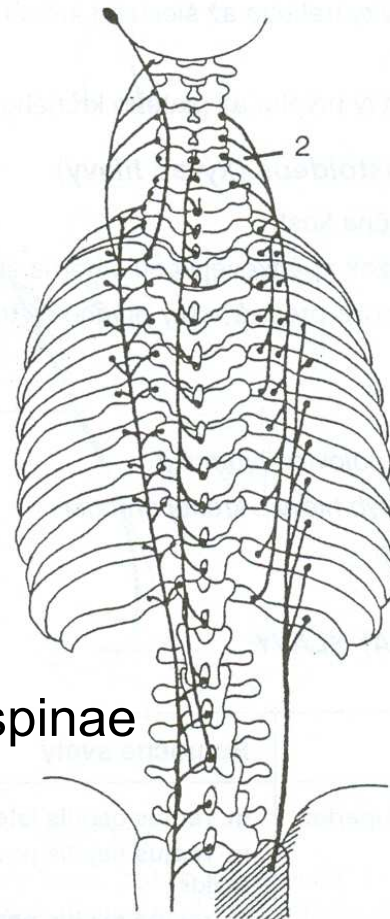
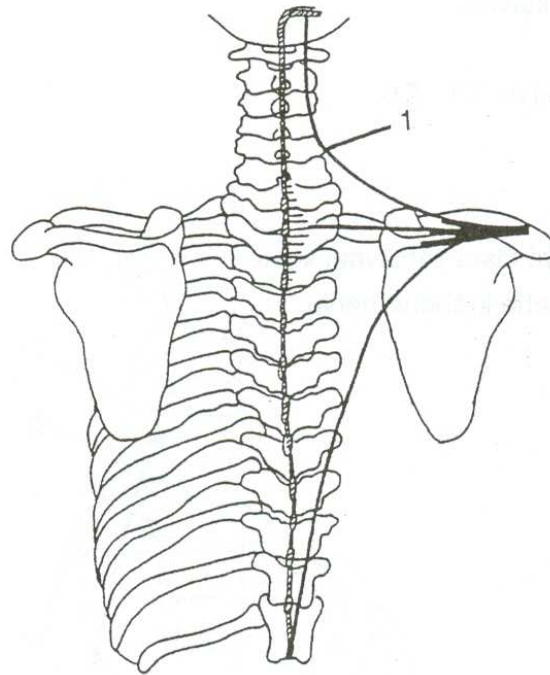
Scaleni



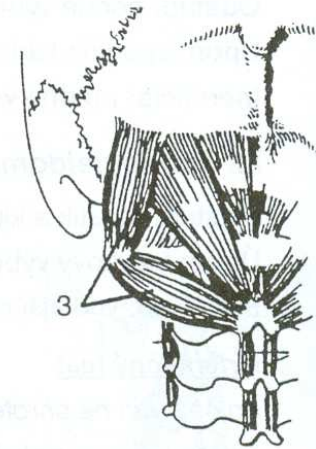
EXTENZE - ZÁKLON



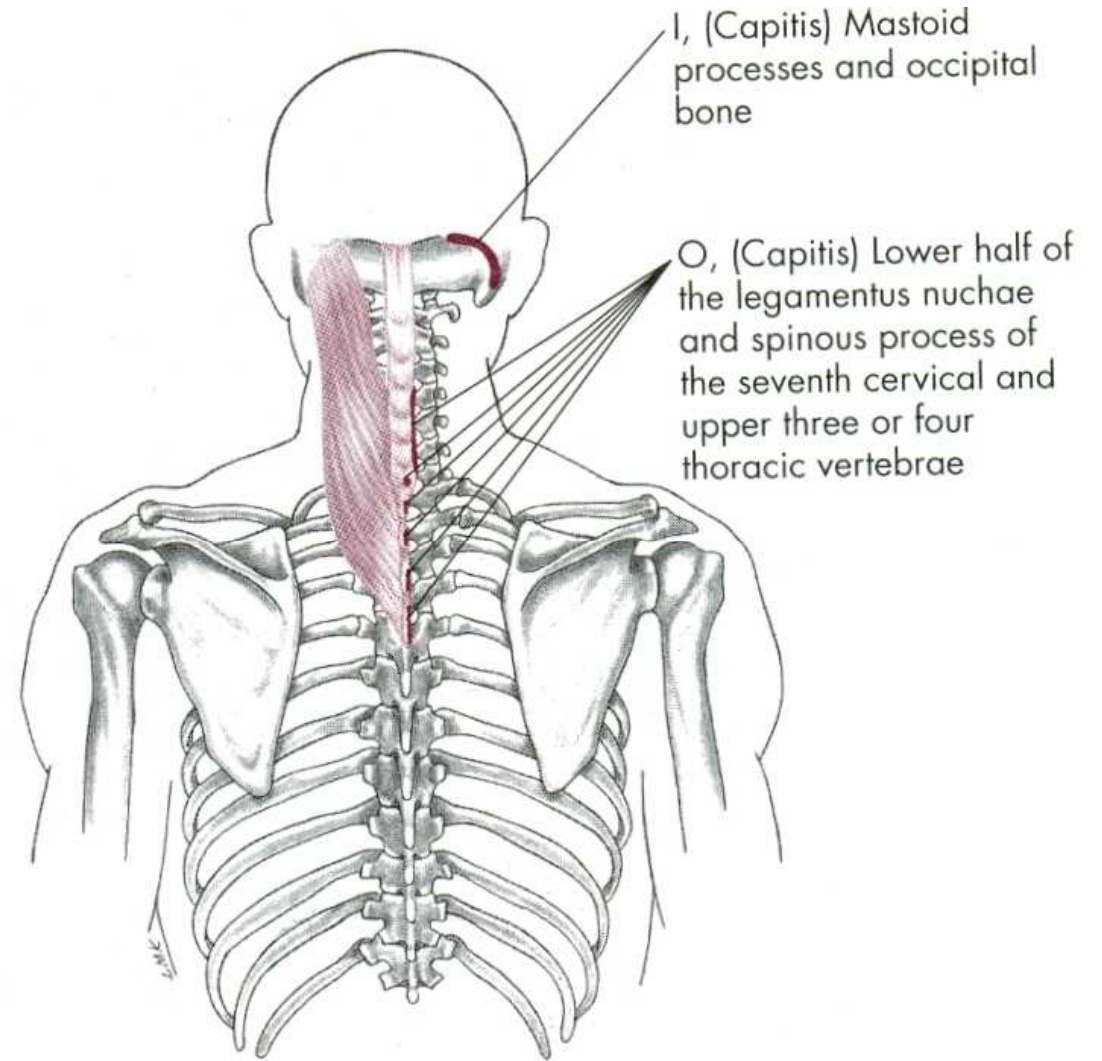
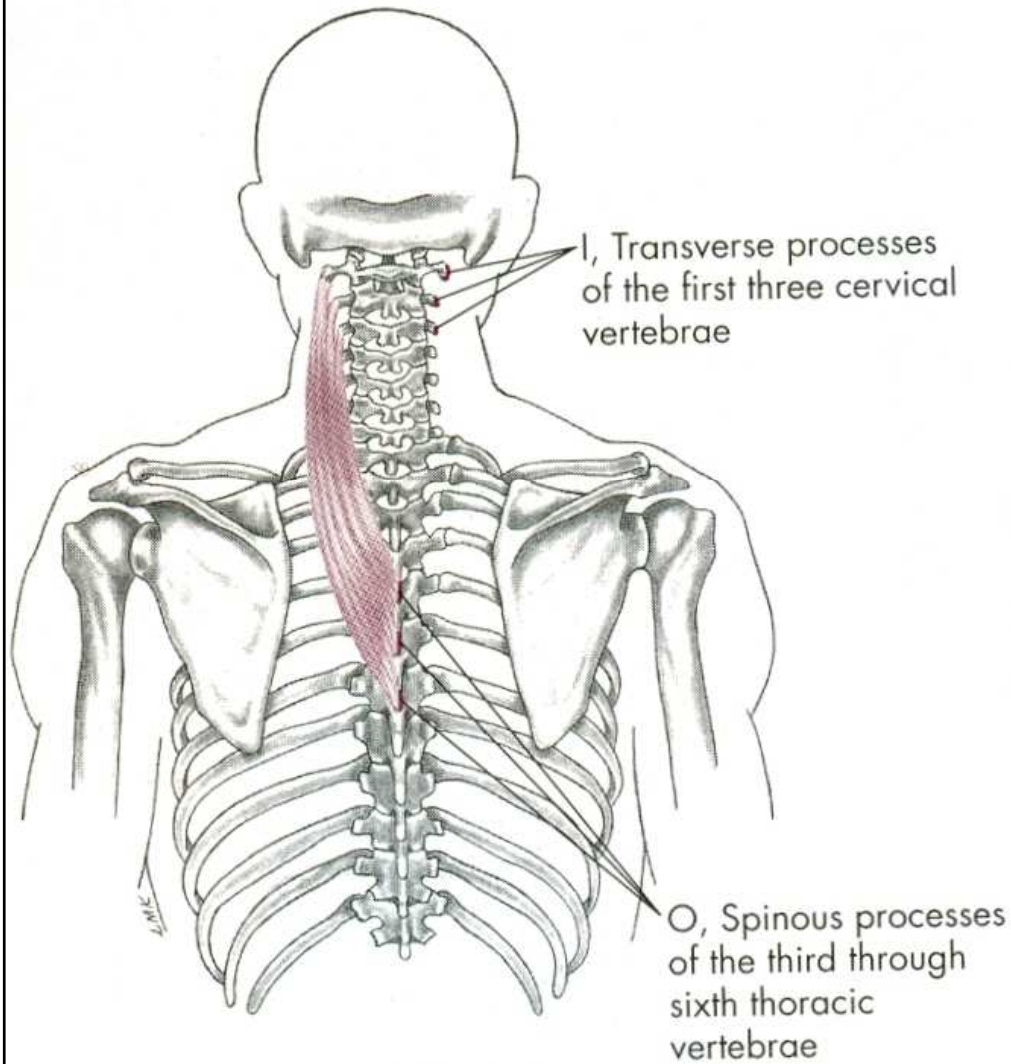
m. trapezius



m. erector spinae



hluboké svaly šíjové



FLEXE HLAVY

mm. scaleni – svaly kloněné

mm. praevertebrales – dlouhé svaly hlavy a krku

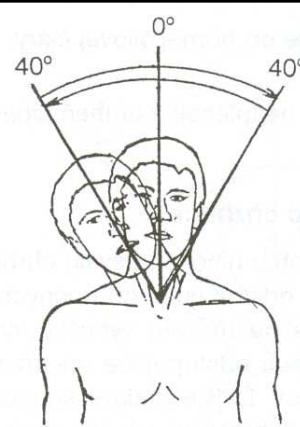
m. sternocleidomastoideus – zdvihač hlavy

EXTENZE HLAVY

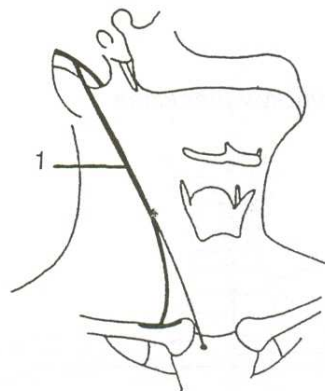
m. trapezius-pars superior –
sval trapézový-horní část

m. erector spinae – vzpřimovače hlavy a trupu

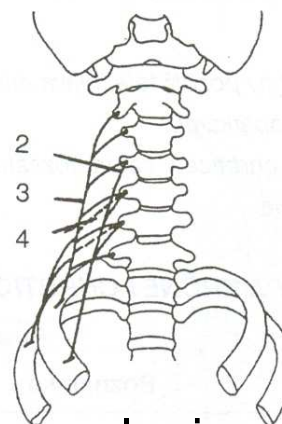
LATEROFLEXE - ÚKLON



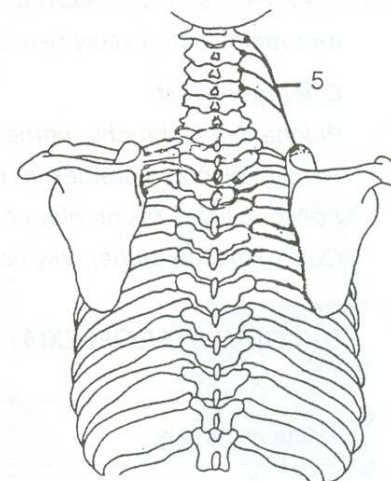
m. sternocleidomastoideus



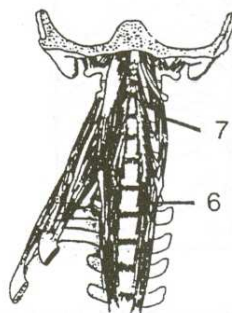
mm. scaleni



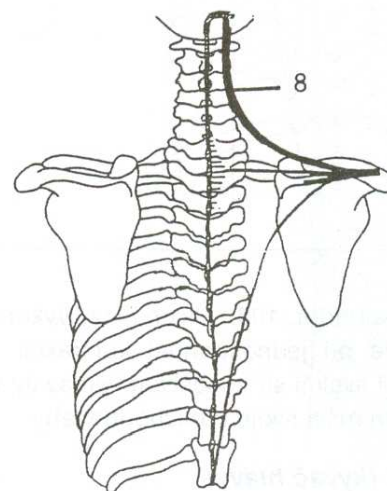
m. levator scapulae



m. longus capitis

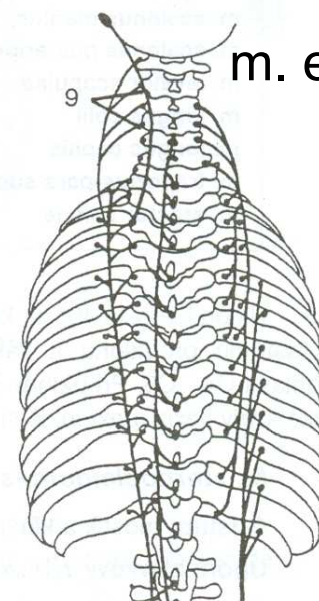


m. longus colli

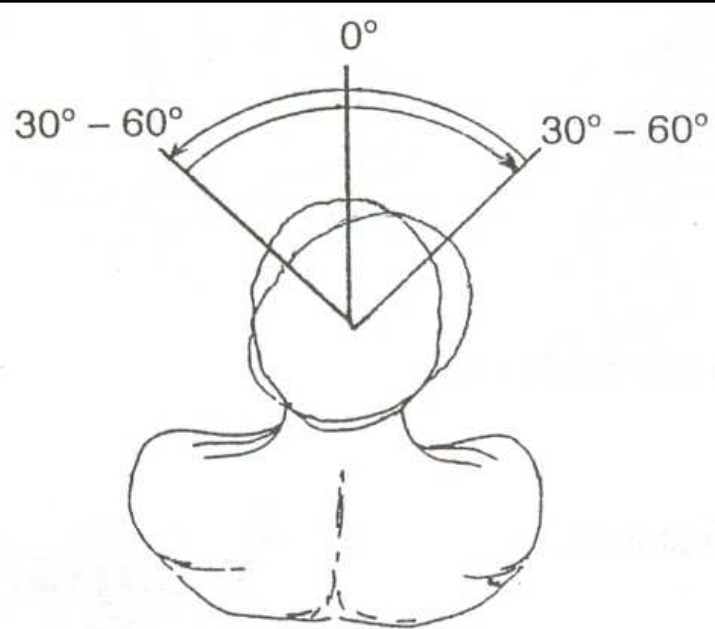


m. trapezius

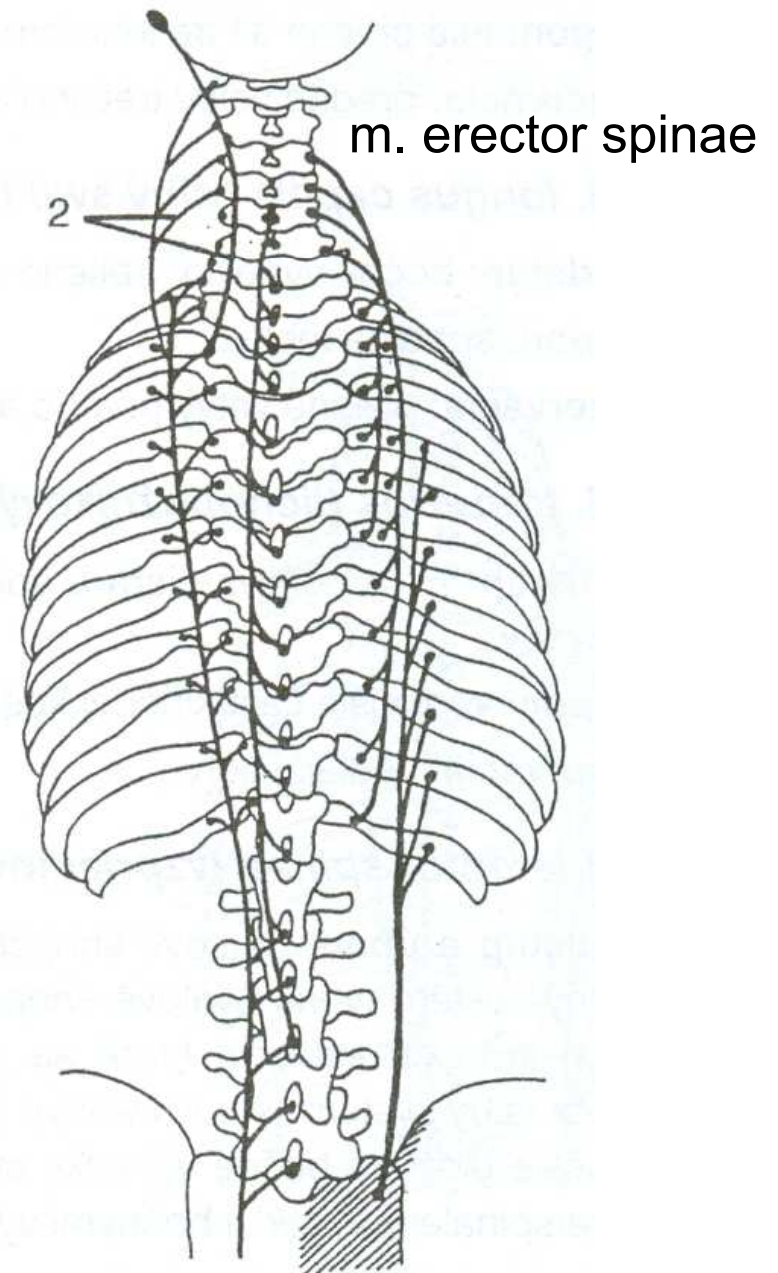
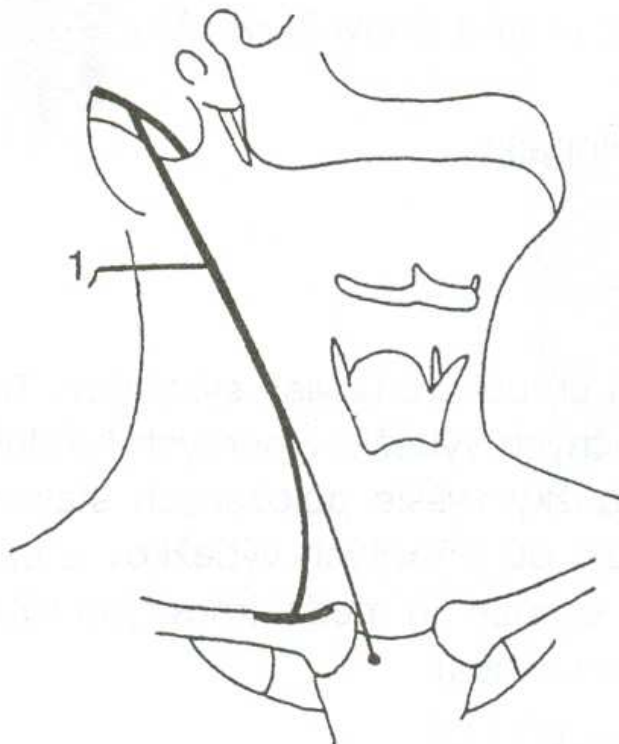m. erector spinae



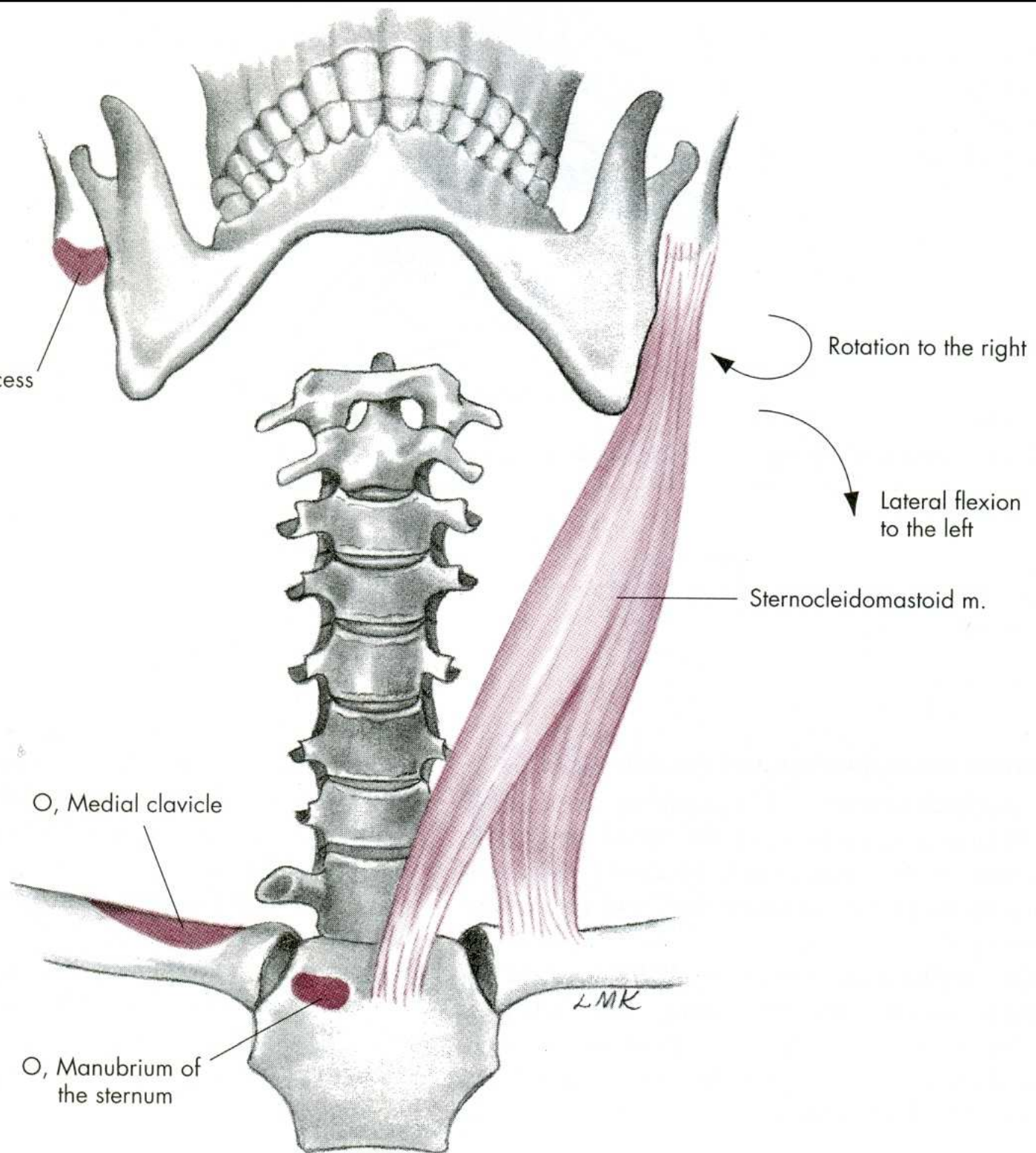
ROTACE - OTÁČENÍ

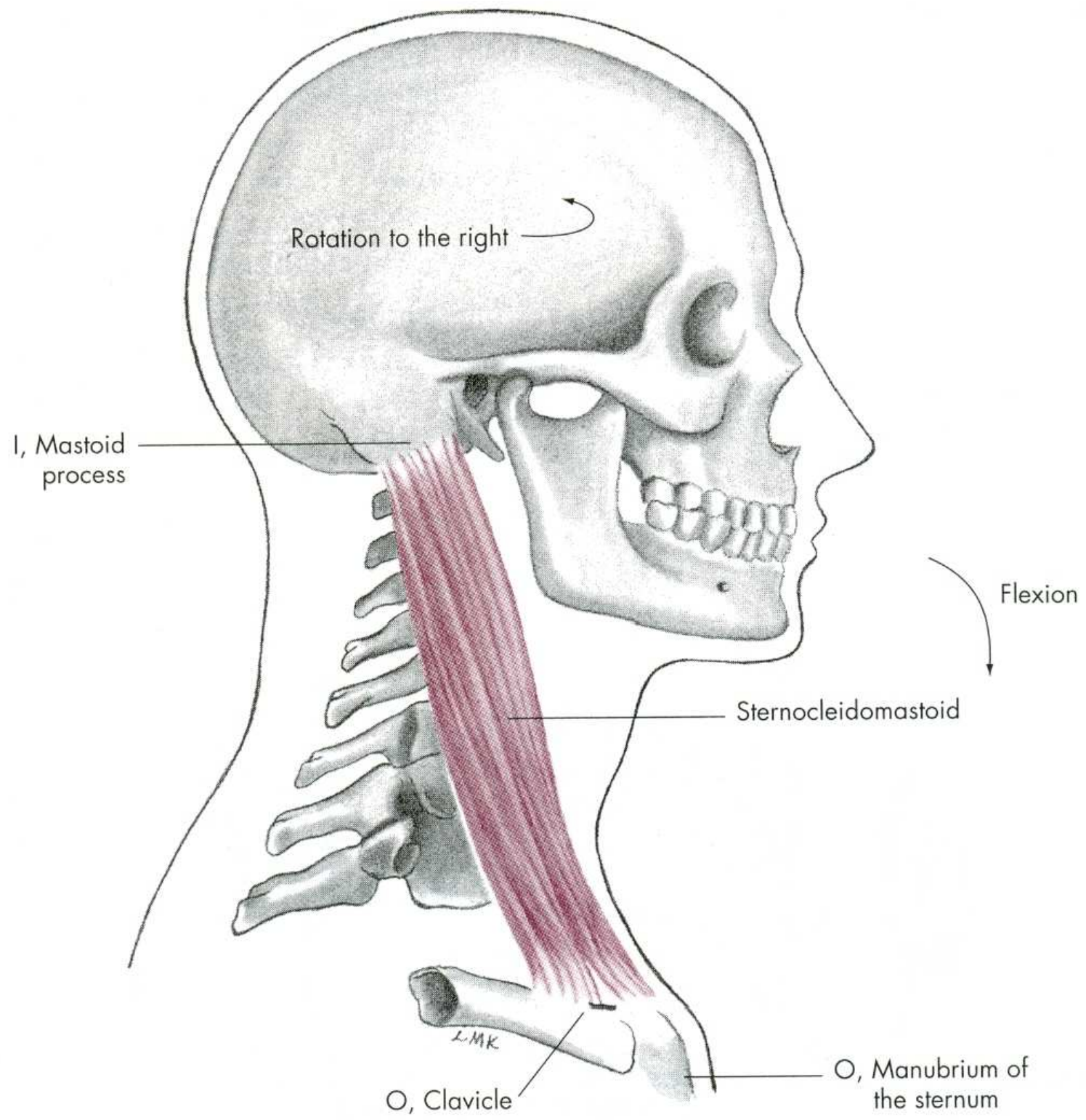


m. sternocleidomastoideus



I, Mastoid process





LATEROFLEXE HLAVY a KRKU

m. sternocleidomastoideus – zdvihač hlavy

mm. scaleni – svaly kloněné

m. levator scapulae – zdvihač lopatky

m. trapezius-pars superior –
svaly trapézový-horní část

ROTACE HLAVY a KRKU

m. sternocleidomastoideus – zdvihač hlavy

m. erector spinae – transverzospinální systém

m. erector spinae – spinotransverzální systém

POHYBY TRUPU

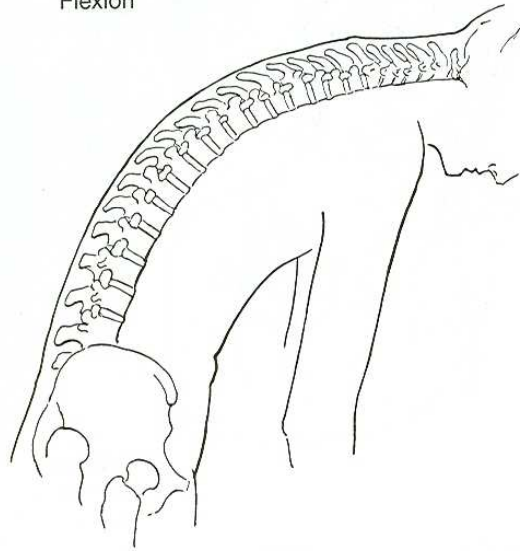
VENTRÁLNÍ FLEXE - PŘEDKLON

DORZÁLNÍ FLEXE - ZÁKLON

LATEROFLEXE - ÚKLON

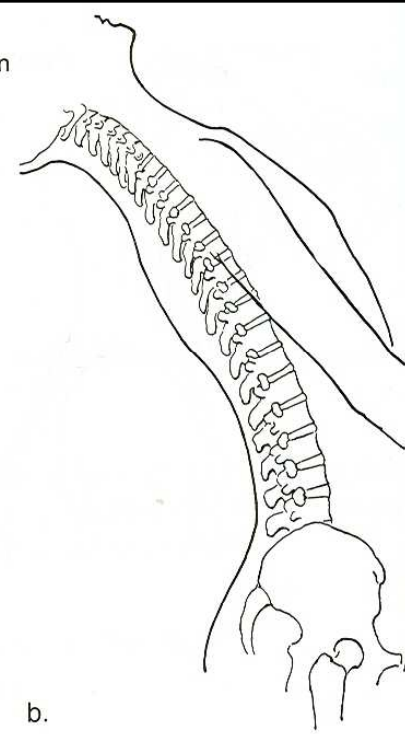
ROTACE - OTÁČENÍ

Flexion



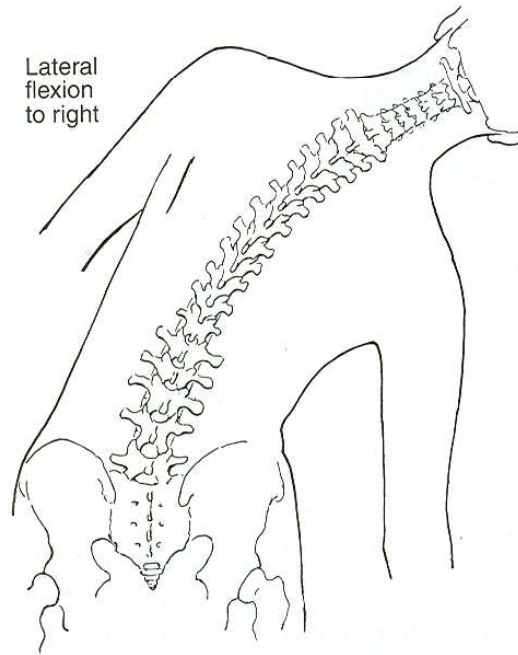
a.

Hyperextension



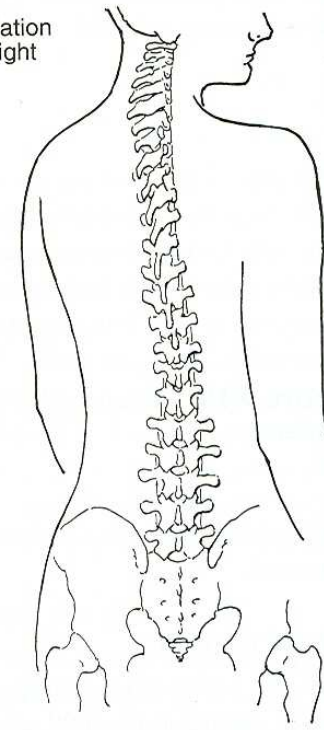
b.

Lateral flexion to right



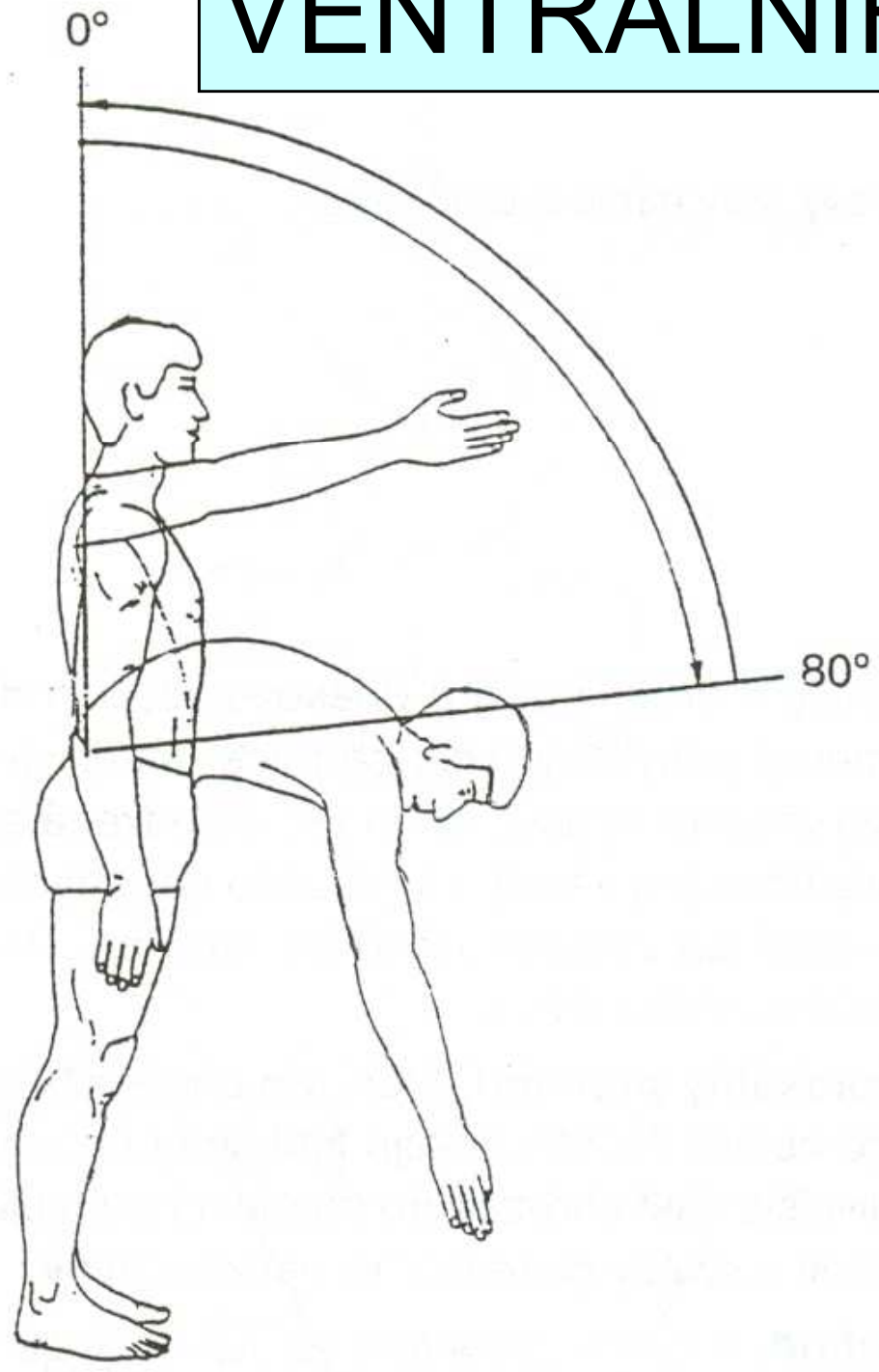
c.

Rotation to right

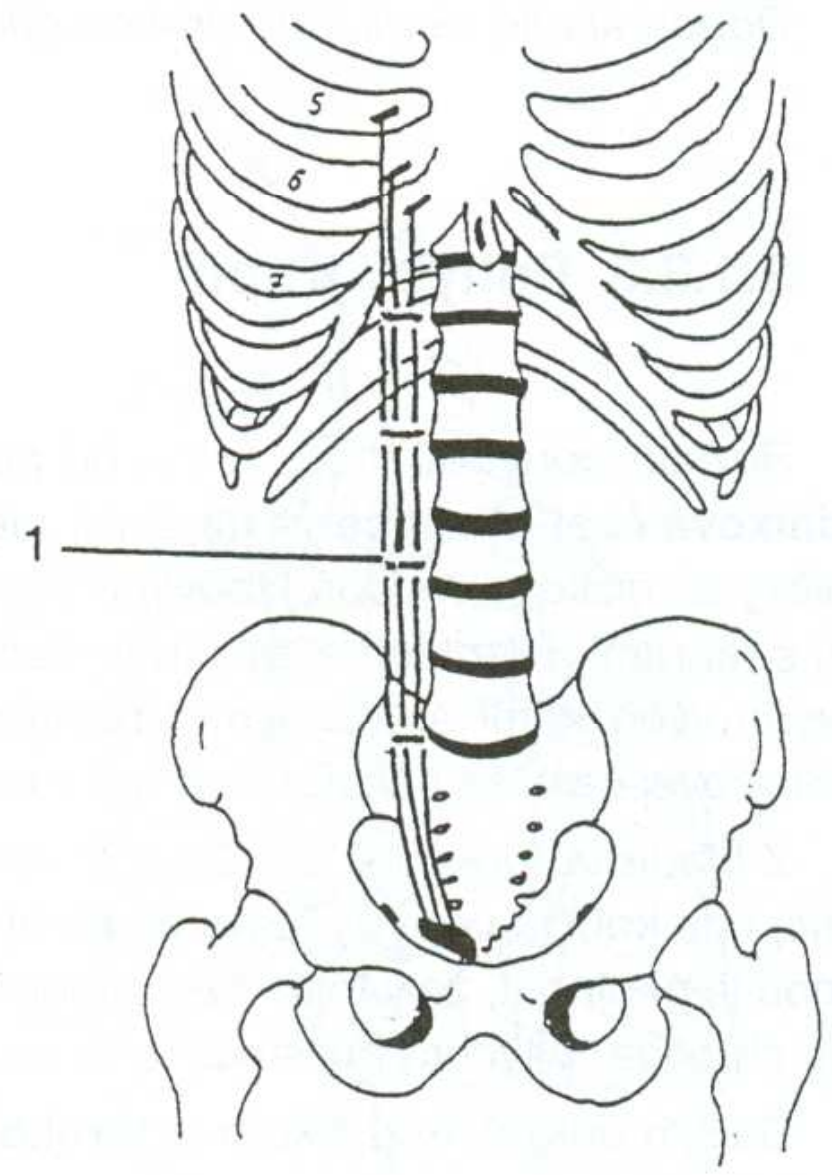


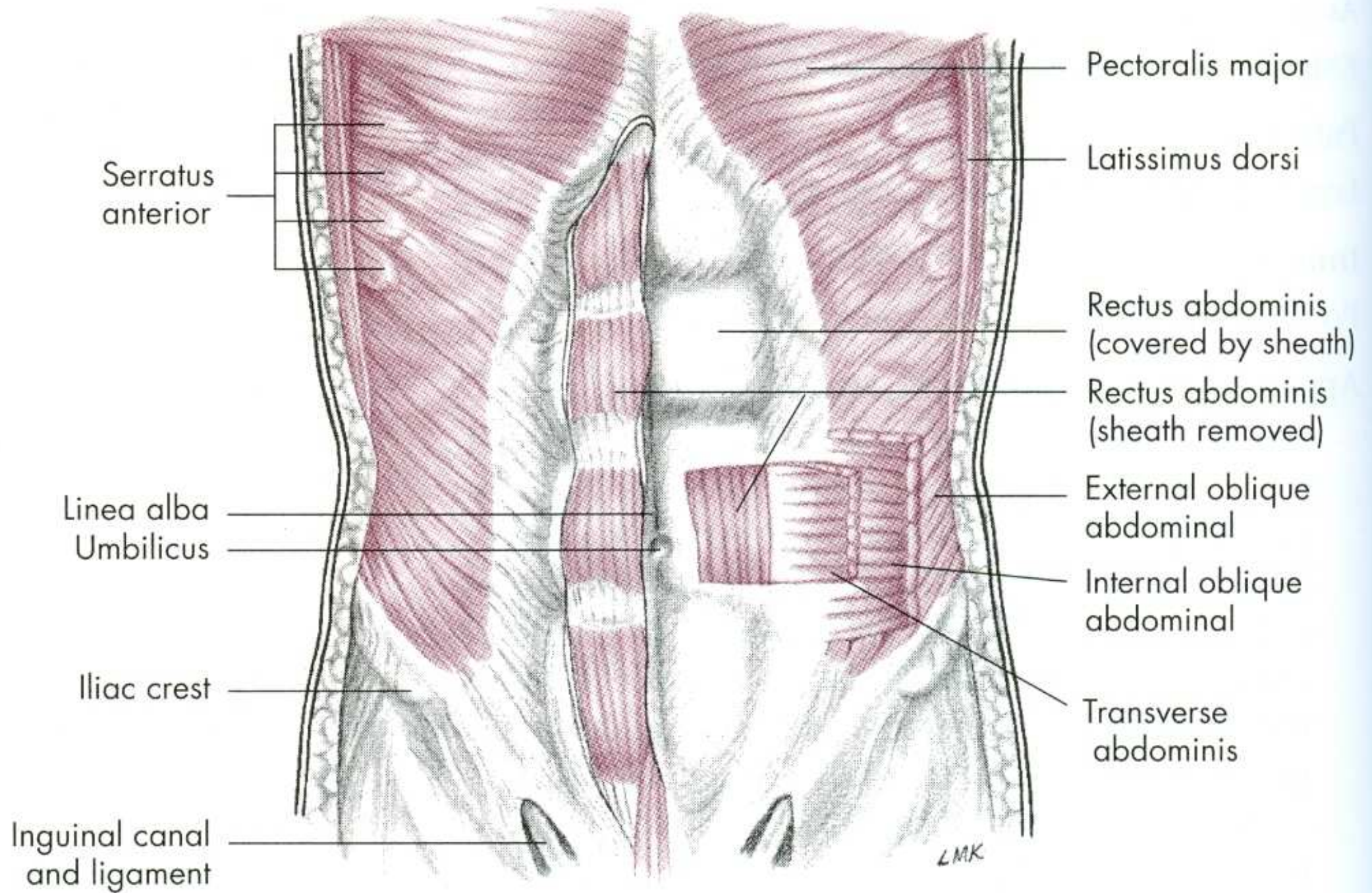
d.

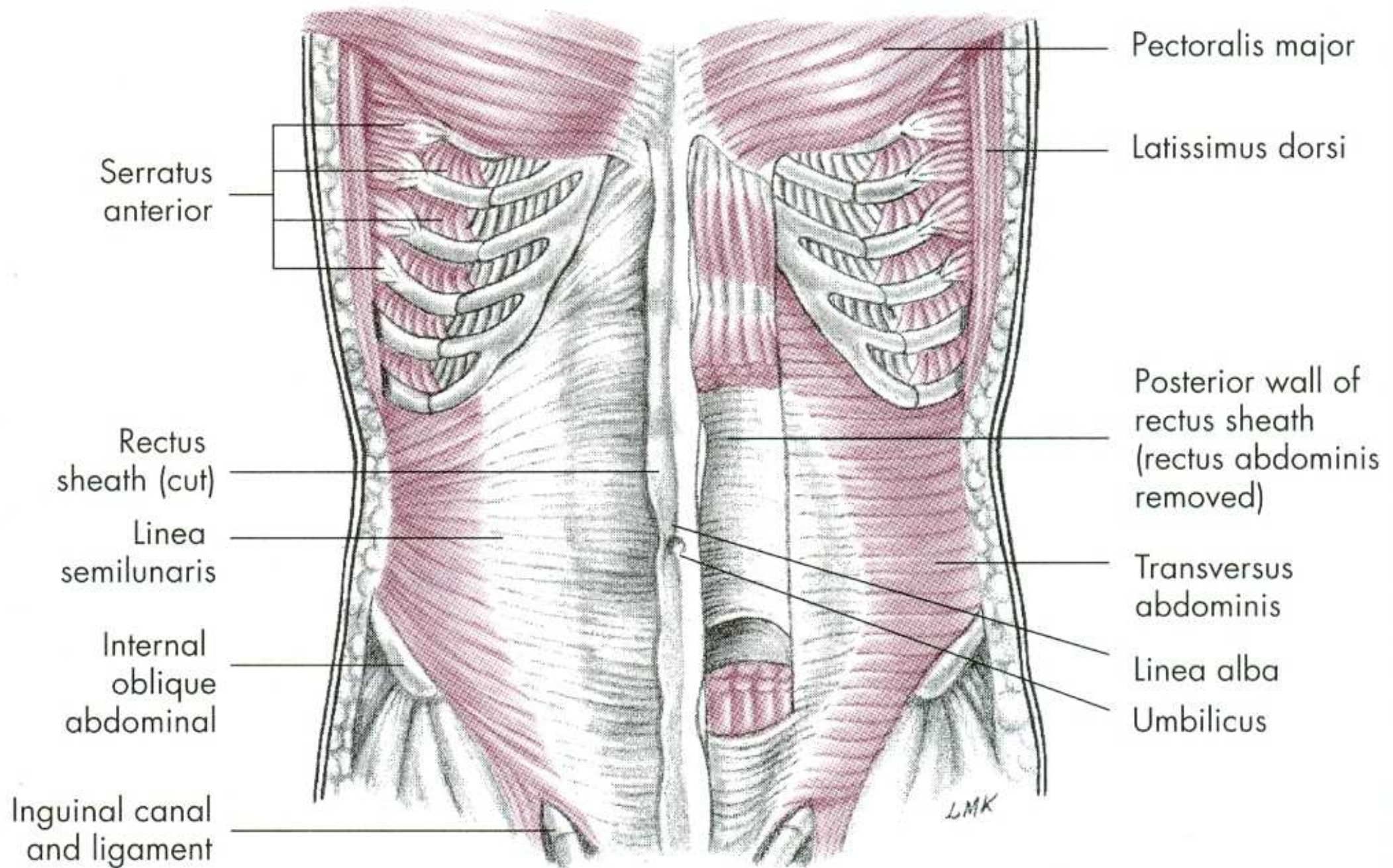
VENTRÁLNÍFLEXE - PŘEDKLON



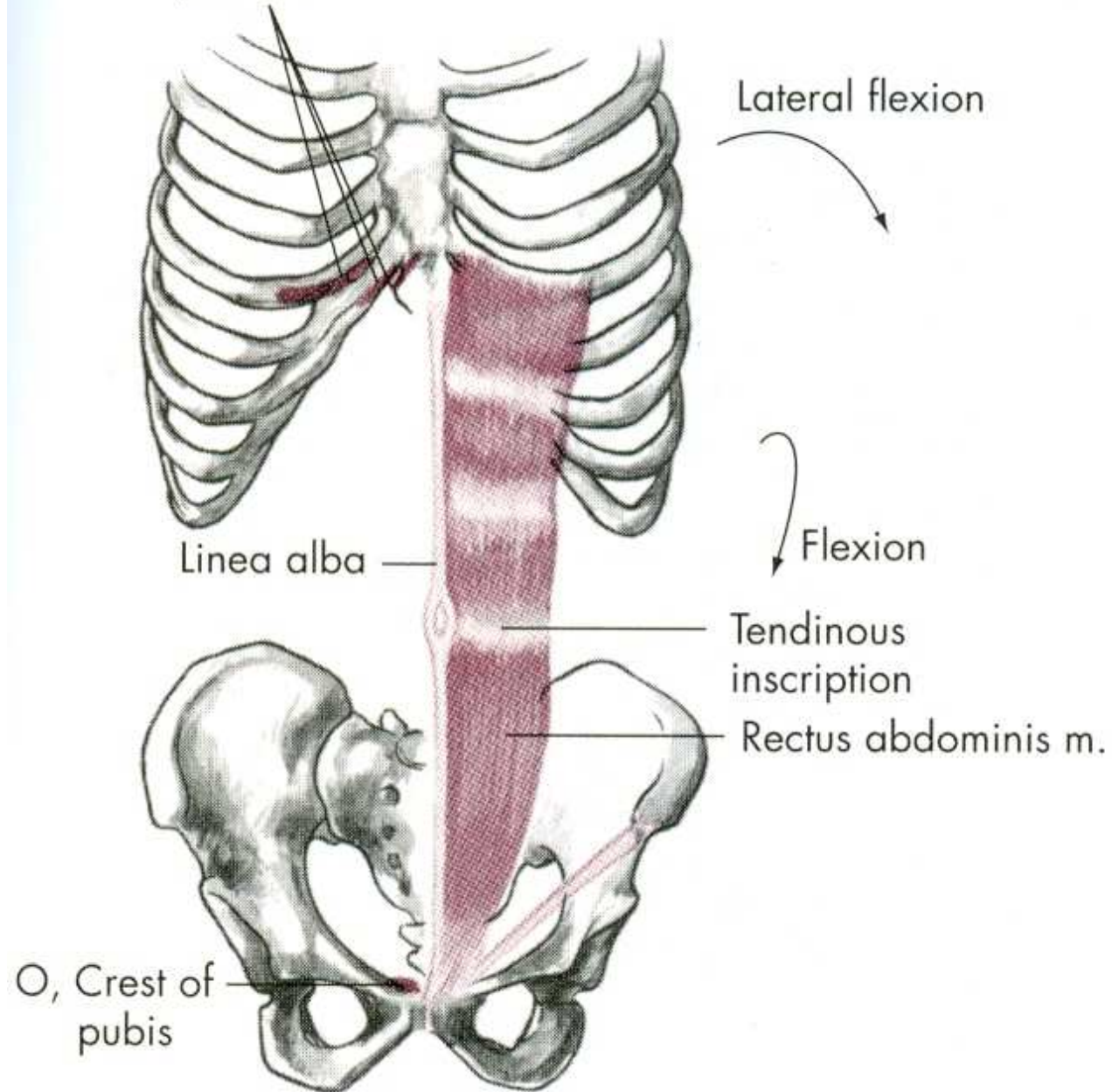
m. rectus abdominis



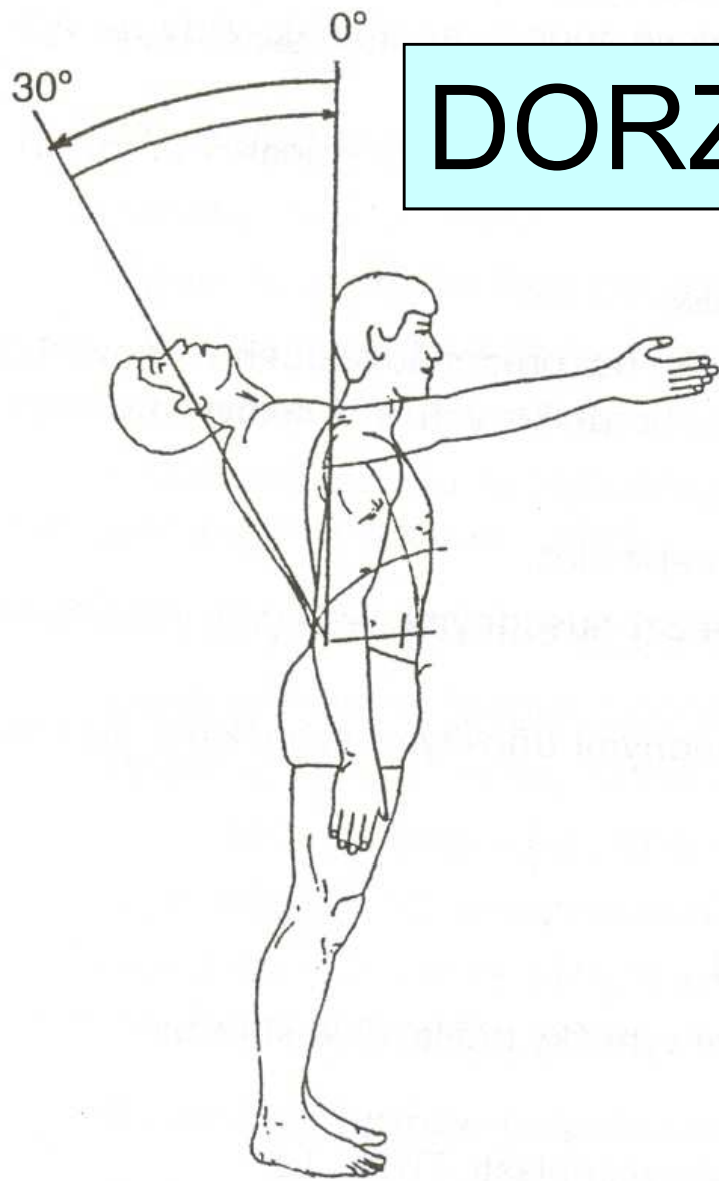




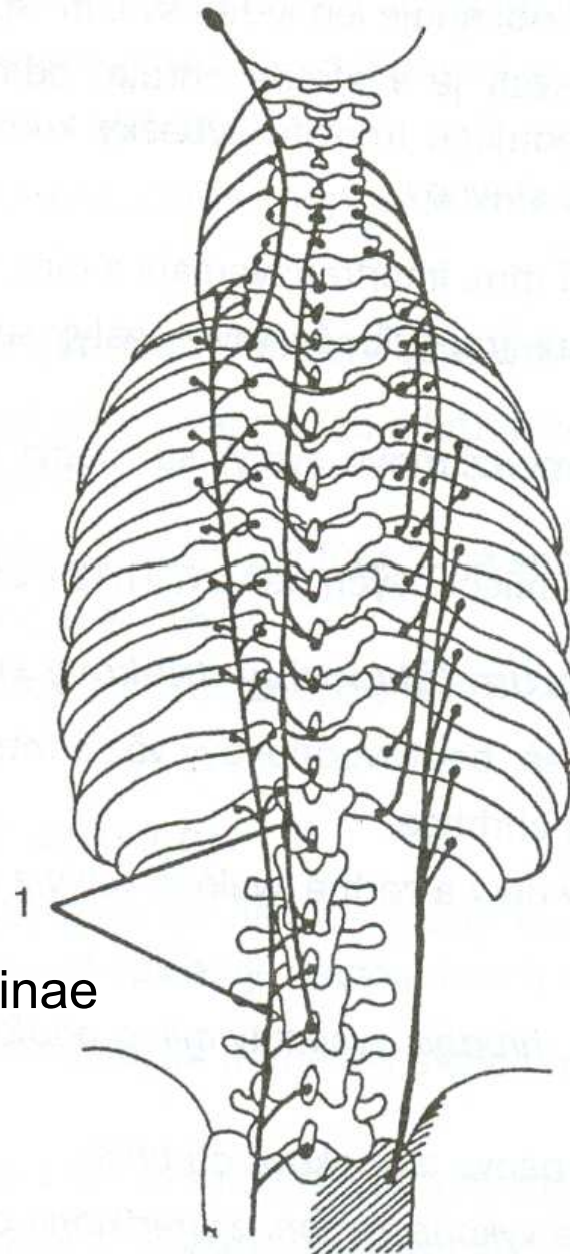
- I, Cartilage of fifth, sixth, and seventh ribs, xiphoid process



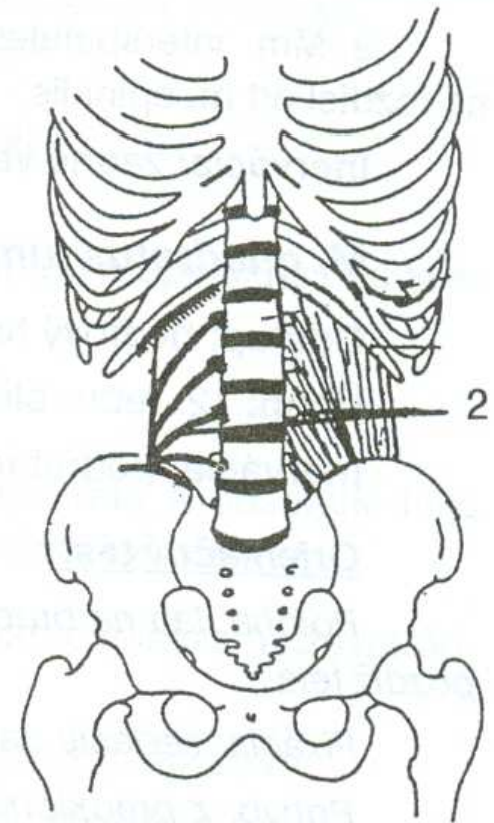
DORZÁLNÍ FLEXE - ZÁKLON

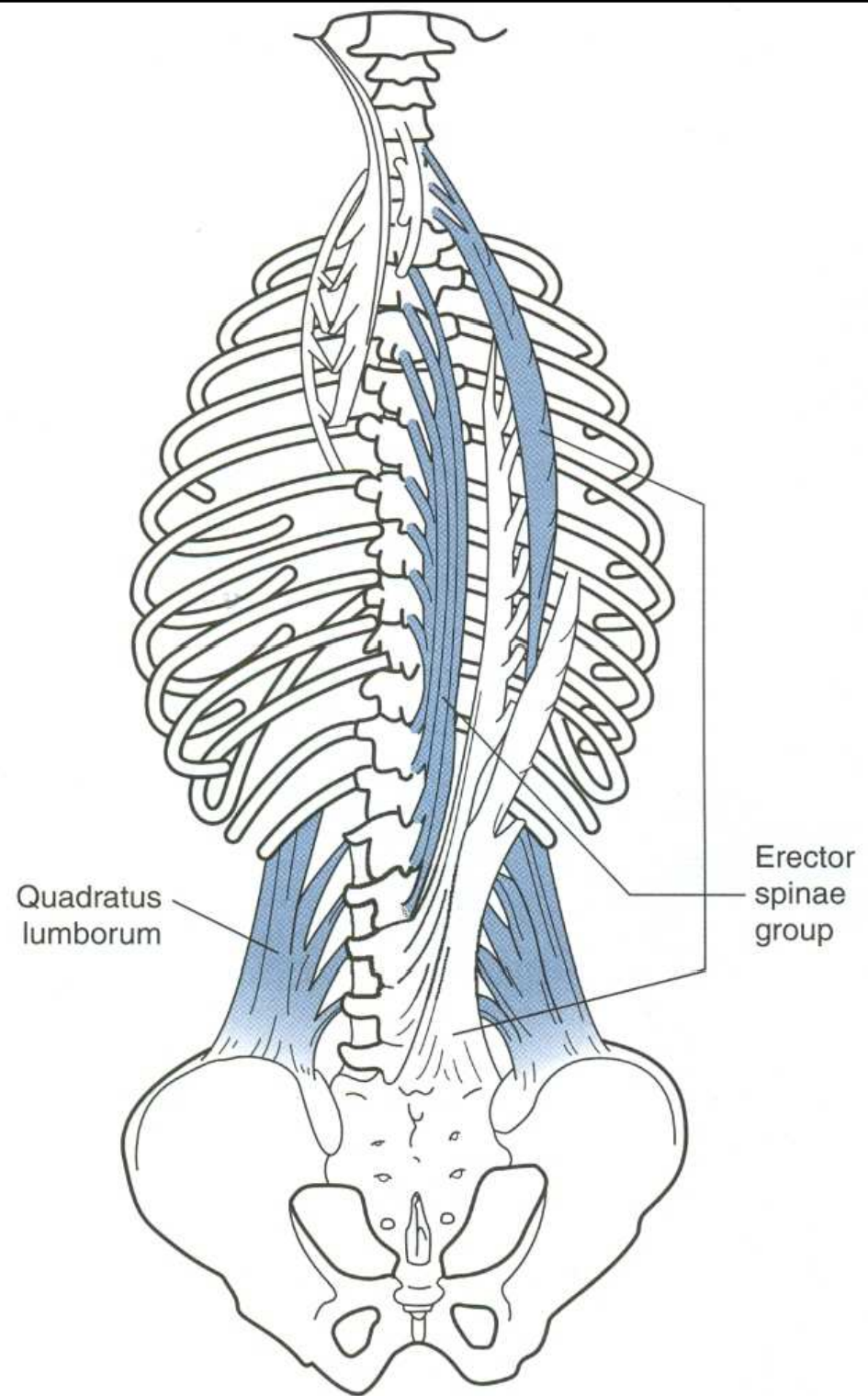


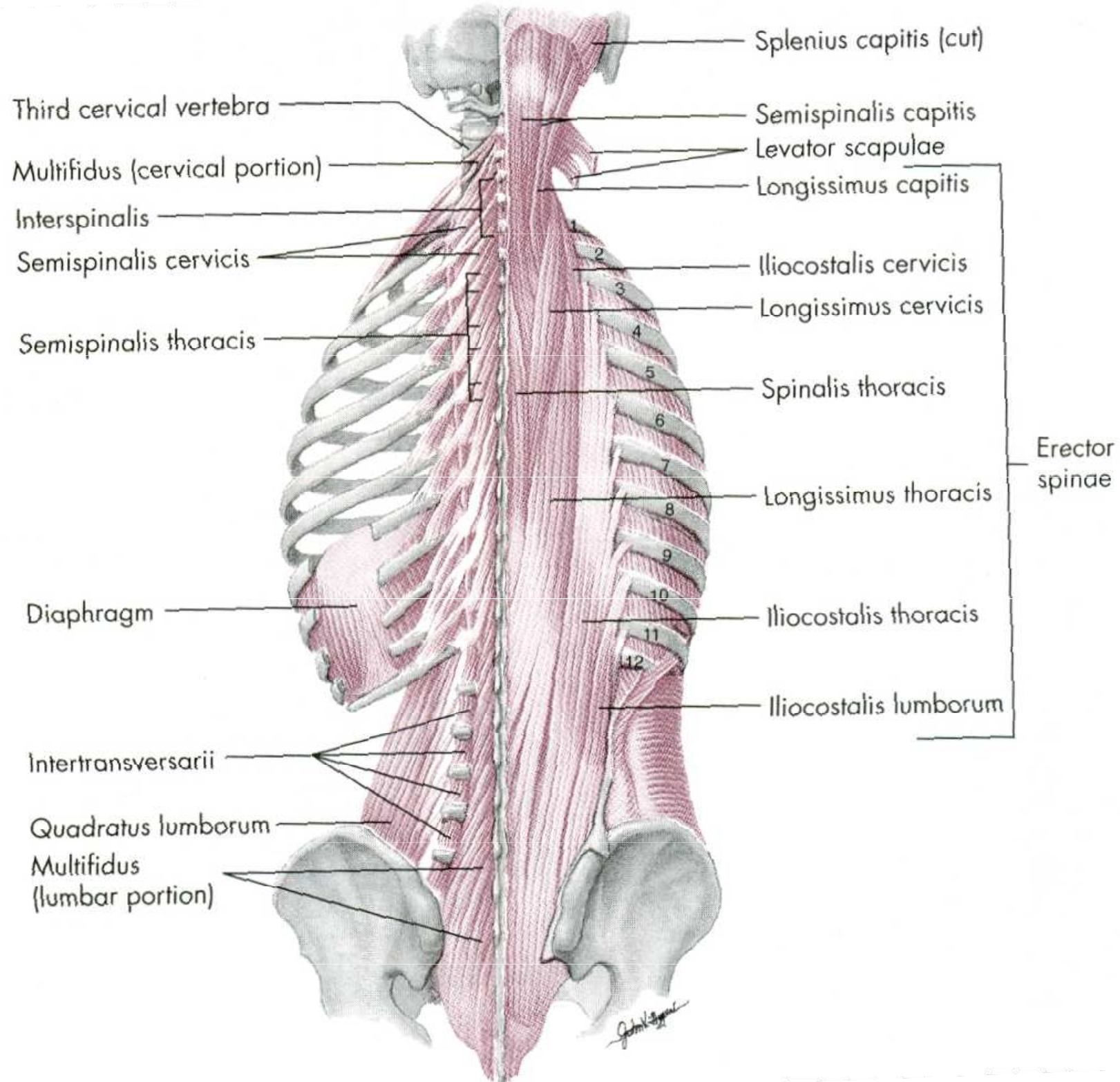
m. erector spinae



m. quadratus lumborum







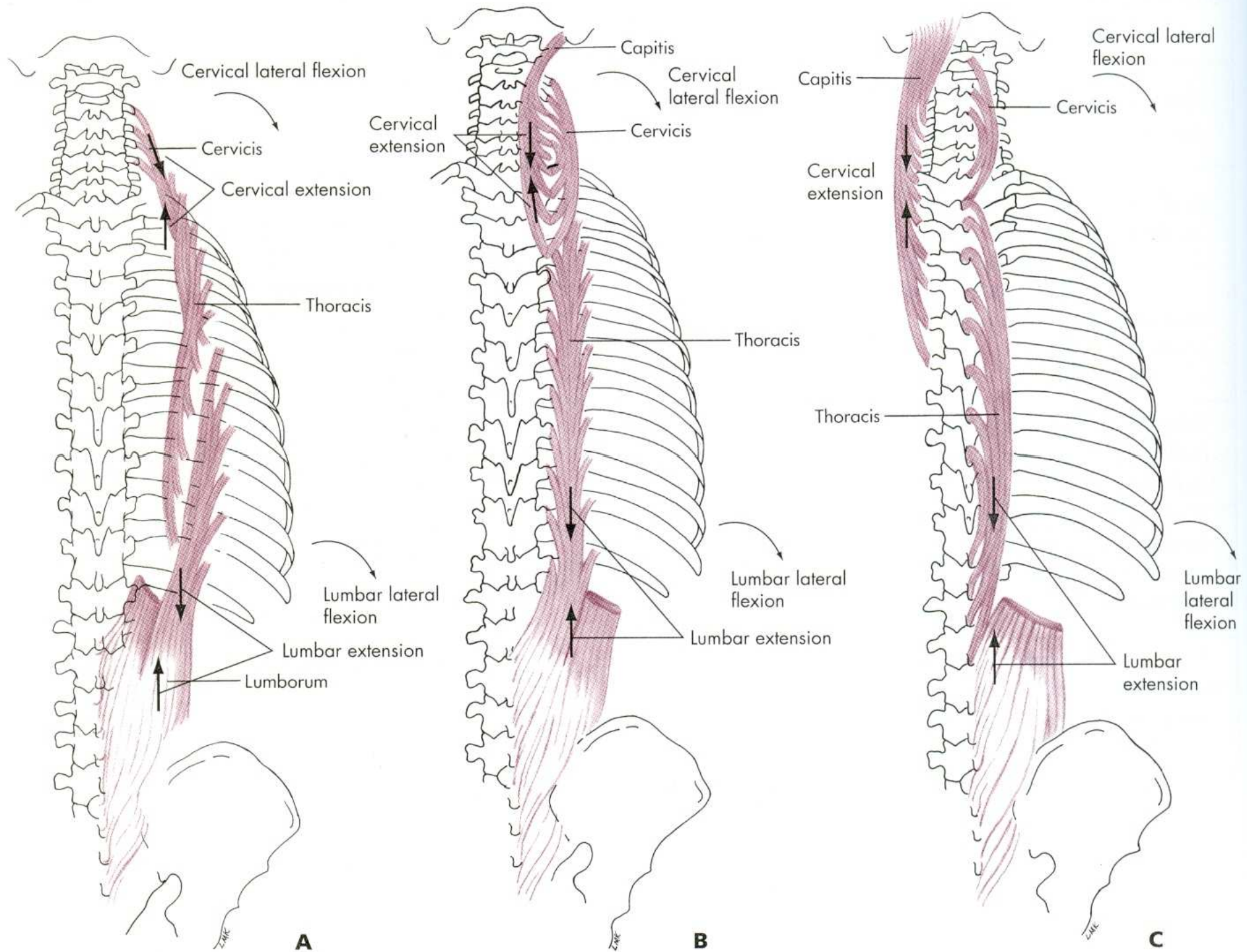


FIG. 12.15 • Erector spinae (sacrospinalis) muscle, posterior view. **A**, iliocostalis; **B**, longissimus; **C**, spinalis.

VENTRÁLNÍ FLEXE

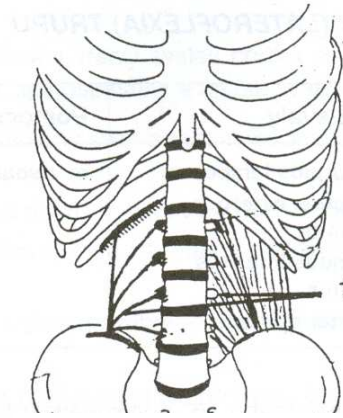
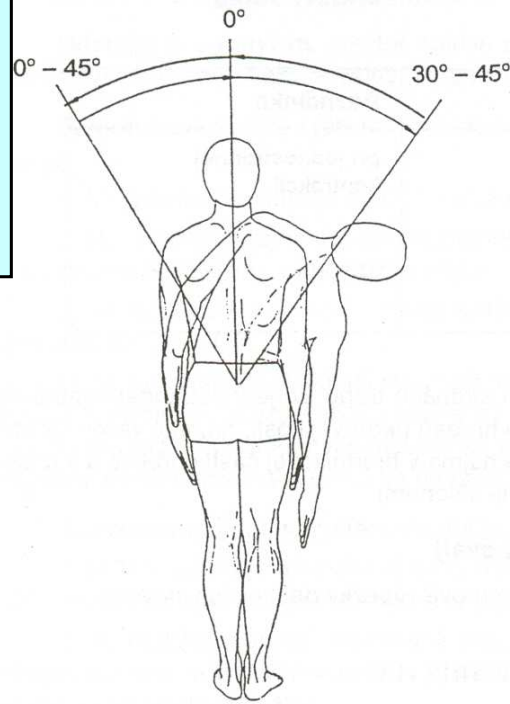
m. rectus abdominis – přímý sval břišní

DORZÁLNÍ FLEXE


m. erector spinae – hluboké svaly zádové

m. quadratus lumborum –
čtyřhranný sval bederní

LATEROFLEXE - ÚKLON

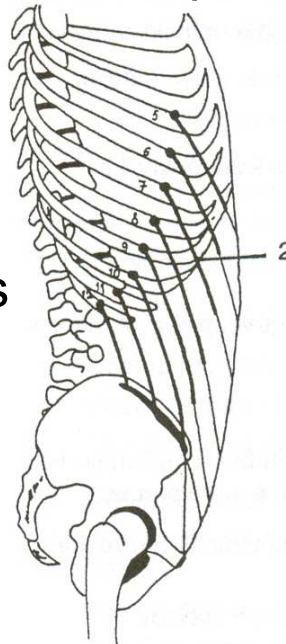


m. quadratus lumborum

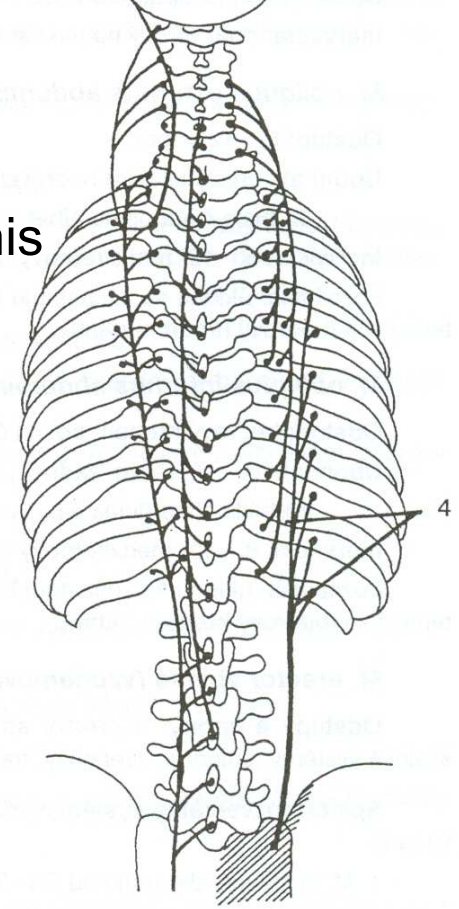
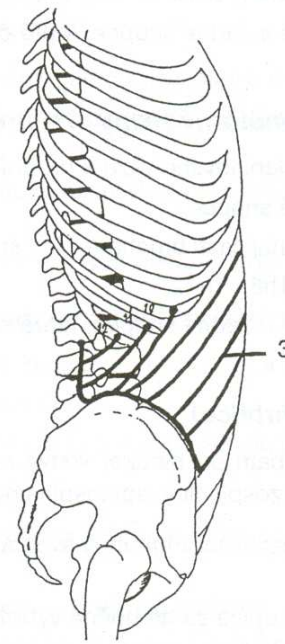


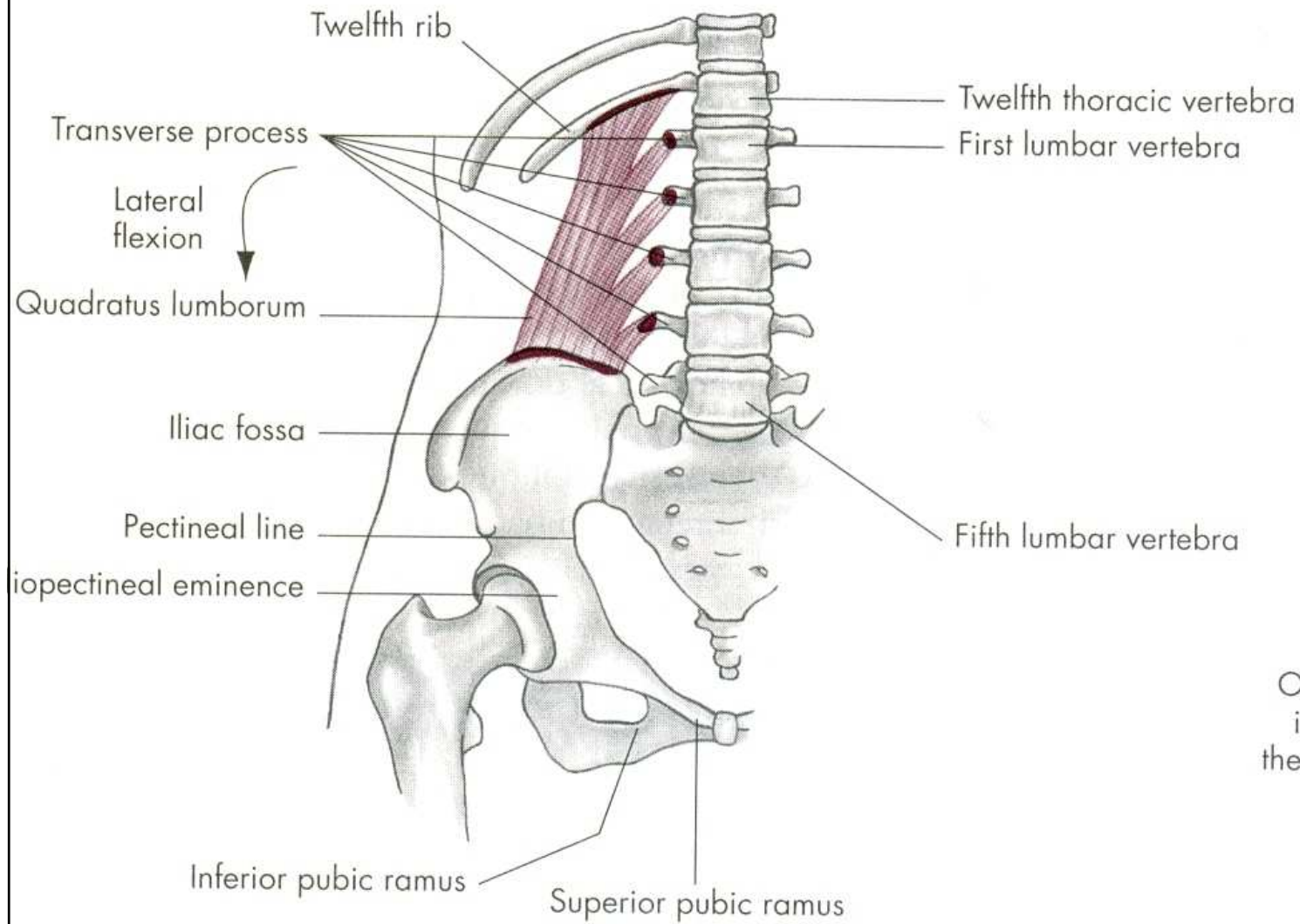
m. erector spinae

m. obliquus internus abdominis

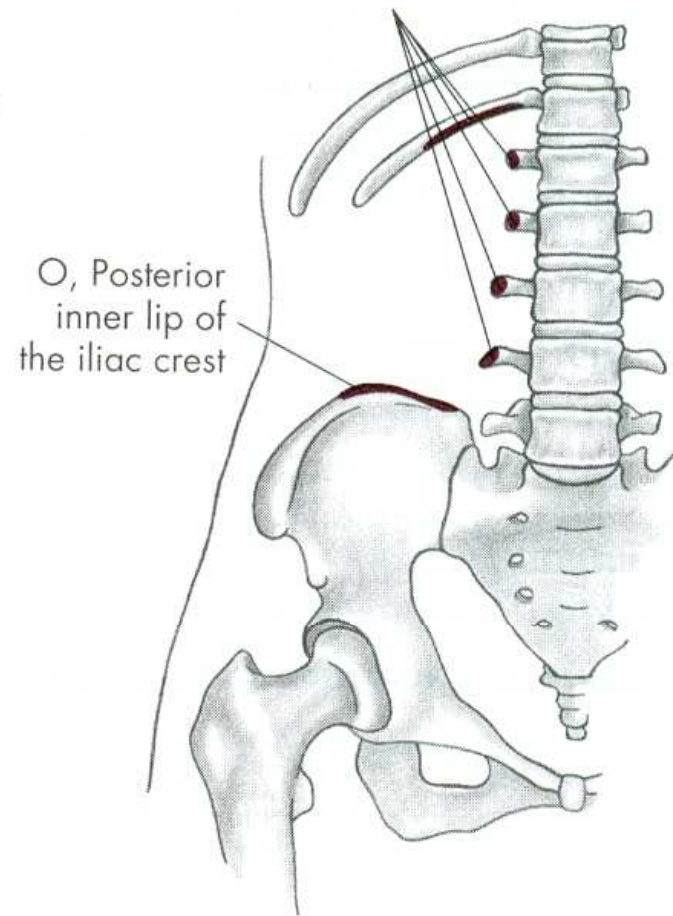


m. obliquus externus abdominis





I, Approximately one-half length of lower border of the twelfth rib and transverse process of the upper four lumbar vertebrae



LATEROFLEXE

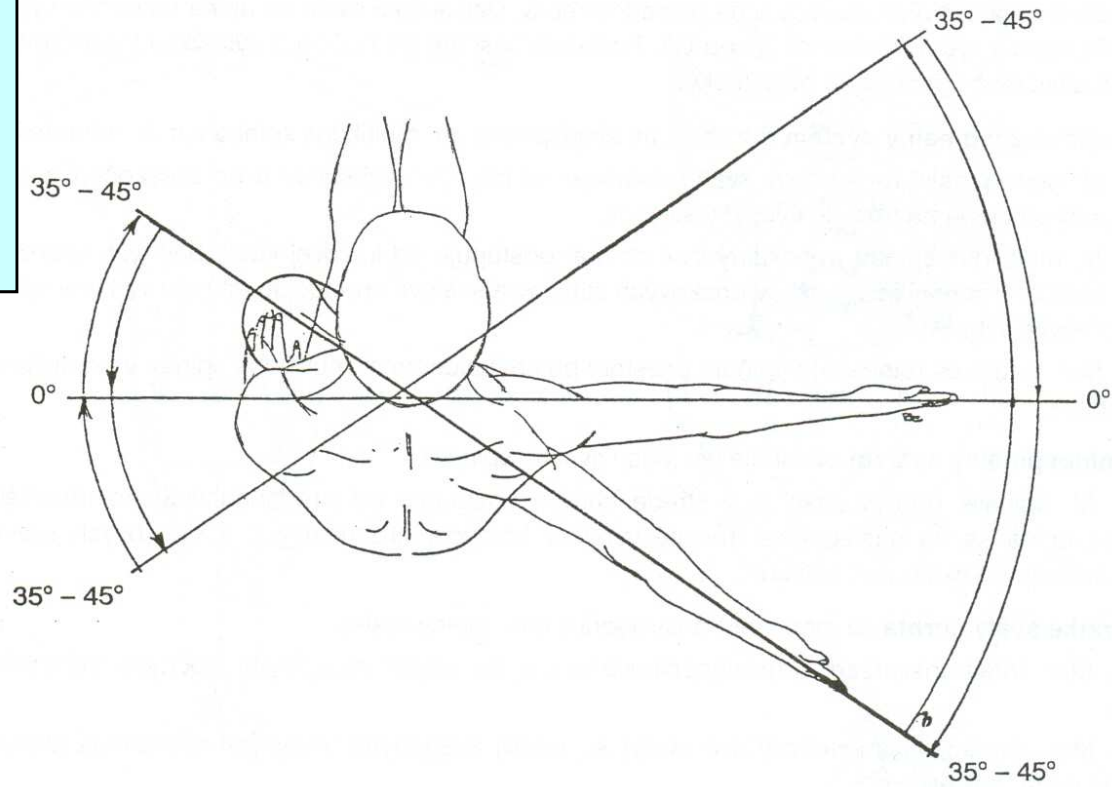
m. quadratus lumborum –
čtyřhranný sval bederní

m. obliquus externus abdominis
– vnější šikmý sval břišní

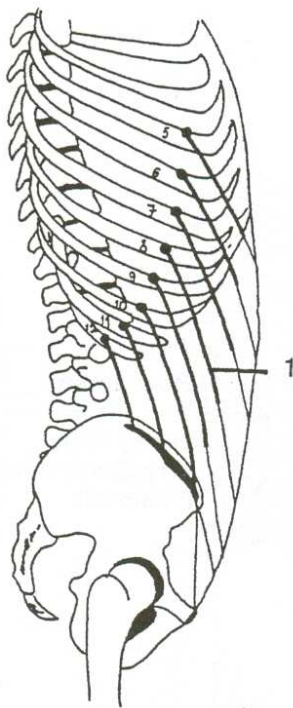
m. obliquus internus abdominis
– vnitřní šikmý sval břišní

m. erector spinae – hluboké svaly zádové

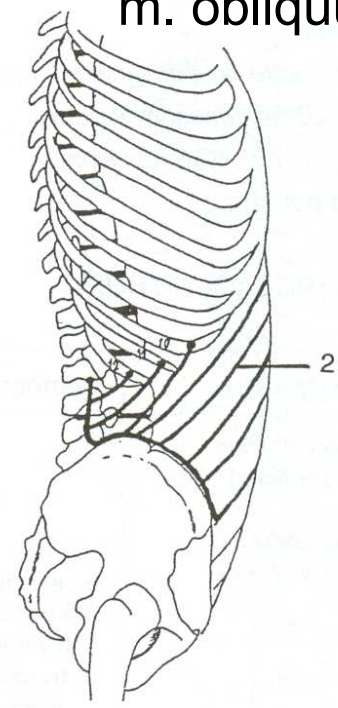
ROTACE - OTÁČENÍ

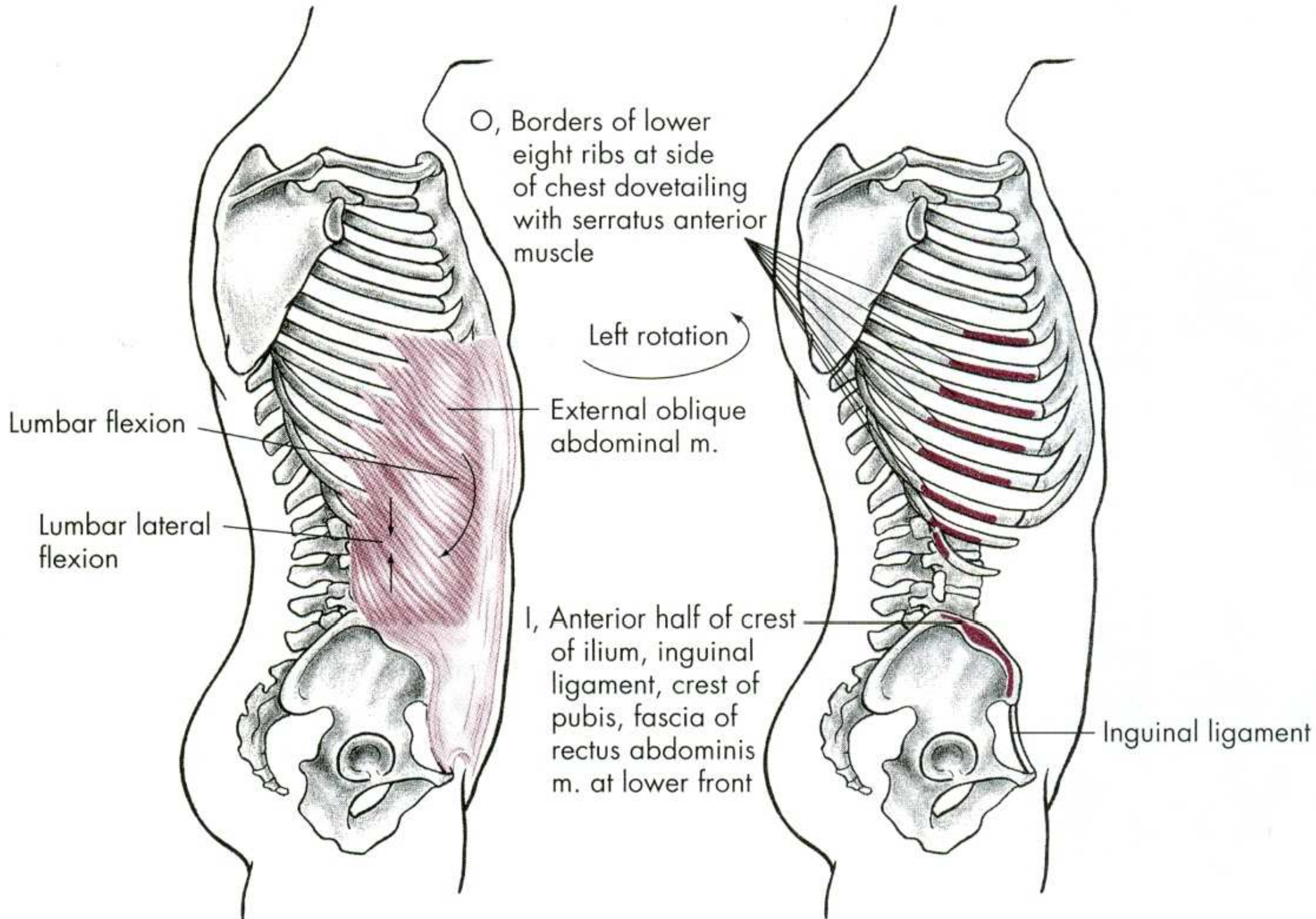


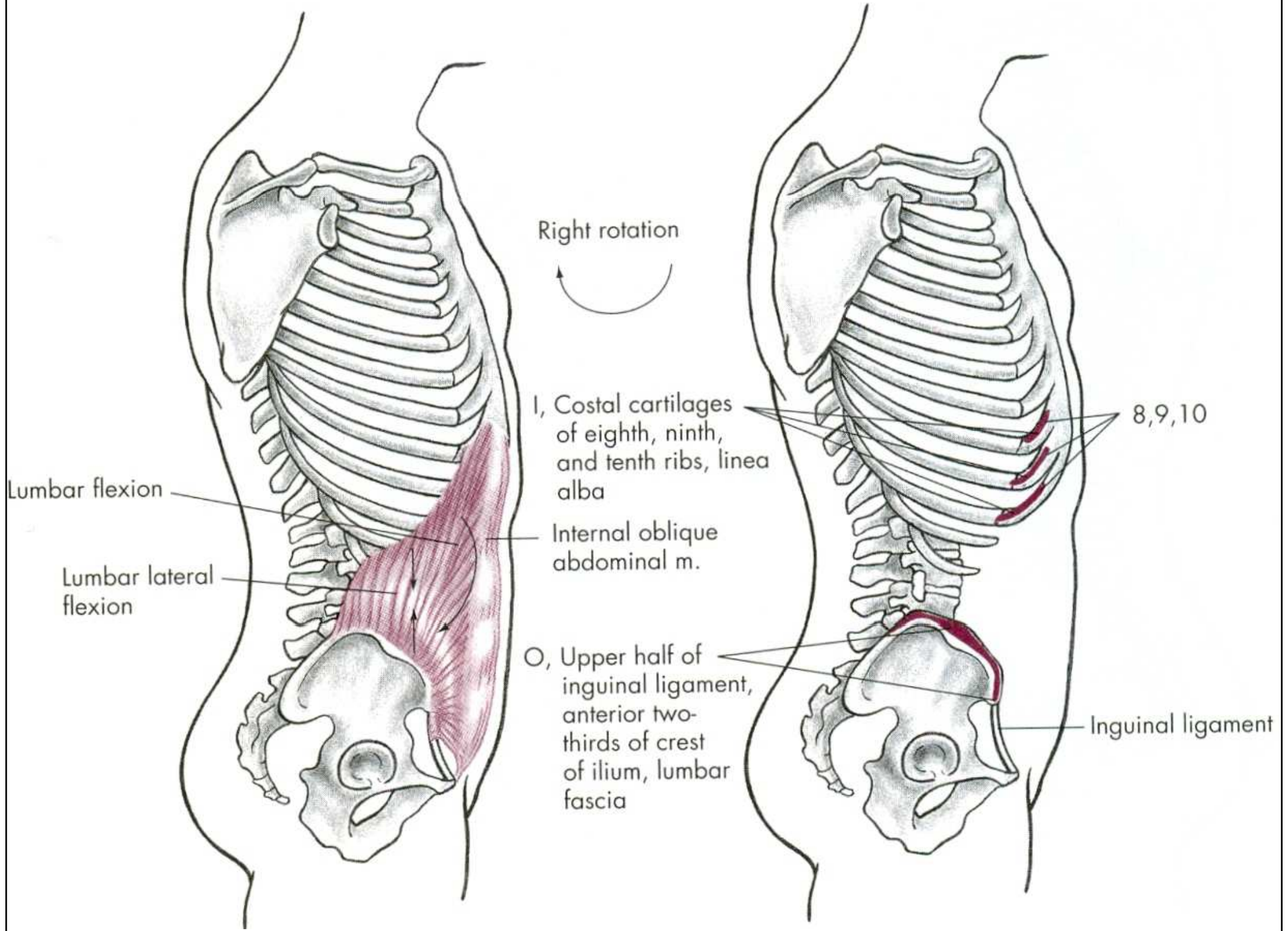
m. obliquus externus abdominis

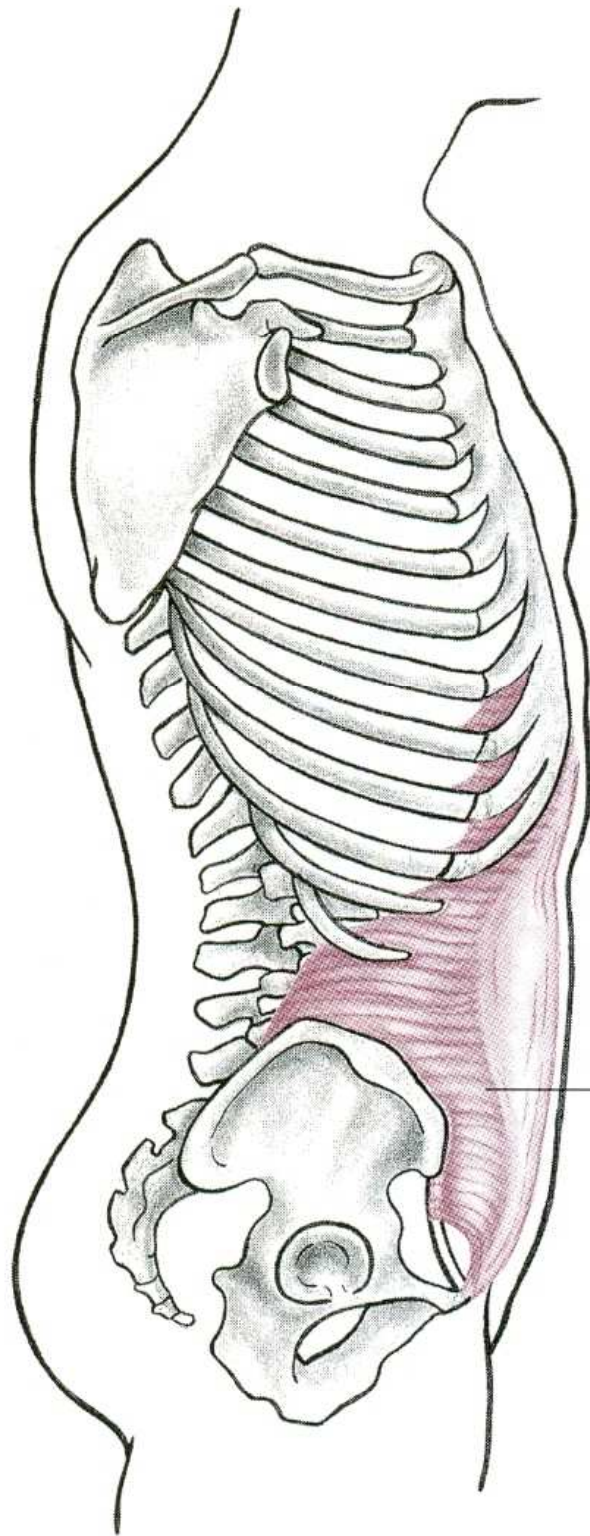


m. obliquus internus abdominis



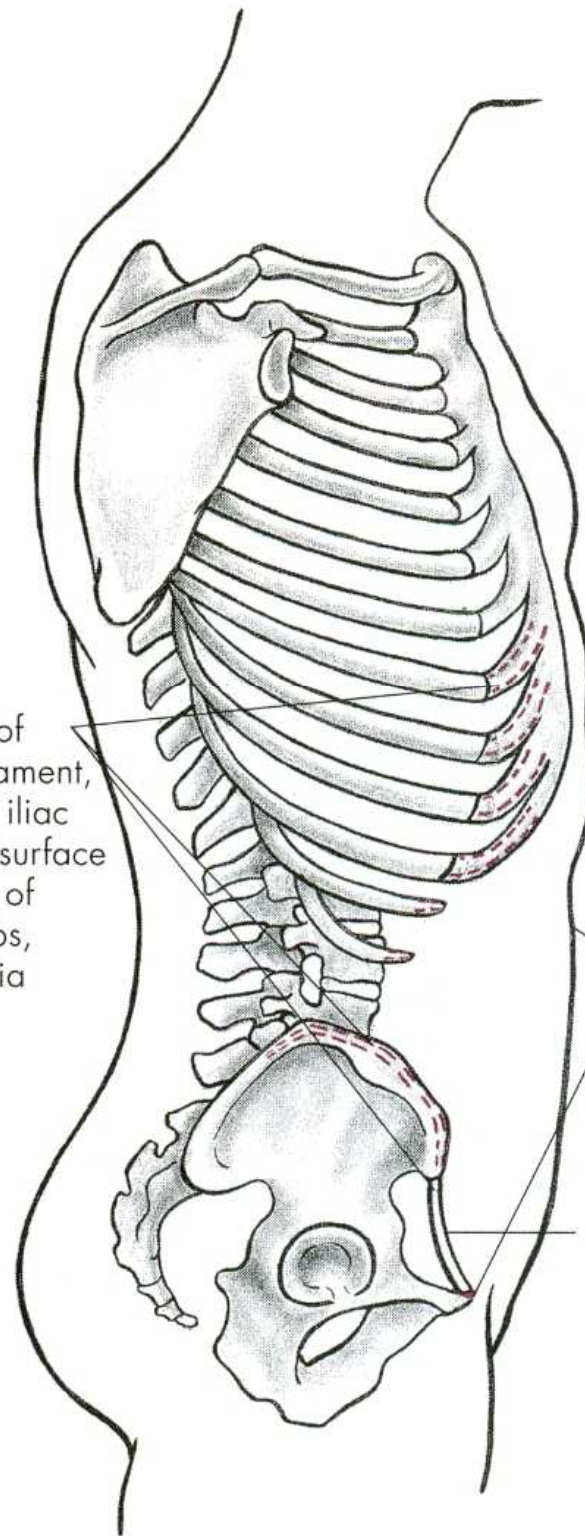






O, Outer third of inguinal ligament, inner rim of iliac crest, inner surface of cartilage of lower six ribs, lumbar fascia

Transversus abdominus m.



I, Crest of pubis, iliopectineal line, and linea alba joining its fellow from other side

Inguinal ligament

ROTACE

m. obliquus externus abdominis
– vnější šikmý sval břišní

m. obliquus internus abdominis
– vnitřní šikmý sval břišní

POHYBY PÁNVE


ELEVACE - ZDVIHNUTÍ

INKLINACE/ANTEVERZE
- VYSAZENÍ

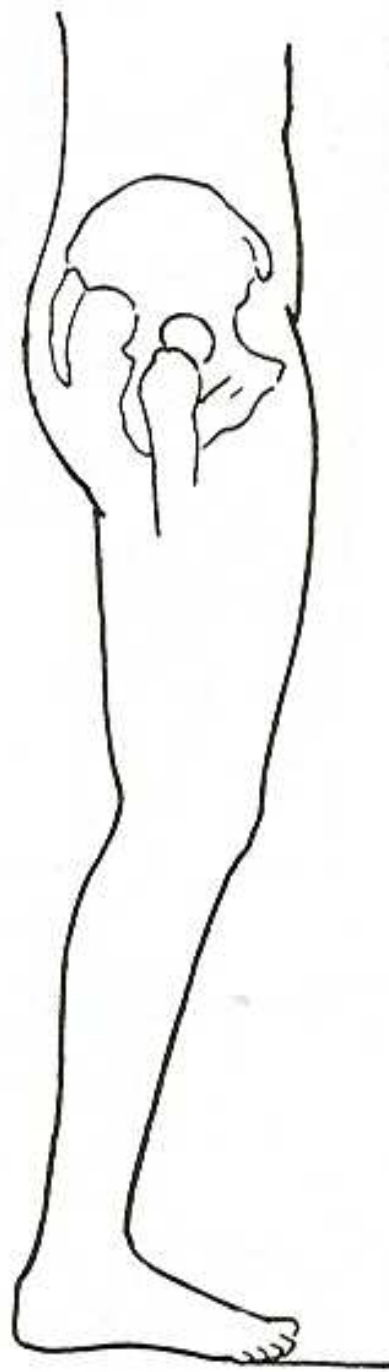
REKLINACE/RETROVERZE
- PODSAZENÍ

ELEVACE

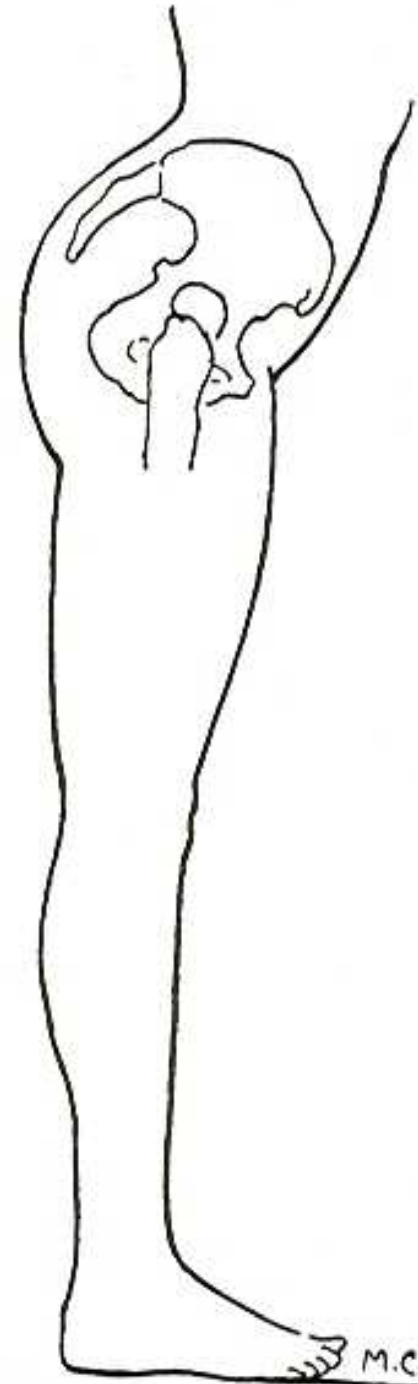
m. quadratus lumborum –
čtyřhranný sval bederní



a.



REKLINACE



INKLINACE

M.C.

INKLINACE - ANTEVERZE

m.iliopsoas – sval bedrokyčlostehenní

m.glutaeus minimus – malý sval hýžd'ový

m.sartorius – sval krejčovský

m.tensor fasciae latae –
napínač stehenní povázky

REKLINACE - RETROVERZE

m.semitendinosus – sval pološlašitý

m.semimembranosus – sval poloblanitý

m.glutaeus maximus – velký sval hýžd'ový

m.biceps femoris – dvojhlavý sval stehenní

POHYBY LOPATKY

ELEVACE - ZDVIHNUTÍ

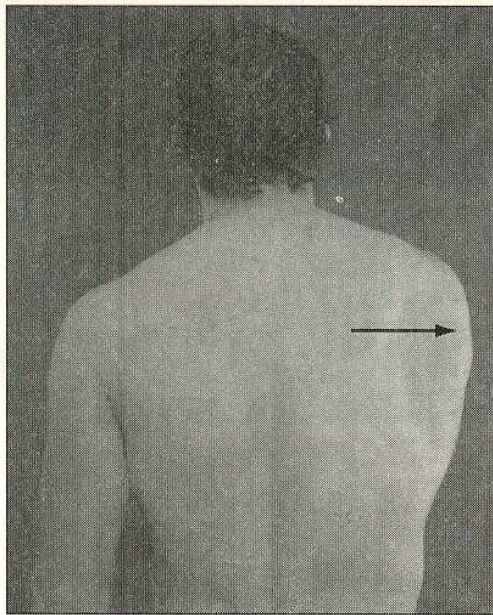
DEPRESE - POKLES

PROTRAKCE - ODTAŽENÍ

RETRAKCE - PŘITAŽENÍ

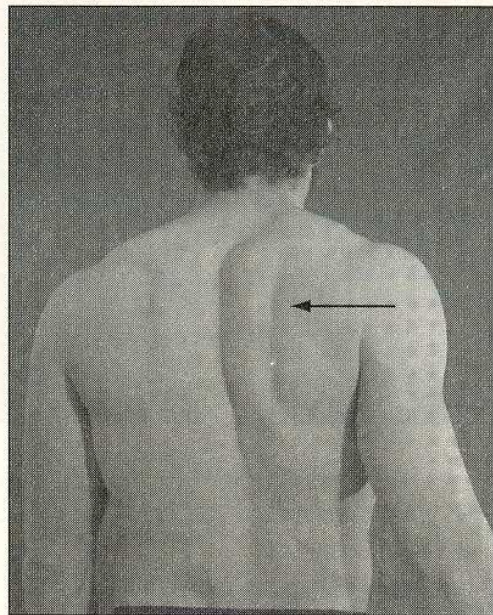
ANTEVERZE – ZEVNÍ ROTACE

RETROVERZE – VNITŘNÍ ROTACE



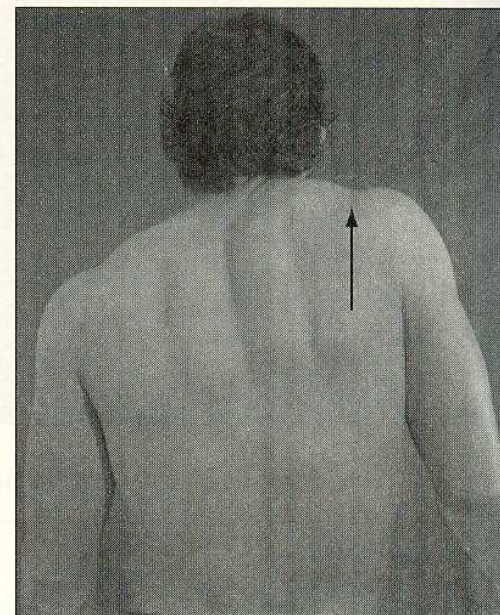
Abduction
(protraction)

A



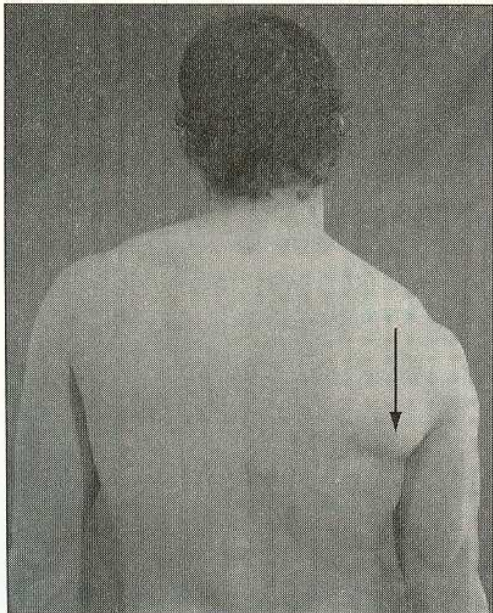
Adduction
(retraction)

B

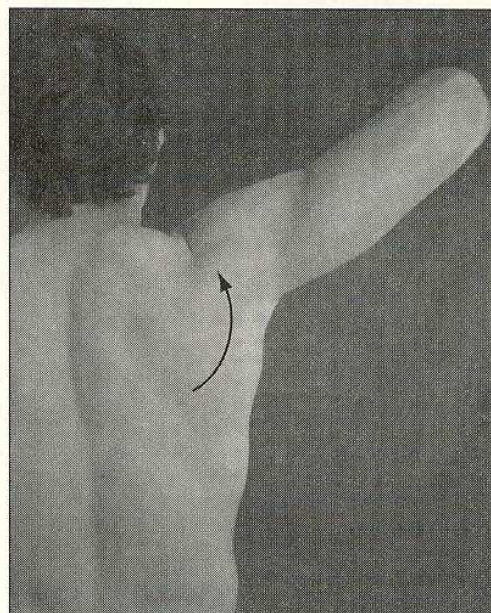


Elevation

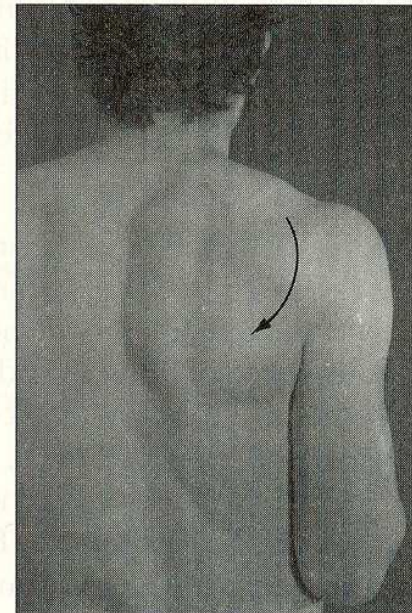
C



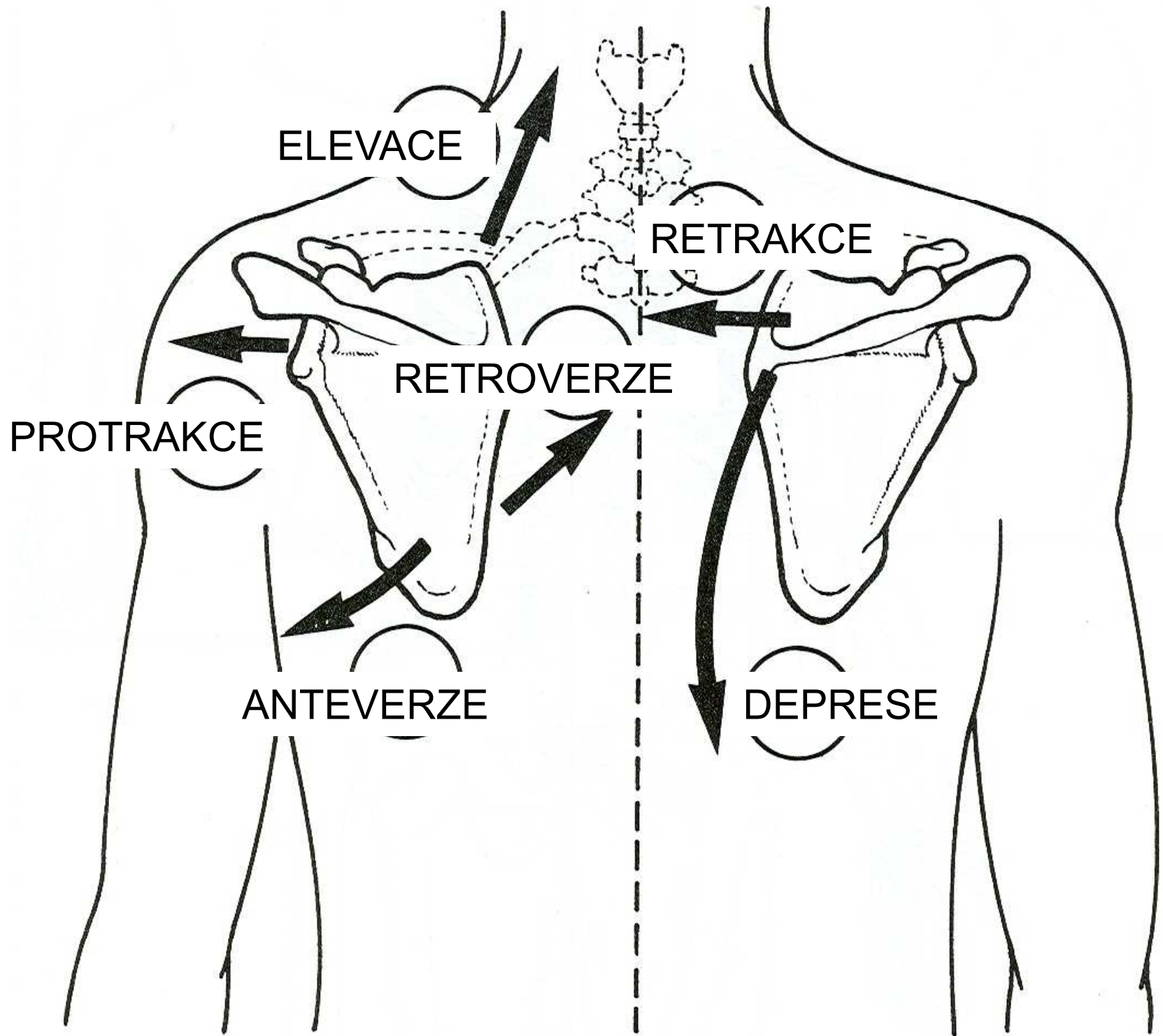
Depression



Upward rotation



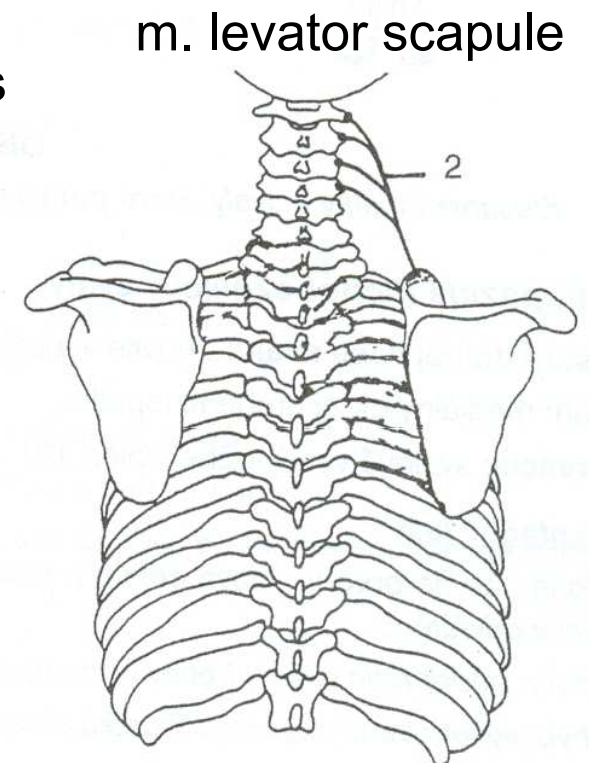
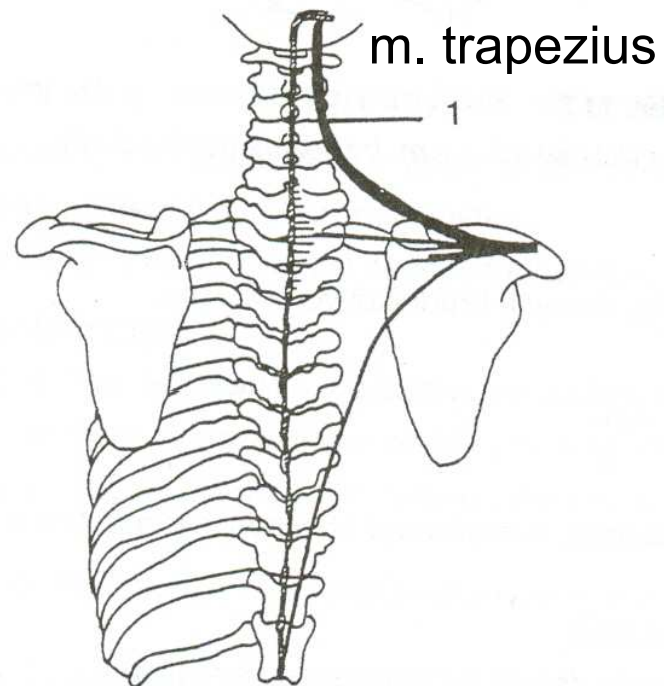
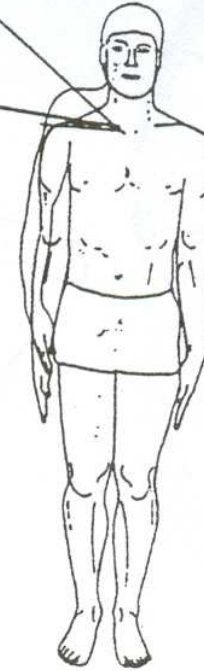Downward rotation



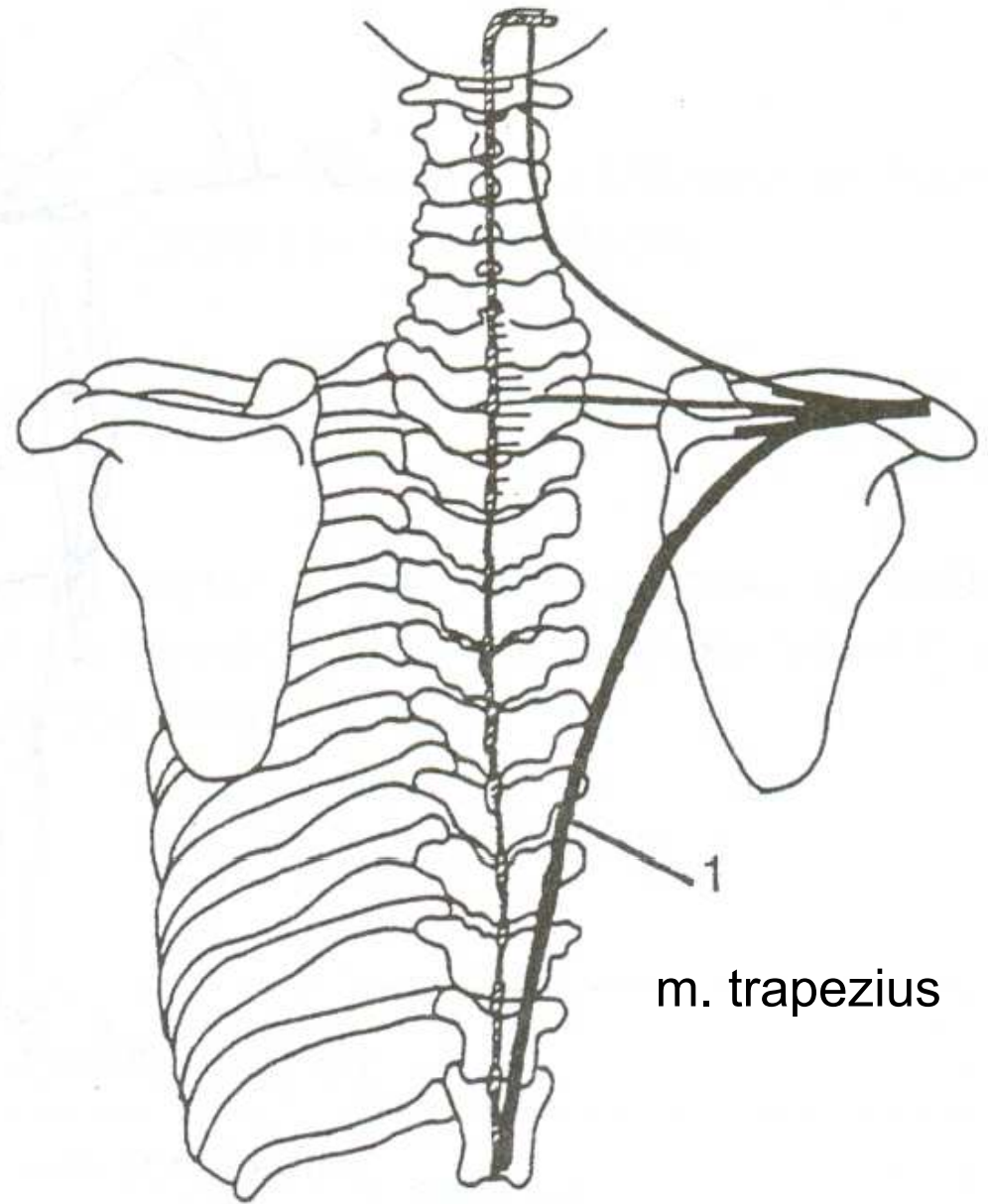
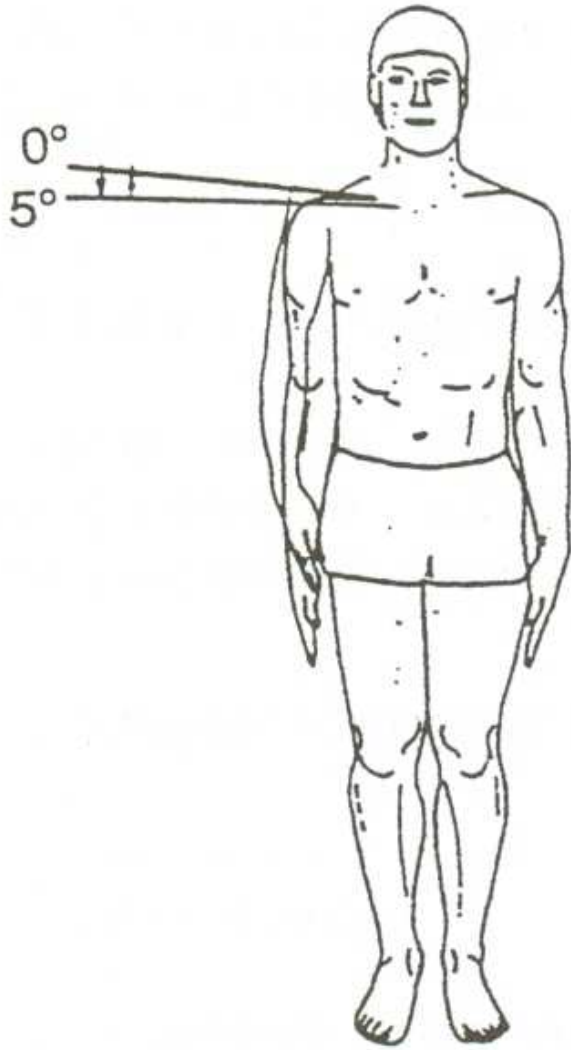
ELEVACE - ZDVIHNUTÍ

35° - 40°

0°



DEPRESE - POKLES



ELEVACE LOPATKY

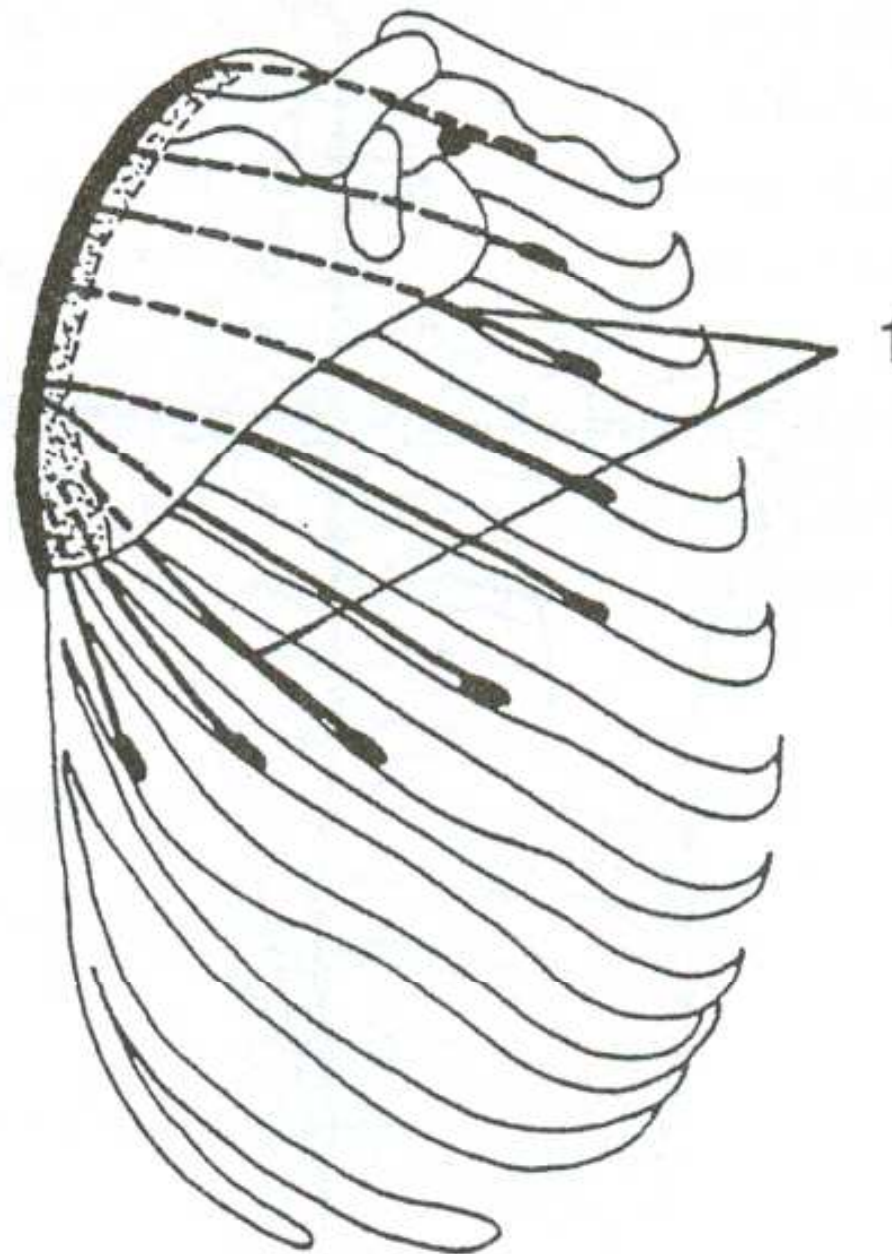
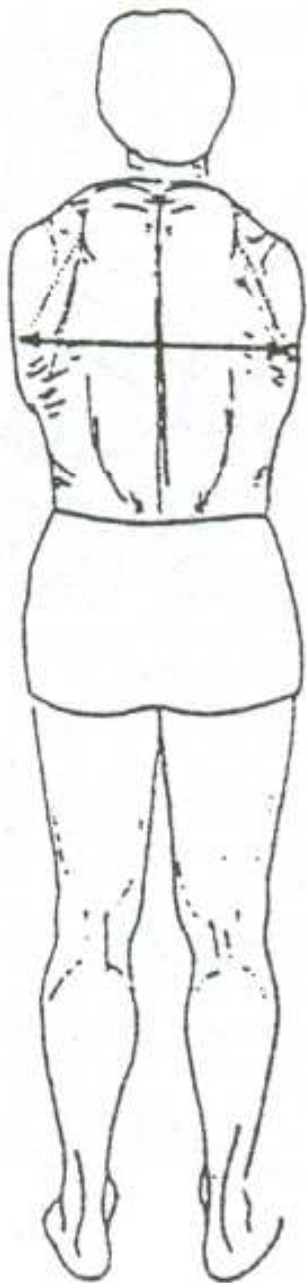
m.trapezius-pars superior –
sval trapezový-vrchní část

m.levator scapule – zdvihač lopatky

DEPRESE LOPATKY

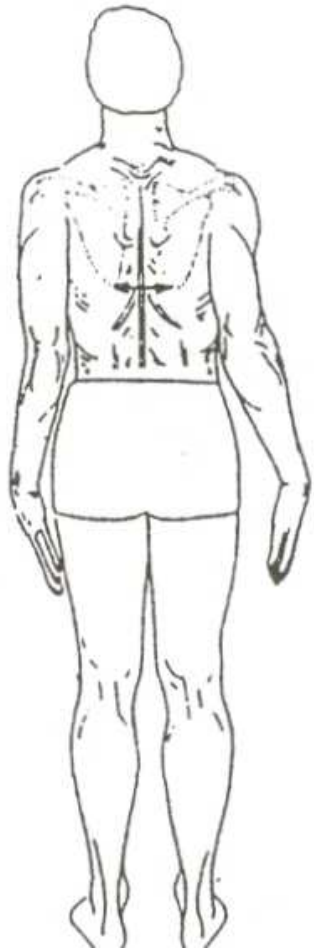
m.trapezius-pars inferior –
sval trapezový-spodní část

PROTRAKCE - ODTAŽENÍ

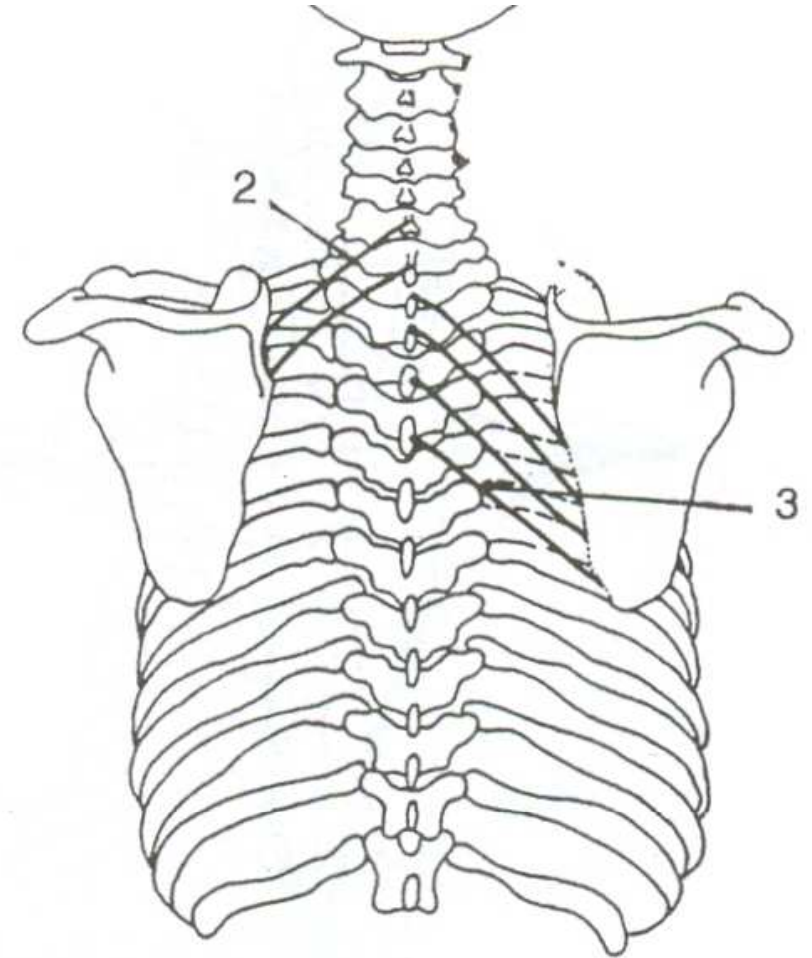
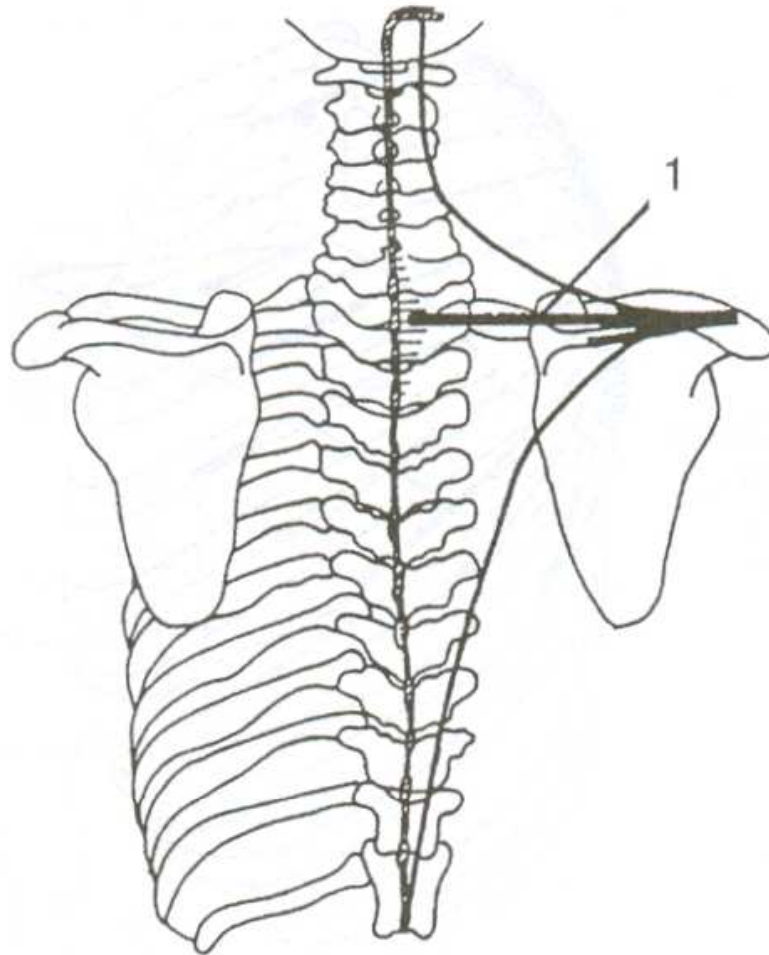


m. serratus anterior

RETRAKCE - PŘITAŽENÍ



m. trapezius m. rhomboideus minor



m. rhomboideus major

PROTRAKCE LOPATKY

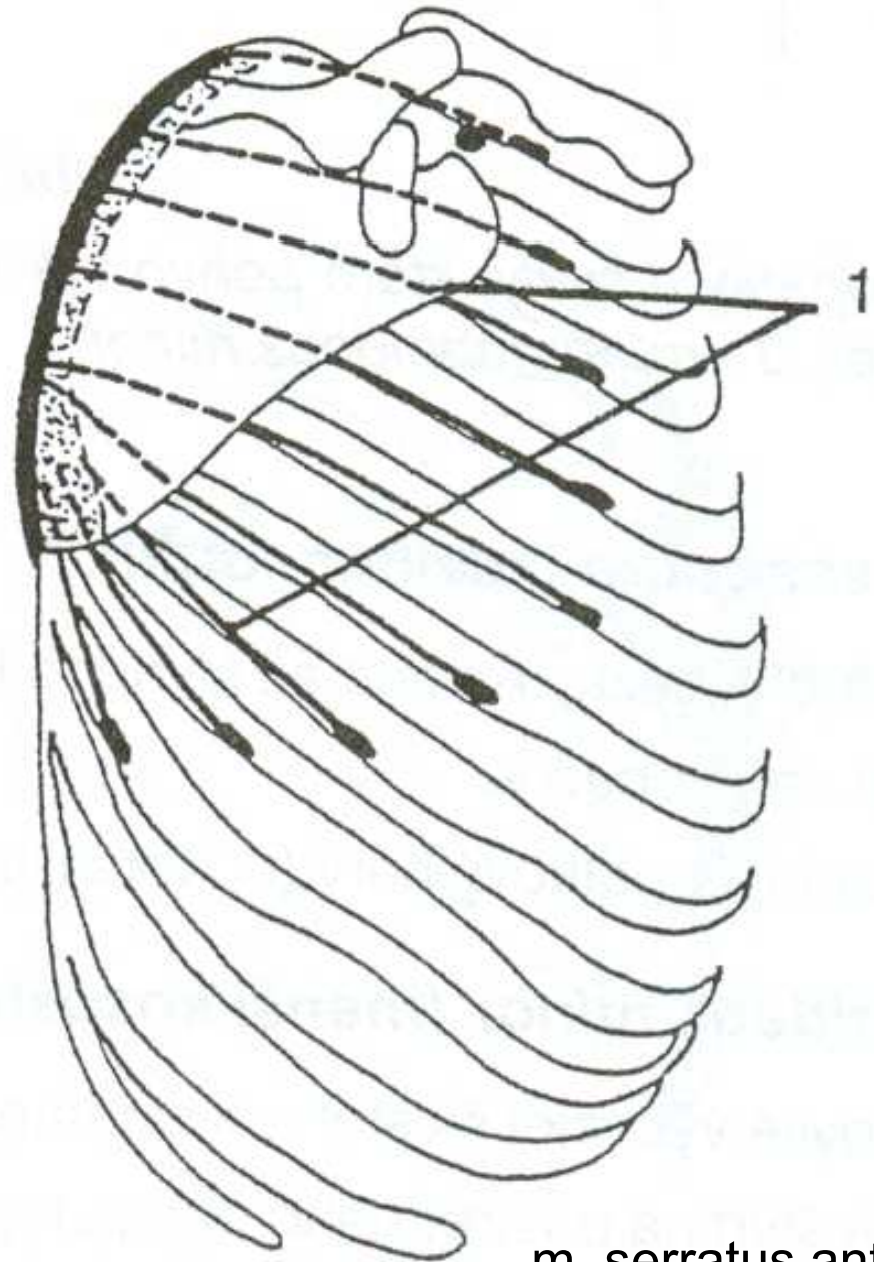
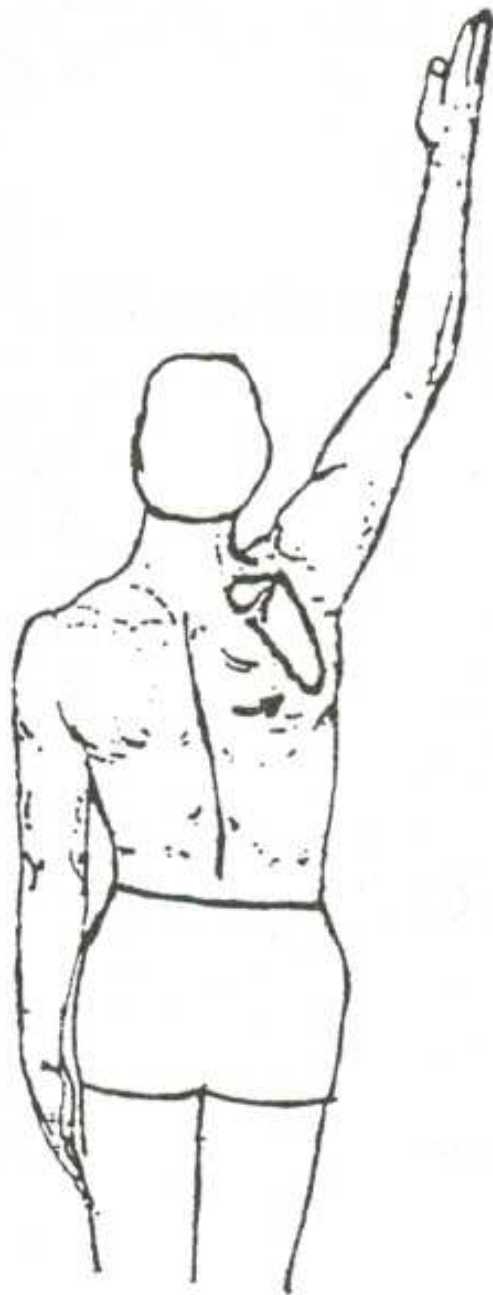
m.serratus anterior – přední sval pilovitý

RETRAKCE LOPATKY

m. trapezius – sval trapézová-střední část

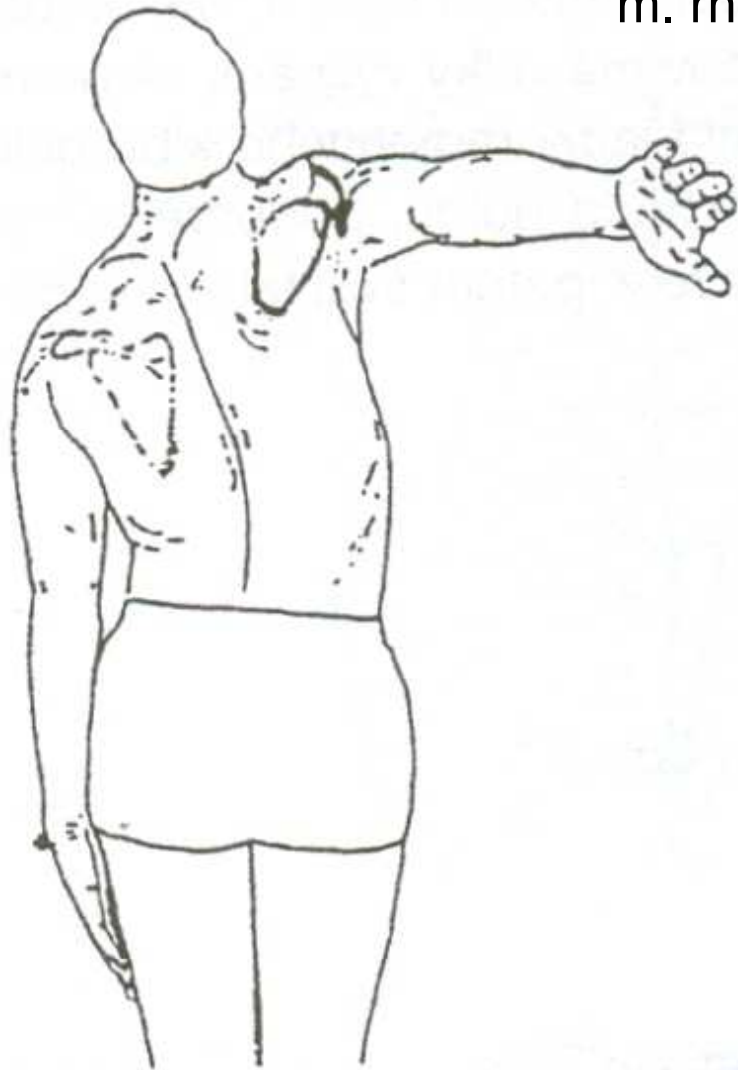mm. rhomboidei – svaly rombické

ANTEVERZE – ZEVNÍ ROTACE

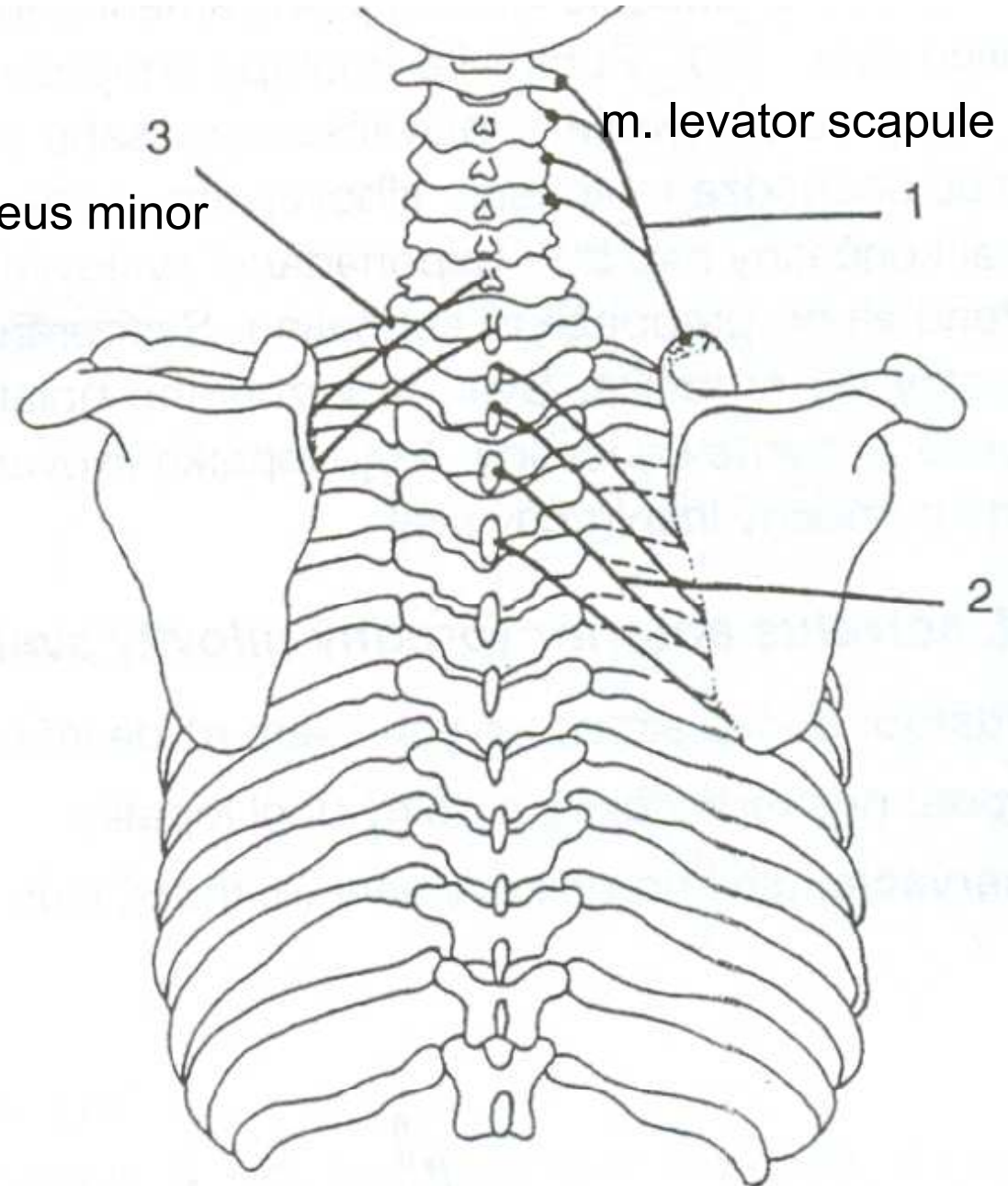


m. serratus anterior

RETROVERZE – VNITŘNÍ ROTACE



m. rhomboideus minor



m. levator scapulae

1

2

3

m. rhomboideus major

ANTEVERZE LOPATKY

m. serratus anterior – přední sval pilovitý

RETROVERZE LOPATKY

m. levator scapulae – zdvihač lopatky

mm. rhomboidei – svaly rombické

Rhomboids
Trapezius
Levator scapulae

Rhomboids
Trapezius
Levator
scapulae

Serratus
Anterior
Pectoralis
minor

Trapezius
Pectoralis minor

Trapezius
Serratus anterior
Rhomboids
Pectoralis minor
Levator scapulae

