

Impaled head

Martin Missmann, Thomas Tauscher, Siegfried Jank, Frank Kloss, Robert Gassner

Although case reports of trauma describe single events only, they can contain very useful scientific information for applied surgery. The portrait of Gregor Baci from the collection of Archduke Ferdinand II of Austria (figure A) provokes the question: is the legend that Baci survived a piercing injury with a lance only a myth, or does medical fact indicate that such severe impalement of the head and neck can be survived? We were able to provide the answer, when a similar case of impalement presented to us. The patient, a craftsman, was injured when a metal bar fell from the ceiling of a church with an altitude of about 14 m, impaling his head in an anterior-posterior direction (figure B). The track of the metal bar followed a mediocaudal line that was near parallel to the Frankfurt

horizontal line. The bar entered at the anterior wall of the maxillary sinus, passed the pterygopalatine and infratemporal fossa, and exited at a point mediocaudal to the mastoid process. The patient had to undergo surgical treatment twice, and had a year of episodes with headache and moderate diplopia, but now, about 5 years after the accident, the patient does not show any related clinical symptoms. This case shows that even severe penetrating traumas of the head and neck can be survived without sequelae of serious physiological dysfunction. Moreover, some of the penetrating objects are in size and shape similar to surgical tools, and therefore such pathways to deeper structures—eg, the infratemporal fossa—might be feasible for endoscopic skull-base surgery.

Lancet 2010; 375: 317

Department of Cranio-Maxillofacial and Oral Surgery (M Missmann MD, S Jank MD, F Kloss MD, Prof R Gassner MD) and Department of Vascular Surgery (T Tauscher MD), University Hospital of Innsbruck, Innsbruck, Austria

Correspondence to: Prof Robert Gassner, Department of Cranio-Maxillofacial and Oral Surgery, University Hospital of Innsbruck, Innsbruck 6020, Austria
robert.gassner@uki.at

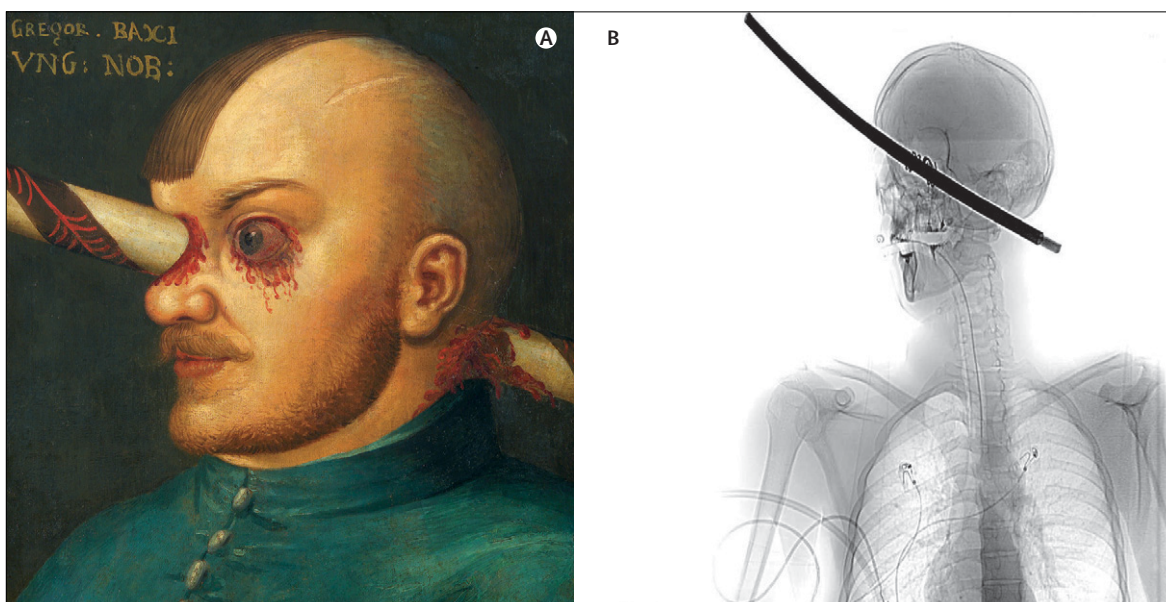


Figure: Impaled head

(A) Portrait of Hungarian hussar Gregor Baci, Ambras castle, Innsbruck, Austria (16th century). Reproduced with permission from Kunsthistorisches Museum mit MVK und ÖTM. (B) CT scan of patient (posterior-anterior scout view, approximately semi-lateral view of the head, positive).