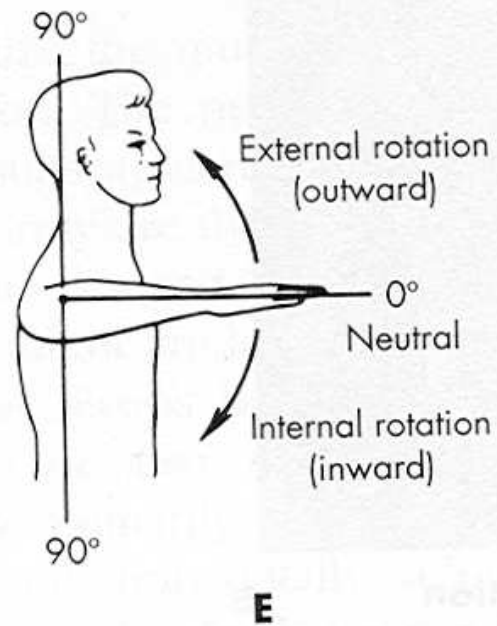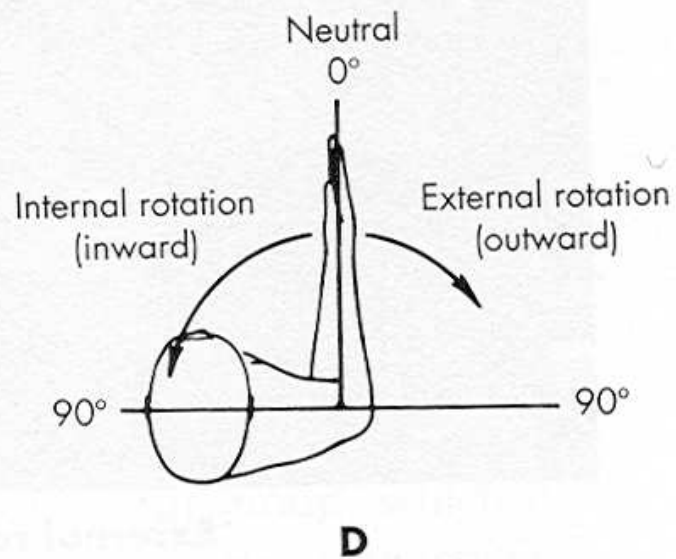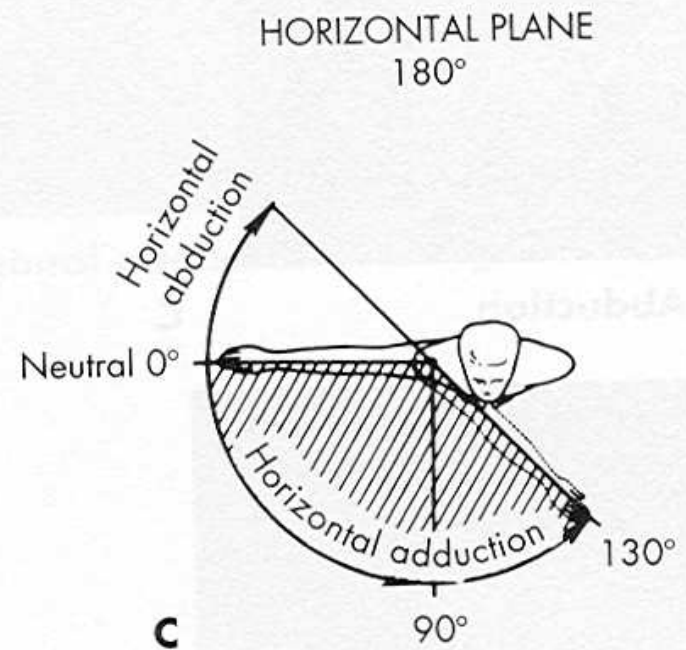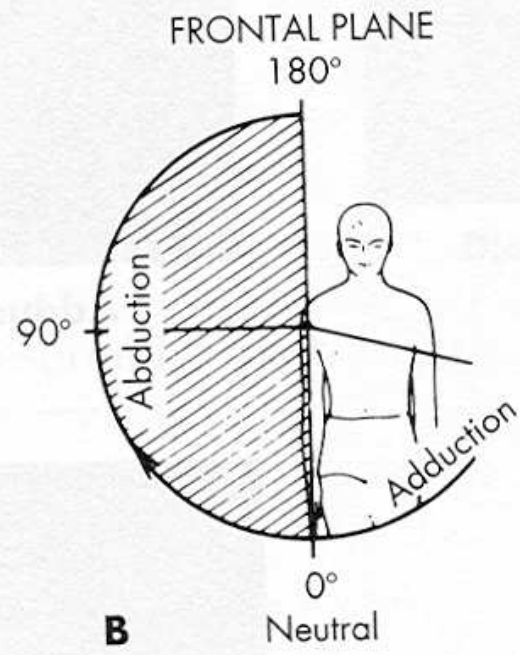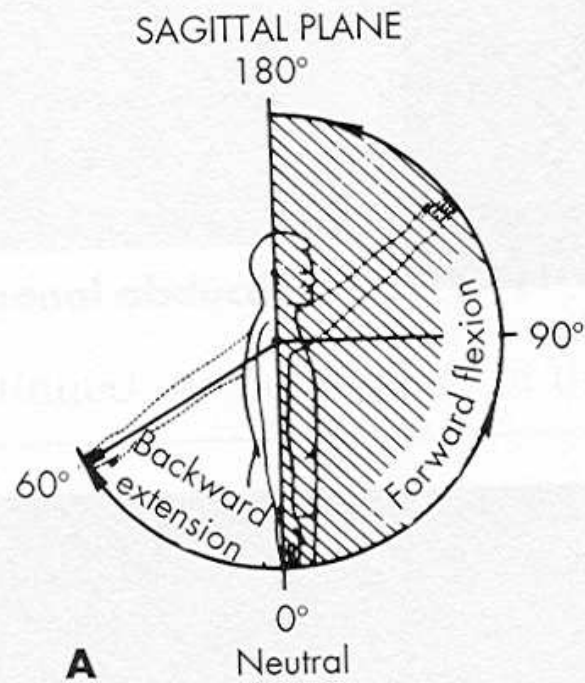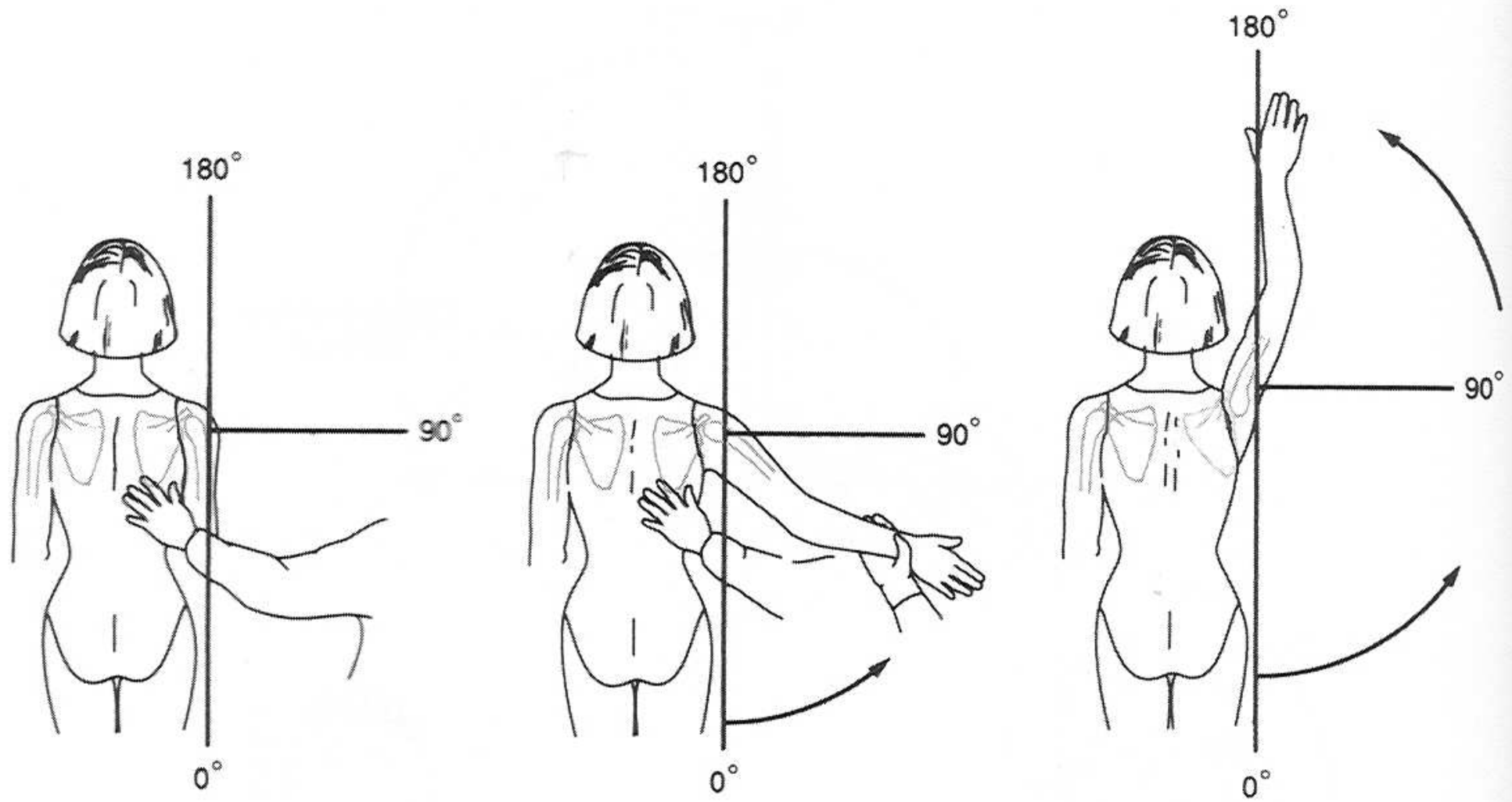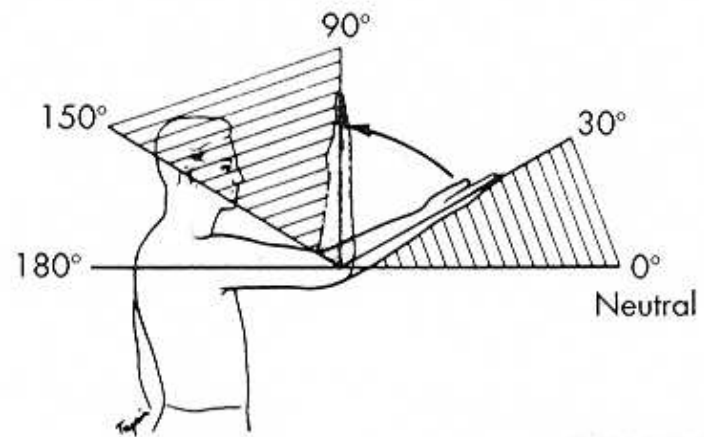
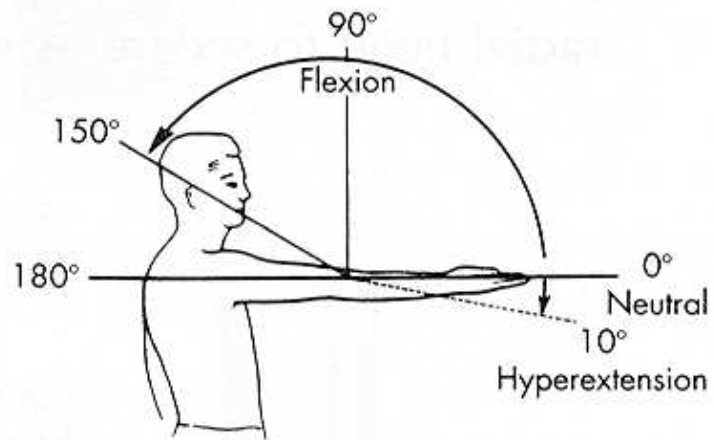


a.

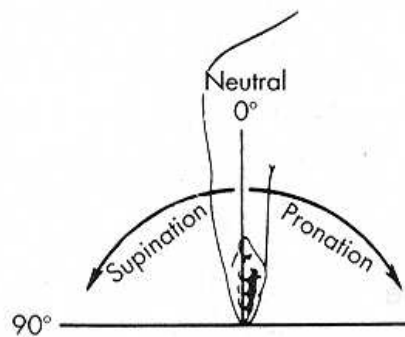
b.

c.

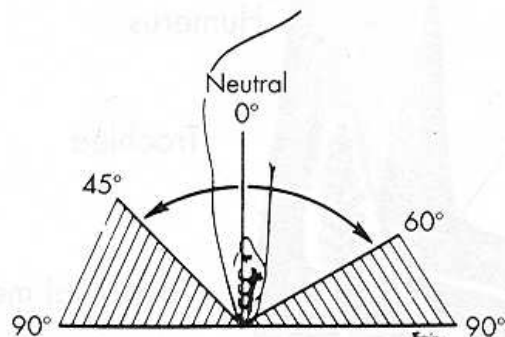
Figure C.6 Range of shoulder joint (glenohumeral) motion: (a) starting position; (b) abduction; (c) sideward-upward elevation of arm (combining abduction of arm and upward rotation of scapula).



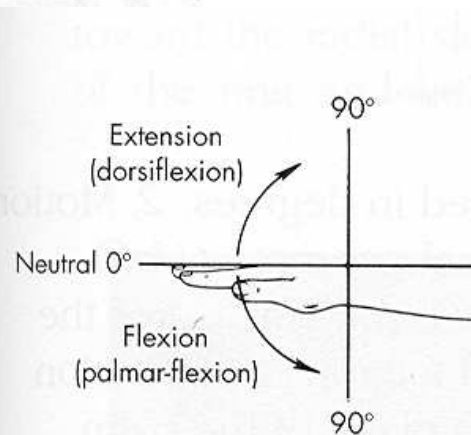
B



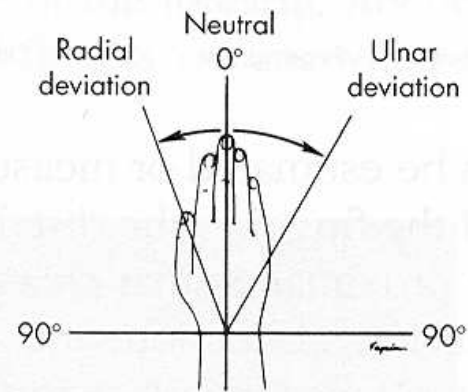
A



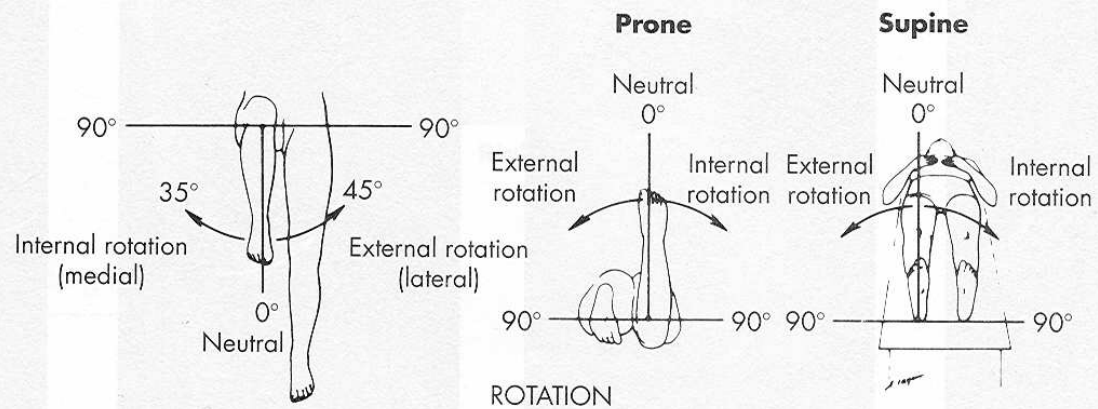
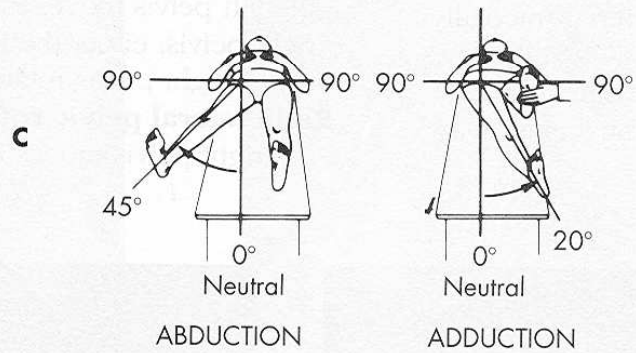
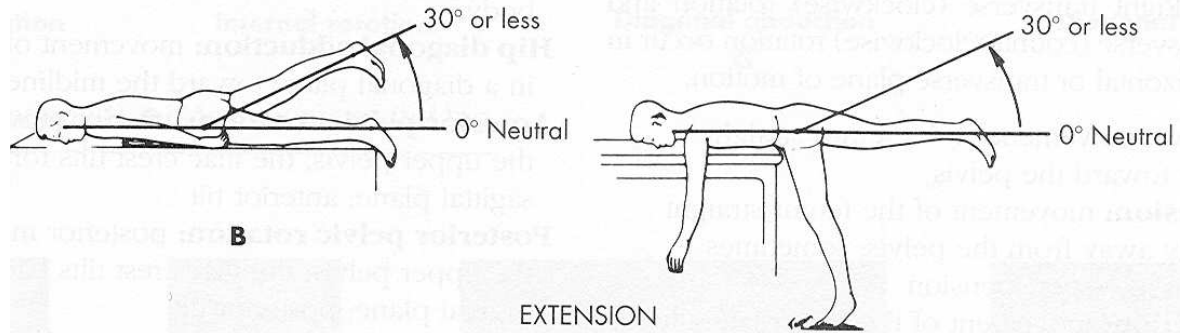
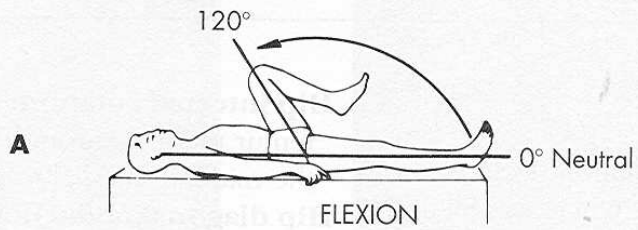
B

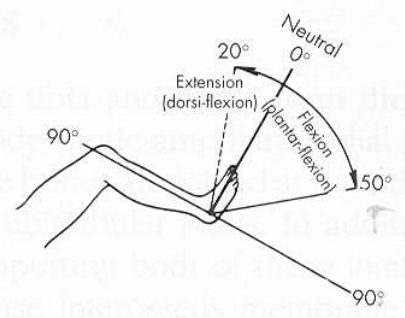
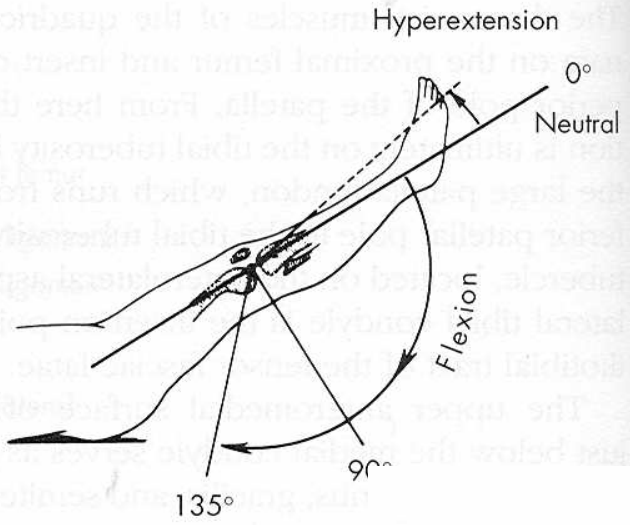


A



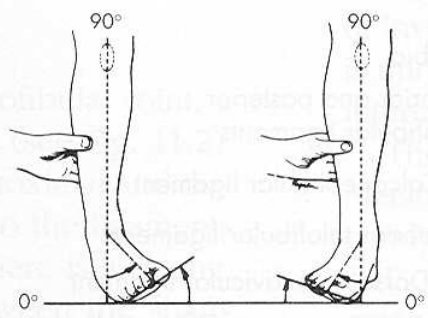
B





Ankle joint

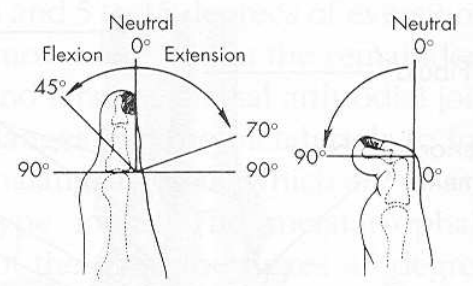
A



Inversion

Eversion

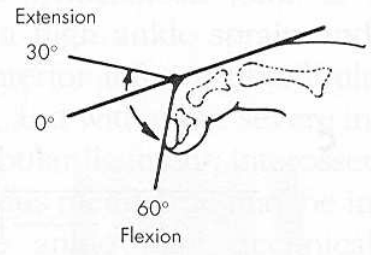
B



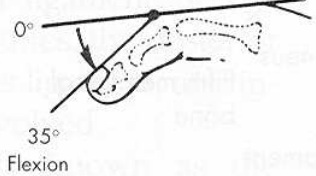
Metatarsophalangeal joint

Interphalangeal joint

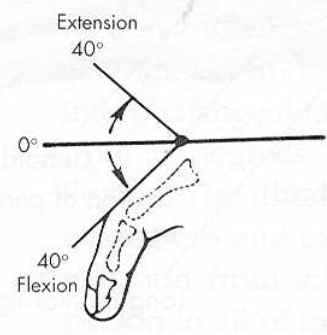
C



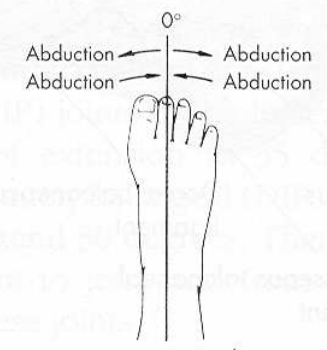
Distal interphalangeal joint



Proximal interphalangeal joint



Metatarsophalangeal joint



Toe spread

D

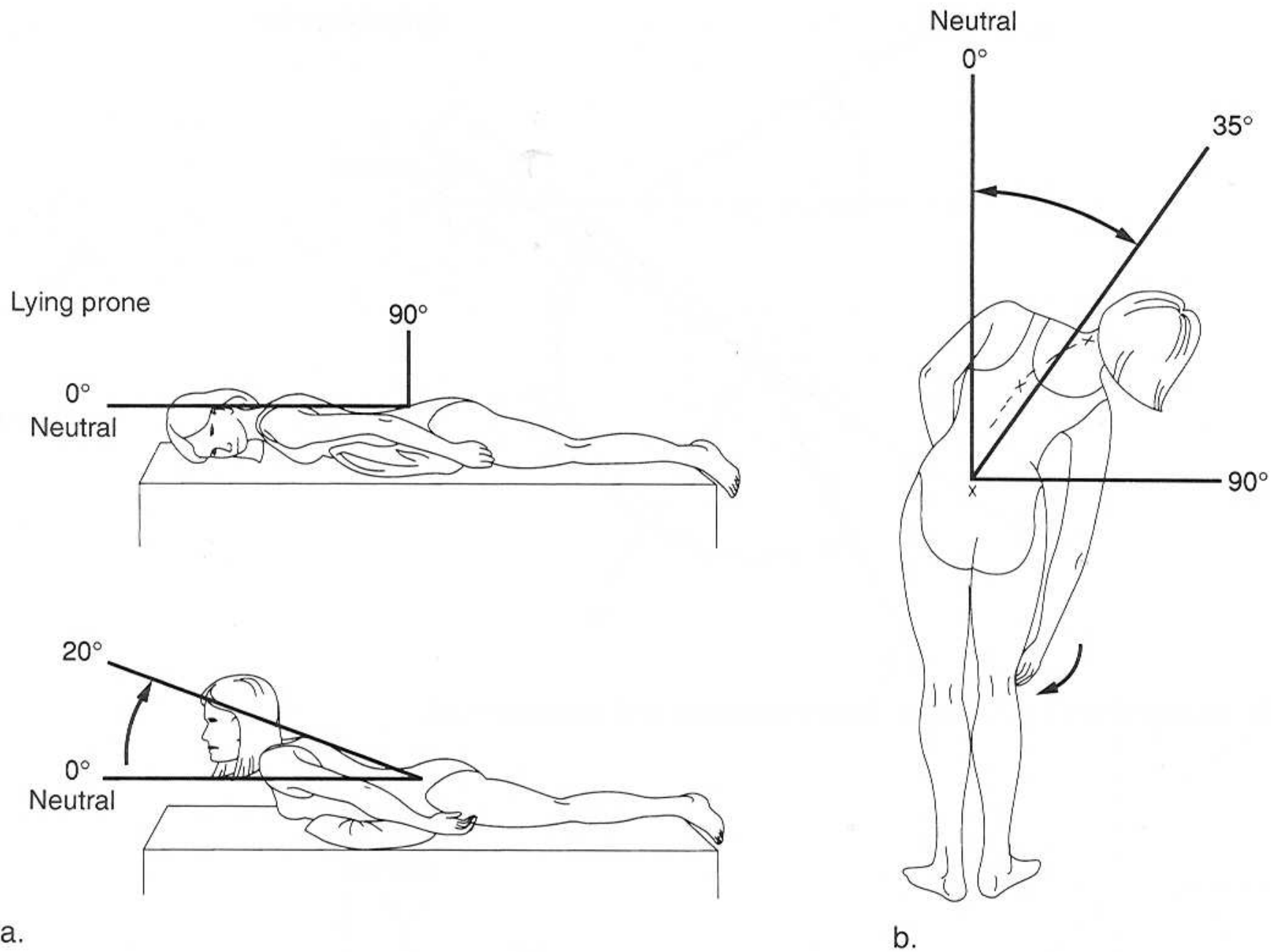


Figure C.11 Range of motion in the thoracic and lumbar spine: (a) hyperextension; (b) lateral flexion.