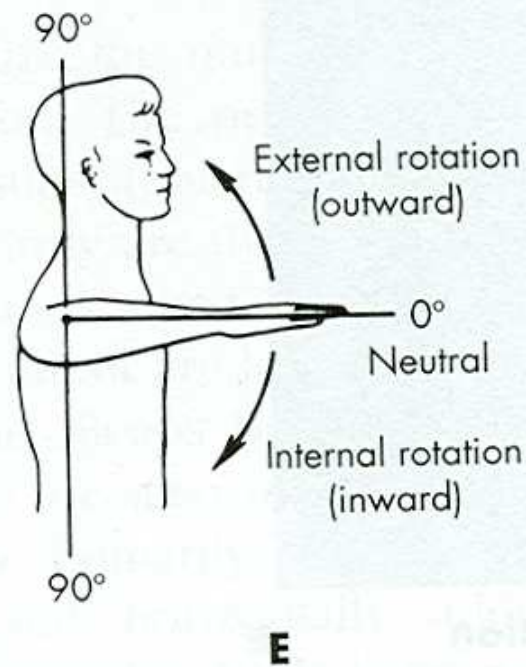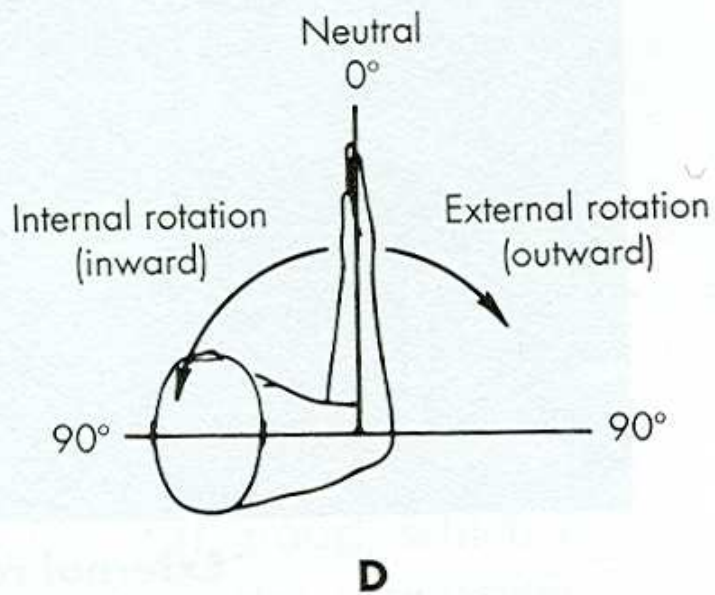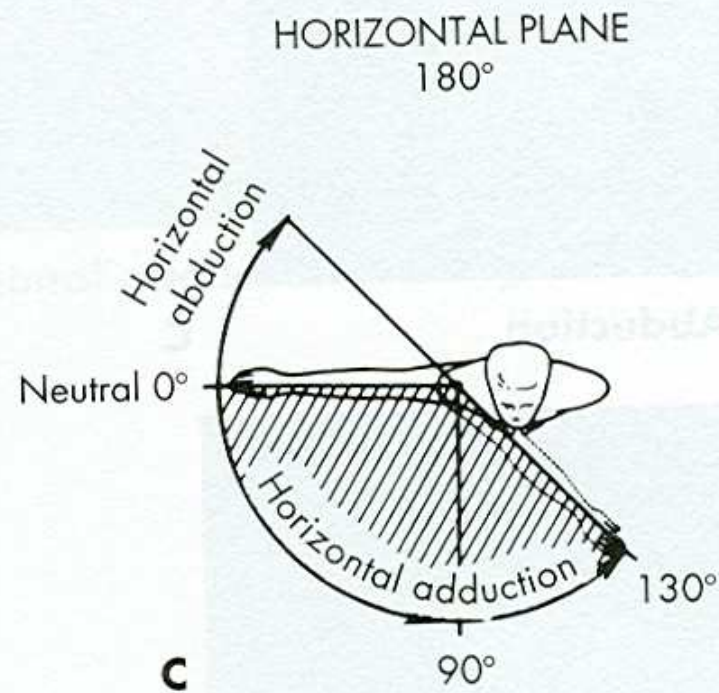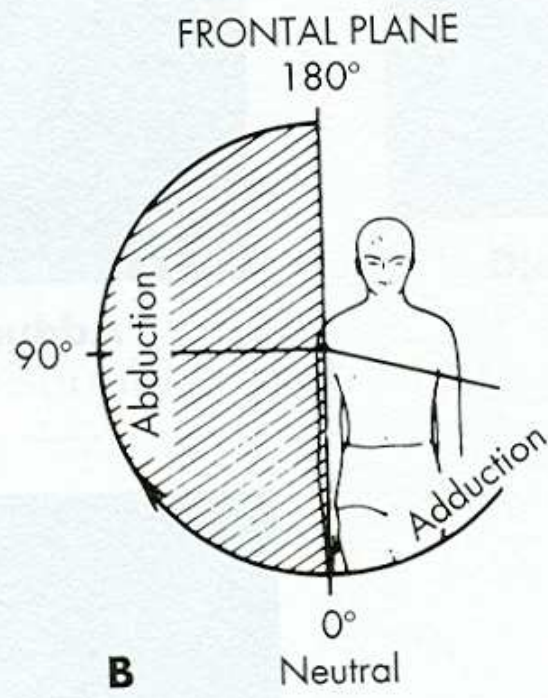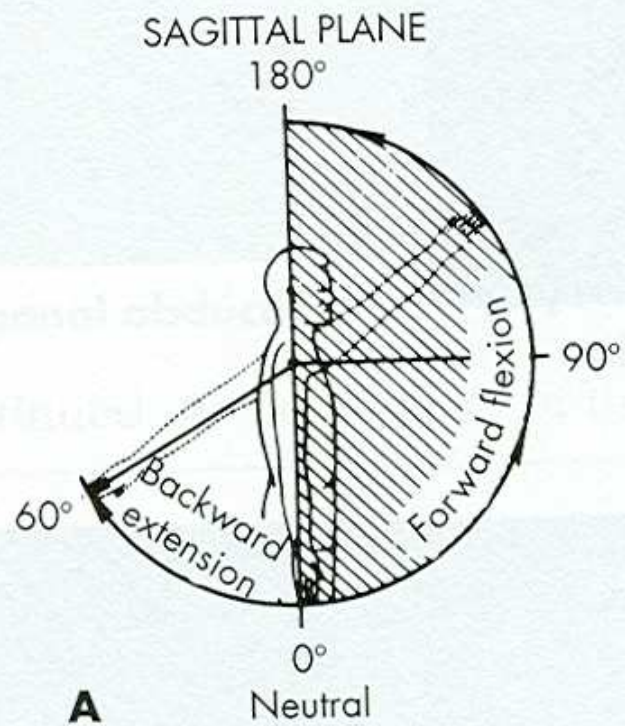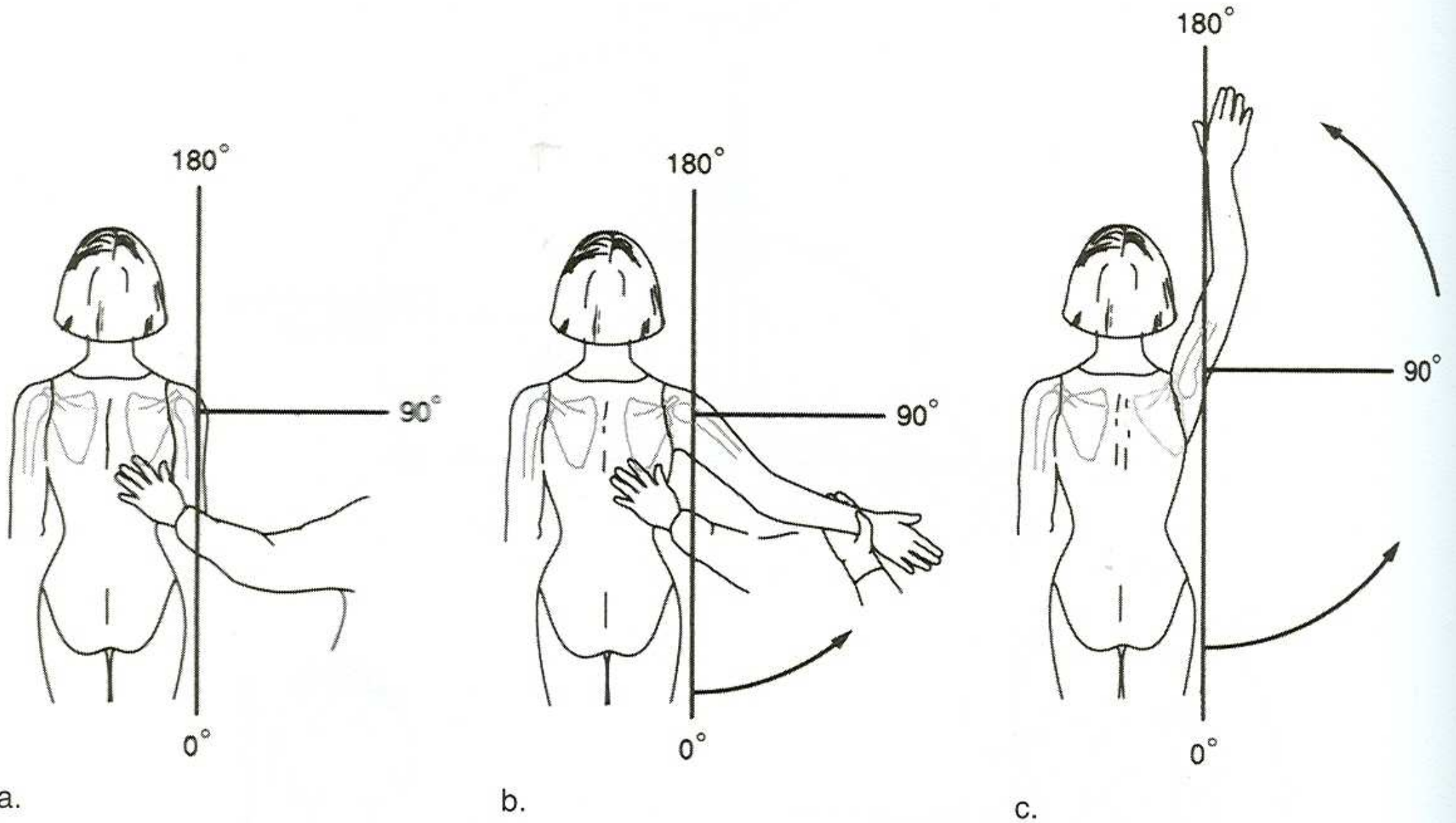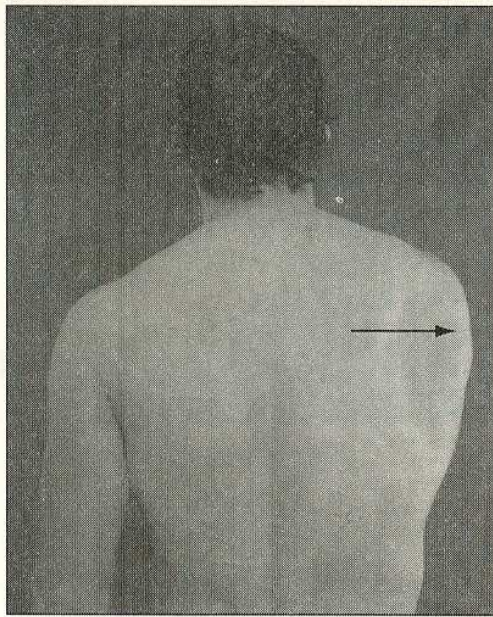
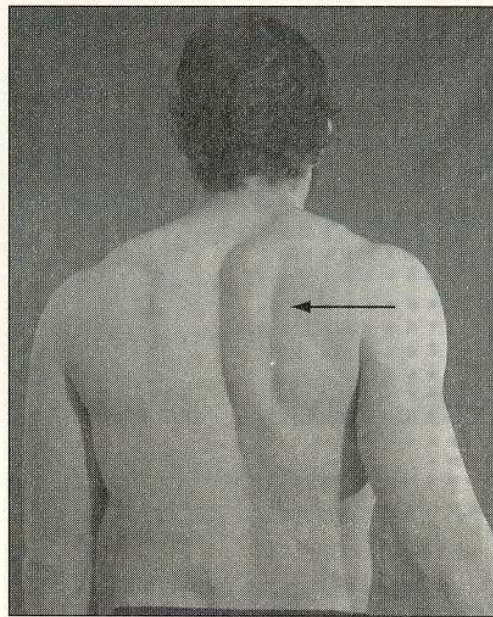


**Figure C.6** Range of shoulder joint (glenohumeral) motion: (a) starting position; (b) abduction; (c) sideward-upward elevation of arm (combining abduction of arm and upward rotation of scapula).



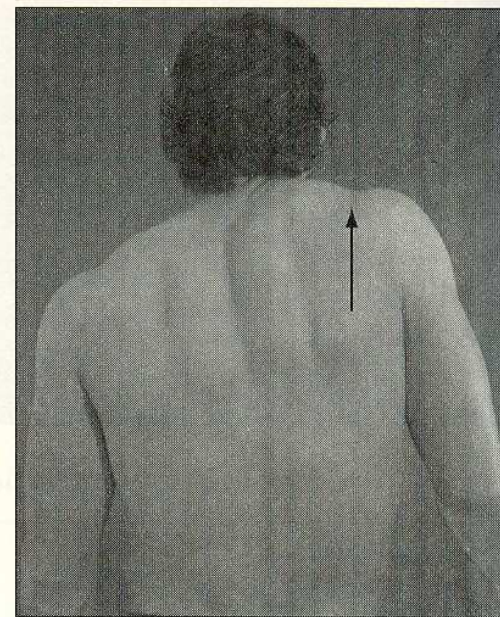
**Abduction**  
(protraction)

**A**



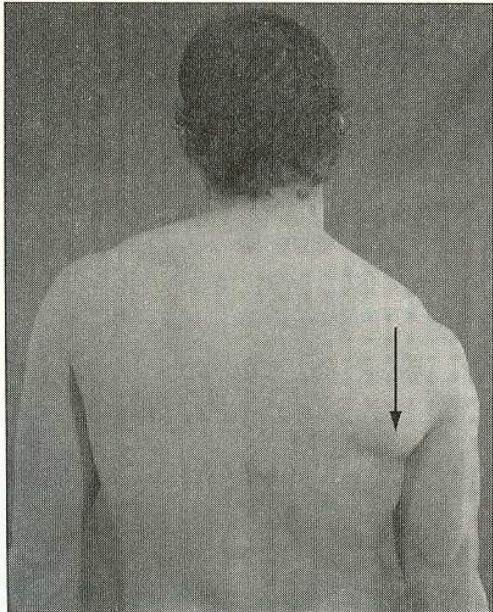
**Adduction**  
(retraction)

**B**

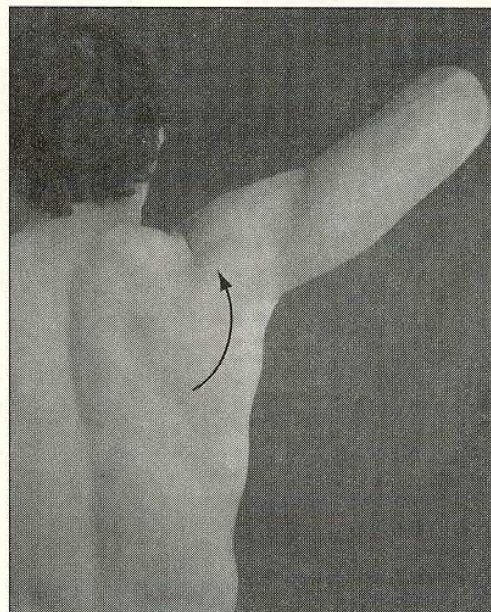


**Elevation**

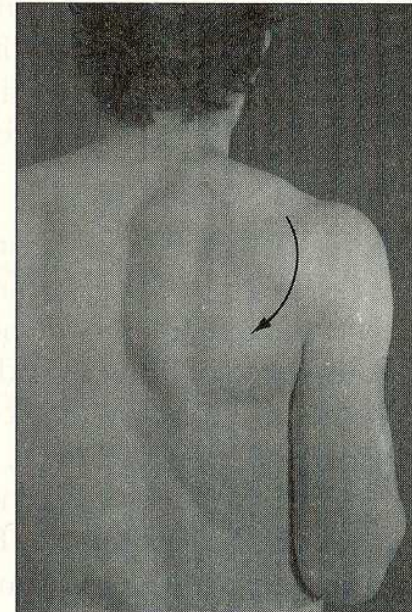
**C**



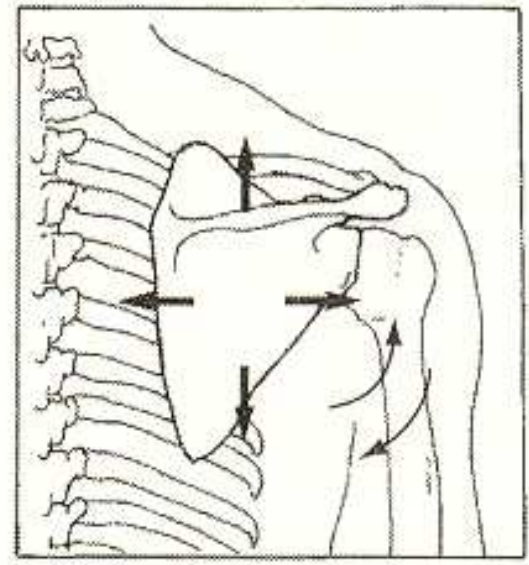
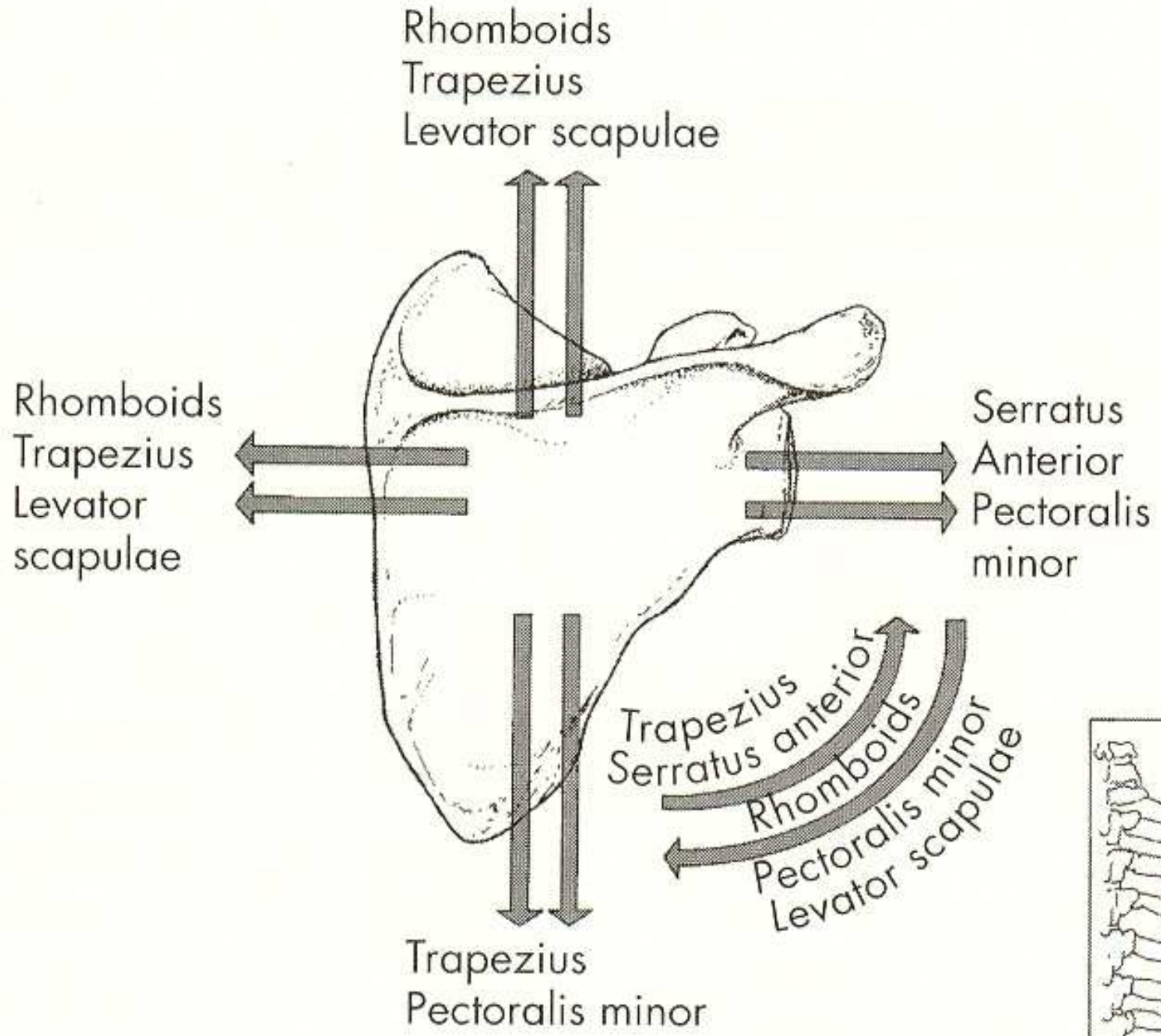
**Depression**

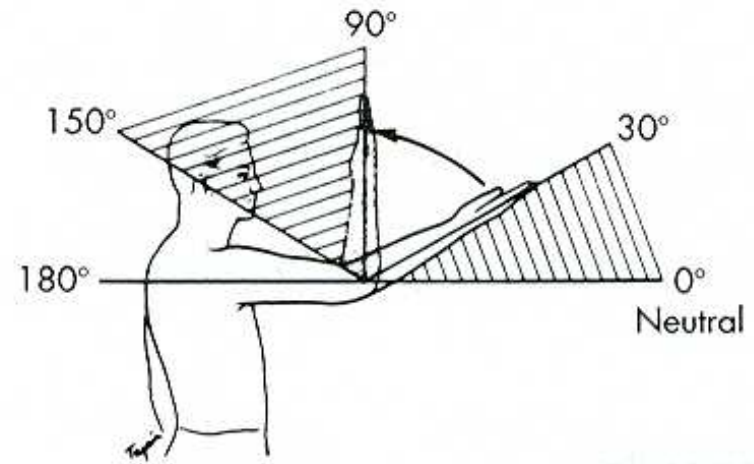
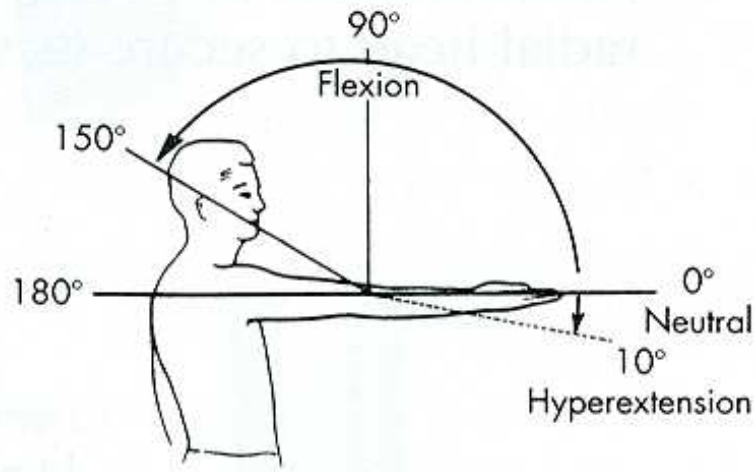


**Upward rotation**

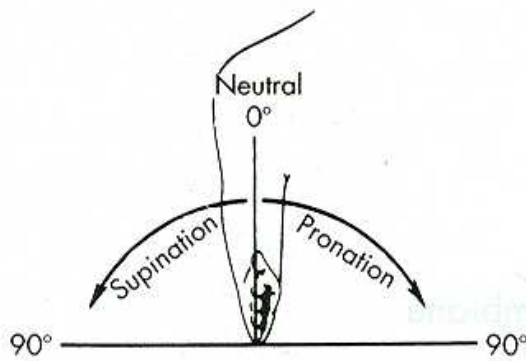


**Downward rotation**

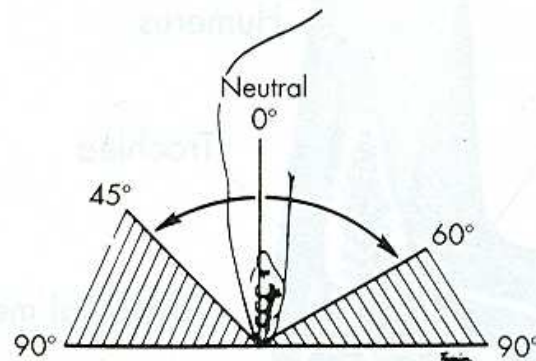




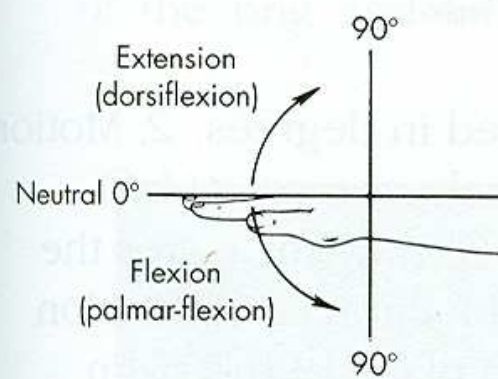
**B**



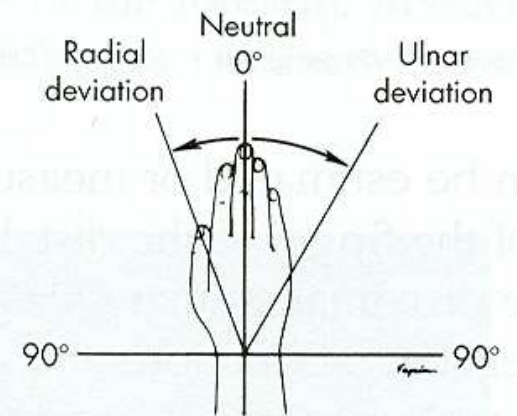
**A**



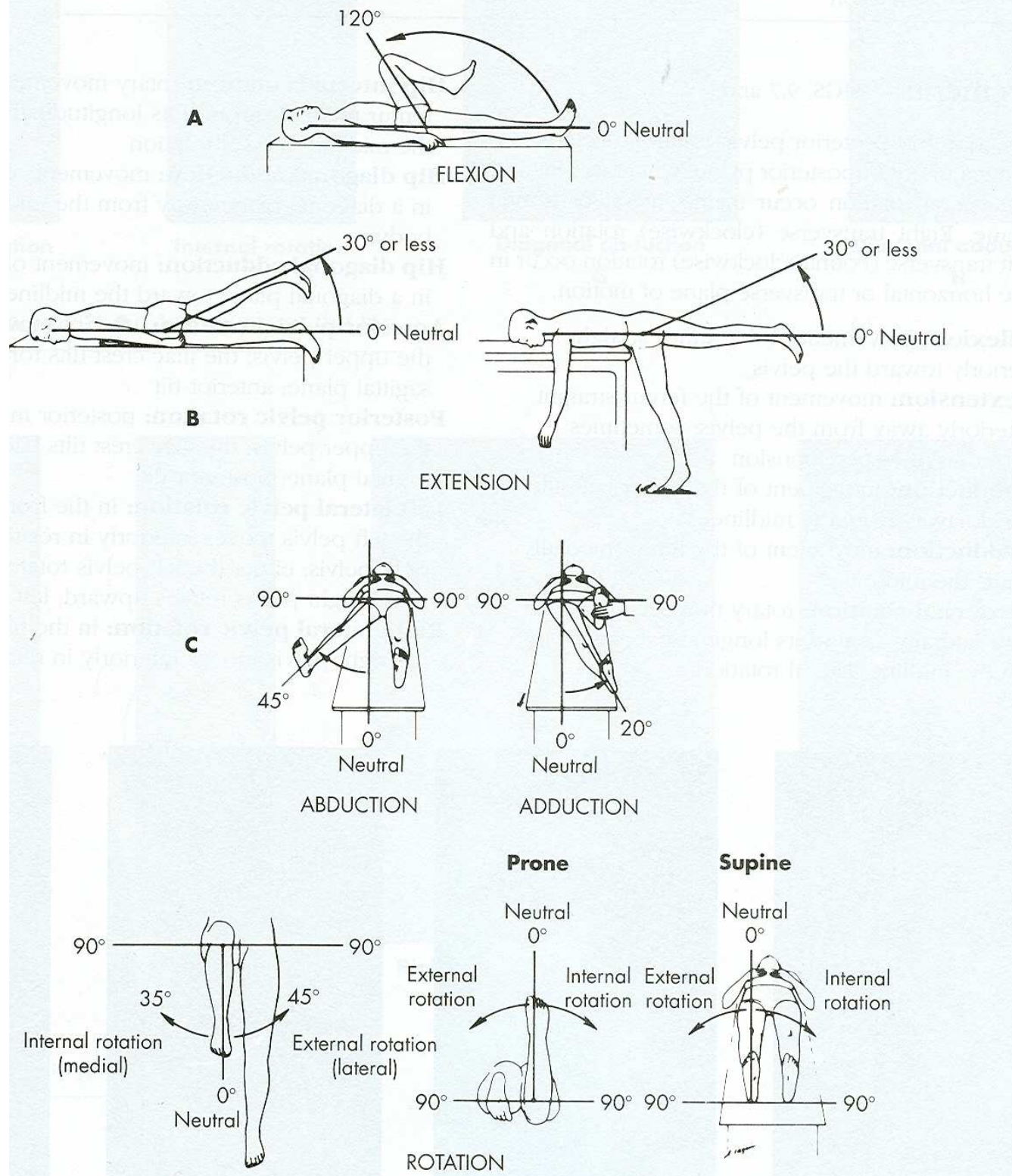
**B**

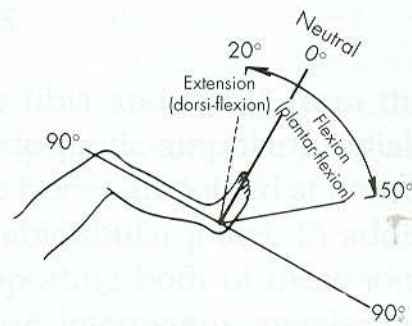
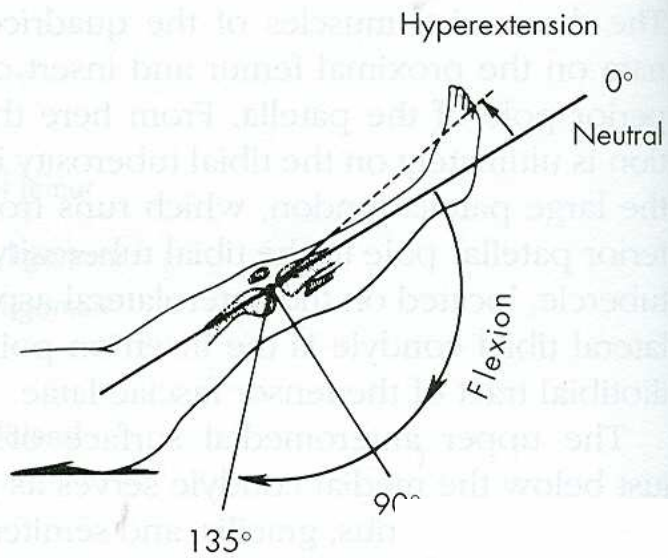


**A**



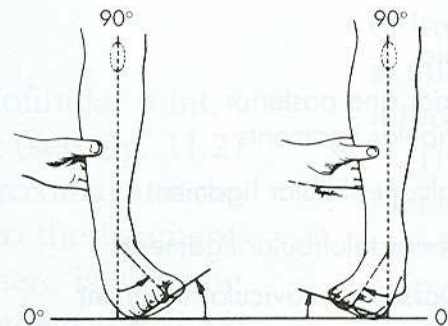
**B**





Ankle joint

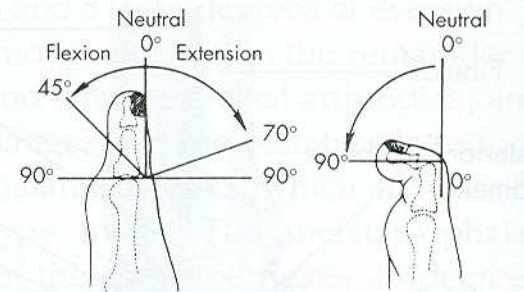
**A**



Inversion

Eversion

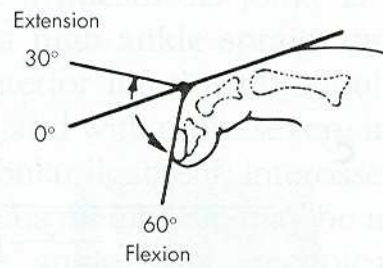
**B**



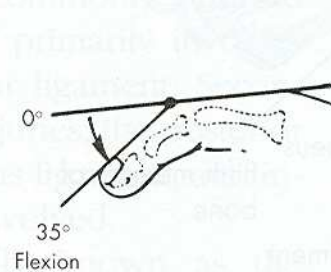
Metatarsophalangeal joint

Interphalangeal joint

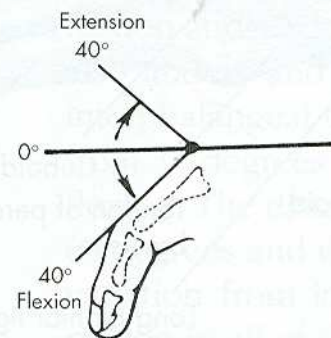
**C**



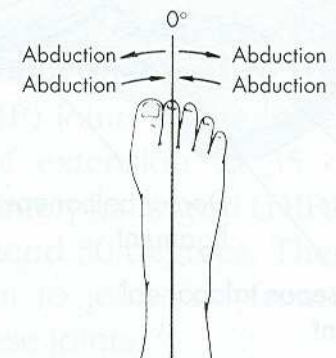
Distal interphalangeal joint



Proximal interphalangeal joint



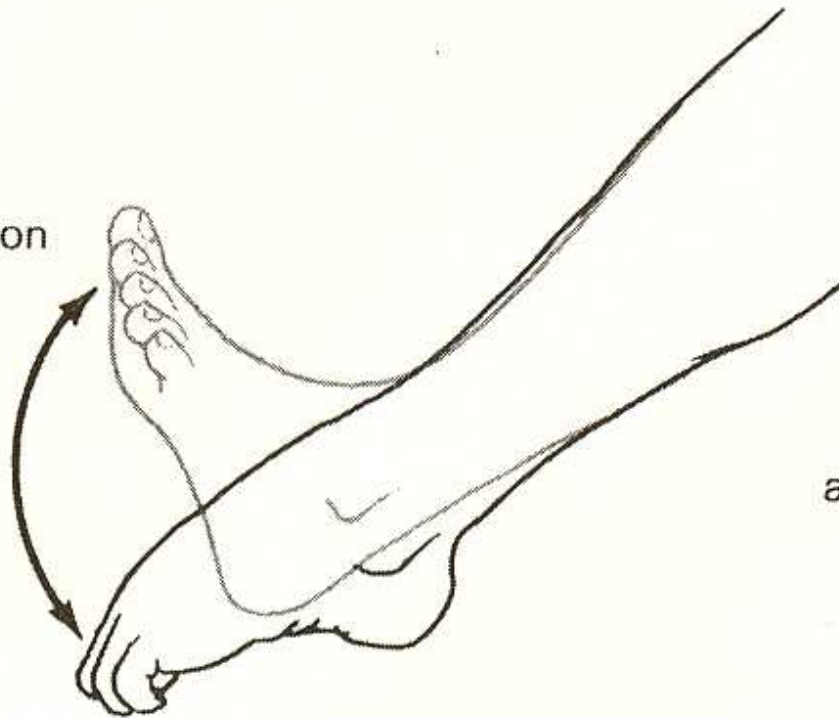Metatarsophalangeal joint



Toe spread

**D**

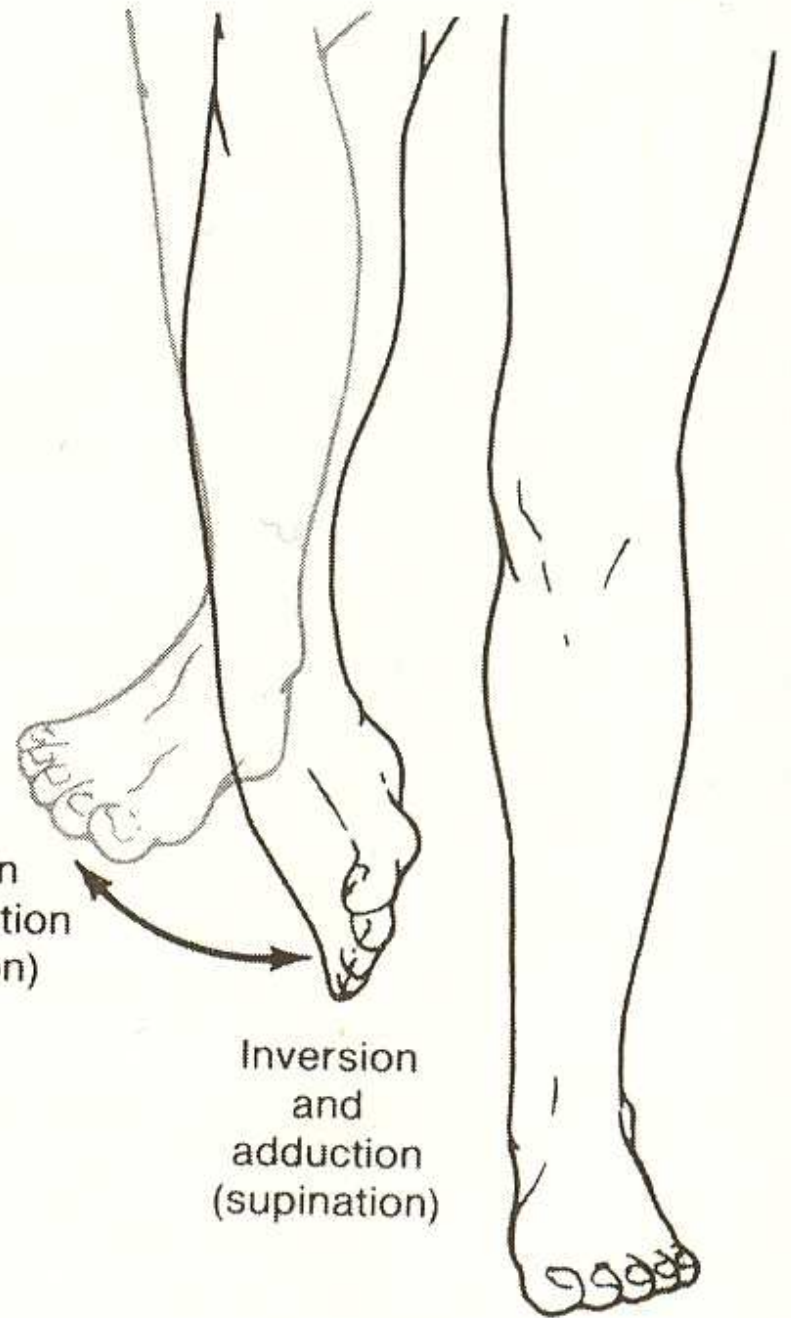
Dorsiflexion



Plantar flexion

a.

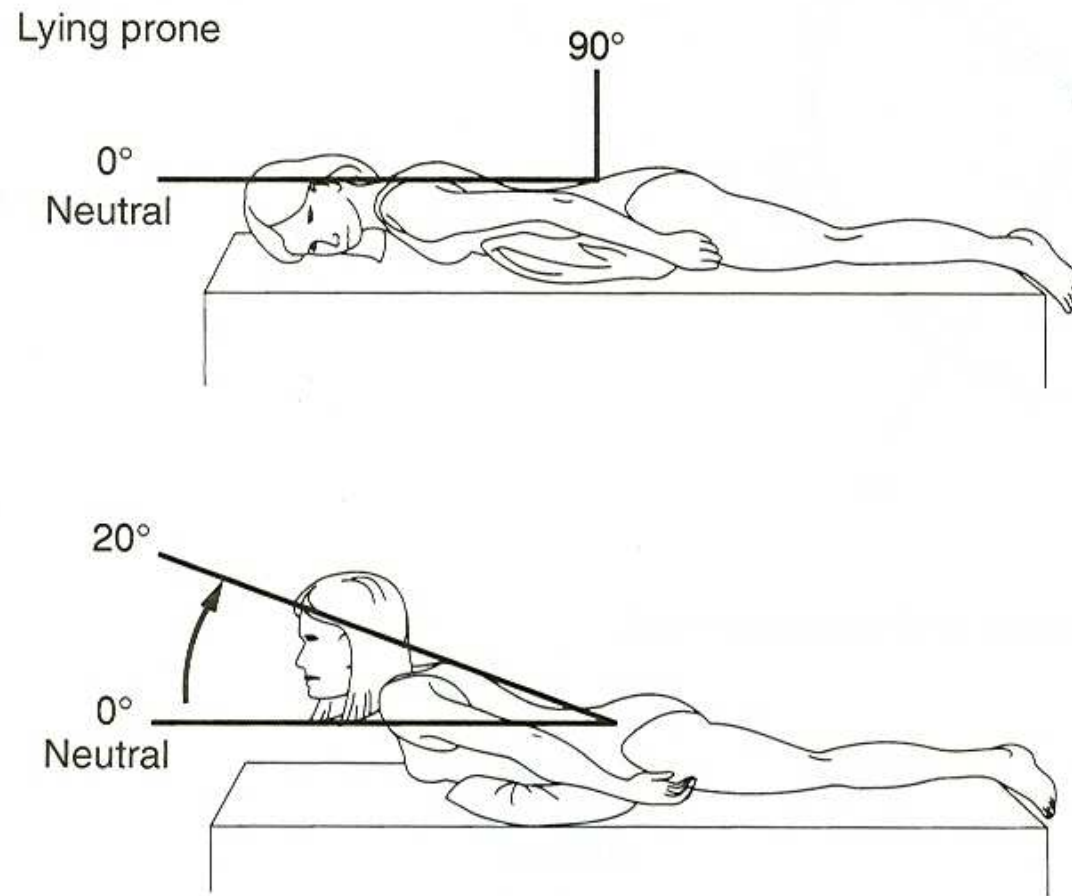
Eversion  
and abduction  
(pronation)



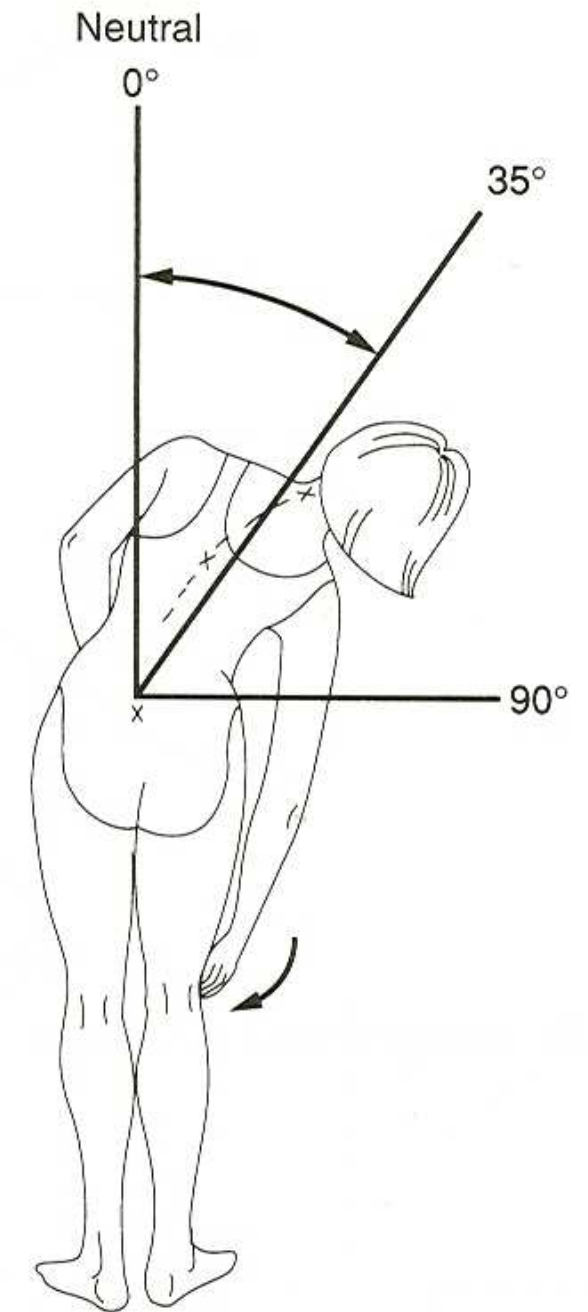
Inversion  
and  
adduction  
(supination)

b.





a.



b.

**Figure C.11** Range of motion in the thoracic and lumbar spine: (a) hyperextension; (b) lateral flexion.