

# POHYBY HORNÍCH KONČETIN



# POHYBY RAMENNÍHO KLOUBU

FLEXE - PŘEDPAŽENÍ

EXTENZE - ZAPAŽENÍ

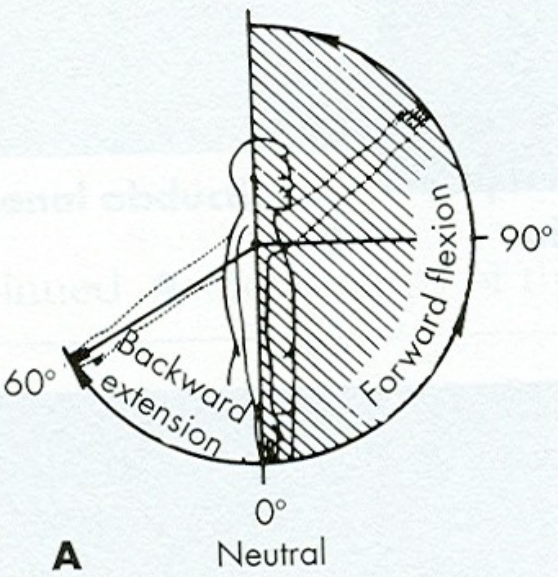
ABDUKCE - UPAŽENÍ

ADDUKCE - PŘIPAŽENÍ

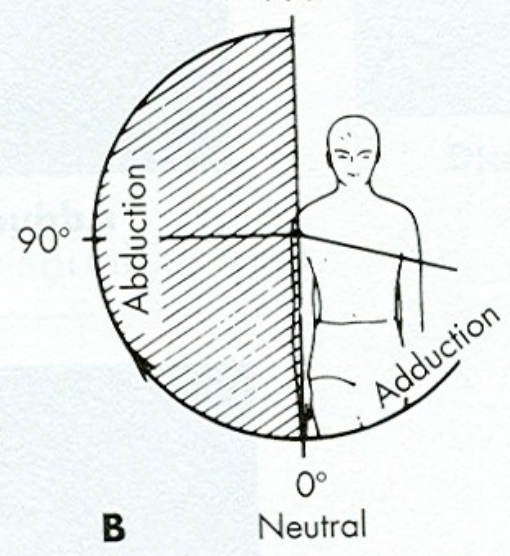
VNITŘNÍ ROTACE

VNĚJŠÍ ROTACE

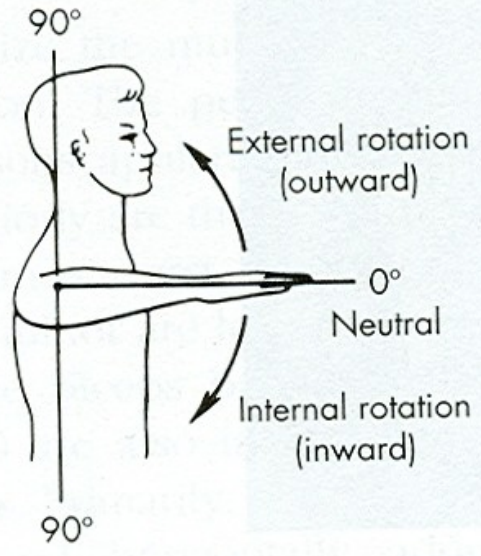
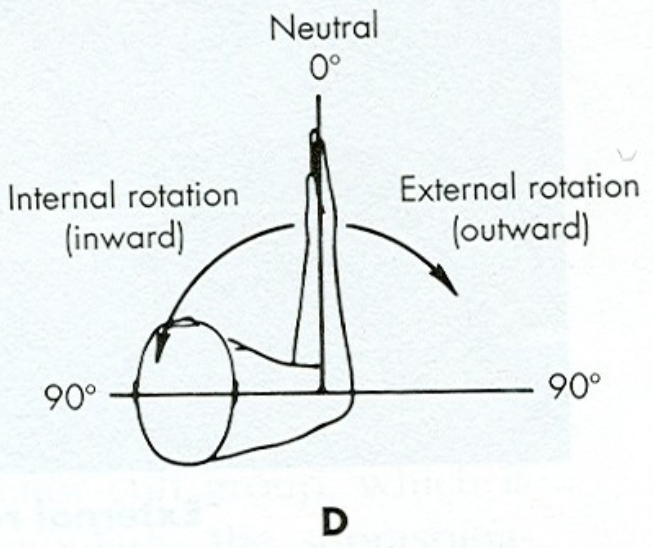
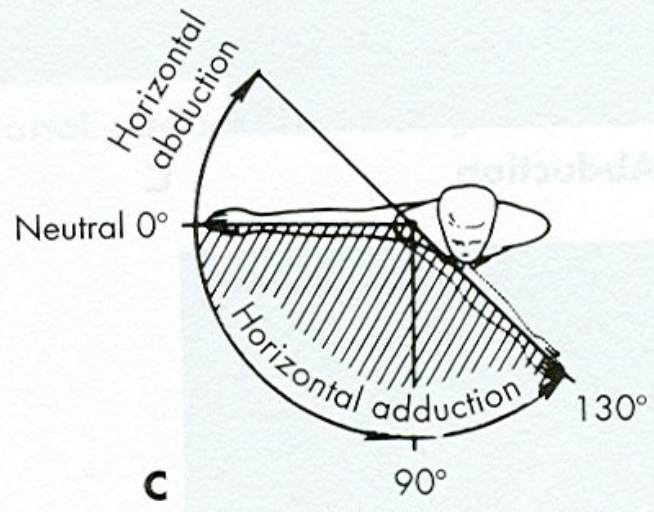
SAGITTAL PLANE  
180°



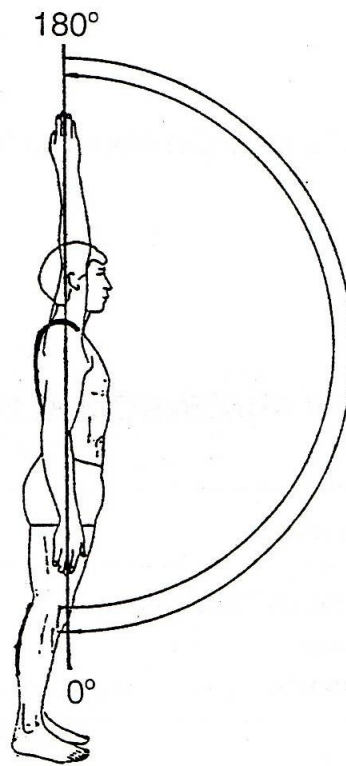
FRONTAL PLANE  
180°



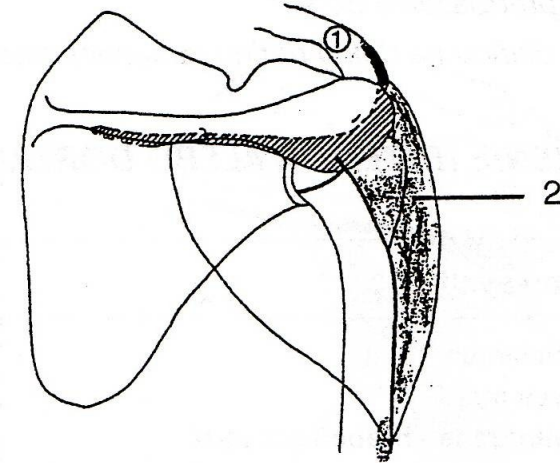
HORIZONTAL PLANE  
180°



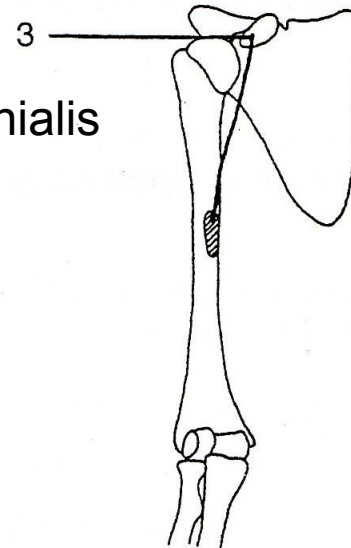
# FLEXE - PŘEDPAŽENÍ



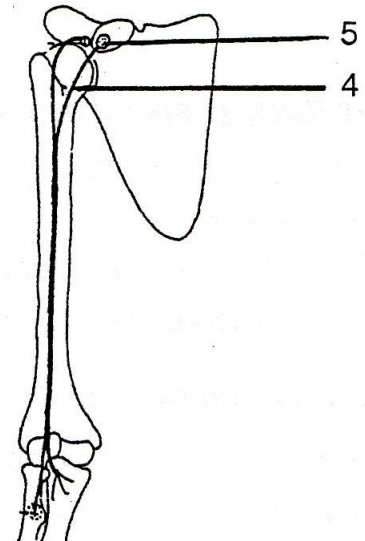
m. deltoideus  
(pars clavicularis)



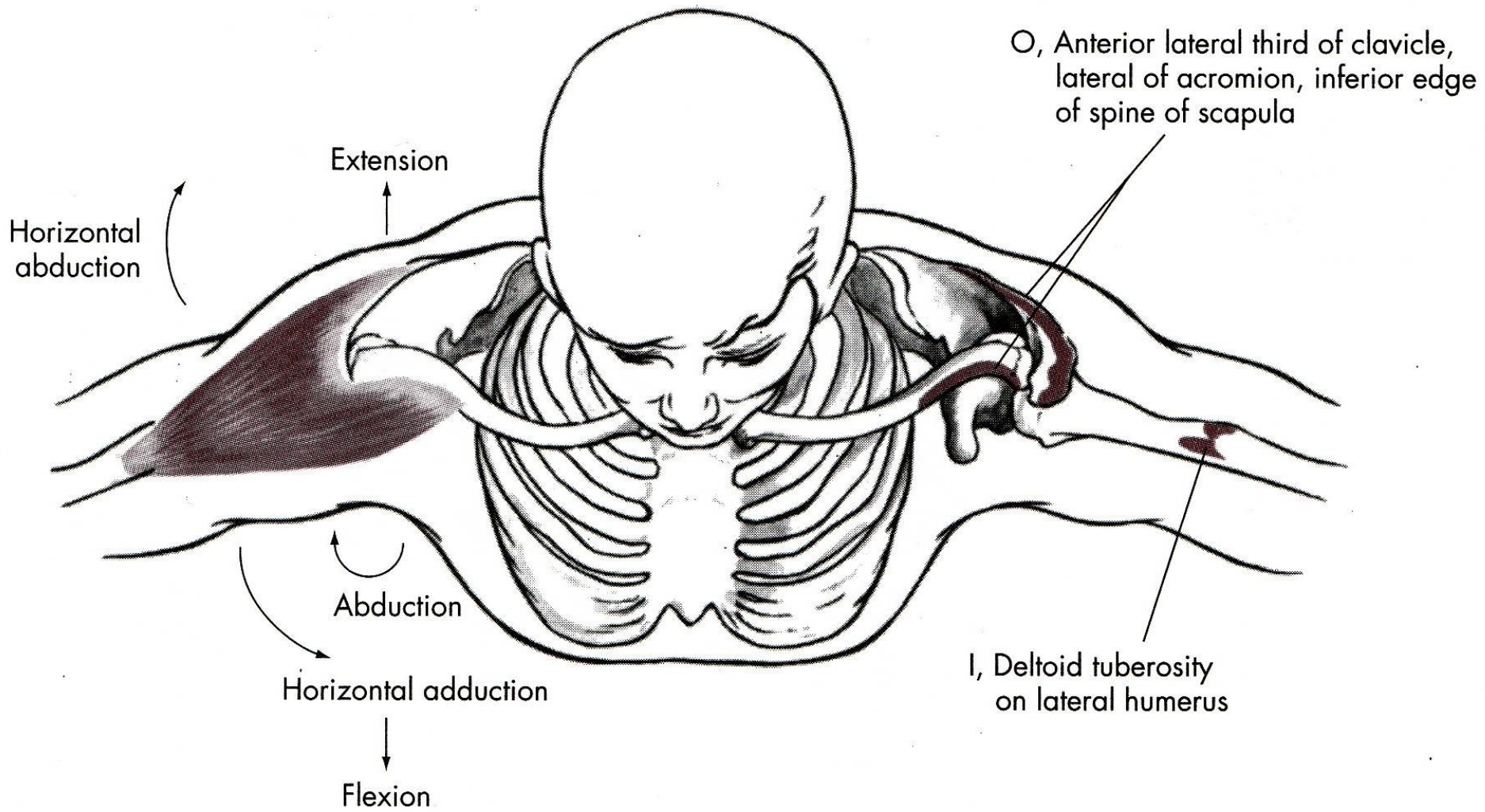
m. coracobrachialis

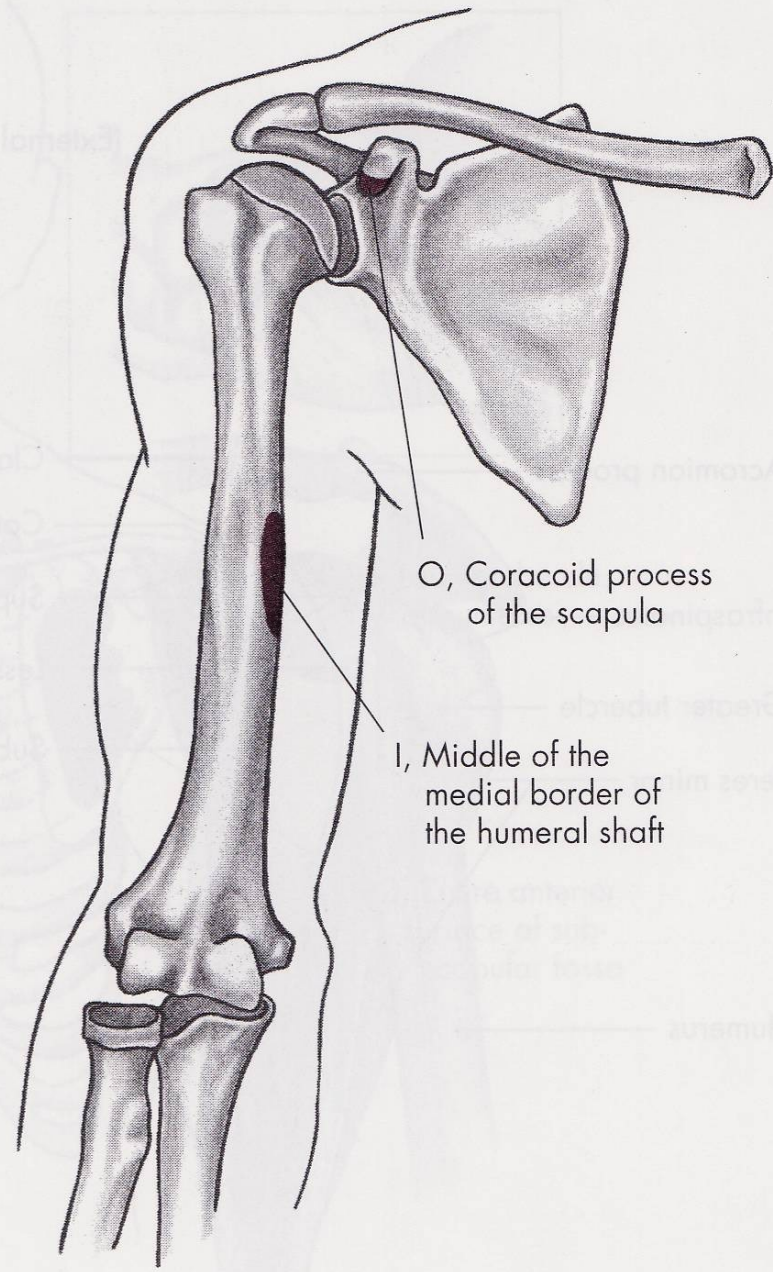
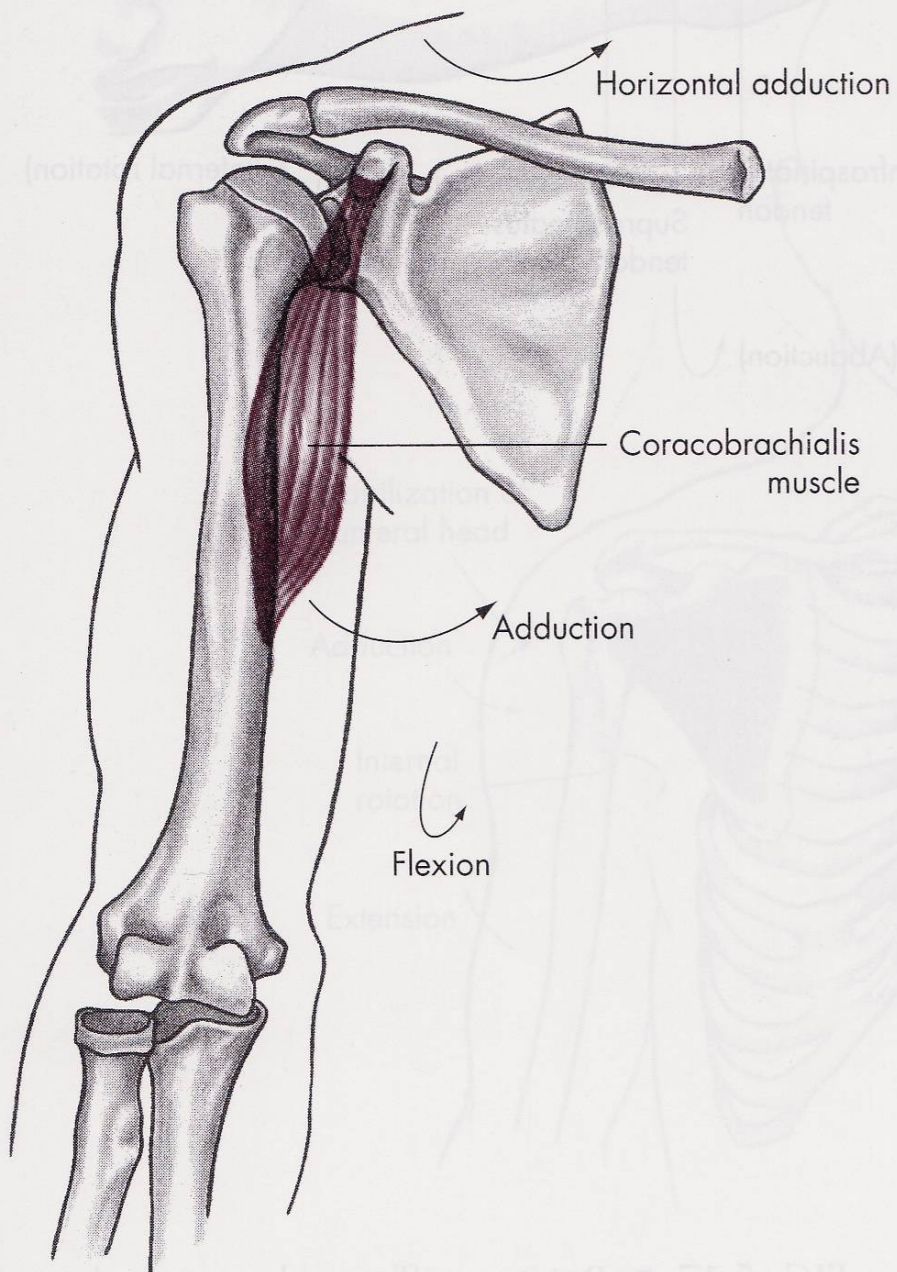


m. biceps brachii









# FLEXE

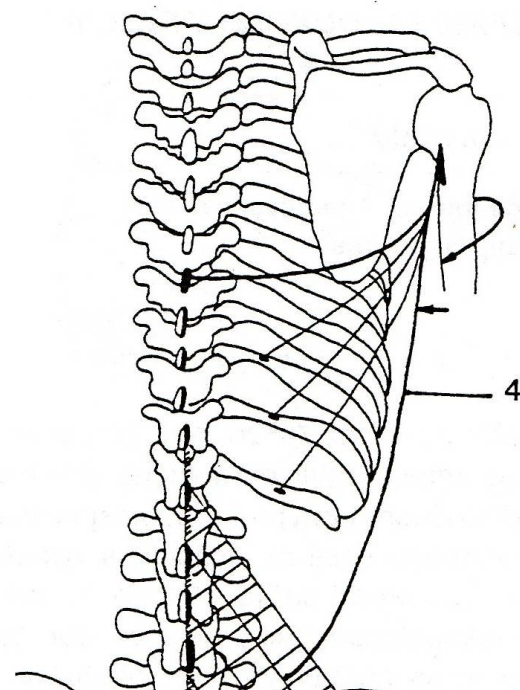
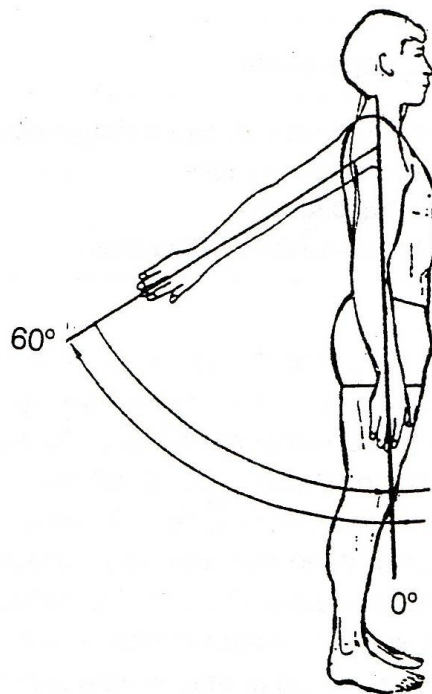
m. deltoideus-pars clavicularis  
– sval deltový-kliční část

m. coracobrachialis – vnitřní sval pažní

m. biceps brachii-caput breve –  
dvojhlavý sval pažní-krátká hlava

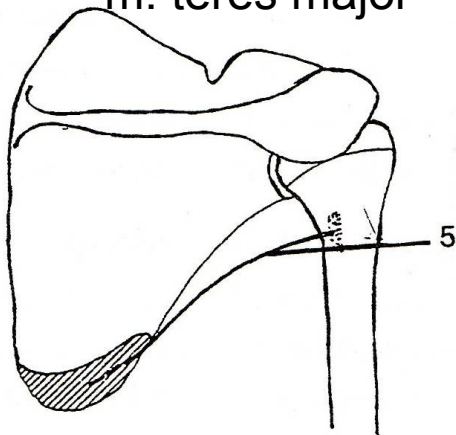


# EXTENZE - ZAPAŽENÍ

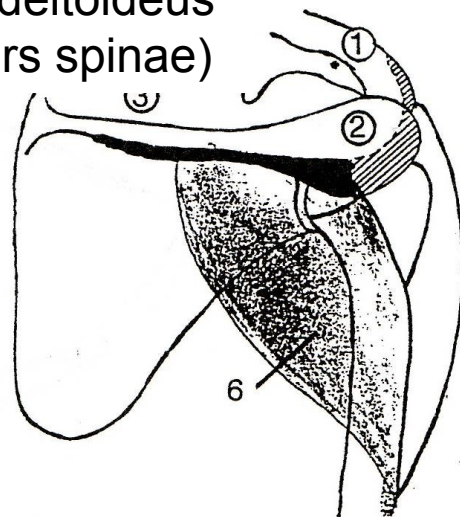


m. latissimus dorsi

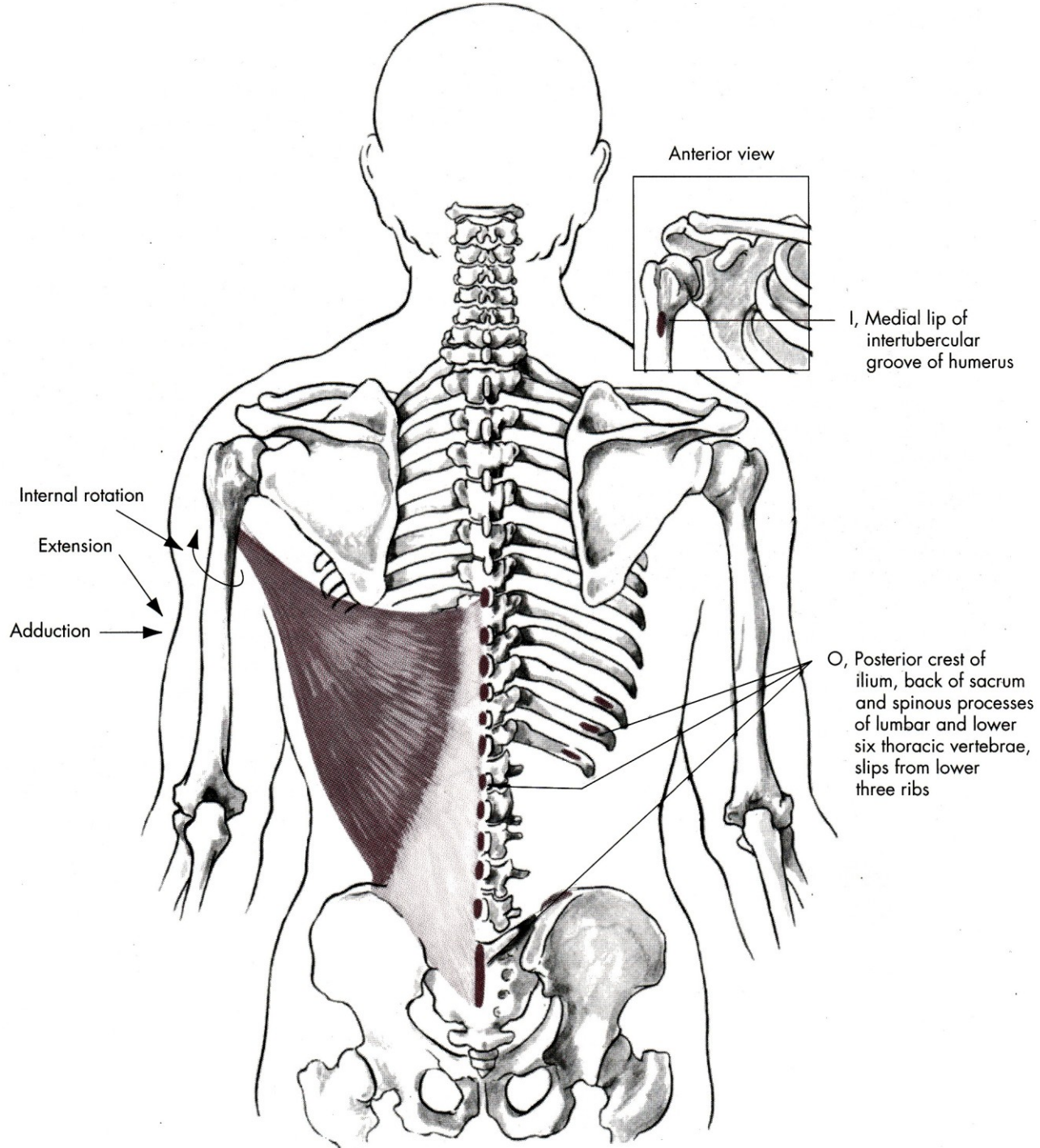
m. teres major



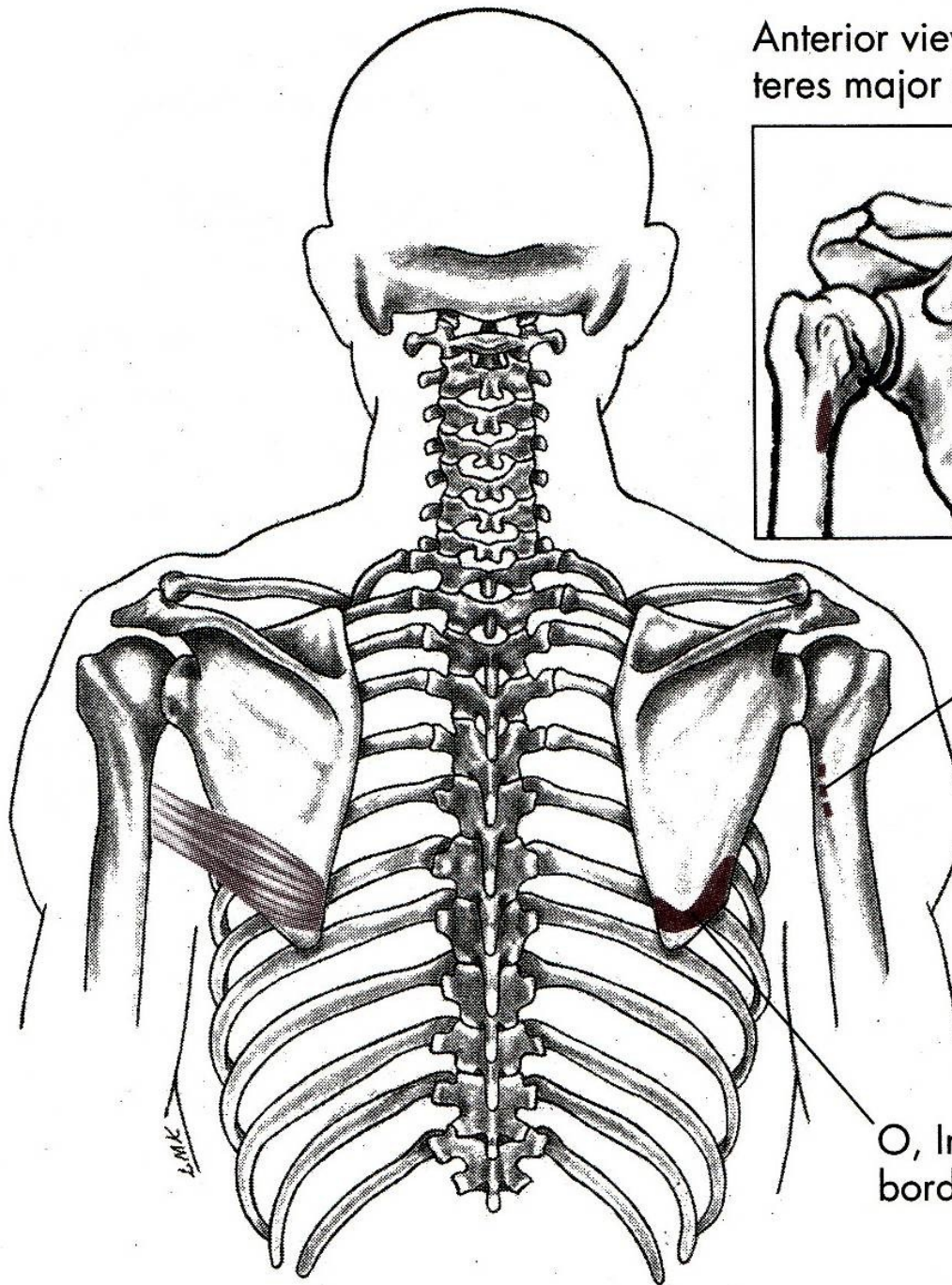
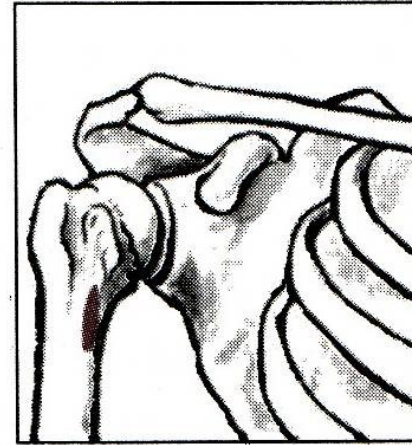
m. deltoideus  
(pars spinae)







Anterior view with  
teres major insertion



I, Medial lip of the  
intertubercular groo  
of the humerus

O, Inferior third of lateral  
border of scapula

L.M.K.

# EXTENZE

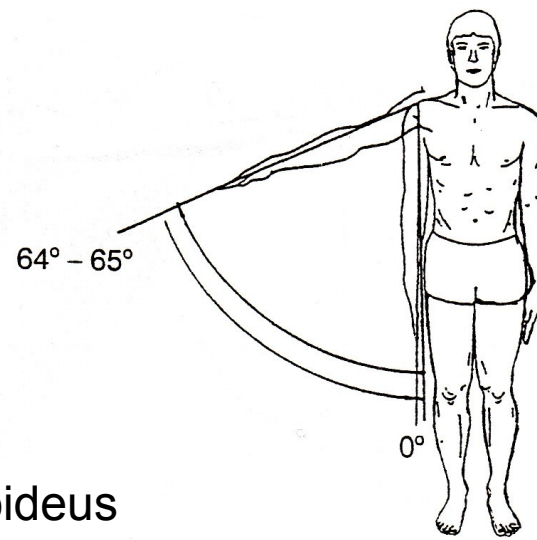
m. deltoideus-pars spinae  
– sval deltový-spinální část

m. latissimus dorsi – široký sval zádový

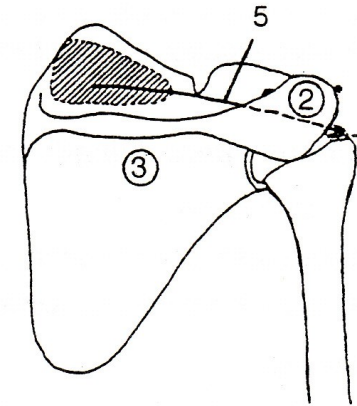
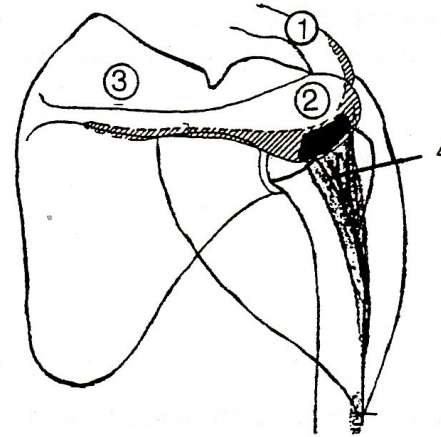
m. teres major – velký sval oblý



# ABDUKCE - UPAŽENÍ

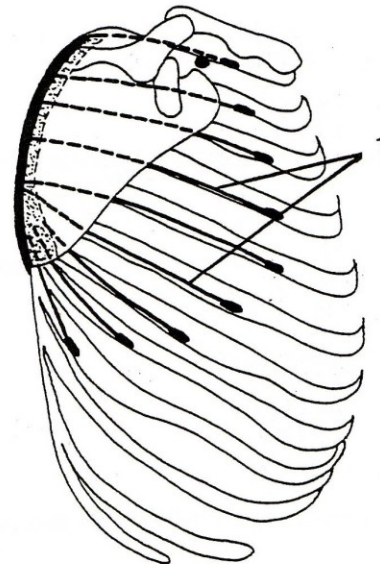
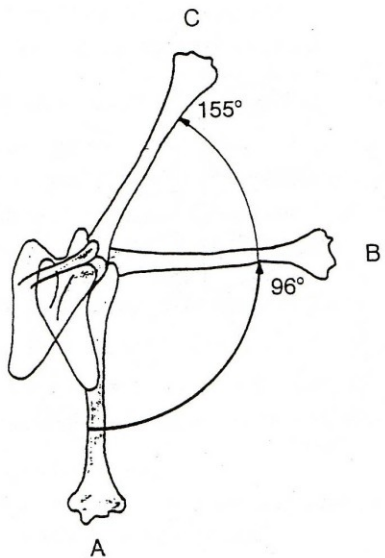


m. deltoideus  
(pars akromialis)

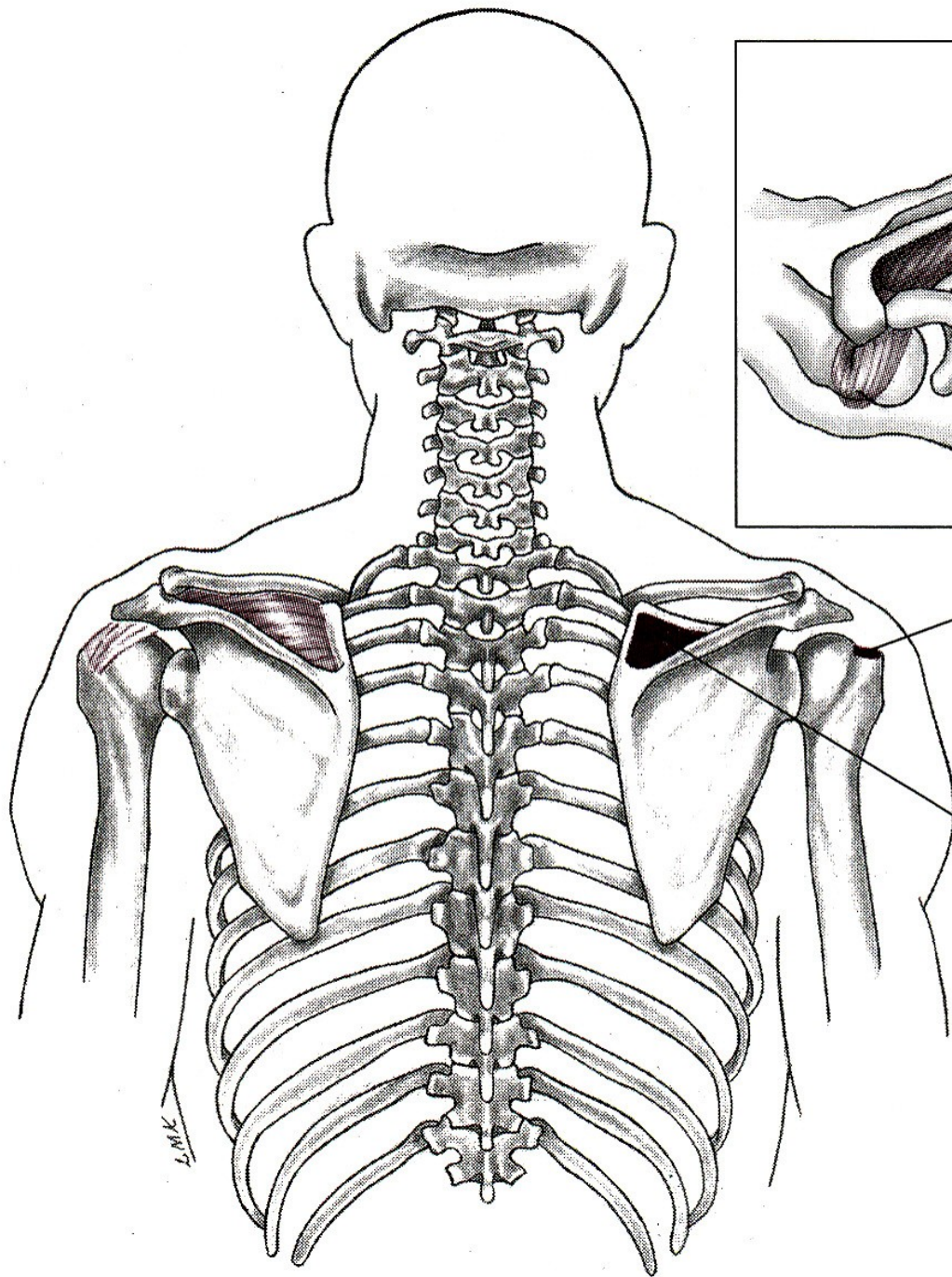


m. supraspinatus

m. serratus anterior





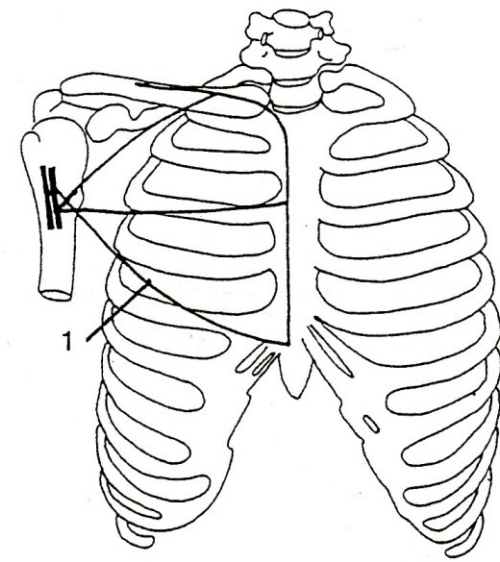
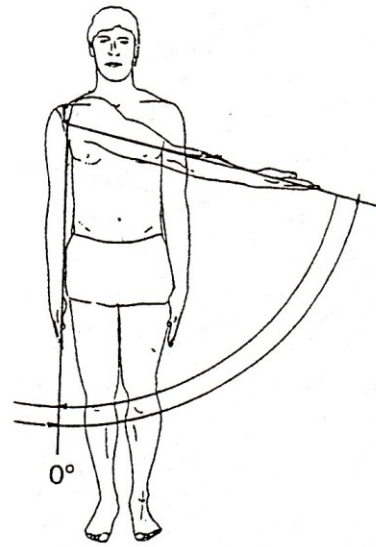


I, Superiorly on greater tubercle of humerus

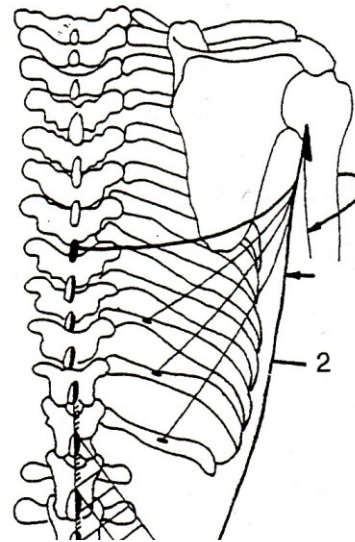
O, Medial two-thirds of supraspinatus fossa

L.M.K.

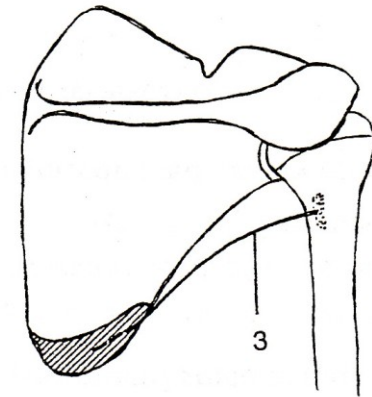
# ADDUKCE - PŘIPAŽENÍ



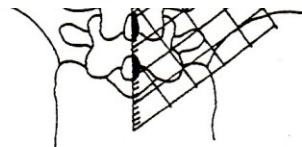
m. pectoralis major



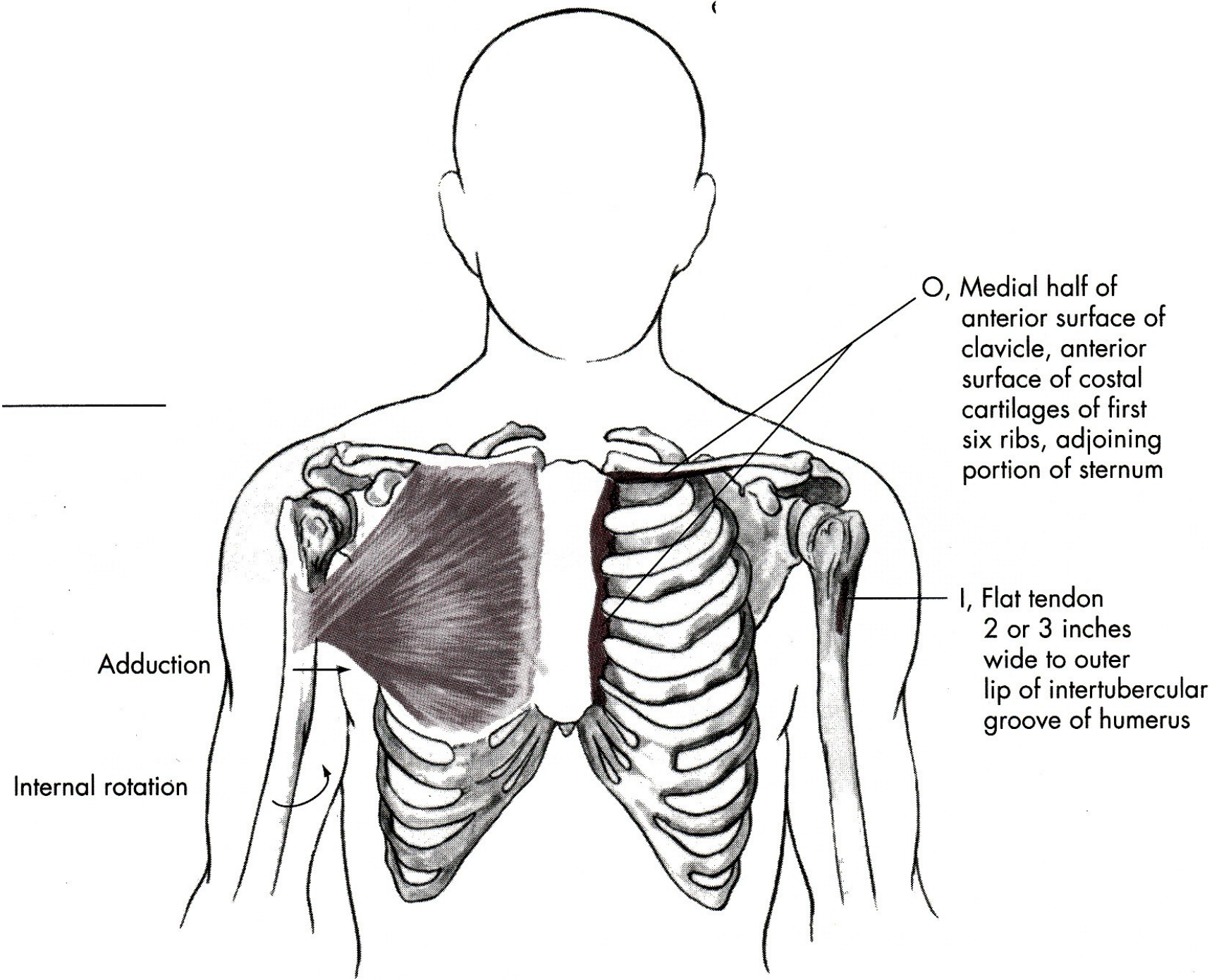
m. latissimus dorsi



m. teres major







Adduction

Internal rotation

O, Medial half of anterior surface of clavicle, anterior surface of costal cartilages of first six ribs, adjoining portion of sternum

I, Flat tendon 2 or 3 inches wide to outer lip of intertubercular groove of humerus

# ABDUKCE

m. deltoideus-pars akromion  
– sval deltový-akromiální část

m. supraspinatus – sval nadhřebenový

# ADDUKCE

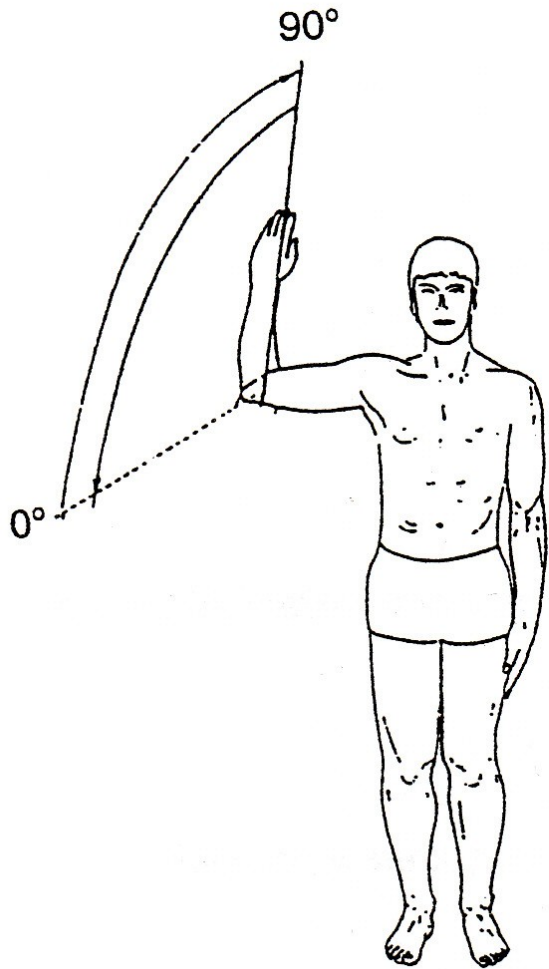
m. pectoralis major – velký sval prsní

m. latissimus dorsi – široký sval zádový

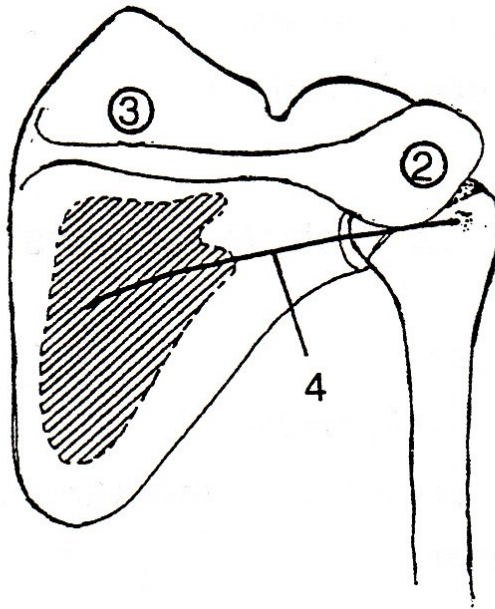
m. teres major – velký sval oblý



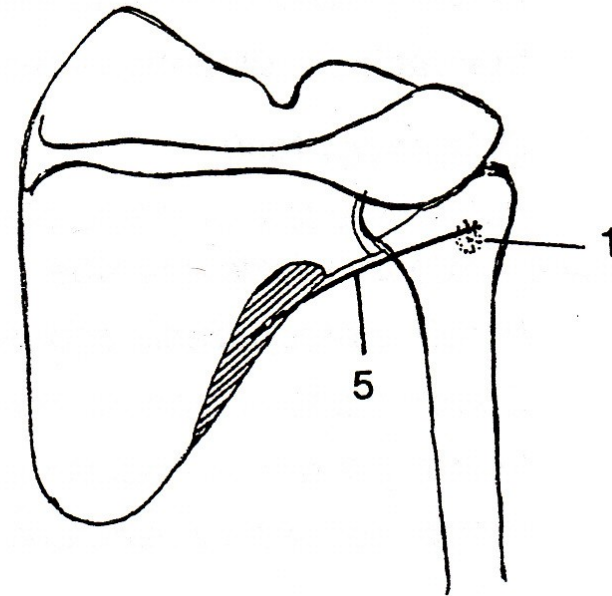
# VNĚJŠÍ ROTACE



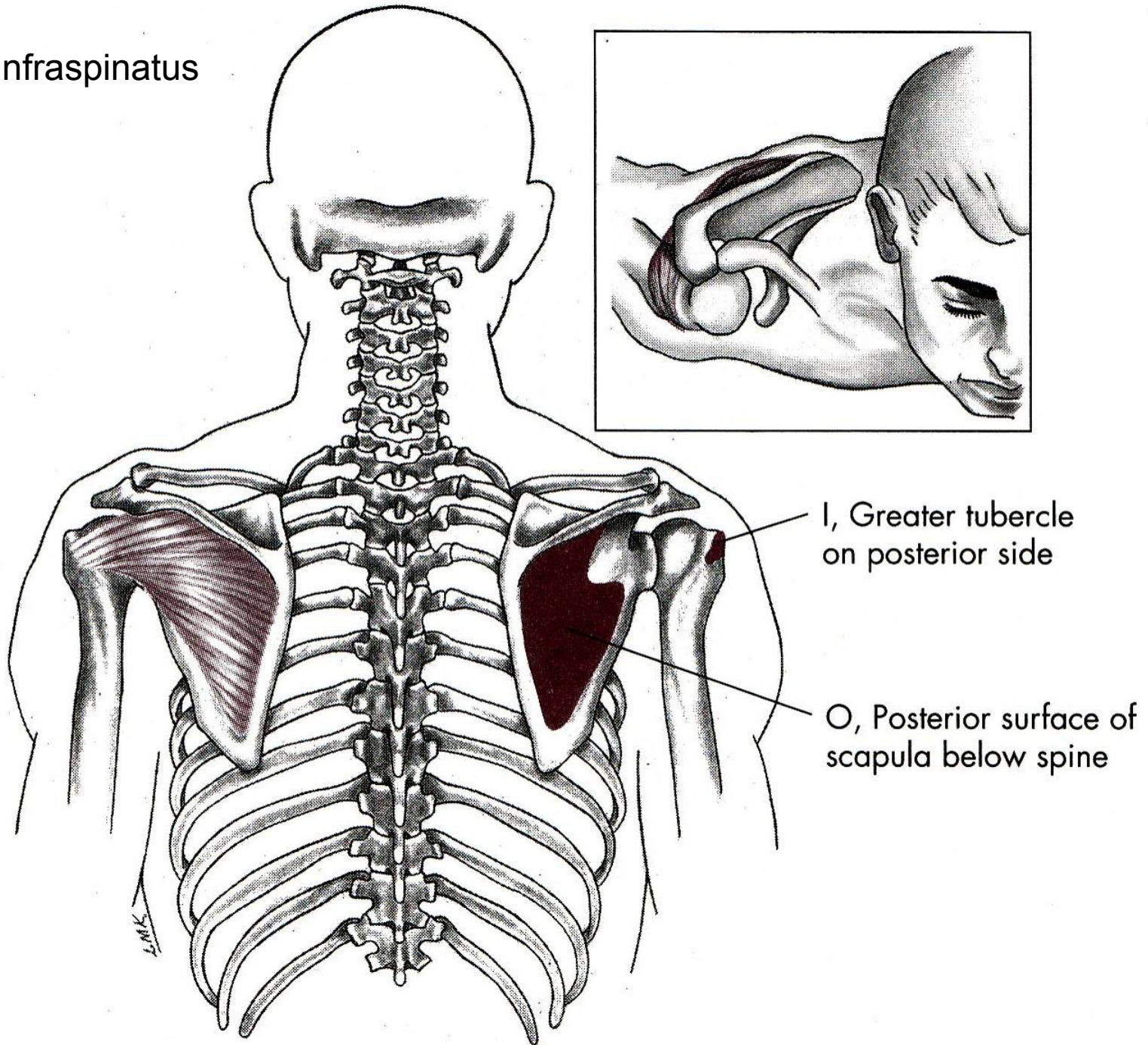
m. infraspinatus



m. teres minor

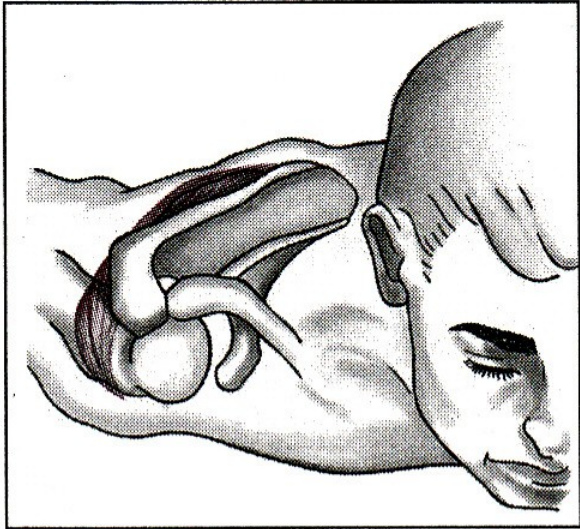
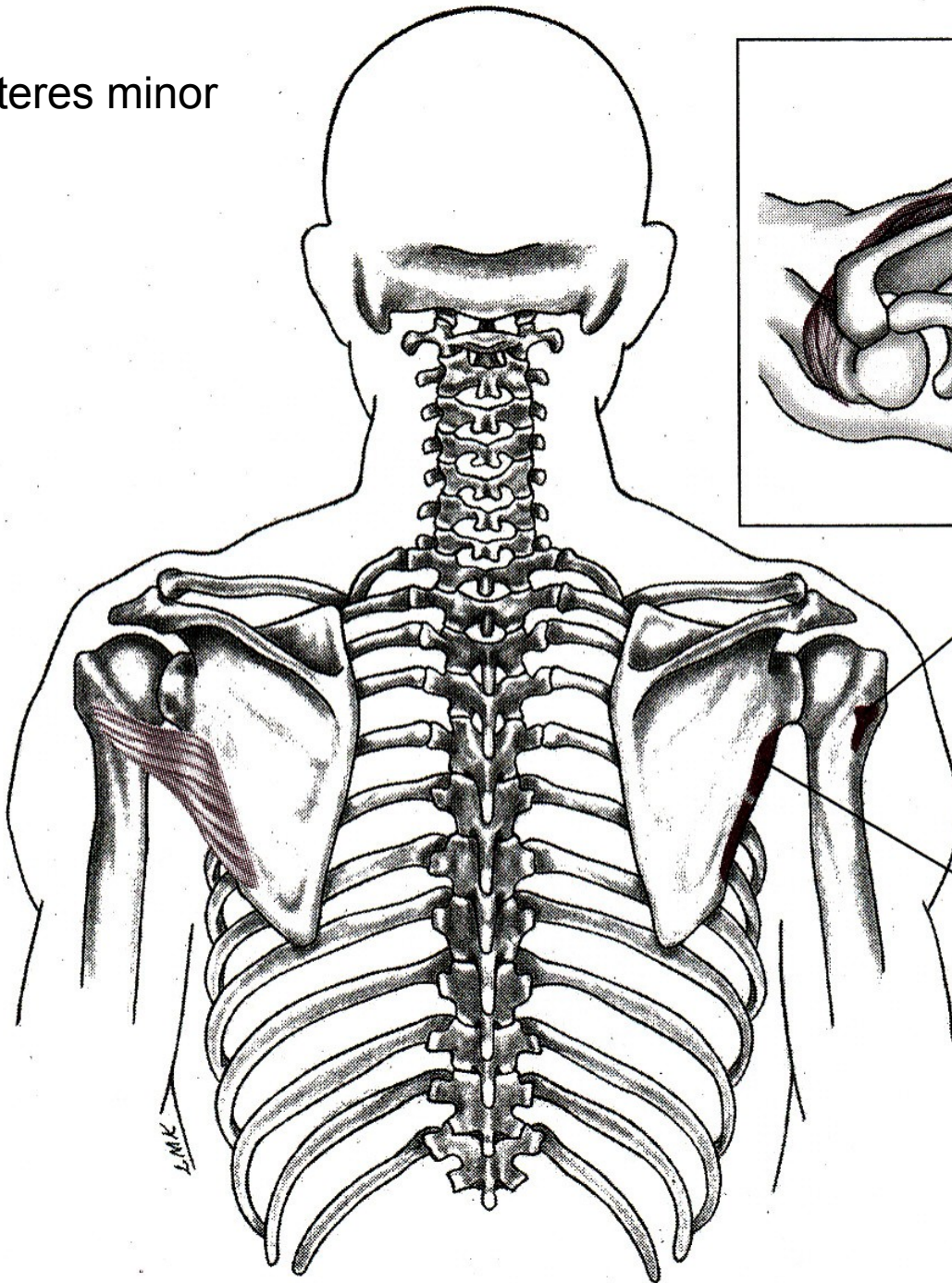


m. infraspinatus





m. teres minor

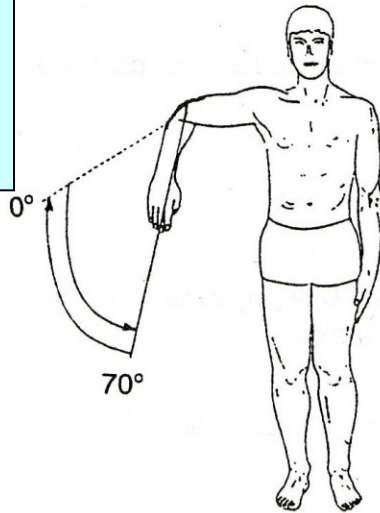


I, Greater tubercle  
of humerus on  
posterior side

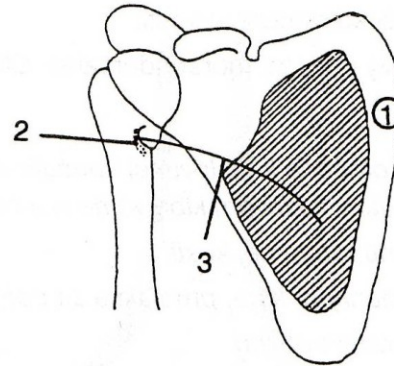
O, Posterior scapula,  
lateral border

L.M.K.

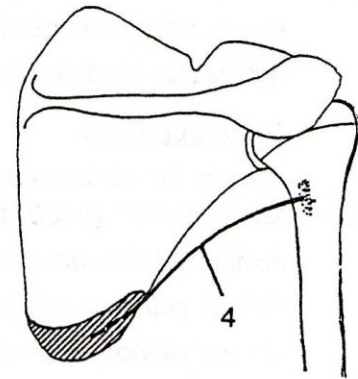
# VNITŘNÍ ROTACE



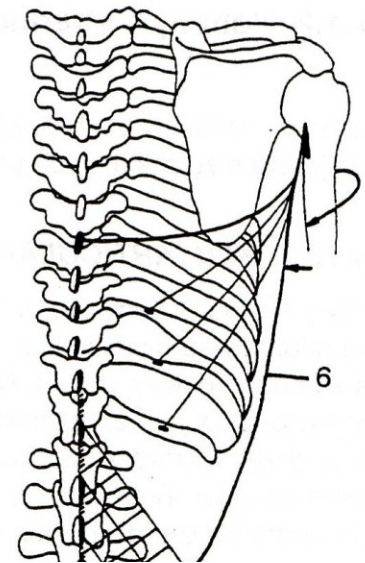
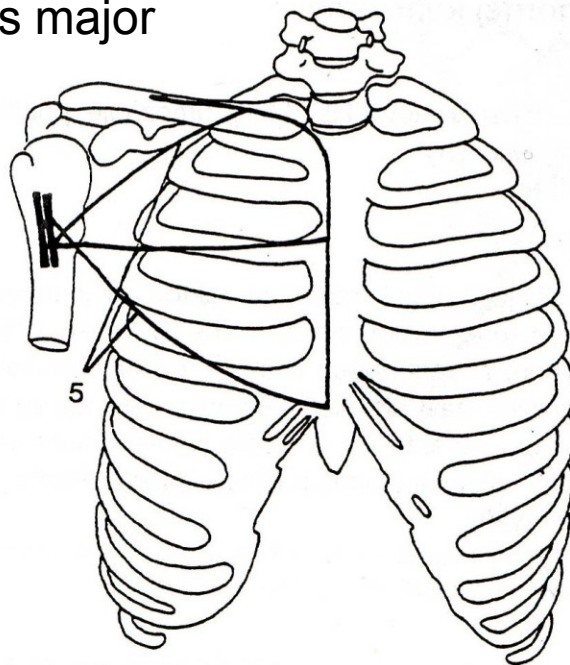
m. subscapularis



m. teres major



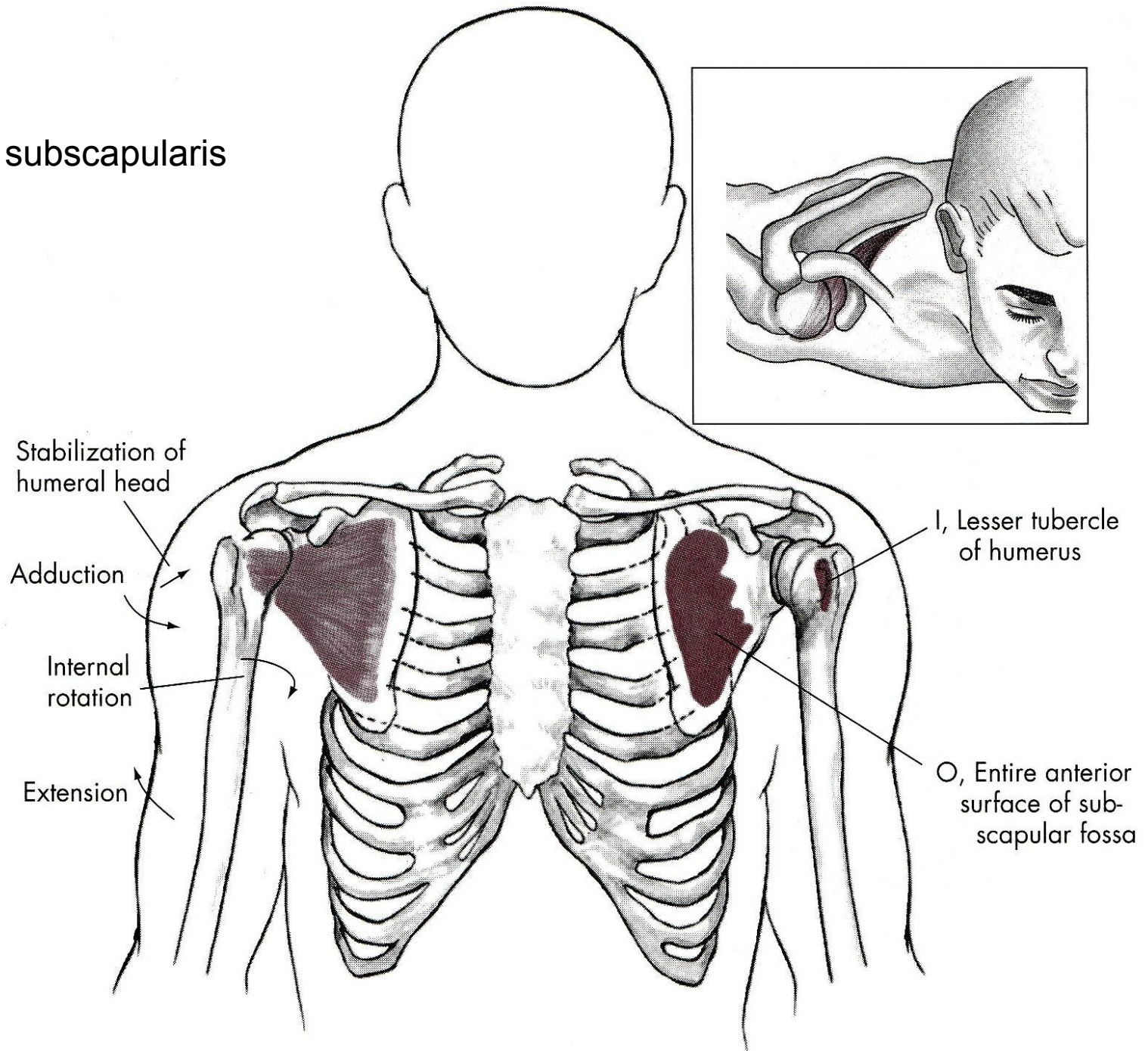
m. pectoralis major



m. latissimus dorsi



# m. subscapularis



Stabilization of humeral head

Adduction

Internal rotation

Extension

I, Lesser tubercle of humerus

O, Entire anterior surface of subscapular fossa

# VNĚJŠÍ ROTACE

m. infraspinatus – sval podhřebenový

m. teres minor – malý sval oblý

# VNITŘNÍ ROTACE

m. subscapularis – sval podlopatkový

m. teres major – velký sval oblý

m. pectoralis major – velký sval prsní

m. latissimus dorsi – široký sval zádový

# POHYBY LOKETNÍHO KLOUBU

FLEXE

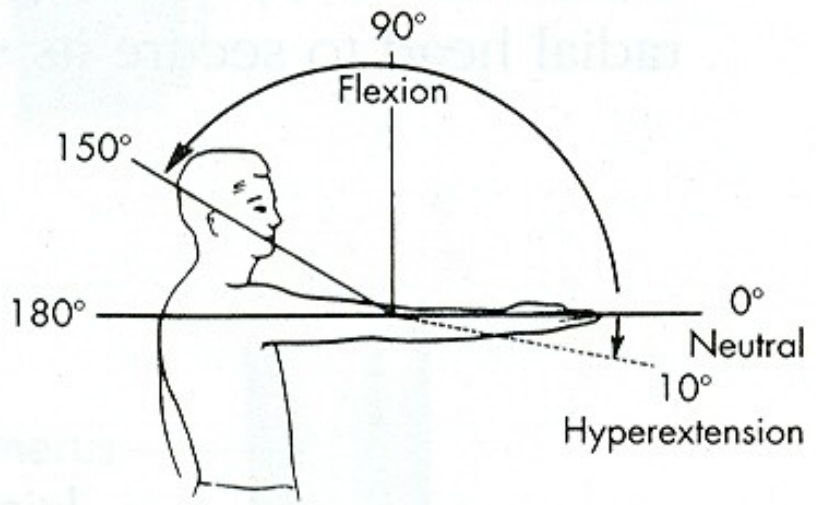
EXTENZE

# POHYBY PŘEDLOKTÍ

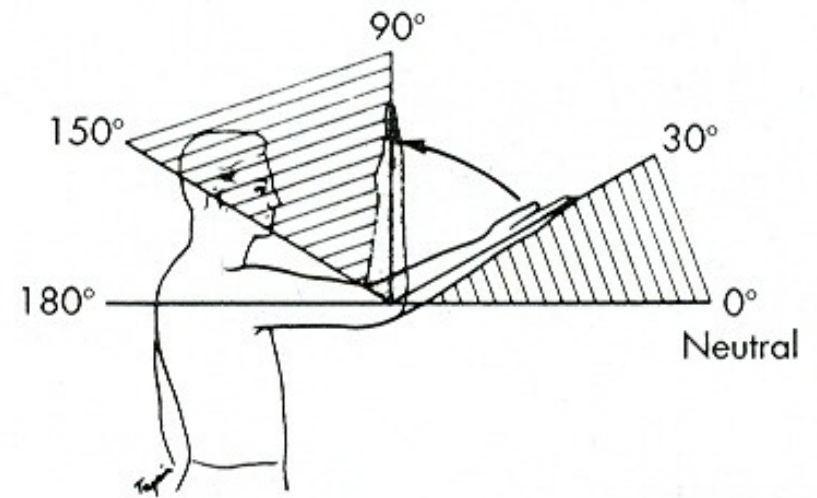
SUPINACE

PRONACE

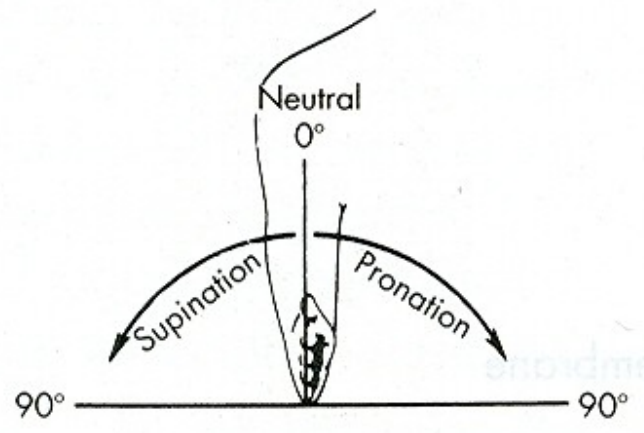




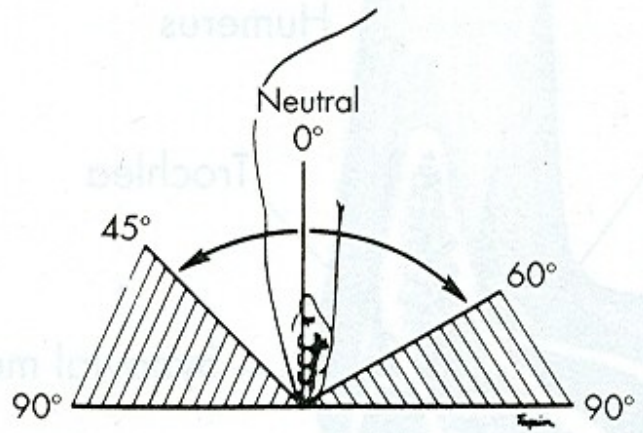
**A**



**B**

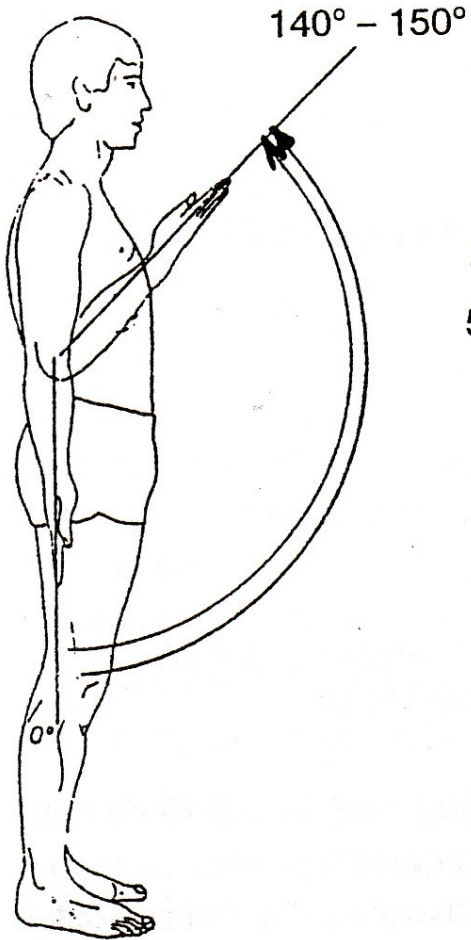


**A**

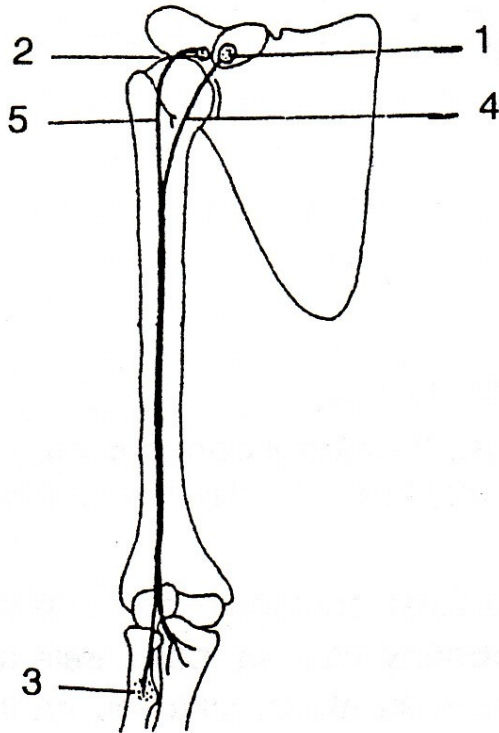


**B**


# FLEXE



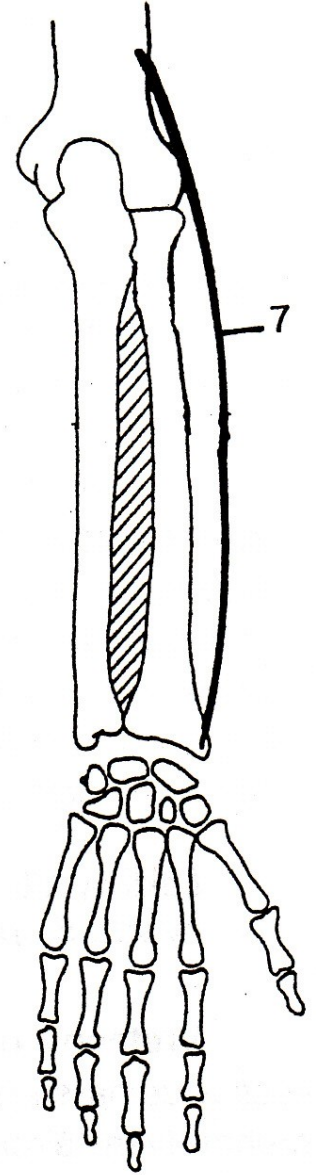
m. biceps brachii

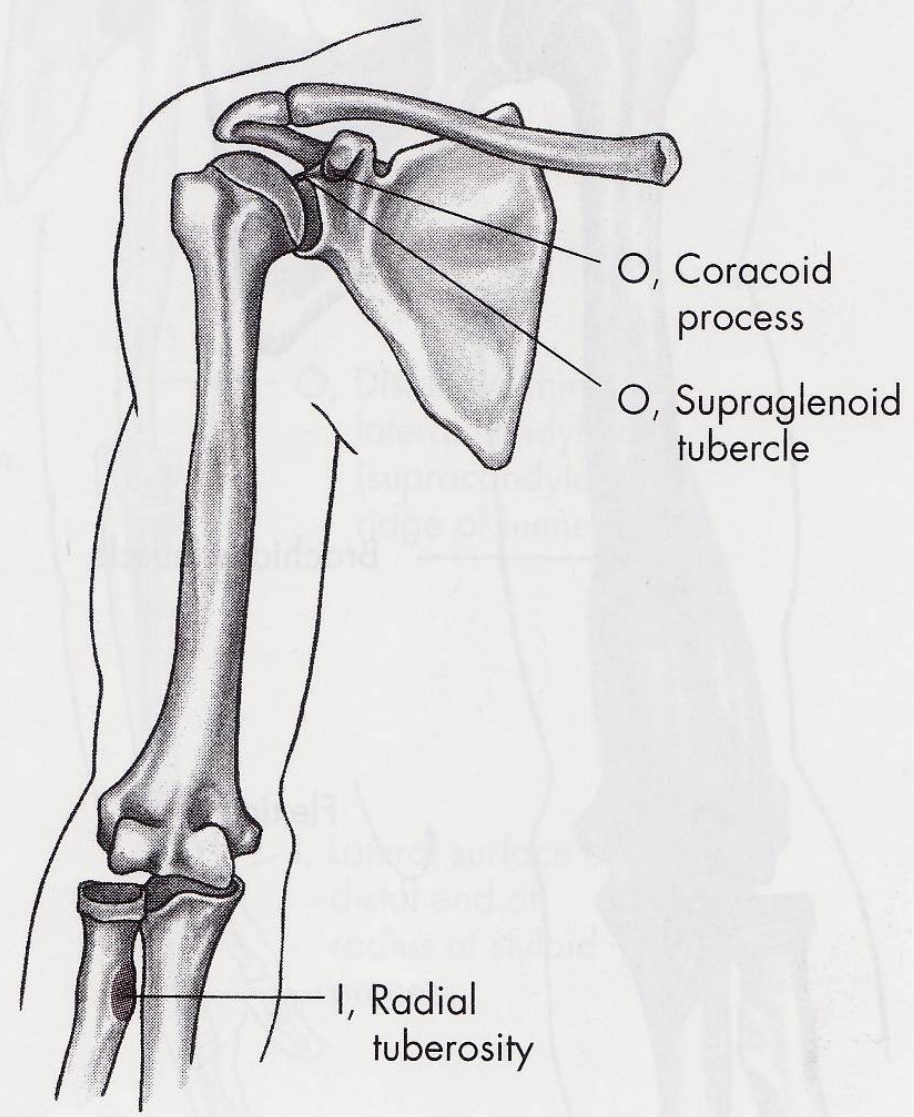
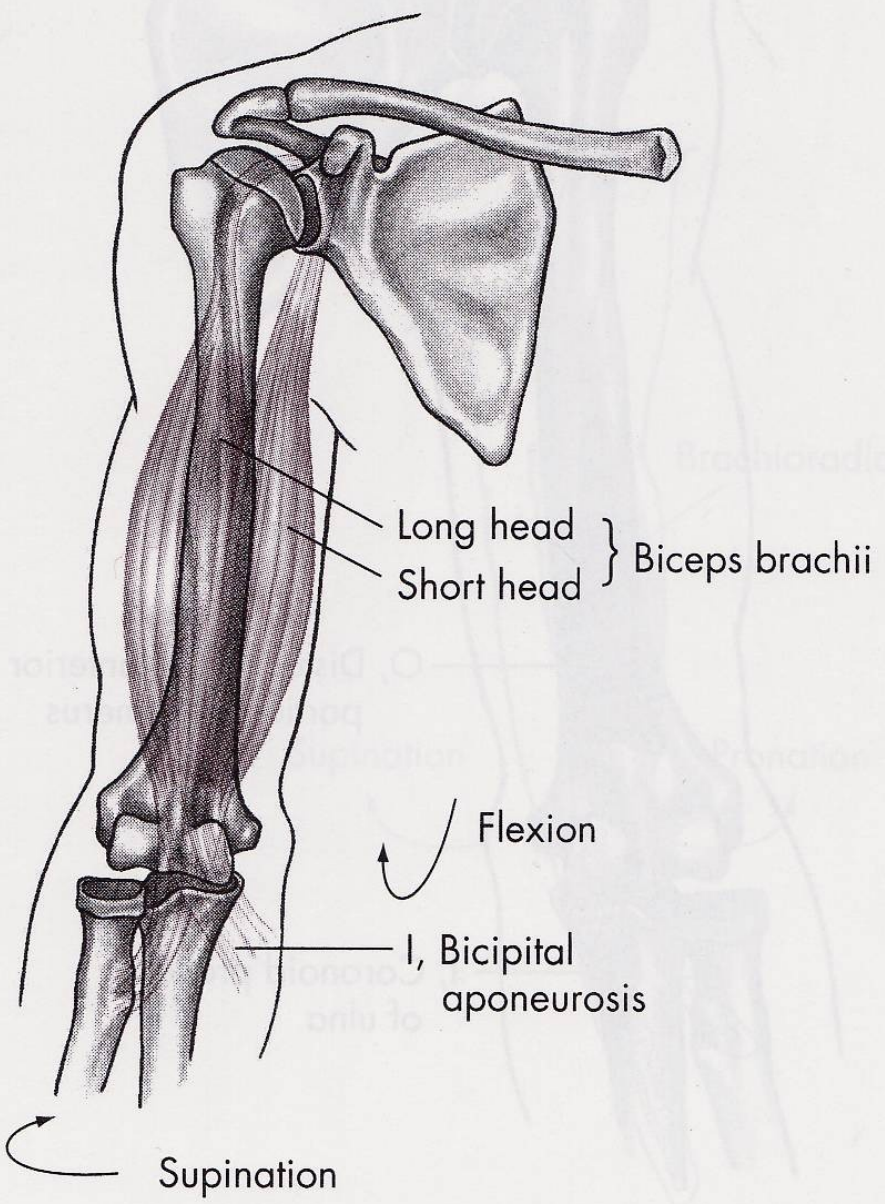


m. brachialis

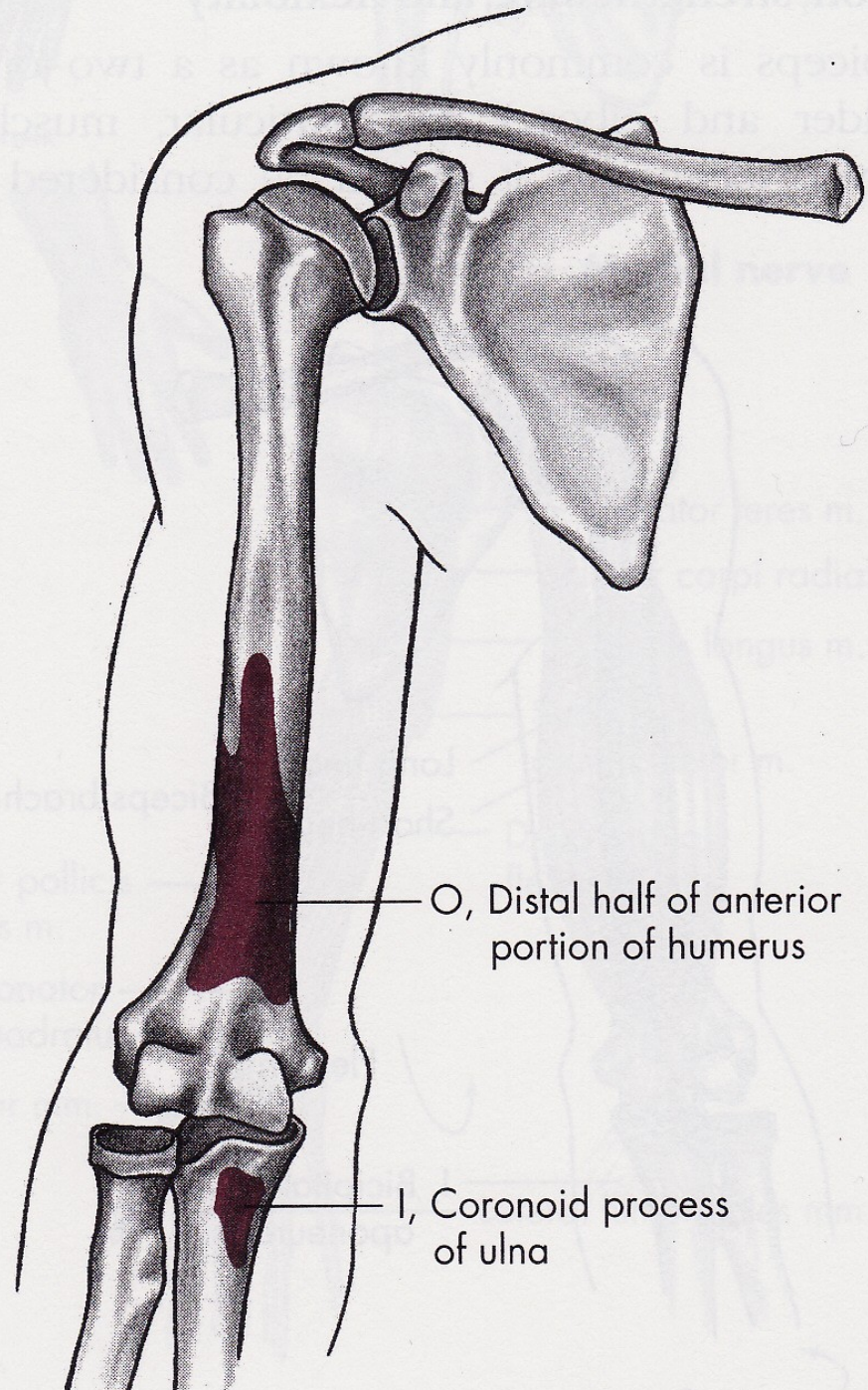
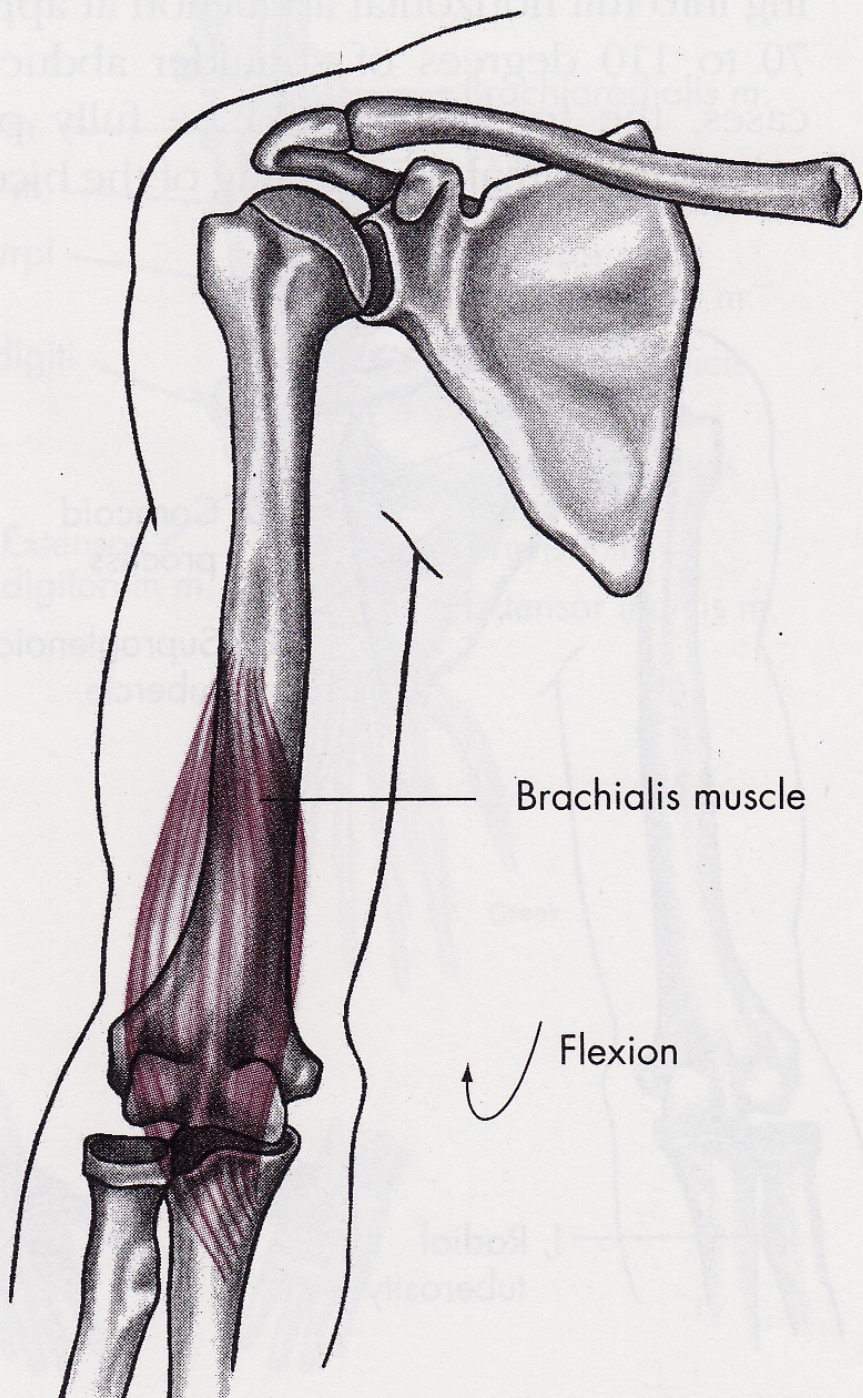


m. brachioradialis

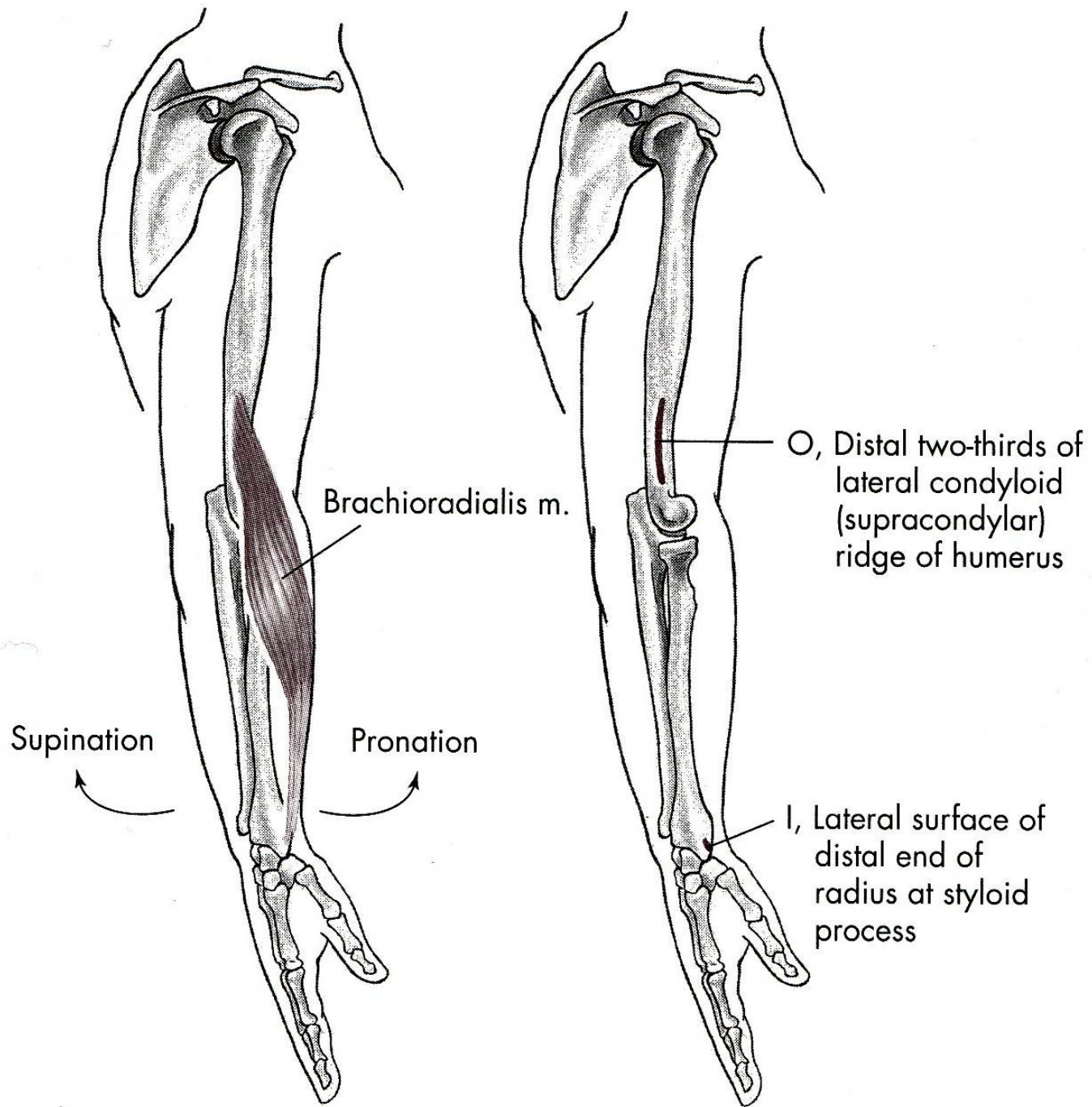




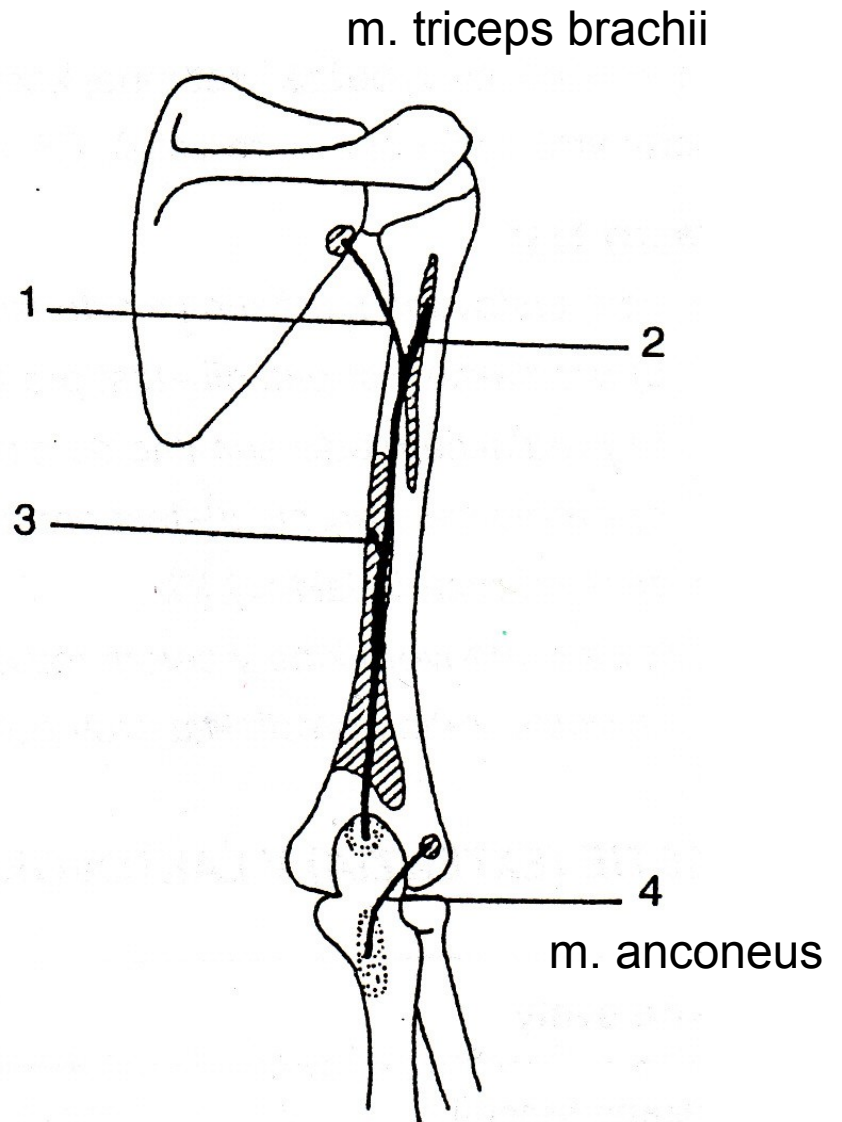
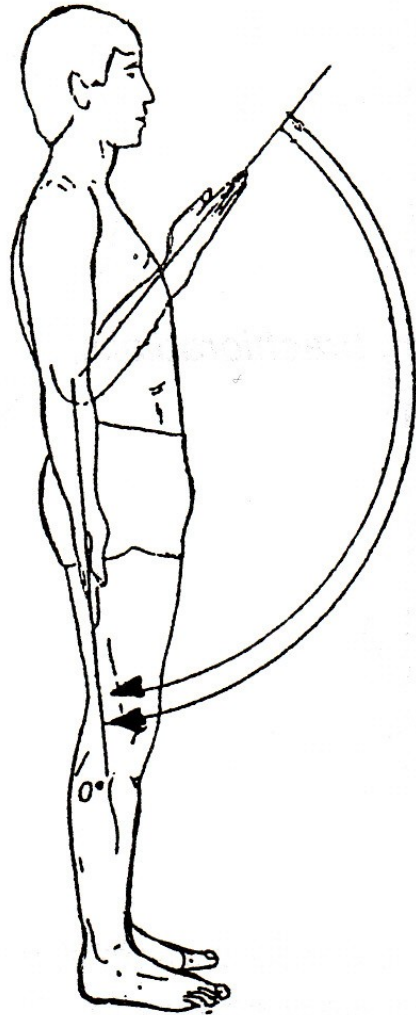






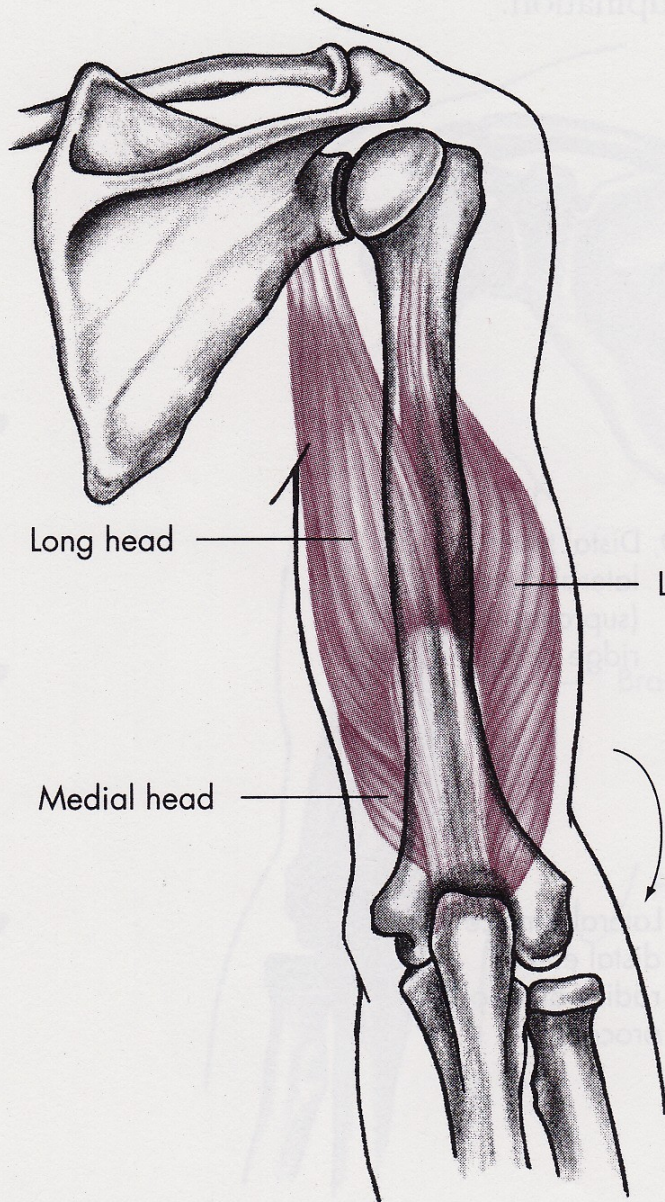


# EXTENZE

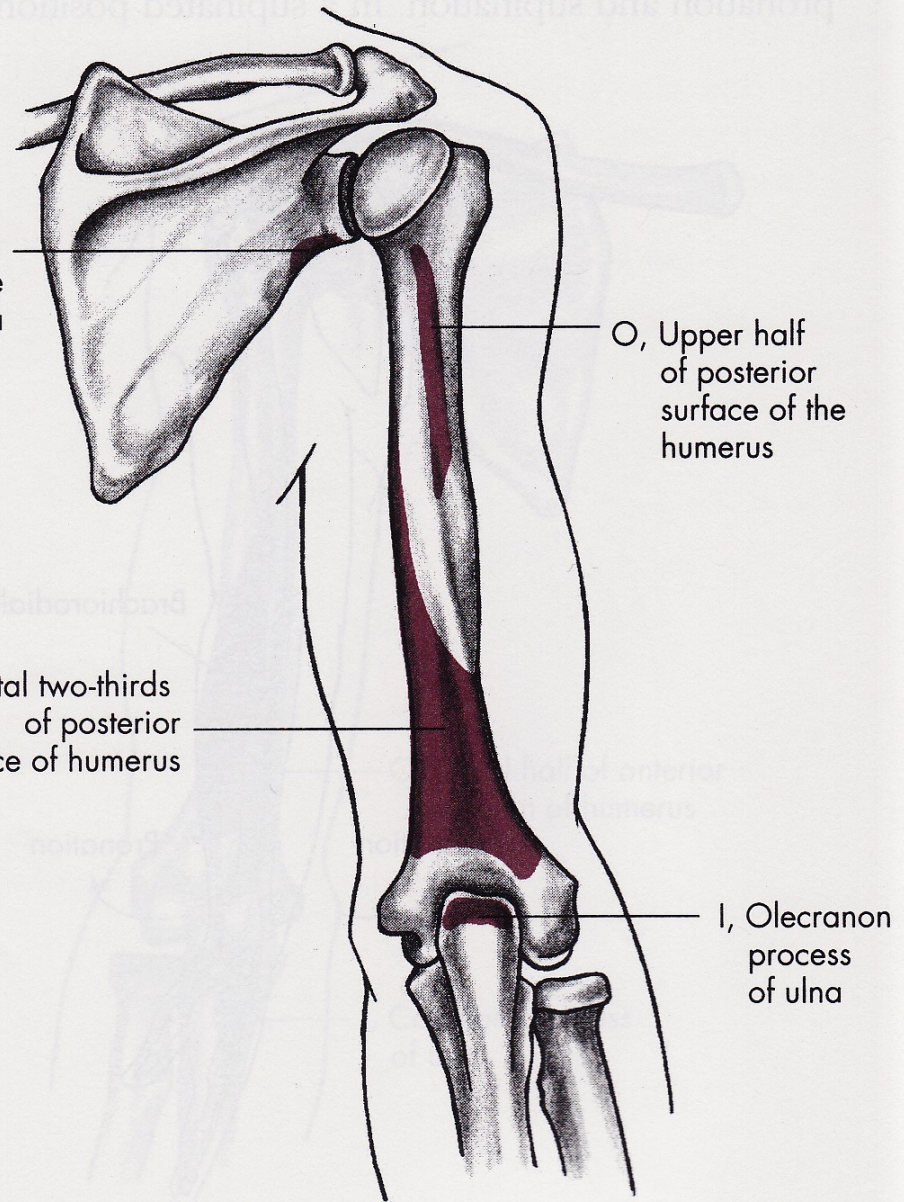




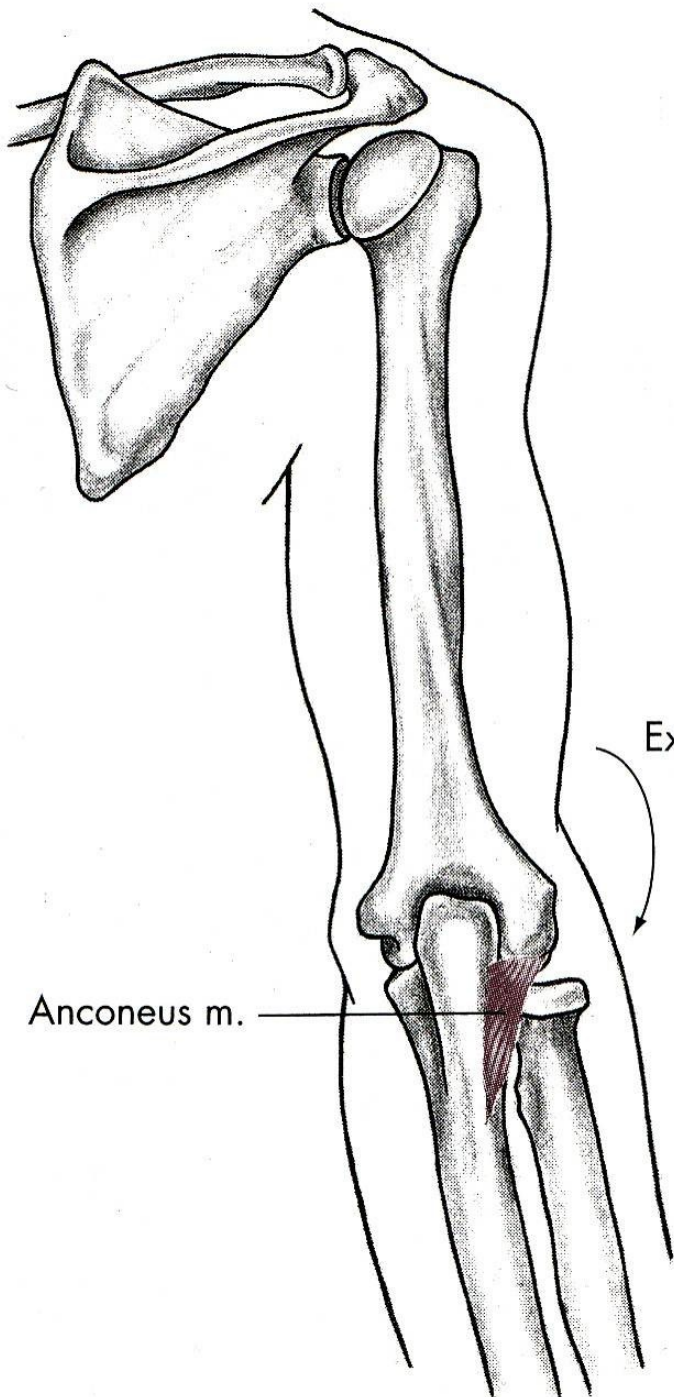
# m. triceps brachii



O, Infraglenoid tubercle of scapula



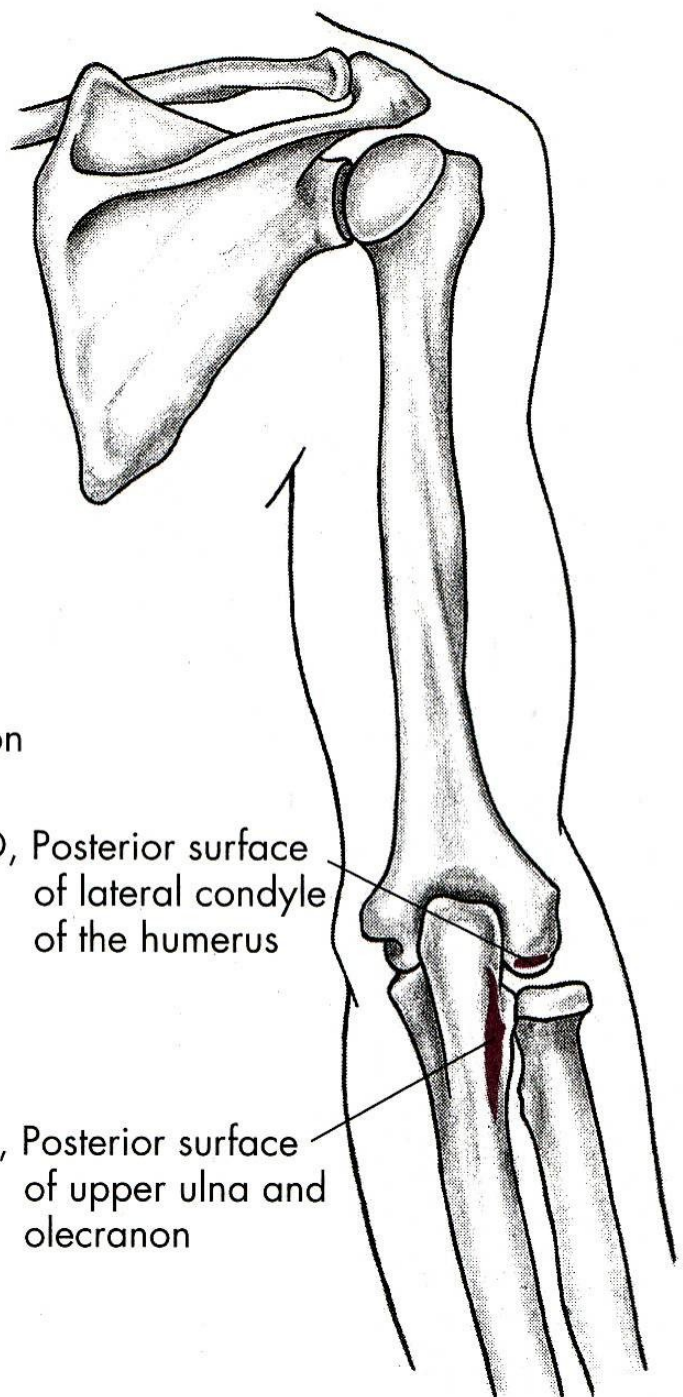




Extension

O, Posterior surface of lateral condyle of the humerus

I, Posterior surface of upper ulna and olecranon



# FLEXE

m. biceps brachii – dvojhlavý sval pažní

m. brachialis – hluboký sval pažní

m. brachioradialis – pažní sval vřetenní

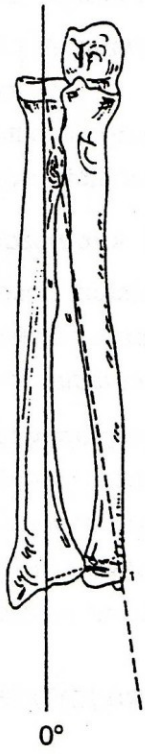
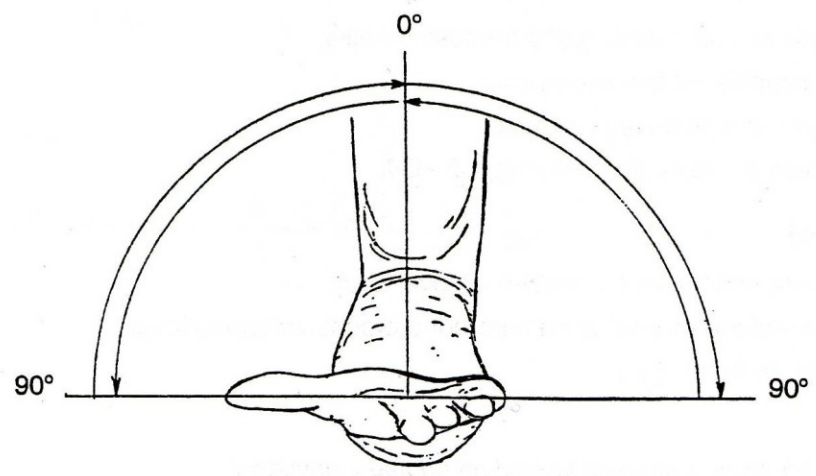
# EXTENZE

m. triceps brachii – trojhlavý sval pažní

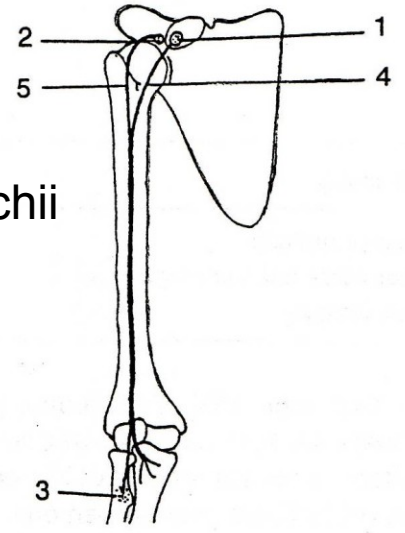
m. anconeus – sval loketní



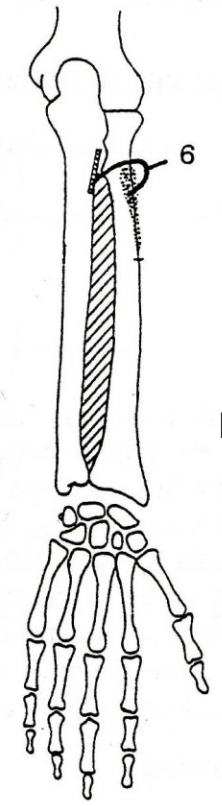
# SUPINACE

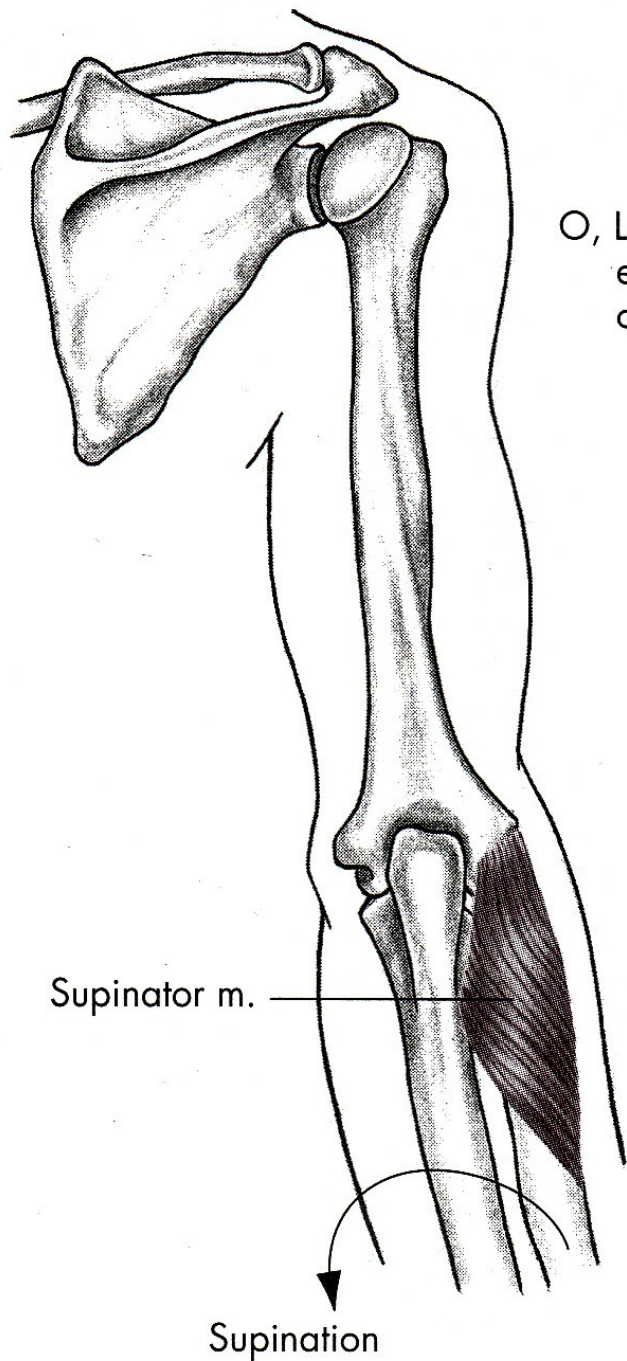


m. biceps brachii

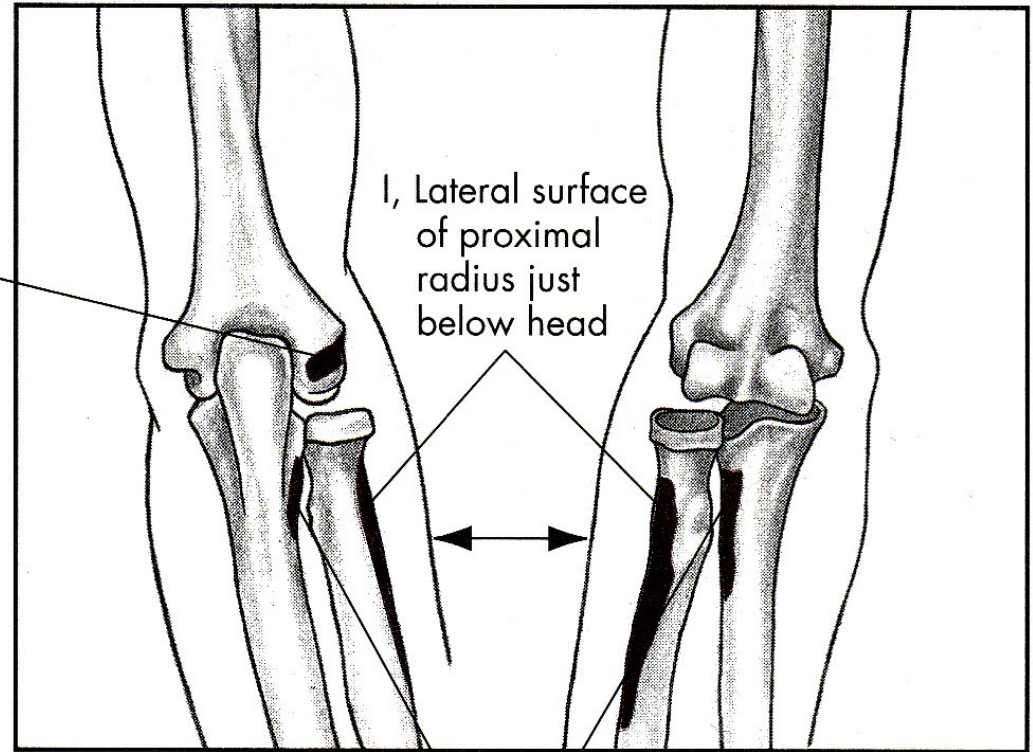


m. supinator





O, Lateral epicondyle of humerus

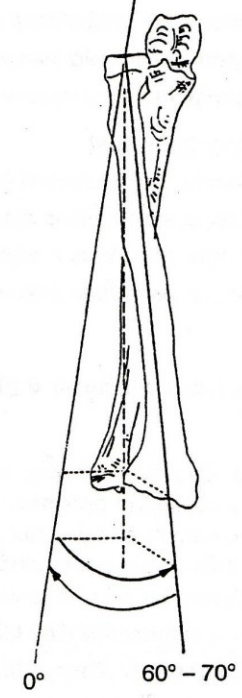
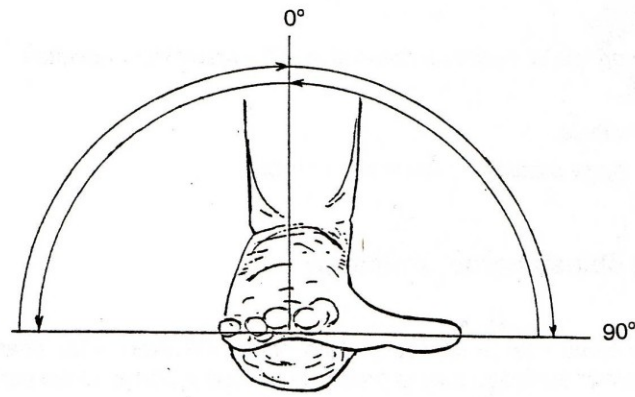


Posterior

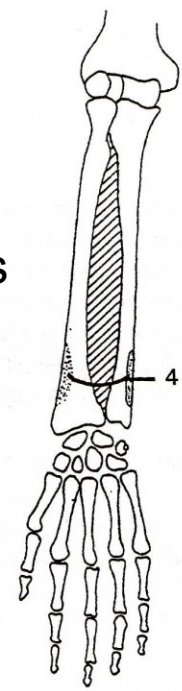
Anterior

O, Neighboring posterior part of ulna

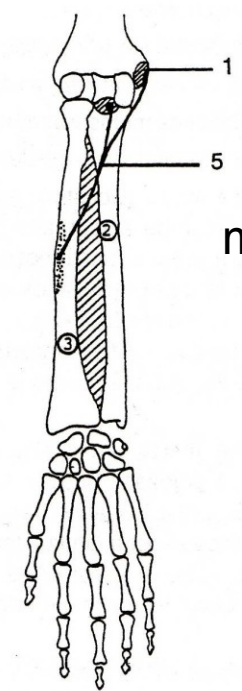
# PRONACE



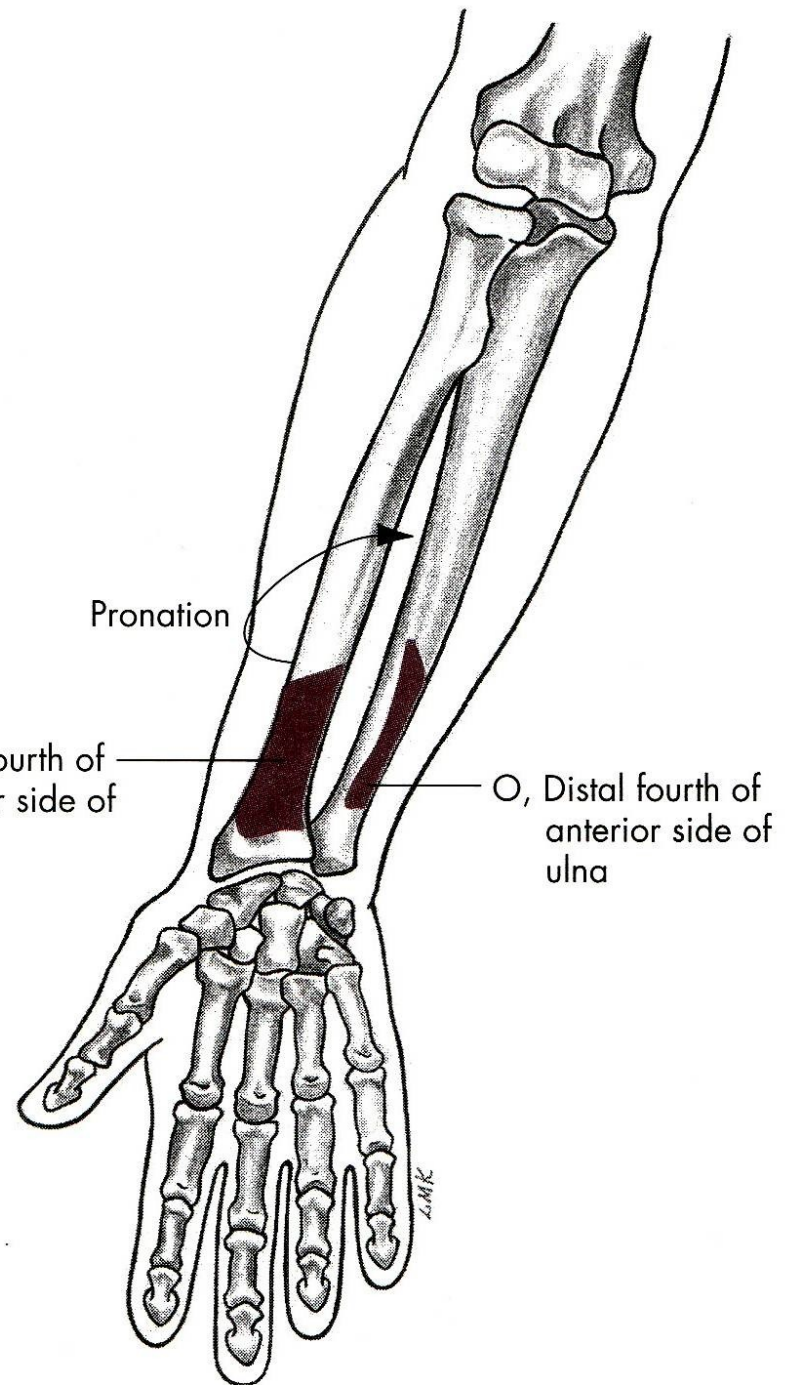
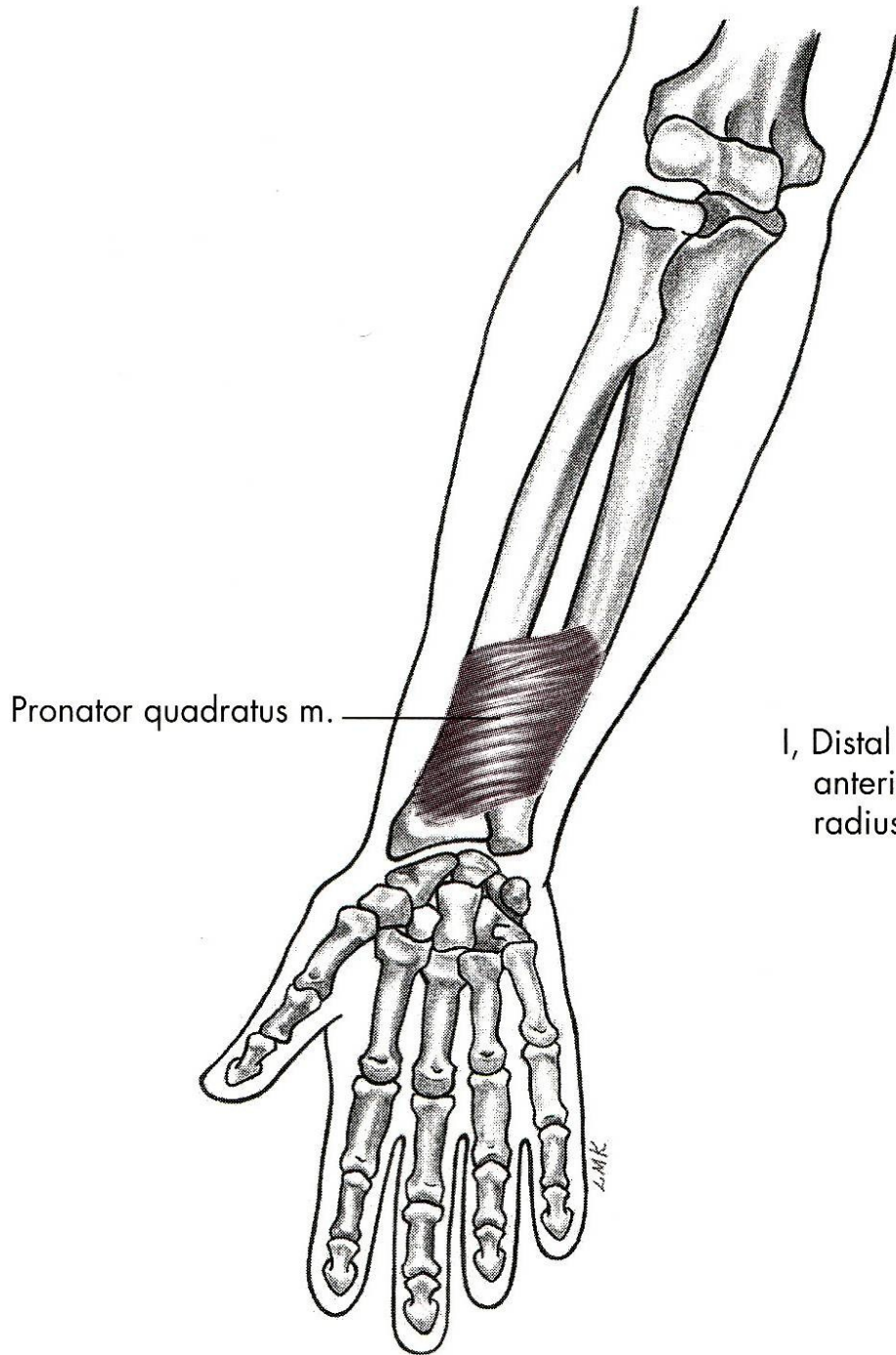
m. pronator quadratus



m. pronator teres

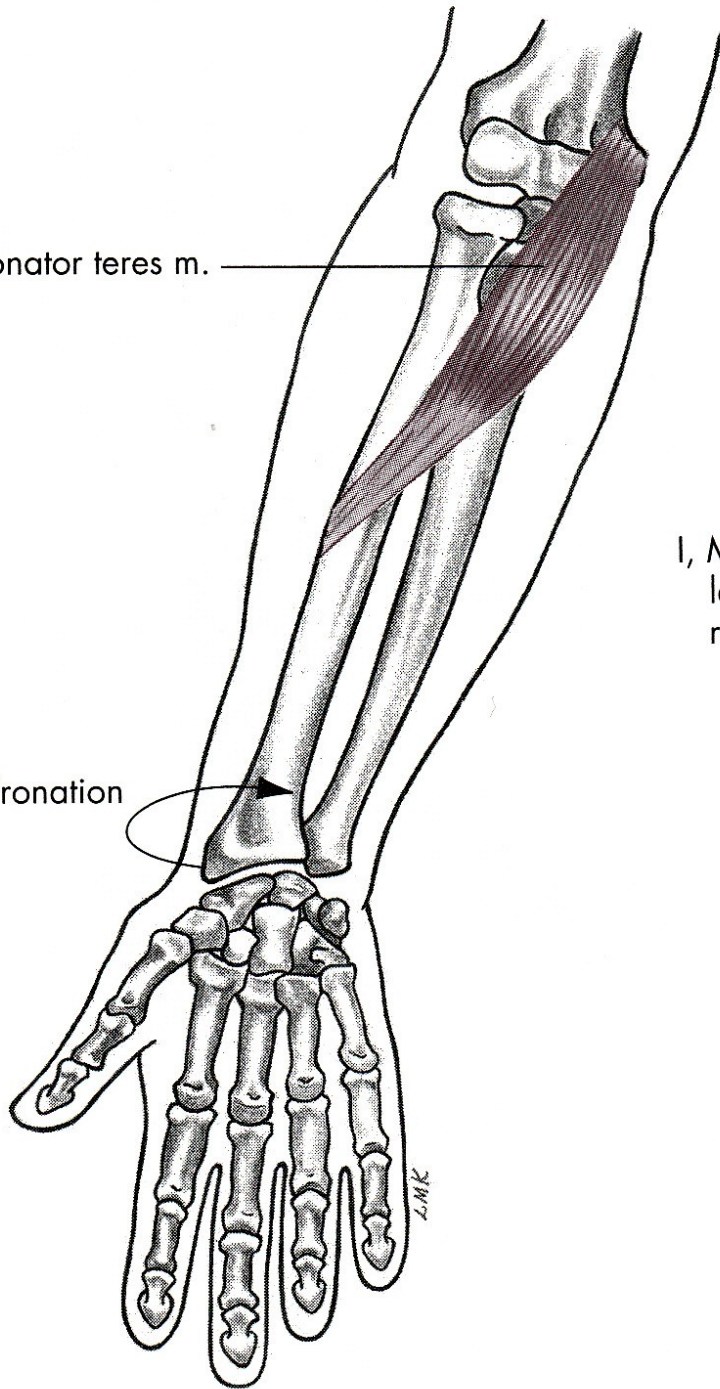






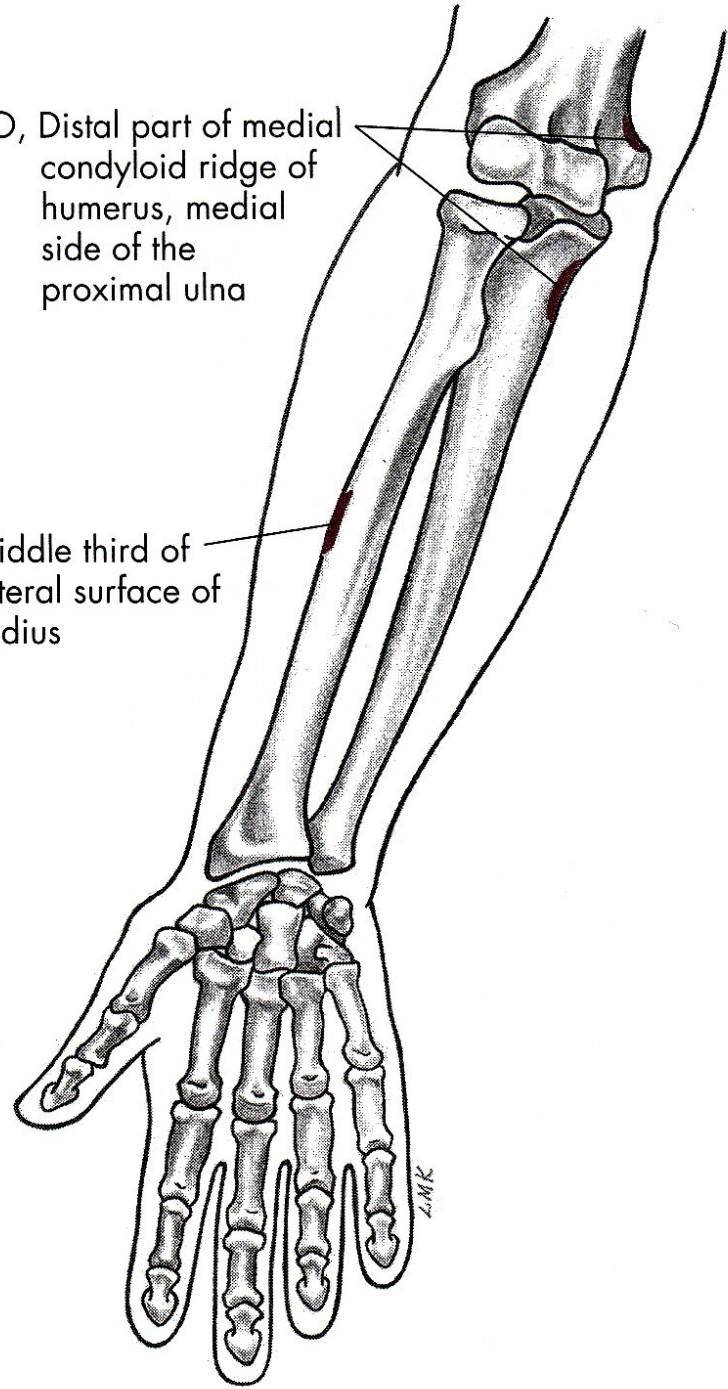
Pronator teres m.

Pronation



O, Distal part of medial condyloid ridge of humerus, medial side of the proximal ulna

I, Middle third of lateral surface of radius



# SUPINACE

m. biceps brachii – dvojhlavý sval pažní

m. supinator – sval supinující

# PRONACE

m. pronator teres – pronující sval oblý

m. pronator quadratus –  
pronující sval čtyřhranný



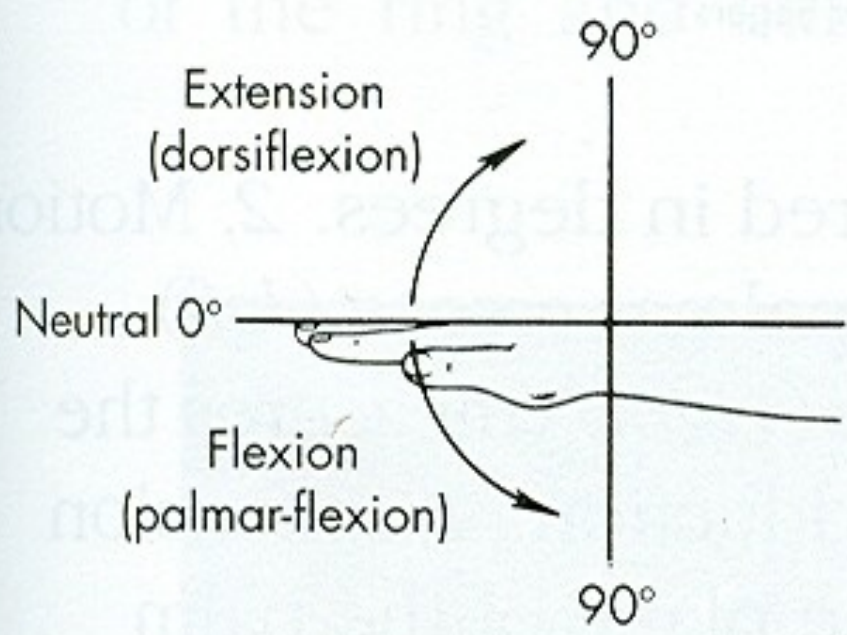
POHYBY ZÁPĚSTÍ

PALMÁRNÍ FLEXE - OHNUTÍ

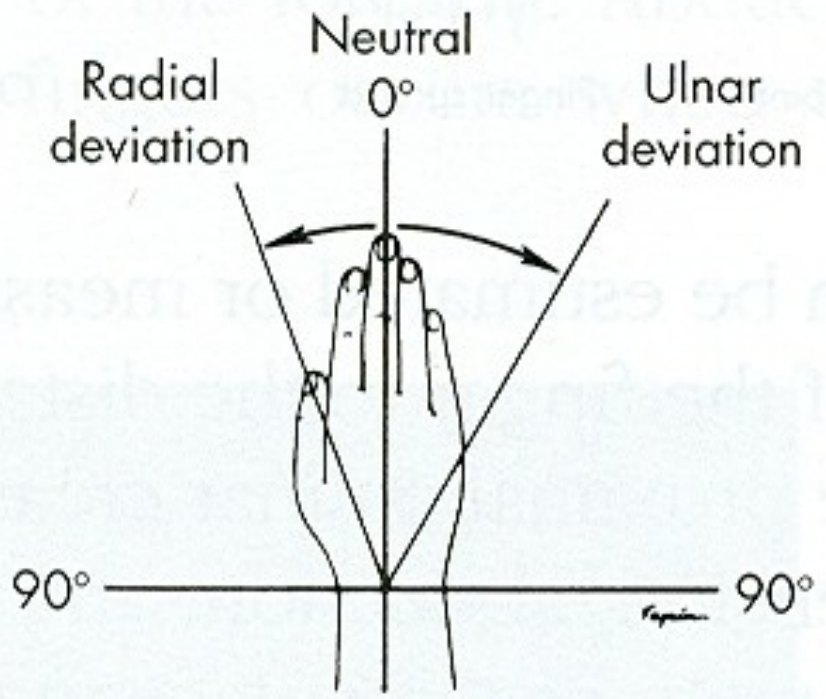
DORZÁLNÍ FLEXE - NATAŽENÍ

ULNÁRNÍ DUKCE

RADIÁLNÍ DUKCE

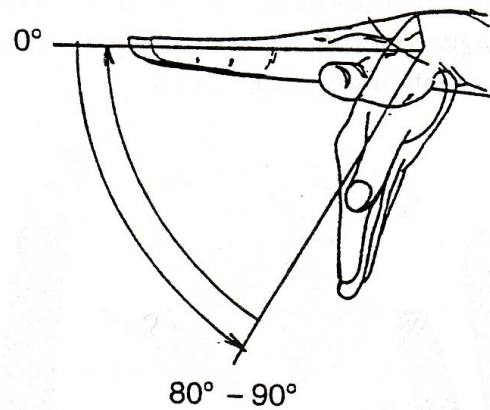


**A**

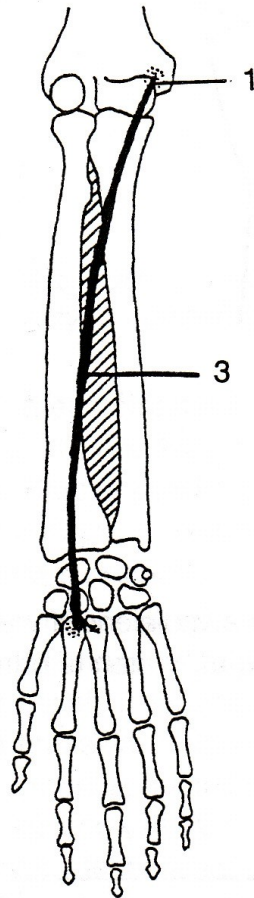


**B**

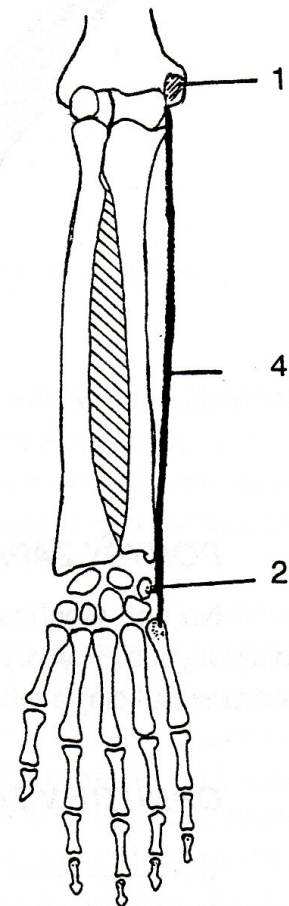
# PALMÁRNÍ FLEXE



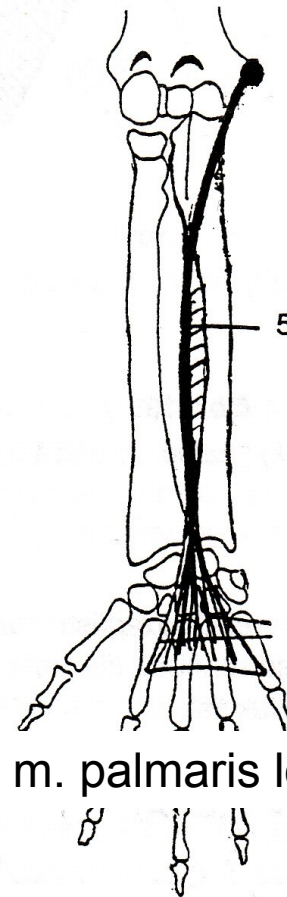
m. flexor carpi radialis



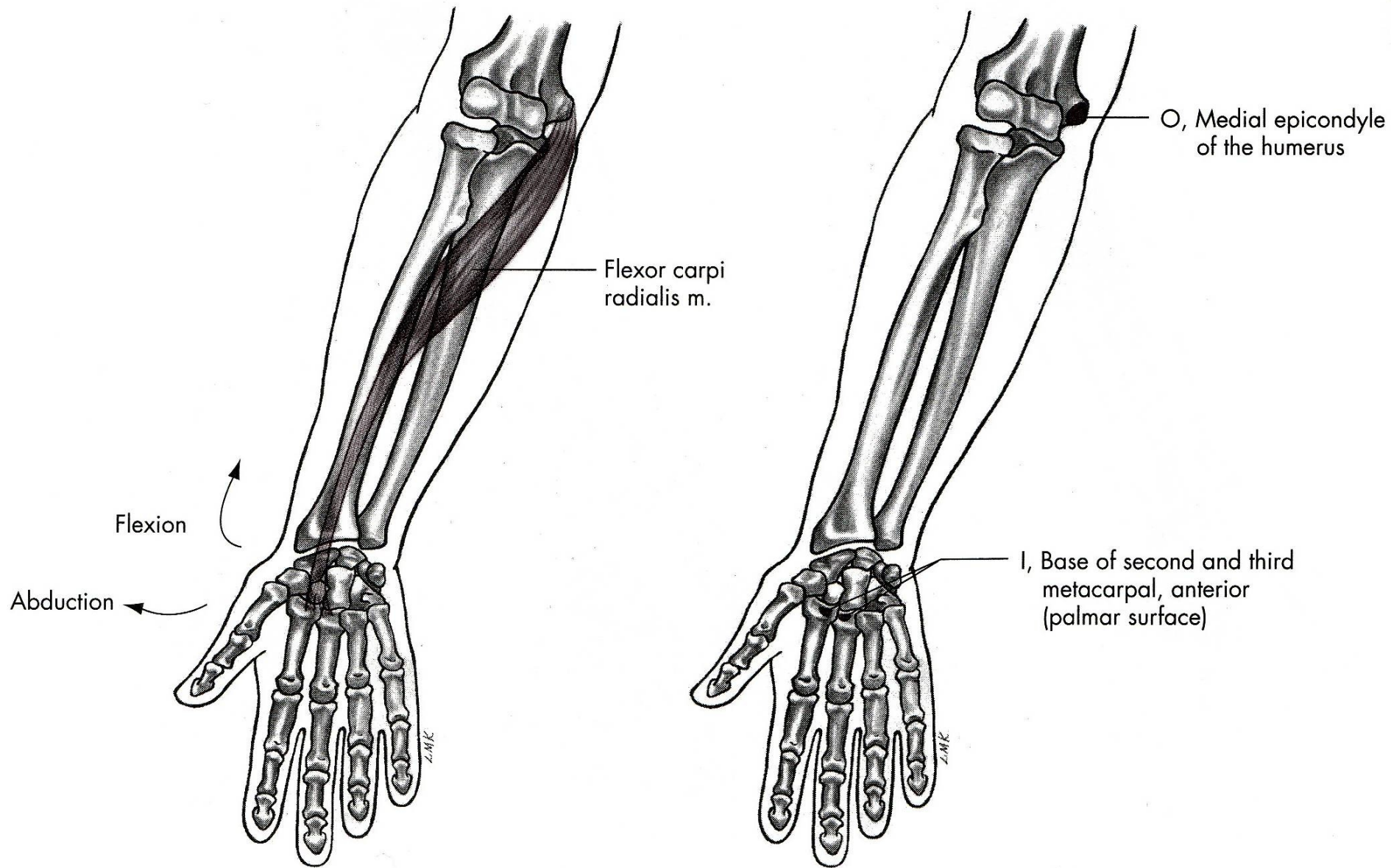
m. flexor carpi ulnaris



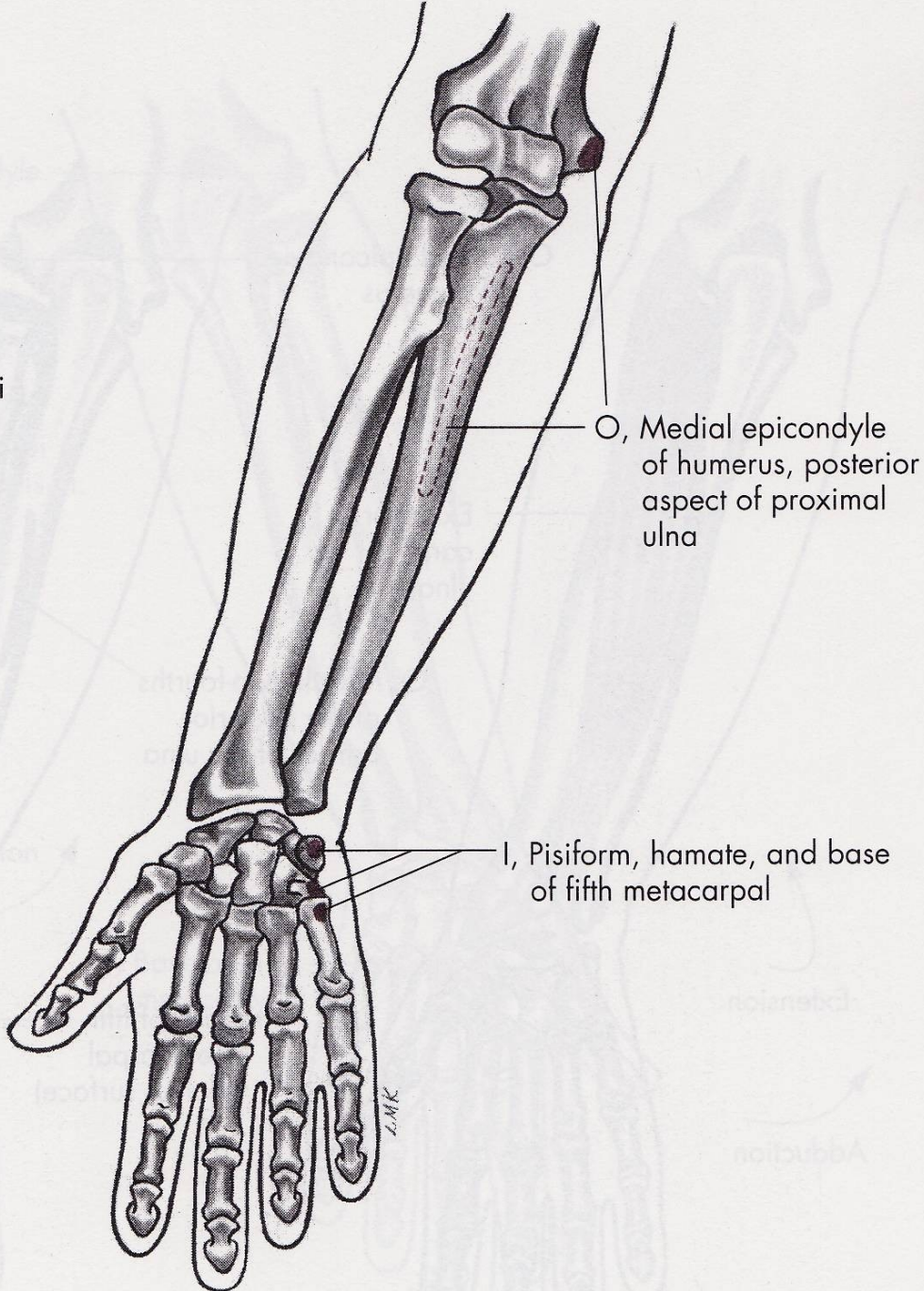
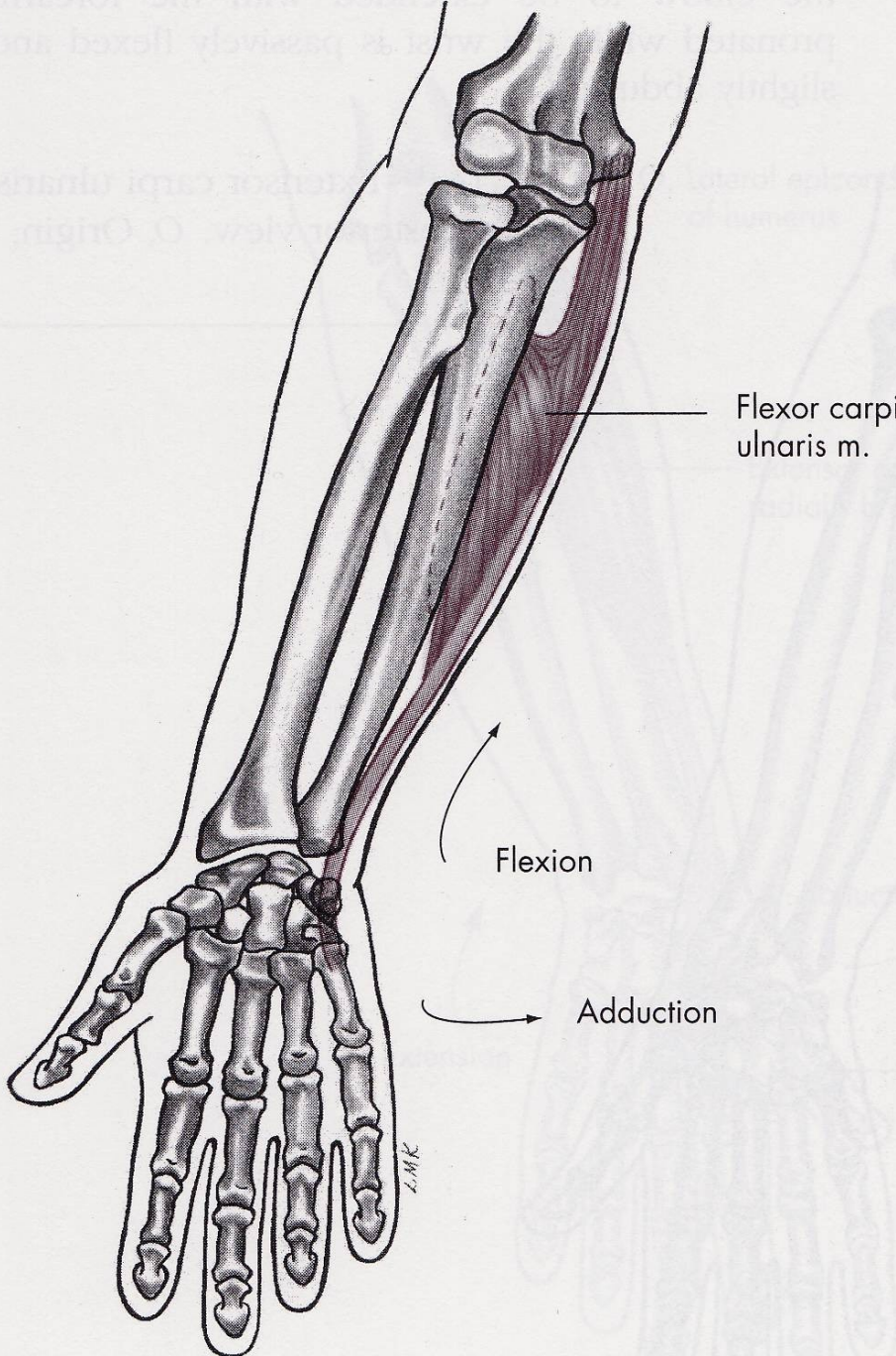
m. palmaris longus



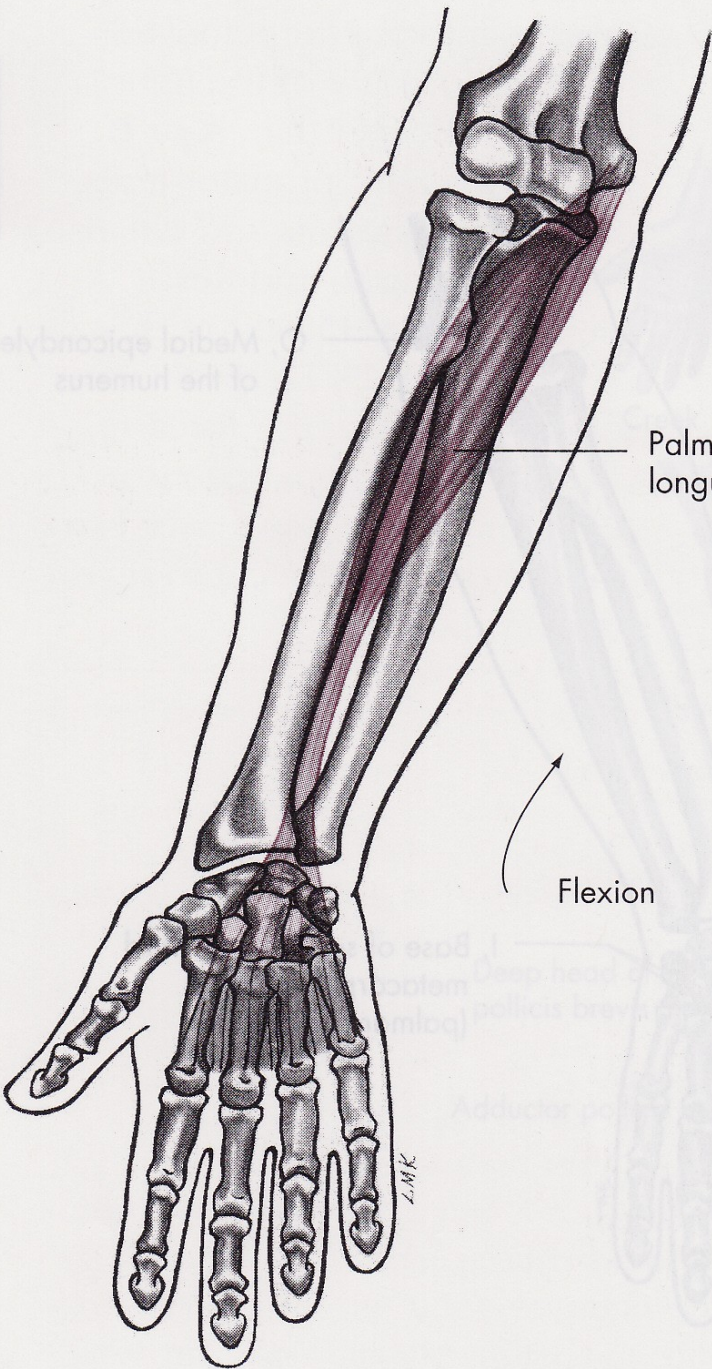






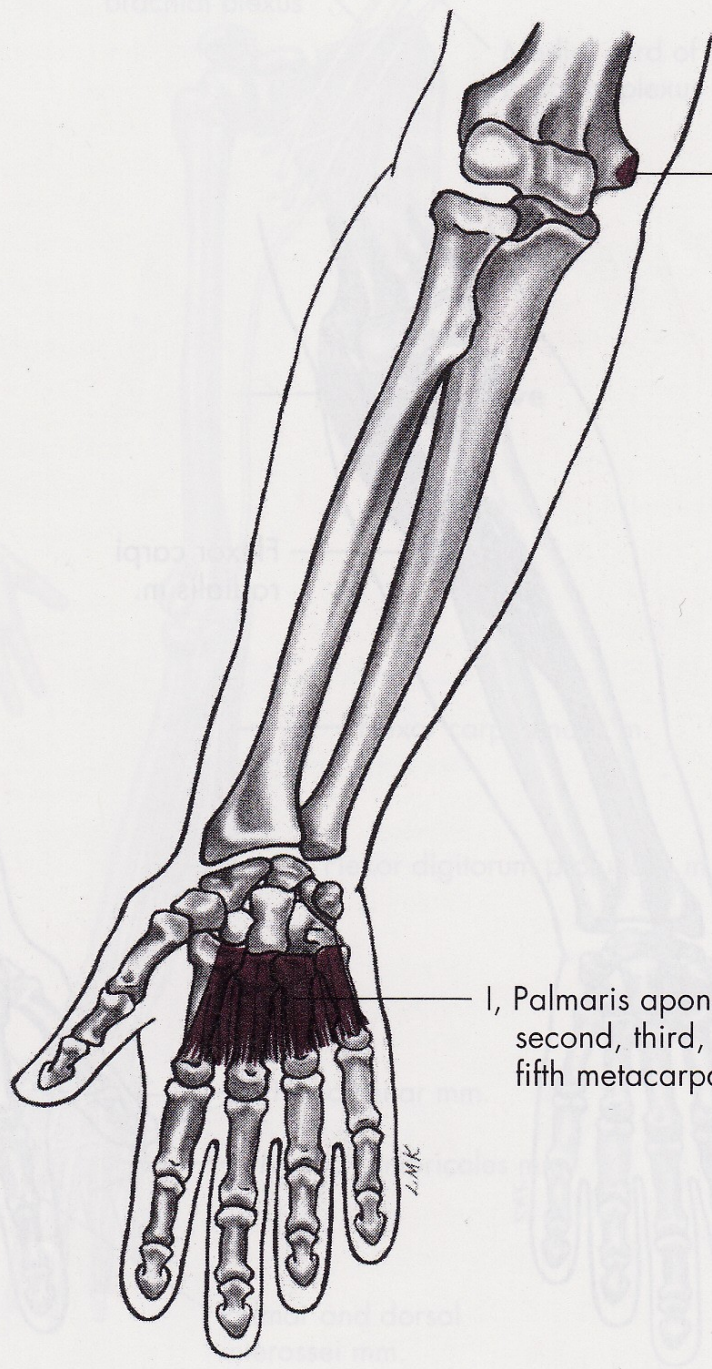






Palmaris longus m.

Flexion



O, Medial epicondyle of humerus

I, Palmaris aponeurosis of second, third, fourth, and fifth metacarpals

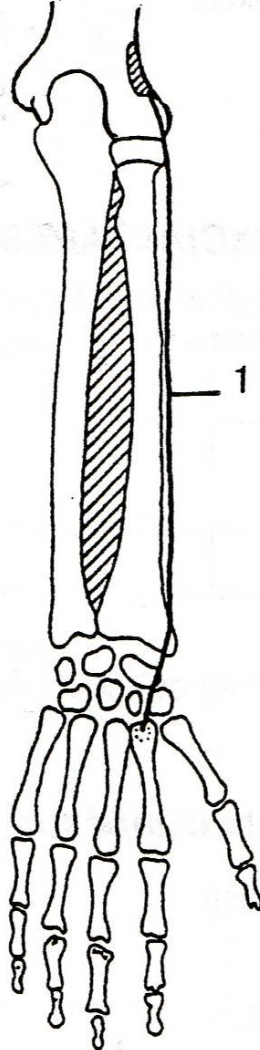
ZMK

ZMK

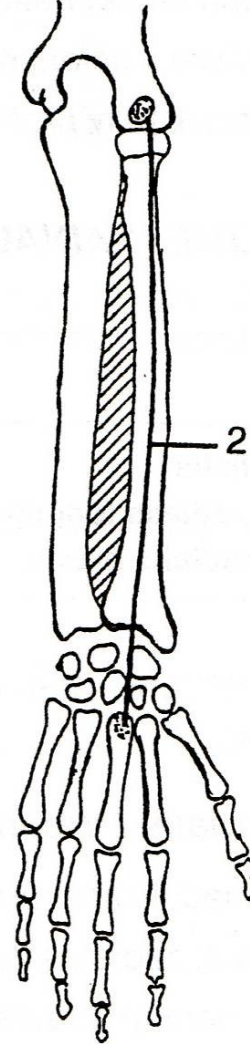


# DORZÁLNÍ FLEXE

m. extensor carpi  
radialis longus



m. extensor carpi  
radialis brevis



m. extensor carpi  
ulnaris

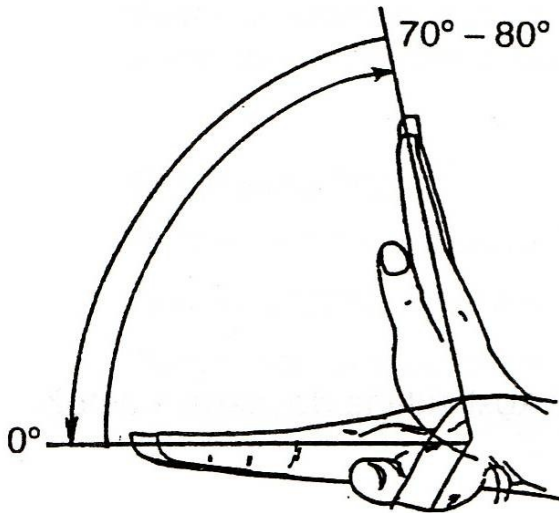
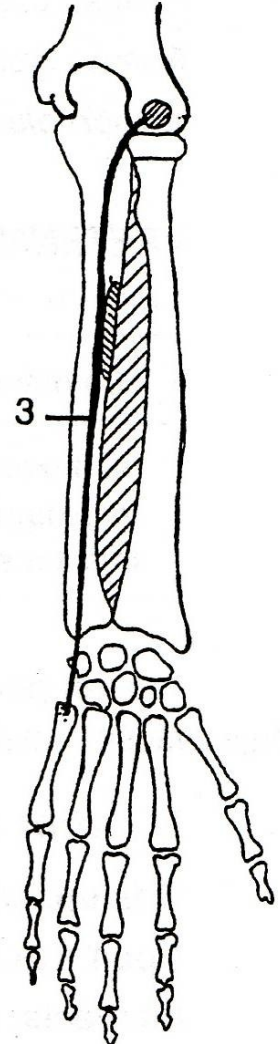
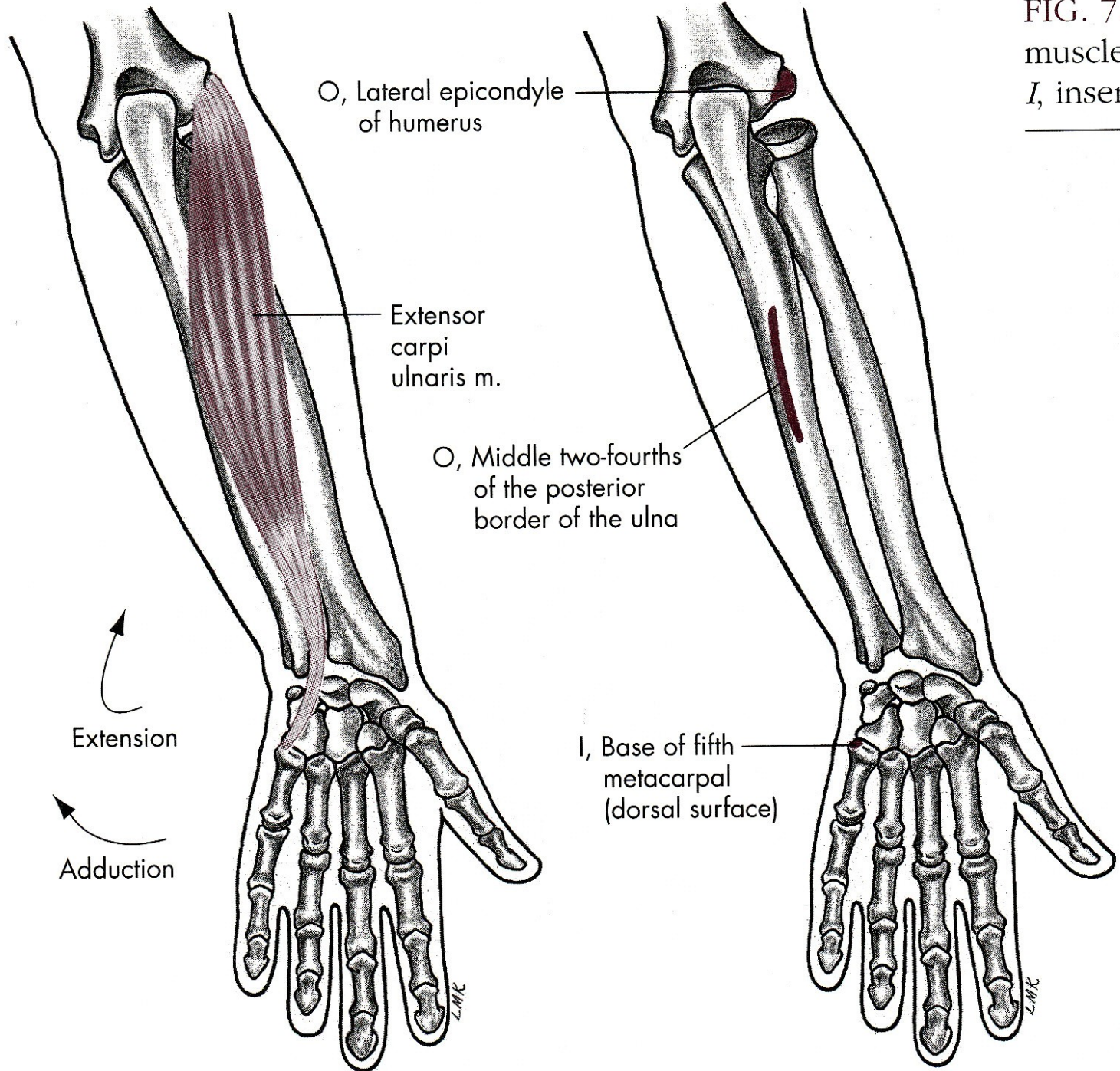
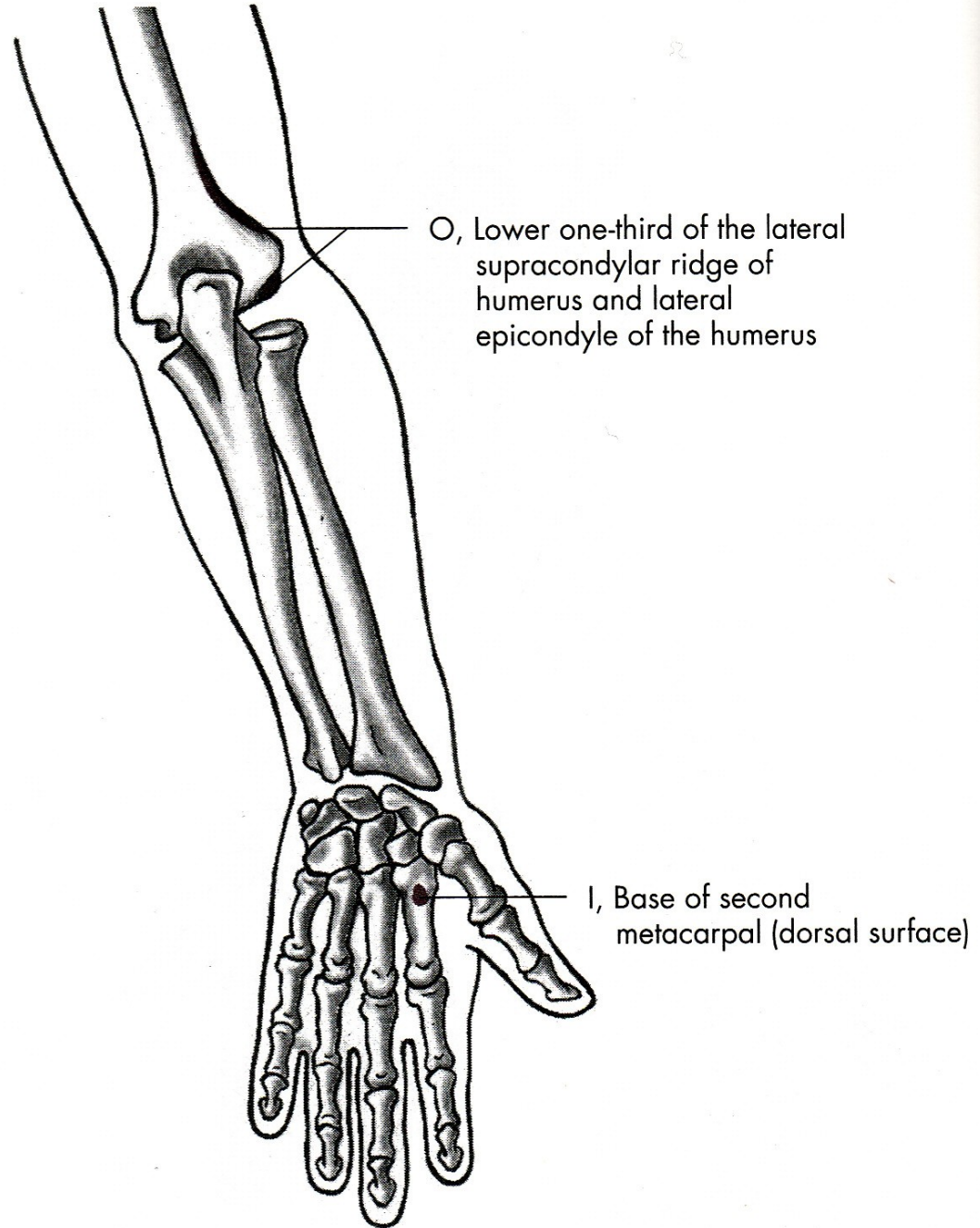
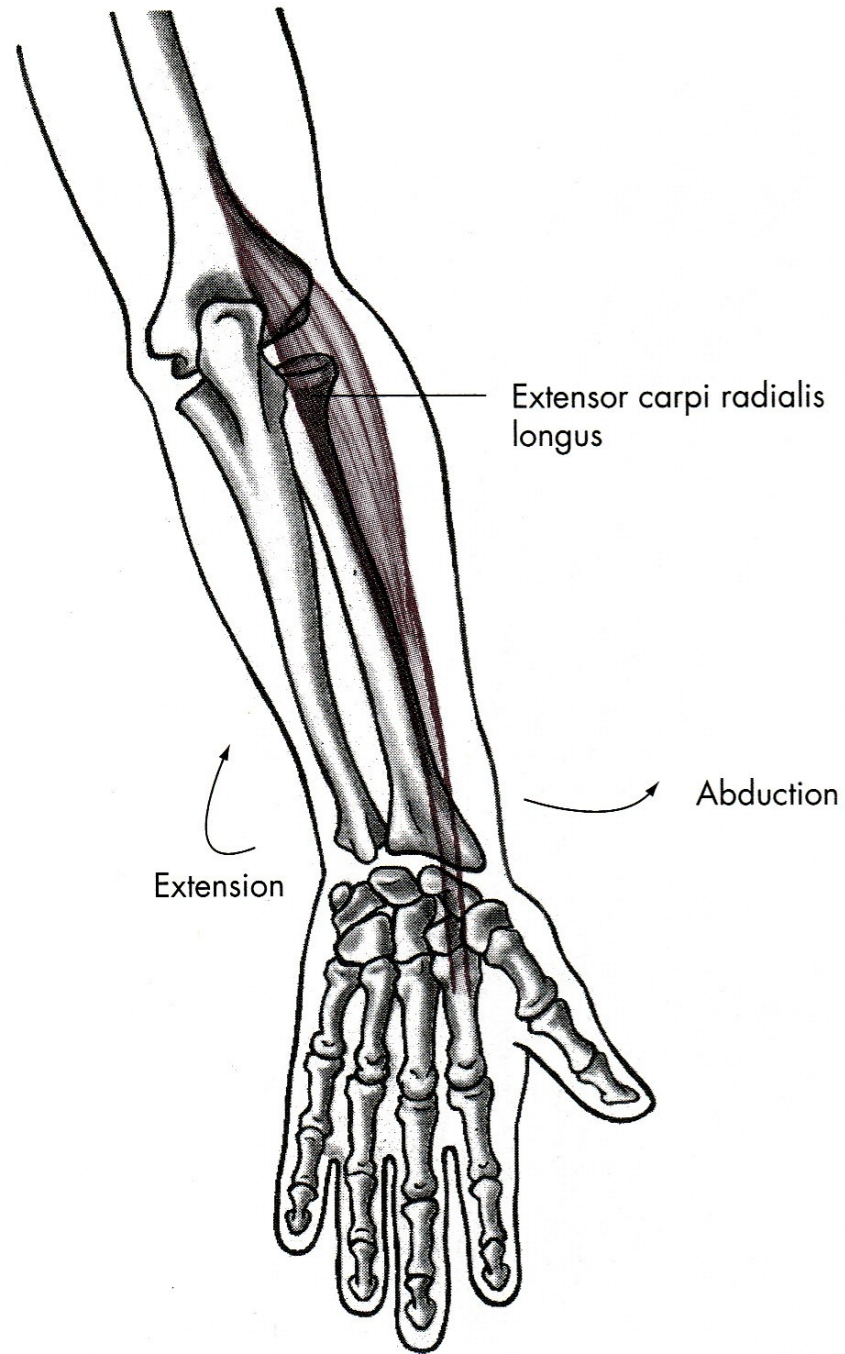


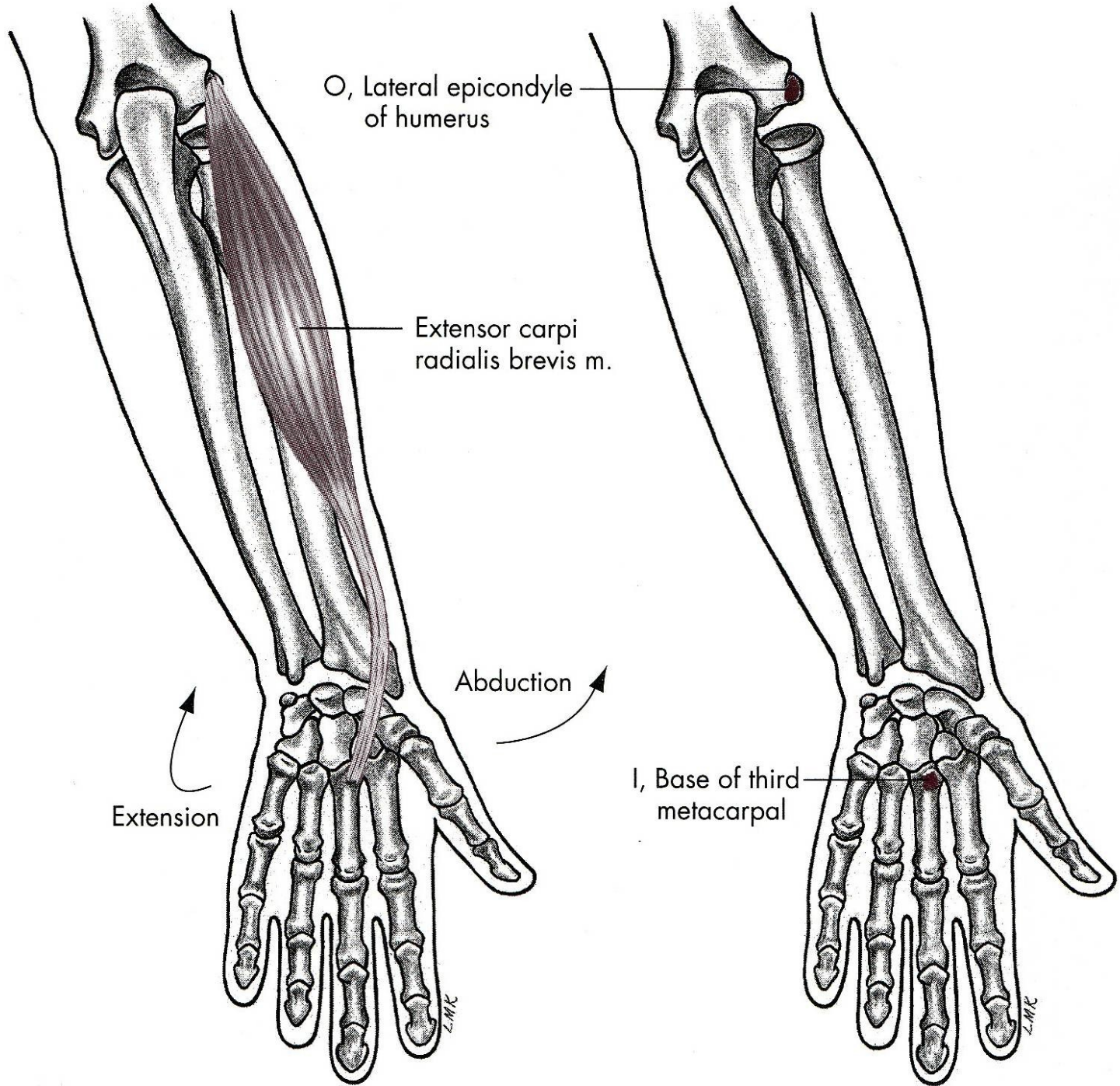
FIG. 7.1  
muscle,  
*I*, inserti











# PALMÁRNÍ FLEXE

m. flexor carpi radialis – zevní ohybač zápěstí

m. flexor carpi ulnaris – vnitřní ohybač zápěstí

m. palmaris longus – dlouhý sval dlaňový

# DORZÁLNÍ FLEXE

m. extensor carpi radialis longus et brevis –  
dlouhý a krátký zevní natahovač zápěstí

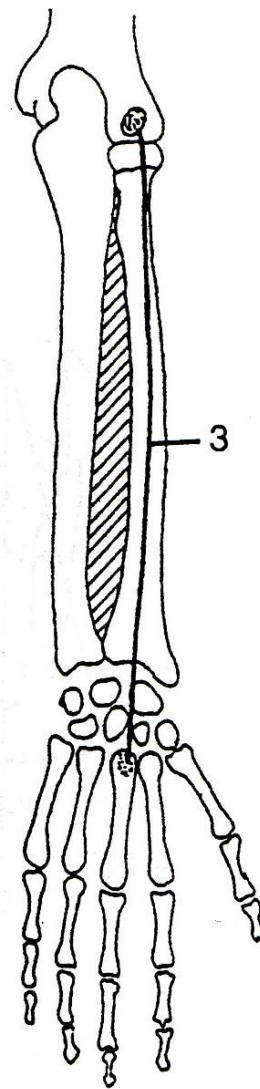
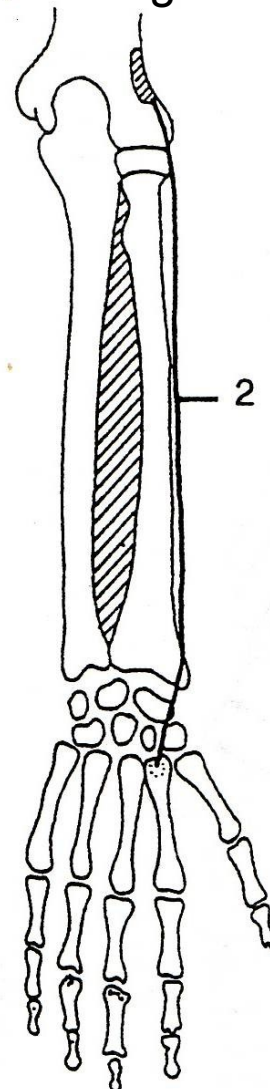
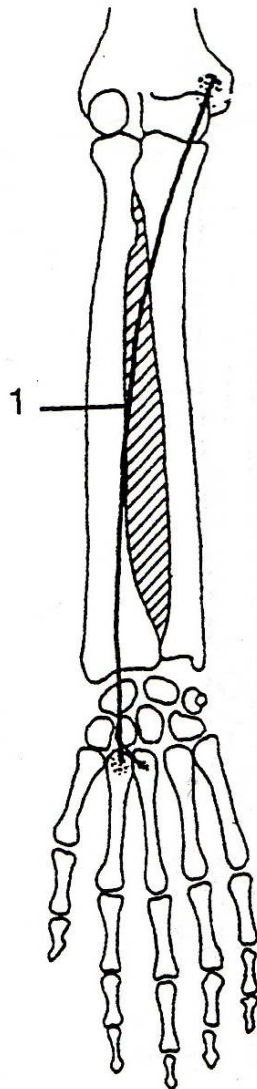
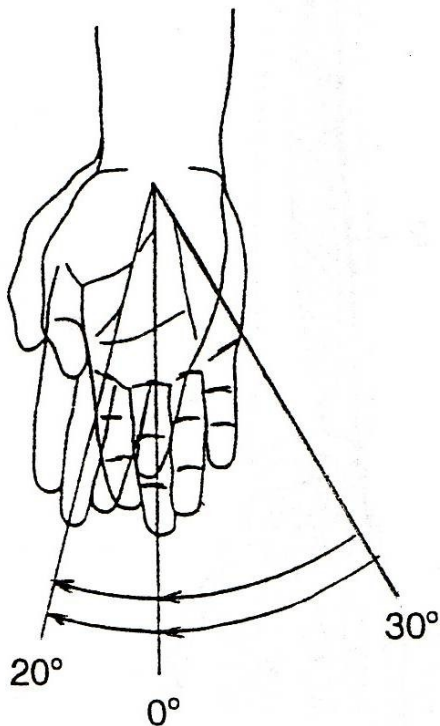
m. extensor carpi ulnaris –  
vnitřní natahovač zápěstí

# RADIÁLNÍ DUKCE

m. flexor carpi radialis

m. extensor carpi radialis longus

m. extensor carpi radialis brevis

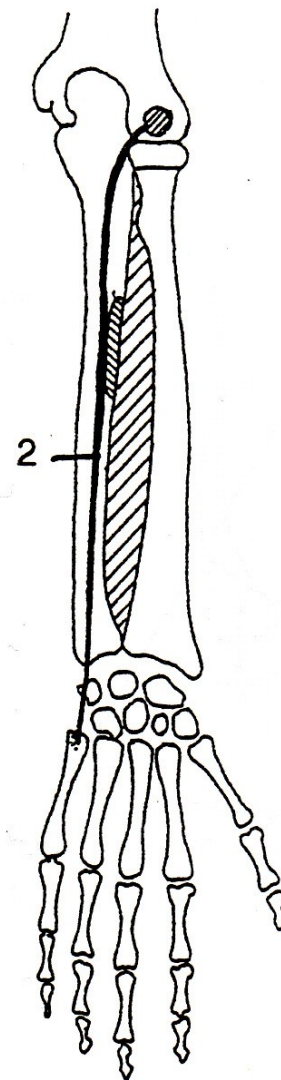
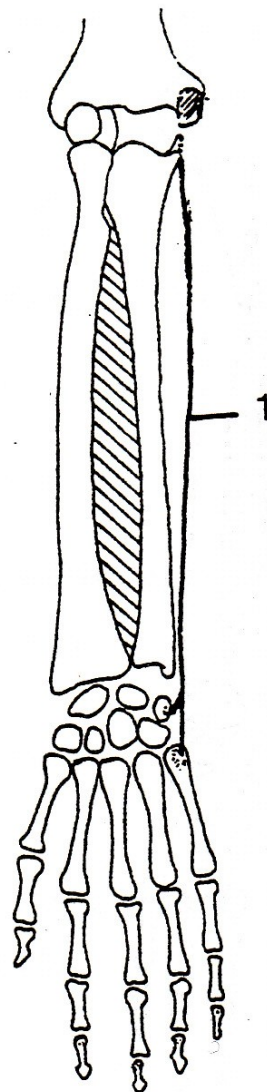
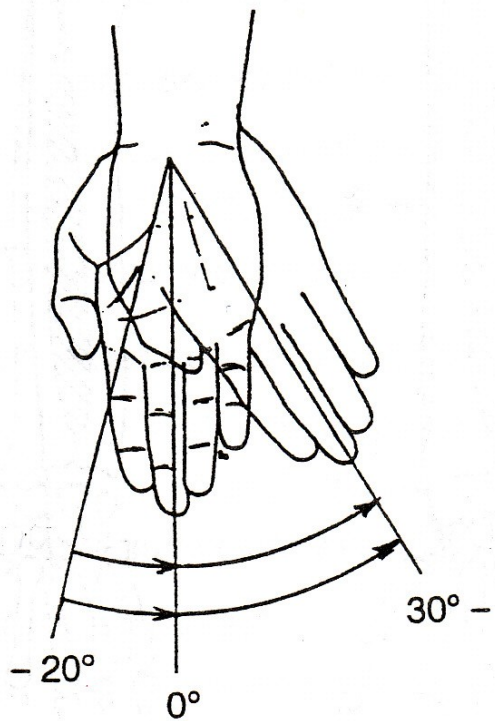




# ULNÁRNÍ DUKCE

m. flexor carpi ulnaris

m. extensor carpi ulnaris



# RADIÁLNÍ DUKCE

m. extensor carpi radialis longus et brevis –  
dlouhý a krátký zevní natahovač zápěstí

m. flexor carpi radialis – zevní ohybač zápěstí

# ULNÁRNÍ DUKCE

m. extensor carpi ulnaris –  
vnitřní natahovač zápěstí

m. flexor carpi ulnaris – vnitřní ohybač zápěstí

# POHYBY PRSTŮ

FLEXE - OHNUTÍ

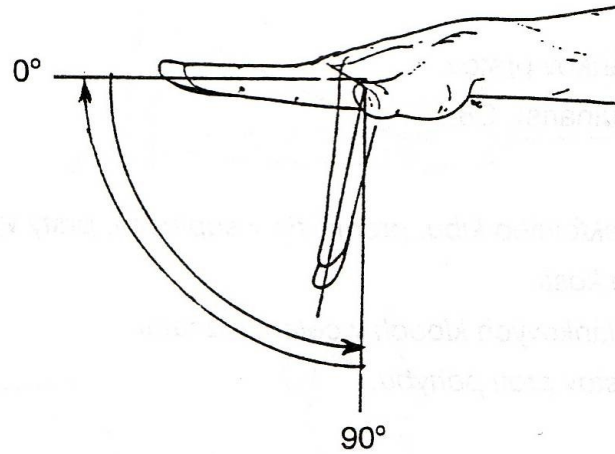
EXTENZE - NATAŽENÍ

ABDUKCE - ODTAŽENÍ

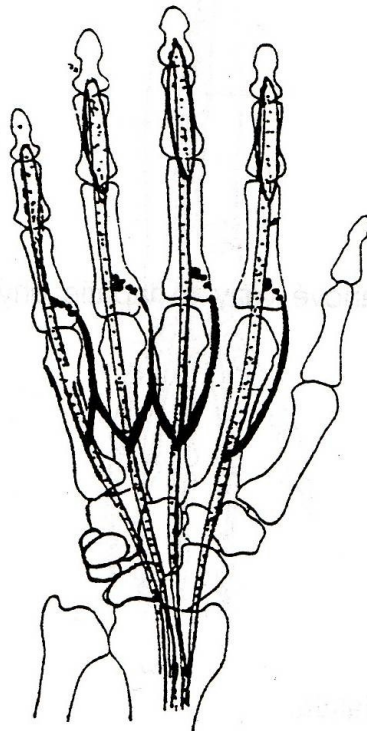
ADDUKCE - PŘITAŽENÍ



# FLEXE - OHNUTÍ

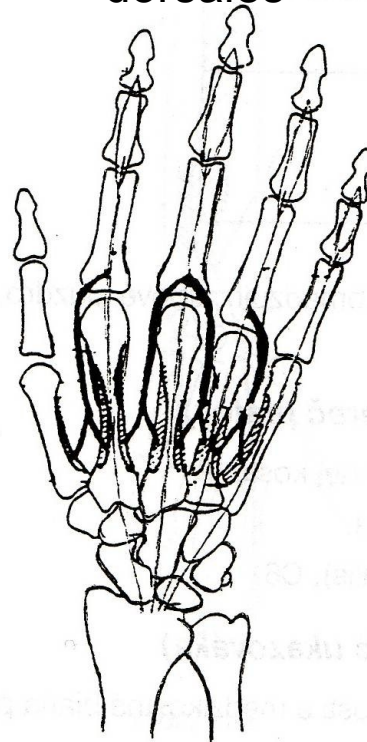


mm. lumbricales



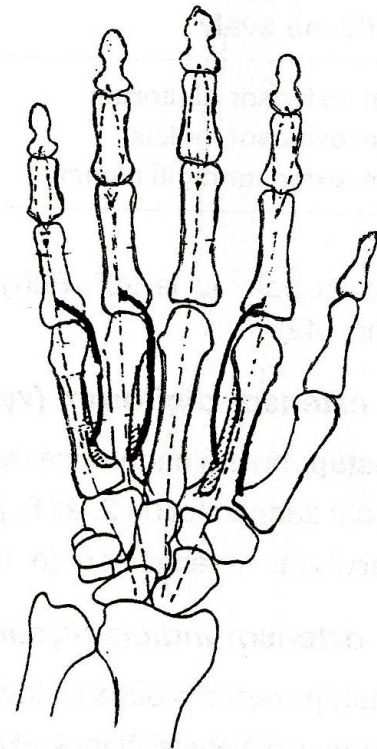
A

mm. Interossei dorsales

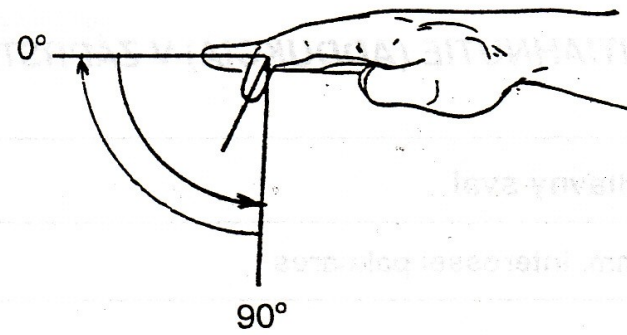
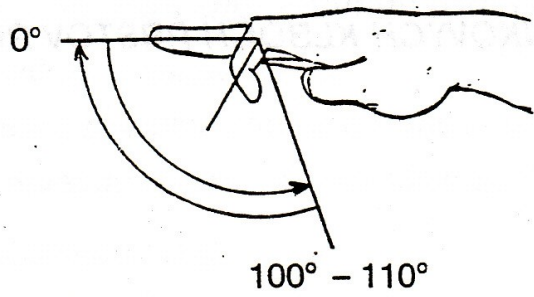


B

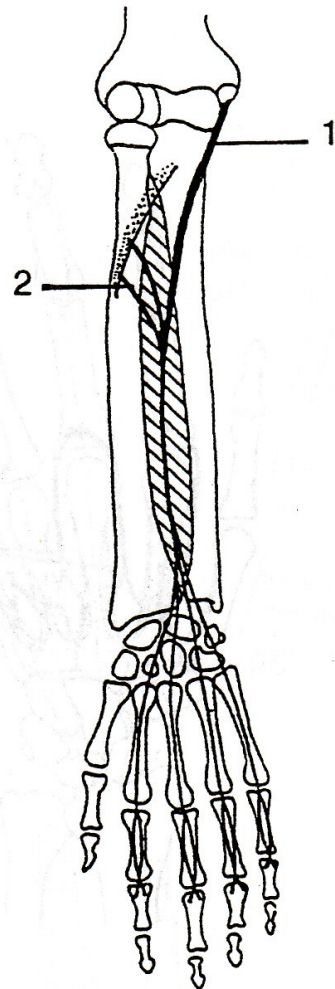
mm. Interossei palmares



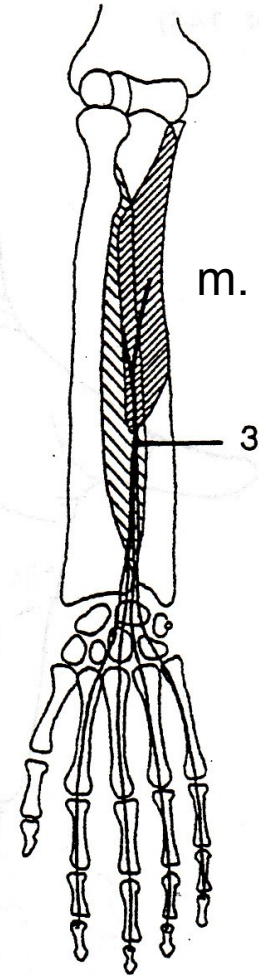
C



m. flexor digitorum superficialis

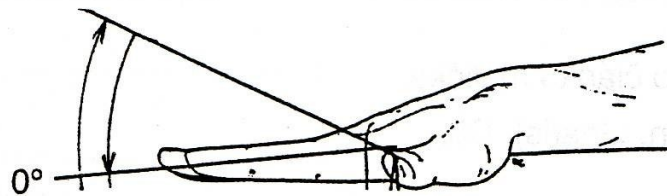


m. flexor digitorum profundus



# EXTENZE - NATAŽENÍ

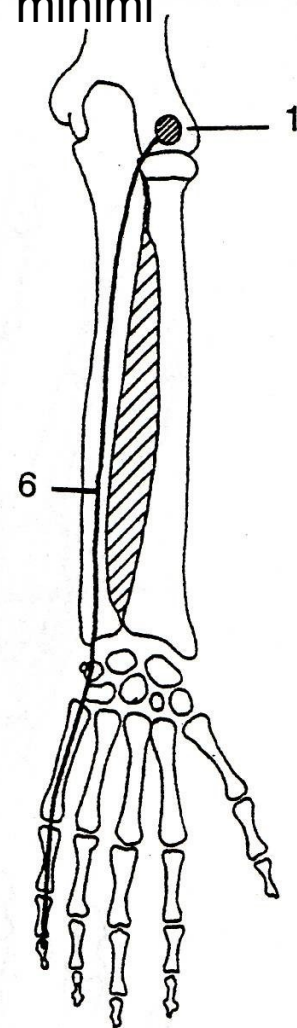
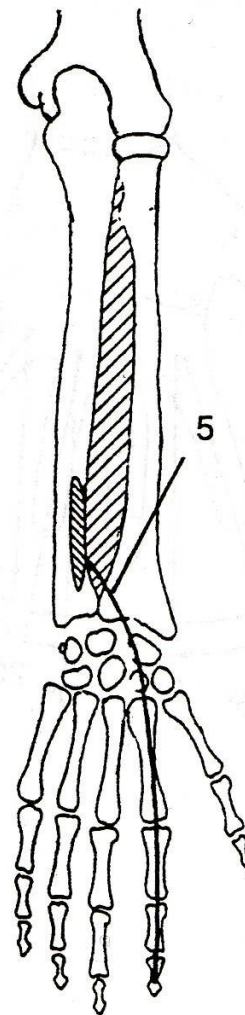
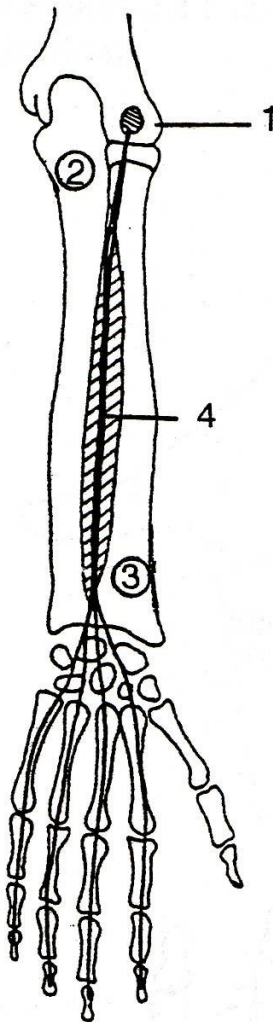
20° - 30°



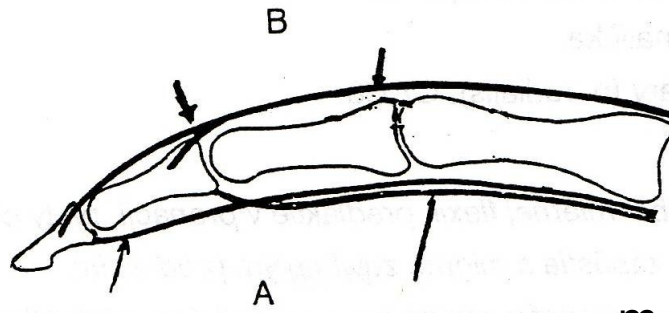
m. extensor indicis

m. extensor digiti  
minimi

m. extensor digitorum



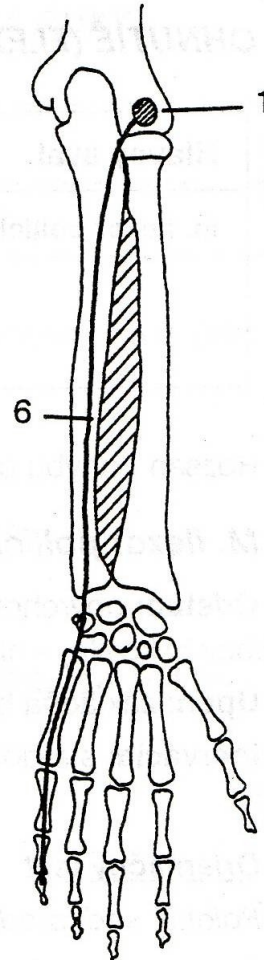
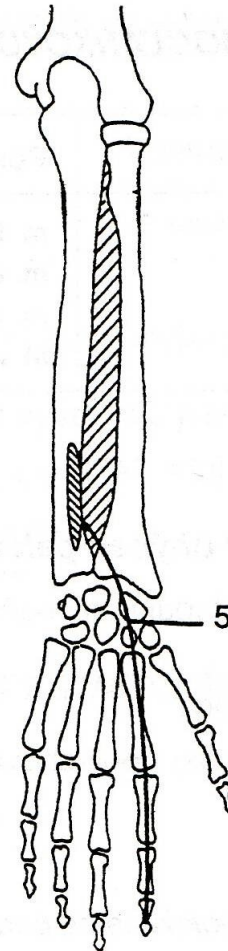
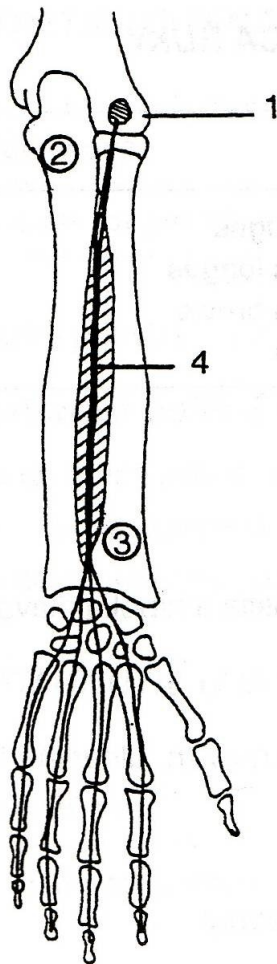


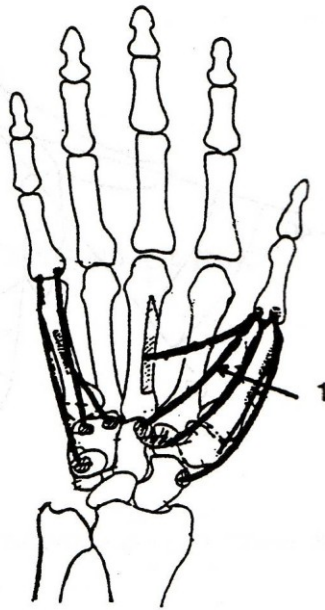
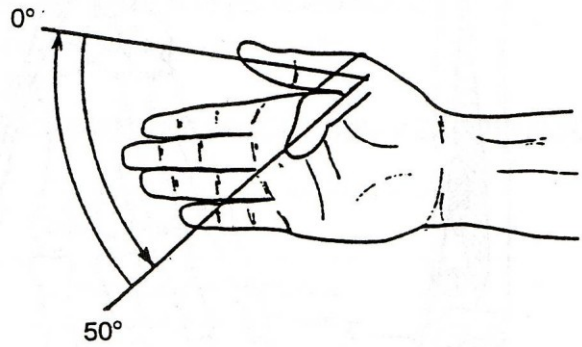


m. extensor indicis

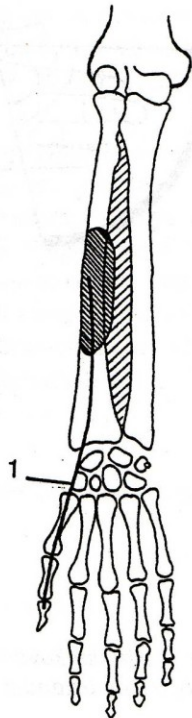
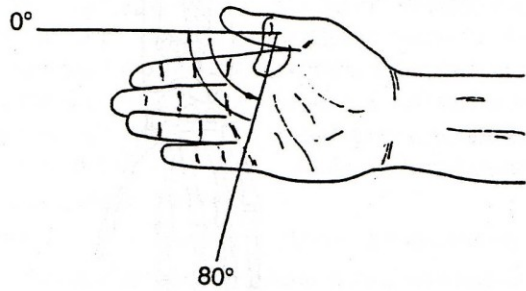
m. extensor digiti  
minimi

m. extensor digitorum

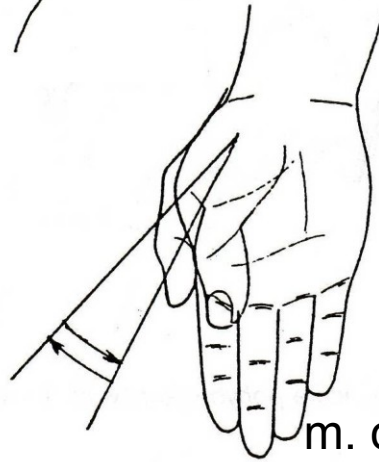




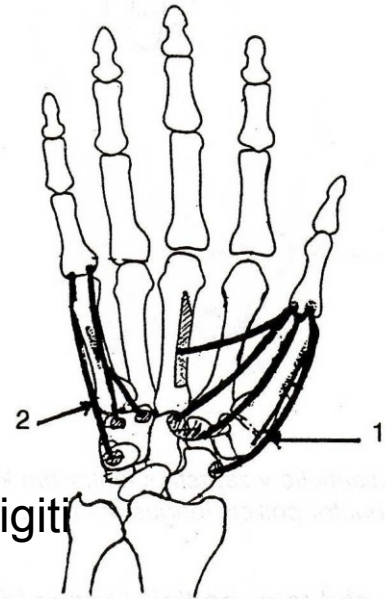
m. flexor pollicis brevis



m. flexor pollicis longus



m. opponens digiti  
minimi



m. opponens pollicis