

POHYBY DOLNÍCH KONČETIN



POHYBY KYČELNÍHO KLOUBU

FLEXE - PŘEDNOŽENÍ

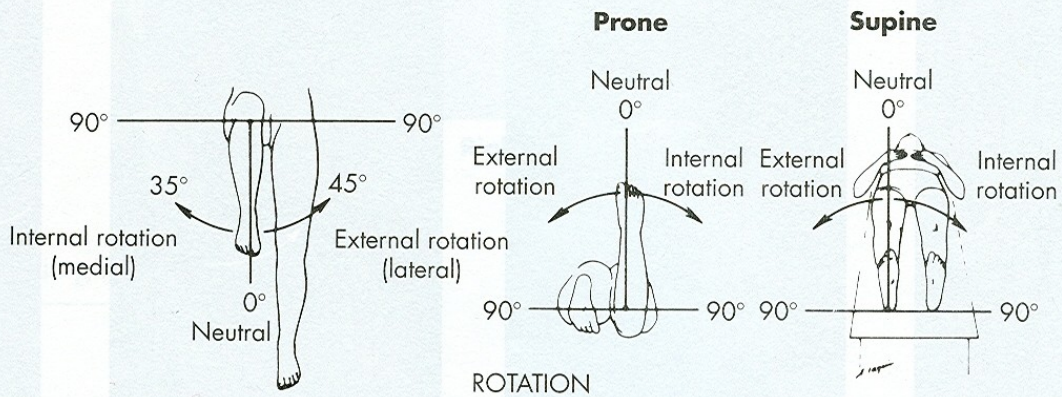
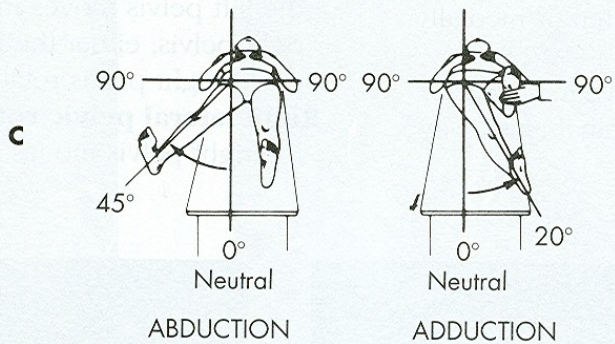
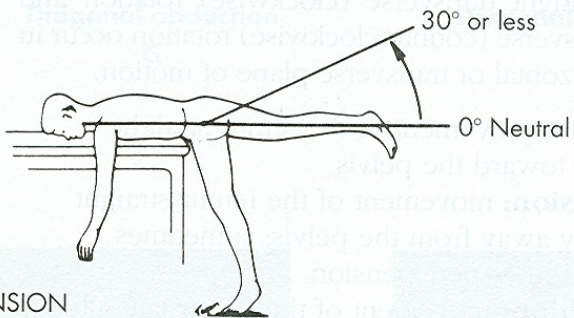
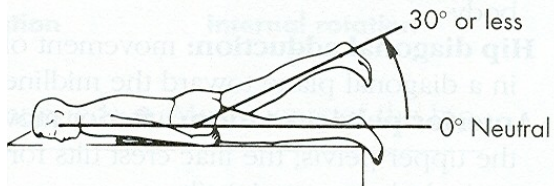
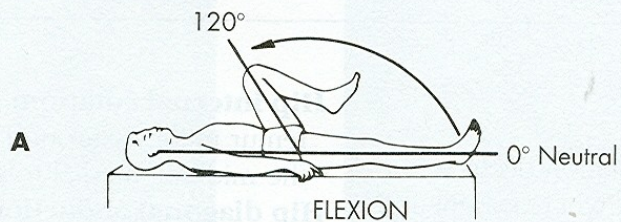
EXTENZE - ZANOŽENÍ

ABDUKCE - UNOŽENÍ

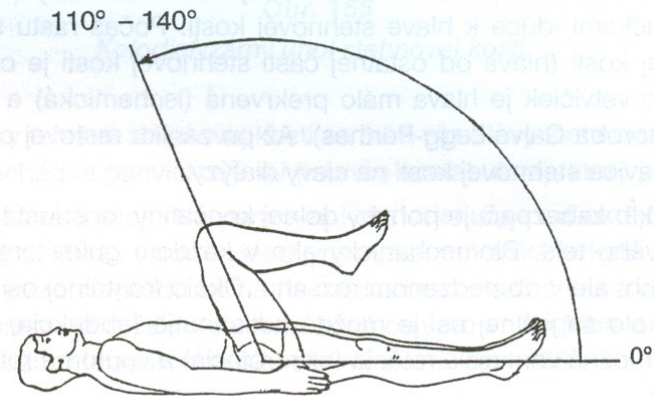
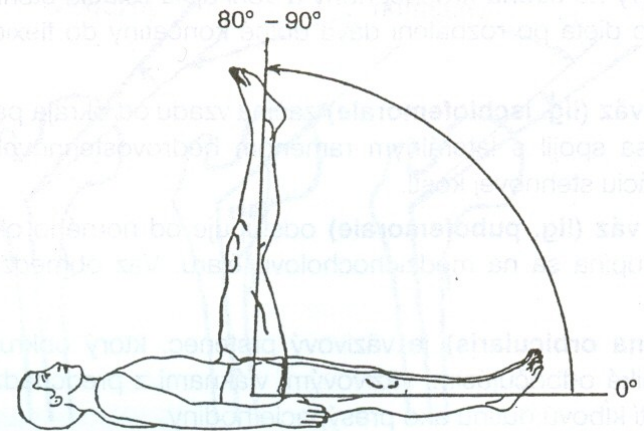
ADDUKCE - PŘINOŽENÍ

VNĚJŠÍ ROTACE

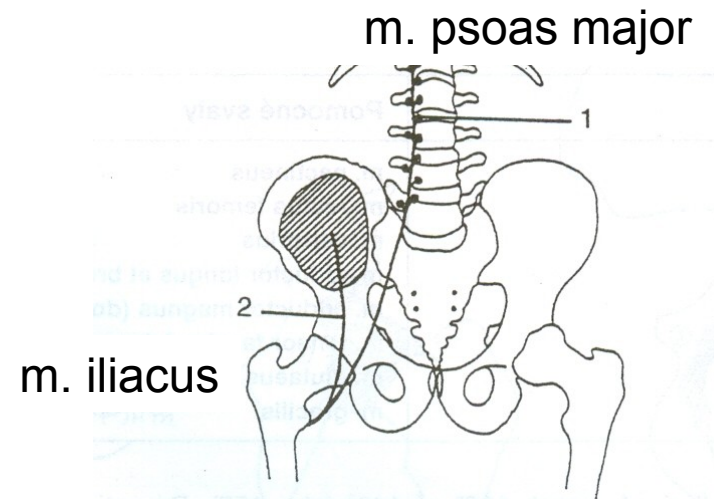
VNITŘNÍ ROTACE



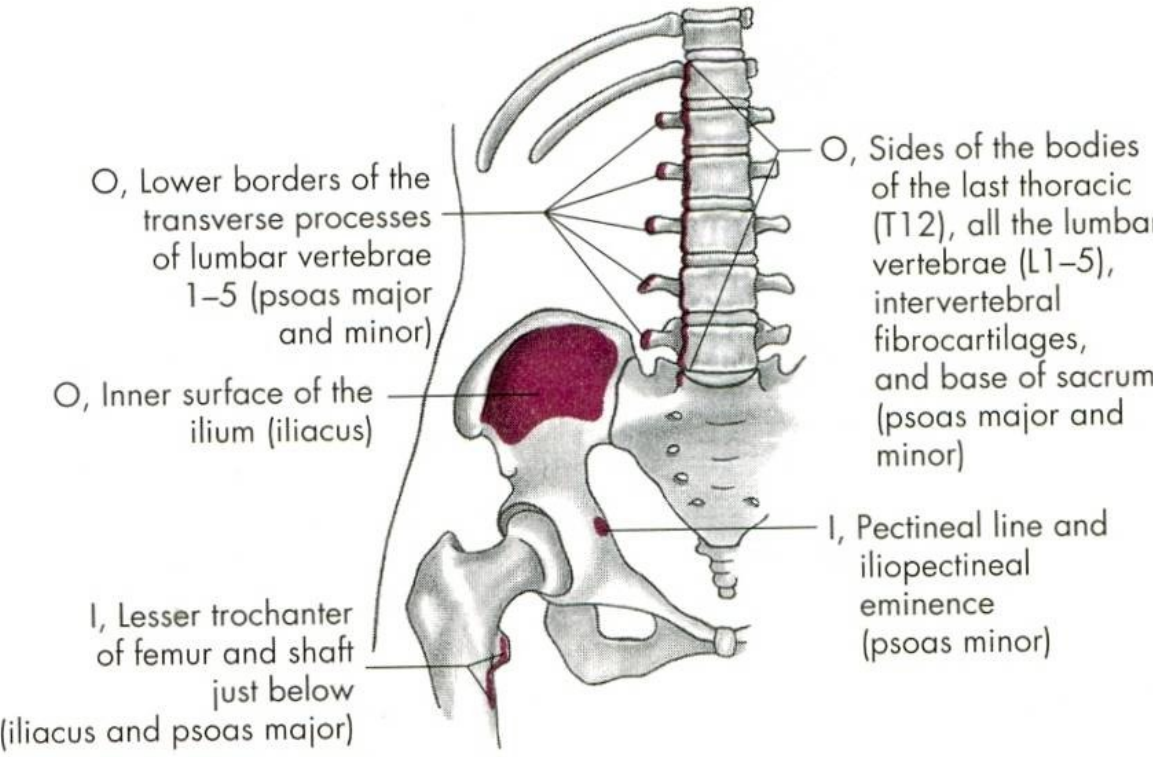
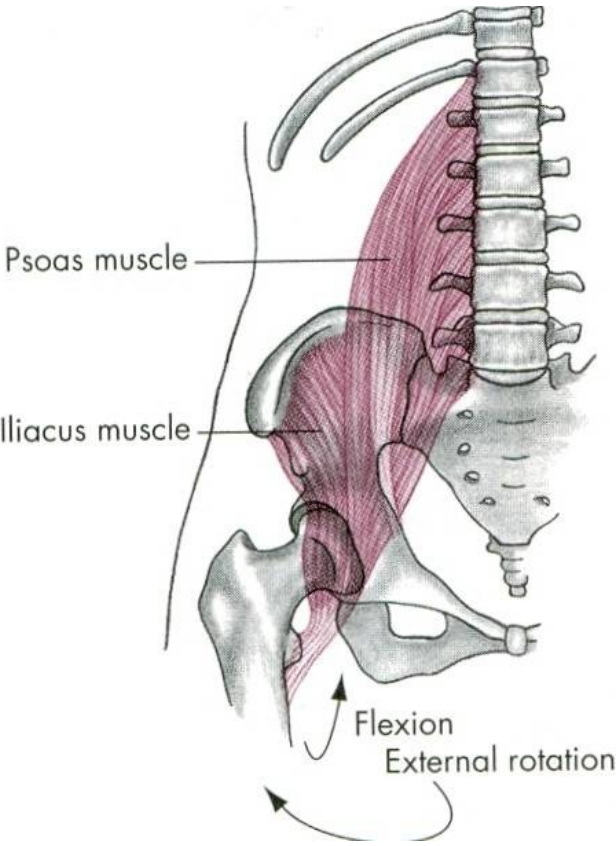
FLEXE - PŘEDNOŽENÍ



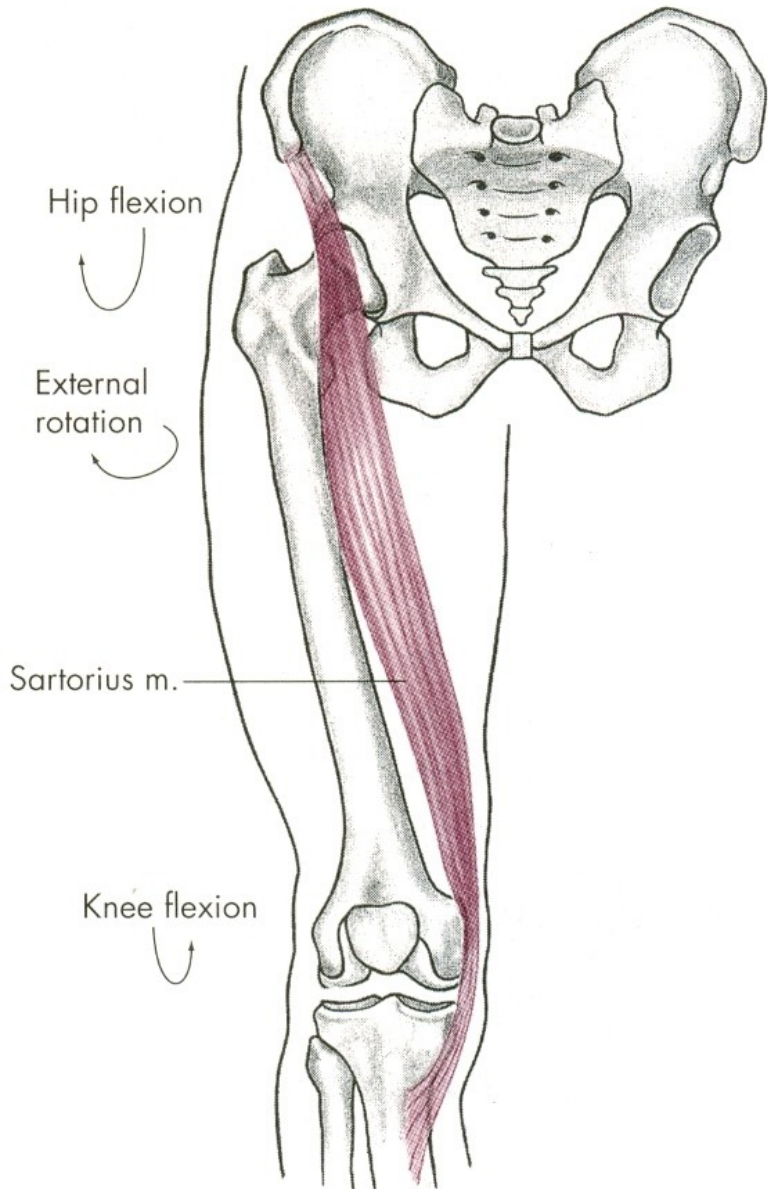
m. iliopsoas



m. iliopsoas

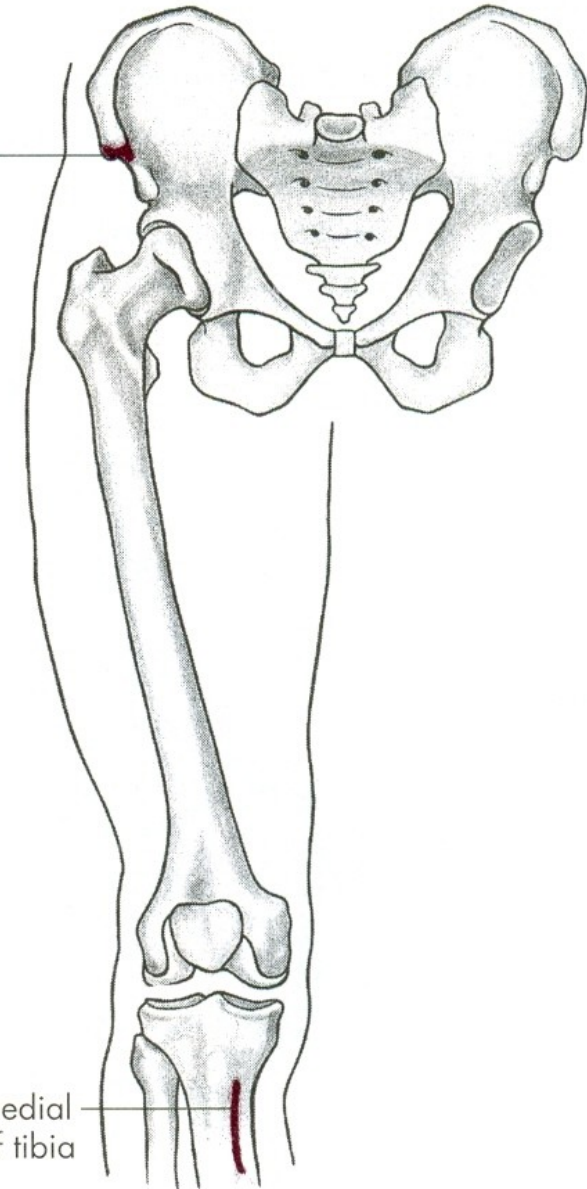


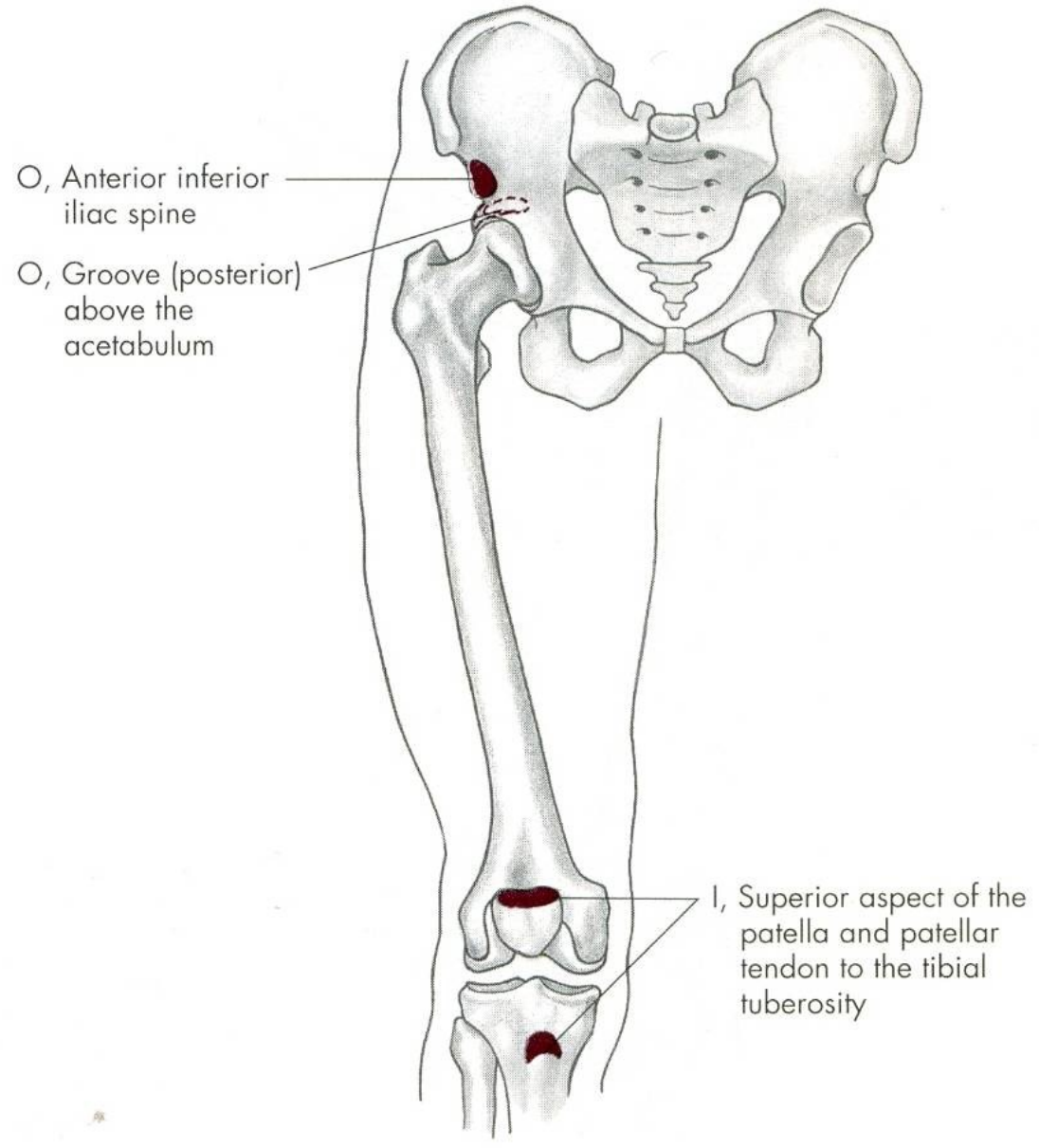
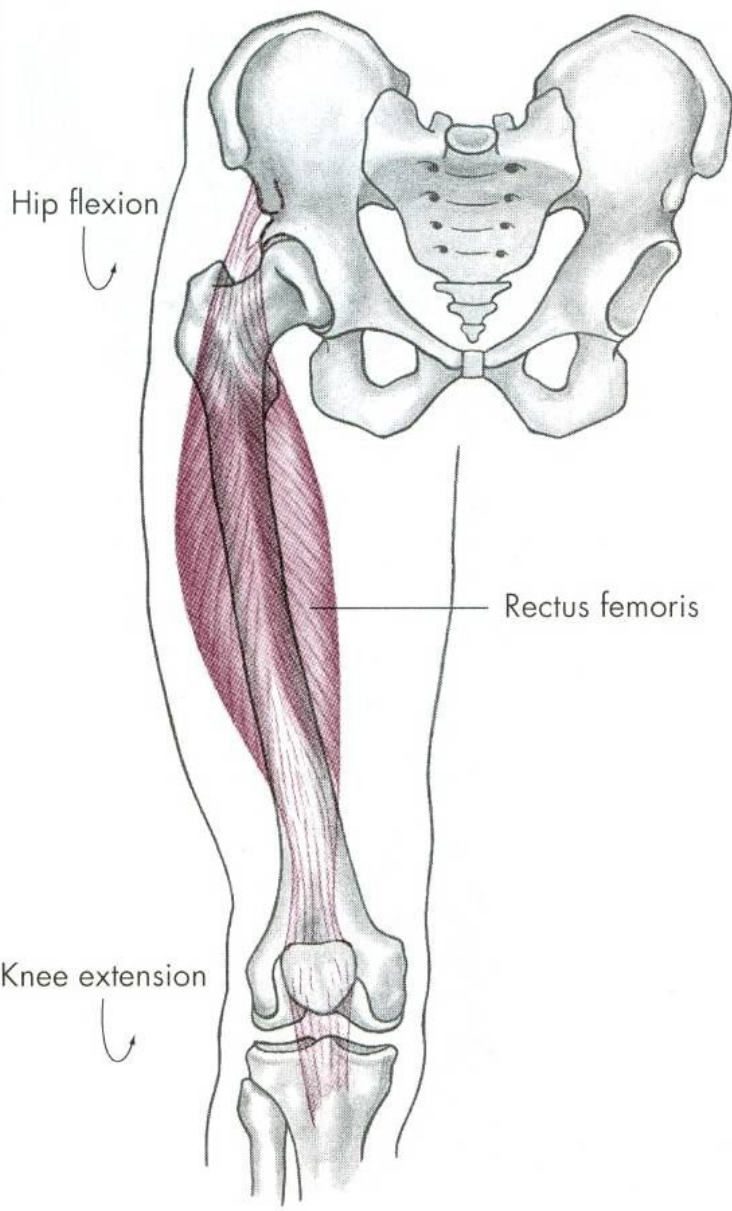
m. sartorius

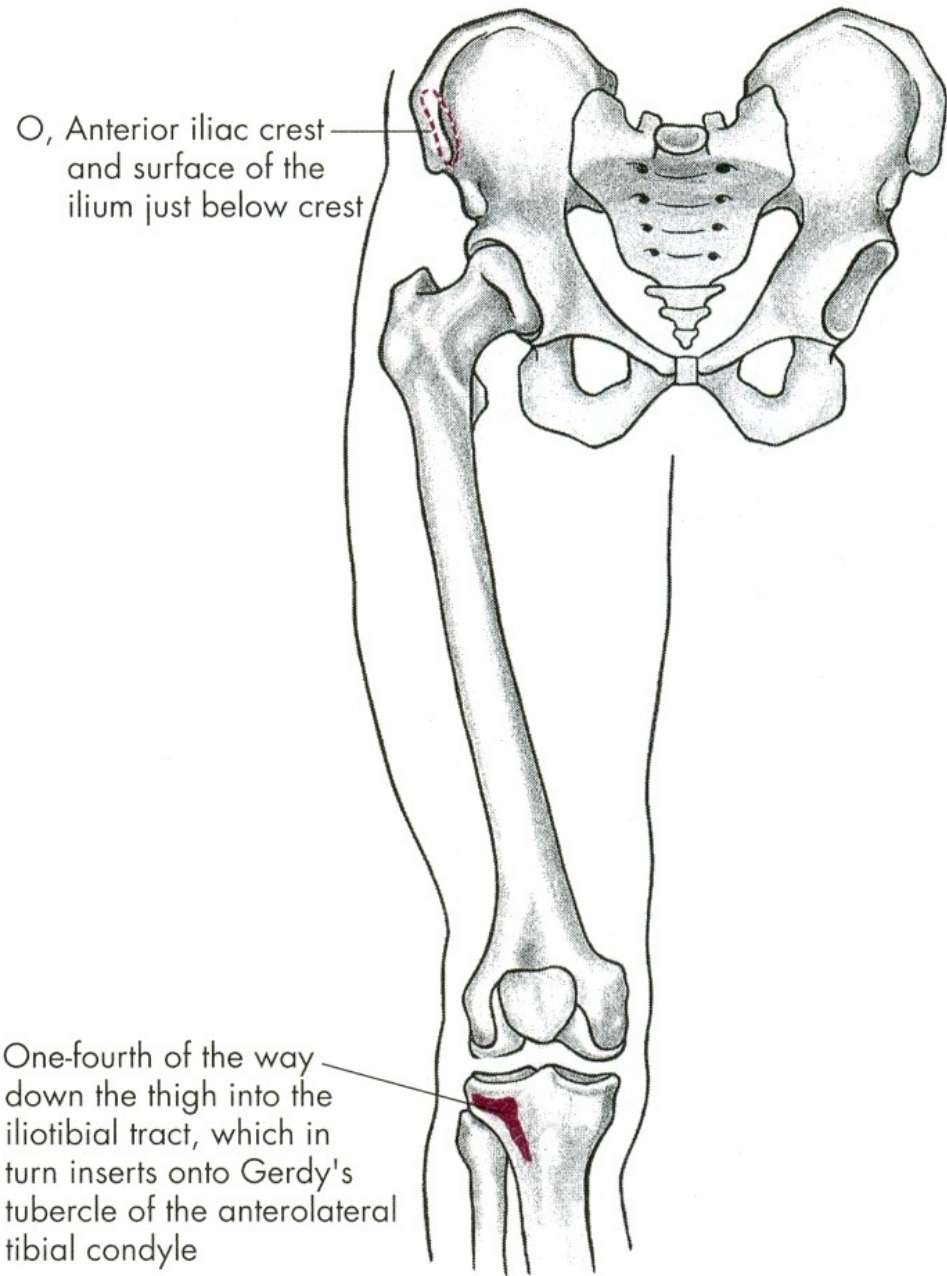
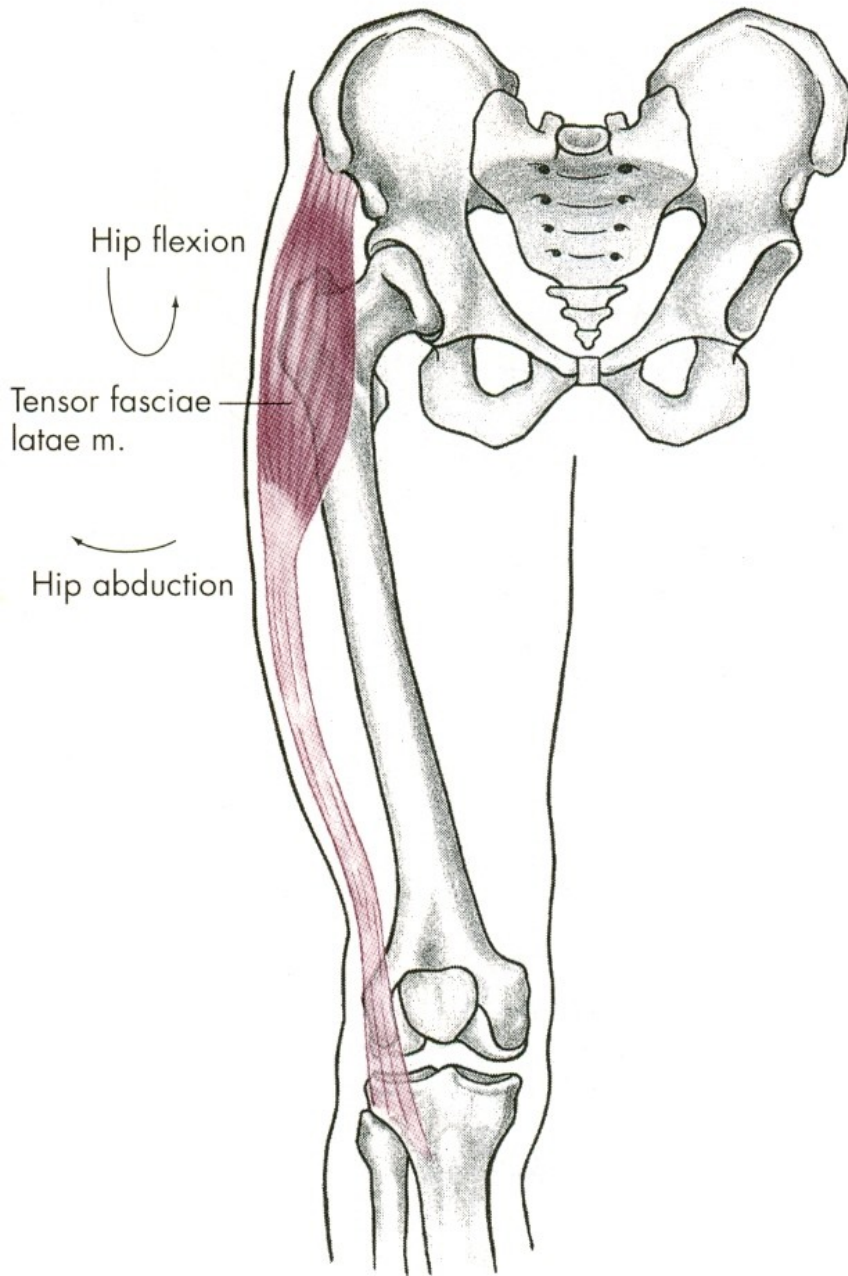


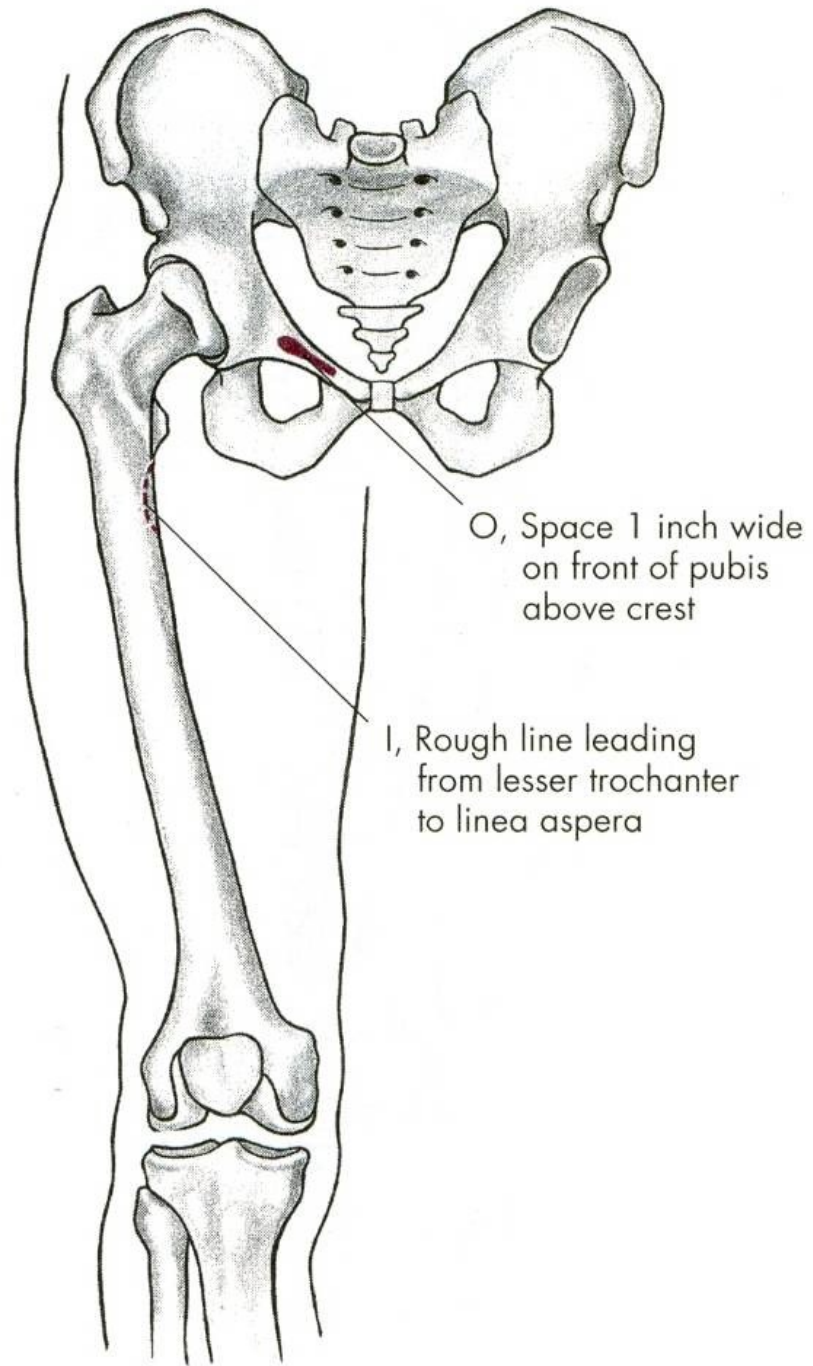
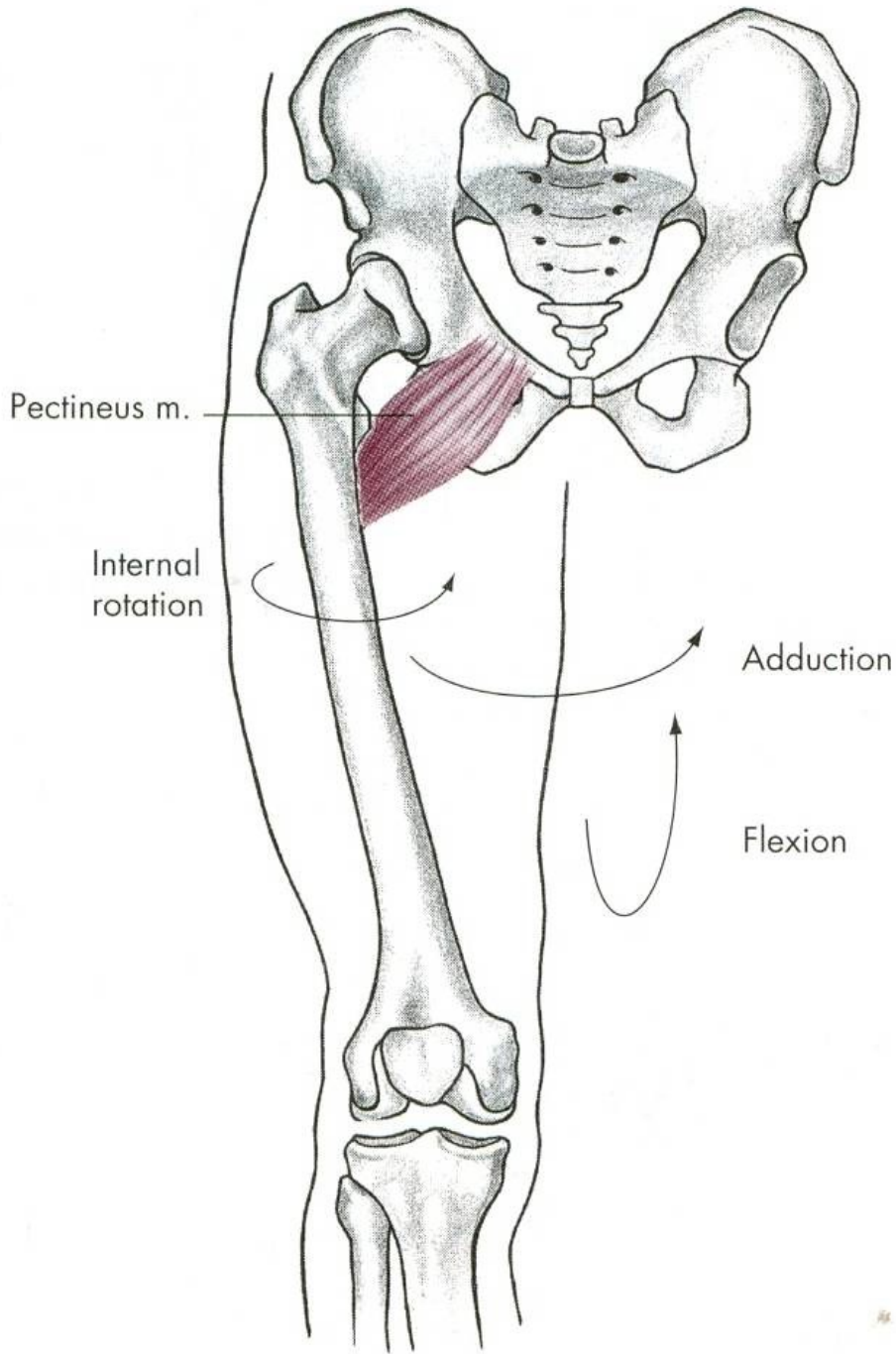
O, Anterior superior iliac spine and notch just below spine of ilium

I, Anterior medial condyle of tibia









FLEXE

m. iliopsoas – sval bedrokyčlostehenní

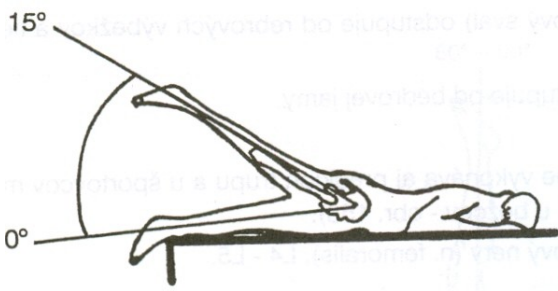
m. rectus femoris –
přímá hlava čtyřhlavého svalu stehenního

m. pectineus – sval hřebenový

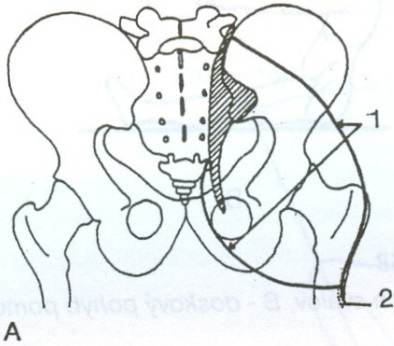
m. sartorius – sval krejčovský

m. gracilis – štíhlý sval stehenní

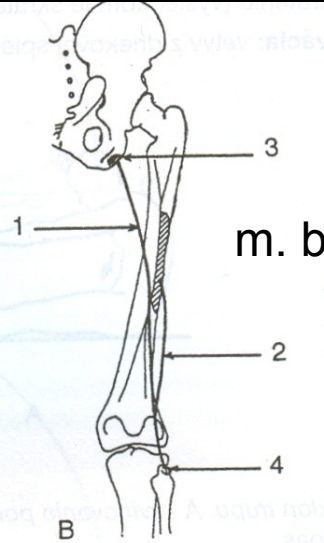
EXTENZE - ZANOŽENÍ



m. gluteus maximus

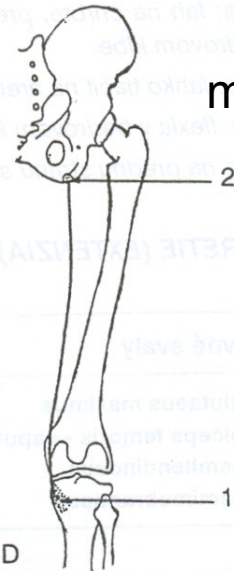


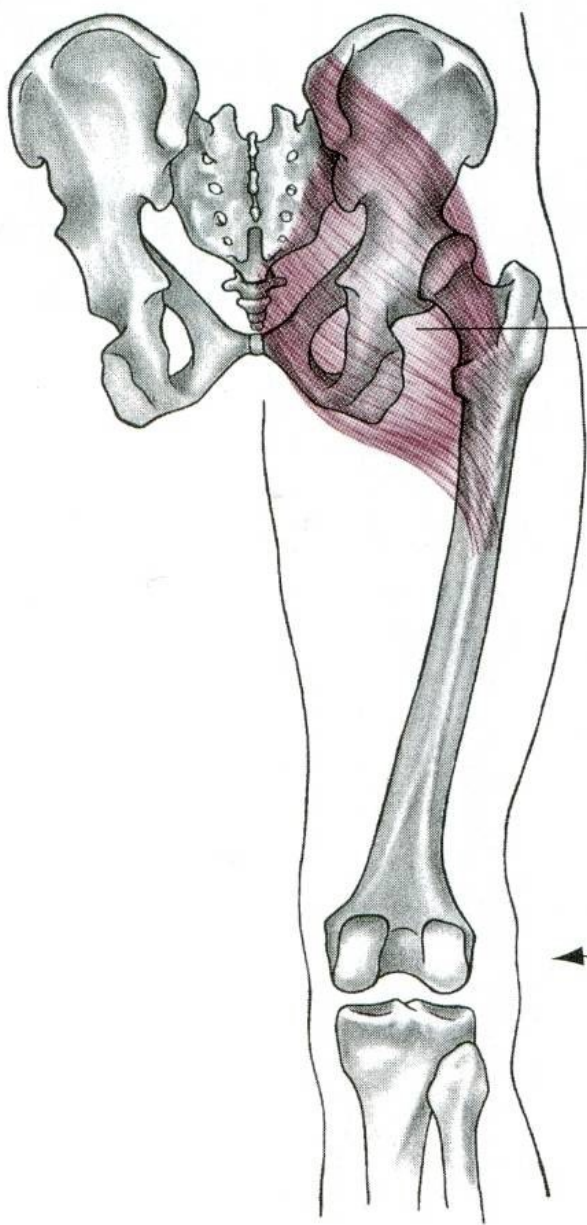
m. semimembranosus



m. biceps femoris

m. semitendinosus

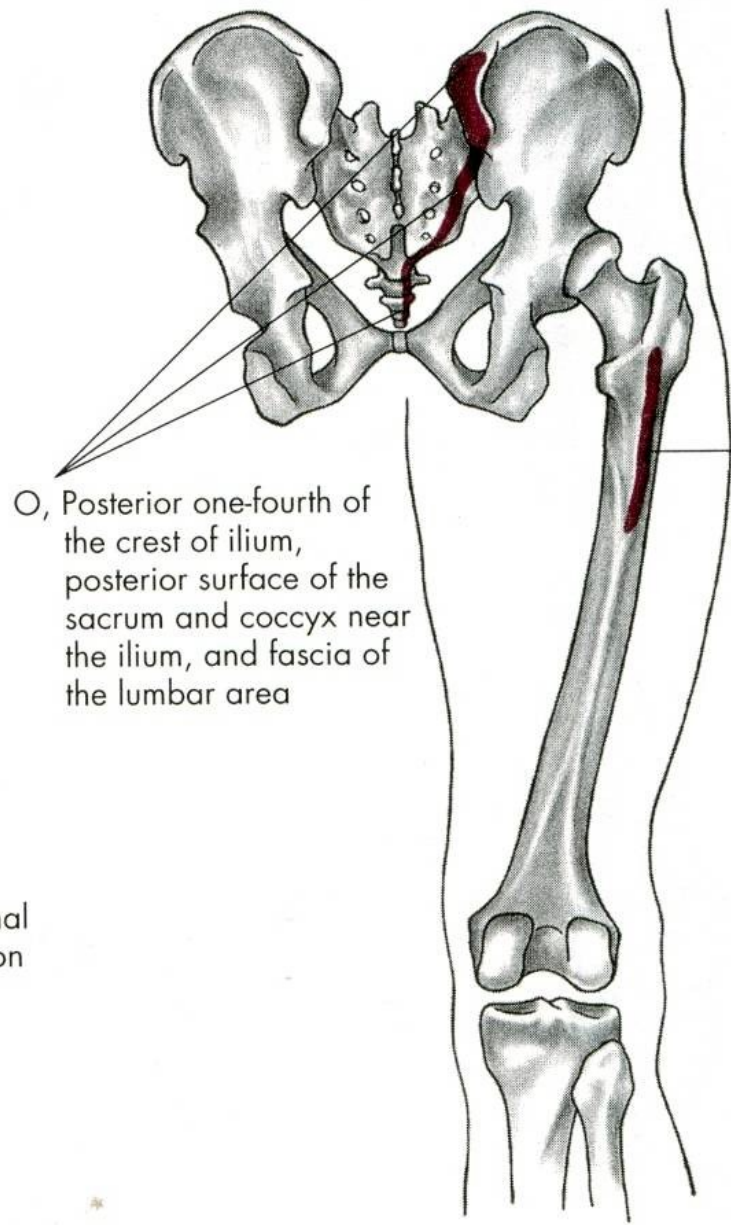




Gluteus maximus

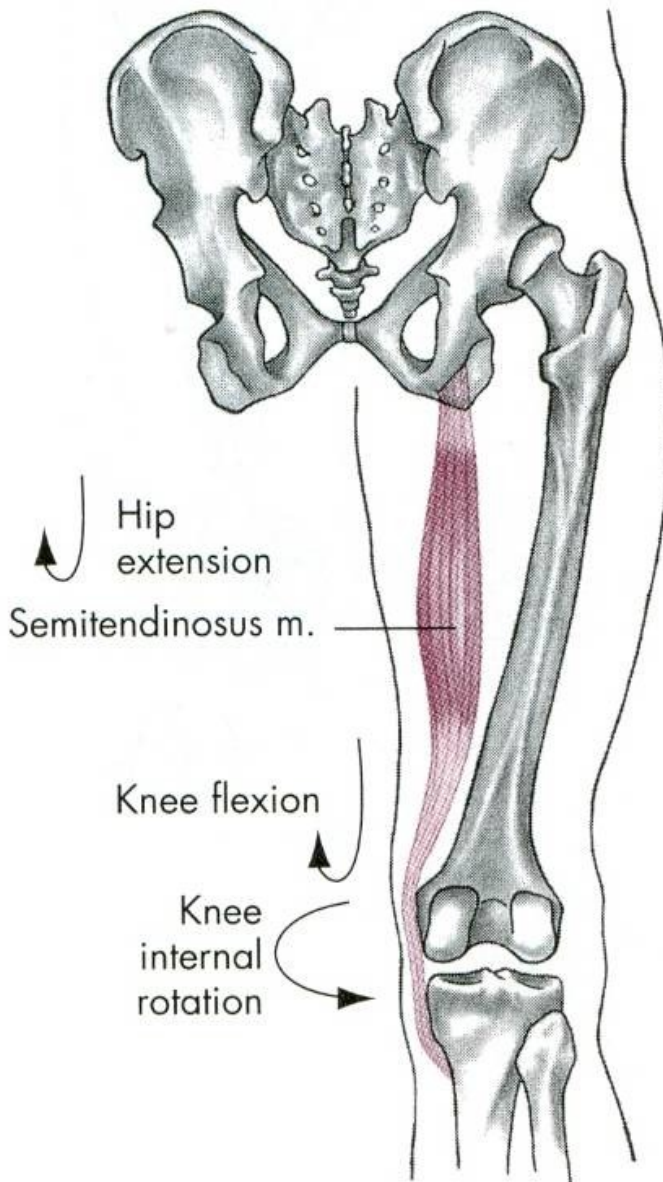
↘ Extension

↶ External rotation

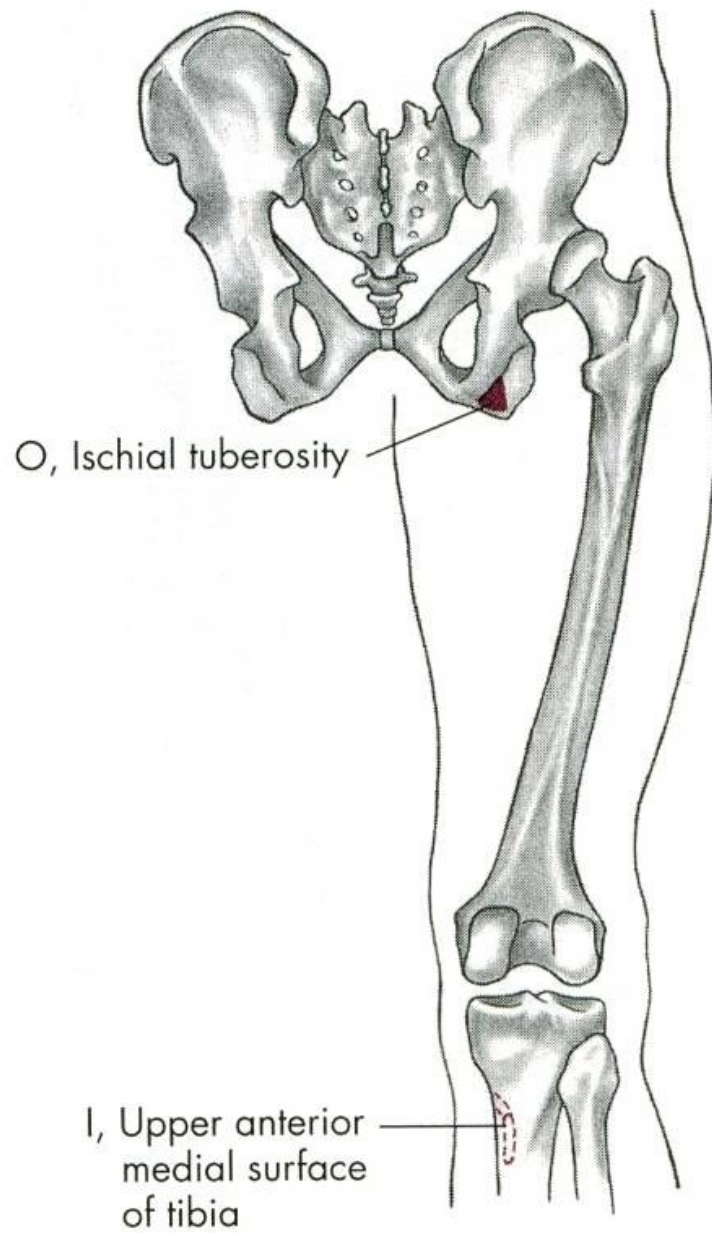


○, Posterior one-fourth of the crest of ilium, posterior surface of the sacrum and coccyx near the ilium, and fascia of the lumbar area

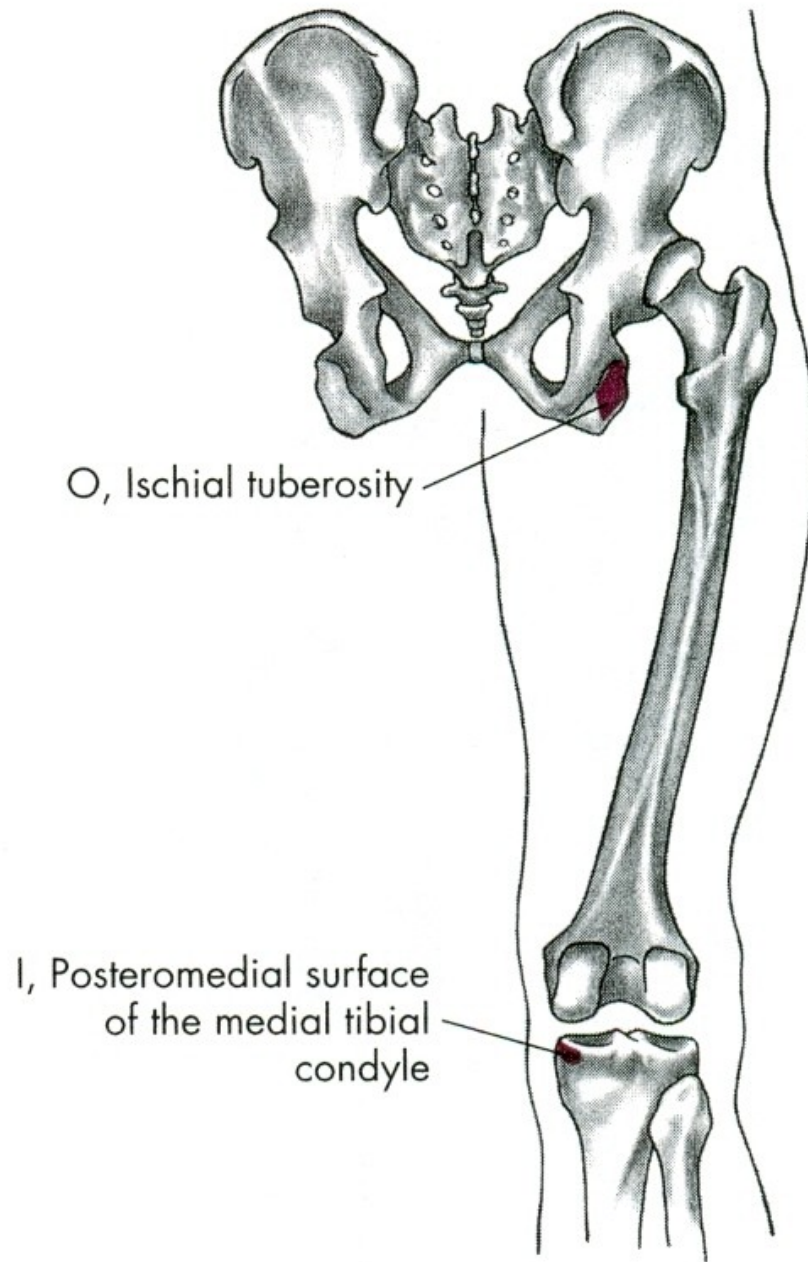
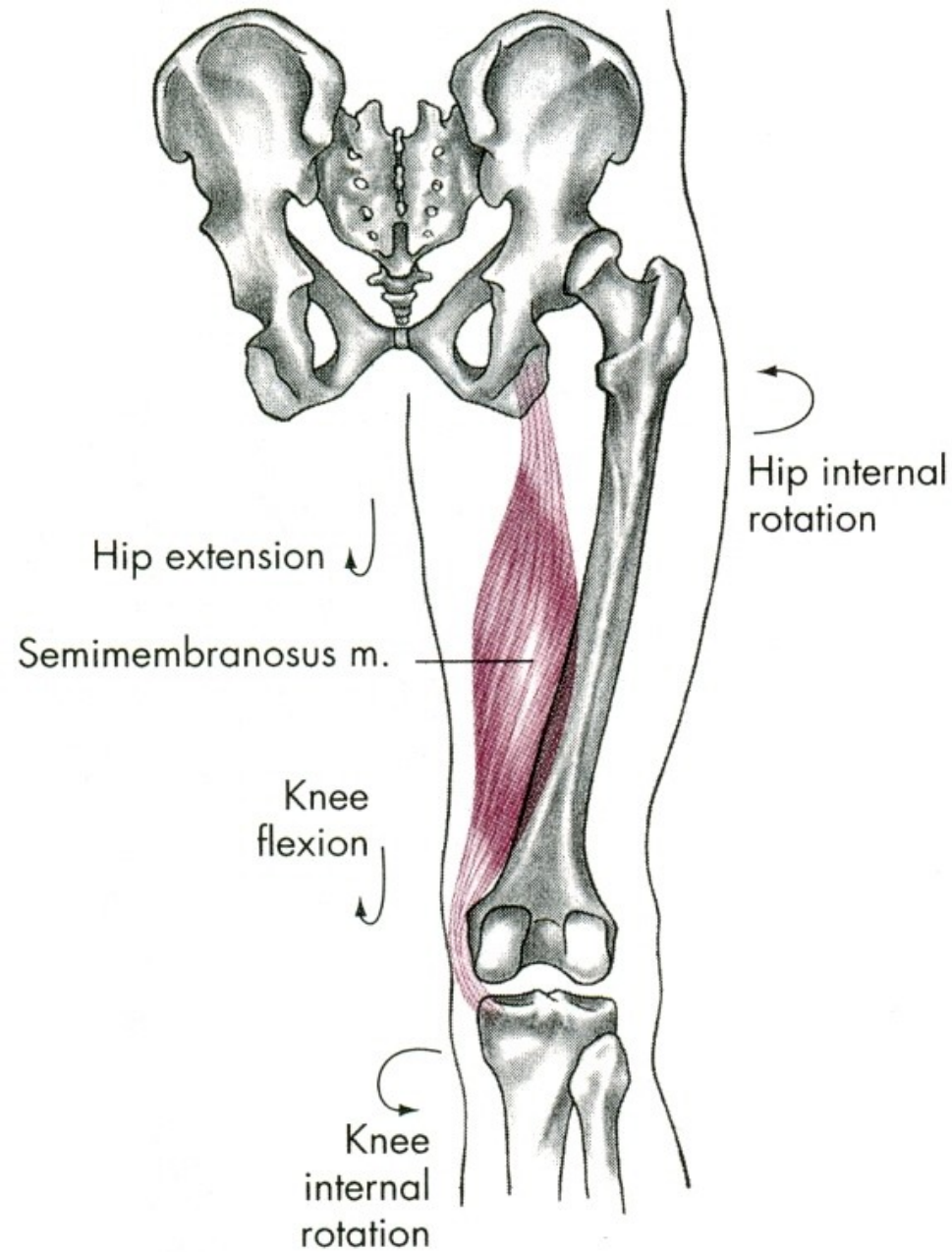
I, Oblique ridge on lateral surface of the greater trochanter and iliotibial band of fascia latae

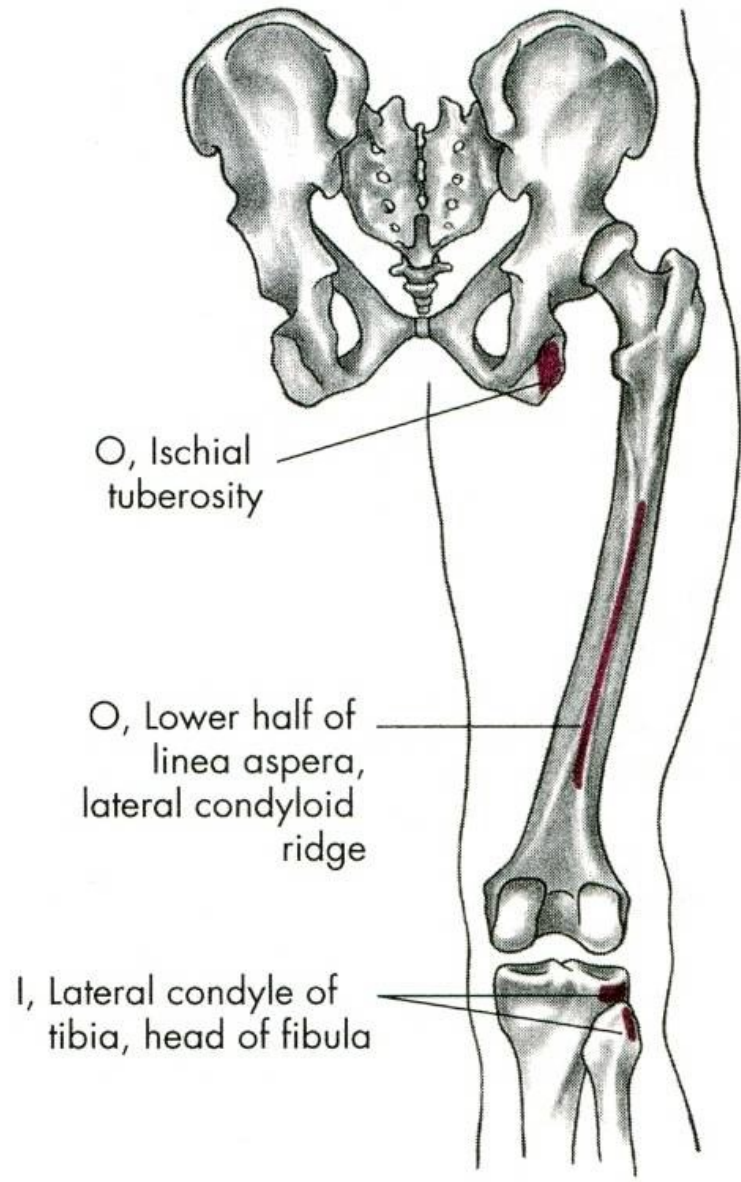
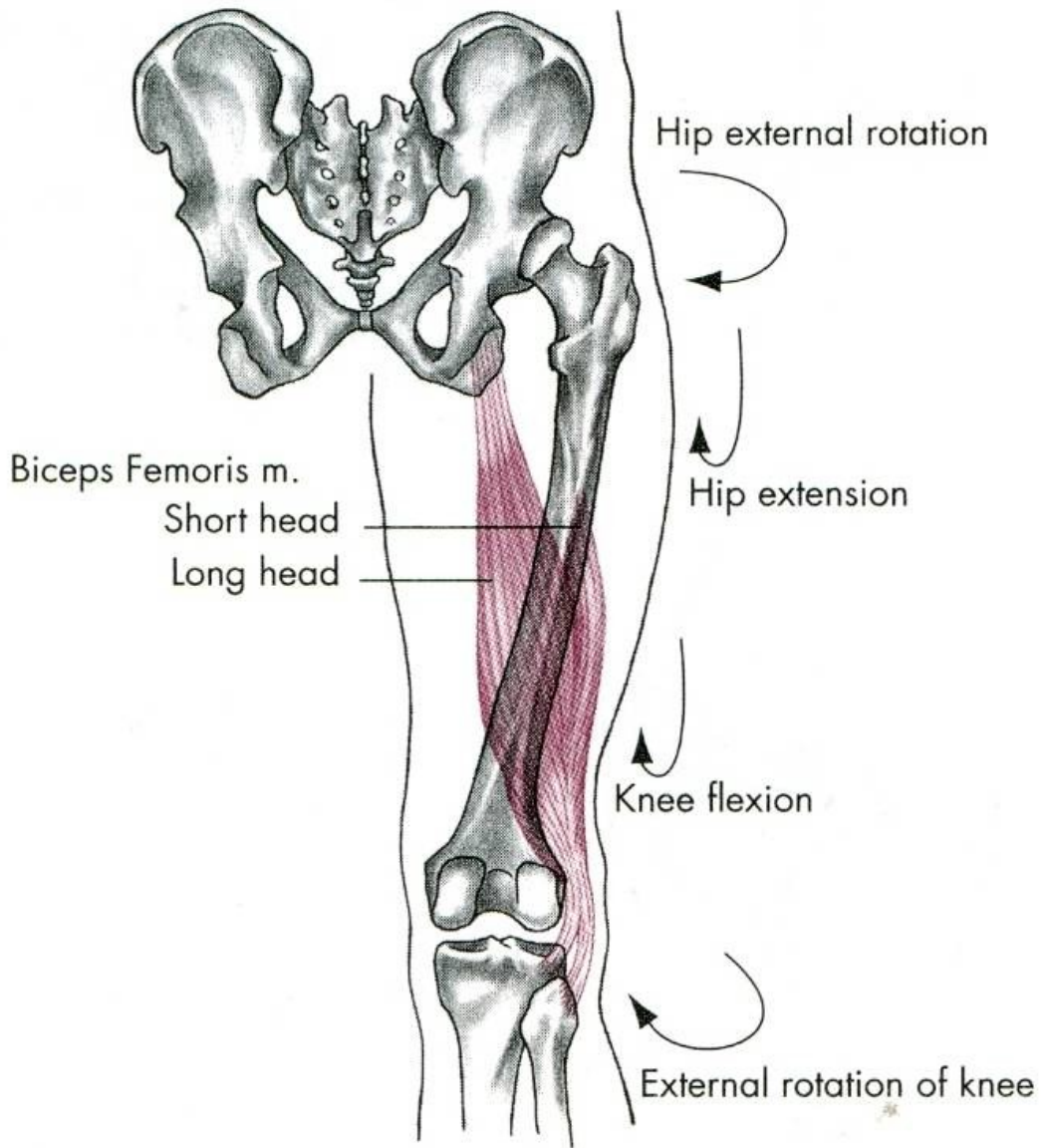


Hip internal rotation



I, Upper anterior medial surface of tibia





EXTENZE

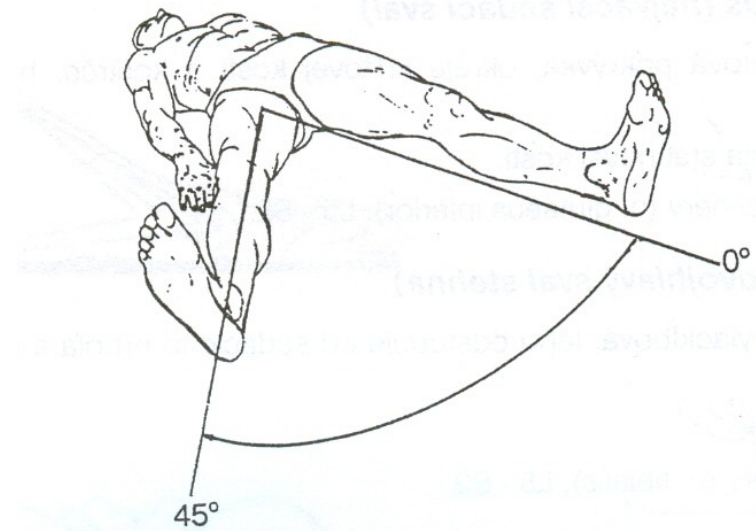
m. gluteus maximus – velký sval hýžd'ový

m. biceps femoris – dvojhlavý sval stehenní

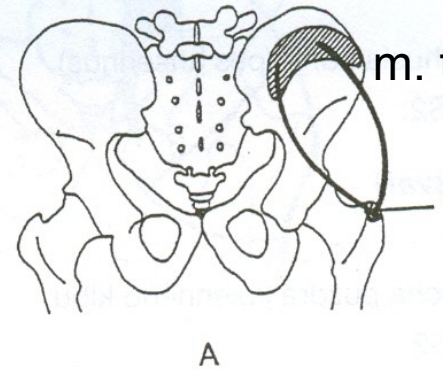
m. semitendinosus – sval pološlašitý

m. semimembranosus – sval poloblanitý

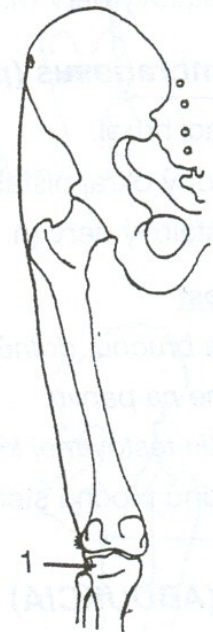
ABDUKCE - UNOŽENÍ



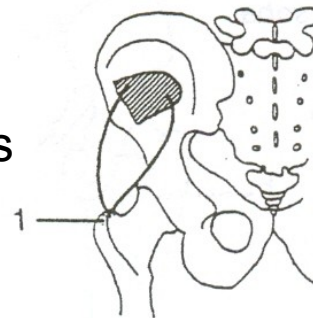
m. gluteus medius

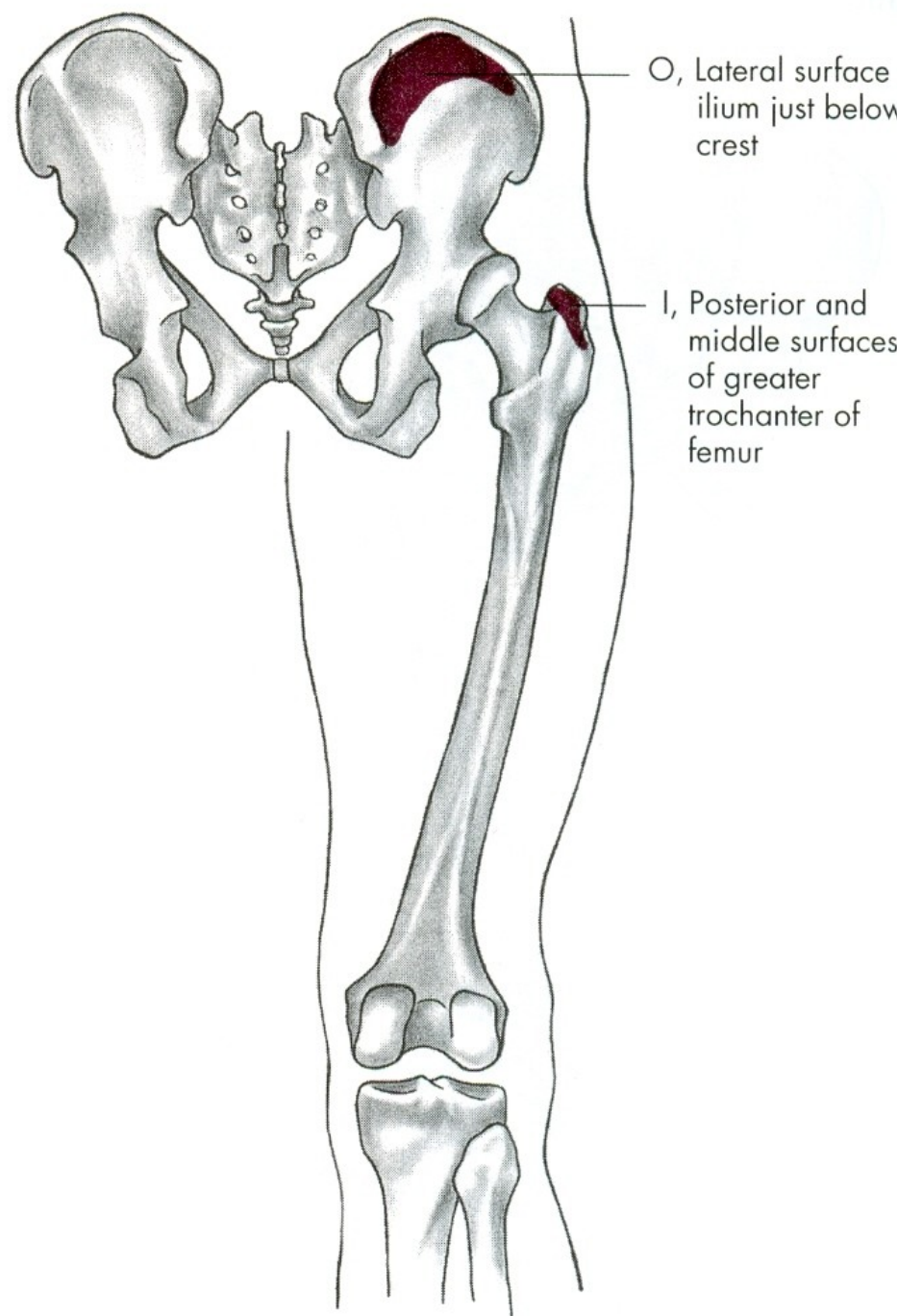
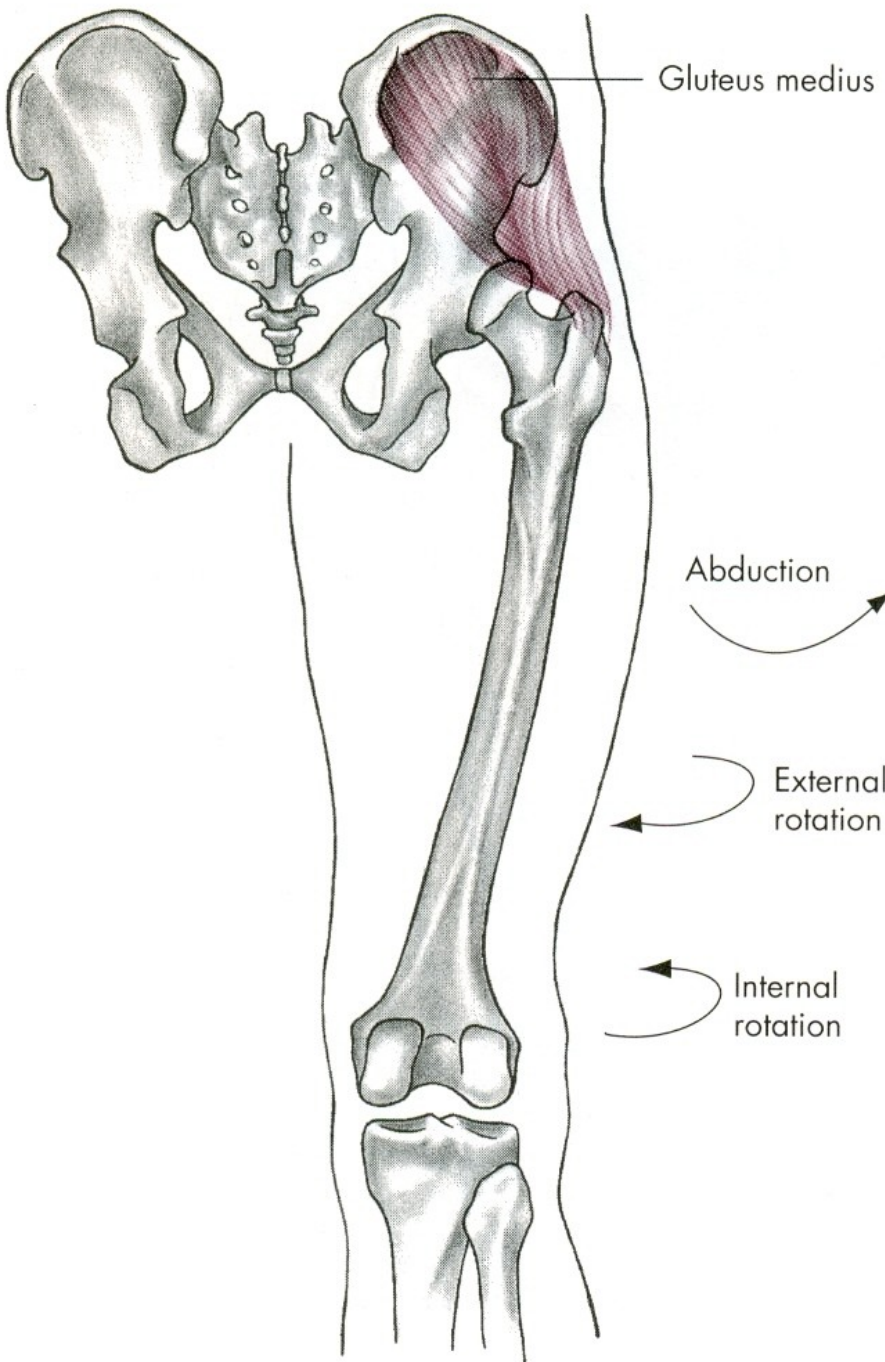


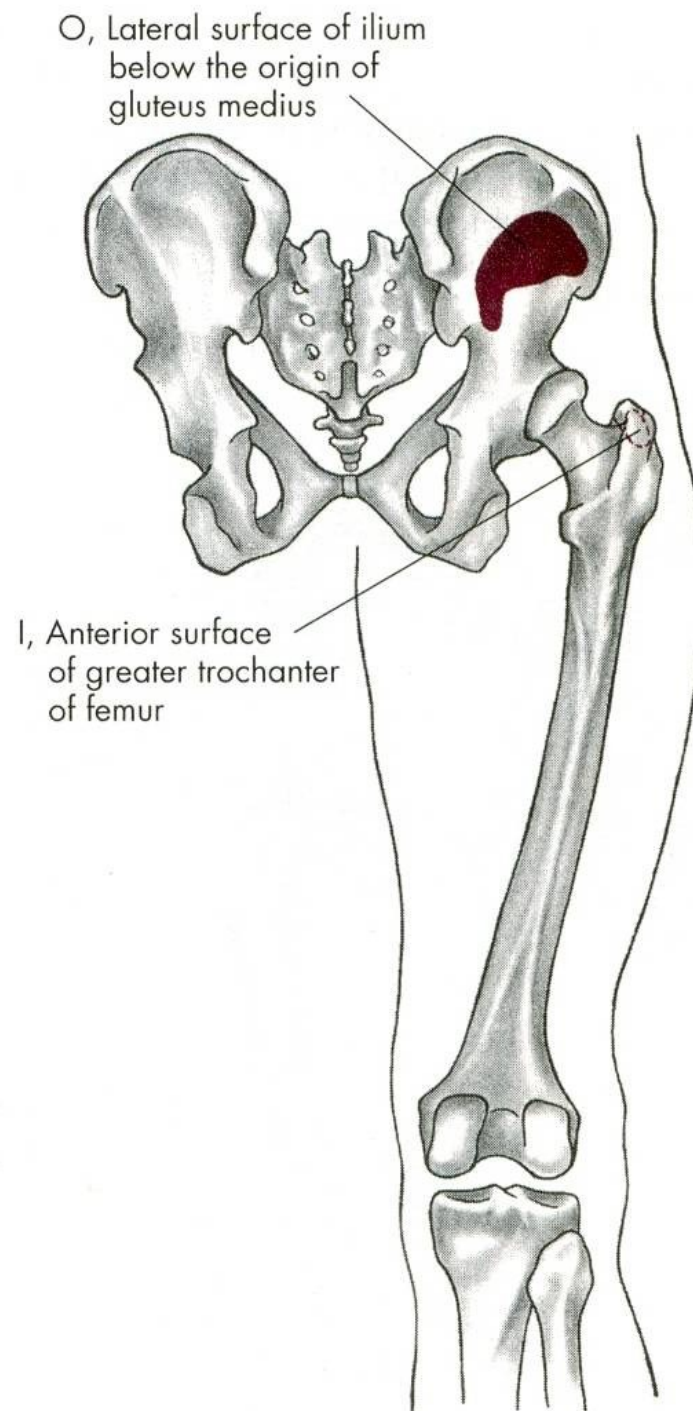
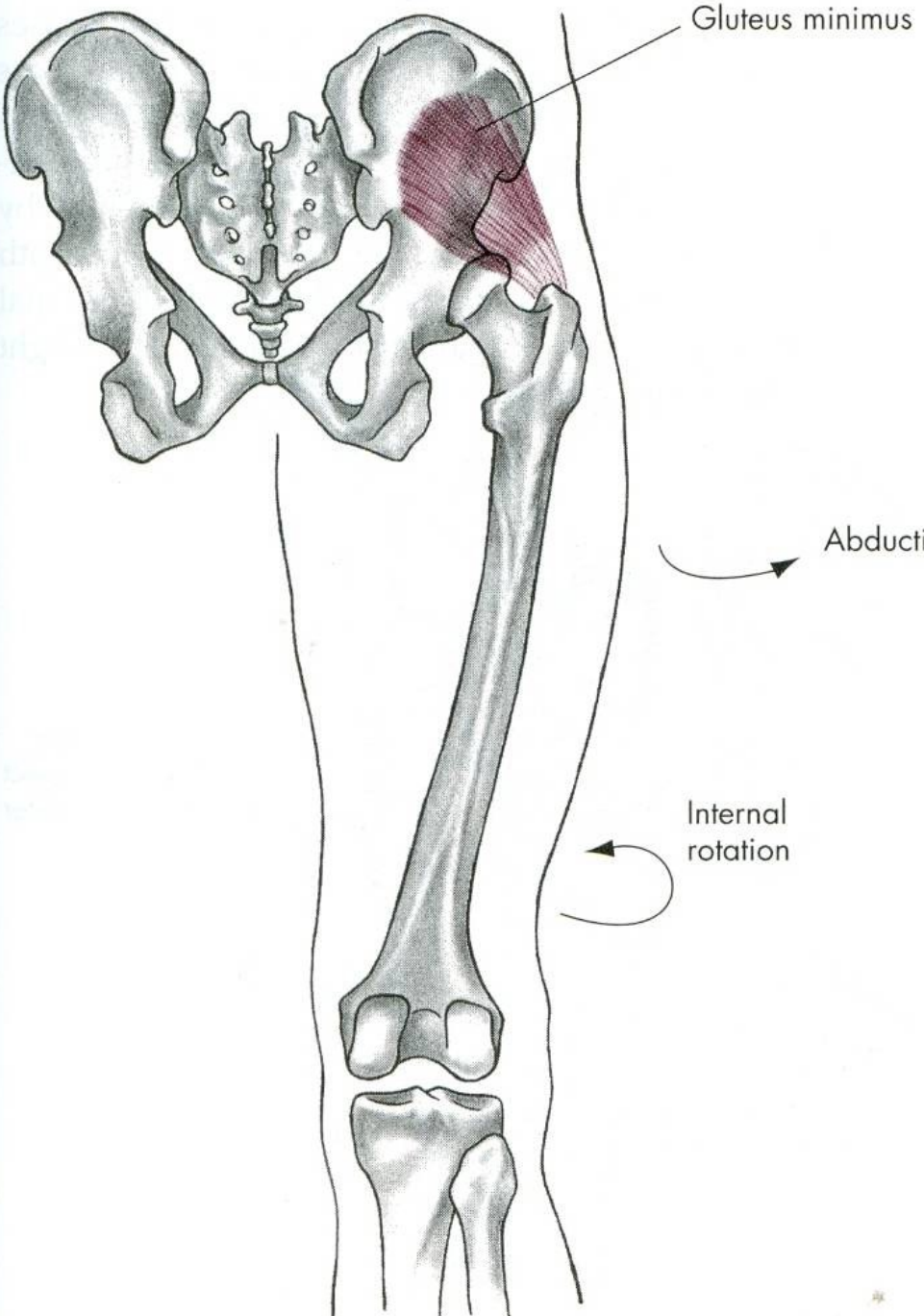
m. tensor fasciae latae



m. gluteus minimus







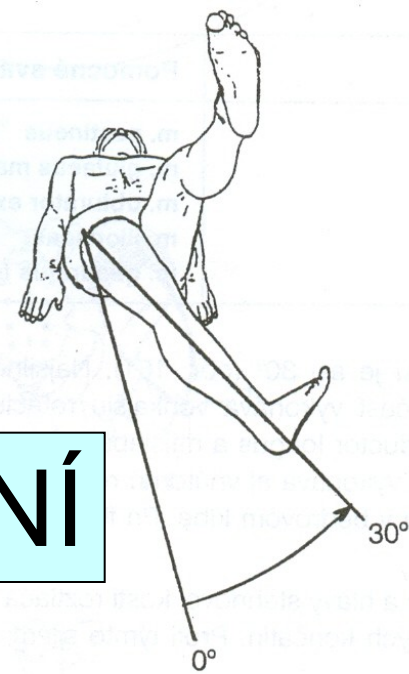
ABDUKCE

m. gluteus medius – střední sval hýžd'ový

m. gluteus minimus – malý sval hýžd'ový

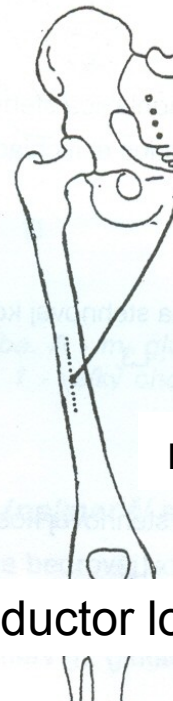
m. tensor fasciae latae –
napínač stehenní povázky

ADDUKCE - PŘINOŽENÍ




m. gracilis

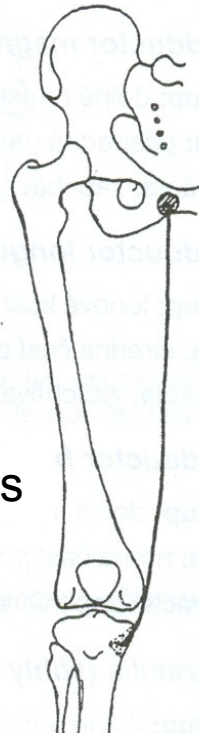
m. adductor magnus

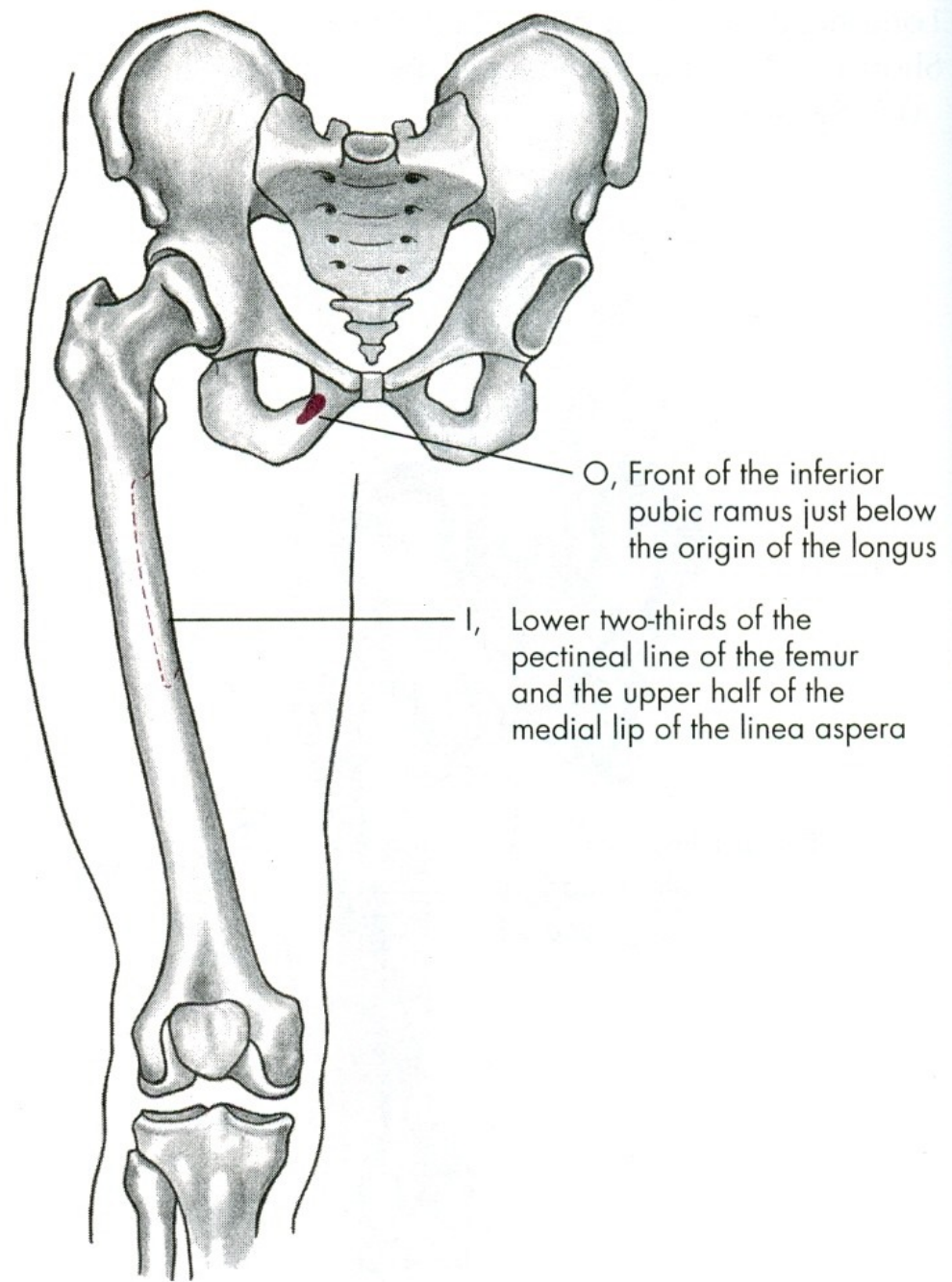
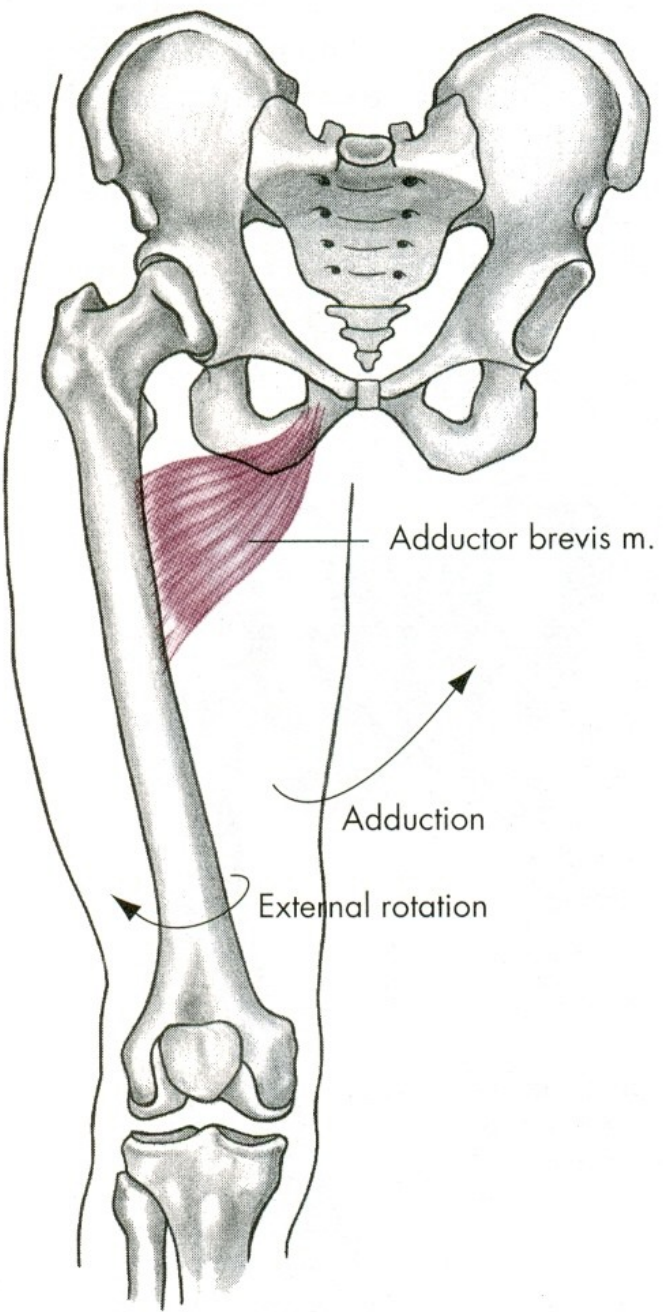


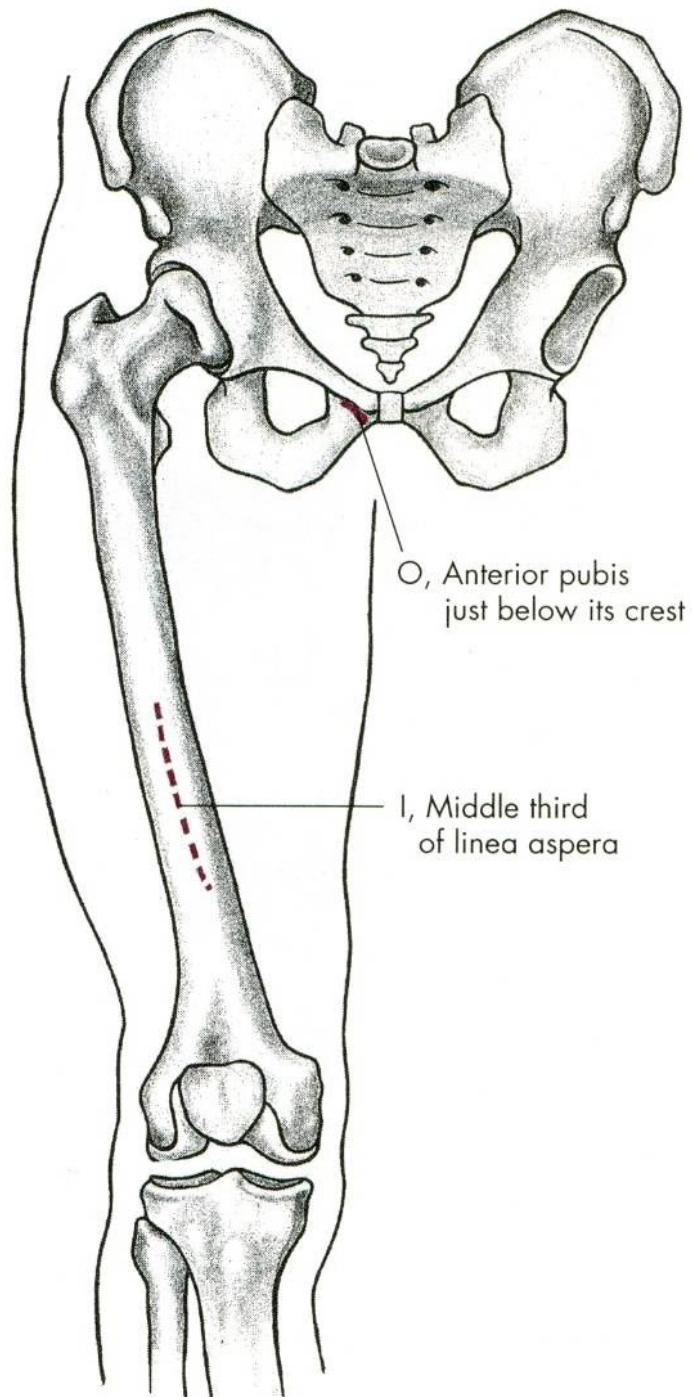
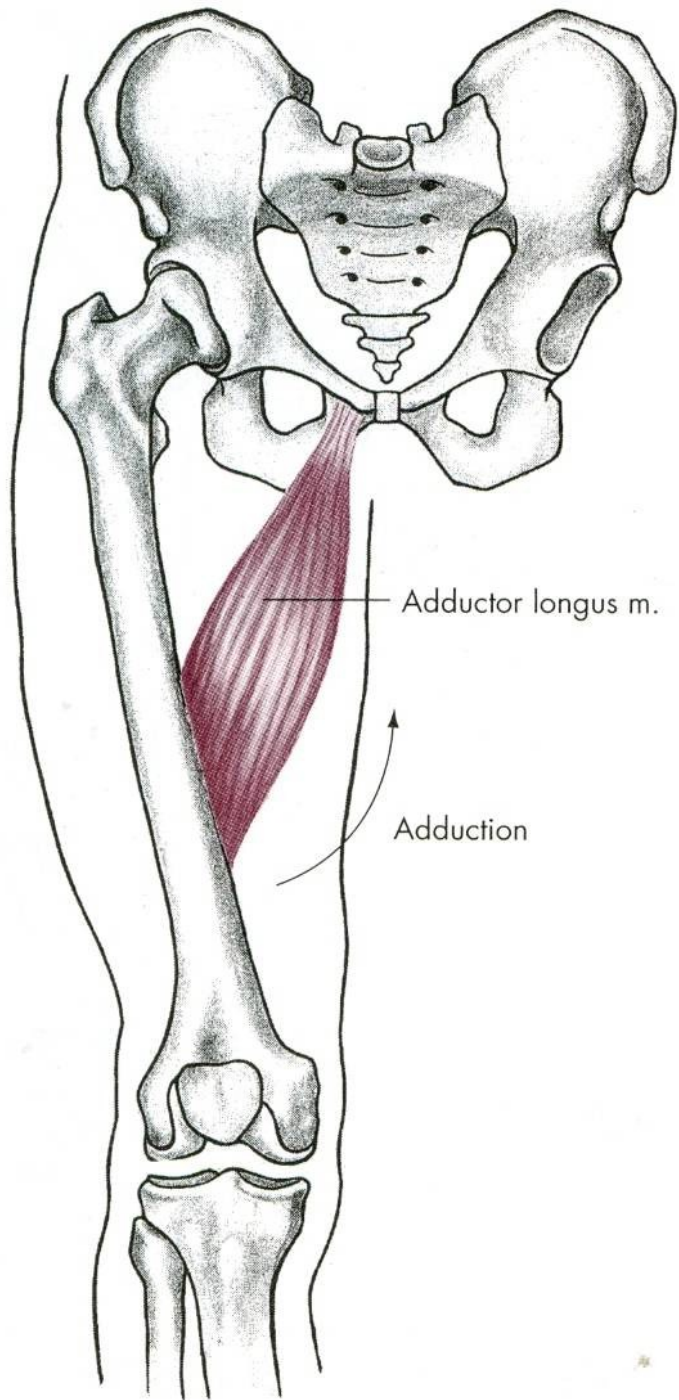
m. adductor longus

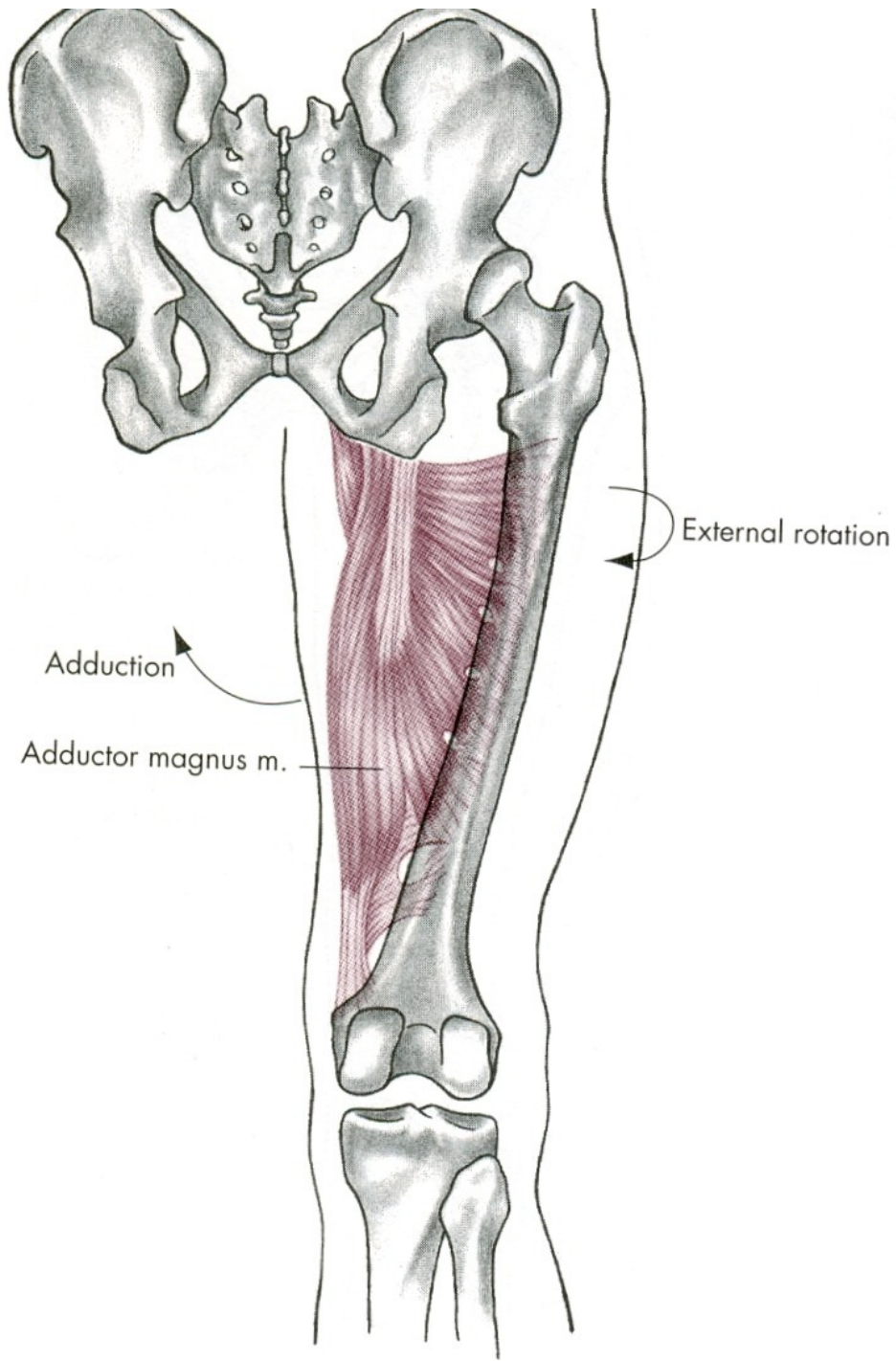


m. adductor brevis



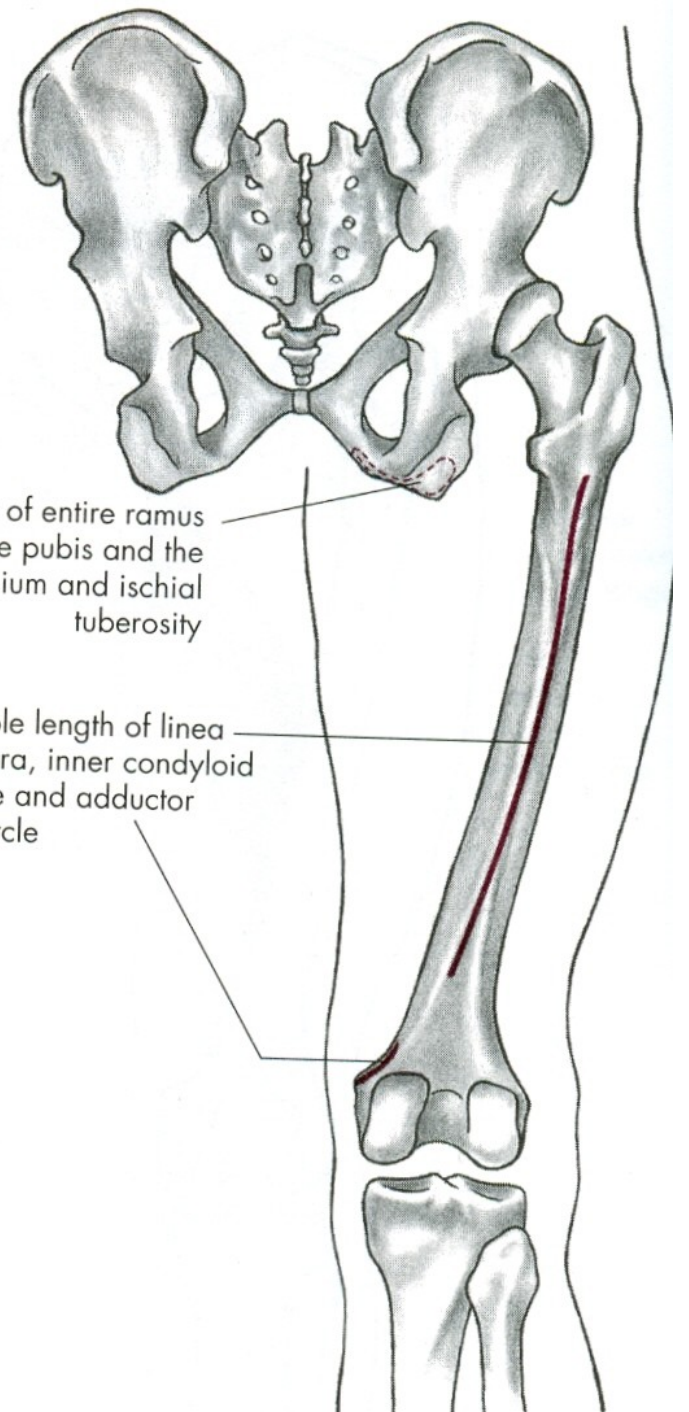


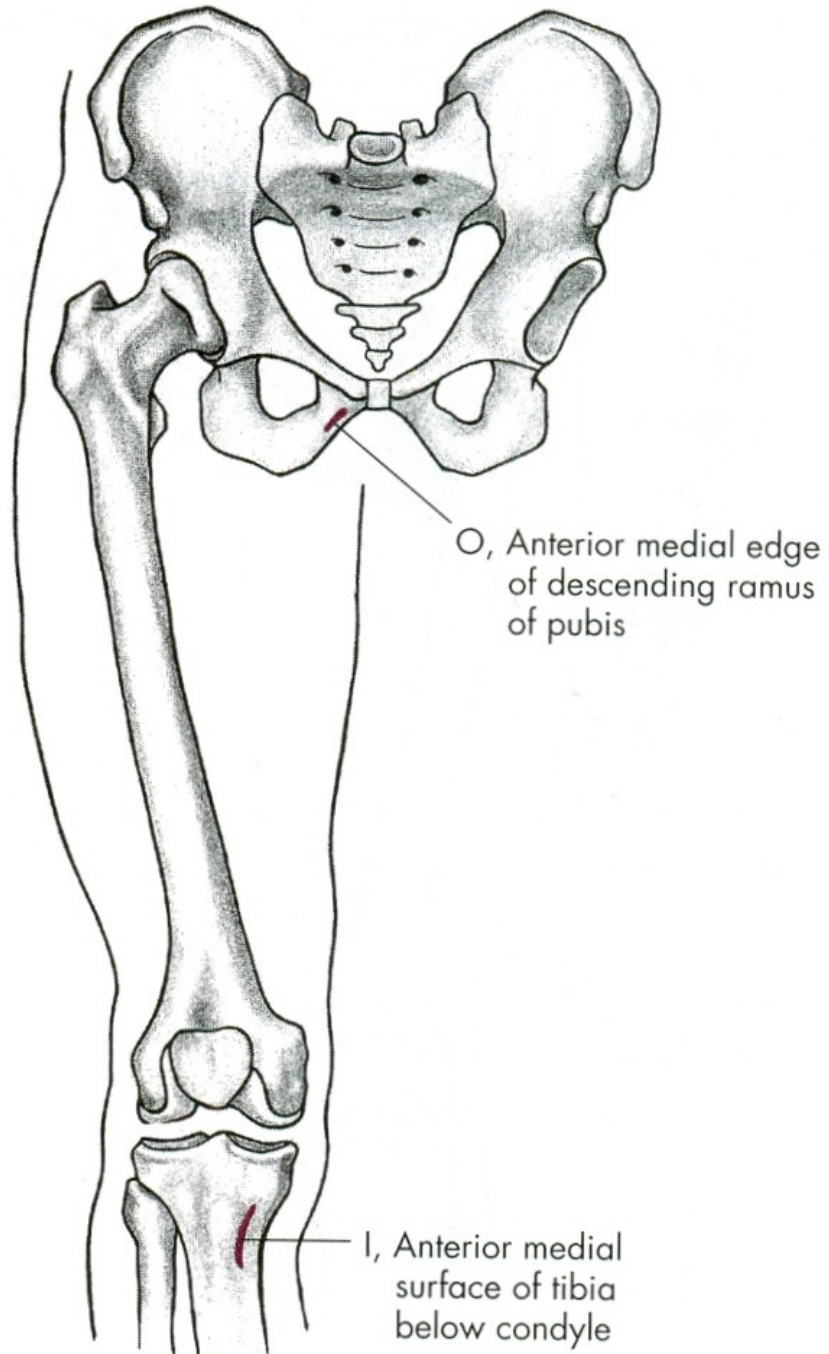
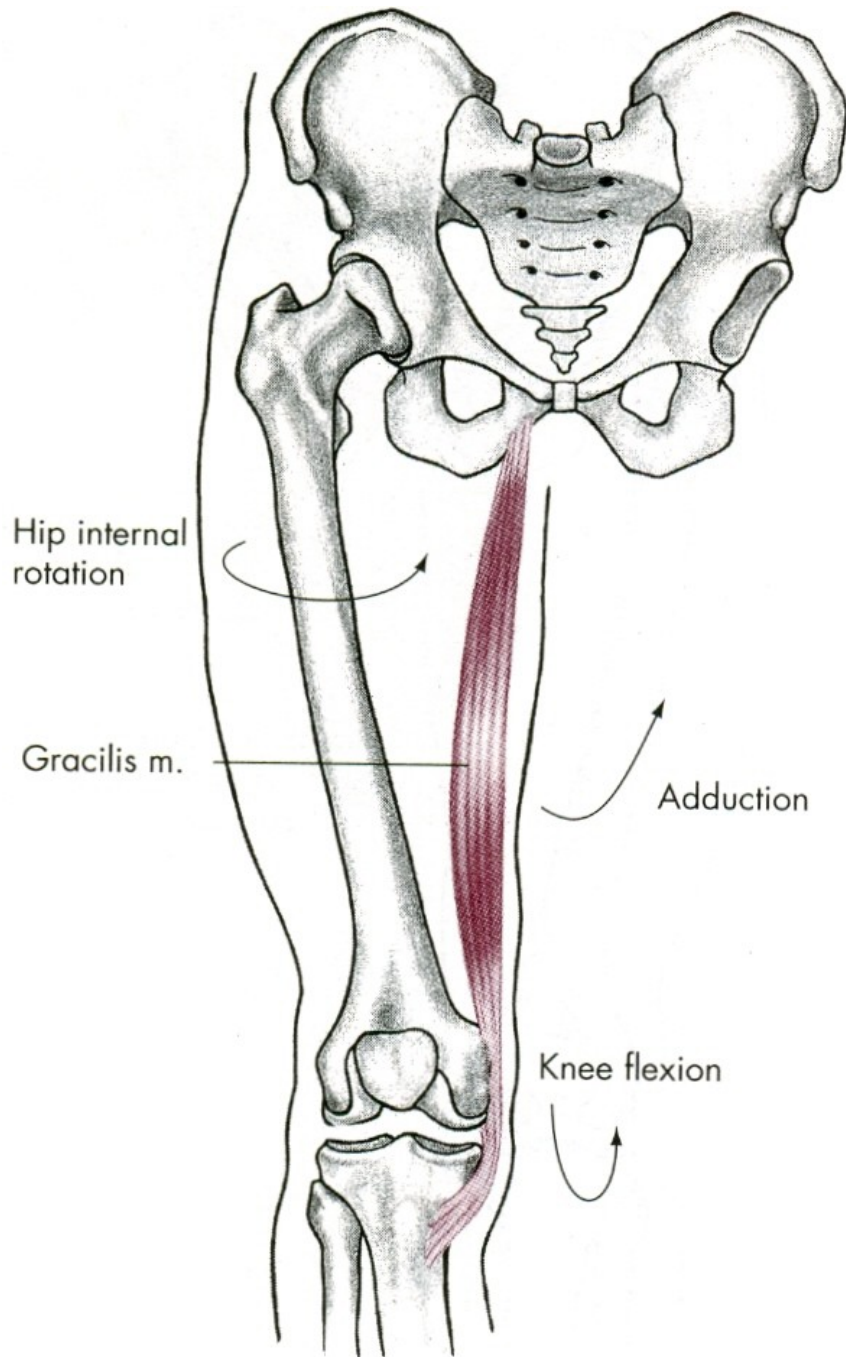




O, Edge of entire ramus of the pubis and the ischium and ischial tuberosity

I, Whole length of linea aspera, inner condyloid ridge and adductor tubercle





ADDUKCE

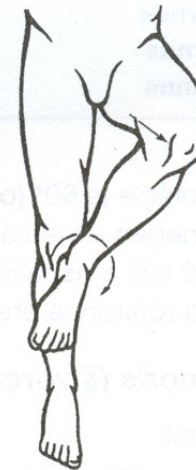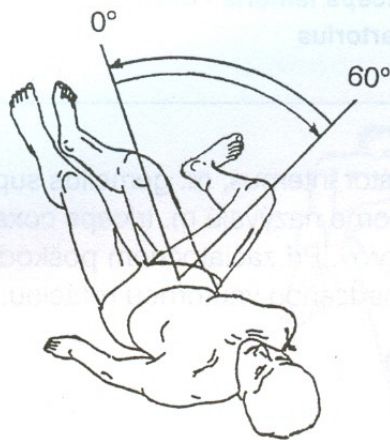
m. adductor magnus – velký přitahovač

m. adductor longus – dlouhý přitahovač

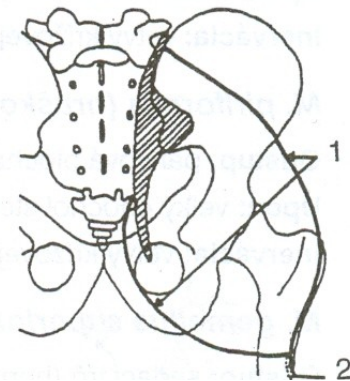
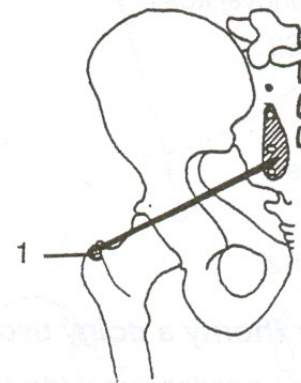
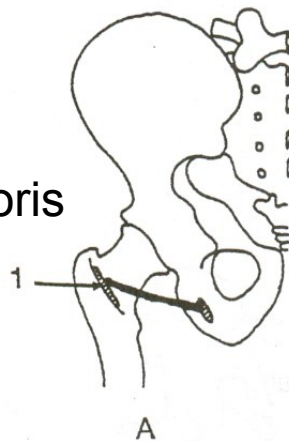
m. adductor brevis – krátký přitahovač

m. gracilis – štíhlý sval stehenní

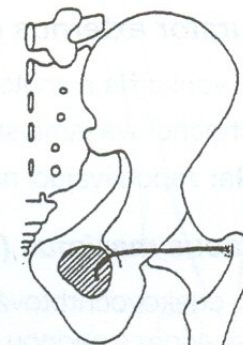
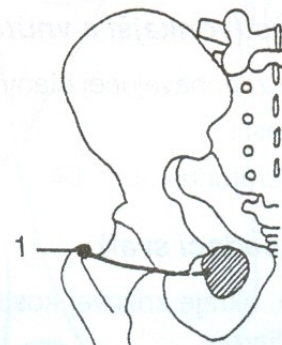
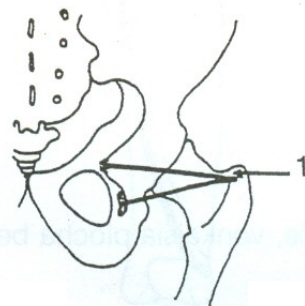
VNĚJŠÍ ROTACE



m. quadratus femoris



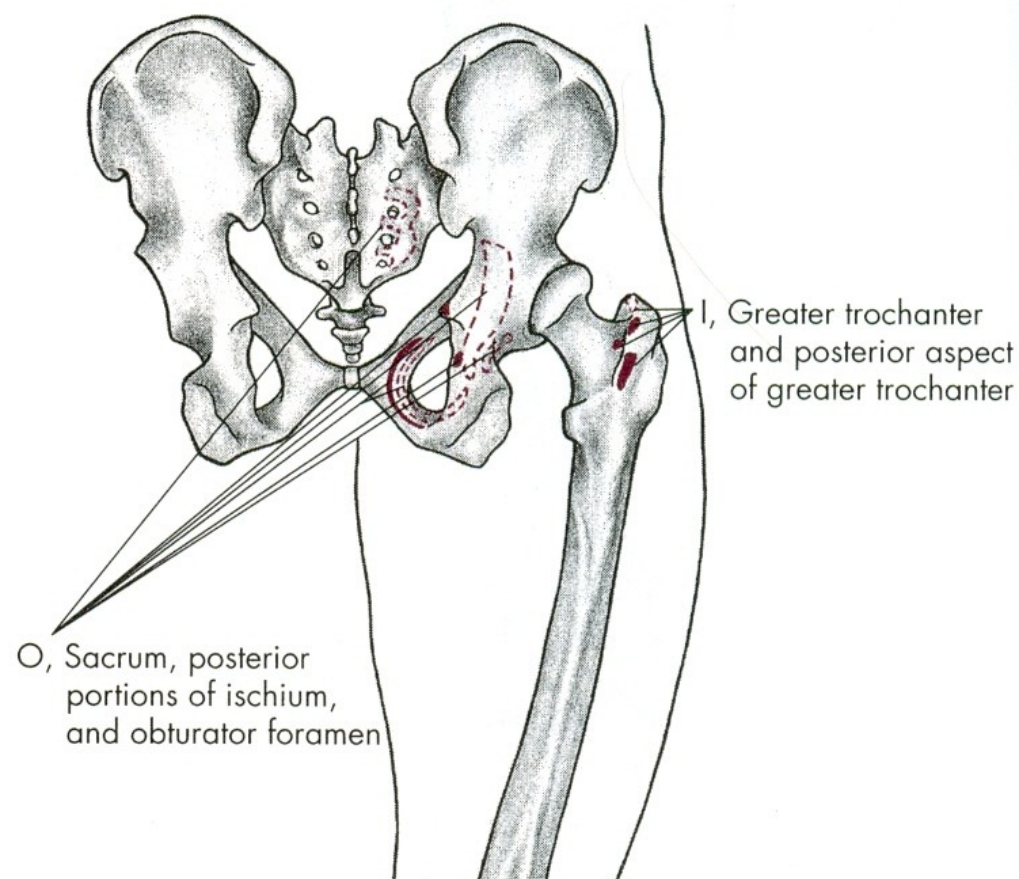
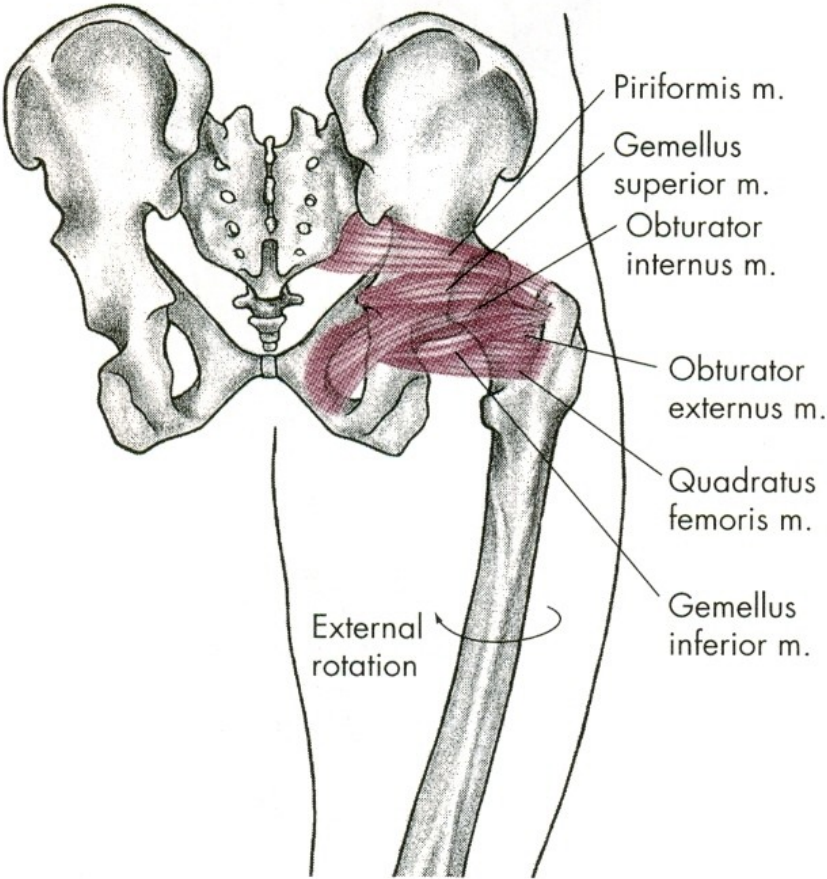
m. piriformis m. gluteus maximus



m. gemellus superior

m. obturator externus

m. obturator internus



ZEVNÍ ROTACE

m. quadratus femoris – čtyřhlavý sval stehenní

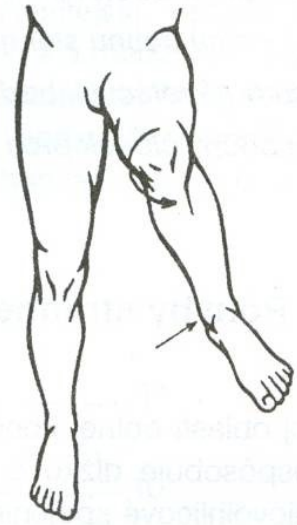
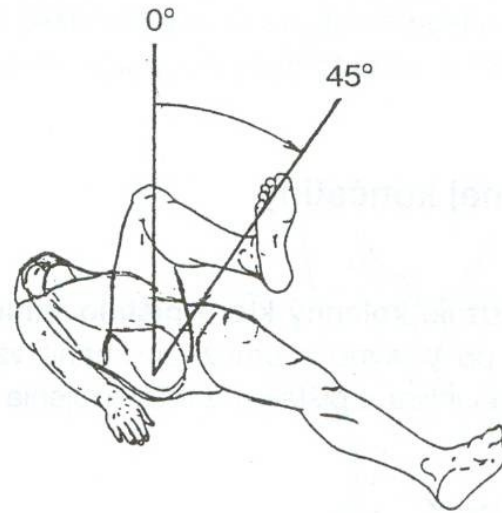
m. piriformis – hruškovitý sval

mm. gemeli

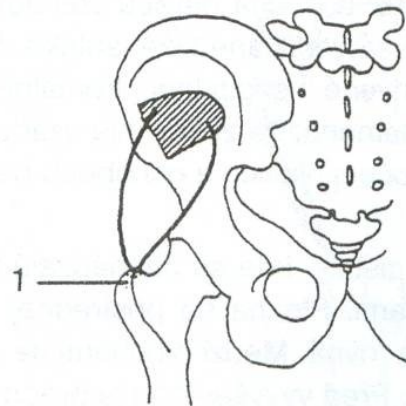
mm. obturatorii – ucpávače

m. gluteus maximus – velký sval hýžd'ový

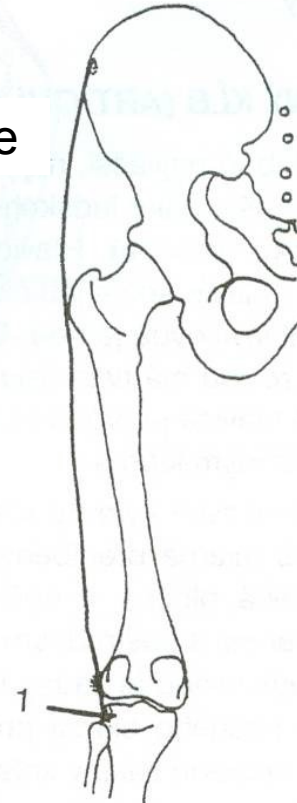
VNITŘNÍ ROTACE



m. tensor fasciae latae



m. gluteus minimus



VNITŘNÍ ROTACE

m. gluteus minimus –
malý sval hýžd'ový-přední snopce

m. tensor fasciae latae –
napínač stehenní povázky

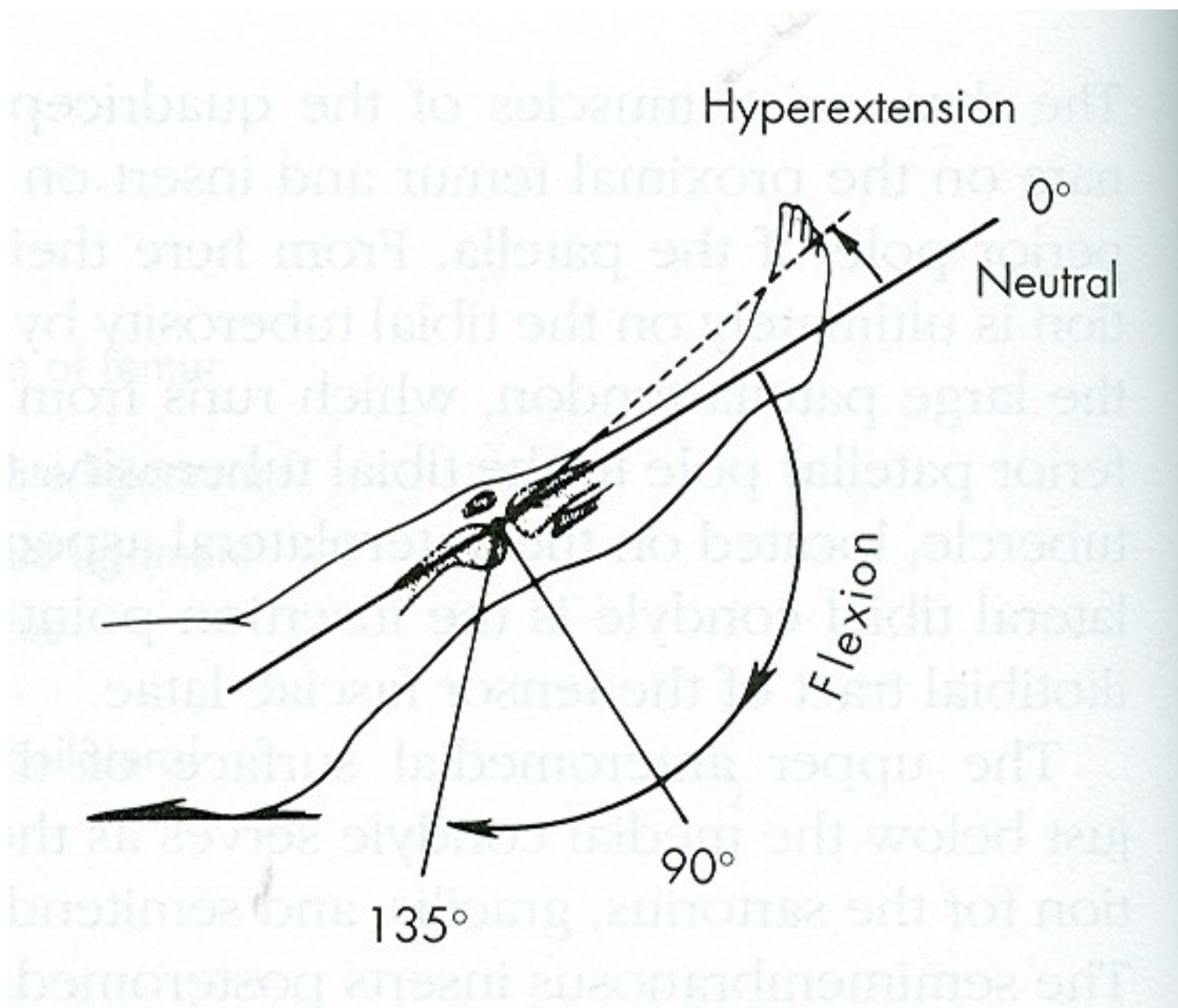
POHYBY KOLENNÍHO KLOUBU

FLEXE

EXTENZE

ZEVNÍ ROTACE

VNITŘNÍ ROTACE



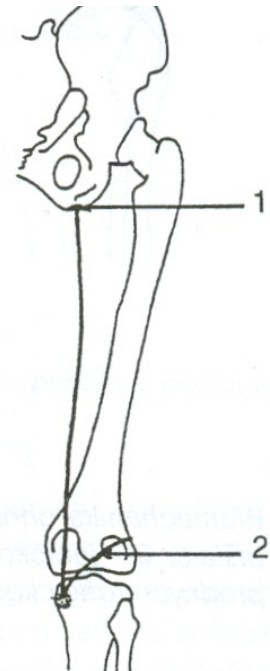
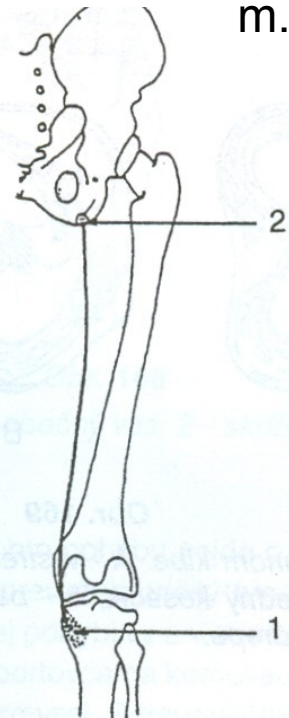
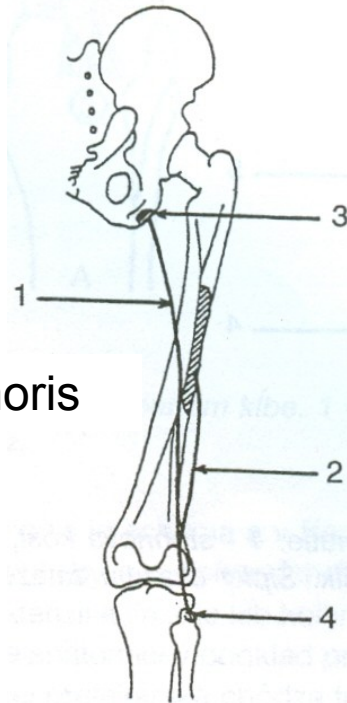
FLEXE

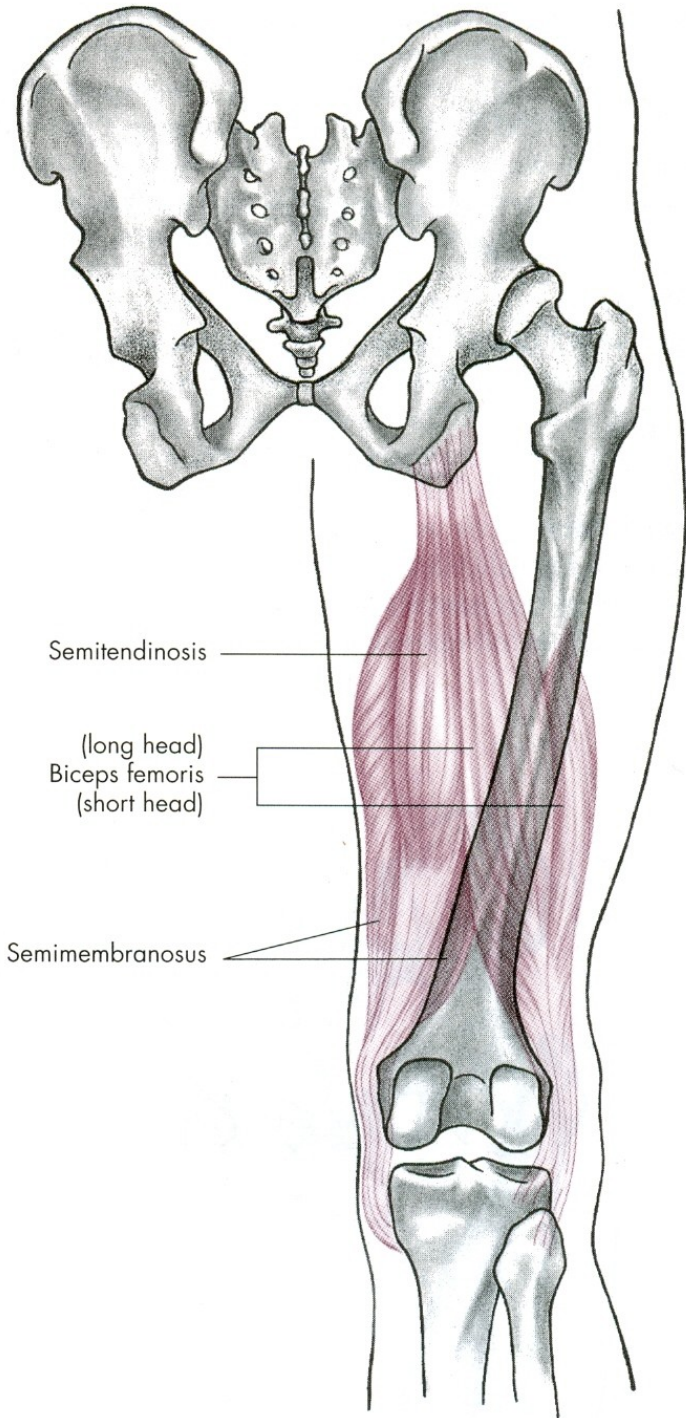
- 140°

0°

m. semitendinosus

m. semimembranosus

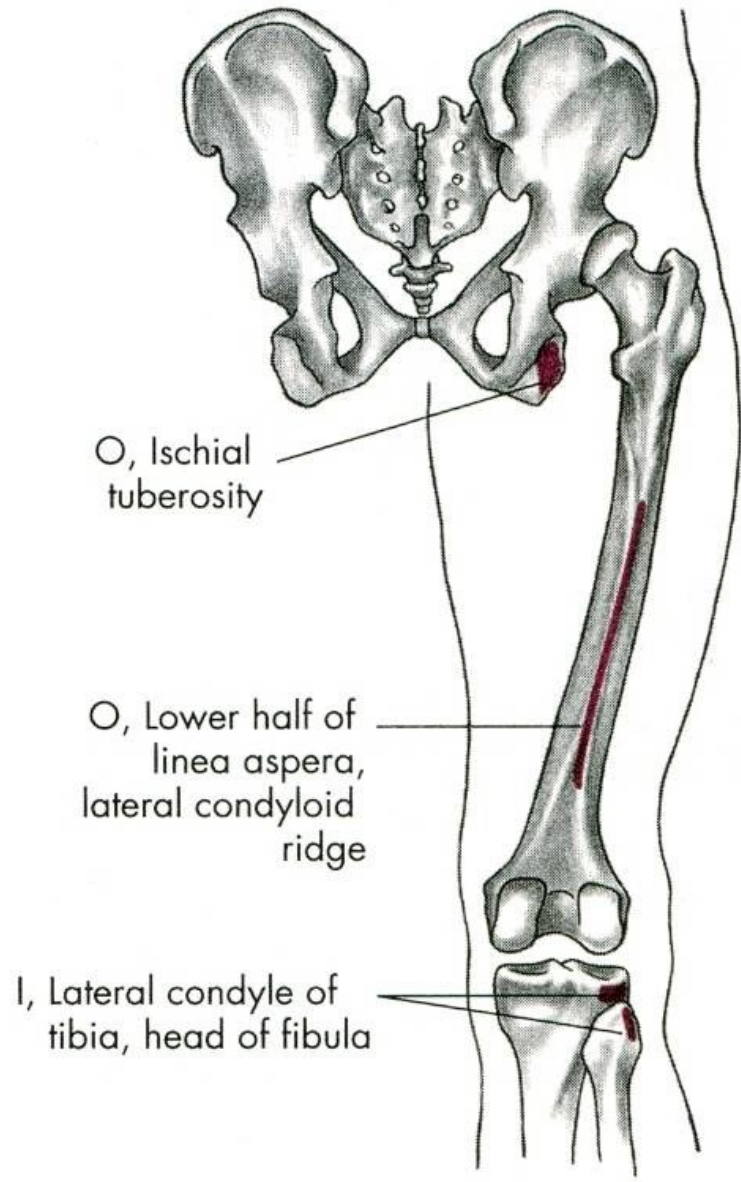
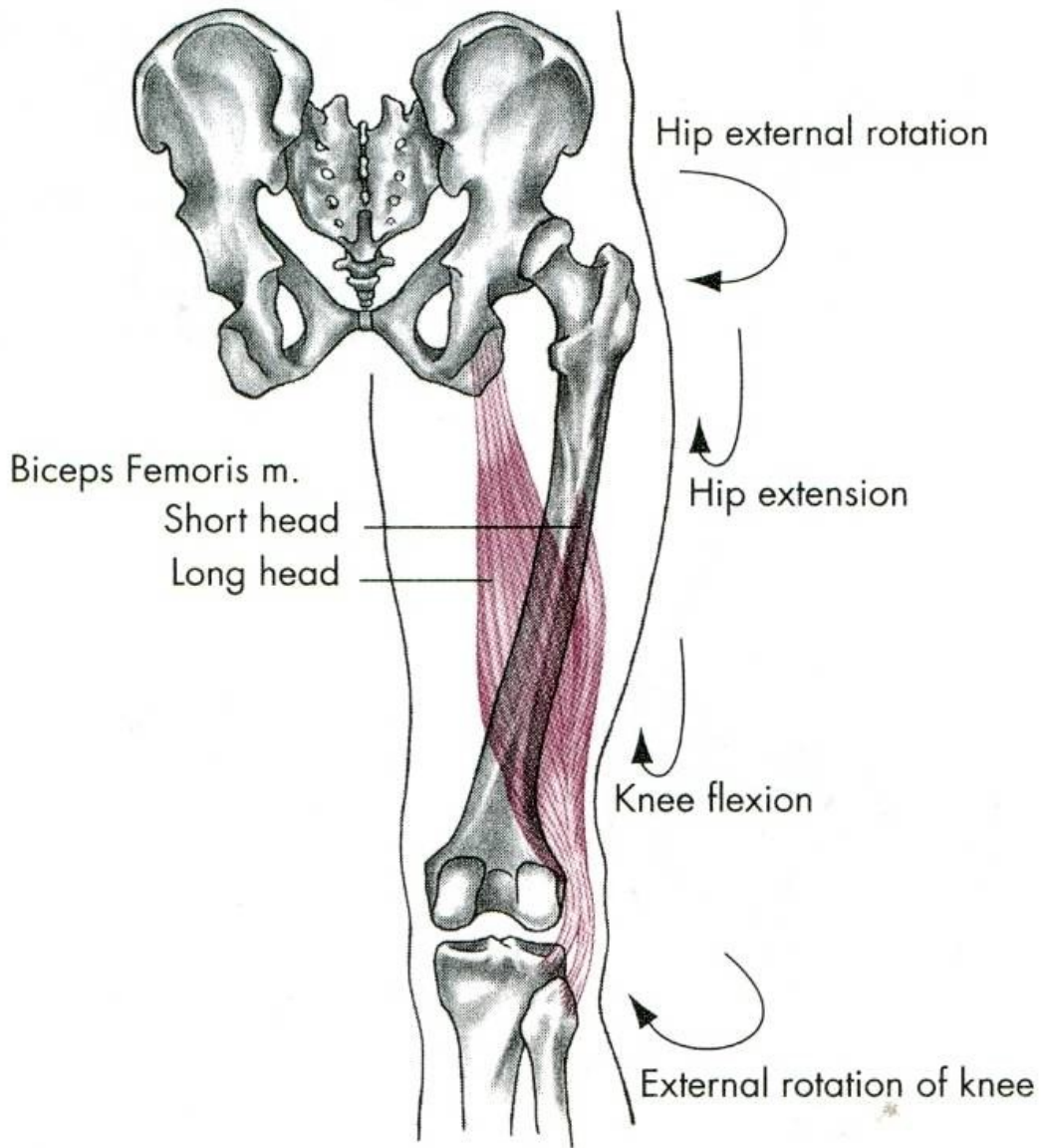


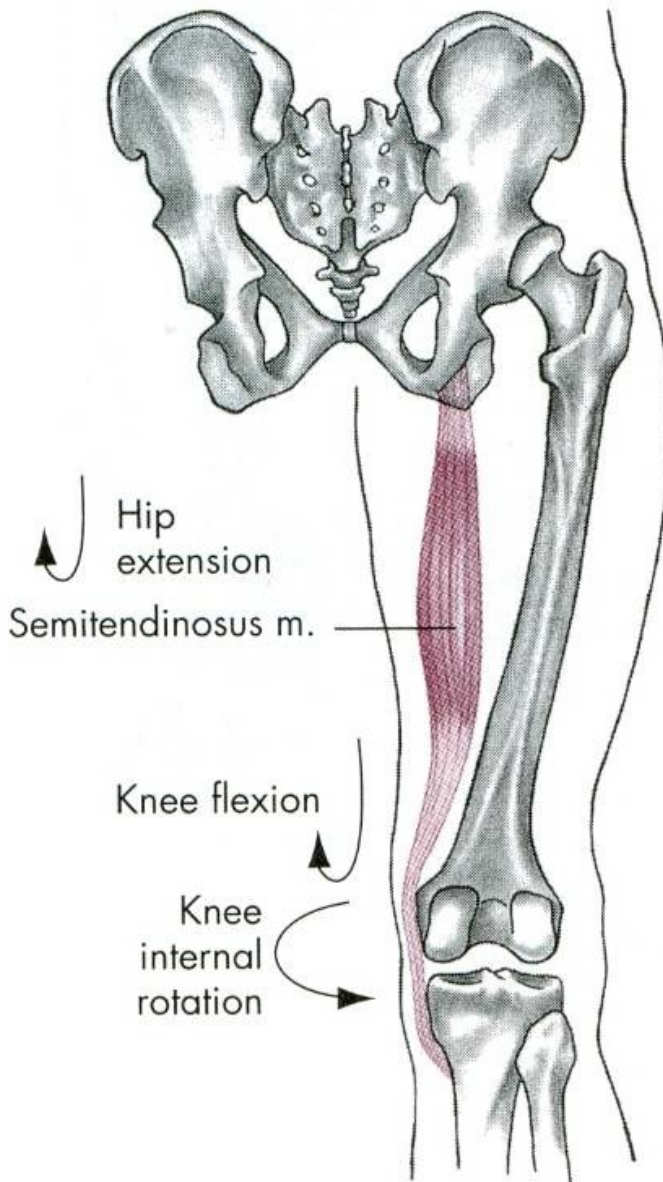


Semitendinosus

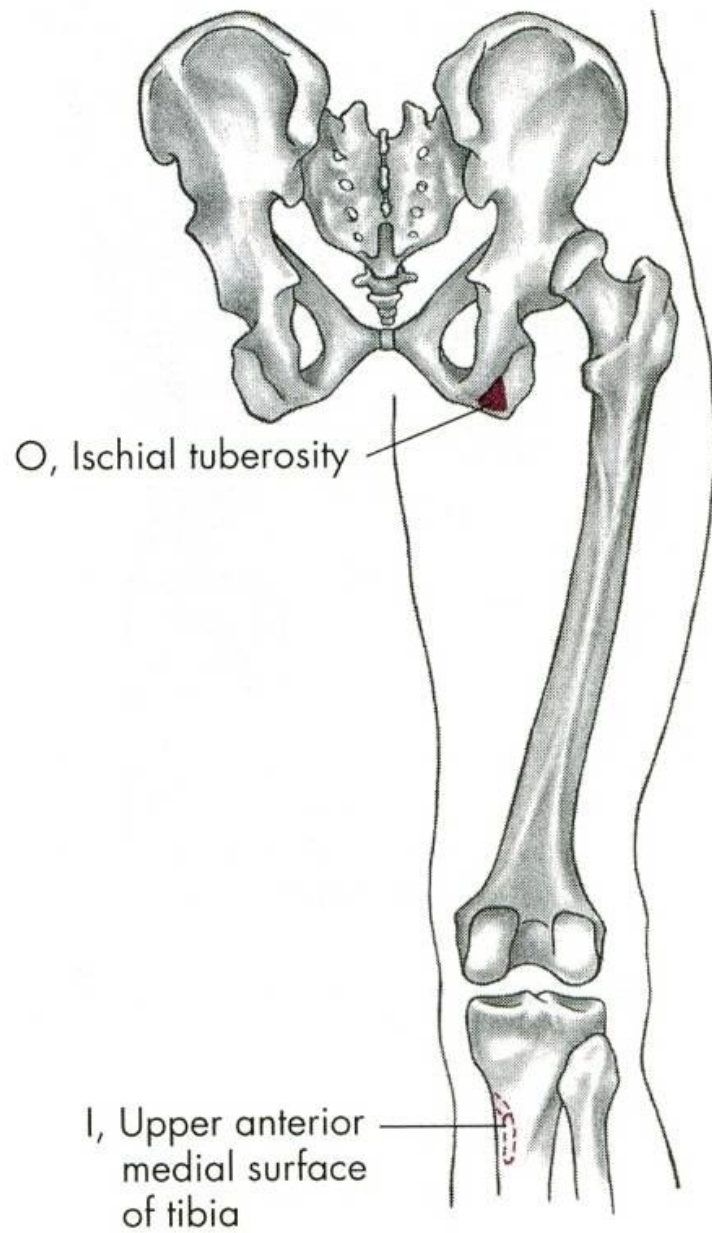
(long head)
Biceps femoris
(short head)

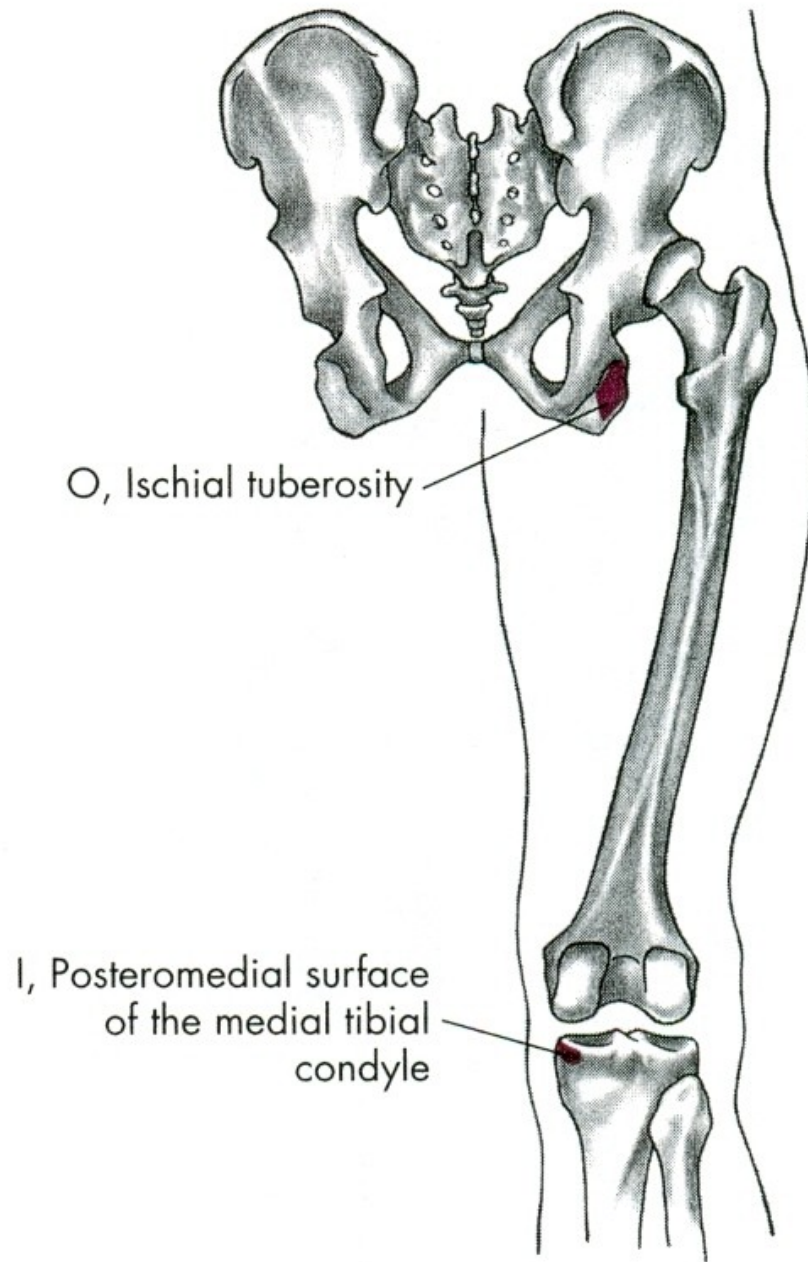
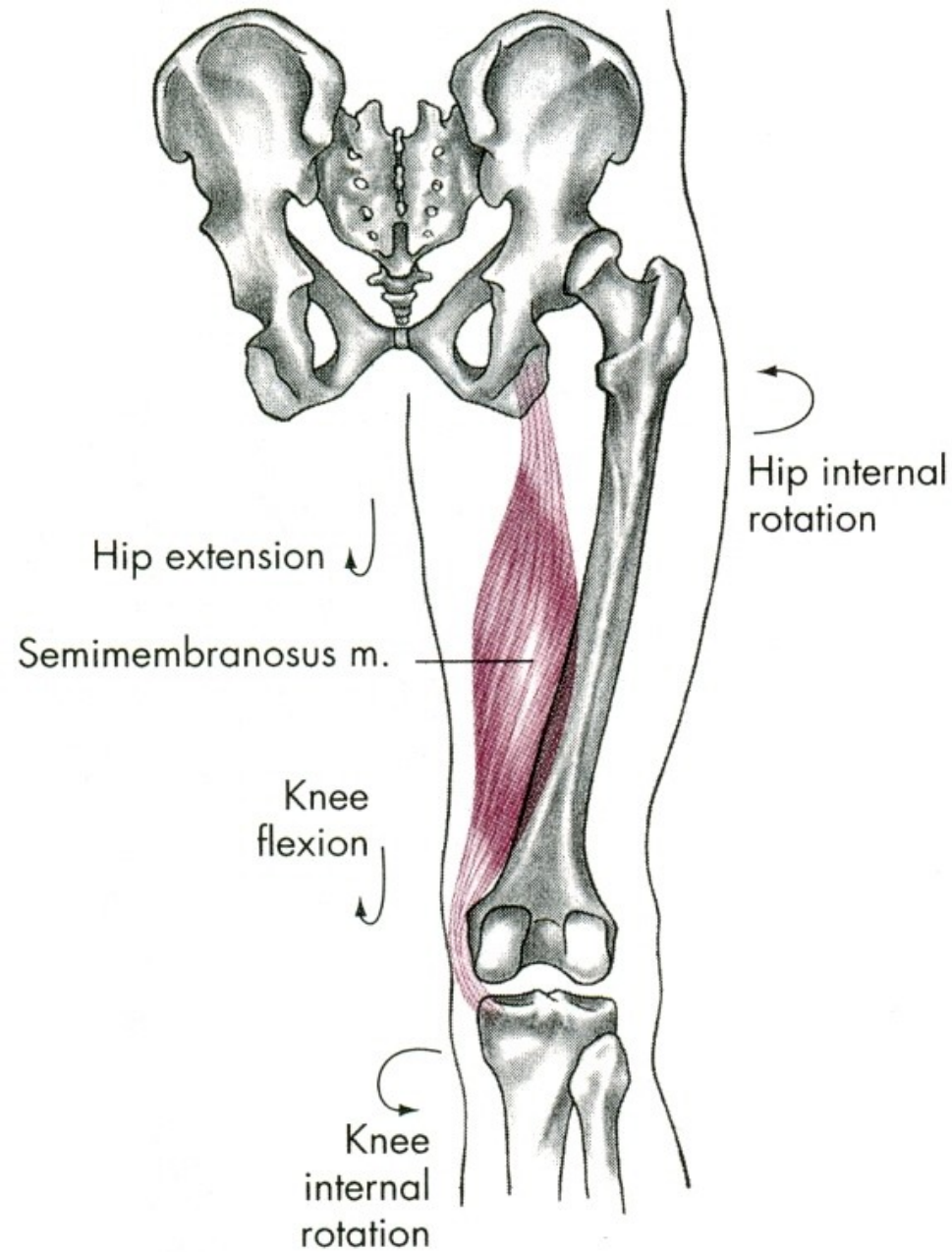
Semimembranosus

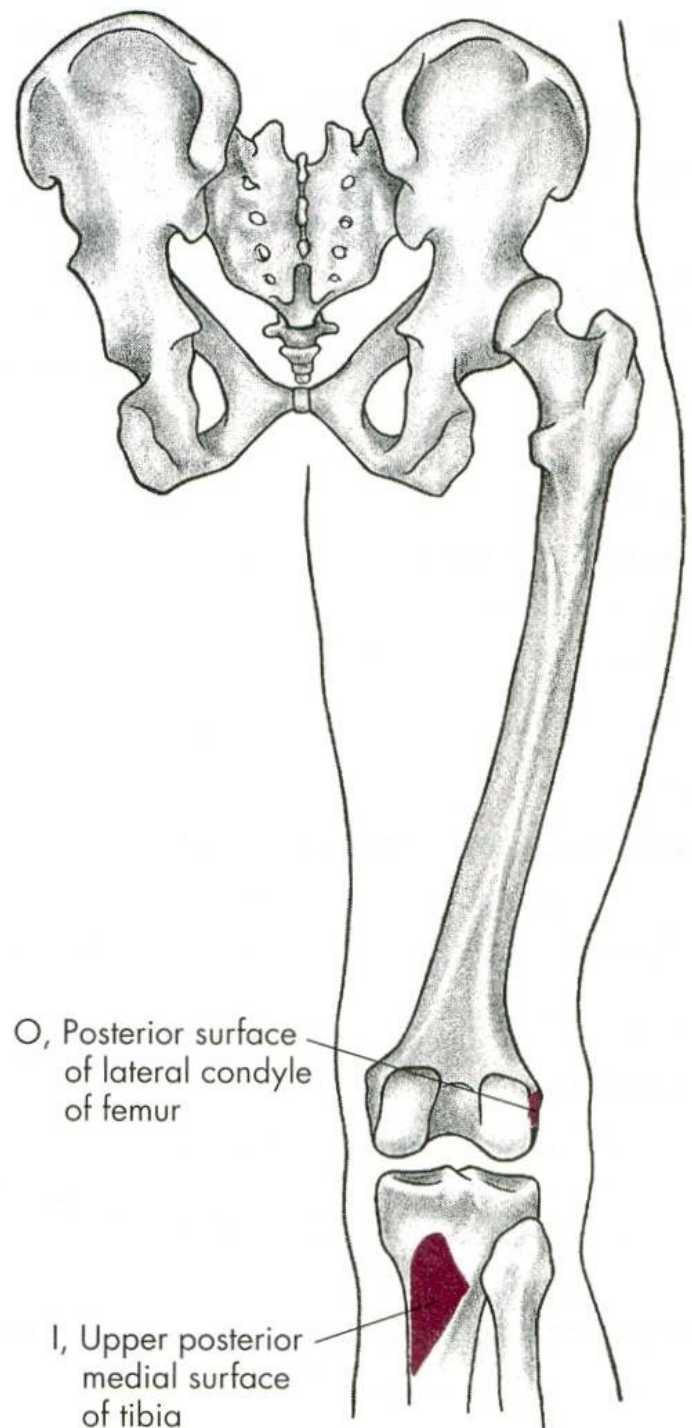
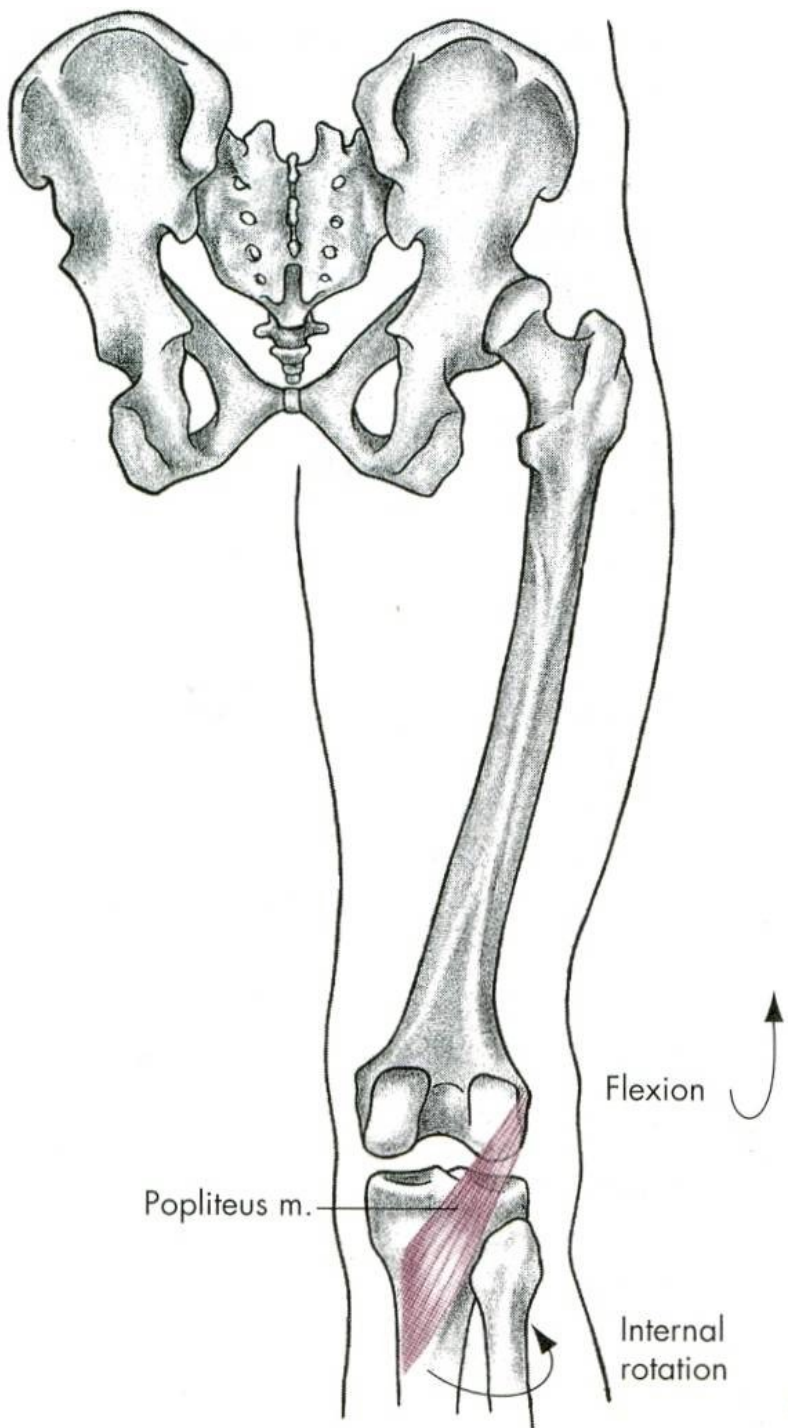




Hip internal rotation

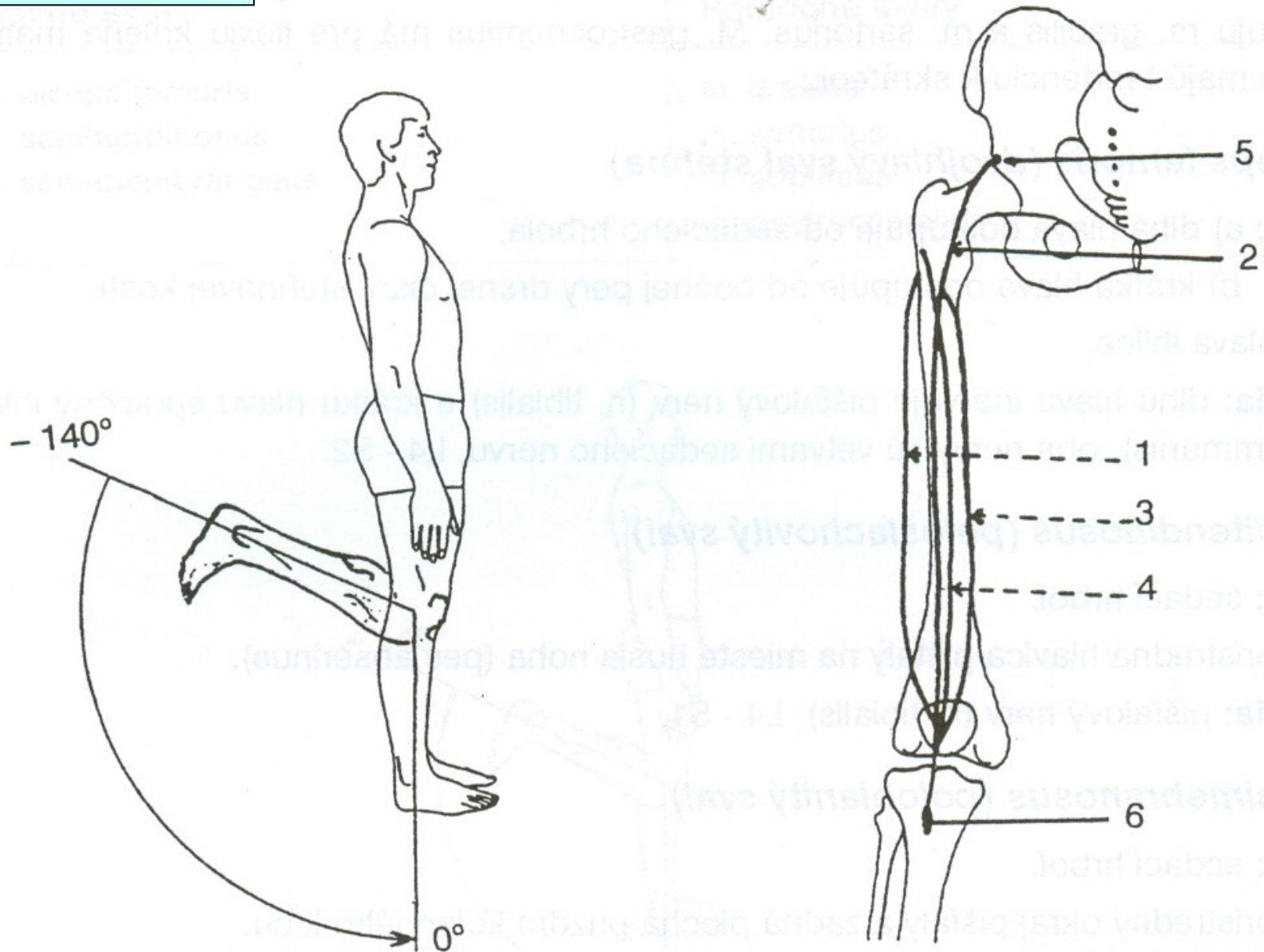


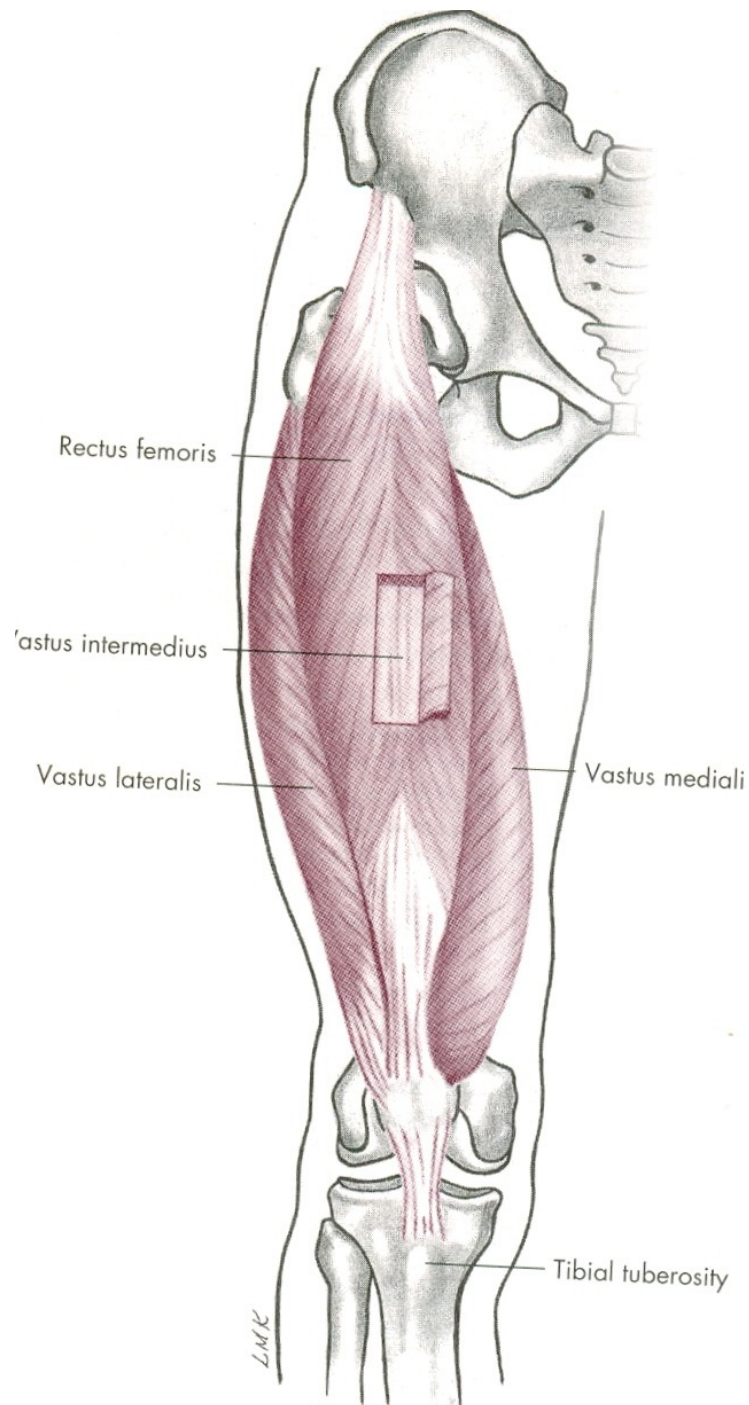


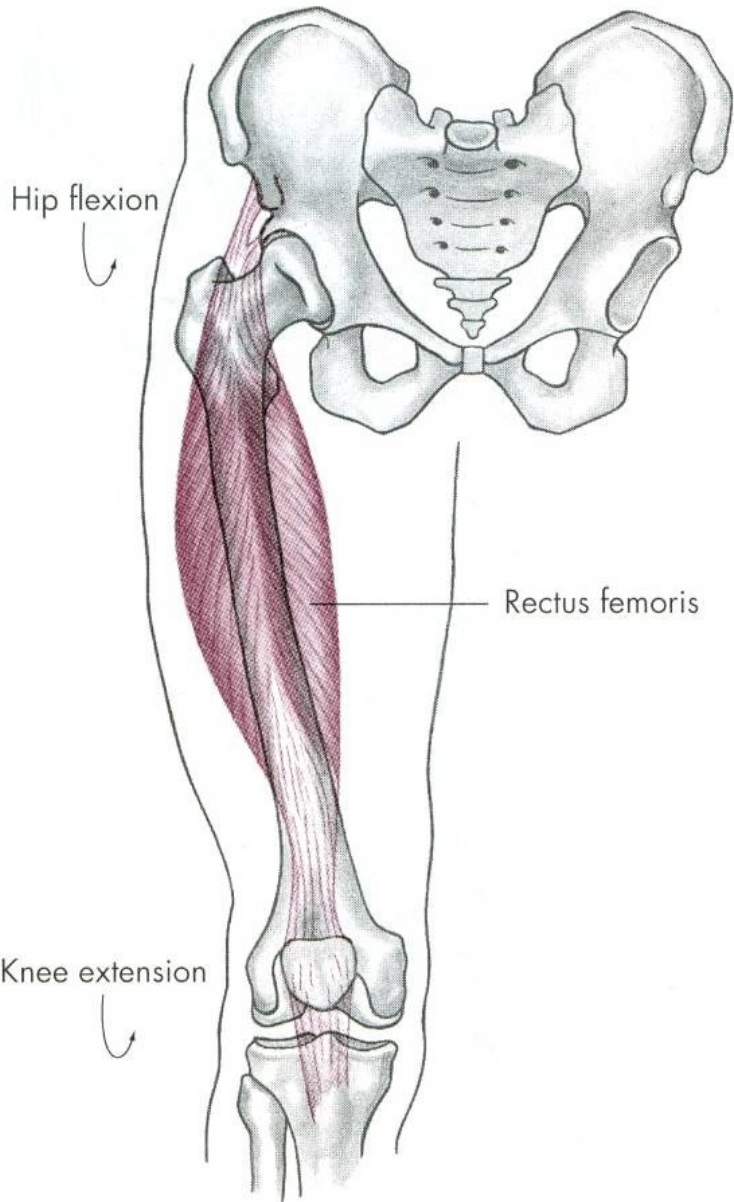


EXTENZE

m. quadriceps femoris

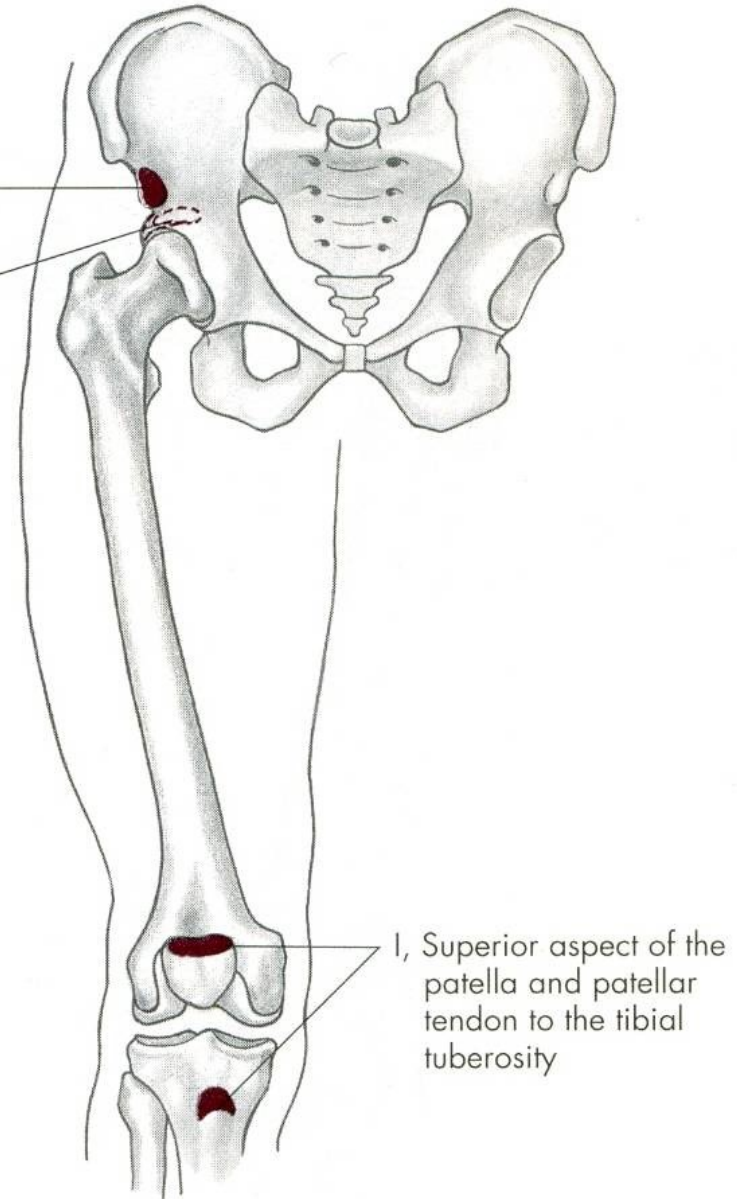


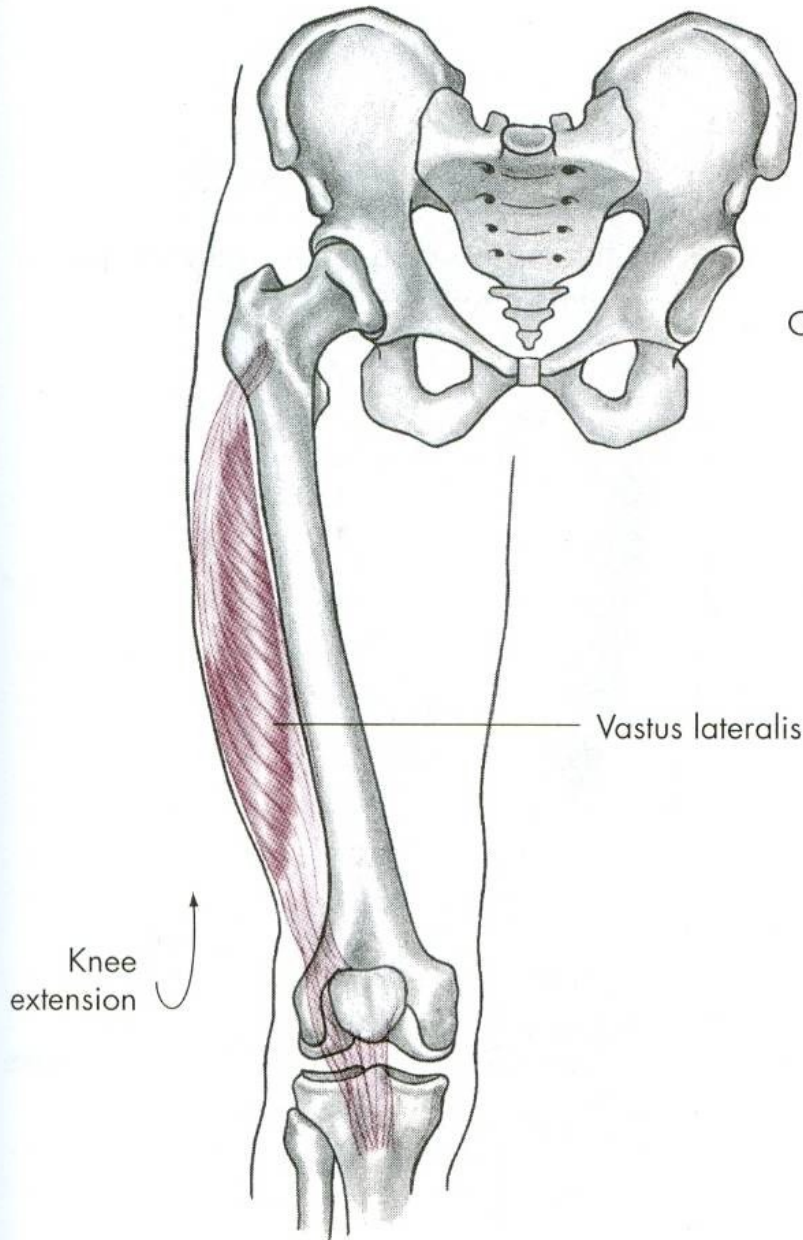




O, Anterior inferior iliac spine

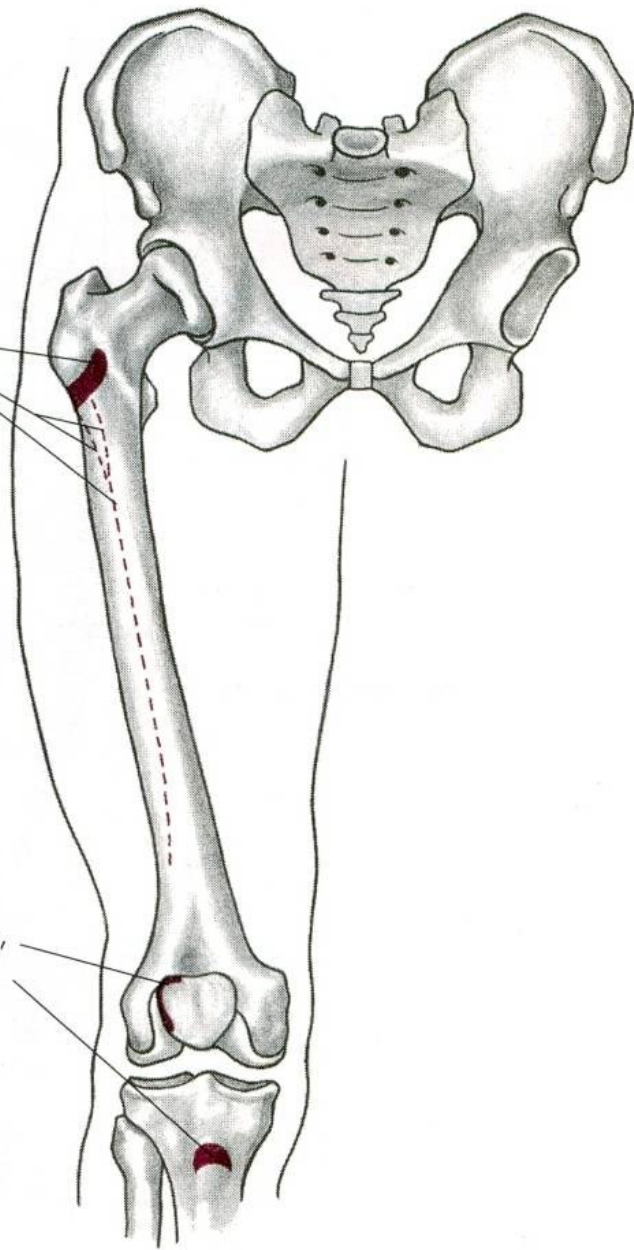
O, Groove (posterior) above the acetabulum

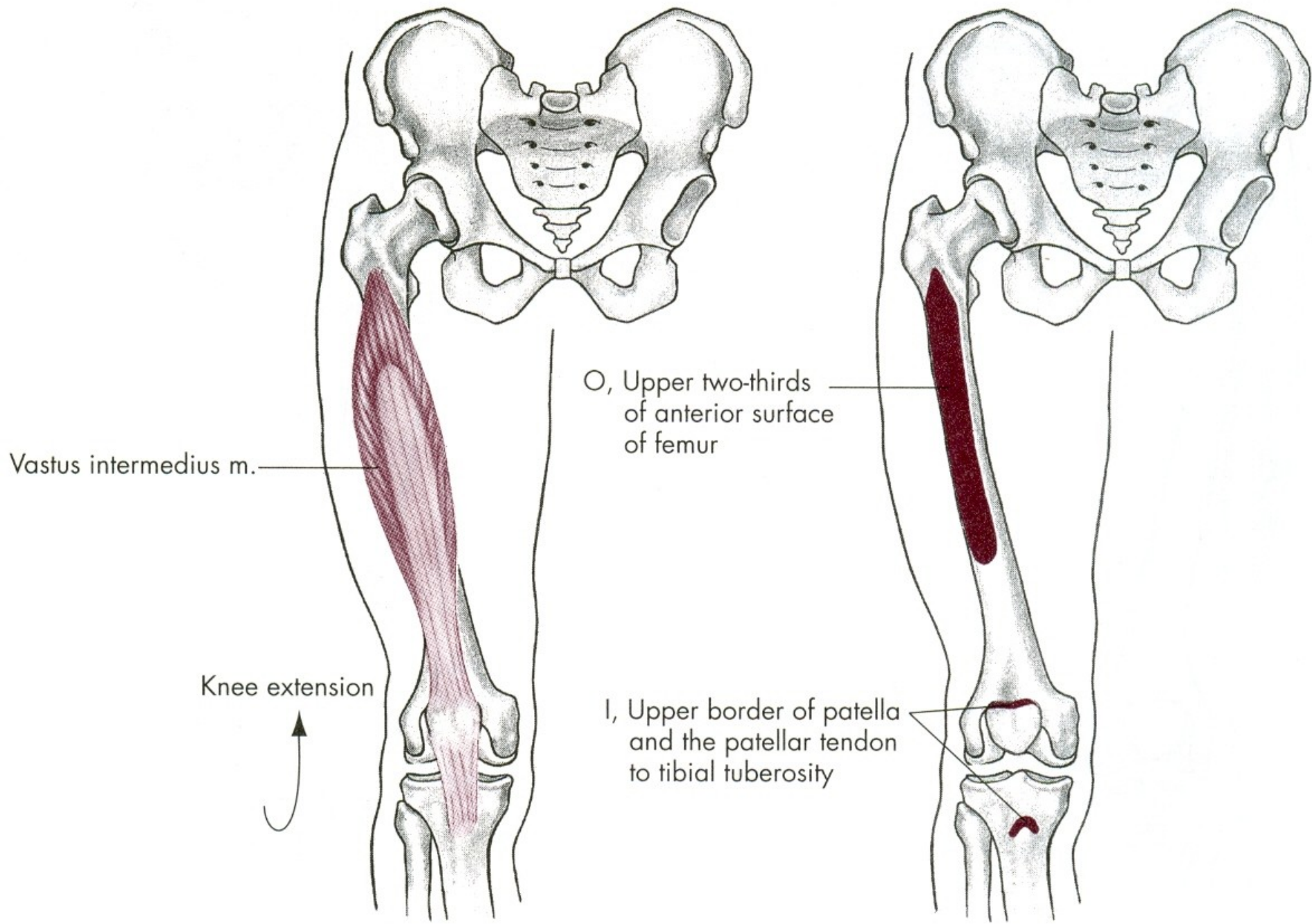


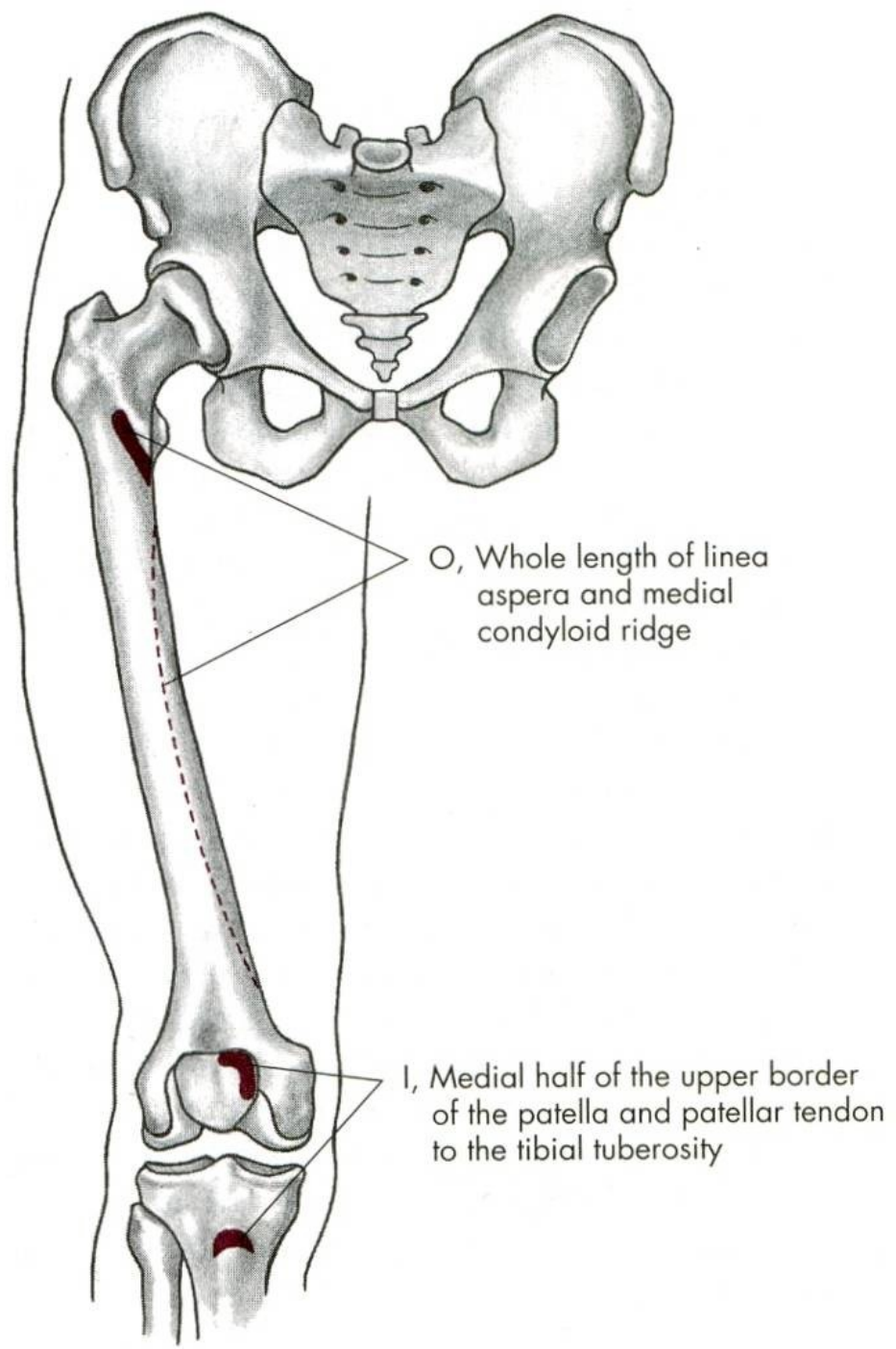
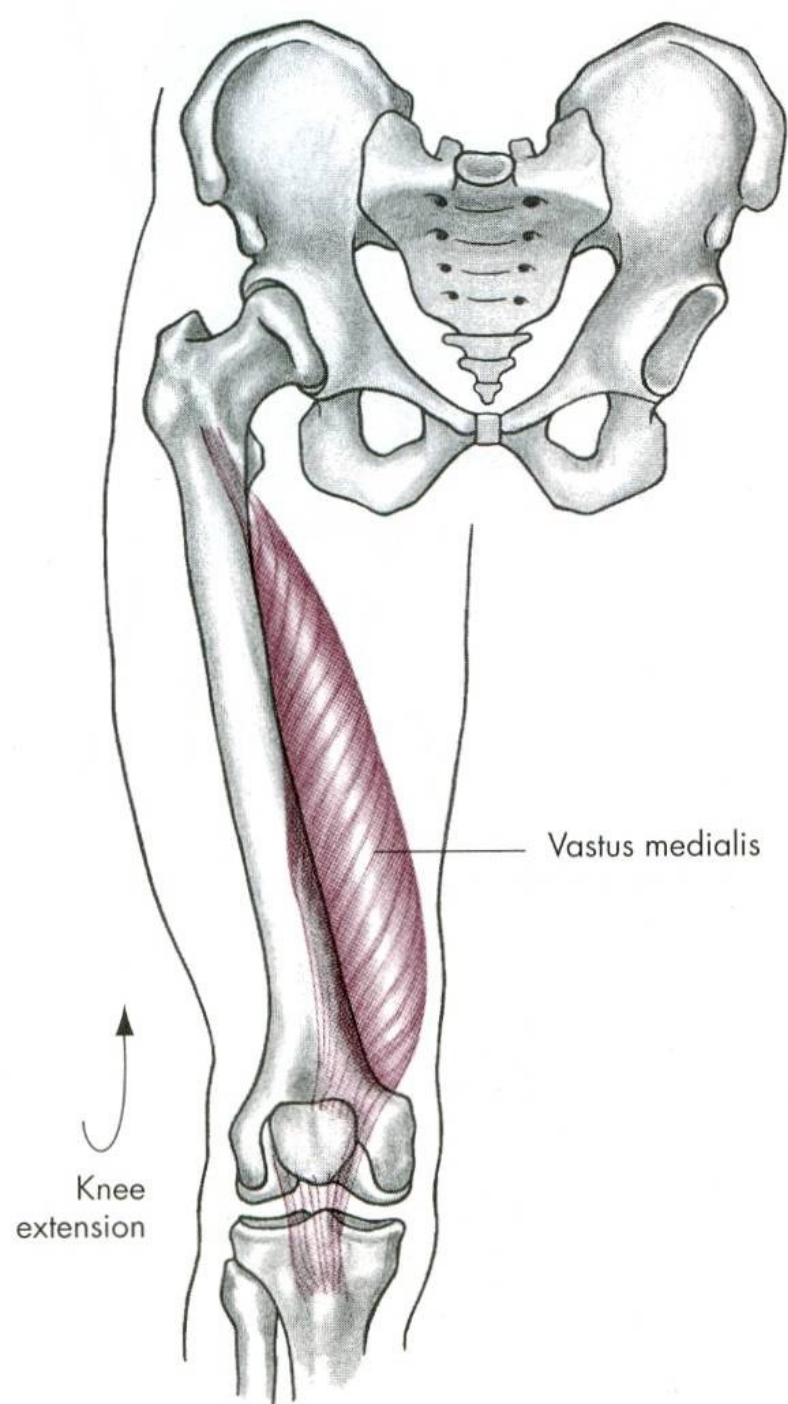


O, Intertrochanteric line, anterior and inferior borders of the greater trochanter, upper half of the linea aspera and the entire lateral intermuscular septum

I, Lateral border of patella, patellar tendon to tibial tuberosity







FLEXE

m. biceps femoris – dvojhlavý sval stehenní

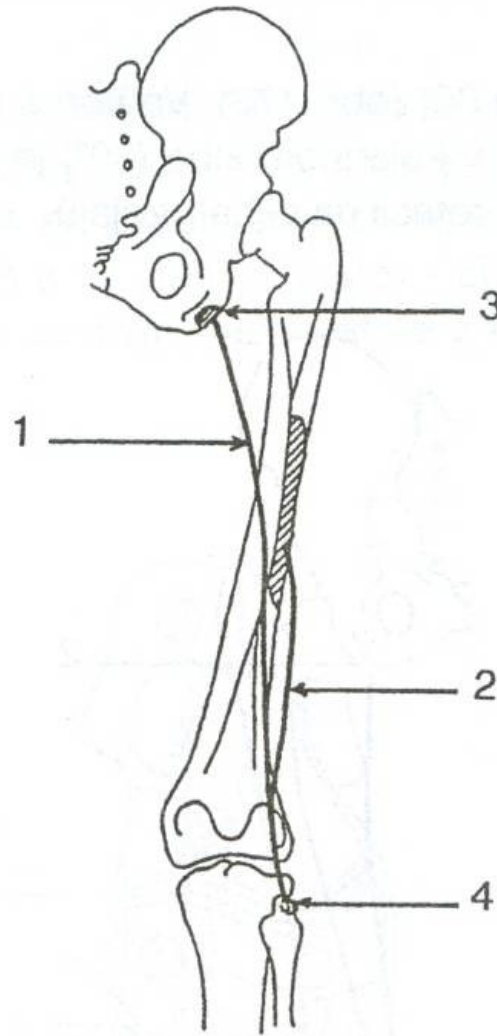
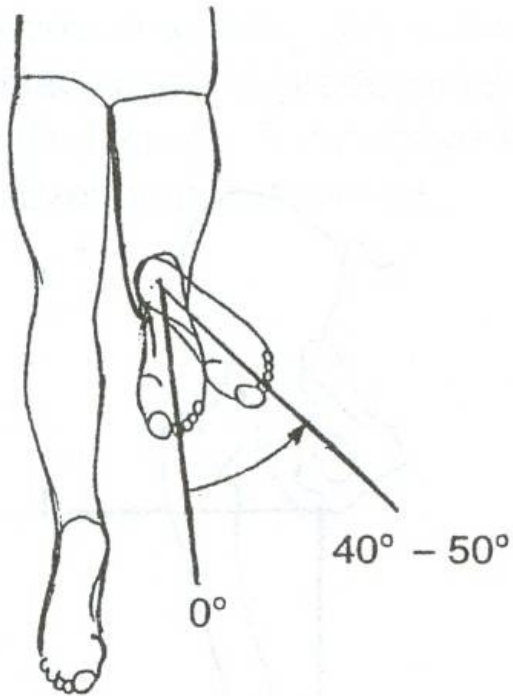
m. semitendinosus – sval pološlašitý

m. semimembranosus – sval poloblantý

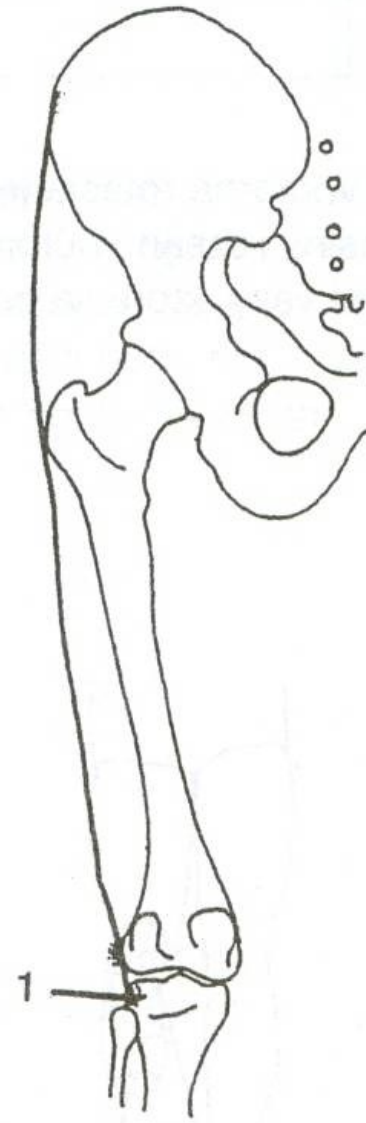
EXTENZE

m. quadriceps femoris – čtyřhlavý sval stehenní

ZEVNÍ ROTACE

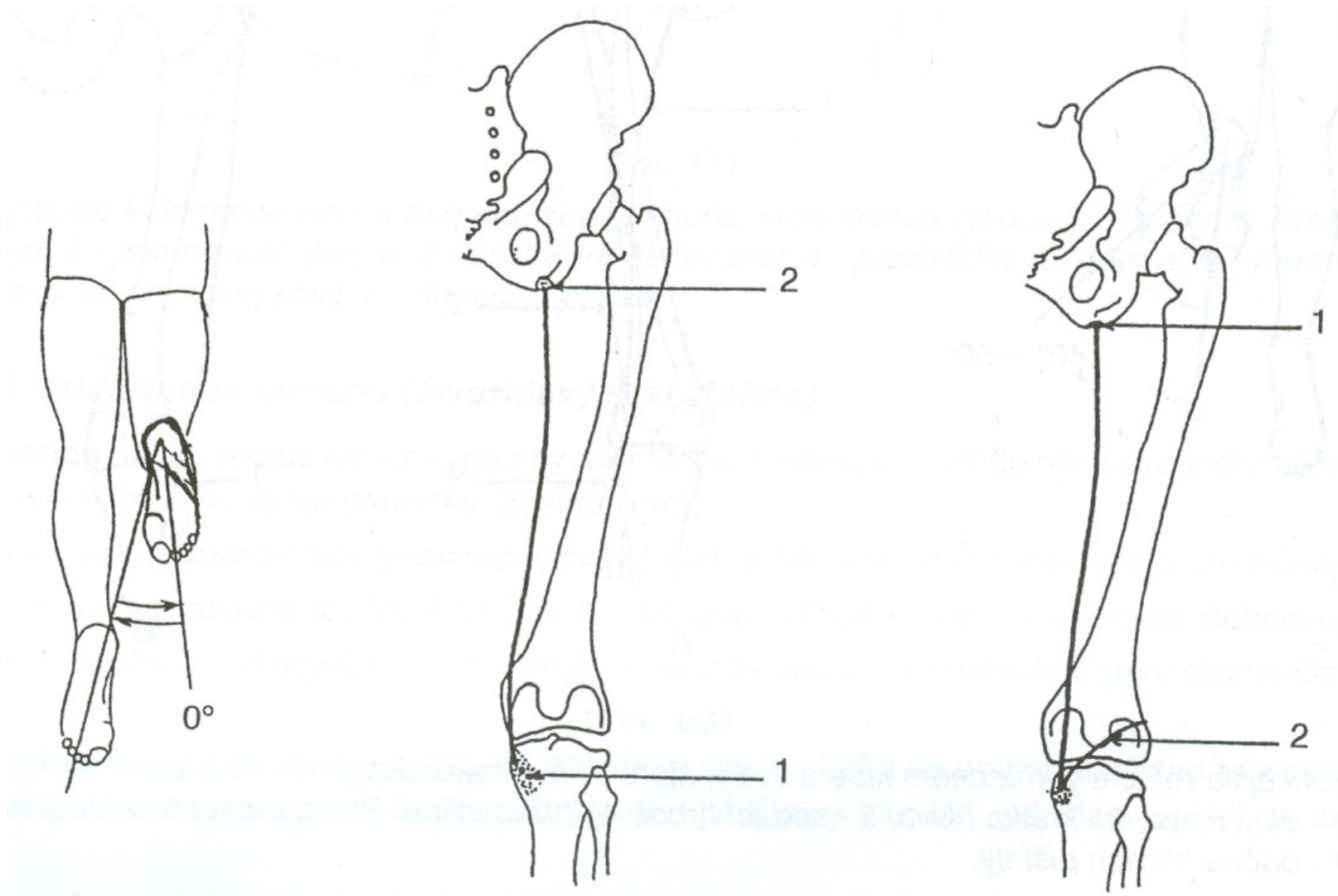


m. biceps femoris



m. tensor fasciae latae

VNITŘNÍ ROTACE



m. semitendinosus

m. semimembranosus

ZEVNÍ ROTACE

m. biceps femoris – dvojhlavý sval stehenní

m. tensor fasciae latae –
napínač stehenní povázky

VNITŘNÍ ROTACE

m. semitendinosus – sval pološlašitý

m. semimembranosus – sval poloblanitý

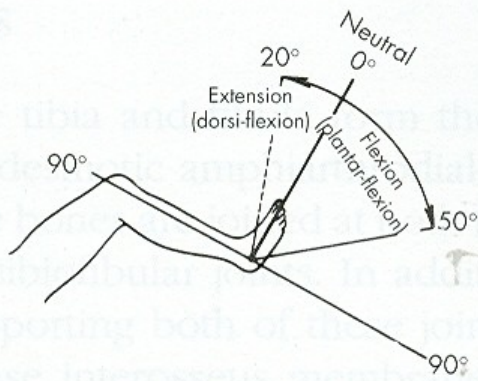
POHYBY HLEZENNÍHO KLOUBU

PLANTÁRNÍ FLEXE –
PROPNUŤÍ ŠPIČEK

DORZÁLNÍ FLEXE - FAJFKY

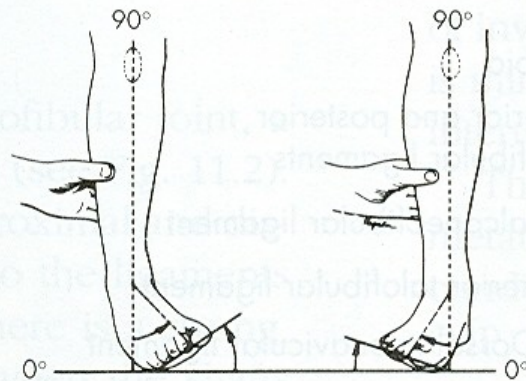
PRONACE

SUPINACE



Ankle joint

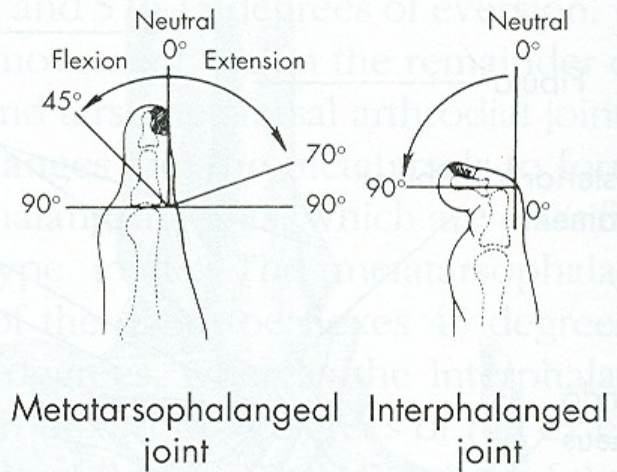
A



Inversion

Eversion

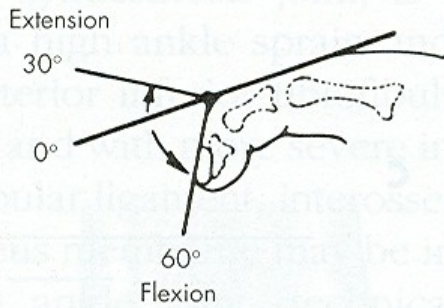
B



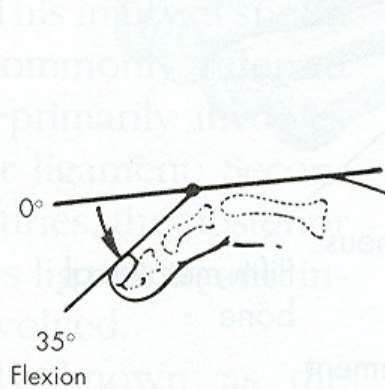
Metatarsophalangeal joint

Interphalangeal joint

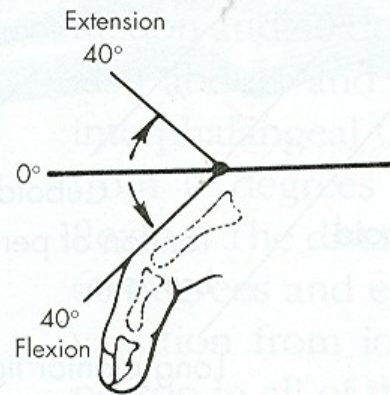
C



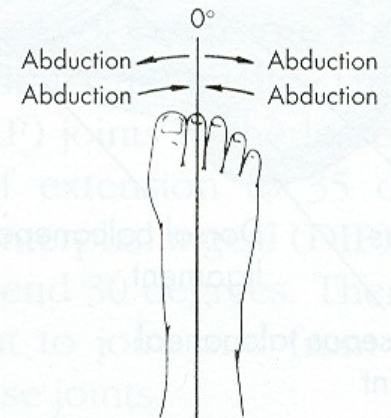
Distal interphalangeal joint



Proximal interphalangeal joint



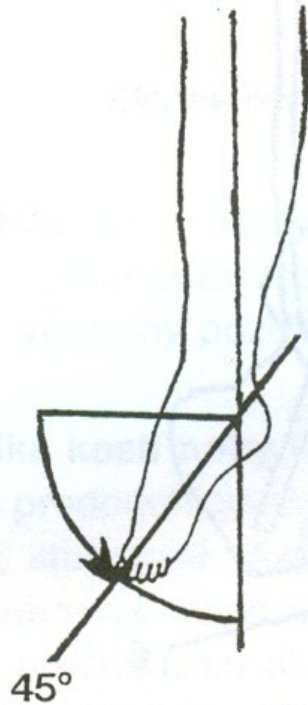
Metatarsophalangeal joint



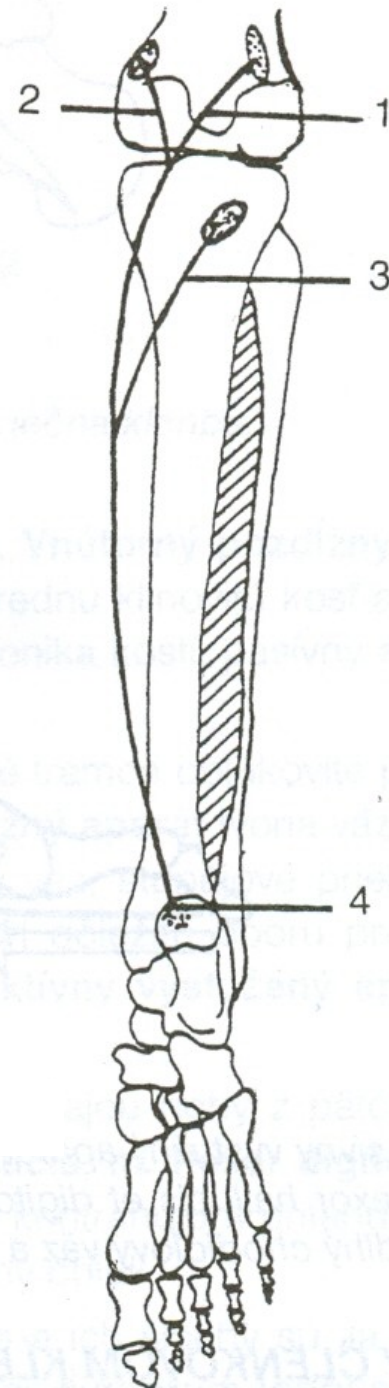
Toe spread

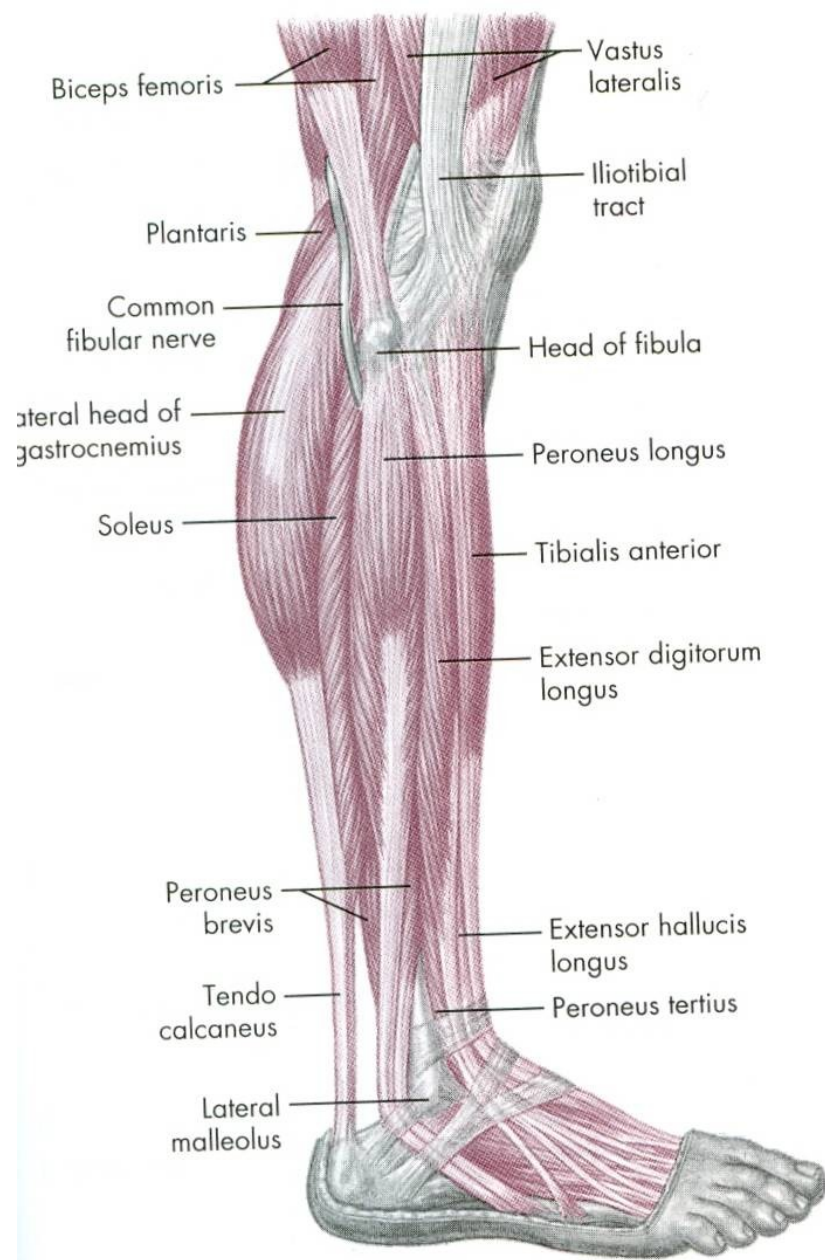
D

PLANTÁRNÍ FLEXE – PROPNU TÍ ŠPIČEK

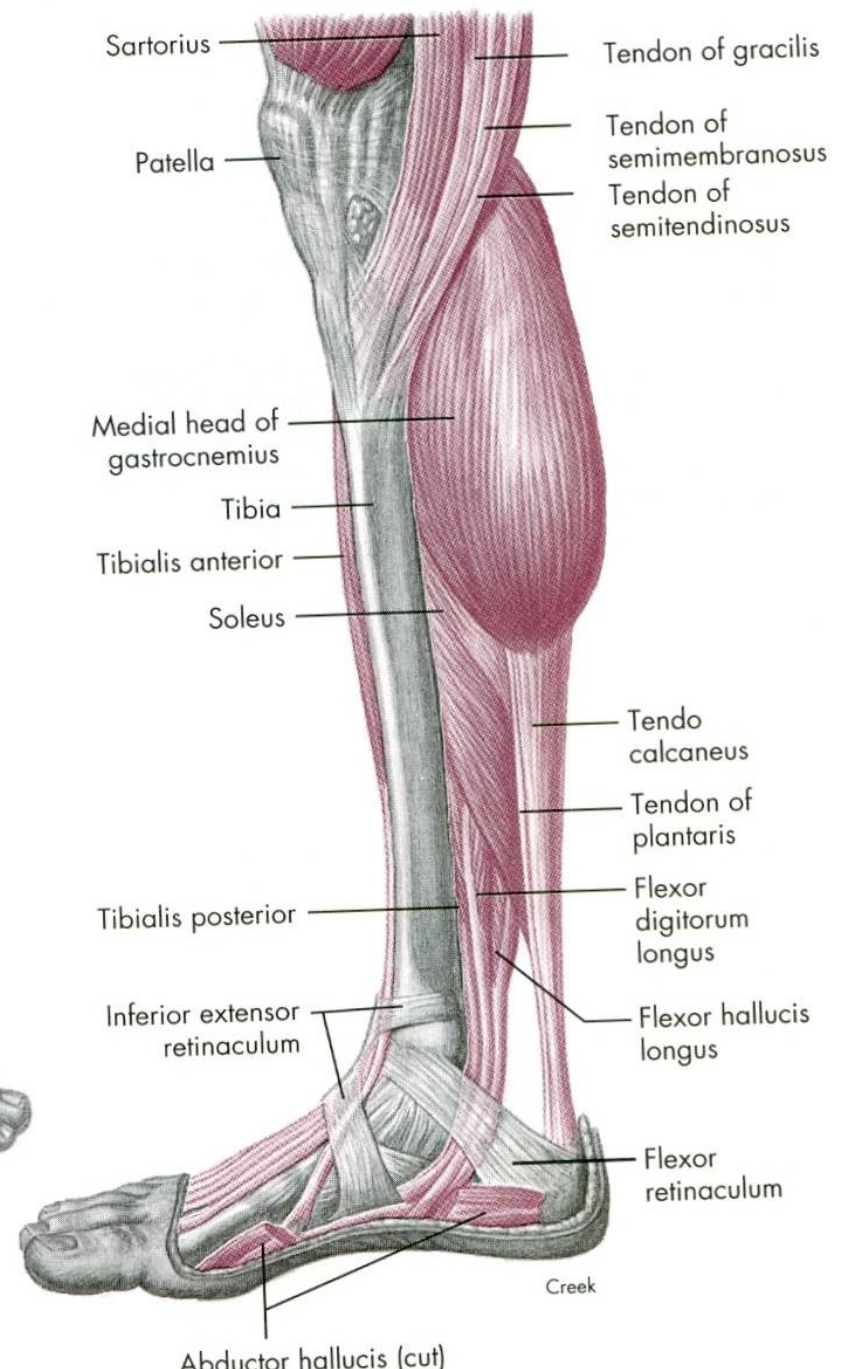


m. triceps surae



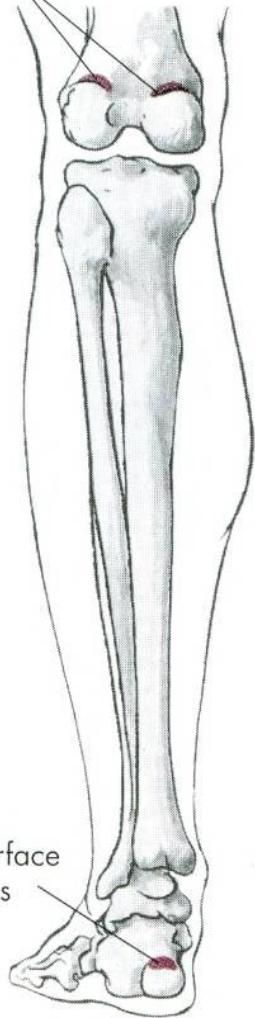


A



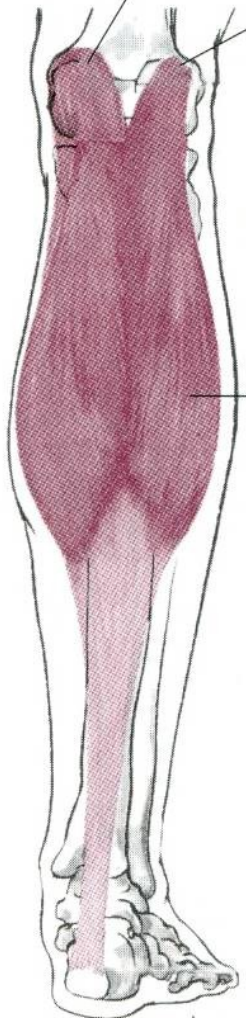
Creek

O, Posterior surfaces of two condyles of femur



I, Posterior surface of calcaneus

Medial head
Lateral head



Knee flexion

Gastrocnemius m

Plantar flexion

Proximal two-thirds of posterior surfaces of tibia and fibula

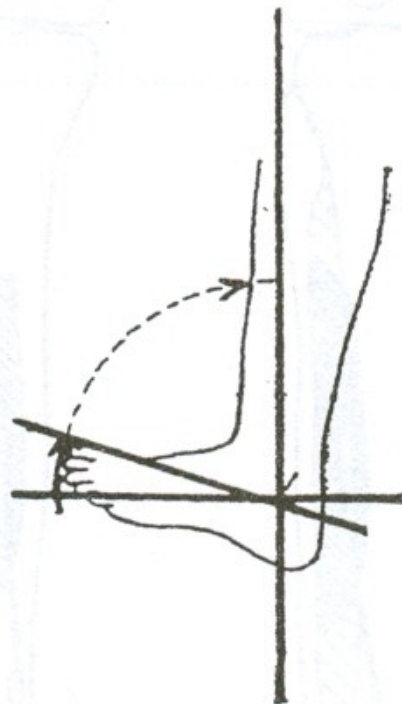
Posterior surface of calcaneus



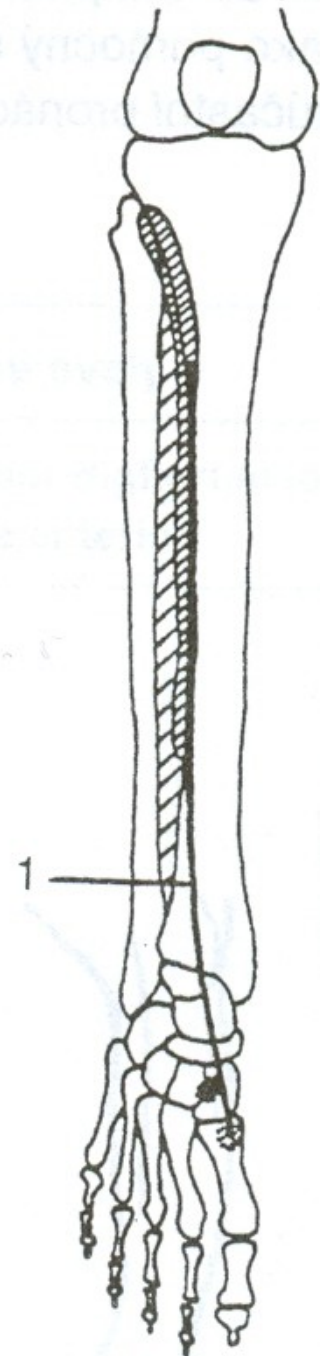
Soleus m.

Plantar flexion

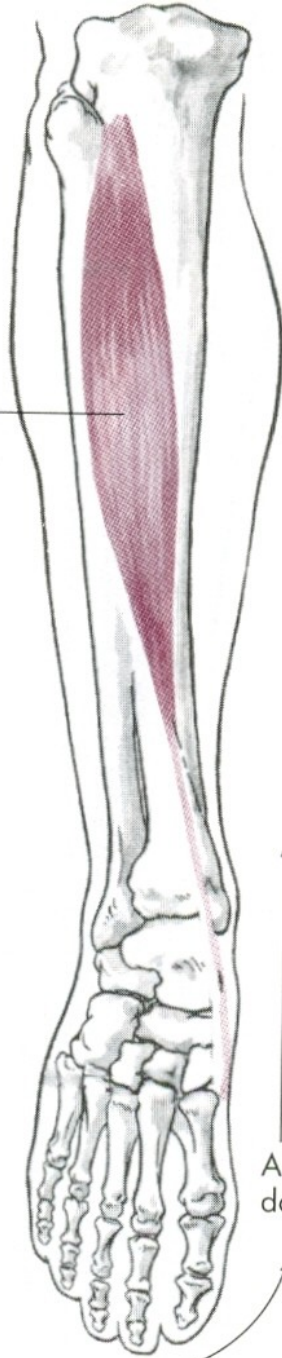
DORZÁLNÍ FLEXE - FAJFKY



m. tibialis anterior



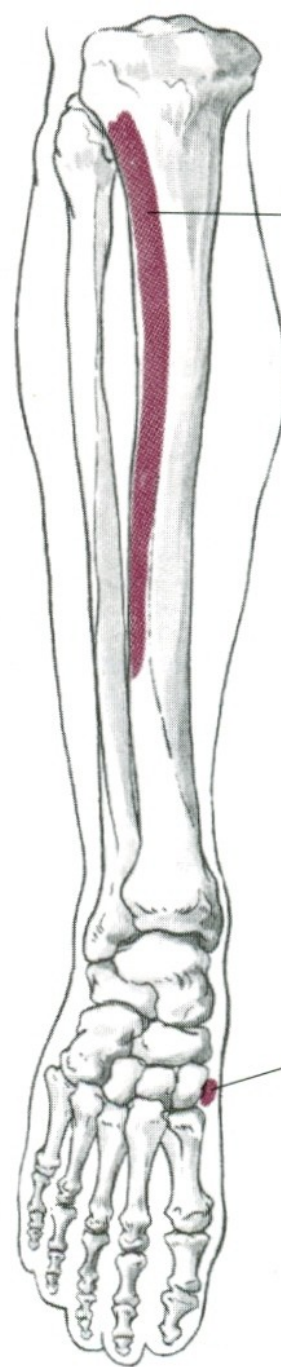
Tibialis anterior m.



Ankle dorsal flexion

Foot inversion

O, Upper two-thirds of lateral surface of tibia



I, Inner surface of medial cuneiform, base of the first metatarsal bones

PLANTÁRNÍ FLEXE

m. triceps surae – trojhlavý sval lýtkový

DORZÁLNÍ FLEXE

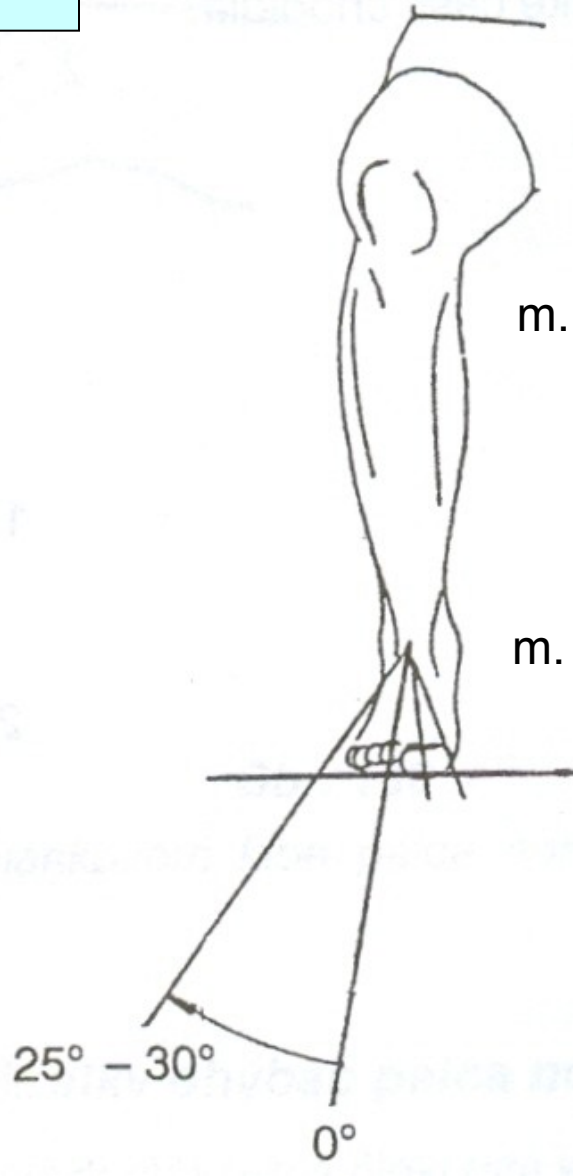
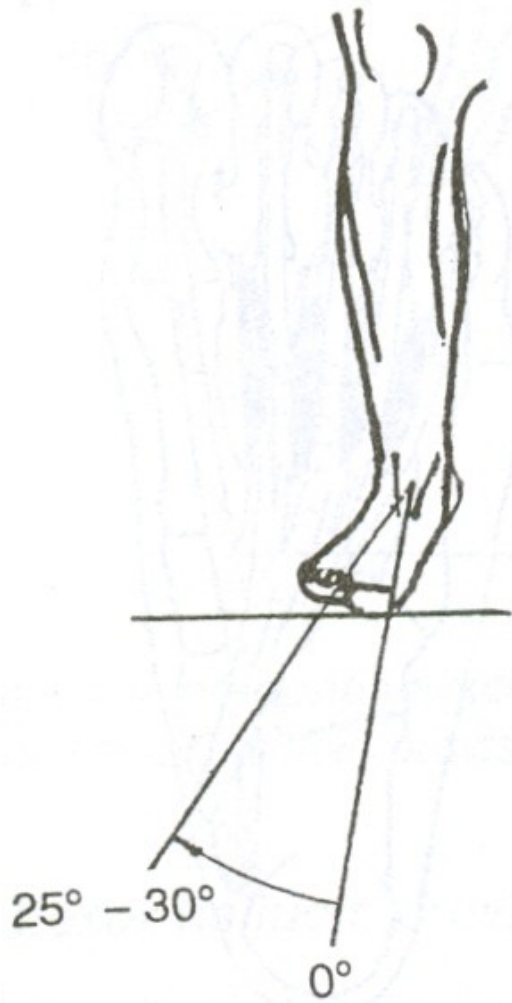
m. tibialis anterior – přední sval holenní

POHYBY DOLNÍHO KLOUBU ZÁNÁRTNÍHO

EVERZE

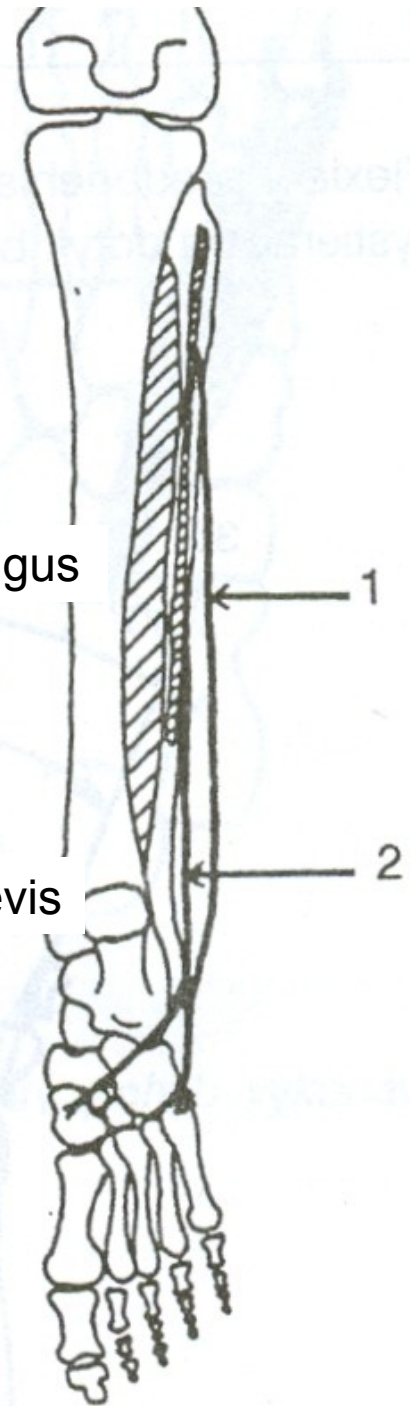
INVERSE

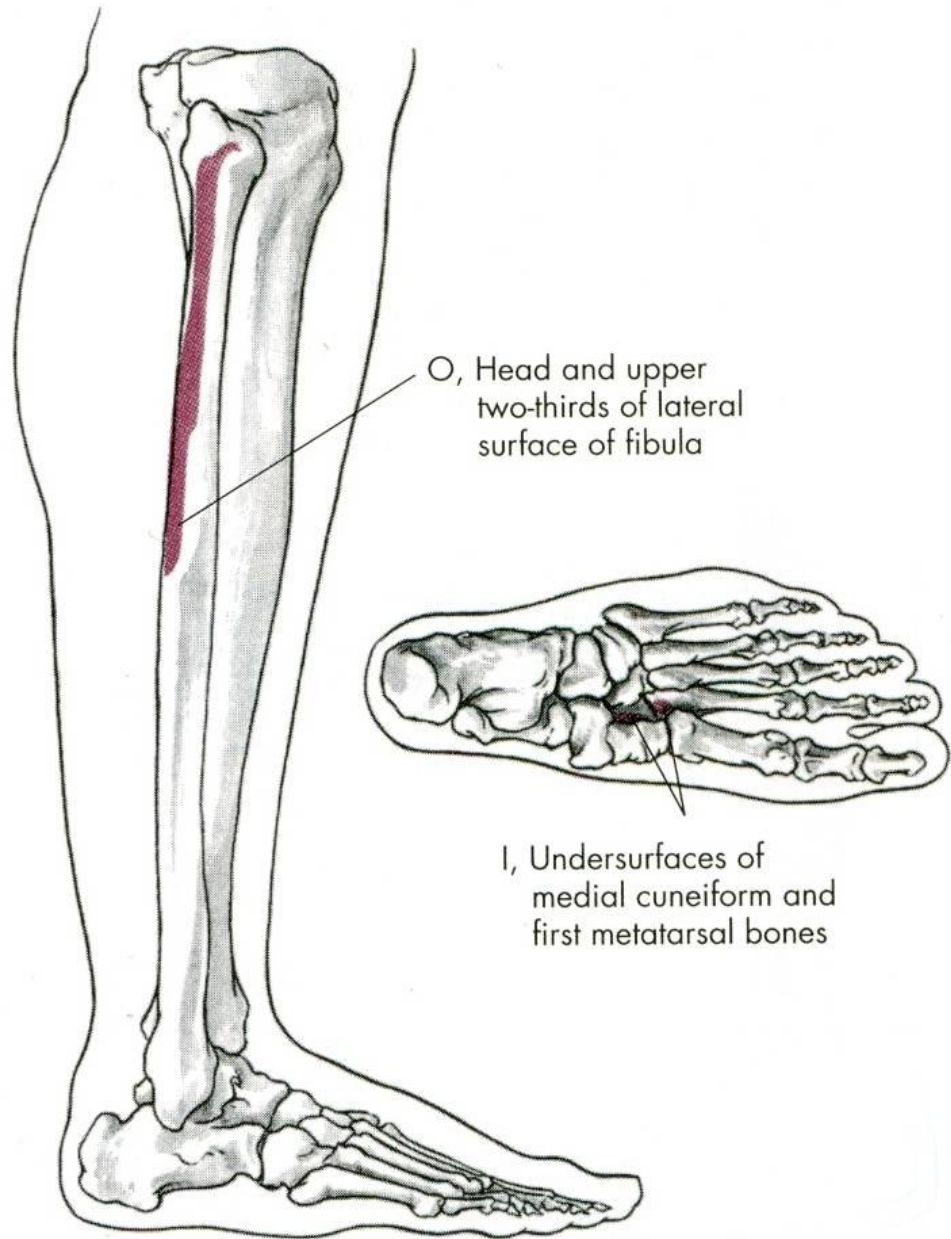
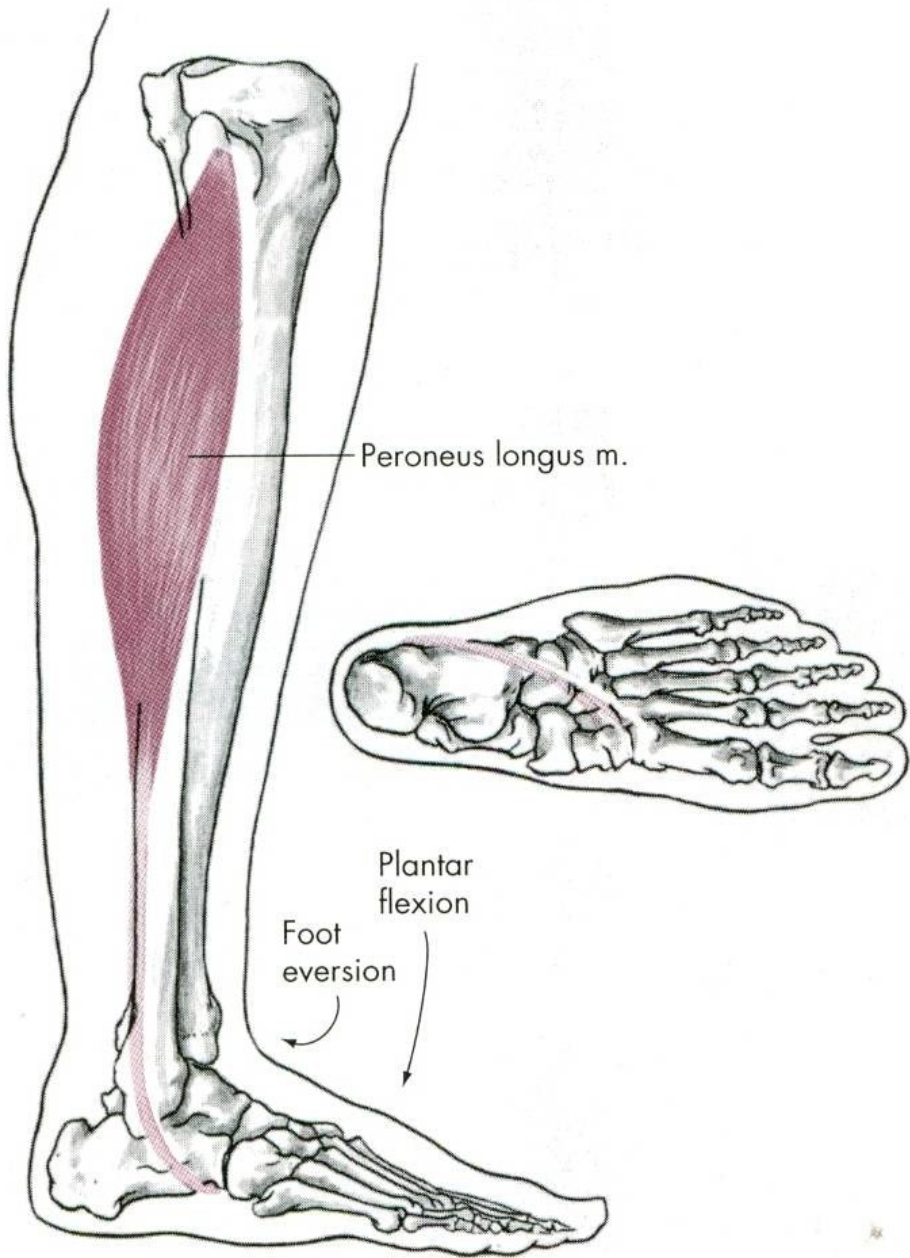
EVERZE

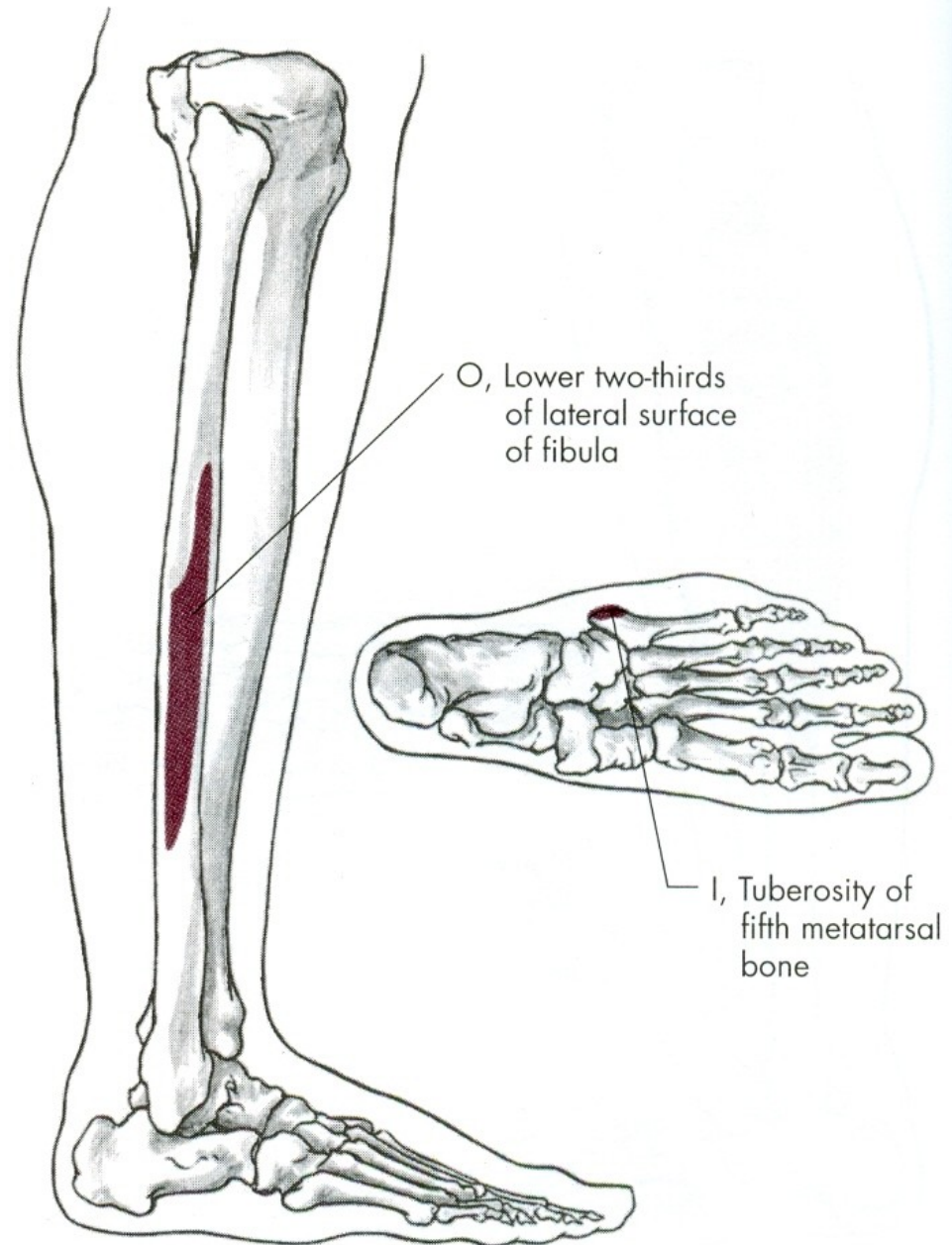
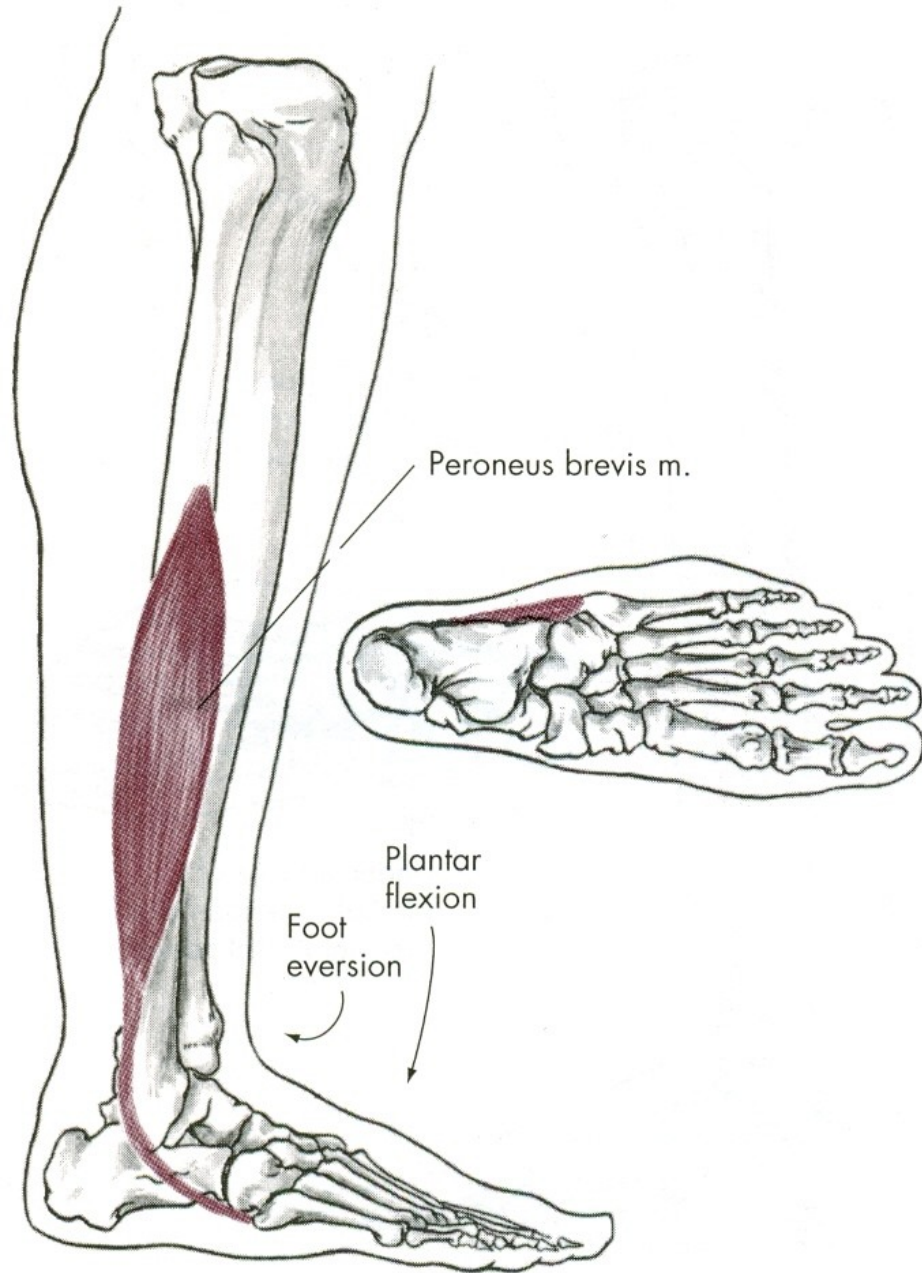


m. peroneus longus

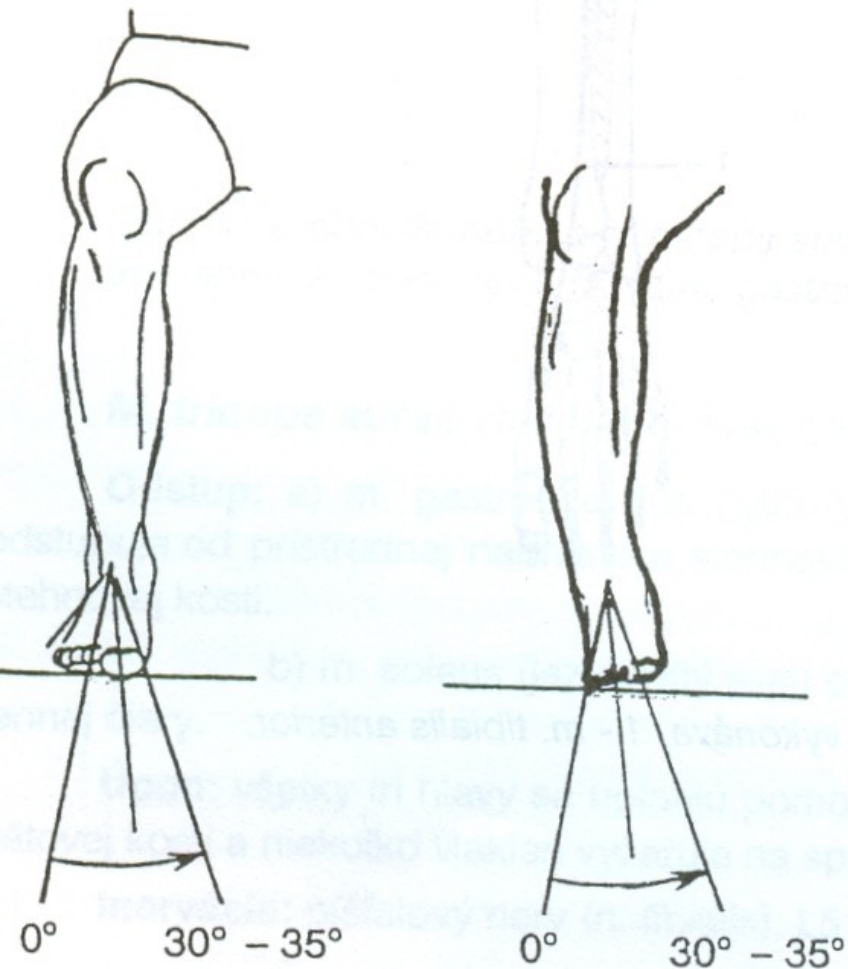
m. peroneus brevis







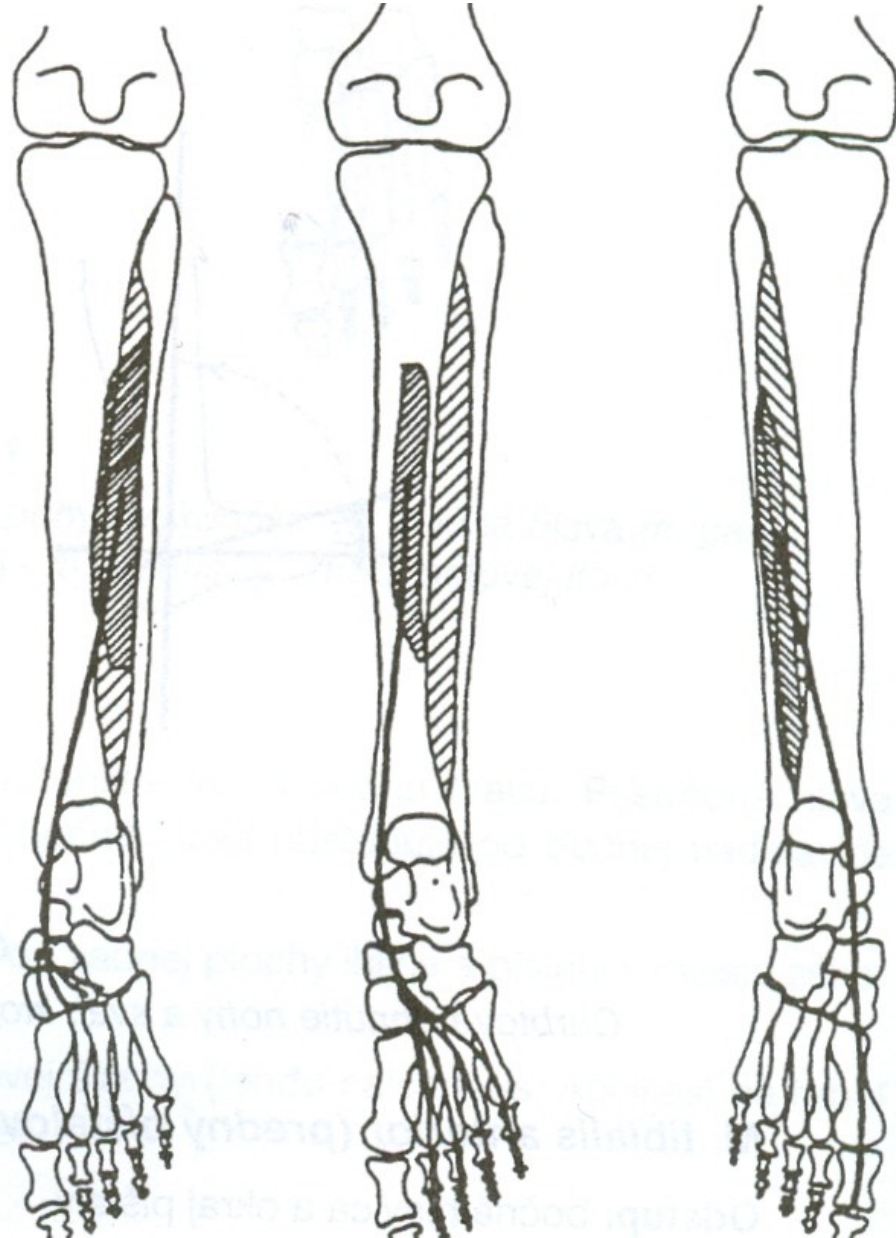
INVERSE



m. tibialis posterior

m. flexor digitorum longus

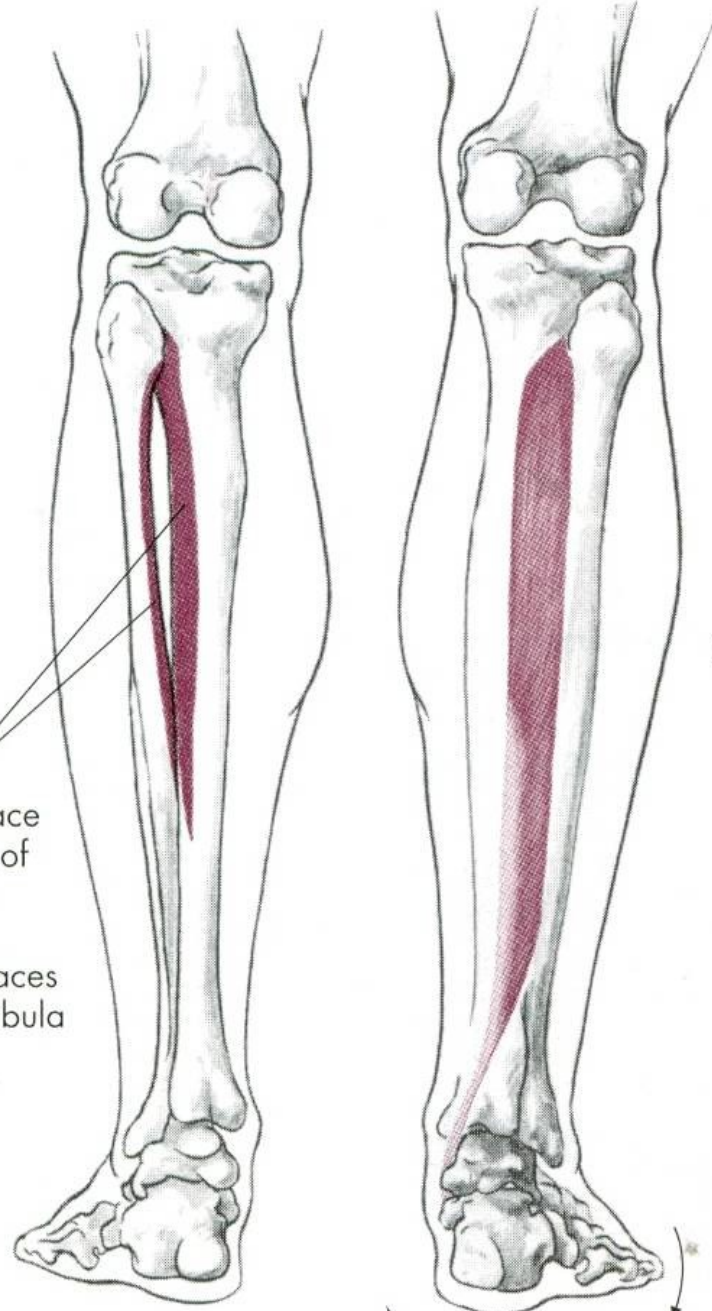
m. flexor hallucis longus



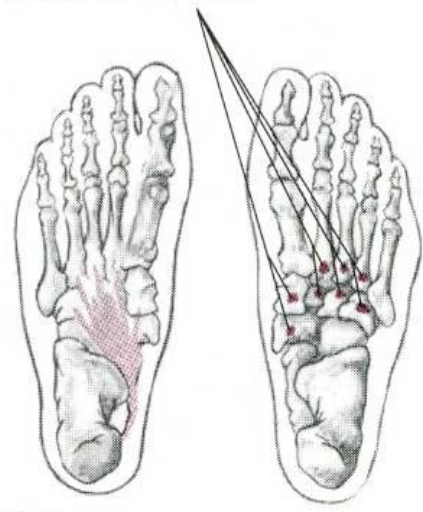
m. tibialis posterior

O, Posterior surface of upper half of interosseous membrane, adjacent surfaces of tibia and fibula

I, Lower inner surfaces of navicular and cuneiform bones, bases of second, third, fourth, and fifth metatarsal bones



Foot inversion
Plantar flexion



EVERSE NOHY

m. peroneus longus

m. peroneus brevis

INVERSE NOHY

m. tibialis posterior – zadní sval holenní

m. flexor digitorum longus

m. flexor hallucis longus

POHYBY PRSTŮ

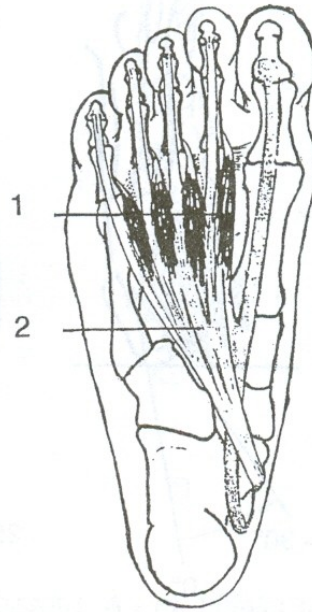
FLEXE - OHNUTÍ

EXTENZE - NATAŽENÍ

ABDUKCE - ODTAŽENÍ

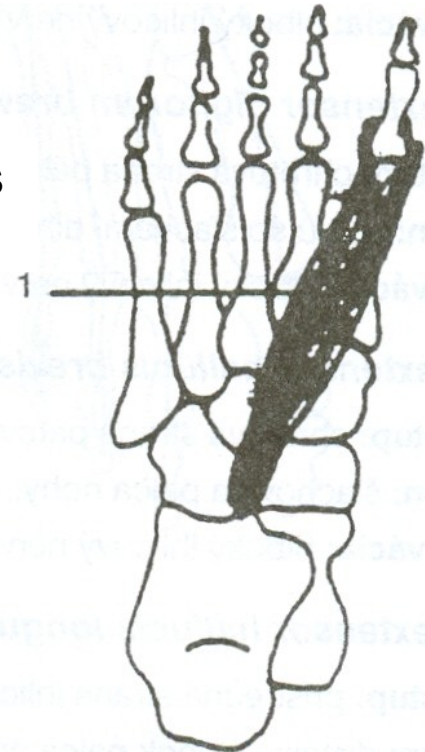
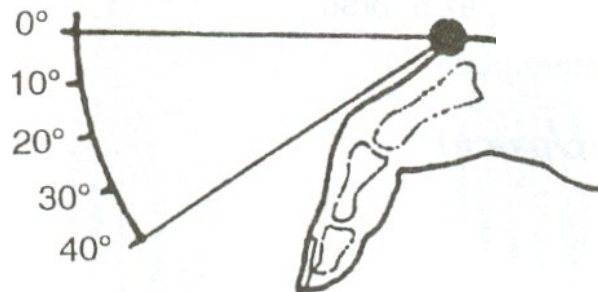
ADDUKCE - PŘITAŽENÍ

mm. lumbricales



FLEXE

m. flexor hallucis
brevis



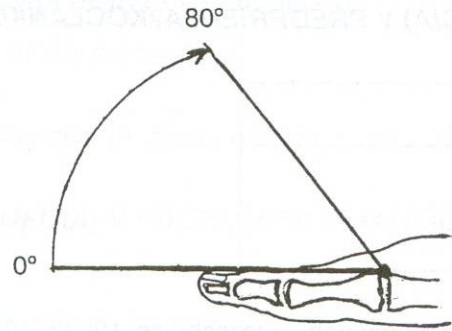
FLEXE PRSTŮ a PALCE

mm. lumbricales

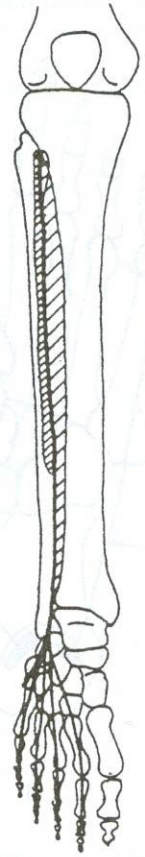
m. flexor digitorum brevis et longus –
krátký a dlouhý ohybač prstů

m. flexor hallucis brevis et longus –
krátký a dlouhý ohybač palce

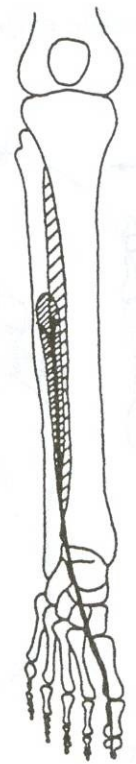
EXTENZE



m. extensor digitorum longus



m. extensor hallucis longus



m. extensor hallucis brevis

