

POHYBY HORNÍCH KONČETIN



POHYBY RAMENNÍHO KLOUBU

FLEXE - PŘEDPAŽENÍ

EXTENZE - ZAPAŽENÍ

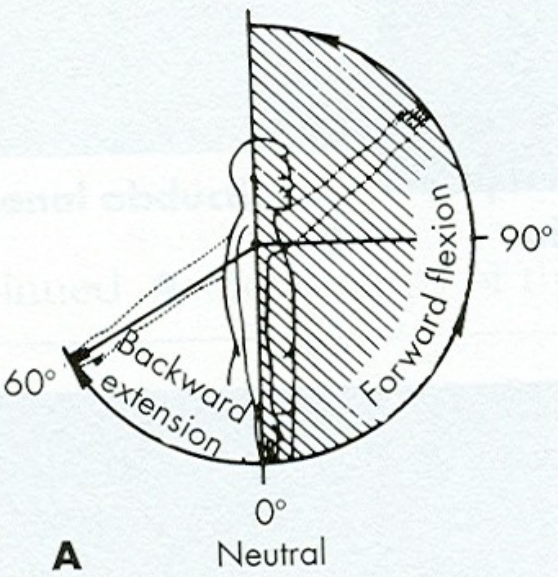
ABDUKCE - UPAŽENÍ

ADDUKCE - PŘIPAŽENÍ

VNITŘNÍ ROTACE

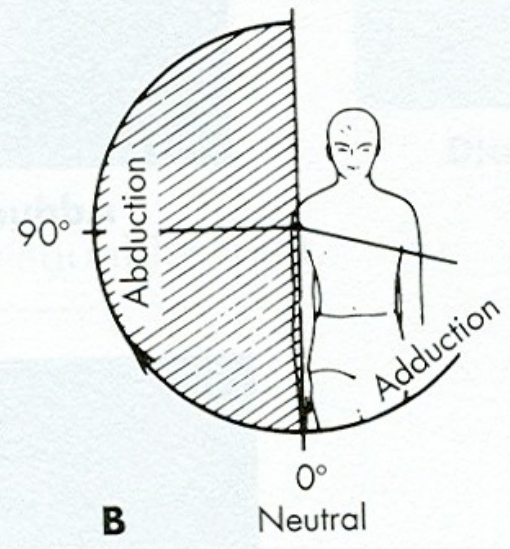
VNĚJŠÍ ROTACE

SAGITTAL PLANE
180°



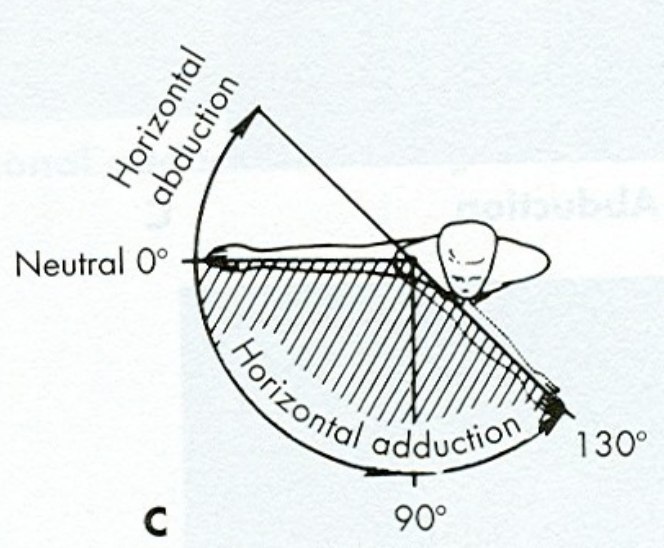
A

FRONTAL PLANE
180°

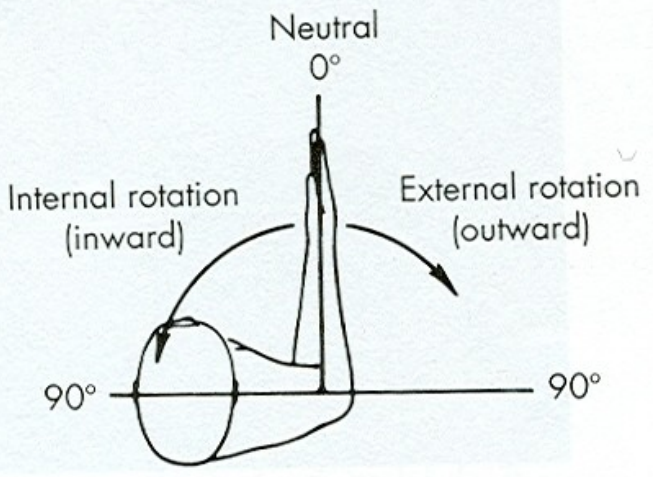


B

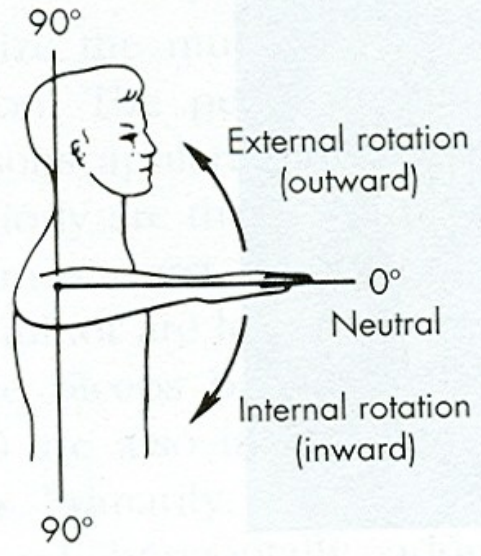
HORIZONTAL PLANE
180°



C

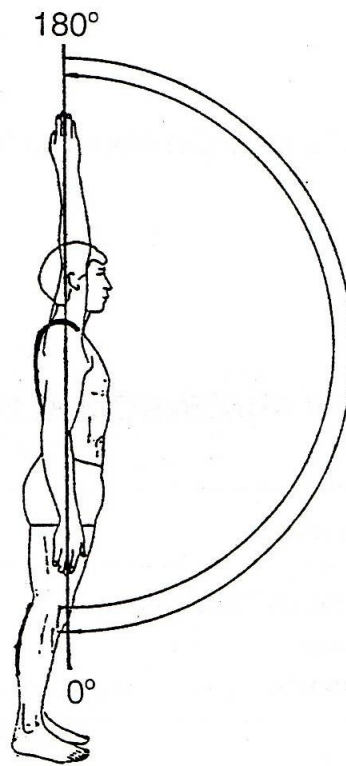


D

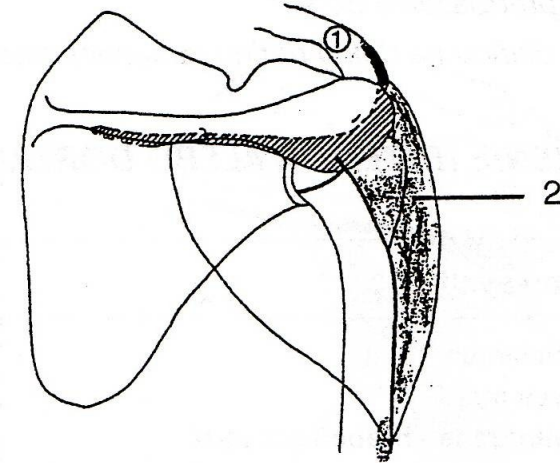


E

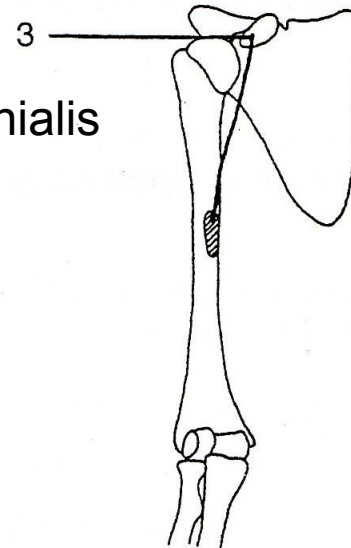
FLEXE - PŘEDPAŽENÍ



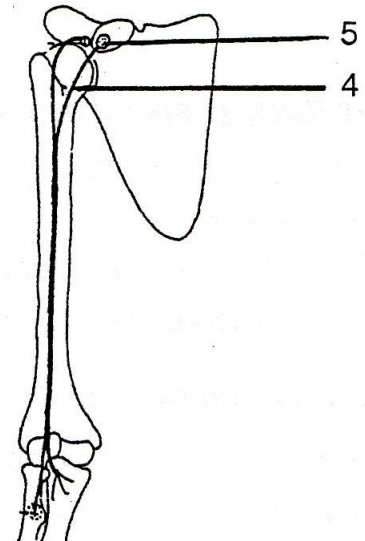
m. deltoideus
(pars clavicularis)

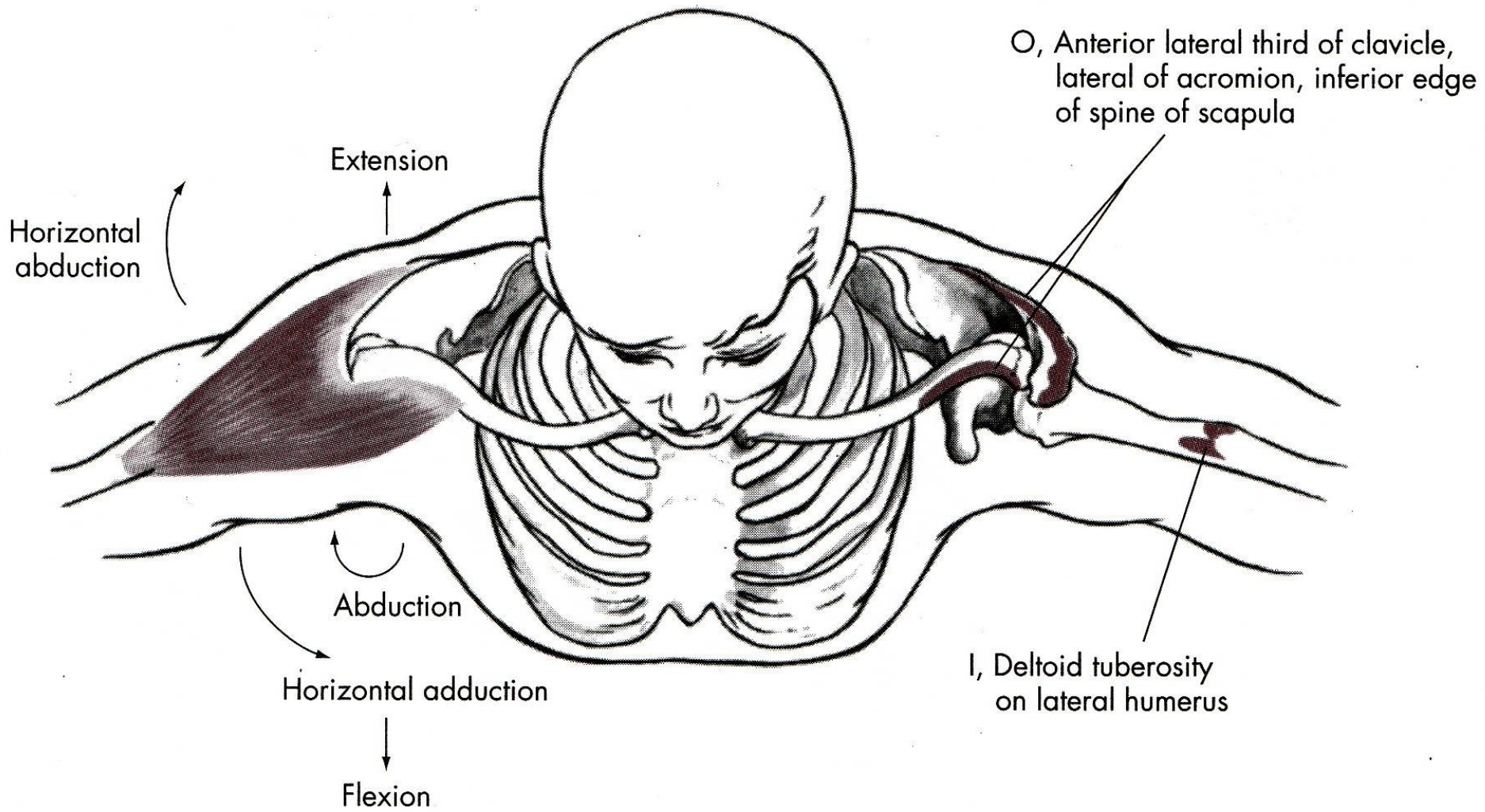


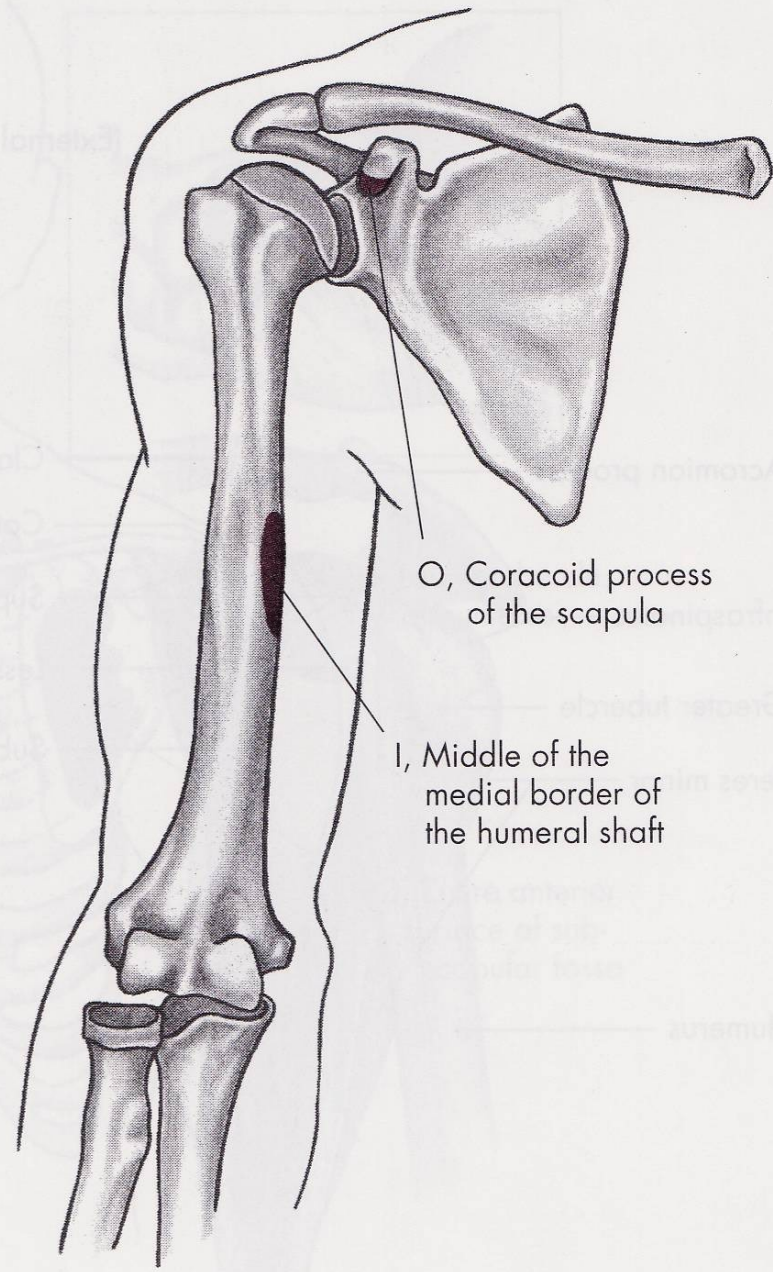
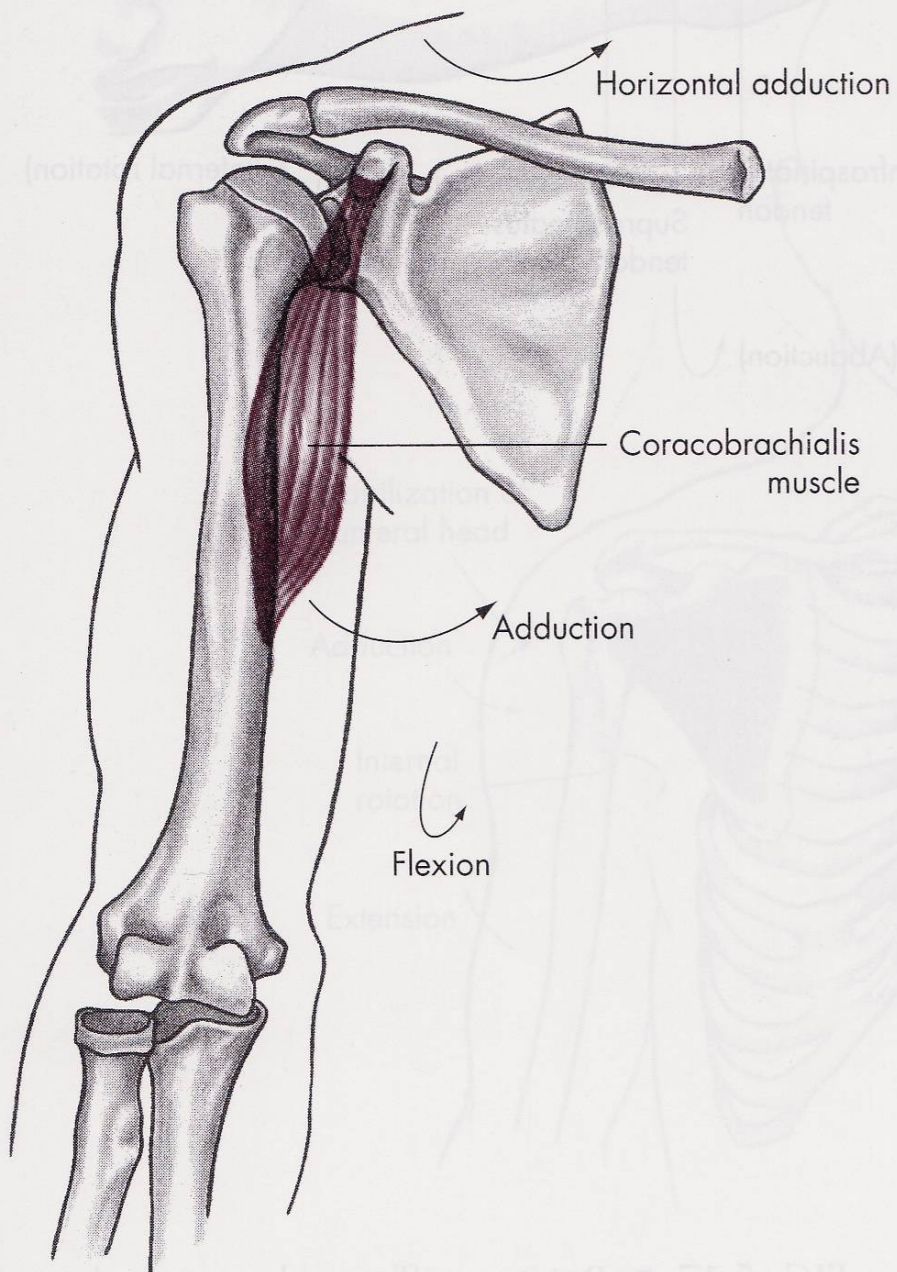
m. coracobrachialis



m. biceps brachii







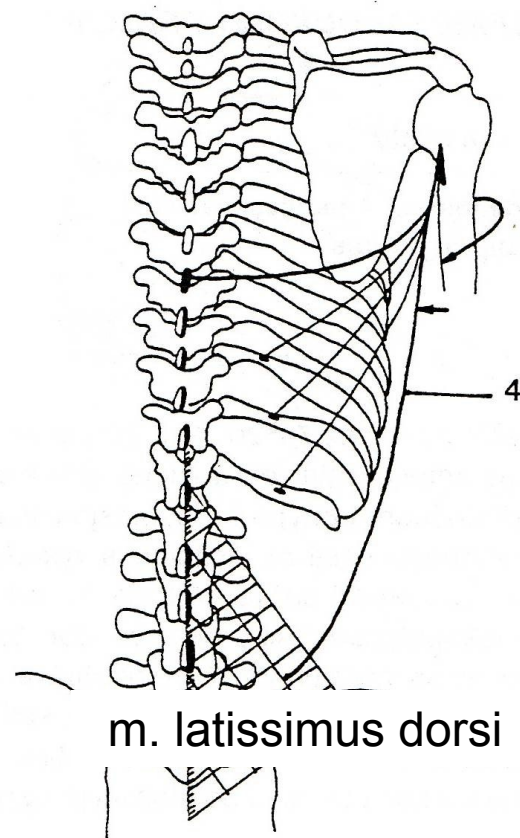
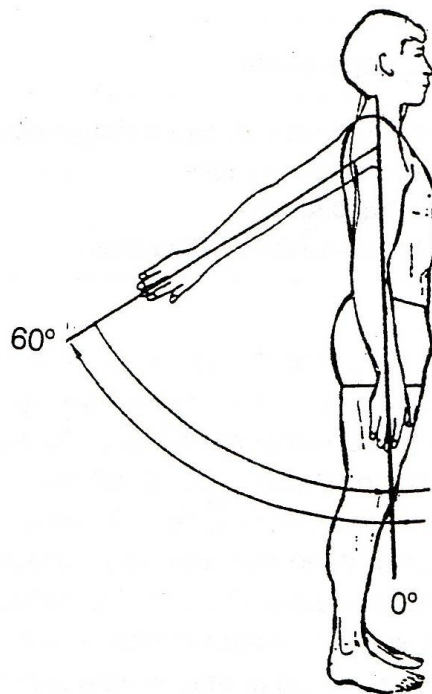
FLEXE

m. deltoideus-pars clavicularis
– sval deltový-kliční část

m. coracobrachialis – vnitřní sval pažní

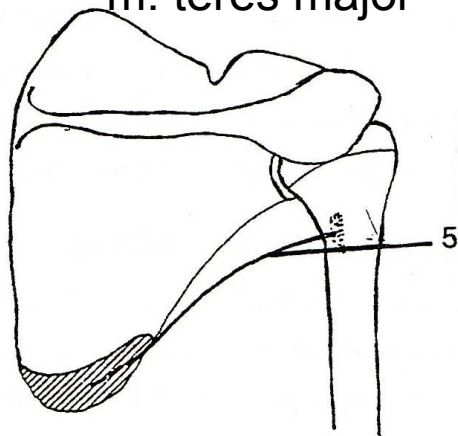
m. biceps brachii-caput breve –
dvojhlavý sval pažní-krátká hlava

EXTENZE - ZAPAŽENÍ

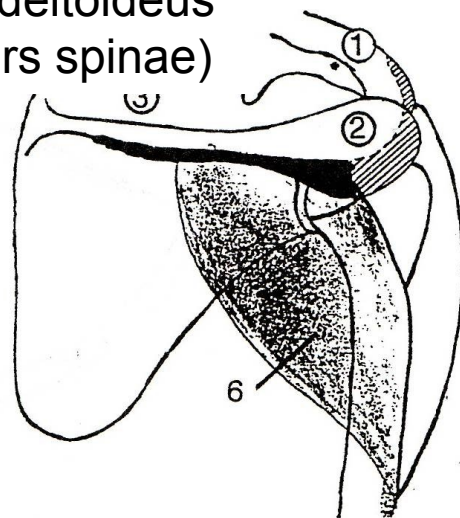


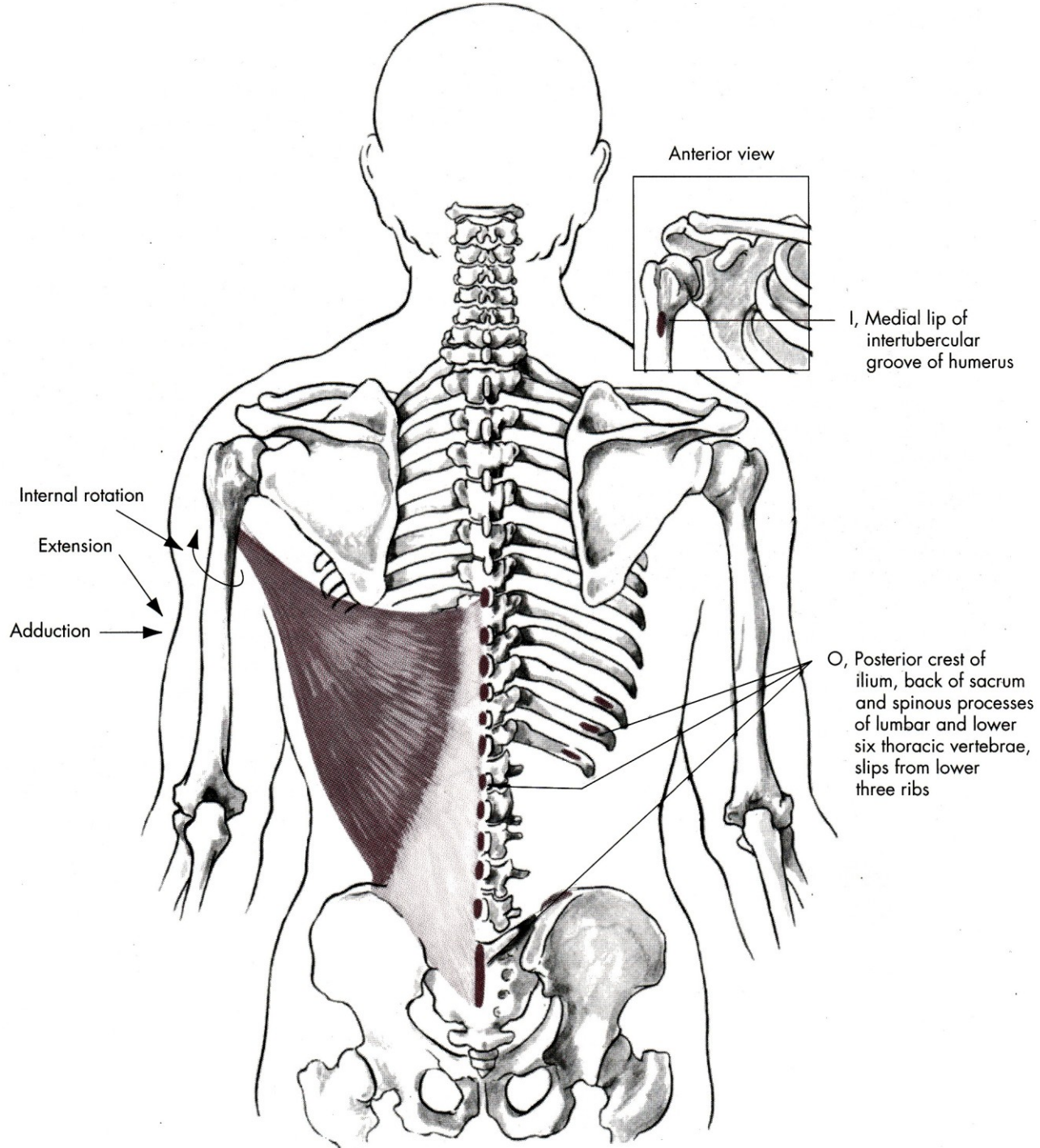
m. latissimus dorsi

m. teres major

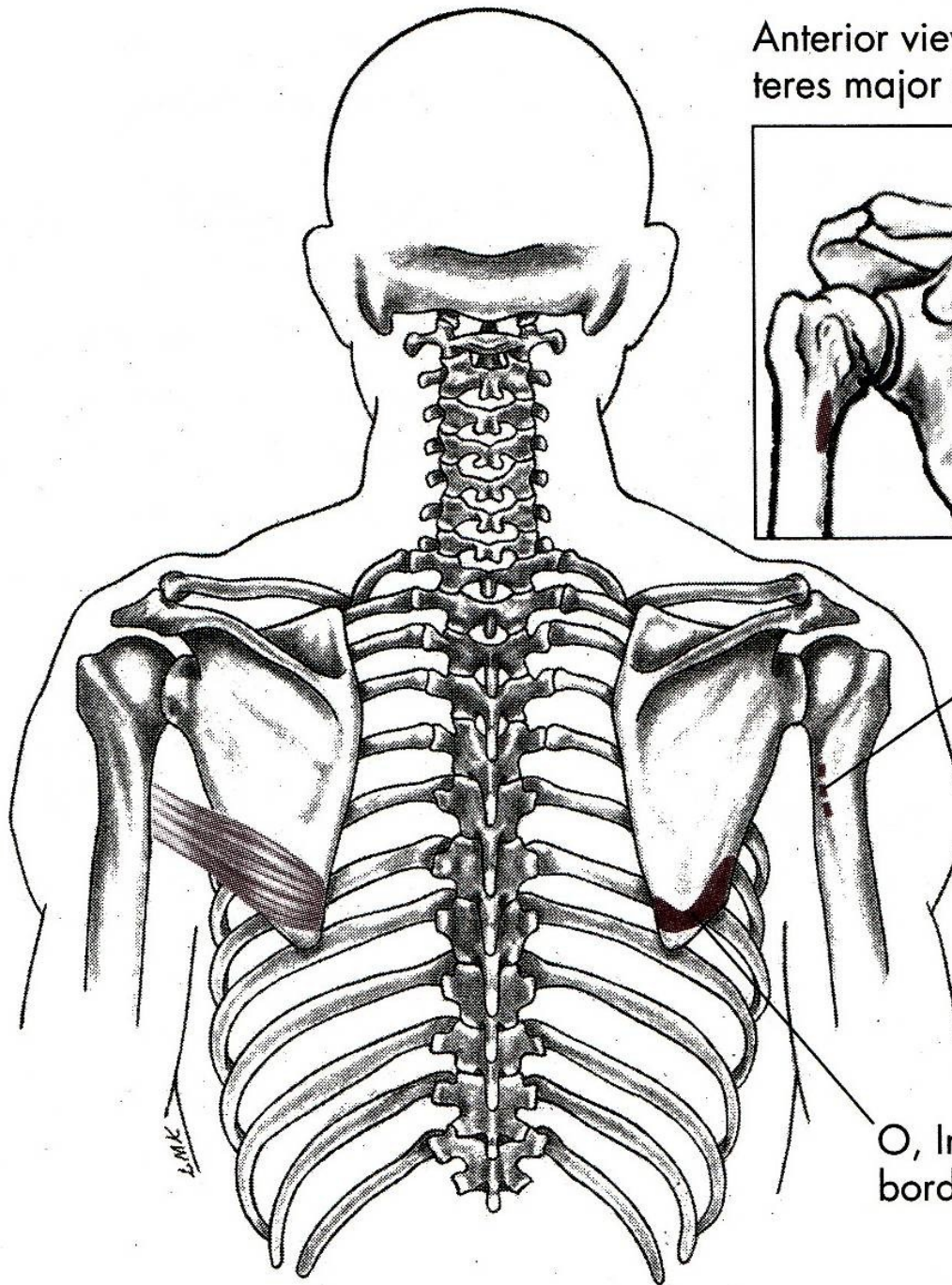
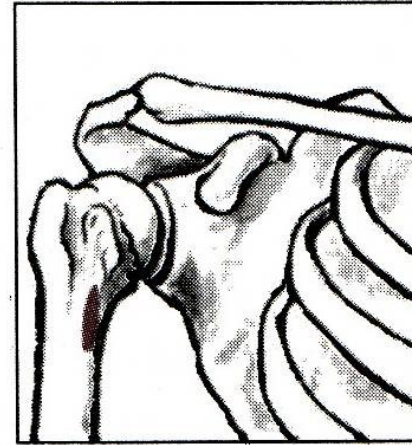


m. deltoideus
(pars spinae)





Anterior view with
teres major insertion



I, Medial lip of the
intertubercular groove
of the humerus

O, Inferior third of lateral
border of scapula

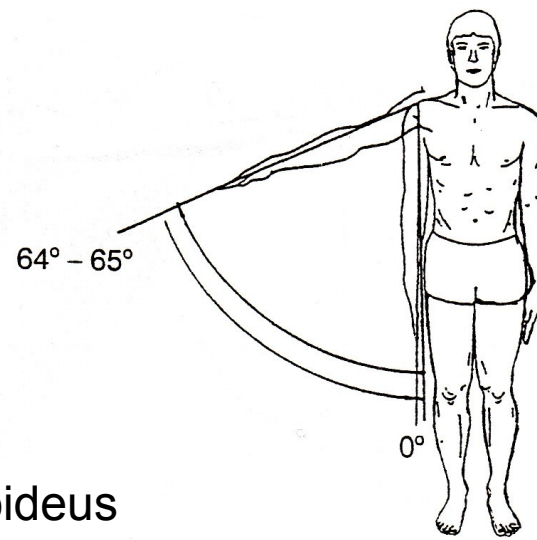
EXTENZE

m. deltoideus-pars spinae
– sval deltový-spinální část

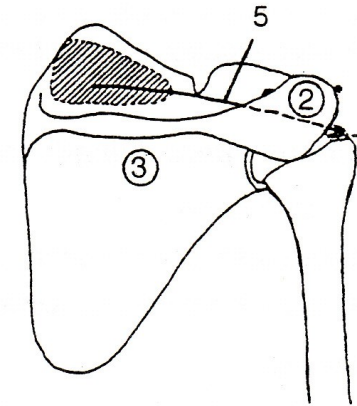
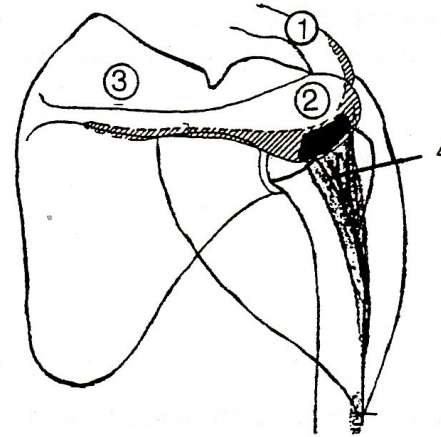
m. latissimus dorsi – široký sval zádový

m. teres major – velký sval oblý

ABDUKCE - UPAŽENÍ

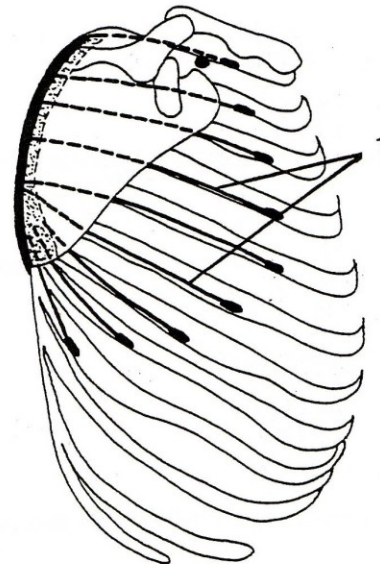
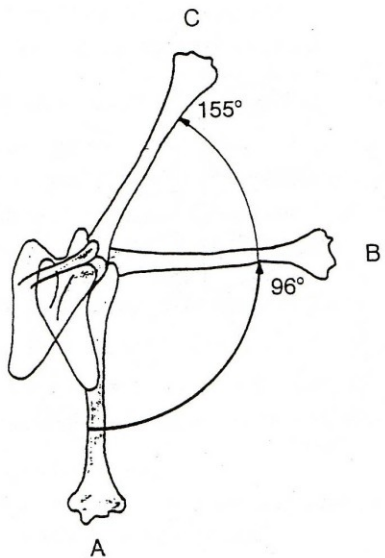


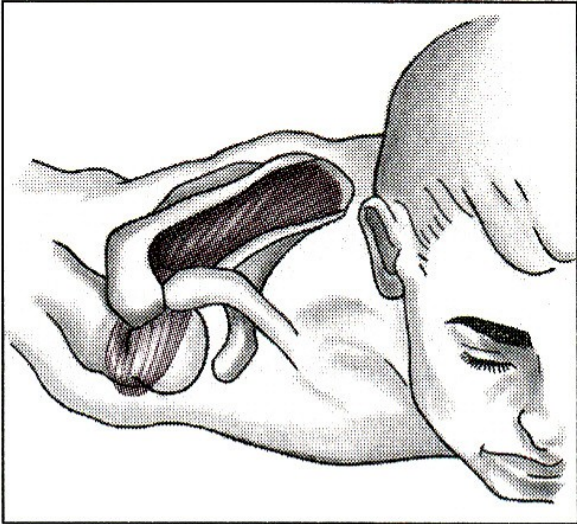
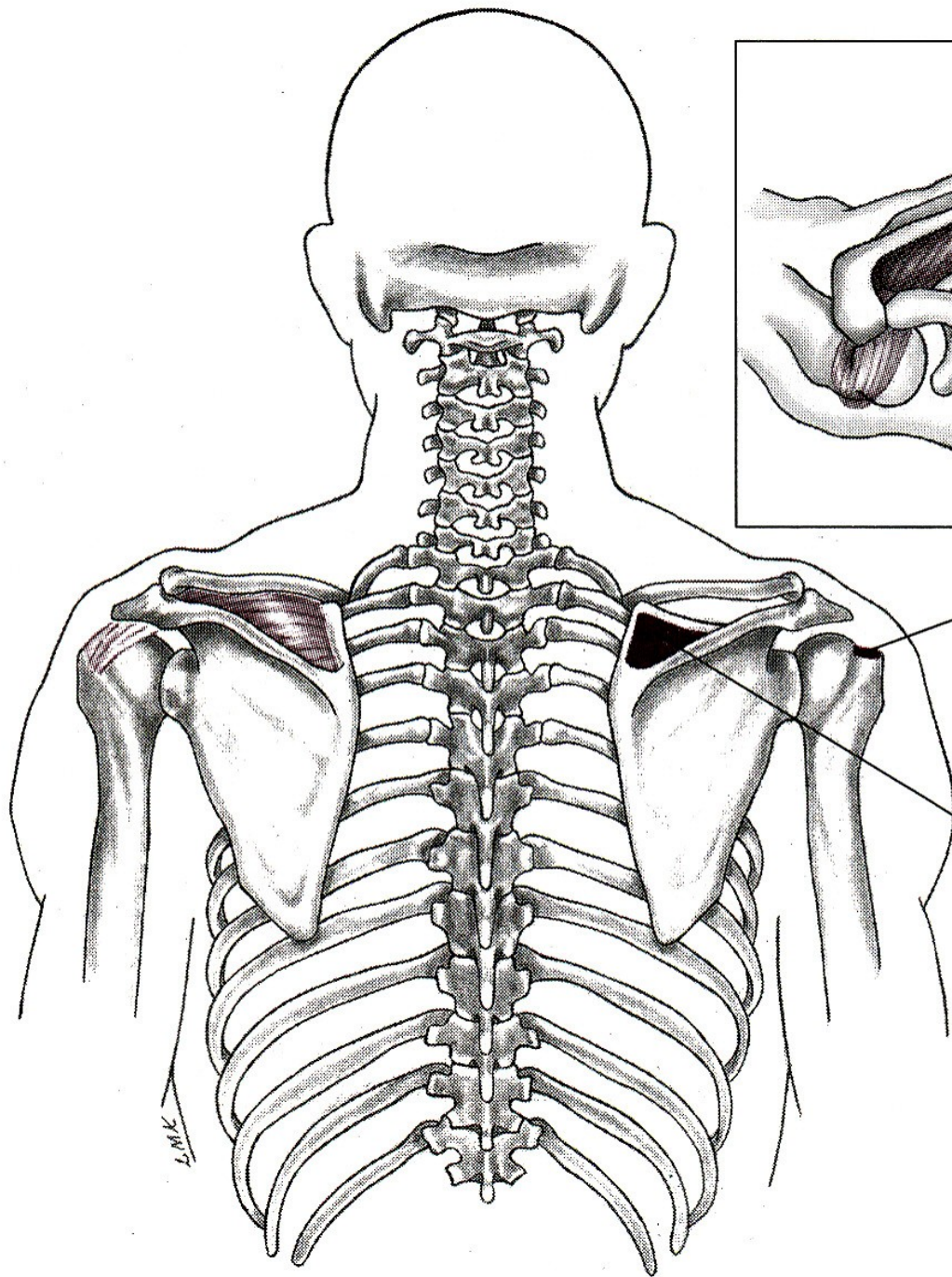
m. deltoideus
(pars akromialis)



m. supraspinatus

m. serratus anterior



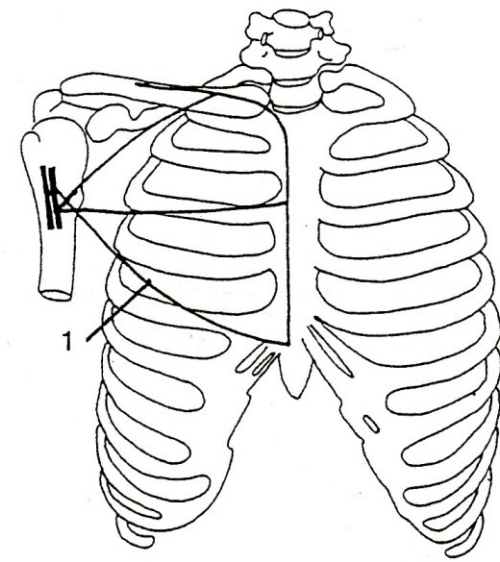
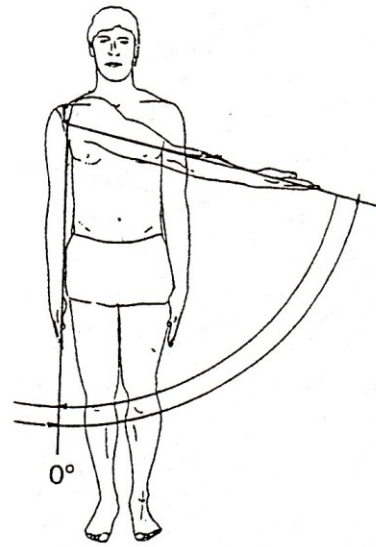


I, Superiorly on greater tubercle of humerus

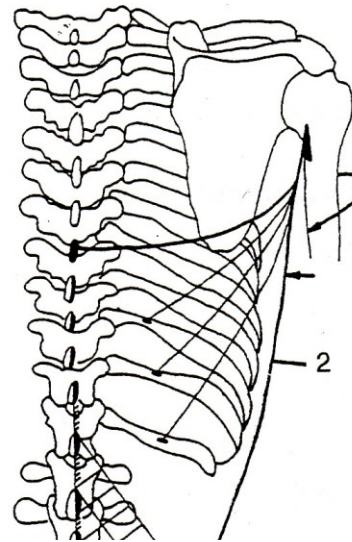
O, Medial two-thirds of supraspinatus fossa

L.M.K.

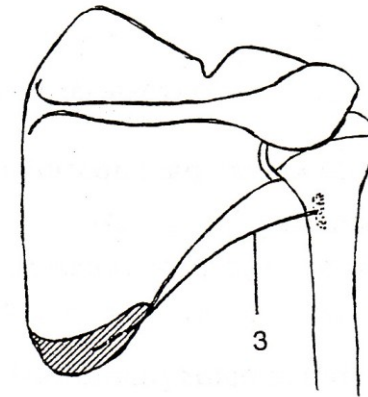
ADDUKCE - PŘIPAŽENÍ



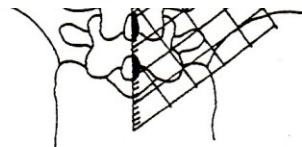
m. pectoralis major

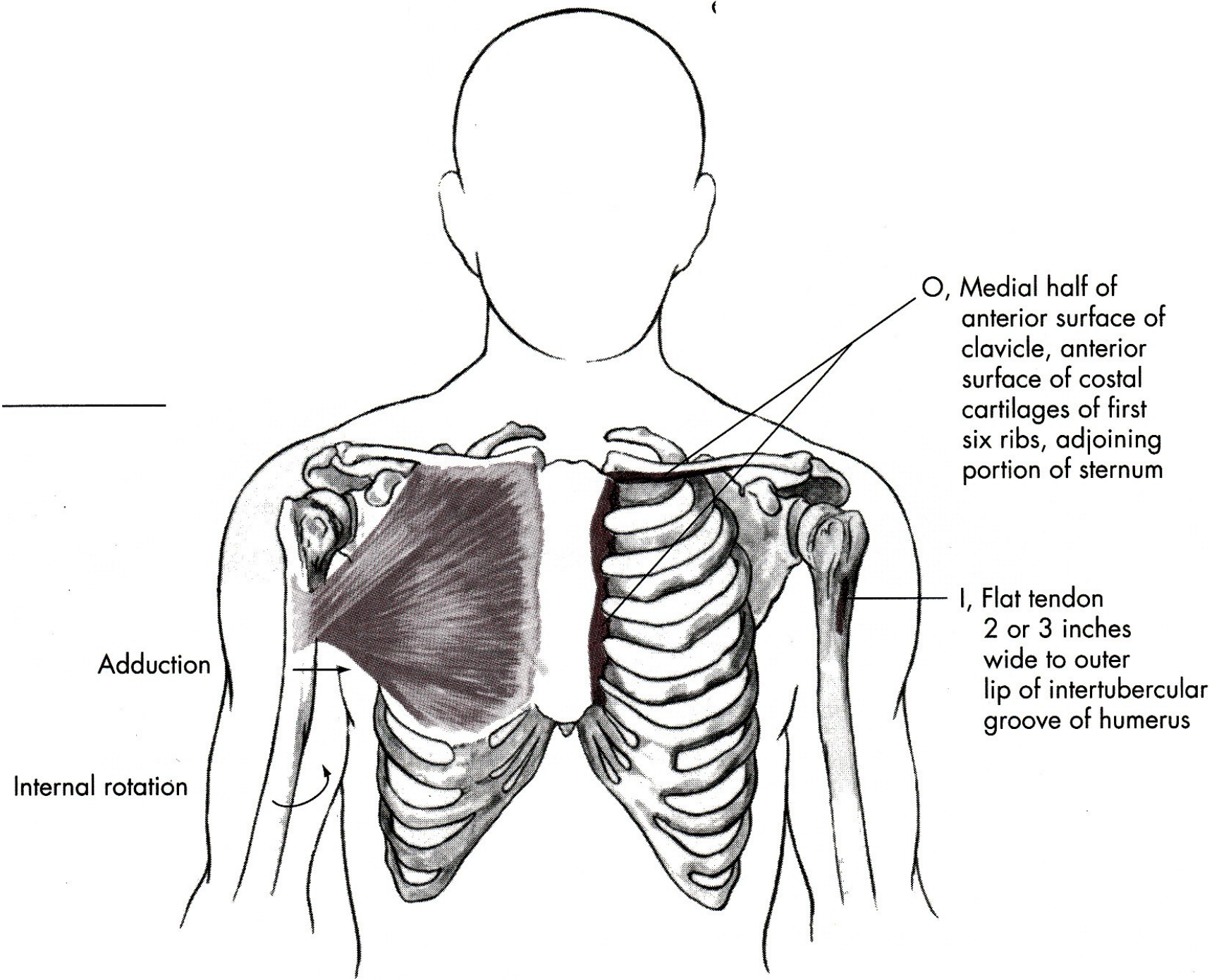


m. latissimus dorsi



m. teres major





Adduction

Internal rotation

O, Medial half of anterior surface of clavicle, anterior surface of costal cartilages of first six ribs, adjoining portion of sternum

I, Flat tendon 2 or 3 inches wide to outer lip of intertubercular groove of humerus

ABDUKCE

m. deltoideus-pars akromion
– sval deltový-akromiální část

m. supraspinatus – sval nadhřebenový

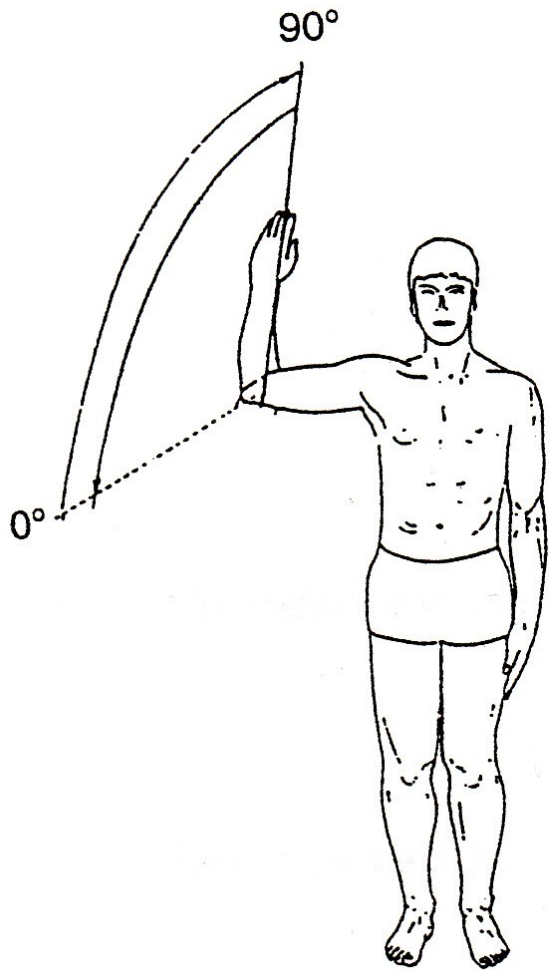
ADDUKCE

m. pectoralis major – velký sval prsní

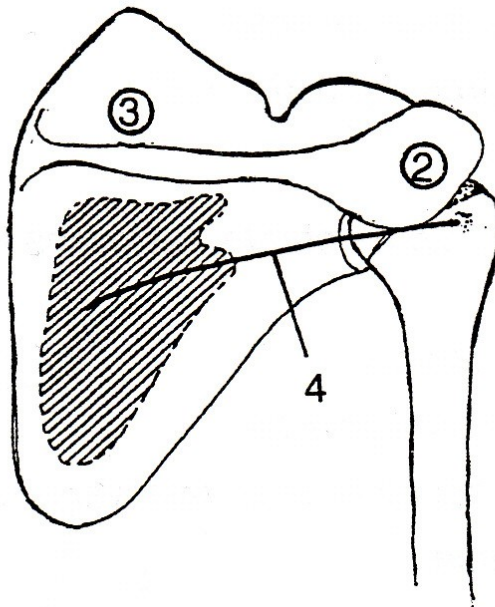
m. latissimus dorsi – široký sval zádový

m. teres major – velký sval oblý

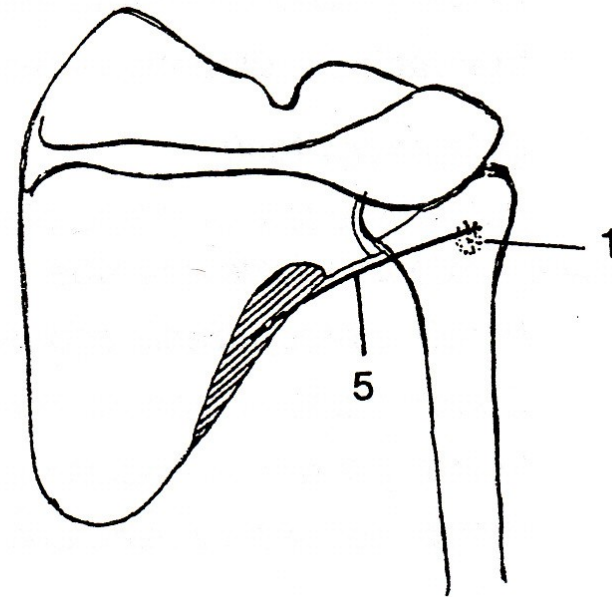
VNĚJŠÍ ROTACE



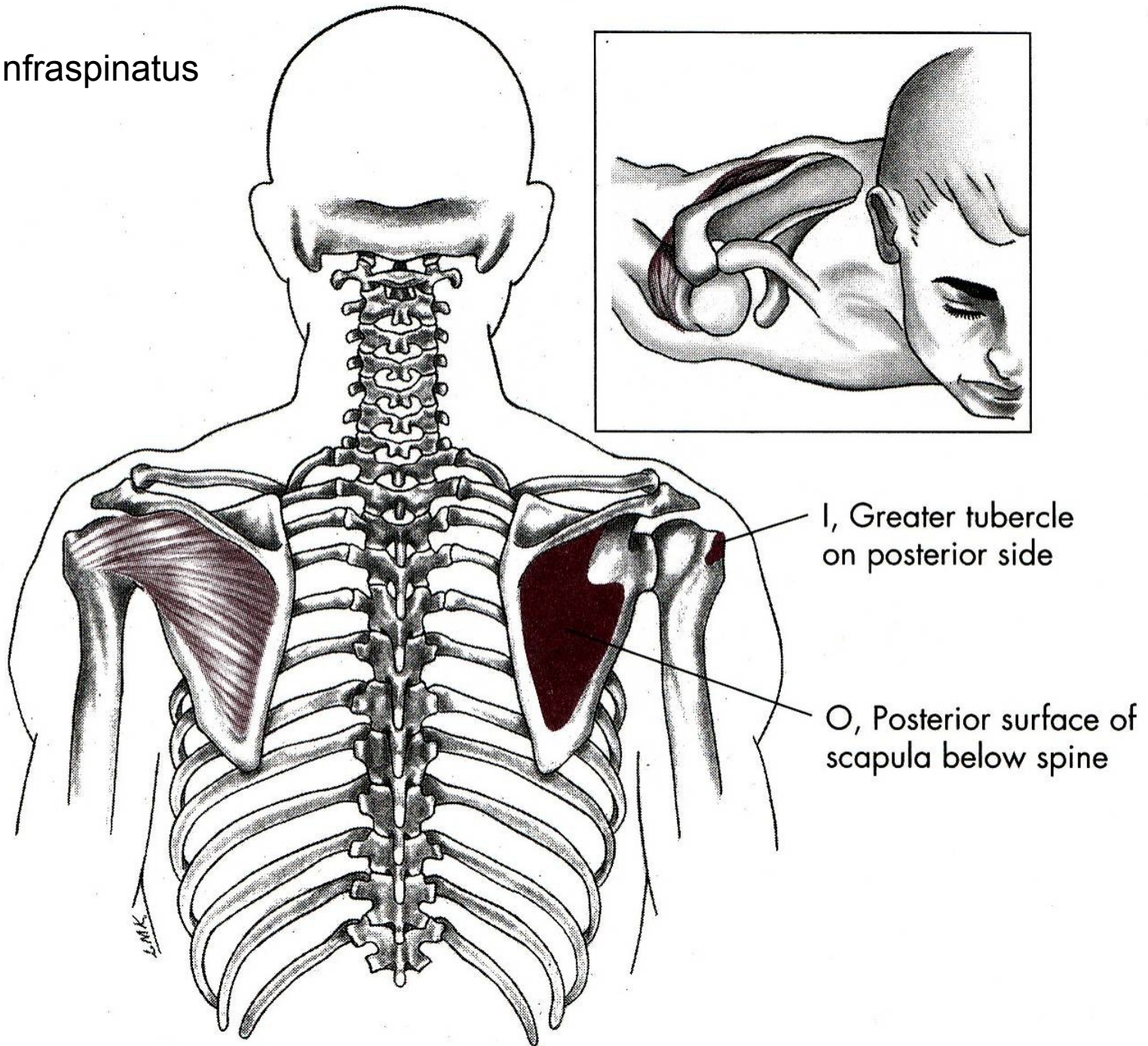
m. infraspinatus



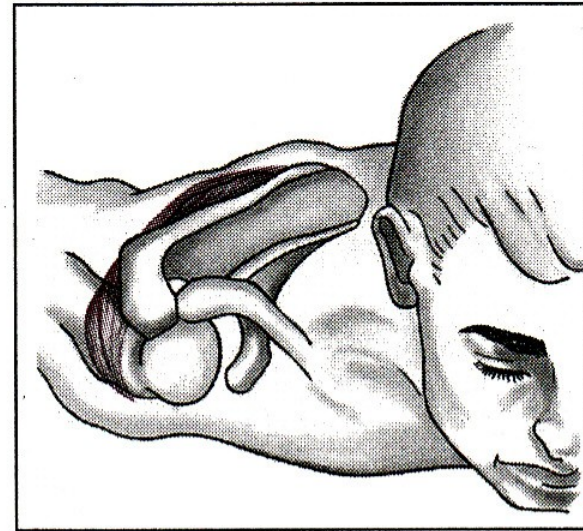
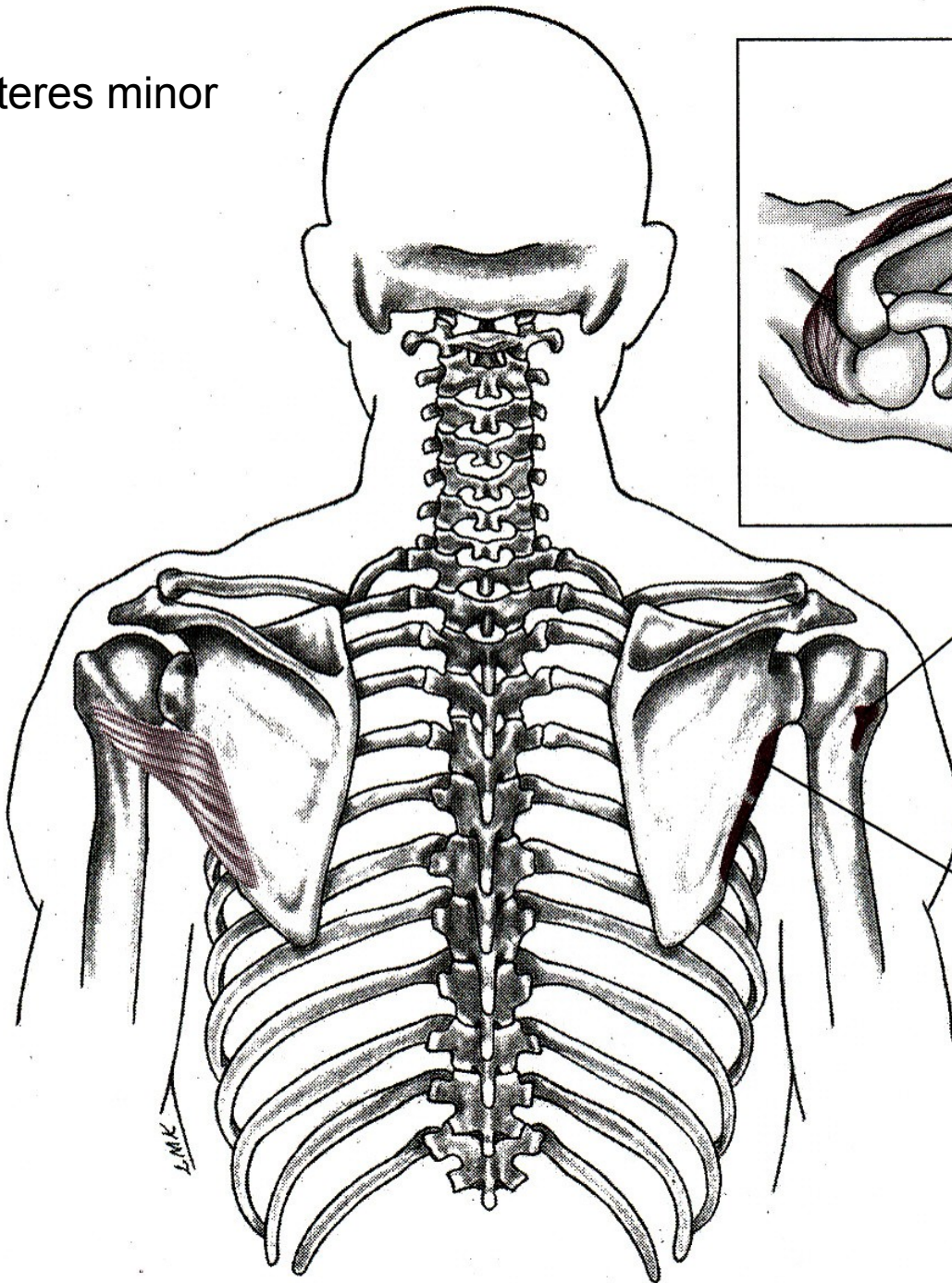
m. teres minor



m. infraspinatus



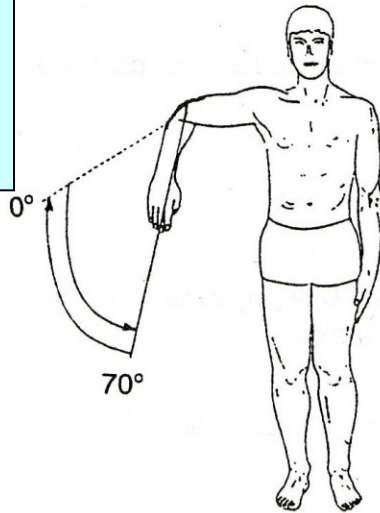
m. teres minor



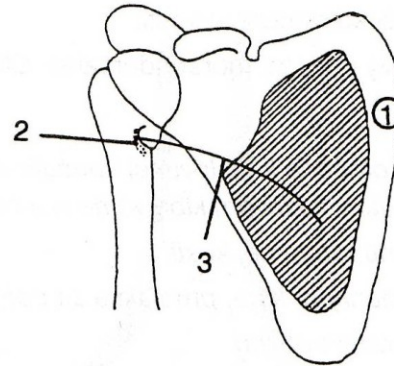
I, Greater tubercle
of humerus on
posterior side

O, Posterior scapula,
lateral border

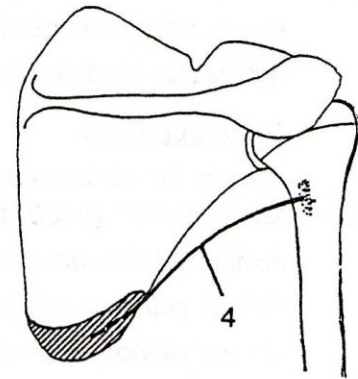
VNITŘNÍ ROTACE



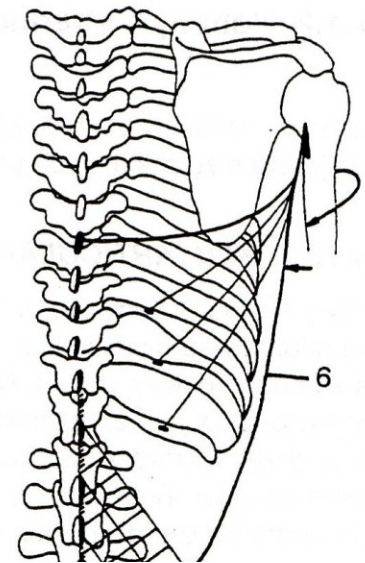
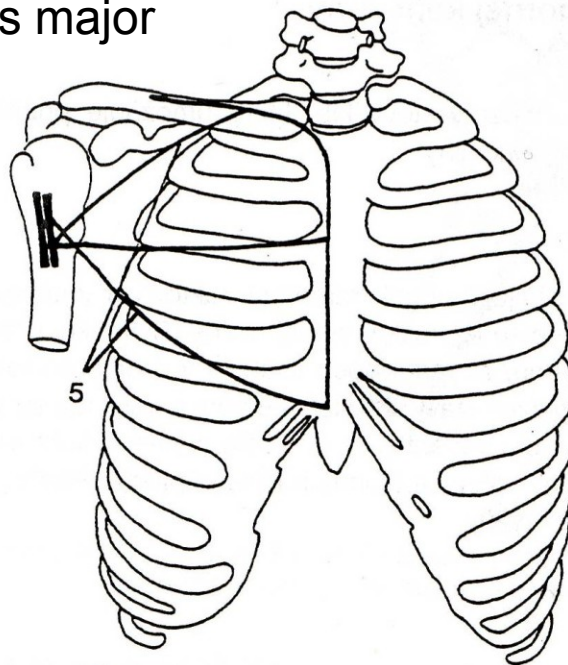
m. subscapularis



m. teres major

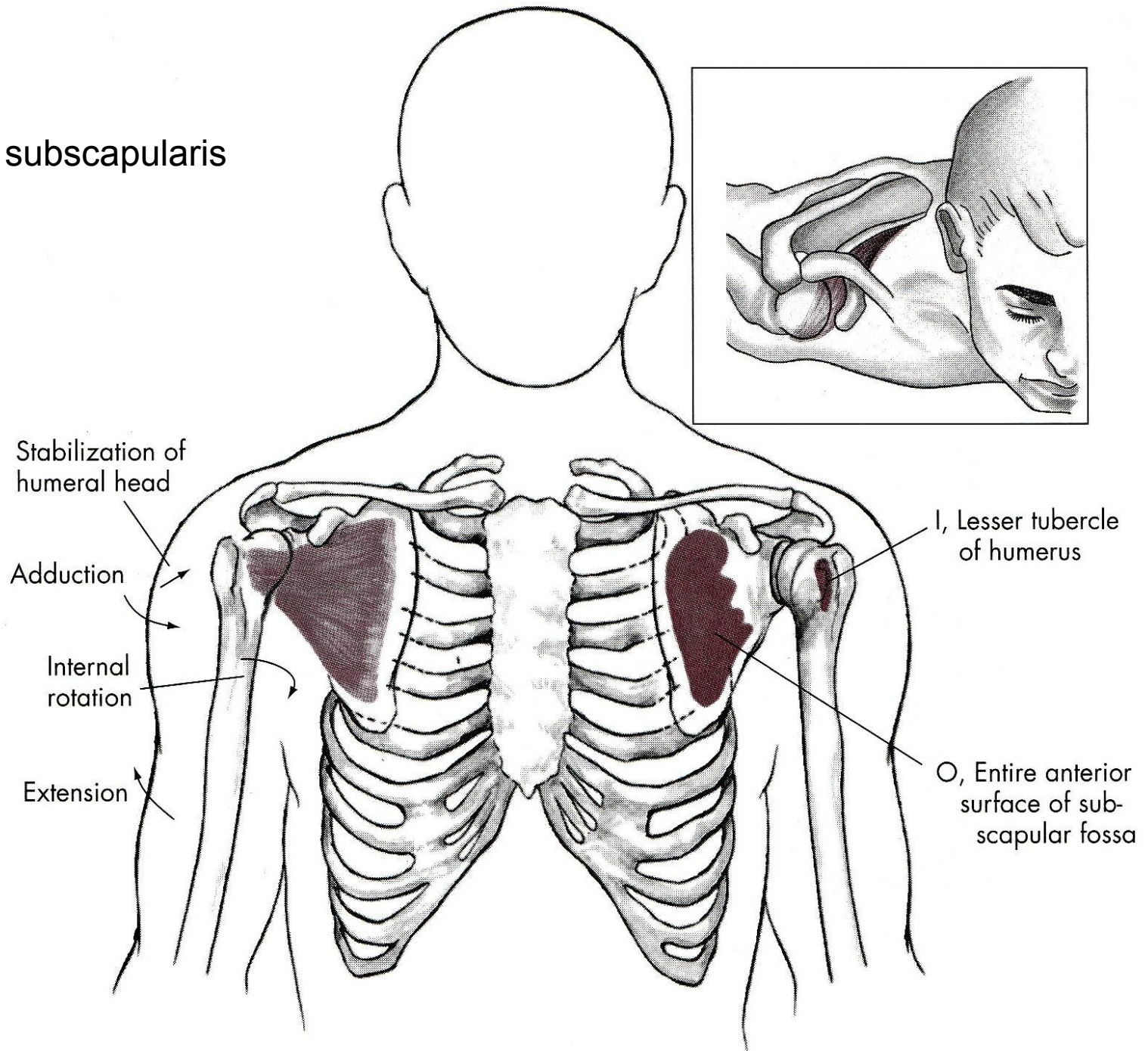


m. pectoralis major



m. latissimus dorsi

m. subscapularis



Stabilization of humeral head

Adduction

Internal rotation

Extension

I, Lesser tubercle of humerus

O, Entire anterior surface of subscapular fossa

VNĚJŠÍ ROTACE

m. infraspinatus – sval podhřebenový

m. teres minor – malý sval oblý

VNITŘNÍ ROTACE

m. subscapularis – sval podlopatkový

m. teres major – velký sval oblý

m. pectoralis major – velký sval prsní

m. latissimus dorsi – široký sval zádový

POHYBY LOKETNÍHO KLOUBU

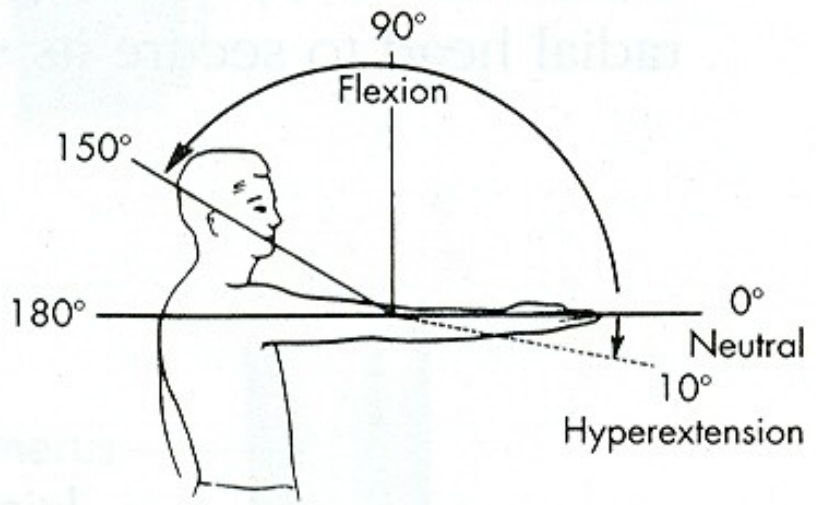
FLEXE

EXTENZE

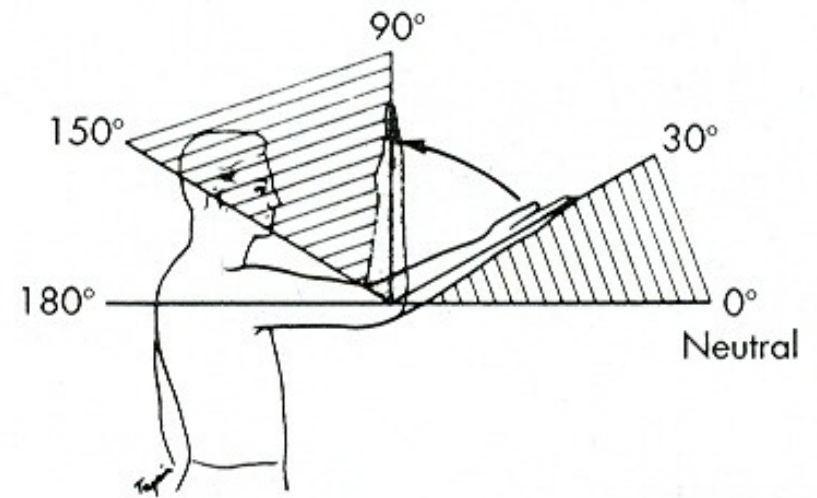
POHYBY PŘEDLOKTÍ

SUPINACE

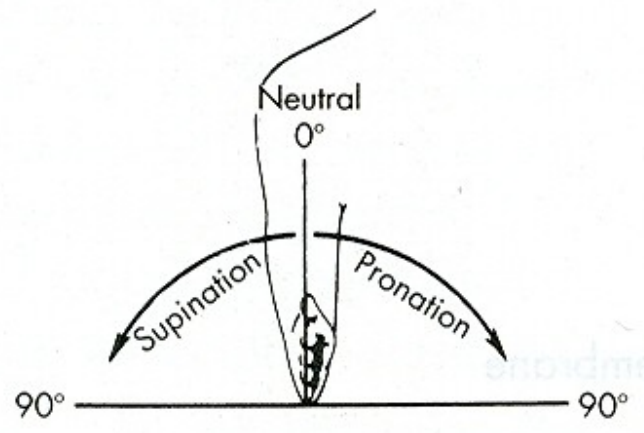
PRONACE



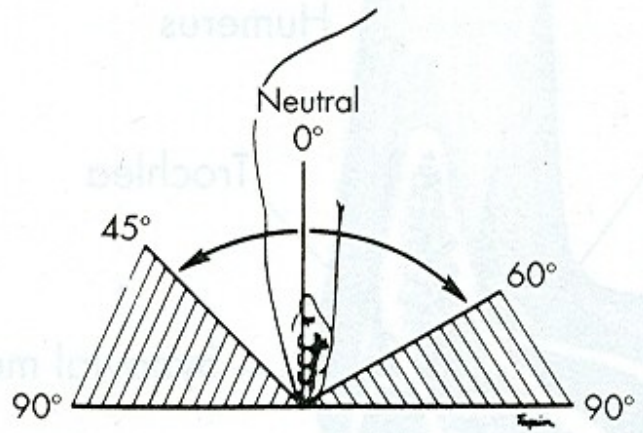
A



B

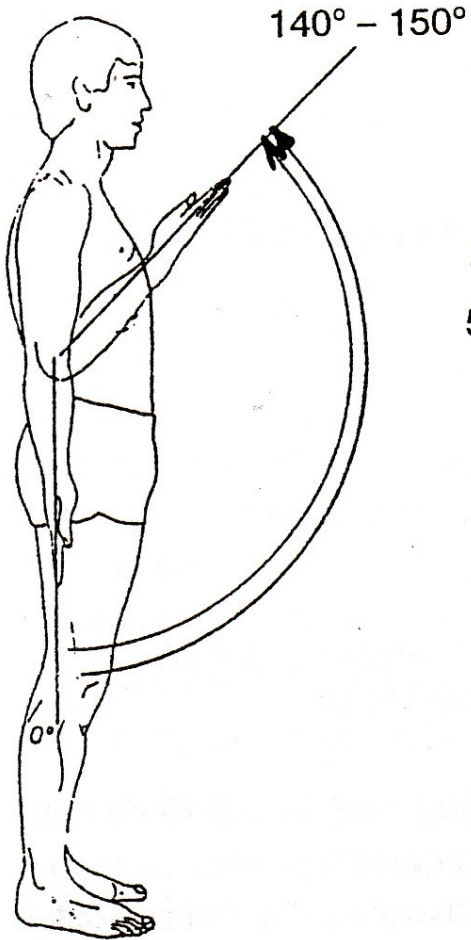


A

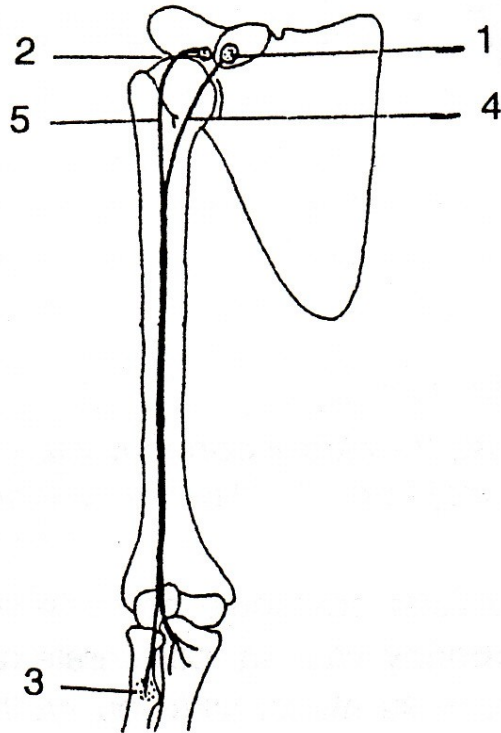


B


FLEXE



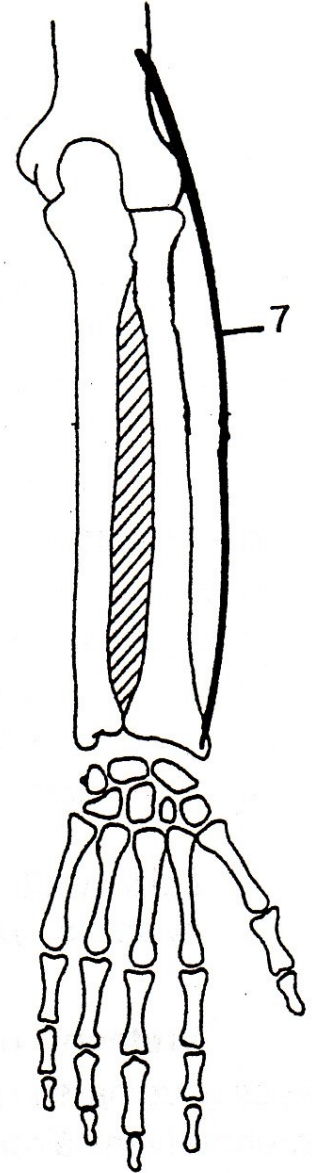
m. biceps brachii

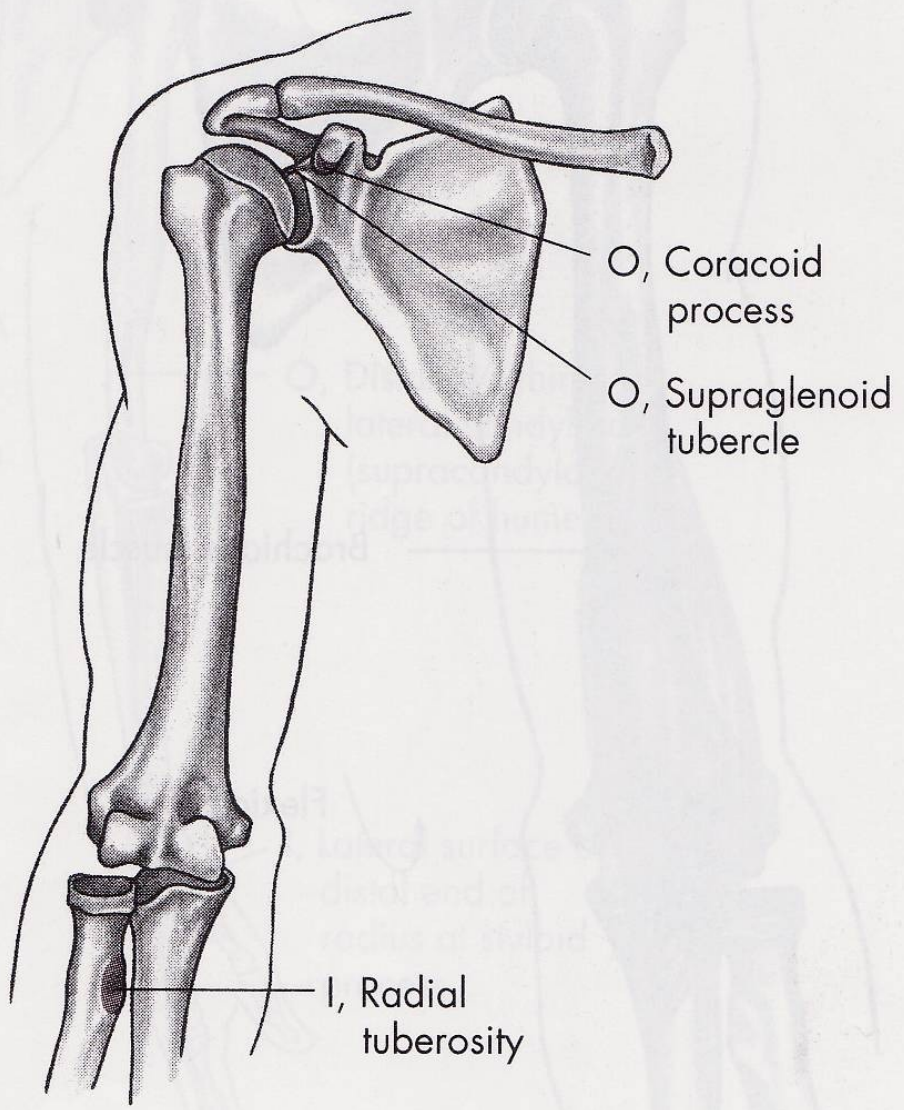
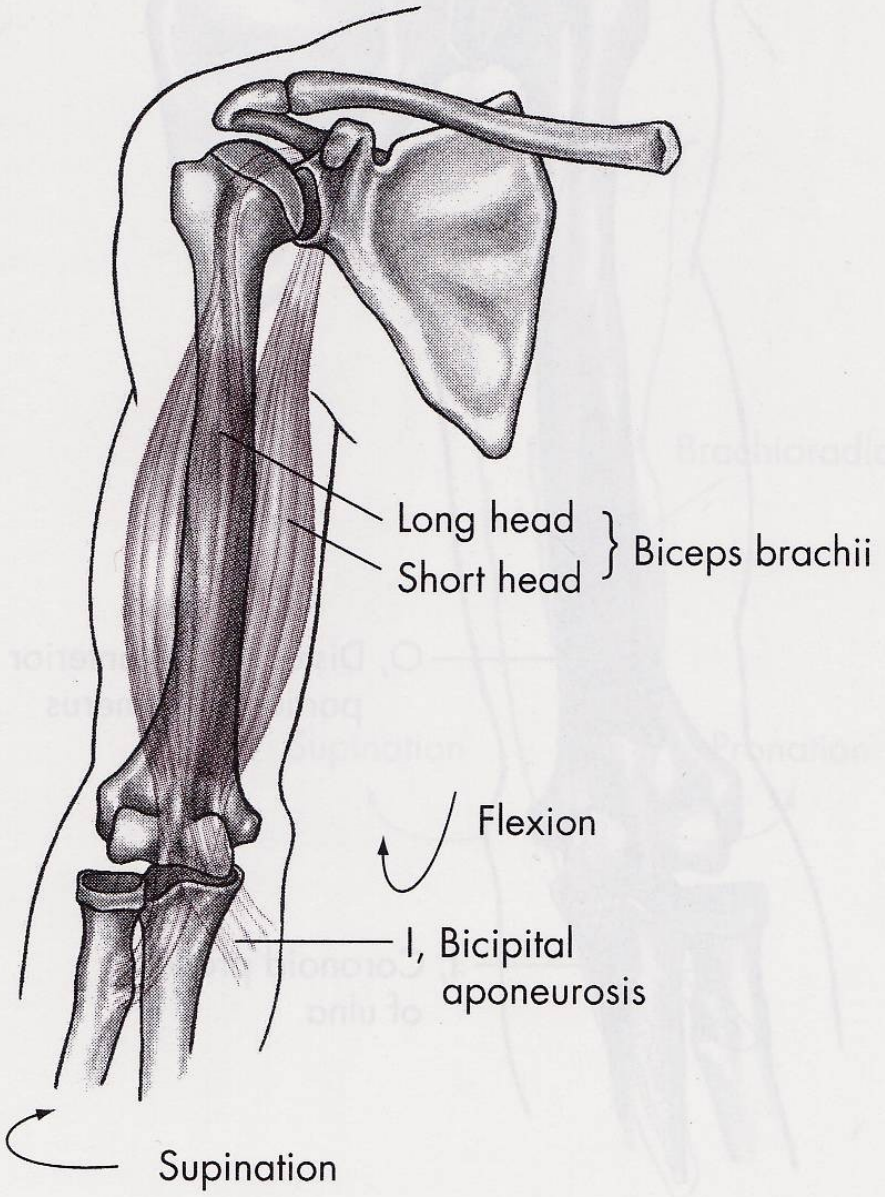


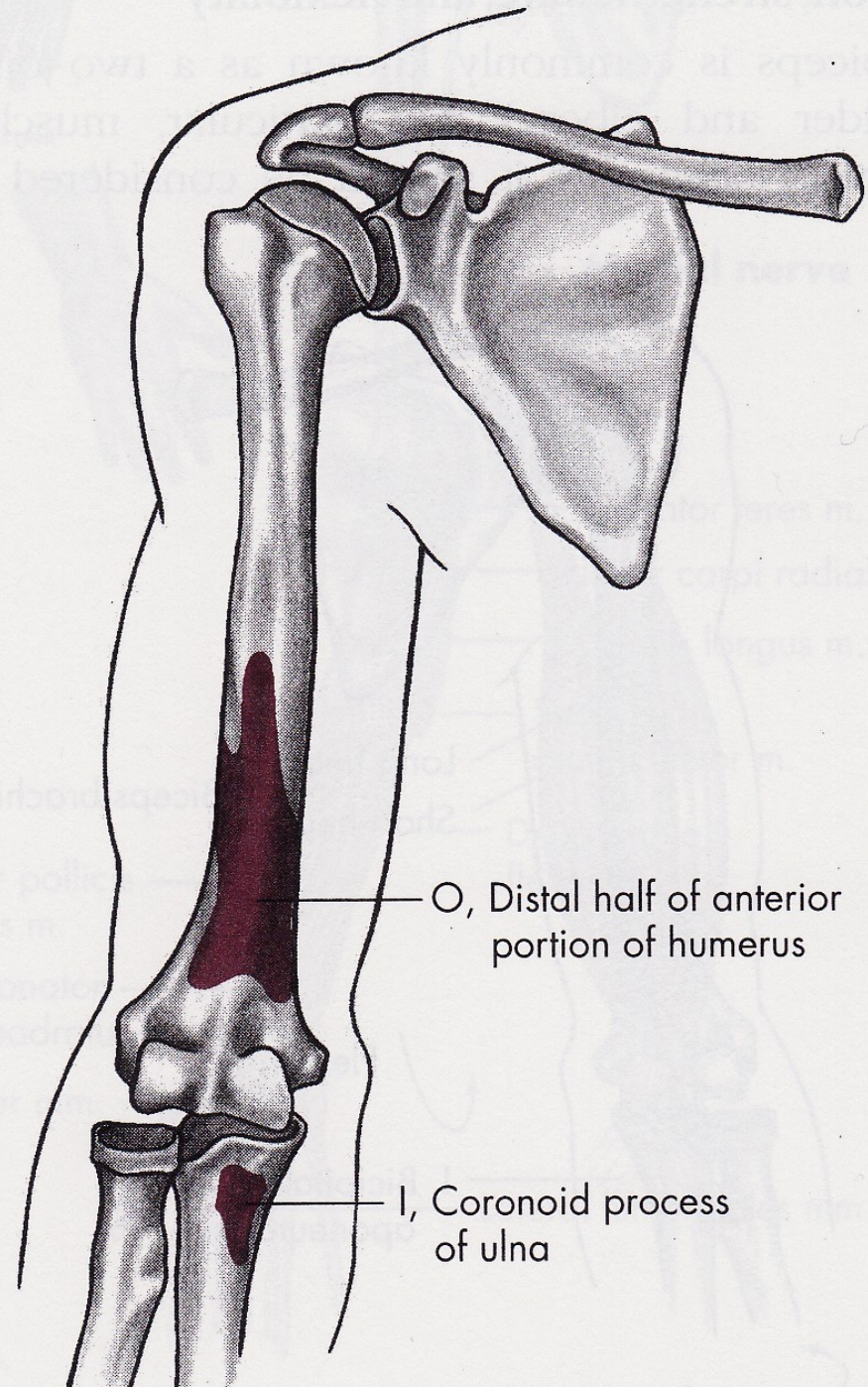
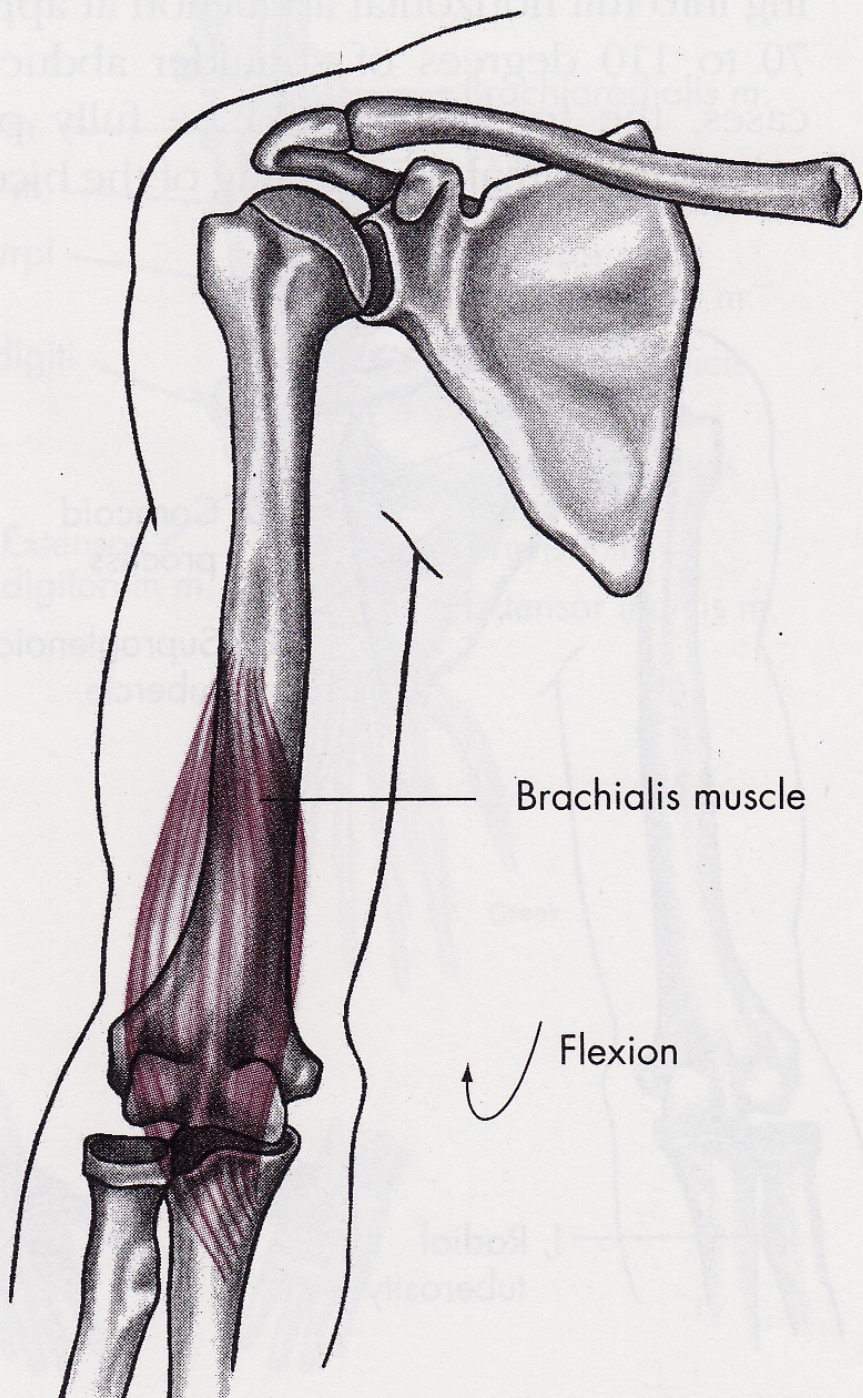
m. brachialis

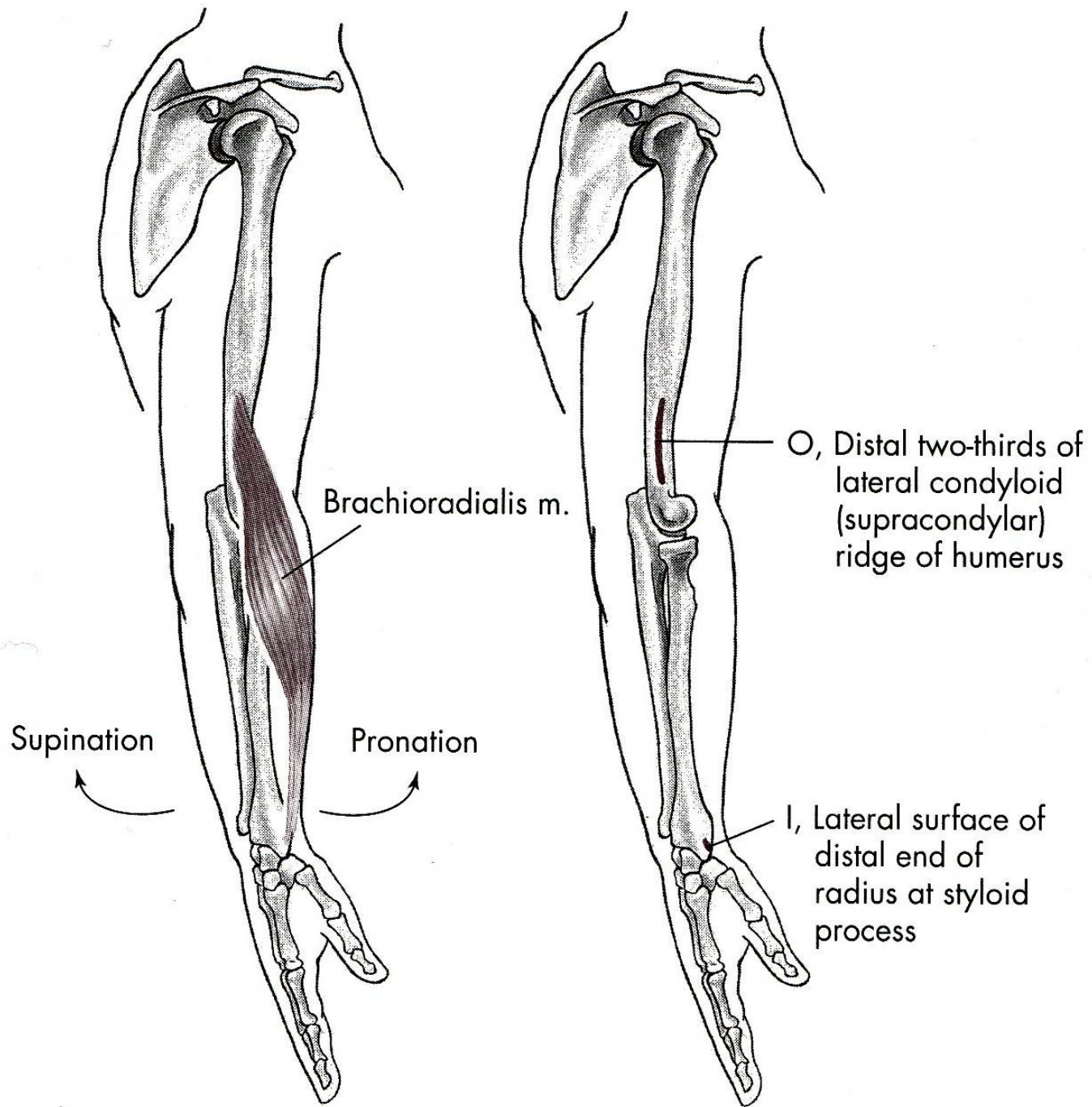


m. brachioradialis

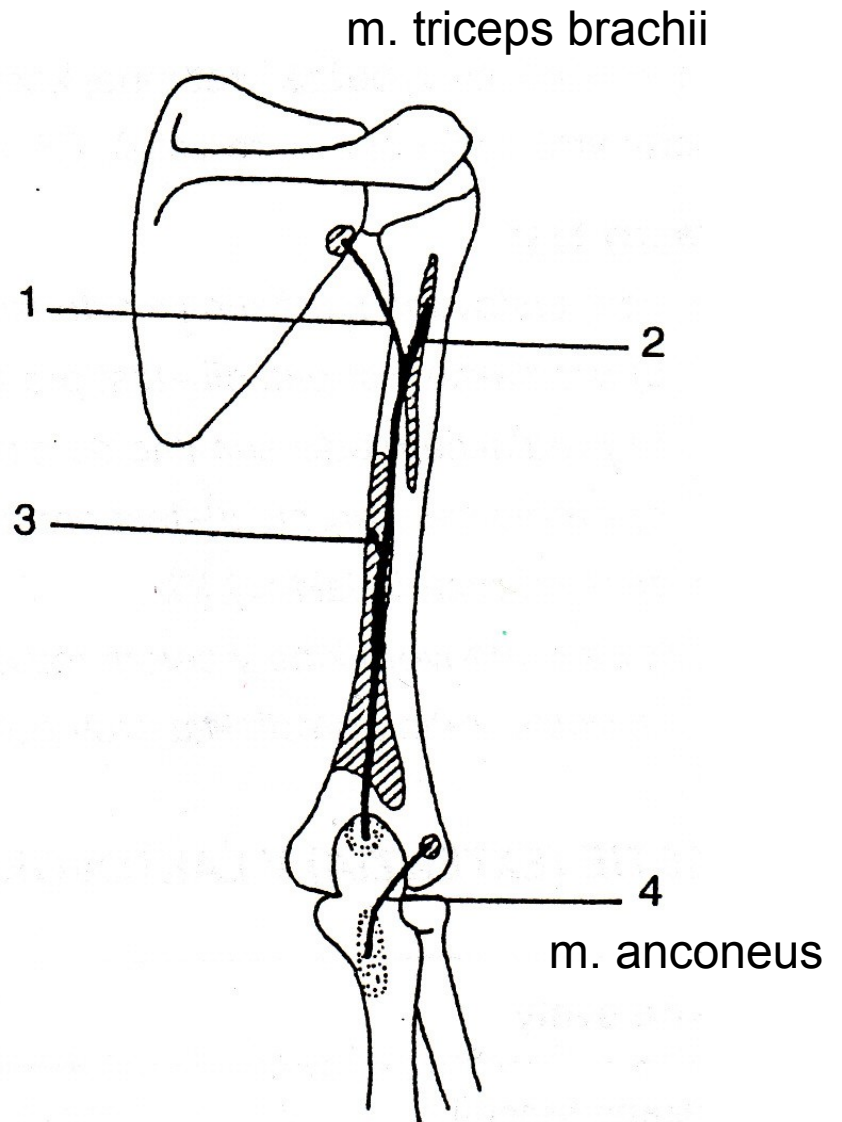
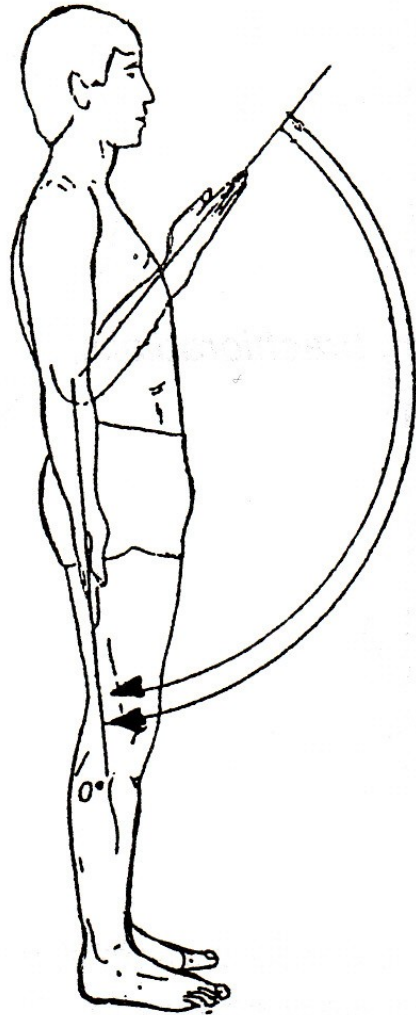




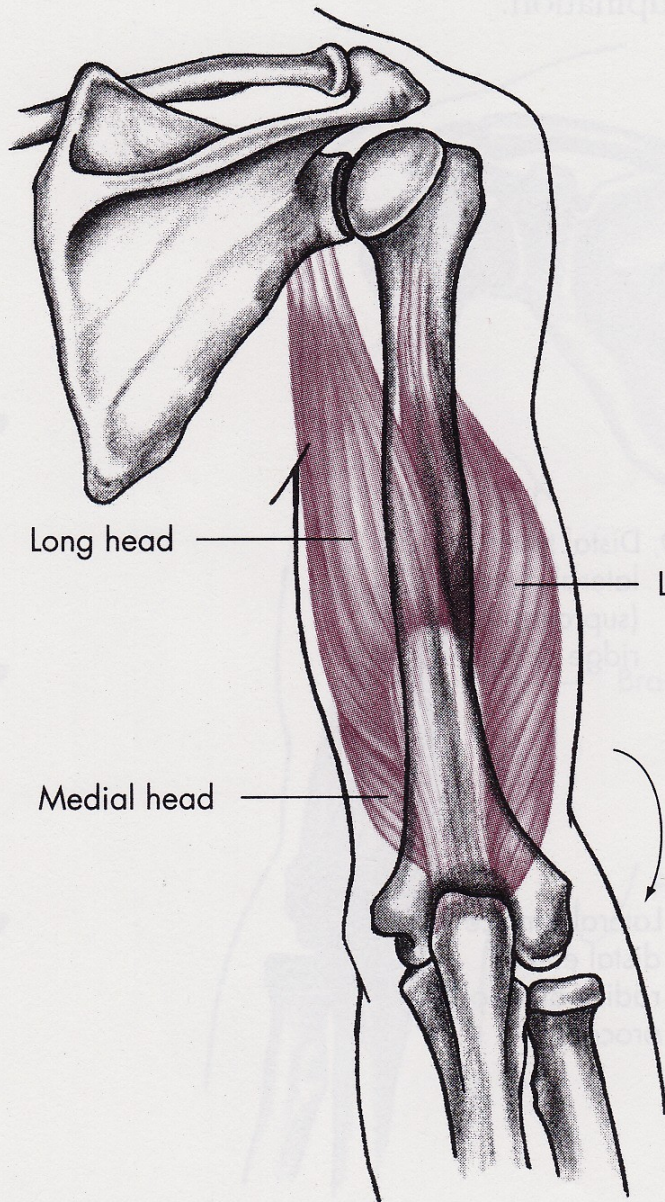




EXTENZE

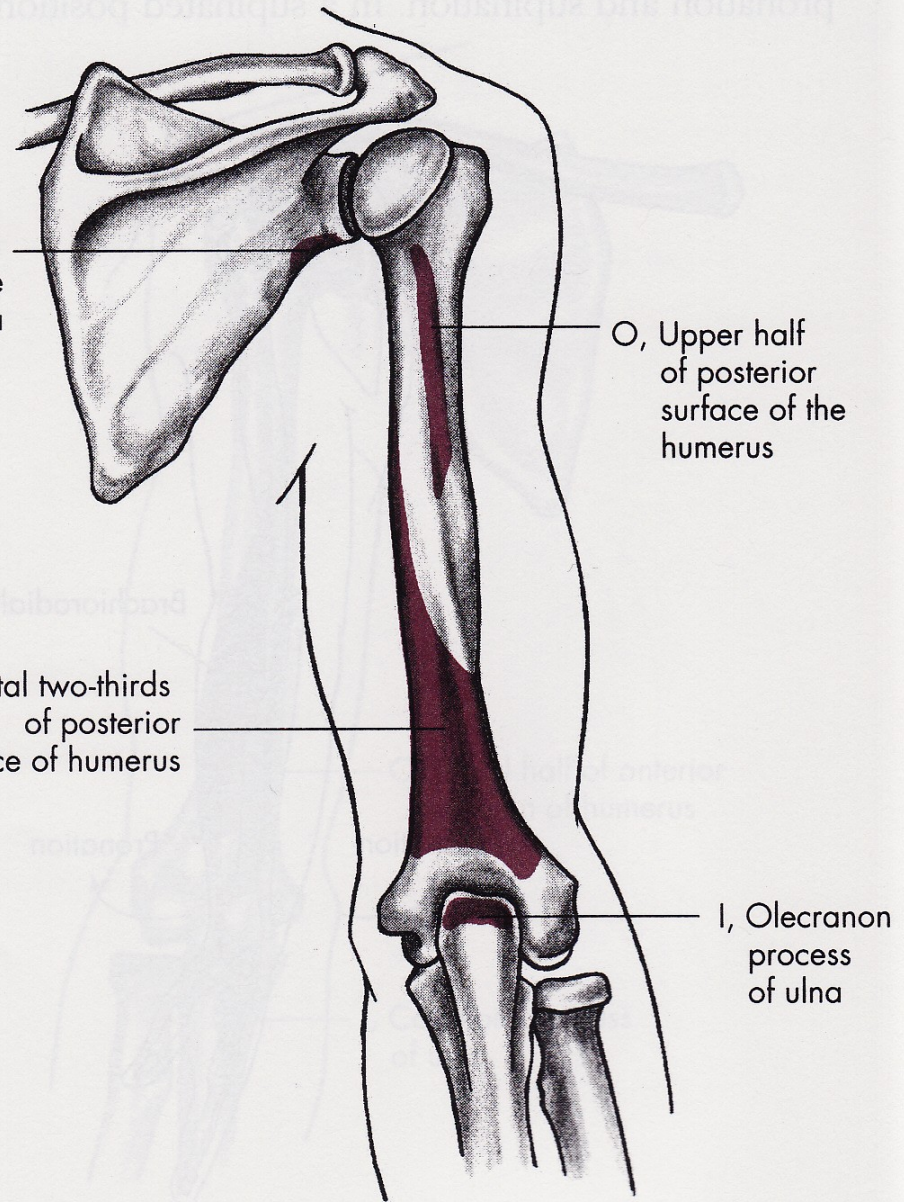


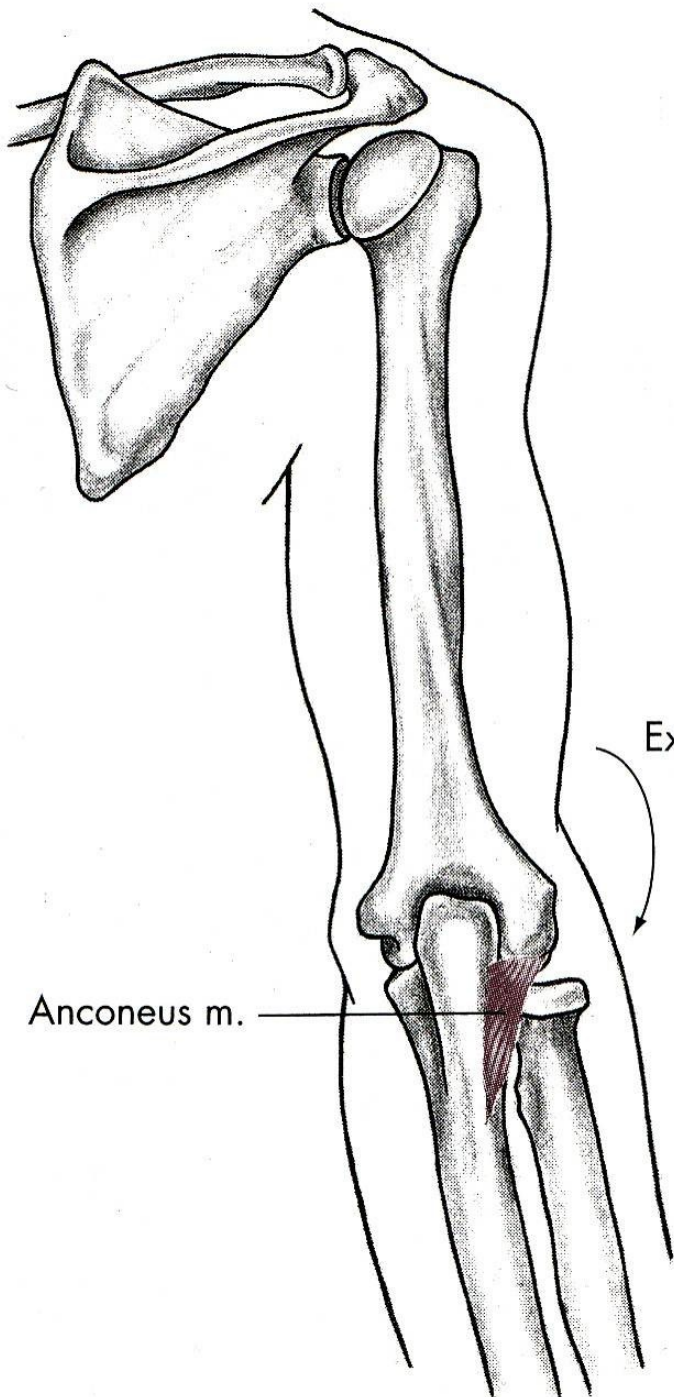
m. triceps brachii



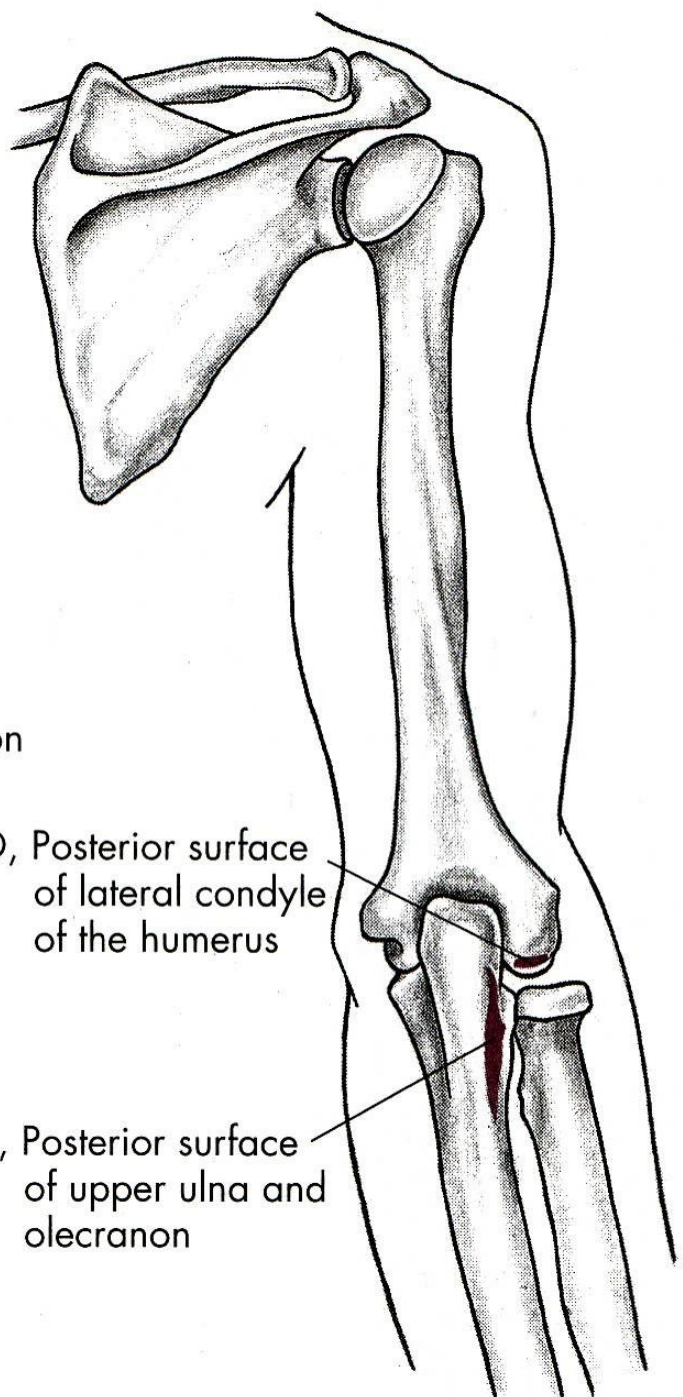
O, Infraglenoid tubercle of scapula

O, Distal two-thirds of posterior surface of humerus





Extension



O, Posterior surface of lateral condyle of the humerus

I, Posterior surface of upper ulna and olecranon

FLEXE

m. biceps brachii – dvojhlavý sval pažní

m. brachialis – hluboký sval pažní

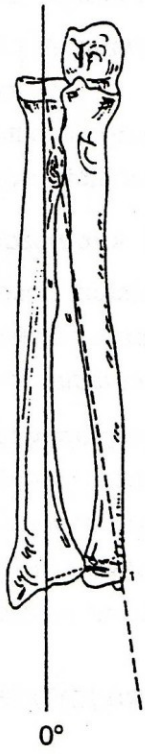
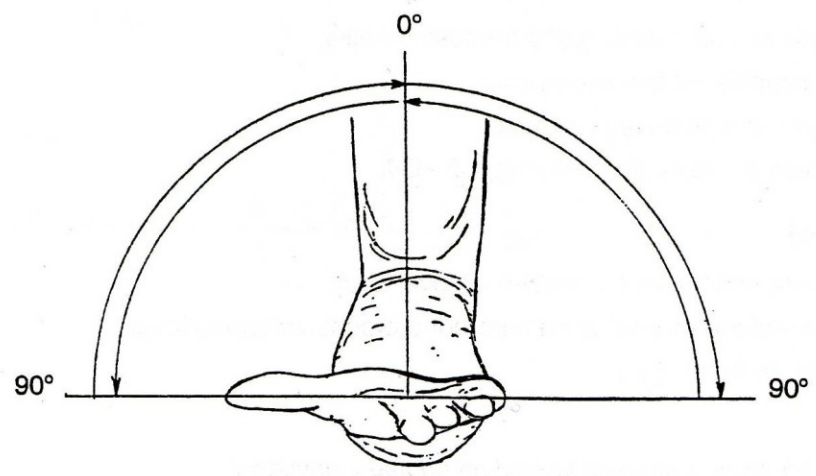
m. brachioradialis – pažní sval vřetenní

EXTENZE

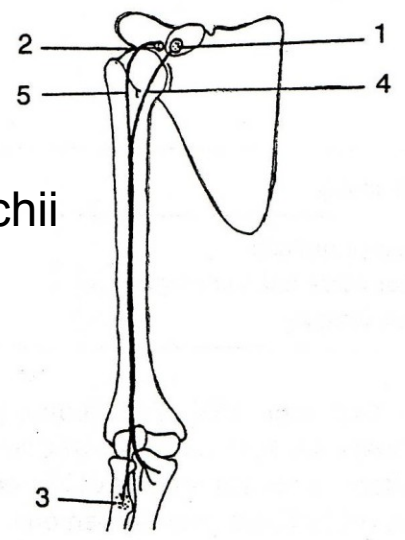
m. triceps brachii – trojhlavý sval pažní

m. anconeus – sval loketní

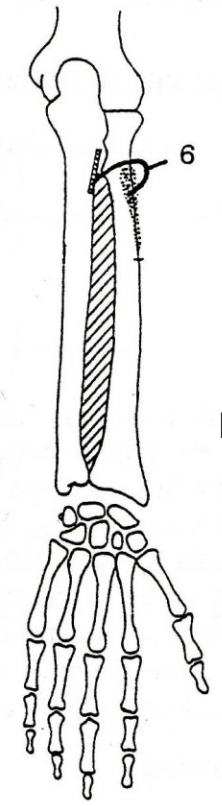
SUPINACE

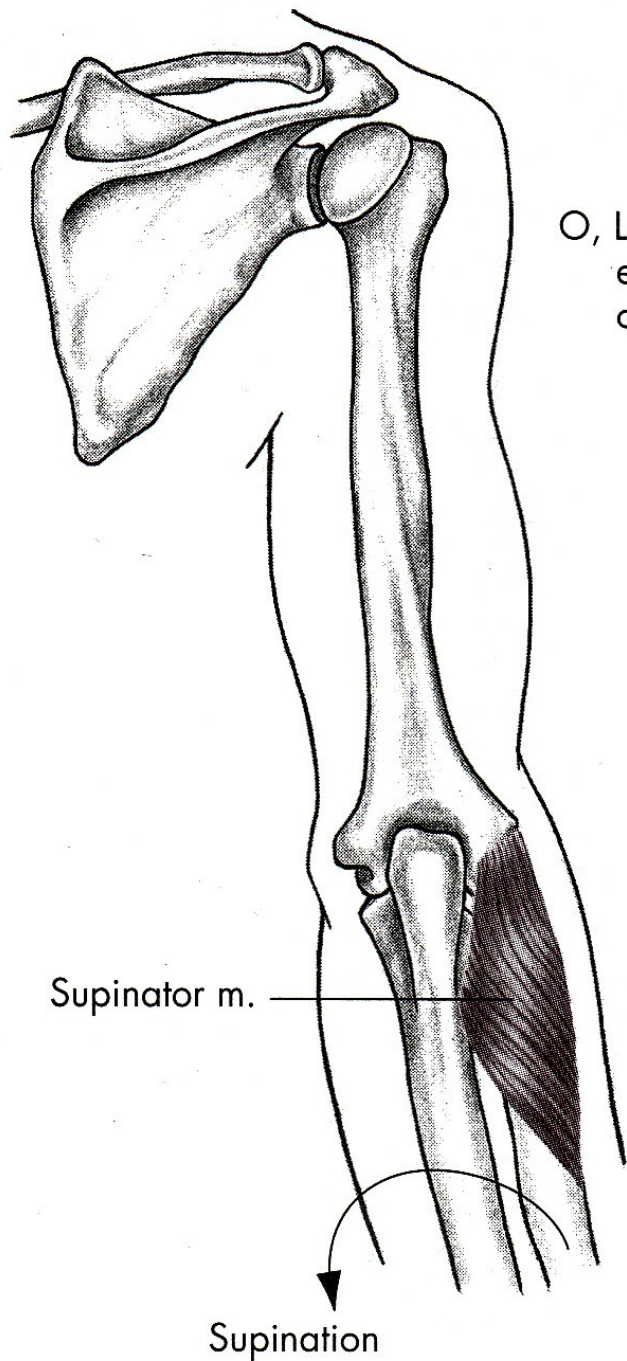


m. biceps brachii

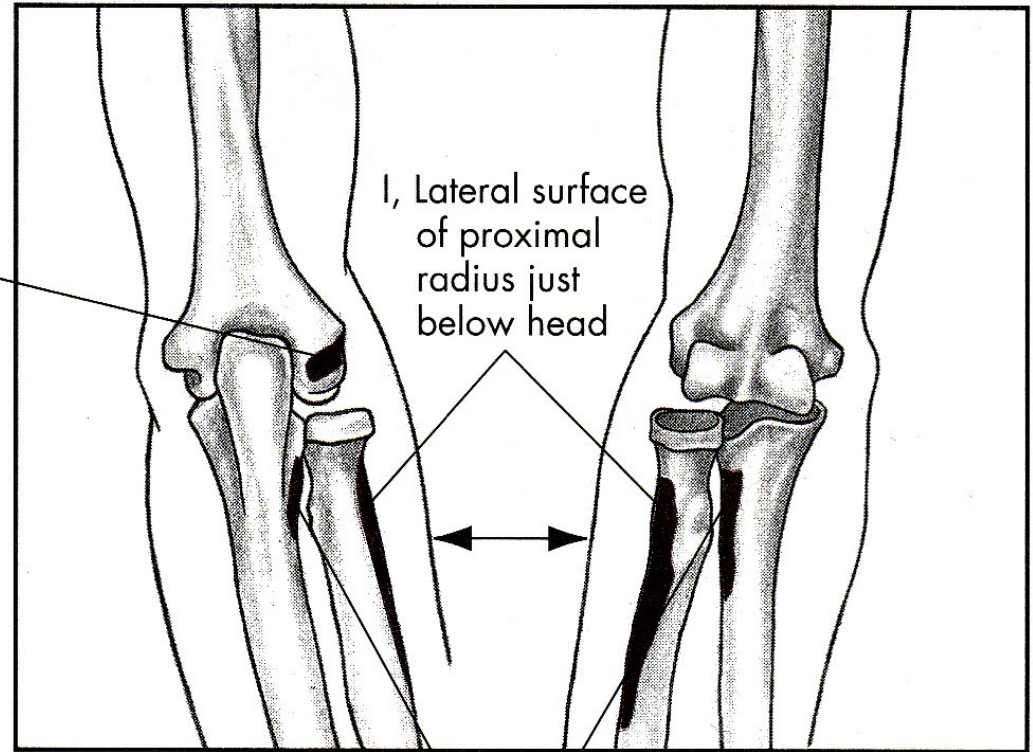


m. supinator





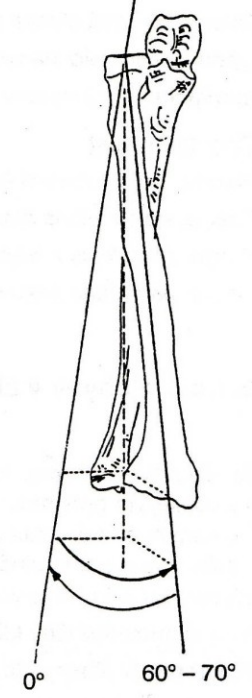
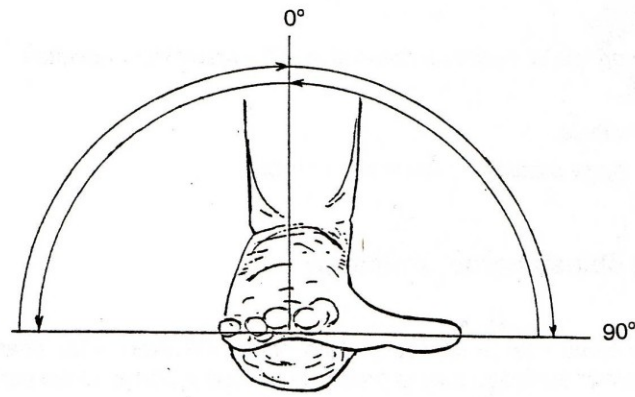
O, Lateral epicondyle of humerus



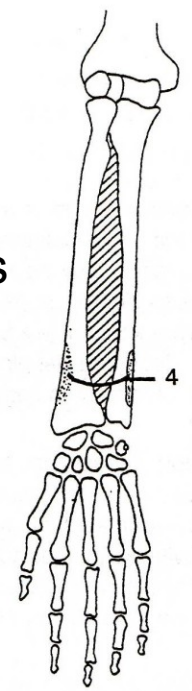
Posterior

Anterior

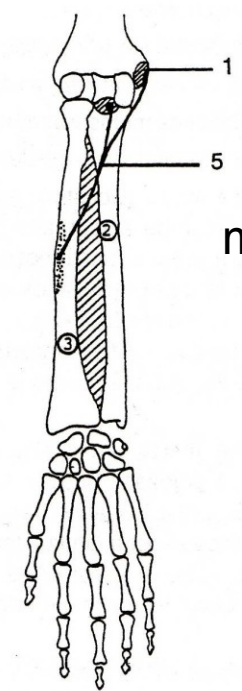
PRONACE

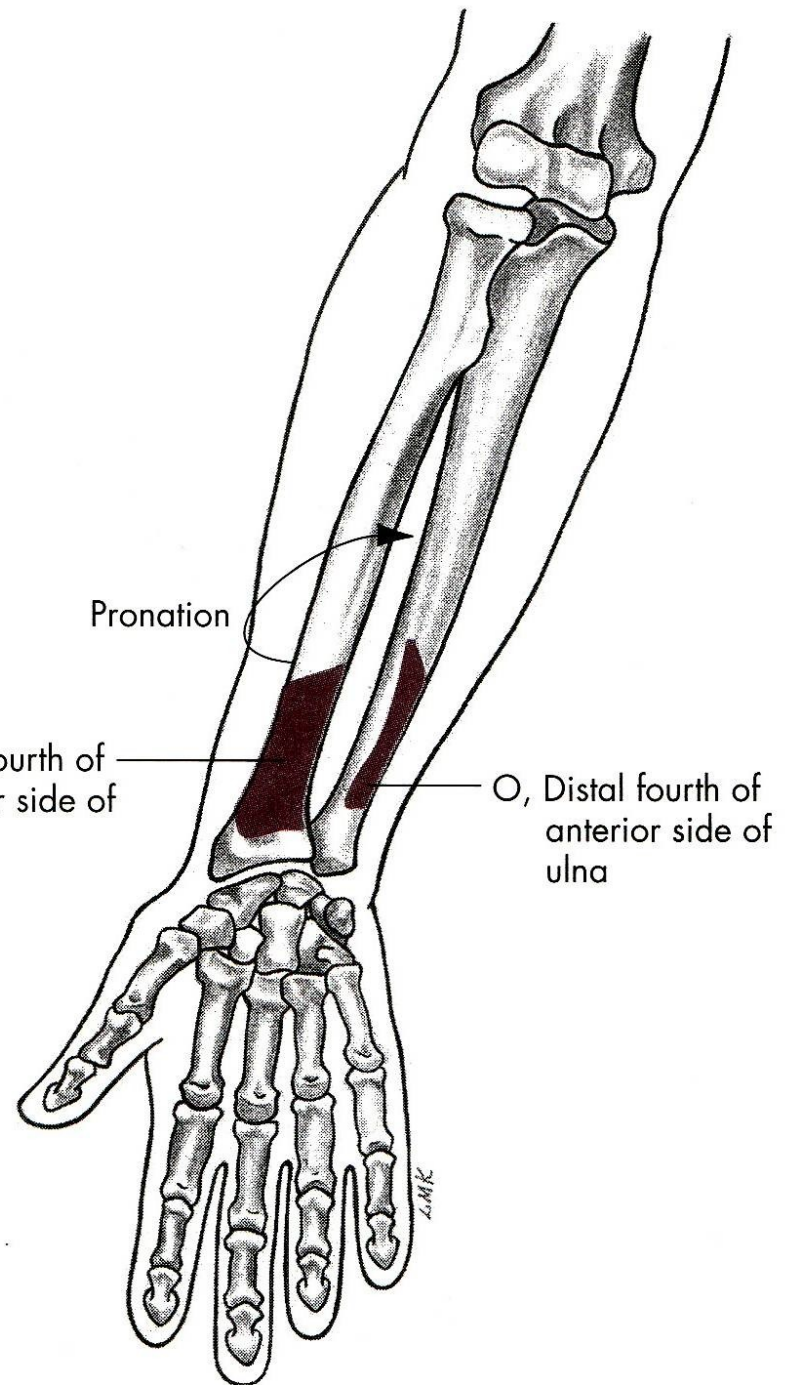
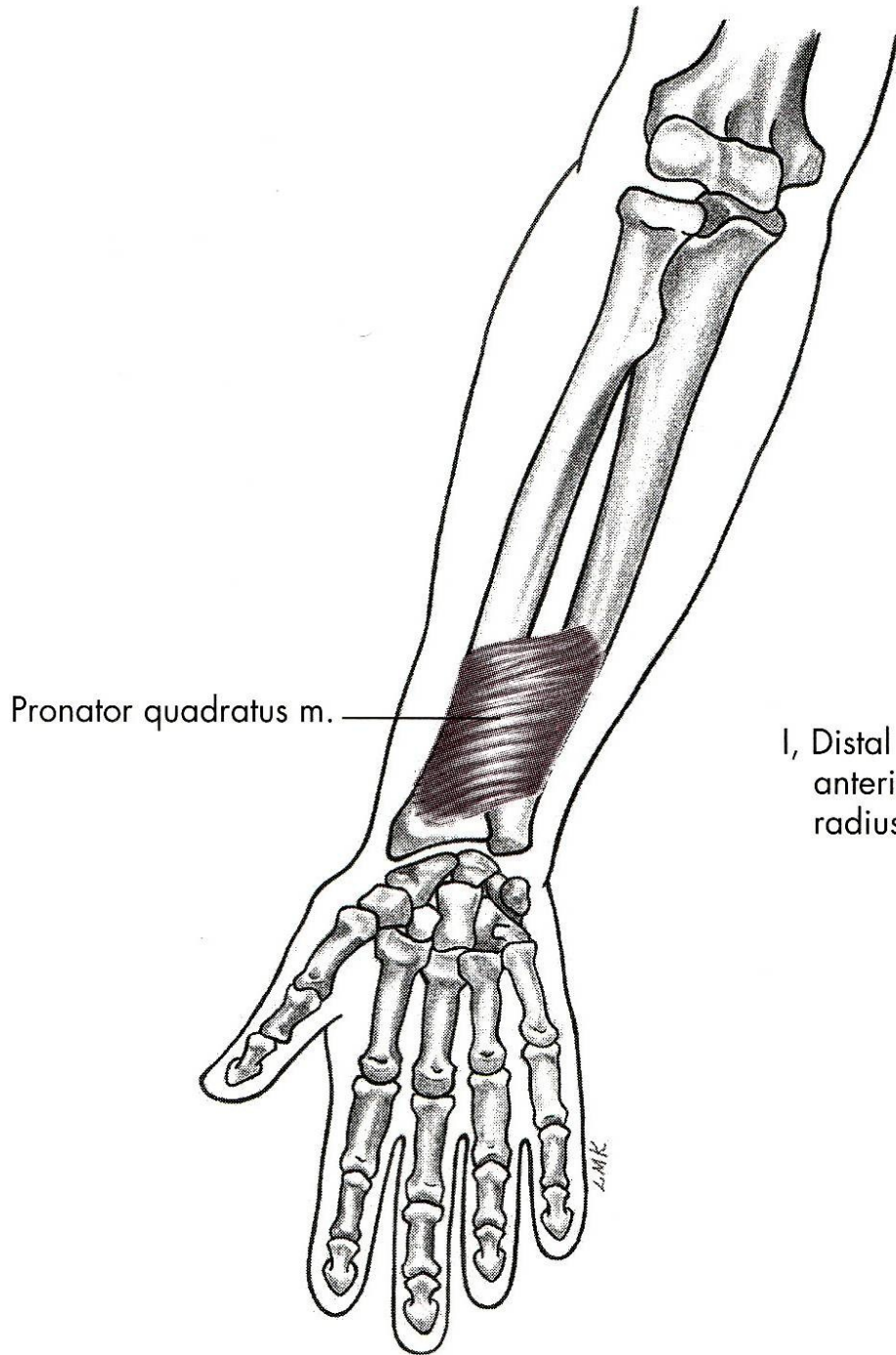


m. pronator quadratus



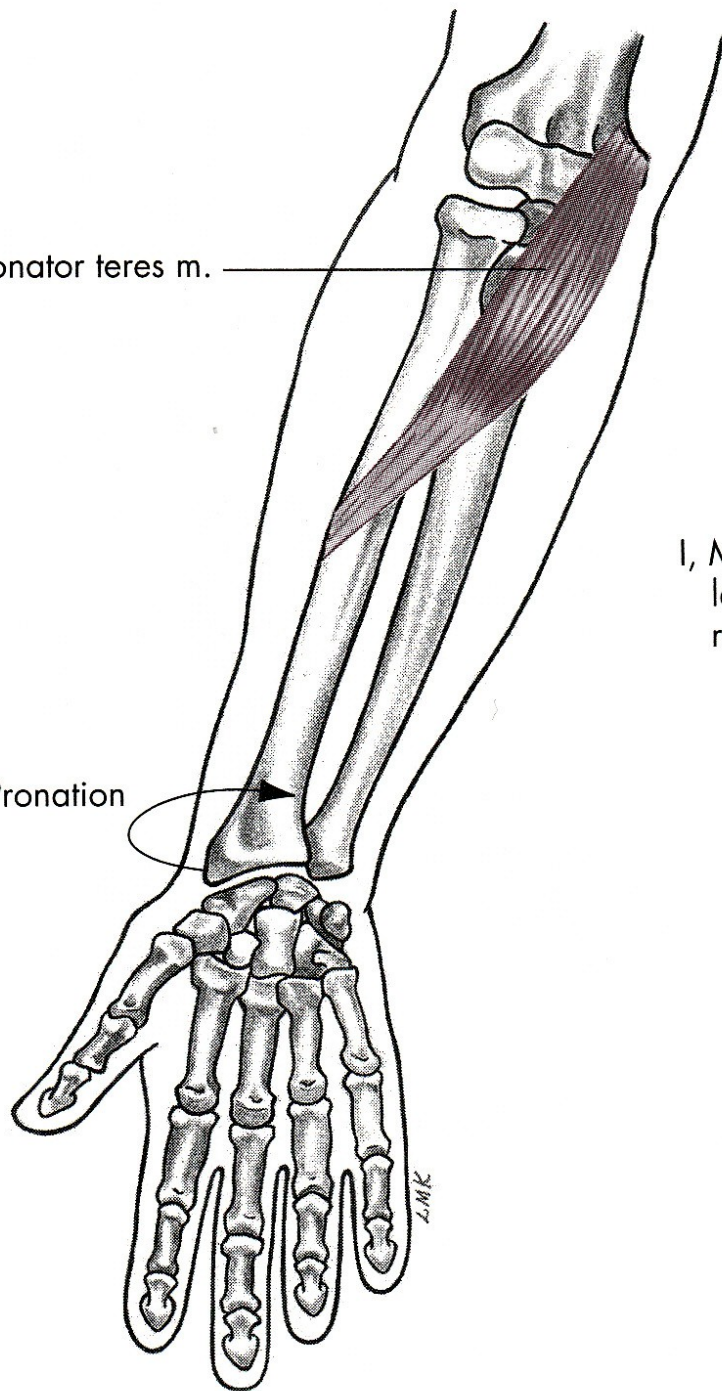
m. pronator teres





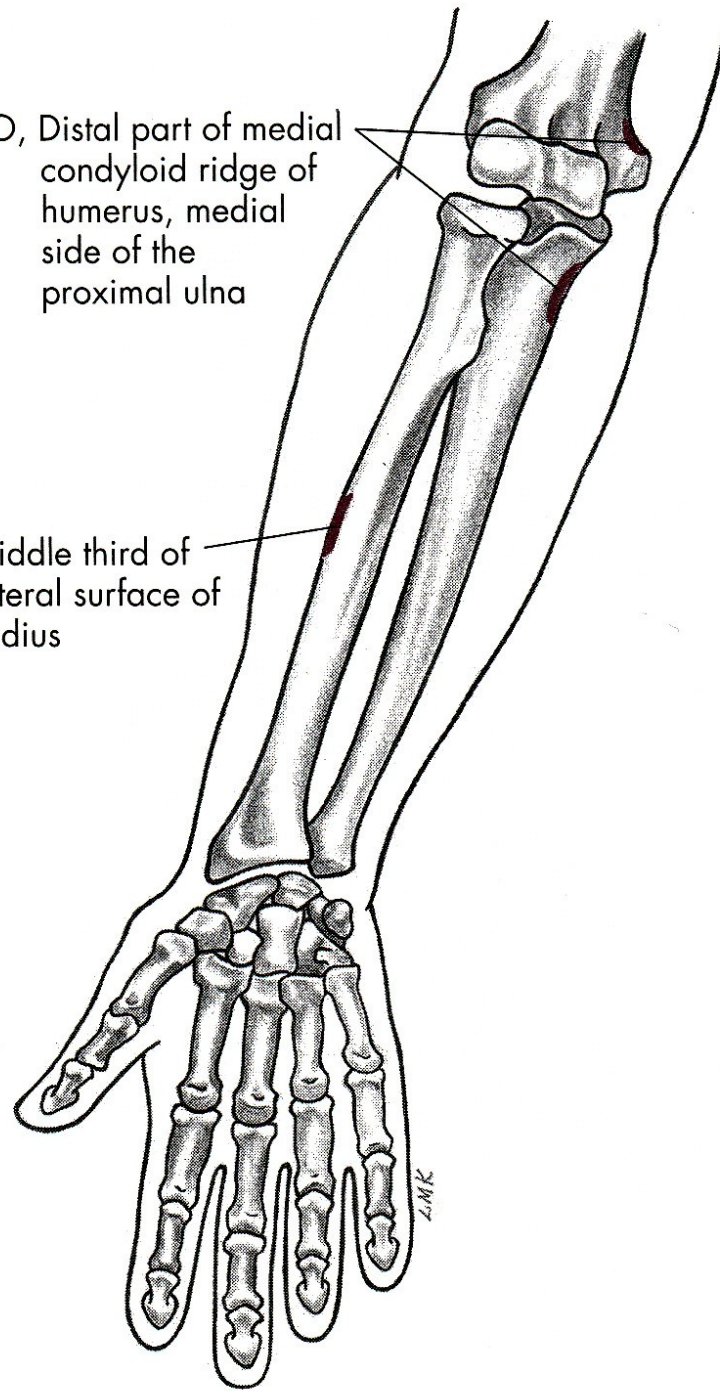
Pronator teres m.

Pronation



O, Distal part of medial condyloid ridge of humerus, medial side of the proximal ulna

I, Middle third of lateral surface of radius



SUPINACE

m. biceps brachii – dvojhlavý sval pažní

m. supinator – sval supinující

PRONACE

m. pronator teres – pronující sval oblý

m. pronator quadratus –
pronující sval čtyřhranný

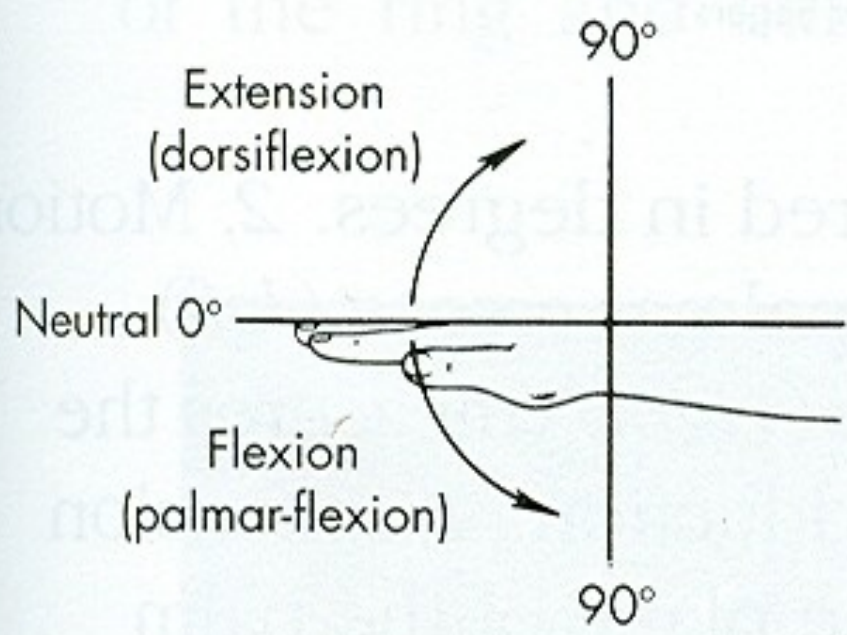
POHYBY ZÁPĚSTÍ

PALMÁRNÍ FLEXE - OHNUTÍ

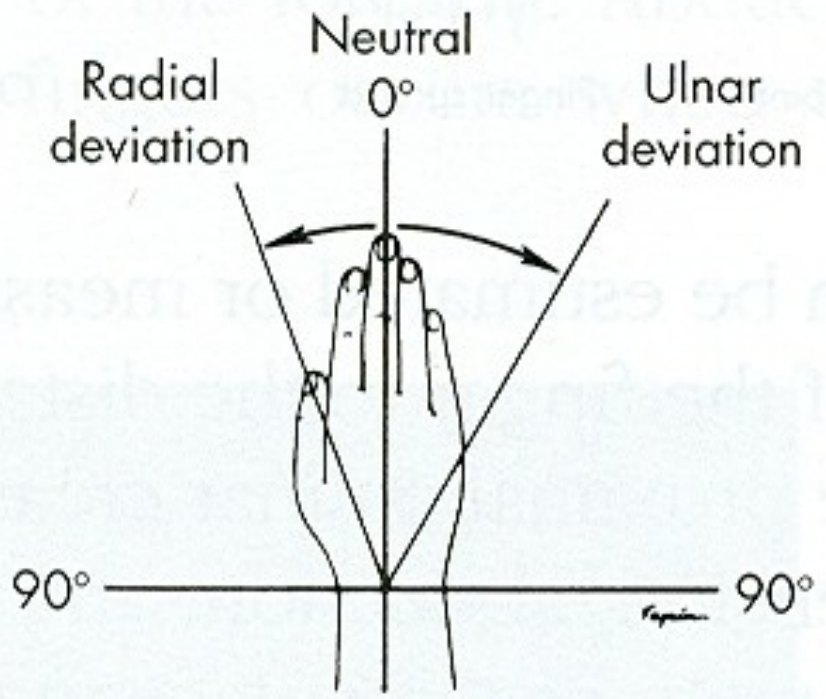
DORZÁLNÍ FLEXE - NATAŽENÍ

ULNÁRNÍ DUKCE

RADIÁLNÍ DUKCE

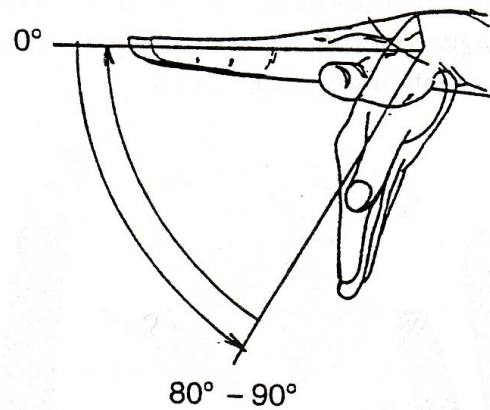


A

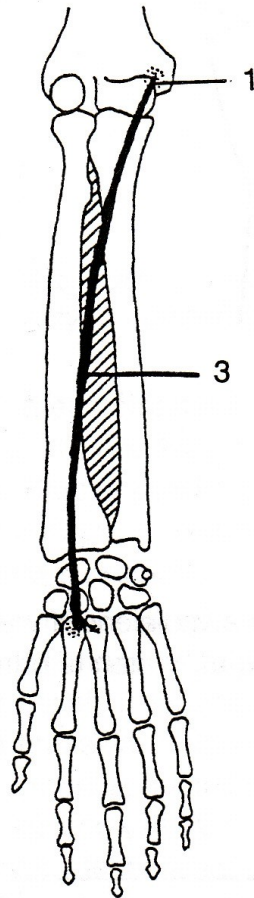


B

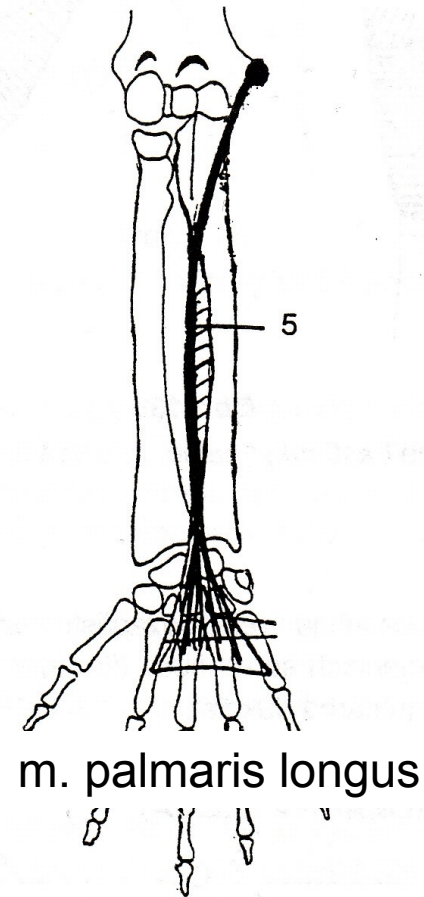
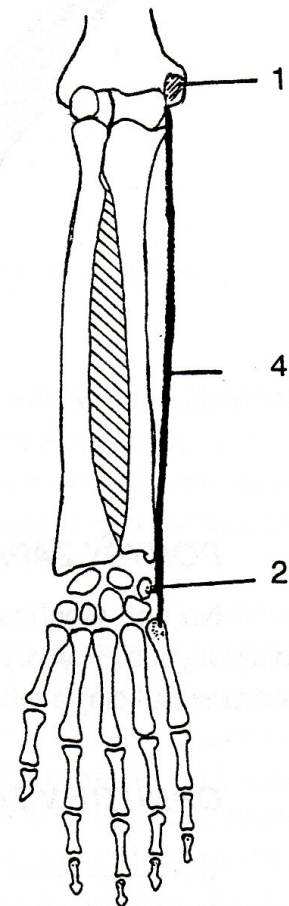
PALMÁRNÍ FLEXE



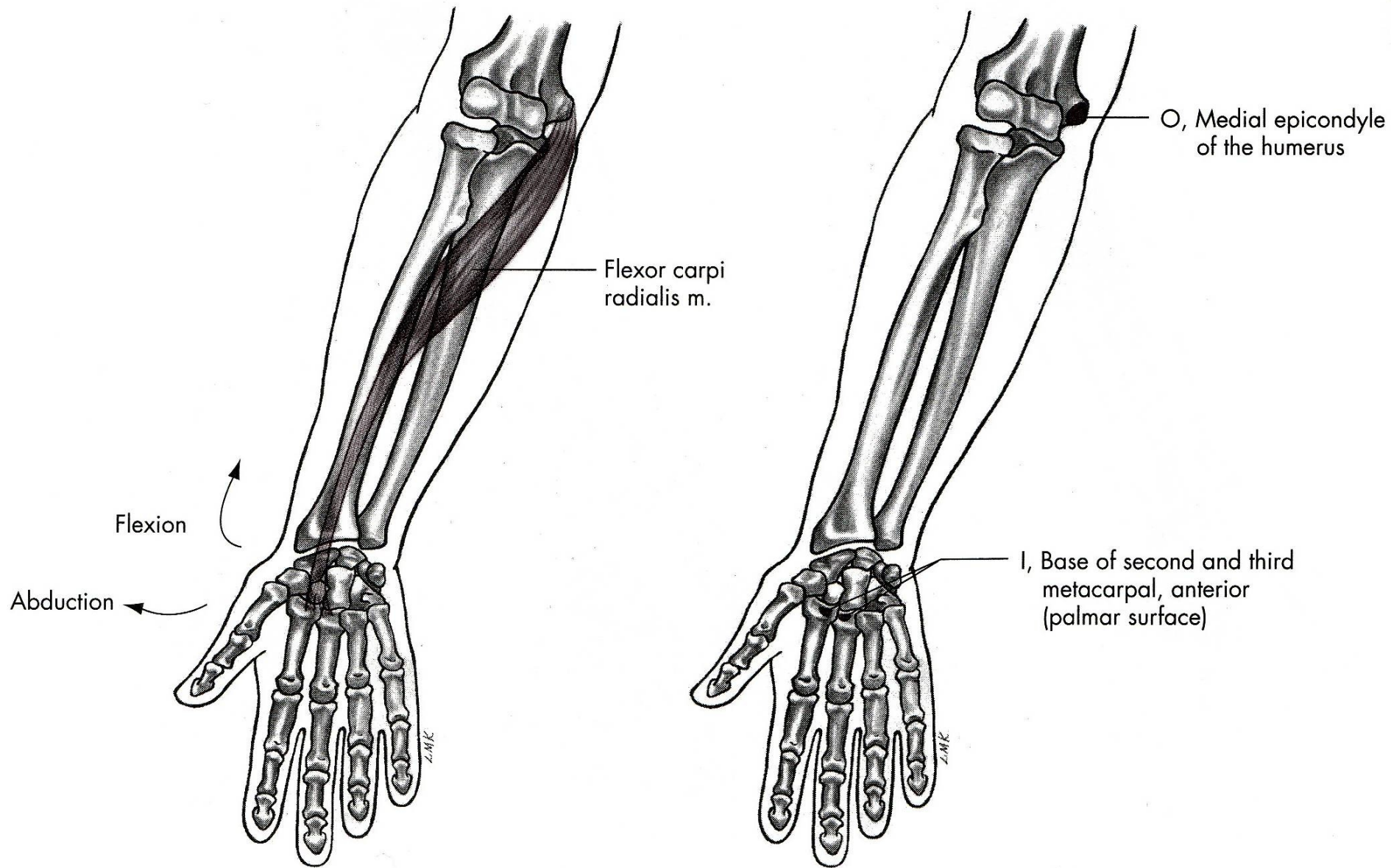
m. flexor carpi radialis

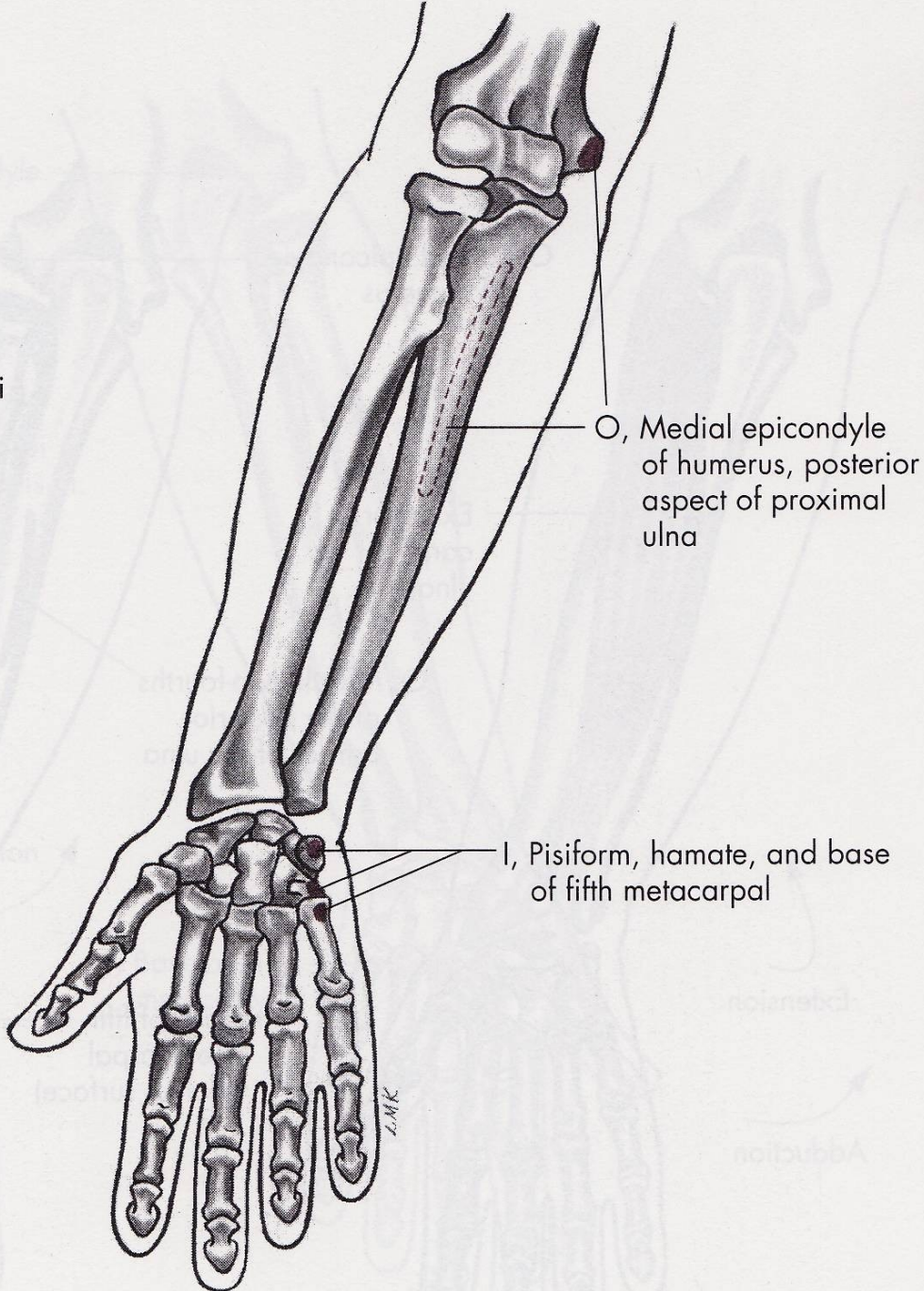
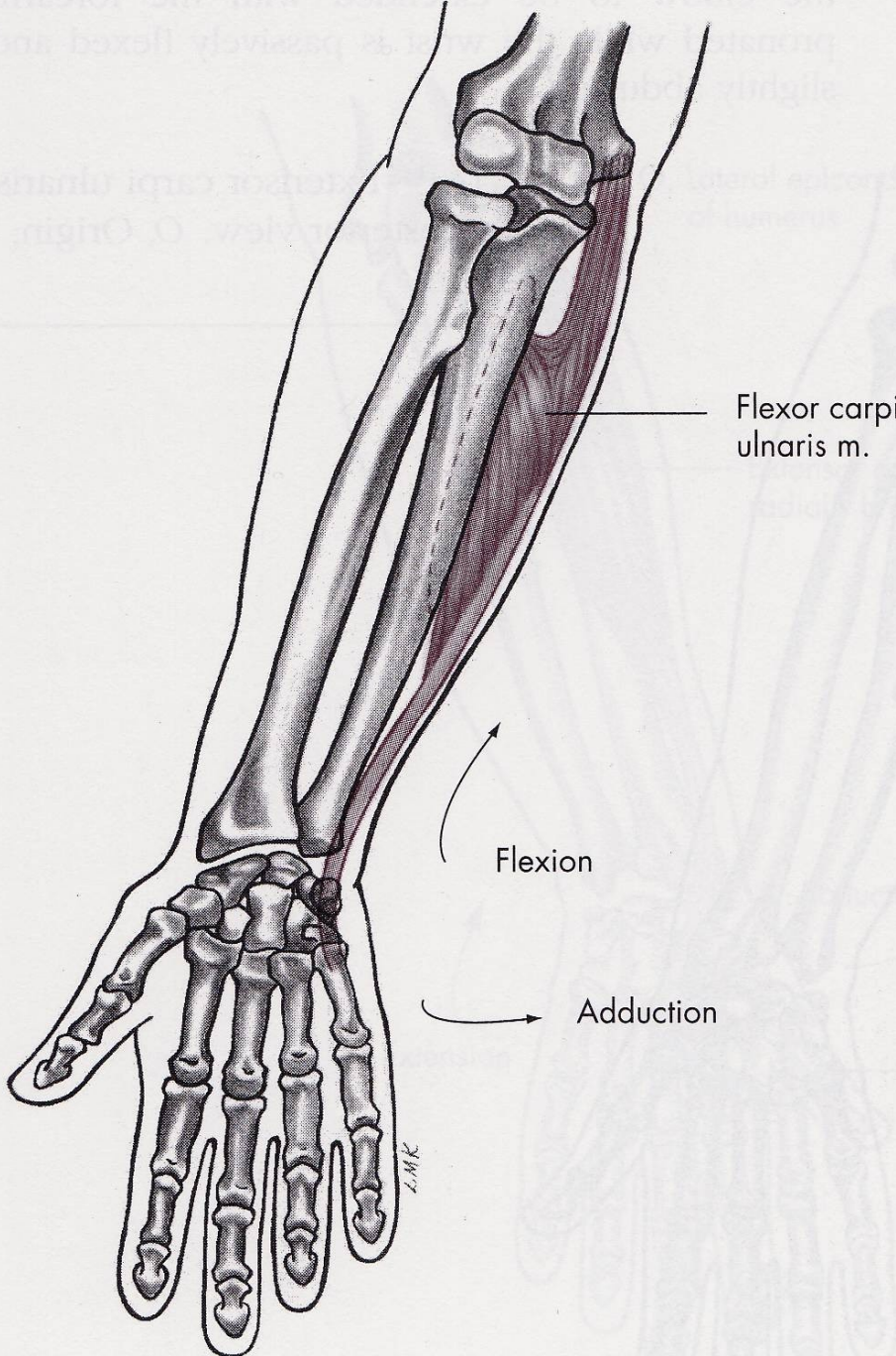


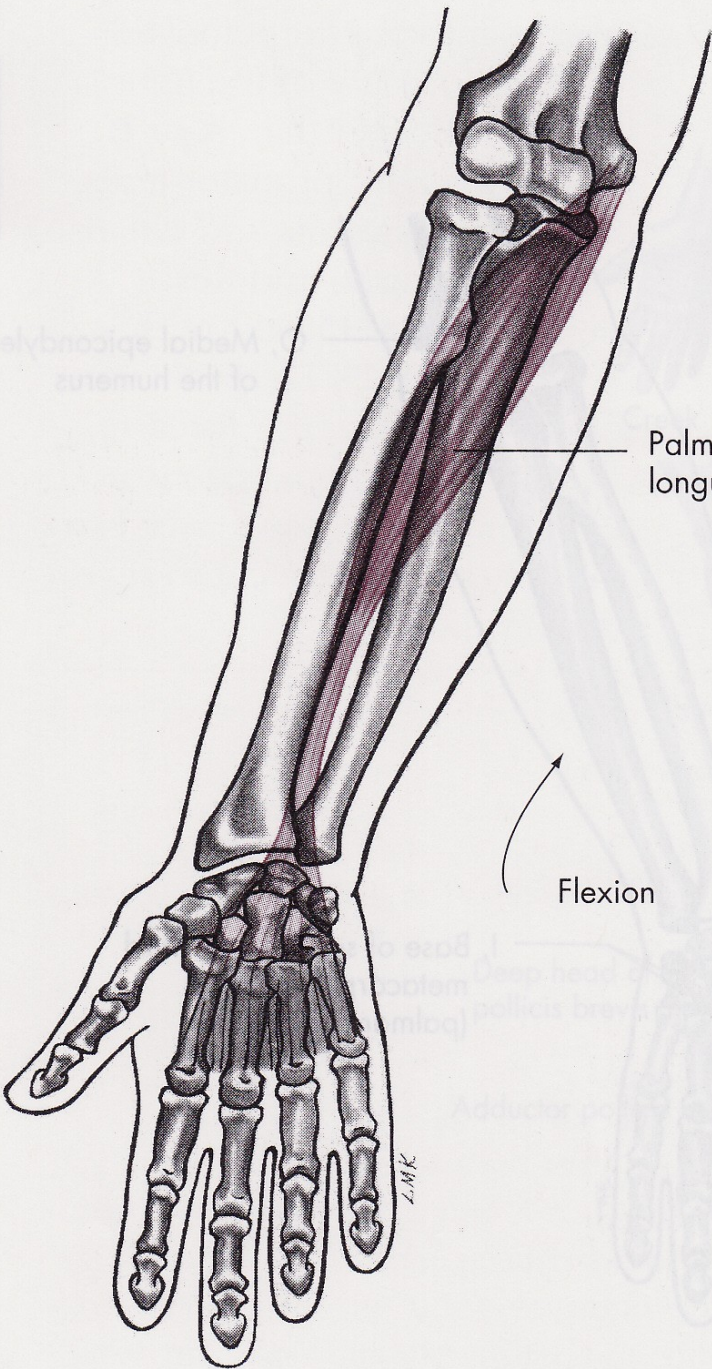
m. flexor carpi ulnaris



m. palmaris longus

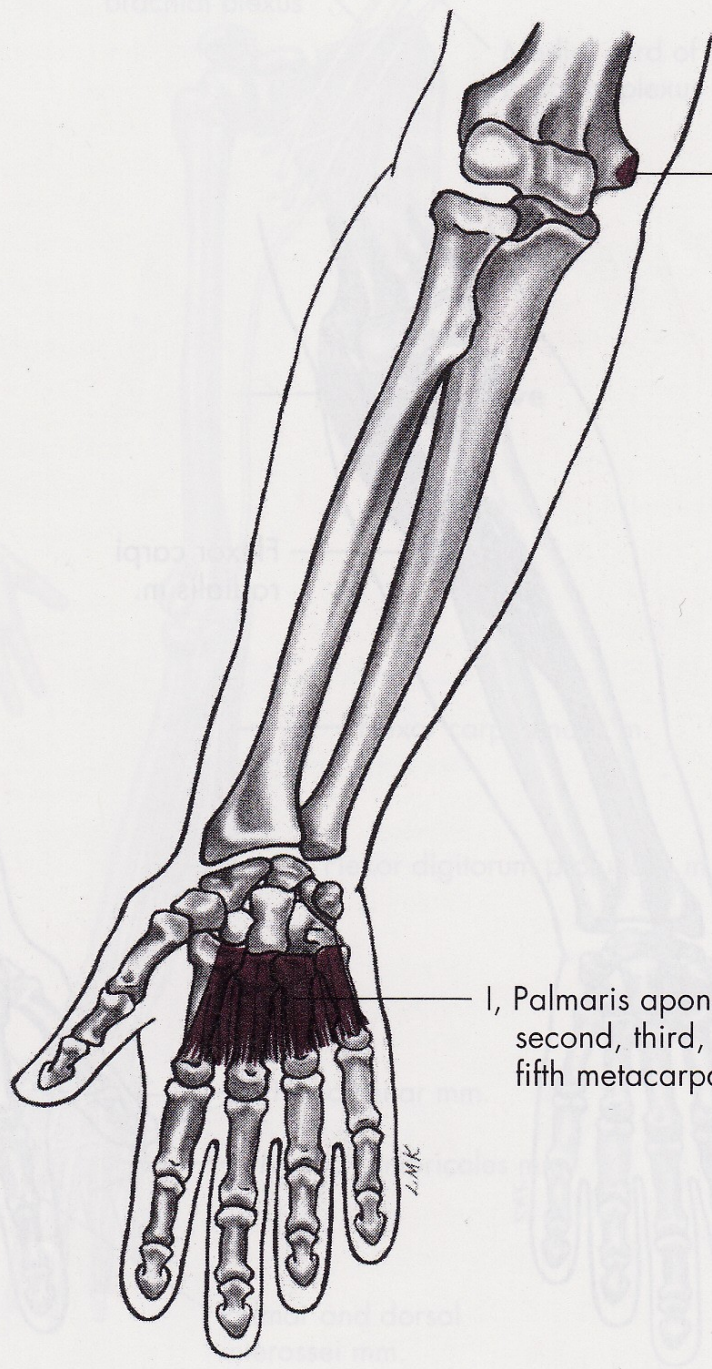






Palmaris longus m.

Flexion



O, Medial epicondyle of humerus

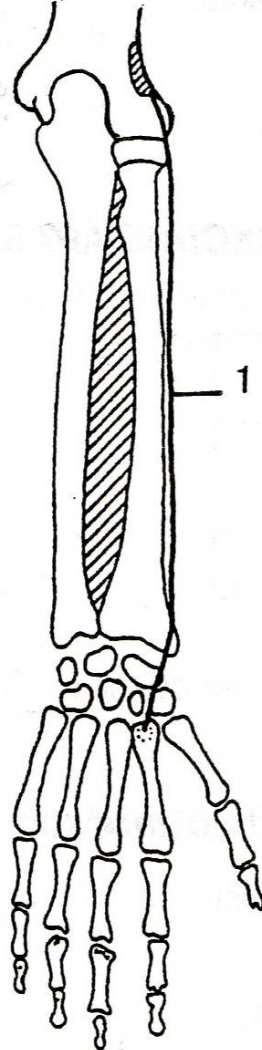
I, Palmaris aponeurosis of second, third, fourth, and fifth metacarpals

ZMK

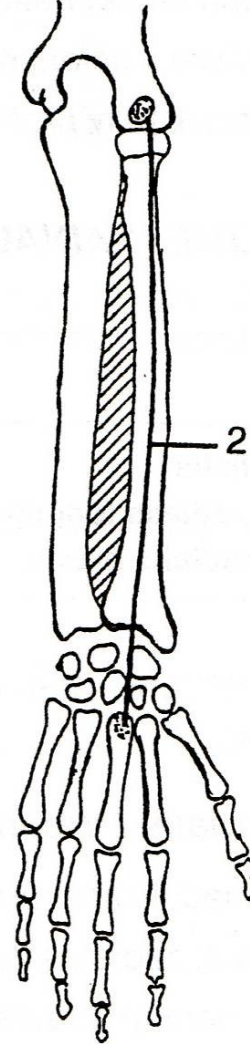
ZMK

DORZÁLNÍ FLEXE

m. extensor carpi
radialis longus



m. extensor carpi
radialis brevis



m. extensor carpi
ulnaris

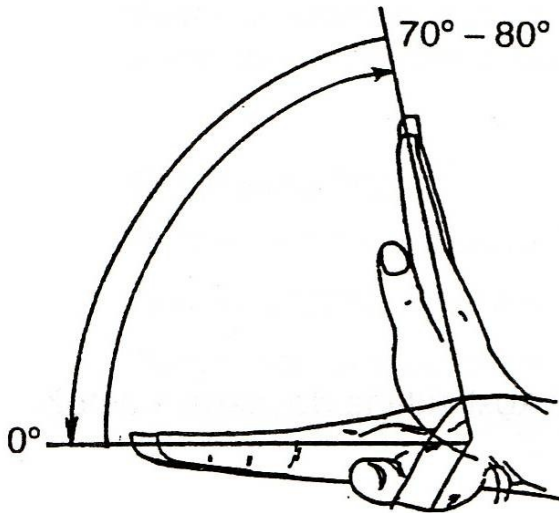
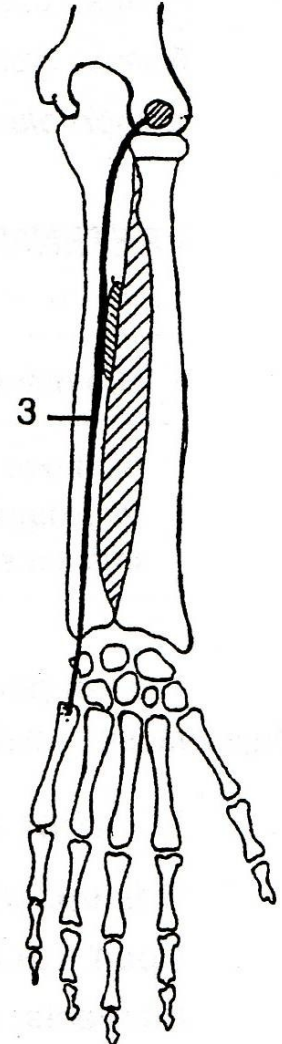
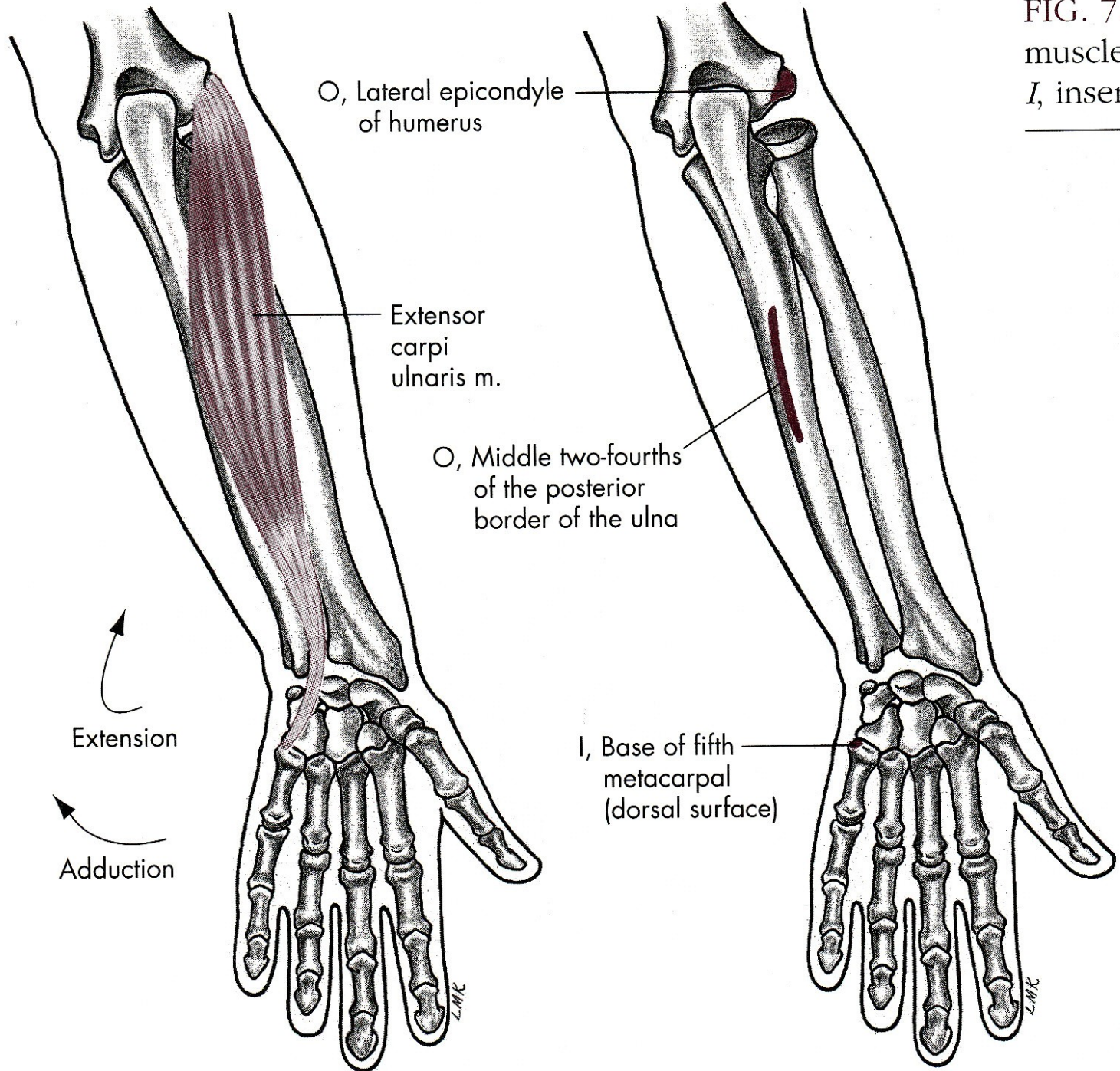
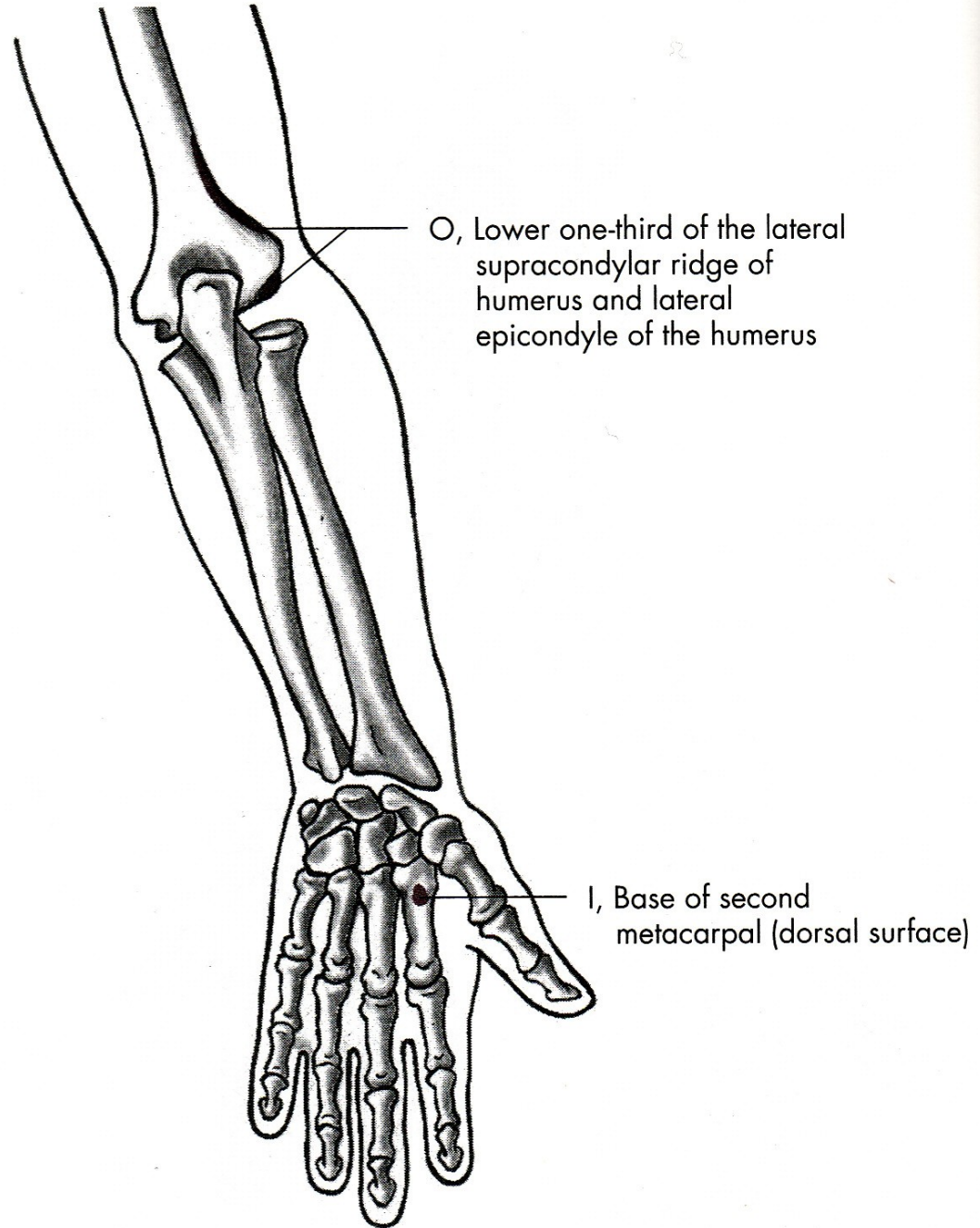
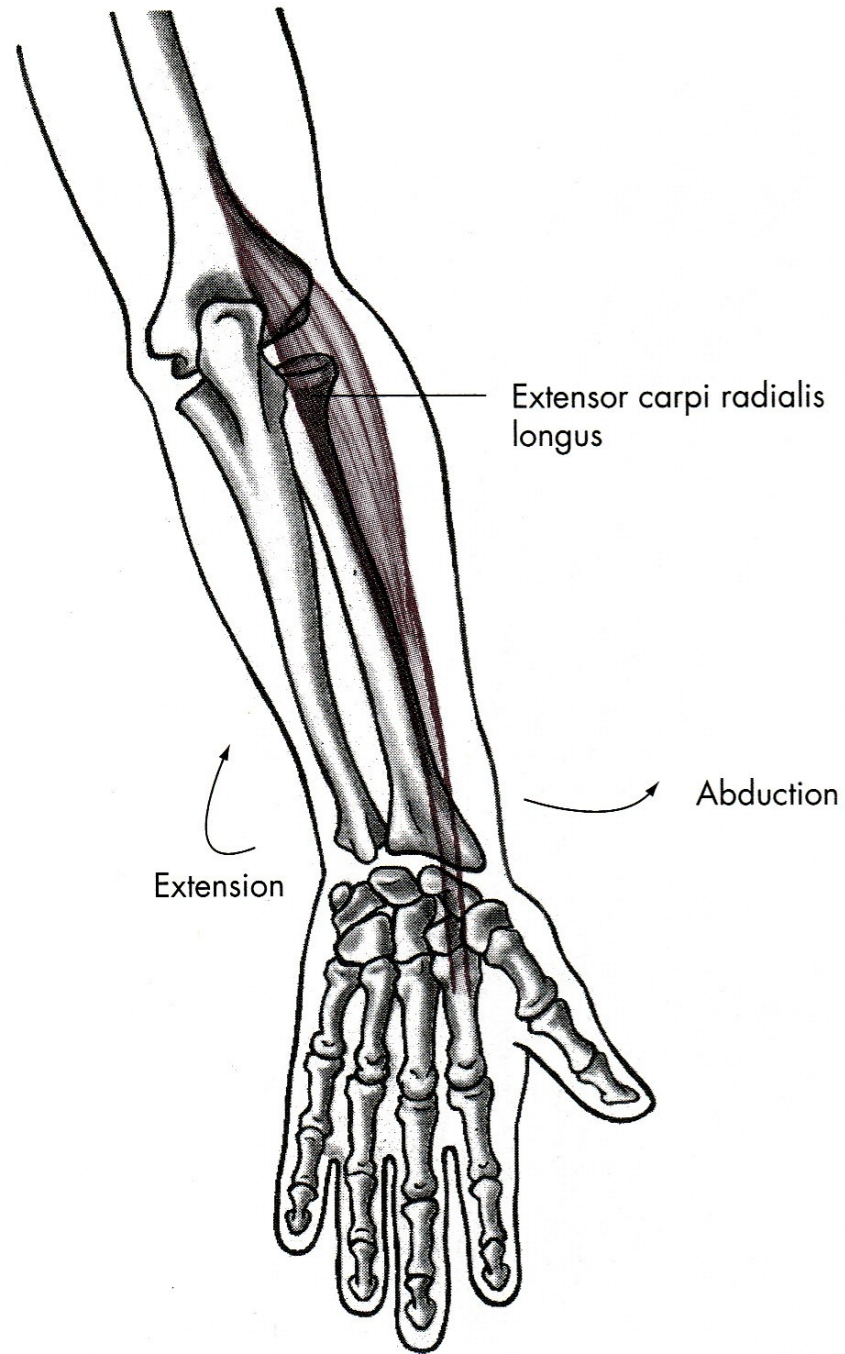
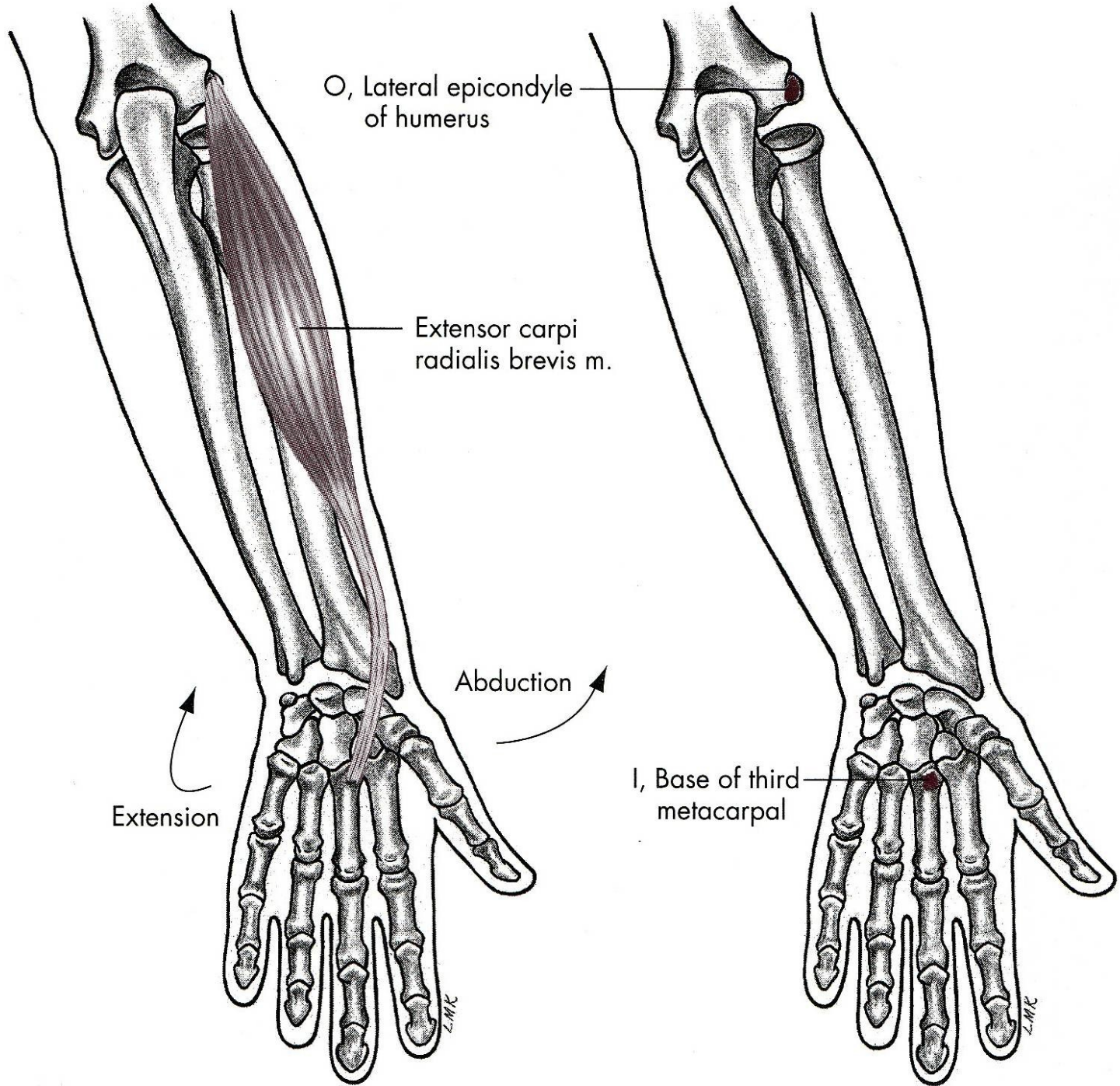


FIG. 7.1
muscle,
I, inserti







PALMÁRNÍ FLEXE

m. flexor carpi radialis – zevní ohybač zápěstí

m. flexor carpi ulnaris – vnitřní ohybač zápěstí

m. palmaris longus – dlouhý sval dlaňový

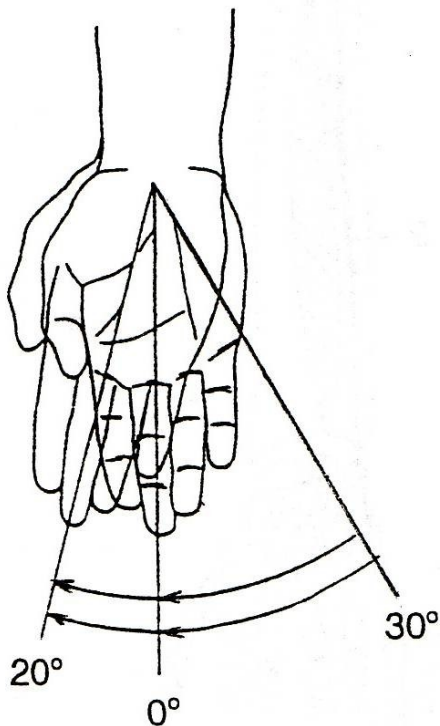
DORZÁLNÍ FLEXE

m. extensor carpi radialis longus et brevis –
dlouhý a krátký zevní natahovač zápěstí

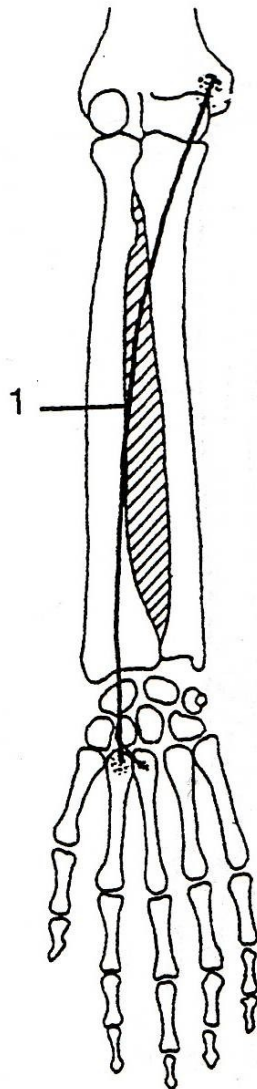
m. extensor carpi ulnaris –
vnitřní natahovač zápěstí

RADIÁLNÍ DUKCE

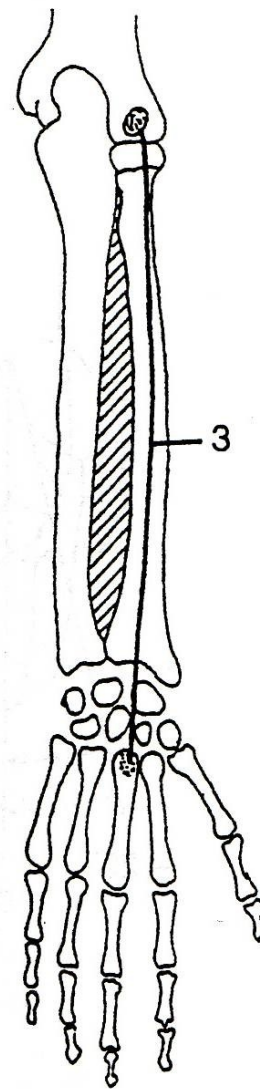
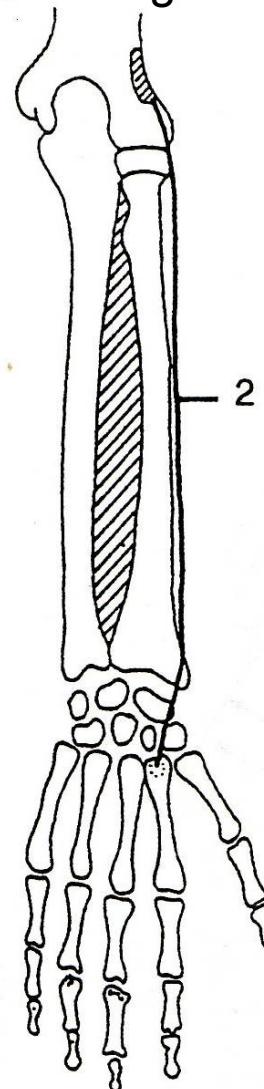
m. flexor carpi radialis



m. extensor carpi radialis longus



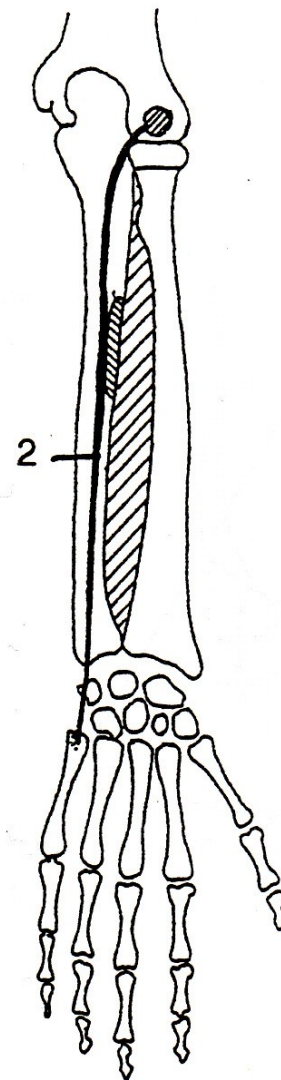
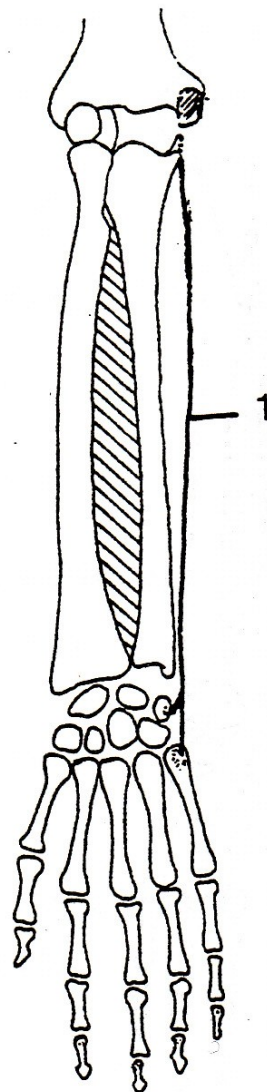
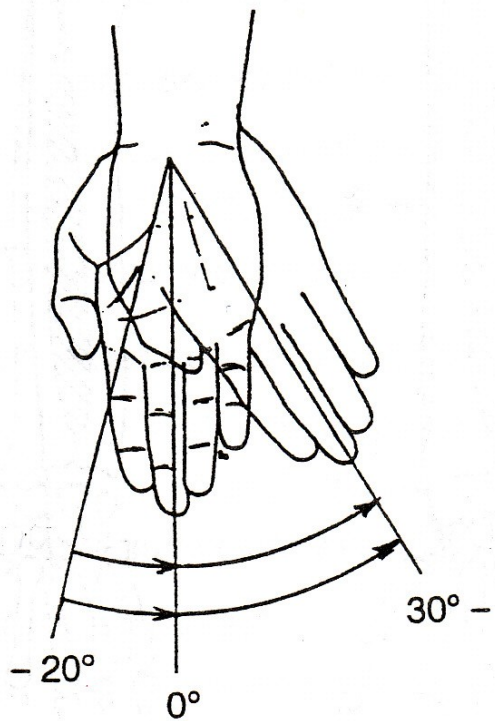
m. extensor carpi radialis brevis



ULNÁRNÍ DUKCE

m. flexor carpi ulnaris

m. extensor carpi ulnaris



RADIÁLNÍ DUKCE

m. extensor carpi radialis longus et brevis –
dlouhý a krátký zevní natahovač zápěstí

m. flexor carpi radialis – zevní ohybač zápěstí

ULNÁRNÍ DUKCE

m. extensor carpi ulnaris –
vnitřní natahovač zápěstí

m. flexor carpi ulnaris – vnitřní ohybač zápěstí

POHYBY PRSTŮ

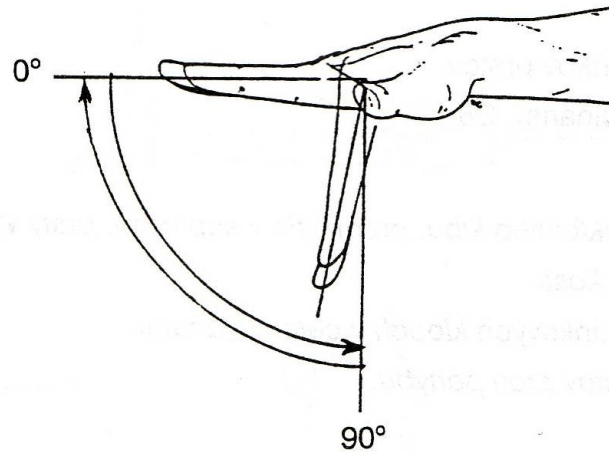
FLEXE - OHNUTÍ

EXTENZE - NATAŽENÍ

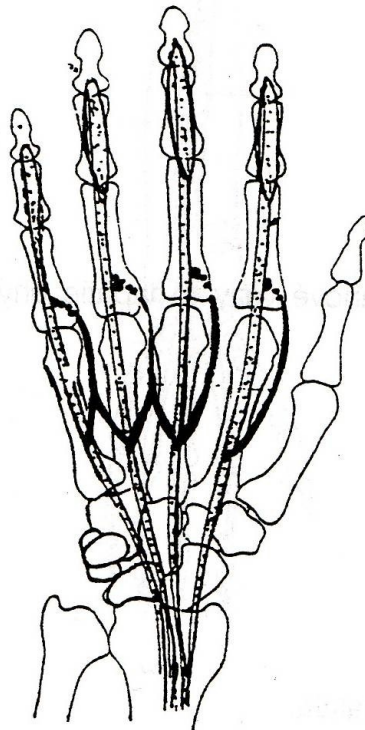
ABDUKCE - ODTAŽENÍ

ADDUKCE - PŘITAŽENÍ

FLEXE - OHNUTÍ

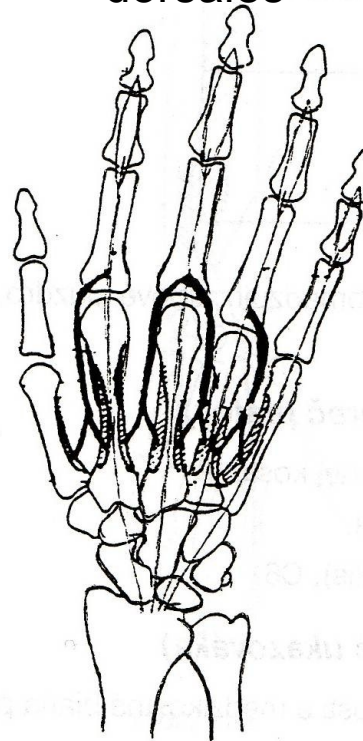


mm. lumbricales



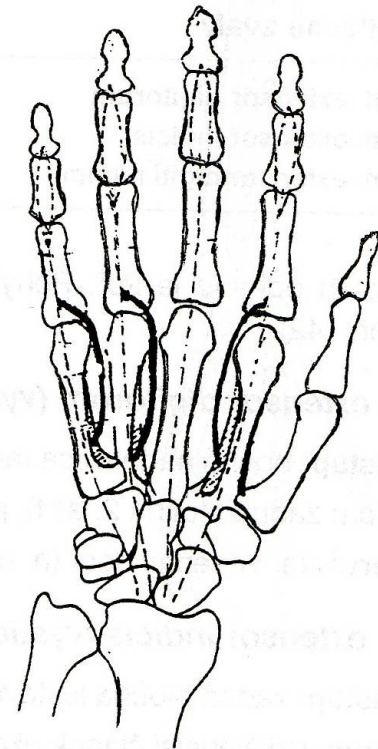
A

mm. Interossei dorsales

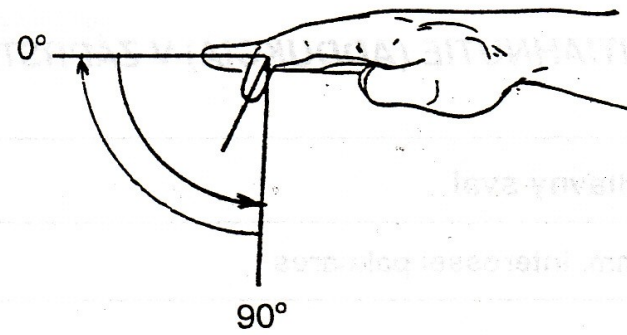
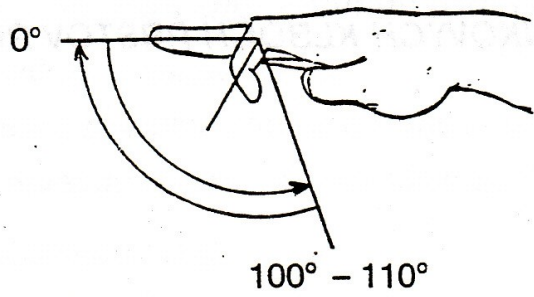


B

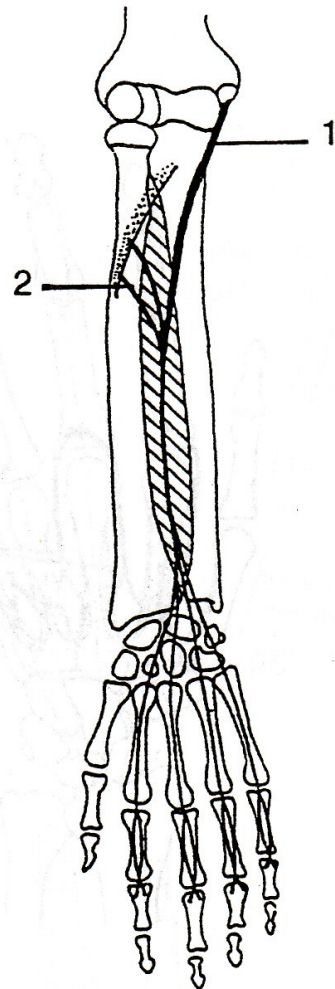
mm. Interossei palmares



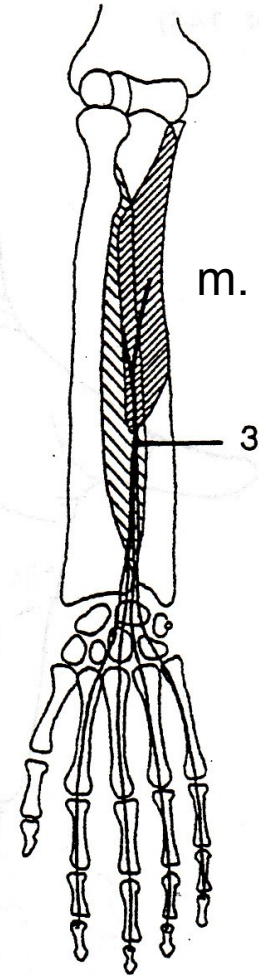
C



m. flexor digitorum superficialis

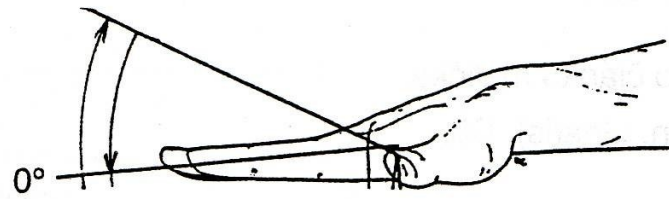


m. flexor digitorum profundus



EXTENZE - NATAŽENÍ

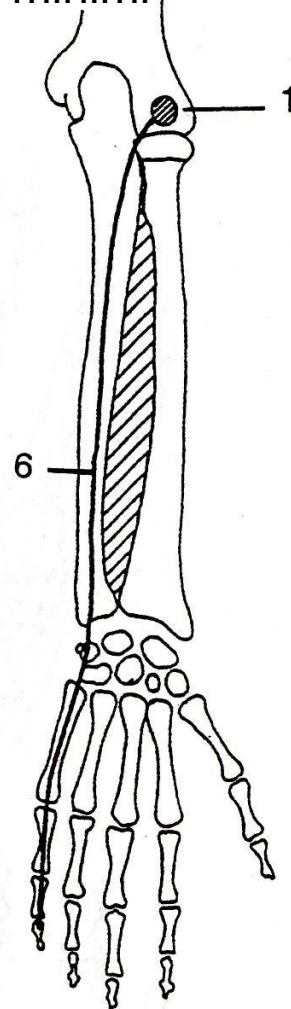
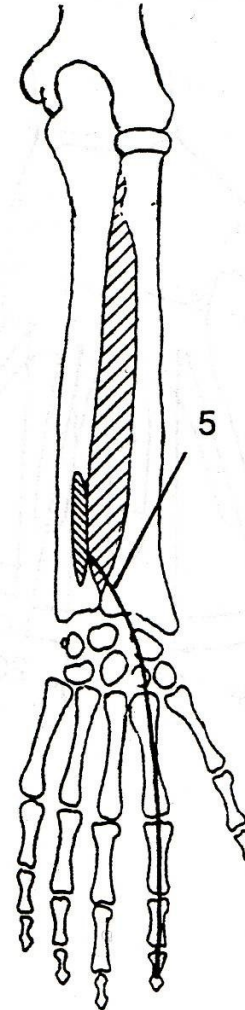
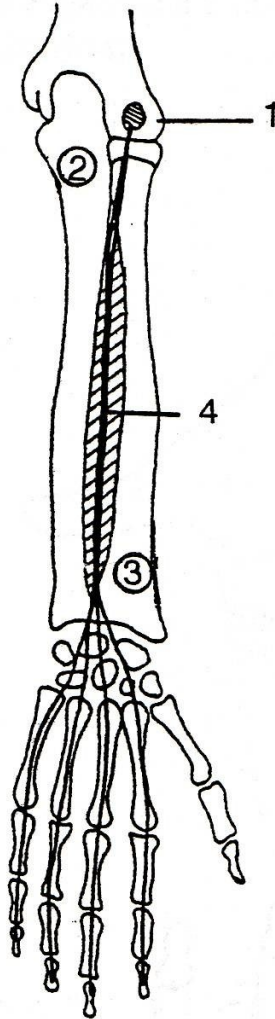
20° - 30°

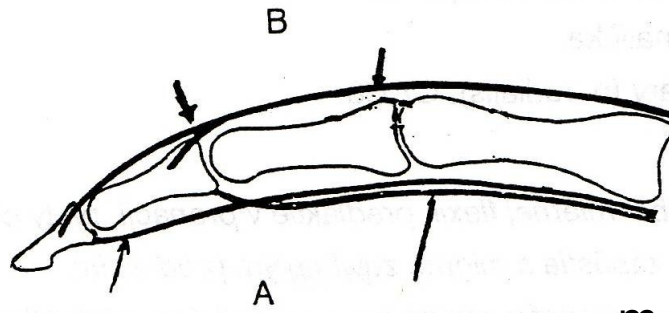


m. extensor indicis

m. extensor digiti
minimi

m. extensor digitorum

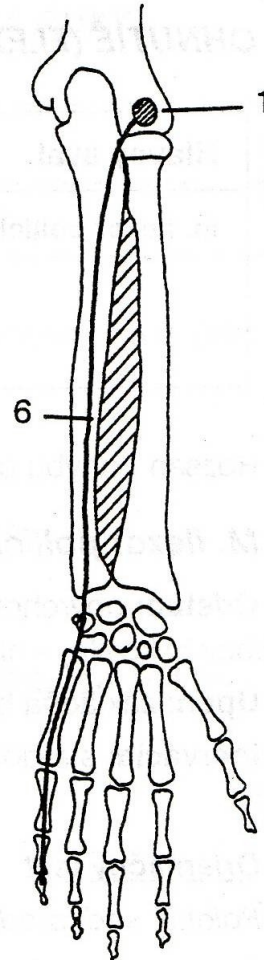
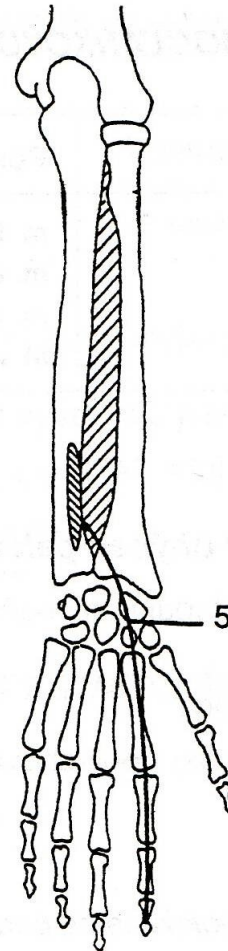
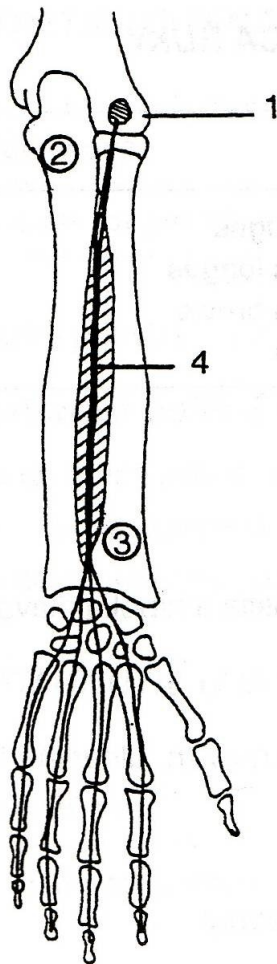


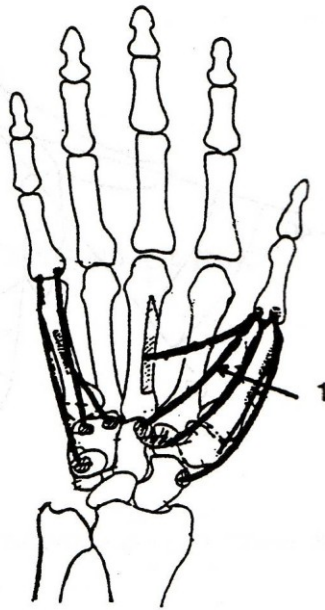
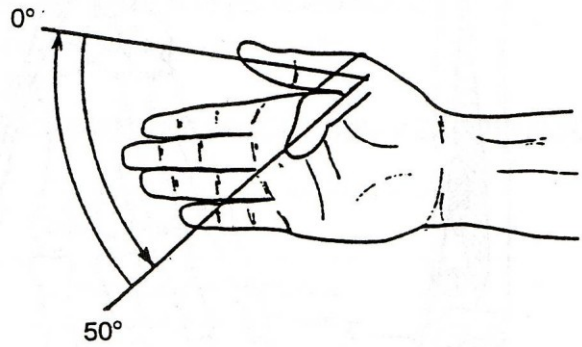


m. extensor indicis

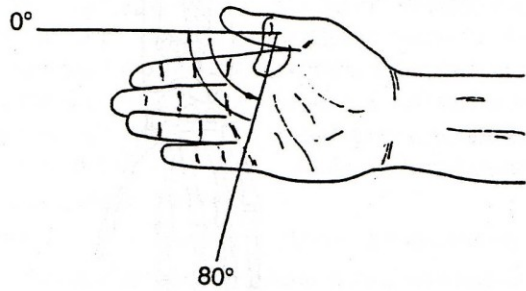
m. extensor digiti
minimi

m. extensor digitorum

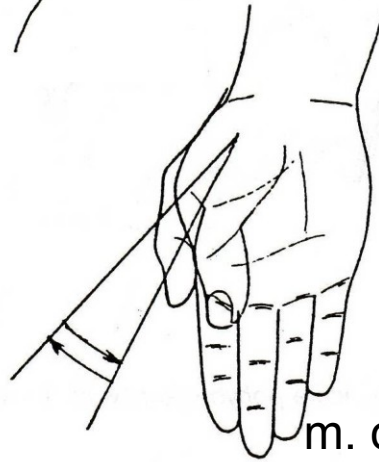
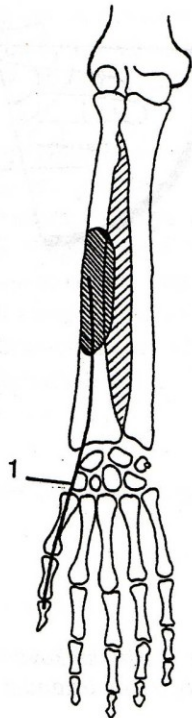




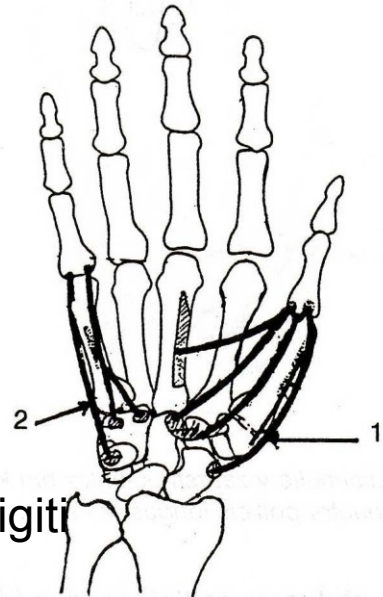
m. flexor pollicis brevis



m. flexor pollicis longus



m. opponens digiti
minimi



m. opponens pollicis