

# POHYBY HLAVY A TRUPU



# POHYBY PÁNVE A LOPATEK

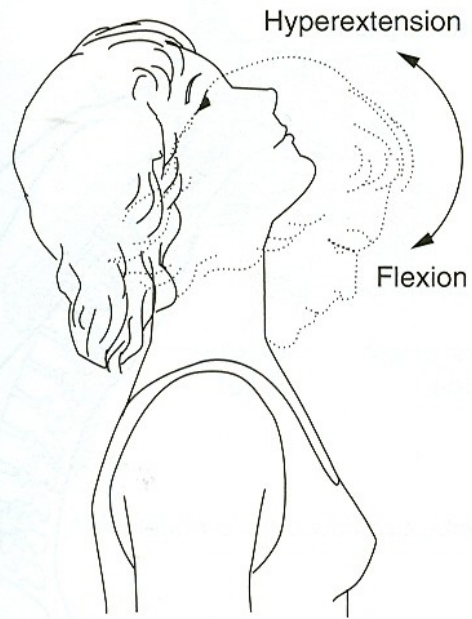
# POHYBY HLAVY

FLEXE - PŘEDKLON

EXTENZE - ZÁKLON

LATEROFLEXE - ÚKLON

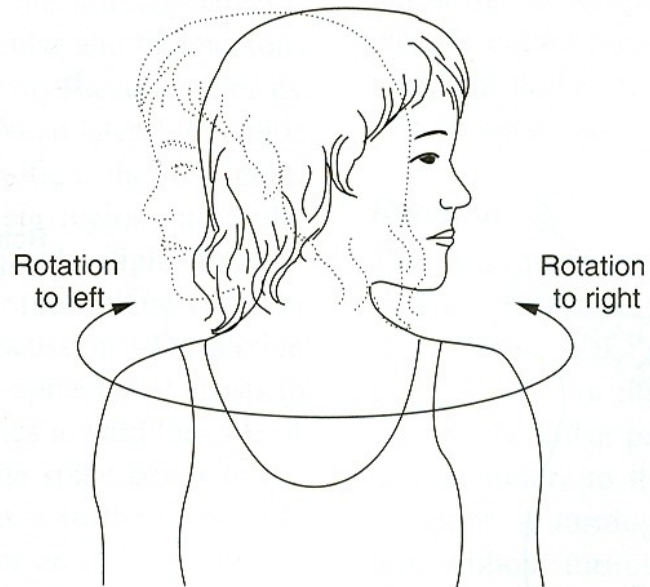
ROTACE - OTÁČENÍ



a.

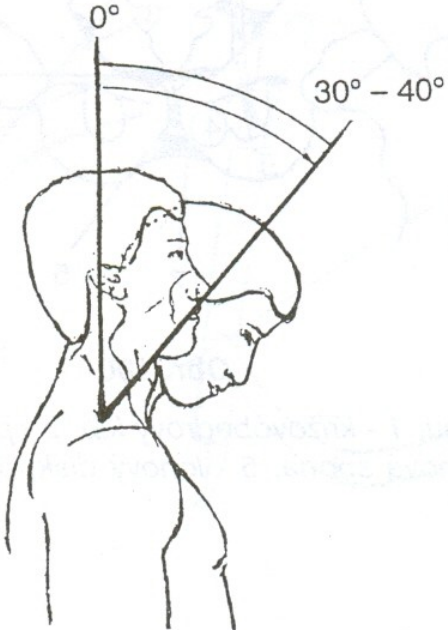


b.

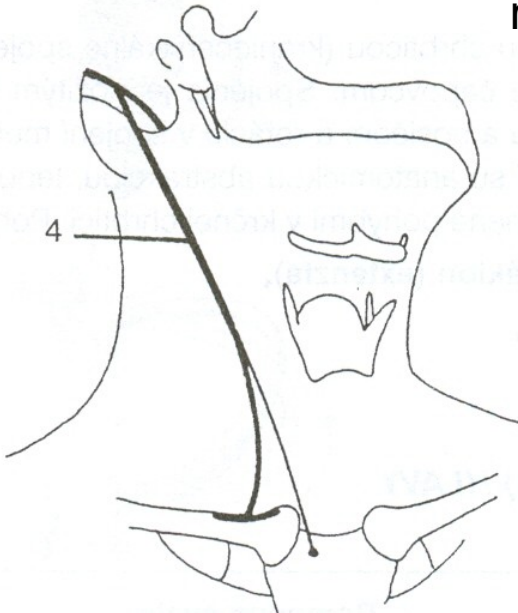
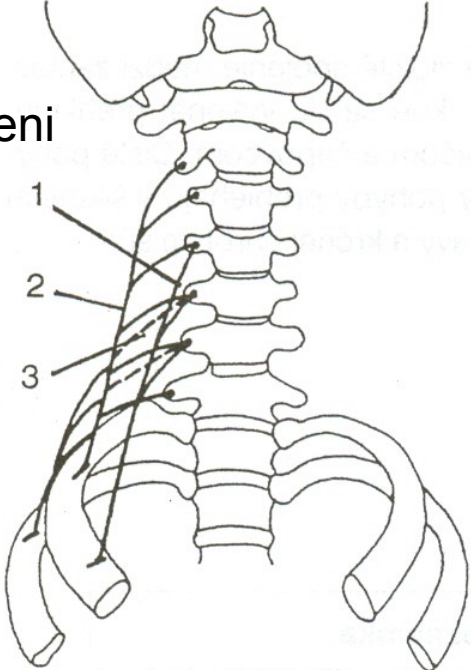


c.

# FLEXE - PŘEDKLON

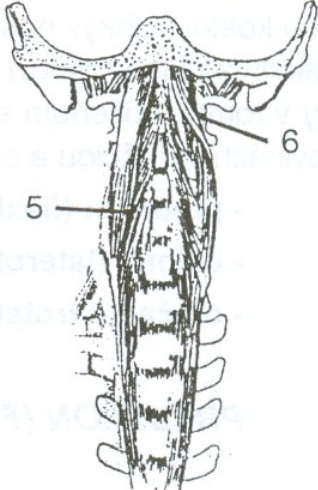


mm. scaleni



m. sternocleidomastoideus

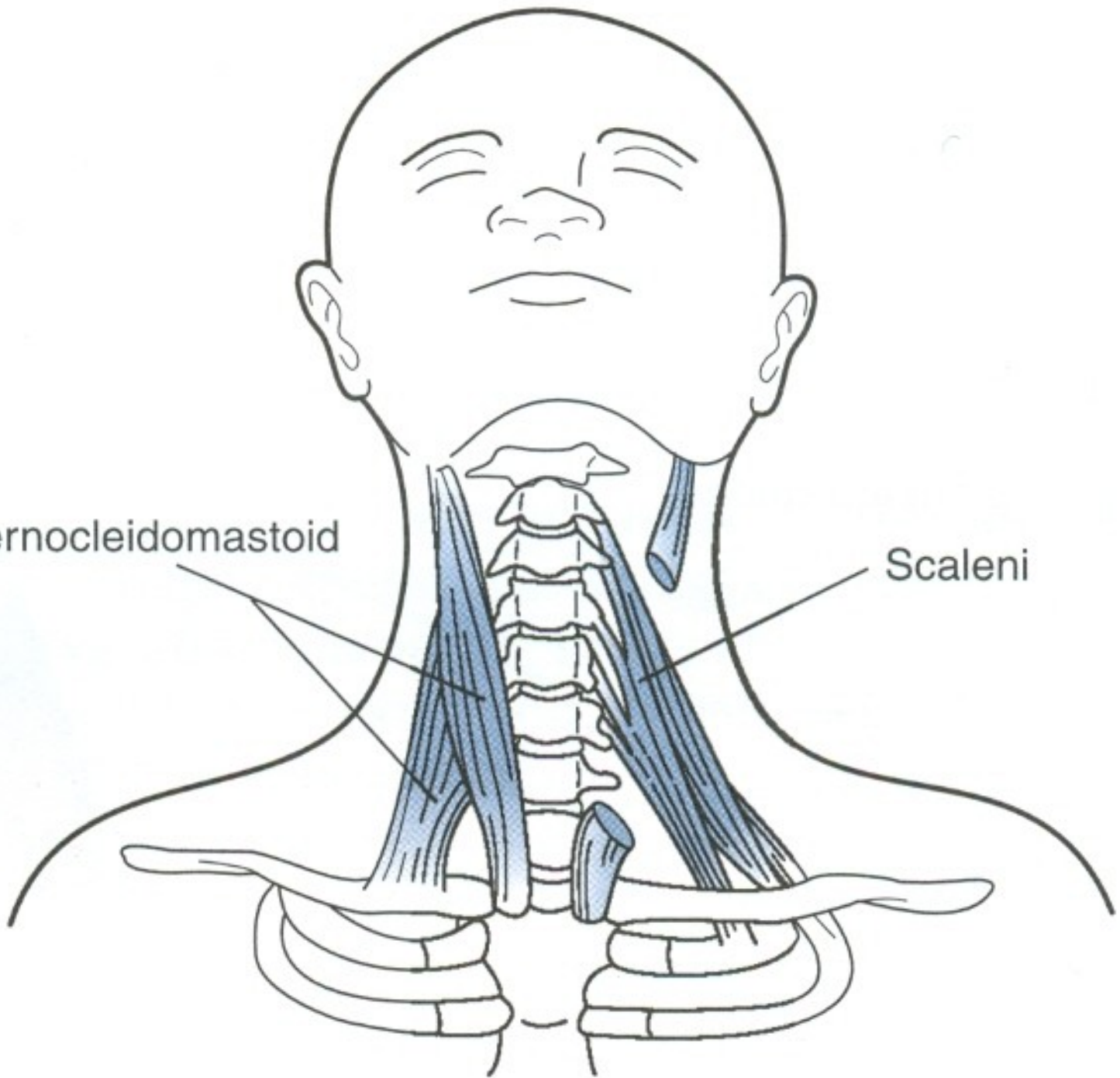
m. longus colli



m. longus capitis

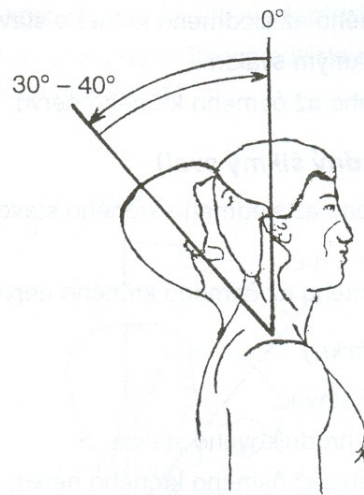
Sternocleidomastoid

Scaleni

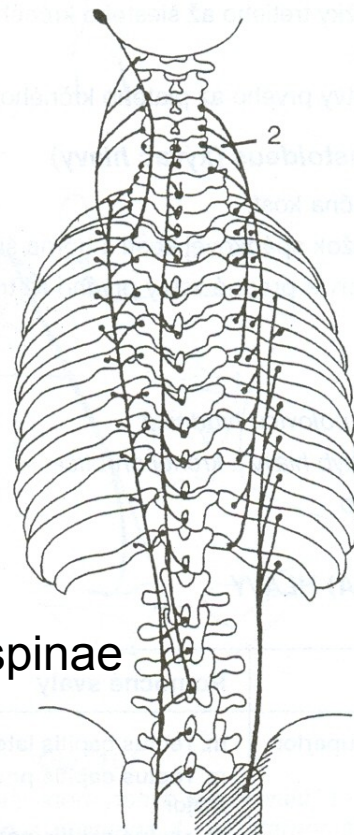
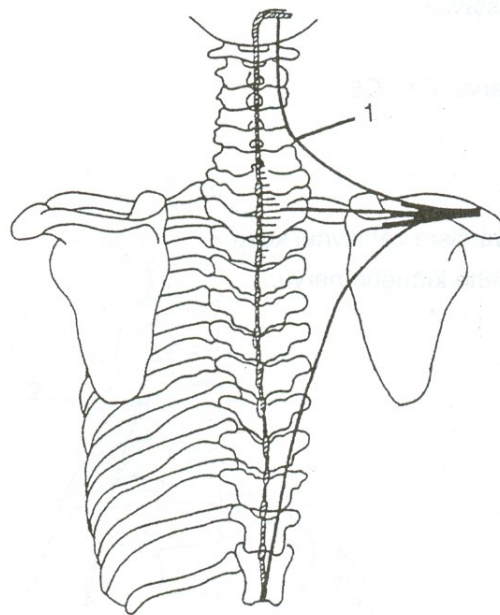




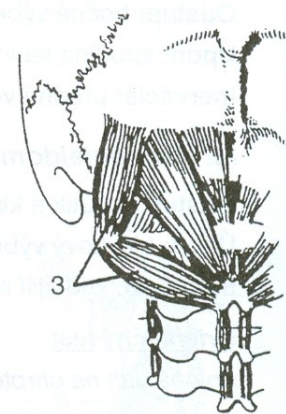
# EXTENZE - ZÁKLON



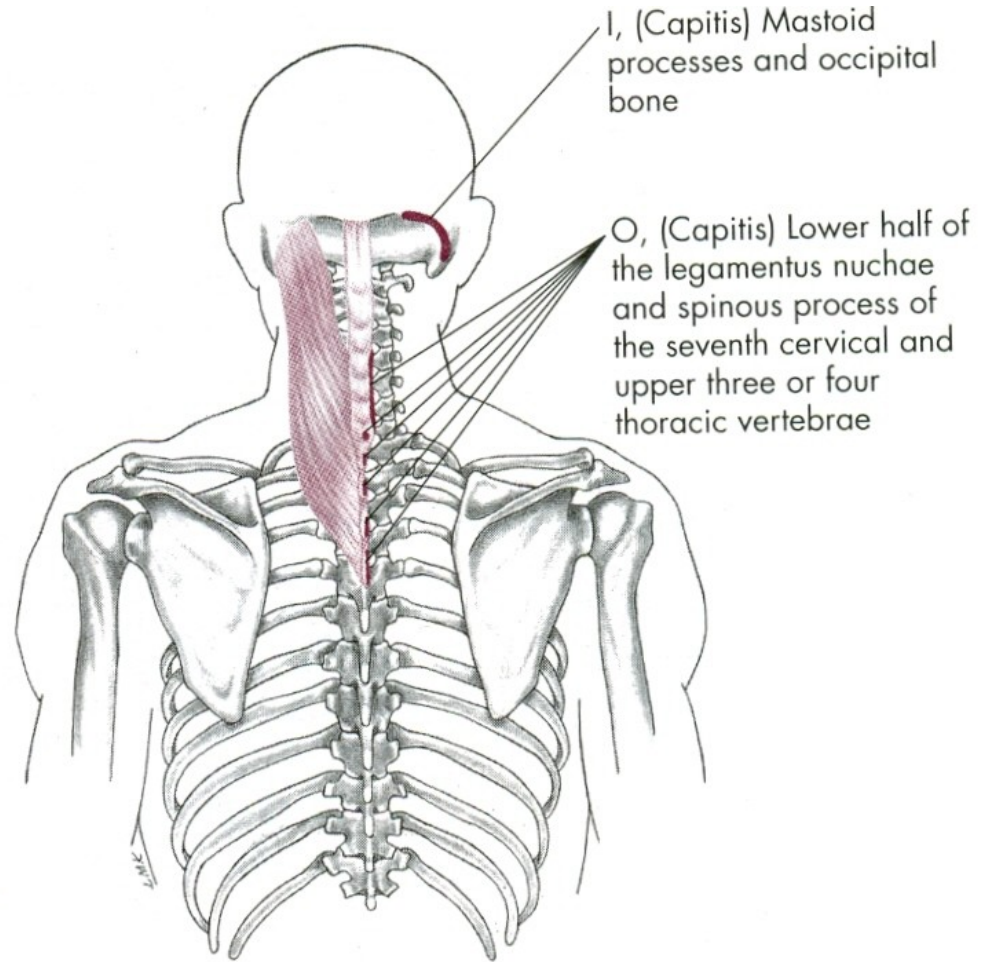
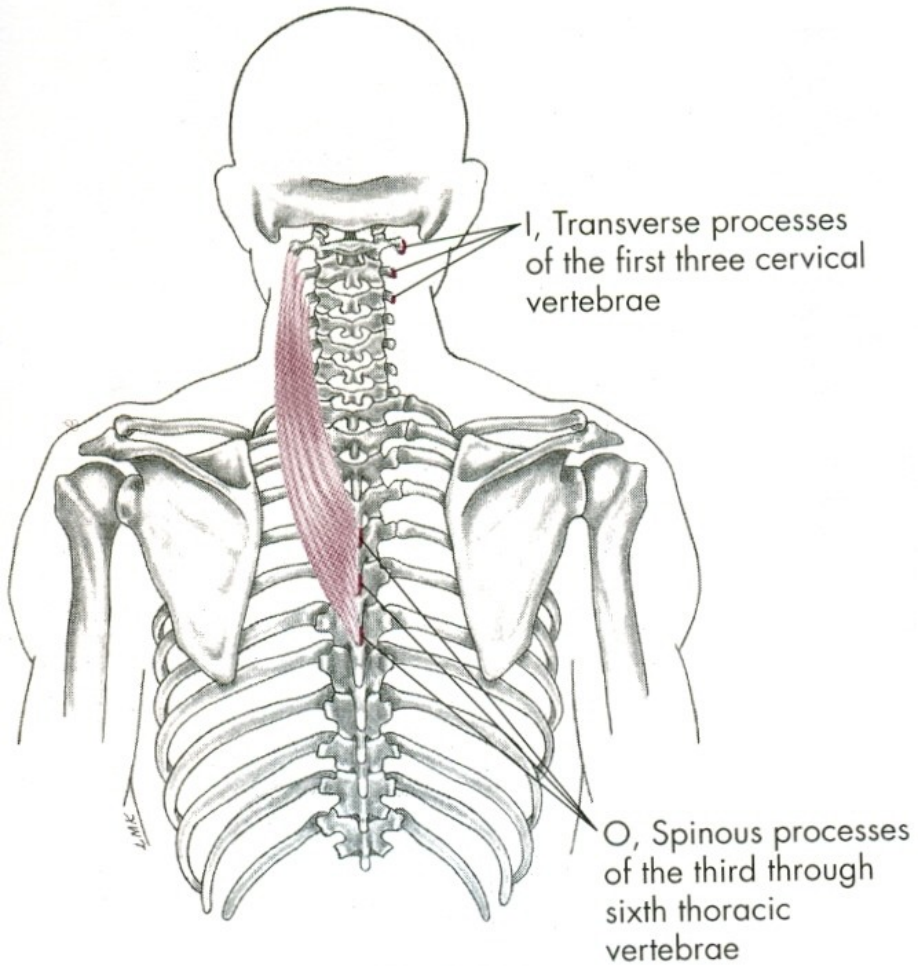
m. trapezius



m. erector spinae



hluboké svaly šíjové



## FLEXE HLAVY

mm. scaleni – svaly kloněné

mm. praevertebrales – dlouhé svaly hlavy a krku

m. sternocleidomastoideus – zdvihač hlavy

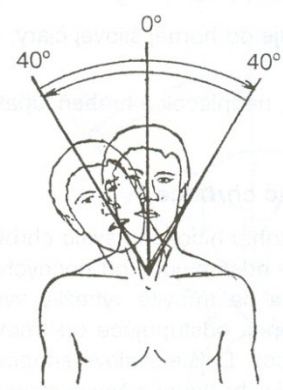
## EXTENZE HLAVY

m. trapezius-pars superior –  
sval trapézový-horní část

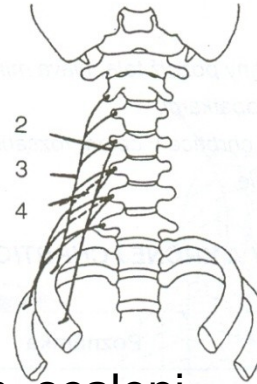
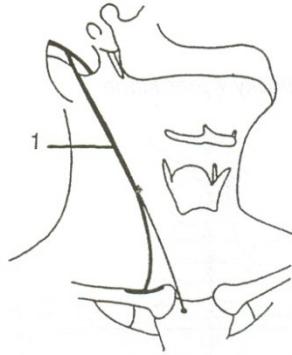m. erector spinae – vzpřimovače hlavy a trupu



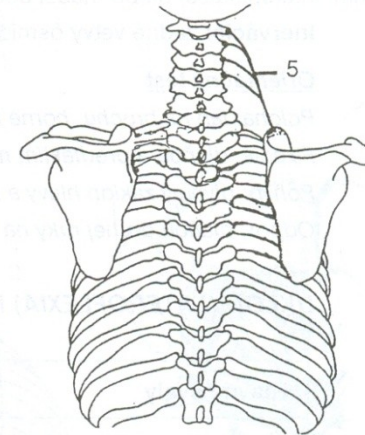
# LATEROFLEXE - ÚKLON



m. sternocleidomastoideus

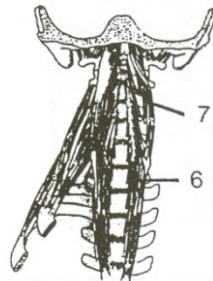


mm. scaleni

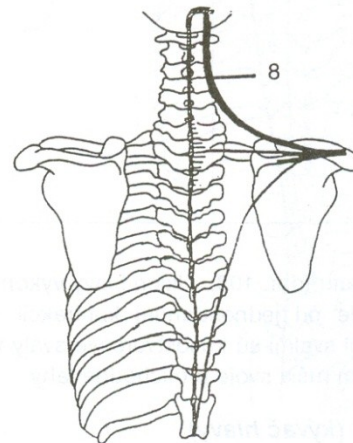


m. levator scapulae

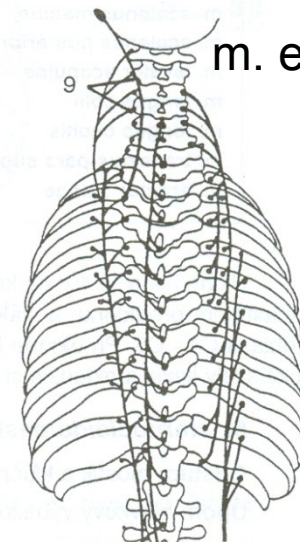
m. longus capitis



m. longus colli

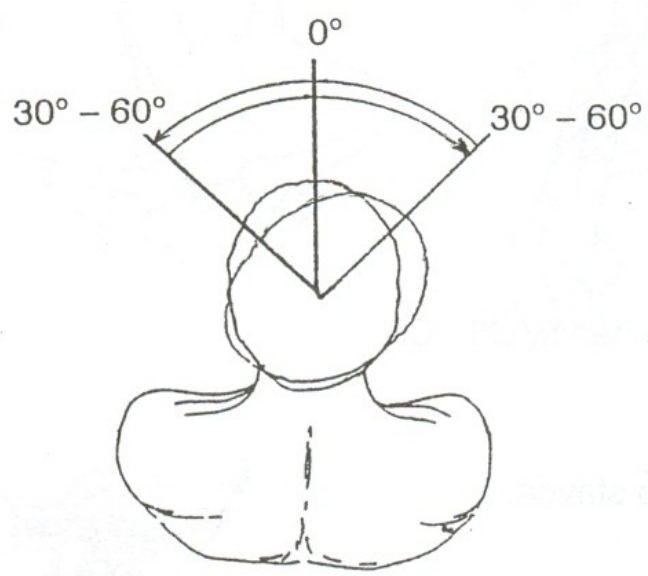


m. trapezius

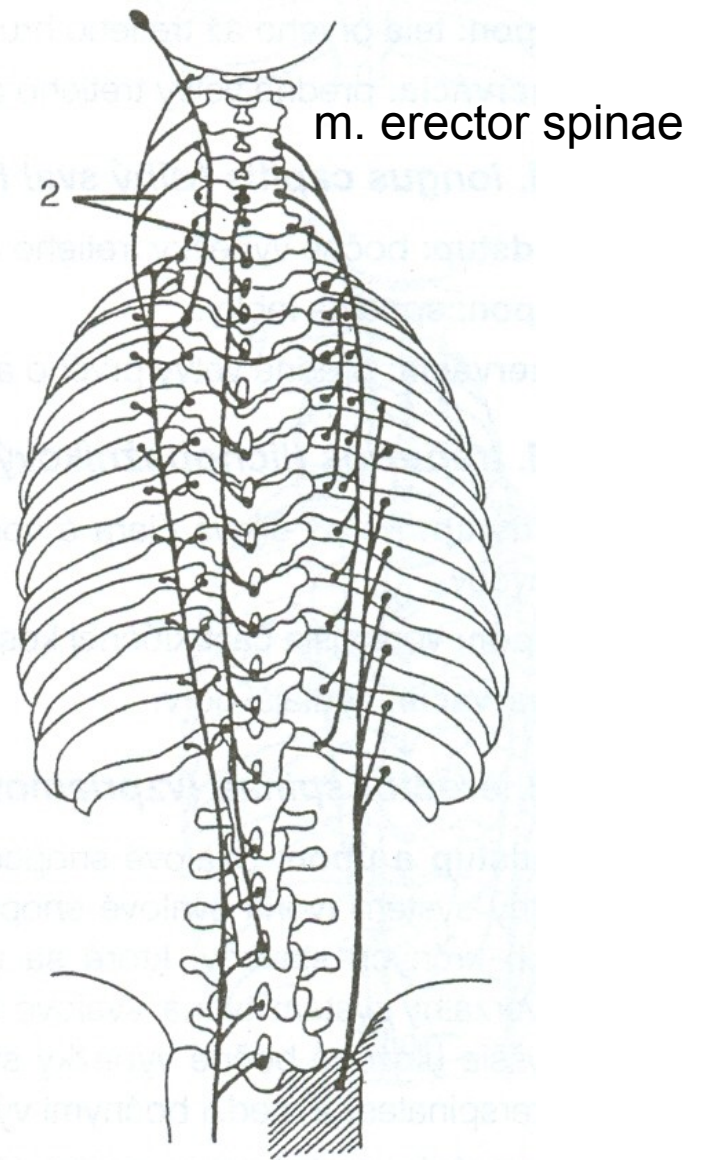
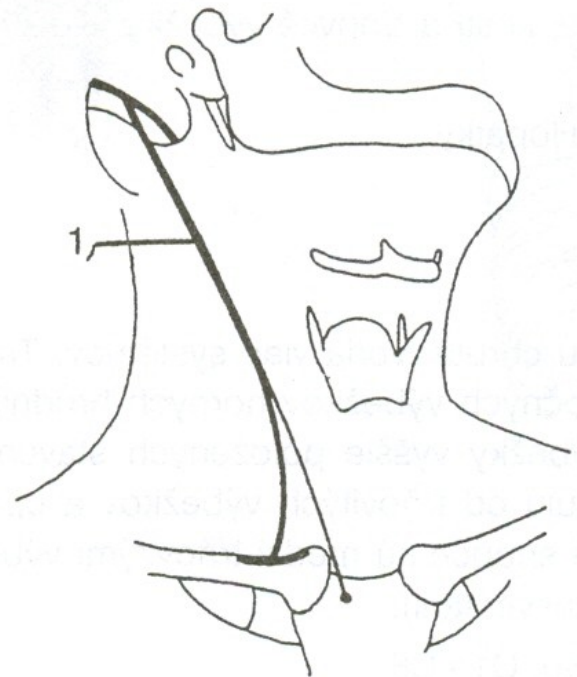


m. erector spinae

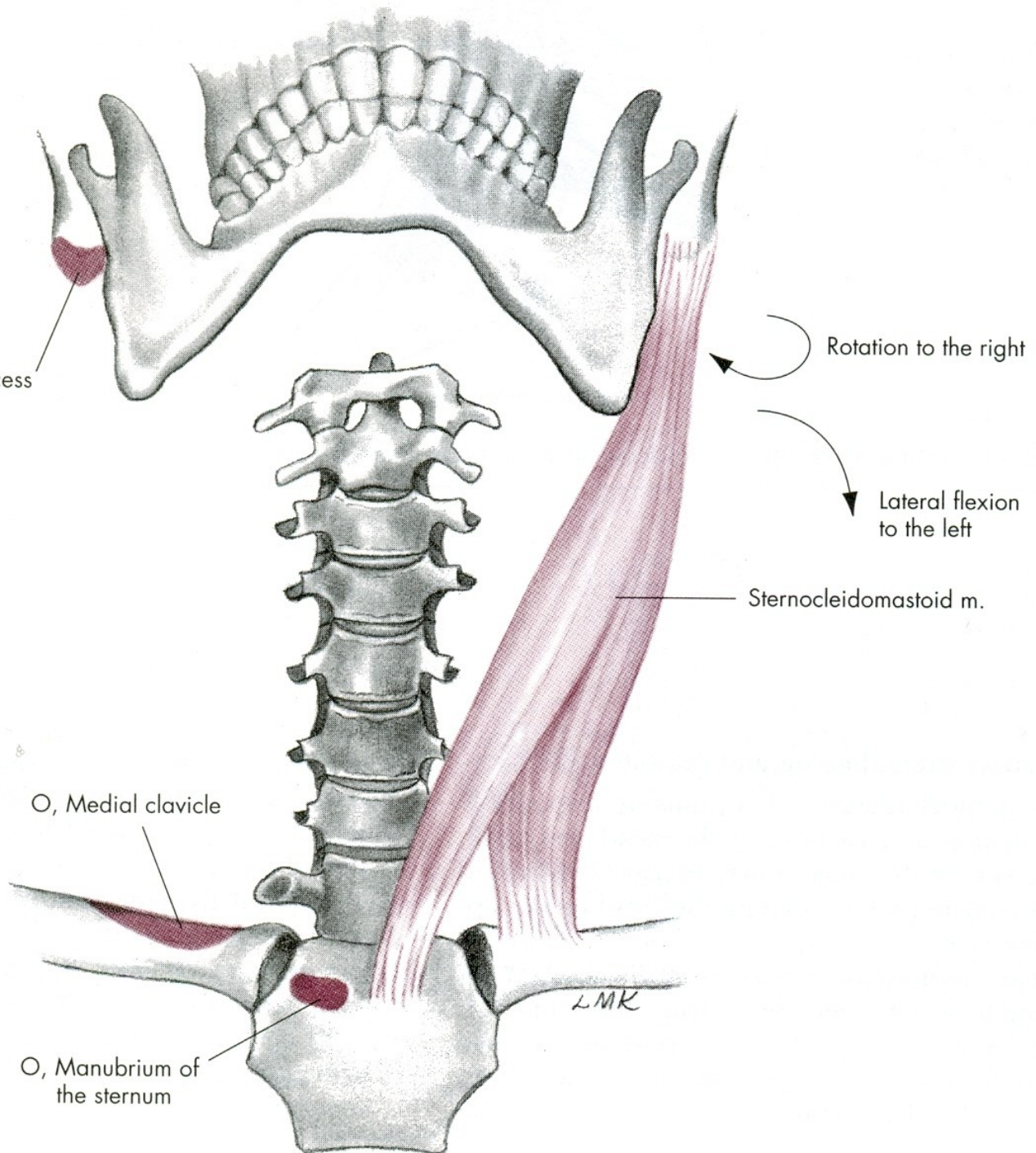
# ROTACE - OTÁČENÍ



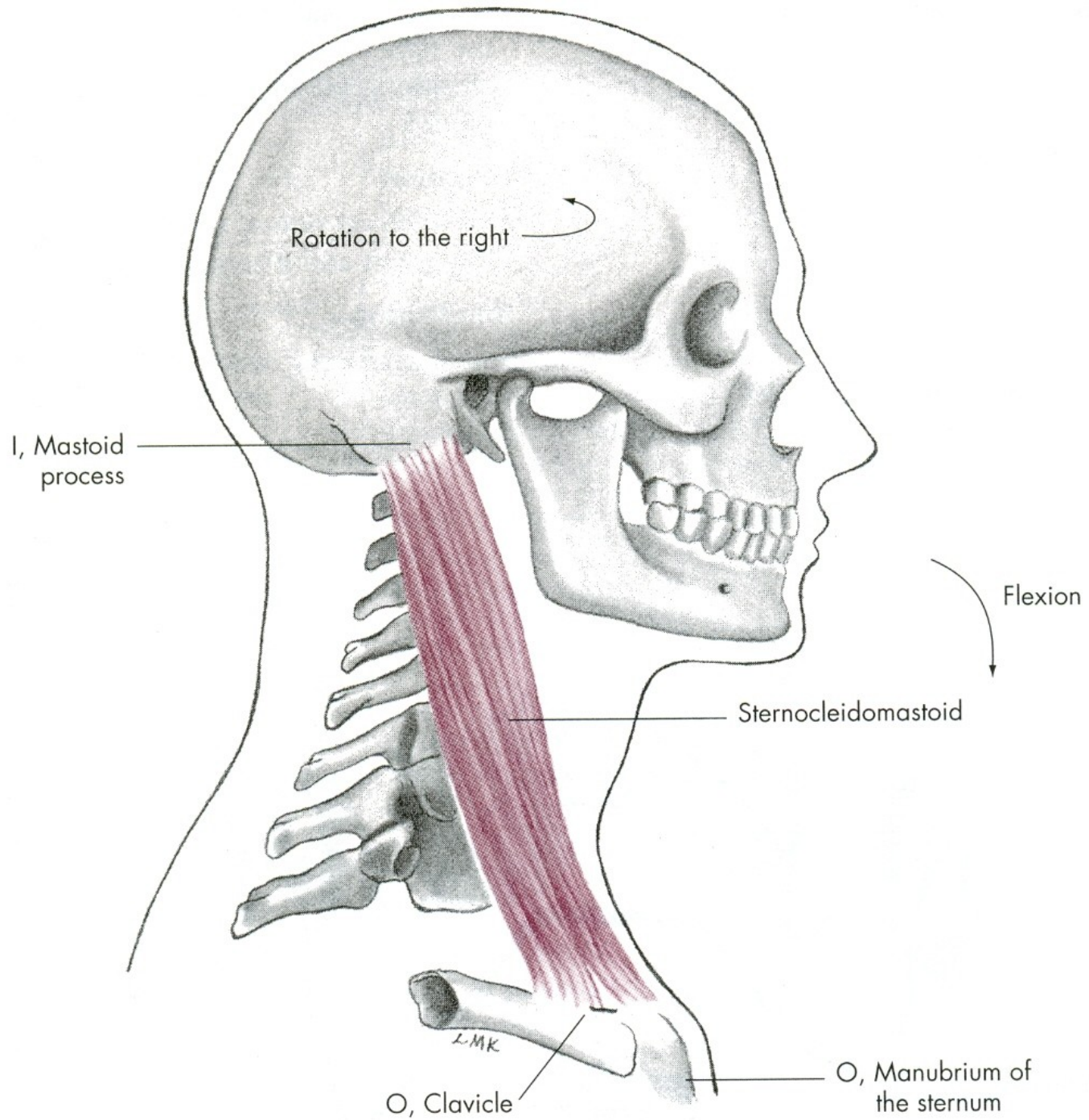
m. sternocleidomastoideus



I, Mastoid process







# LATEROFLEXE HLAVY a KRKU

m. sternocleidomastoideus – zdvihač hlavy

mm. scaleni – svaly kloněné

m. levator scapulae – zdvihač lopatky

m. trapezius-pars superior –  
svaly trapézový-horní část

# ROTACE HLAVY a KRKU

m. sternocleidomastoideus – zdvihač hlavy

m. erector spinae – transverzospinální systém

m. erector spinae – spinotransverzální systém



# POHYBY TRUPU

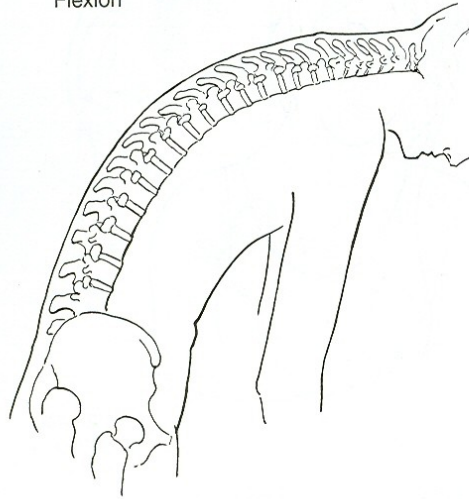
VENTRÁLNÍ FLEXE - PŘEDKLON

DORZÁLNÍ FLEXE - ZÁKLON

LATEROFLEXE - ÚKLON

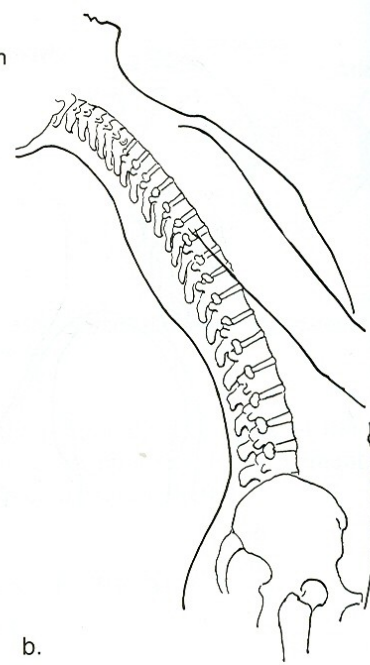
ROTACE - OTÁČENÍ

Flexion



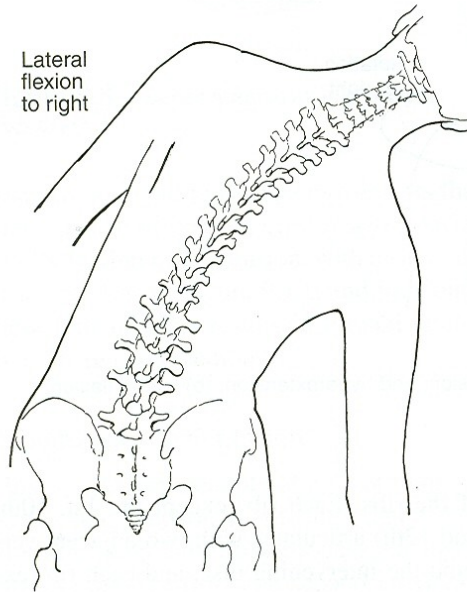
a.

Hyperextension



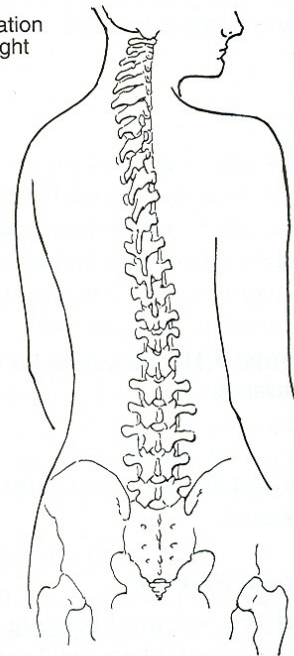
b.

Lateral flexion to right



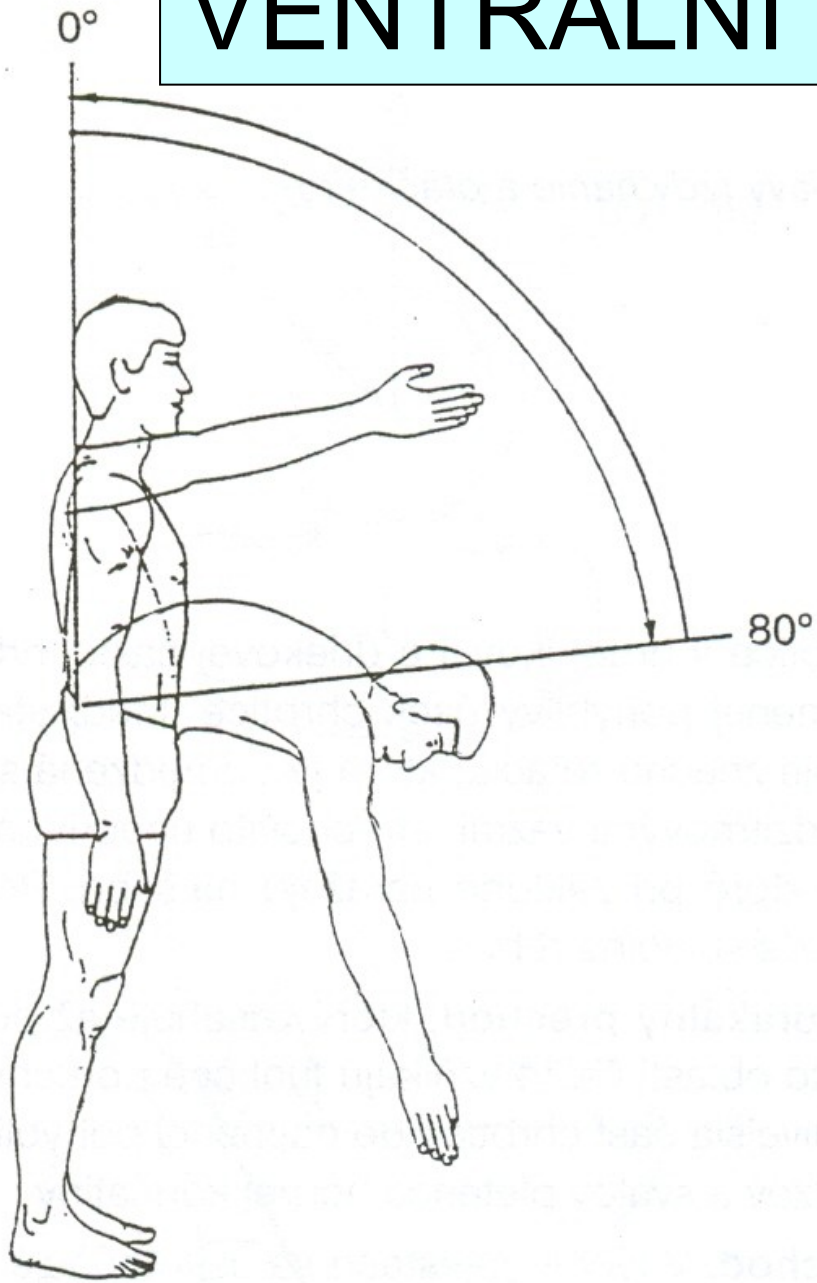
c.

Rotation to right

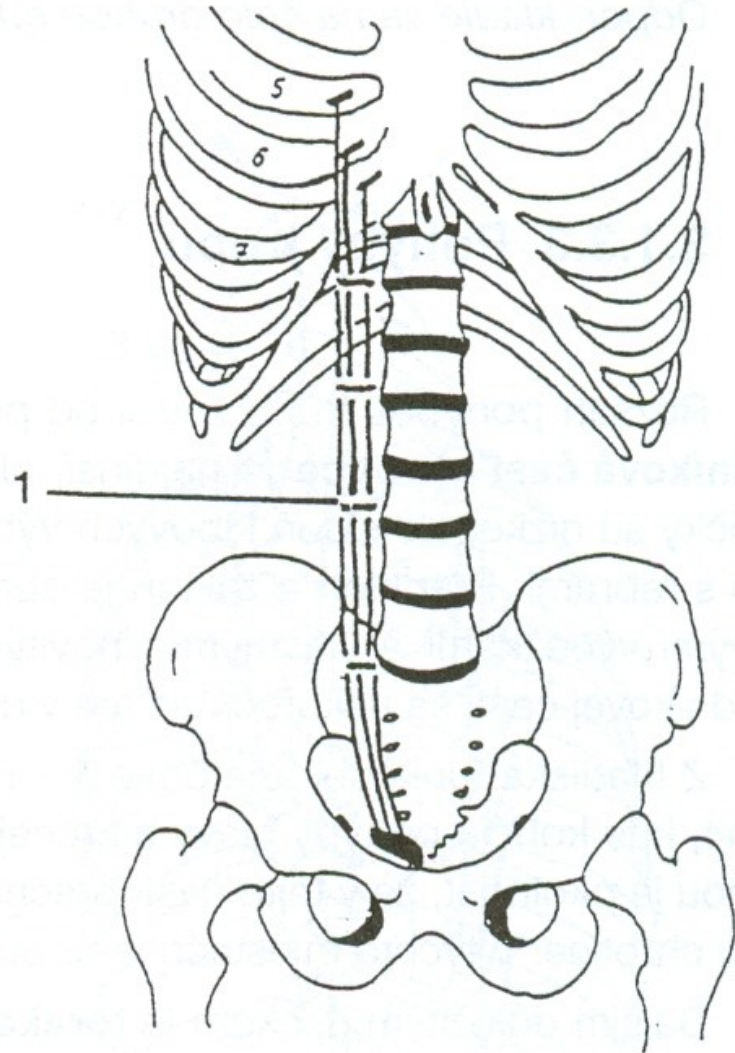


d.

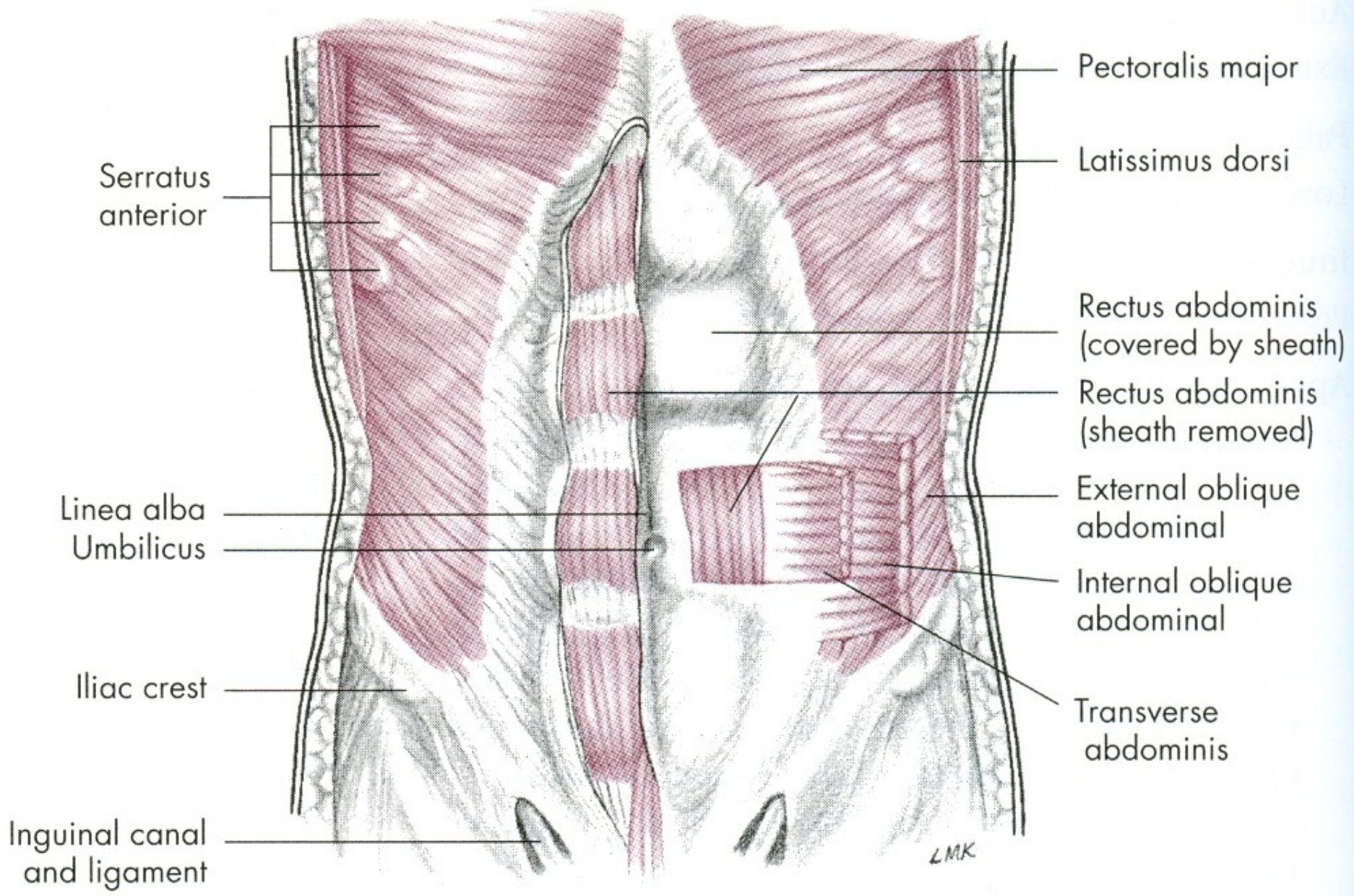
# VENTRÁLNÍ FLEXE - PŘEDKLON



m. rectus abdominis







Pectoralis major

Latissimus dorsi

Rectus abdominis  
(covered by sheath)

Rectus abdominis  
(sheath removed)

External oblique  
abdominal

Internal oblique  
abdominal

Transverse  
abdominis

Serratus  
anterior

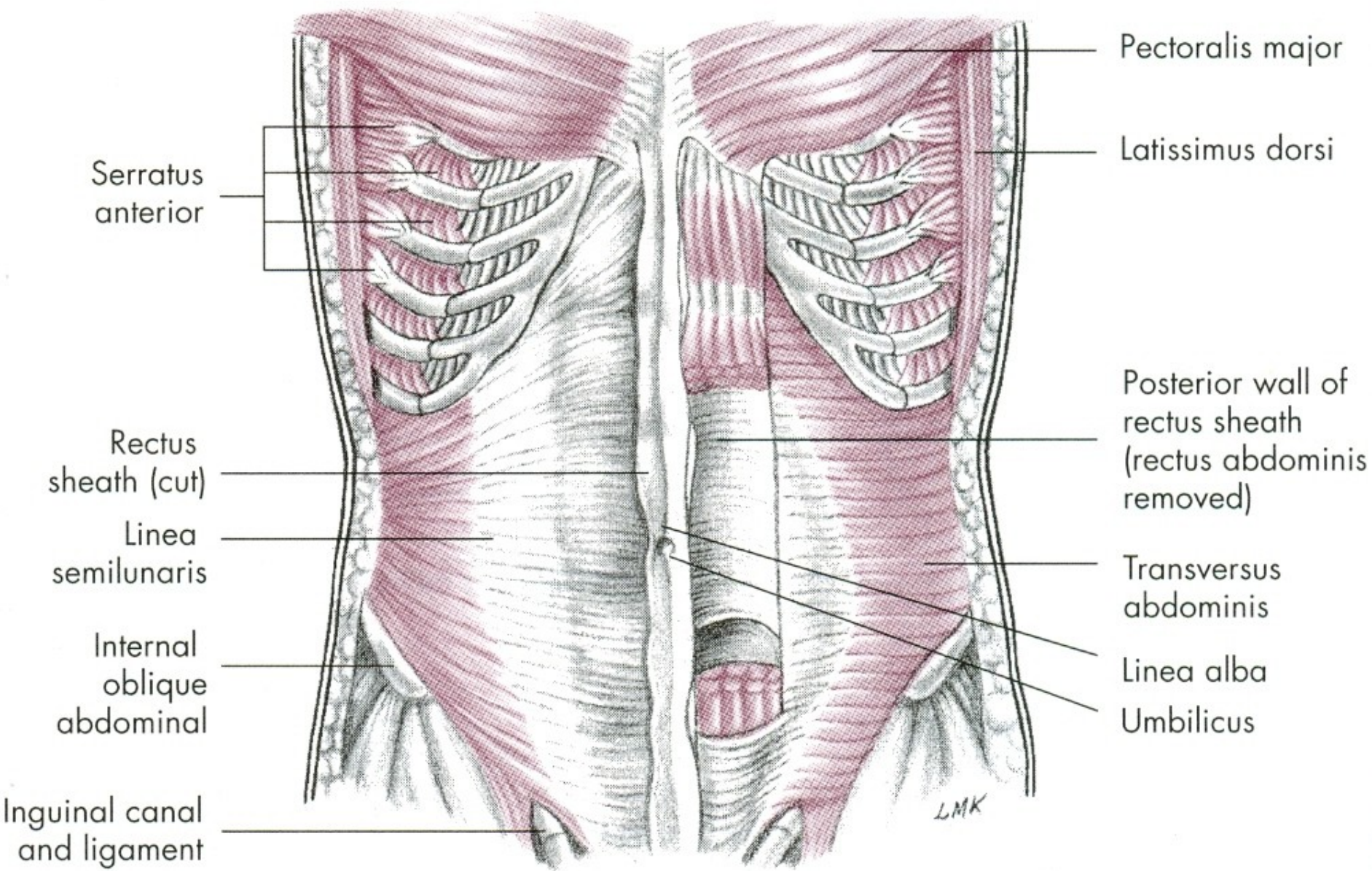
Linea alba  
Umbilicus

Iliac crest

Inguinal canal  
and ligament

L.M.K.





Serratus anterior

Rectus sheath (cut)

Linea semilunaris

Internal oblique abdominal

Inguinal canal and ligament

Pectoralis major

Latissimus dorsi

Posterior wall of rectus sheath (rectus abdominis removed)

Transversus abdominis

Linea alba

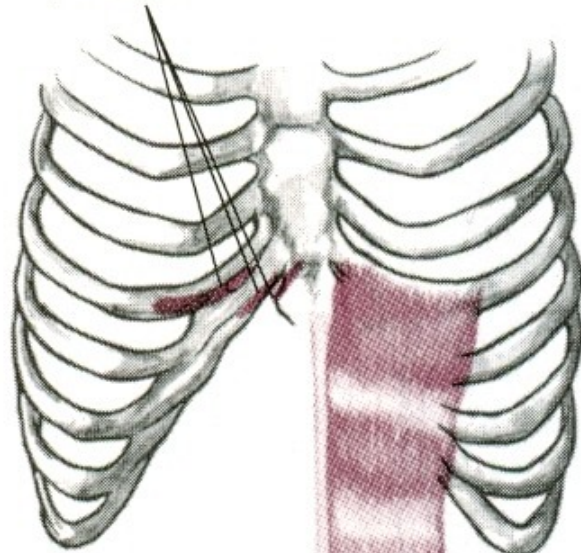
Umbilicus

LMK



I, Cartilage of fifth, sixth, and seventh ribs, xiphoid process

Lateral flexion



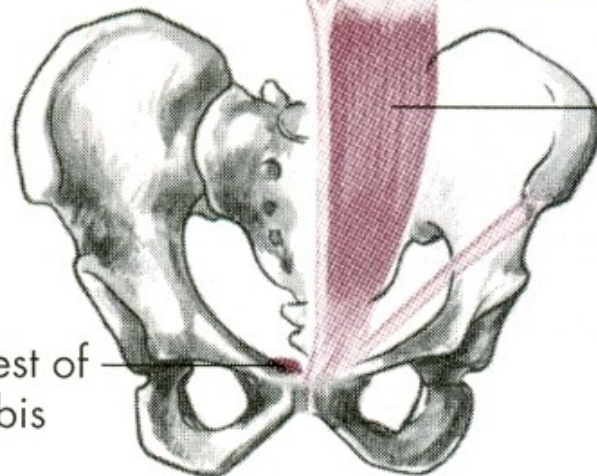
Linea alba

Flexion

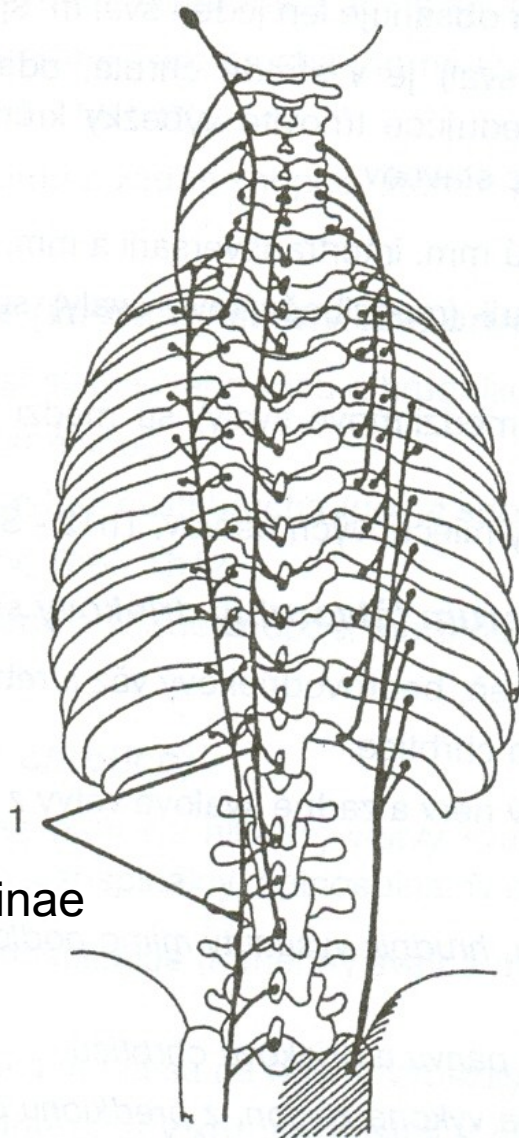
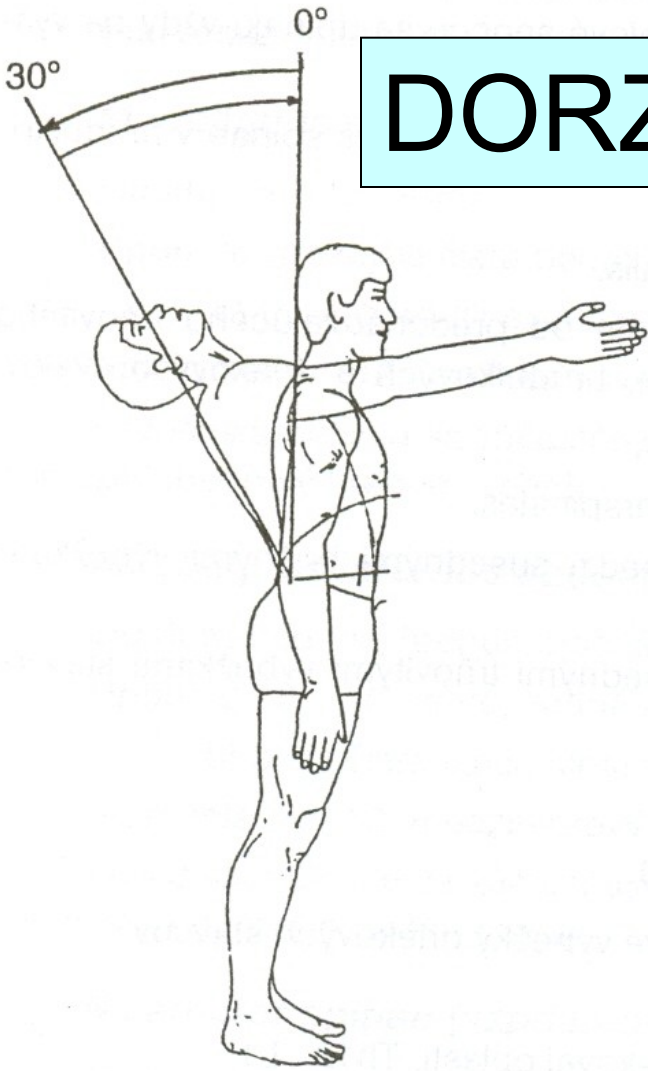
Tendinous inscription

Rectus abdominis m.

O, Crest of pubis

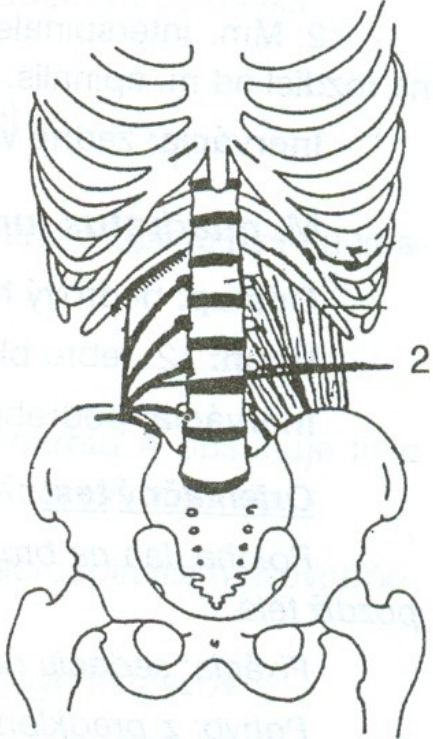


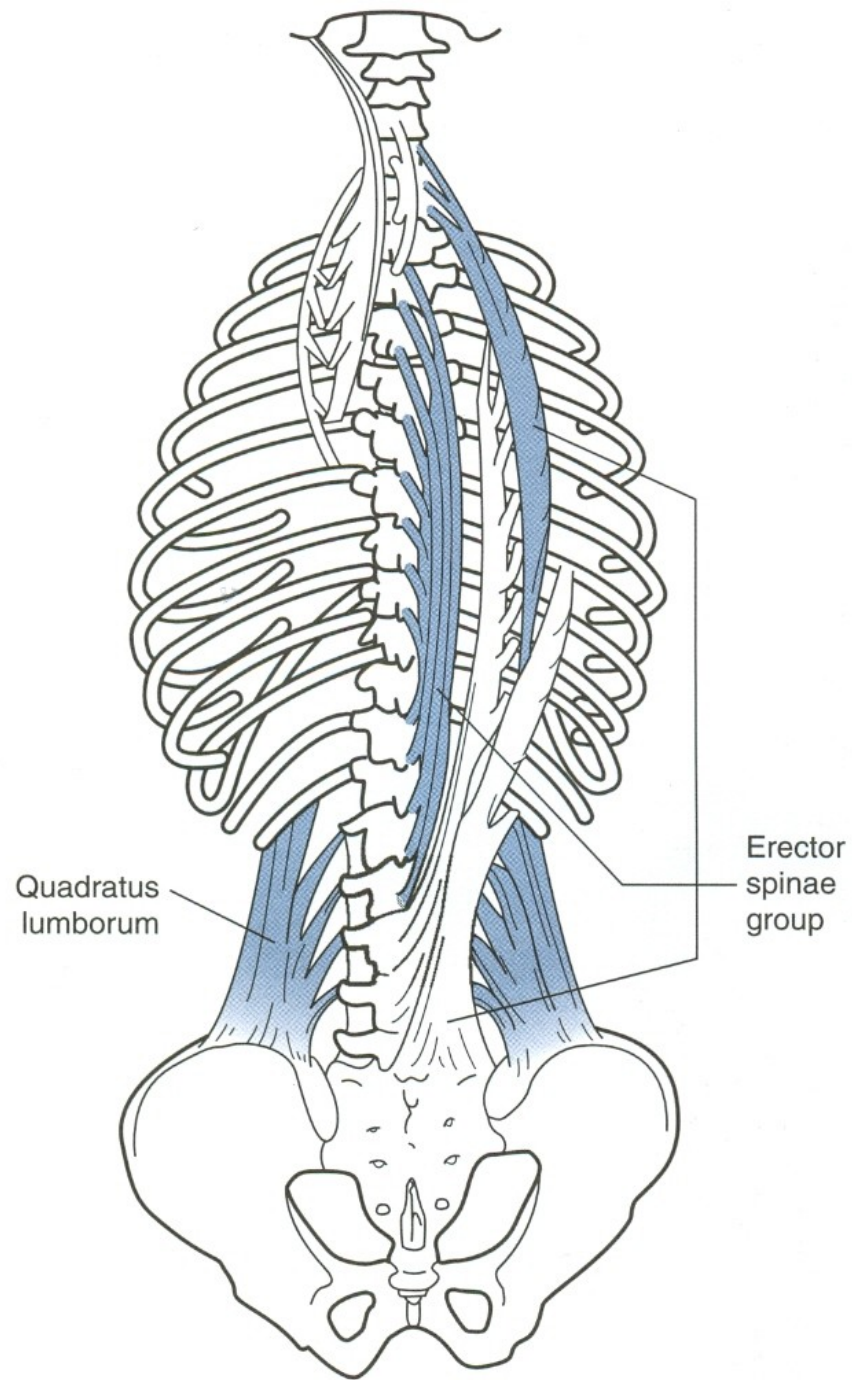
# DORZÁLNÍ FLEXE - ZÁKLON



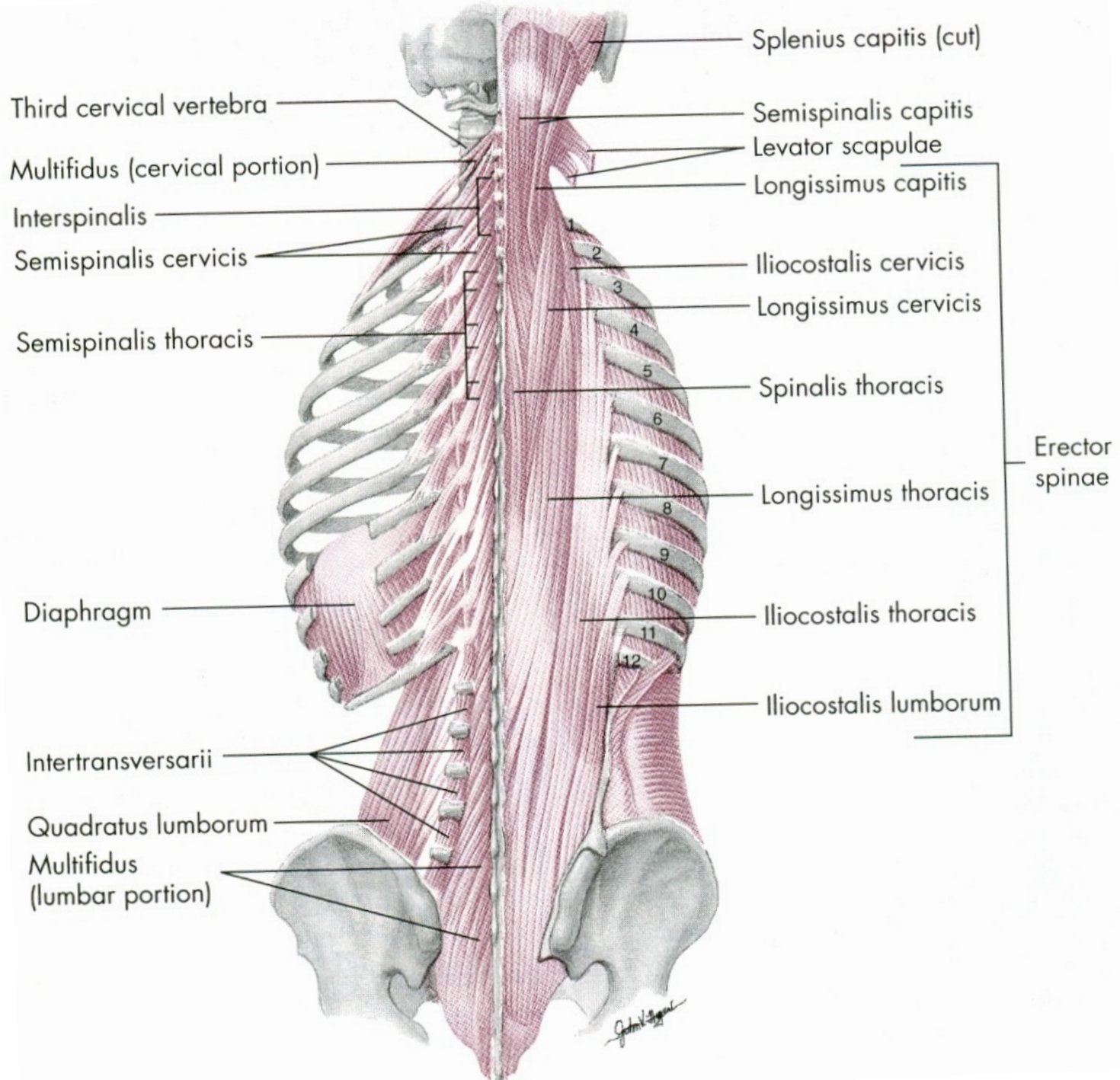
m. erector spinae

m. quadratus lumborum









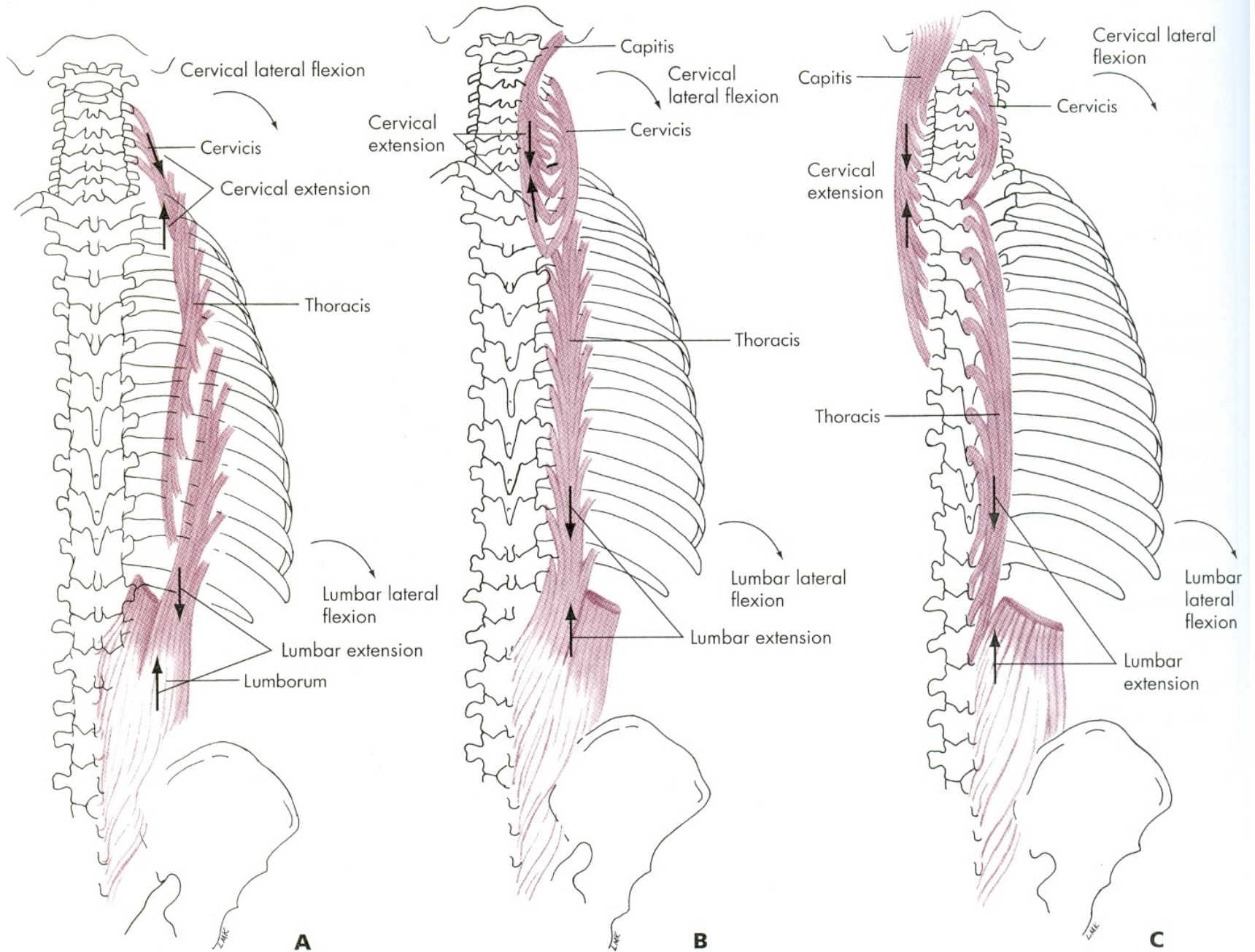


FIG. 12.15 • Erector spinae (sacrospinalis) muscle, posterior view. **A**, iliocostalis; **B**, longissimus; **C**, spinalis.



# VENTRÁLNÍ FLEXE

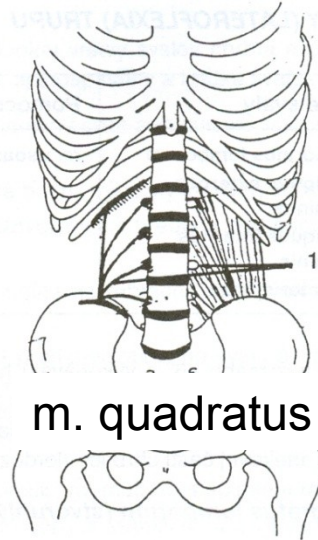
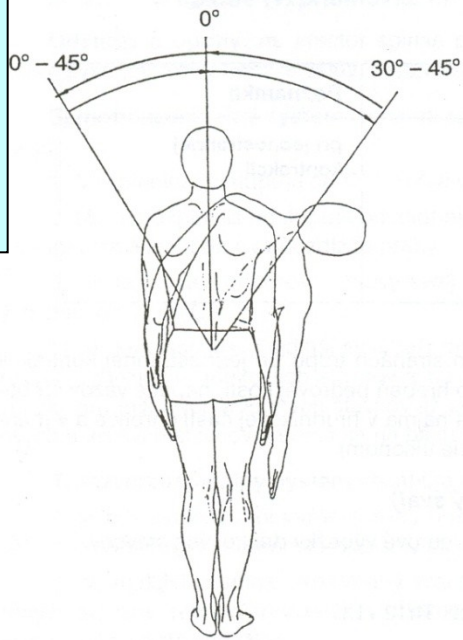
m. rectus abdominis – přímý sval břišní

# DORZÁLNÍ FLEXE

m. erector spinae – hluboké svaly zádové

m. quadratus lumborum –  
čtyřhranný sval bederní

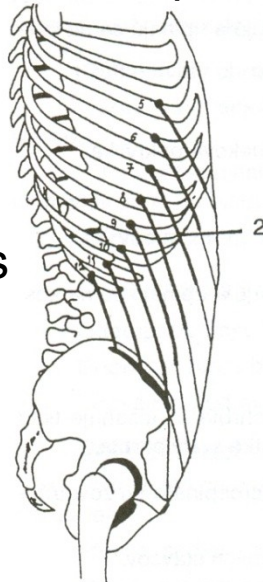
# LATEROFLEXE - ÚKLON



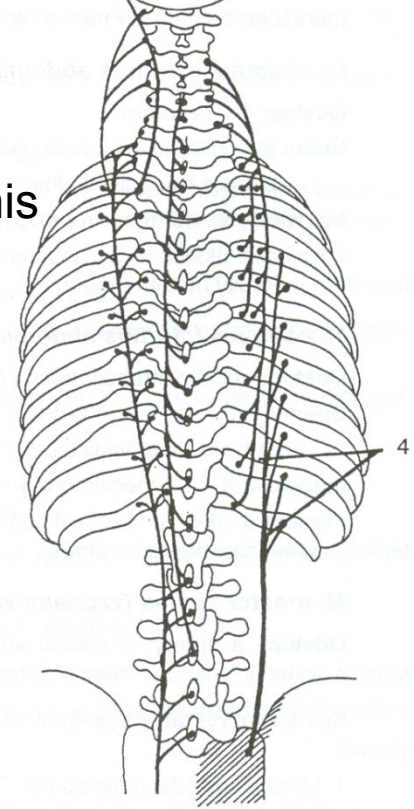
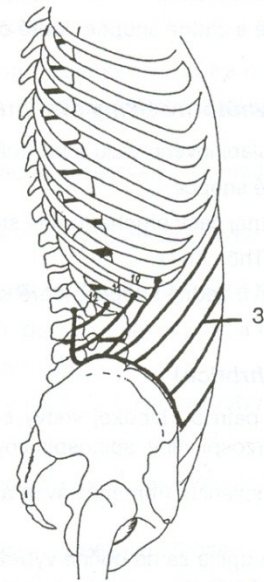
m. quadratus lumborum

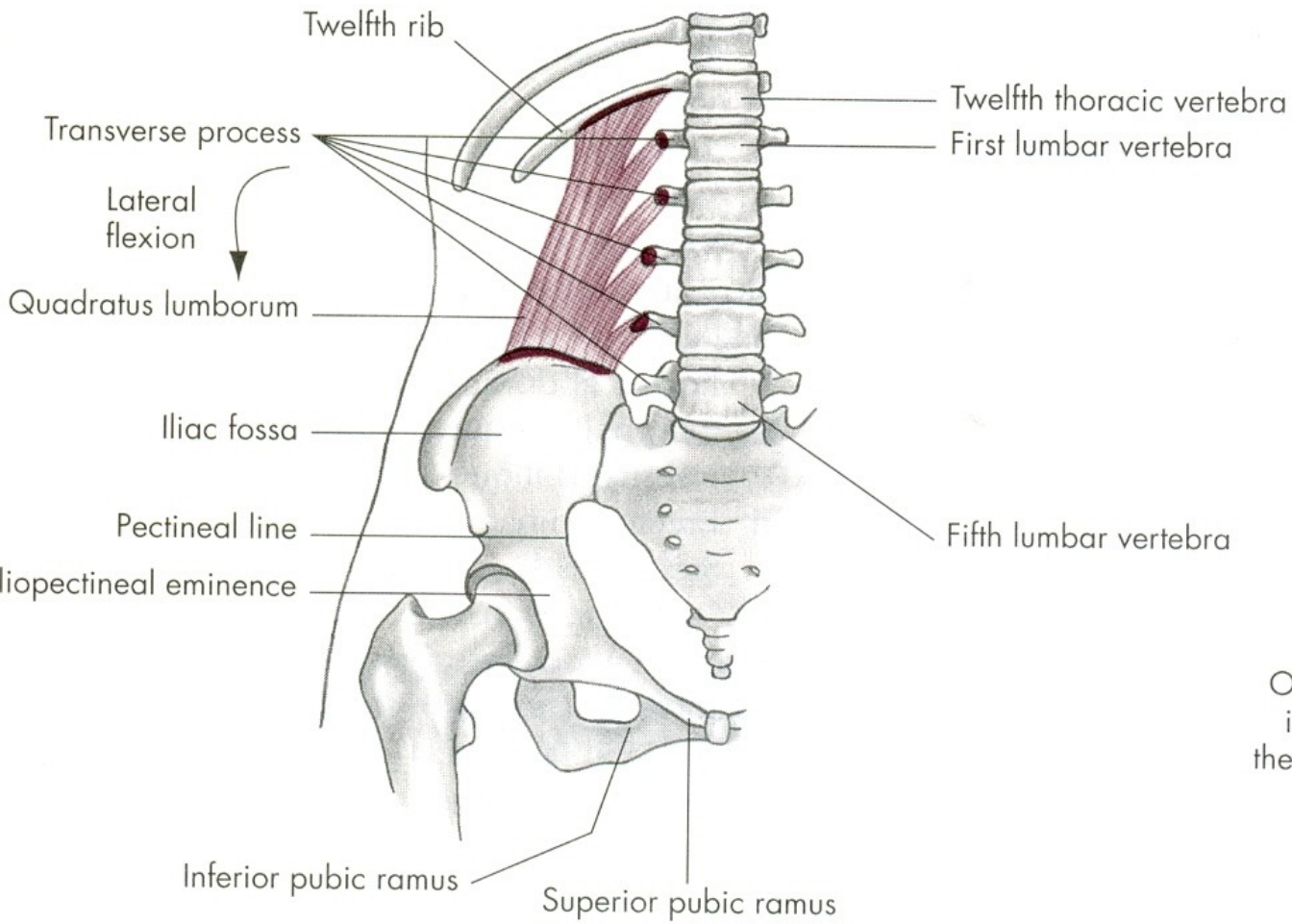
m. erector spinae

m. obliquus internus abdominis

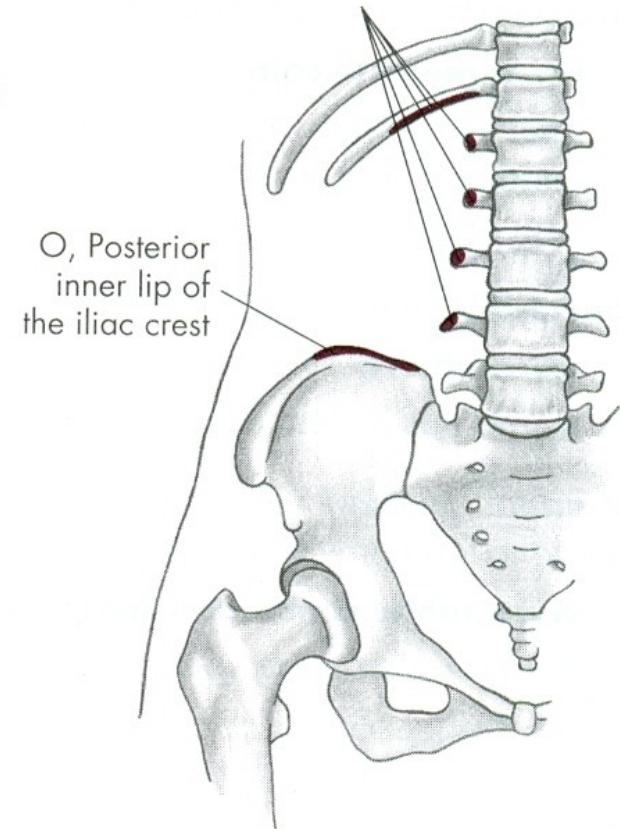


m. obliquus externus abdominis





I, Approximately one-half length of lower border of the twelfth rib and transverse process of the upper four lumbar vertebrae



# LATEROFLEXE

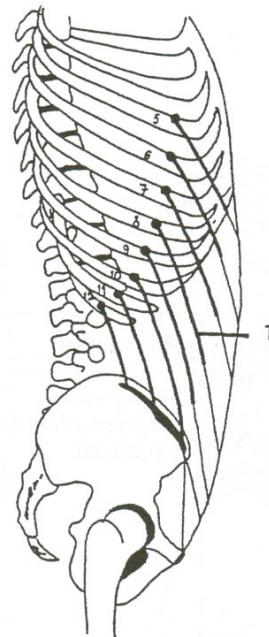
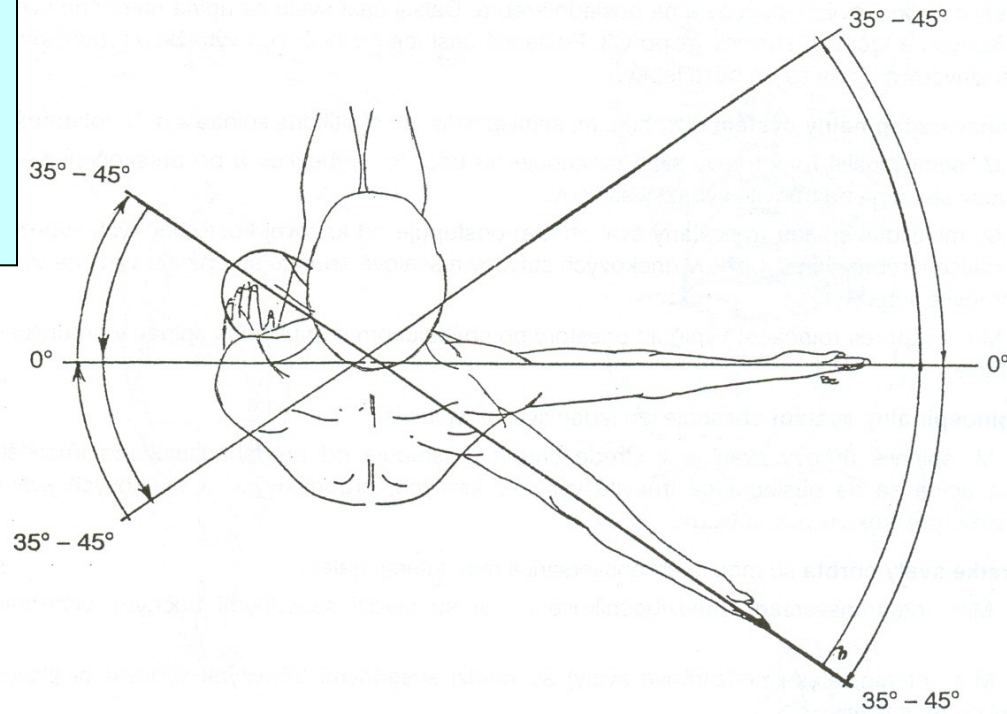
m. quadratus lumborum –  
čtyřhranný sval bederní

m. obliquus externus abdominis  
– vnější šikmý sval břišní

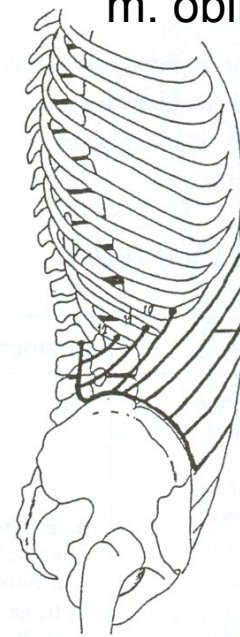
m. obliquus internus abdominis  
– vnitřní šikmý sval břišní

m. erector spinae – hluboké svaly zádové

# ROTACE - OTÁČENÍ

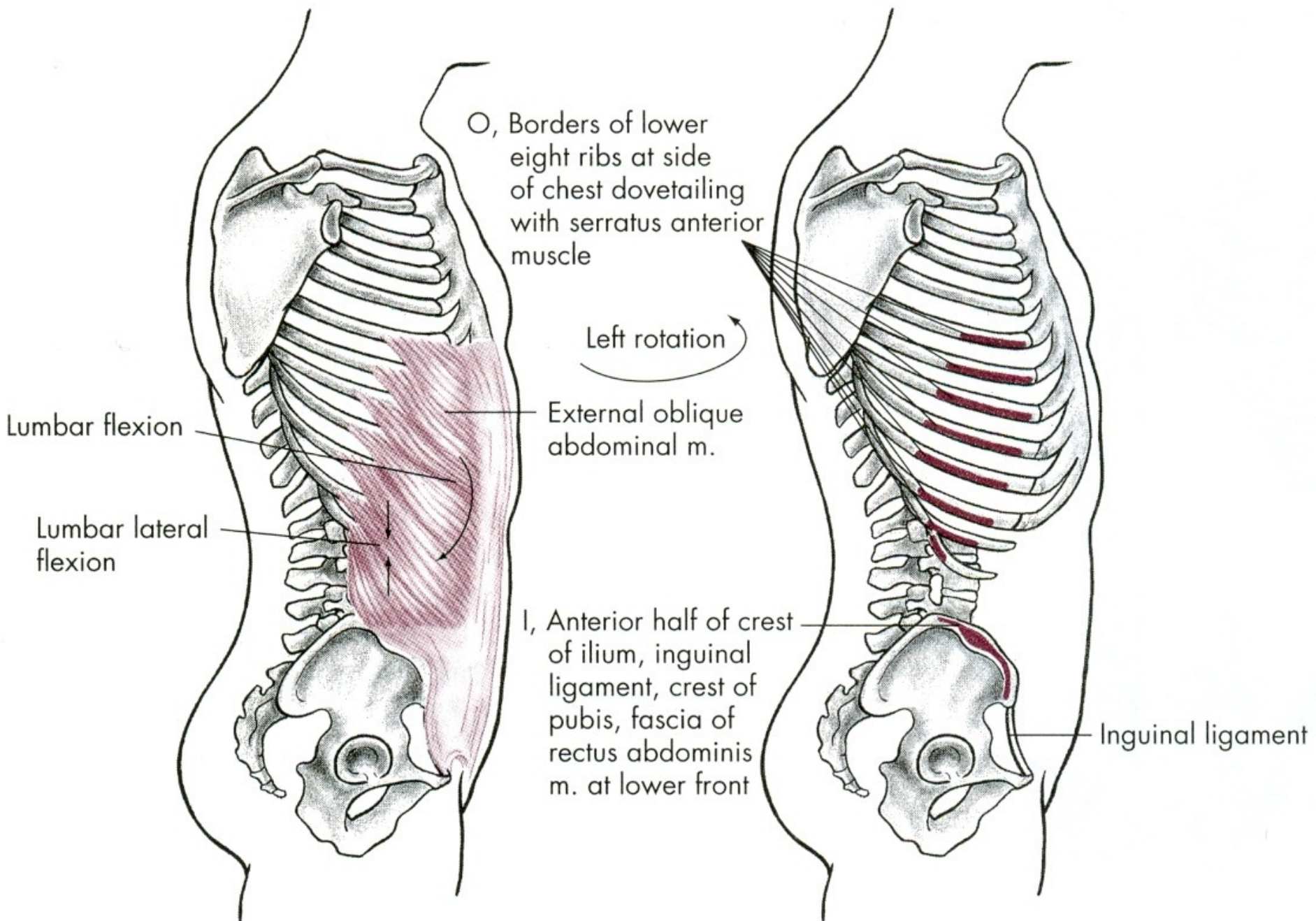


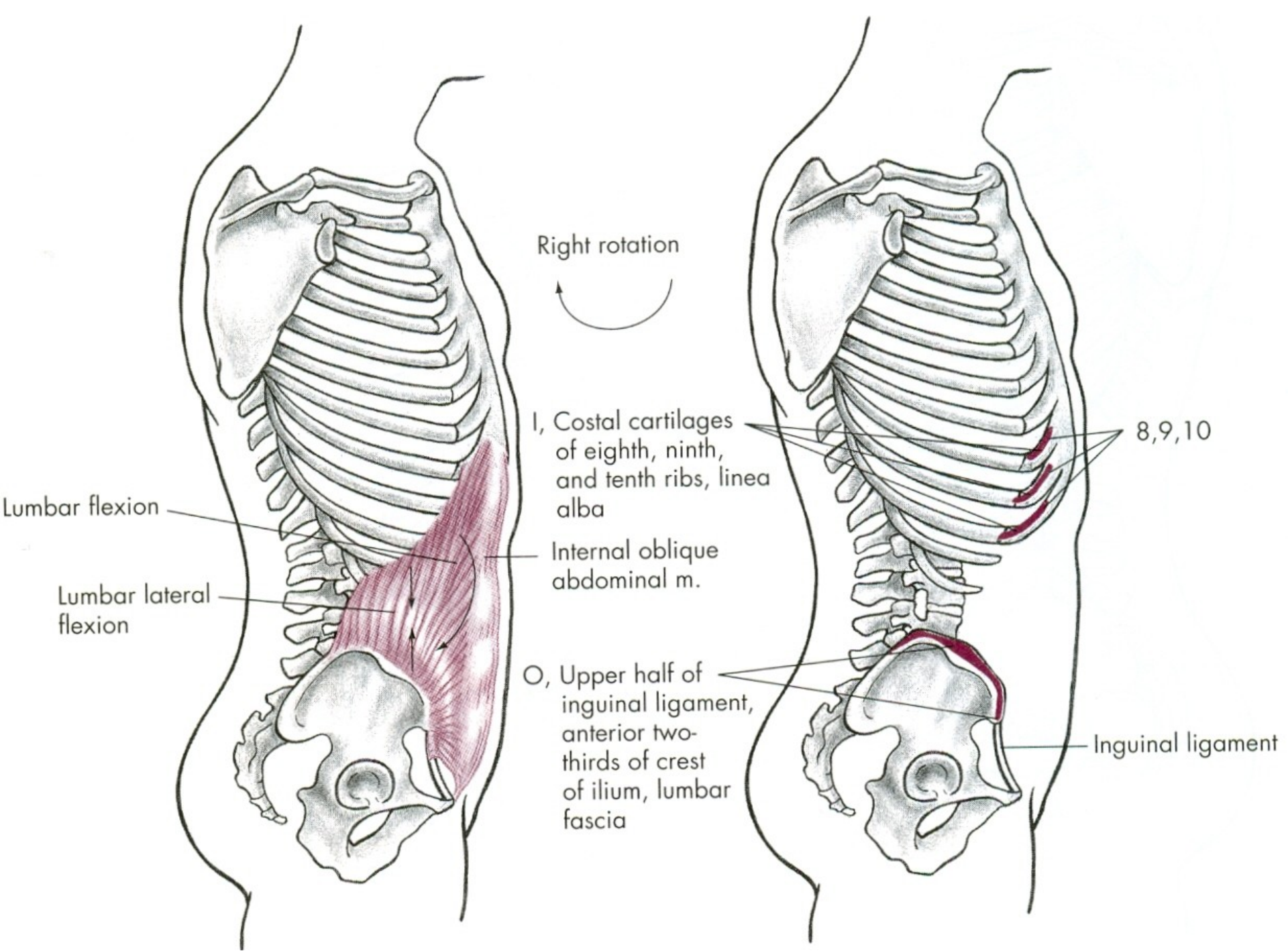
m. obliquus externus abdominis



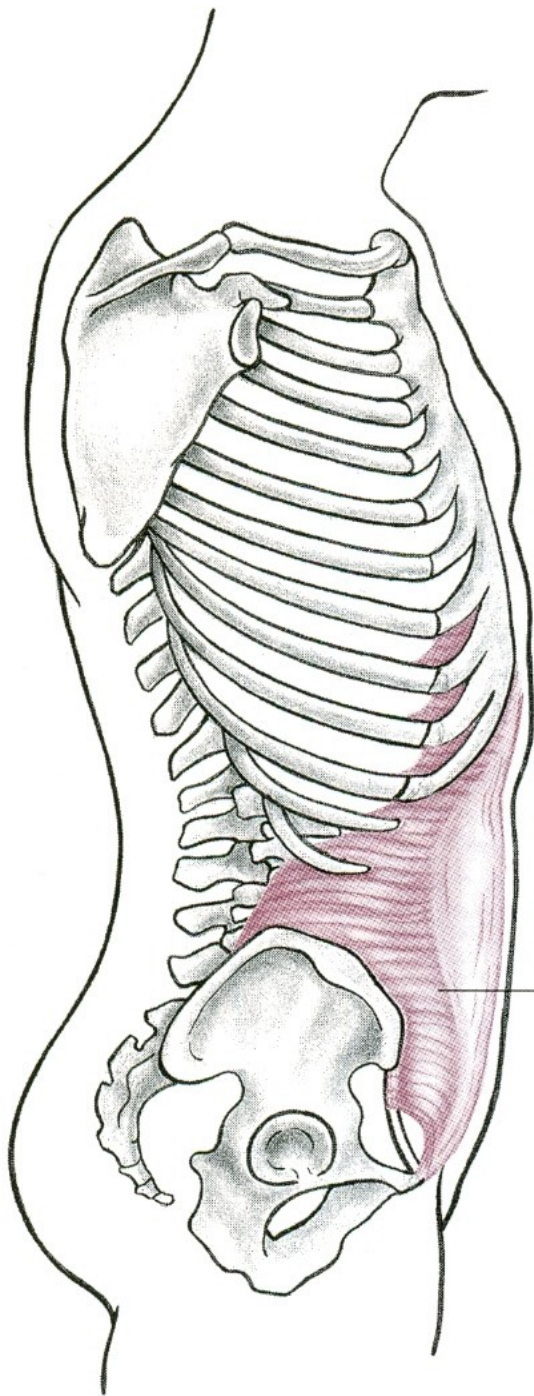
m. obliquus internus abdominis





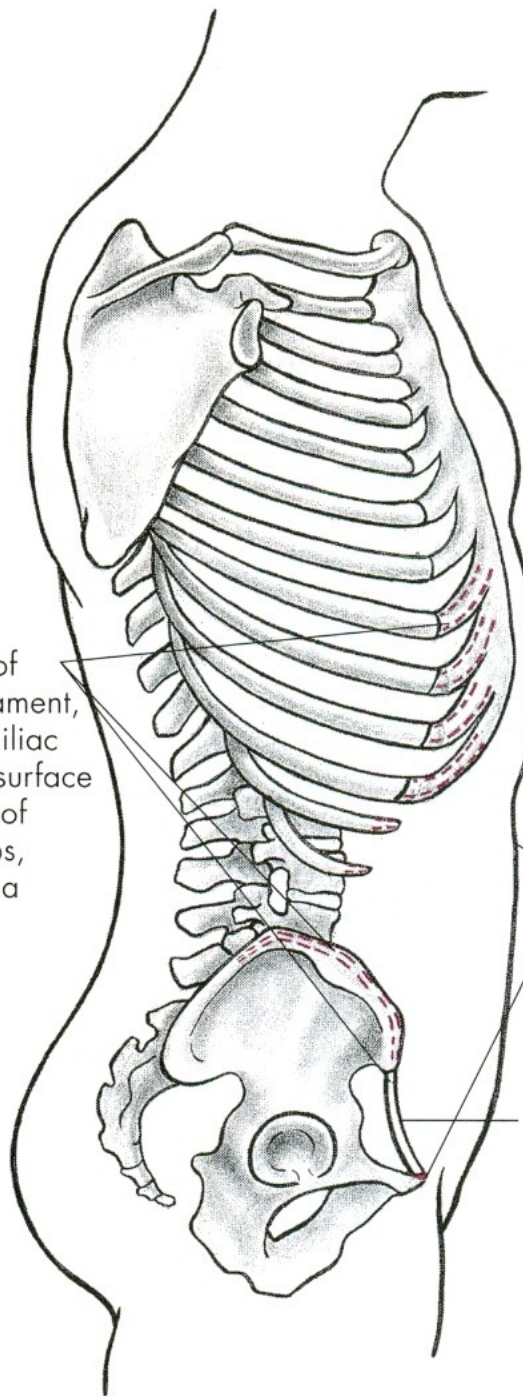






O, Outer third of inguinal ligament, inner rim of iliac crest, inner surface of cartilage of lower six ribs, lumbar fascia

Transversus abdominis m.



I, Crest of pubis, iliopectineal line, and linea alba joining its fellow from other side

Inguinal ligament



# ROTACE

m. obliquus externus abdominis  
– vnější šikmý sval břišní

m. obliquus internus abdominis  
– vnitřní šikmý sval břišní

# POHYBY PÁNVE

ELEVACE - ZDVIHNUTÍ

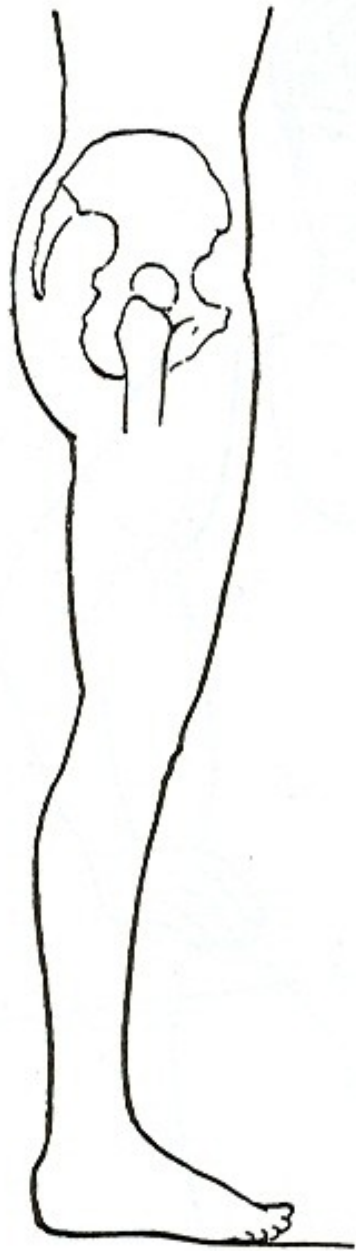
INKLINACE/ANTEVERZE  
- VYSAZENÍ

REKLINACE/RETROVERZE  
- PODSAZENÍ

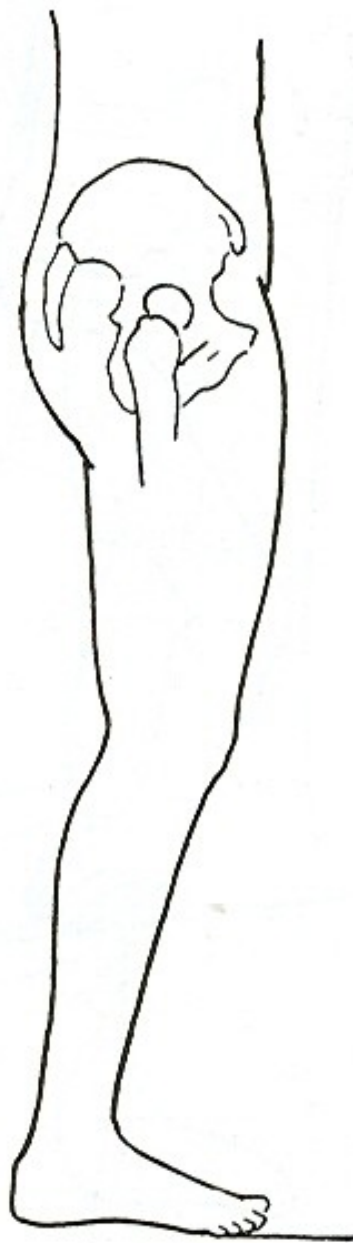
# ELEVACE

m. quadratus lumborum –  
čtyřhranný sval bederní

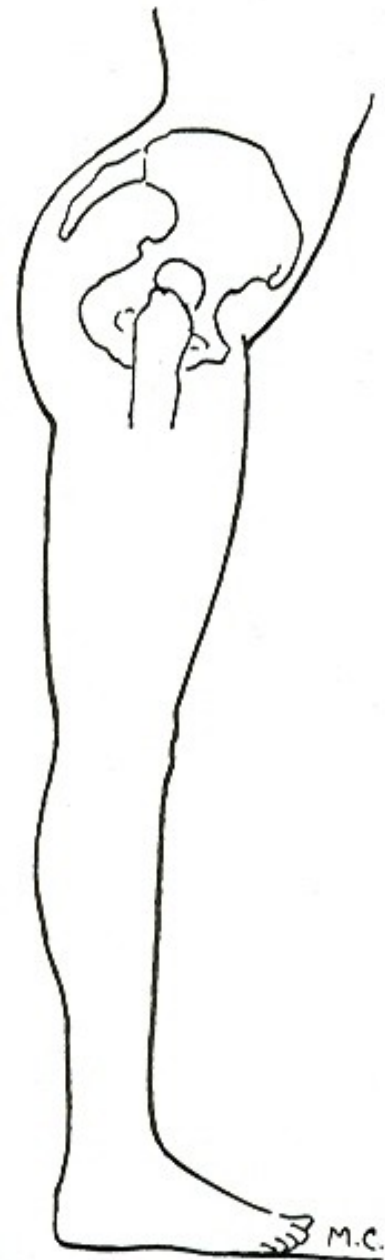




a.



**REKLINACE**



**INKLINACE**

# INKLINACE - ANTEVERZE

m.iliopsoas – sval bedrokyčlostehenní

m.glutaeus minimus – malý sval hýžd'ový

m.sartorius – sval krejčovský

m.tensor fasciae latae –  
napínač stehenní povázky

# REKLINACE - RETROVERZE

m.semitendinosus – sval pološlašitý

m.semimembranosus – sval poloblanitý

m.glutaeus maximus – velký sval hýžd'ový

m.biceps femoris – dvojhlavý sval stehenní



# POHYBY LOPATKY

ELEVACE - ZDVIHNUTÍ

DEPRESE - POKLES

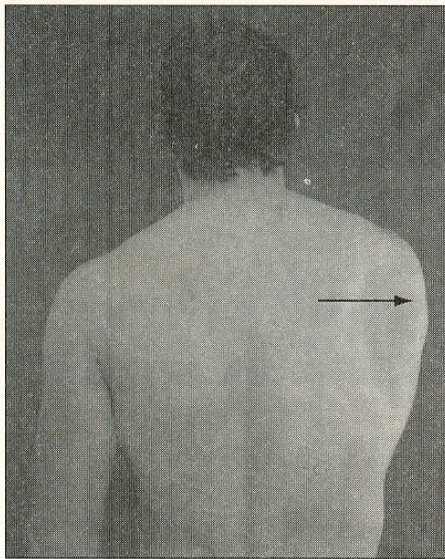
PROTRAKCE - ODTAŽENÍ

RETRAKCE - PŘITAŽENÍ

ANTEVERZE – ZEVNÍ ROTACE

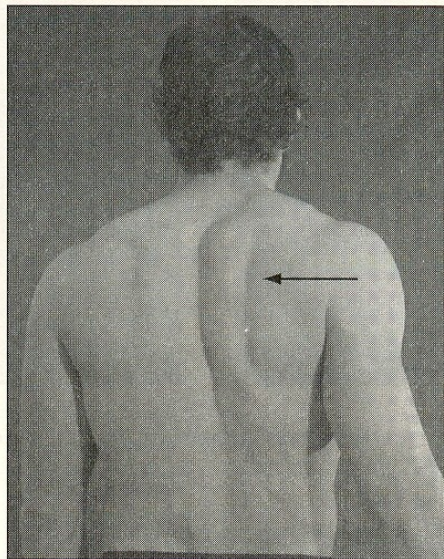
RETROVERZE – VNITŘNÍ ROTACE





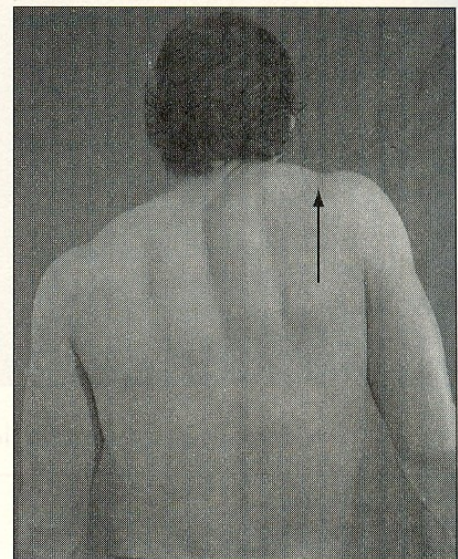
**Abduction**  
(protraction)

**A**



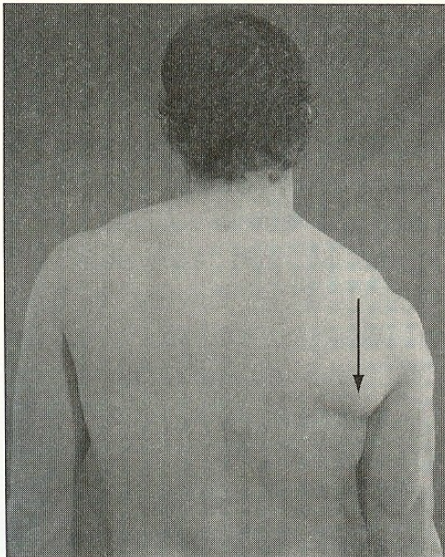
**Adduction**  
(retraction)

**B**

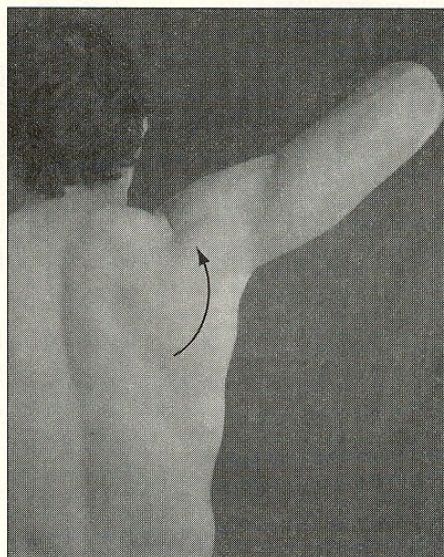


**Elevation**

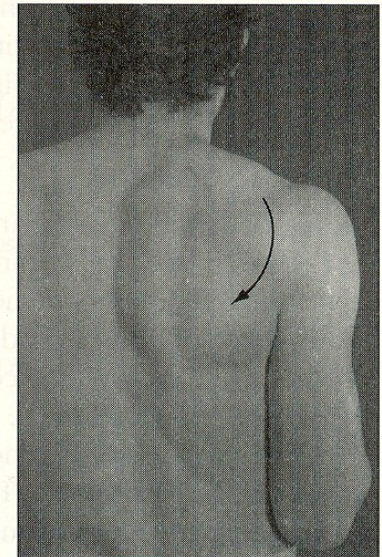
**C**



**Depression**

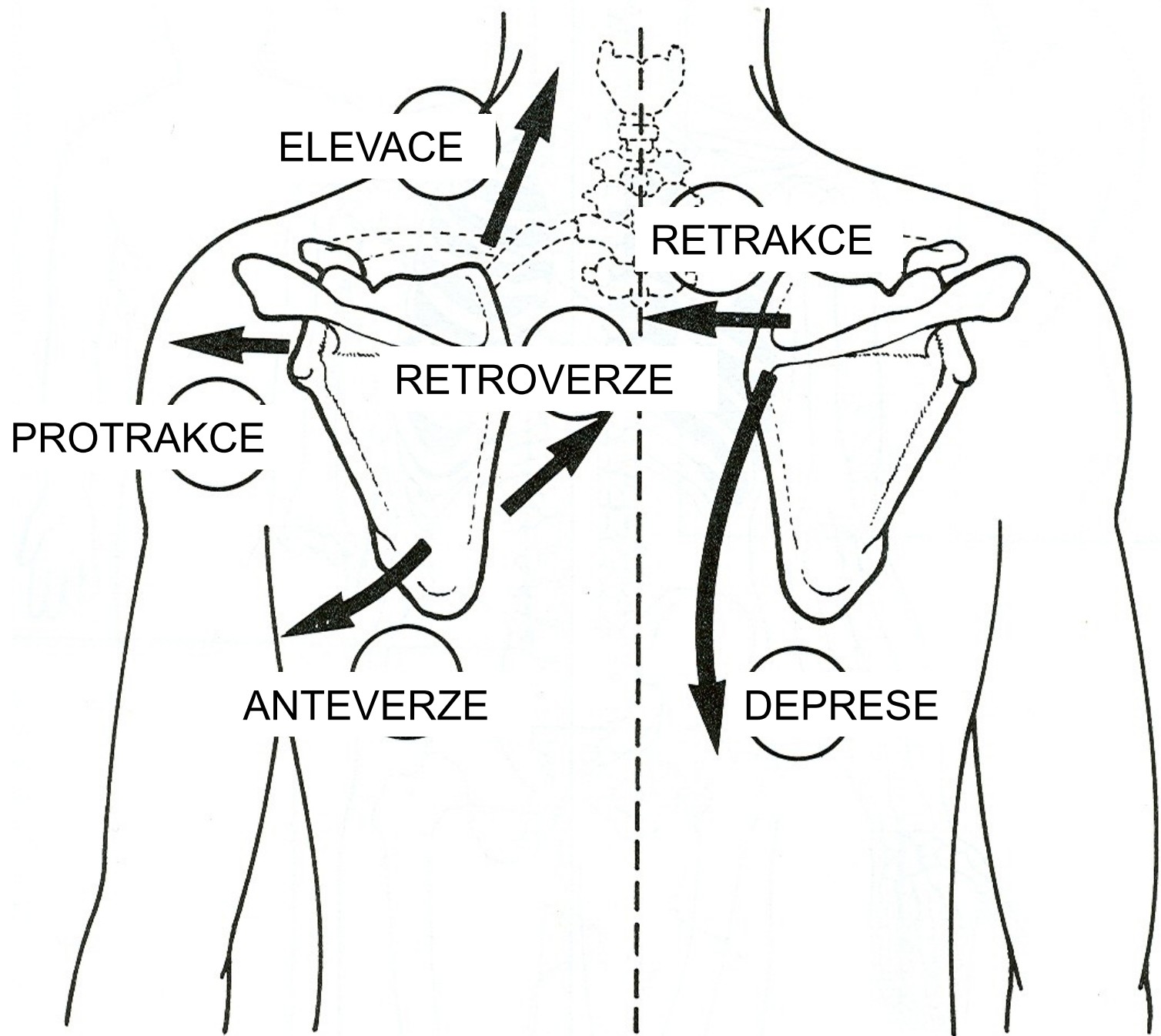


**Upward rotation**



**Downward rotation**

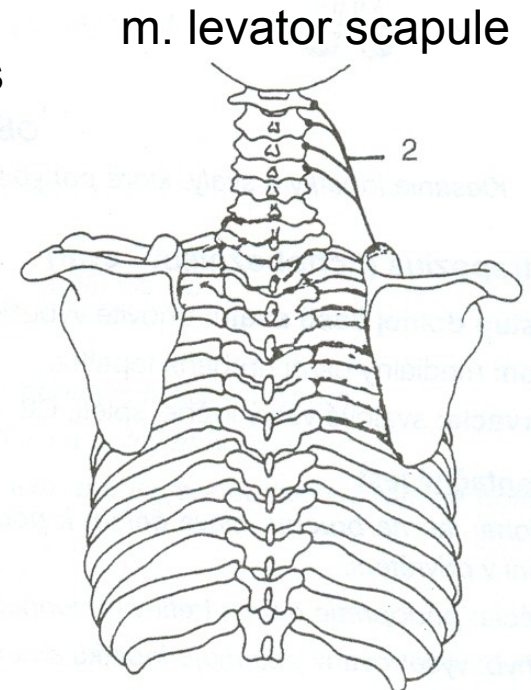
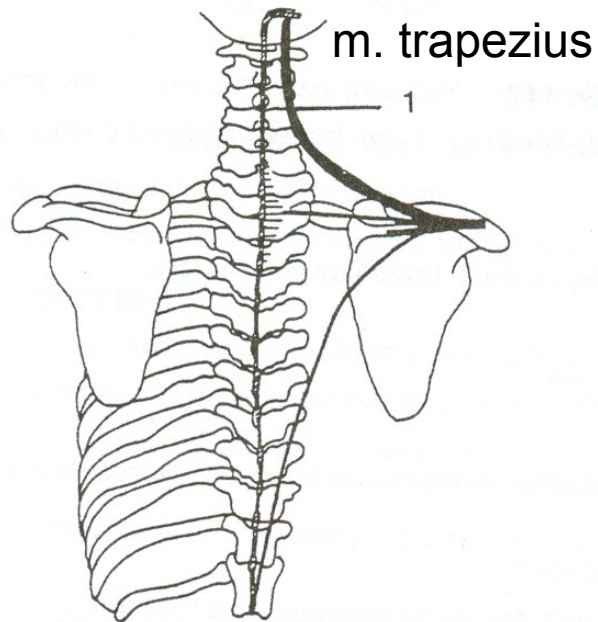
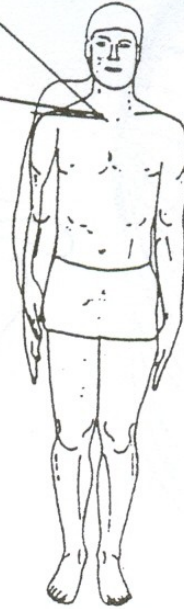



# ELEVACE - ZDVIHNUTÍ

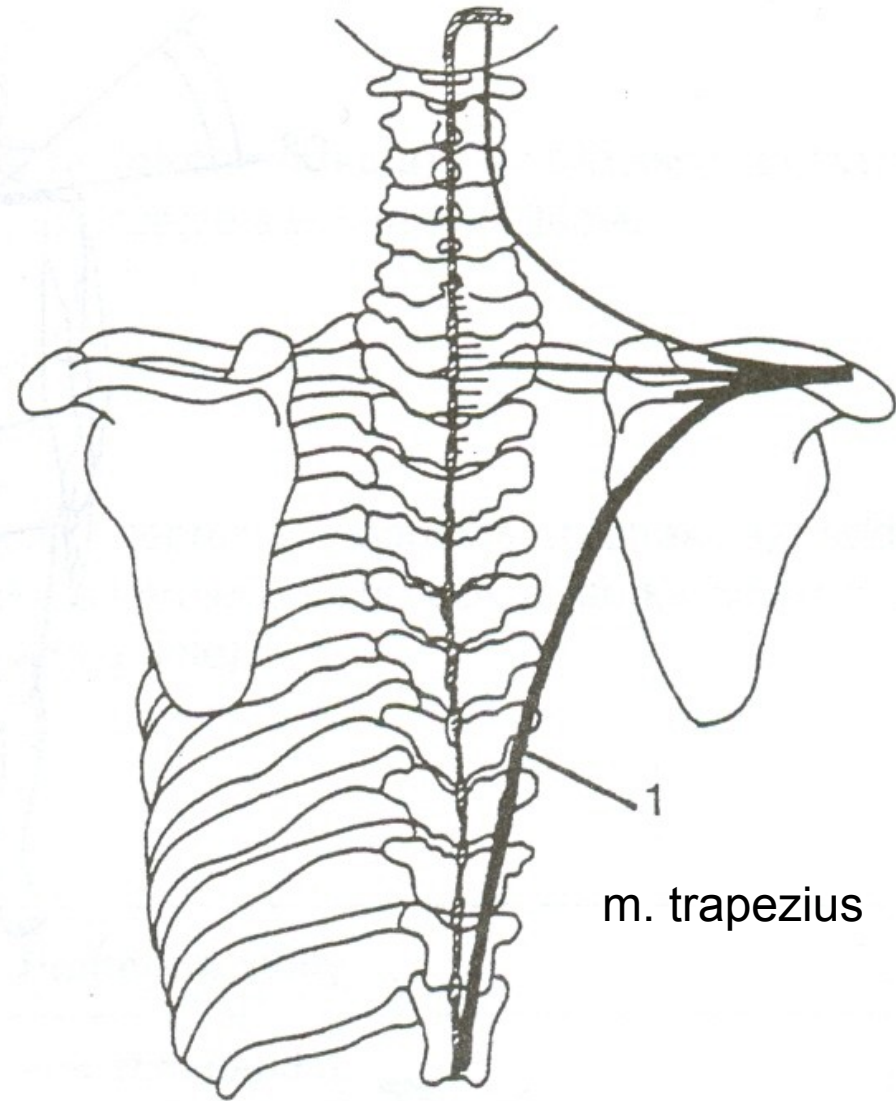
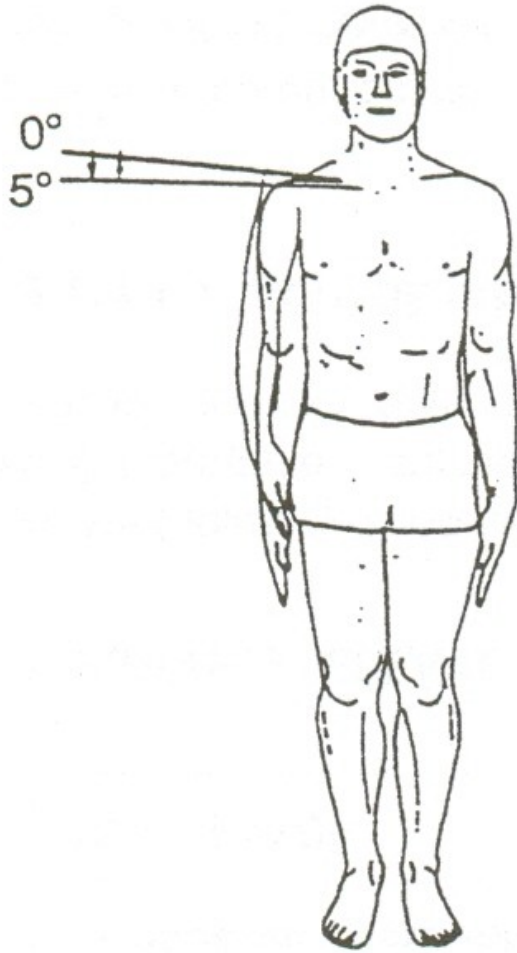
35° - 40°

0°





# DEPRESE - POKLES



# ELEVACE LOPATKY

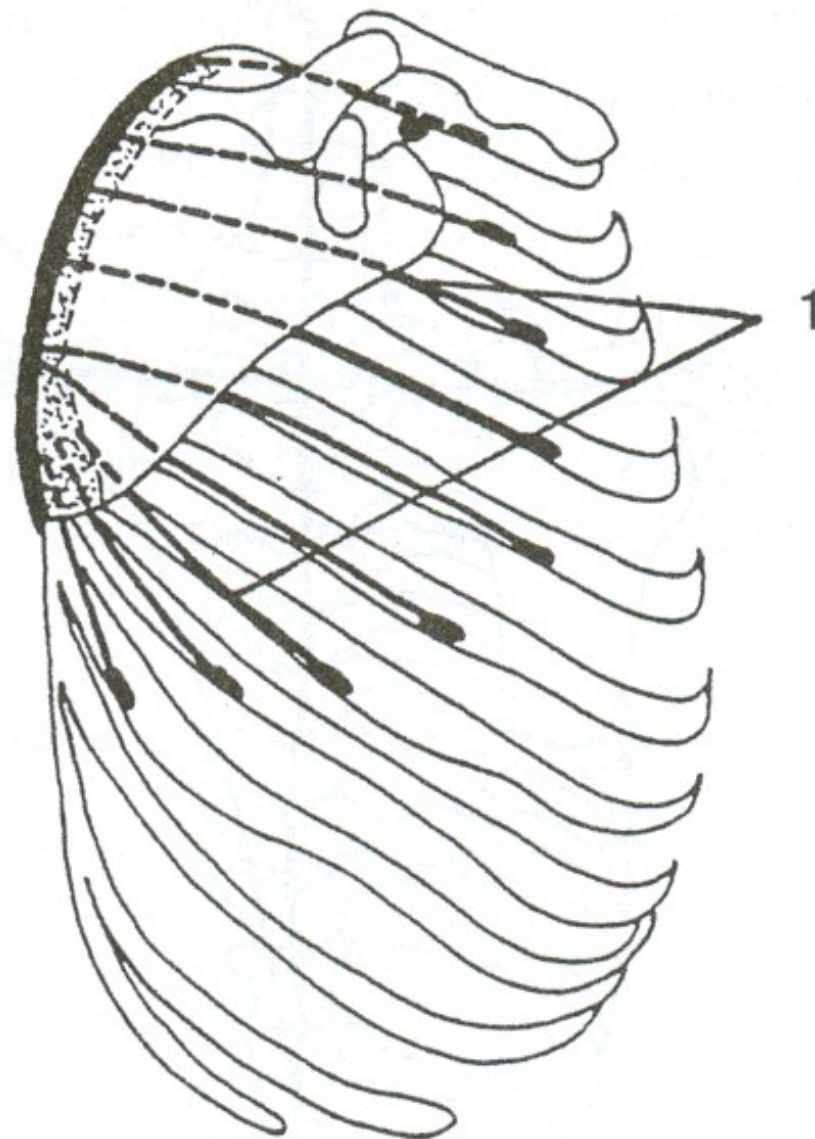
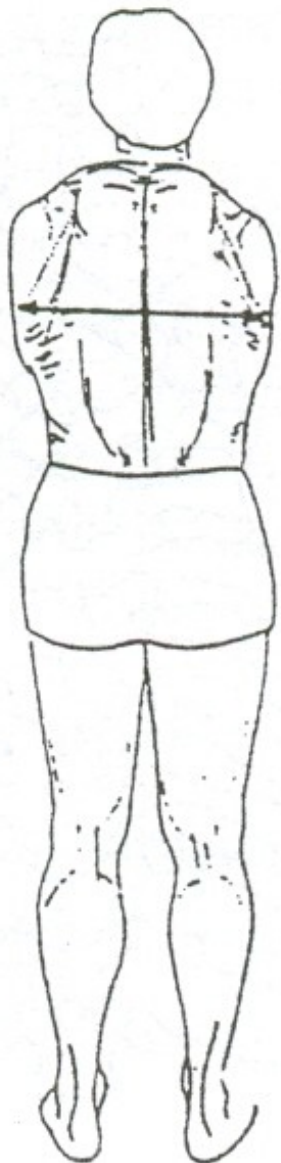
m.trapezius-pars superior –  
sval trapezový-vrchní část

m.levator scapule – zdvihač lopatky

# DEPRESE LOPATKY

m.trapezius-pars inferior –  
sval trapezový-spodní část

# PROTRAKCE - ODTAŽENÍ

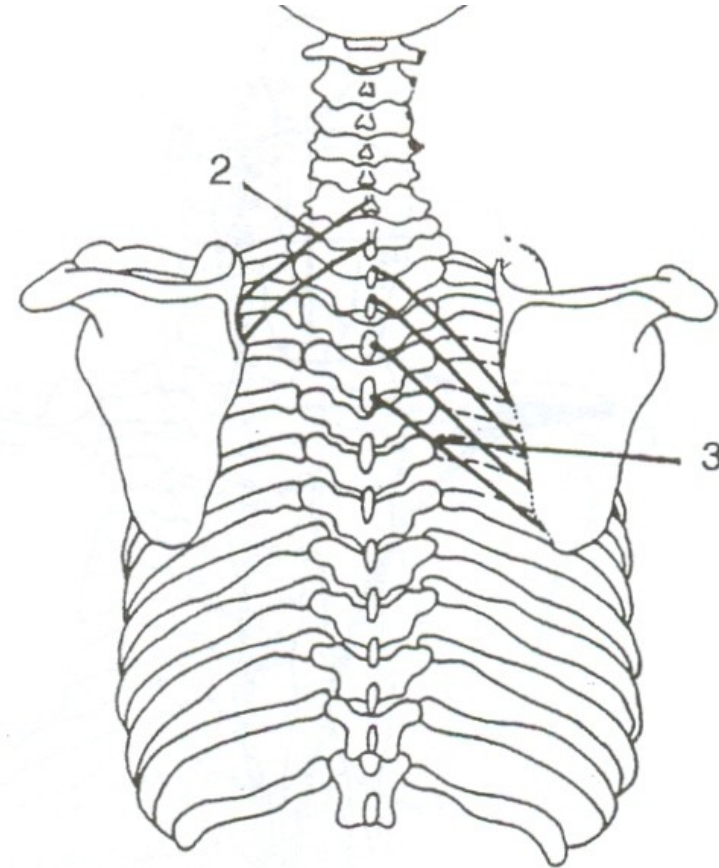
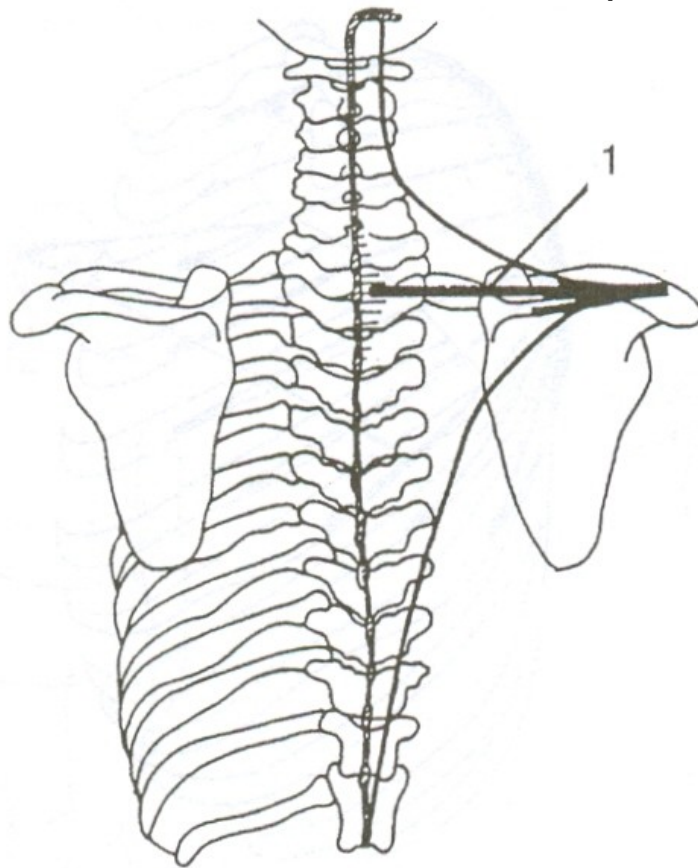


m. serratus anterior

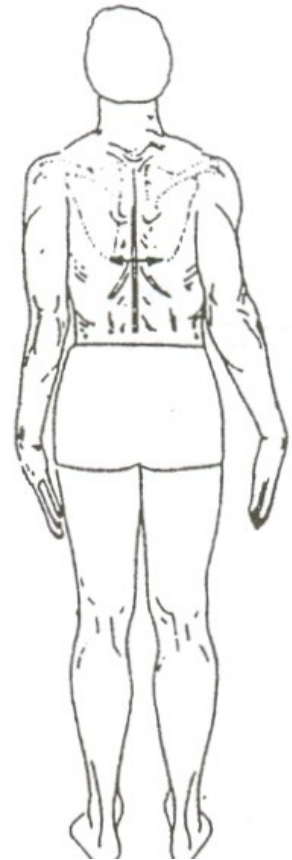# RETRAKCE - PŘITAŽENÍ

m. trapezius

m. rhomboideus minor



m. rhomboideus major





# PROTRAKCE LOPATKY

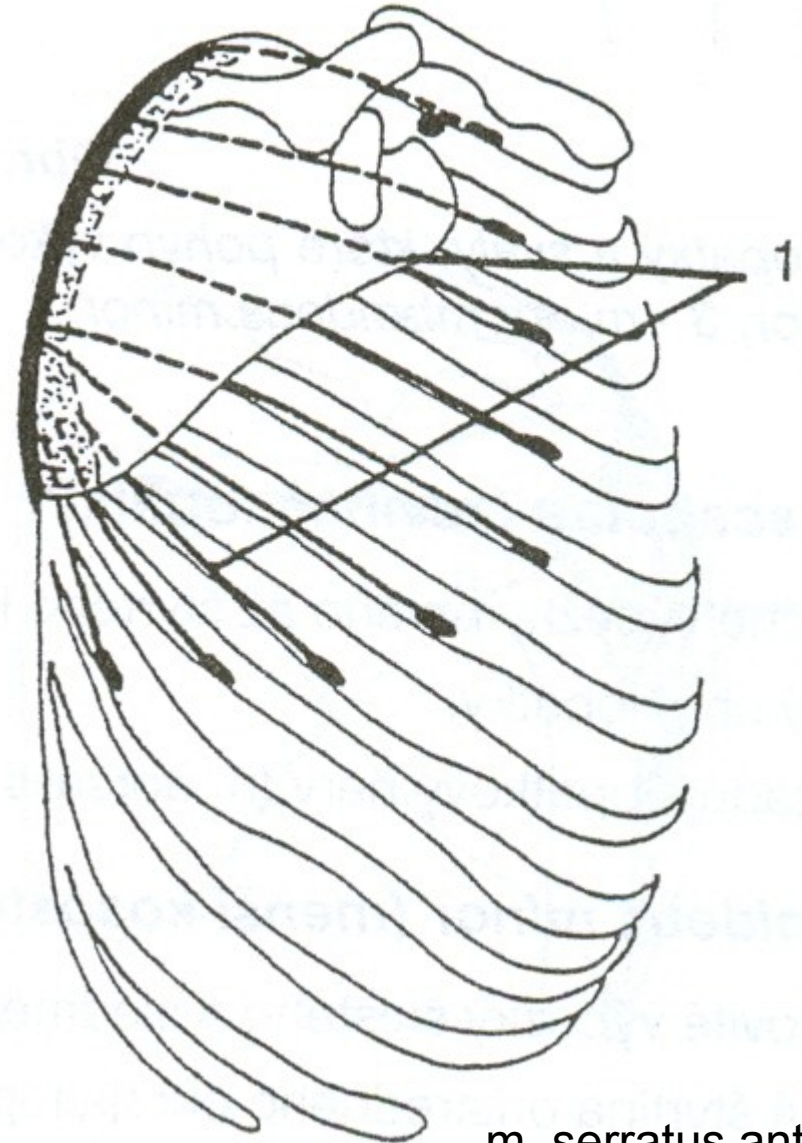
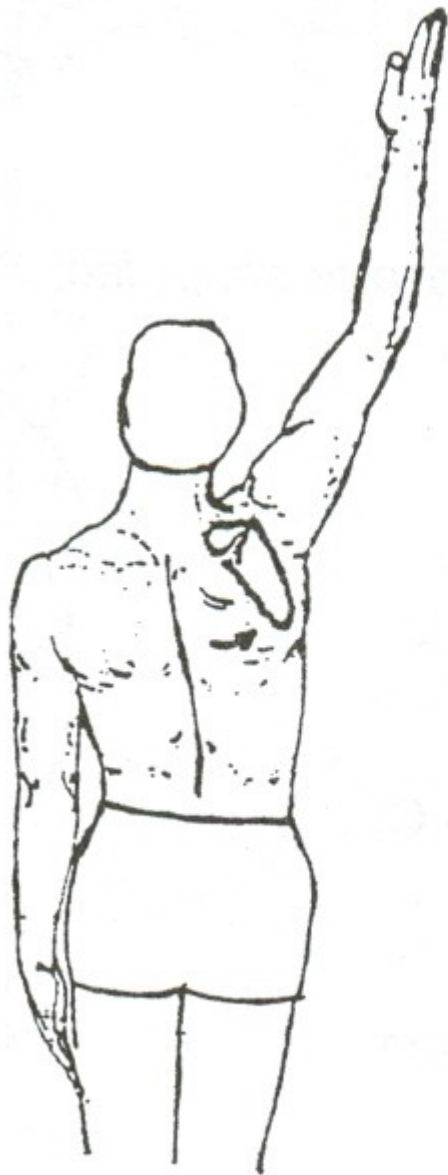
m.serratus anterior – přední sval pilovitý

# RETRAKCE LOPATKY

m. trapezius – sval trapézová-střední část

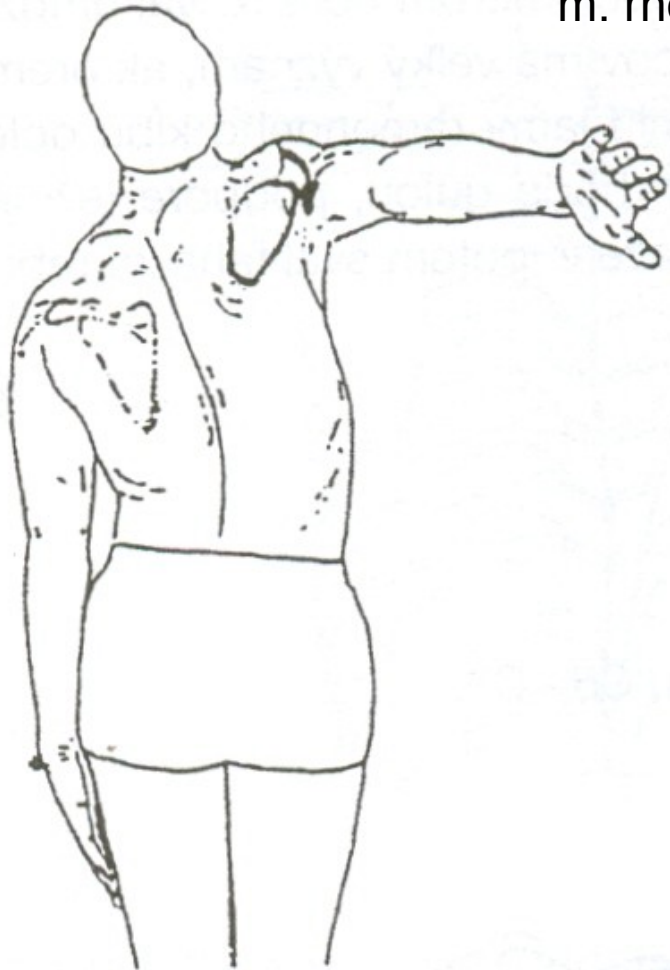
mm. rhomboidei – svaly rombické

# ANTEVERZE – ZEVNÍ ROTACE

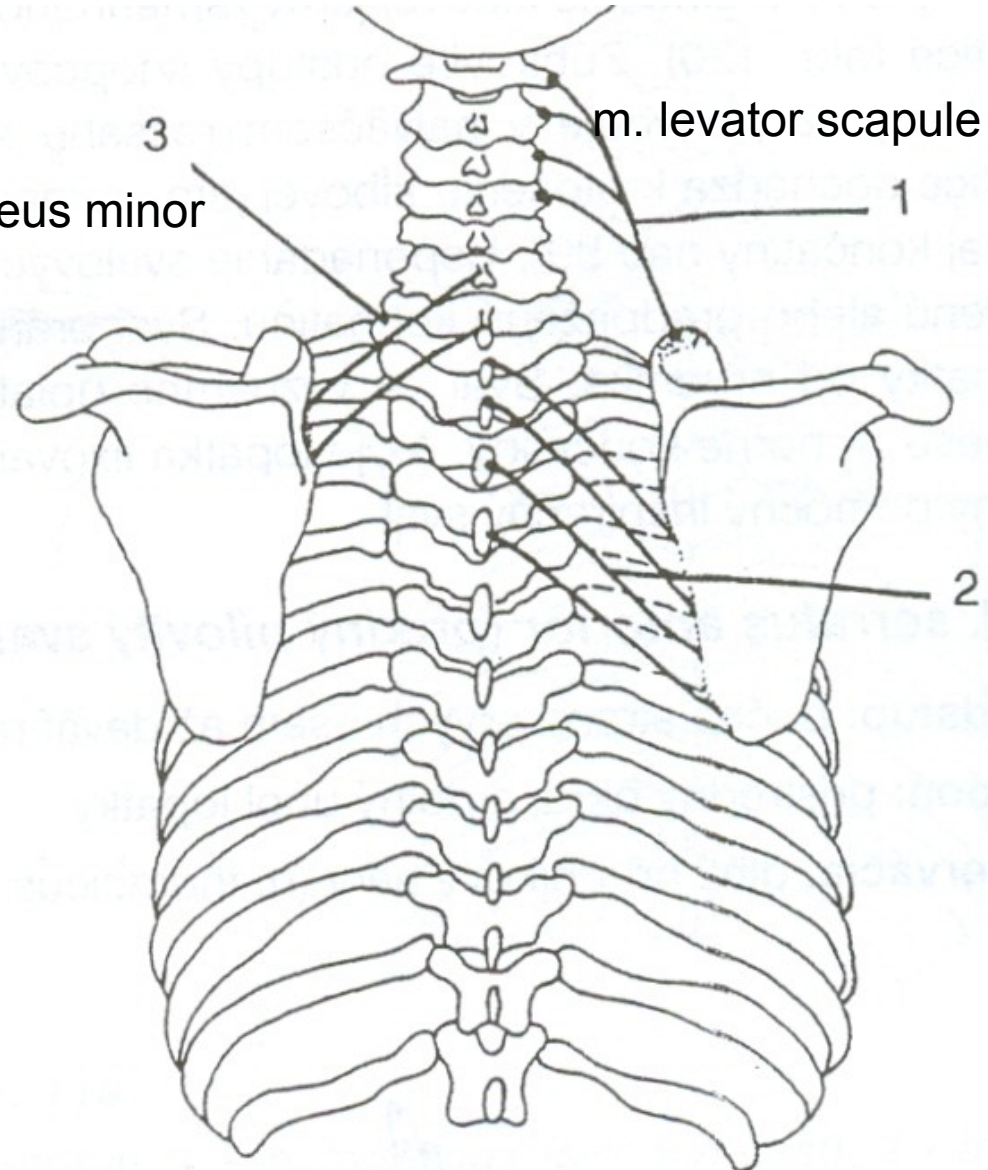


m. serratus anterior

# RETROVERZE – VNITŘNÍ ROTACE



m. rhomboideus minor



m. levator scapulae

1

2

m. rhomboideus major

# ANTEVERZE LOPATKY

m. serratus anterior – přední sval pilovitý

# RETROVERZE LOPATKY

m. levator scapulae – zdvihač lopatky

mm. rhomboidei – svaly rombické



Rhomboids  
Trapezius  
Levator scapulae

Rhomboids  
Trapezius  
Levator scapulae

Serratus  
Anterior  
Pectoralis  
minor

Trapezius  
Pectoralis minor

Trapezius  
Serratus anterior  
Rhomboids  
Pectoralis minor  
Levator scapulae

