

POHYBY HLAVY A TRUPU



POHYBY PÁNVE A LOPATEK

	Neck	Trunk
Anterior	Sternocleidomastoid Scalenes (3) Prevertebral group (4)	Rectus abdominis External oblique Internal oblique Transverse abdominis
Posterior	Erector spinae group (3) Splenius capitis Splenius cervicis Suboccipital group (4)	Erector spinae group (3) Transversospinalis group (3) Interspinales Intertransversarii
Lateral		Quadratus lumborum

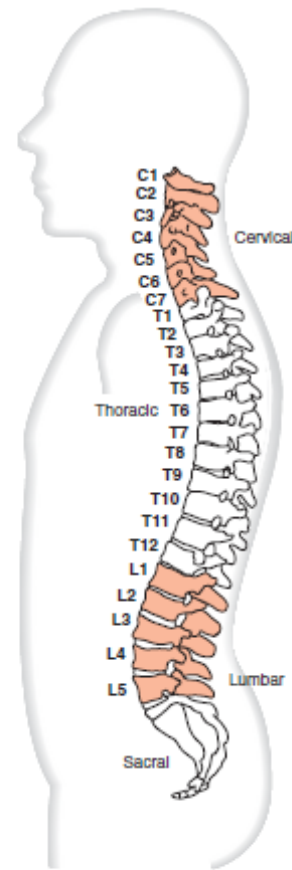


Figure 15-1. The anterior-posterior curves of the vertebral column (lateral view).

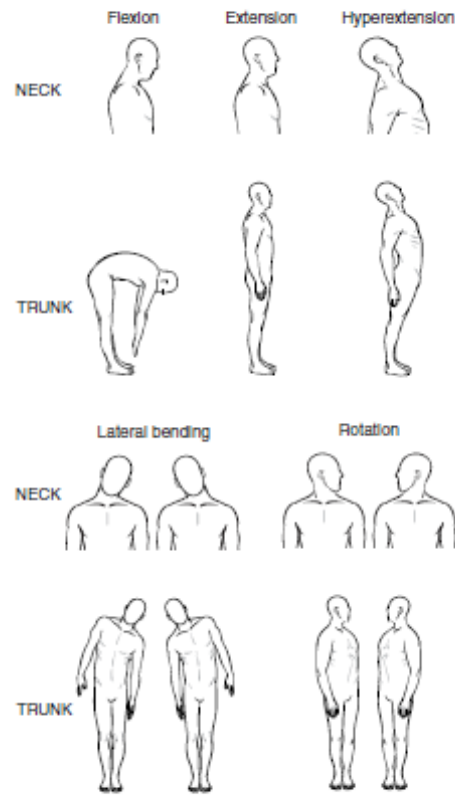


Figure 15-2. Motions of the neck and trunk.

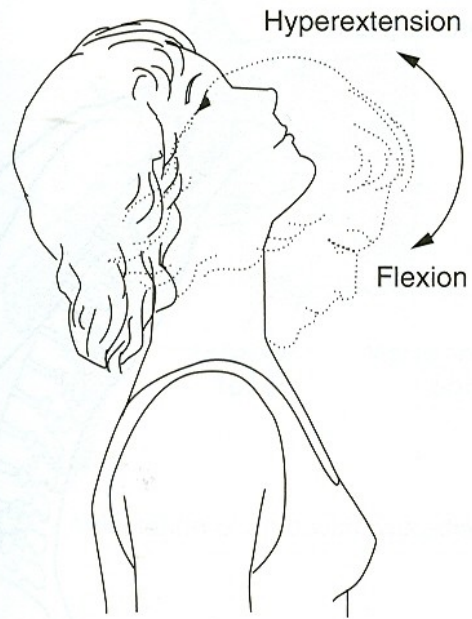
POHYBY HLAVY A KRKU

FLEXE - PŘEDKLON

EXTENZE - ZÁKLON

LATEROFLEXE - ÚKLON

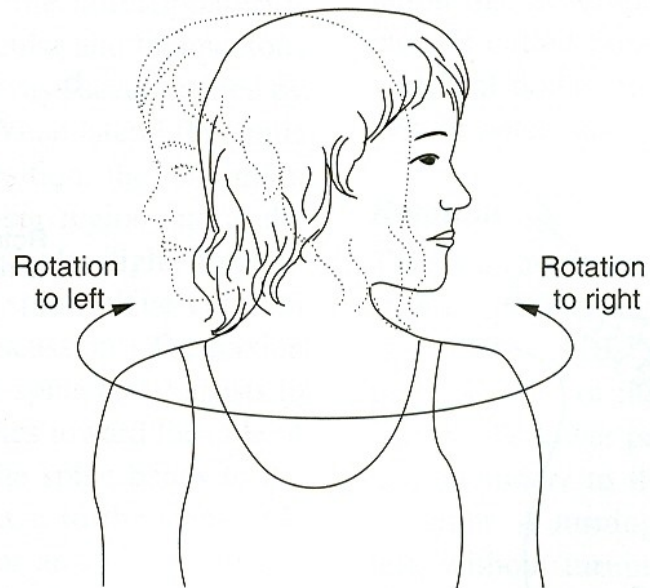
ROTACE - OTÁČENÍ



a.



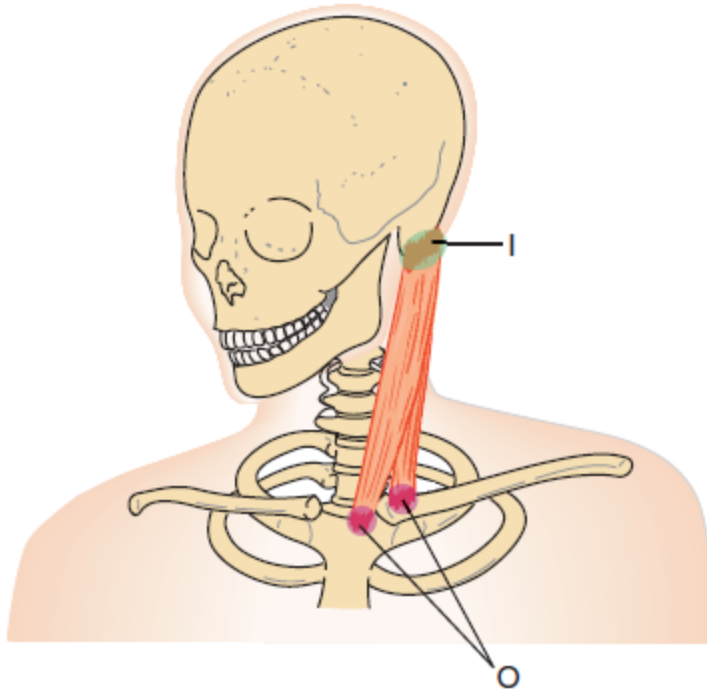
b.



c.

Pohyby hlavy a krku: Přední skupina

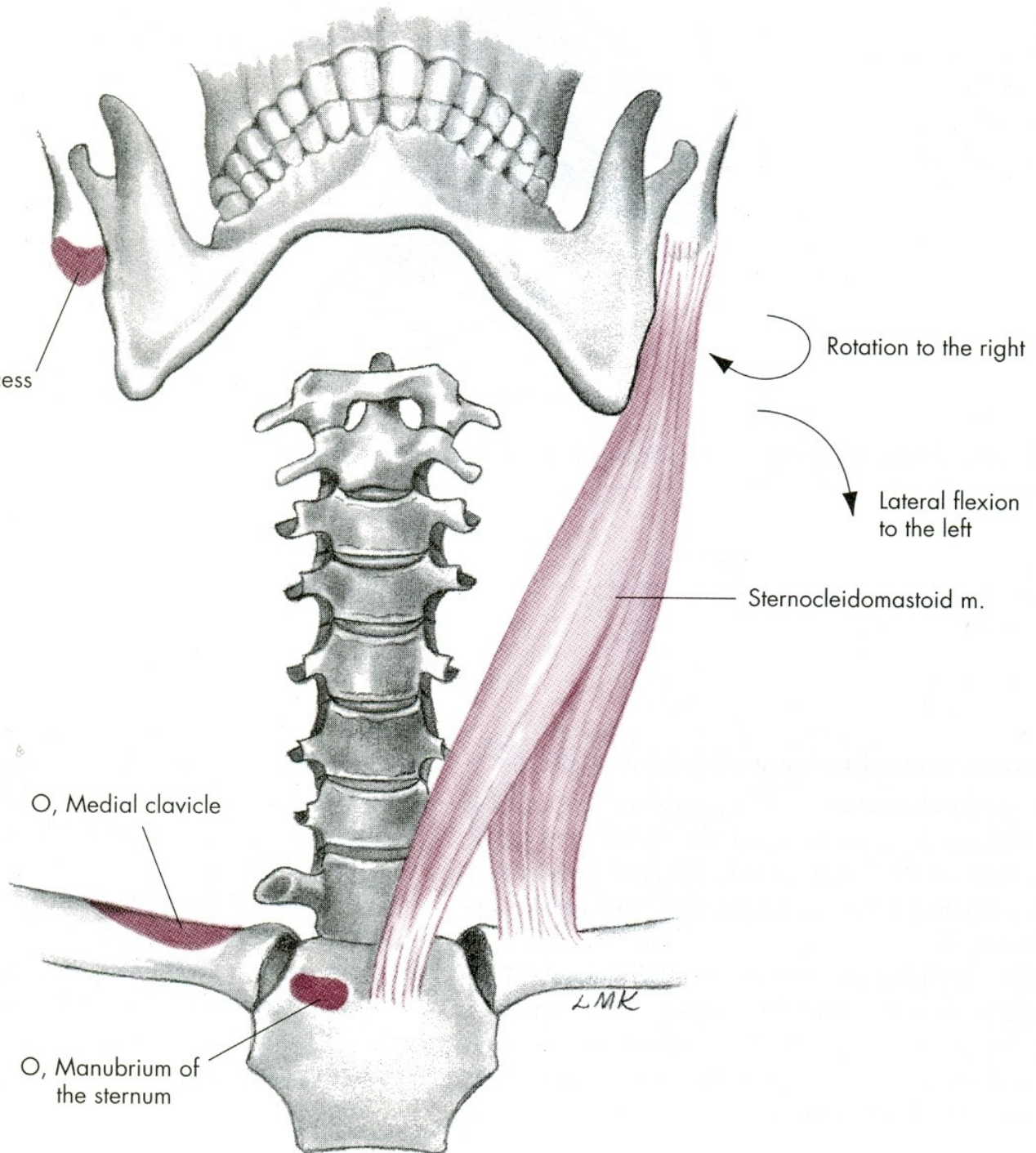
sternocleidomastoid

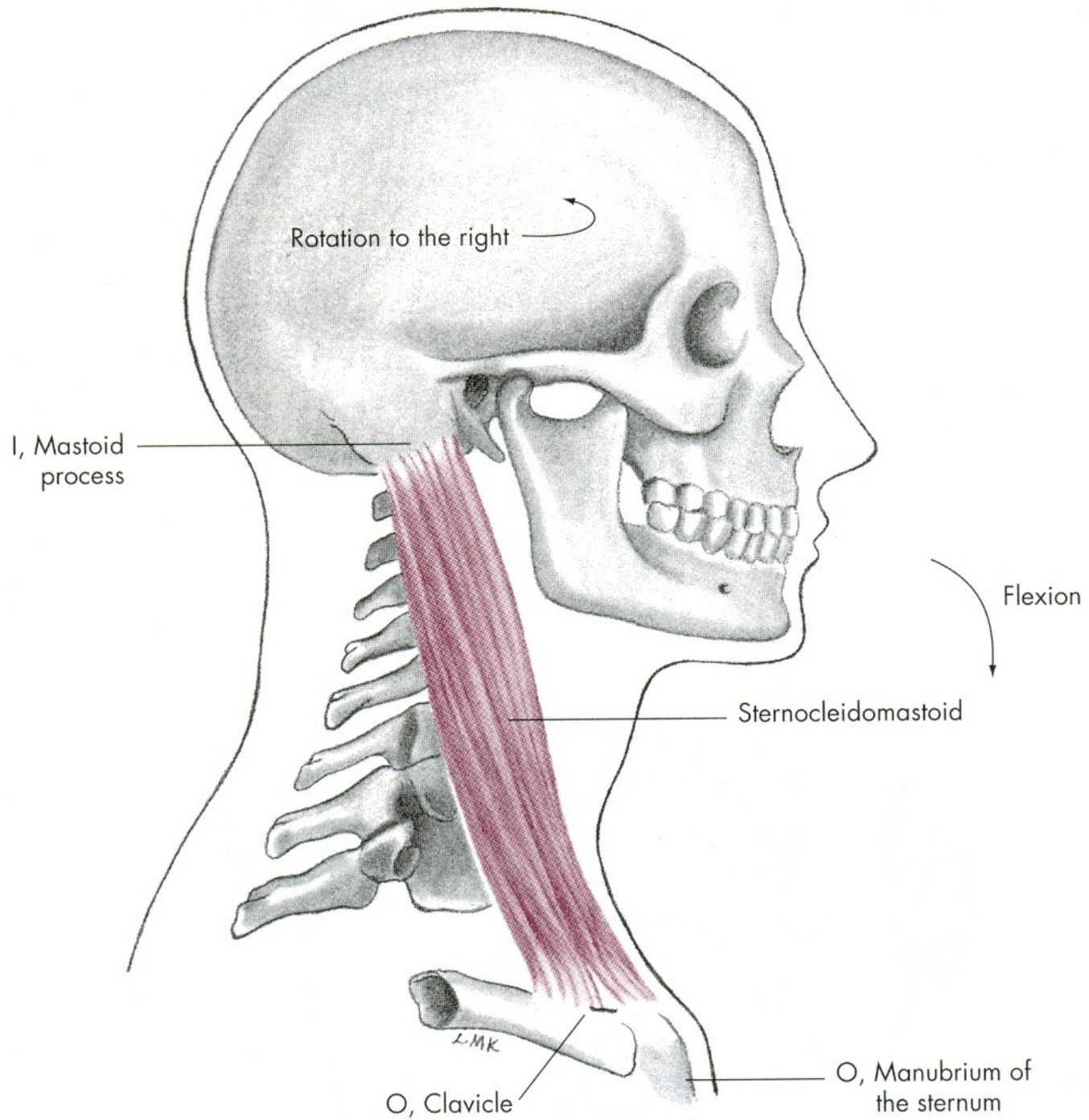


Sternocleidomastoid

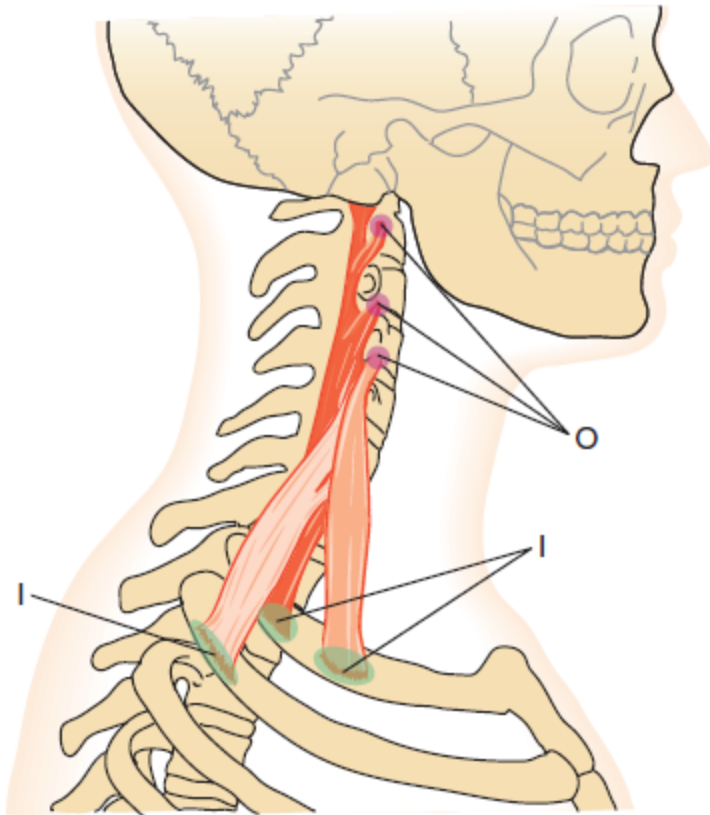
- | | |
|----------|--|
| O | Sternum and clavicle |
| I | Mastoid process |
| A | Bilateral: Flexes neck, hyperextends head
Unilateral: Laterally bends the neck; rotates head to the opposite side |
| N | Accessory nerve (cranial XI); second and third cervical nerves |

I, Mastoid process





scalenes



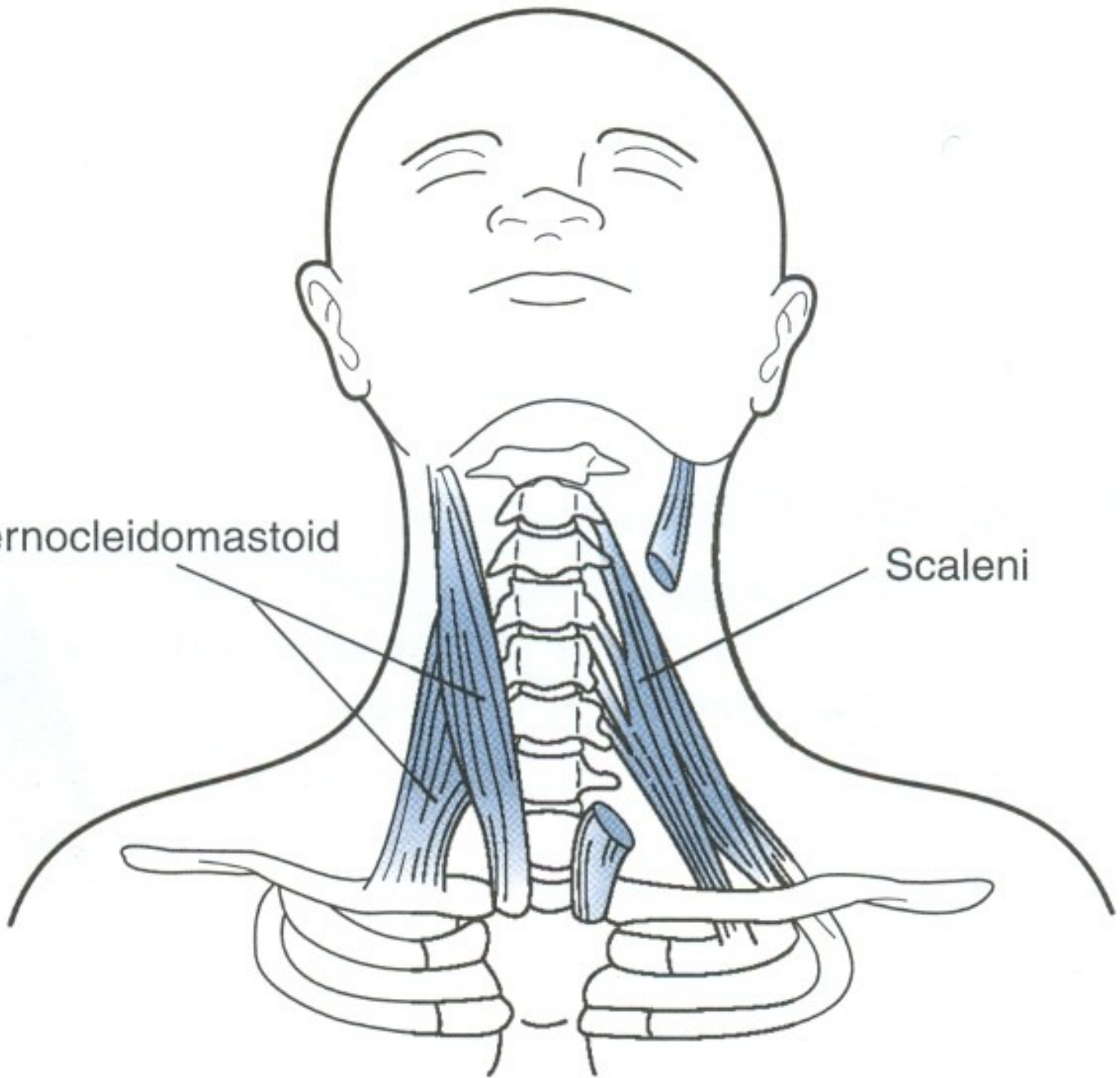
Scalenes

- O** Transverse processes of the cervical vertebrae
- I** First and second rib
- A** Bilateral: Assists in neck flexion
Unilateral: Neck lateral bending
- N** Lower cervical nerves

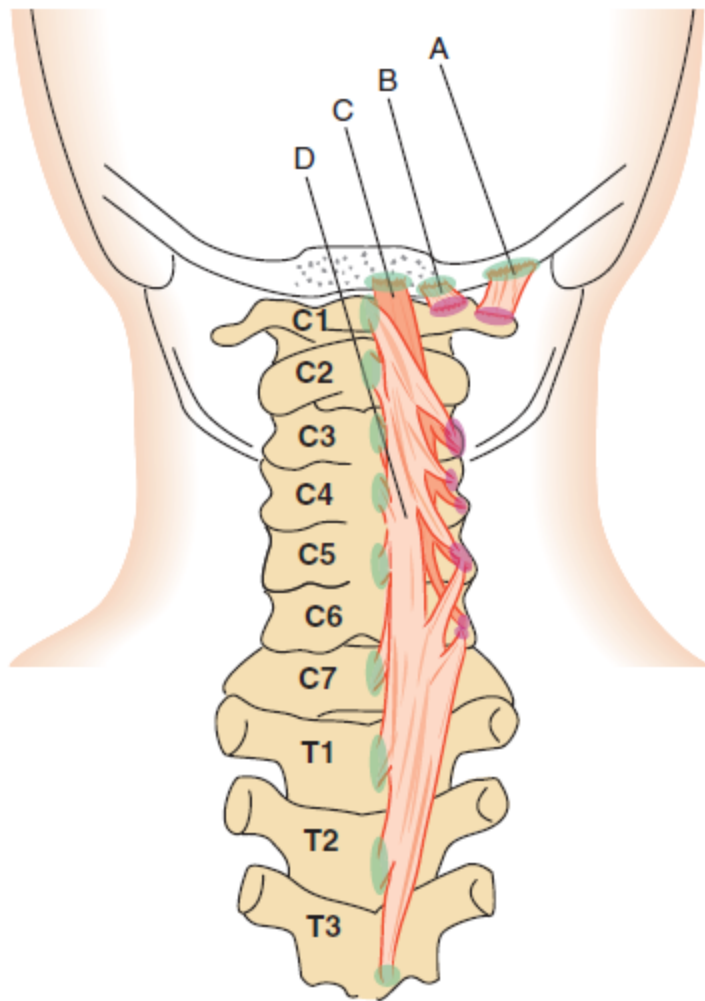
57 scalenes

Sternocleidomastoid

Scaleni



prevertebral muscles



Prevertebral Muscles

- O** Collectively from bodies and transverse processes of C2 through T2
- I** Collectively to the occiput and transverse processes and bodies of C1 through C6
- A** Flex head and neck, as in “tuck the chin”; assists in lateral bending of head on neck
- N** Branches of C1 through C7 (varies with individual muscle)

- A. Rectus capitis lateralis
- B. Rectus capitis anterior
- C. Longus capitis
- D. Longus colli

58 prevertebral muscles

Table 15-4 Prevertebral Muscles (Anterior)

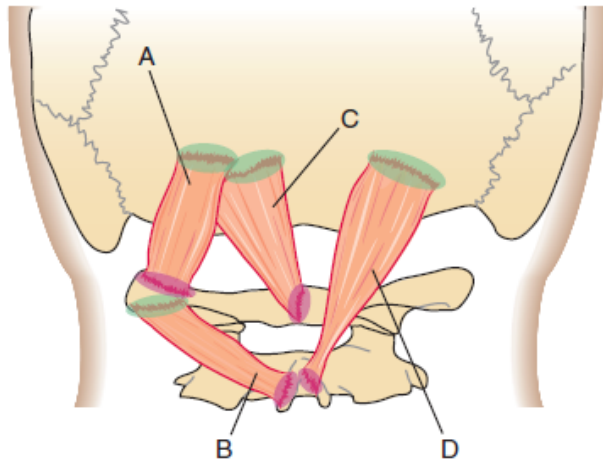
Muscle	Origin	Insertion	Action
Longus colli	Bodies and transverse processes of C3-T2	Transverse processes and bodies of C1-C6	Flex neck
Longus capitis	Transverse processes of C3-C6	Occipital bone	Flex head
Rectus capitis anterior	Atlas (C2)	Occipital bone	Flex head
Rectus capitis lateralis	Transverse process of atlas	Occipital bone	Laterally bend head

Table 15-5 Muscles of the Mouth and Hyoid Bone

Group	Muscle	Action
Superficial cervical Suprahyoid	Platysma	Draws lower lip down and out, tensing skin over neck Raises hyoid bone and/or tongue
	Digastric	
	Stylohyoid	
	Mylohyoid	
	Geniohyoid	
Infrahyoid	Sternohyoid	Lowers hyoid bone
	Sternothyroid	
	Thyrohyoid	
	Omohyoid	

Pohyby hlavy a krku:
Zadní skupina

suboccipital muscles



Suboccipital Muscles

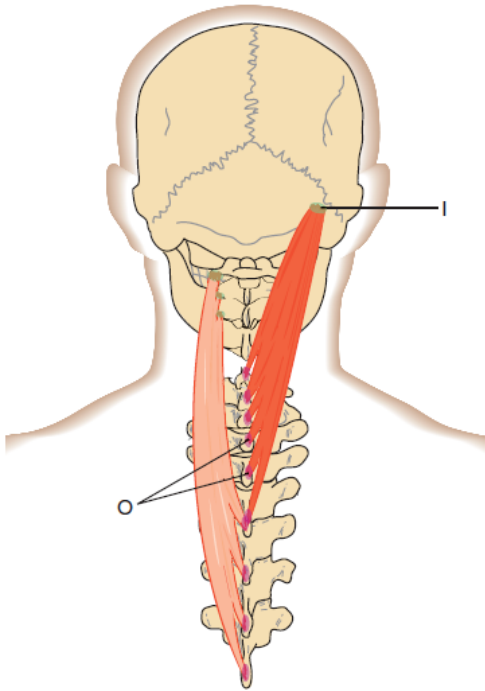
- O** Collectively from the transverse and spinous processes of C1 through C2
- I** Collectively to the occiput and transverse process of C1
- A** Extension of head on neck and assists with lateral bending and rotation to the same side
- N** Suboccipital nerve

- A. Obliquus capitis superior
- B. Obliquus capitis inferior
- C. Rectus capitis posterior minor posterior
- D. Rectus capitis posterior major

Table 15-6 Suboccipital Muscles (Posterior)

Muscle	Location	Head Motion
Obliquus capitis superior	Posterior	Extension
Obliquus capitis inferior	Posterior	Extension, lateral bending, rotation to the same side
Rectus capitis posterior minor	Posterior	Extension
Rectus capitis posterior major	Posterior	Extension, lateral bending, rotation to the same side

splenius capitis

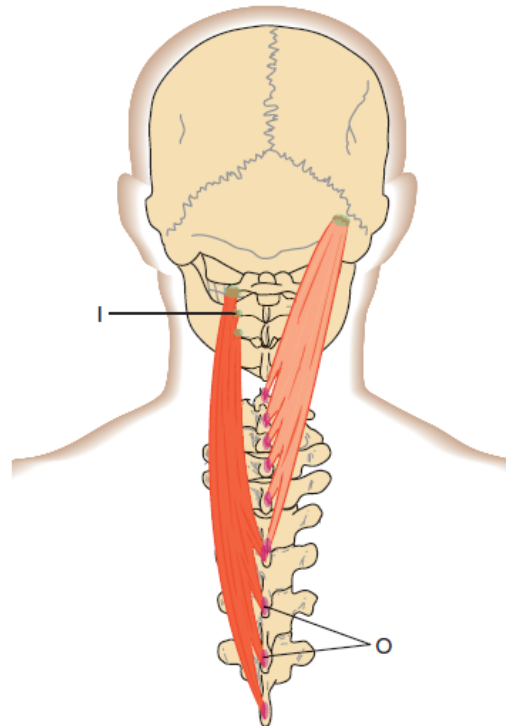


Splenius Capitis

- O** Lower half of nuchal ligament; spinous processes of C7 through T3
- I** Lateral occipital bone; mastoid process
- A** Bilateral: Head and neck extension
Unilateral: Rotate and laterally bend face to same side
- N** Middle and lower cervical nerves

+ svaly zadní skupiny trupu, za specifických podmínek i m. levator scapulae a část m. trapezius

splenius cervicis



Splenius Cervicis

- O** Spinous processes of T3 through T6
- I** Transverse processes of C1 through C3
- A** Bilateral: Neck extension
Unilateral: Neck rotation and lateral bending to same side
- N** Middle and lower cervical nerves

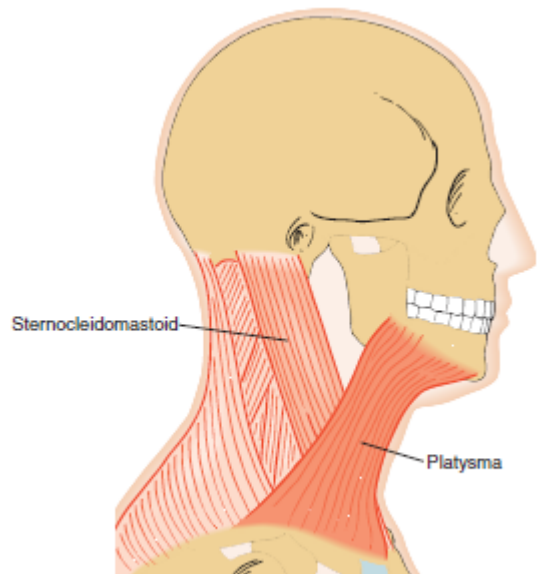
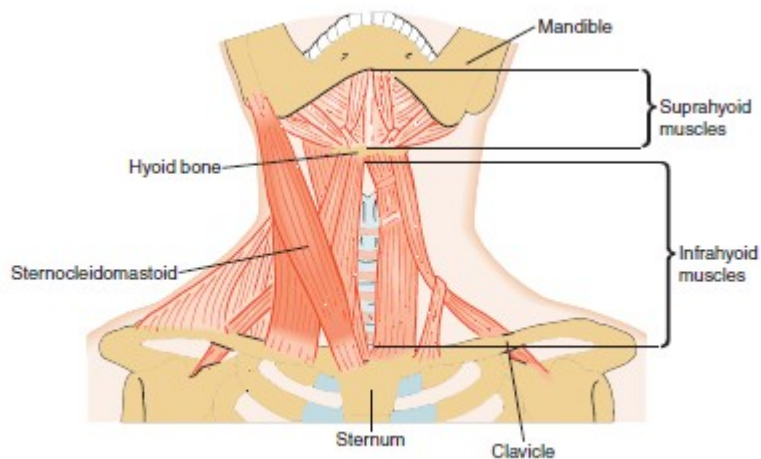


Figure 15-29. Platysma muscle (side view).



1. Muscles of t

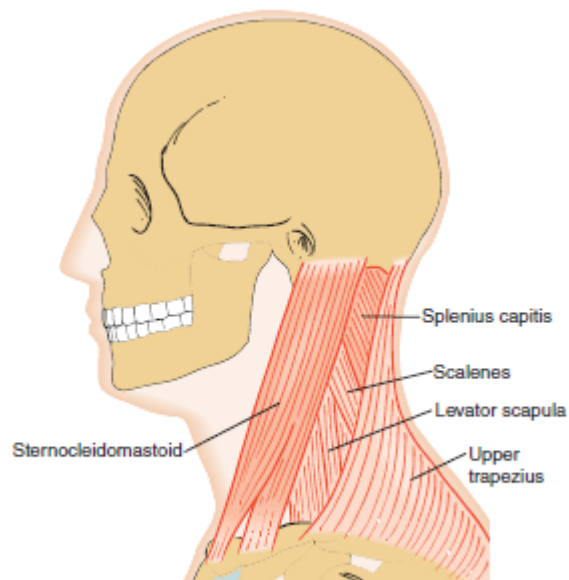


Figure 15-31. Muscles of the neck (lateral view).

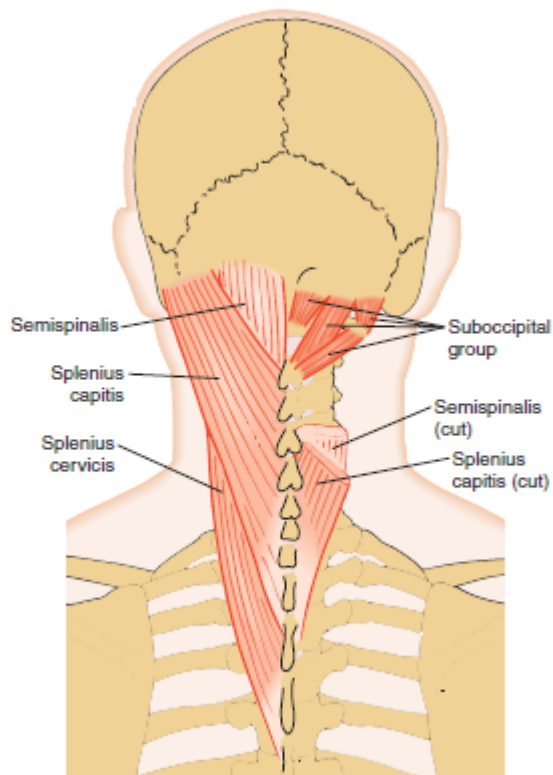


Figure 15-32. Muscles of the neck (posterior view).

POHYBY TRUPU

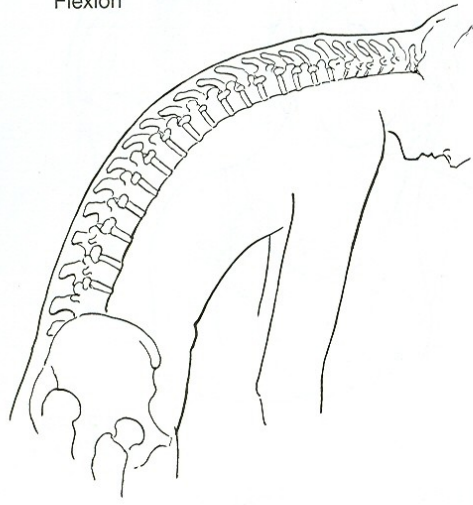
VENTRÁLNÍ FLEXE - PŘEDKLON

DORZÁLNÍ FLEXE - ZÁKLON

LATEROFLEXE - ÚKLON

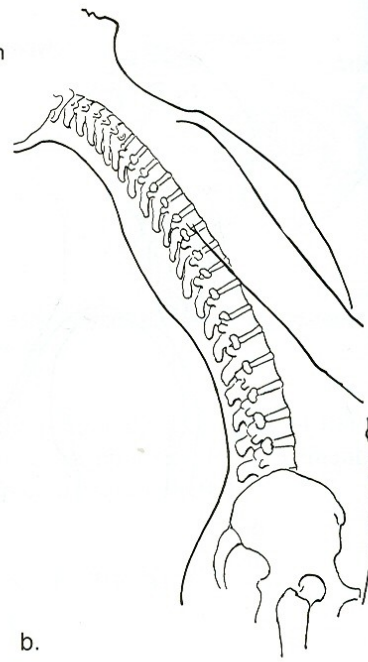
ROTACE - OTÁČENÍ

Flexion



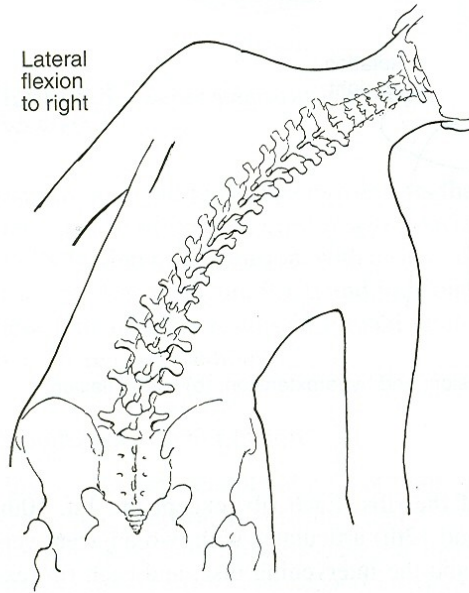
a.

Hyperextension



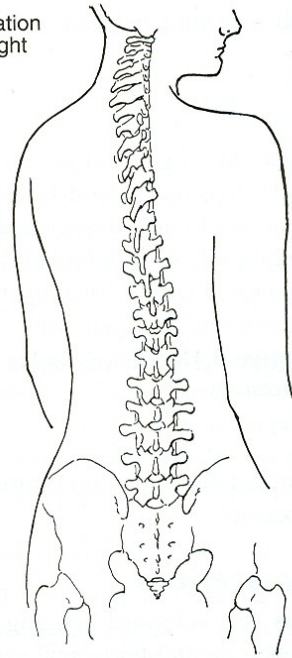
b.

Lateral flexion to right



c.

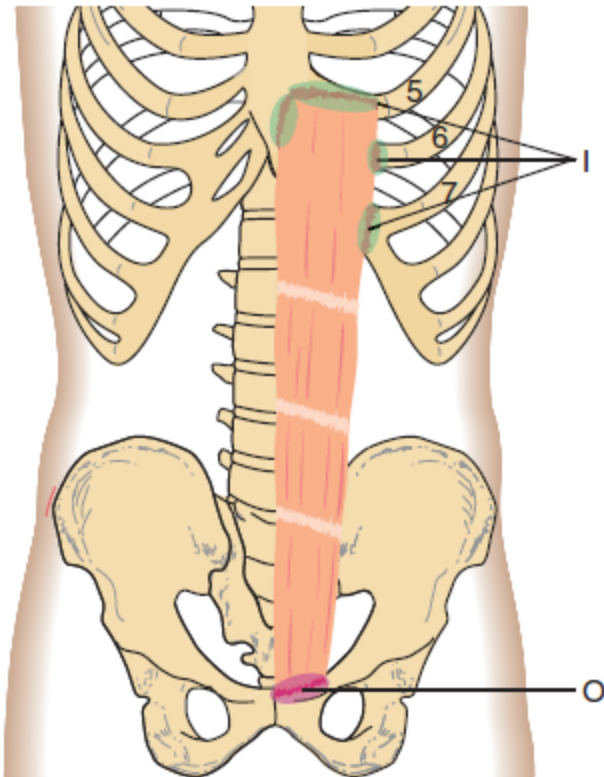
Rotation to right



d.

Pohyby trupu:
Přední skupina

rectus abdominis



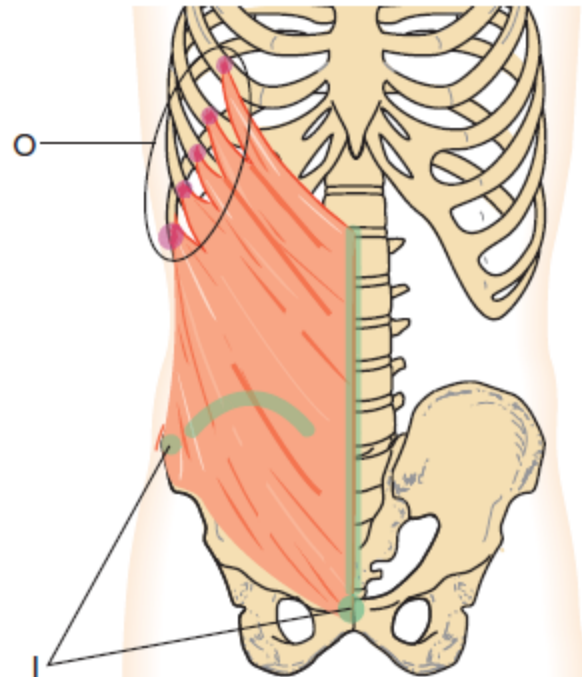
Rectus Abdominis

- O** Pubis
- I** Xiphoid process and costal cartilages of fifth, sixth, and seventh ribs
- A** Trunk flexion; compression of abdomen
- N** Seventh through 12th intercostal nerves

62 rectus abdominis

Lippert & Minor: Kinesiology Flashcards 3e, © 2011 F. A. Davis Company

external oblique

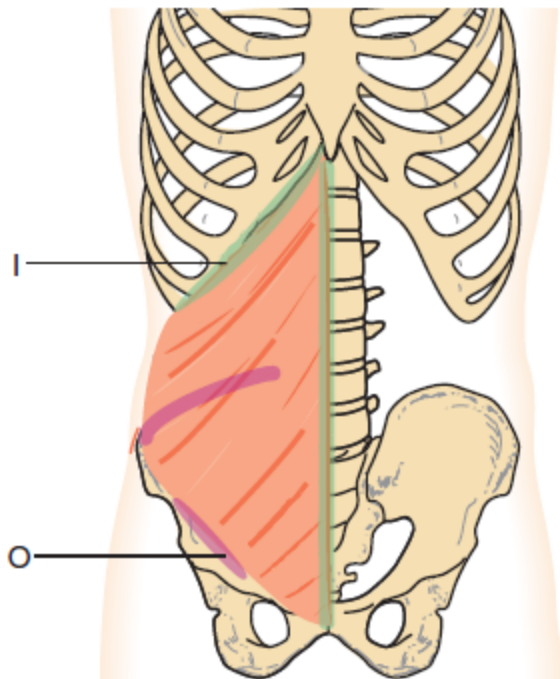


External Oblique

- O** Lower eight ribs laterally
- I** Iliac crest and linea alba
- A** Bilateral: Trunk flexion; compression of abdomen
Unilateral: Trunk lateral bending; rotation to opposite side
- N** Eighth through 12th intercostal, iliohypogastric, and ilioinguinal nerves

63 external oblique

internal oblique

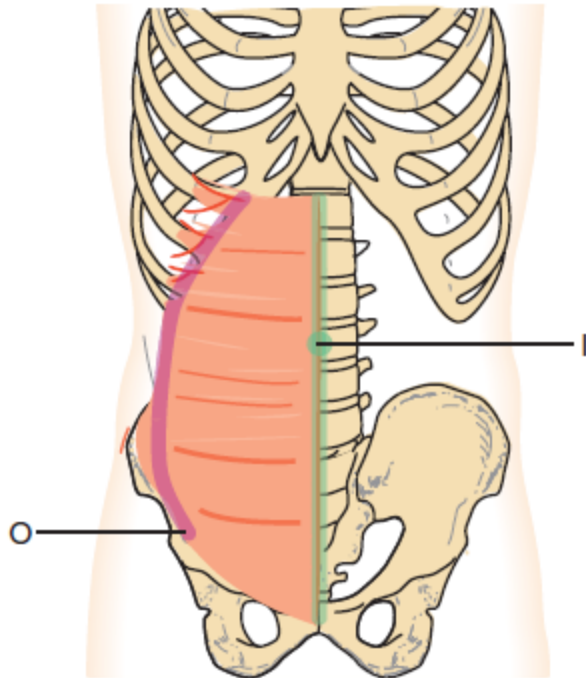


Internal Oblique

- O** Inguinal ligament, iliac crest, thoracolumbar fascia
- I** Tenth, 11th, and 12th ribs; abdominal aponeurosis into linea alba
- A** Bilateral: Trunk flexion; compression of abdomen
Unilateral: Trunk lateral bending; rotation to same side
- N** Eighth through 12th intercostal, iliohypogastric, and ilioinguinal nerves

64 internal oblique

transverse abdominis

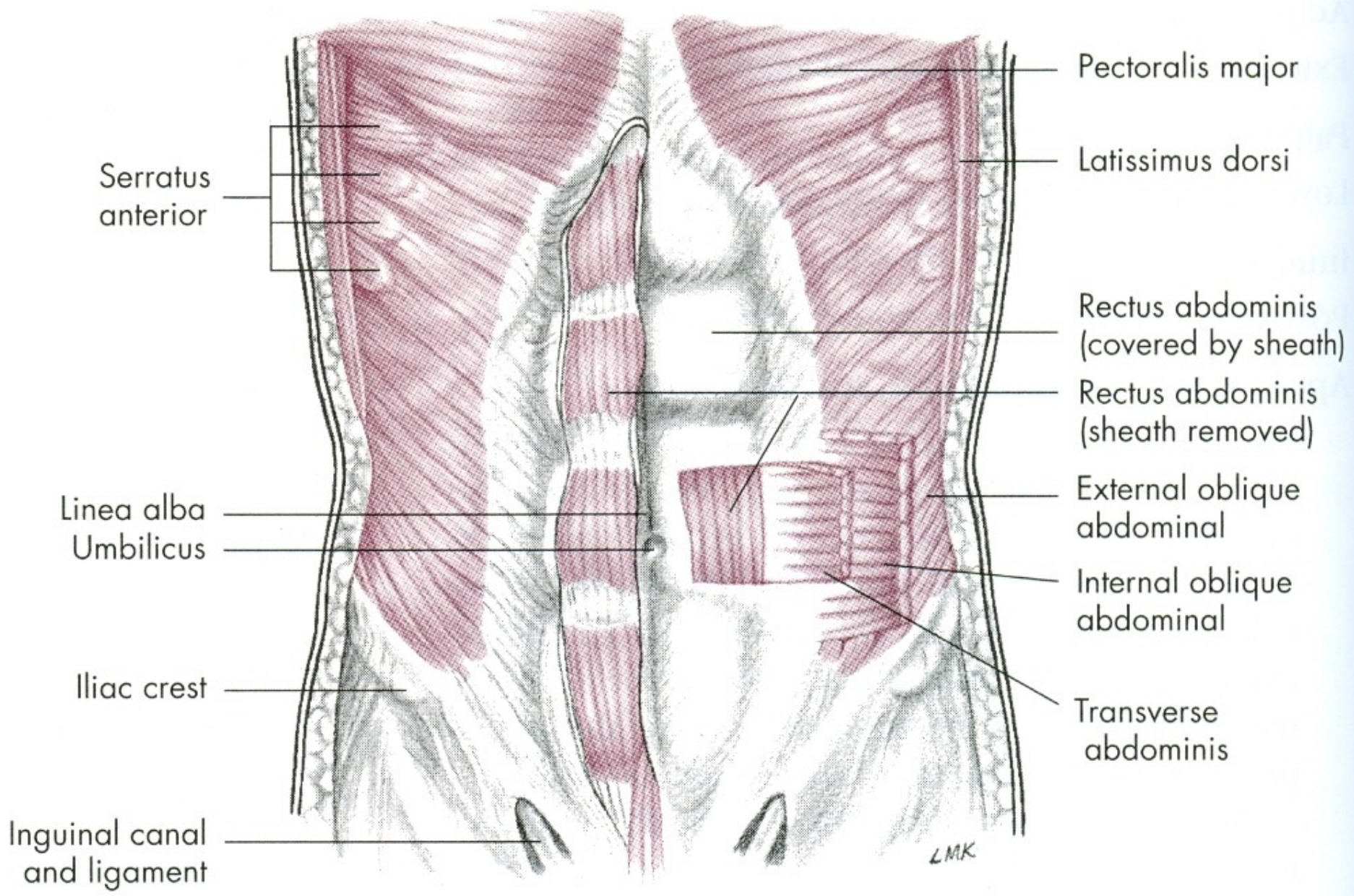


Transverse Abdominis

- O** Inguinal ligament, iliac crest, thoracolumbar fascia, and last six ribs
- I** Abdominal aponeurosis and linea alba
- A** Compression of abdomen
- N** Seventh through 12th intercostal, iliohypogastric, and ilioinguinal nerves

65 transverse abdominis

Lippert & Minor: Kinesiology Flashcards 3e, © 2011 F. A. Davis Company



Pectoralis major

Latissimus dorsi

Rectus abdominis
(covered by sheath)

Rectus abdominis
(sheath removed)

External oblique
abdominal

Internal oblique
abdominal

Transverse
abdominis

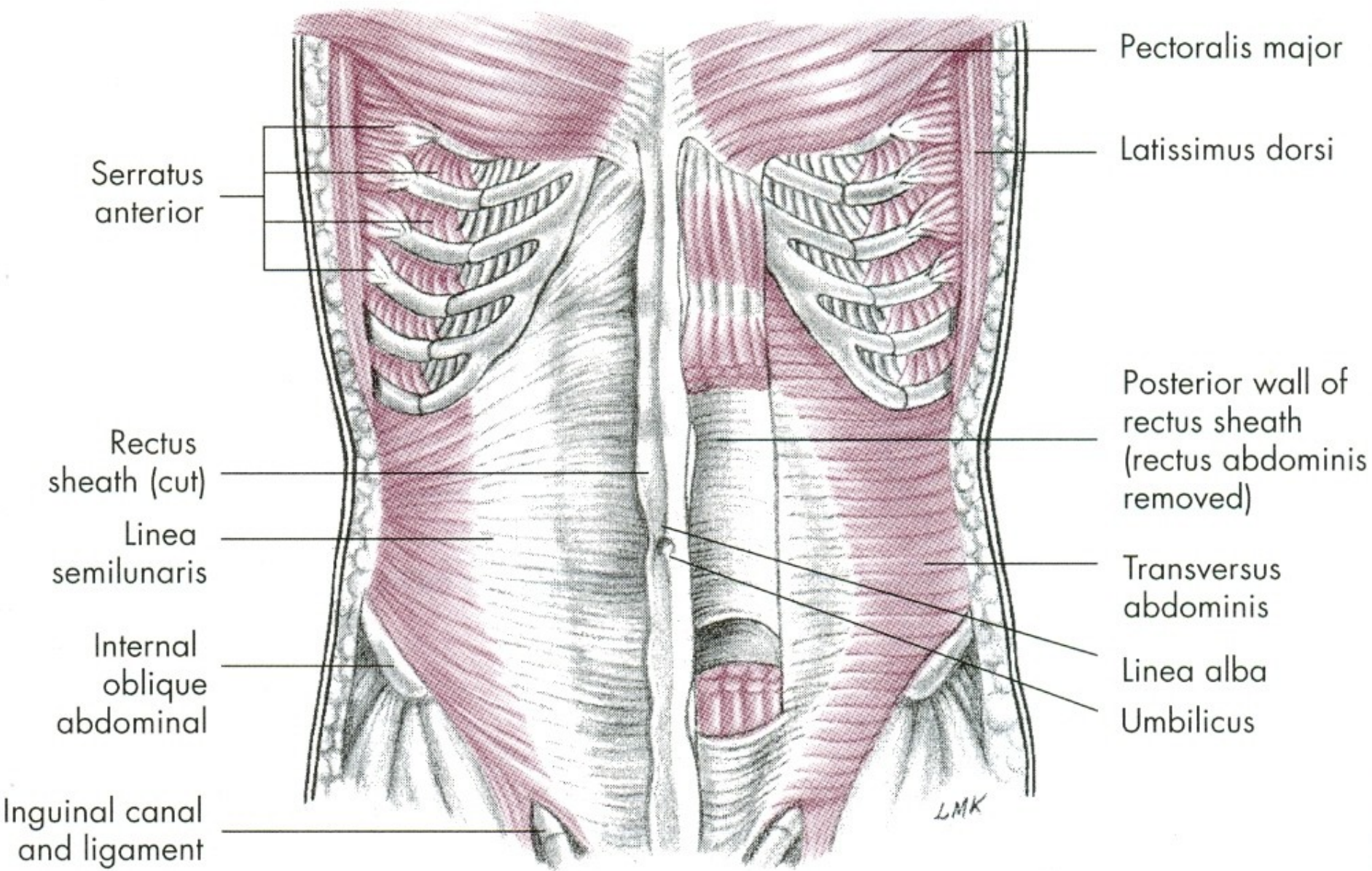
Serratus
anterior

Linea alba
Umbilicus

Iliac crest

Inguinal canal
and ligament

L.M.K.



Serratus anterior

Rectus sheath (cut)

Linea semilunaris

Internal oblique abdominal

Inguinal canal and ligament

Pectoralis major

Latissimus dorsi

Posterior wall of rectus sheath (rectus abdominis removed)

Transversus abdominis

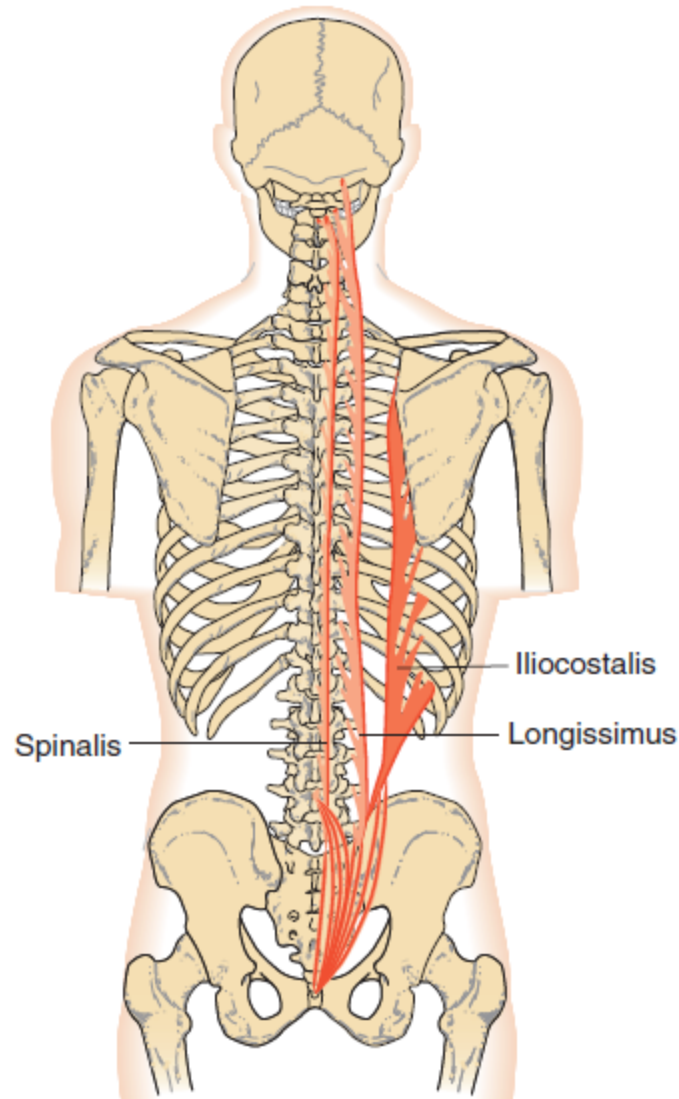
Linea alba

Umbilicus

LMK

Pohyby trupu:
Zadní skupina

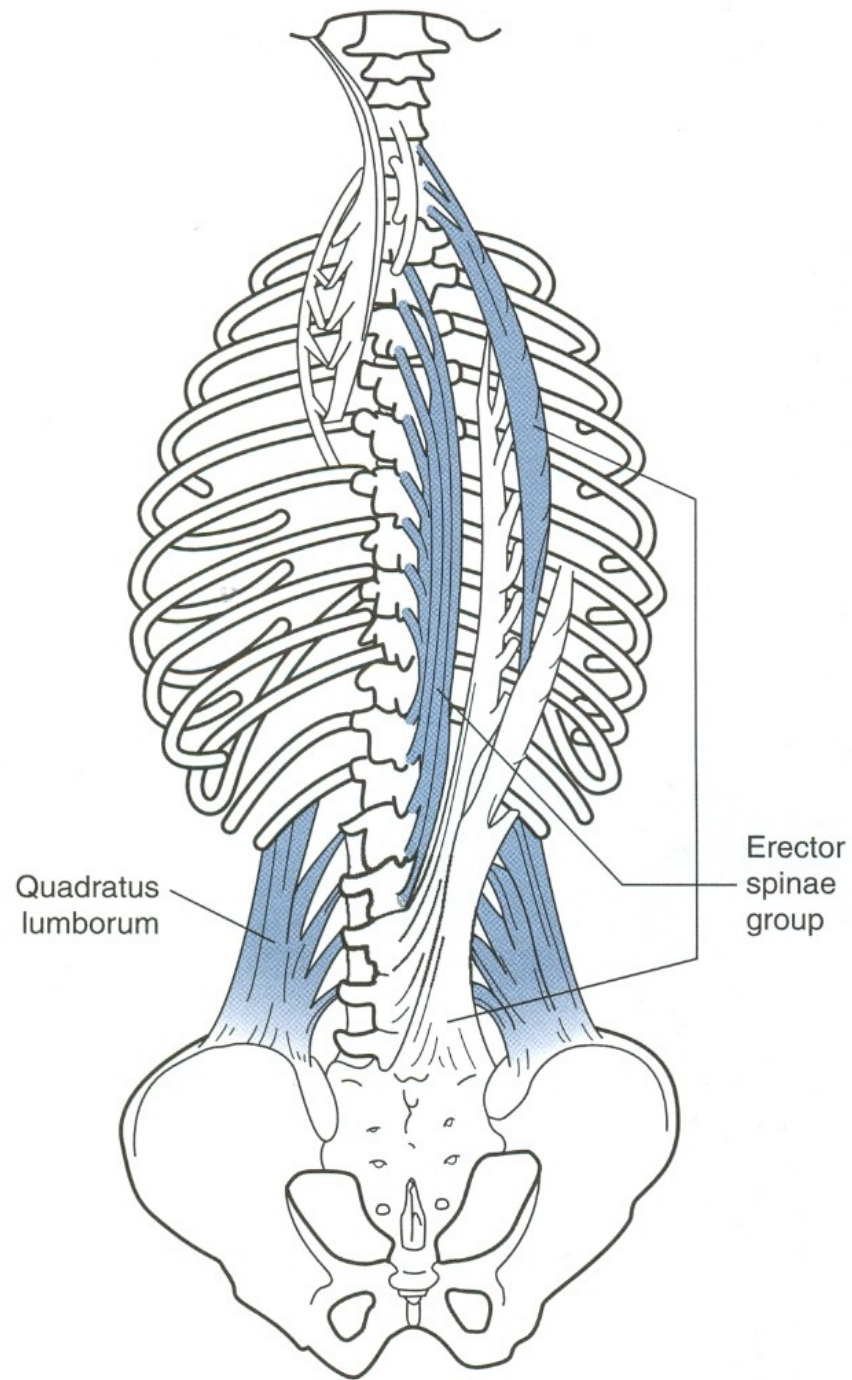
erector spinae



Erector Spinae

- O** Spinous processes, transverse processes, and posterior ribs from the occiput to the sacrum and ilium
- I** Spinous processes, transverse processes, and posterior ribs from the occiput to the sacrum and ilium
- A** Bilateral: Neck and trunk extension
Unilateral: Neck and trunk lateral bending
- N** Spinal nerves

66 erector spinae



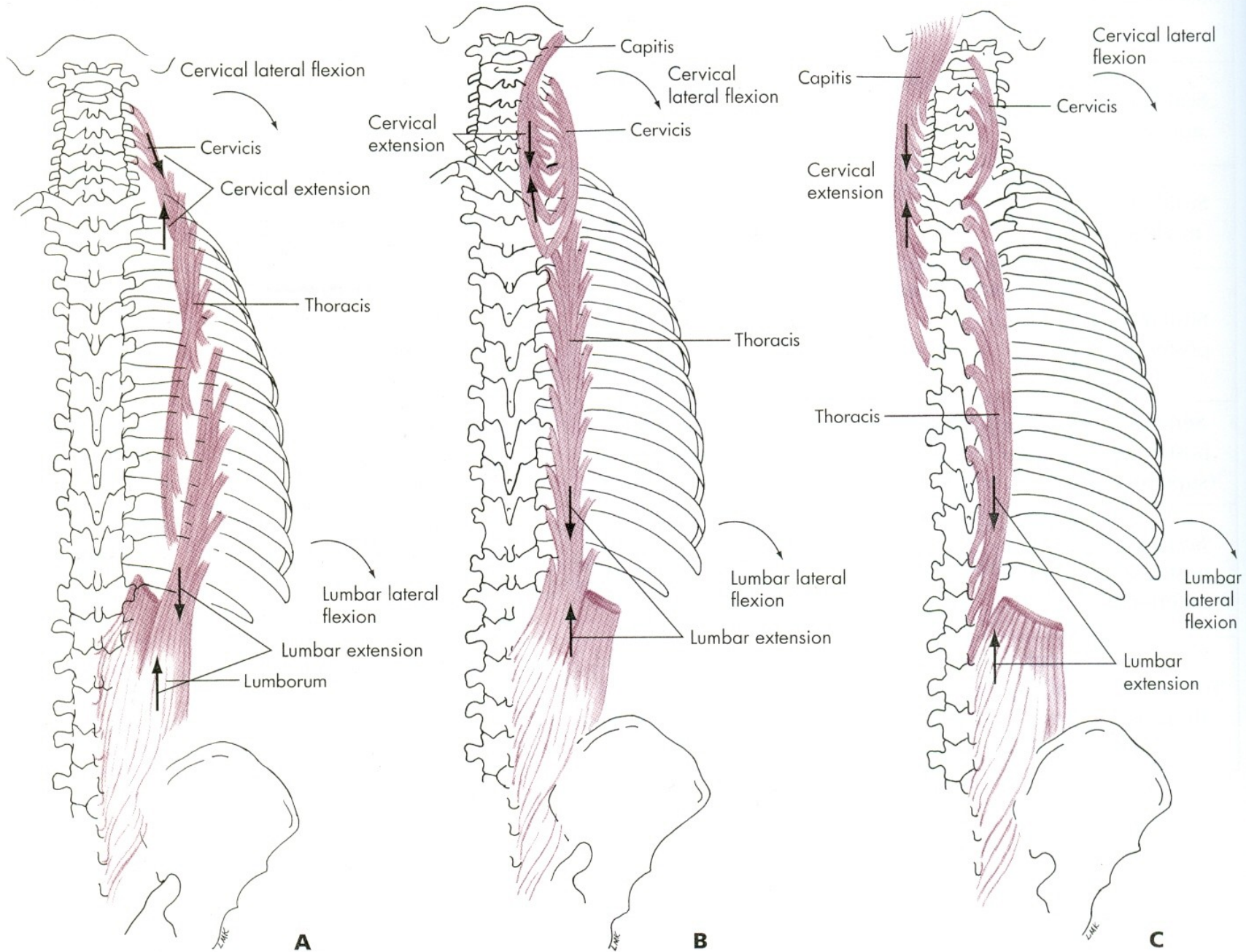
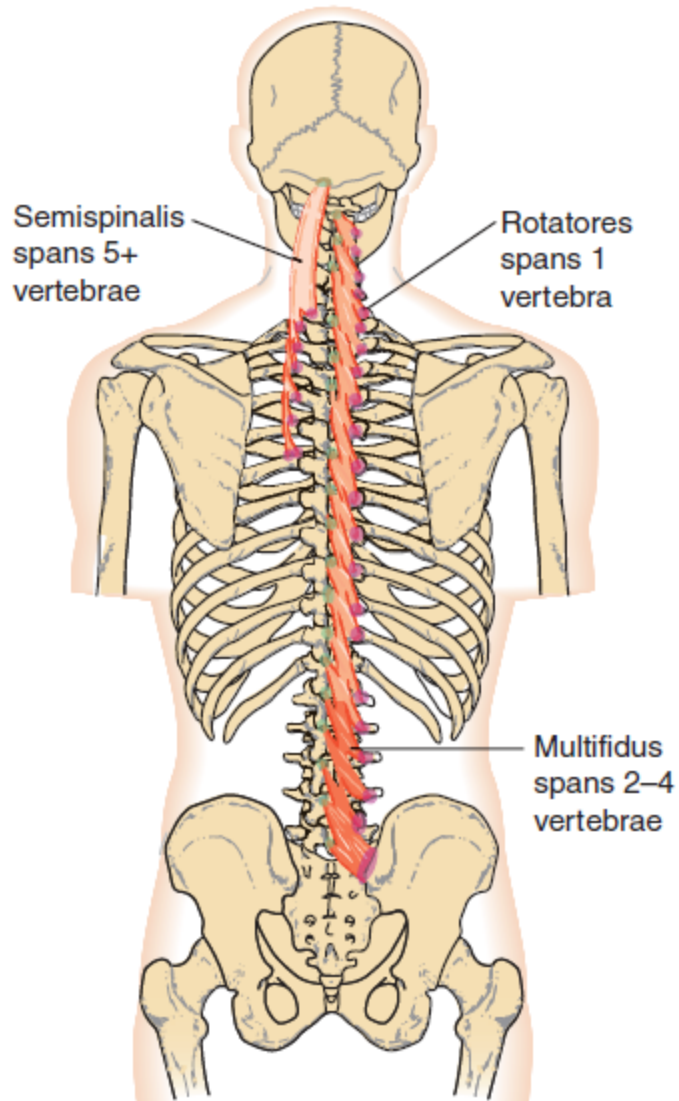


FIG. 12.15 • Erector spinae (sacrospinalis) muscle, posterior view. **A**, iliocostalis; **B**, longissimus; **C**, spinalis.

transversospinalis



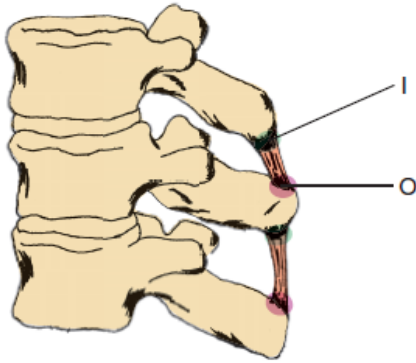
Transversospinalis

- O** Transverse processes
- I** Spinous processes of vertebra above
- A** Bilateral: Neck and trunk extension
Unilateral: Neck and trunk rotation to opposite side
- N** Spinal nerves

67 transversospinalis

Lippert & Minor: Kinesiology Flashcards 3e, © 2011 F. A. Davis Company

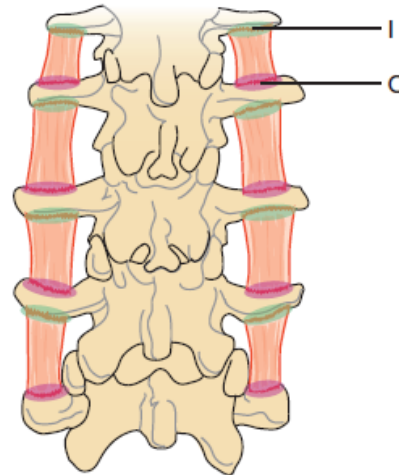
interspinales



Interspinales

- O** Spinous process below
- I** Spinous process above
- A** Neck and trunk extension
- N** Spinal nerves

intertransversarii



Intertransversarii

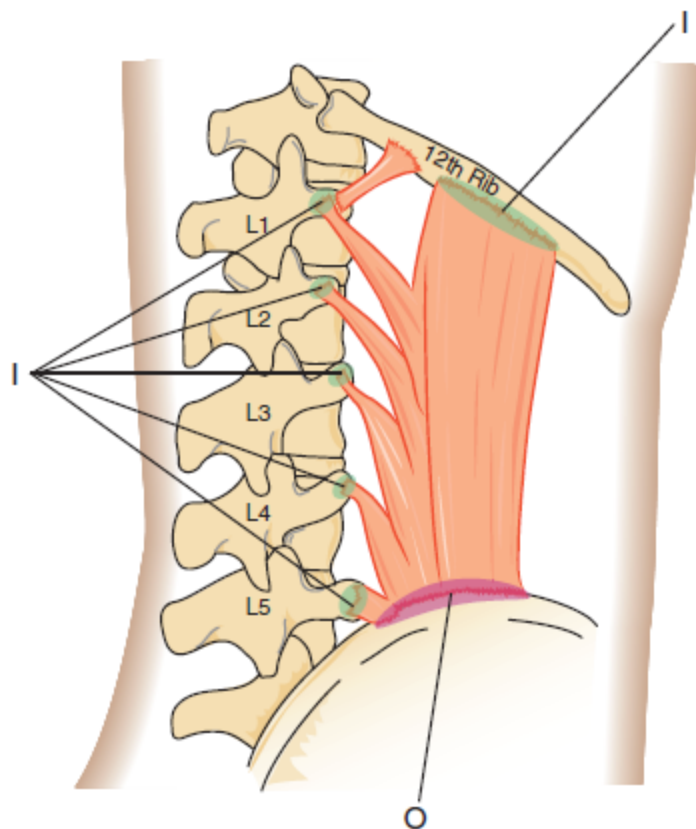
- O** Transverse process below
- I** Transverse process above
- A** Neck and trunk lateral bending
- N** Spinal nerves

Table 15-7 Posterior Trunk Muscles

Attachments	Action	Muscles
Spinous process to spinous process	Extension	Spinalis (ES) Interspinales
Transverse process to transverse process	Extension, lateral bending	Longissimus (ES) Intertransversarii
Spinous to transverse process	Extension, rotation	Splenius cervicis
Transverse to spinous process	Extension, rotation	Semispinalis (T) Multifidus (T) Rotatores (T)
Transverse process to rib, or rib to rib	Extension, lateral bending	Iliocostalis (ES)

ES, erector spinae; T, transversospinalis.

quadratus lumborum



Quadratus Lumborum

- O** Iliac crest
- I** Twelfth rib, transverse processes of all five lumbar vertebrae
- A** Trunk lateral bending
- N** Twelfth thoracic and first lumbar nerves

70 quadratus lumborum

Lippert & Minor: Kinesiology Flashcards 3e, © 2011 F. A. Davis Company

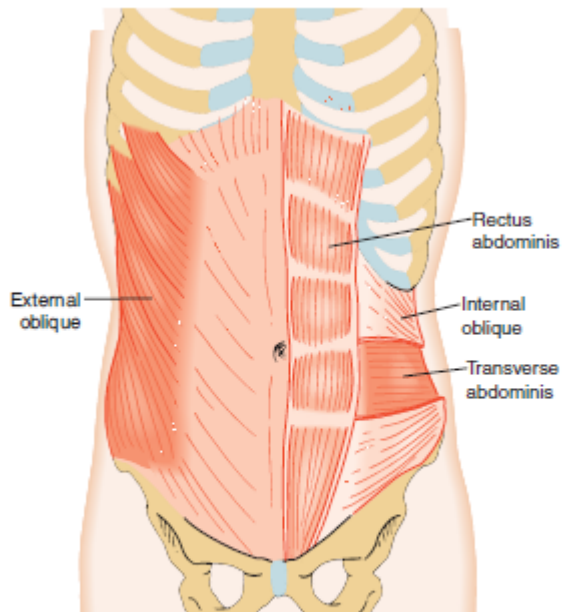
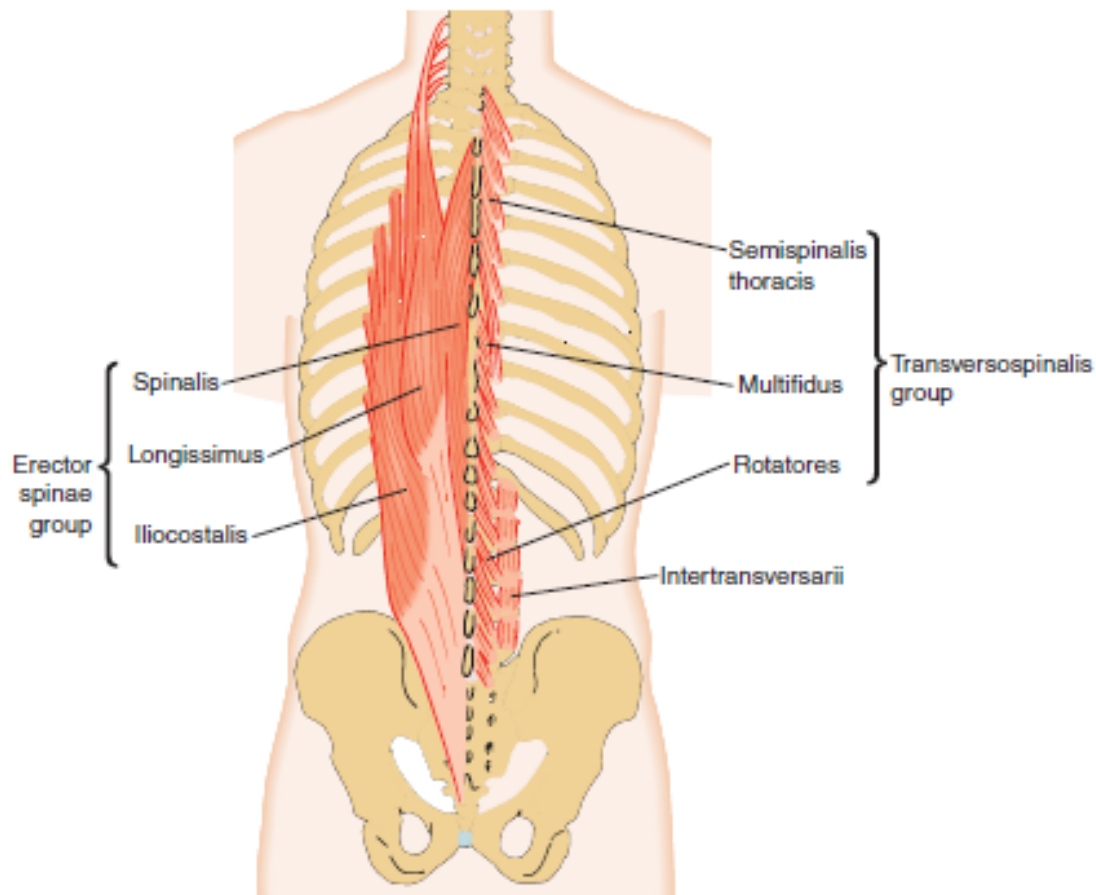


Figure 15-33. Muscles of the trunk (anterior view). Note that the external oblique is shown only on one side, and that a portion of the internal oblique has been cut away to show the transverse abdominis deep to it.



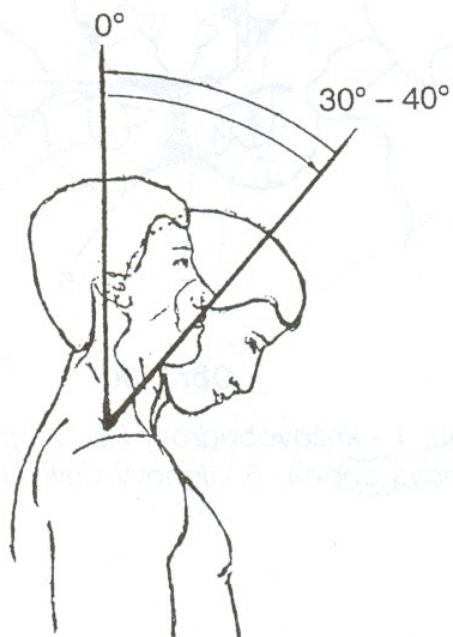
Posterior view

1. Muscles of the trunk (posterior view).

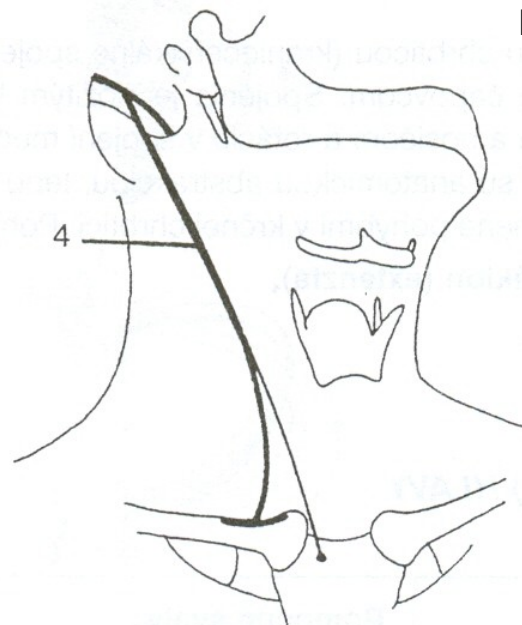
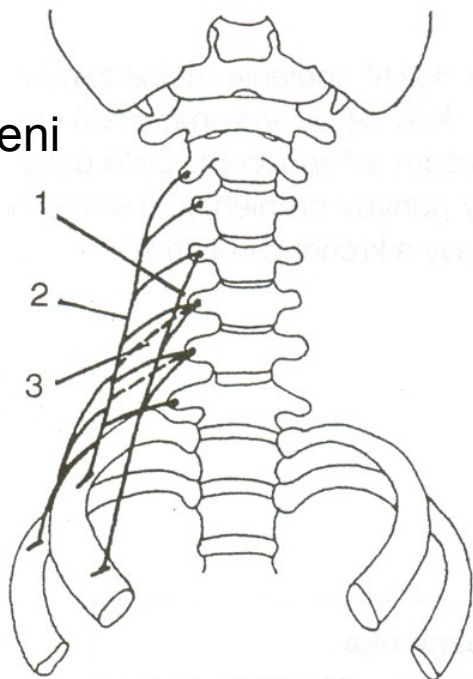
Table 15-8 Prime Movers of the Neck and Trunk

Action	Muscle
Head (Occiput on C1)	
Flexion	Prevertebral group
Extension	Suboccipital group
Neck	
Flexion	Sternocleidomastoid
Extension	Splenius capitis, splenius cervicis, erector spinae, transversospinalis, interspinales
Lateral bending	Sternocleidomastoid, splenius capitis, splenius cervicis, scalenes, erector spinae, intertransversarii
Rotation (same side)	Splenius capitis, splenius cervicis
Rotation (opposite side)	Sternocleidomastoid, transversospinalis
Trunk	
Flexion	Rectus abdominis, external oblique, internal oblique
Extension	Erector spinae, transversospinalis, interspinales
Lateral bending	Quadratus lumborum, erector spinae, internal oblique, external oblique, intertransversarii
Rotation same side	Internal oblique
Rotation opposite side	External oblique, transversospinalis
Compression of abdomen	Rectus abdominis, external oblique, internal oblique, transverse abdominis

FLEXE - PŘEDKLON

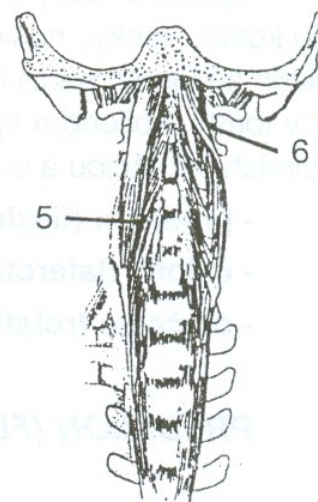


mm. scaleni



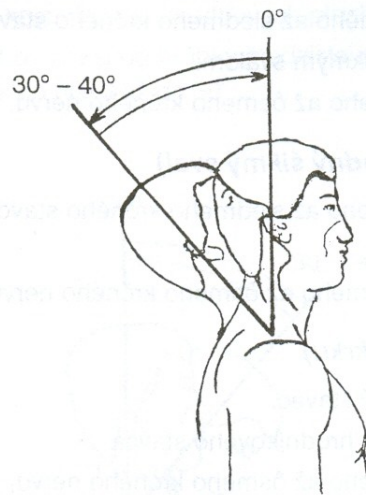
m. sternocleidomastoideus

m. longus colli

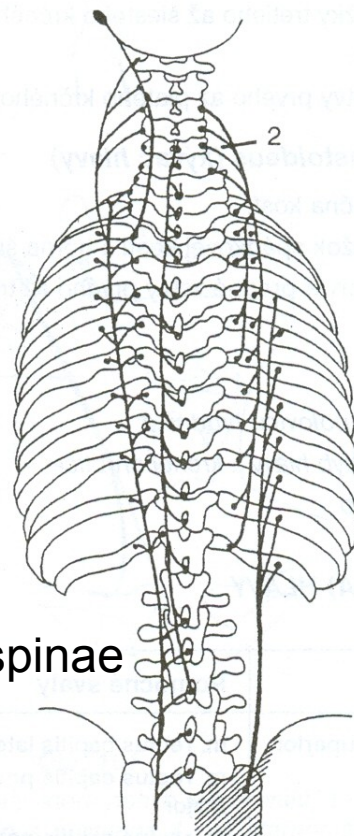
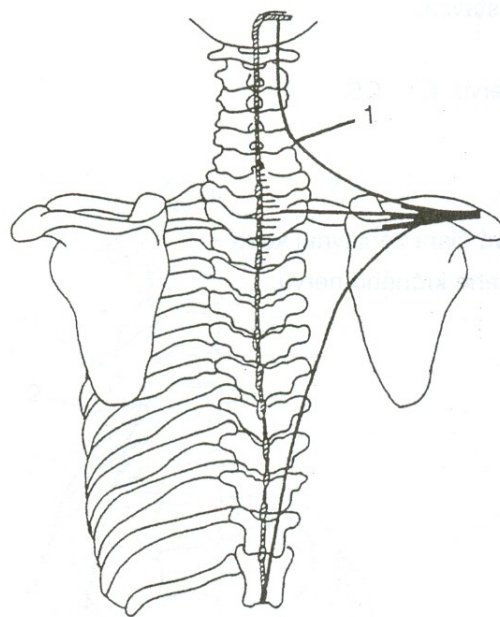


m. longus capitis

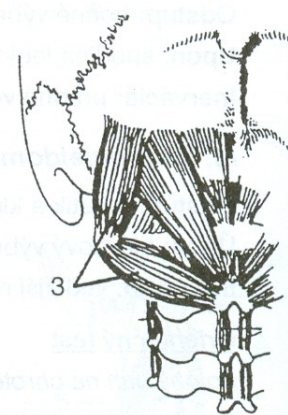
EXTENZE - ZÁKLON



m. trapezius

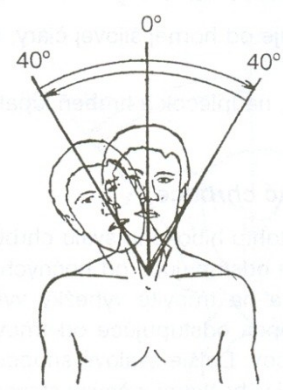


m. erector spinae

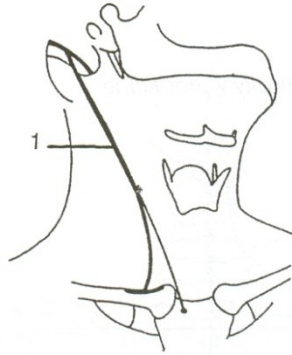

hluboké svaly šíjové

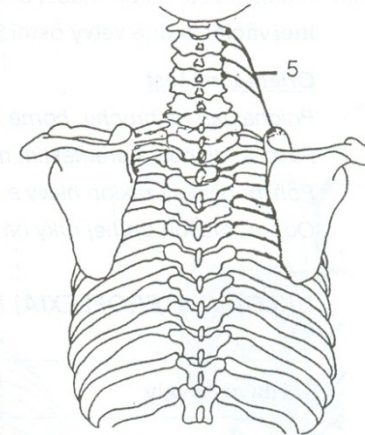
LATEROFLEXE - ÚKLON



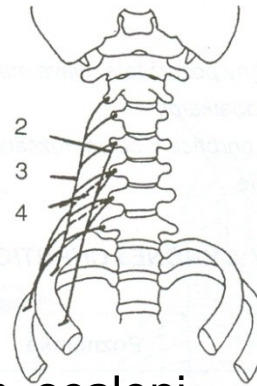
m. sternocleidomastoideus



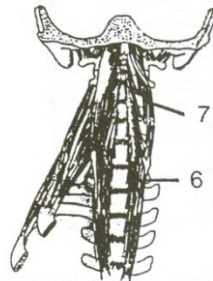
m. levator scapule



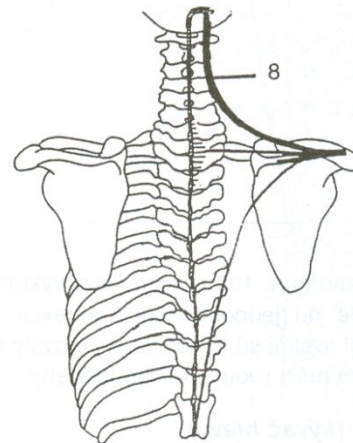
mm. scaleni



m. longus capitis

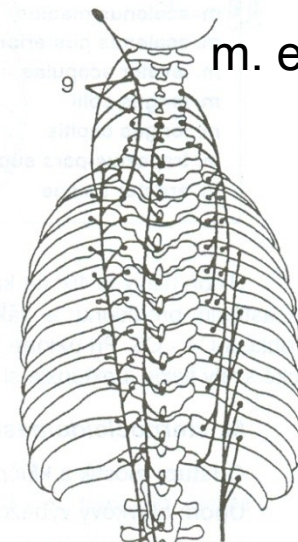


m. longus colli

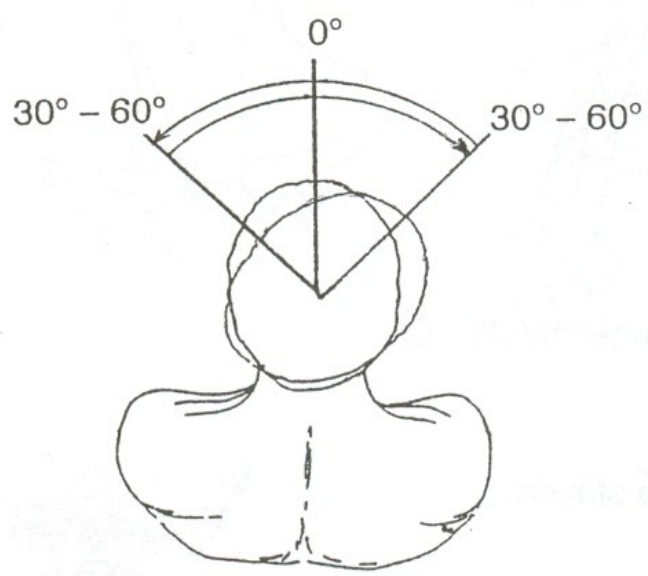


m. trapezius

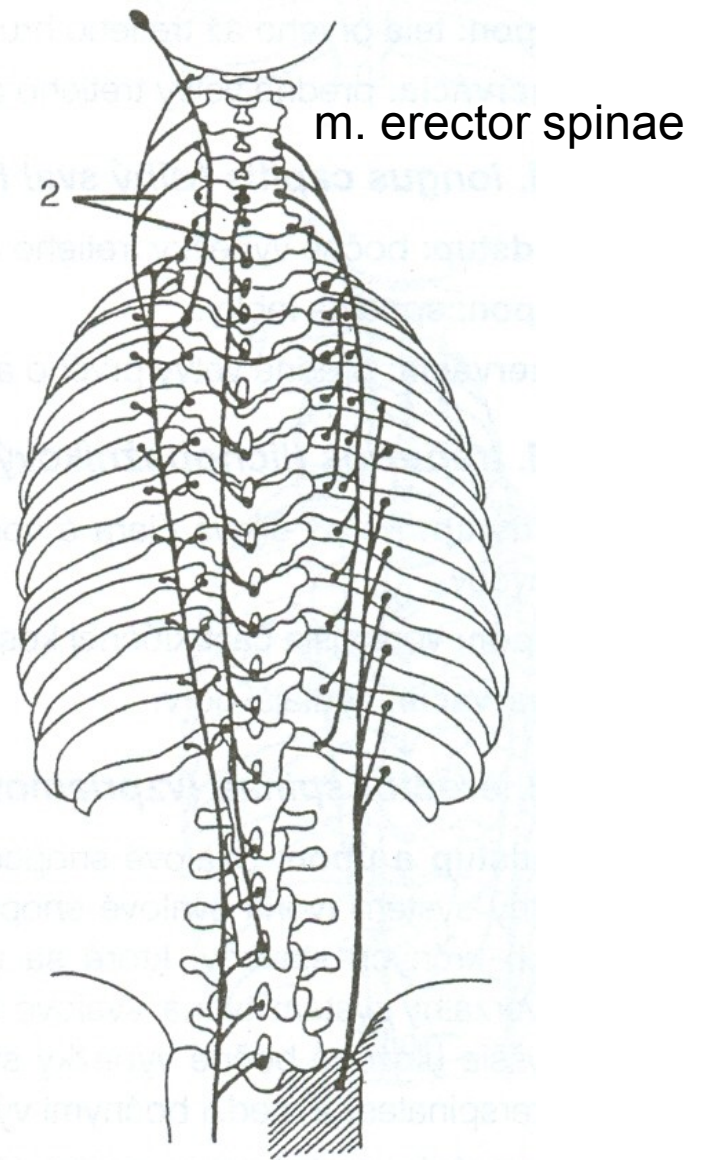
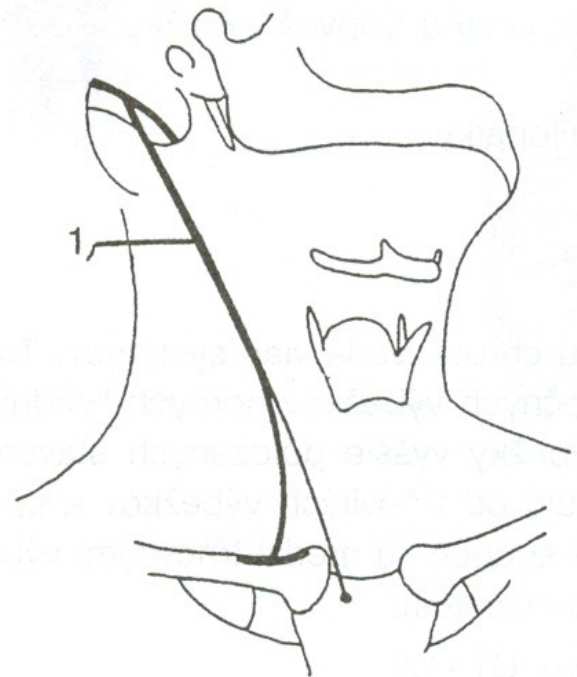
m. erector spinae



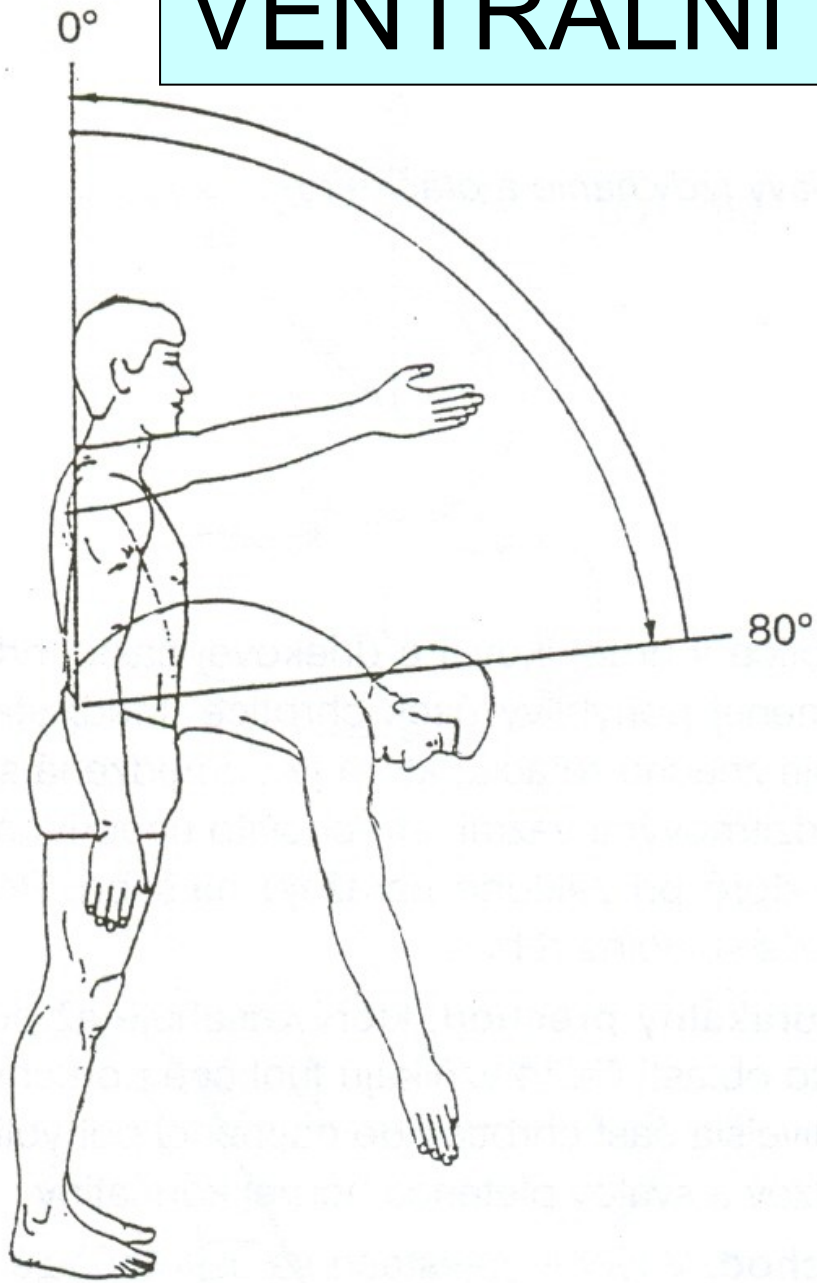
ROTACE - OTÁČENÍ



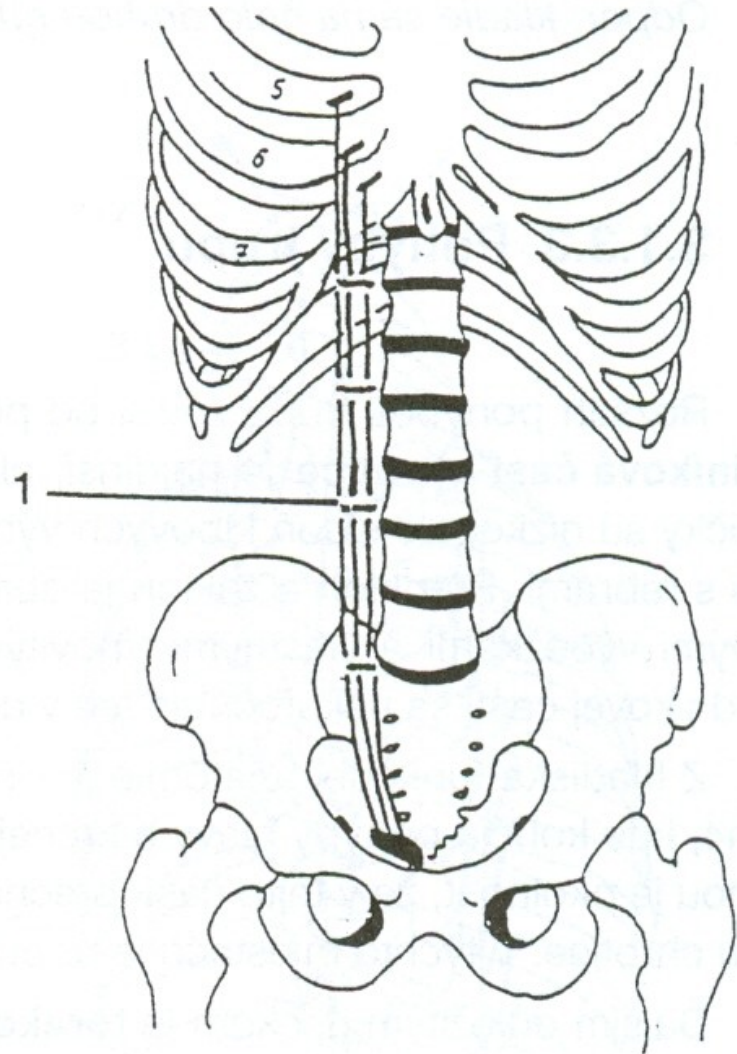
m. sternocleidomastoideus



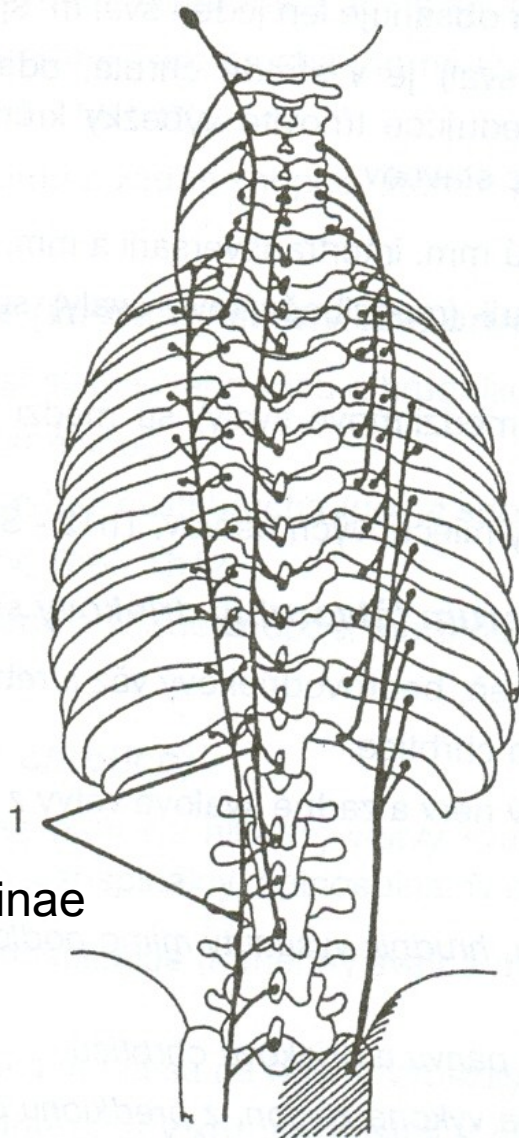
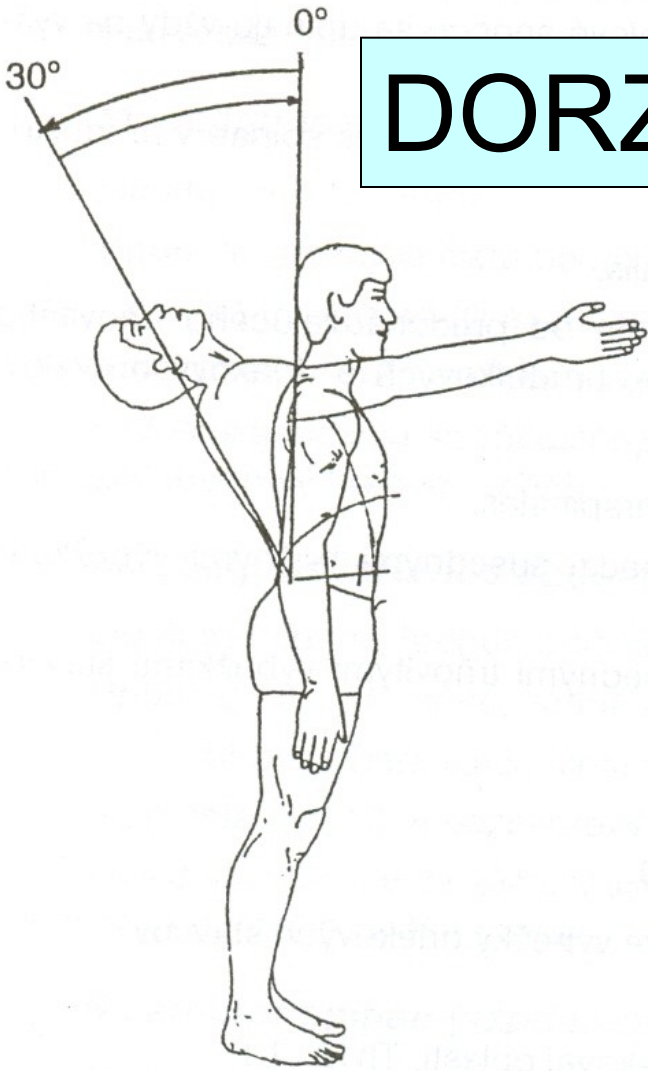
VENTRÁLNÍ FLEXE - PŘEDKLON



m. rectus abdominis

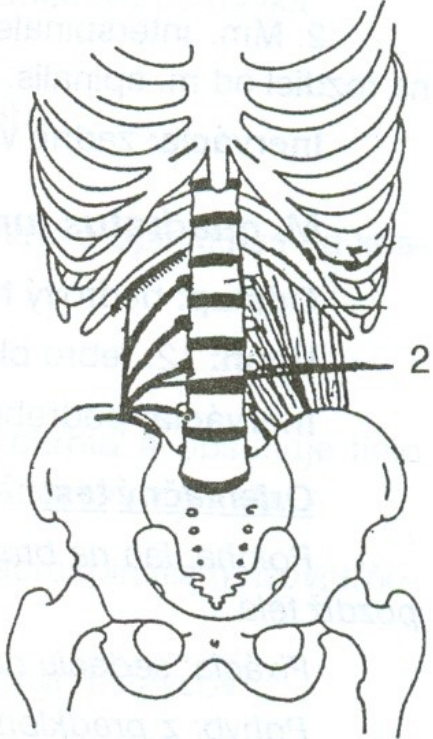


DORZÁLNÍ FLEXE - ZÁKLON

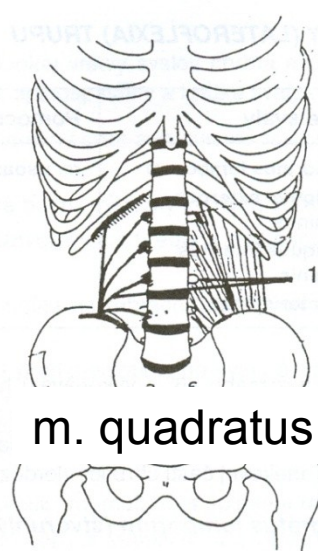
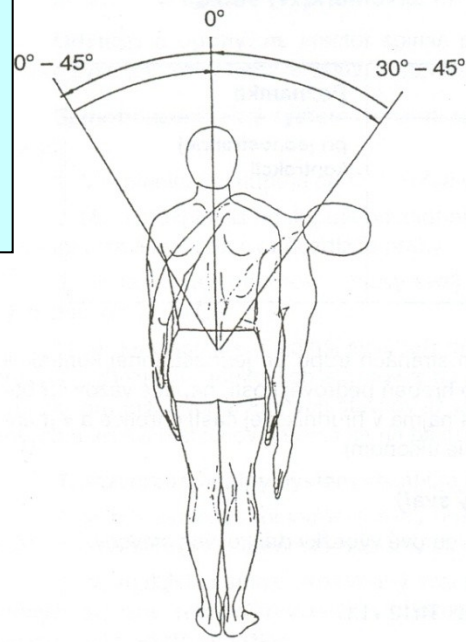


m. erector spinae

m. quadratus lumborum



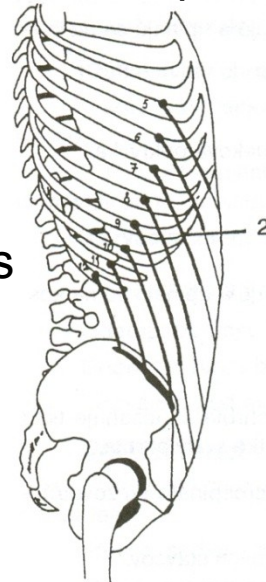
LATEROFLEXE - ÚKLON



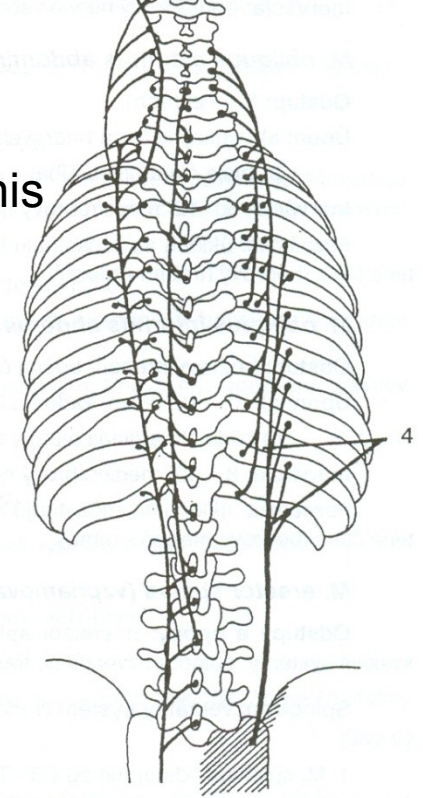
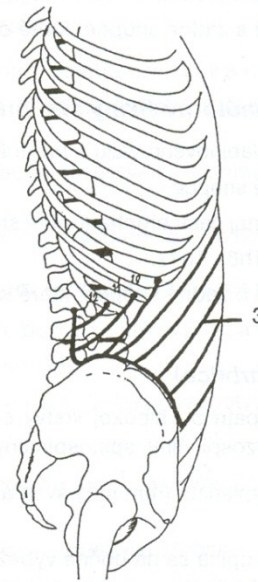
m. quadratus lumborum

m. erector spinae

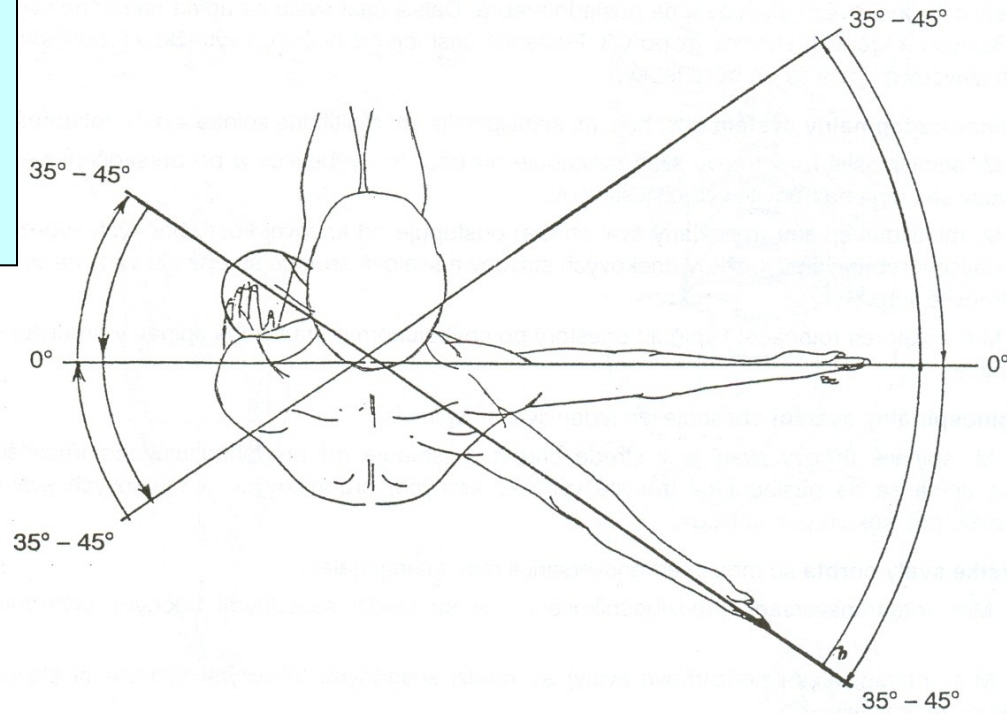
m. obliquus internus abdominis



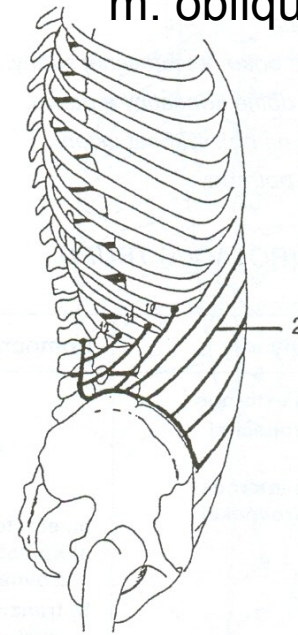
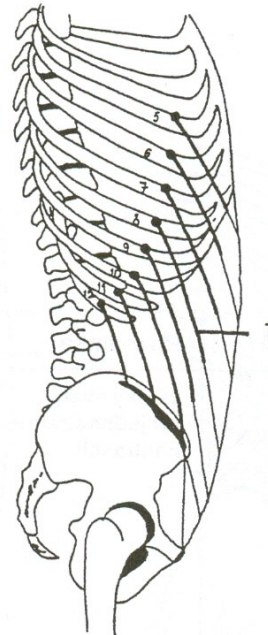
m. obliquus externus abdominis



ROTACE - OTÁČENÍ



m. obliquus internus abdominis



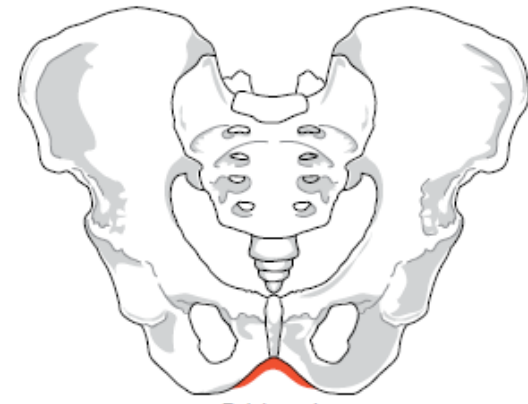
m. obliquus externus abdominis

POHYBY PÁNVE

ELEVACE - ZDVIHNUTÍ

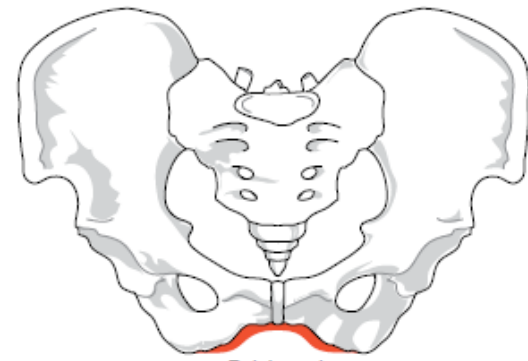
INKLINACE/ANTEVERZE
- VYSAZENÍ

REKLINACE/RETROVERZE
- PODSAZENÍ

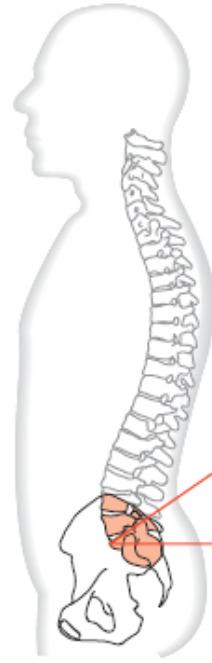

Pelvic arch
Male Pelvis

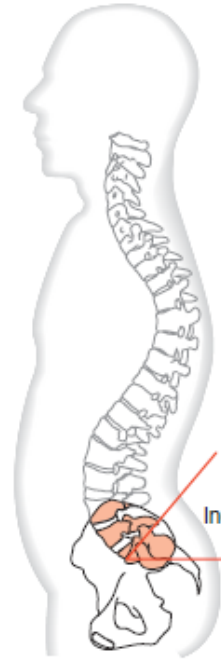A



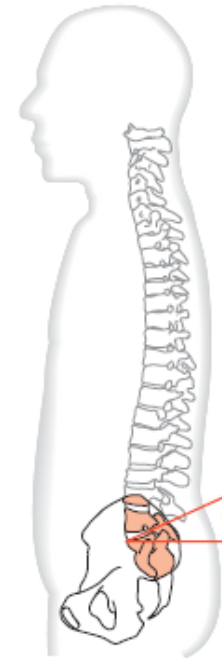Pelvic arch
Female Pelvis



Lumbosacral angle

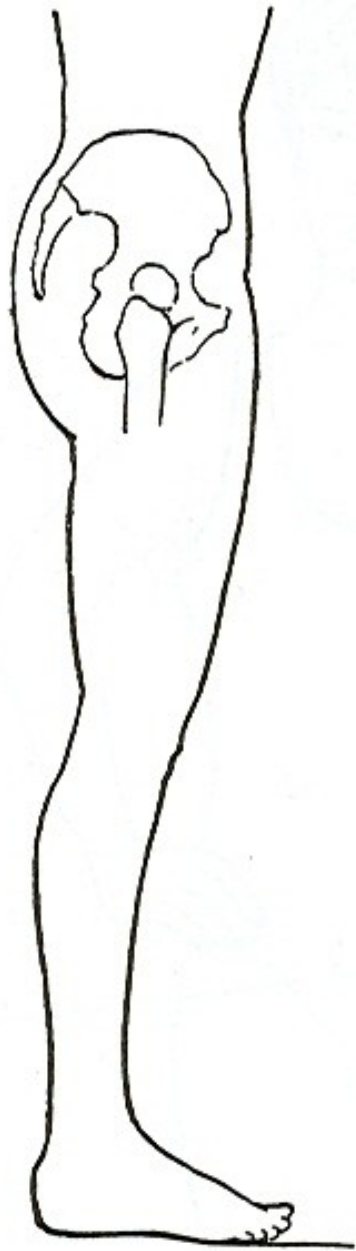


Increased lordosis

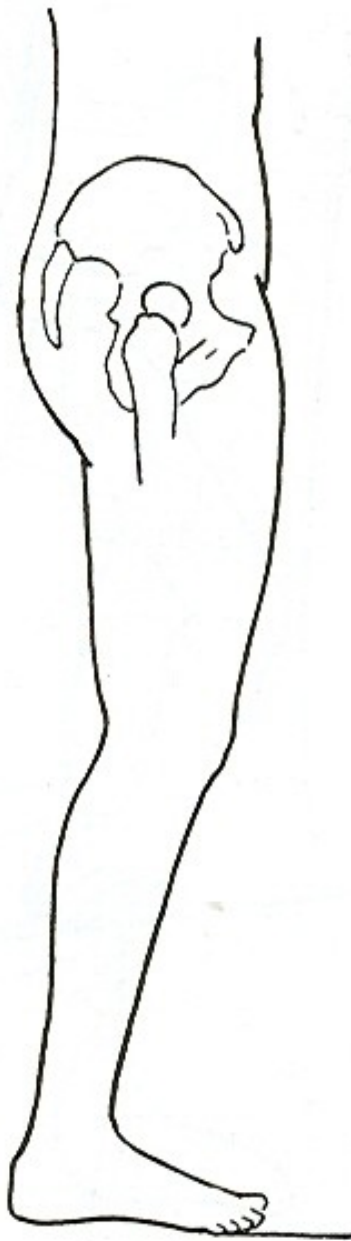


Decreased lordosis

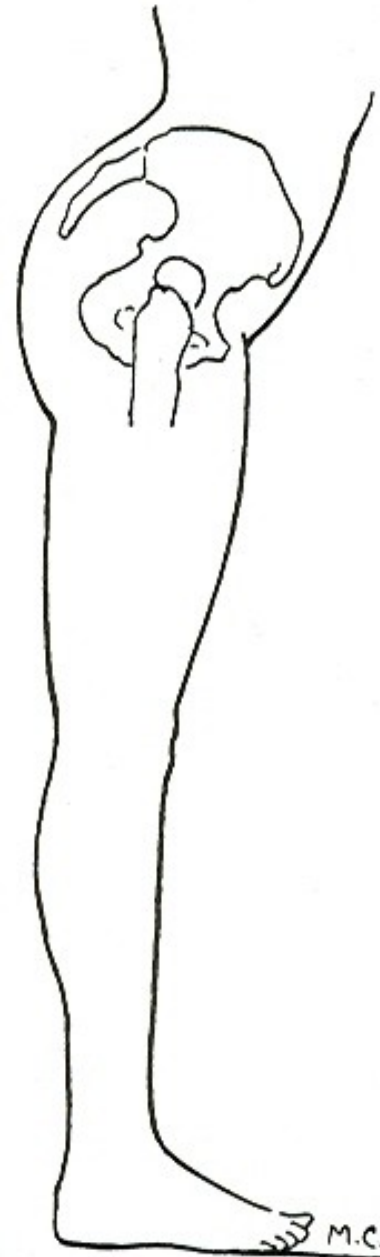
Figure 17-12. The lumbosacral angle is determined by drawing one line parallel to the ground and another line along the base of the sacrum. The angle increases or decreases as lumbar lordosis increases or decreases, respectively.



a.



REKLINACE



INKLINACE

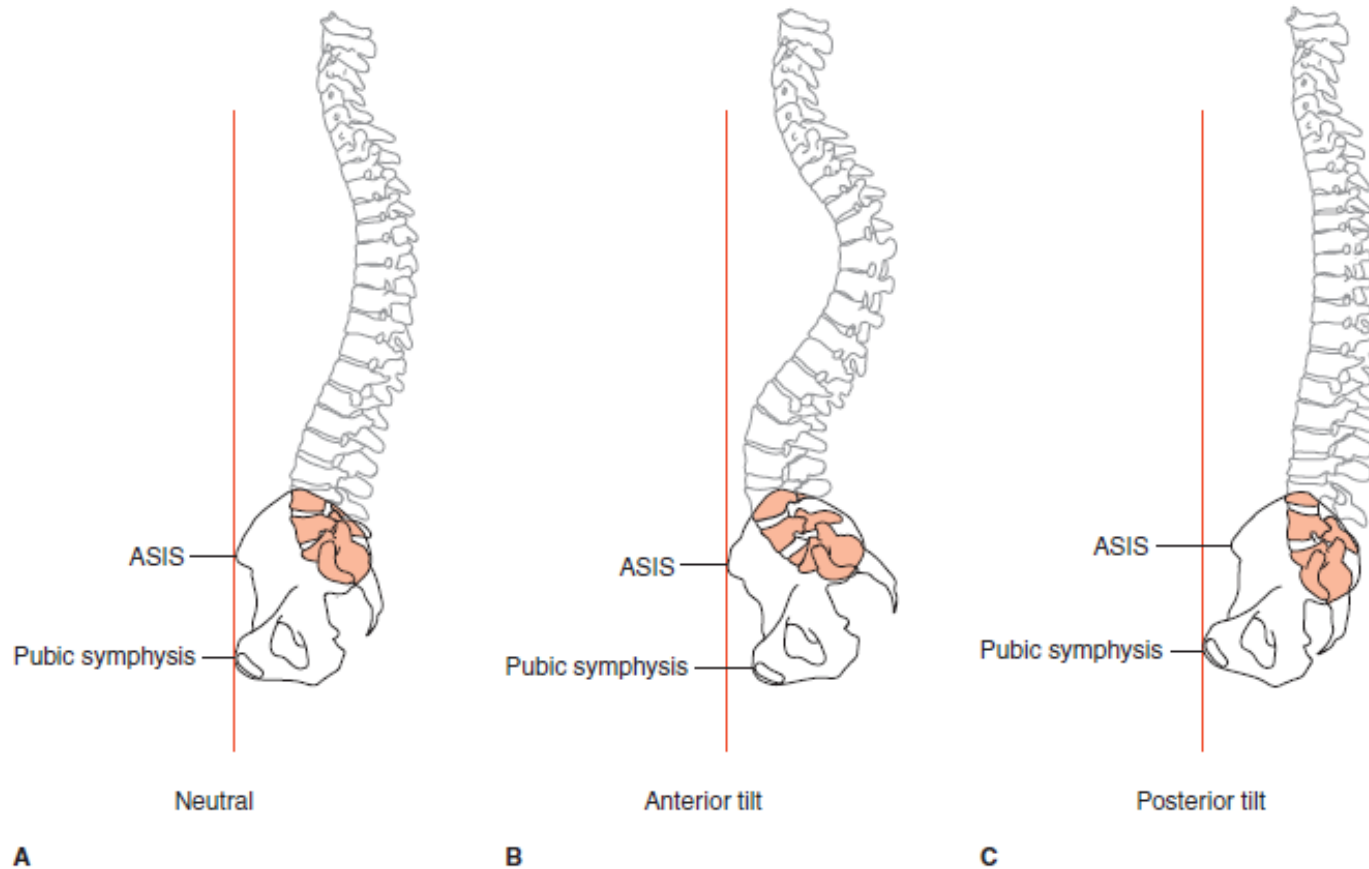


Figure 17-13. Pelvic movement in the sagittal plane. **(A)** The anterior superior iliac spine (ASIS) and the pubic symphysis should be in the same vertical plane. **(B)** Anterior tilt occurs when the pelvis tilts forward, moving the ASIS anterior to the pubic symphysis. **(C)** Posterior tilt occurs when the pelvis tilts backward, moving the ASIS posterior to the pubic symphysis.

Keeping the body upright when the pelvis tilts forward requires the joints above and below the pelvis to move in the opposite direction. Therefore, when the pelvis tilts anteriorly, the lumbar portion of the vertebral column goes into hyperextension and the hip joints flex. Thus, when a person with a hip flexion contracture stands in the upright position, the pelvis tilts anteriorly and the lumbar region hyperextends. Conversely, a person with tight hamstrings may stand with the pelvis tilted posteriorly and the lumbar curve flattened.

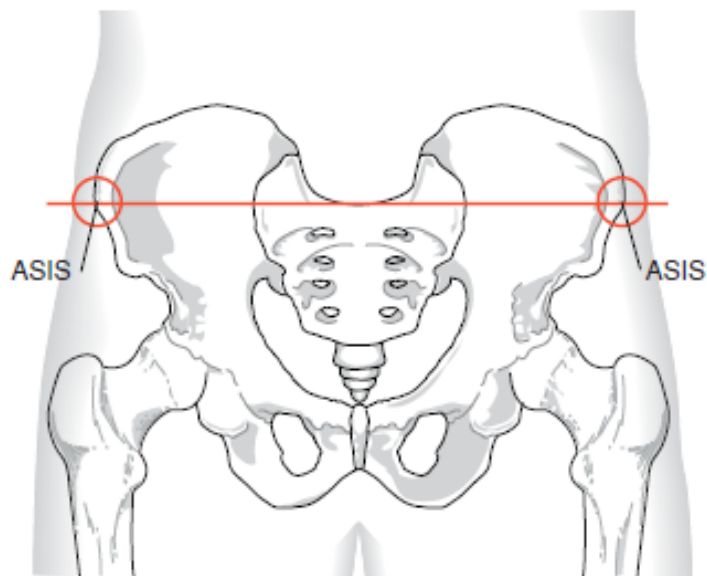


Figure 17-14. Pelvic movement in the frontal plane. When standing upright on both feet, the iliac crests and the ASISs should be level.

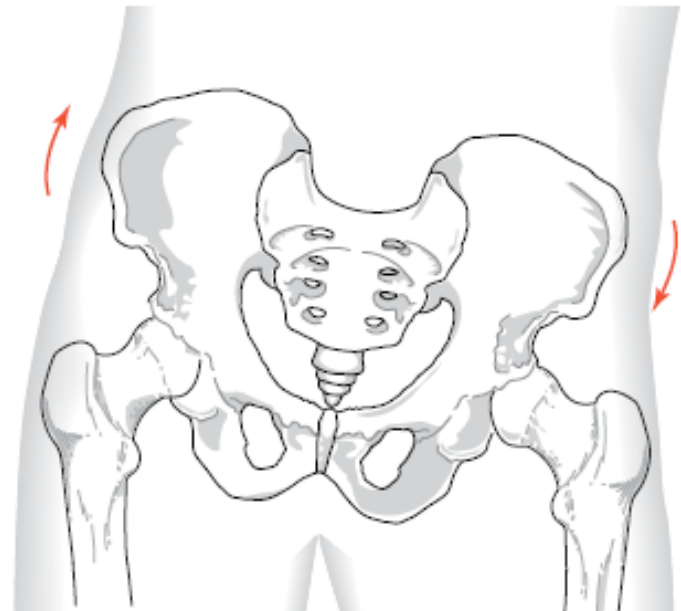


Figure 17-15. Lateral tilt (anterior view). One side of the pelvis moves up while the other side moves down.

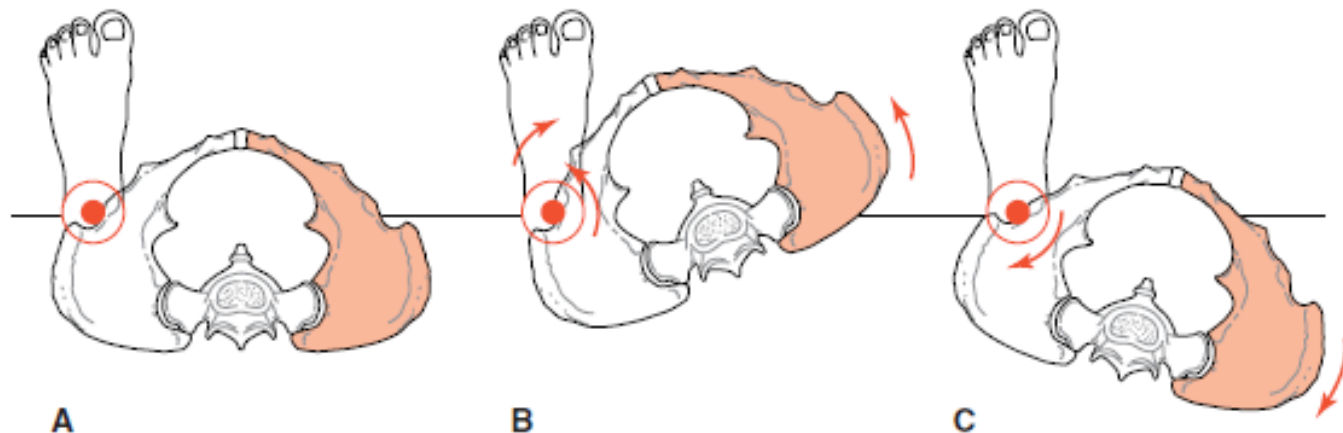


Figure 17-18. Pelvic rotation in the transverse plane (superior view). **(A)** In the anatomical (neutral) position, both ASISs are in the same plane. **(B)** With forward rotation, the pelvis on the right moves forward. This causes the left pelvis to rotate around the femoral head, resulting in hip medial rotation. **(C)** With backward rotation, the pelvis on the right moves backward. This causes the left pelvis to rotate on the femoral head, resulting in hip lateral rotation.

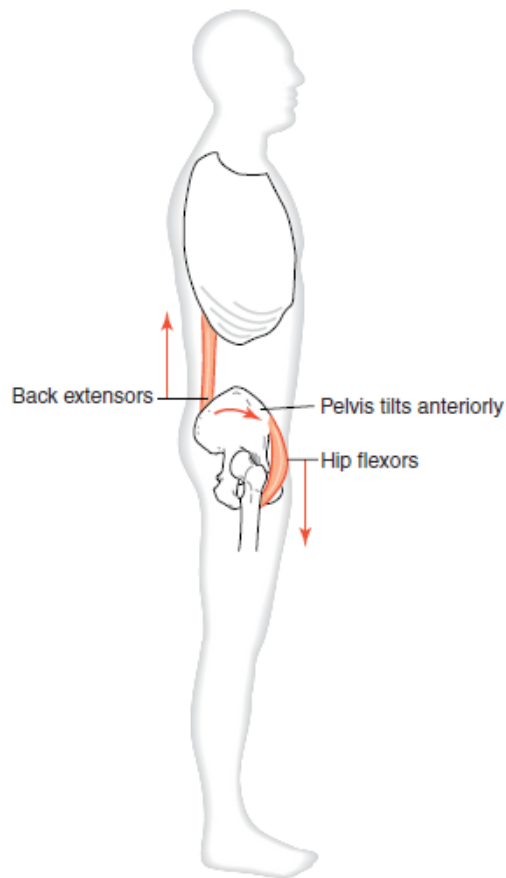


Figure 17-19. Force couple causing anterior pelvic tilt (lateral view). The trunk extensors pulling up (posteriorly) and the hip flexors anterior pulling down (anteriorly) cause the pelvis to tilt anteriorly.

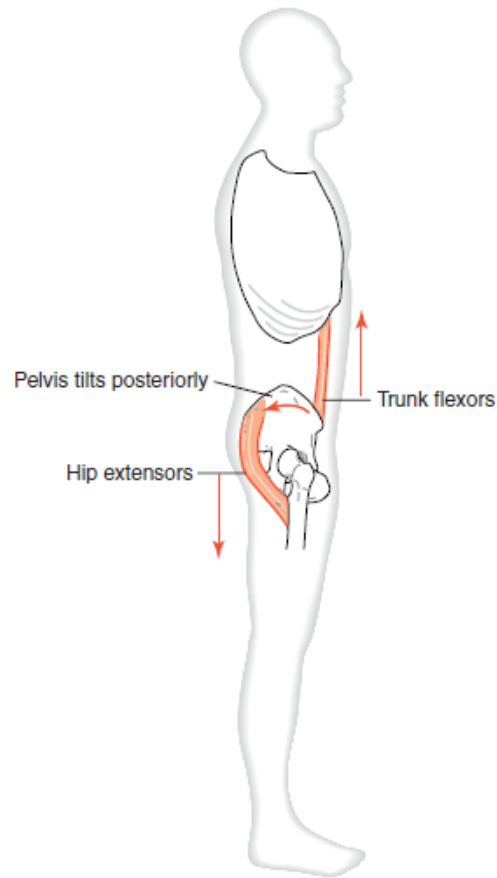


Figure 17-20. Force couple causing posterior pelvic tilt (lateral view). The trunk flexors pulling up (anteriorly) and the hip extensors pulling down (posteriorly) cause the pelvis to tilt posteriorly.

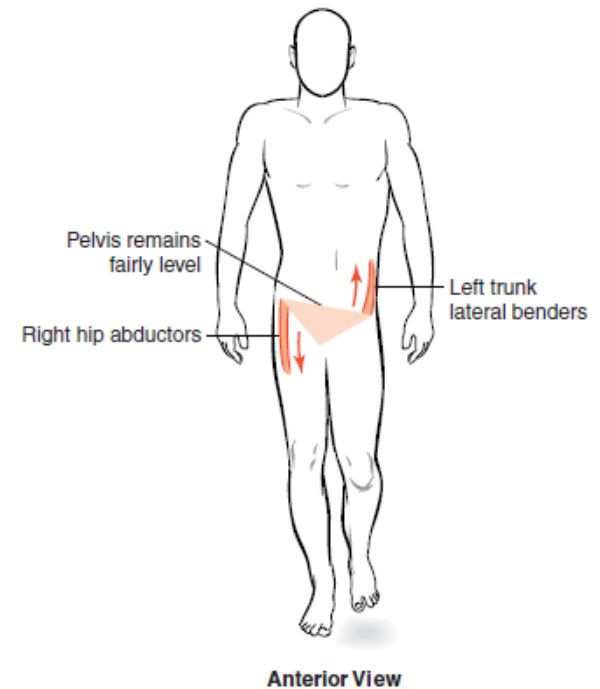


Figure 17-21. Force couple keeps the pelvis level in the frontal plane. In a reversal of muscle action, the left trunk lateral benders pull up while the right hip abductors pull down. This keeps the pelvis fairly level as opposed to letting the pelvis drop on the unsupported side.

Table 17-1 Associated Motions of the Pelvic Girdle, Vertebral Column, and Hip Joints

Pelvic Girdle	Vertebral Column	Hip
Anterior tilt	Hyperextension	Flexion
Posterior tilt	Flexion	Extension
Lateral tilt (unsupported side)	Lateral bending (to supported side)	Adduction: weight-bearing side Abduction: non-weight-bearing side
Rotation (forward)	Rotation: to opposite side	Medial rotation: weight-bearing side
Rotation (backward)	Rotation: to opposite side	Lateral rotation: weight-bearing side

POHYBY LOPATKY

ELEVACE - ZDVIHNUTÍ

DEPRESE - POKLES

PROTRAKCE - ODTAŽENÍ

RETRAKCE - PŘITAŽENÍ

ANTEVERZE – ZEVNÍ ROTACE

RETROVERZE – VNITŘNÍ ROTACE

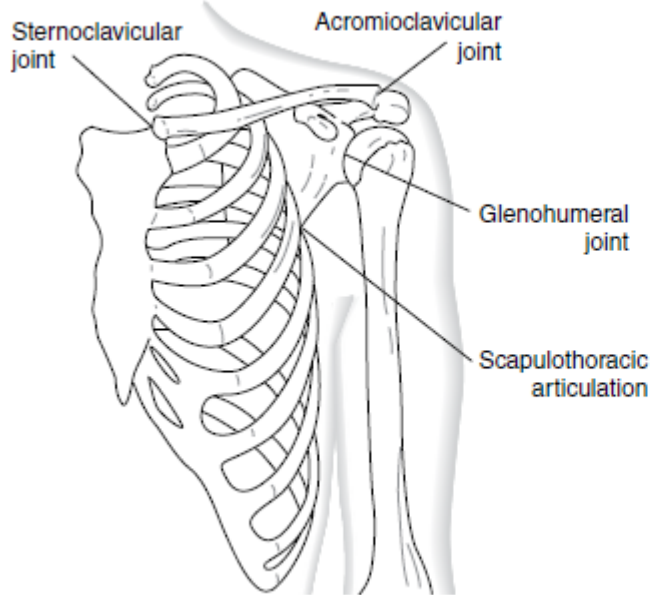


Figure 9-1. The shoulder complex (anterior view).

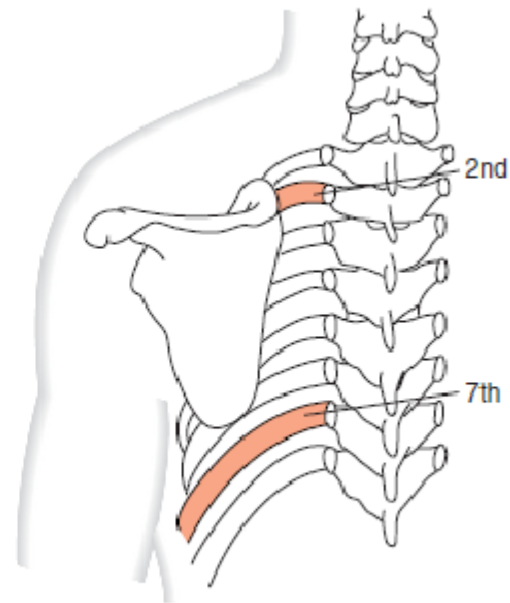


Figure 9-2. Resting position of the scapula on the thorax (posterior view).

Jako referenční bod při rotaci bereme dolní úhel lopatky!

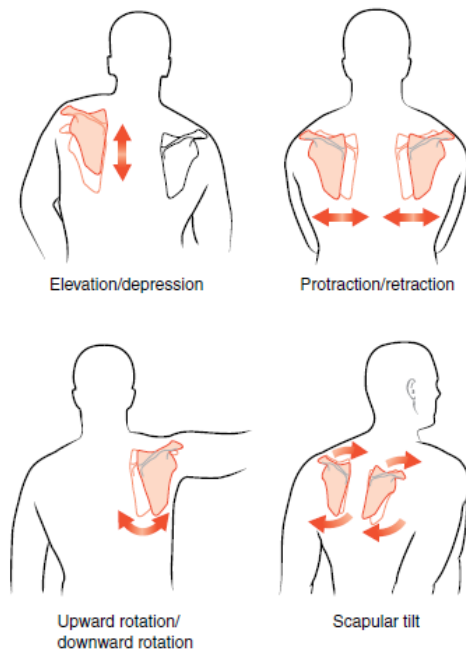


Figure 9-9. Shoulder girdle motions (posterior view).

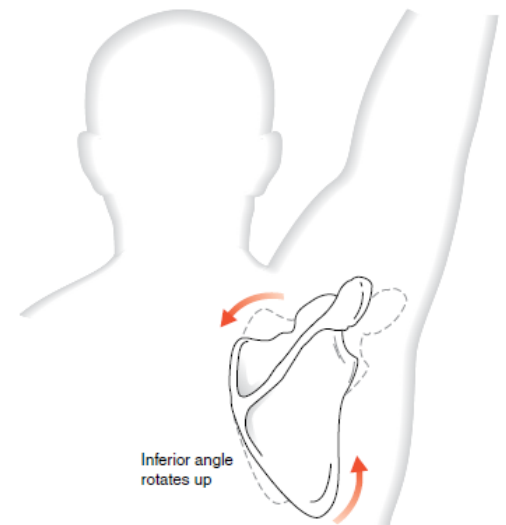
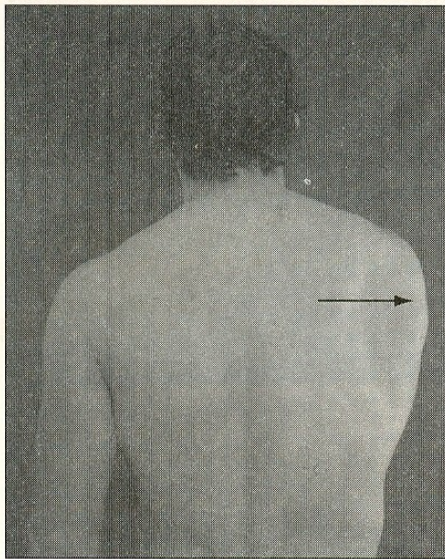
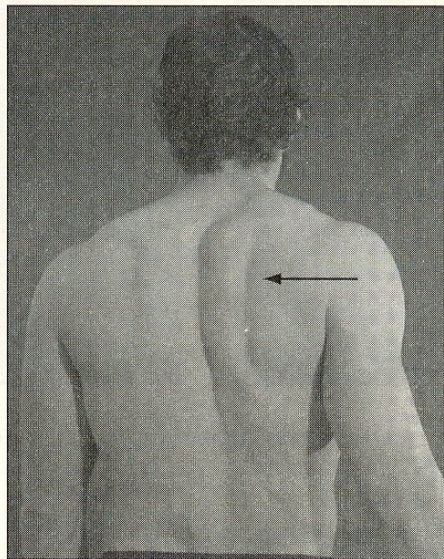


Figure 9-10. Scapular motion during upward rotation.



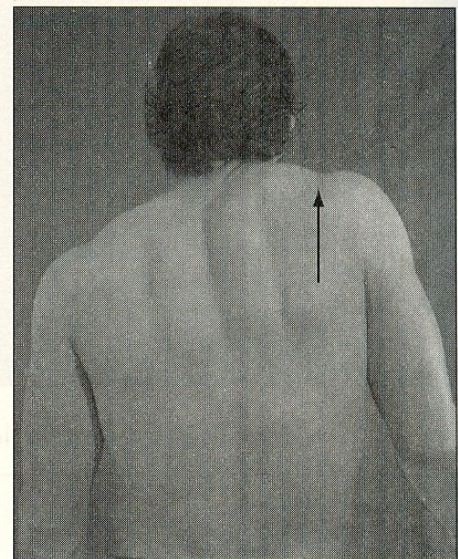
Abduction
(protraction)

A



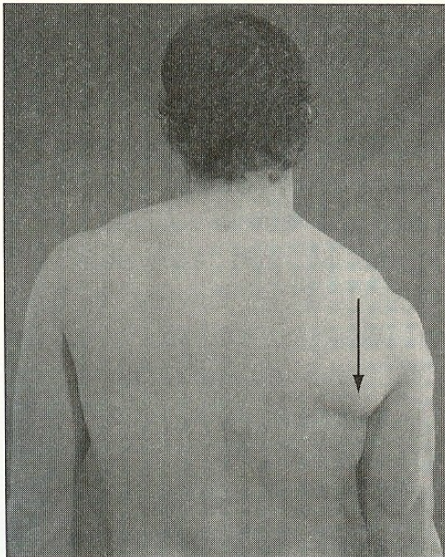
Adduction
(retraction)

B

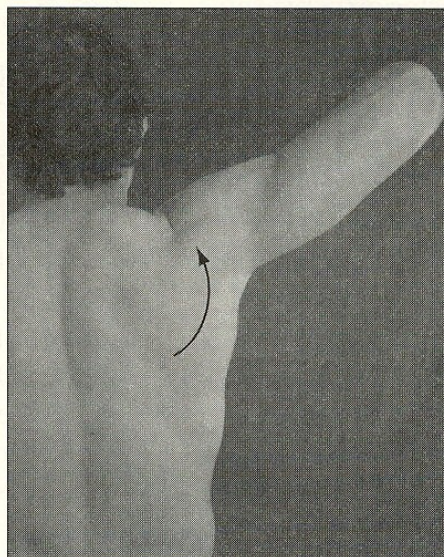


Elevation

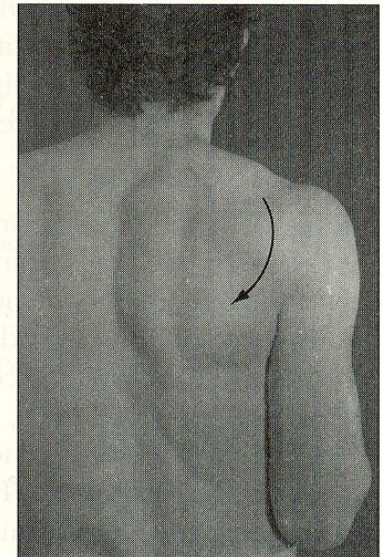
C



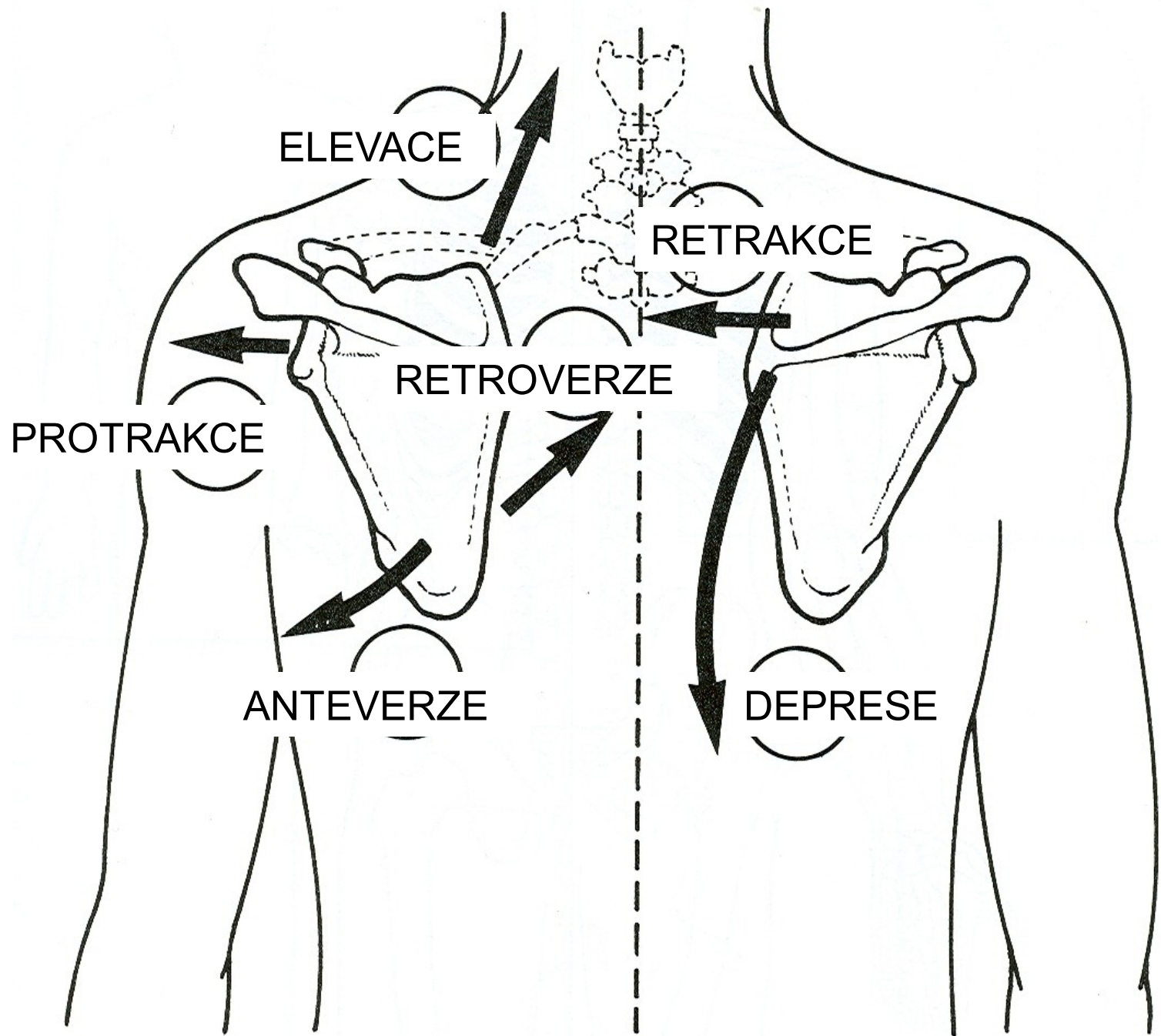
Depression



Upward rotation



Downward rotation



Svaly odpovědné za pohyb lopatky:

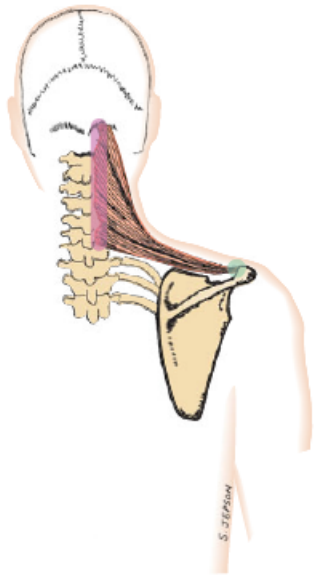
m. Trapezius (zadní sk.)

m. levator scapulae

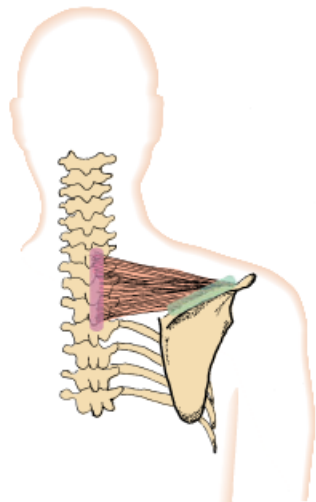
mm. rhomboidei

m. serratus anterior (boční)

m. pectoralis minor (přední)



The upper trapezius muscle (posterior view).



The middle trapezius muscle (posterior view).

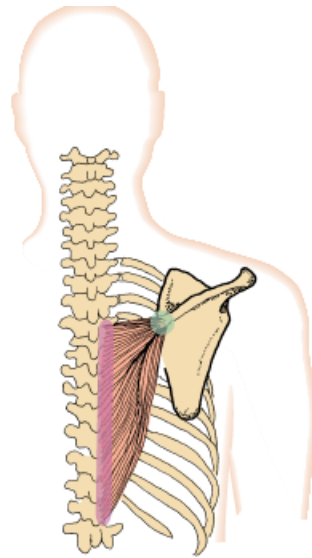


Figure 9-15. The lower trapezius muscle (posterior view).

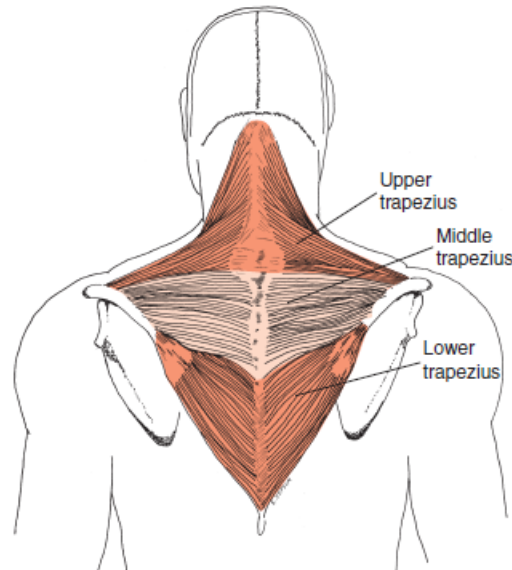


Figure 9-12. The three parts of the trapezius muscle (posterior view).

Upper Trapezius Muscle

- O Occipital bone, nuchal ligament on upper cervical spinous processes
- I Outer third of clavicle, acromion process
- A Scapular elevation and upward rotation
- N Spinal accessory (cranial nerve XI), C3 and C4 sensory component

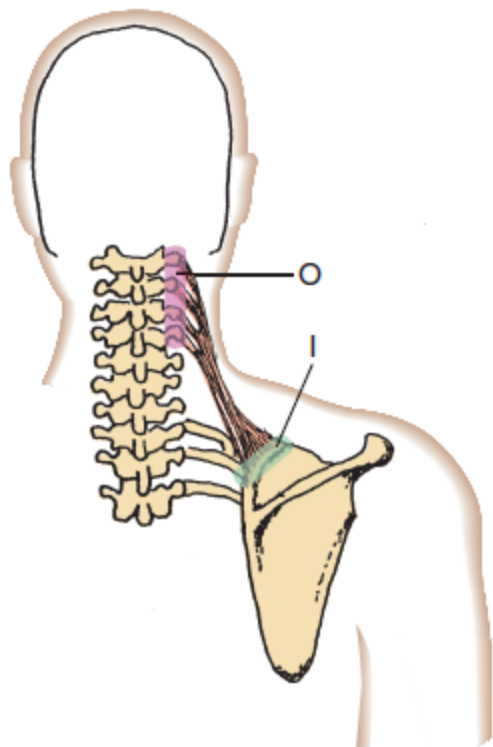
Middle Trapezius Muscle

- O Spinous processes of C7 through T3
- I Scapular spine
- A Scapular retraction
- N Spinal accessory (cranial nerve XI), C3 and C4 sensory component

Lower Trapezius Muscle

- O Spinous processes of middle and lower thoracic vertebrae
- I Base of the scapular spine
- A Scapular depression and upward rotation
- N Spinal accessory (cranial nerve XI), C3 and C4 sensory component

levator scapula



Levator Scapula

- O** Transverse processes of first four cervical vertebrae
- I** Vertebral border of scapula between the superior angle and spine
- A** Scapular elevation and downward rotation
- N** Third and fourth cervical nerves and dorsal scapular nerve

Vnitřní rotace – návrat do anatomického postavení lopatky!

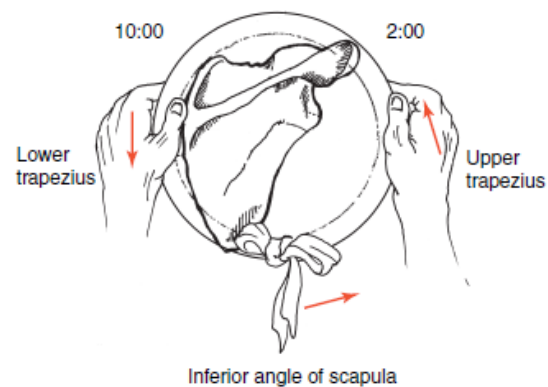
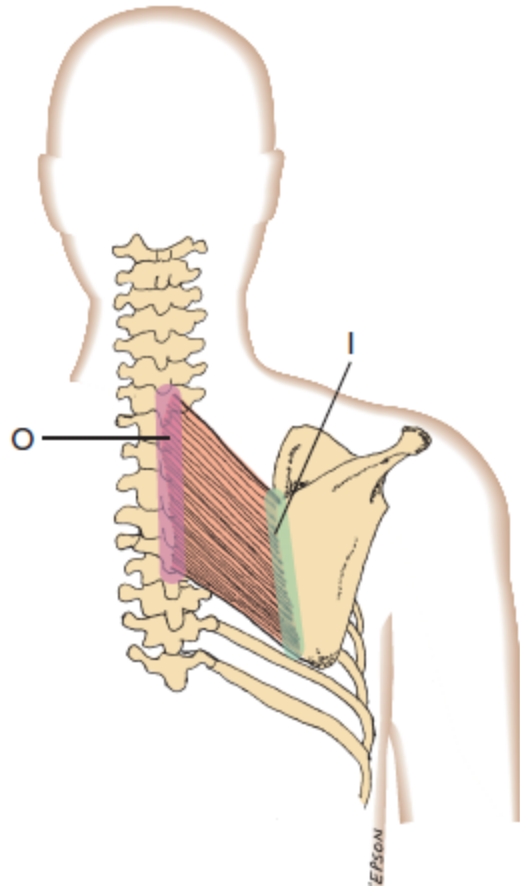


Figure 9-16. Rotational movement of the right scapula.

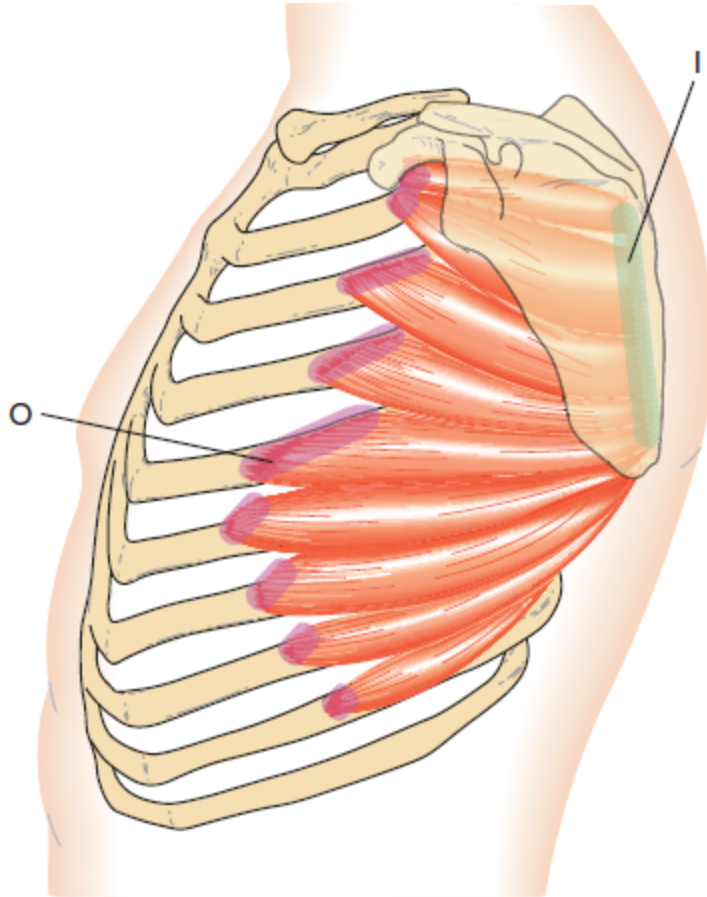
rhomboids



Rhomboids

- O** Spinous processes of C7 through T5
- I** Vertebral border of scapula between the spine and inferior angle
- A** Scapular retraction, elevation, and downward rotation
- N** Dorsal scapular nerve

serratus anterior

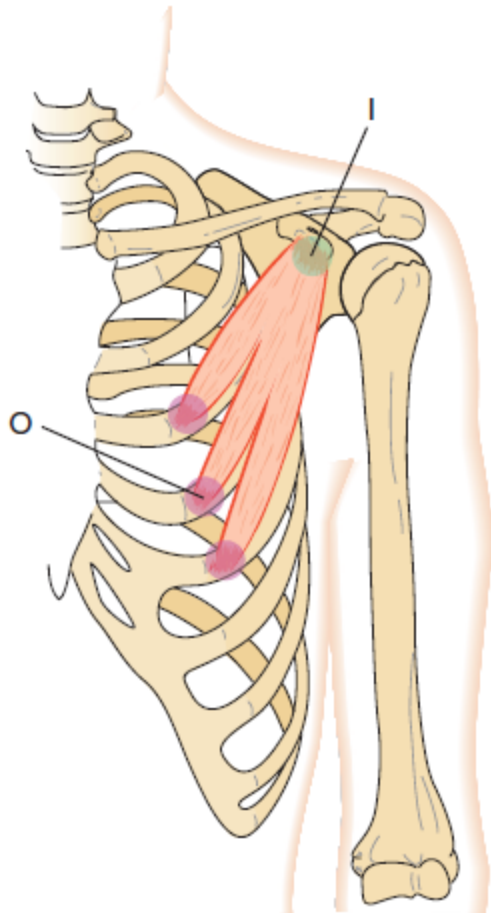


Serratus Anterior

- O** Lateral surface of the upper eight ribs
- I** Vertebral border of the scapula, anterior surface
- A** Scapular protraction and upward rotation
- N** Long thoracic nerve

Udržuje vnitřní plochu lopatky v optimálním postavení k žebřům, disfunkce vede k tzv. scapula alata (winged scapula)

pectoralis minor



Pectoralis Minor

- O** Anterior surface, third through fifth ribs
- I** Coracoid process of the scapula
- A** Scapular depression, protraction, downward rotation, and tilt
- N** Medial pectoral nerve

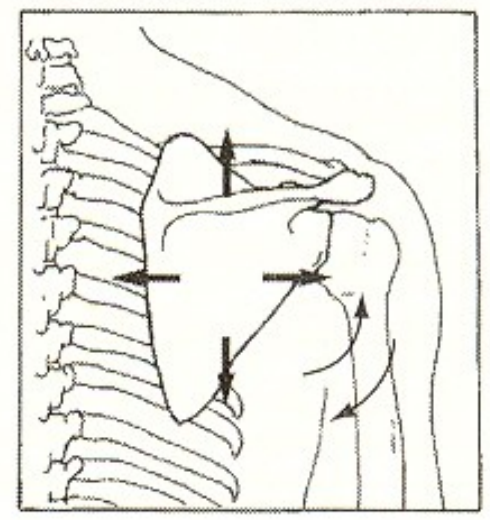
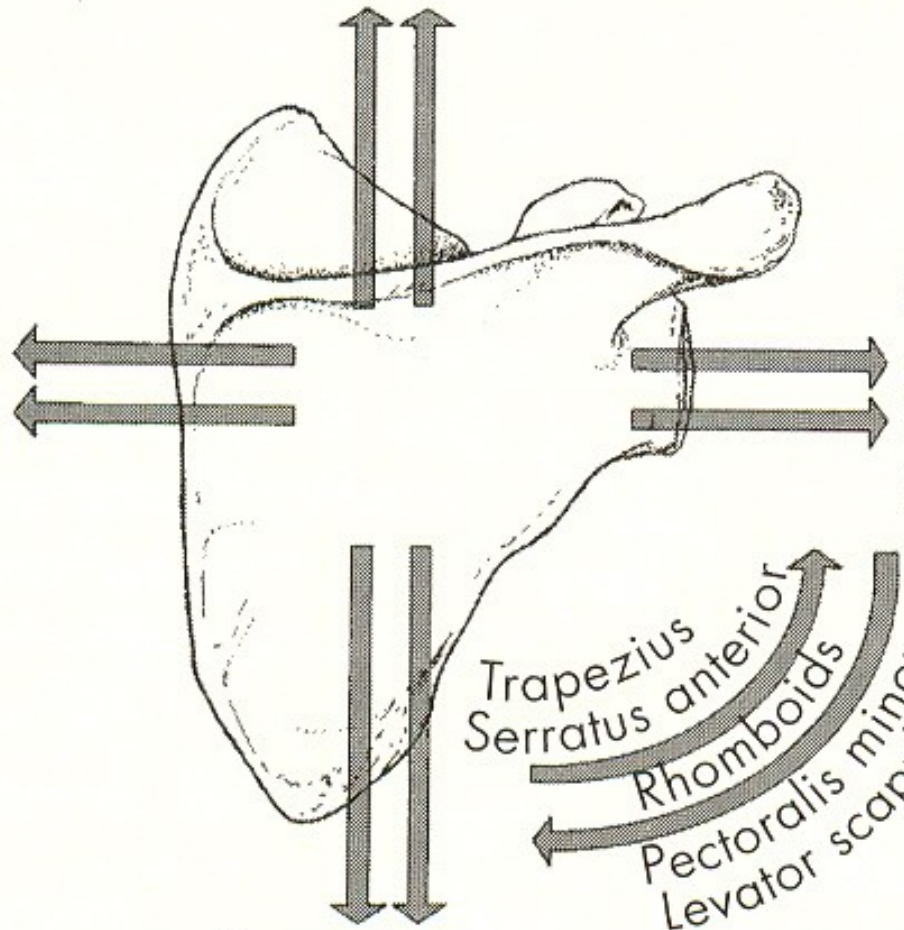
Rhomboids
Trapezius
Levator scapulae

Rhomboids
Trapezius
Levator scapulae

Serratus Anterior
Pectoralis minor

Trapezius
Pectoralis minor

Trapezius anterior
Serratus anterior
Rhomboids
Pectoralis minor
Levator scapulae



Skapulohumerální rytmus (2:1):

Popisuje vztah mezi pohybem ramenního pletence a ramenního kloubu.

Do 30 stupňů je možná čistá abdukce (flexe) v ramenním kloubu. Nad tento úhel je potřeba pro každé 2 stupně o jeden stupeň rotovat lopatku.

Jde o tzv. píd'alkový efekt –

Deltový sval by rychle vyčerpal svoji schopnost kontrakce (byl by zkrácený) díky pohybu lopatky dojde k opětovnému protažení a je možné sval kontrahovat.

Shoulder Joint

Flexion

Extension

Hyperextension

Abduction

Adduction

Medial rotation

Lateral rotation

Horizontal abduction

Horizontal adduction

Shoulder Girdle

Upward rotation; protraction

Downward rotation; retraction

Scapular tilt

Upward rotation

Downward rotation

Protraction

Retraction

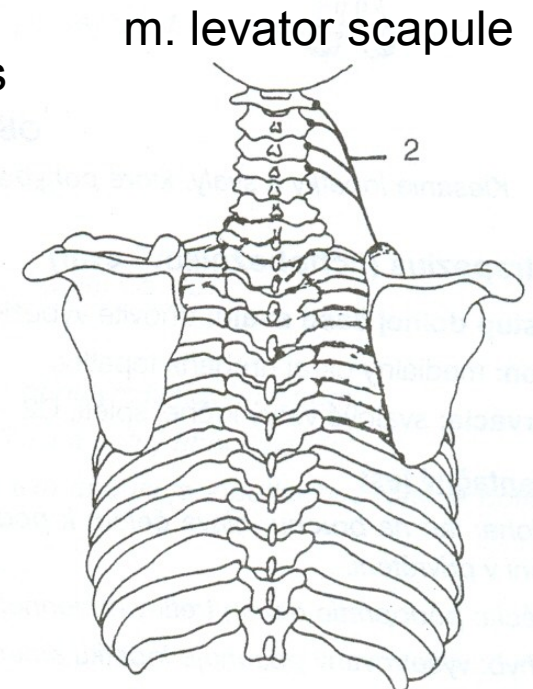
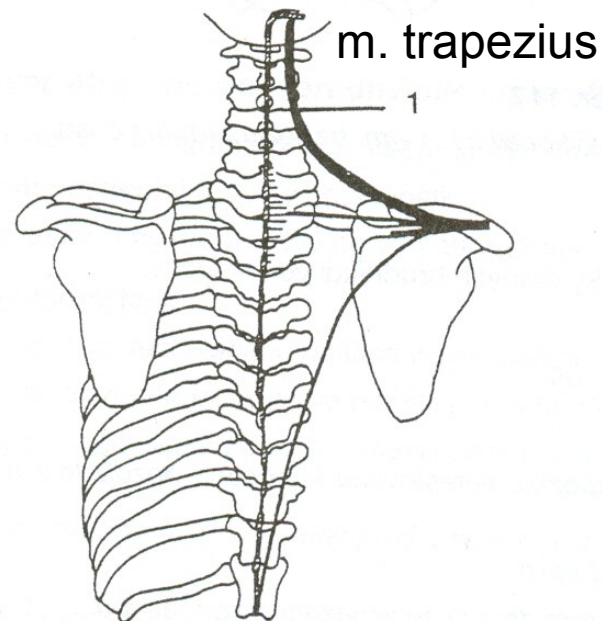
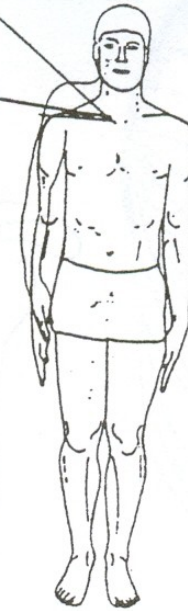Retraction

Protraction

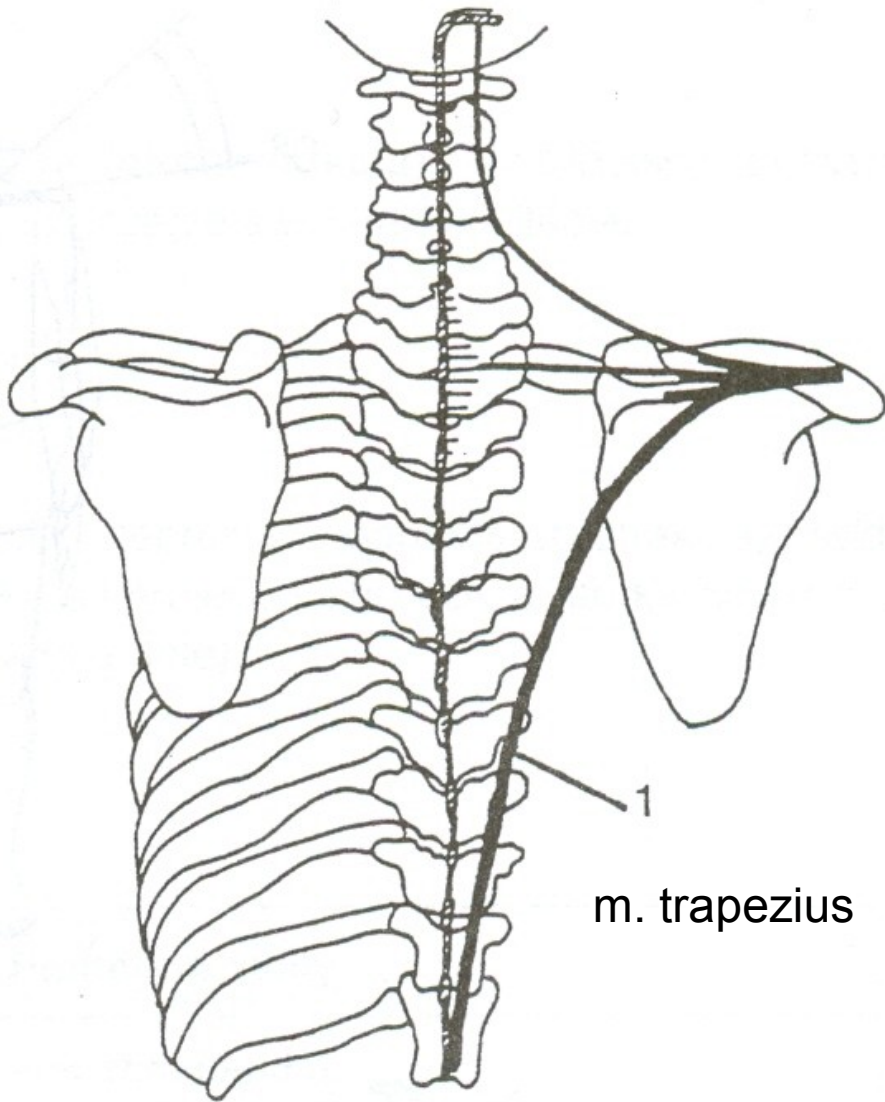
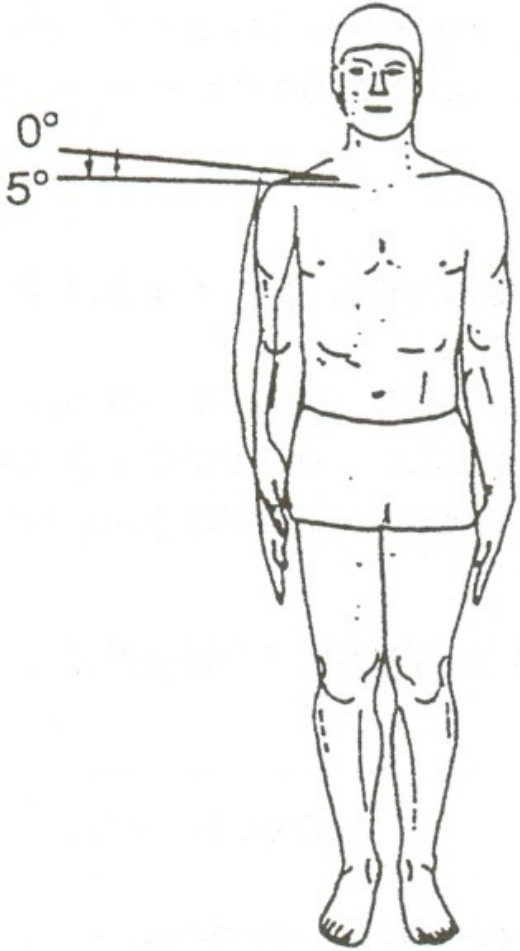
ELEVACE - ZDVIHNUTÍ

35° - 40°

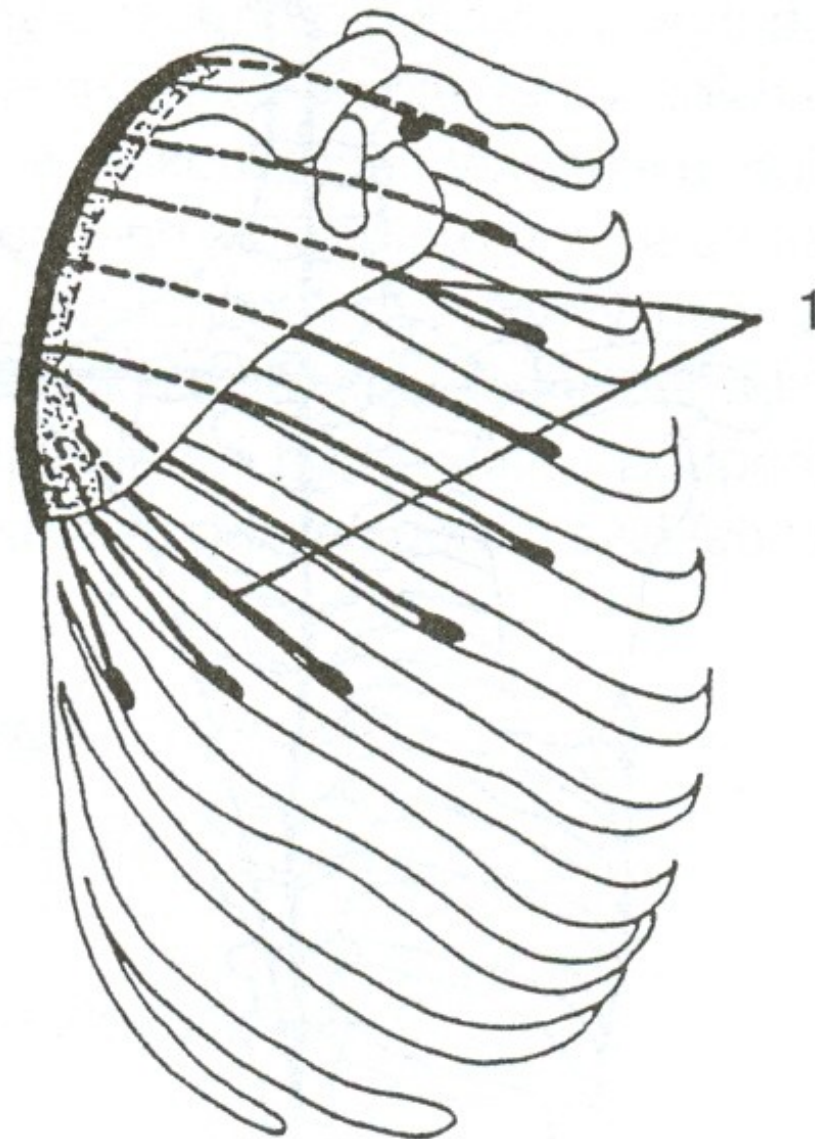
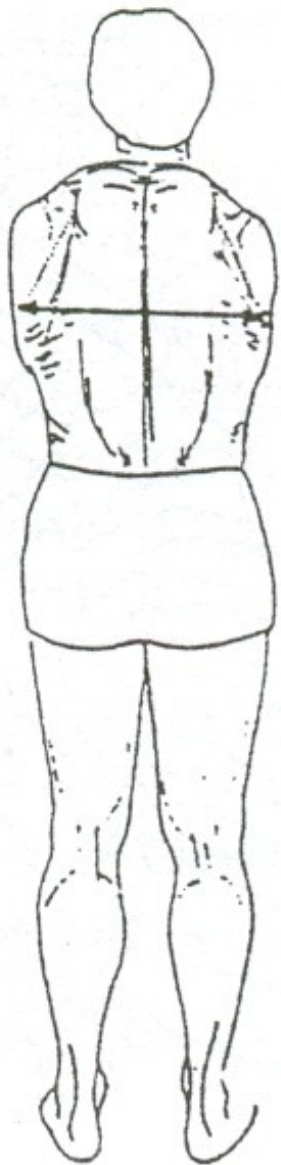
0°



DEPRESE - POKLES



PROTRAKCE - ODTAŽENÍ

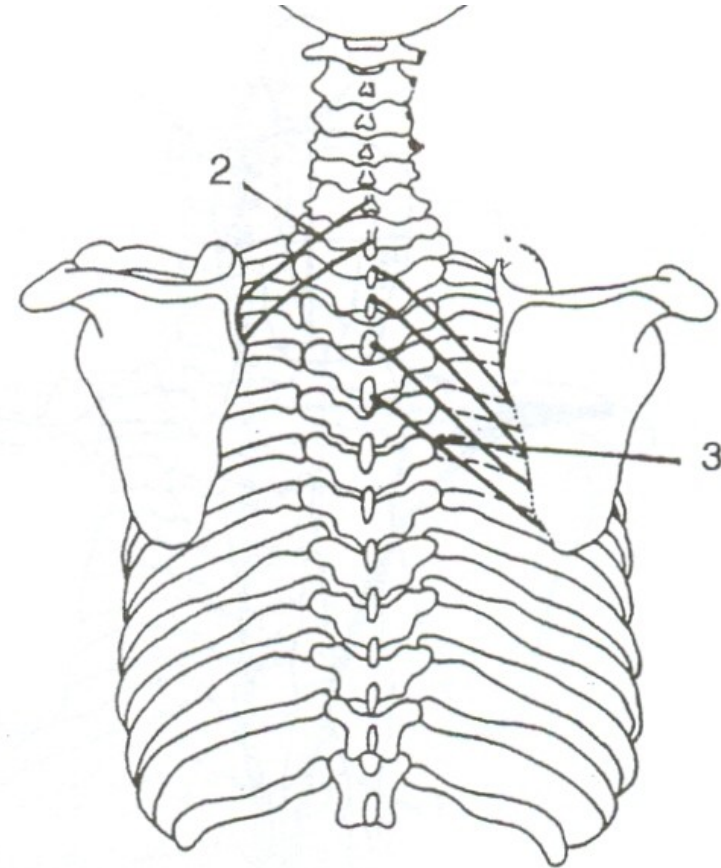
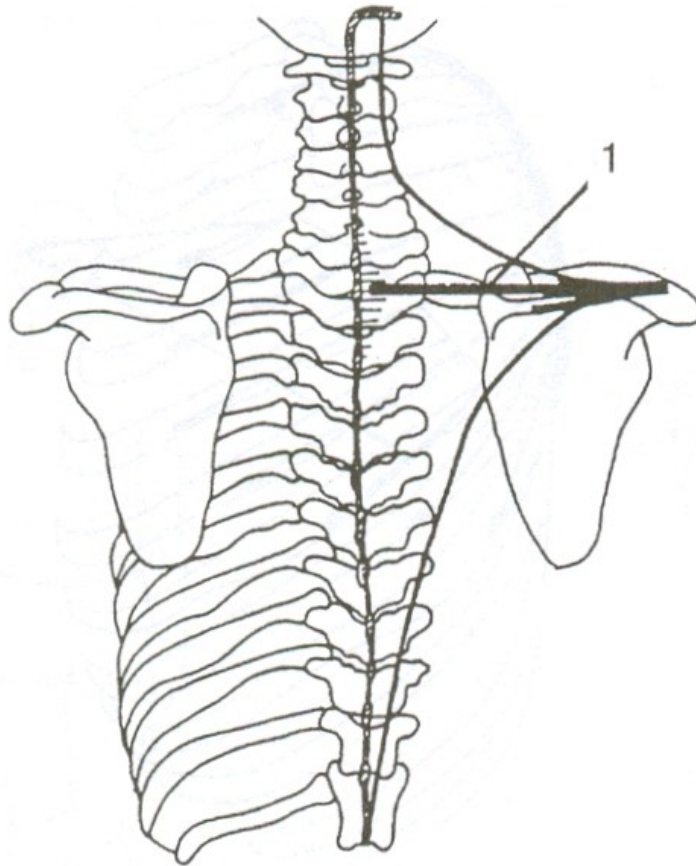
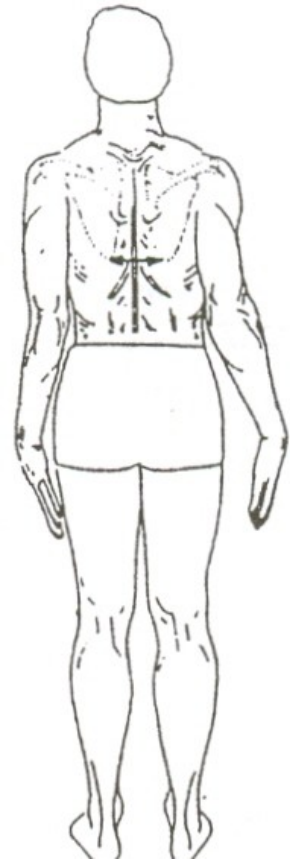

m. serratus anterior

RETRAKCE - PŘITAŽENÍ

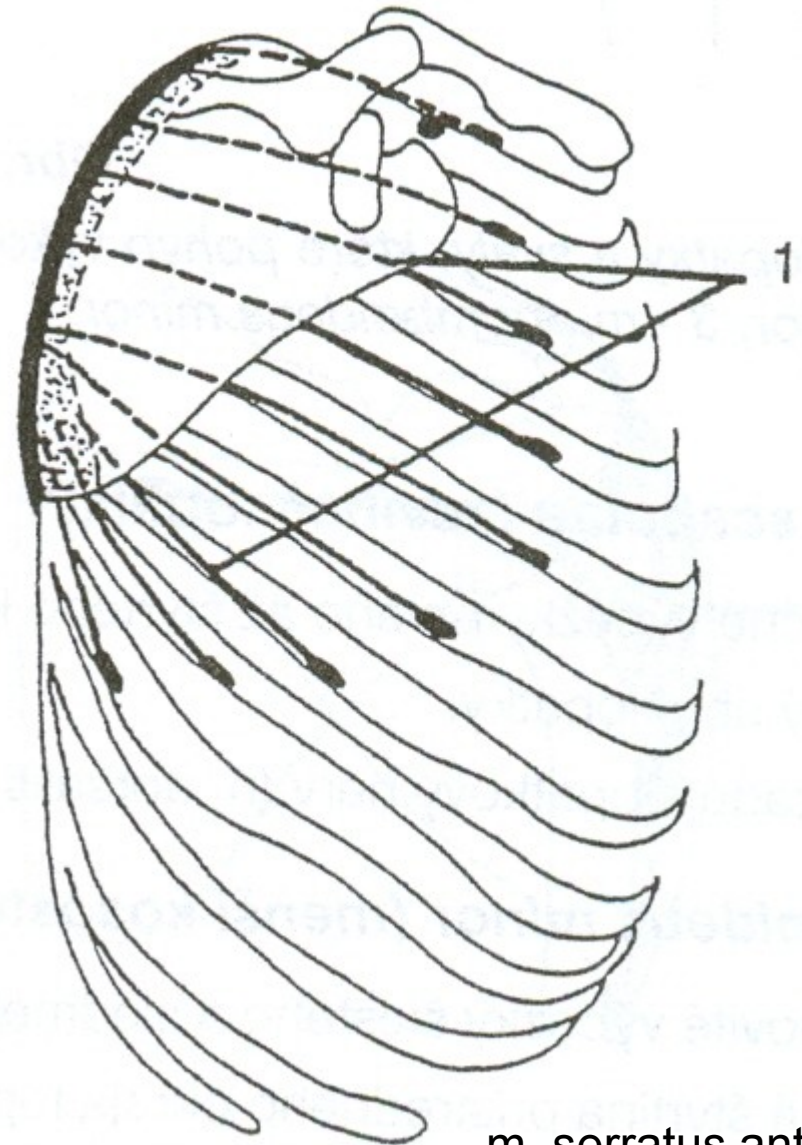
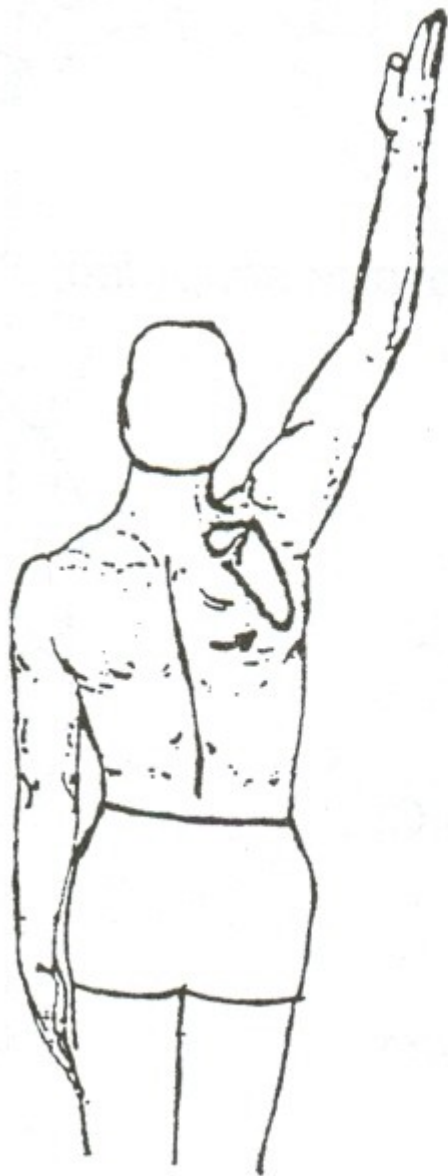
m. trapezius

m. rhomboideus minor



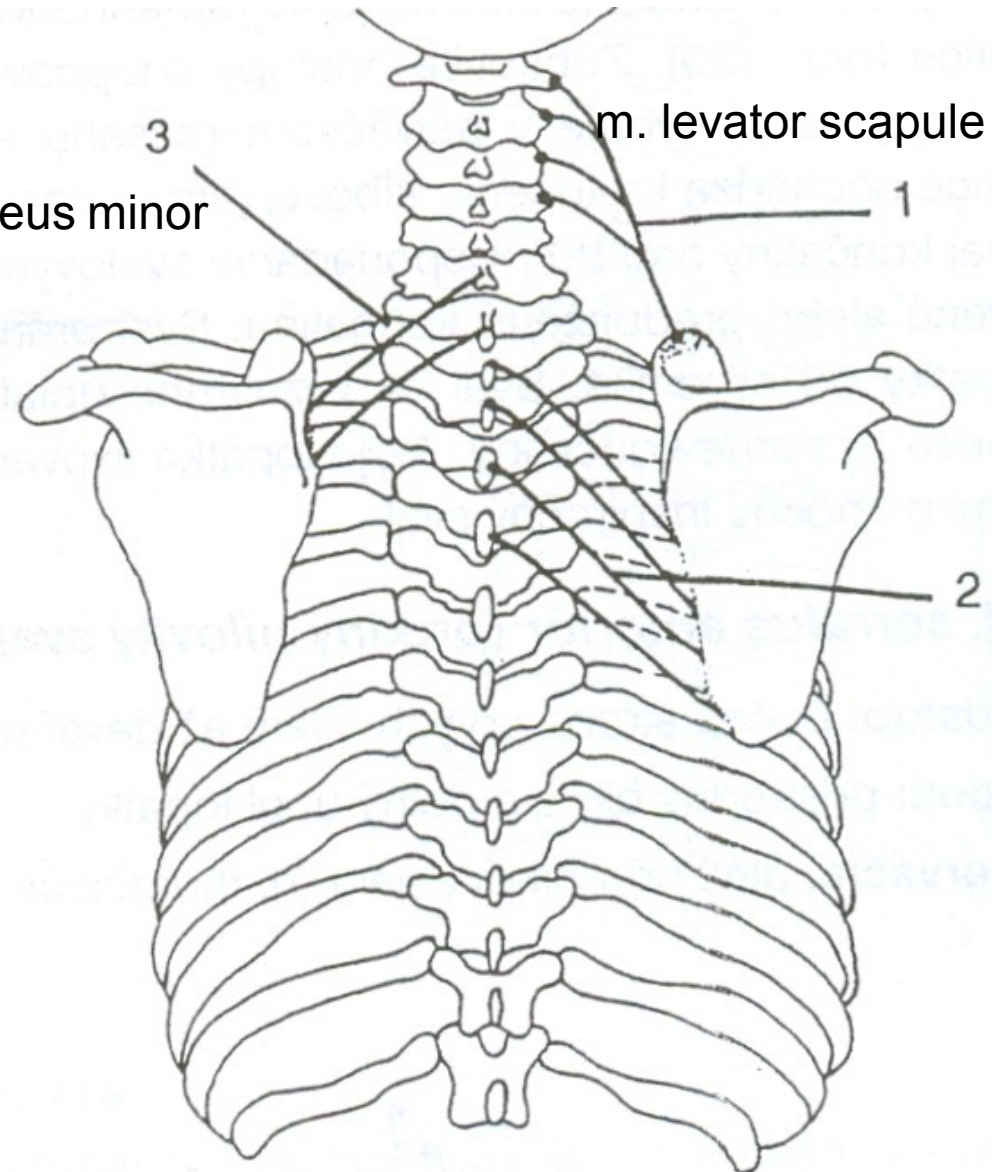
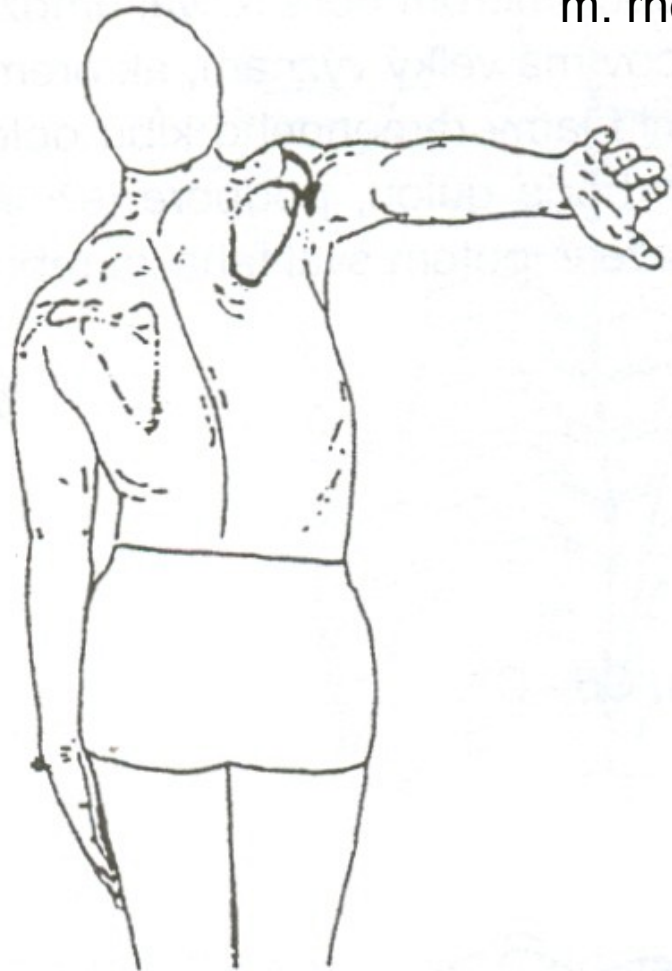m. rhomboideus major

ANTEVERZE – ZEVNÍ ROTACE



m. serratus anterior

RETROVERZE – VNITŘNÍ ROTACE



m. rhomboideus major