

POHYBY HORNÍCH KONČETIN



POHYBY RAMENNÍHO KLOUBU

FLEXE - PŘEDPAŽENÍ

EXTENZE - ZAPAŽENÍ

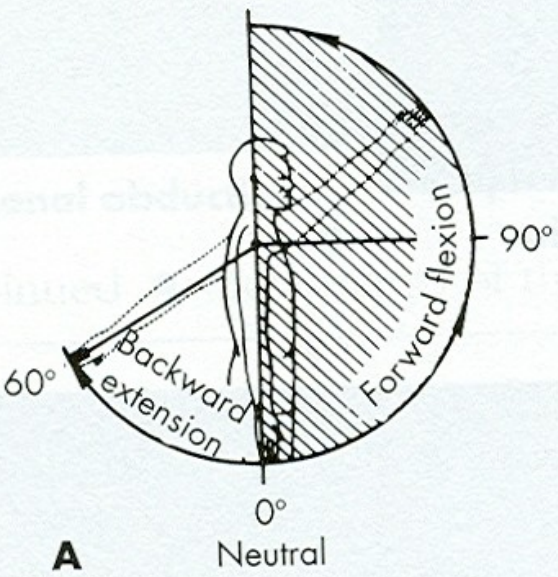
ABDUKCE - UPAŽENÍ

ADDUKCE - PŘIPAŽENÍ

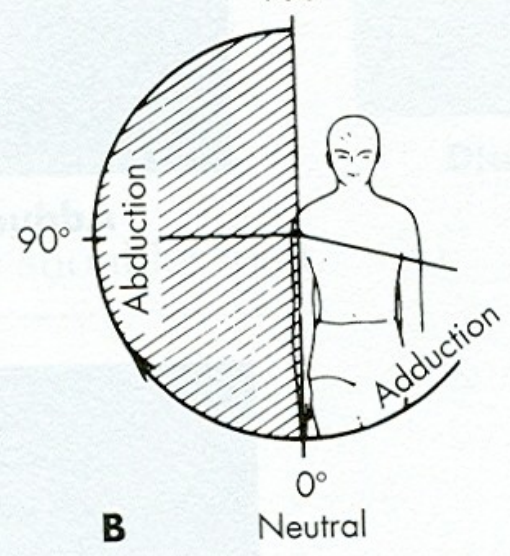
VNITŘNÍ ROTACE

VNĚJŠÍ ROTACE

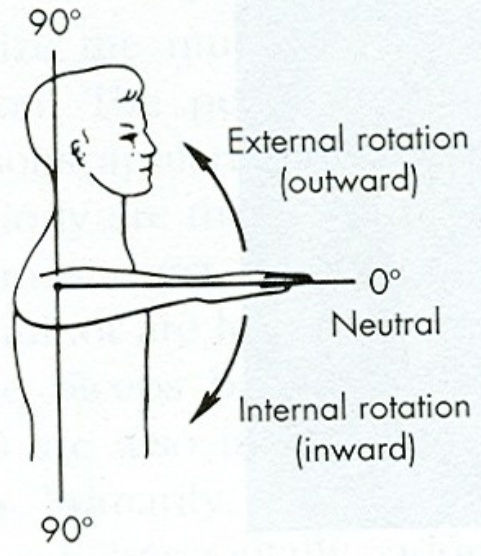
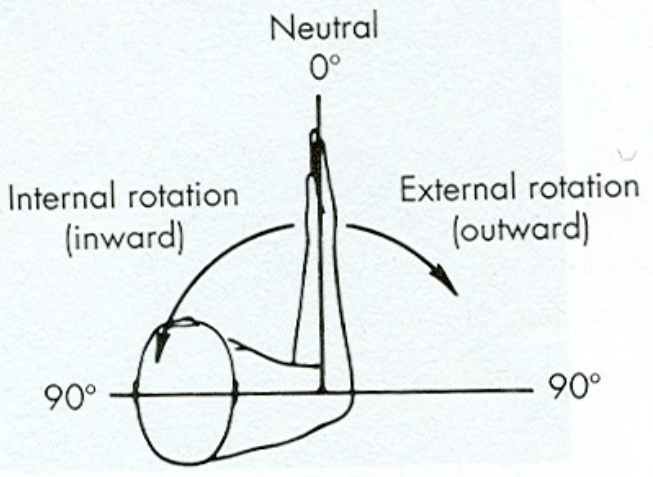
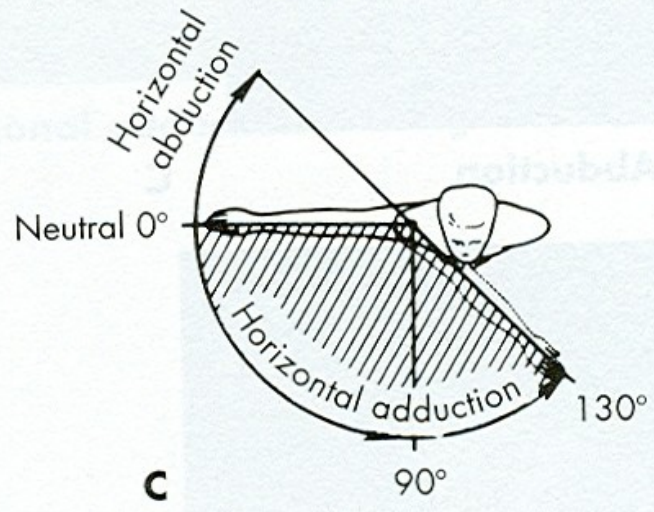
SAGITTAL PLANE
180°



FRONTAL PLANE
180°

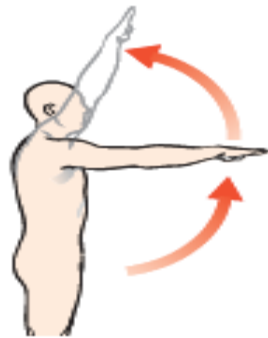


HORIZONTAL PLANE
180°

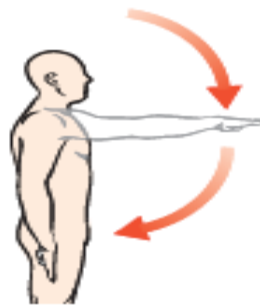

D

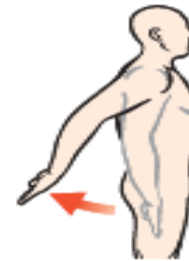E



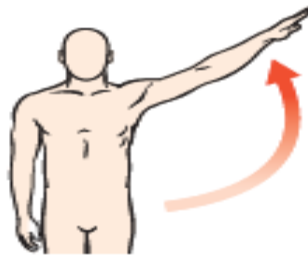
Flexion



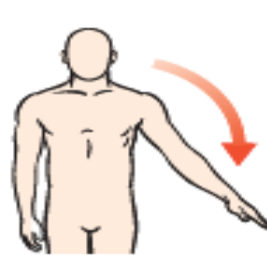
Extension



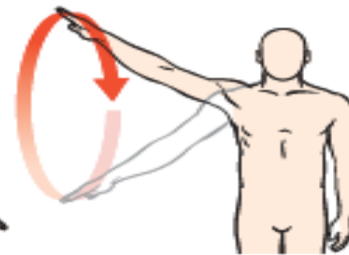
Hyperextension



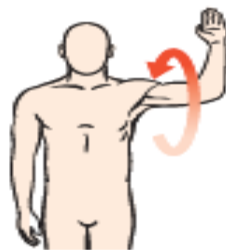
Abduction



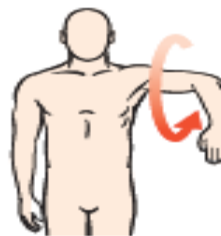Adduction



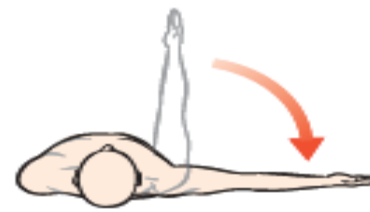Circumduction



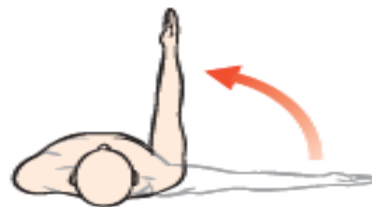Lateral rotation



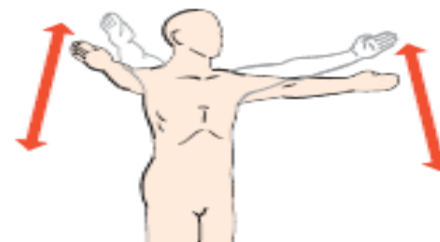Medial rotation



Horizontal abduction



Horizontal adduction



Scaption

Figure 10-2. Shoulder joint motions.

Muscles of the Shoulder Joint

The muscles that span the shoulder joint are as follows:

- Deltoid
- Pectoralis major
- Latissimus dorsi
- Teres major
- Supraspinatus
- Infraspinatus
- Teres minor
- Subscapularis
- Coracobrachialis
- Biceps brachii
- Triceps brachii, long head

Biceps a triceps jsou vícekloubové svaly – jejich primární funkce je ve funkci loketního kloubu – tzn. budou probrány později

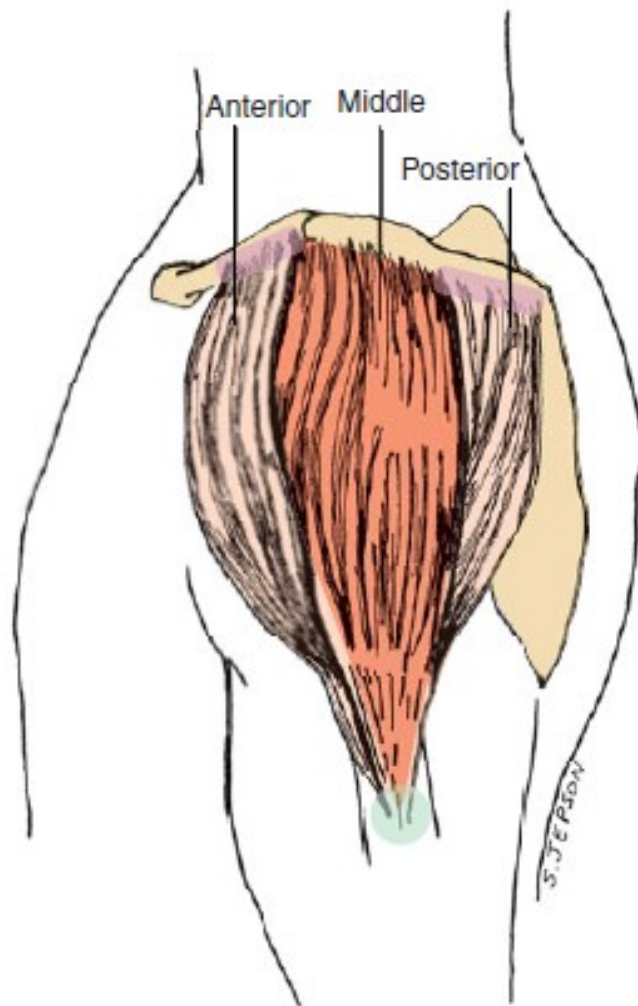


Figure 10-8. The three parts of the deltoid muscle (lateral view).

Anterior Deltoid Muscle

- O Lateral third of the clavicle
- I Deltoid tuberosity
- A Shoulder abduction, flexion, medial rotation, and horizontal adduction
- N Axillary nerve (C5, C6)

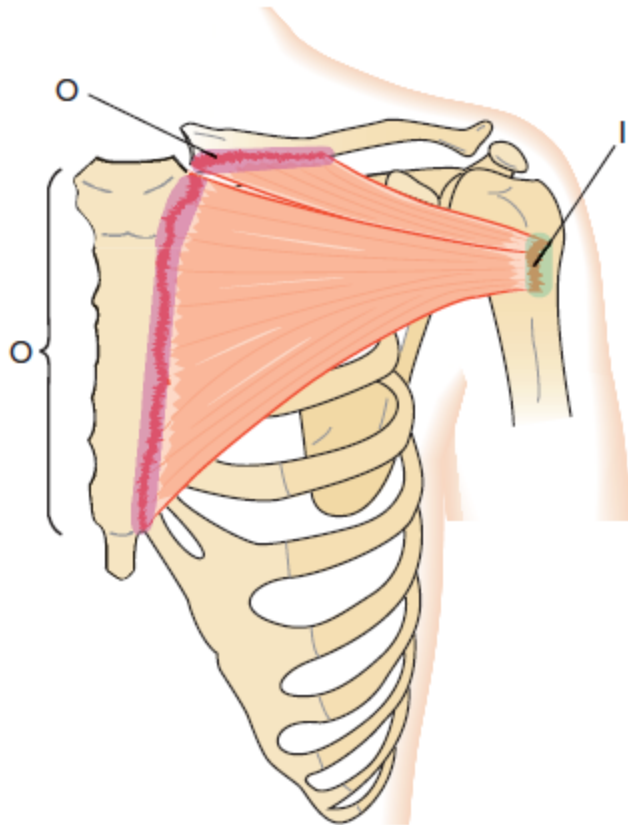
Middle Deltoid Muscle

- O Acromion process
- I Deltoid tuberosity (same as anterior deltoid muscle)
- A Shoulder abduction
- N Axillary nerve (C5, C6)

Posterior Deltoid Muscle

- O Spine of scapula
- I Deltoid tuberosity (same as anterior deltoid muscle)
- A Shoulder abduction, extension, hyperextension, lateral rotation, horizontal abduction
- N Axillary nerve (C5, C6)

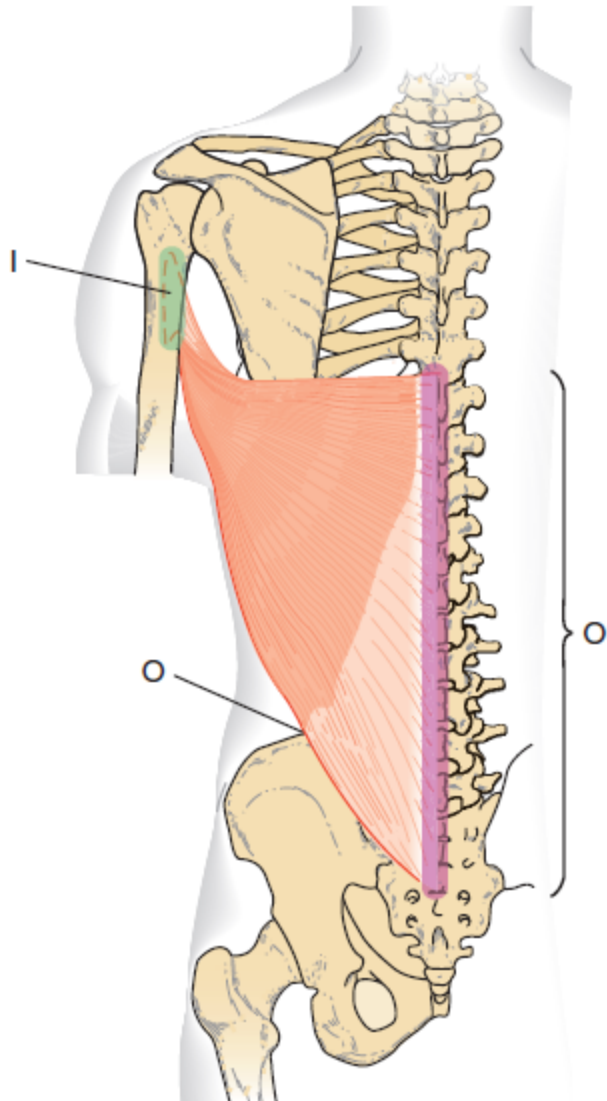
pectoralis major



Pectoralis Major

- O** Medial third of clavicle, sternum, costal cartilage of first six ribs
- I** Lateral lip of bicipital groove of humerus
- A** Both: Shoulder adduction, medial rotation, horizontal adduction
Clavicular portion: Shoulder flexion to approximately first 60 degrees
Sternal portion: Shoulder extension to approximately first 60 degrees (180° - 120°)
- N** Lateral and medial pectoral nerve

latissimus dorsi



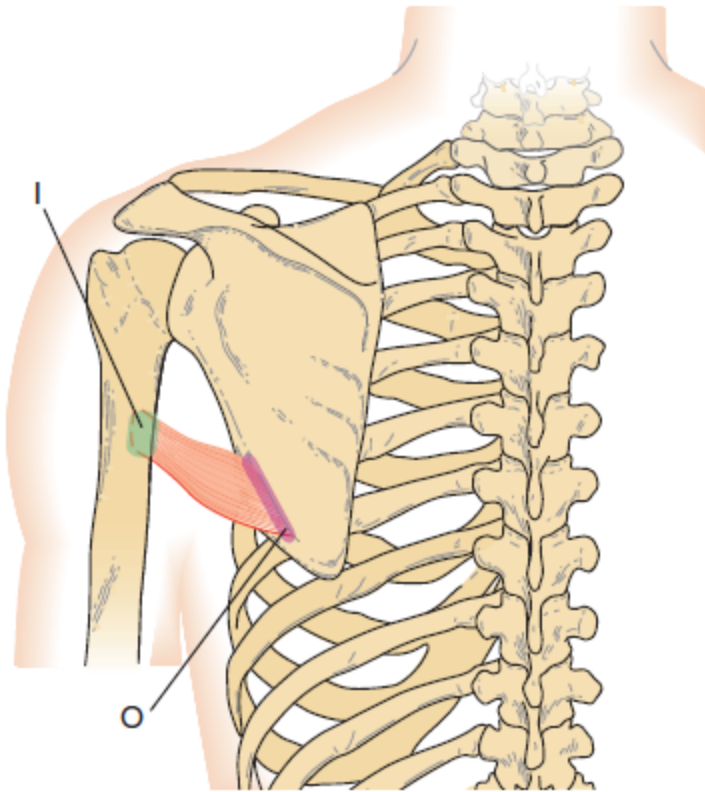
Latissimus Dorsi

- O** Spinous processes of T7 through L5 (via dorsolumbar fascia), posterior surface of sacrum, iliac crest, and lower three ribs
- I** Medial floor of bicipital groove of humerus
- A** Shoulder extension, adduction, medial rotation, hyperextension
- N** Thoracodorsal nerve

12 latissimus dorsi

Lippert & Minor: Kinesiology Flashcards 3e, © 2011 F. A. Davis Company

teres major

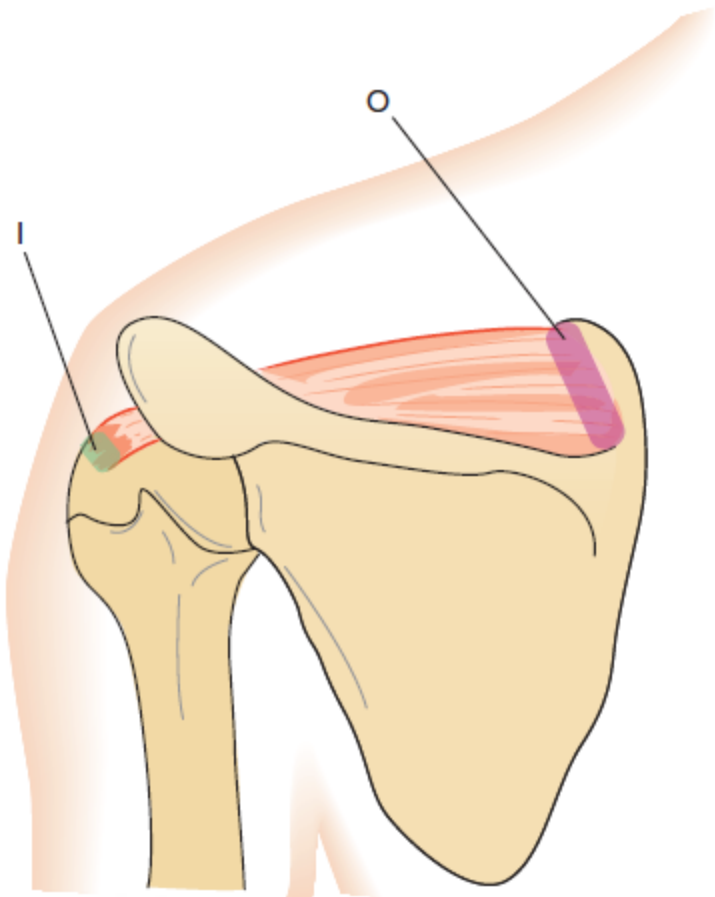


Teres Major

- O** Axillary border of scapula near the inferior angle
- I** Crest below lesser tubercle inferior to the latissimus dorsi muscle attachment
- A** Shoulder extension, adduction, medial rotation
- N** Lower subscapular nerve

“little helper” of the latissimus dorsi muscle

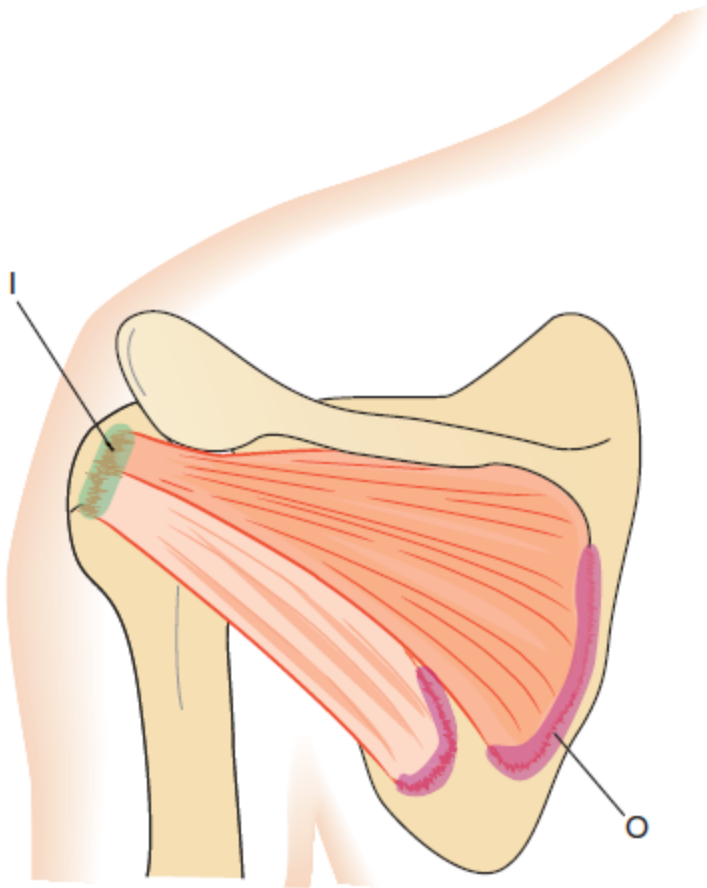
supraspinatus



Supraspinatus

- | | |
|----------|-----------------------------------|
| O | Supraspinous fossa of the scapula |
| I | Greater tubercle of the humerus |
| A | Shoulder abduction |
| N | Suprascapular nerve |

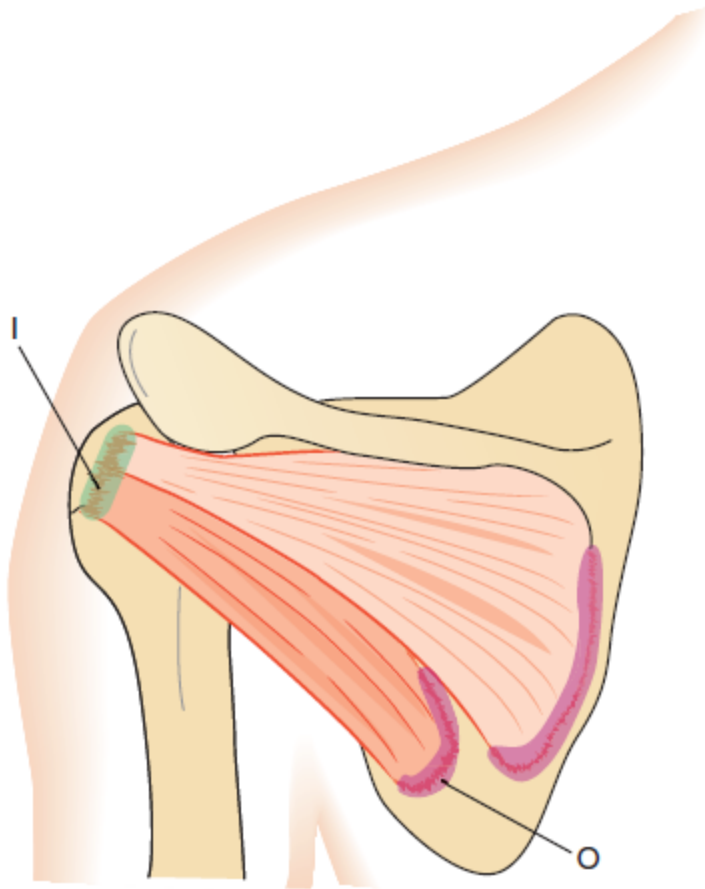
infraspinatus



Infraspinatus

- | | |
|----------|--|
| O | Infraspinous fossa of scapula |
| I | Greater tubercle of humerus |
| A | Shoulder lateral rotation,
horizontal abduction |
| N | Suprascapular nerve |

teres minor



Teres Minor

- O** Axillary border of scapula
- I** Greater tubercle of humerus
- A** Shoulder lateral rotation, horizontal abduction
- N** Axillary nerve

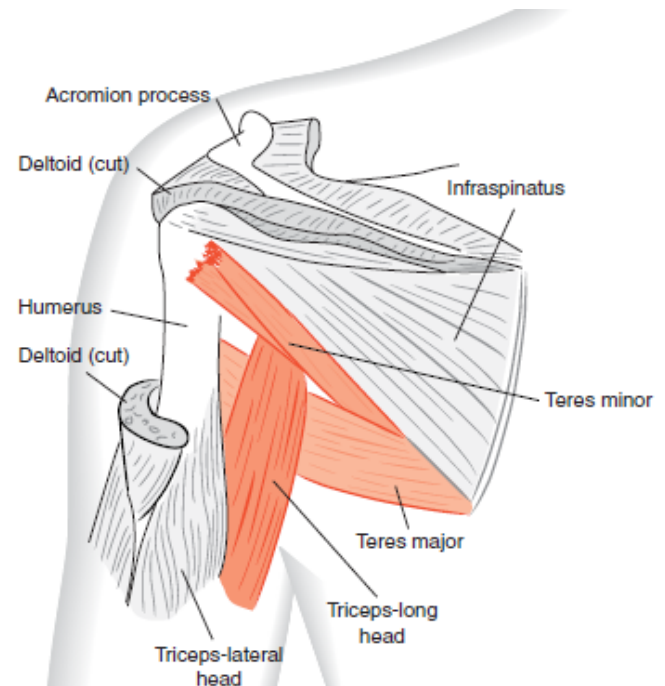
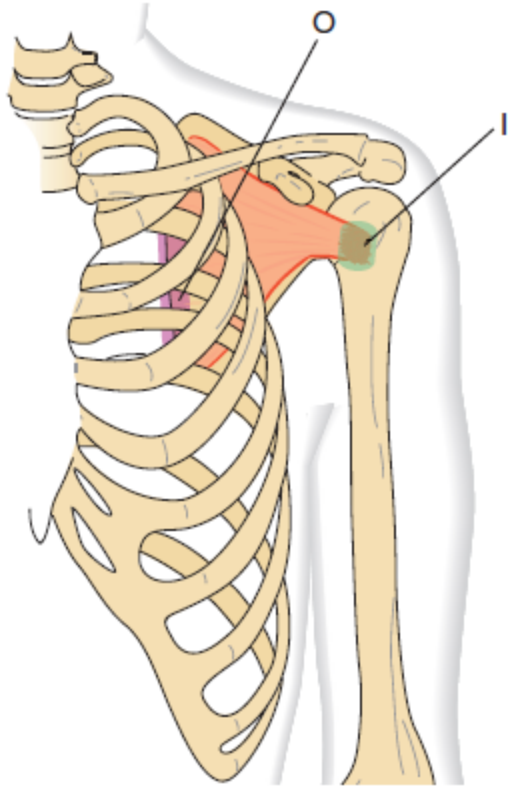


Figure 10-14. The long head of the triceps muscle separates the teres major and teres minor muscles at the axilla (*posterior view*)

subscapularis



Subscapularis

- | | |
|----------|-----------------------------------|
| O | Subscapular fossa of the scapula |
| I | Lesser tubercle of the humerus |
| A | Shoulder medial rotation |
| N | Upper and lower subscapular nerve |

Rotátorová manžeta je velmi složitá anatomická struktura zajišťující maximální možnou koaptaci kloubních ploch ramenního kloubu jak ve statické pozici, tak při dynamickém procesu. Jejím účelem je zajišťovat co nejvýhodnější postavení hlavice a glenoidu, čímž je kloub dostatečně centrován. Tato ideální pozice chrání měkké struktury kloubu před poškozením.

Složení rotátorové manžety

Rotátorová manžeta je složena z:

- kloubního pouzdra,
- okolních ligament,
- úponů šlach m. supraspinatus, infraspinatus, teres minor a subscapularis
- akronym – **SITS**

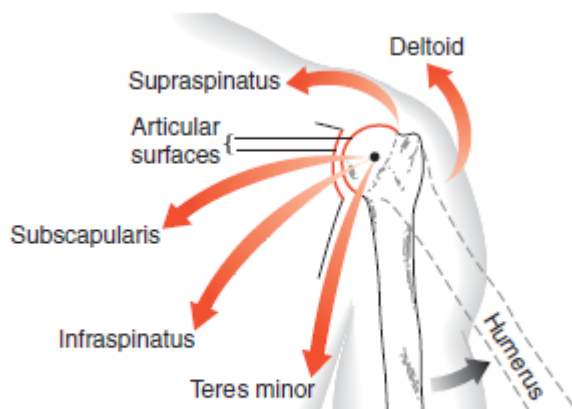
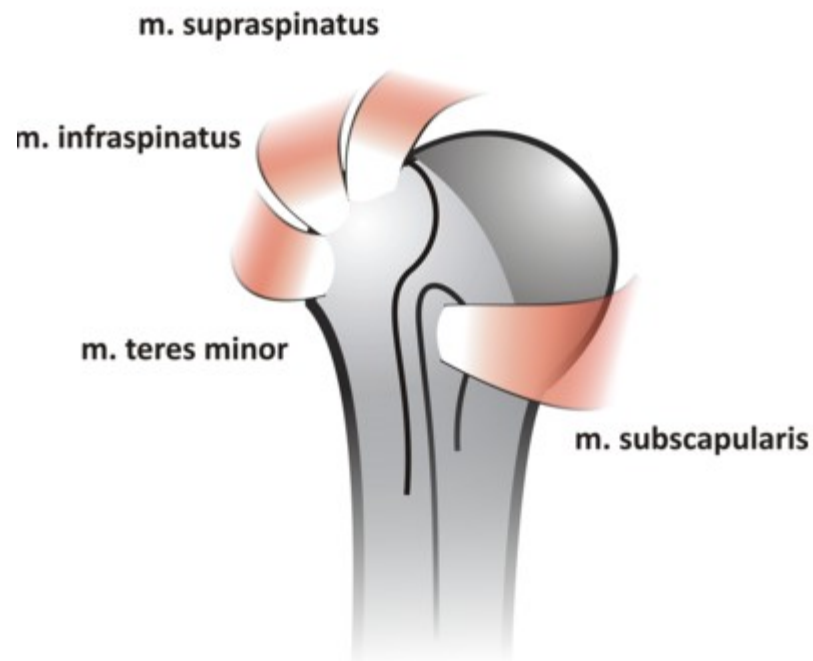
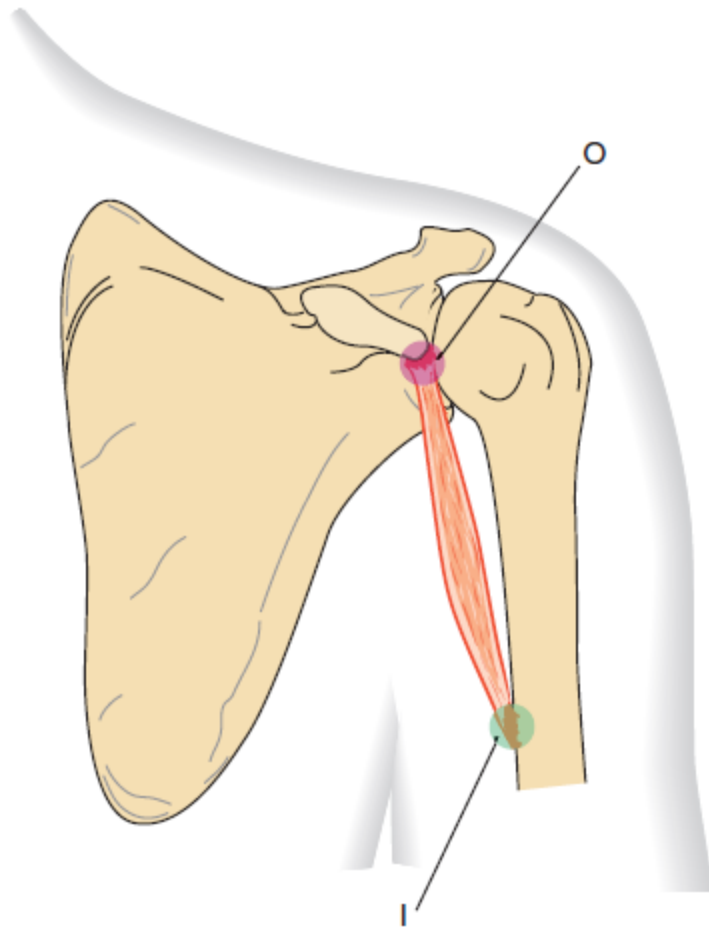


Figure 10-21. Force couple of the deltoid and rotator cuff muscles (SITS) rotating the humeral head in the glenoid fossa during shoulder abduction.



coracobrachialis



Coracobrachialis

- O** Coracoid process of the scapula
- I** Medial surface of the humerus near the midpoint
- A** Stabilizes the shoulder joint
- N** Musculocutaneous nerve

Table 10-1

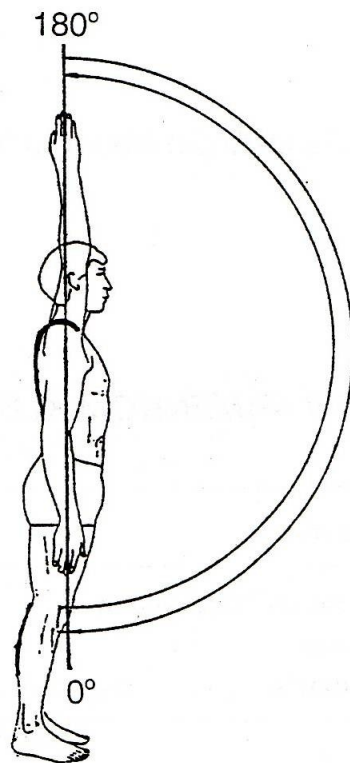
Prime Mover Muscles
of the Shoulder Joint

Action	Muscles
Flexion	Anterior deltoid, pectoralis major (clavicular)*
Extension	Posterior deltoid, latissimus dorsi, teres major, pectoralis major (sternal)†
Hyperextension	Latissimus dorsi, posterior deltoid
Abduction	Deltoid, supraspinatus
Adduction	Pectoralis major, teres major, latissimus dorsi
Horizontal abduction	Posterior deltoid, infraspinatus, teres minor
Horizontal adduction	Pectoralis major, anterior deltoid
Lateral rotation	Infraspinatus, teres minor, posterior deltoid
Medial rotation	Latissimus dorsi, teres major, subscapularis, pectoralis major, anterior deltoid

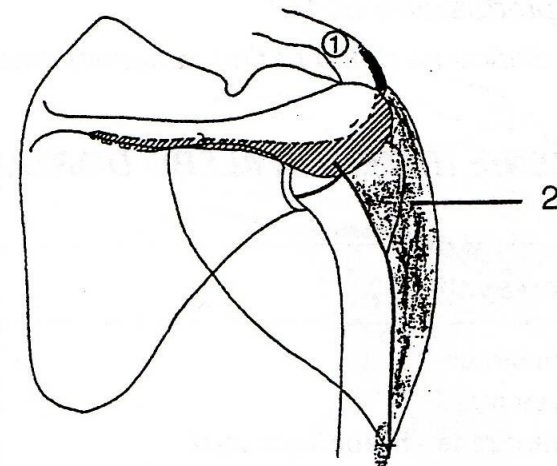
*To approximately 60 degrees.

†To approximately 120 degrees.

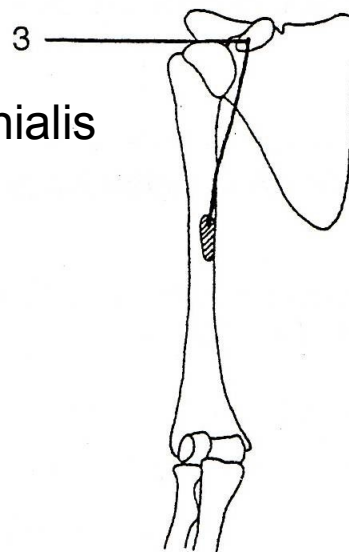
FLEXE - PŘEDPAŽENÍ



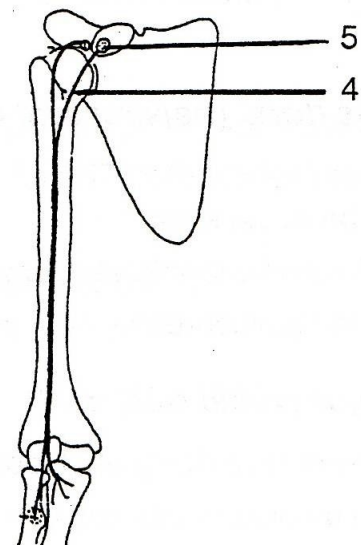
m. deltoideus
(pars clavicularis)



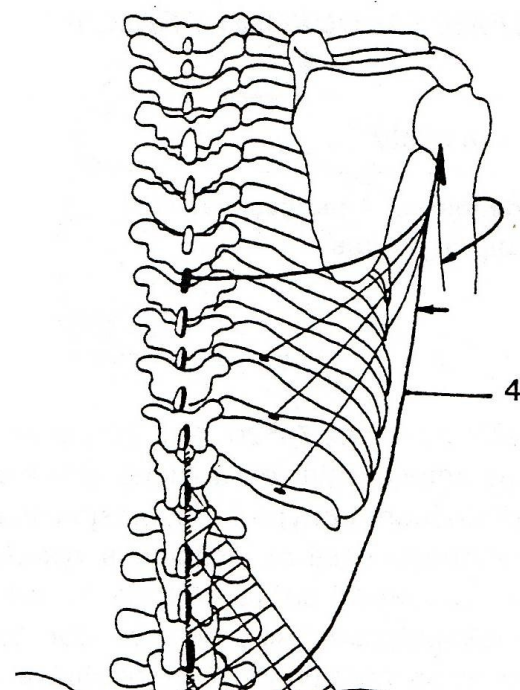
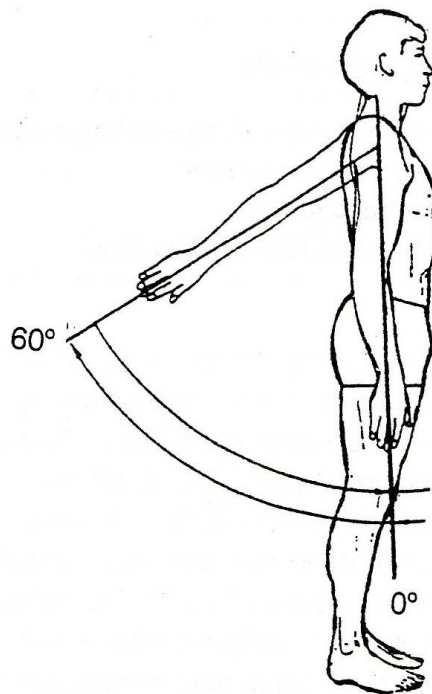
m. coracobrachialis



m. biceps brachii

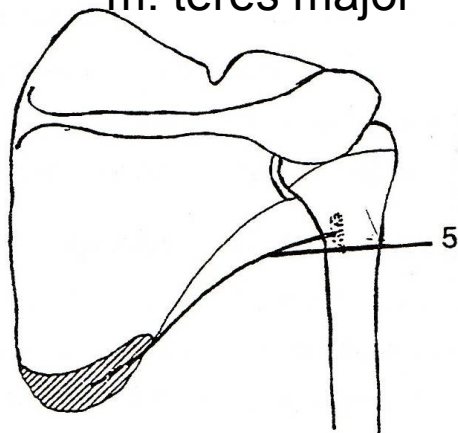


EXTENZE - ZAPAŽENÍ

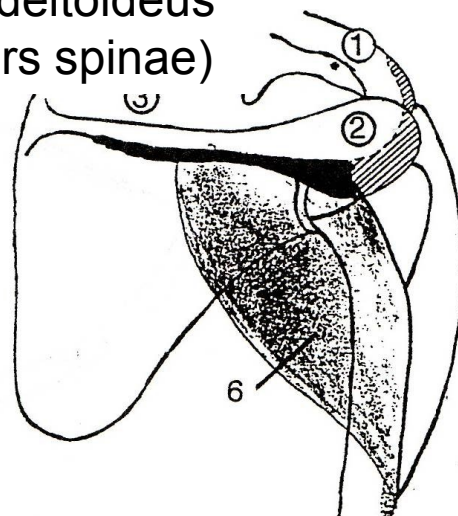


m. latissimus dorsi

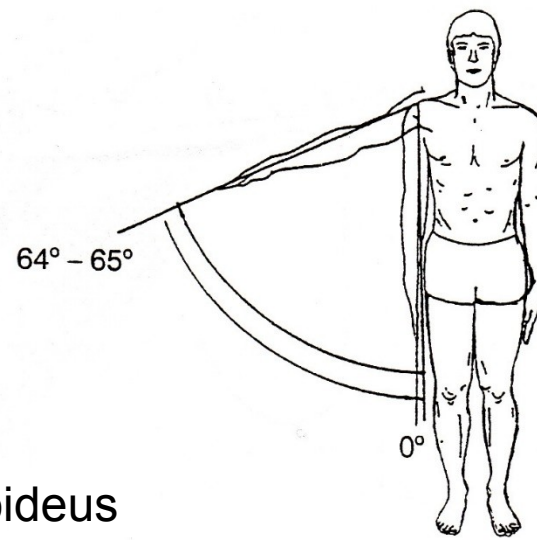
m. teres major



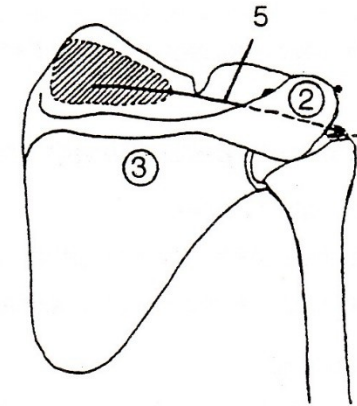
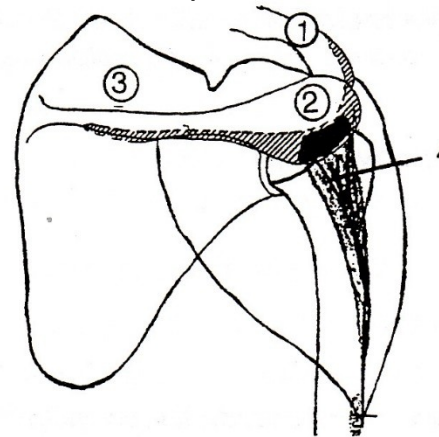
m. deltoideus
(pars spinae)



ABDUKCE - UPAŽENÍ

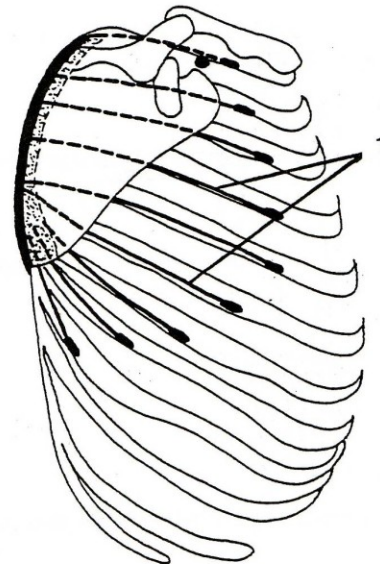
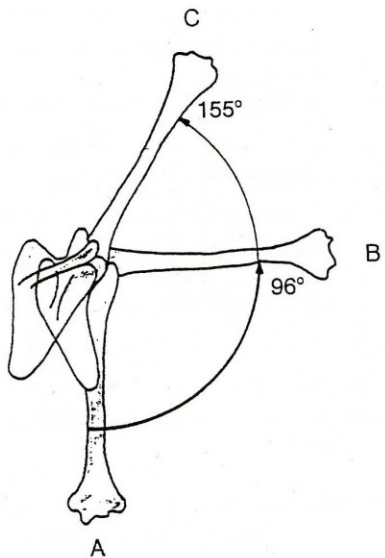


m. deltoideus
(pars akromialis)

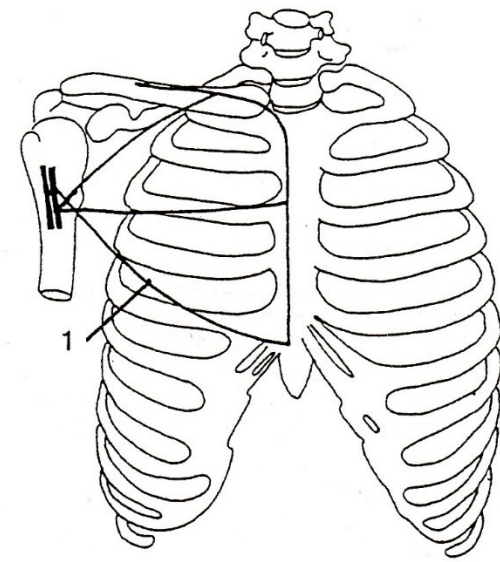
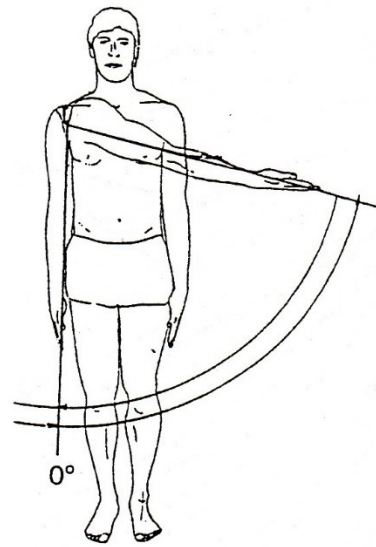


m. supraspinatus

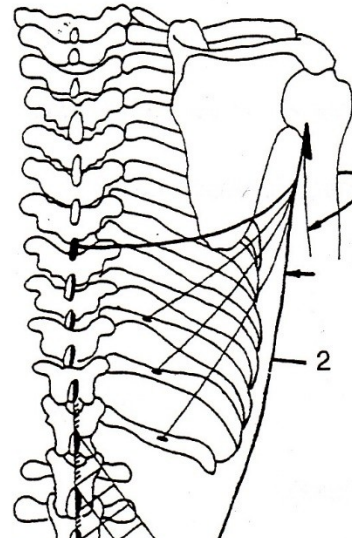
m. serratus anterior



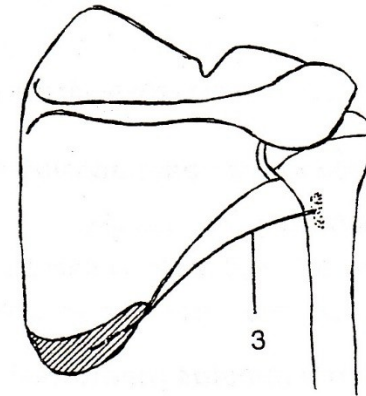
ADDUKCE - PŘIPAŽENÍ



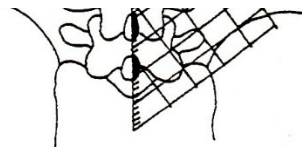
m. pectoralis major



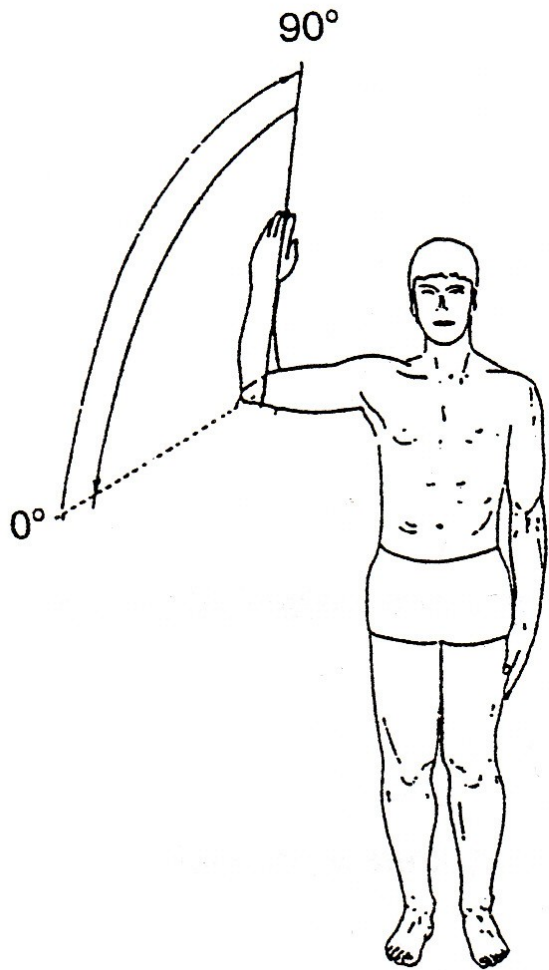
m. latissimus dorsi



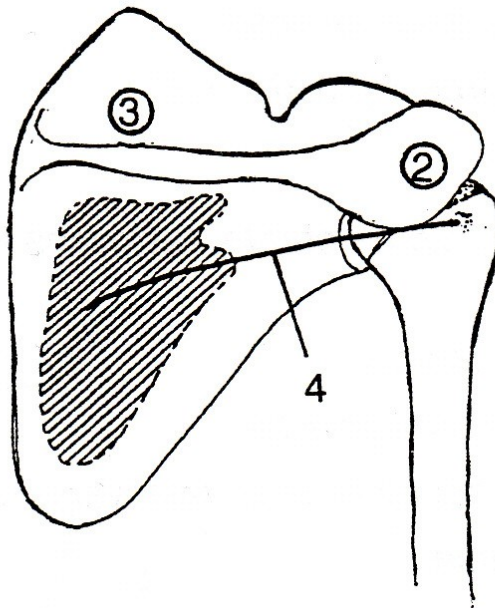
m. teres major



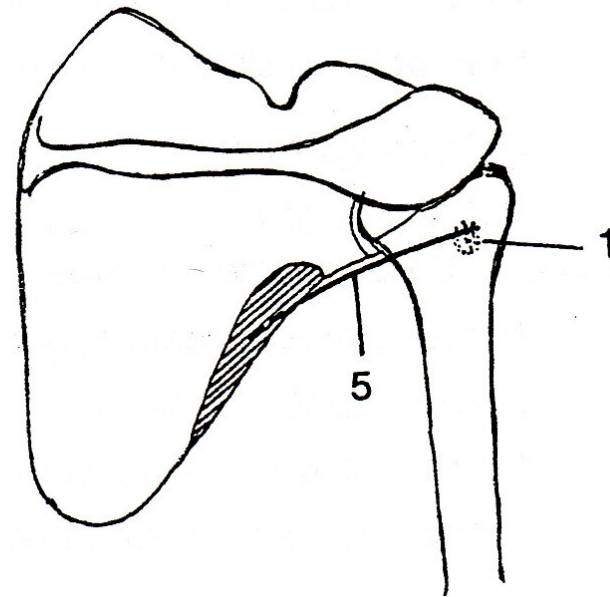
VNĚJŠÍ ROTACE



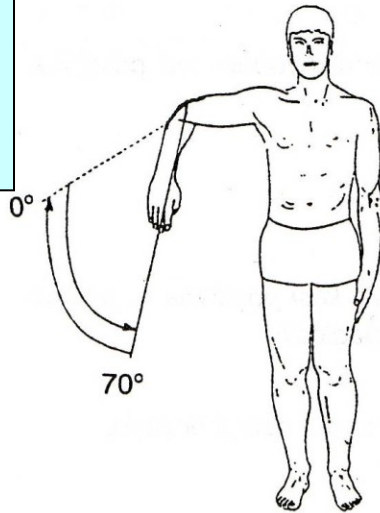
m. infraspinatus



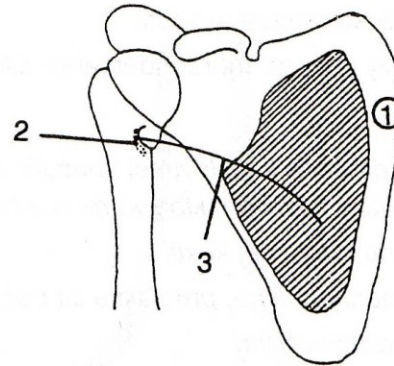
m. teres minor



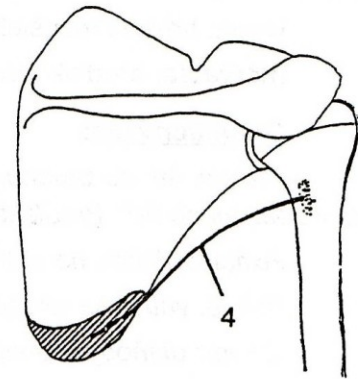
VNITŘNÍ ROTACE



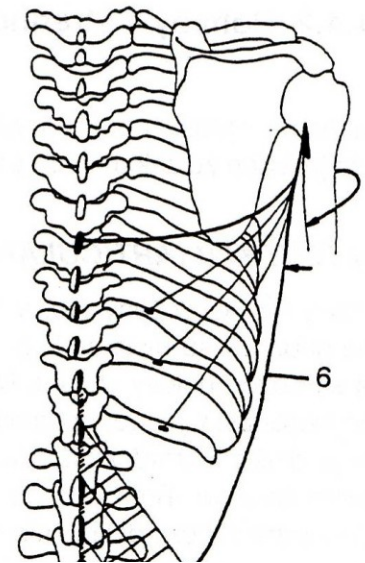
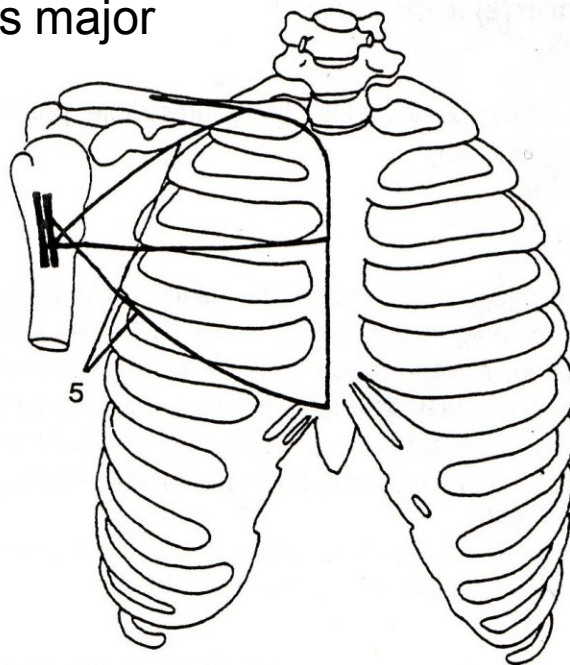
m. subscapularis



m. teres major



m. pectoralis major



m. latissimus dorsi

POHYBY LOKETNÍHO KLOUBU

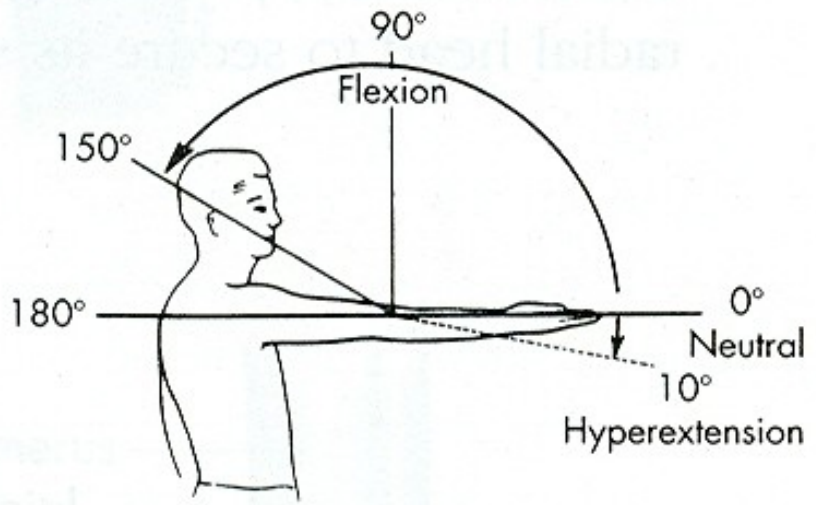
FLEXE

EXTENZE

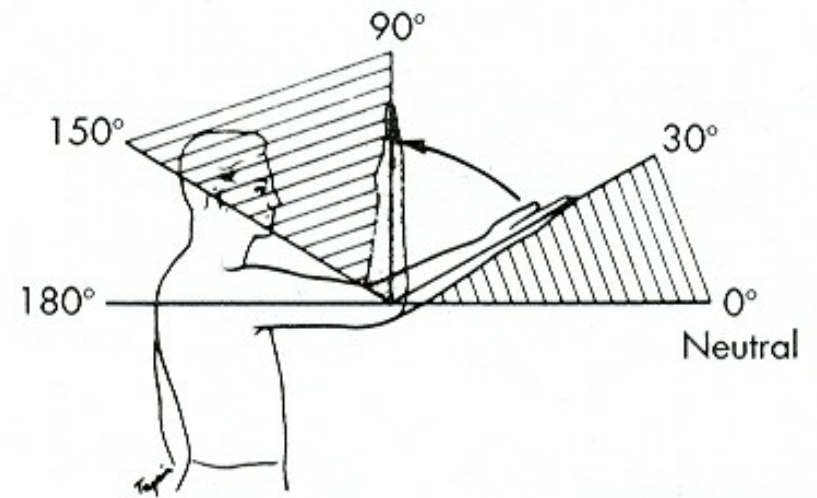
POHYBY PŘEDLOKTÍ

SUPINACE

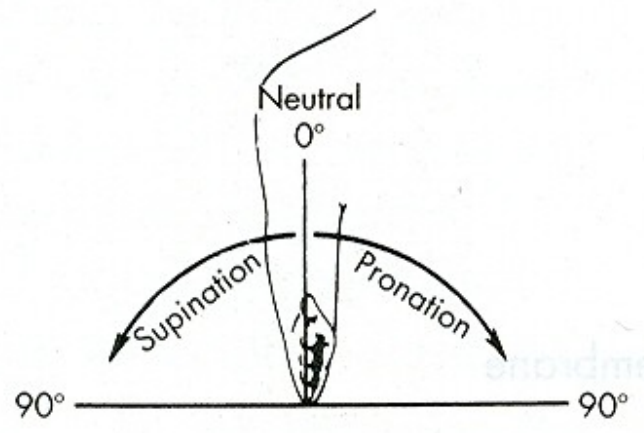
PRONACE



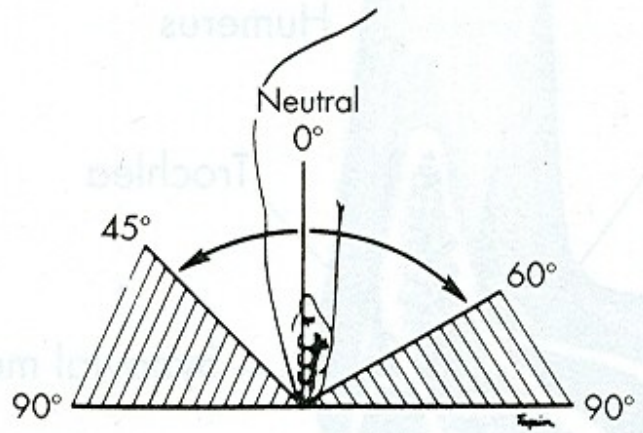
A



B



A



B

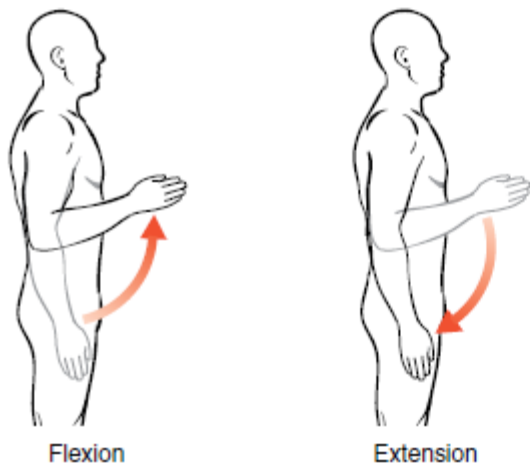


Figure 11-2. Elbow motions.

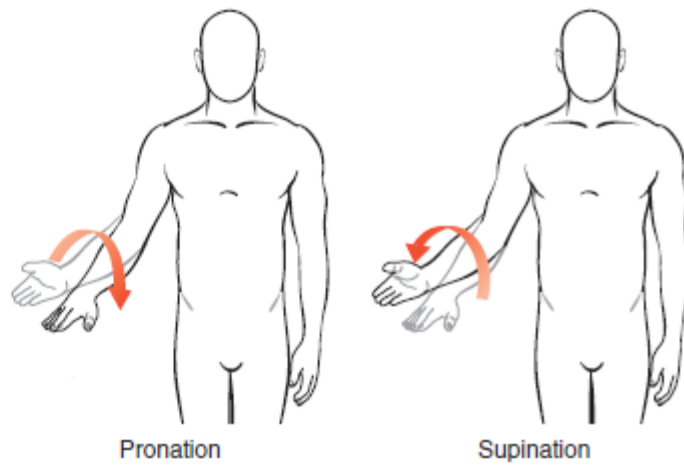


Figure 11-4. Forearm motions.

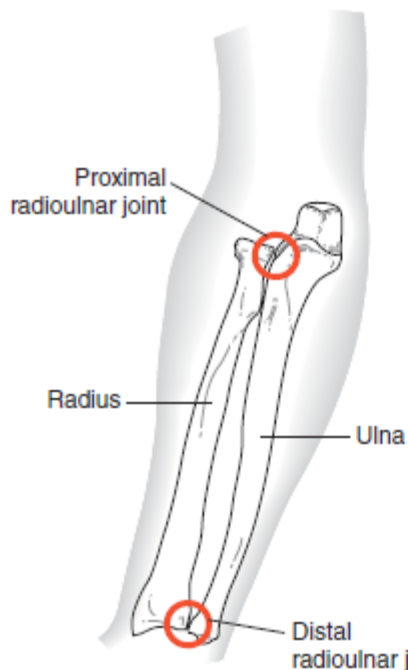


Figure 11-3. The radioulnar joints (anterior view).

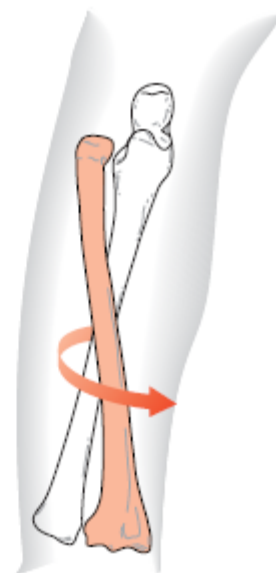


Figure 11-5. The radius moves around the ulna (anterior view).

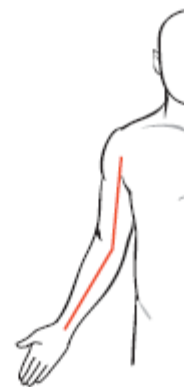

Figure 11-6. The carrying angle (anterior view).

Muscles of the Elbow and Forearm

Brachialis

Brachioradialis

Biceps

Supinator

Triceps

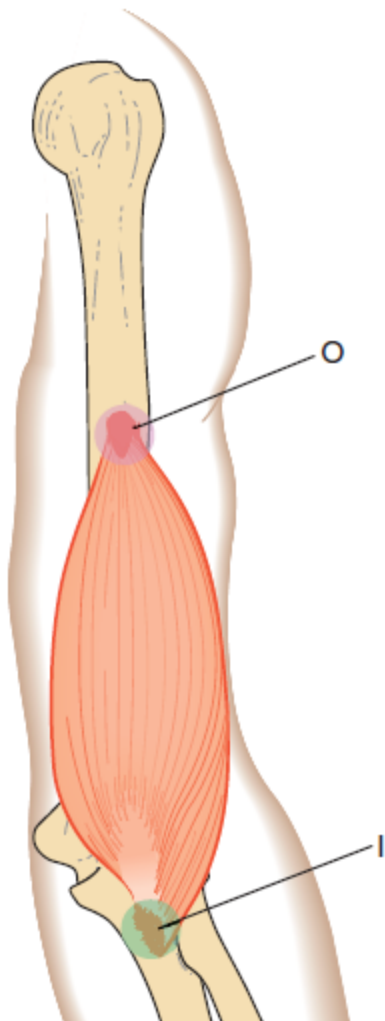
Anconeus

Pronator teres

Pronator quadratus

Because the brachialis muscle has no attachment on the radius, it has no role in pronation or supination. However, this muscle is a very strong elbow flexor, regardless of the forearm's position, and is therefore sometimes called the "workhorse of the elbow joint."

brachialis

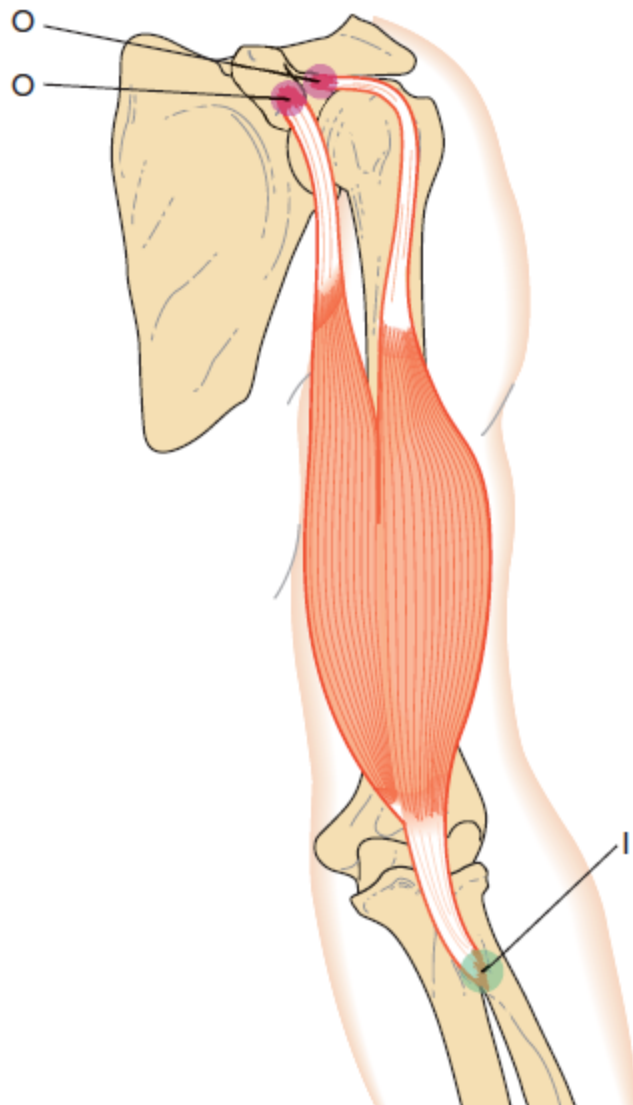


Brachialis

O	Distal half of humerus, anterior surface
I	Coronoid process and ulnar tuberosity of the ulna
A	Elbow flexion
N	Musculocutaneous nerve

Because the brachialis muscle has no attachment on the radius, it has no role in pronation or supination. However, this muscle is a very strong elbow flexor, regardless of the forearm's position, and is therefore sometimes called the “workhorse of the elbow joint.”

biceps brachii



Biceps Brachii

- O** Long head: supraglenoid tubercle of scapula
Short head: coracoid process of scapula
- I** Radial tuberosity of radius
- A** Elbow flexion, forearm supination
- N** Musculocutaneous nerve

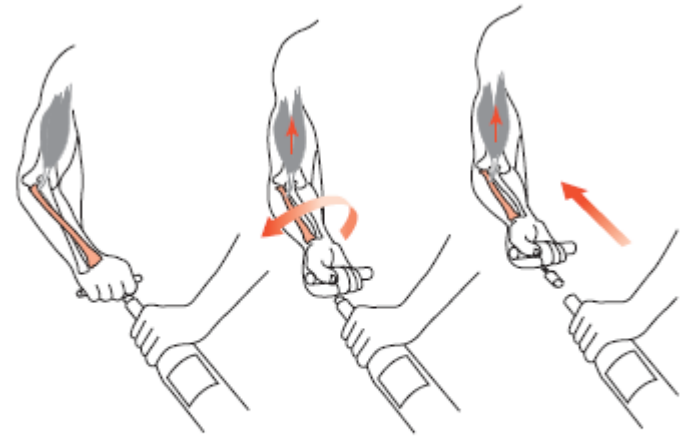
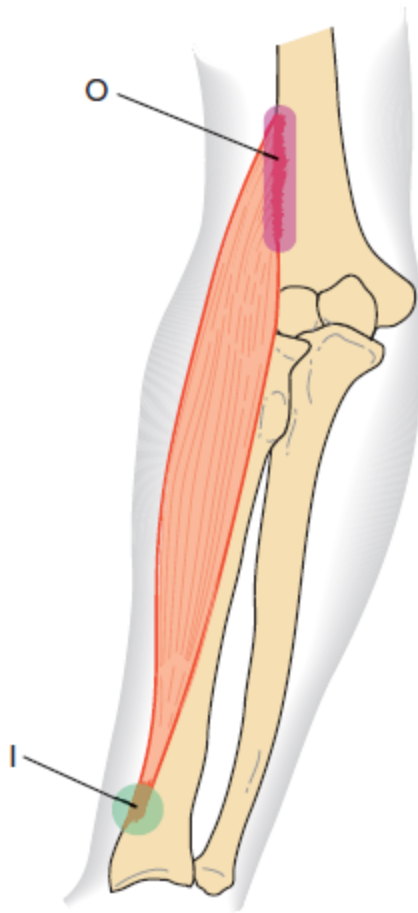


Figure 11-15. Supination action of biceps (anterior view). The action of the biceps as a forearm supinator and elbow flexor is used when pulling a cork out of a bottle with a corkscrew. First, it unscrews the cork (supination); then it pulls on the cork (flexion).

brachioradialis

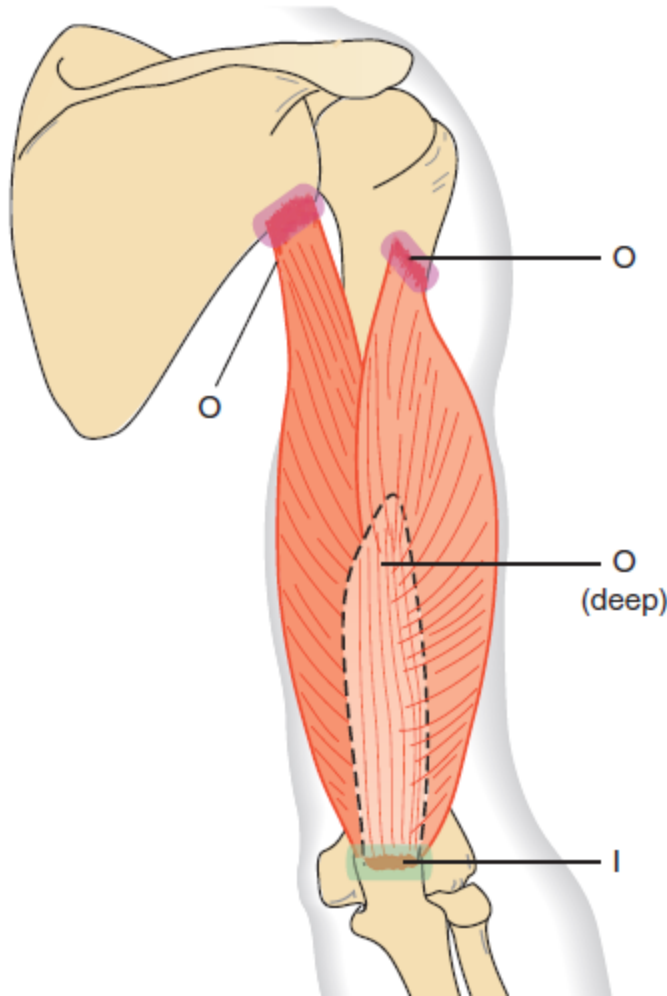


Brachioradialis

- | | |
|----------|--|
| O | Lateral supracondylar ridge on the humerus |
| I | Styloid process of the radius |
| A | Elbow flexion |
| N | Radial nerve |

Because of its more lateral attachment, it is most effective as an elbow flexor when the forearm is in a neutral position

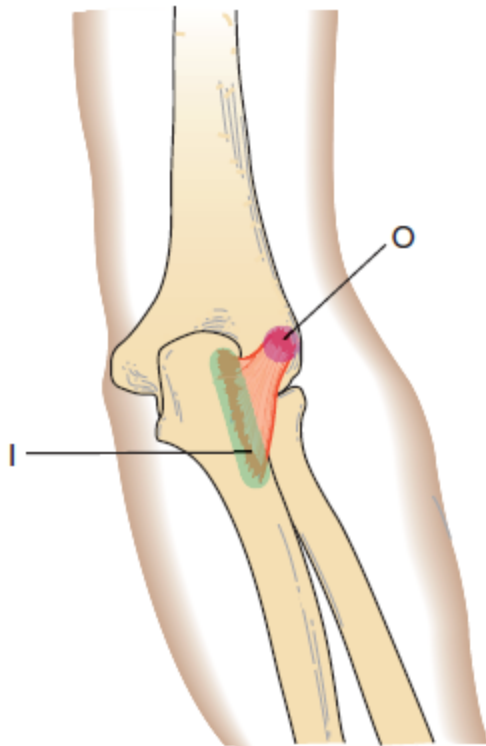
triceps



- O** Long head: Infraglenoid tubercle of scapula
Lateral head: Inferior to greater tubercle on posterior humerus
Medial head: Posterior surface of humerus
- I** Olecranon process of ulna
- A** Elbow extension
- N** Radial nerve

Because it has no attachment on the radius, it can play no role in pronation or supination.

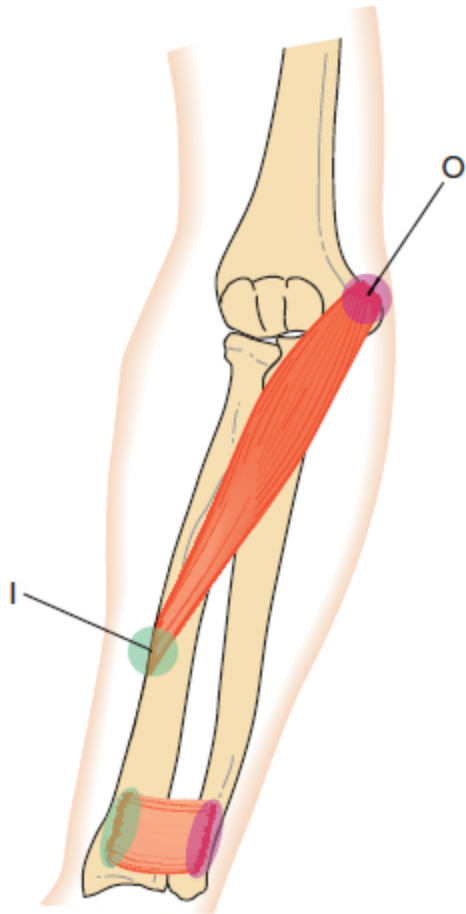
anconeus



Anconeus

- | | |
|----------|---|
| O | Lateral epicondyle of humerus |
| I | Lateral and inferior to olecranon process of ulna |
| A | Not a prime mover in any joint action; assists in elbow extension |
| N | Radial nerve (C7, C8) |

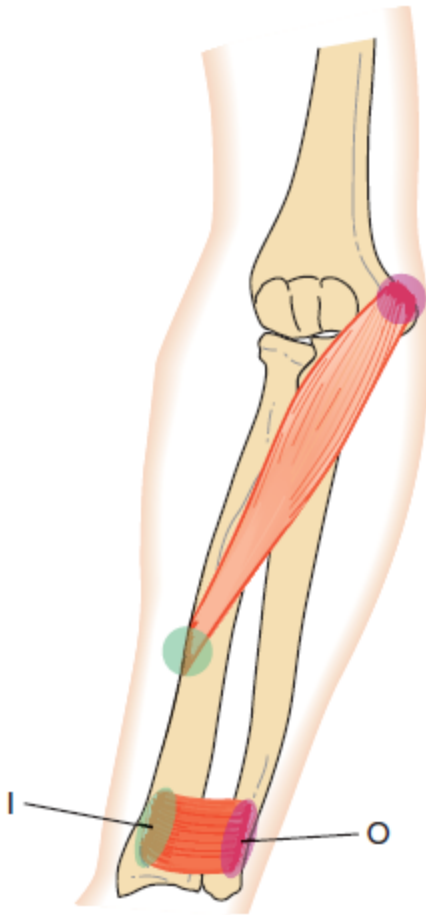
pronator teres



Pronator teres

- | | |
|----------|---|
| O | Medial epicondyle of humerus and coronoid process of ulna |
| I | Lateral aspect of radius at its midpoint |
| A | Forearm pronation, assistive in elbow flexion |
| N | Median nerve |

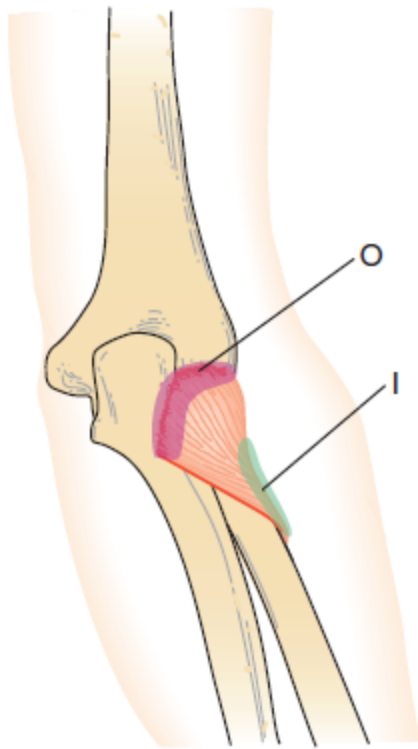
pronator quadratus



Pronator Quadratus

- | | |
|----------|-----------------------------|
| O | Distal one-fourth of ulna |
| I | Distal one-fourth of radius |
| A | Forearm pronation |
| N | Median nerve |

supinator



Supinator

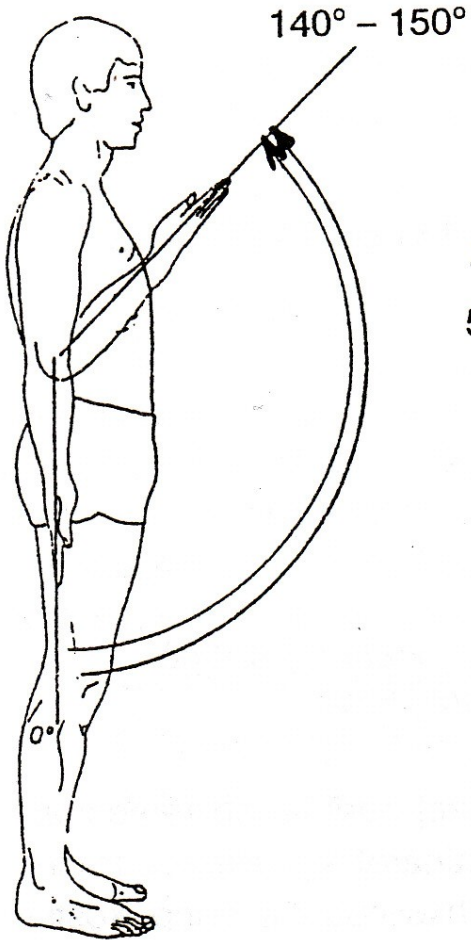
- | | |
|----------|---|
| O | Lateral epicondyle of humerus and adjacent ulna |
| I | Anterior surface of the proximal radius |
| A | Forearm supination |
| N | Radial nerve |

Table 11-1

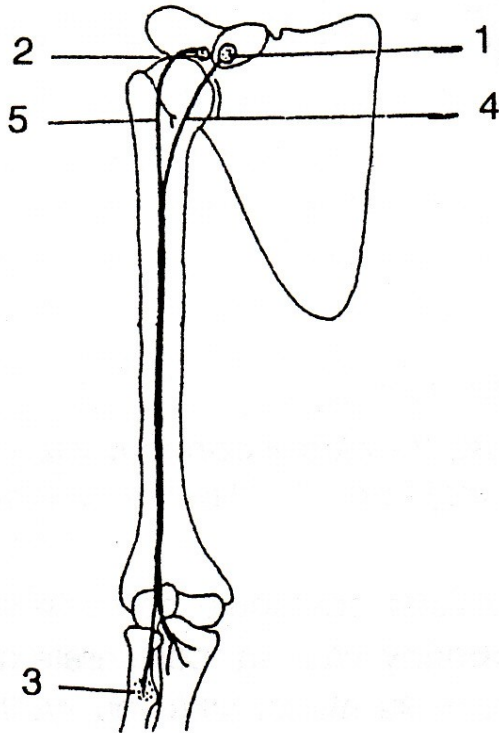
Prime Movers of the Elbow
and Forearm

Action	Muscle
Elbow flexion	Biceps Brachialis Brachioradialis
Elbow extension	Triceps
Forearm pronation	Pronator teres Pronator quadratus
Forearm supination	Biceps Supinator


FLEXE



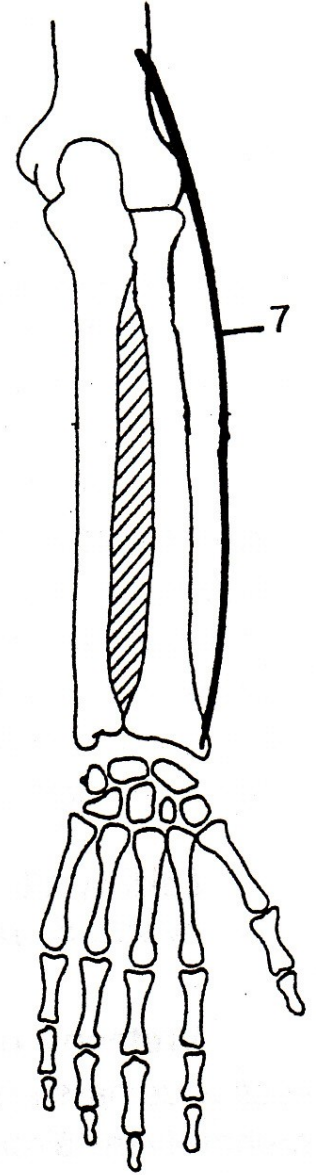
m. biceps brachii



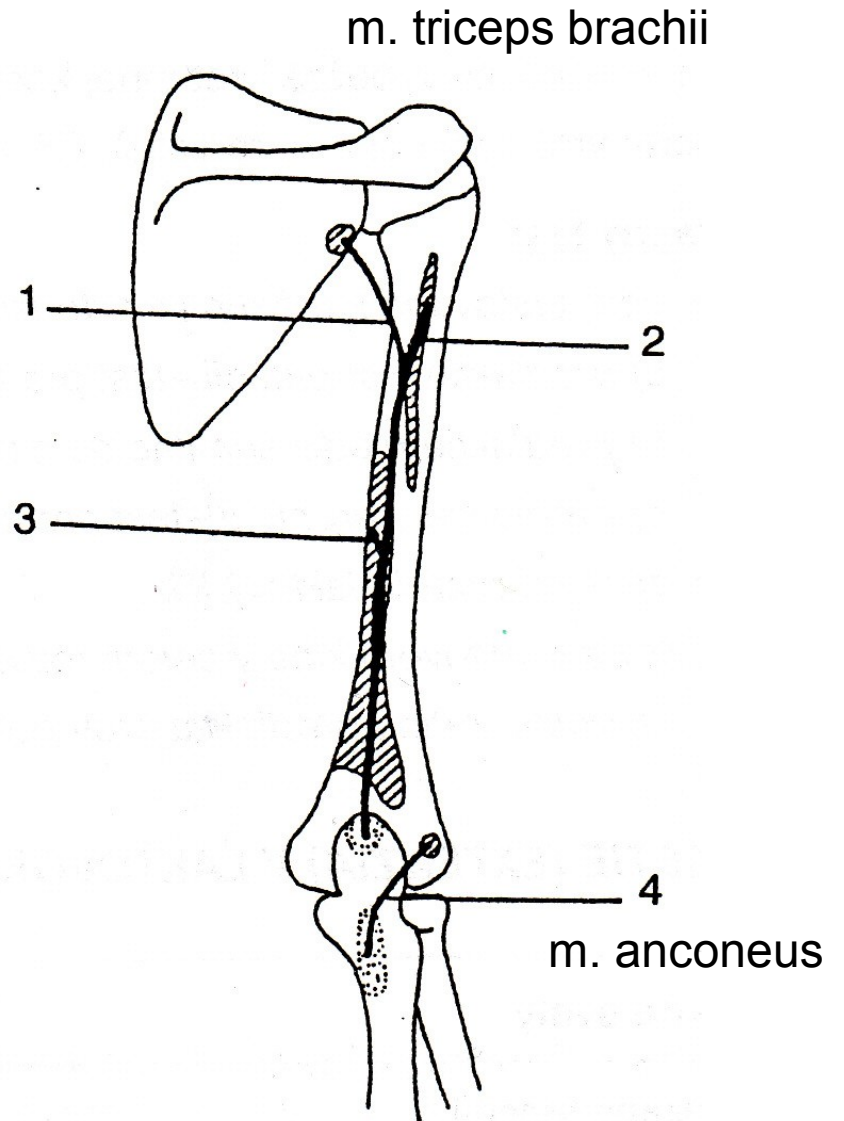
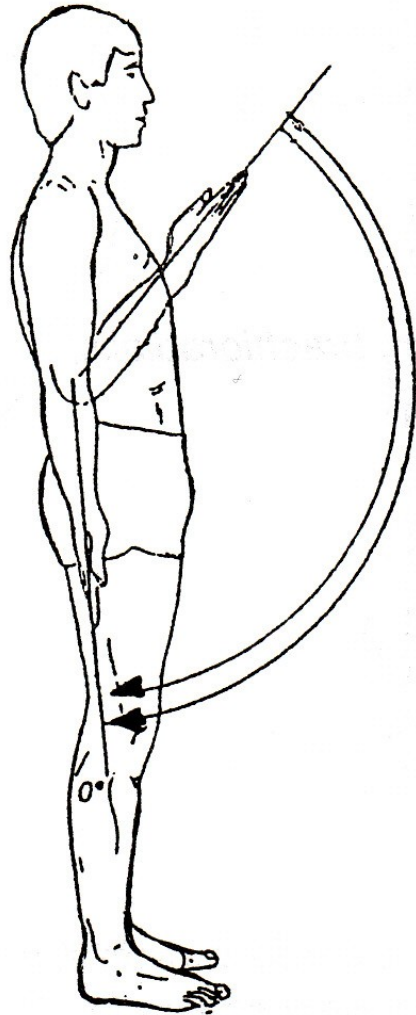
m. brachialis



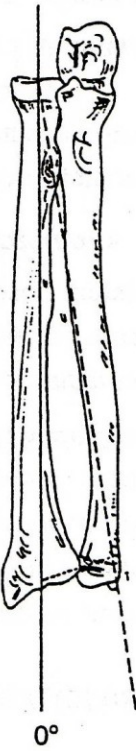
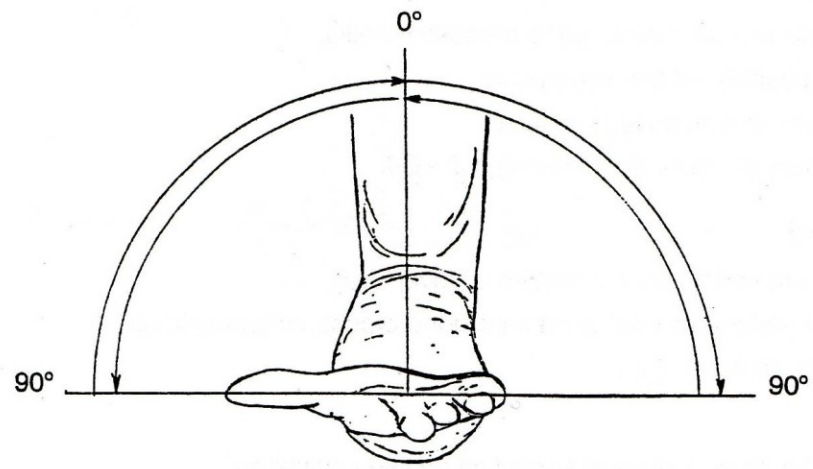
m. brachioradialis



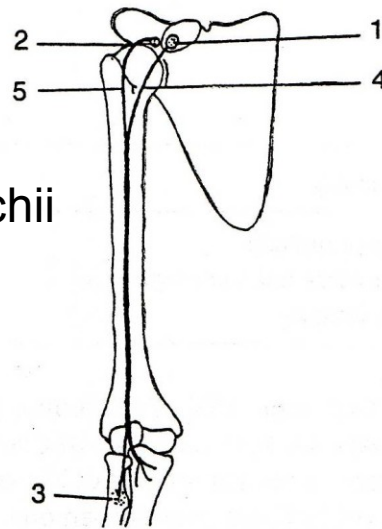
EXTENZE



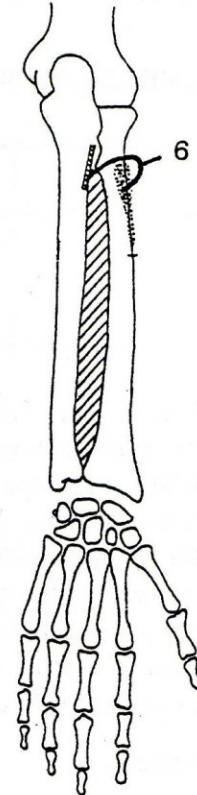
SUPINACE



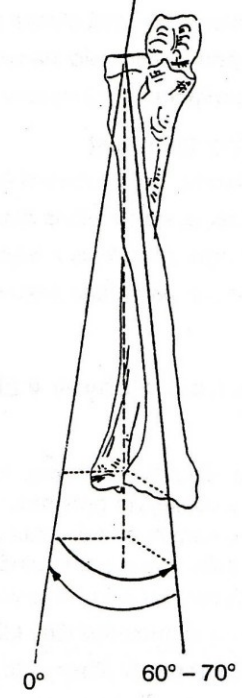
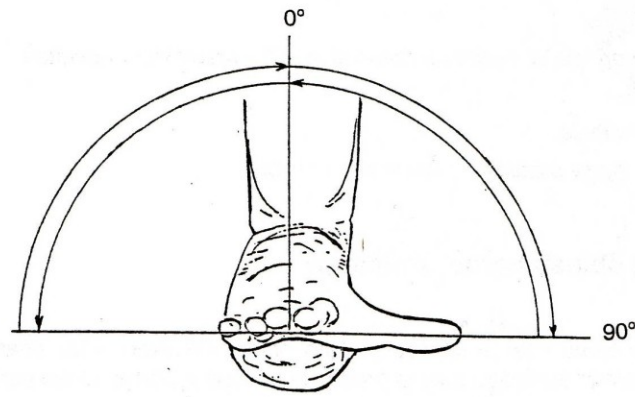
m. biceps brachii



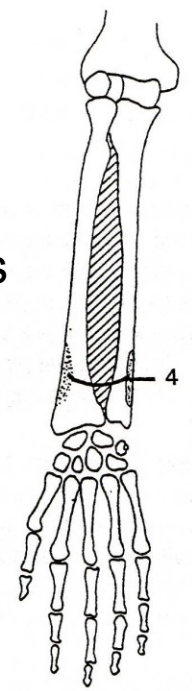
m. supinator



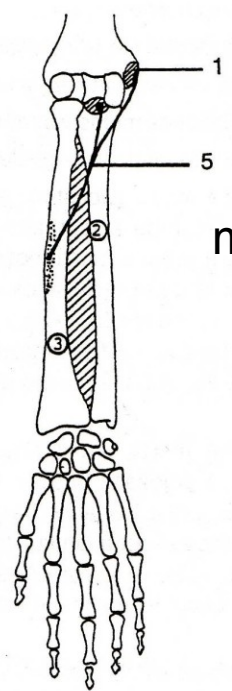
PRONACE



m. pronator quadratus



m. pronator teres



POHYBY ZÁPĚSTÍ

PALMÁRNÍ FLEXE - OHNUTÍ

DORZÁLNÍ FLEXE - NATAŽENÍ

ULNÁRNÍ DUKCE

RADIÁLNÍ DUKCE

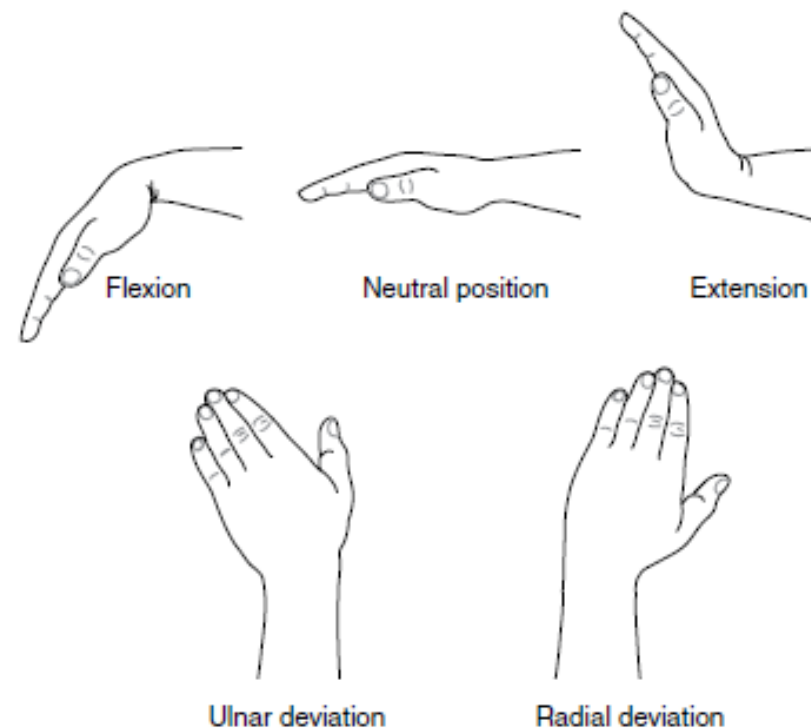
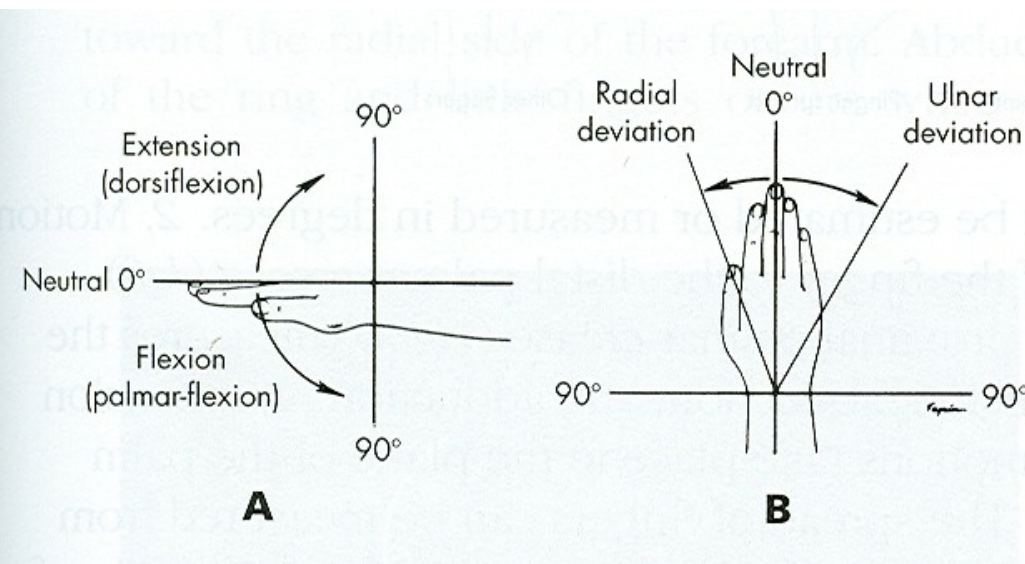


Figure 12-2. Joint motions of the wrist.

Table 12-1 Comparison of Wrist Joint Terminology*

Preferred Terminology	Alternate Terminology	Motion or Position
Flexion	Flexion, palmar flexion	Anterior from anatomical position
Neutral	Extension, neutral	Anatomical position
Extension	Hyperextension, dorsiflexion	Posterior from anatomical position
Radial deviation	Abduction	Lateral from anatomical position
Ulnar deviation	Adduction	Medial from anatomical position

*Bold print indicates which terms are used in this book.

Muscles of the Wrist

Anterior Posterior

Flexor carpi ulnaris

Flexor carpi radialis

Palmaris longus

Posterior

Extensor carpi radialis longus

Extensor carpi radialis brevis

Extensor carpi ulnaris

First, the flexors attach on the medial epicondyle, and the extensors attach on the lateral epicondyle.

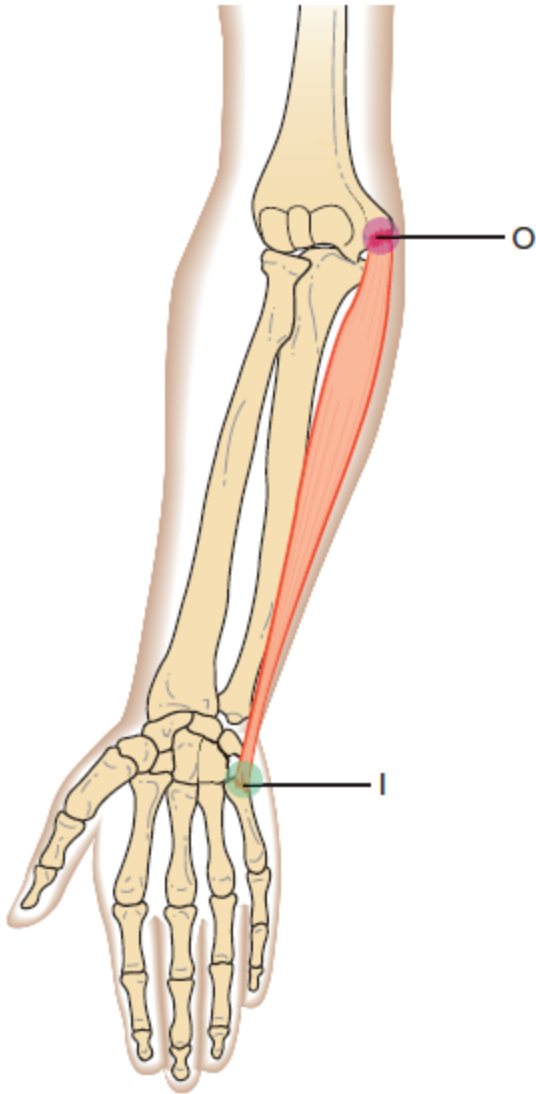
Second, the distal attachment for all the wrist muscles is a metacarpal, except for the palmaris longus muscle.

Third, the names of the muscles tell generally what their action is (flexor, extensor), what they act on (*carpi* means “wrist”), and on what side of the wrist the distal attachment is located (*radialis* means “radial”; *ulnaris* means “ulnar”).

Their names will also describe whether the muscle functions in ulnar or radial deviation.

Svaly, které mají primární funkci pohyb ruky budou popsány později.

flexor carpi ulnaris



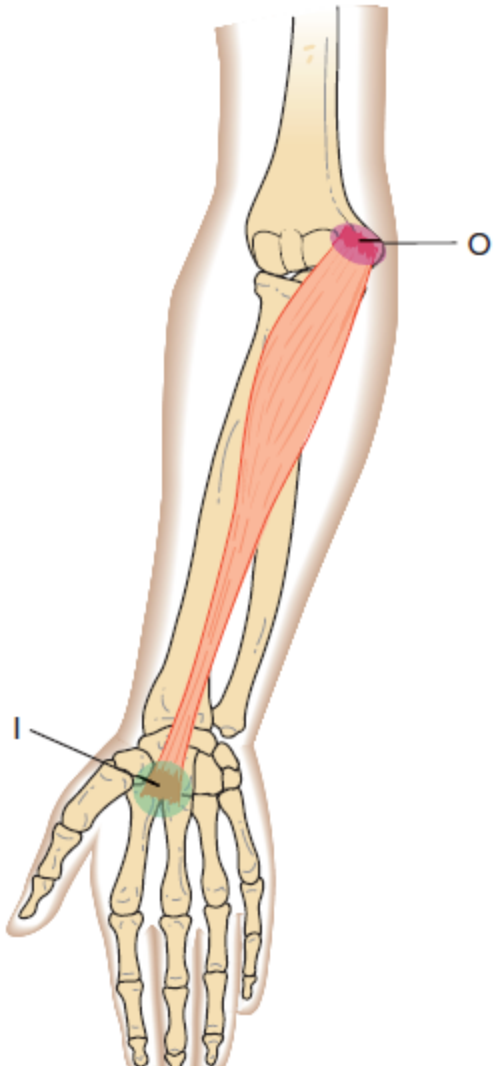
Flexor Carpi Ulnaris

O	Medial epicondyle of humerus
I	Pisiform, and base of fifth metacarpal
A	Wrist flexion, ulnar deviation
N	Ulnar nerve

It is the only wrist muscle attaching to a carpal bone.

27 flexor carpi ulnaris

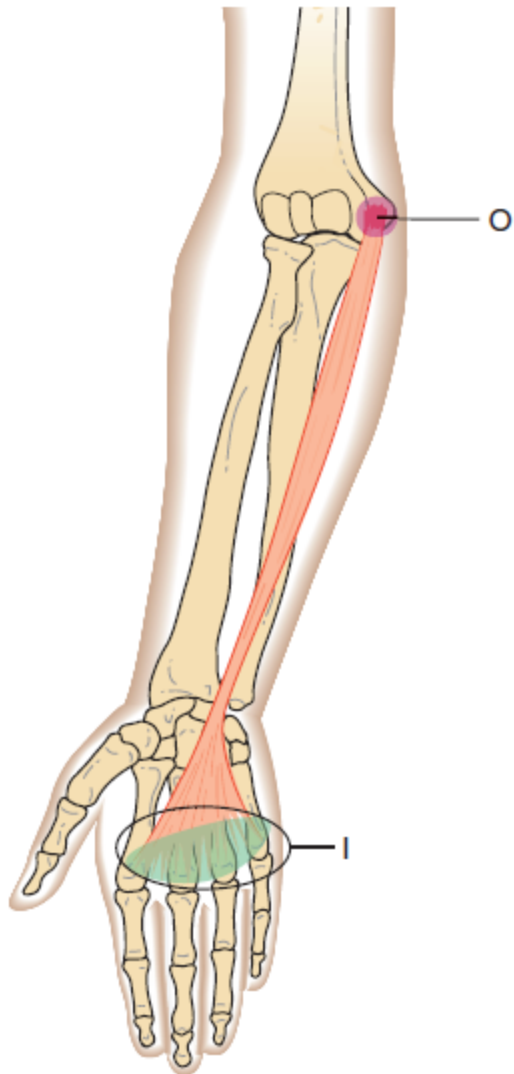
flexor carpi radialis



Flexor Carpi Radialis

- | | |
|----------|--------------------------------------|
| O | Medial epicondyle of the humerus |
| I | Base of second and third metacarpals |
| A | Wrist flexion, radial deviation |
| N | Median nerve |

palmaris longus



Palmaris Longus

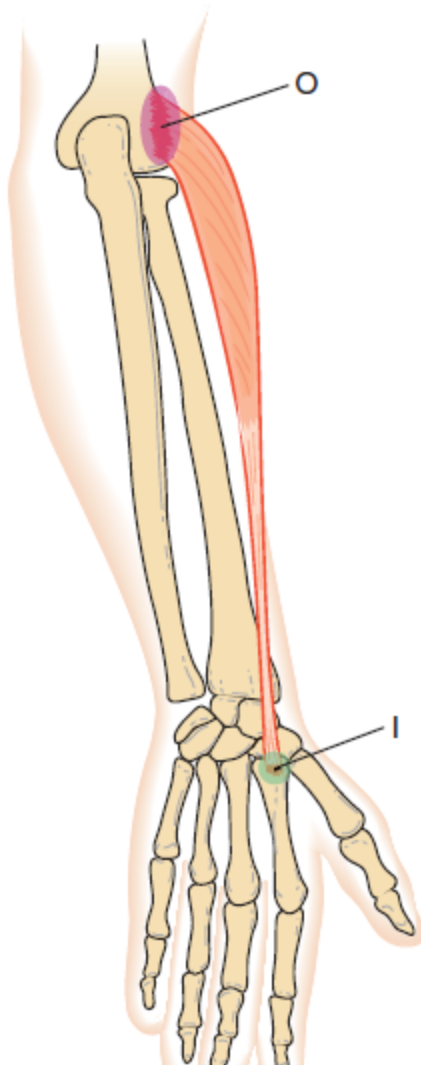
O	Medial epicondyle of humerus
I	Palmar fascia
A	Assistive in wrist flexion
N	Median nerve

This muscle is rather unique because it has only one bony attachment, which is at the proximal end. This muscle is missing in approximately 21% of individuals, either unilaterally or bilaterally

29 palmaris longus

Lippert & Minor: Kinesiology Flashcards 3e, © 2011 F. A. Davis Company

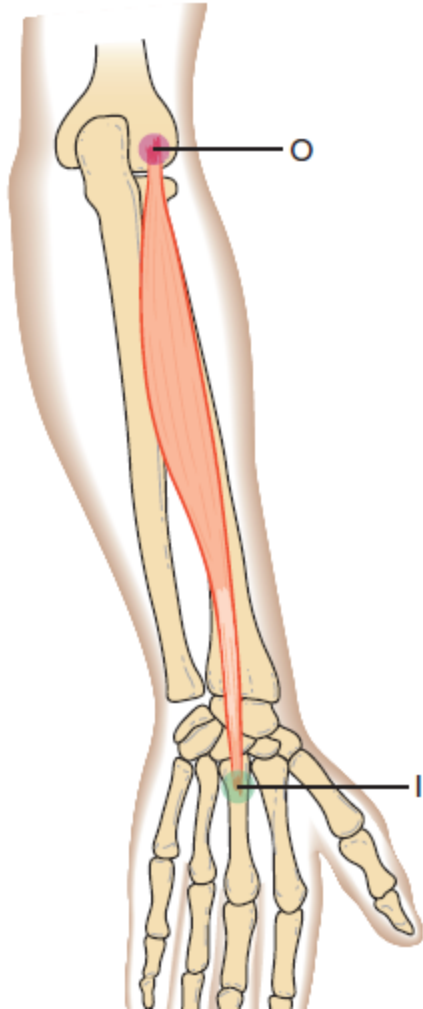
extensor carpi radialis longus



Extensor Carpi Radialis Longus

- | | |
|----------|-----------------------------------|
| O | Supracondylar ridge of humerus |
| I | Base of second metacarpal |
| A | Wrist extension, radial deviation |
| N | Radial nerve |

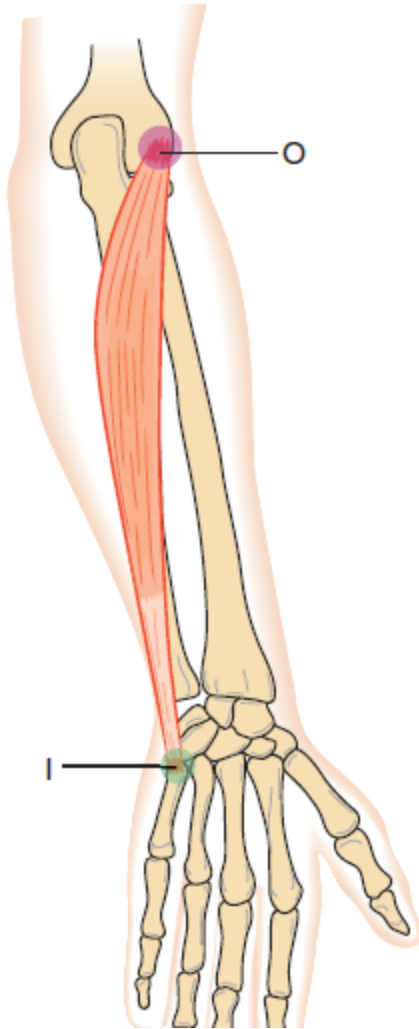
extensor carpi radialis brevis



Extensor Carpi Radialis Brevis

- | | |
|----------|-------------------------------|
| O | Lateral epicondyle of humerus |
| I | Base of third metacarpal |
| A | Wrist extension |
| N | Radial nerve |

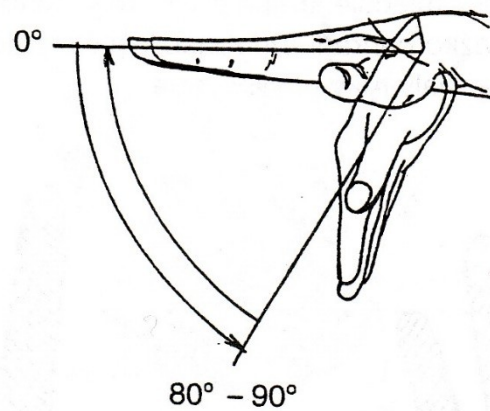
extensor carpi ulnaris



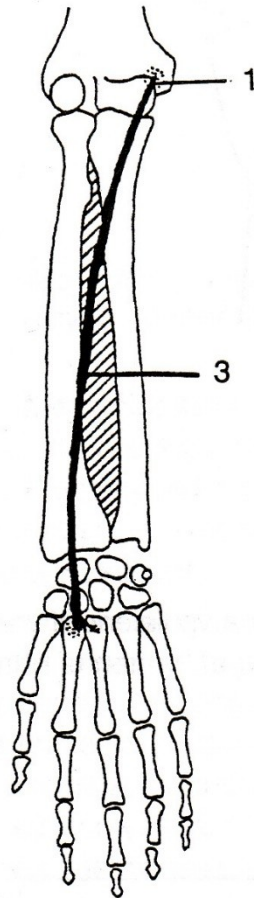
Extensor Carpi Ulnaris

- | | |
|----------|----------------------------------|
| O | Lateral epicondyle of humerus |
| I | Base of fifth metacarpal |
| A | Wrist extension, ulnar deviation |
| N | Radial nerve |

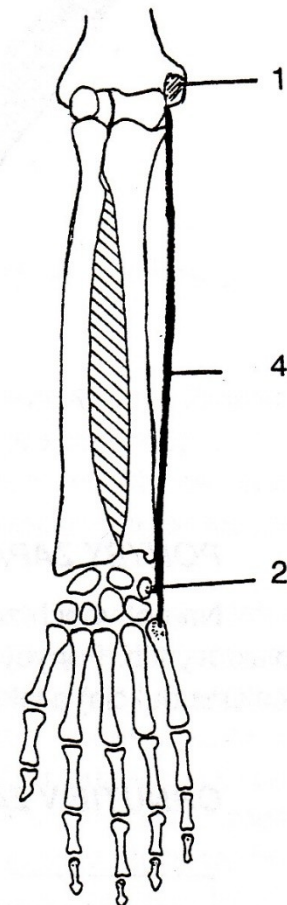
PALMÁRNÍ FLEXE



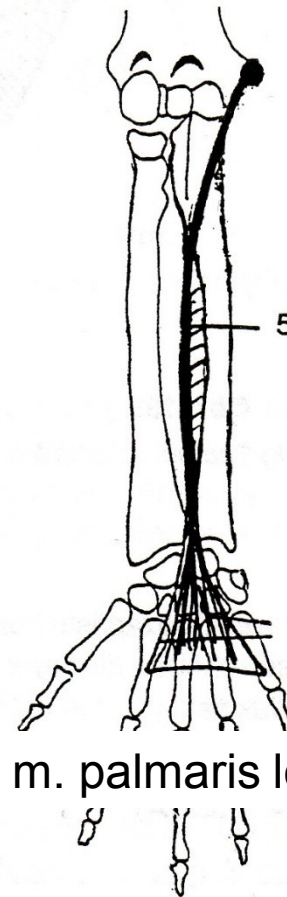
m. flexor carpi radialis



m. flexor carpi ulnaris

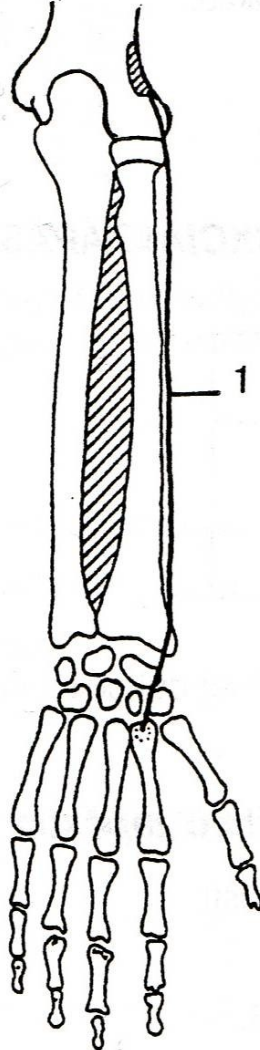


m. palmaris longus

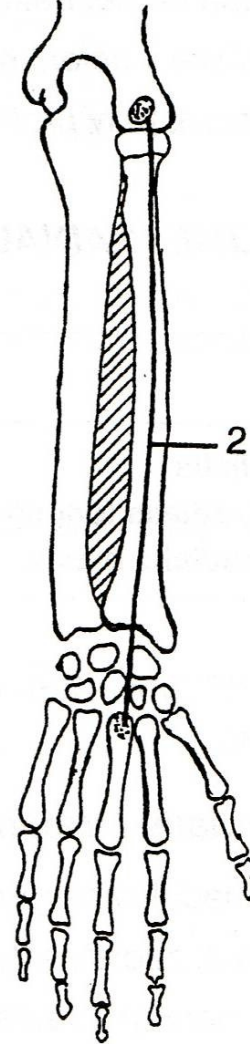


DORZÁLNÍ FLEXE

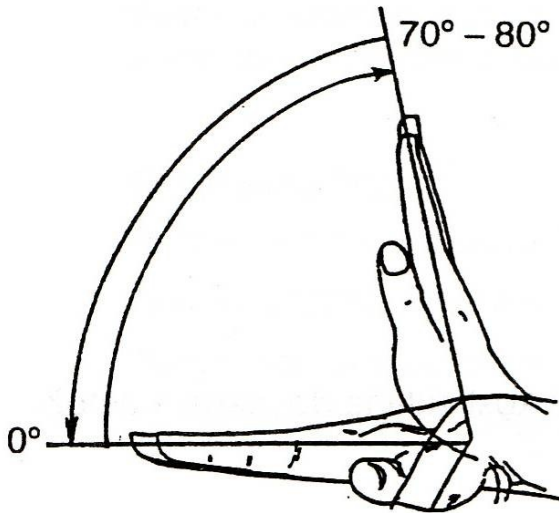
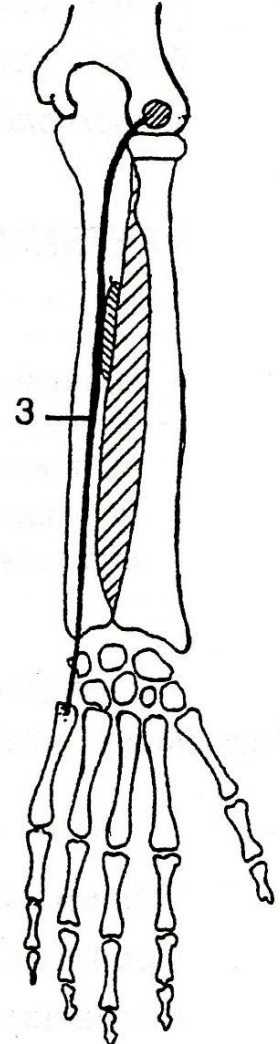
m. extensor carpi
radialis longus



m. extensor carpi
radialis brevis



m. extensor carpi
ulnaris

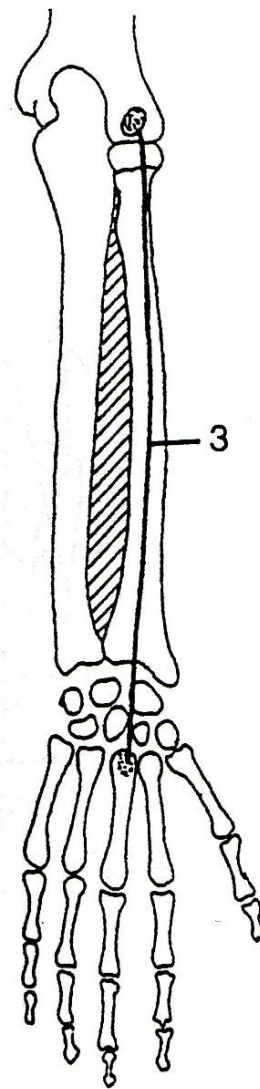
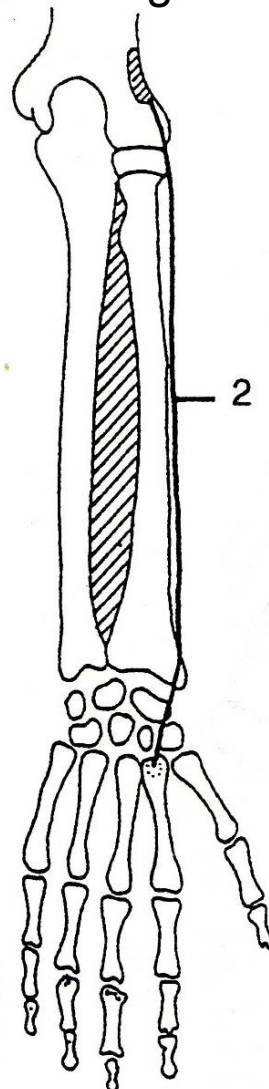
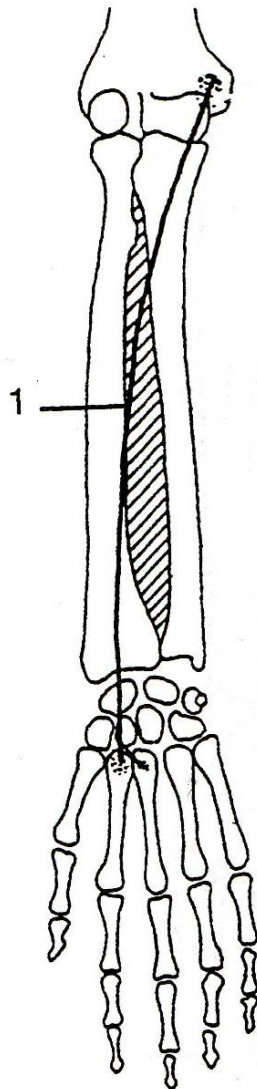
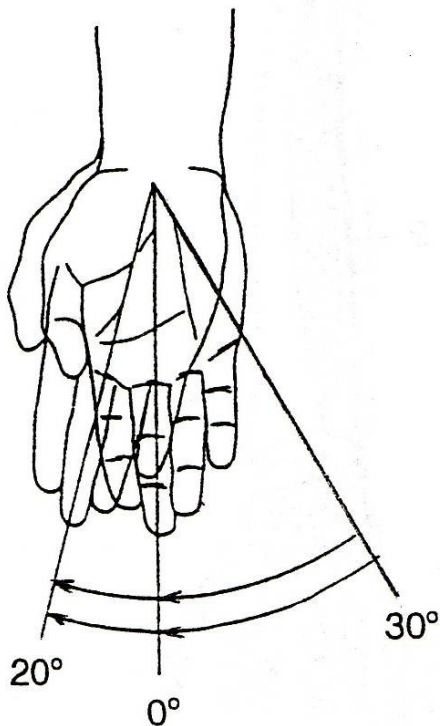


RADIÁLNÍ DUKCE

m. flexor carpi radialis

m. extensor carpi radialis longus

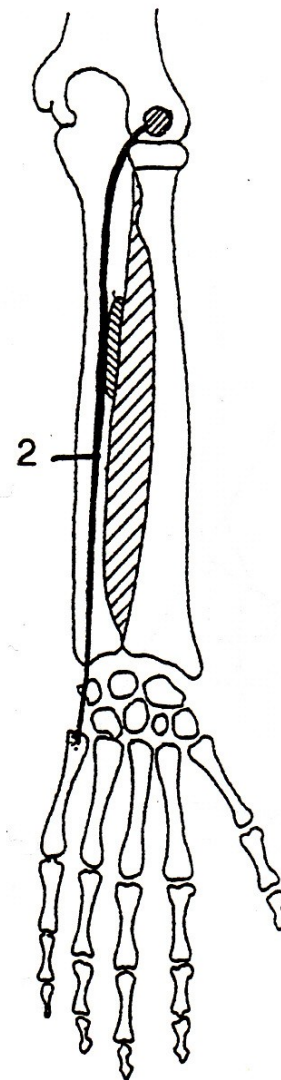
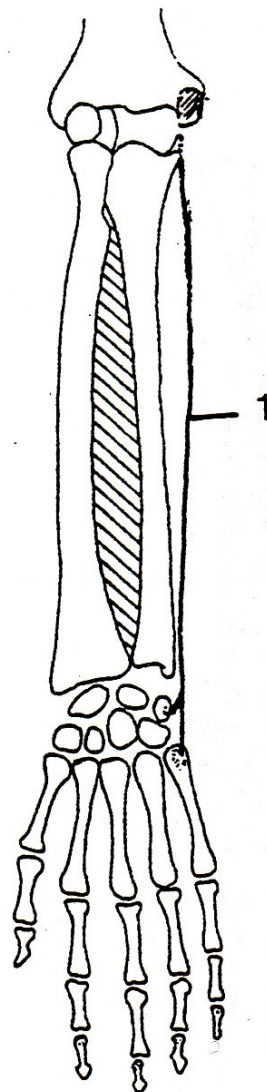
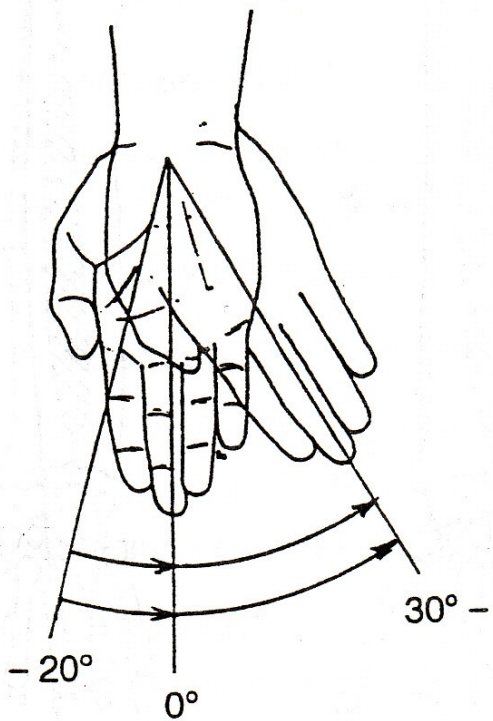
m. extensor carpi radialis brevis



ULNÁRNÍ DUKCE

m. flexor carpi ulnaris

m. extensor carpi ulnaris



POHYBY PRSTŮ

FLEXE - OHNUTÍ

EXTENZE - NATAŽENÍ

ABDUKCE - ODTAŽENÍ

ADDUKCE - PŘITAŽENÍ

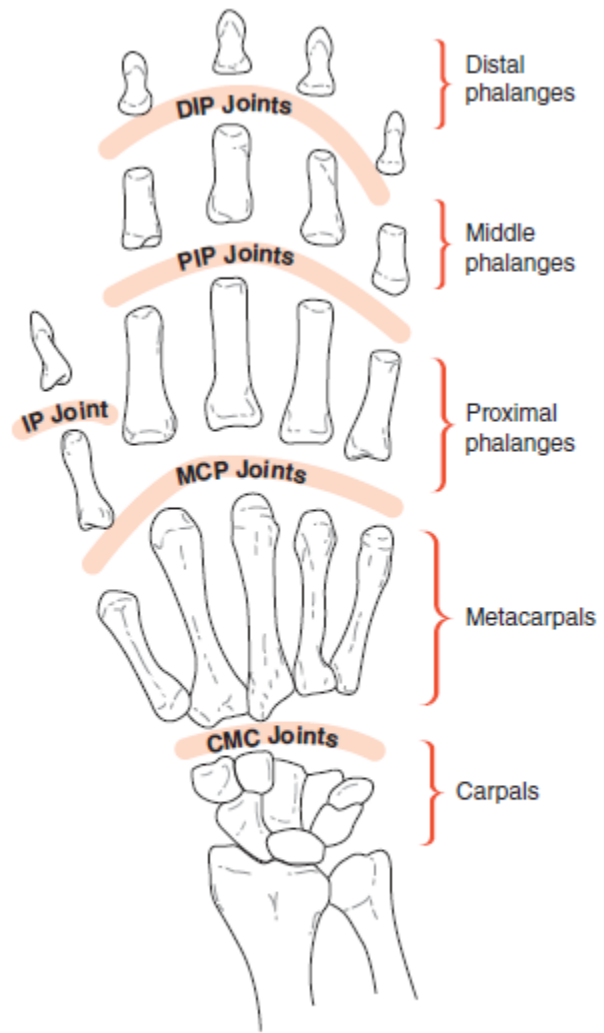
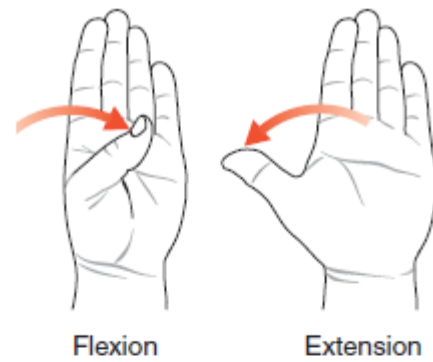
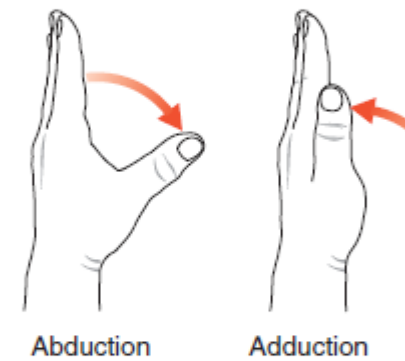


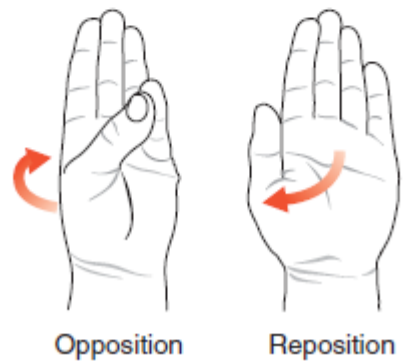
Figure 13-1. Joints and bones of the fingers and thumb (anterior view). Note that each finger has a DIP and PIP joint, whereas the thumb has only an IP joint.



Flexion Extension



Abduction Adduction



Opposition Reposition

Figure 13-3. Motions of the CMC joint of the thumb

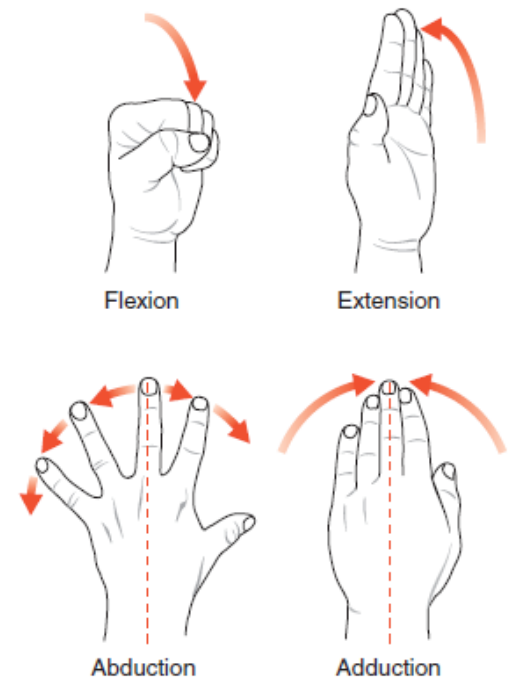
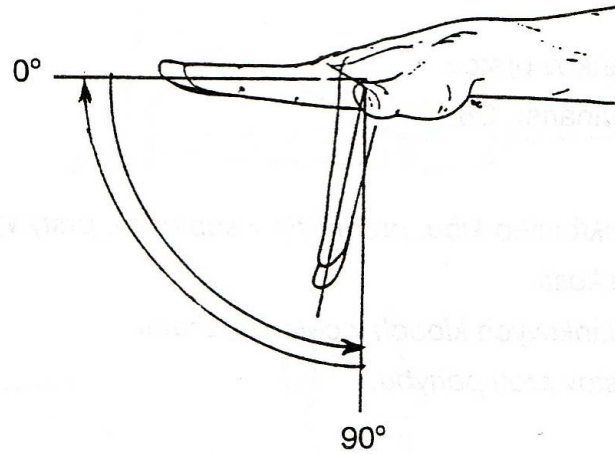
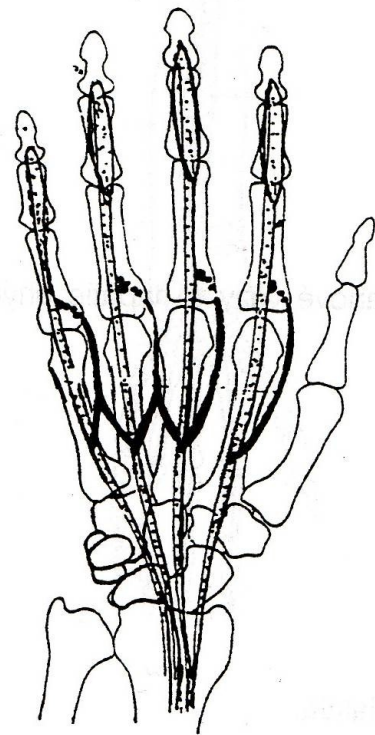


Figure 13-5. Motions of the metacarpophalangeal (MCP) joints and fingers.

FLEXE - OHNUTÍ

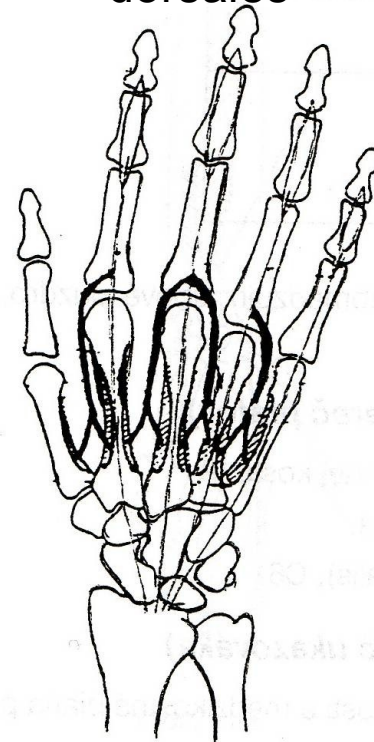


mm. lumbricales



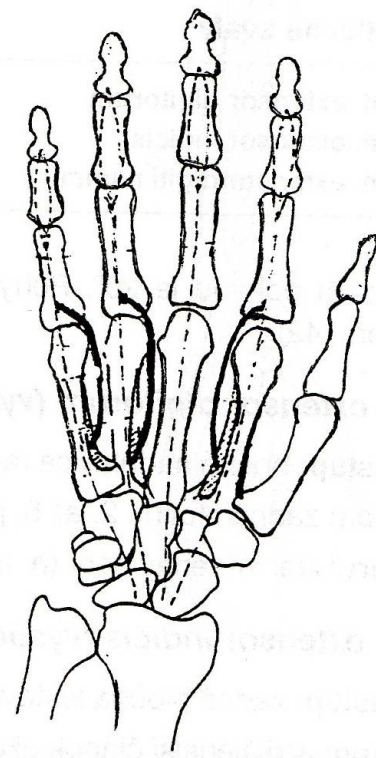
A

mm. Interossei dorsales

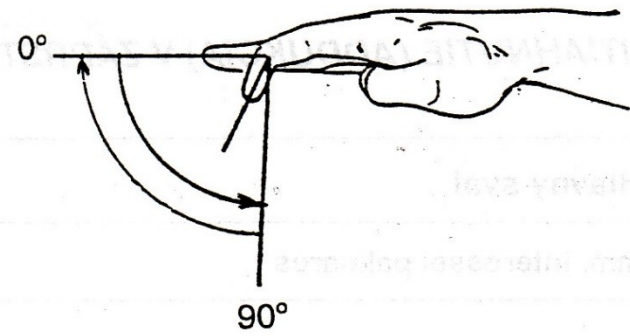
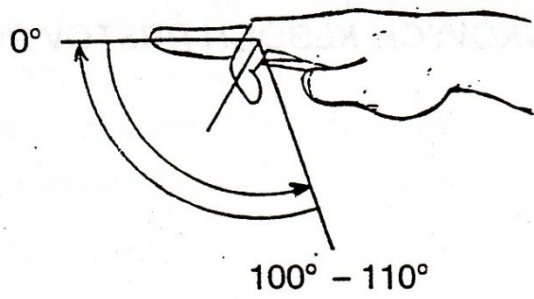


B

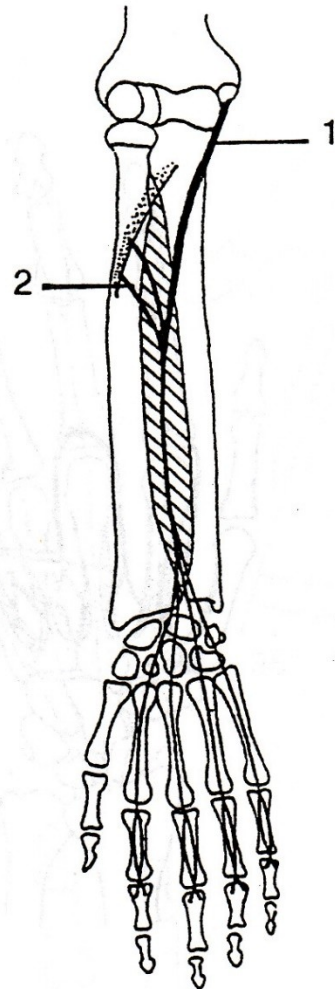
mm. Interossei palmares



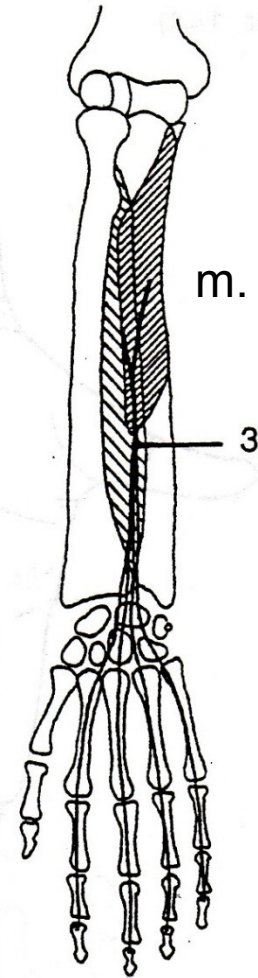
C



m. flexor digitorum superficialis

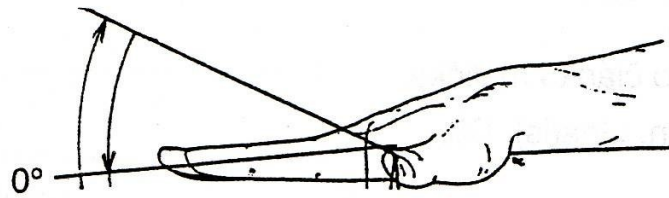


m. flexor digitorum profundus



EXTENZE - NATAŽENÍ

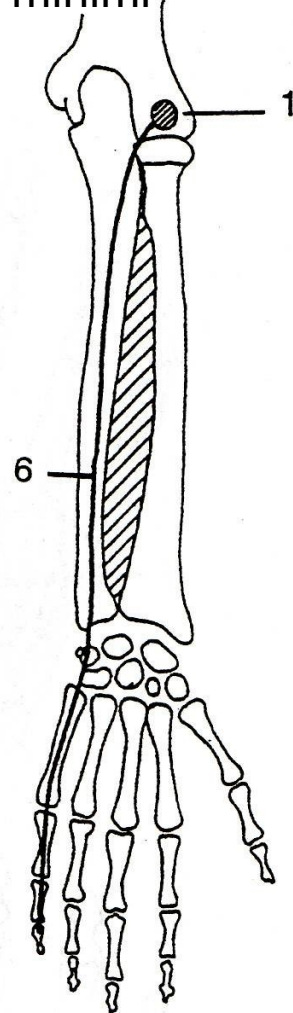
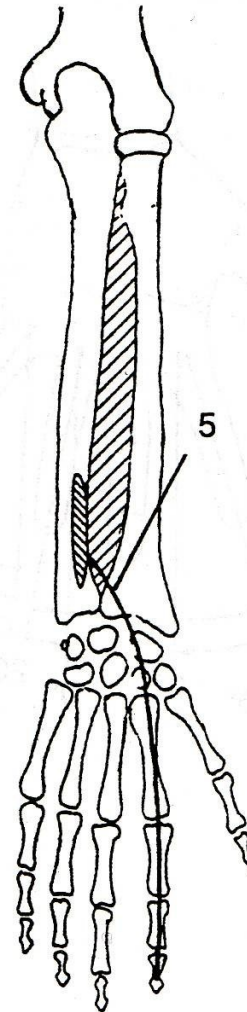
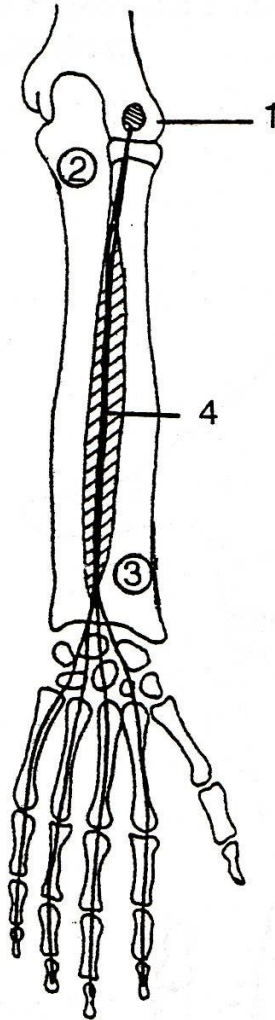
20° - 30°

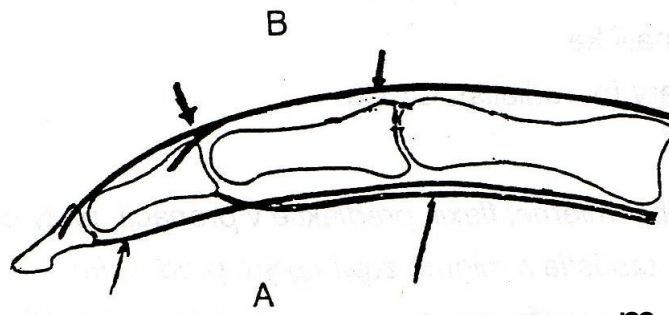


m. extensor indicis

m. extensor digiti
minimi

m. extensor digitorum

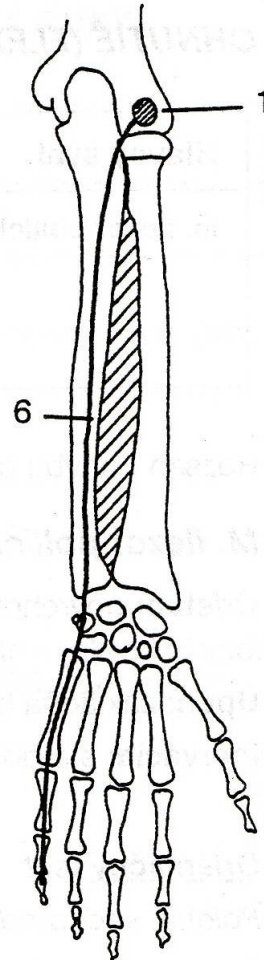
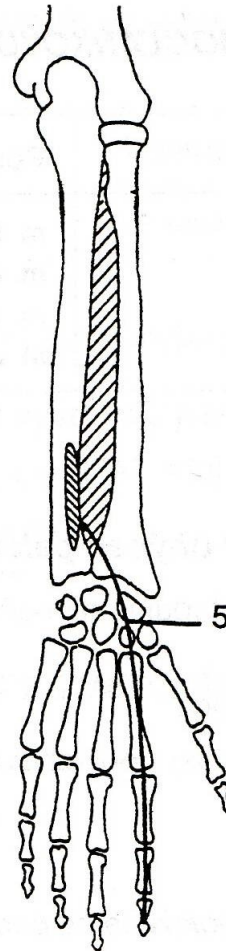
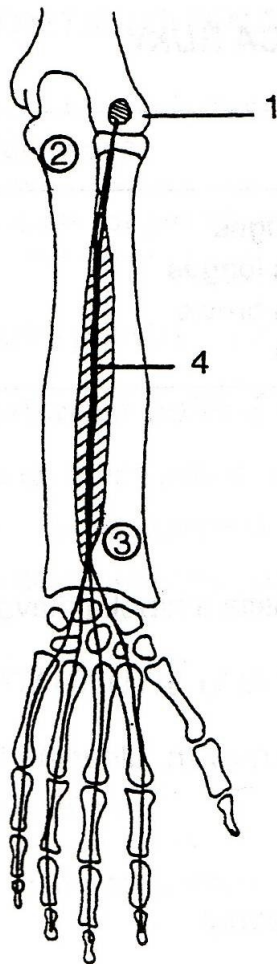


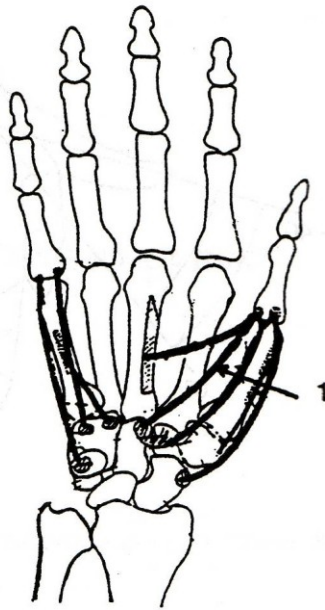
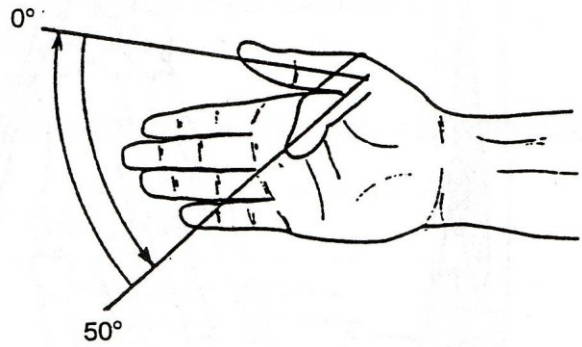


m. extensor indicis

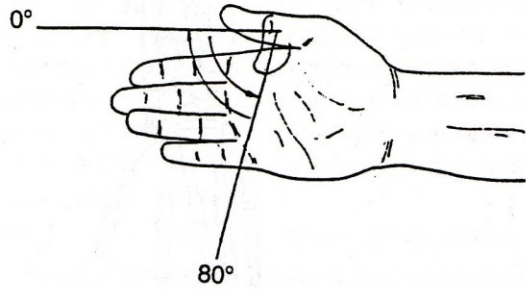
m. extensor digiti
minimi

m. extensor digitorum

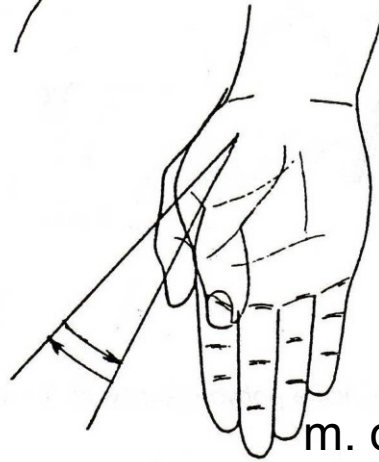
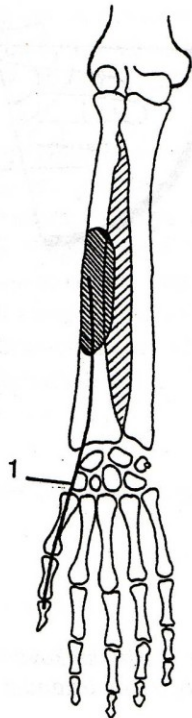




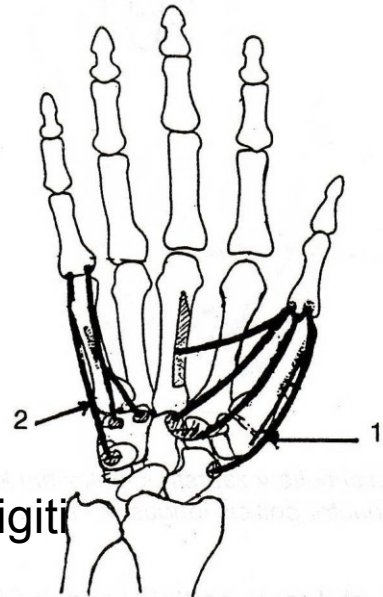
m. flexor pollicis brevis



m. flexor pollicis longus



m. opponens digiti
minimi



m. opponens pollicis