



# Kineziologické vyšetření

ASPEKCE II.





# Hýždě

- ▶ Tvar
- ▶ Symetrie
- ▶ Tonus
- ▶ Intergluteální rýha
- ▶ Infragluteální rýhy





# Hamstringy



- ▶ Napětí
- ▶ Prominence břicha
- ▶ Autoreparační mechanismus kompenzace antevertze pánve





# Adduktory kyčelního kloubu




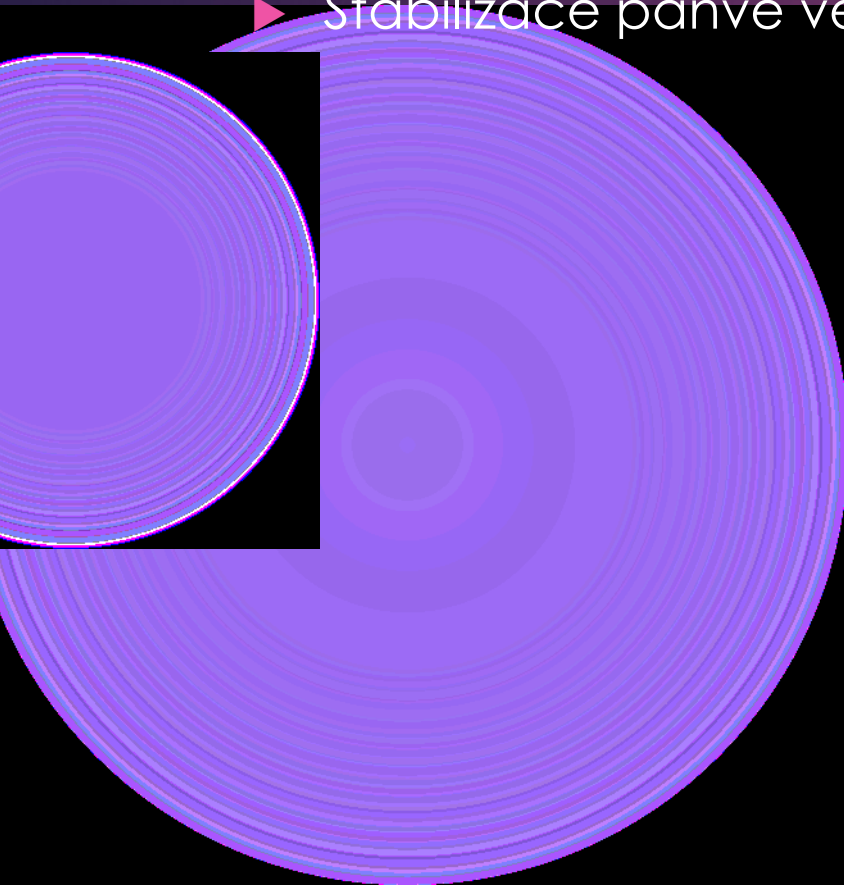
▶ Adduktorový zářez



# Musculus tensor fasciae latae




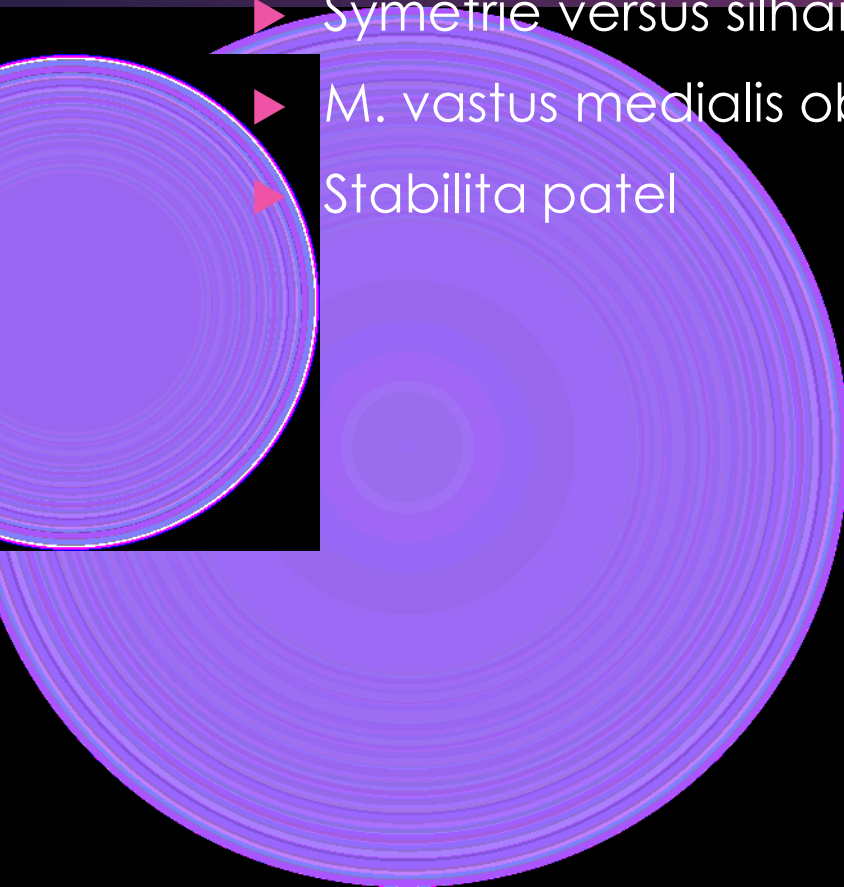


- ▶ Napětí
- ▶ Stabilizace pánve ve všech rovinách



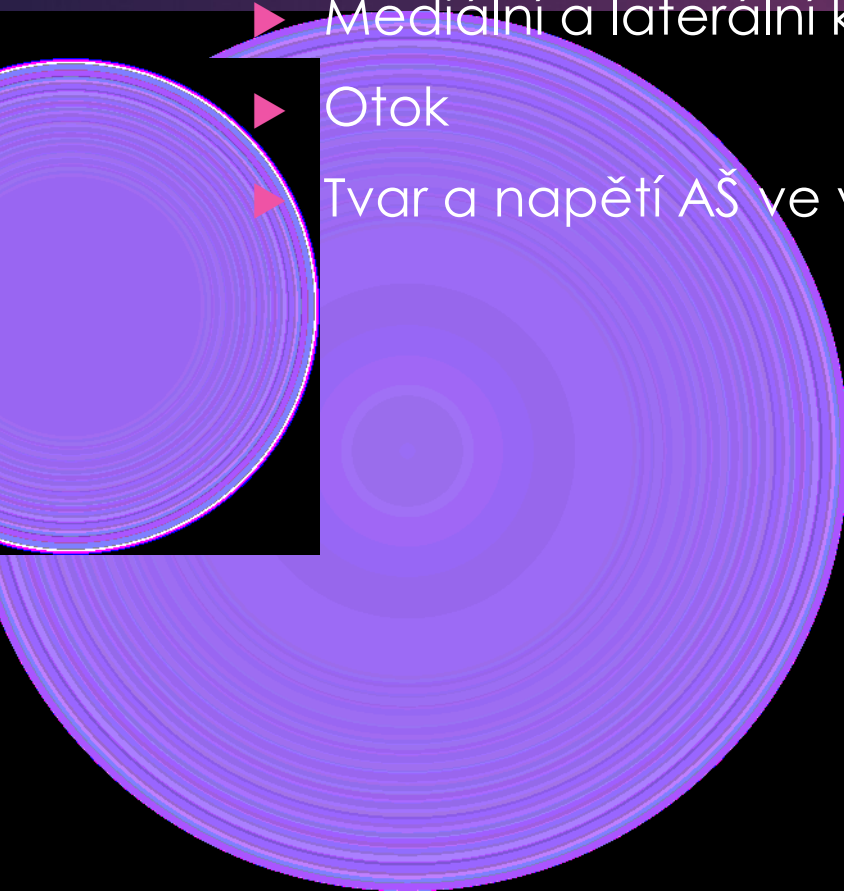

# Musculus quadriceps femoris

- ▶ Napětí
- ▶ Symetrie versus šilhání patel
- ▶ M. vastus medialis obliquus
- ▶ Stabilita patel






# Lýtka

- ▶ Tvar
- ▶ Mediální a laterální kontura
- ▶ Otok
- ▶ Tvar a napětí AŠ ve vztahu k zatížení paty



# Klenby a prstce



- ▶ Podélná klenba – mediální a laterální
- ▶ Příčná klenba – hallux valgus
- ▶ Zajištění klenby – kosti, vazy, svaly
- ▶ Prstce – funkce a tvarové deformity








# Páteř

- ▶ Postavení ve frontální rovině
- ▶ Konkludentní a nekonkludentní křivka
- ▶ Skolióza a skoliotické držení
- ▶ Laterální shift ramen
- ▶ Tajle






# Lopatky

- ▶ Klidové postavení
- ▶ Svalové zajištění
  - ▶ Horní, střední a dolní fixátory lopatek
  - ▶ Svalové smyčky
- ▶ Dynamická stabilizace
- ▶ Centrace versus stabilizace
- ▶ Horní, střední a dolní fixátory lopatek





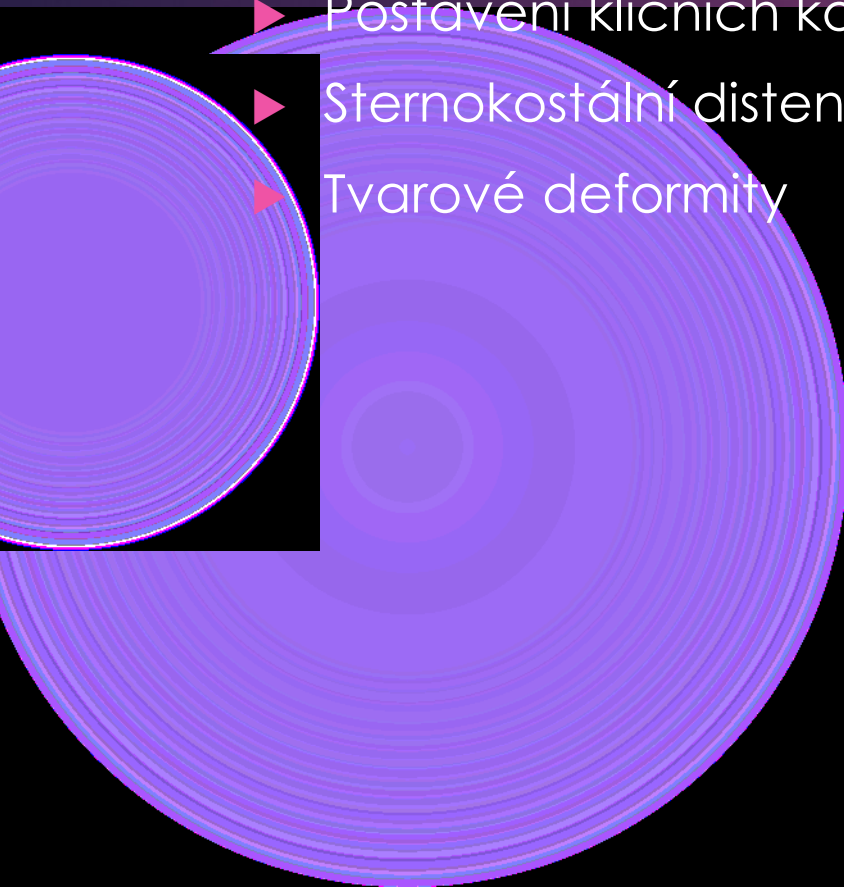
# Břišní stěna

- ▶ Šilhání pupku
- ▶ Prominence svalů
- ▶ Prominence celé břišní stěny



# Hrudník zepředu



- ▶ Postavení ramen
- ▶ Postavení klíčních kostí
- ▶ Sternokostální distenze
- ▶ Tvarové deformity



# Krk zepředu

- ▶ M. sternocleidomastoideus

- ▶ Polykací akt jazylky





# Obličej

- ▶ Mimika

- ▶ Zvýšená a snižená

- ▶ Strukturální změny

- ▶ Skolióza obličeje



# Horní končetiny

▶ Držení horních končetin

▶ Vnitřní rotace

▶ Flexe

▶ Prokrvení horních končetin

