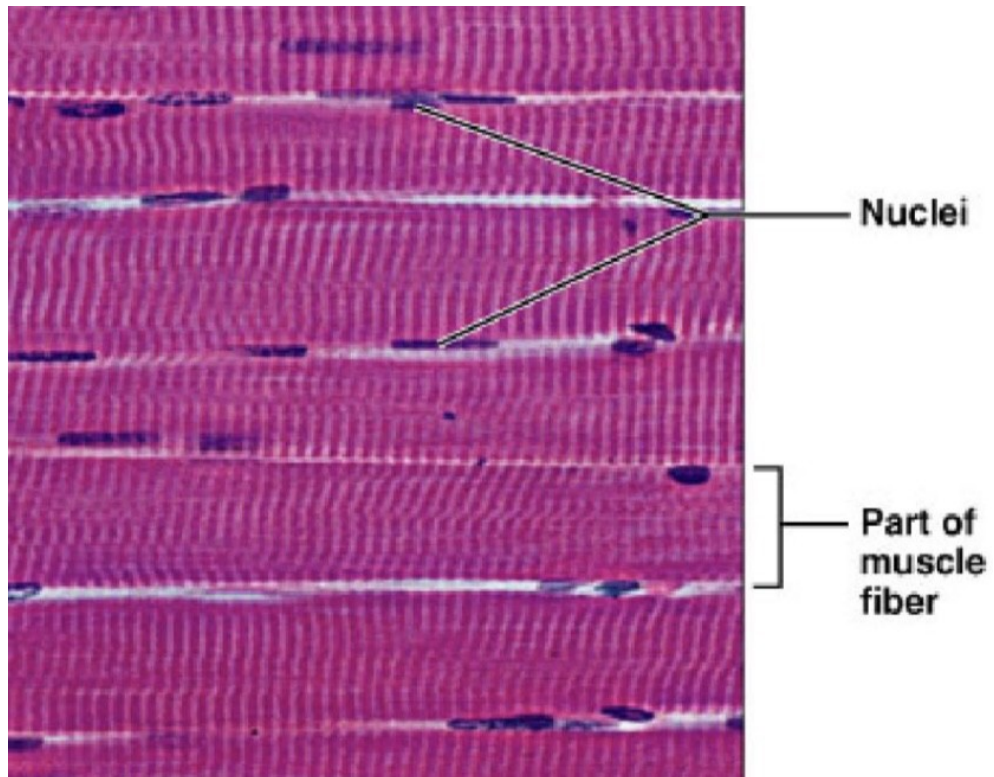


Svalová tkáň – komentovaná prezentace

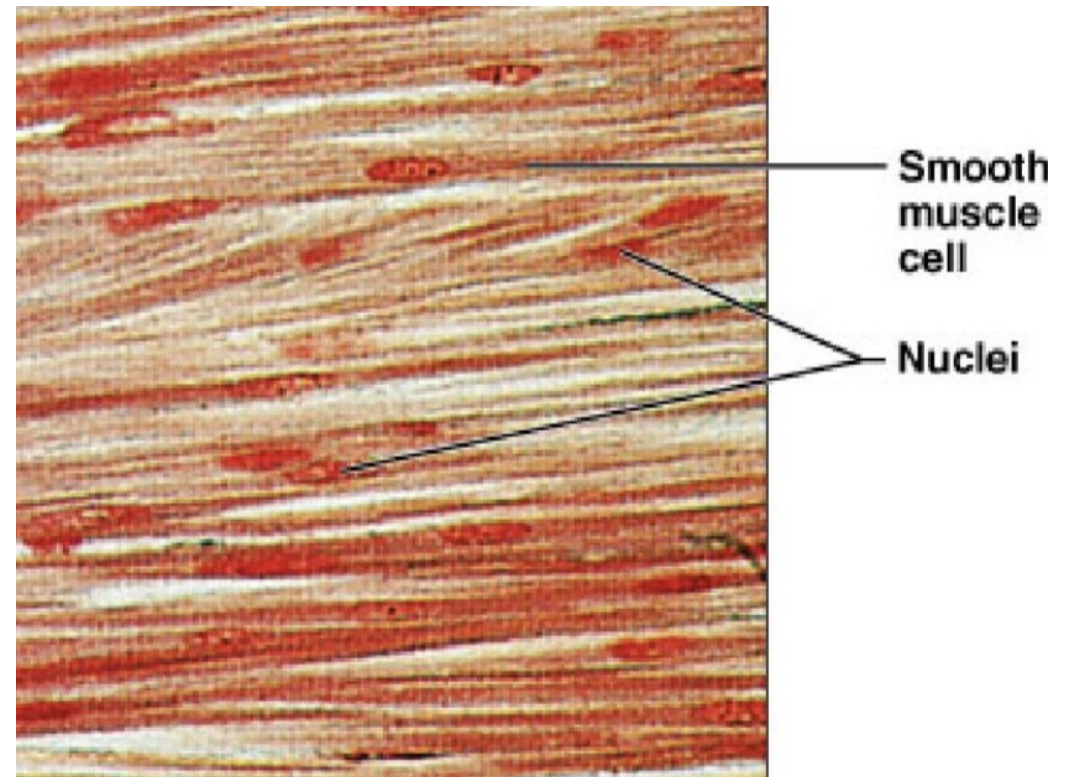
Mgr. Romana Klášterecká, Ph.D.

Svalová tkáň

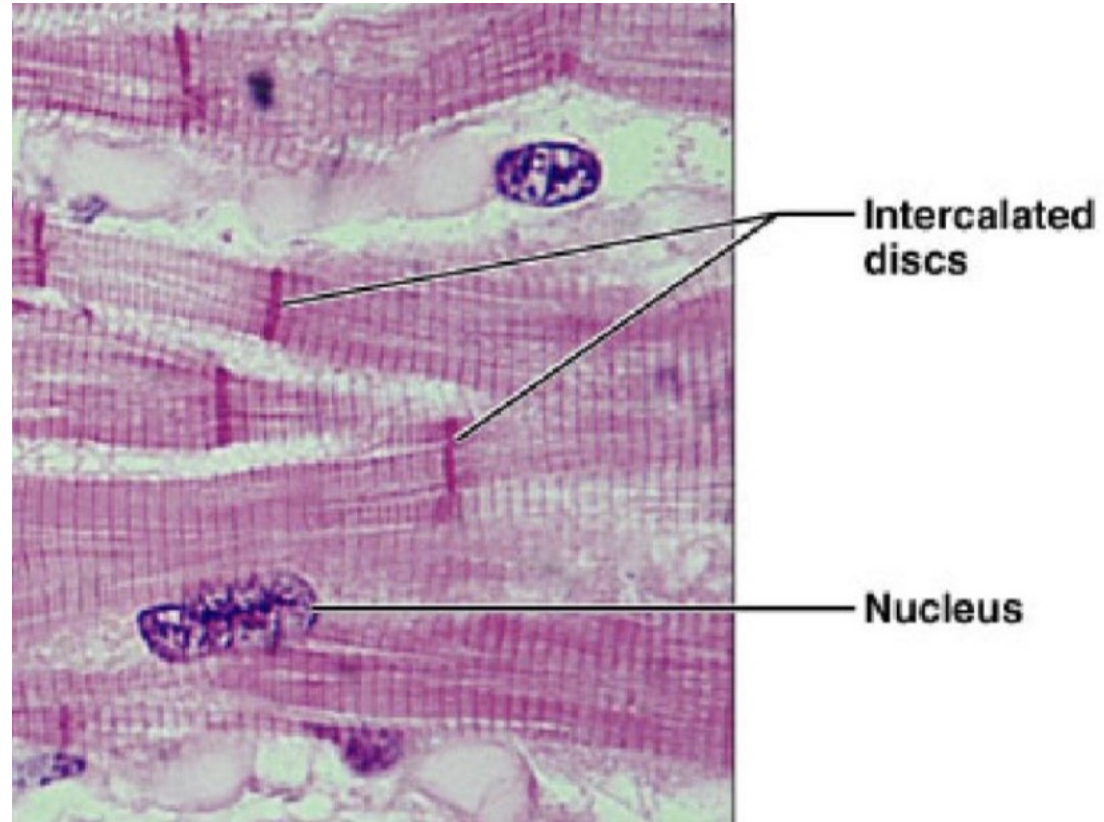
Kosterní



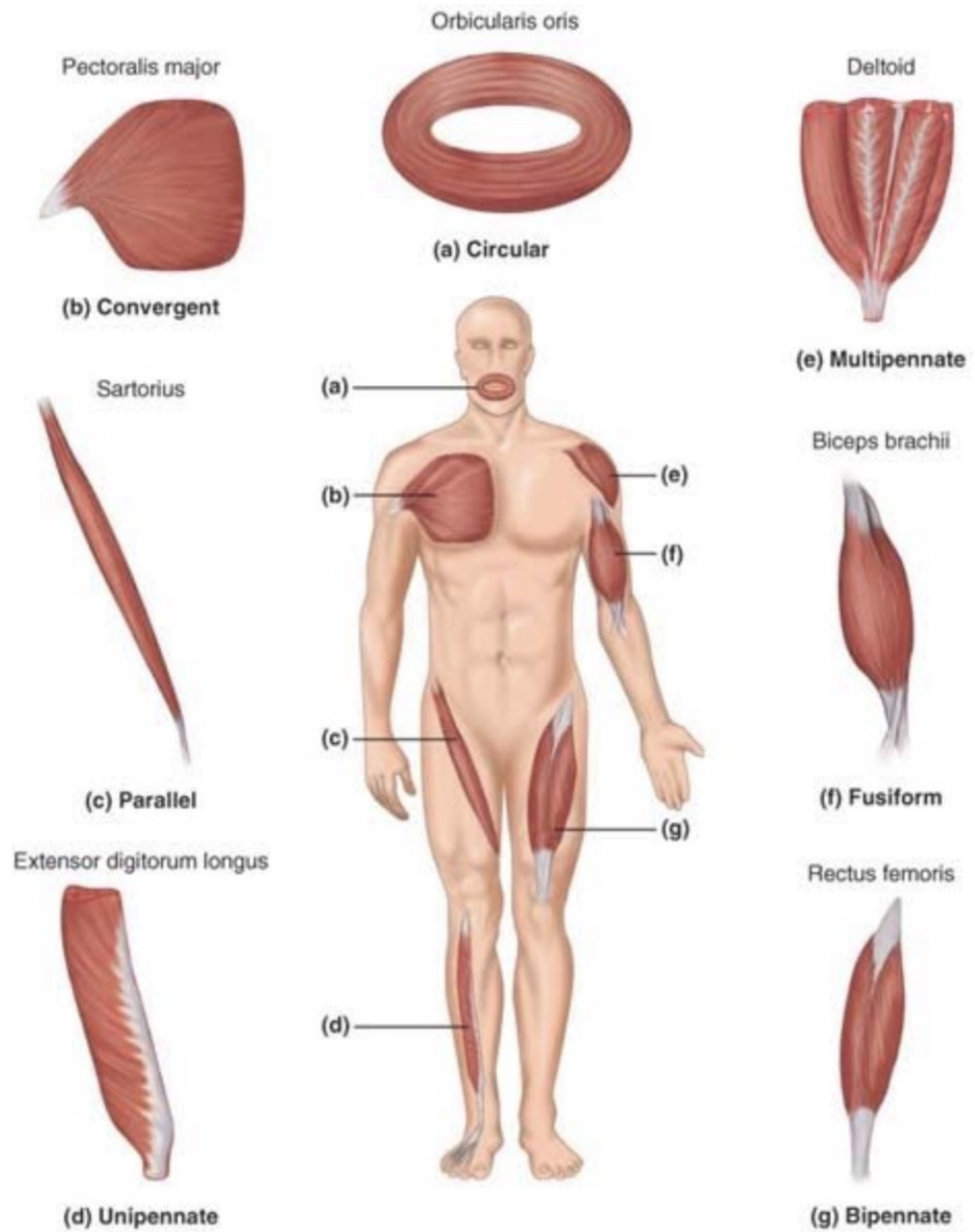
Hladká



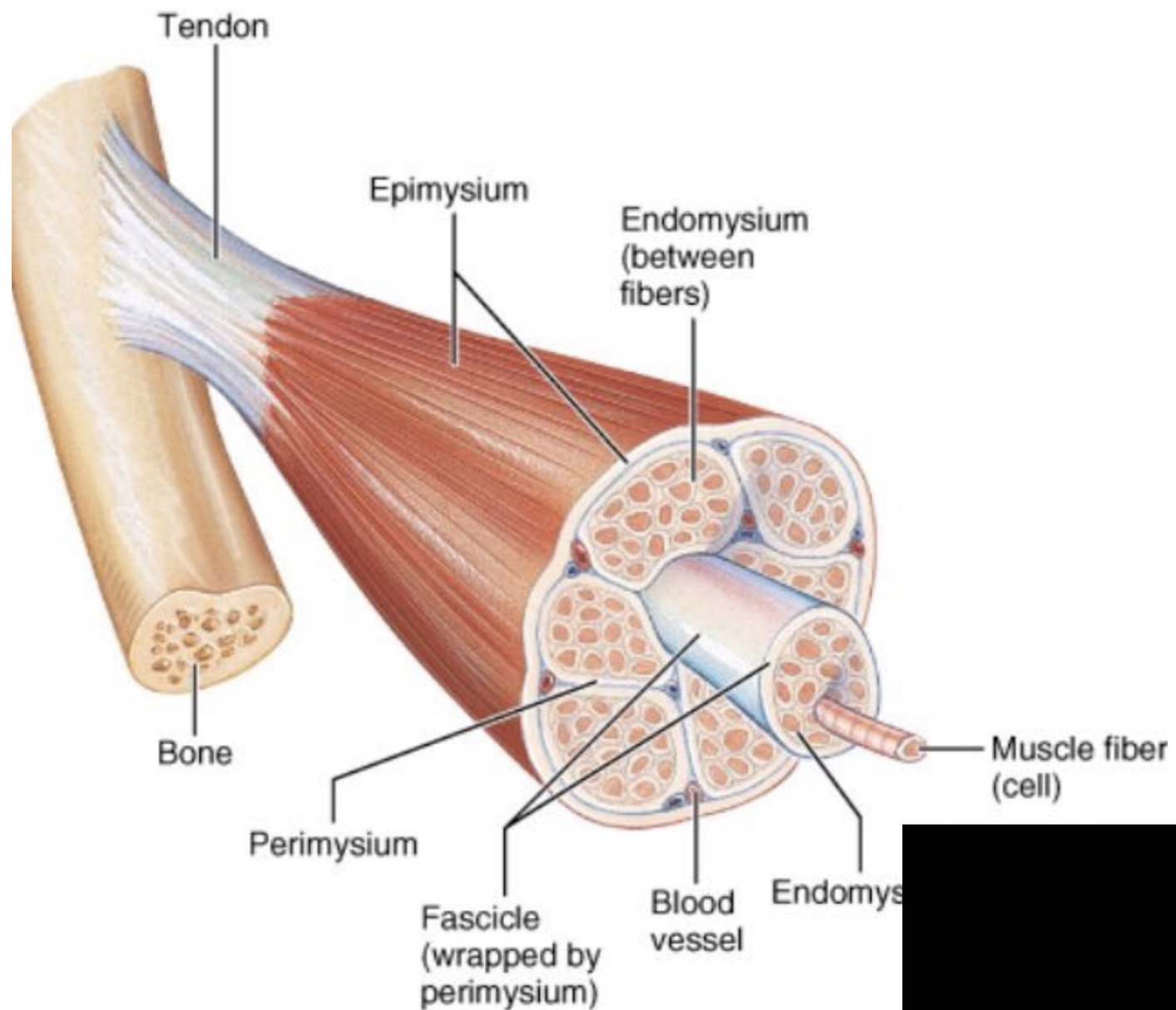
Svalová tkáň - srdeční



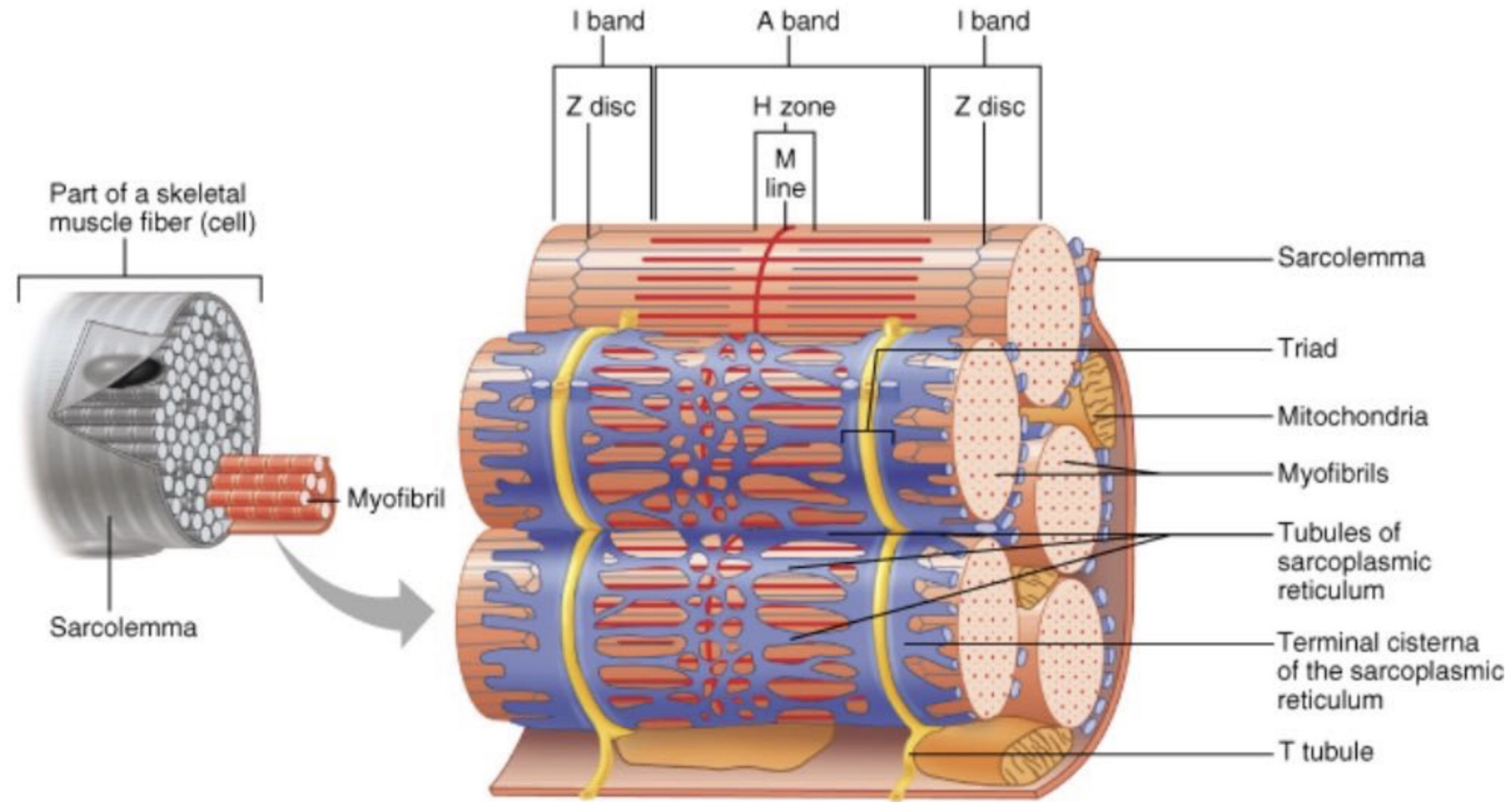
Tvary svalů



Složení svalu



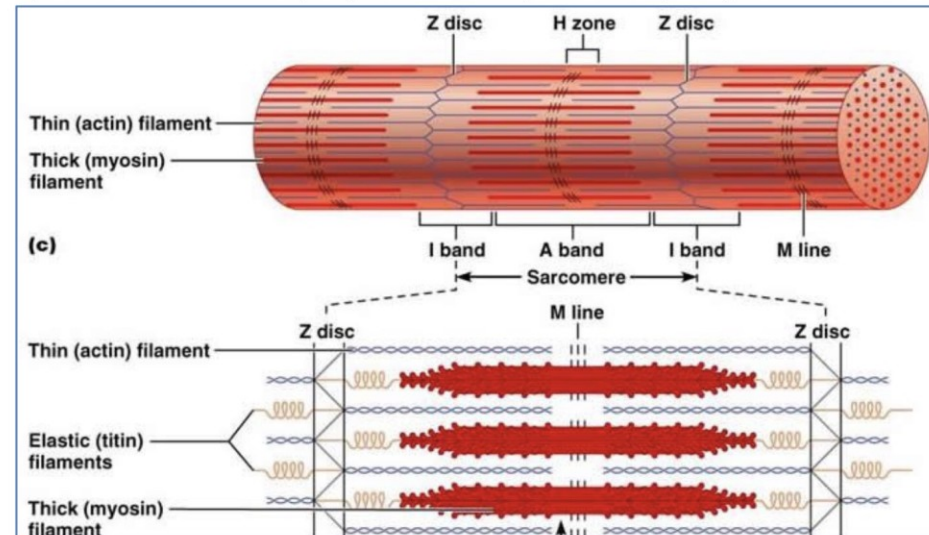
Svalová tkáň



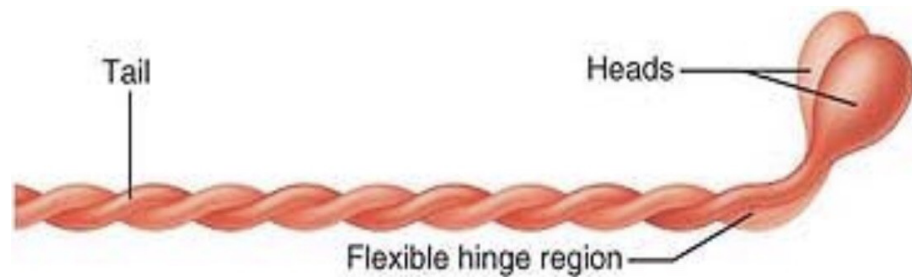
Organizace svalové tkáně

Organisation of Muscle Tissue:

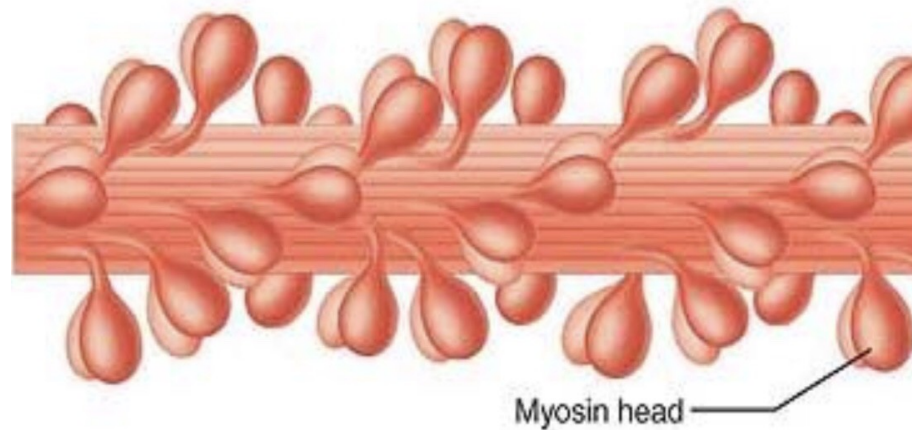
- **Individual Muscle Fibres**
 - Each Muscle Fibre Contains many **Myofibrils (a Muscle Cell's Contractile *Organelles*)**.
 - Each Myofibril contains many **Myo-Filaments (Actin & Myosin) – Contractile *Proteins***.



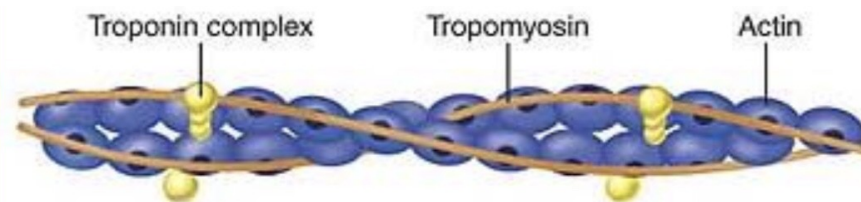
Molekulární stavba



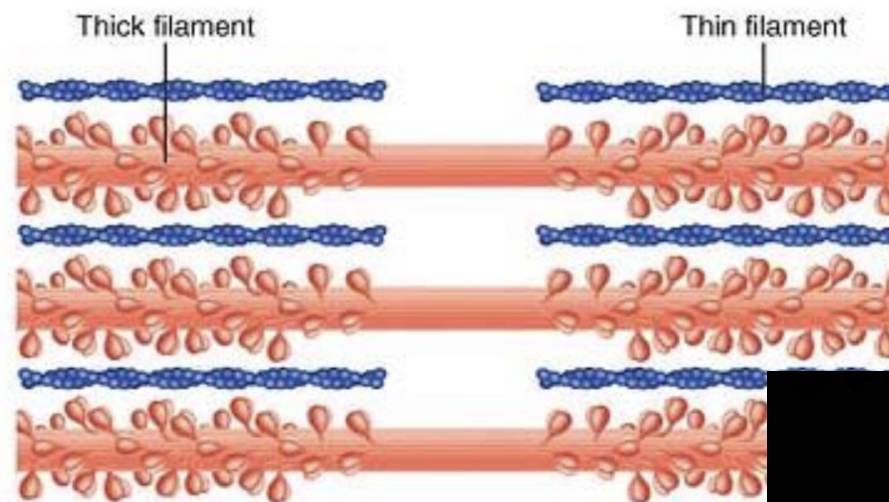
(a) Myosin molecule



(b) Portion of a thick filament

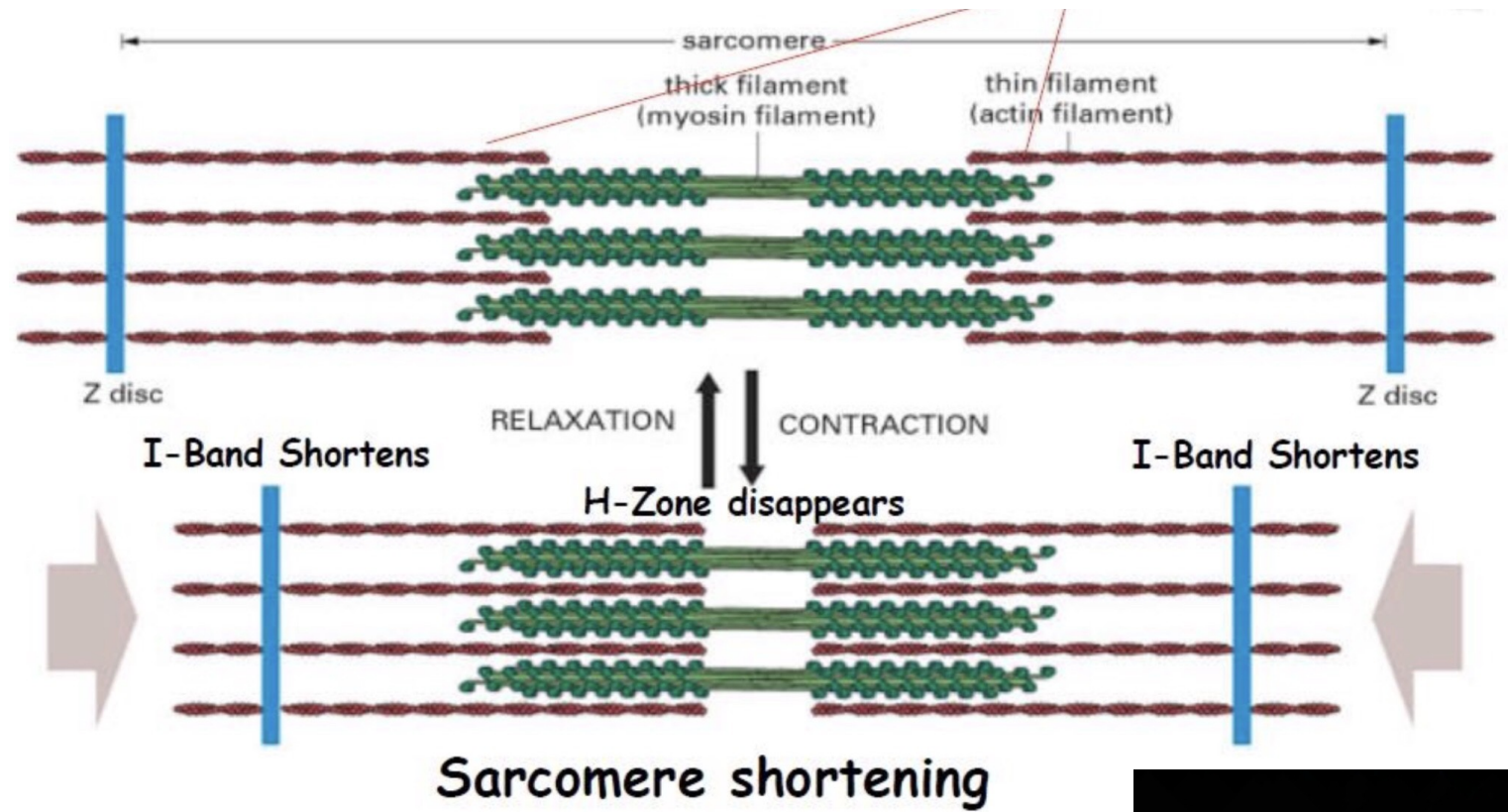


(c) Portion of a thin filament

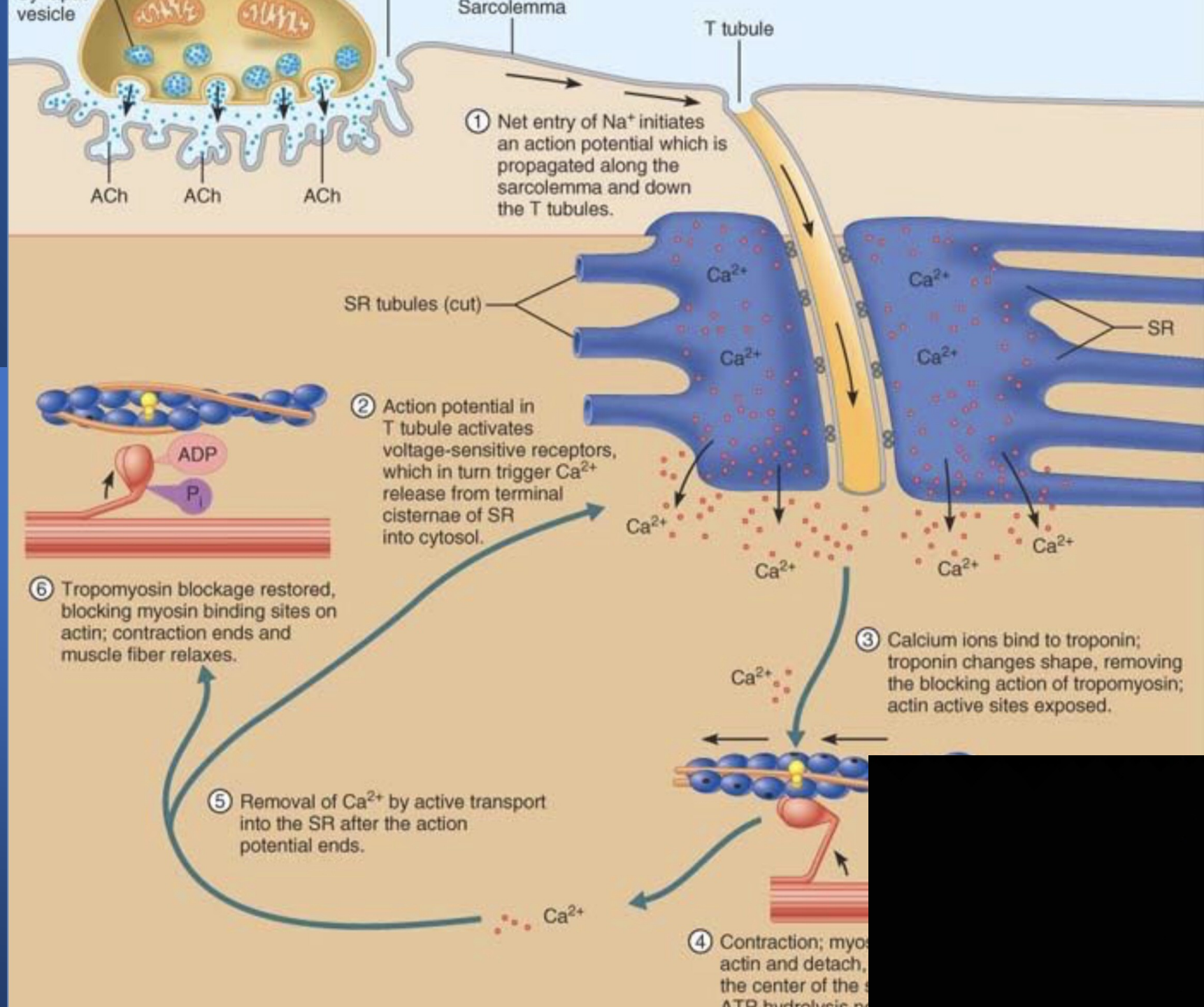


(d) Longitudinal section of filaments within one sarcomere of a myofibril

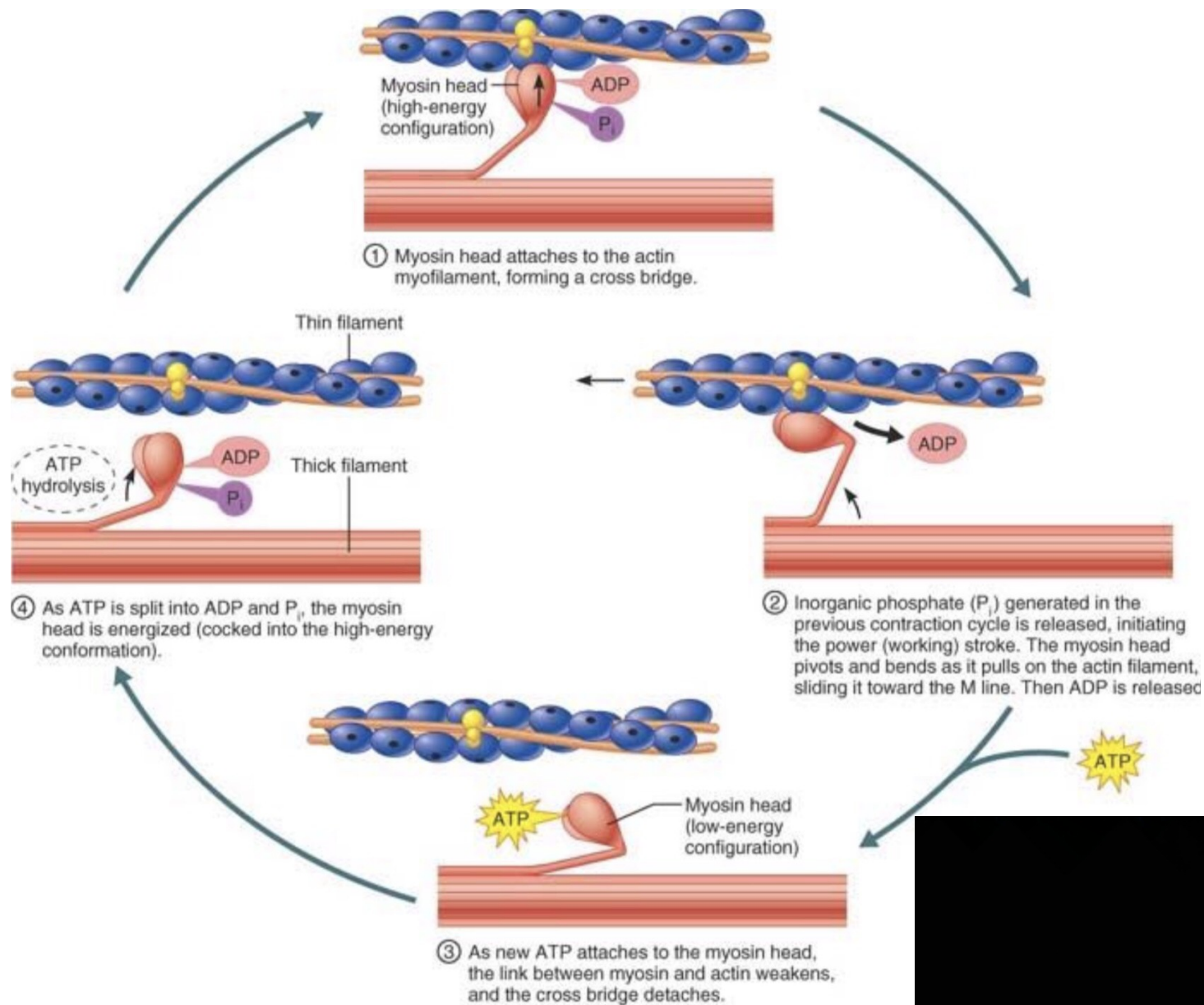
Kontrakce svalu



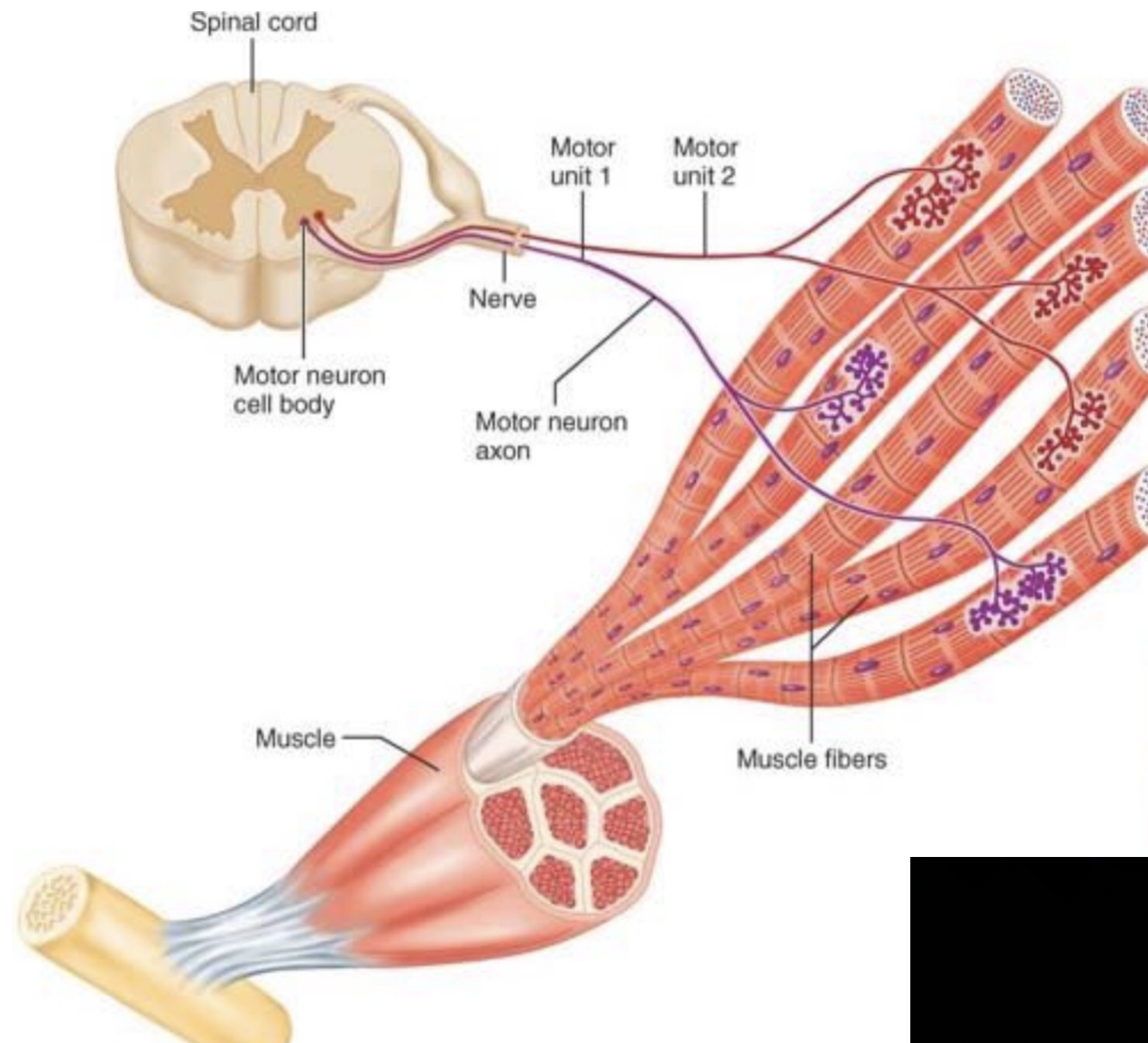
Fyziologie svalové tkáně



Fyziologie svalové tkáně

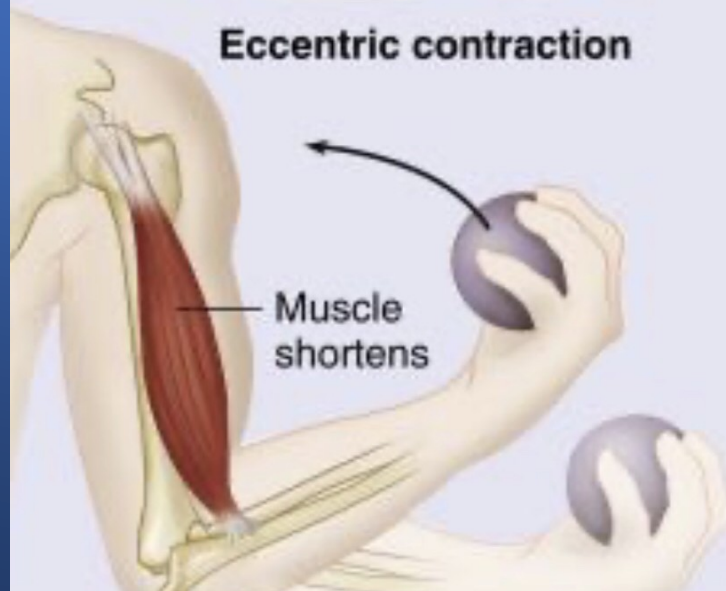
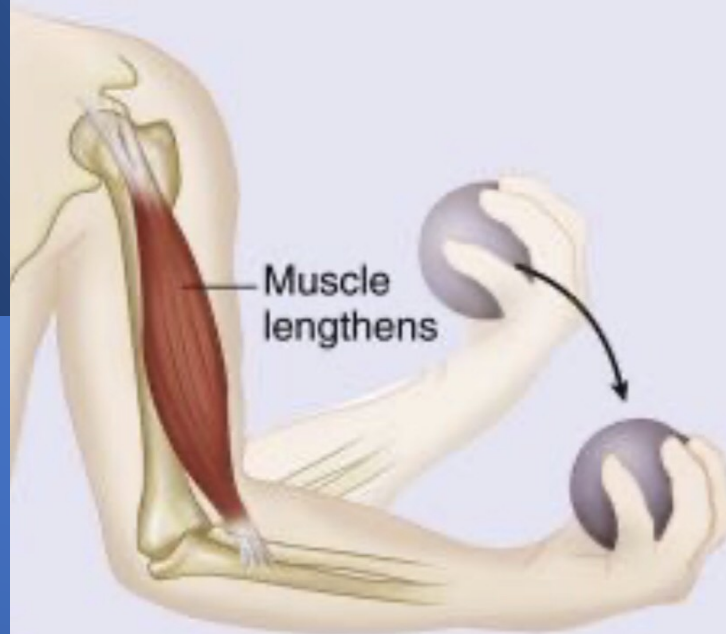


Motorická jednotka



Biomechanika svalu

ISOTONIC
Same tension; changing length



ISOMETRIC
Same length; changing tension

