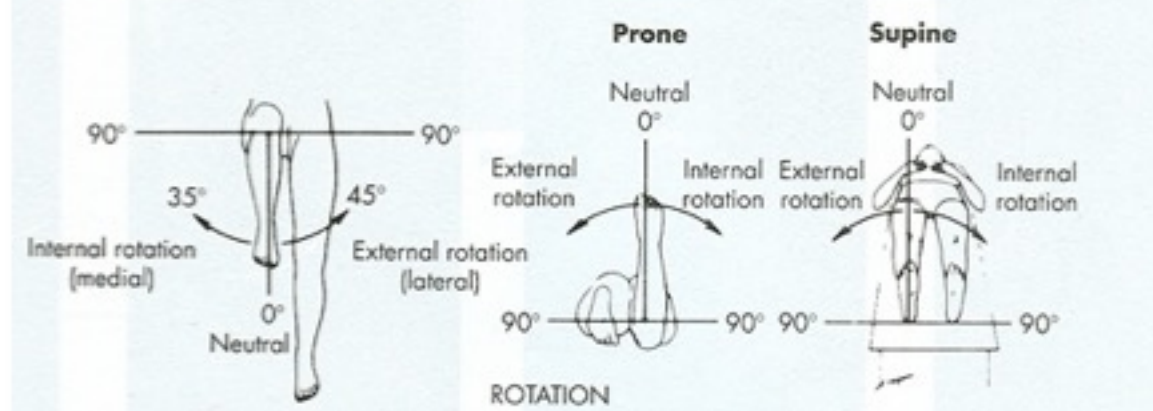
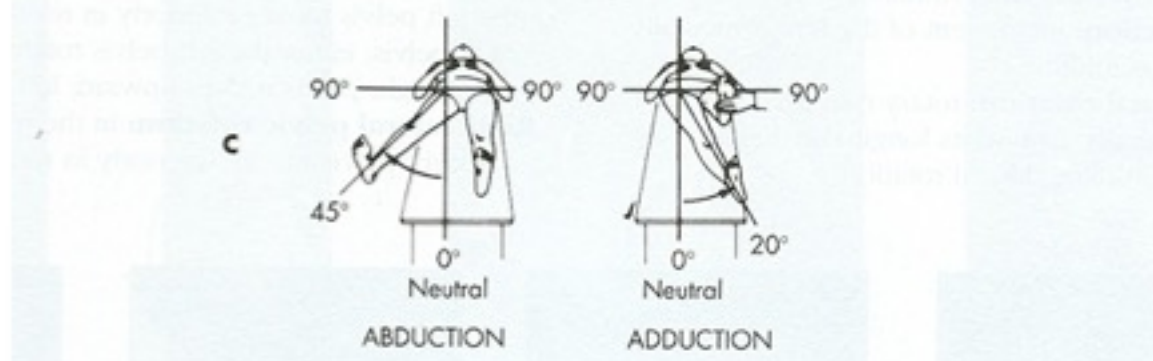
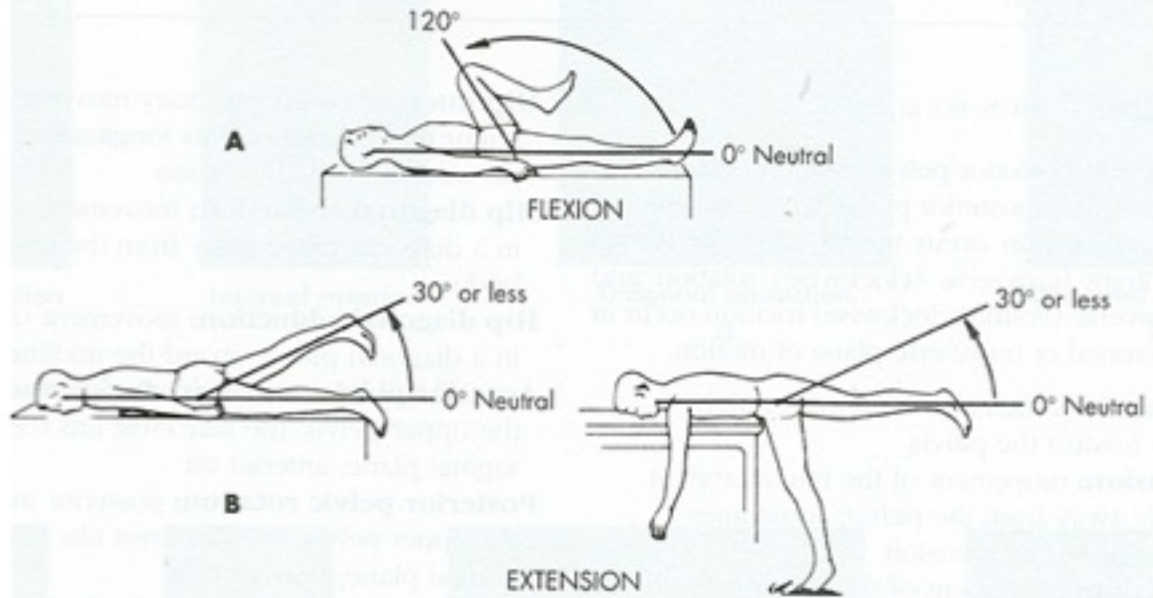


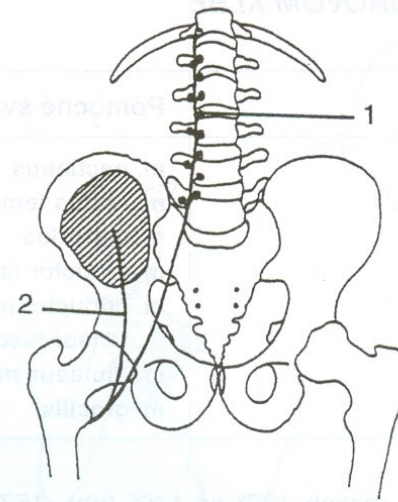
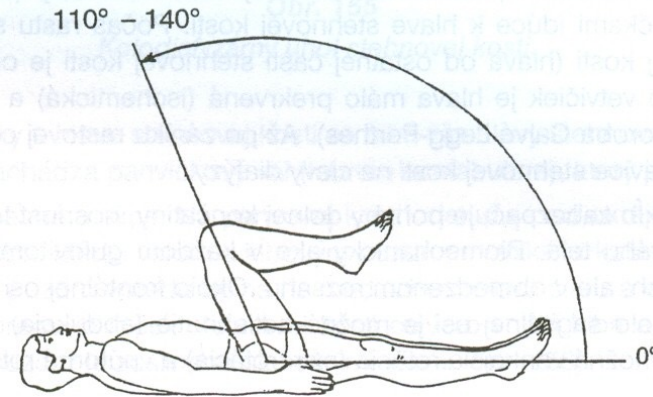
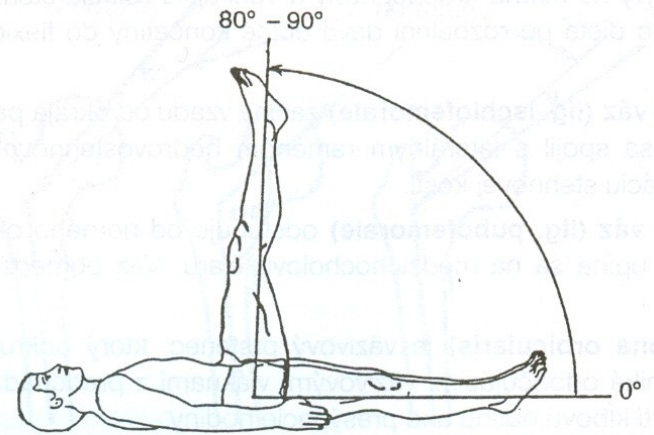
# Kineziologie kyčle

Mgr. Klára Vomáčková



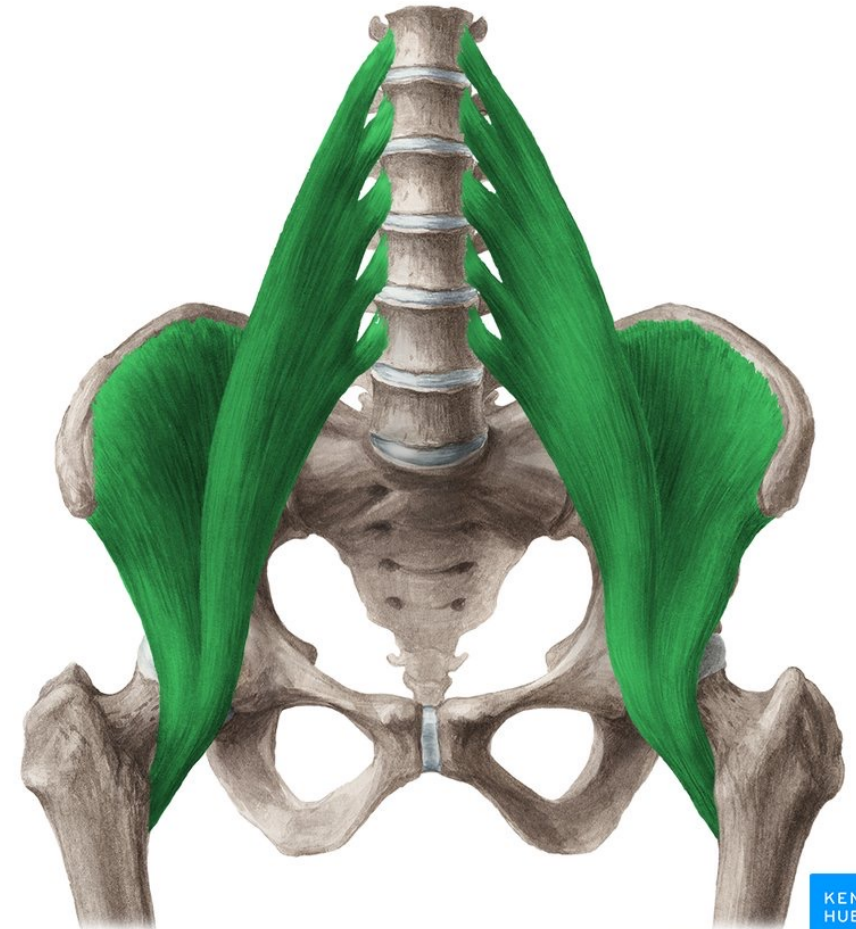
# Flexe

- M. iliopsoas
- M. sartorius
- M. rectus femoris
- M. pectineus
- M. gracilis



# M. iliopsoas

- Z: těla obratlů Th12-L5, processus costarii L1-L5
- Ú: trochanter minor
- Inervace: nervus femoralis, přímé větve z plexus lumbalis L1-L3
- Funkce: flexe dkk, pomocná addukce v KYK, (neprovádí rotaci)!



# M.sartorius

- SIAS- **pes anserinus**
- N. femoralis
- Nejdelší sval těla
- 4-5cm široká „stuha“
- Ošetření: pressura
- Často 3 reflexní změny

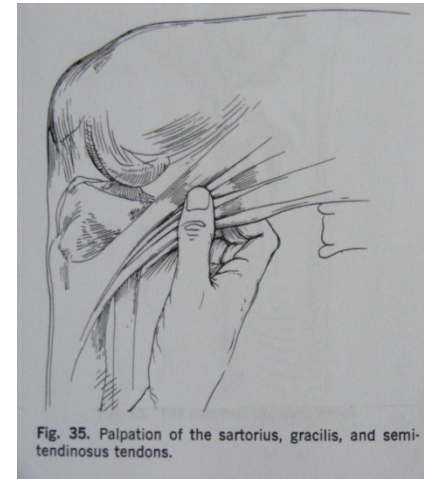
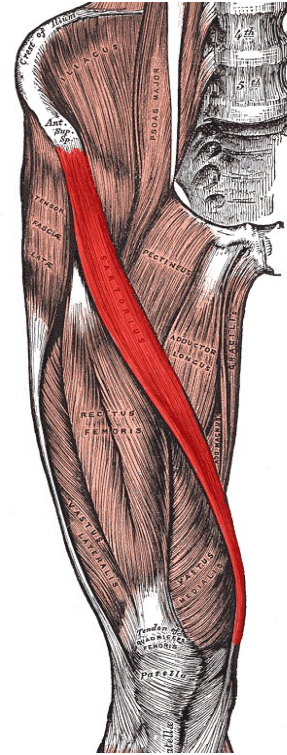
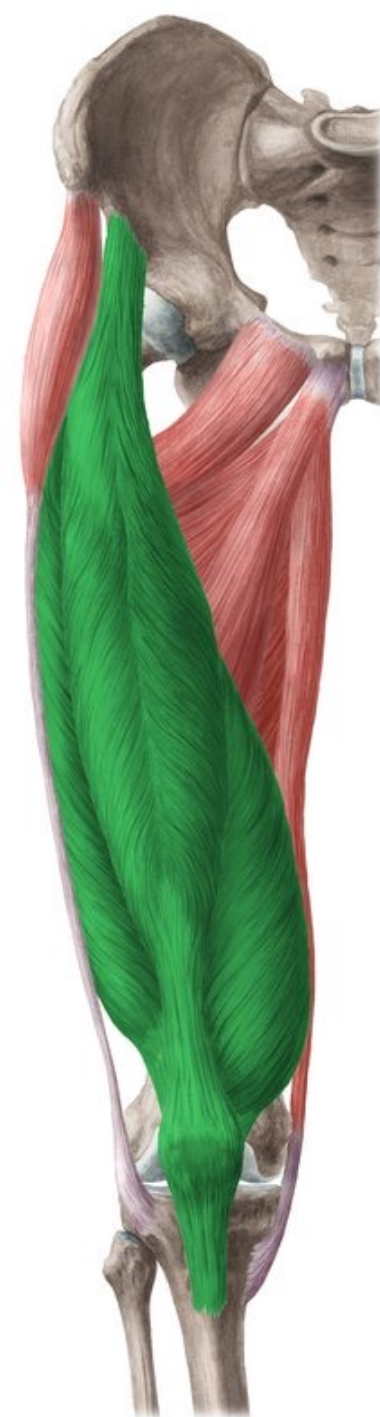


Fig. 35. Palpation of the sartorius, gracilis, and semitendinosus tendons.

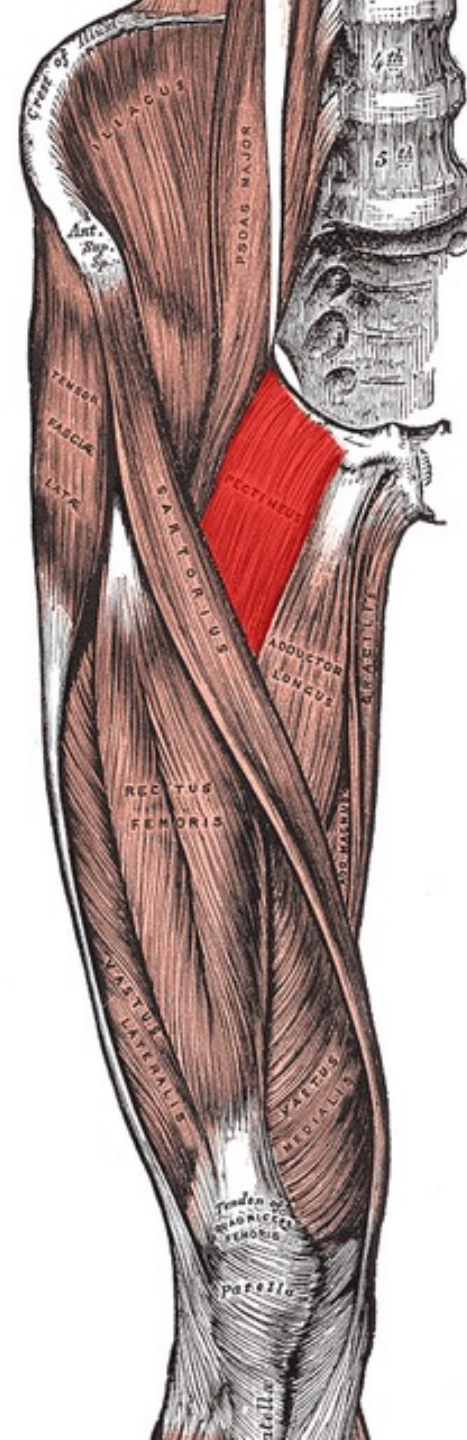
# M. Rectus femoris

- Z: spina iliaca anterior inferior
- Ú: Tuberositas tibiae
- I: n. femoralis (L2-L4)
- F: KYK – FL, KOK-EXT



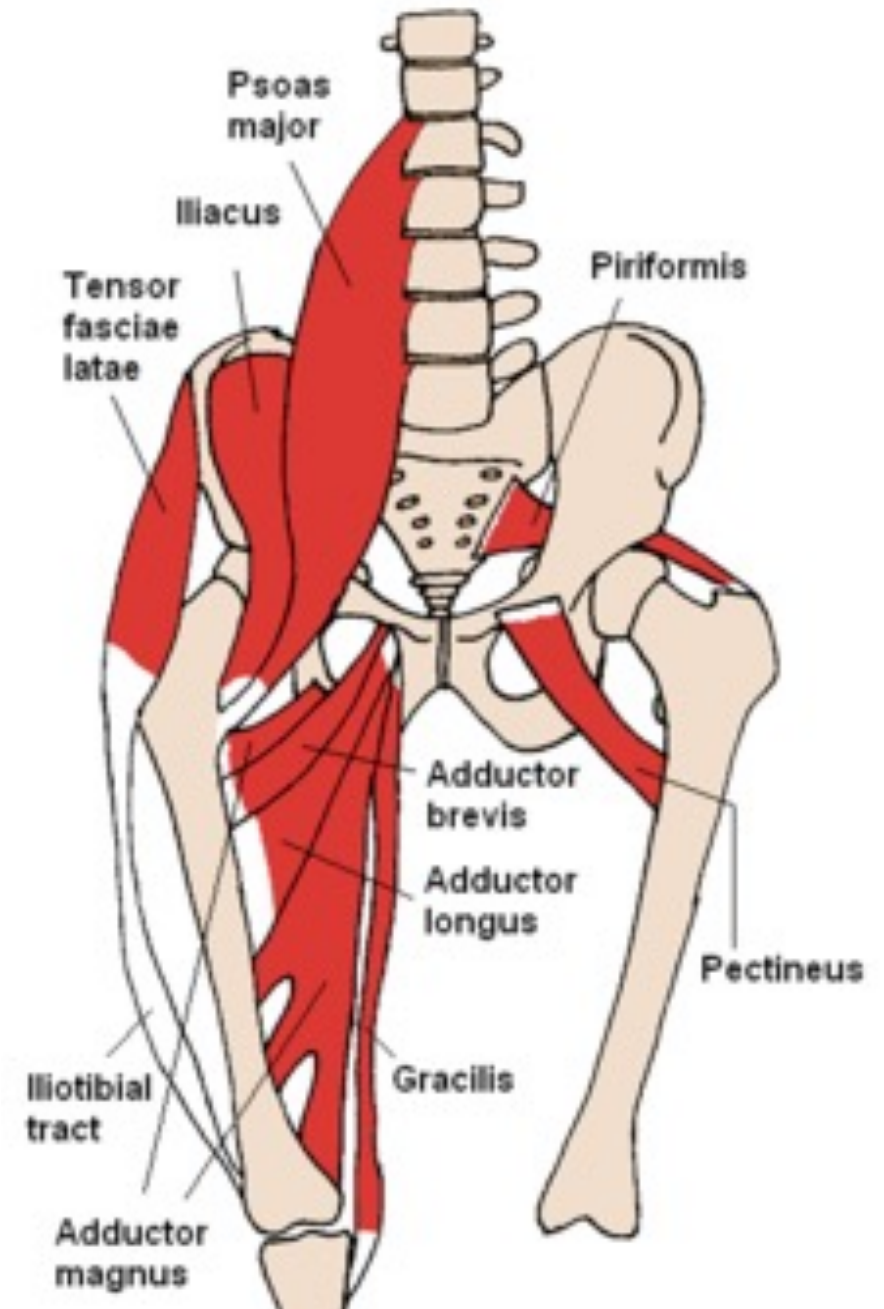
# M. pectineus

- Z: pecten ossis pubis
- Ú: linea pectinea femoris
- I: n. femoralis, n. obturatorius
- F: add, Fl, ZR v KYK



# M. gracilis

- Z: ramus inferior ossis pubis
- Ú: Condylus medialis tibiae (pes anserinus)
- I: n. obturatorius
- F: KYK- add, KOK-FL, VR



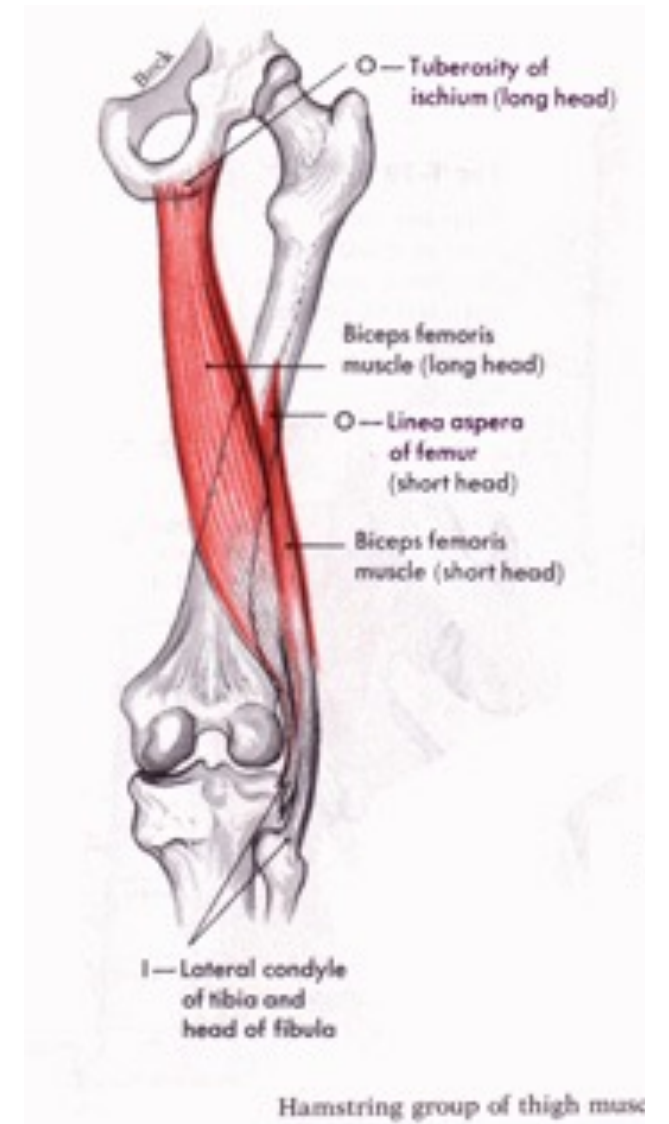


# Extenze

- M. gluteus maximus
- M. biceps femoris
- M. semitendinosus
- M. semimembranosus

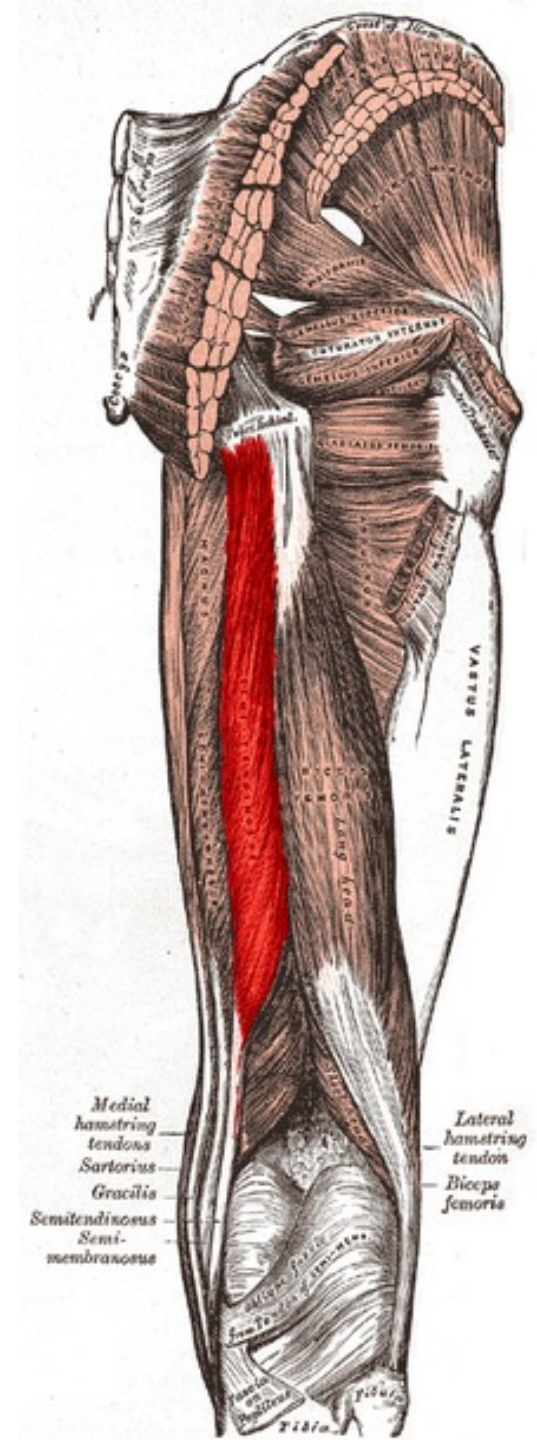
# M. Biceps femoris

- Z: caput longum - tuber ischiadicum, caput breve labium laterale lineae asperae
- Ú: capitulum fibulae
- Často evokuje fční zkrat DK
- F: KOK- FL, KYK – EX, ZR



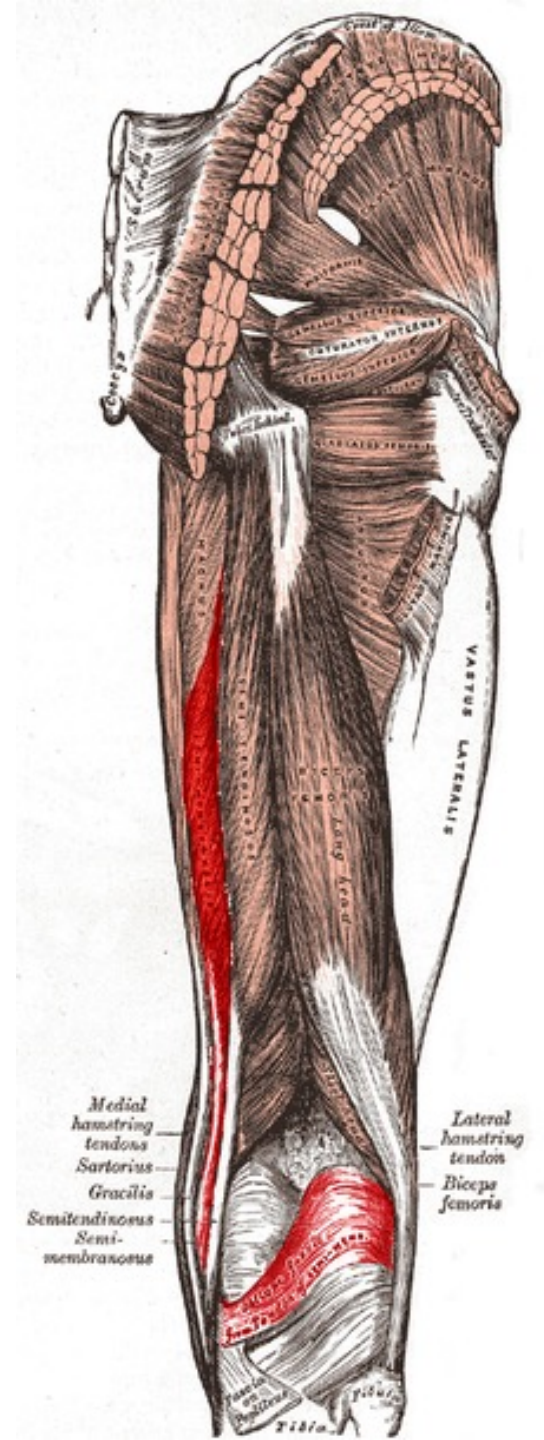
# M. semitendinosus

- Z: tuber ischiadicum
- Ú: condilus medialis tibiae (pes anserinus)
- I: n. ischiadicus
- F: KOK – FL, VR, KYK - Ext



# M. semimembranosus

- Z: tuber ischiadicum
- Ú: condylus medialis tibiae, ligamentum popliteum obliquum
- I: n. ischiadicus
- F: KOK – FL,VR, KYK - EX

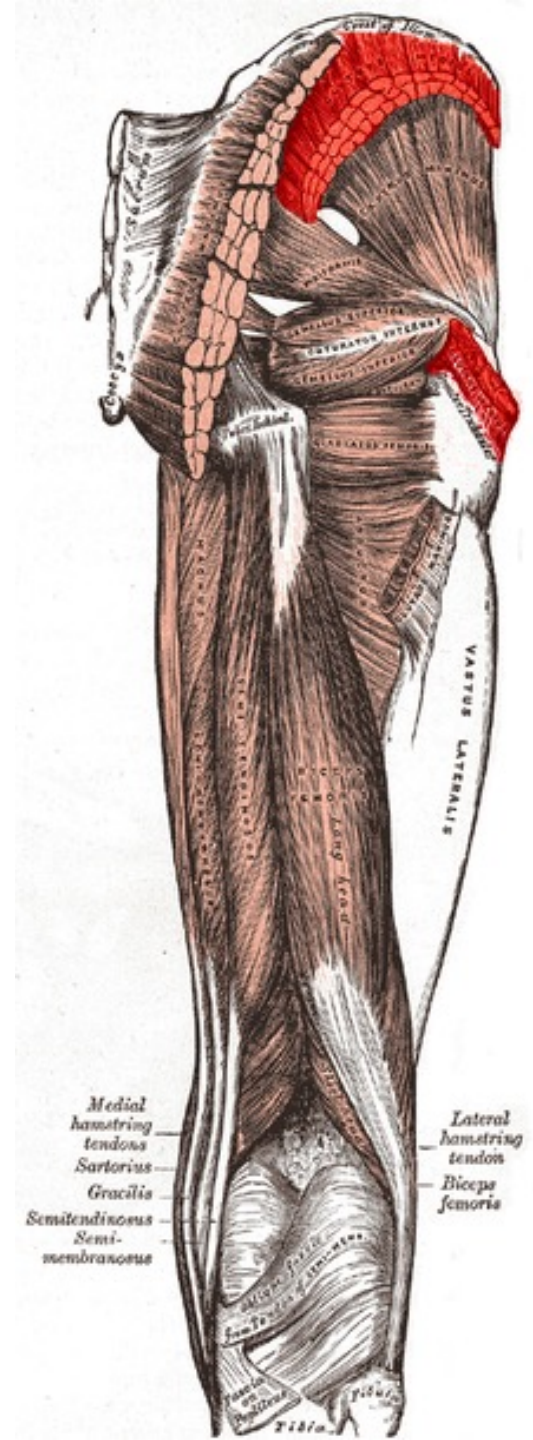


# Abdukce

- M. gluteus medius
- M. gluteus minimus
- M. tensor fasciae latae

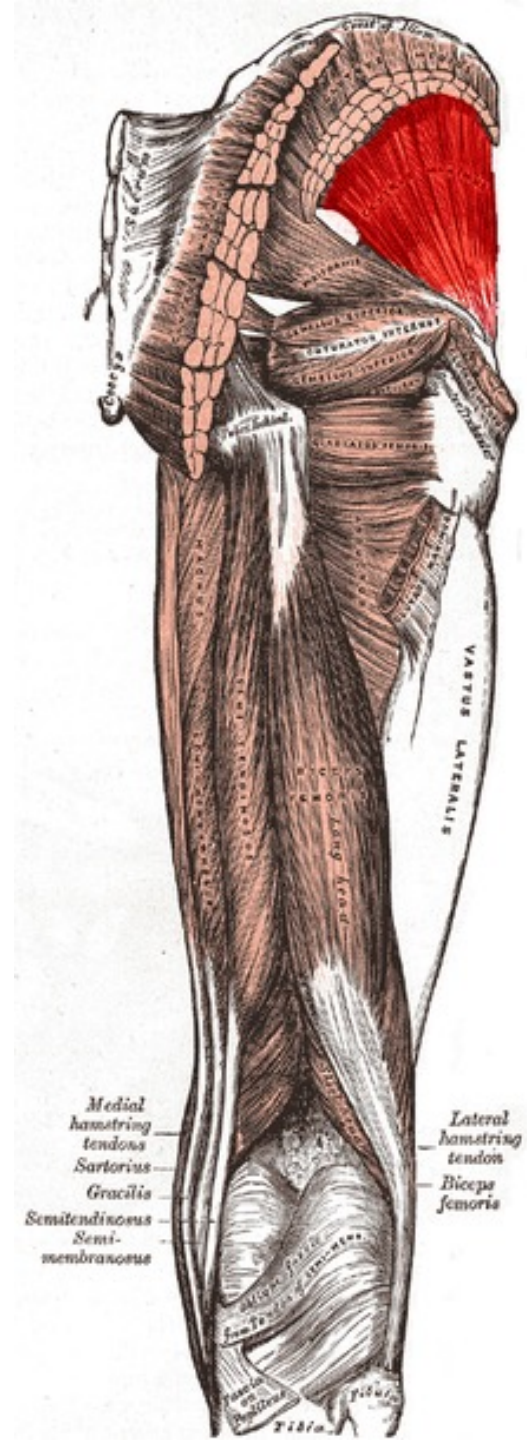
# m. Gluteus medius

- Z: lopata kosti kyčelní až ke crista iliaca
- Ú: trochanter major femoris
- I: n. gluetus superior
- F: Dle části (VR, ABD, ZR) v KYK



# m. Gluteus minimus

- Z: zevní plocha lopaty kosti kyčelní
- Ú: trochanter major femoris
- I: n. gluteus superior
- F: VR, ABD, ZR



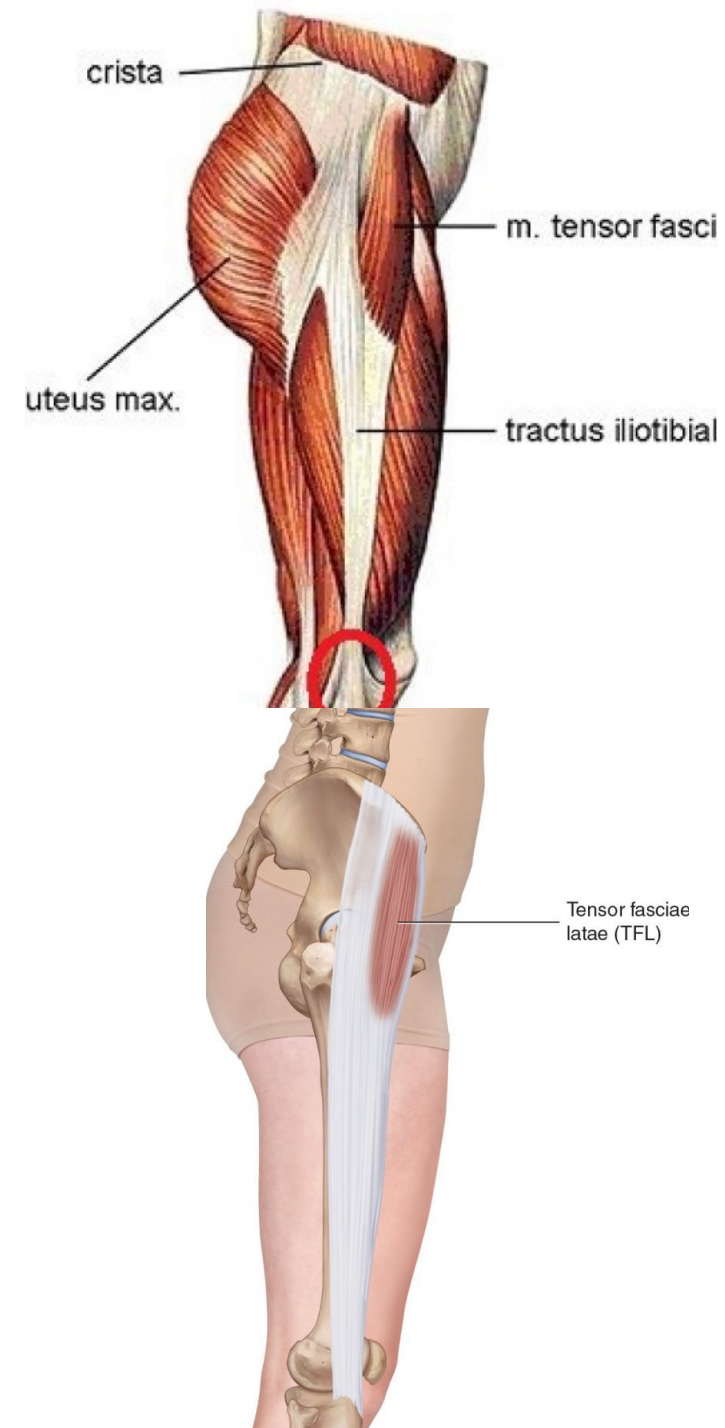
# M. Tensor fasciae latae

Z: spina iliaca anterior superior, část labium externum  
cristae iliacaе

Ú: tractus iliotibialis

I: nervus gluteus superior

F: flexe, ABD, VR v KYK, udržuje extenzi v KOK



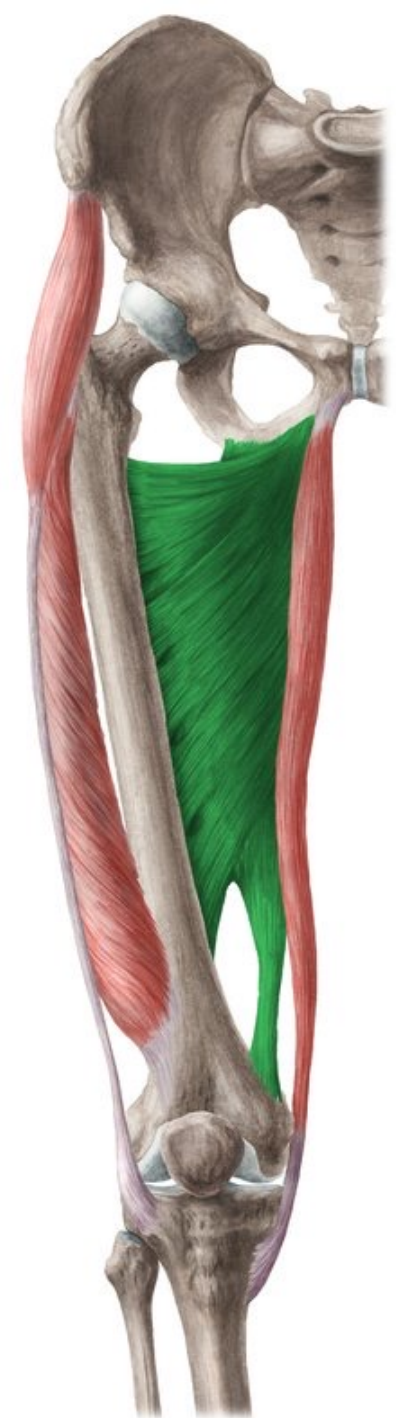

# Addukce

- M. adductor magnus
- M. gracilis
- M. adductor longus
- M. adductor brevis

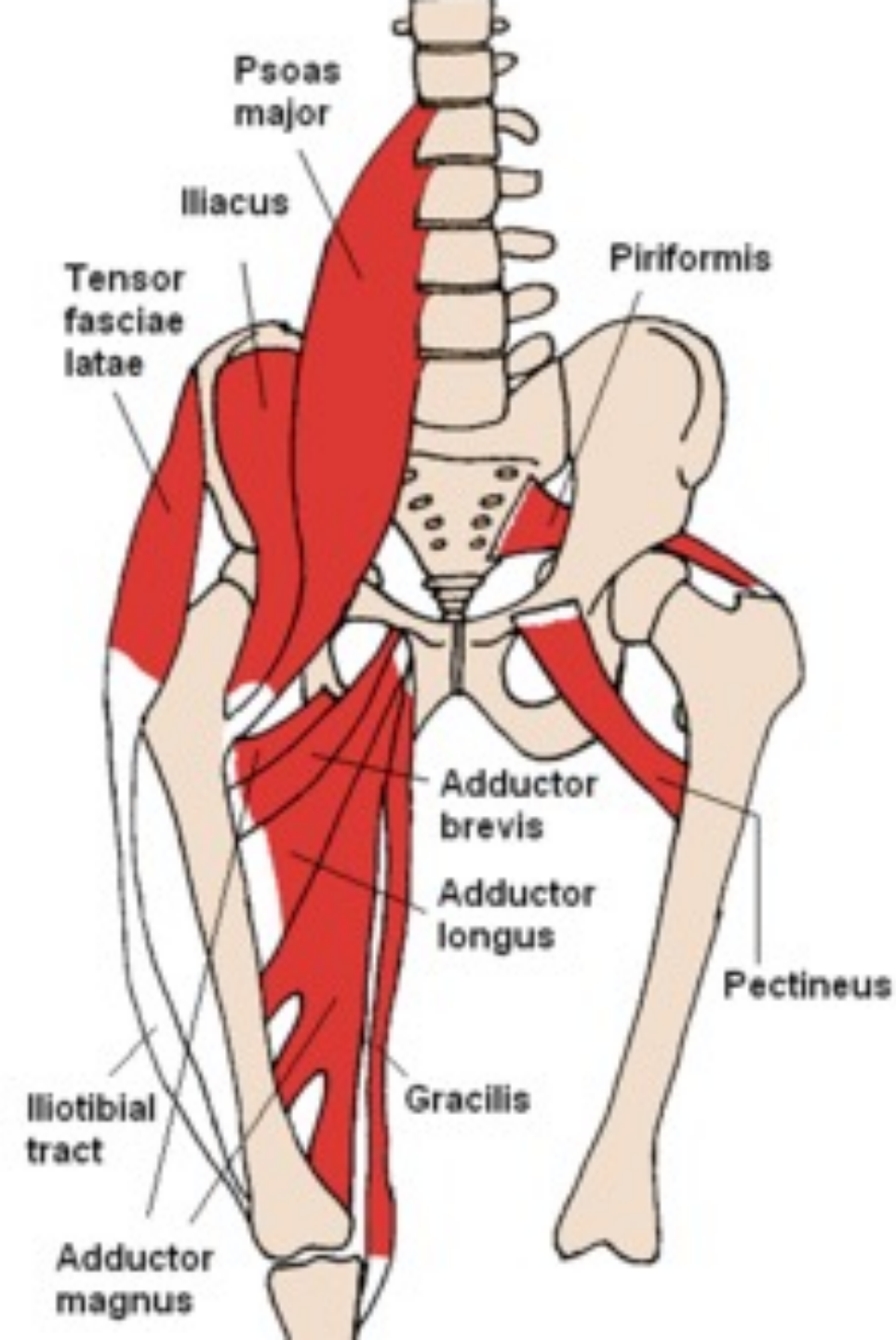
# M. Adductor magnus

- Z: ramus inferior ossis pubis, ramus ossis ischii, tuber ischiadicum
- Ú: labium mediale lineae asperae, epicondylus medialis femoris
- I: n. obturatorius, n. ischiadicus
- F: ADD, EX, pomocná VR i ZR dle vláken v KYK



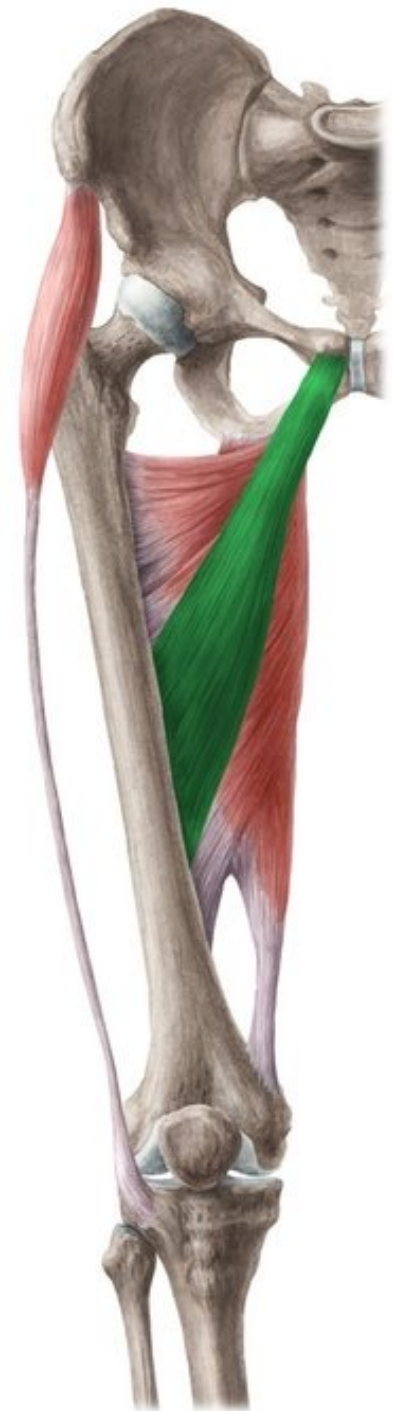# M. Gracilis

- Z: ramus inferior ossis pubis
- Ú: condylus medialis tibiae (pes anserinus)
- I: n. obturatorius
- F: KYK – ADD, KOK – FL, VR



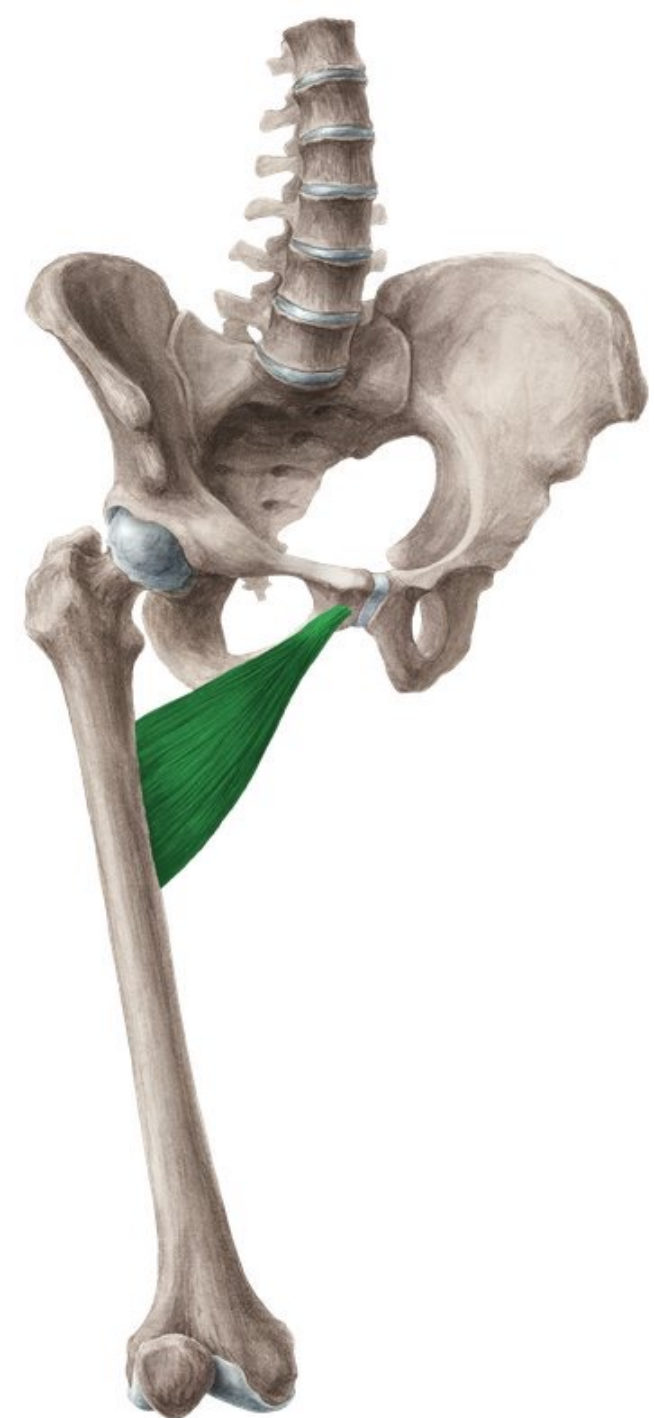# M. Adductor longus

- Z: os pubis
- Ú: labium mediale lineae asperae
- I: n. obturatorius
- F: ADD, FL, ZR v KYK



# M. Adductor brevis

- Z: ramus inferior ossis pubis
- Ú: labium mediale lineae asperae
- I: n. obturatorius
- F: add, fl, ZR v KYK



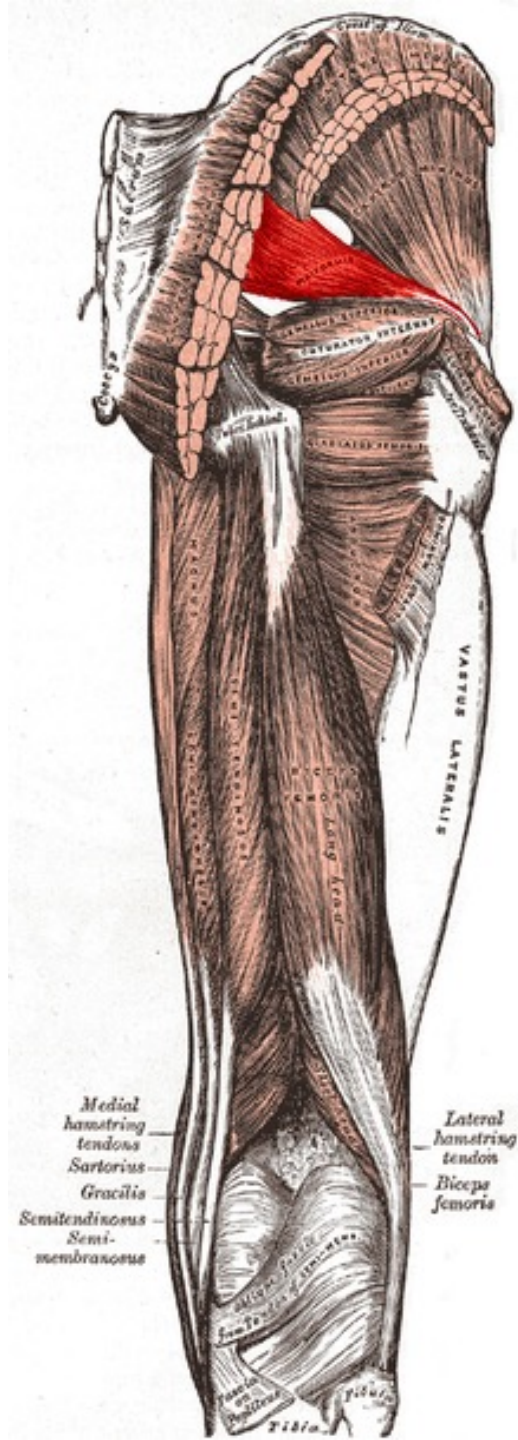
# Zevní rotace

- M. quadratus femoris
- M. piriformis
- M. gemellus superior
- M. gluteus maximus
- M. obturatorius externus
- M. obturatorius internus

# m. Piriformis

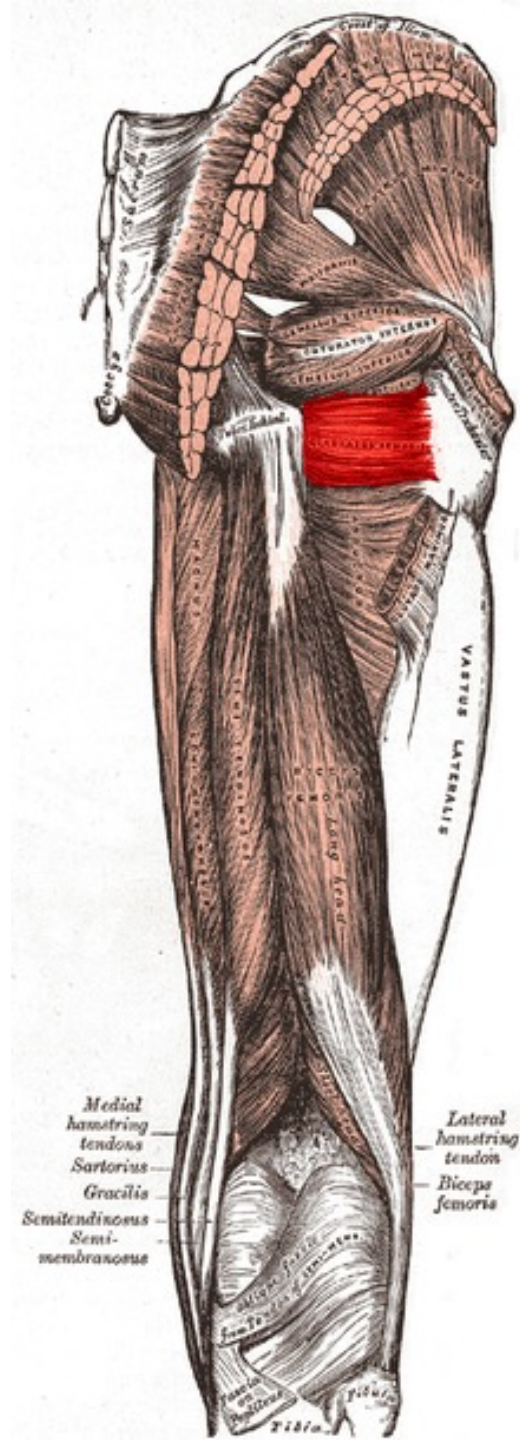
- Z: přední plocha os sakrum
- Ú: trochanter major femoris
- I: plexus sacralis
- F: ZR, Ext, ABD

Hypertonus vede KYK do ZR



# M. Quadratus femoris

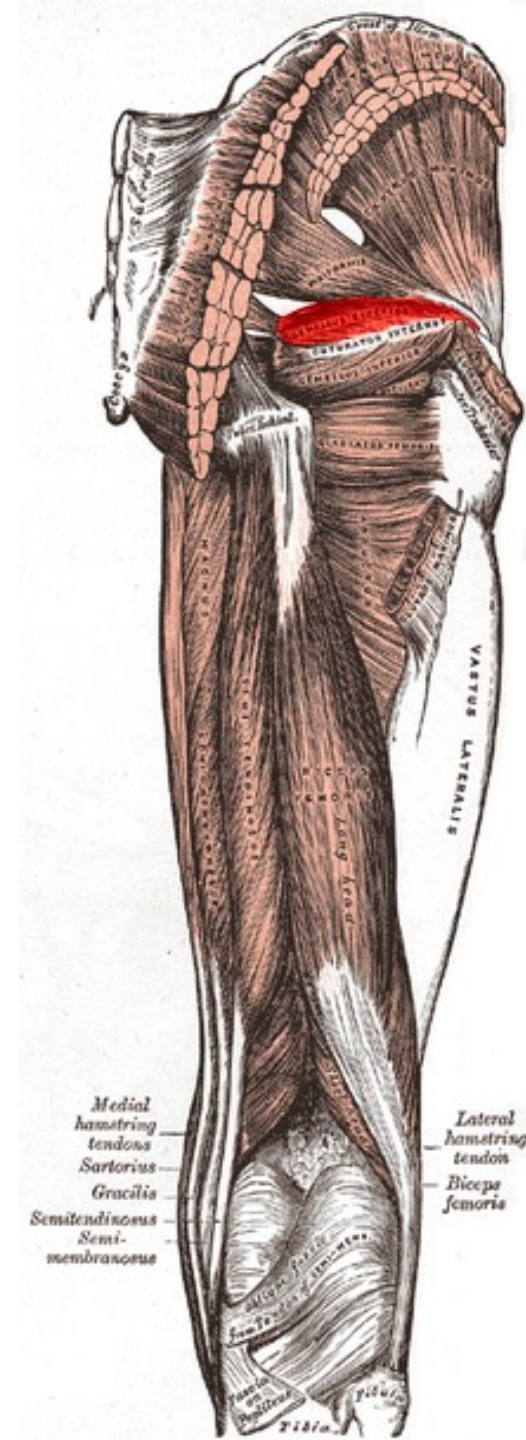
- Z: zevní okraj tuber ichiadicum
- Ú: crista intertrochanteria femuru
- I: plexus sacralis (L4-S1-S2)
- F: ZR v KYK





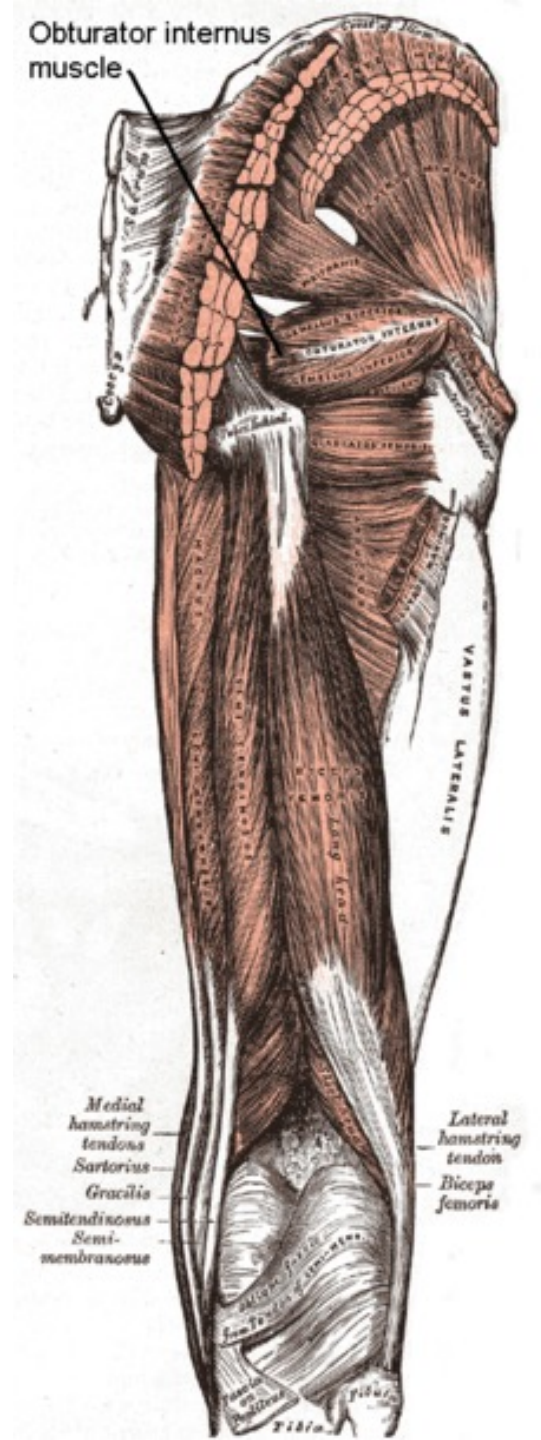
# M. Gemellus superior

- Z: spina ischiadica
- Ú: fossa trochanterica
- I: plexus sacralis (L4-S2)
- F: ZR, ABD v KYK



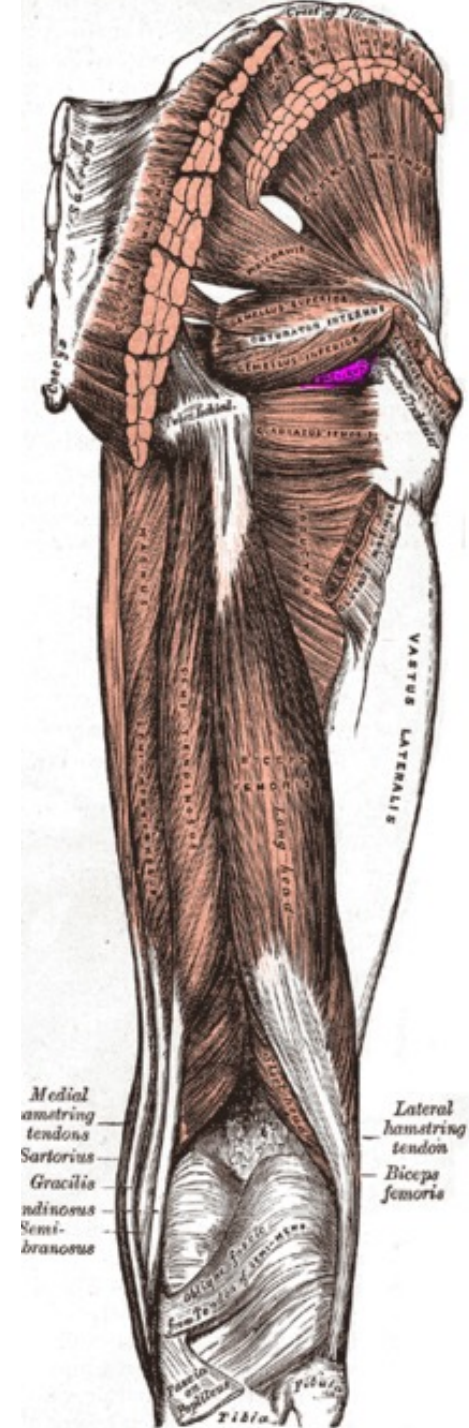
# M. Obturatorius internus

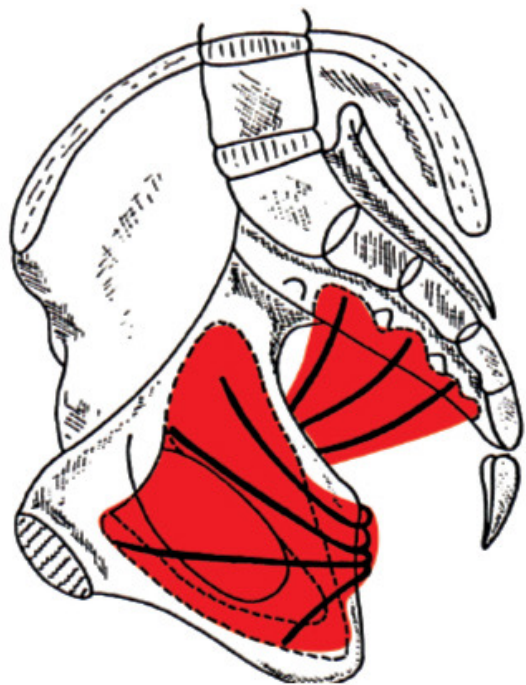
- Z: vnitřní plocha membrána obturatoria a obvody přilehlých kostí
- Ú: fossa trochanterica
- I: plexus sacralis (L4-S2)
- F: ZR, ABD v KYK



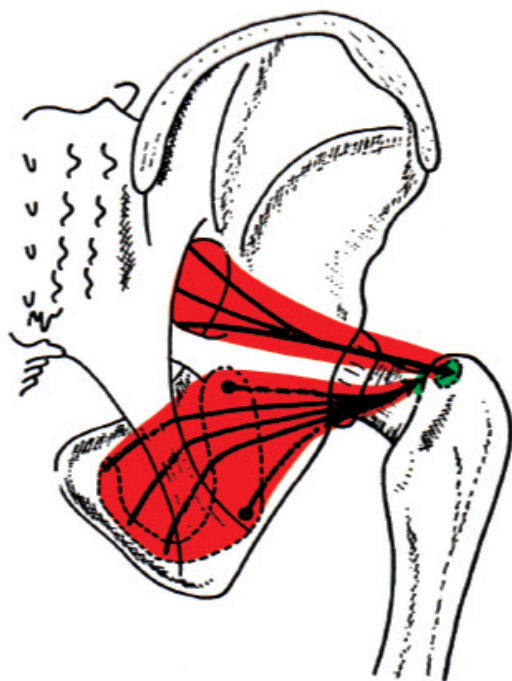
# M. Obturatorius externus

- Z: zevní plocha membrána obturatoria
- Ú: fossa trochanterica
- I: n. obturatorius
- F: ZR, ADD v KYK



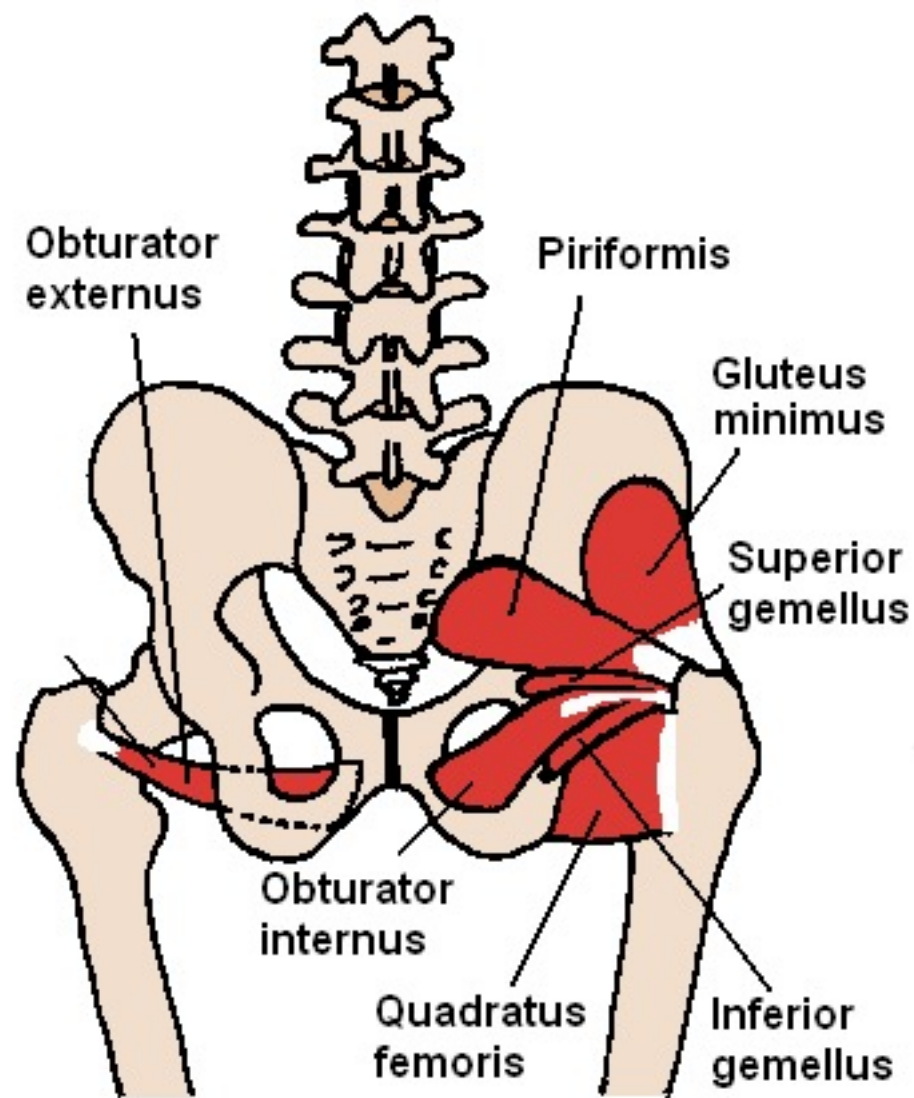


M.piriformis  
M.obturatorius internus



M.piriformis  
M.obturatorius internus  
M.gemellus superior  
M.gemellus inferior

F: femorální supinace  
In: plexus sacralis



Obturator externus  
Piriformis  
Gluteus minimus  
Superior gemellus  
Obturator internus  
Quadratus femoris  
Inferior gemellus

# Vnitřní rotace

- M. tensor fasciae latae
- M. gluteus minimus
- M. gluteus medius

Dotazy?

Děkuji za pozornost