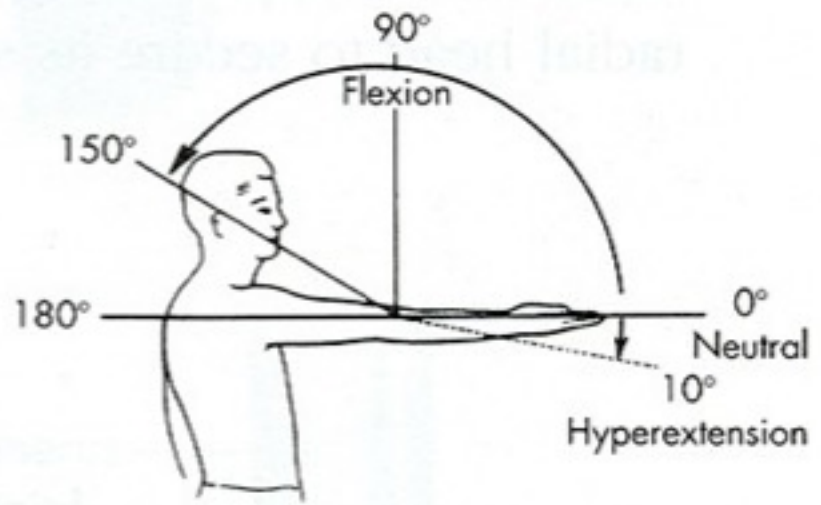


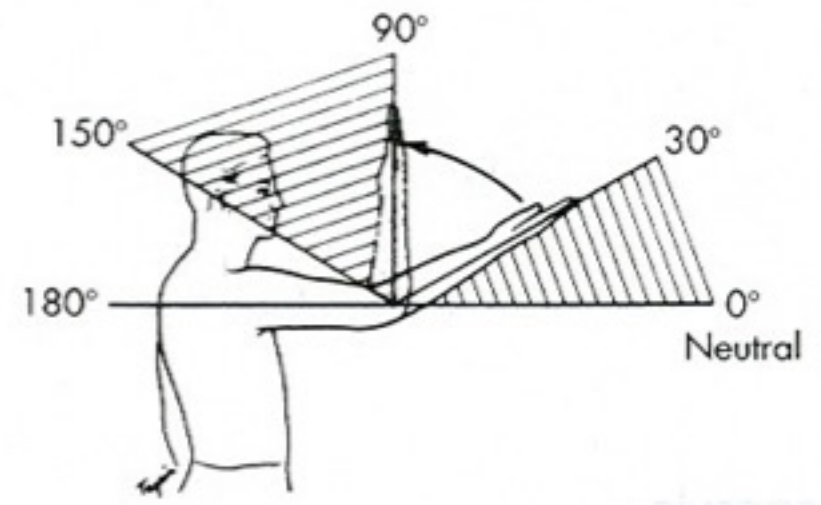
A photograph of a person's arm flexed, showing the bicep and forearm muscles. The person's head is visible in profile on the right side of the frame. The background is a plain, light color.

Pohyby loketního kloubu a zápěstí

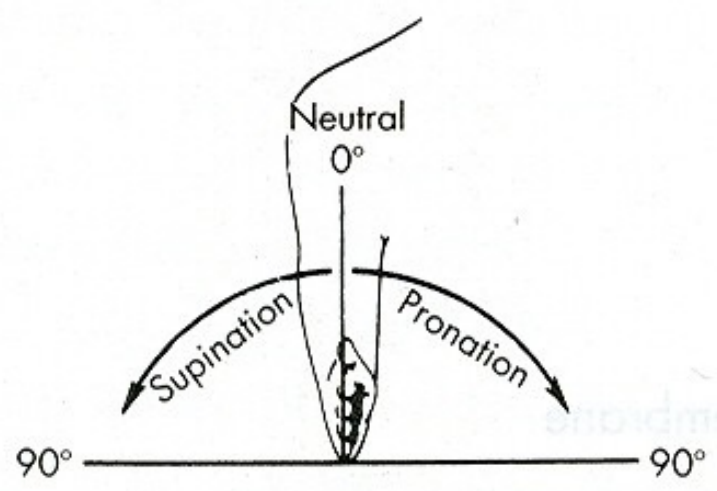
Mgr. Klára Vomáčková



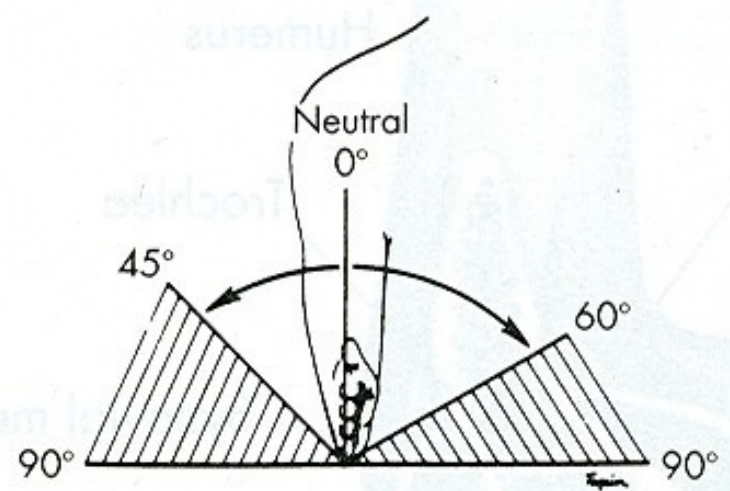
A



B

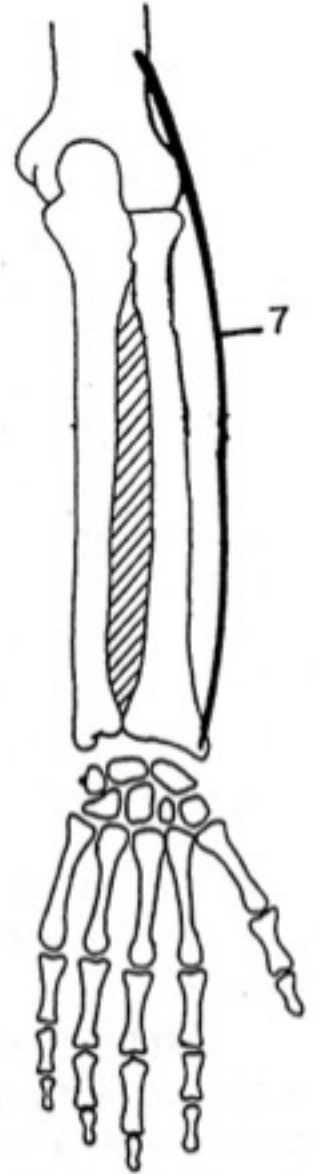
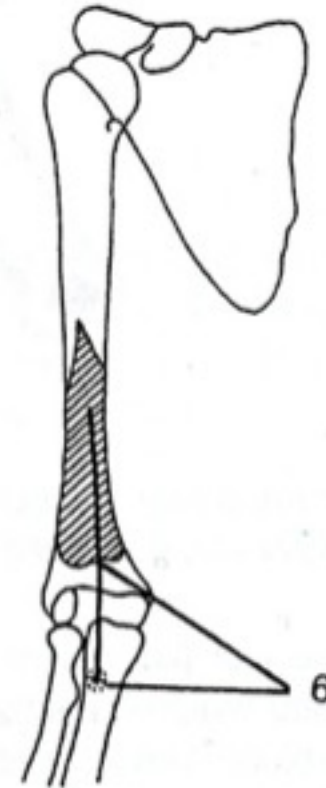
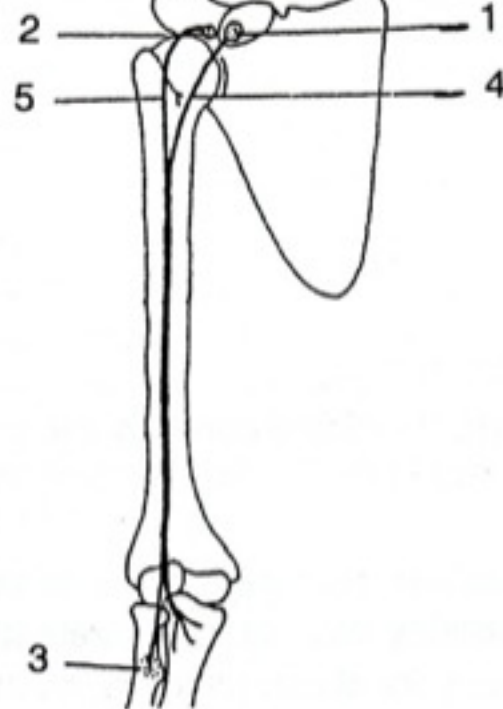
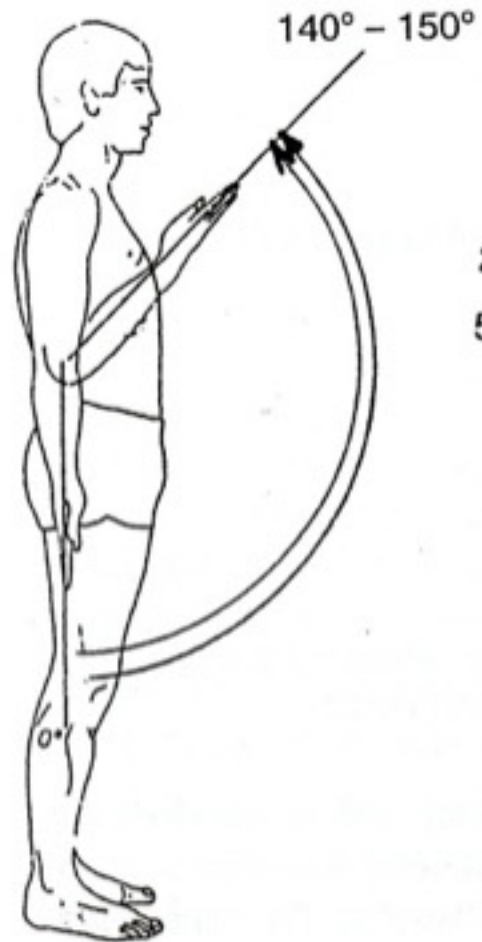


A



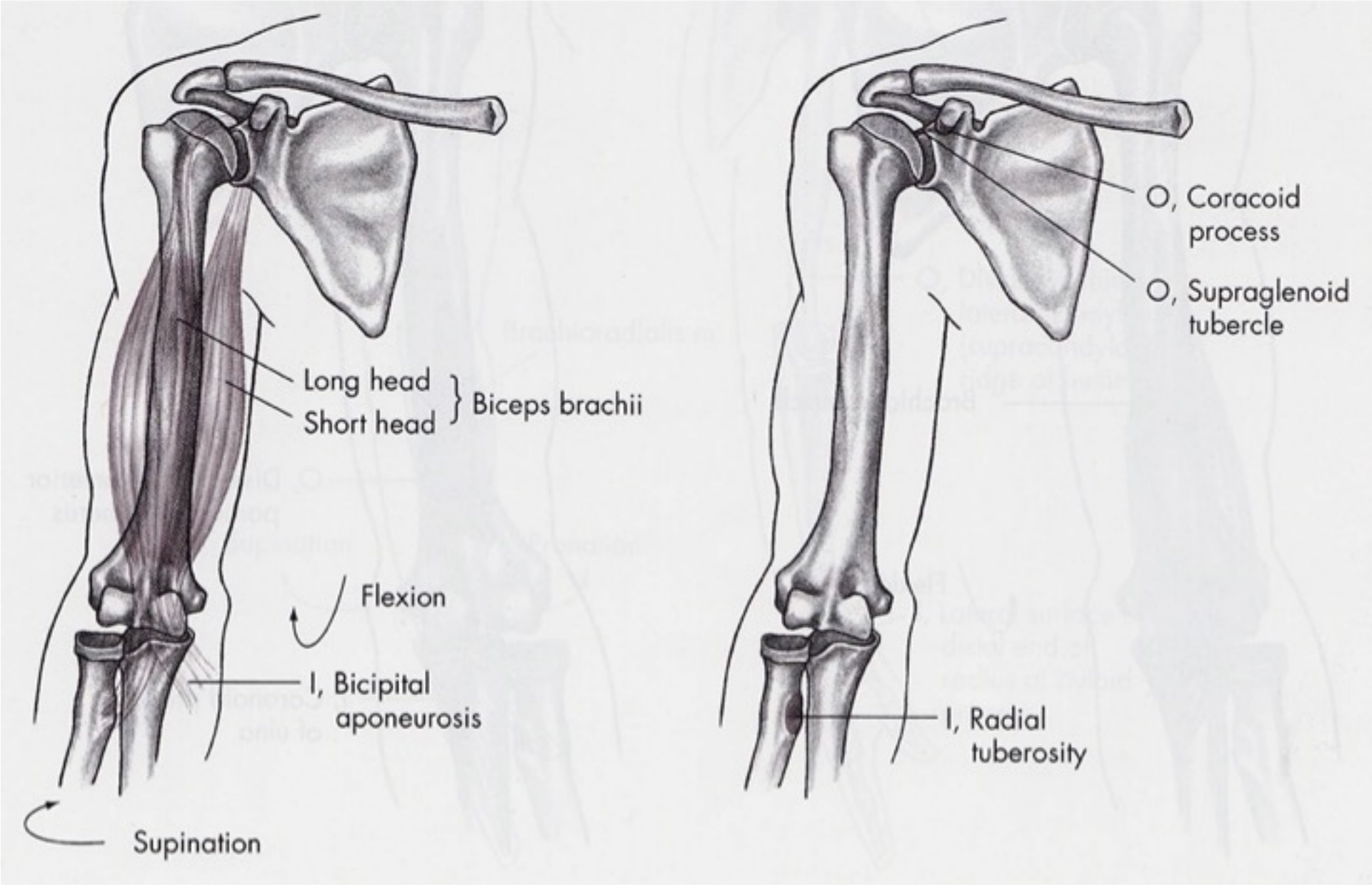
B

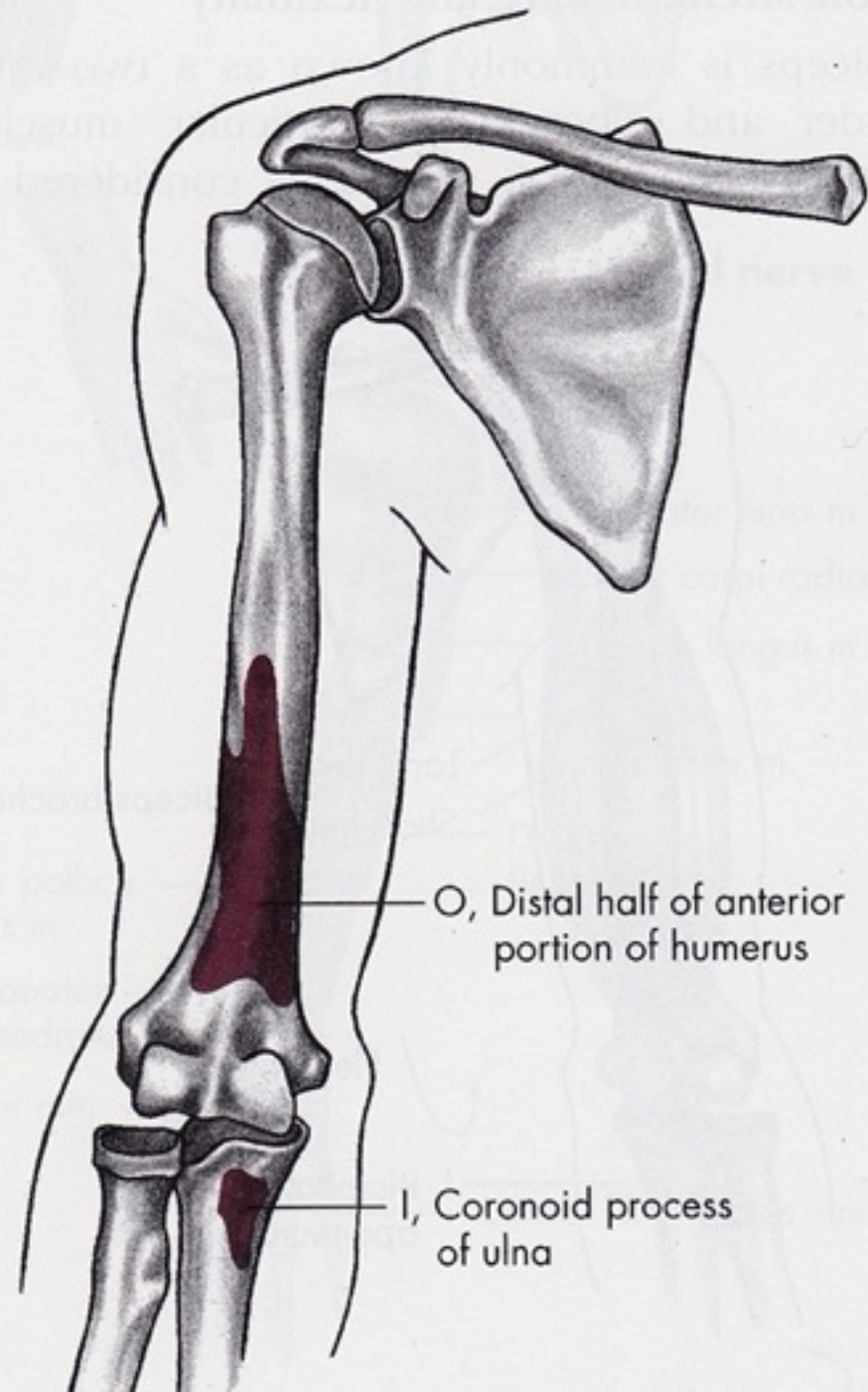
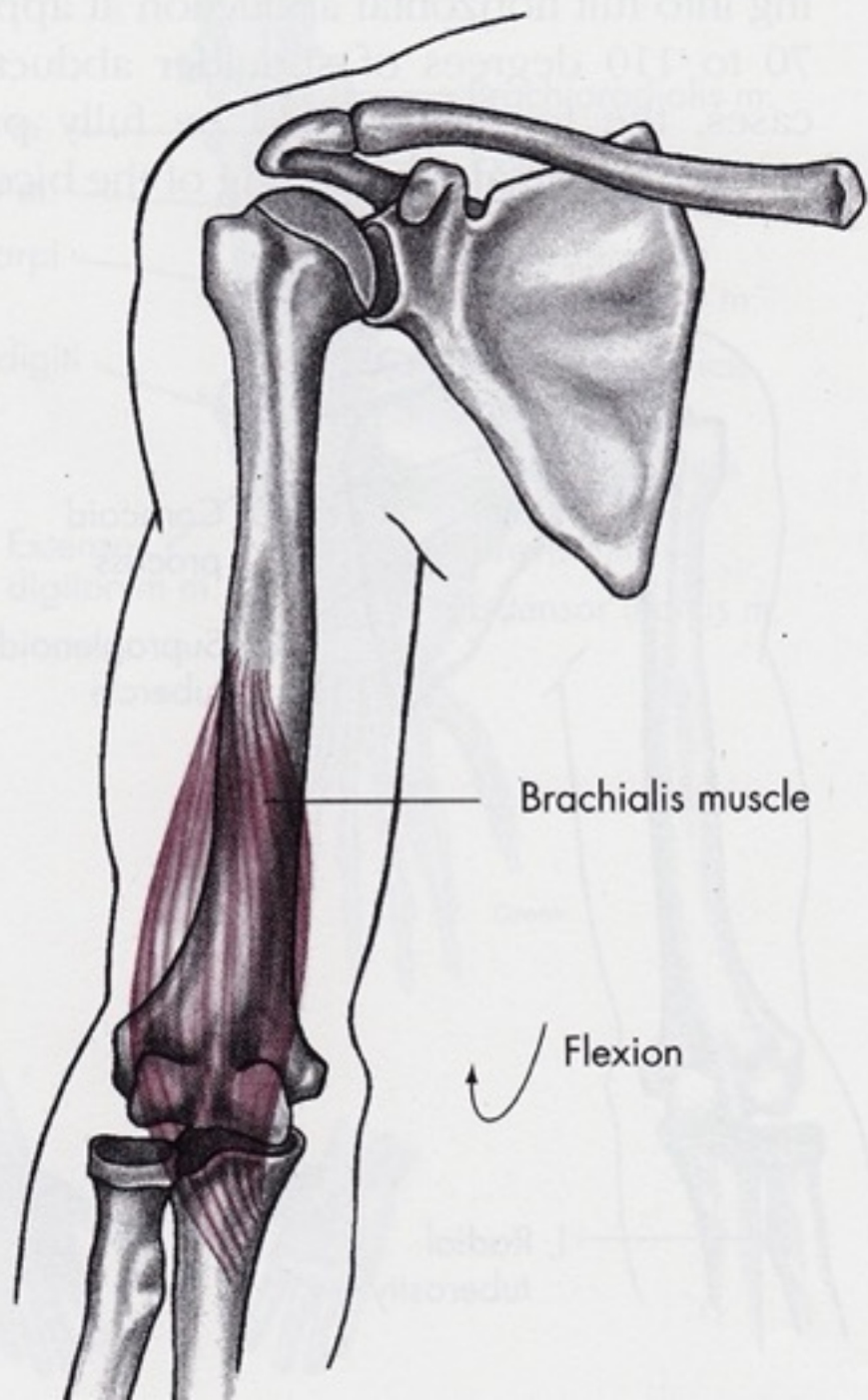
Flexe



Flexe

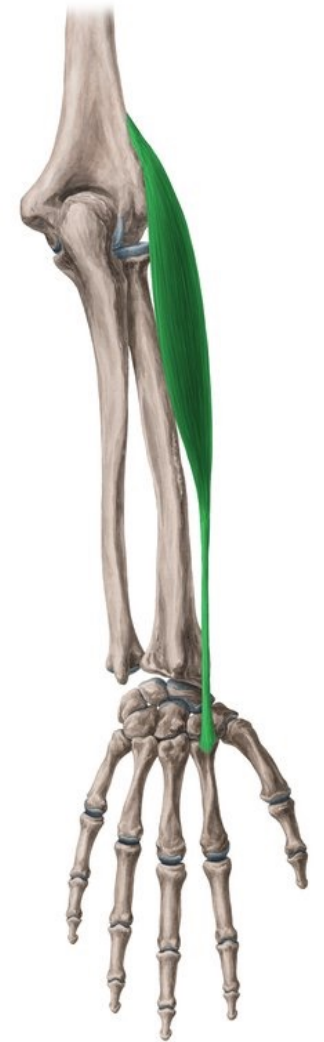- M. biceps brachii
- M. brachialis
- M. brachioradialis

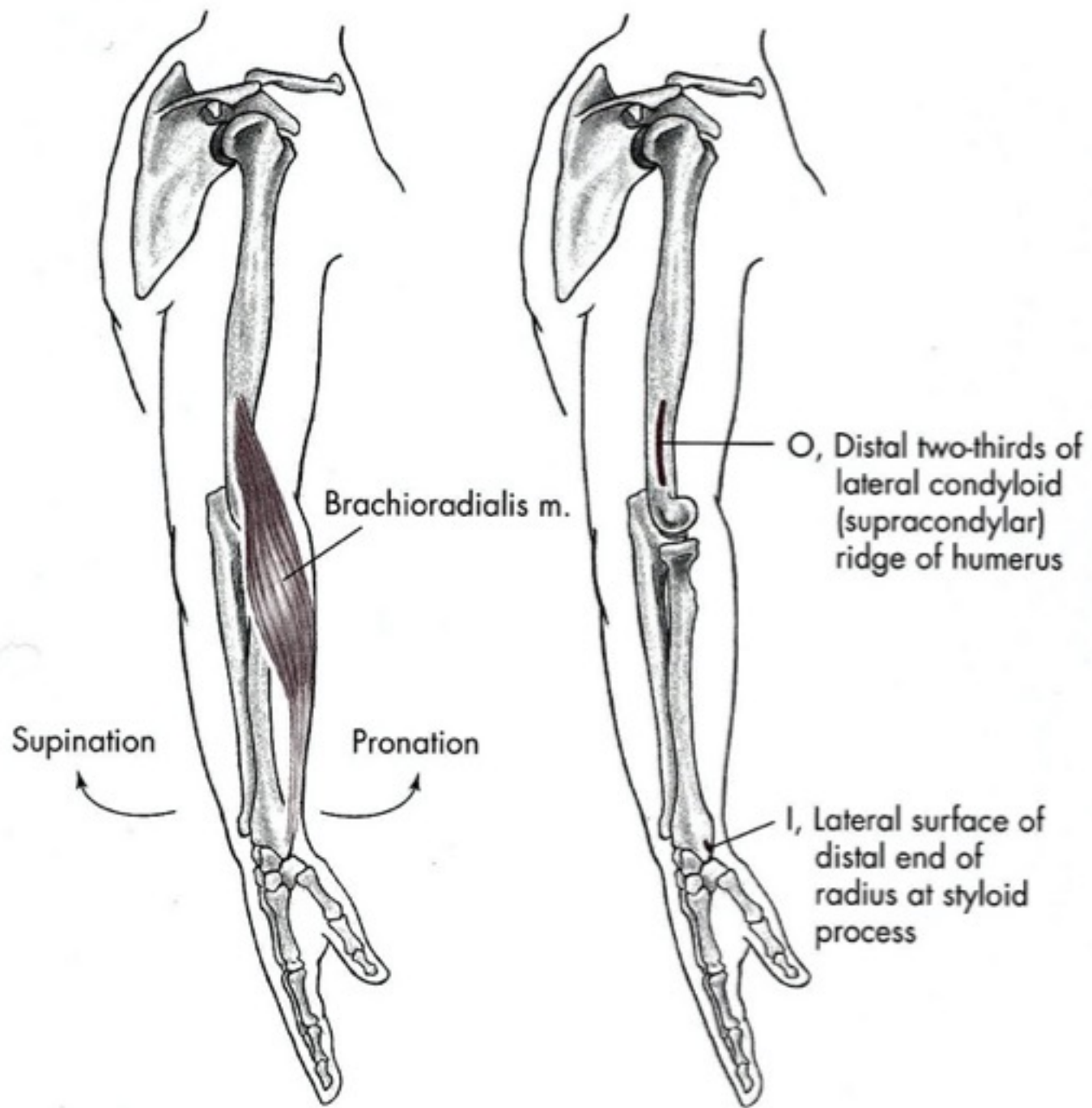




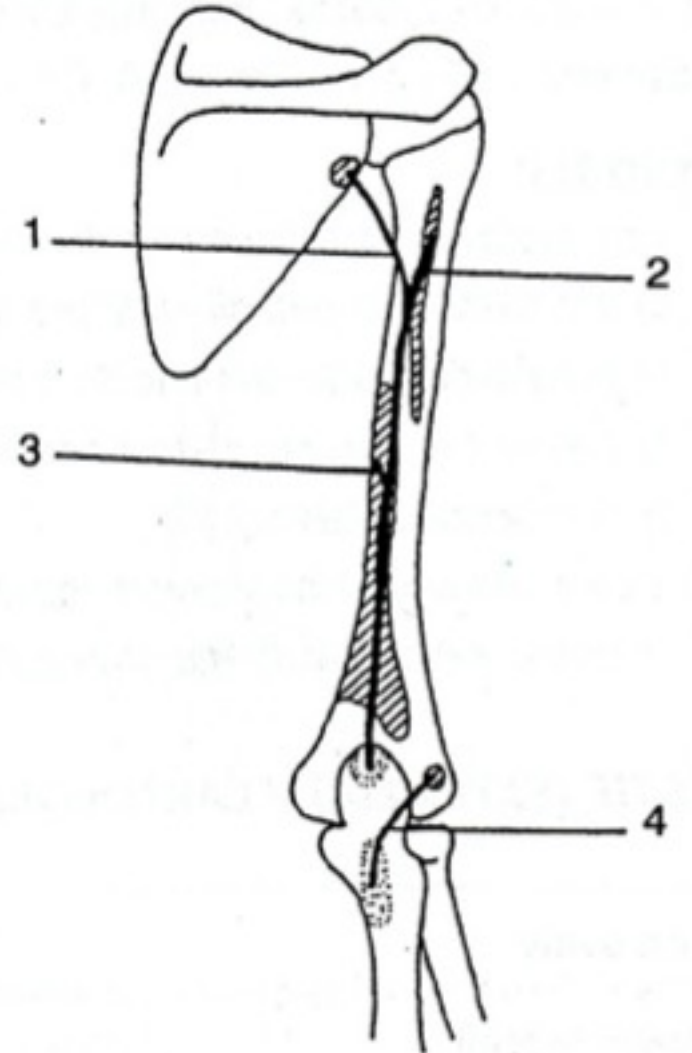
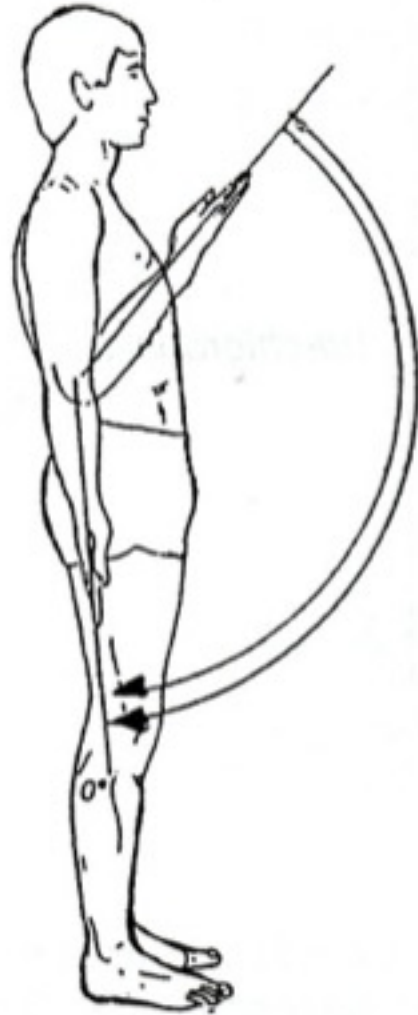
m. brachioradialis

- **Začátek:**
 - *crista supracondylaris lateralis humeri*
 - *septum intermusculare brachii laterale*
- **Úpon:** baze processus styloideus radii, ligamentum collaterale carpi radiale
- **Inervace:** *nervus radialis (ramus superficialis)* C5-6
- **Funkce:** flexe předloktí ve středním postavení, navrácí do středního postavení předloktí ze supinace a pronace





Extenze

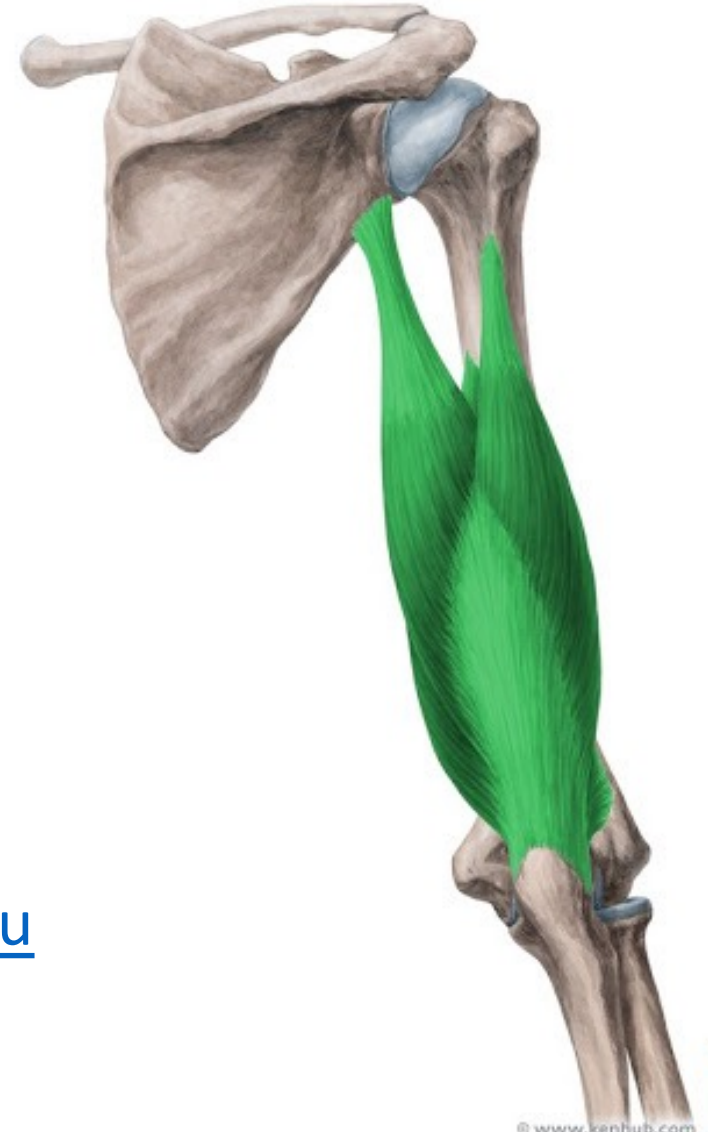

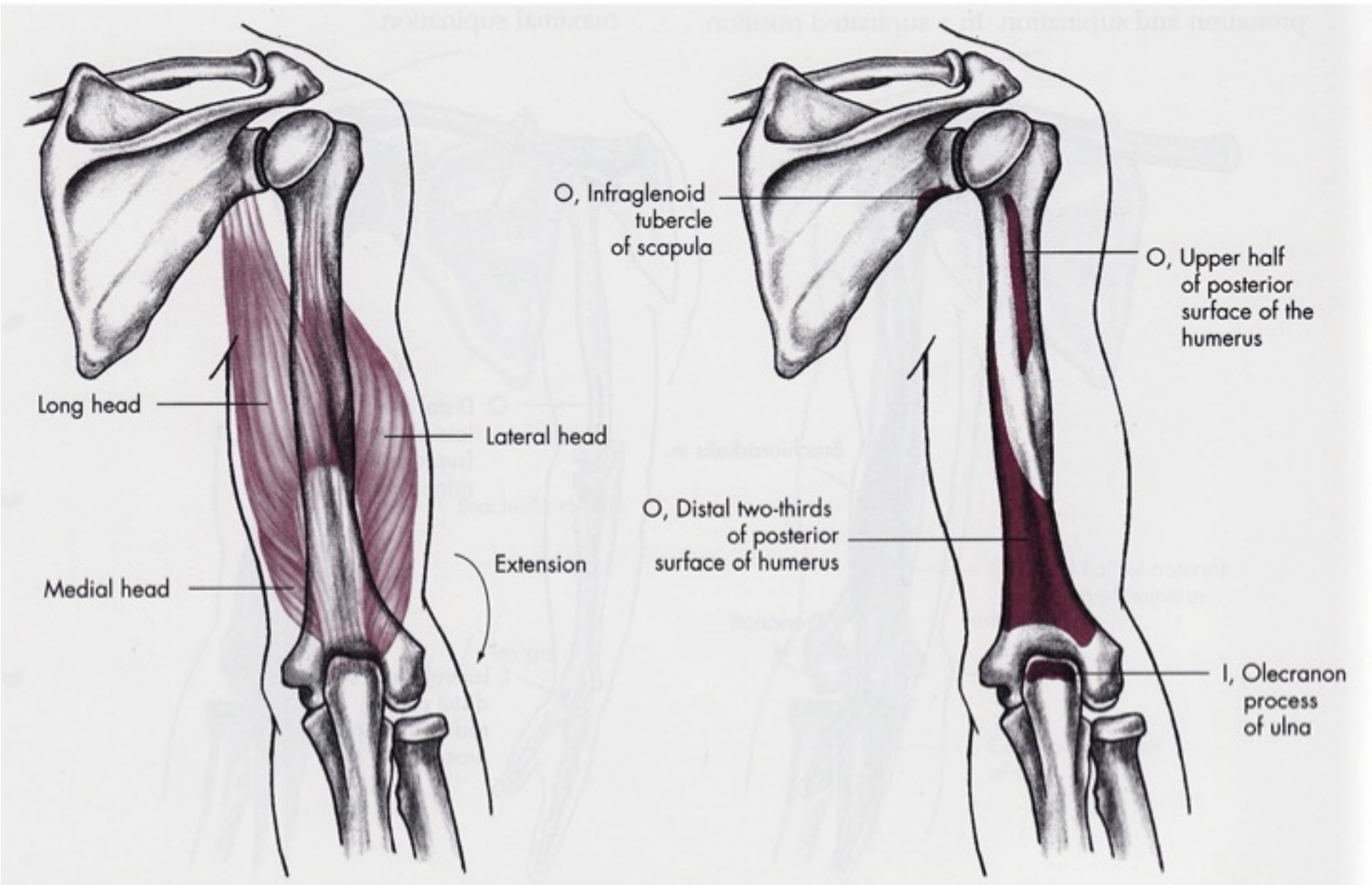
Extenze

- M. triceps brachii
- M. anconeus

m. Triceps brachii

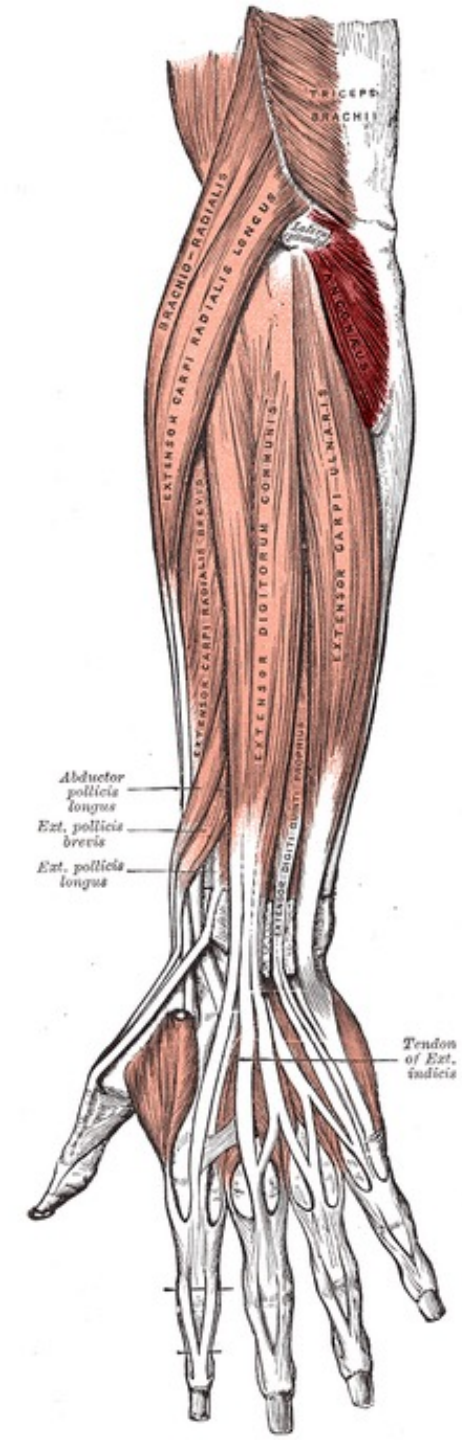
- **Začátek:**
- *caput longum* – *tuberculum infraglenoidale* [scapulae](#);
- *caput laterale* – zadní plocha [humeru](#), proximálně od *sulcus nervi radialis*;
- *caput mediale* – zadní plocha *humeru*, distálně od *sulcus nervi radialis*.
- **Úpon:** *olecranon ulnae*.
- **Inervace:** [nervus radialis](#) (C₆–C₈).
- **Funkce:** extenze [loketního kloubu](#); *caput longum* pomáhá při dorsální flexi a addukci v [ramenním kloubu](#)

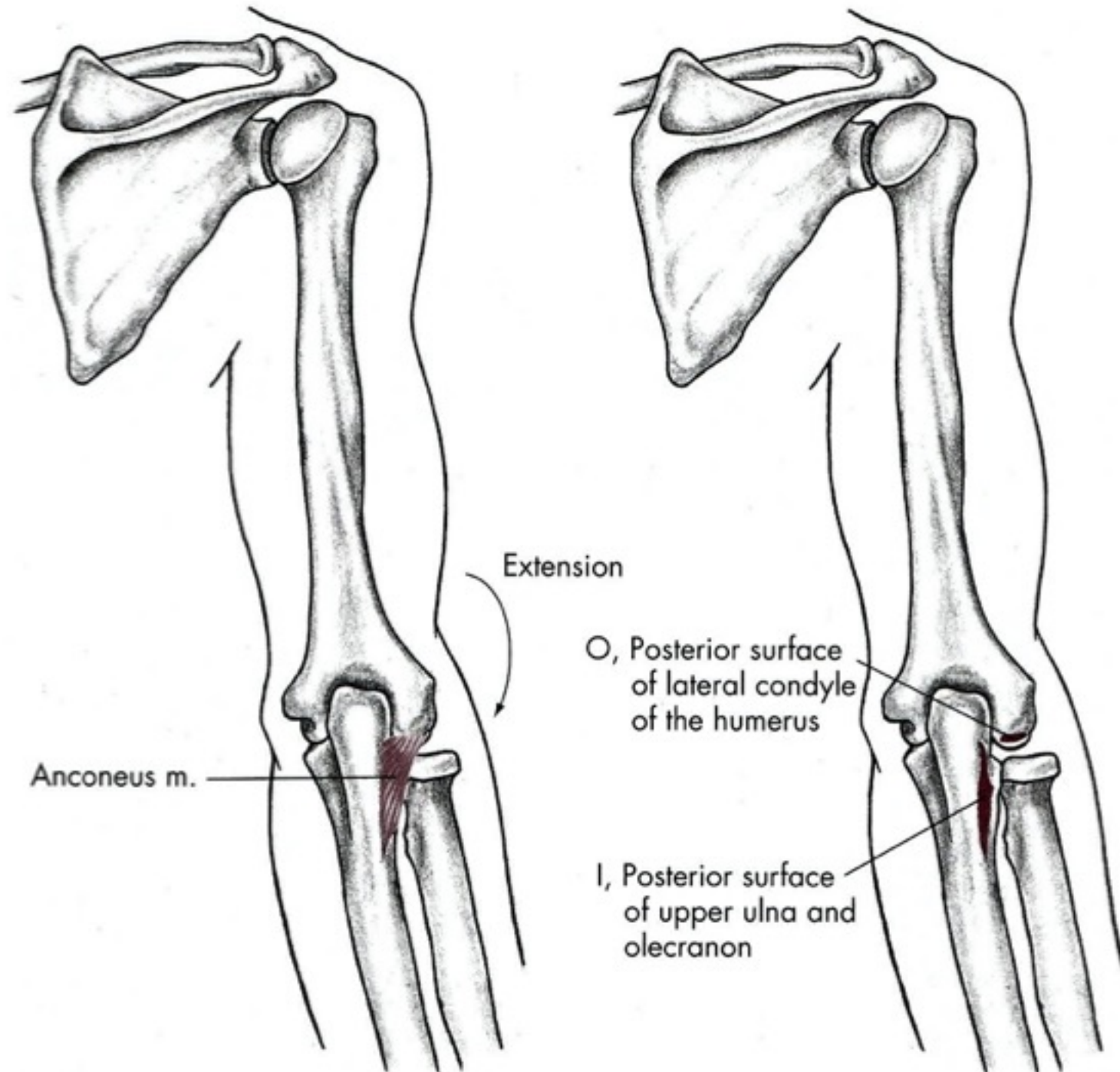




m. Anconeus

- **Začátek:** epicondylus lateralis humeri
- **Úpon:** distálně od olecranon ulnae
- **Inervace:** nervus radialis
- **Funkce:** extenze v předloktí, hluboká vrstva brání uskřinutí kloubního pouzdra při extenzi





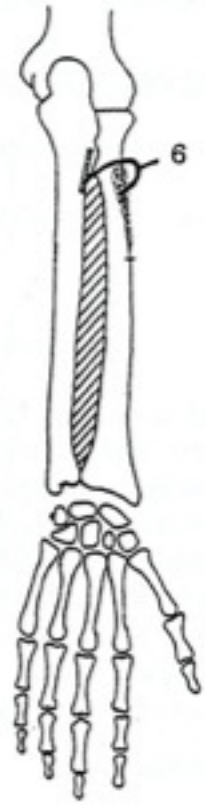
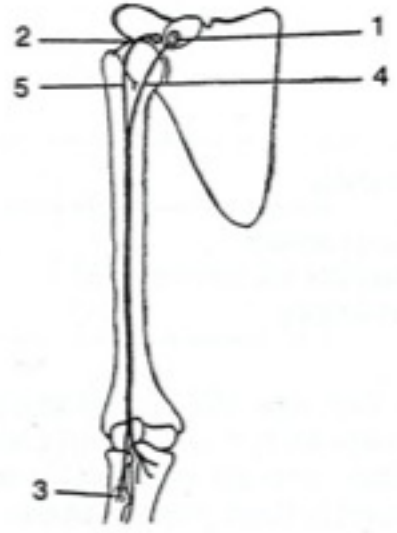
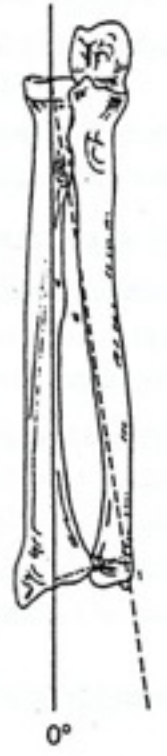
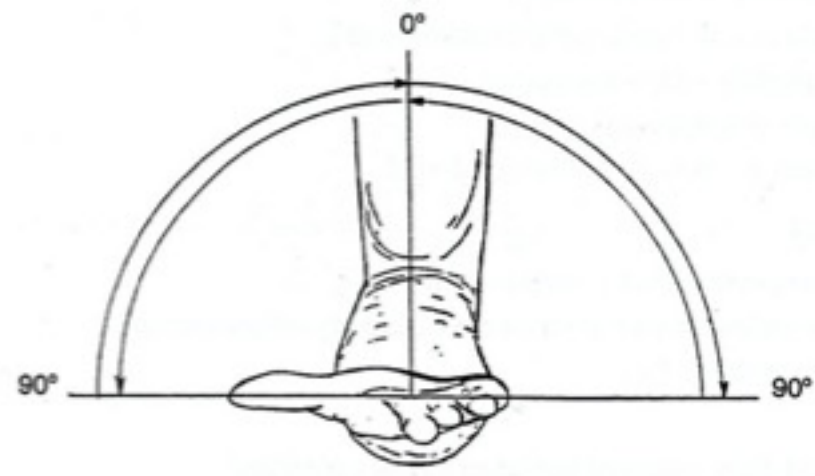
Extension

Anconeus m.

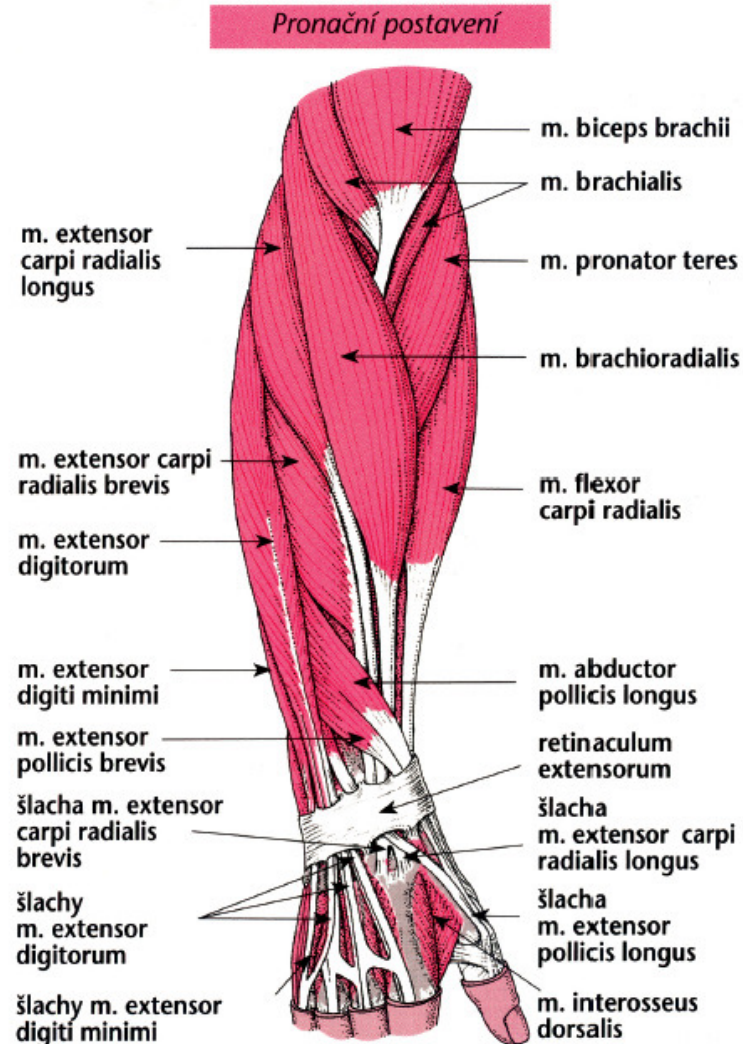
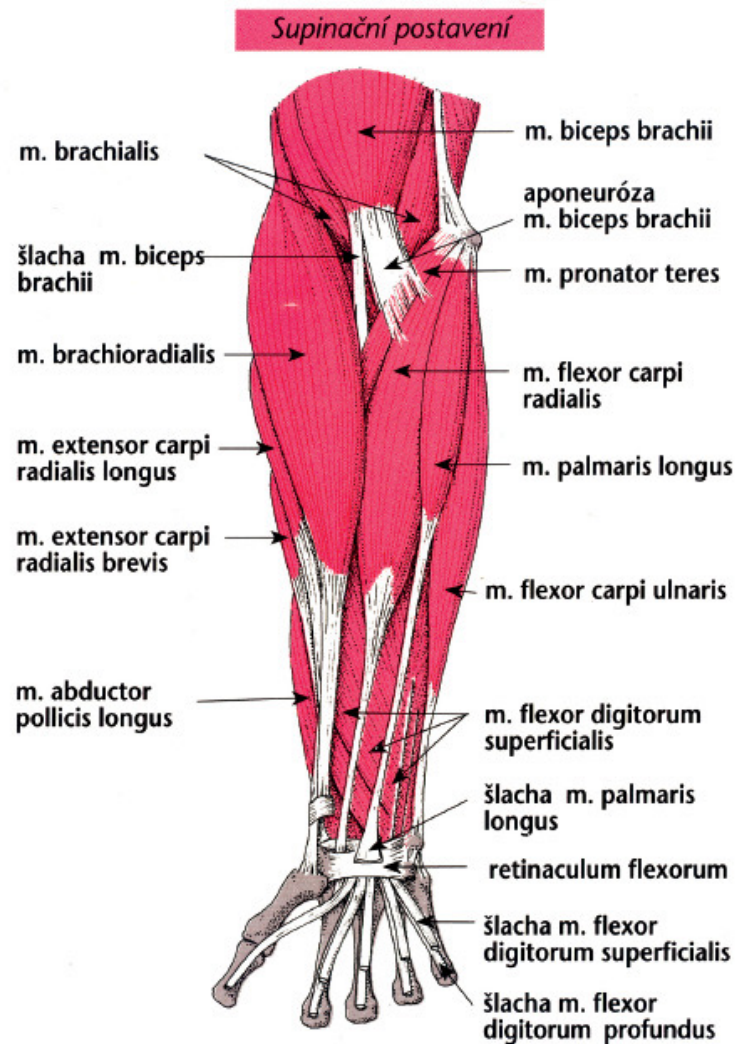
O, Posterior surface of lateral condyle of the humerus

I, Posterior surface of upper ulna and olecranon

Supination



Svaly předloktí

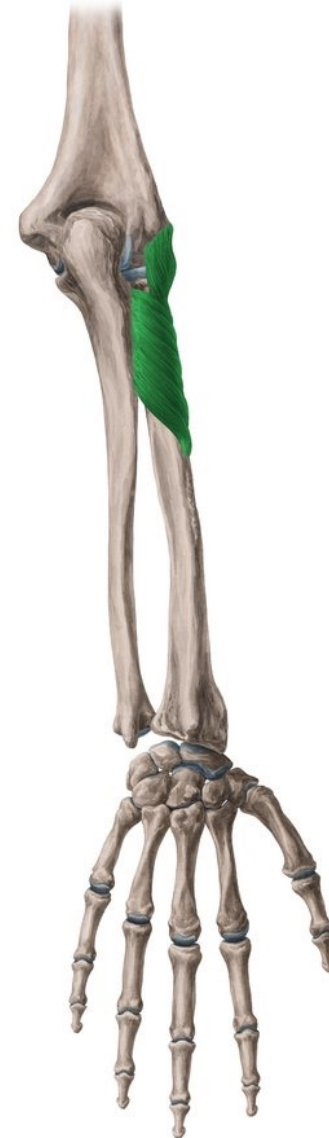

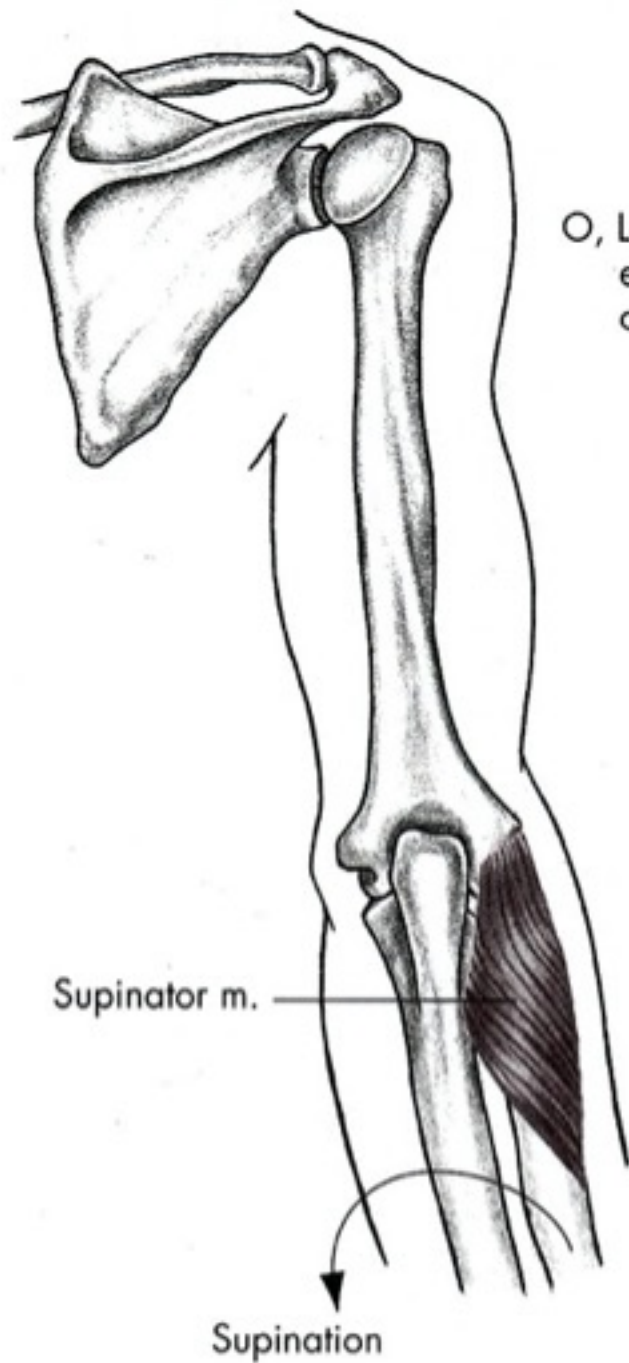
Supinace

- M. biceps brachii
- M. supinator

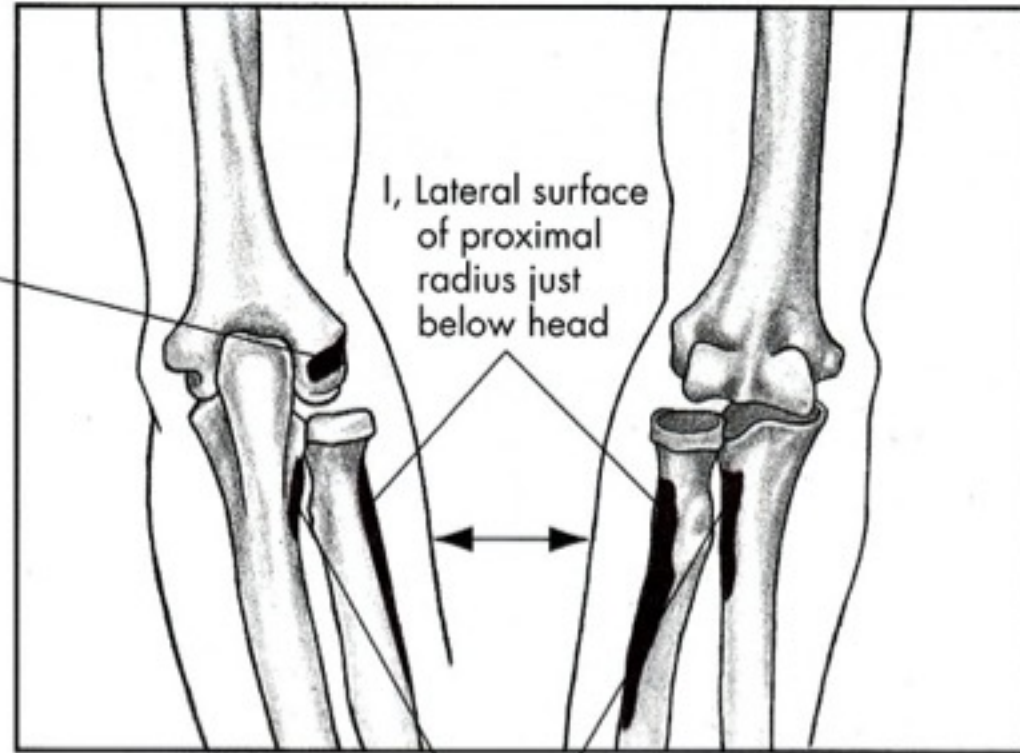
m. supinator

- **Začátek:**
- epicondylus lateralis humeri
- ligamentum collaterale radiale;
- ligamentum anulare radii;
- Crista supinatoria ulnae
- **Úpon:** laterální a palmární plocha radia
- **Inervace:** nervus radialis (ramus profundus) C5-7
- **Funkce:** supinace radia



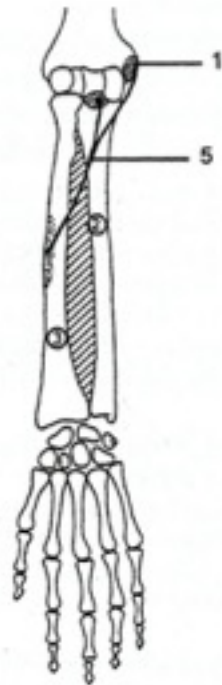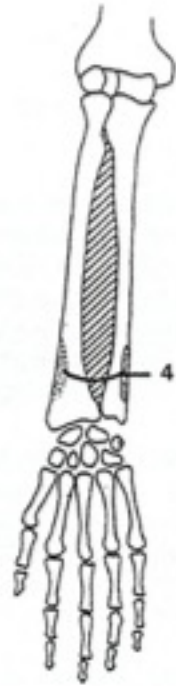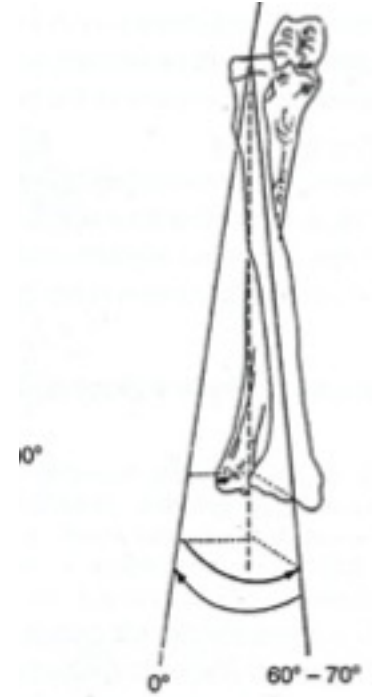
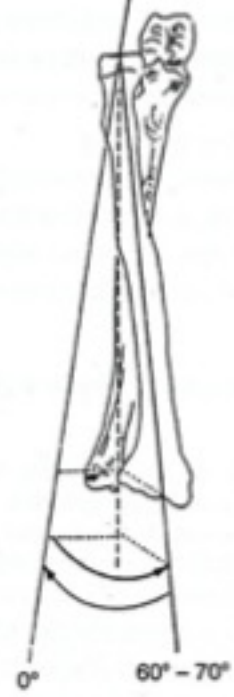
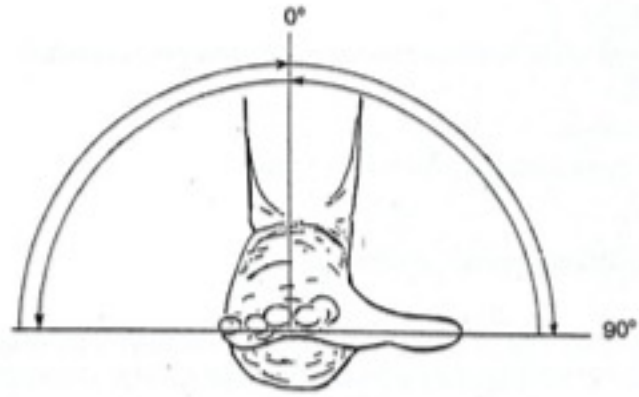


O, Lateral epicondyle of humerus



Posterior

Anterior

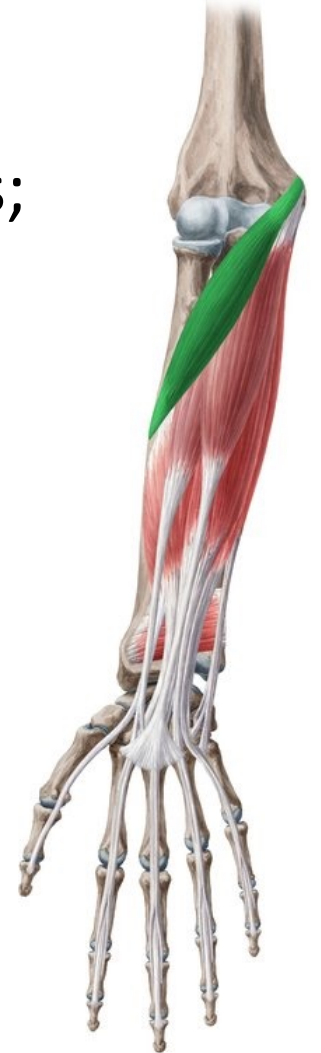

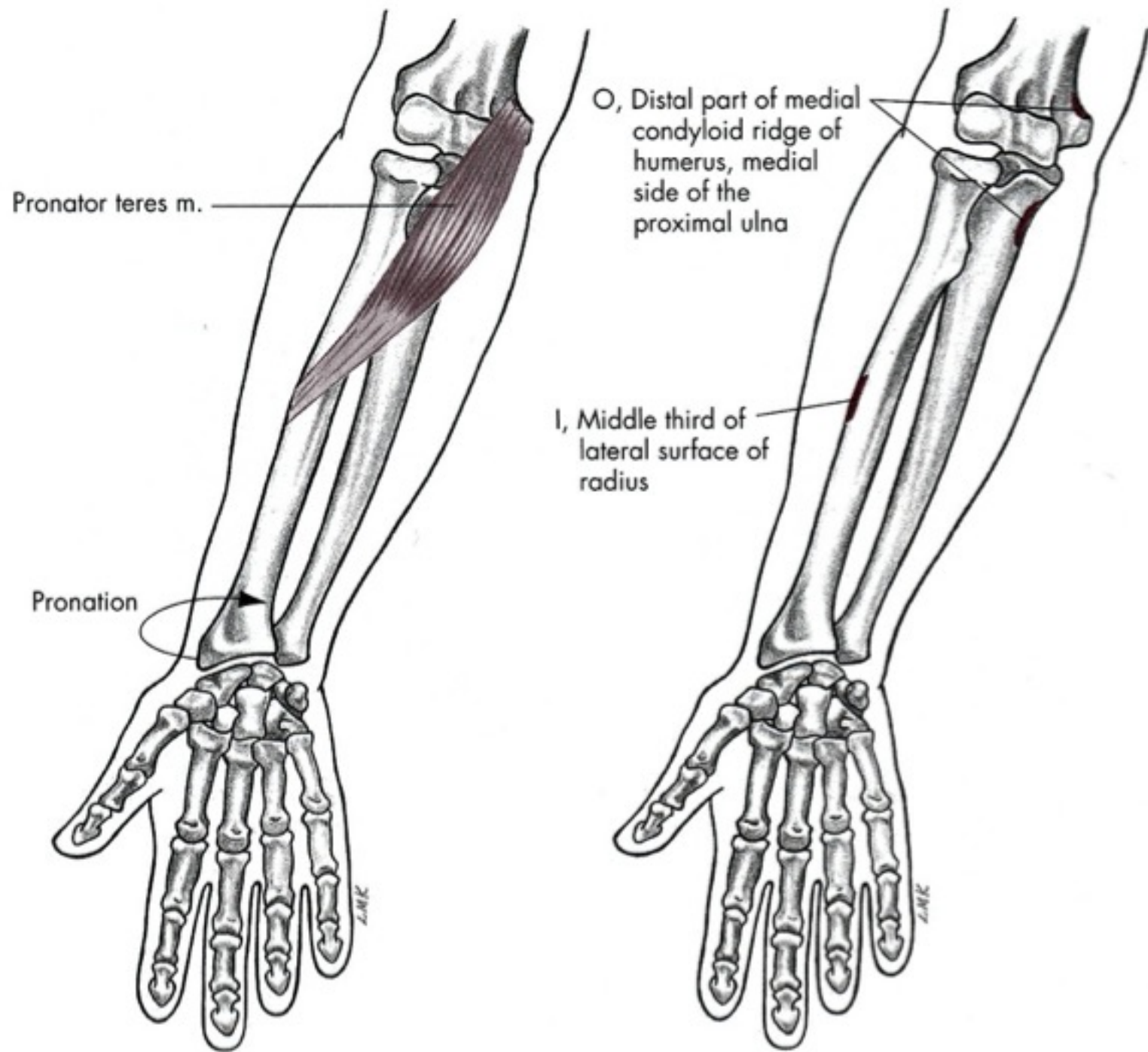
Pronace

- M. pronator teres
- M. pronator quadratus

m. Pronator teres

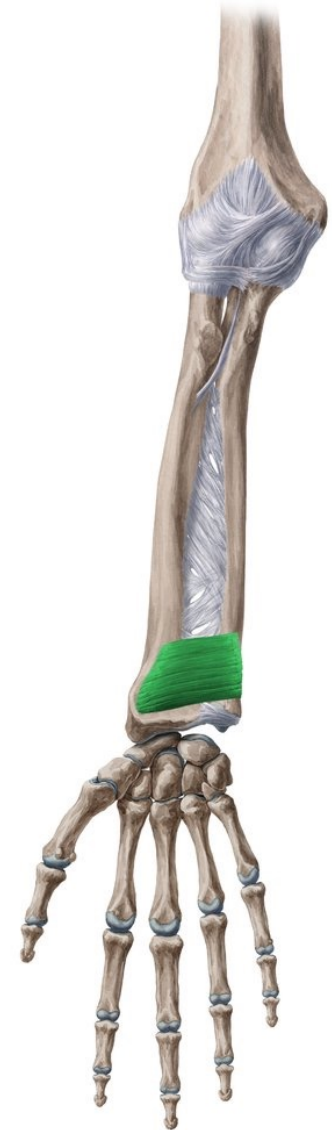- **Začátek: caput humerale:** crista supraepicondylaris medialis;
- **caput ulnare:** processus coronoideus ulnae
- **Úpon:** střed laterálního okraje radia
- **Inervace:** nervus medianus (C7-Th1)
- **Funkce:** pronace předloktí, pomocná flexe LK

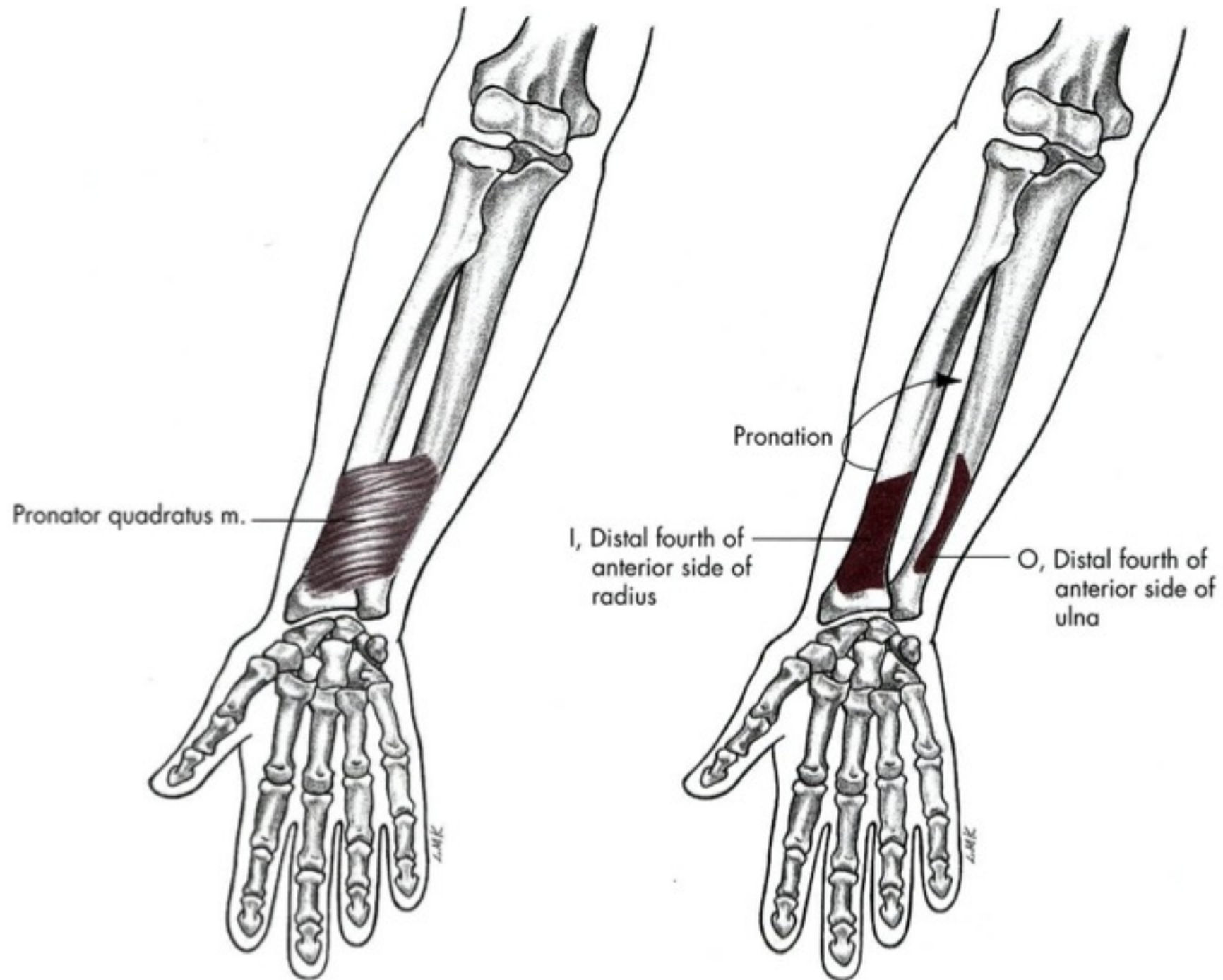




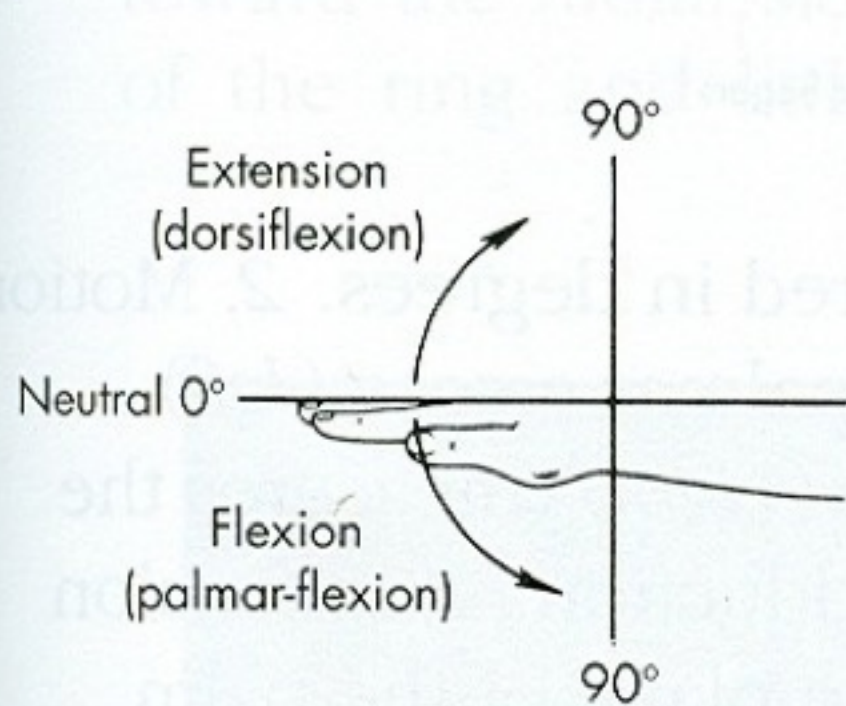
m. Pronator quadratus

- **Začátek:** margo anterior a přední strana distální čtvrtiny ulny
- **Úpon:** palmární strana radia (rozsah stejný jako začátek svalu, jen o něco distálněji)
- **Inervace:** nervus medianus (C₇ a Th₁)
- **Funkce:** pronace předloktí

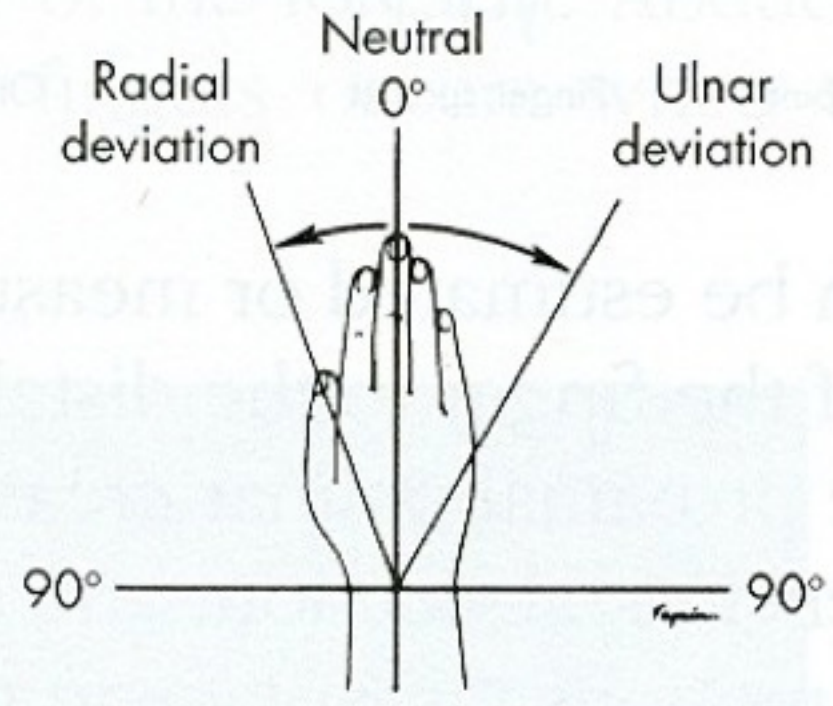




Pohyby zápěstí

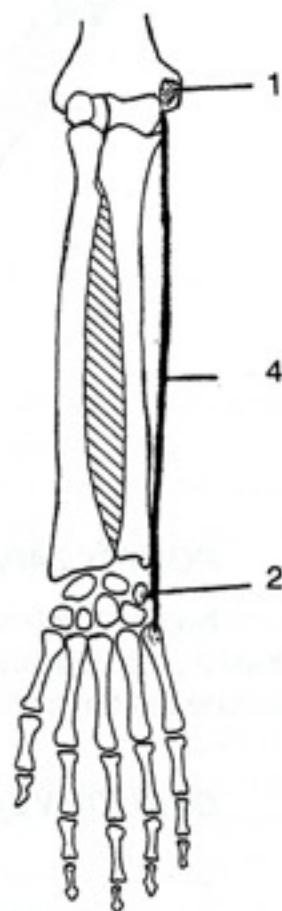
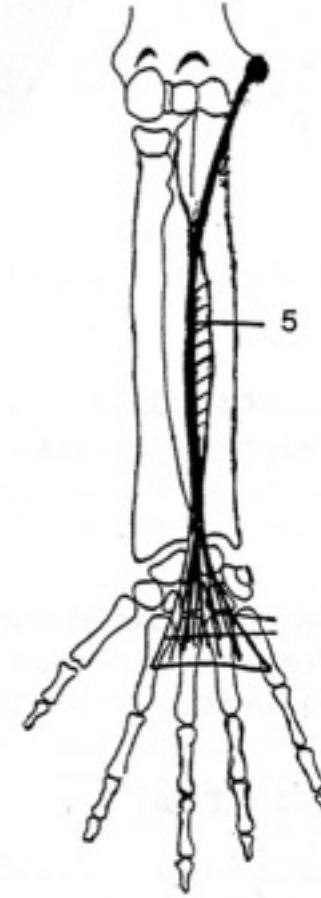
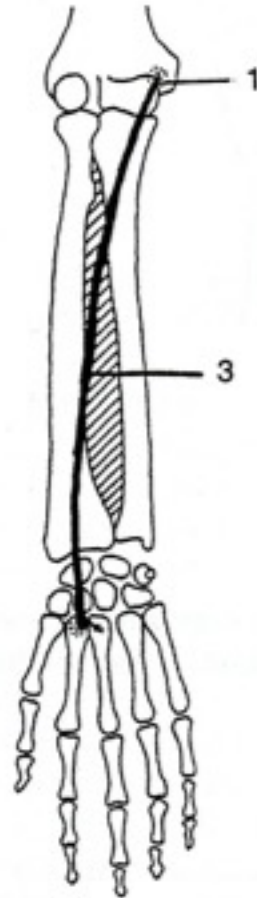
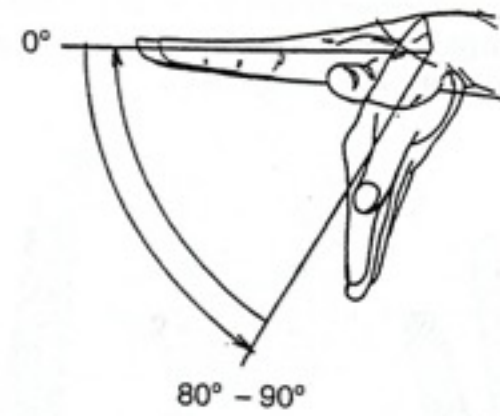


A



B

Palmární flexe

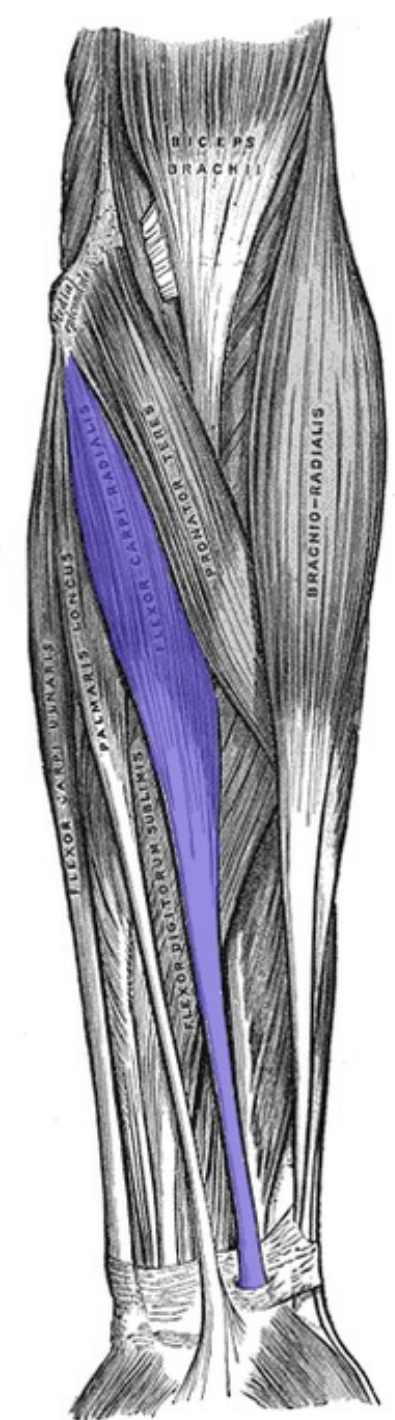


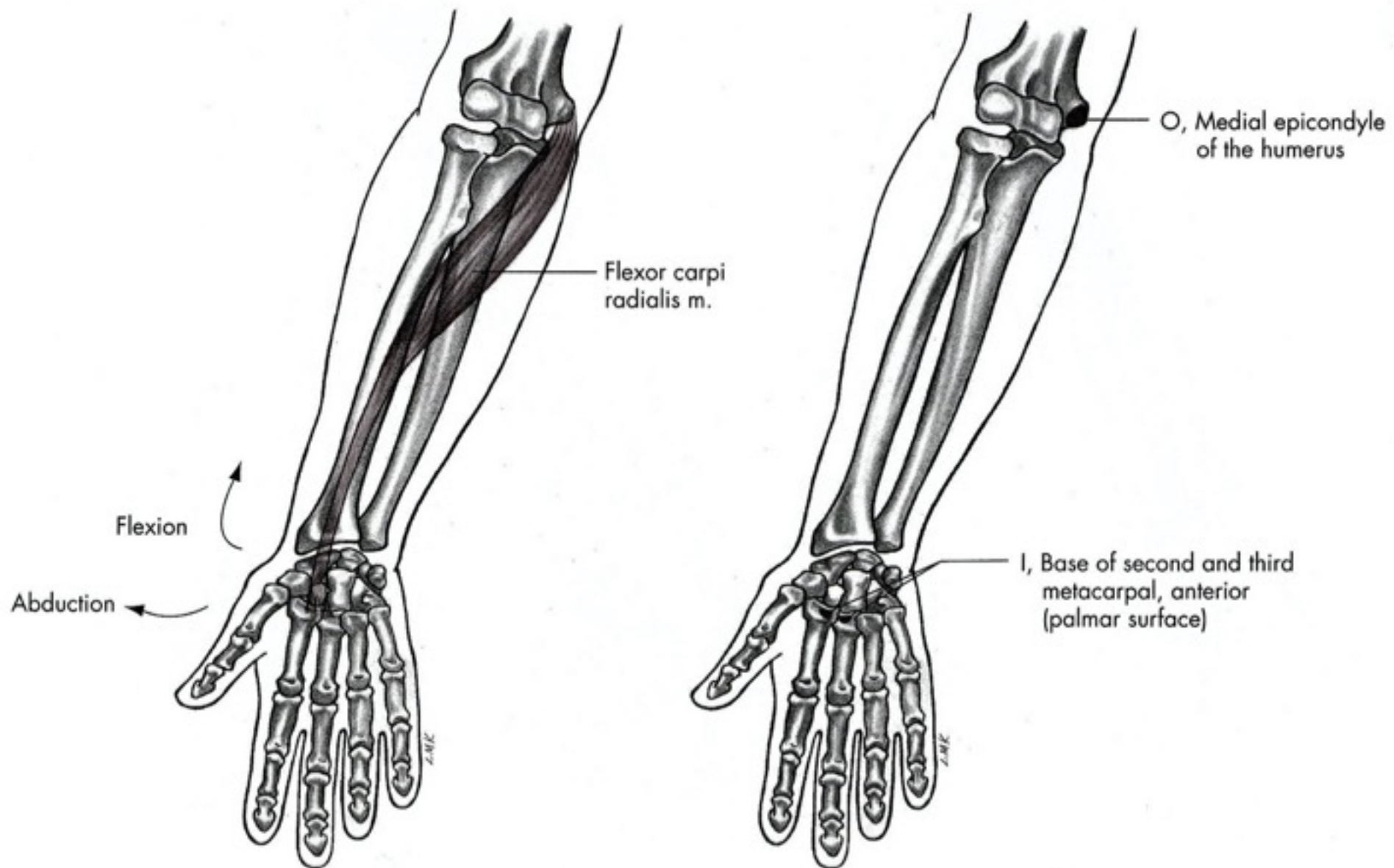
Palmární flexe

- M. flexor carpi radialis
- M. flexor carpi ulnaris
- M. palmaris longus

m. Flexor carpi radialis

- Začátek: mediální epikondyl humeru
- Úpon: baze 2. a 3. metakarpu
- Inervace: nervus medianus
- Funkce: flexe zápěstí, radiální dukce, pomocná flexe loketního kloubu, pronace





Flexor carpi radialis m.

O, Medial epicondyle of the humerus

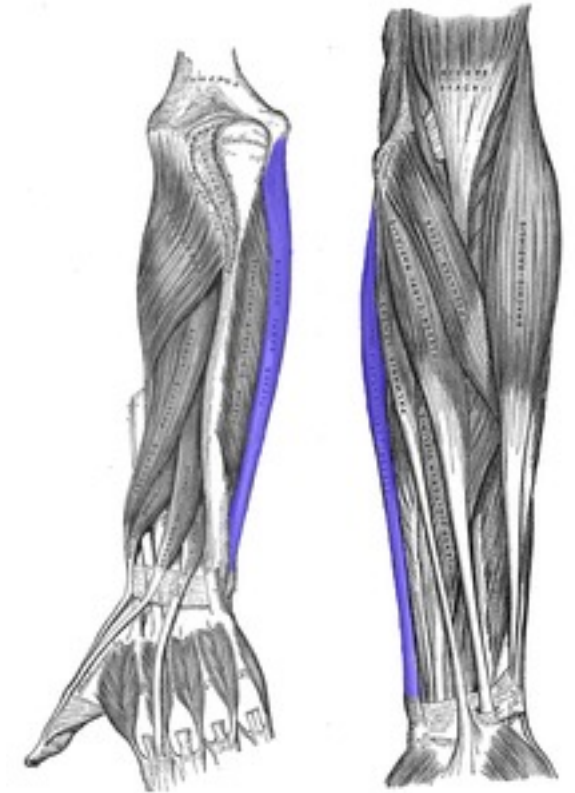
Flexion

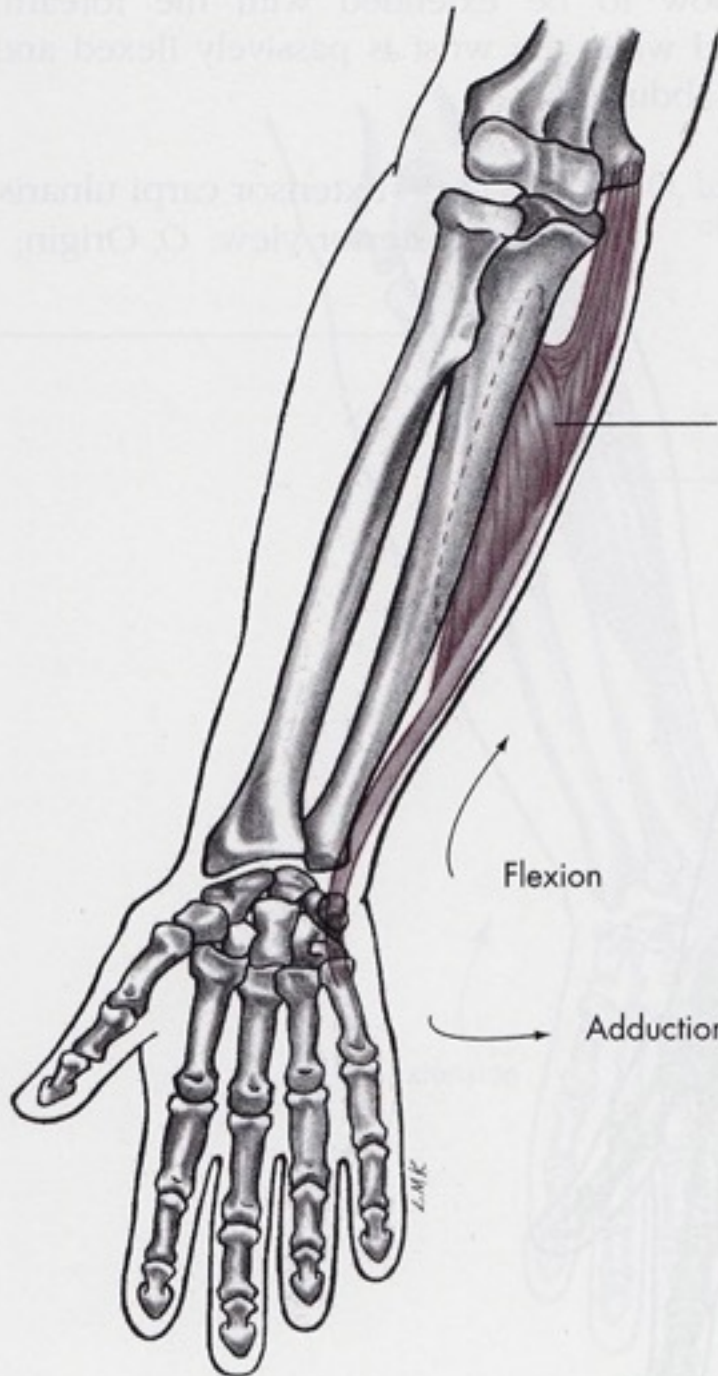Abduction

I, Base of second and third metacarpal, anterior (palmar surface)

m. Flexor carpi ulnaris

- Začátek: mediální epikondyl humeru a olecranon ulnae
- Úpon: os pisiforme, os hamatum a pátý metakarp
- Inervace: nervus ulnaris
- Funkce: flexe zápěstí, ulnární dukce

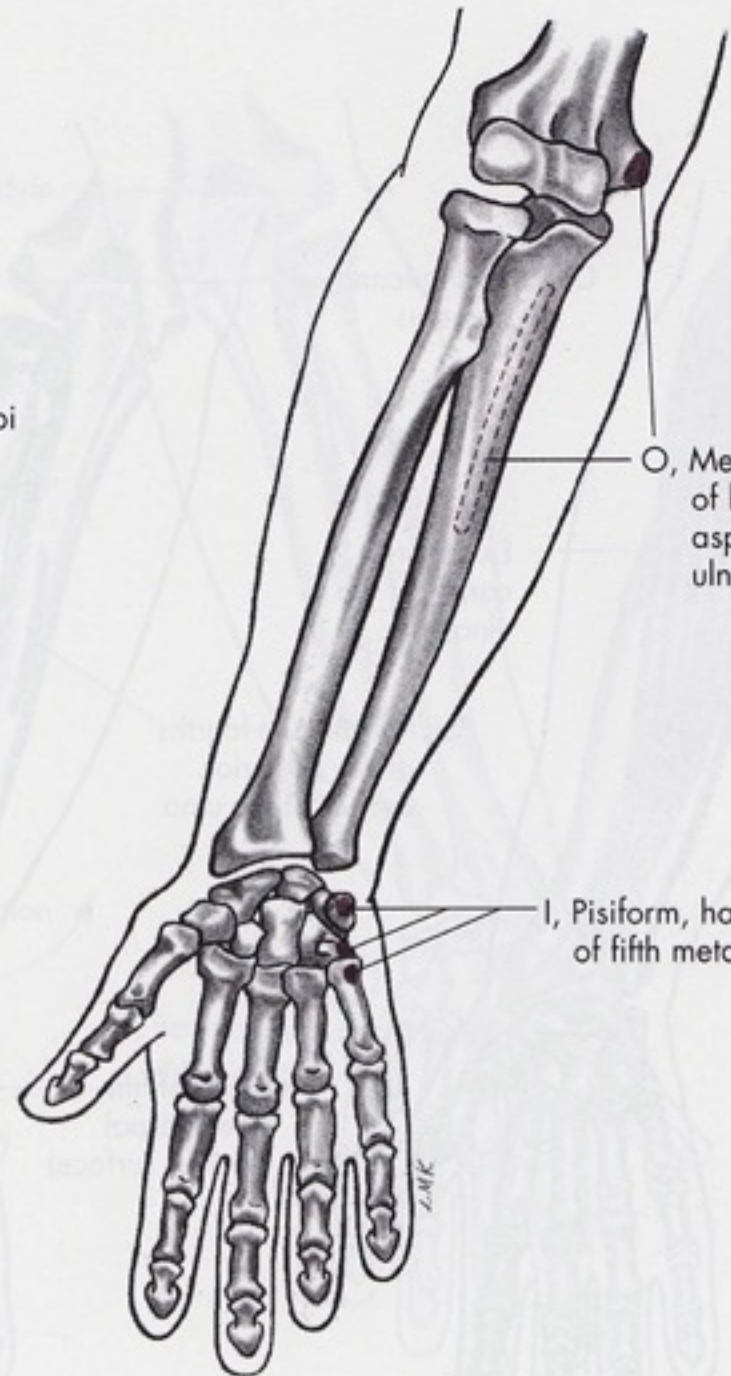




Flexor carpi ulnaris m.

Flexion

Adduction

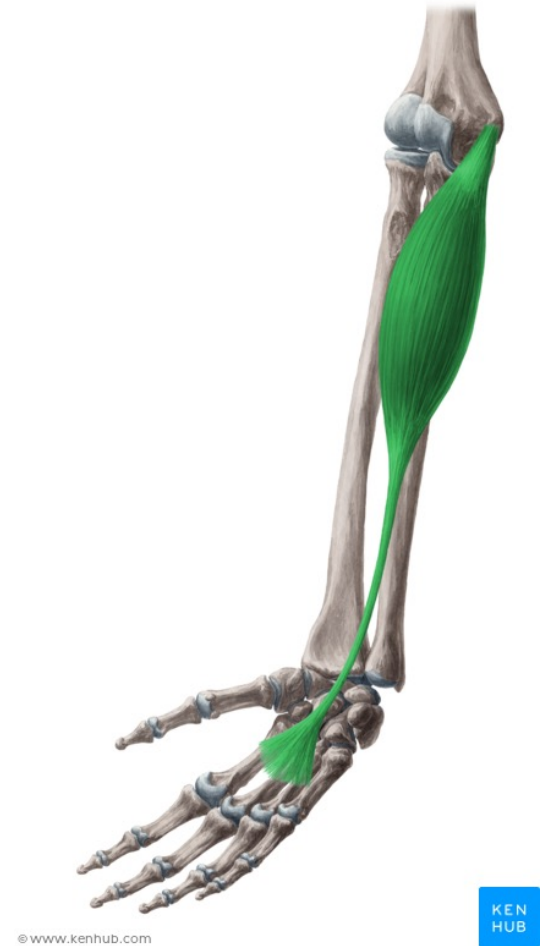

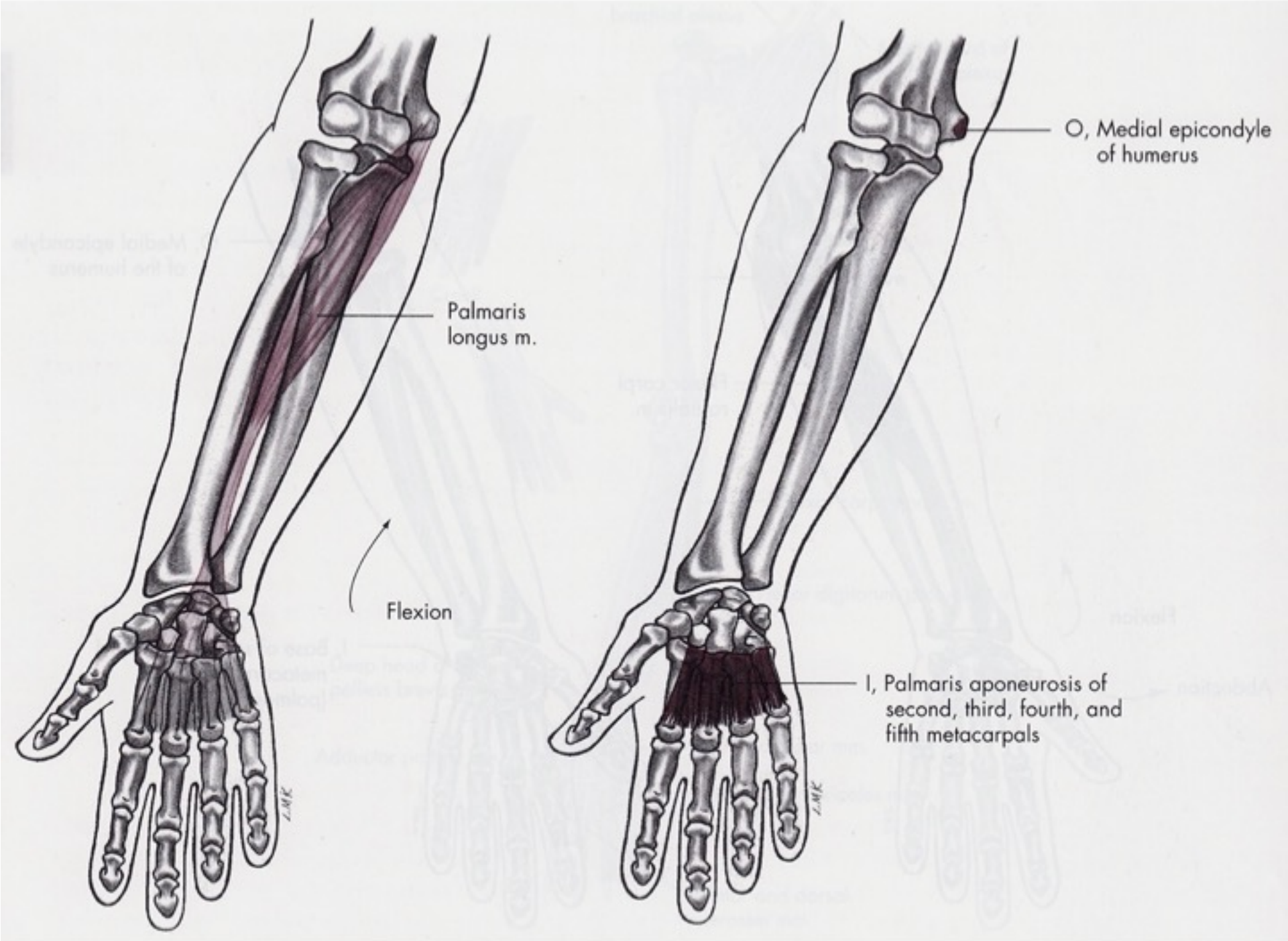
O, Medial epicondyle of humerus, posterior aspect of proximal ulna

I, Pisiform, hamate, and base of fifth metacarpal

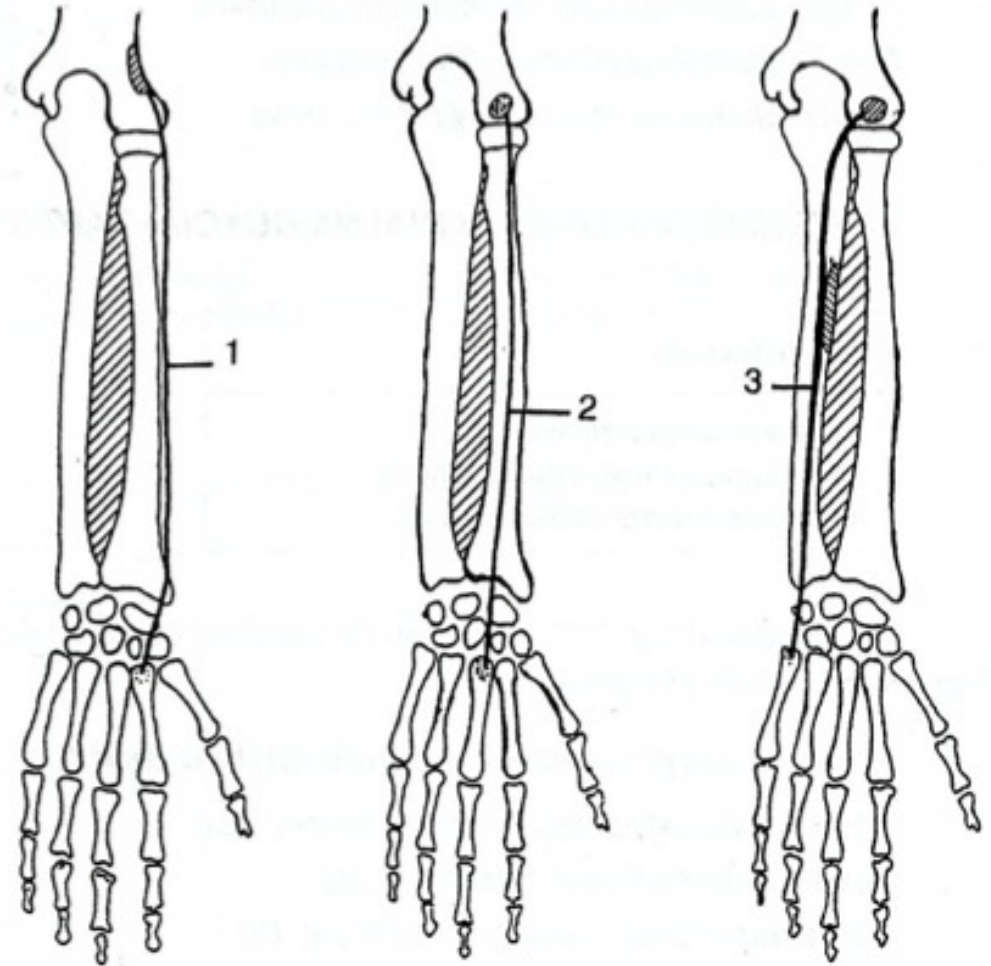

m. Palmaris longus

- **Začátek:** medialní (ulnarní) epikondyl humeru, společná úponová šlacha flexorů
- **Úpon:** retinaculum musculorum flexorum, palmární aponeuróza
- **Inervace:** nervus medianus C7-Th1
- **Funkce:** miska z dlaně, palmární flexe zápěstí





Dorzální flexe

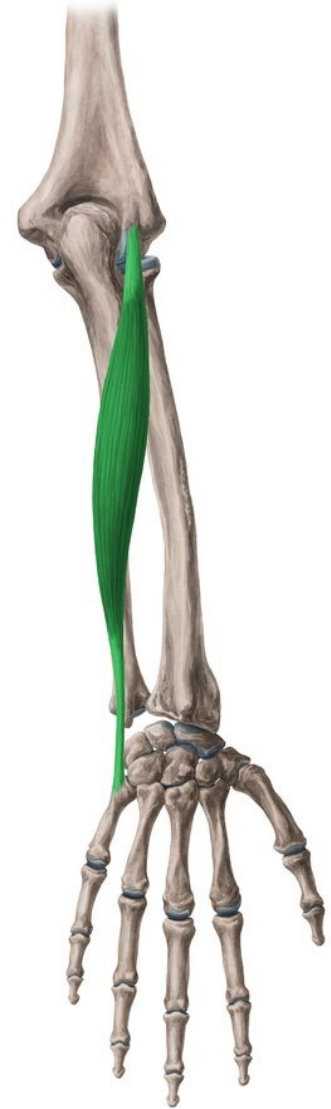

Dorzální flexe

- M. extensor carpi radialis longus et brevis
- M. extensor carpi ulnaris

m. Extensor carpi ulnaris

- **Začátek:** epicondylus lateralis humeri
- **Úpon:** dorzolaterální hrana baze 5. metakarpu
- **Inervace:** nervus radialis (ramus profundus) C5-8
- **Funkce:**
 - extense zápěstí;
 - ulnární dukce zápěstí



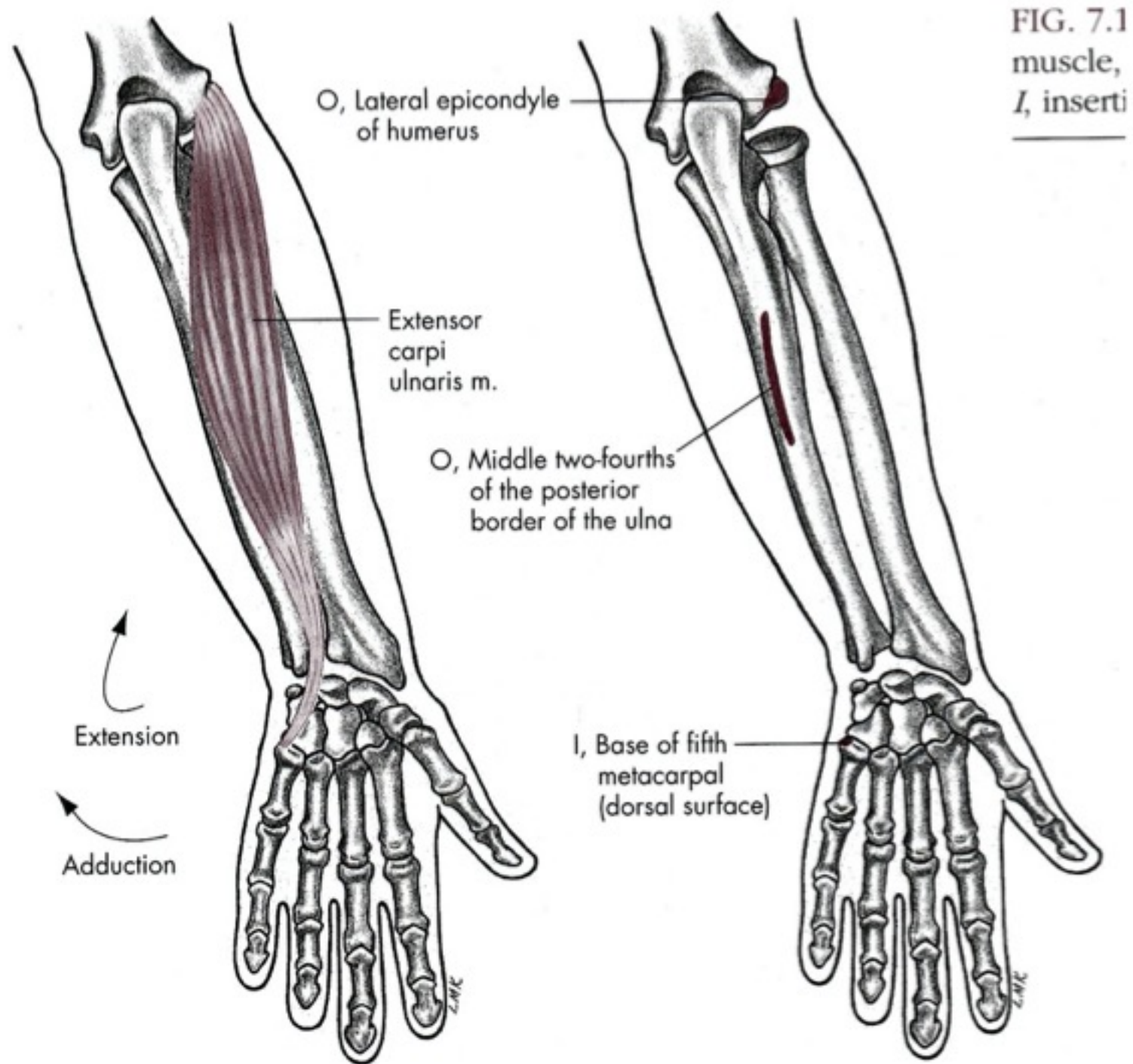
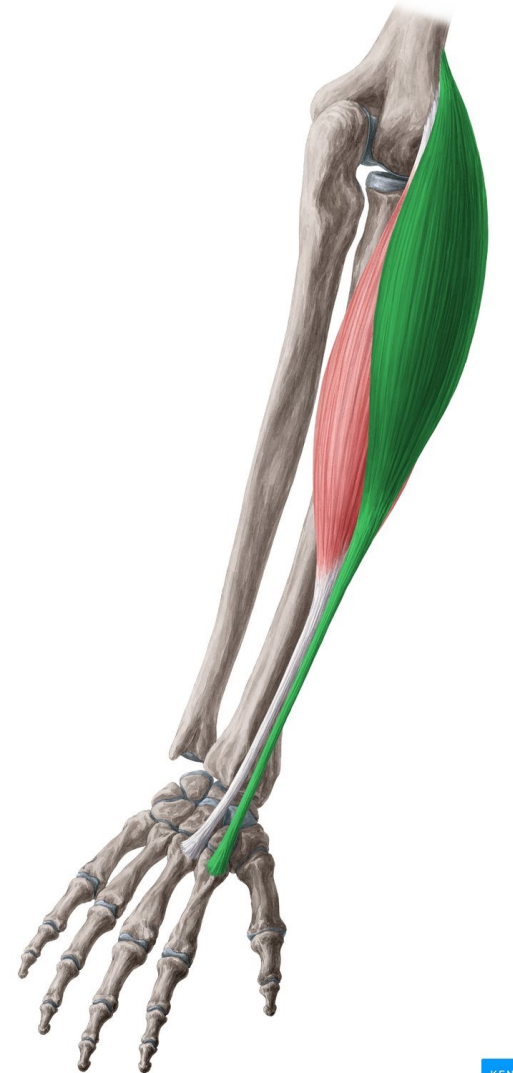


FIG. 7.1
muscle,
I, inserti

m. Extensor carpi radialis longus

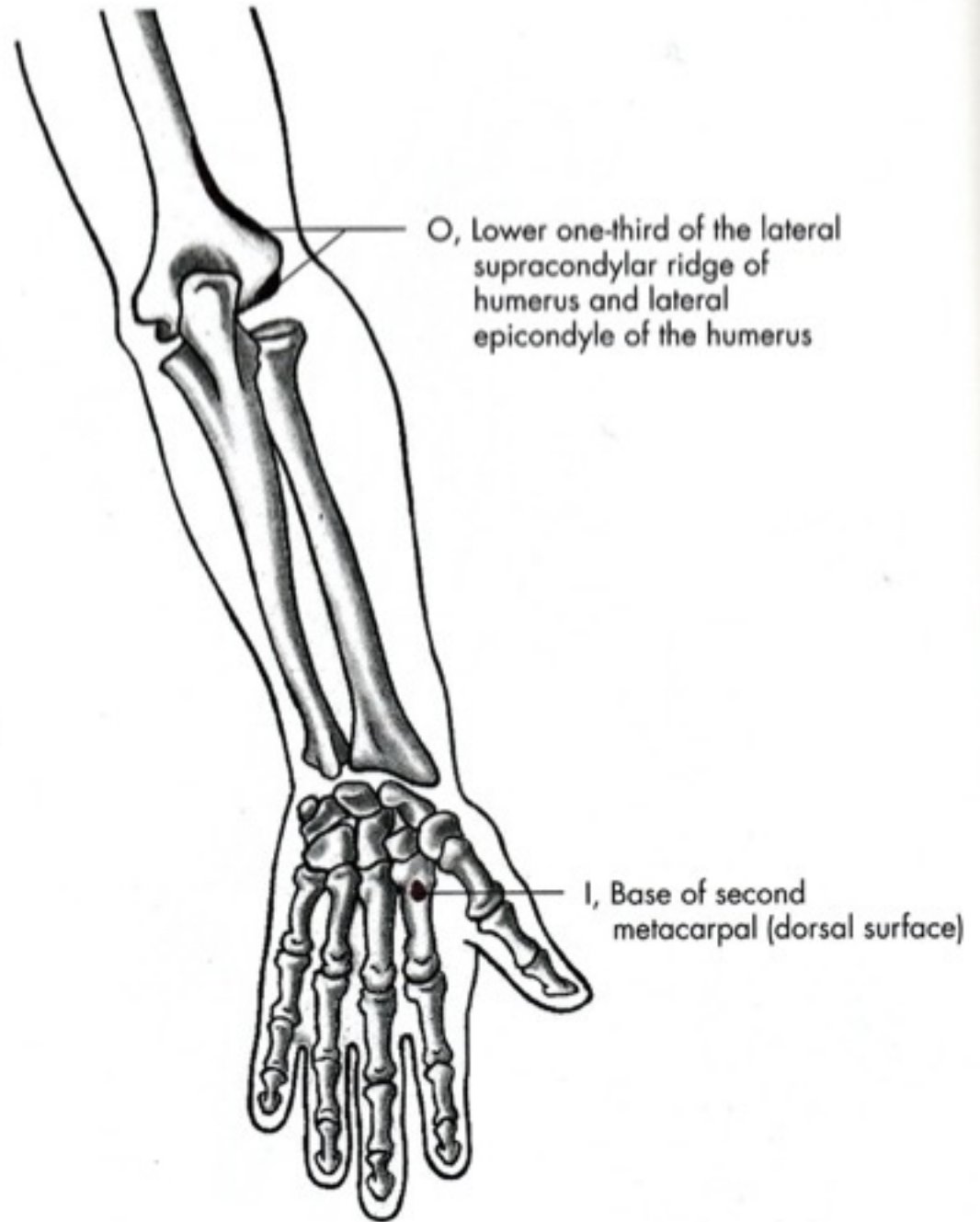
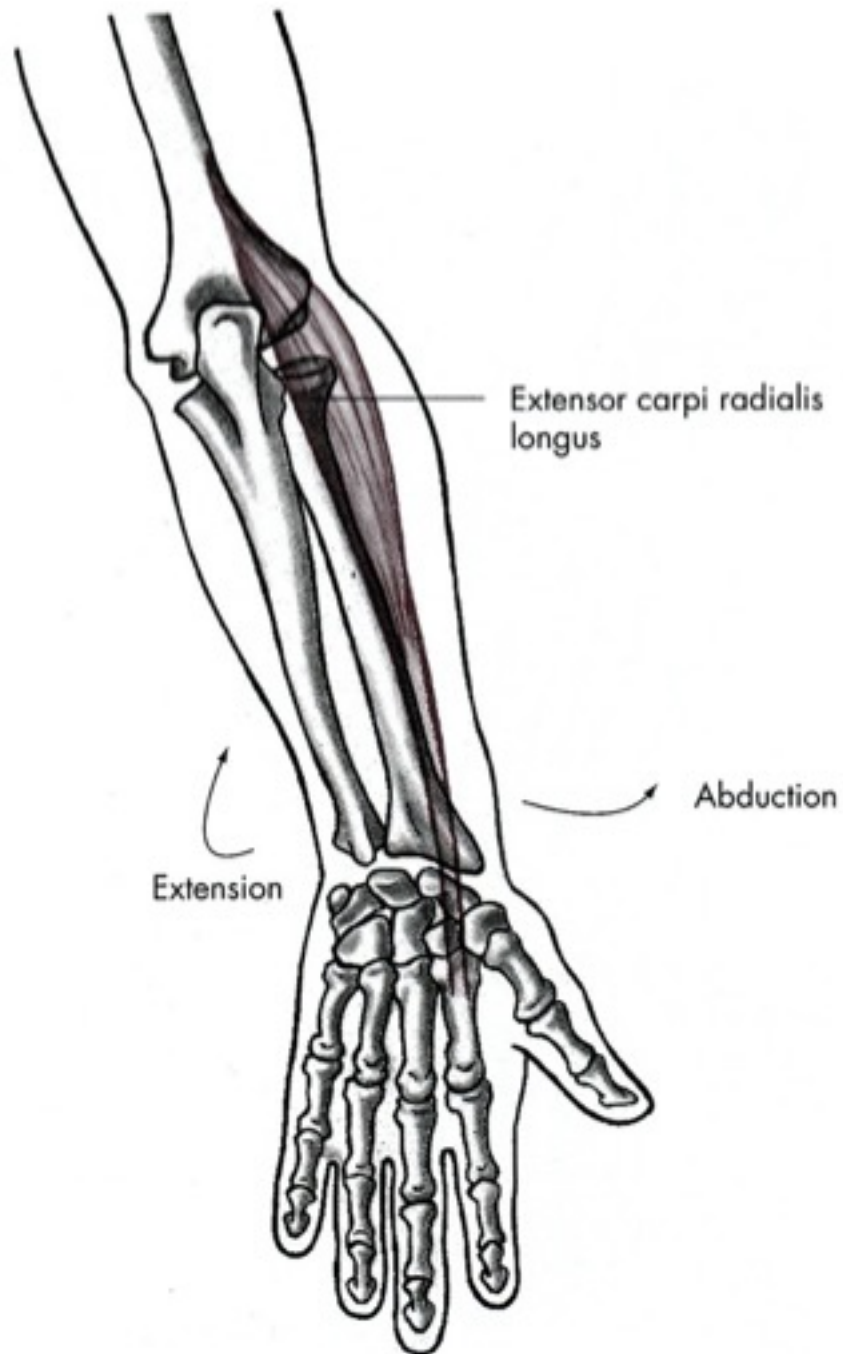
- **Začátek:** distální 1/3 *crista supracondylaris lateralis humeri*, septum intermuskulare brachii laterale
- **Úpon:** dorzolaterální hrana baze 2. metakarpu
- **Inervace:** *nervus radialis (ramus superficialis)* C5-8
- **Funkce:** extense a radiální dukce zápěstí, část participace na flexi lokte

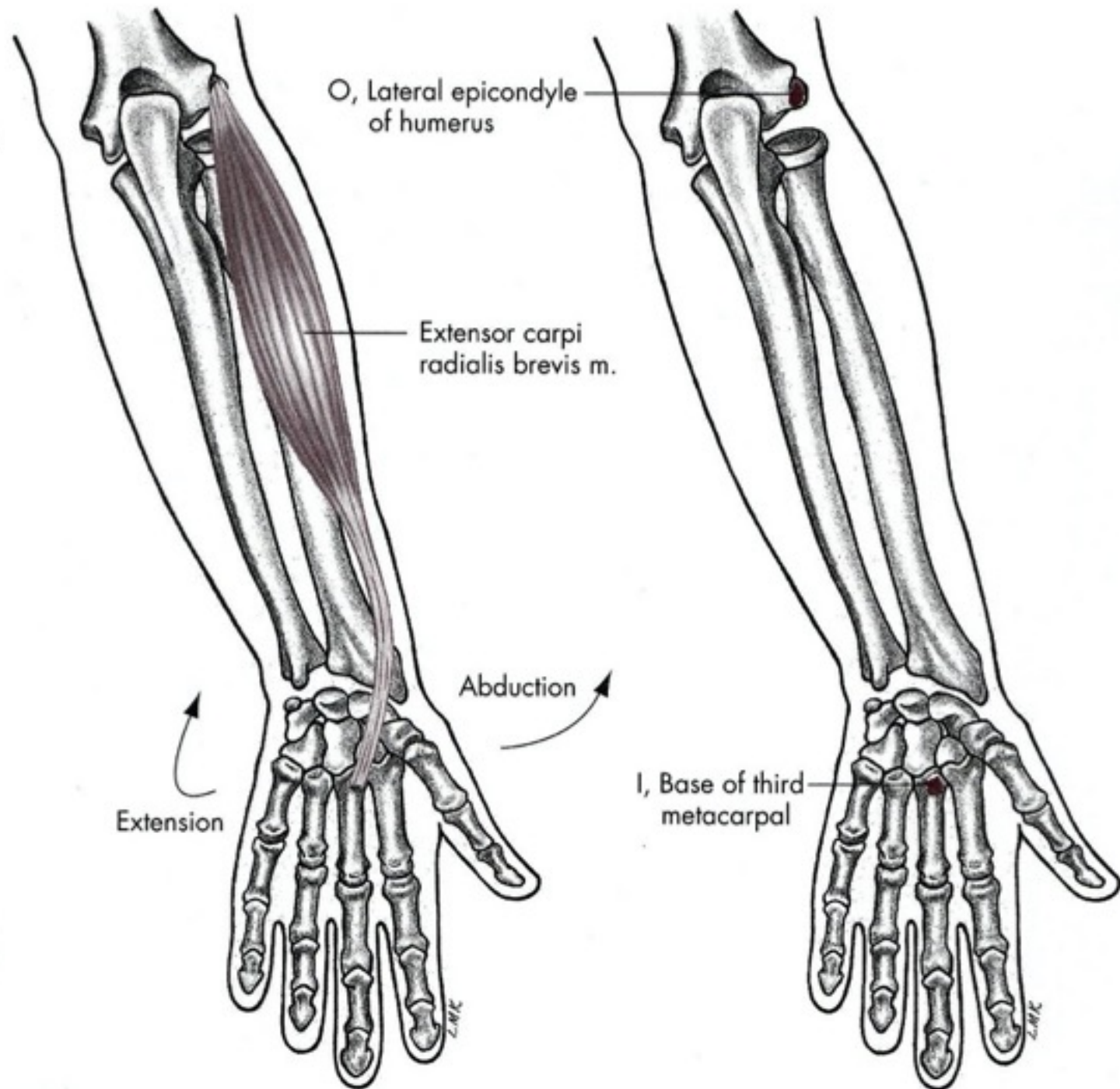


M. extensor carpi radialis brevis

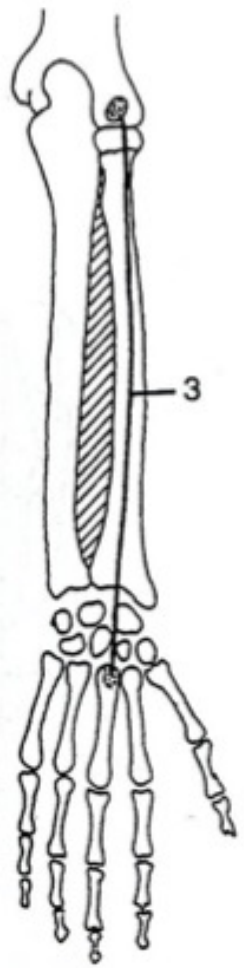
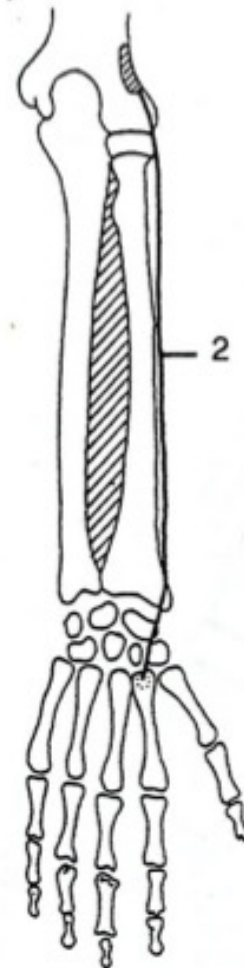
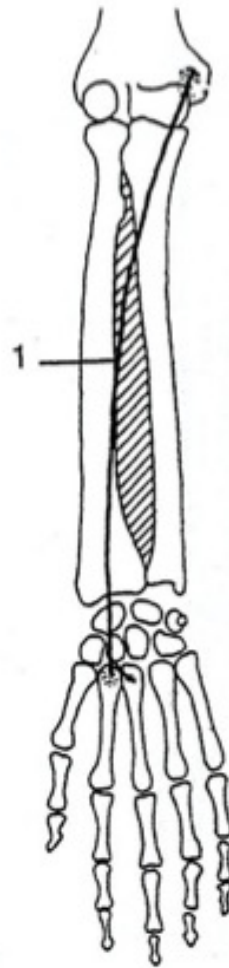
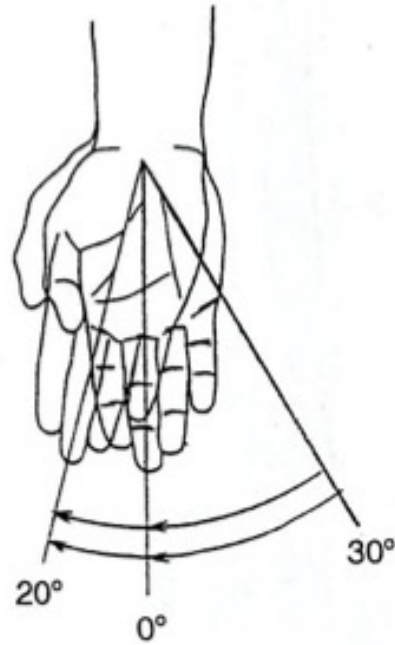
- **Začátek:**
- *epicondylus lateralis humeri, ligamentum collaterale radiale, ligamentum anulare radii*
- **Úpon:** dorzoradiální hrana baze 3. metakarpu
- **Inervace:** *nervus radialis (ramus profundus) C6-8*
- **Funkce:** extenze a radiální dukce zápěstí







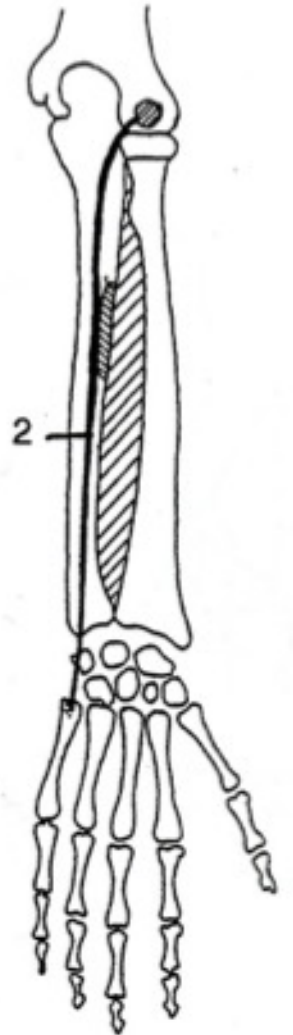
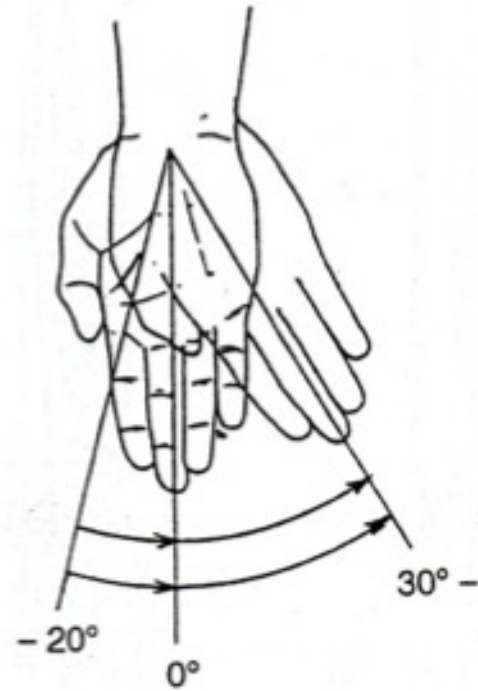
Radiální dukce



Radiální dukce

- M. extensor carpi radialis longus et brevis
- M. flexor carpi radialis

Ulnární dukce

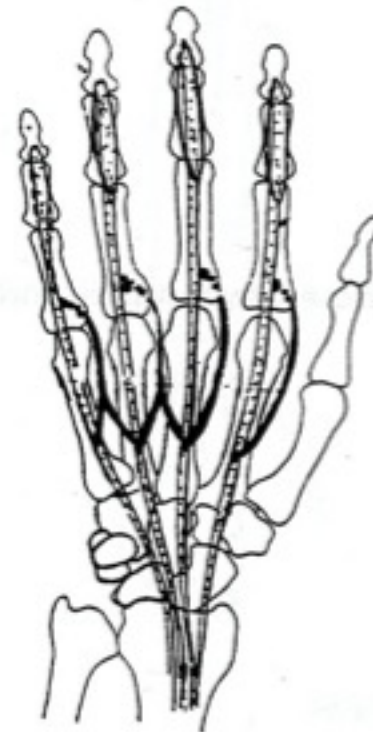
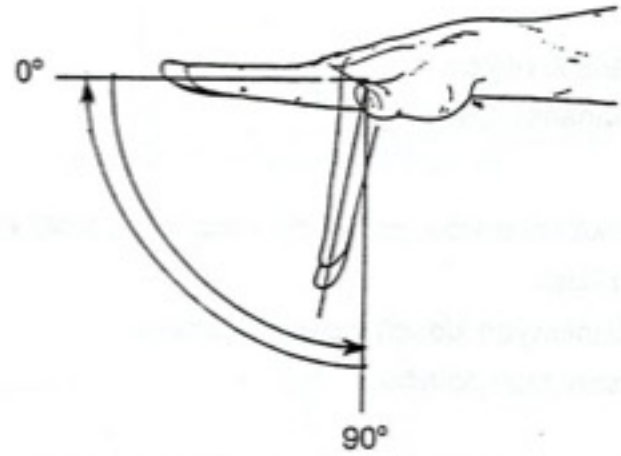


Ulnární dukce

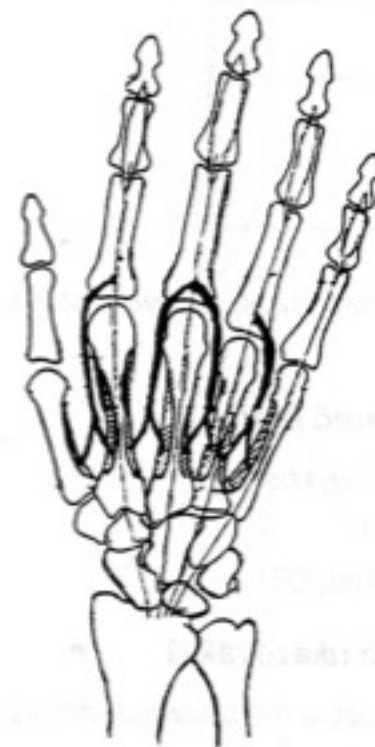- M. extensor carpi ulnaris
- M. flexor carpi ulnaris

Pohyby prstů

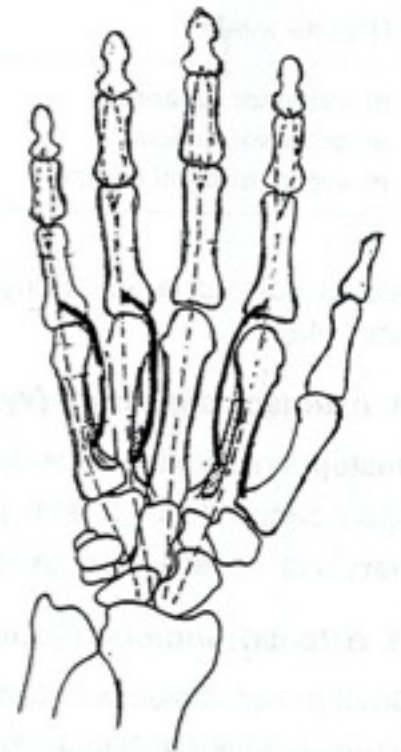
Flexe



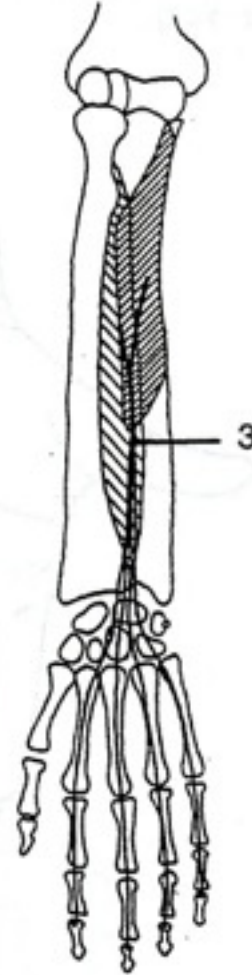
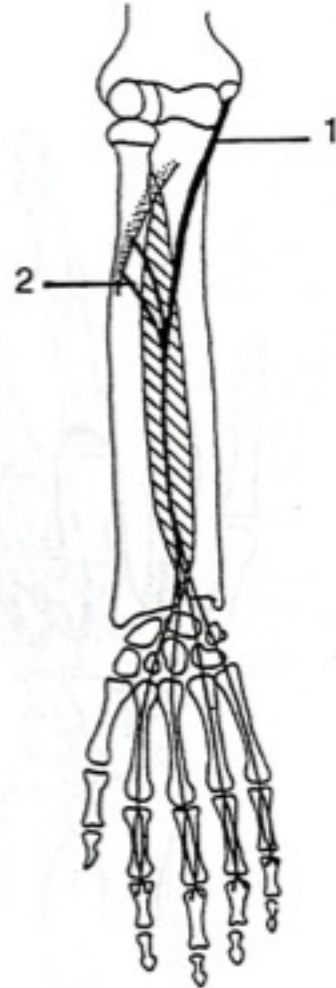
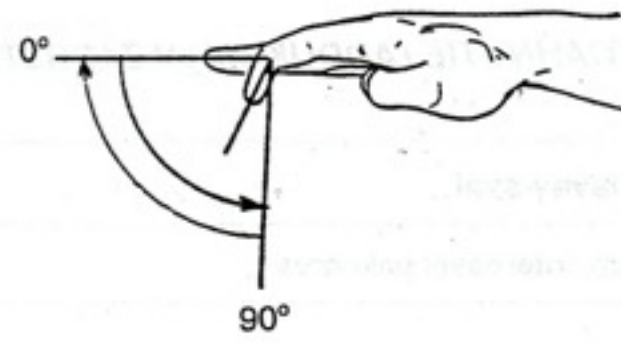
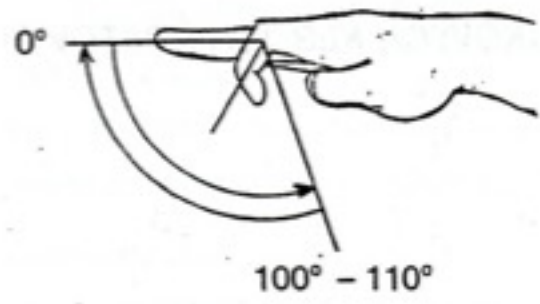
A



B



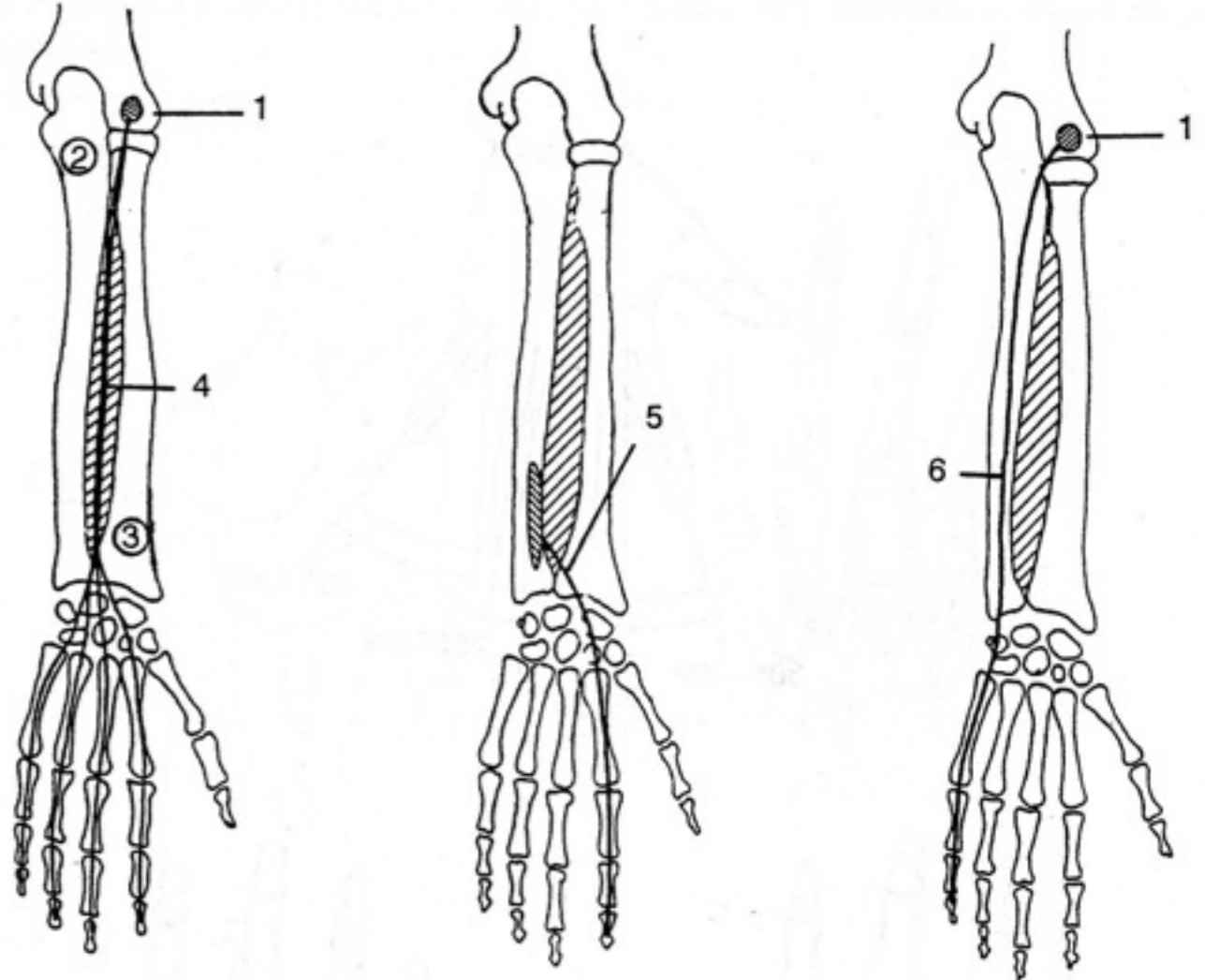
C

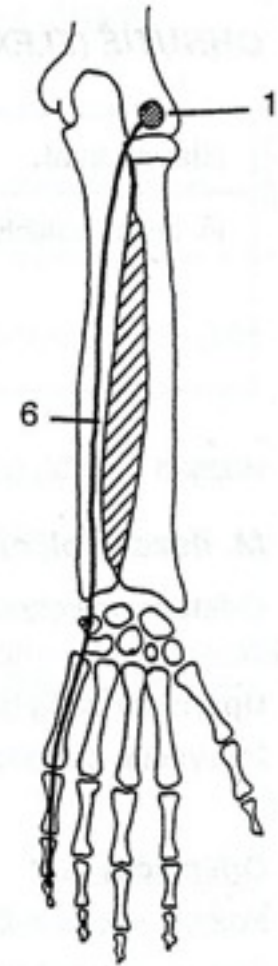
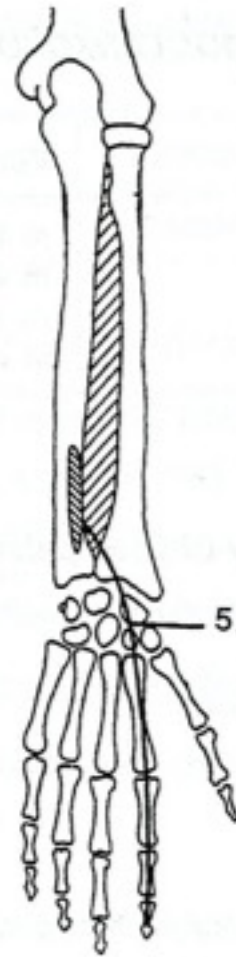
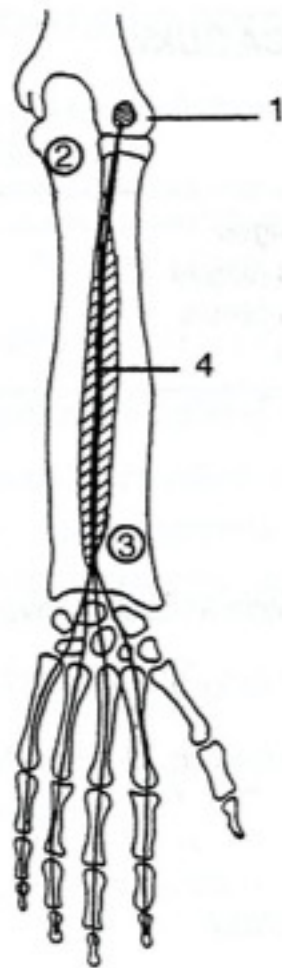
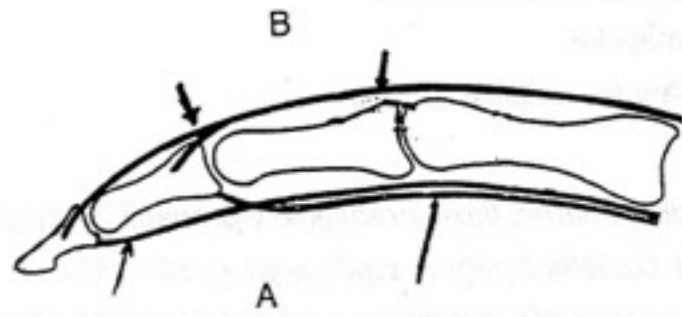


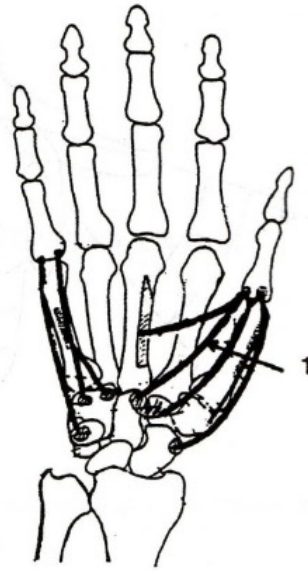
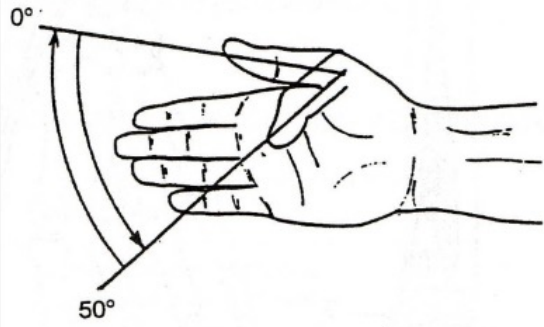
Extenze

20° - 30°

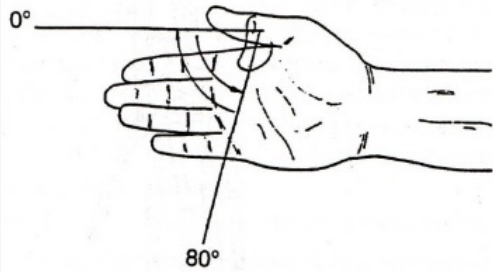
0°



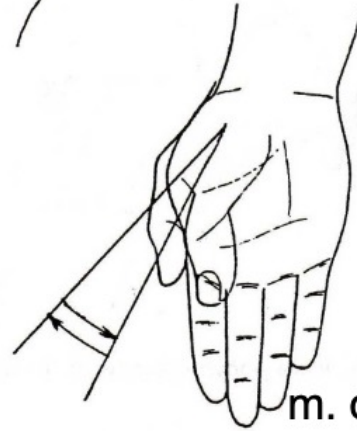
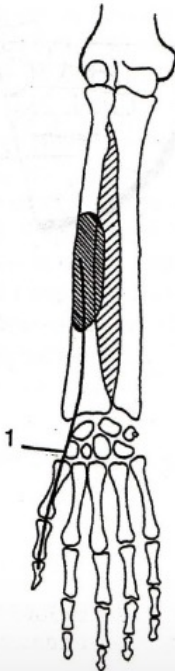




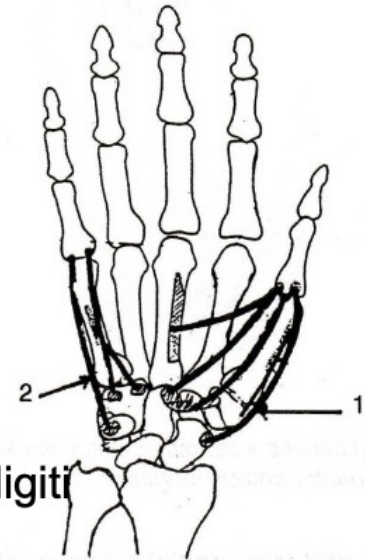
m. flexor pollicis brevis



m. flexor pollicis longus



m. opponens digiti
minimi



m. opponens pollicis

Děkuji za pozornost