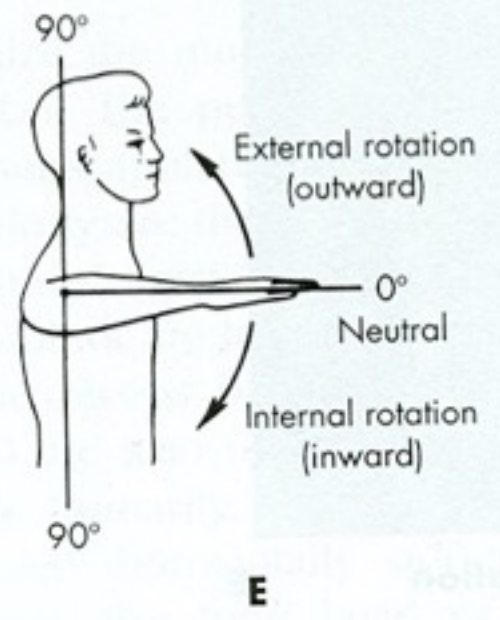
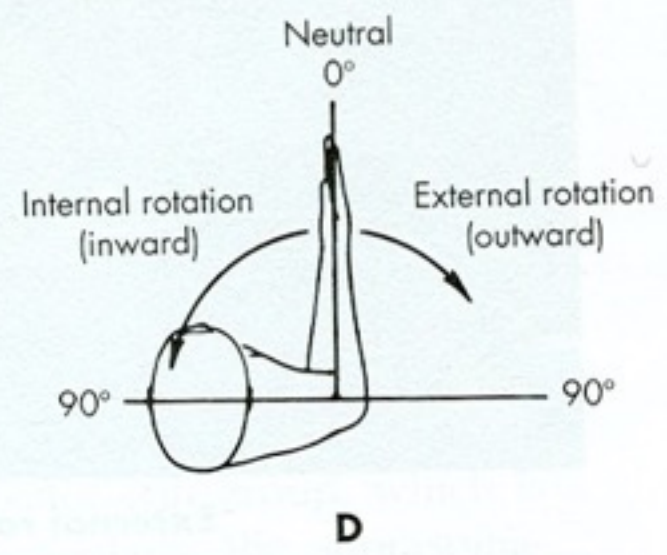
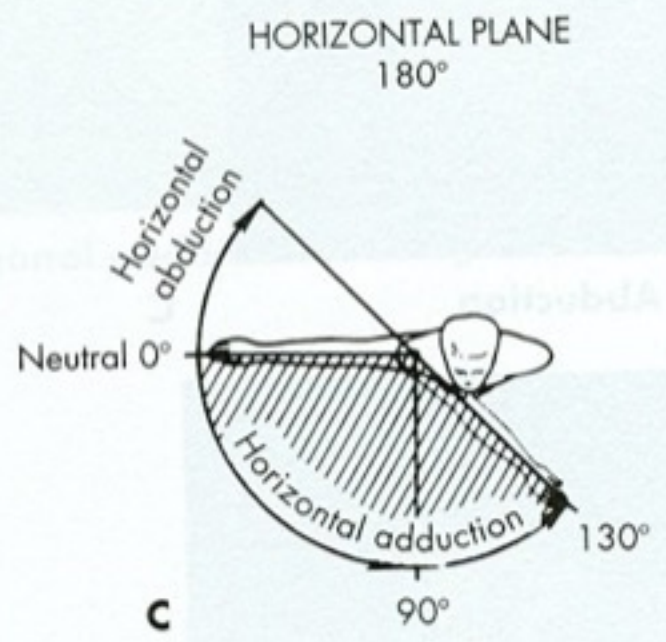
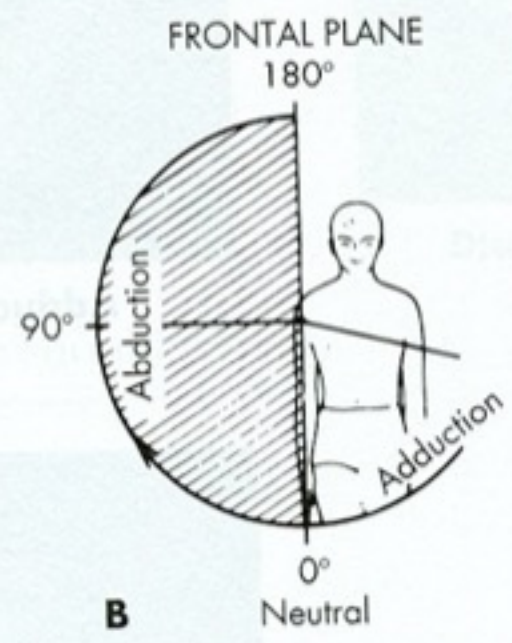
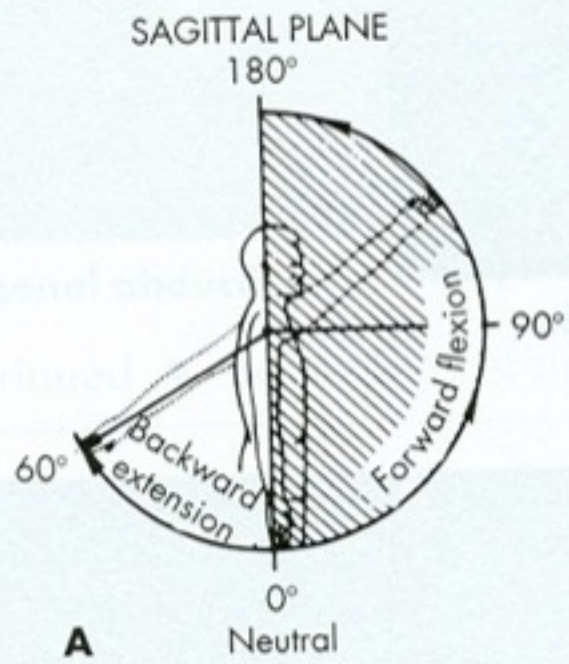
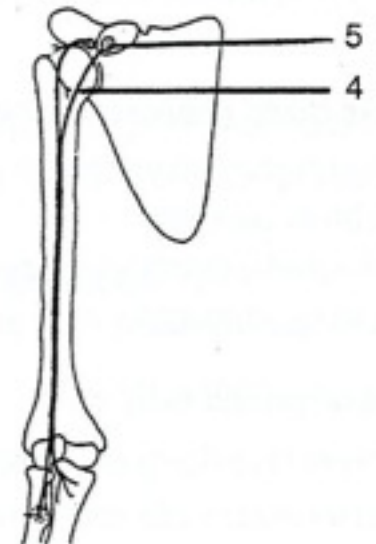
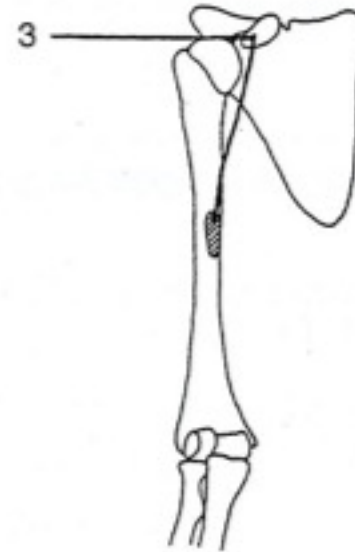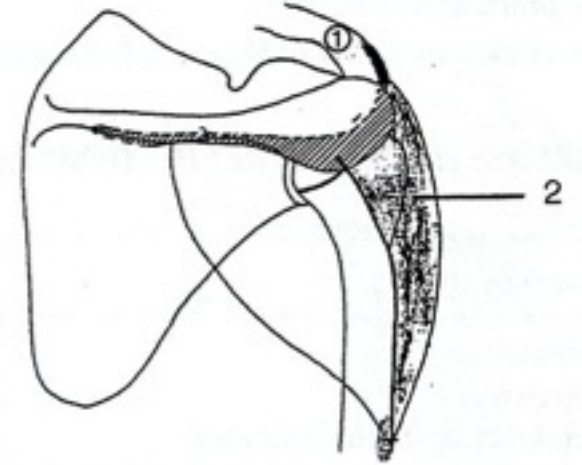
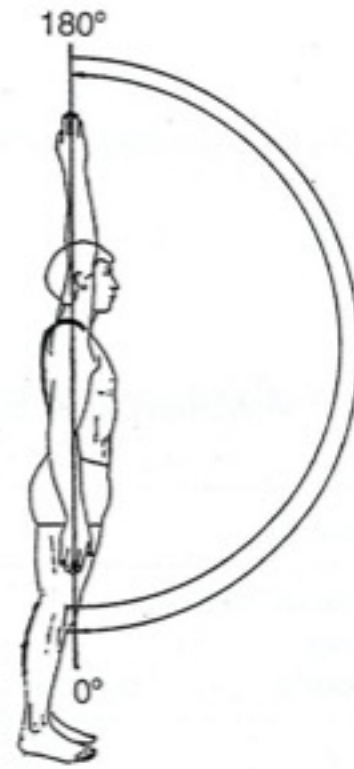


Kineziologie ramenní pletencec

Mgr. Klára Vomáčková



Flexe

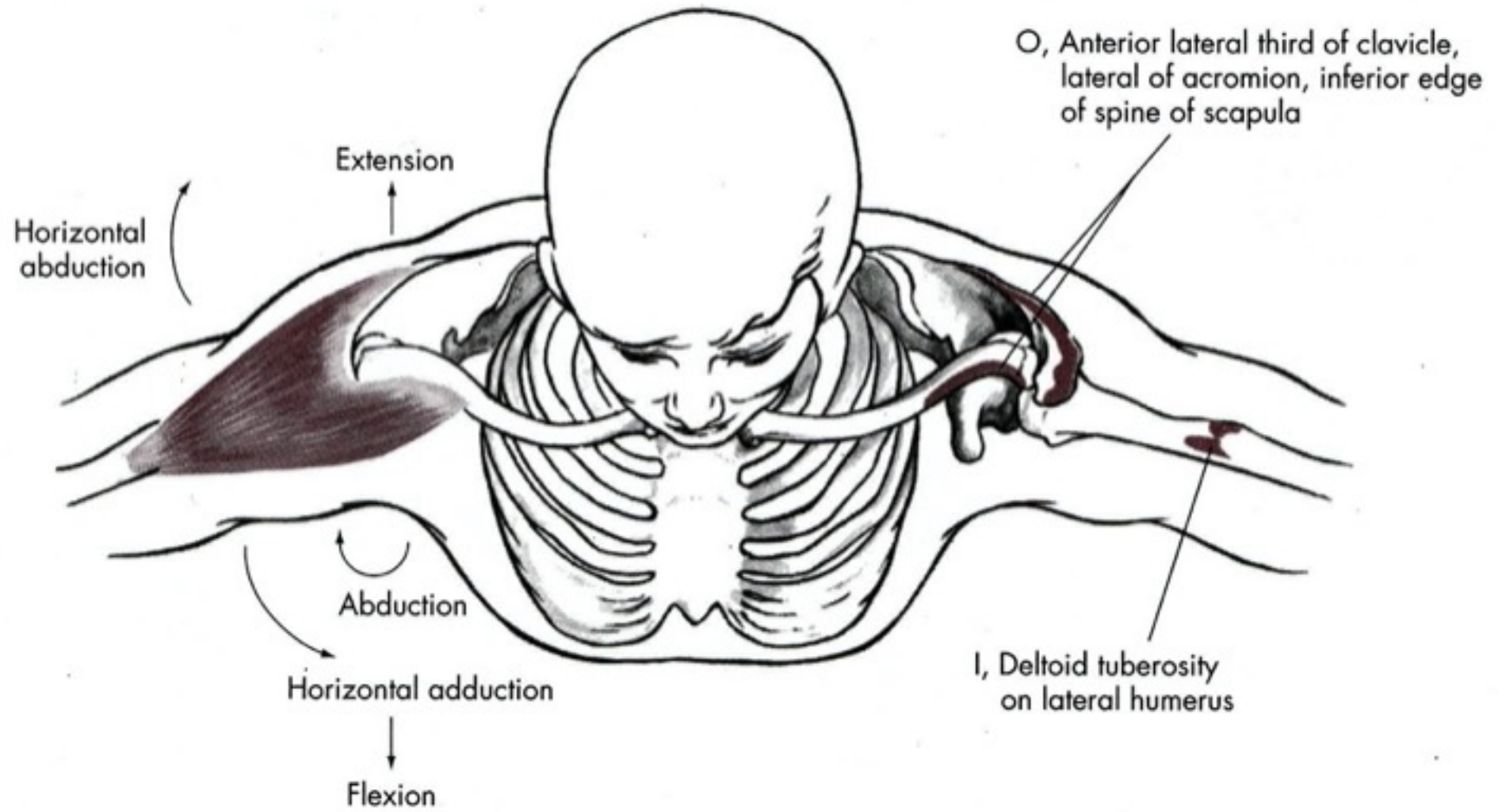


Flexe

- M. deltoideus – pars clavicularis
- M. coracobrachialis
- M. biceps brachii – caput breve

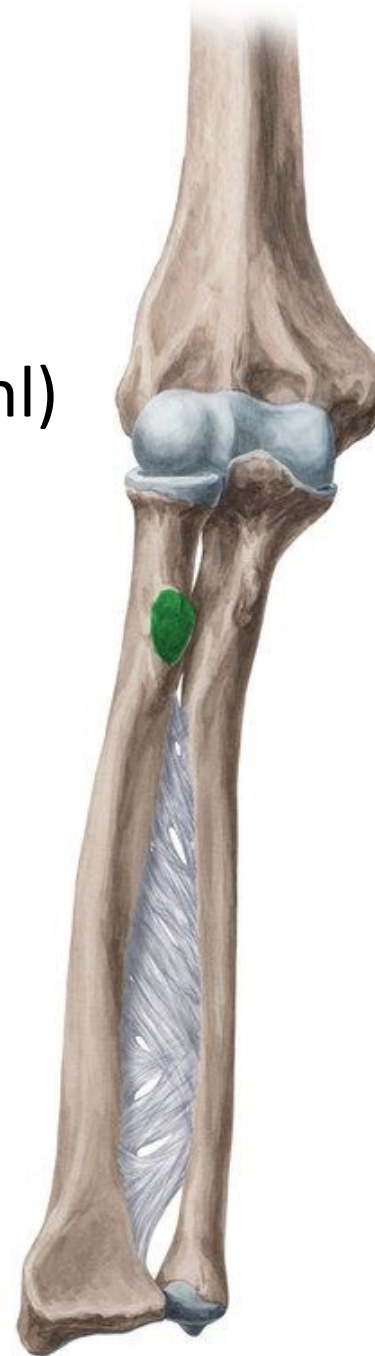M. Deltoideus (3 části)

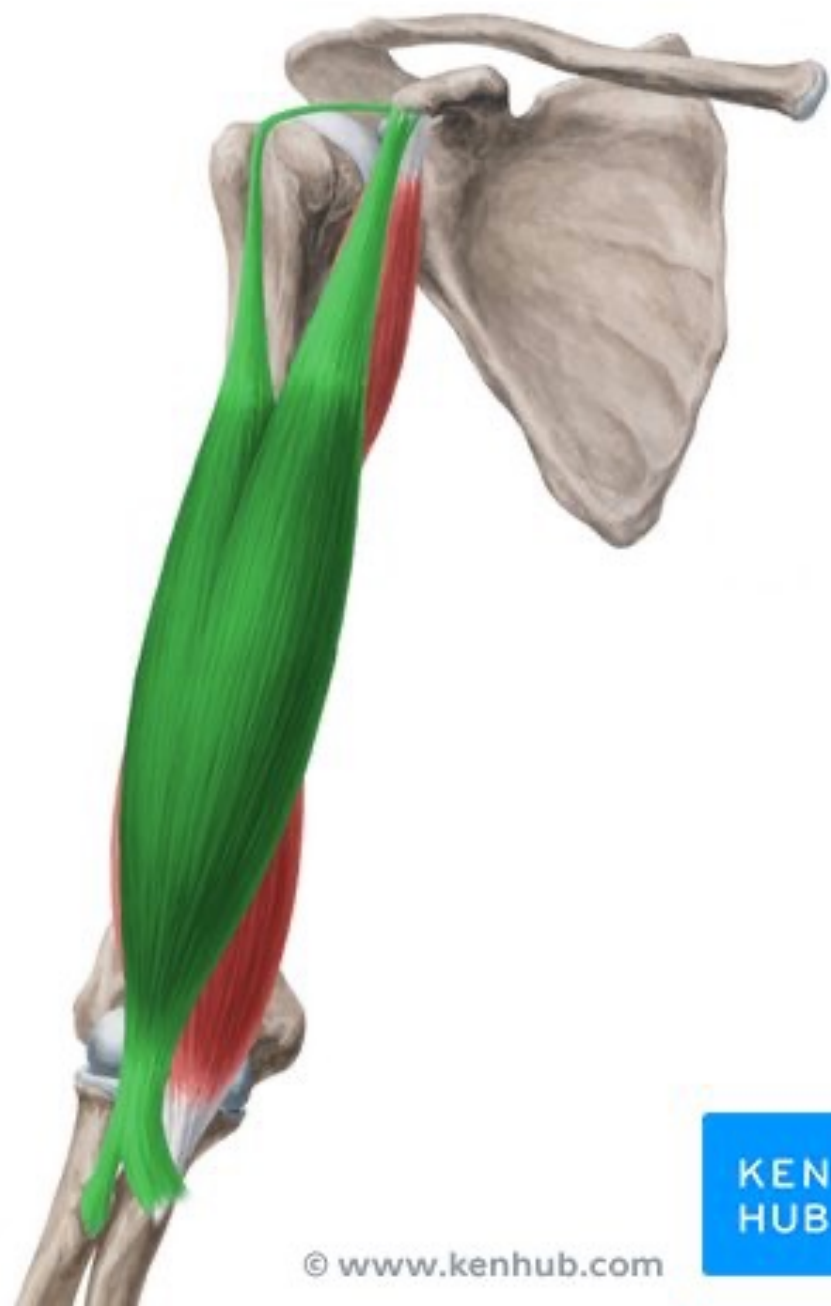- Z: zevní dvě třetiny spina scapulae, acromion, zevní konec claviculy
- K: tuberositas deltoidea humeri
- Inervace: nervus axillaris
- F: předpažení, zapažení, upažení



M. Biceps brachii

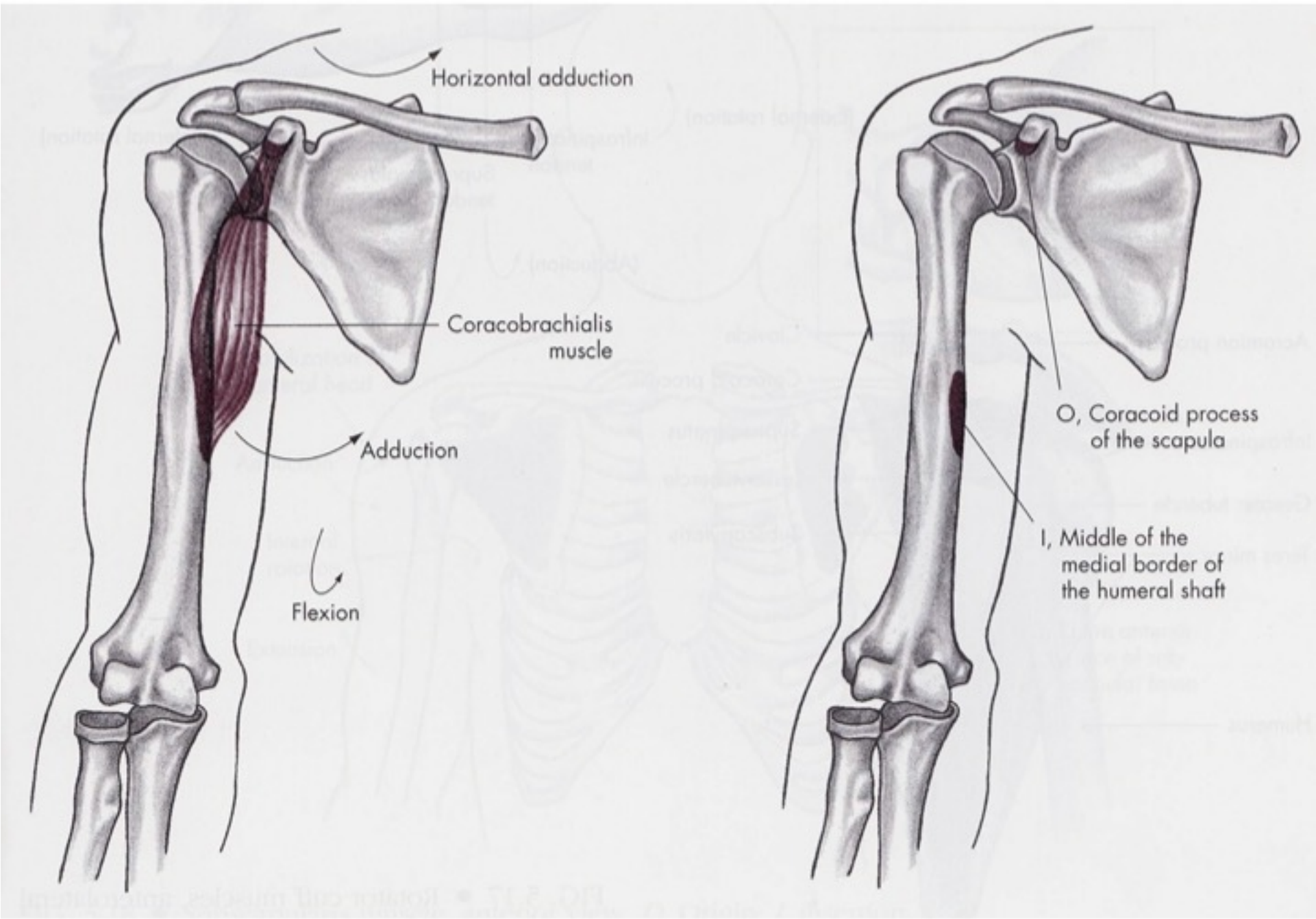
- Z: tuberculum supraglenoidale (dl.hl), processus coracoideus (kr.hl)
- K: tuberositas radii, aponeurosis musclic bicipitis brachii
- I: nervus musculocutaneus
- F: flexe, supinace lok, pomocná abd a add v rak



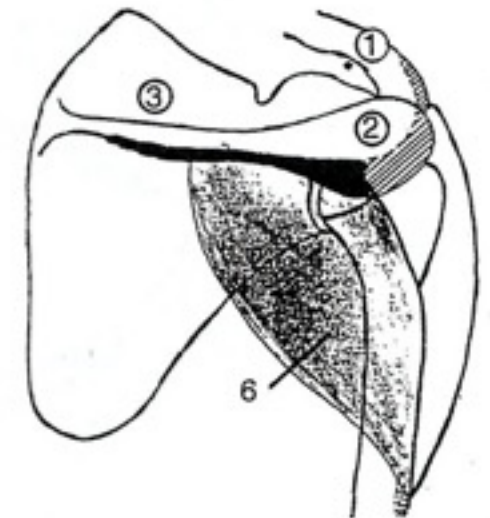
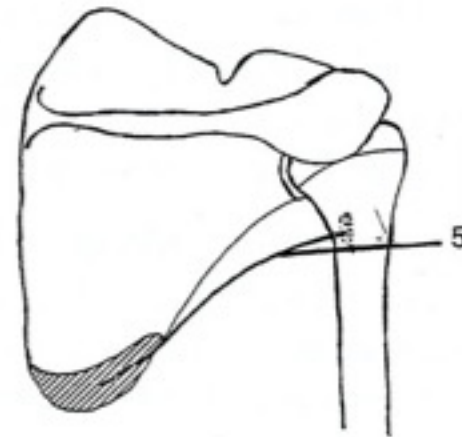
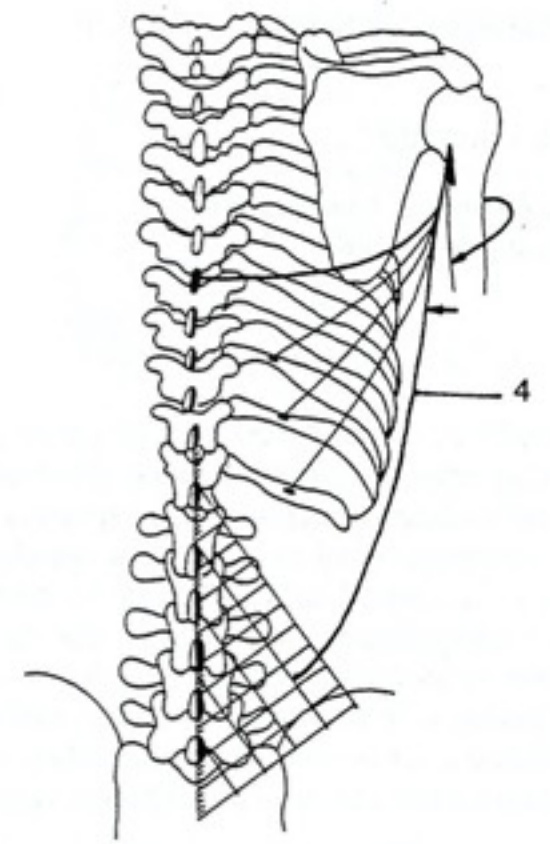
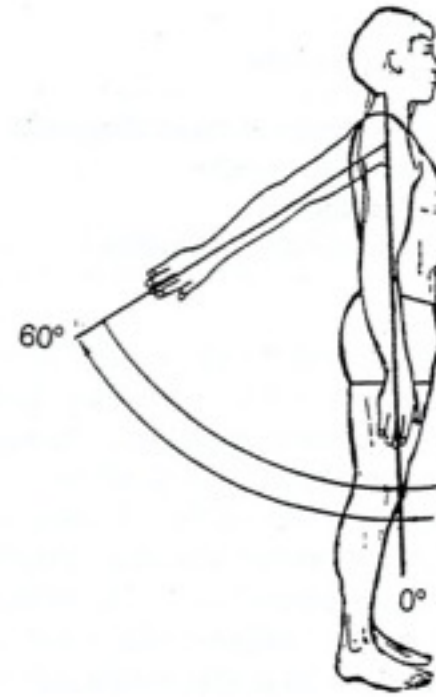


M. coracobrachialis

- Z: processus coracoideus scapulae
- K: crista tuberculi minoris humeri
- I: n. musculocutaneus
- F: pomocná add a pomocná ventrální flexe rak



Extenze

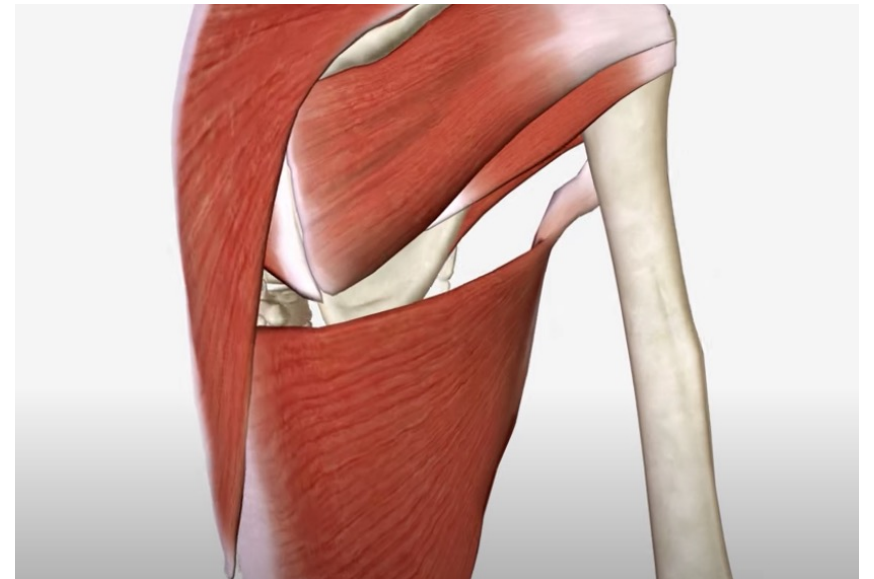


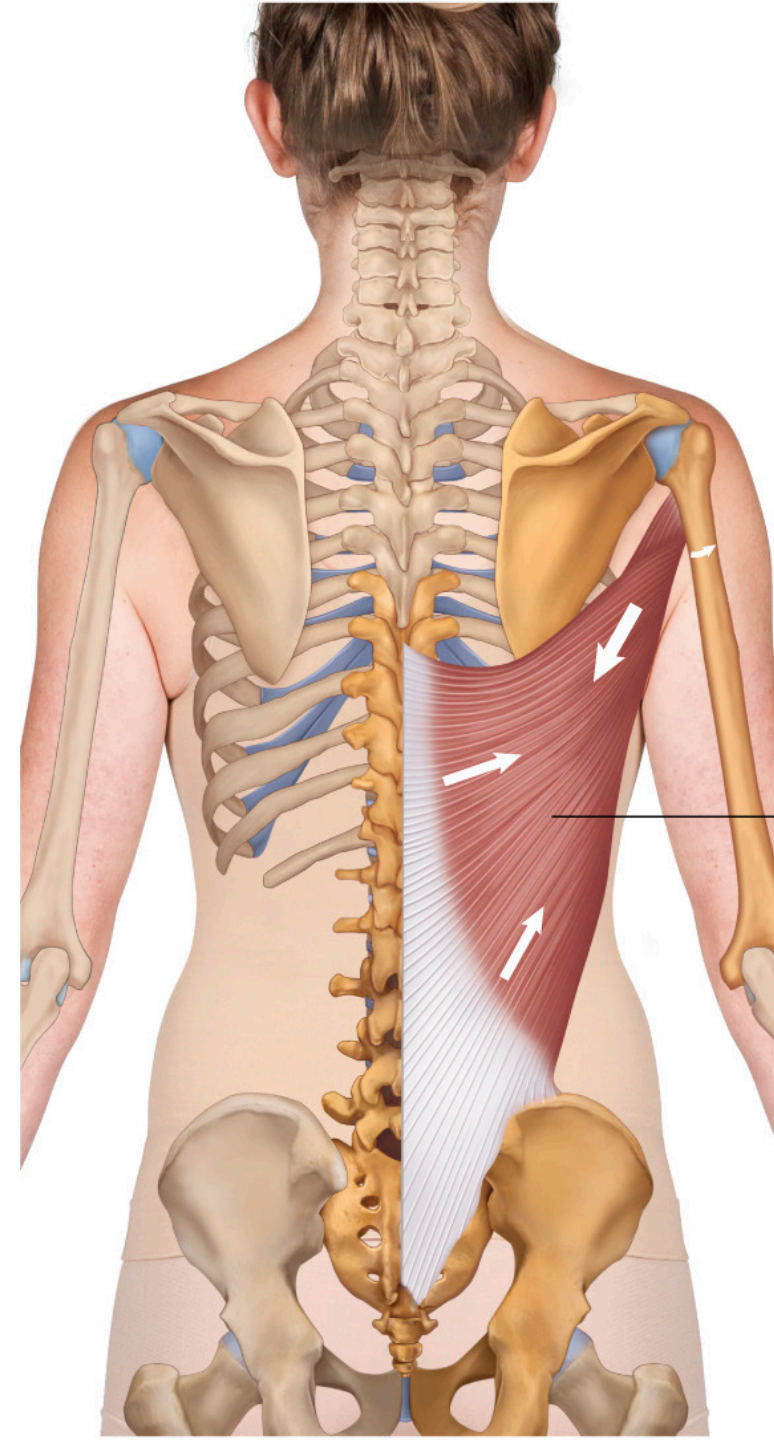
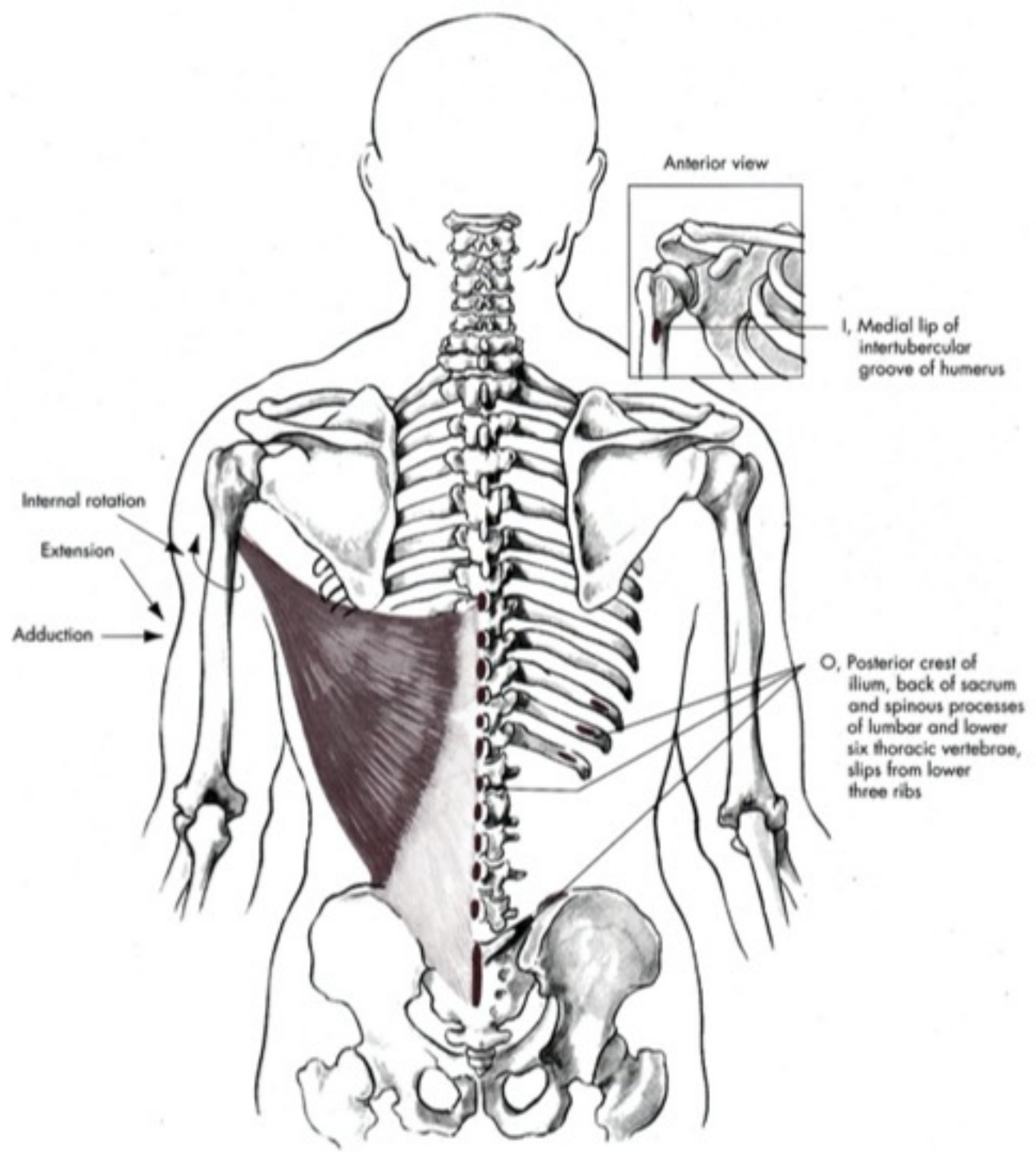
Extenze

- M. deltoideus – pars spinae
- M. latissimus dorsi
- M. teres major

m. Latissimus dorsi

- Z: processus spinosi (Th6-L5), dorsum kosti křížové, crista iliaca, kaudální žebra
- K: crista tuberculi minoris humeri
- I: n. thoracodorsalis
- F: addukce paže, zapažení, vnitřní rotace (přitažení těla k paži – lezení...)

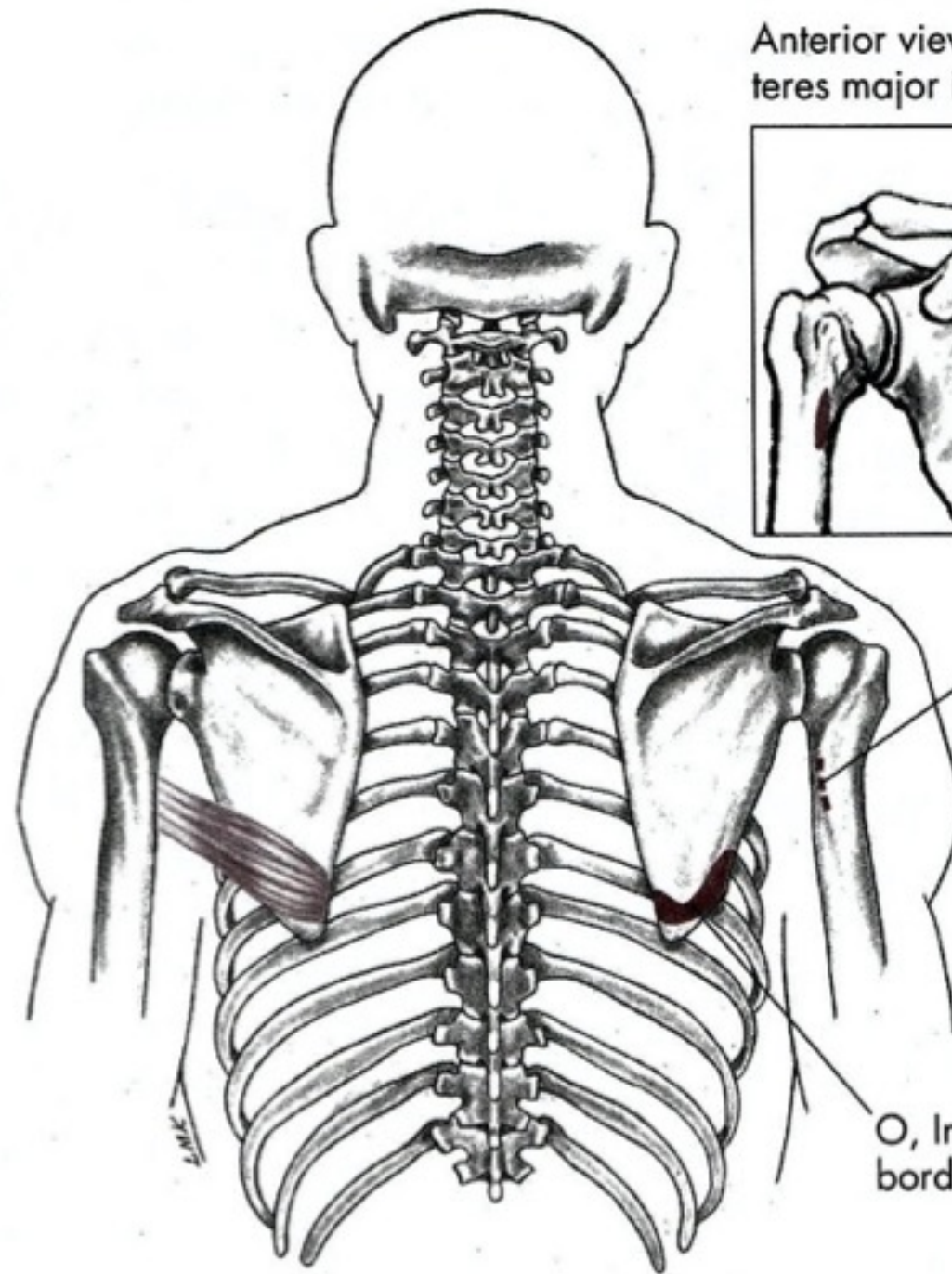
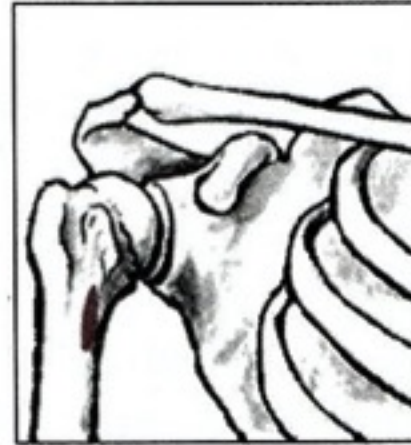



M teres major

- Z: margo lateralis et angulus inferior scapulae
- K: crista tuberculi minoris
- I: n. subscapularis
- F: vnitřní rotace, pomocný při addukci paže

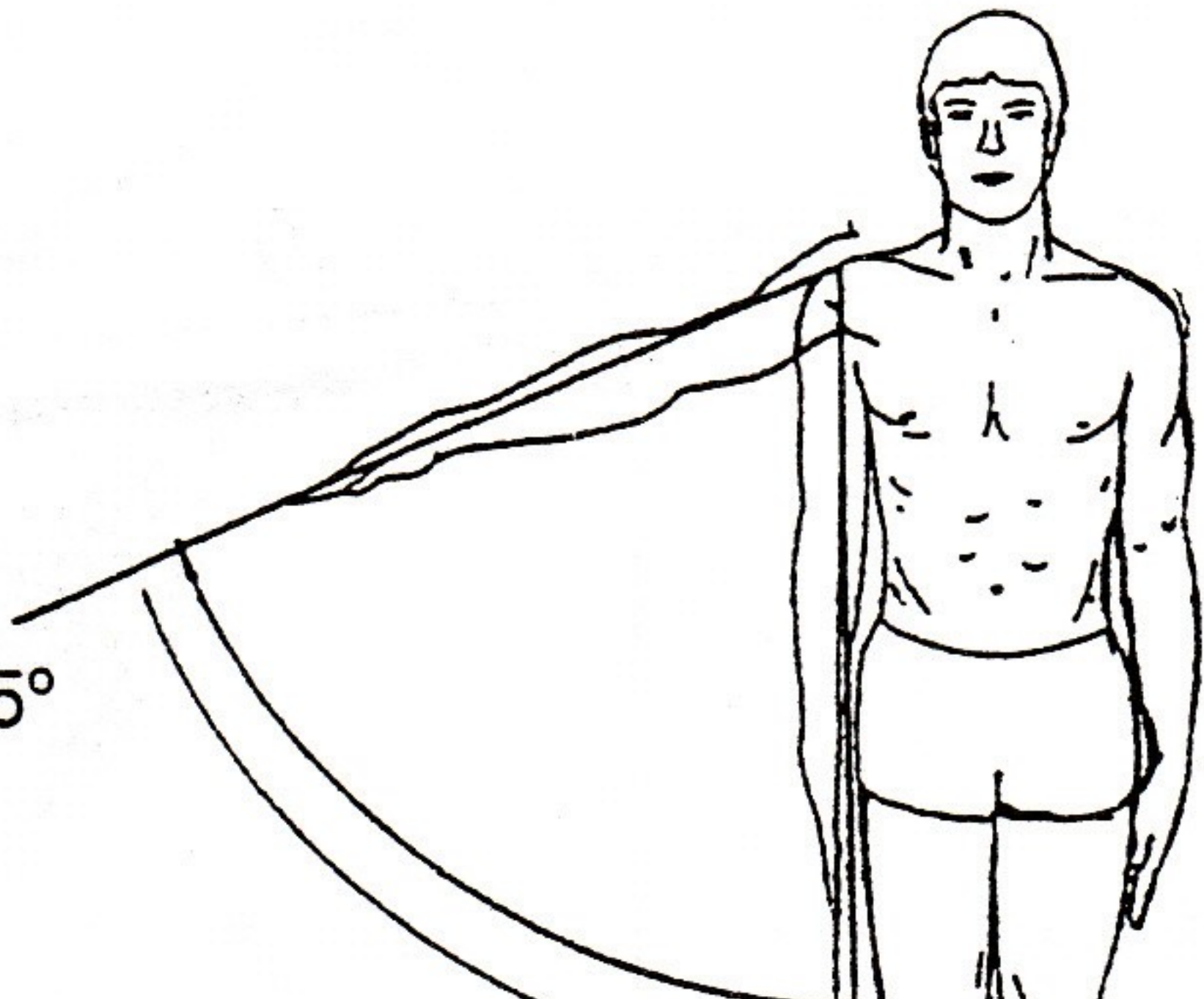
Anterior view with
teres major insertion



I, Medial lip of the
intertubercular groo
of the humerus

O, Inferior third of lateral
border of scapula

64° – 65°

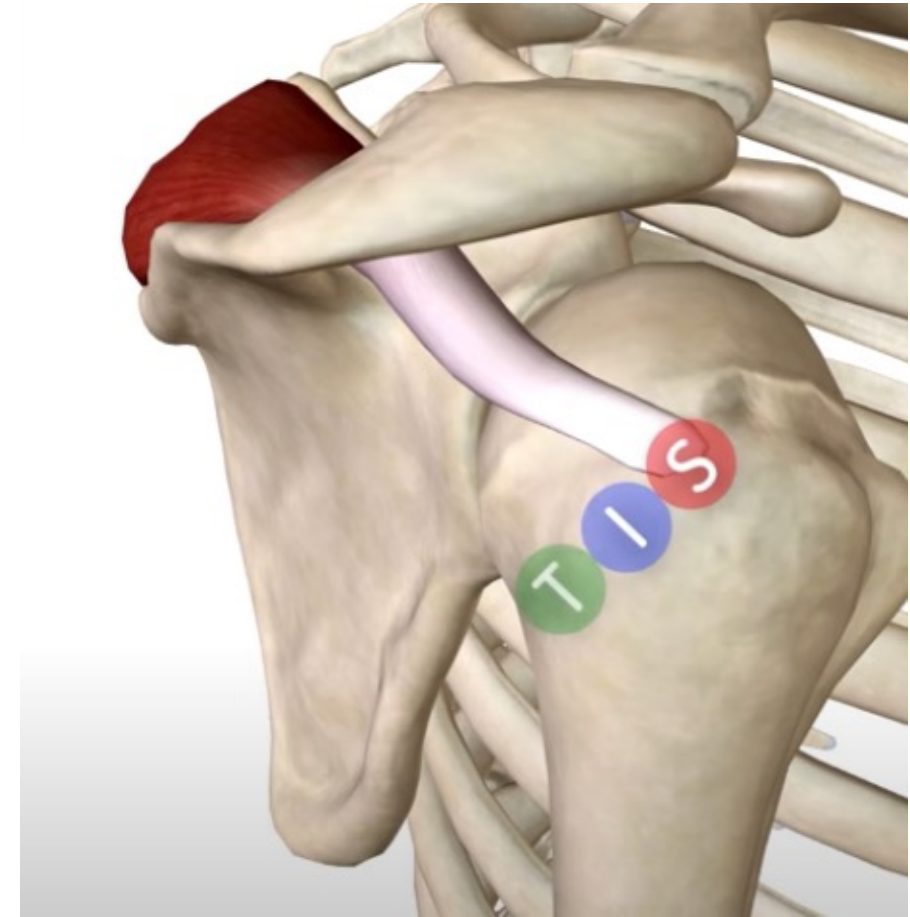


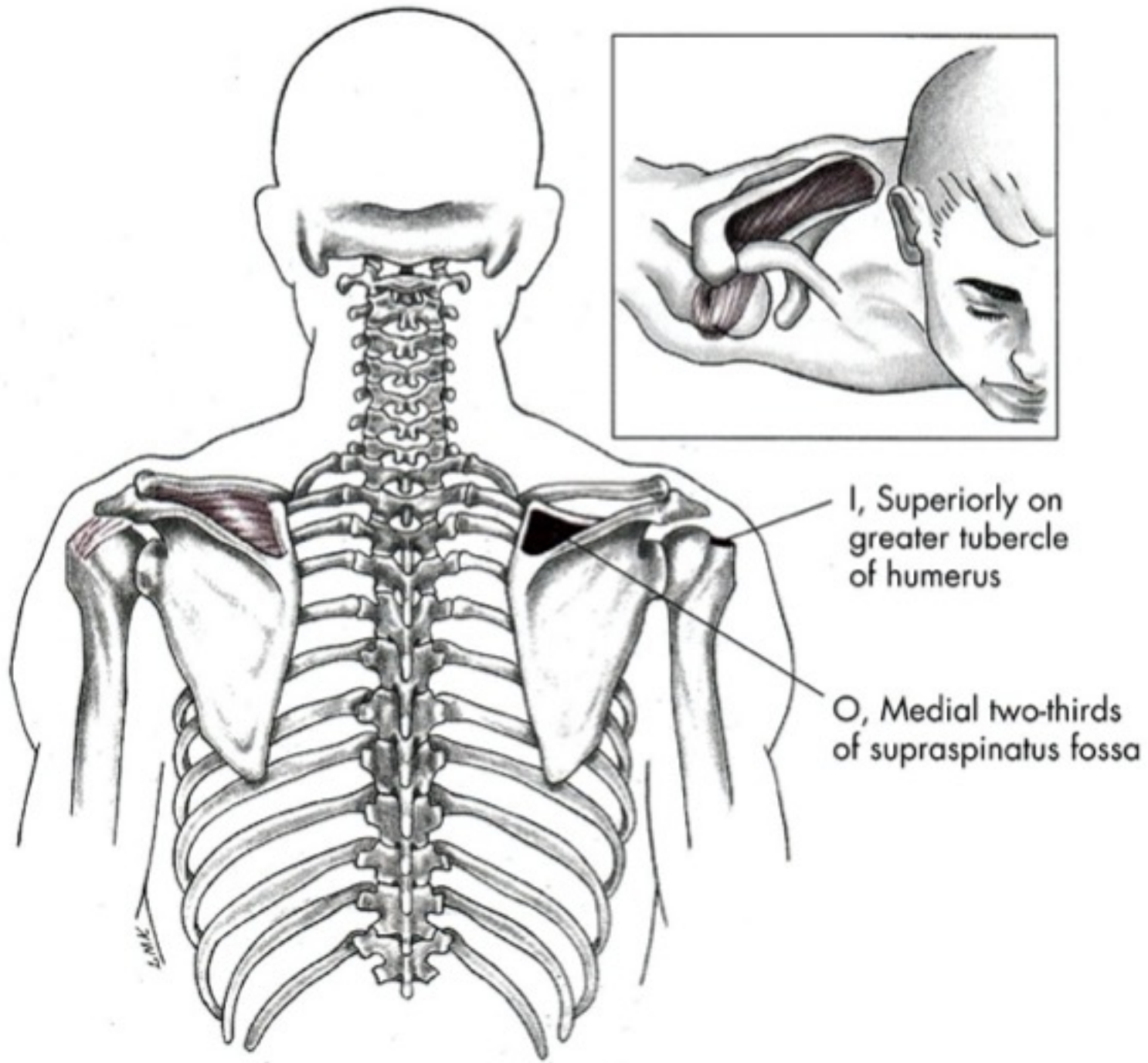
Abdukce

- M. deltoideus – pars akromion
- M. supraspinatus

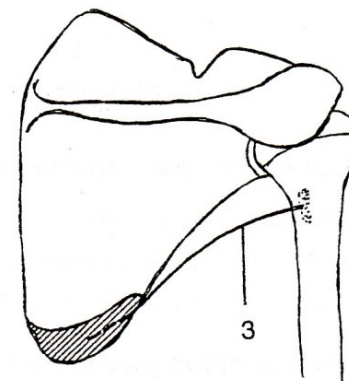
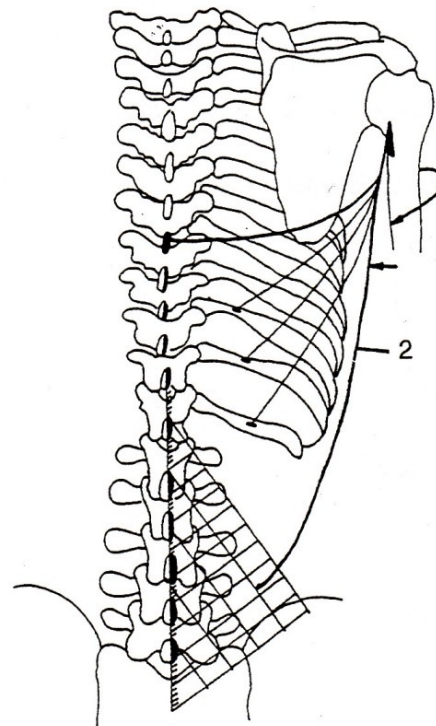
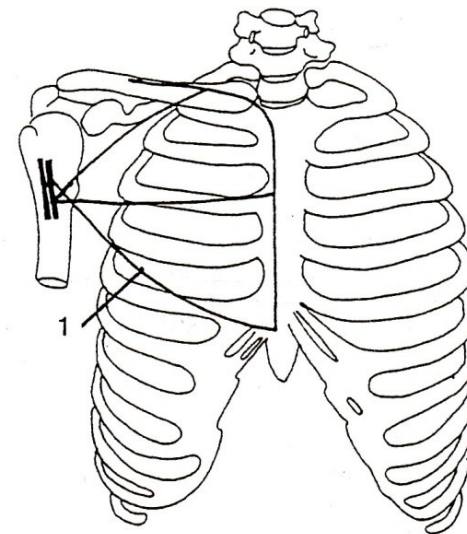
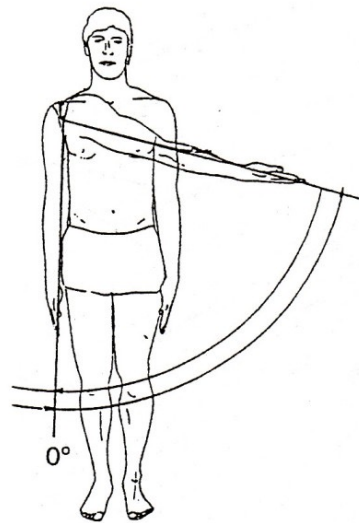
m. supraspinatus

- Z: fossa supraspinata scapulae
- K: tuberculum majus humeri
- I: nervus suprascapularis
- F: začátek abdukce, dynamická stabilizace





Addukce

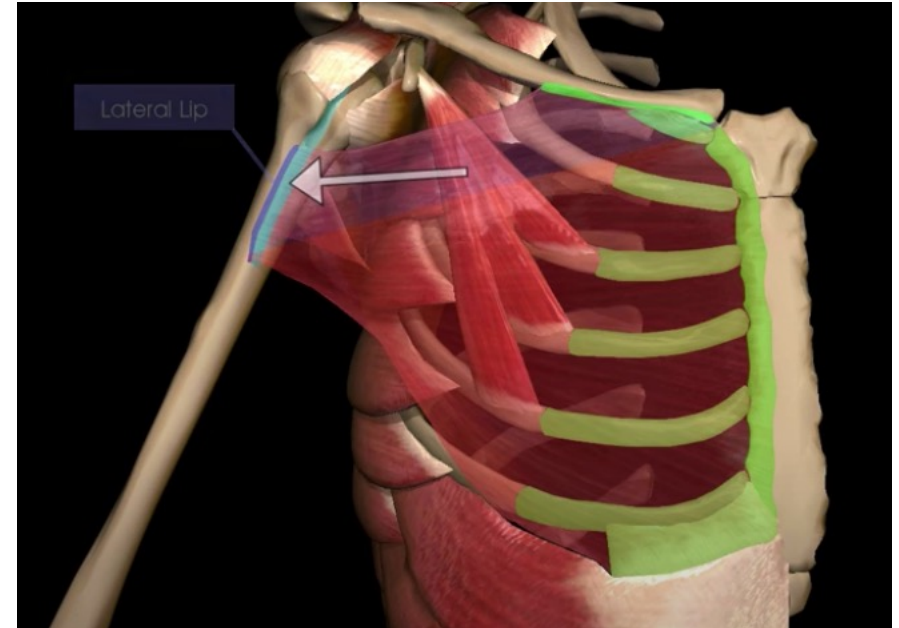


Addukce

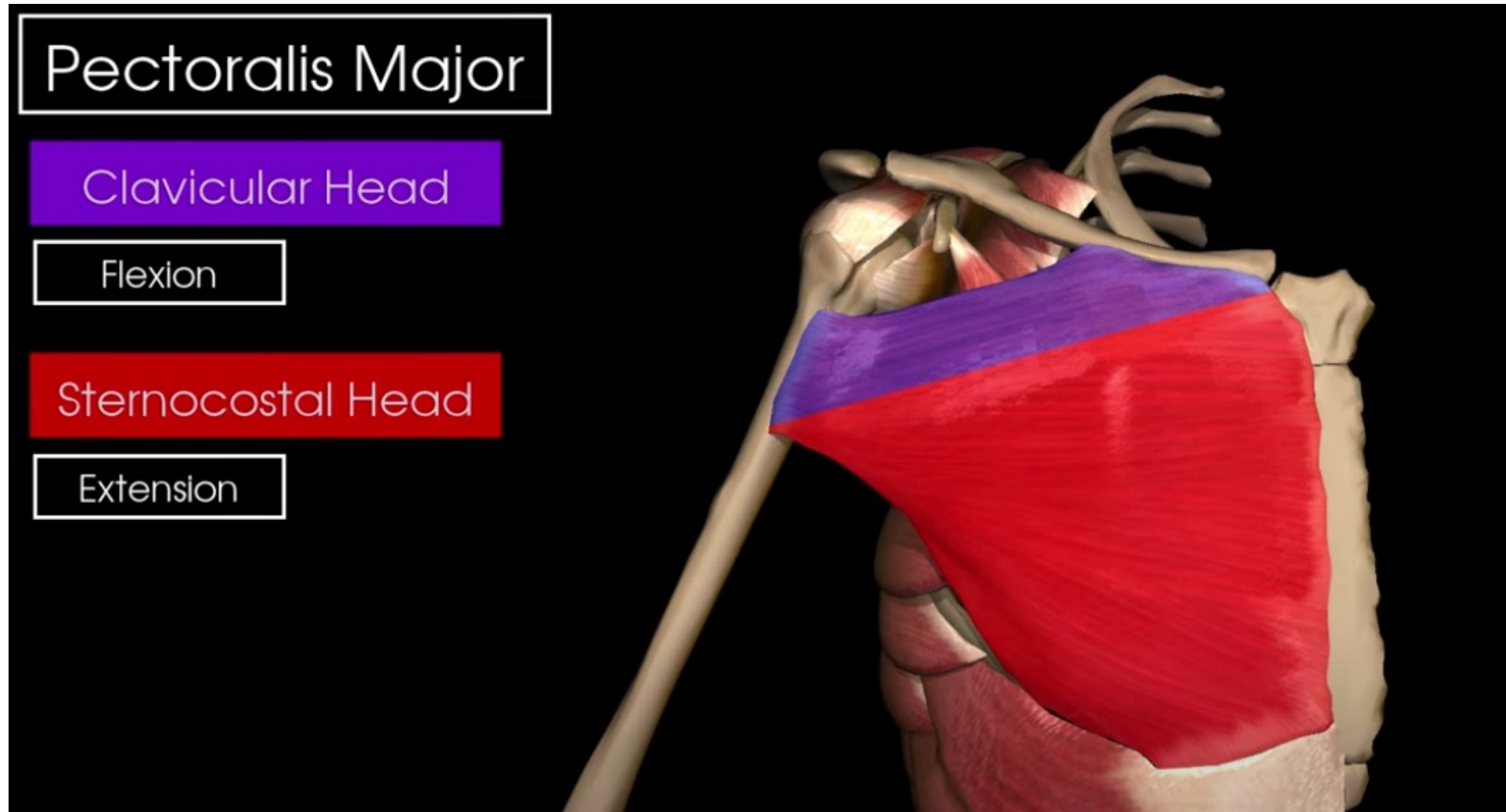
- M. pectoralis major
- M. latissimus dorsi
- M. teres major

m. Pectoralis major

- Z: mediální část klíční kosti, sternum + žebra 1-6, pochva přímého břišního svalu
- K: crista tuberculi majoris humeri
- I: nn. pectorales laterales et mediales
- F (jako celek): pomoc při předpažení, addukce, vnitřní rotace, pomocný nádechový sval



- Extenze zpět z flexe, tedy pouze do roviny

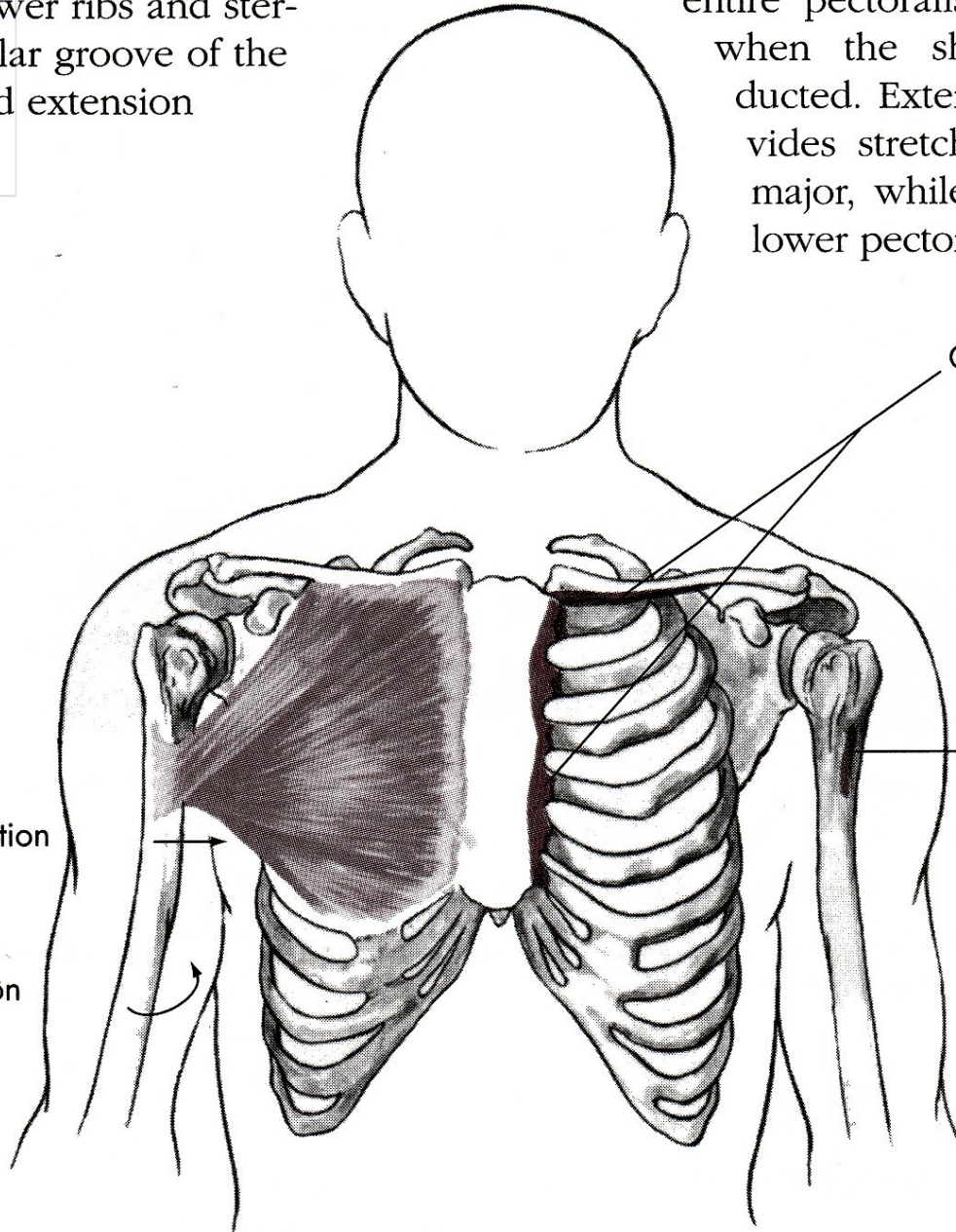


from the lower ribs and sternum to the intertubercular groove of the humerus. It is the primary muscle for adduction and internal rotation of the shoulder. It is also the primary muscle for resisting extension of the arm when the shoulder is in a horizontal position.

entire pectoralis major. It is also stretched when the shoulder is horizontally abducted. Extending the shoulder further stretches the upper part of the pectoralis major, while full abduction stretches the lower part of the pectoralis major.

Pectoralis major
e. O,
insertion.

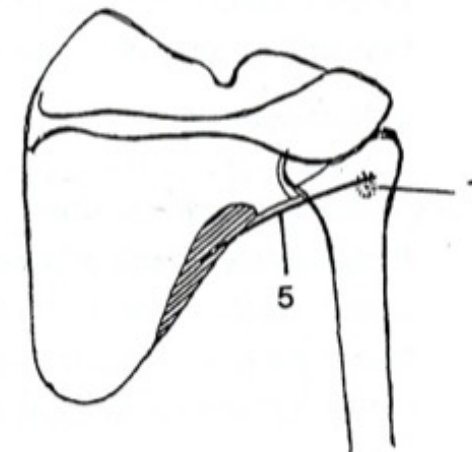
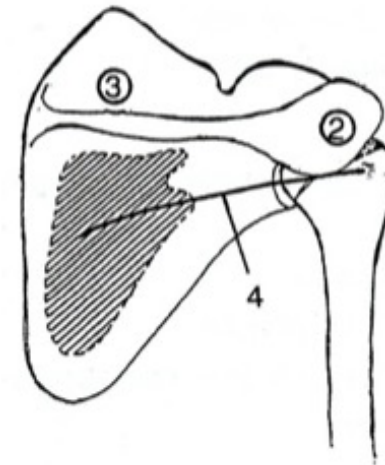
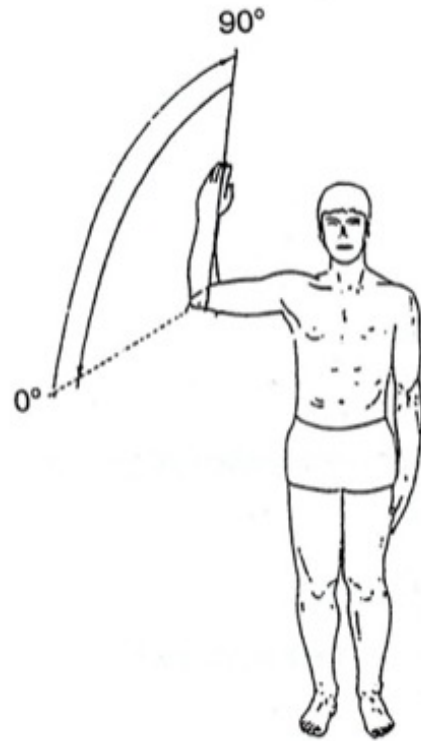
Adduction
Internal rotation



O, Medial half of anterior surface of clavicle, anterior surface of costal cartilages of first six ribs, adjoining portion of sternum

I, Flat tendon 2 or 3 inches wide to outer lip of intertubercular groove of humerus

Vnější rotace

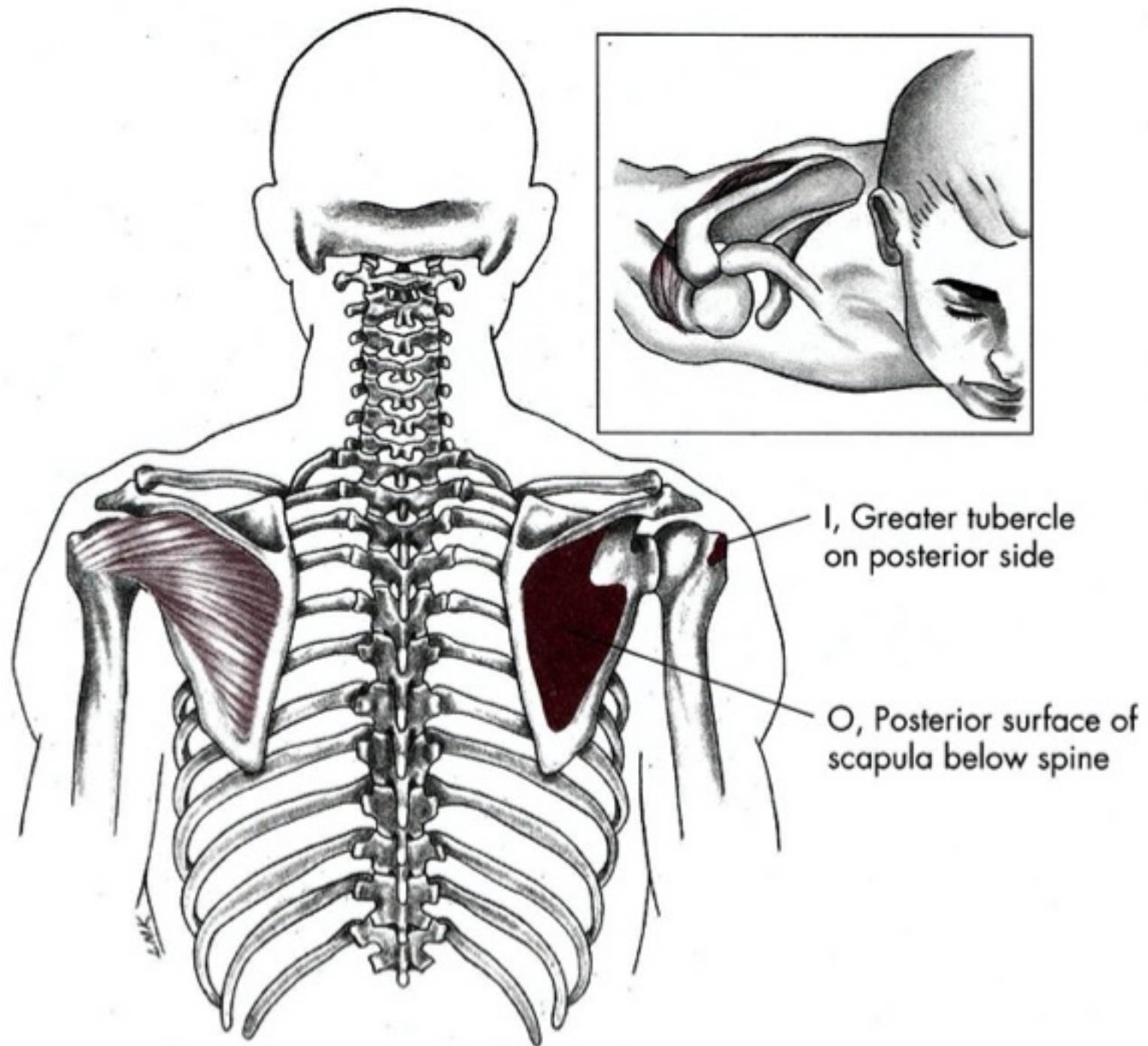


Vnější rotace

- M. infraspinatus
- M. teres minor

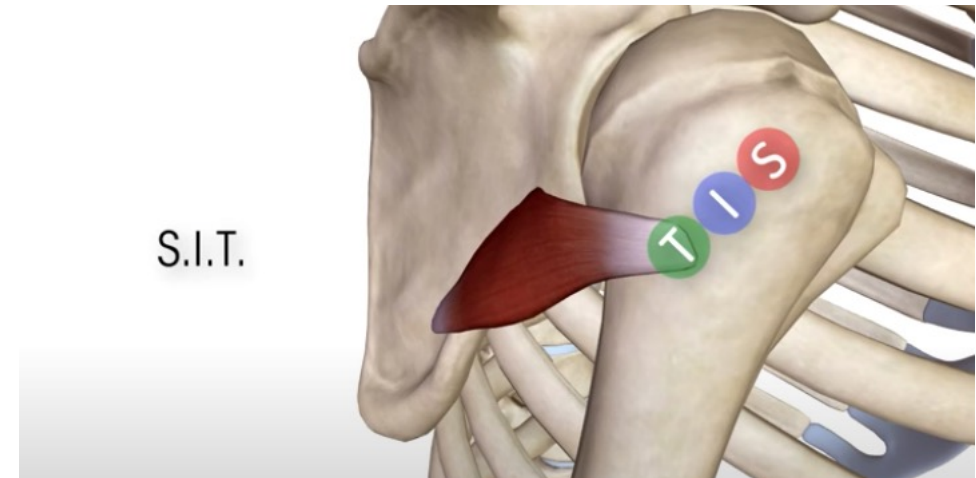
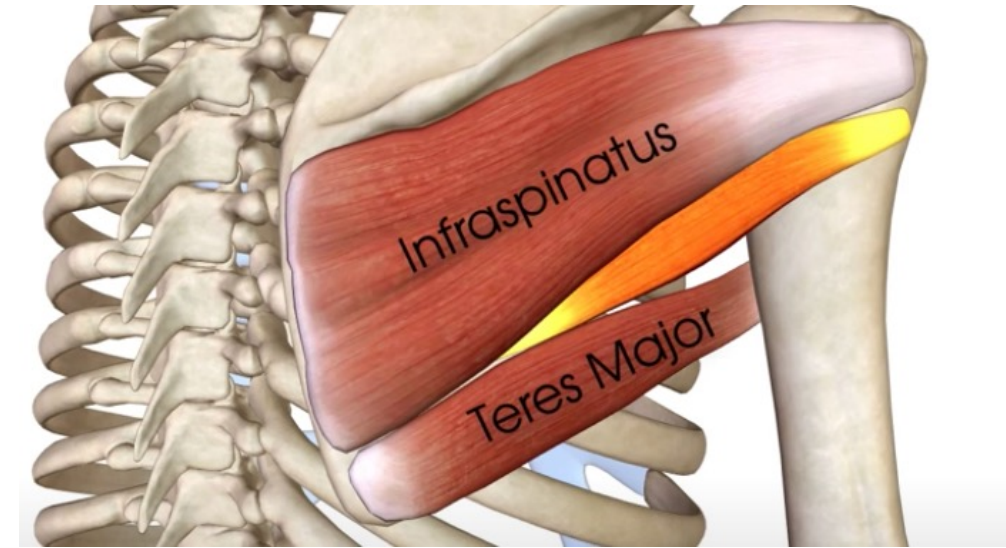
m. infraspinatus

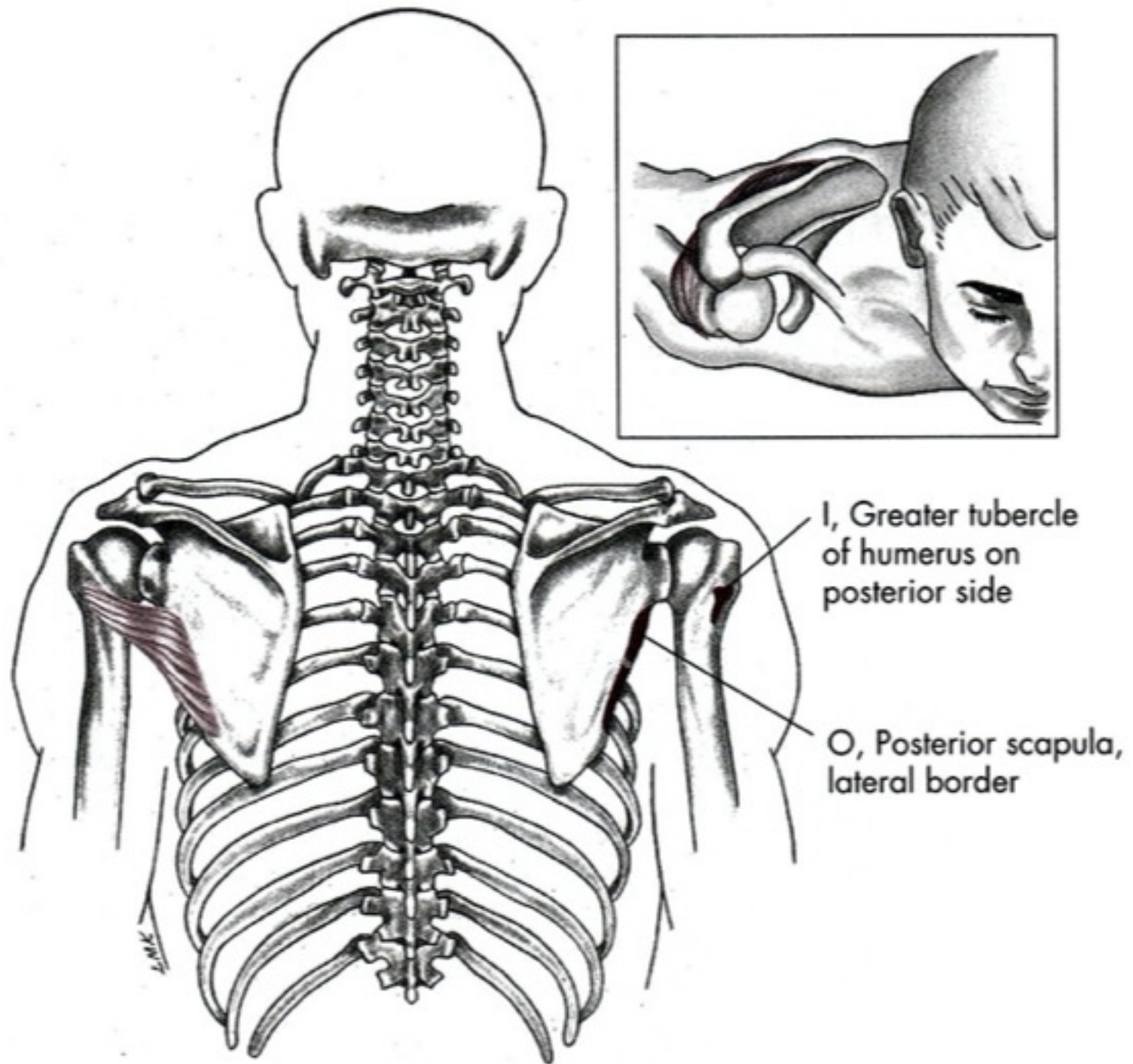
- Z: fossa infraspinata scapulae
- K: tuberculum majus humeri
- I: nervus suprascapularis
- F: zevní rotace paže, dynamická stabilizace ramene



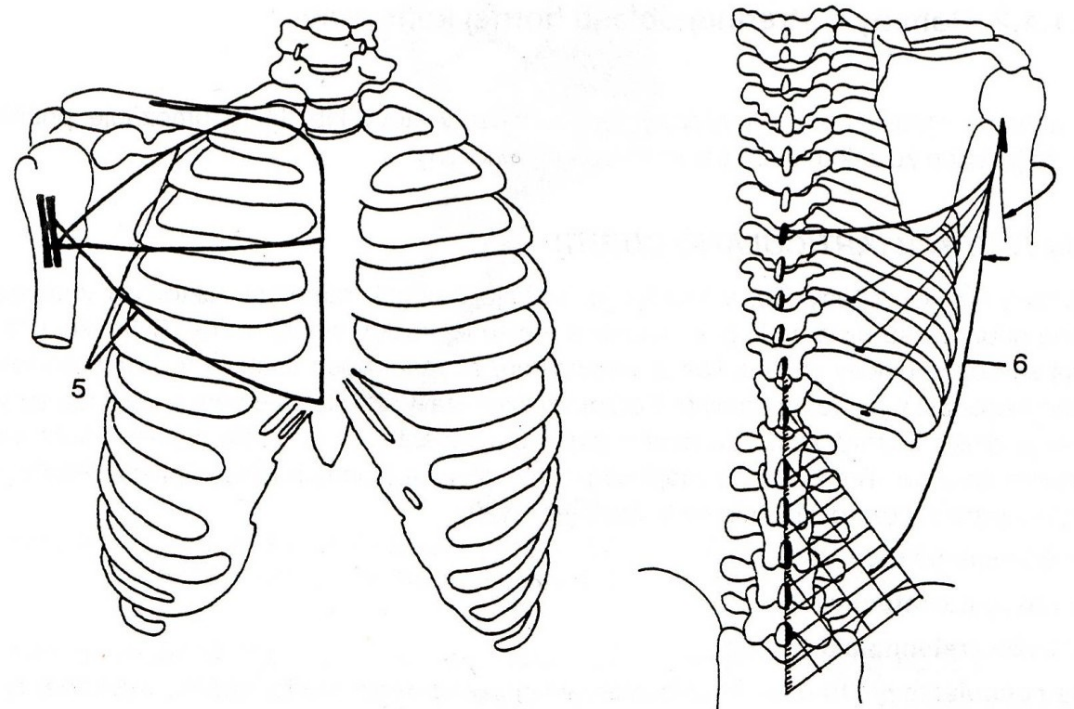
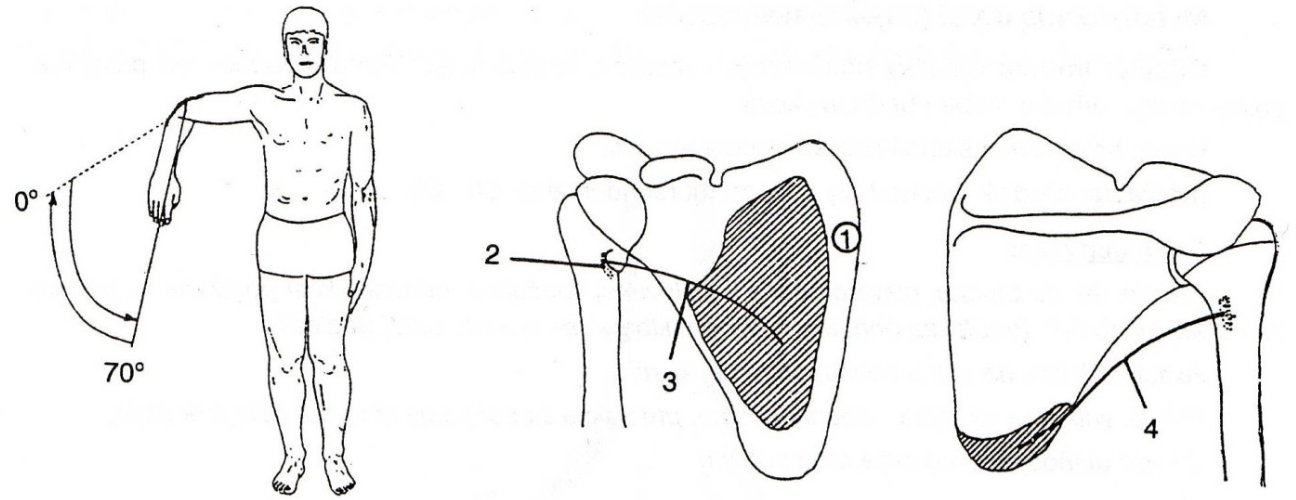
m. Teres minor

- Z: margo lateralis scapulae
- K: tuberculum majus humeri
- I: nervus axillaris
- F: zevní rotace ramenního kloubu, dynamická stabilizace





Vnitřní rotace

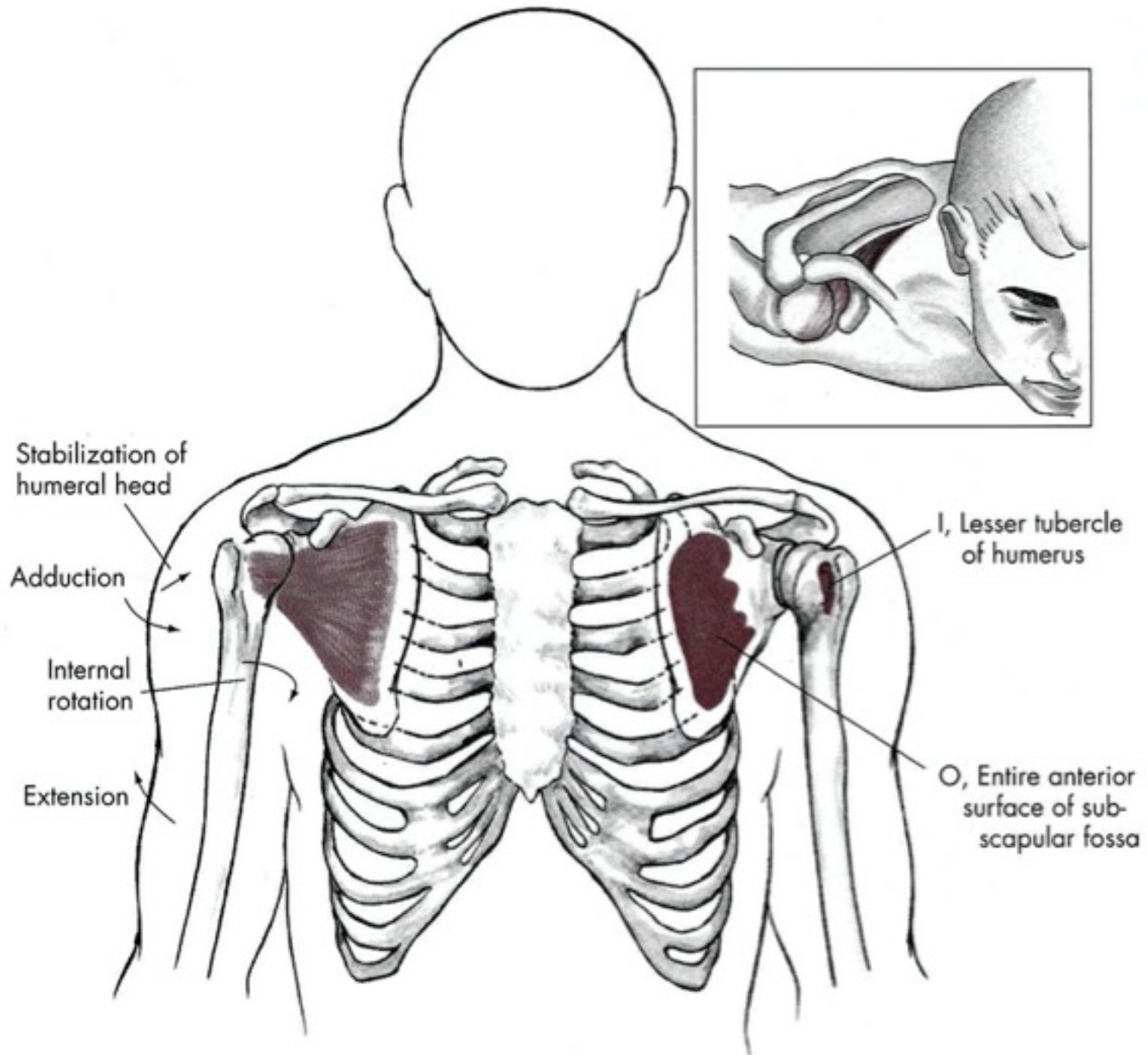


Vnitřní rotace

- M. subscapularis
- M. teres major
- M. pectoralis major
- M. latissimus dorsi

m. subscapularis

- Z: facies anterior scapulae
- K: tuberculum minus humeri
- I: nervus subscapularis
- F: vnitřní rotace paže, dynamická stabilizace



Děkuji za pozornost