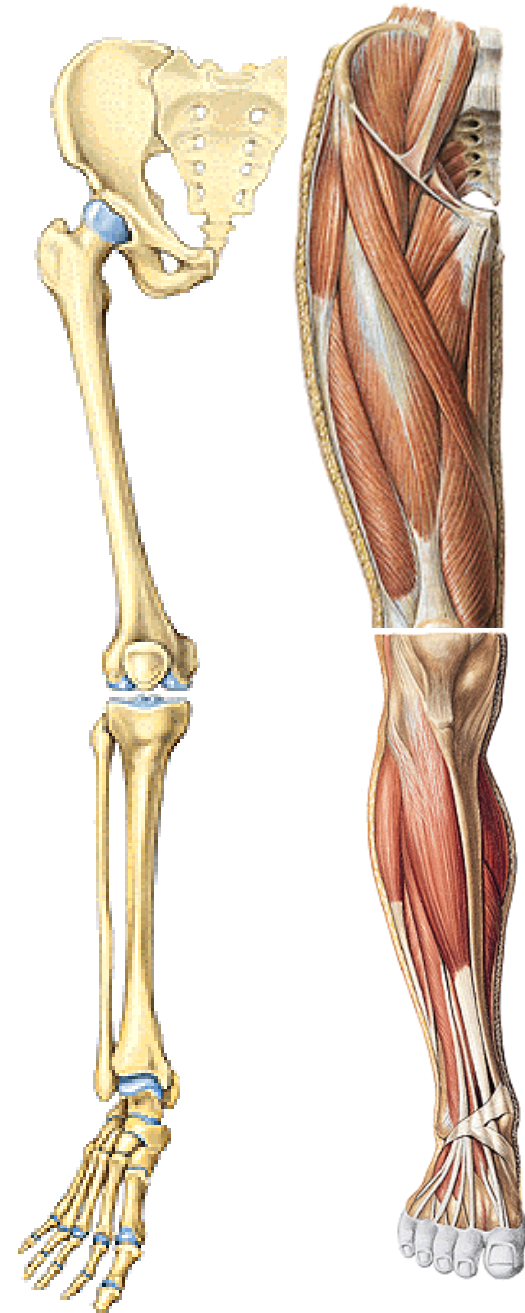


KOSTRA DOLNÍ KONČETINY

(ossa membri inferioris)

Kostra dolní končetiny

- **orgán opory, lokomoce, ochrany vnitřních orgánů**
- **robustnější kosti a silnější svaly než HK**
- **omezený rozsah pohyblivosti**
- **vertikalizace** postavy – těžiště u **S₂** (sklon pánve)
- **pánev tvoří s páteří funkční jednotku** (transmisní systém)
- největší vývojové **změny DK - na noze**



Skelet pánevního pletence

Cingulum membri inferioris

Kost pánevní – *os coxae*
(*os ilium, os ischii, os pubis*)

Skelet volné dolní končetiny

Ossa membri inferioris liberi

Stehno

Stehenní kost – *femur*

Češka – *patella*

Bérec

Holenní kost – *tibia*

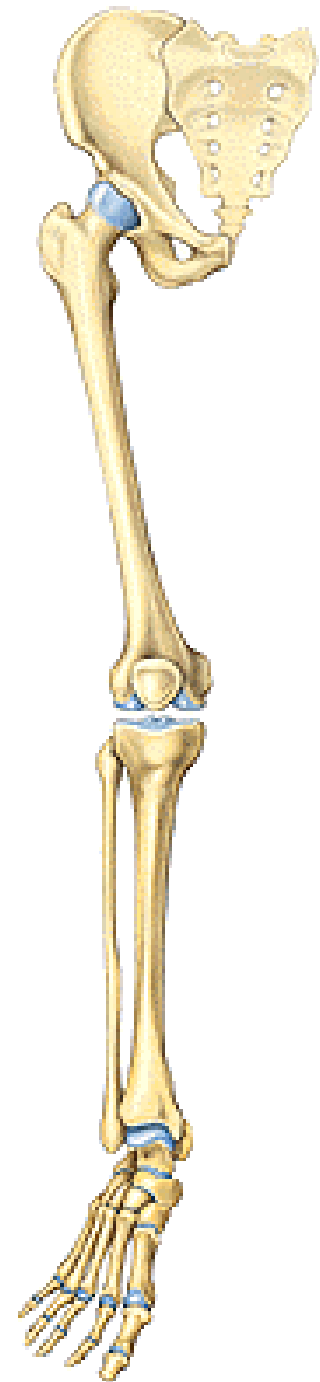
Lýtková kost – *fibula*

Kostra nohy

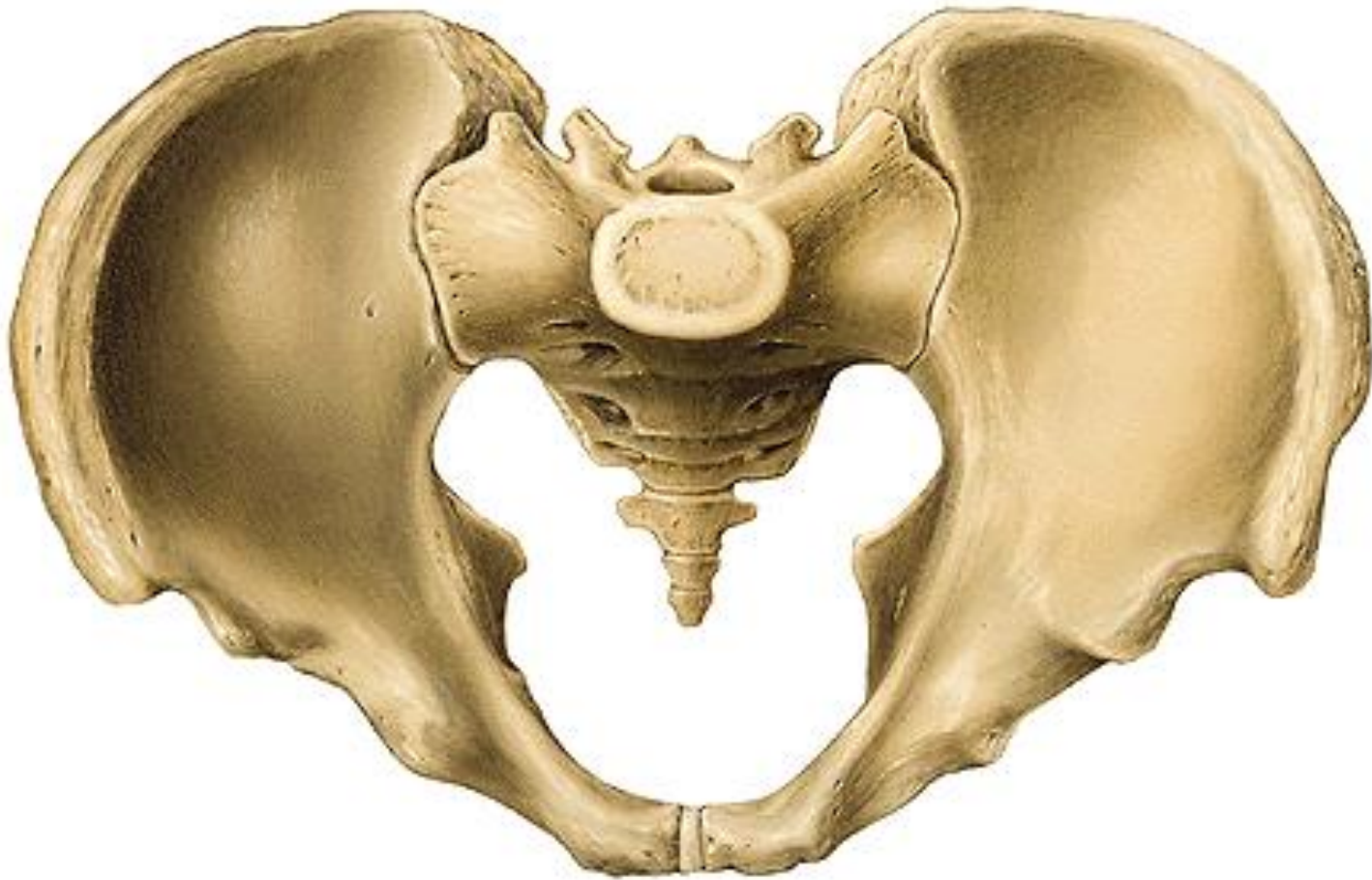Zánártní kosti – *ossa tarsi*

Nártní kosti – *ossa metatarsi*

Kosti prstů nohy (*ossa digitorum pedis – phalanges*)



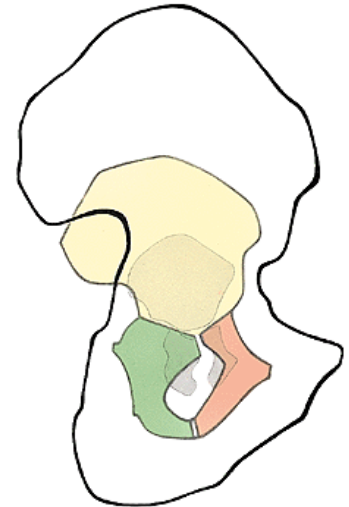
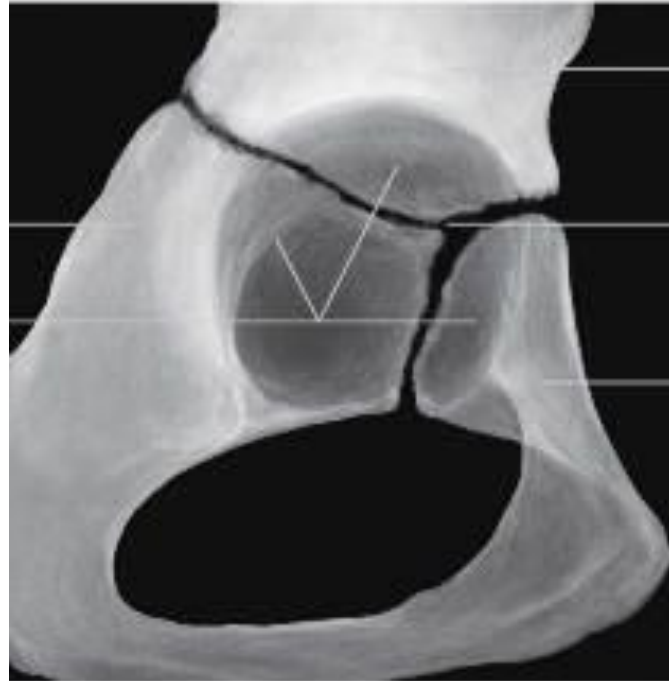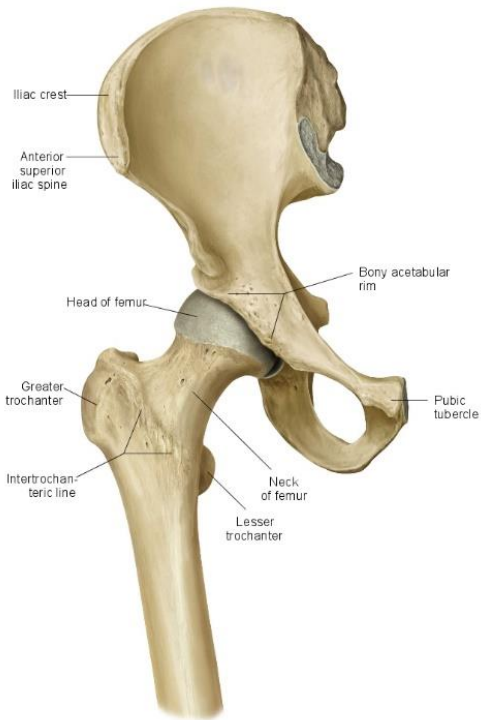
Cingulum membri inferioris



Os coxae

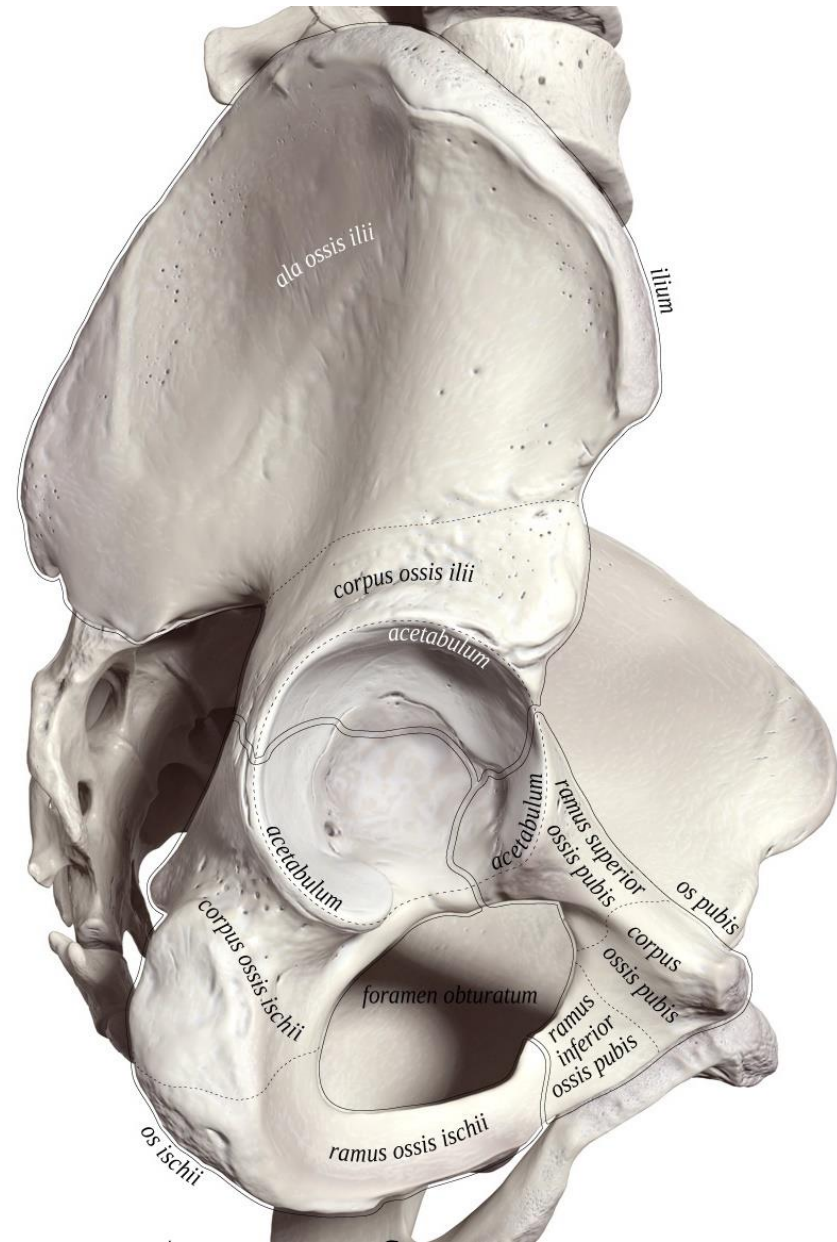
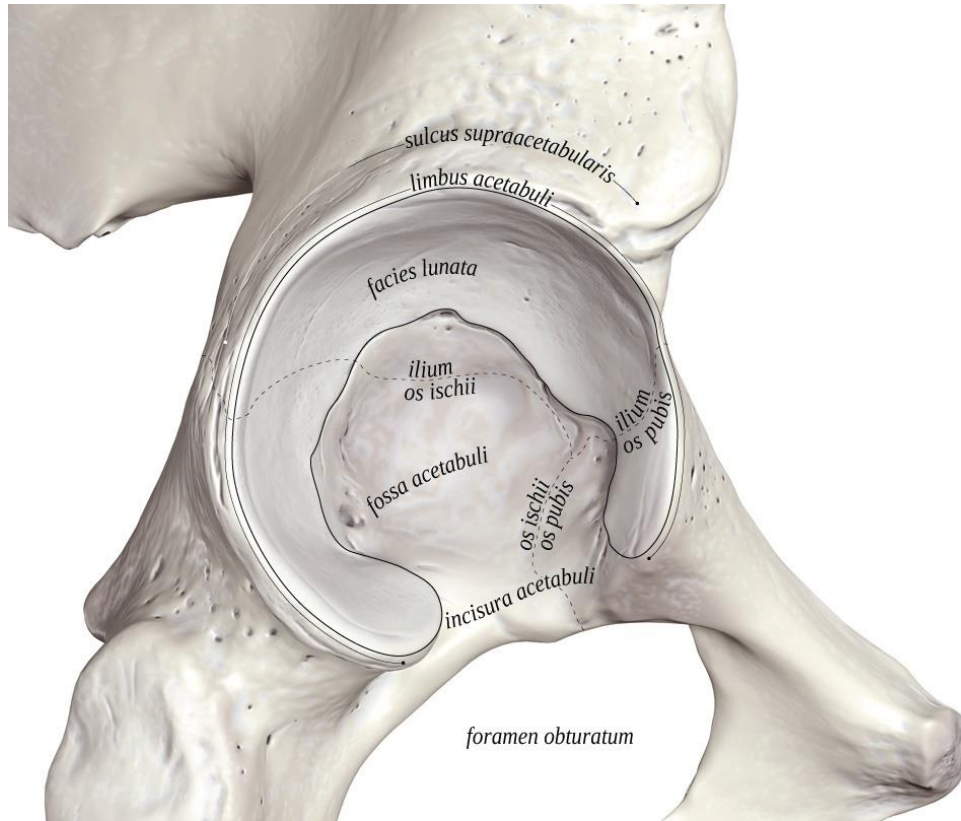
os ilium, os pubis, os ischii

plochá kost – vývojově srůstá ze 3 kostí v kloubní jamce mezi 16. – 20. rokem



acetabulum
facies lunata
fossa acetabuli
incisura acetabuli

foramen obturatum



Os ilium (kyčelní kost)

1) *corpus*

2) *ala*

- mediální plocha zevnitř

fossa iliaca

facies auricularis

tuberositas iliaca

linea arcuata

crista iliaca

labium externum

linea intermedia

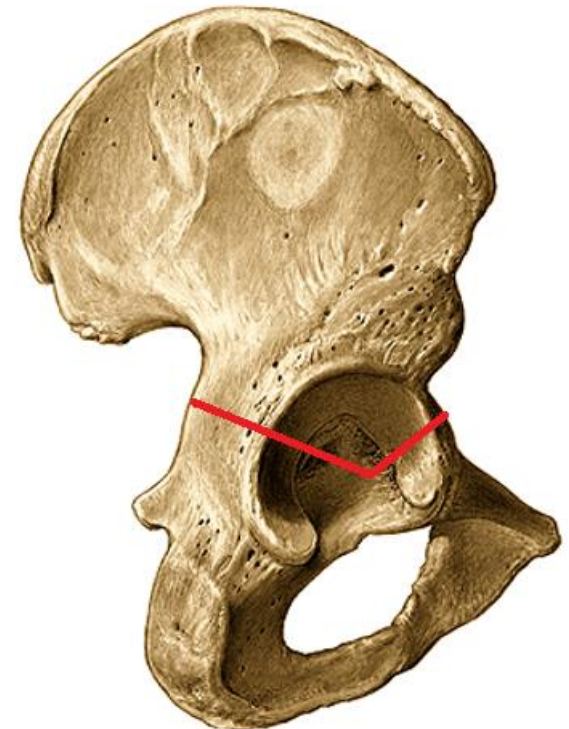
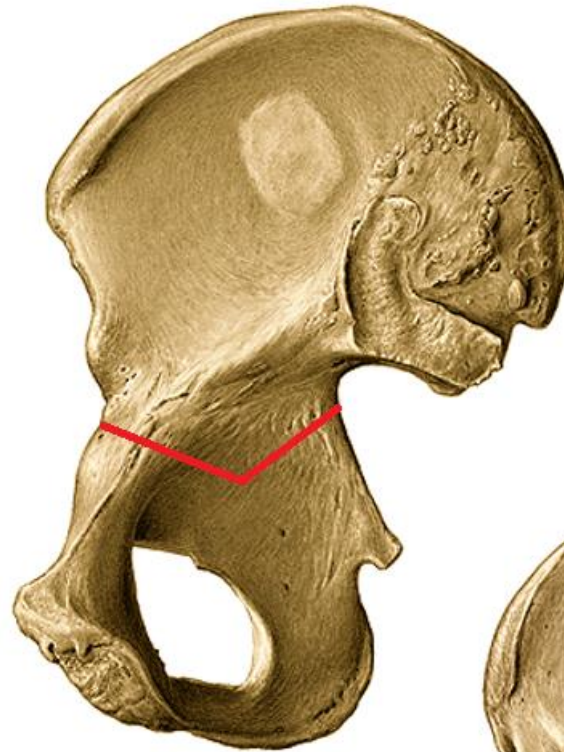
labium internum

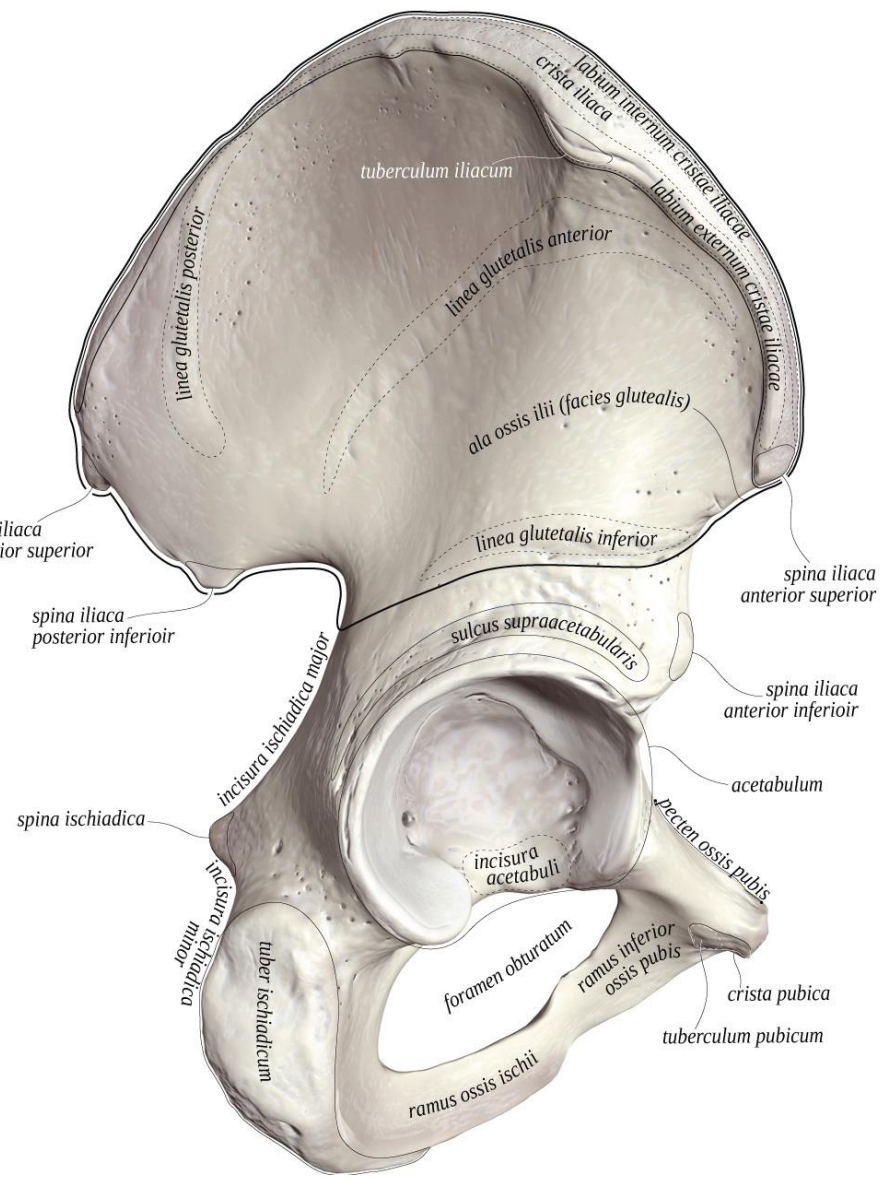
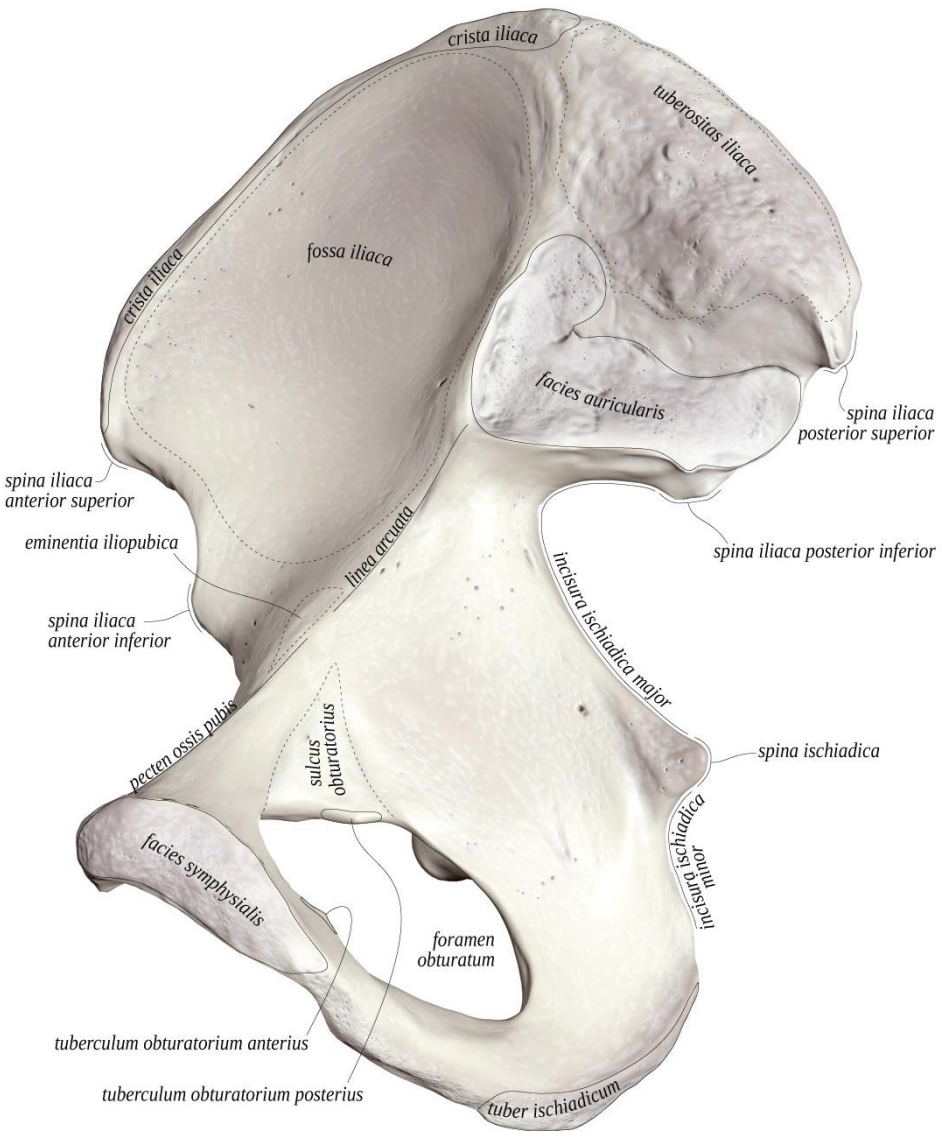
spina iliaca anterior superior et inferior


spina iliaca posterior superior et inferior

- laterální plocha zevní

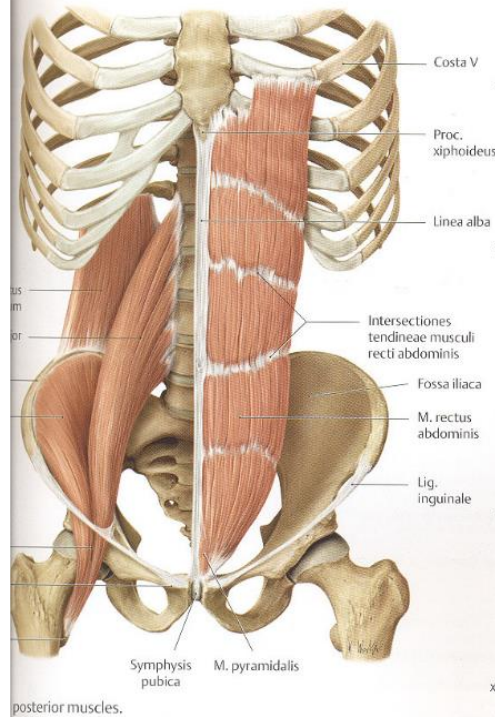
lineae glutaeae posterior, anterior et inferior



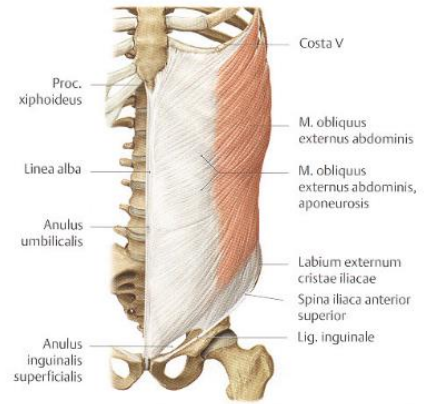




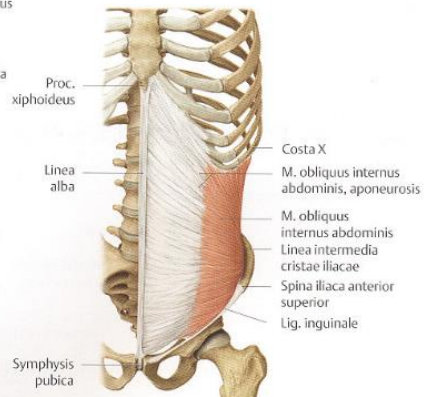
anterior and posterior wall muscles



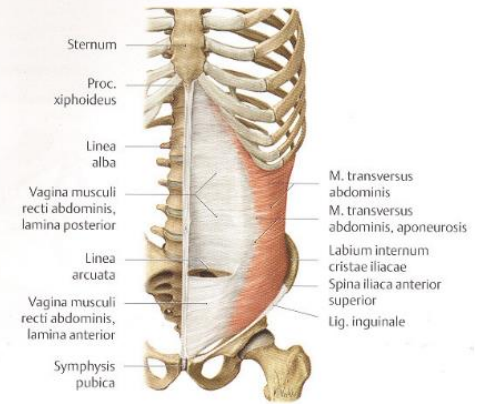
posterior muscles.



B M. obliquus externus abdominis.



C M. obliquus internus abdominis.



D M. transversus abdominis.

Os ischii (sedací kost)

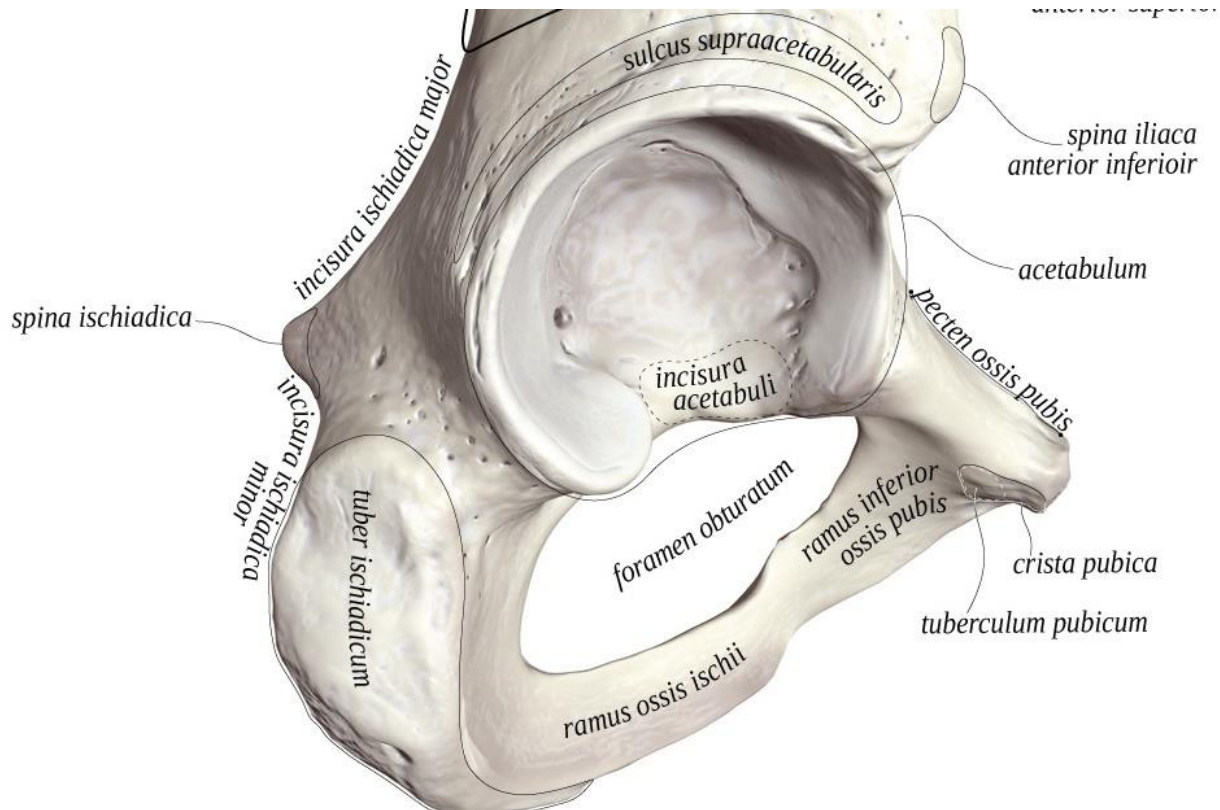
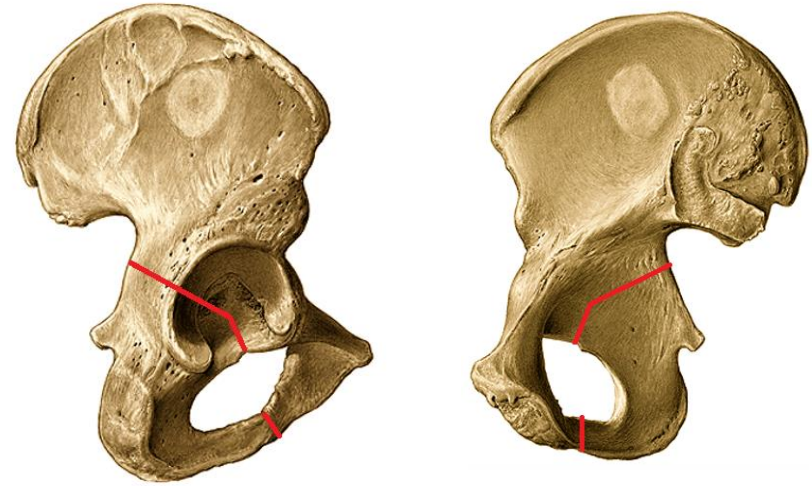
corpus

ramus ossis ischii

tuber ischiadicum

spina ischiadica

incisura ischiadica major et minor



Os pubis (stydká kost)

corpus

ramus superior

eminentia iliopubica

pecten ossis pubis

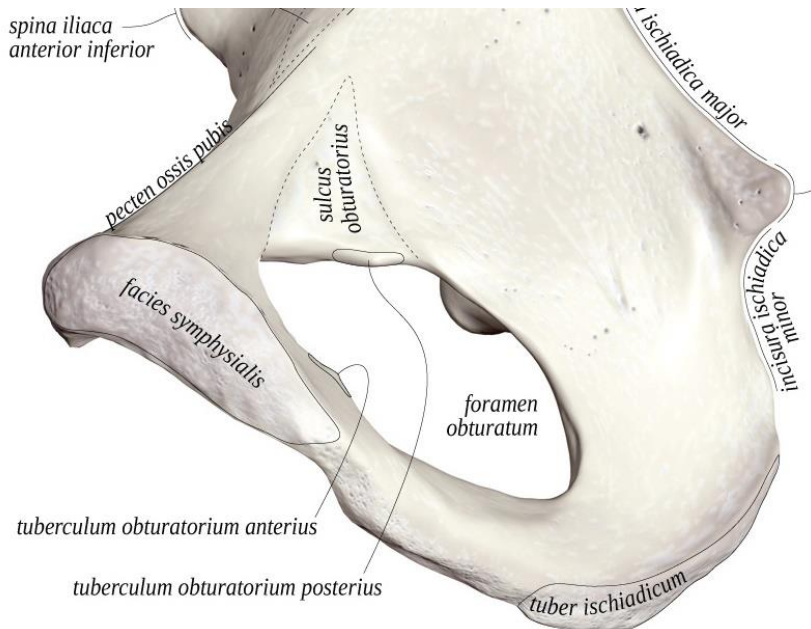
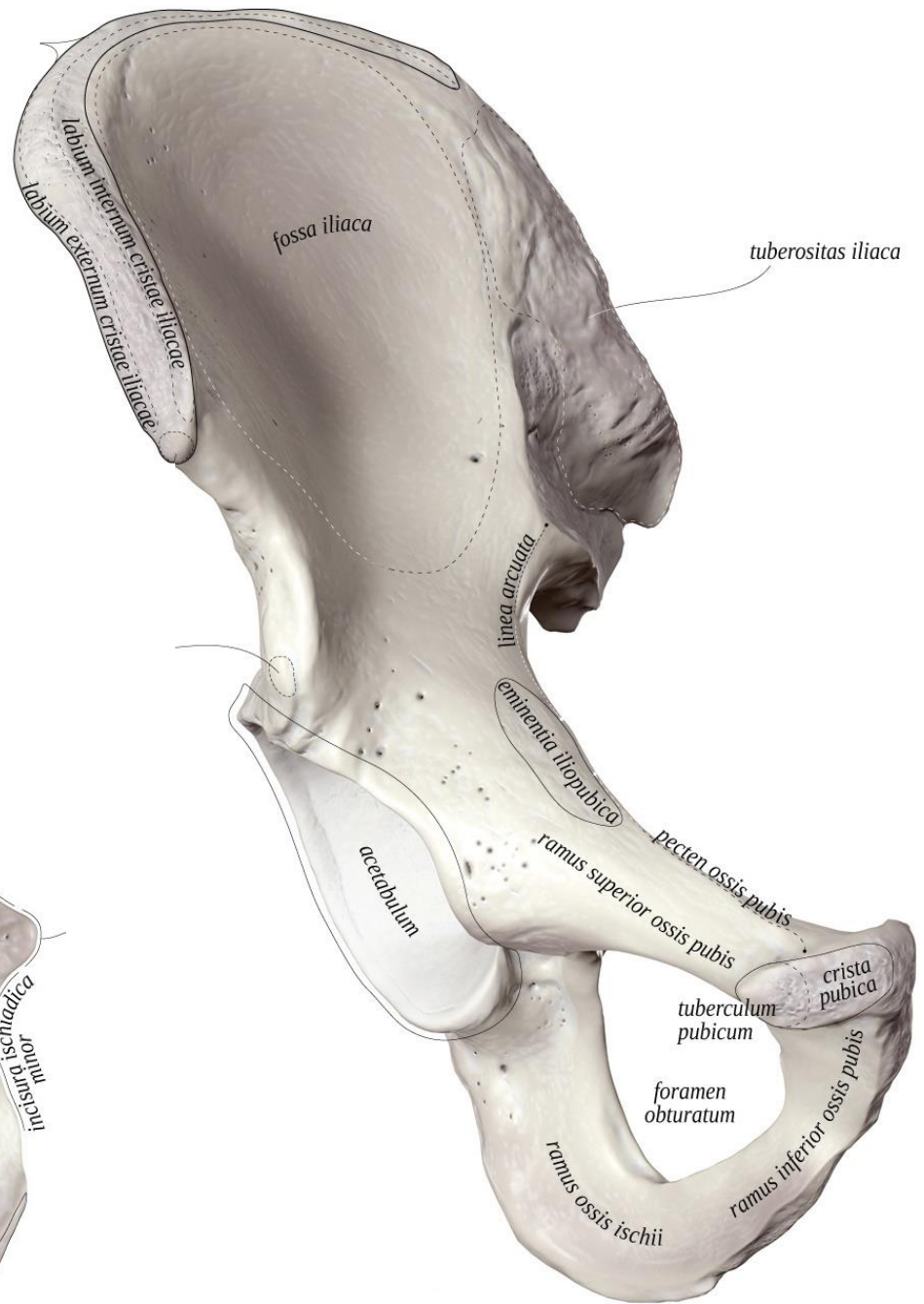
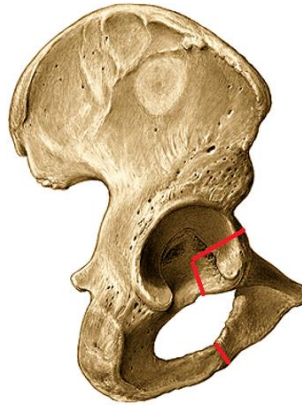
tuberculum pubicum

sulcus obturatorius

ramus inferior

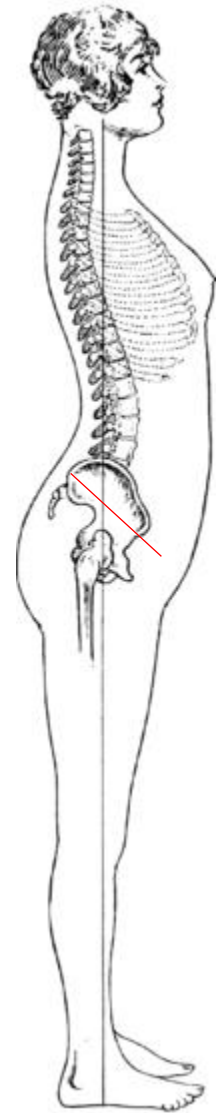
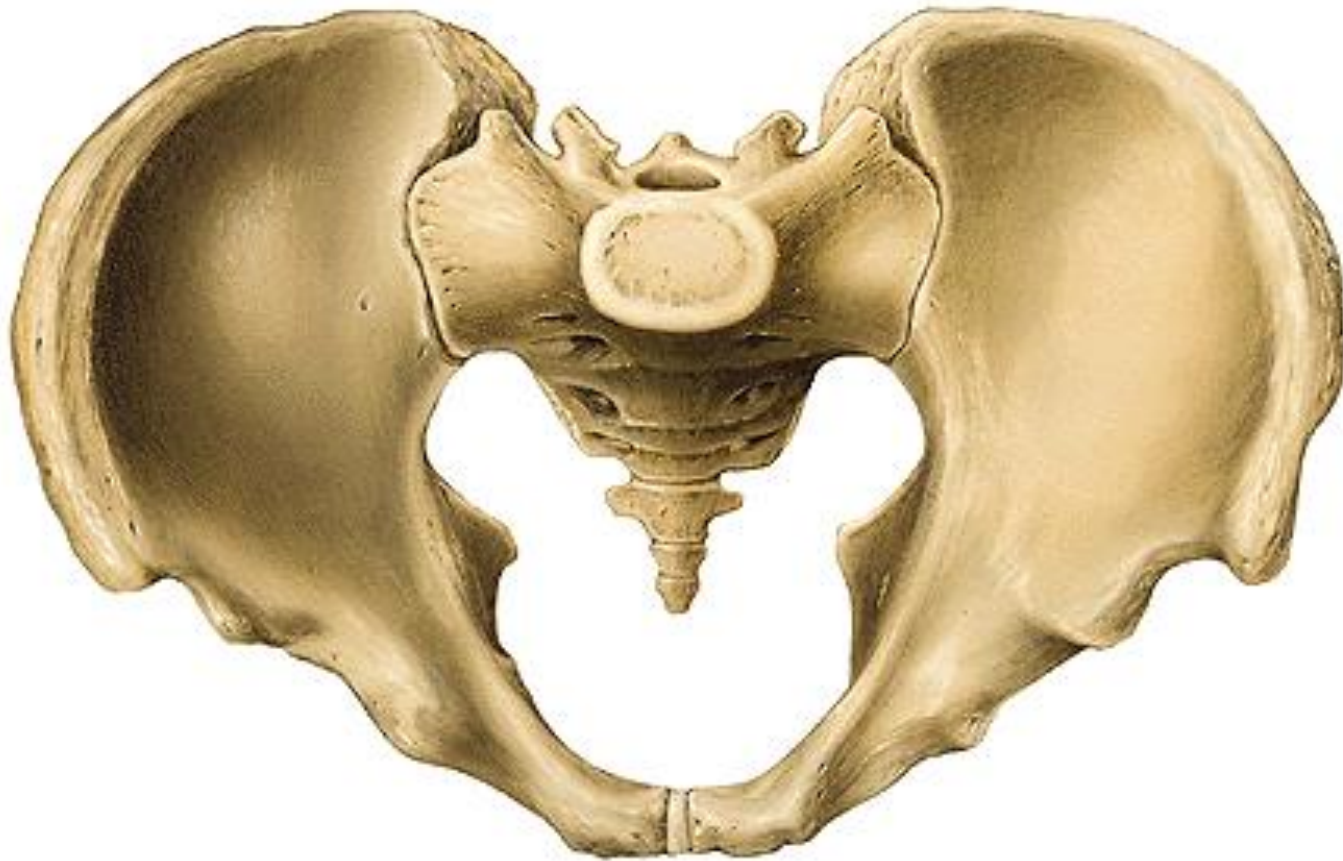facies symphyialis


crista phallica



Pánev (*pelvis*)

Sklon pánve = inclinatio pelvis 60° = úhel roviny vchodu pánevního s horizontální rovinou, důležitý pro vzpřímenou chůzi





■ FIGURE 7.42 Finding the crest of the ilium.



■ FIGURE 7.43 Locating the posterior superior iliac spine.

Femur – stehenní kost

proximální konec

caput femoris

fovea capitis femoris

collum femoris (uvnitř *calcar femorale*)

mezi proximálním koncem a tělem

trochanter major et minor

linea intertrochanterica

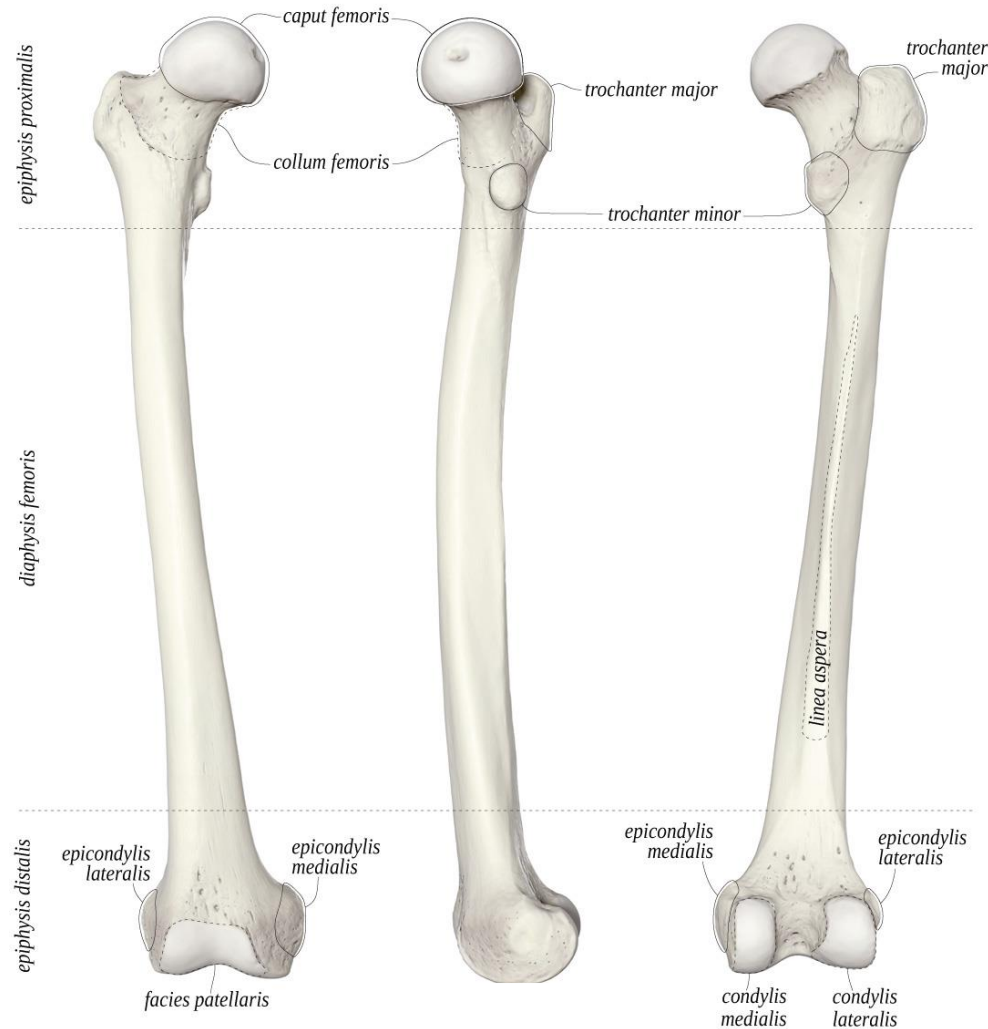
crista intertrochanterica

fossa trochanterica

corpus femoris

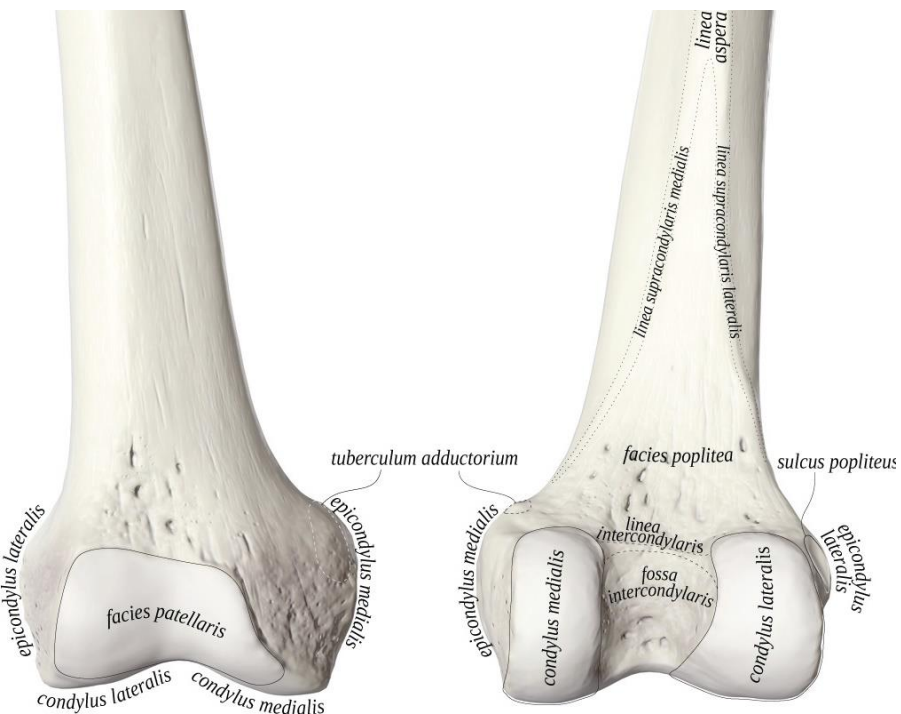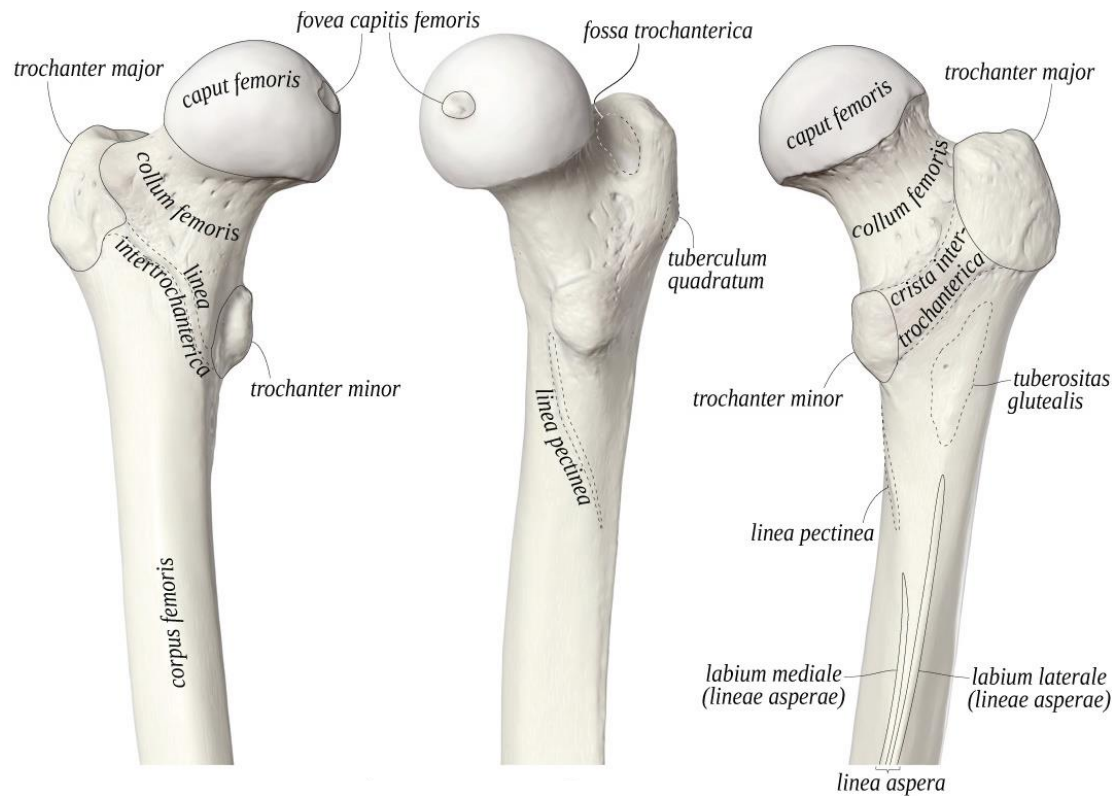
linea aspera – *labium mediale* (*linea pectinea*) et *laterale* (*tuberositas glutea*)

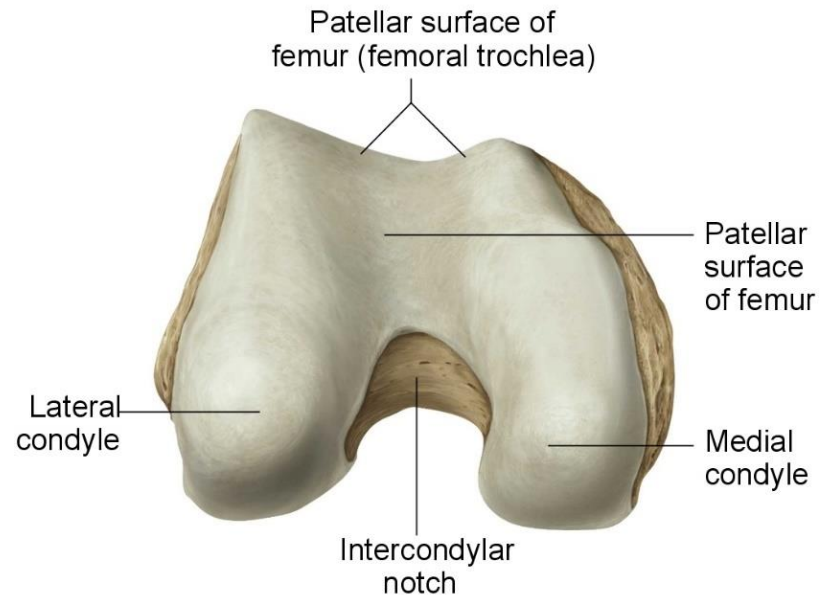
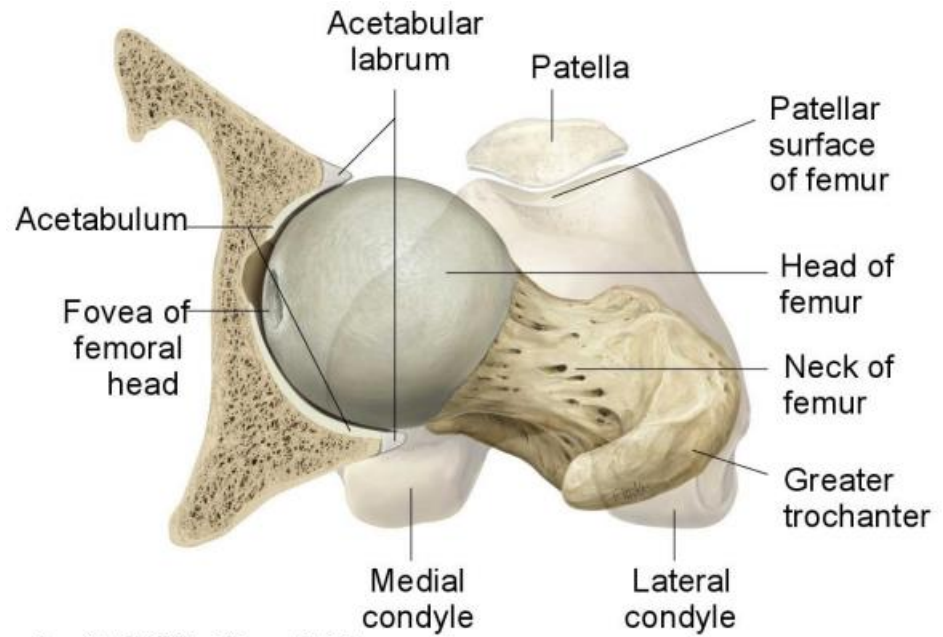
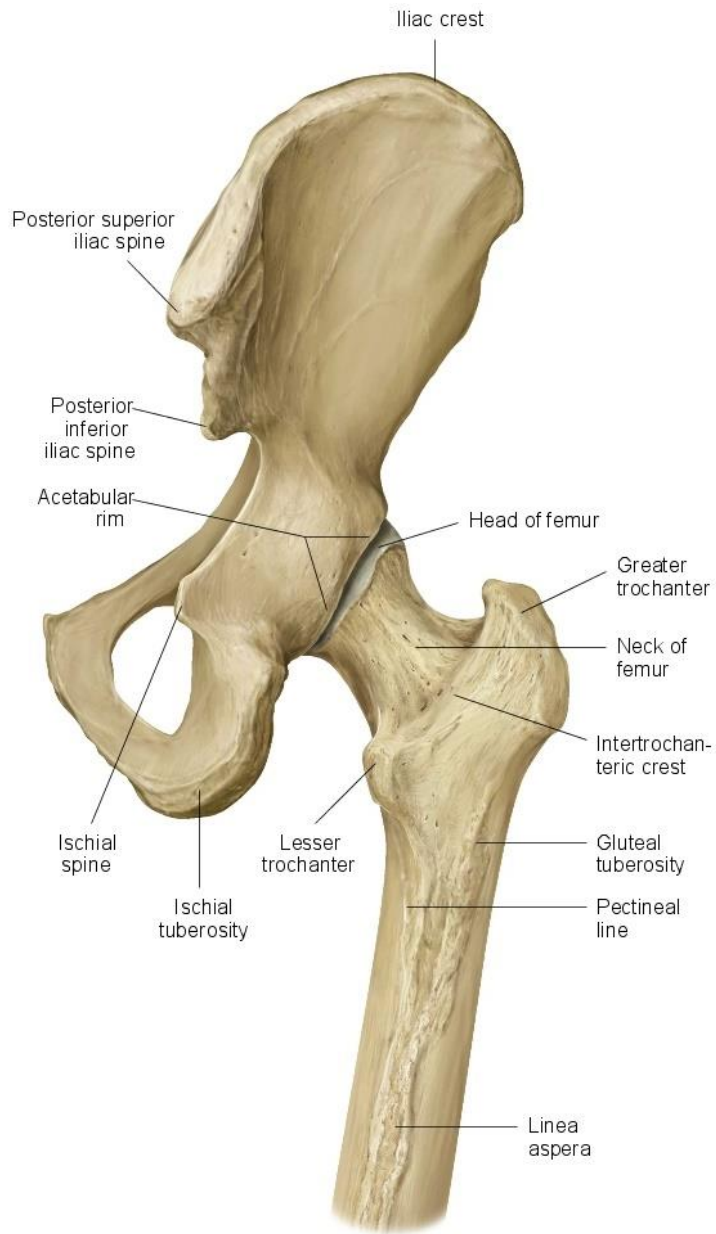
Calcar femorale = *lamina femoris interna*



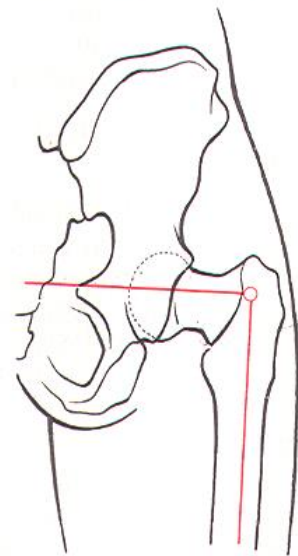
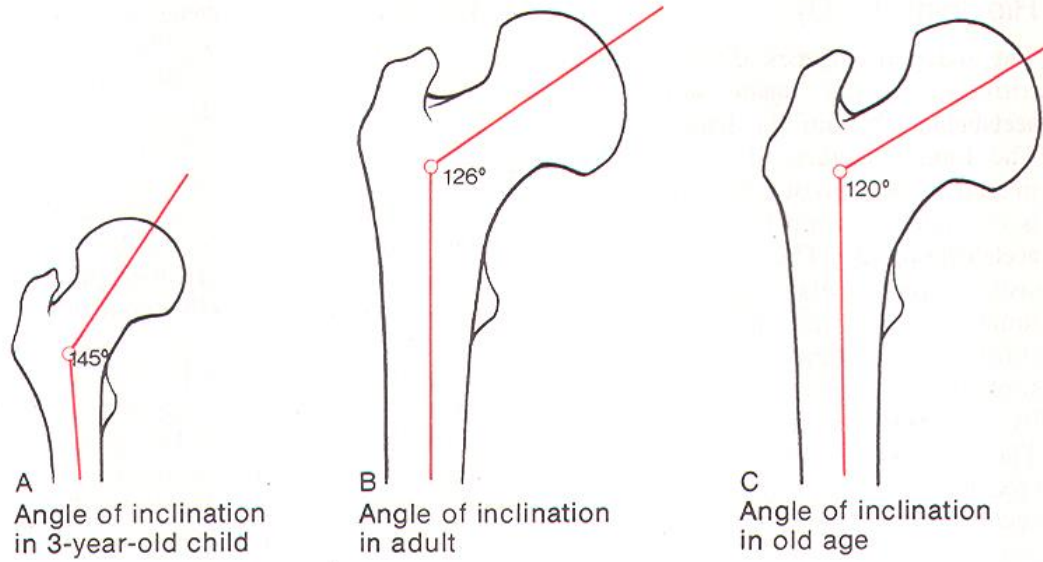
distální konec

- condylus medialis et lateralis*
- epicondylus medialis et lateralis*
- facies patellaris*
- fossa intercondylaris*
- linea intercondylaris*
- facies poplitea*

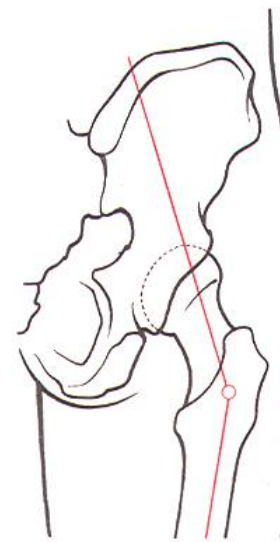




Inkлинаční úhel

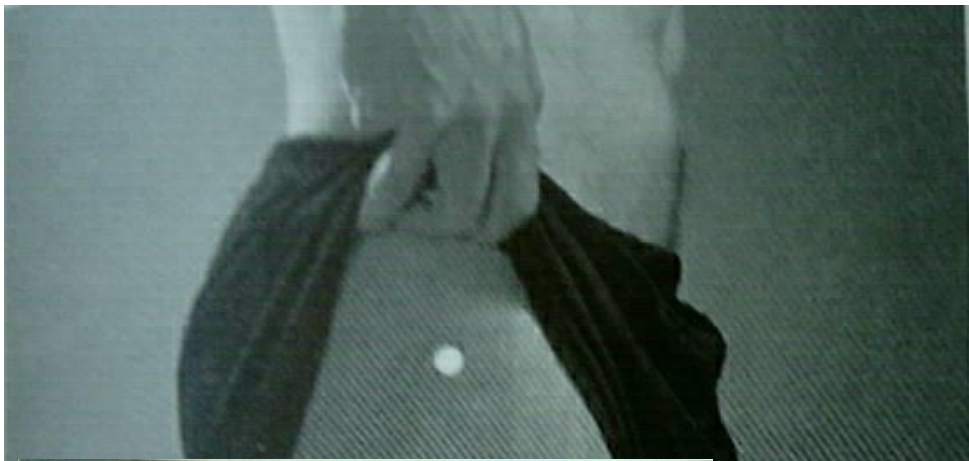

D Coxa vara

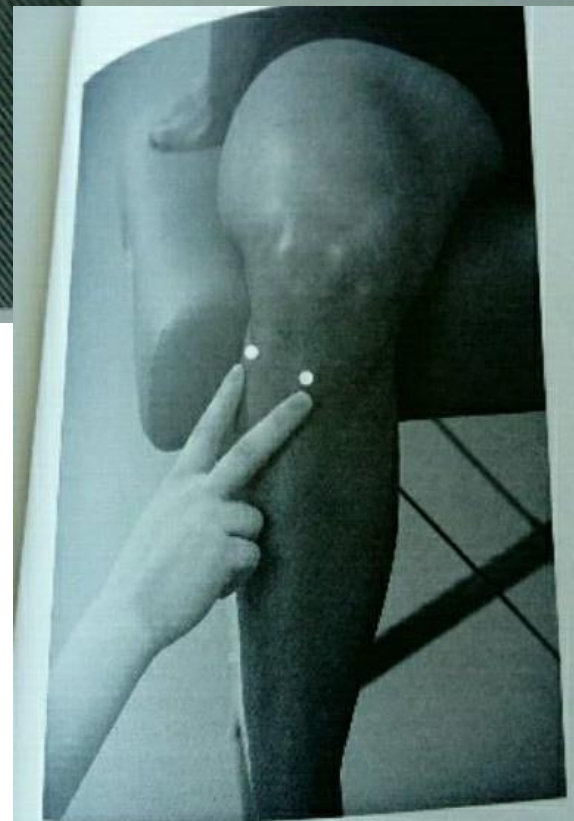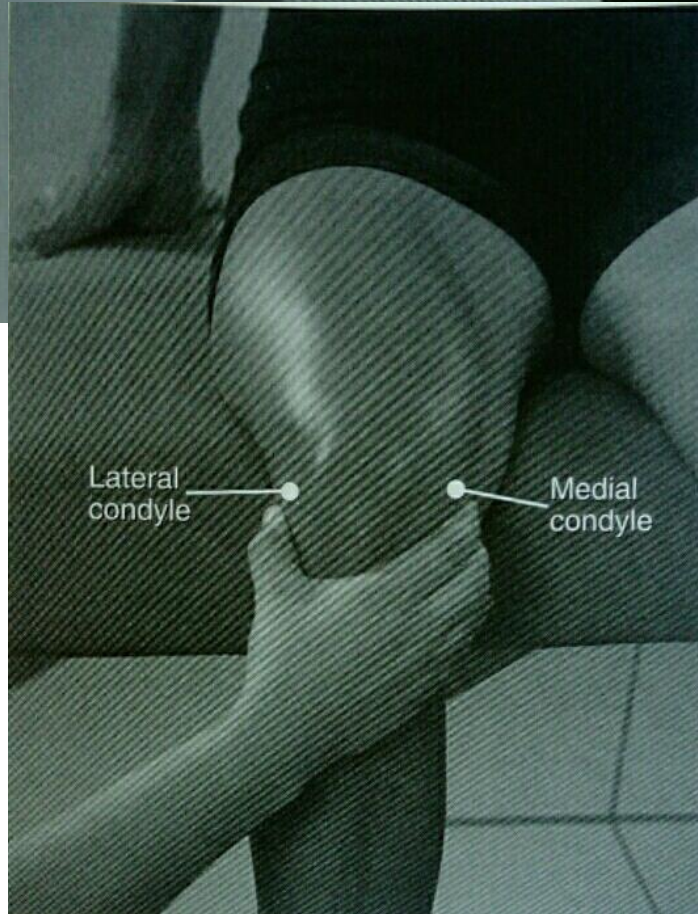


E Coxa valga

Dlouhá osa těla femuru a osa krčku svírá úhel asi 125°, úhel nad 135°=valgózní postavení, pod 120° varózní

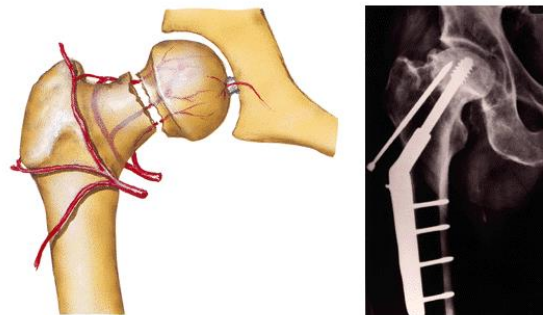


■ FIGURE 10.3 Locating the greater trochanter of the femur.

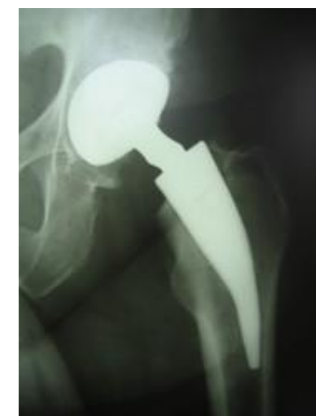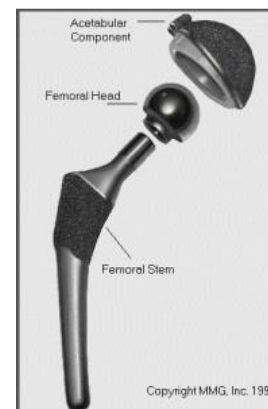
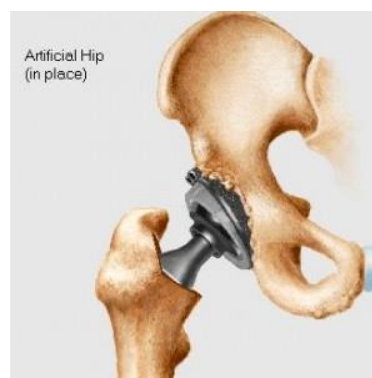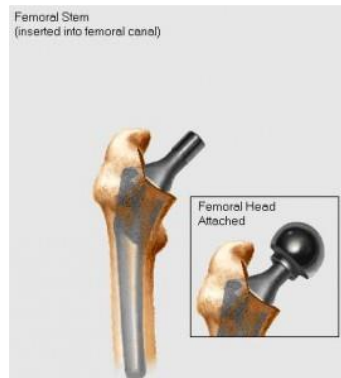


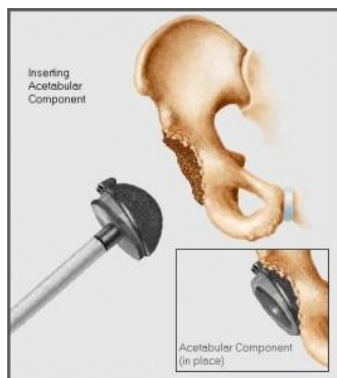■ FIGURE 11.6 Pointing out the tibial tuberosity and head of the fibula.

Fraktura krčku stehenní kosti



Totální endoprotéza kyčelního kloubu

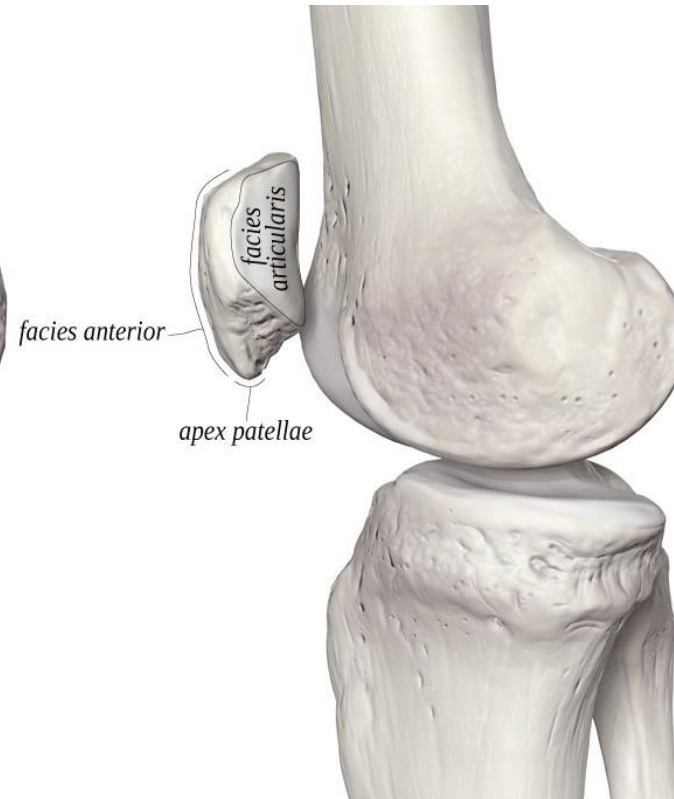
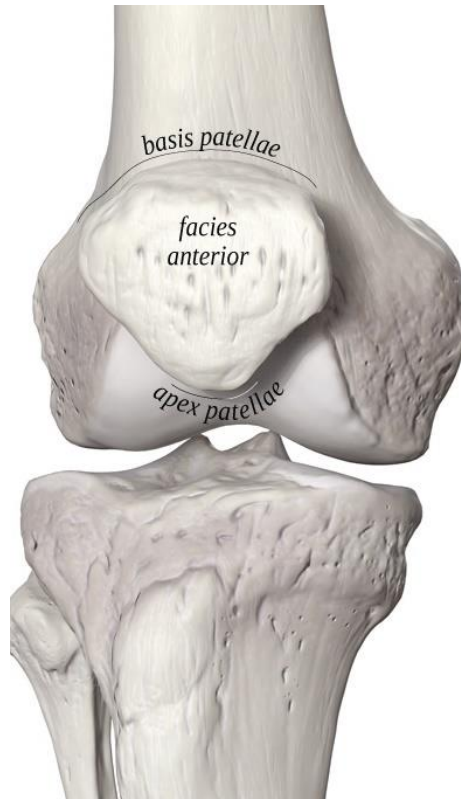


Patella – čéška

basis patellae

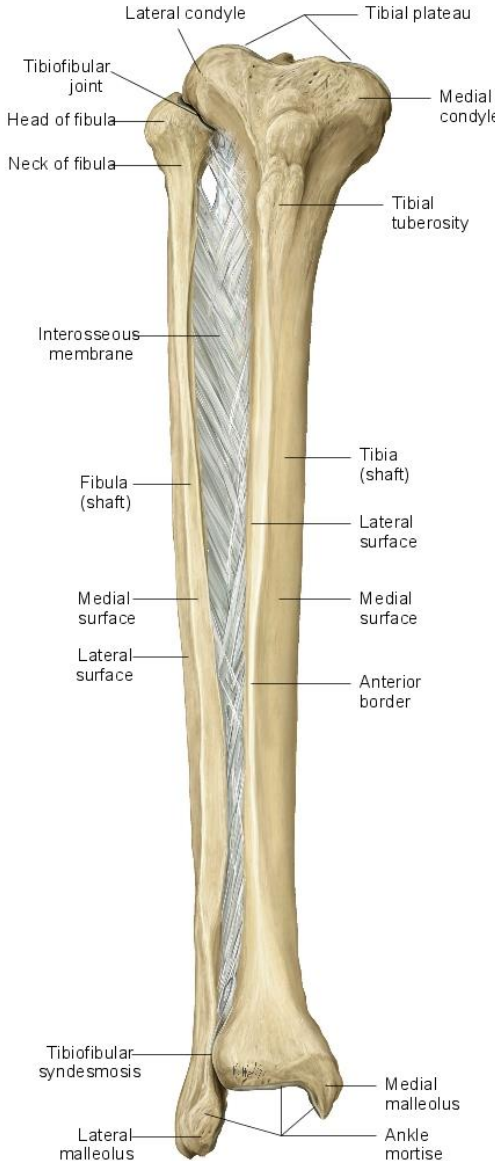
apex patellae

facies articularis patellae

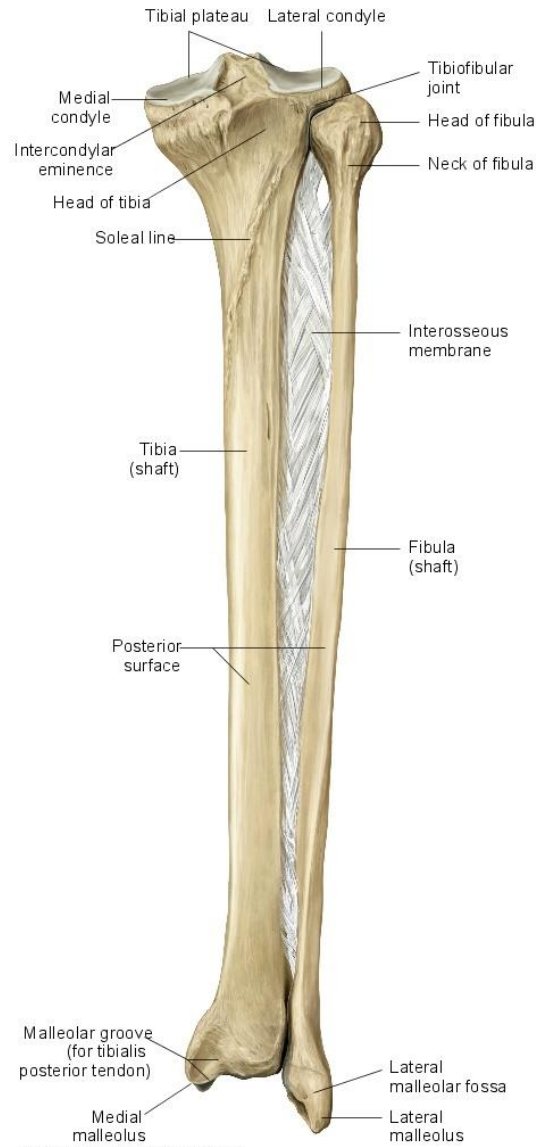


Čéška působí jako kladka - dochází ke změně směru tahu *m. quadriceps femoris*

Kosti bérce (*ossa cruris*)



Copyright ©2008 by Thieme. All rights reserved. Illustration: Karl Wesker



Copyright ©2008 by Thieme. All rights reserved. Illustration: Karl Wesker

Tibia – holenní kost

proximální konec

condylus medialis et lateralis

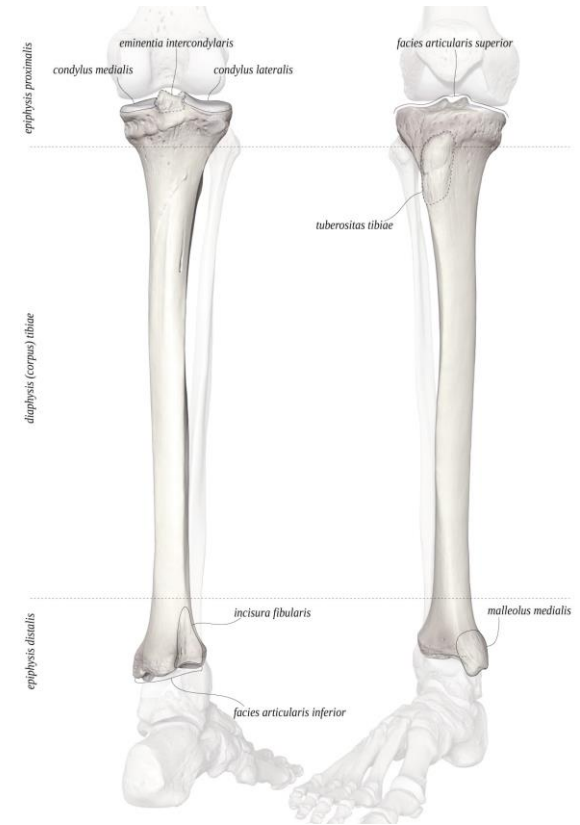
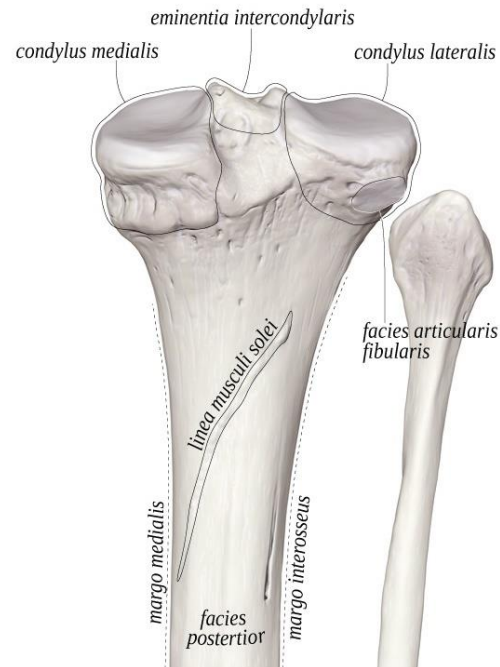
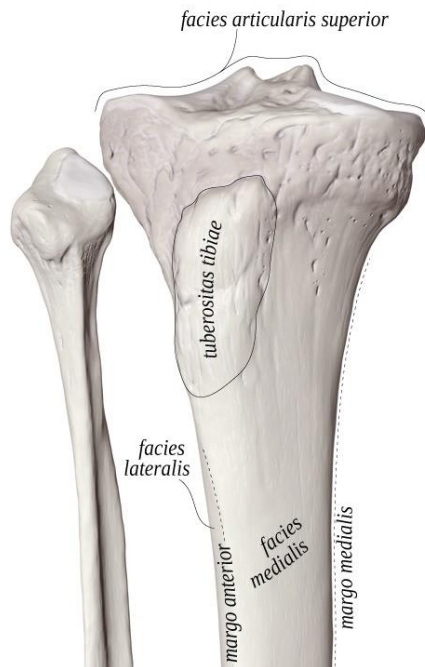
facies articularis superior

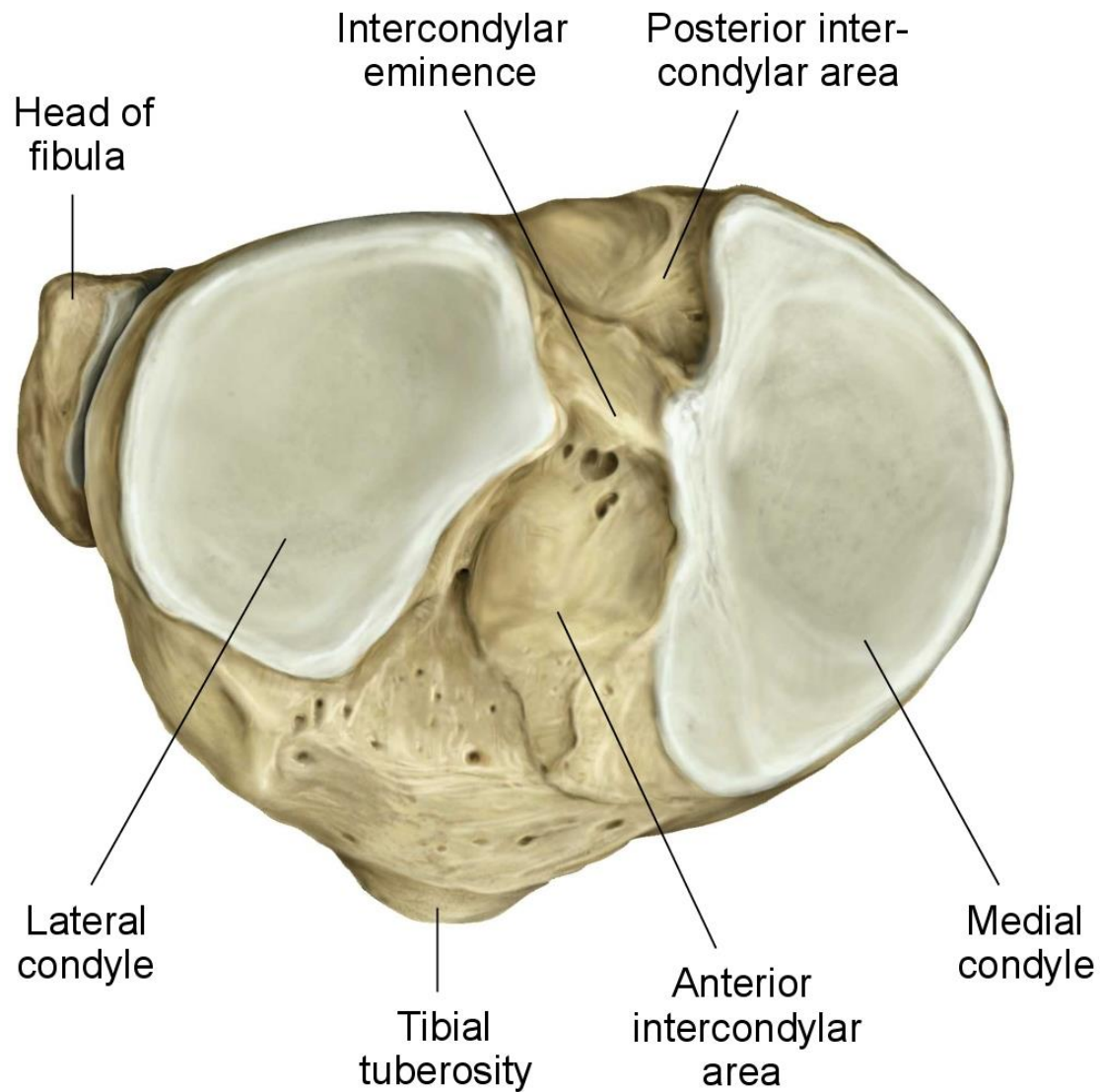
eminentia intercondylaris

tuberculum intercondylare mediale et laterale

area intercondylaris anterior et posterior

facies articularis fibularis





Copyright ©2008 by Thieme. All rights reserved.

Pohled na proximální konce tibie a fibuly

corpus

tuberositas tibiae

linea musculi solei

margo medialis, anterior et
interosseus

distální konec

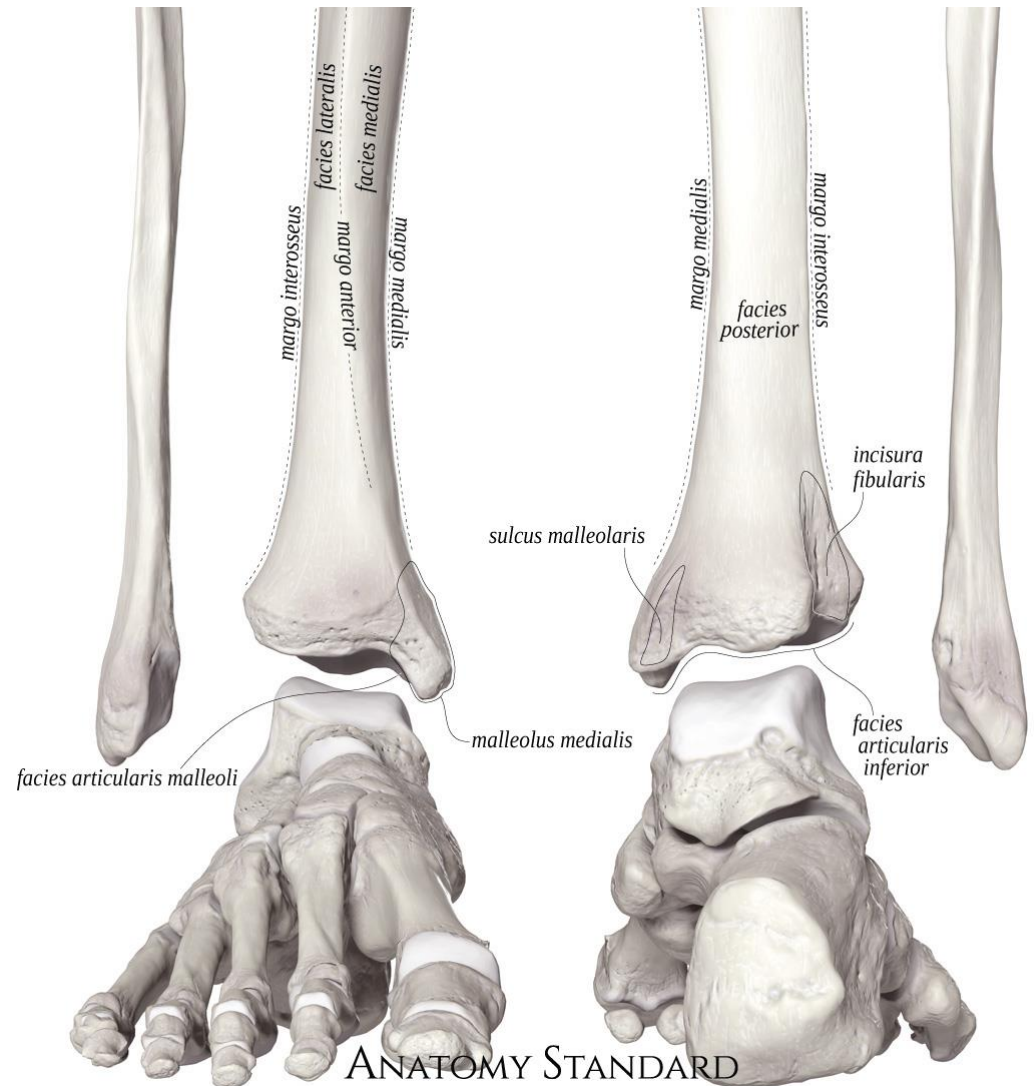
malleolus medialis

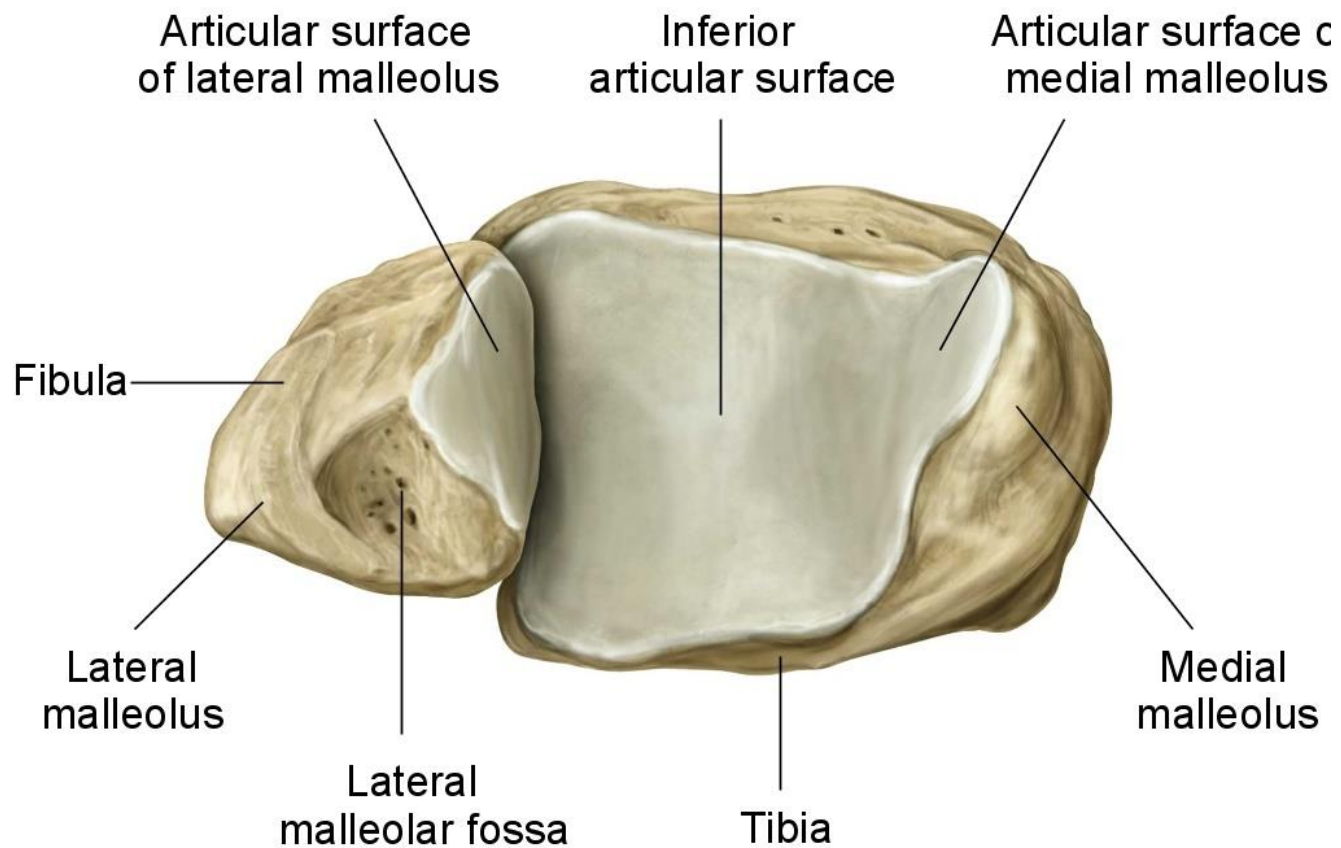
sulcus malleolaris (pro šlachu m. tibialis
posterior)

facies articularis malleoli medialis

incisura fibularis

facies articularis inferior (distalis)





Copyright ©2008 by Thieme. All rights reserved.
Illustrator: Karl Wesker

Pohled na distální konce tibie a fibuly

Fibula – lýtková kost

proximální konec

caput fibulae (facies articularis capitis fibulae)

apex capitis fibulae

corpus

margo anterior, medialis, posterior et interosseus

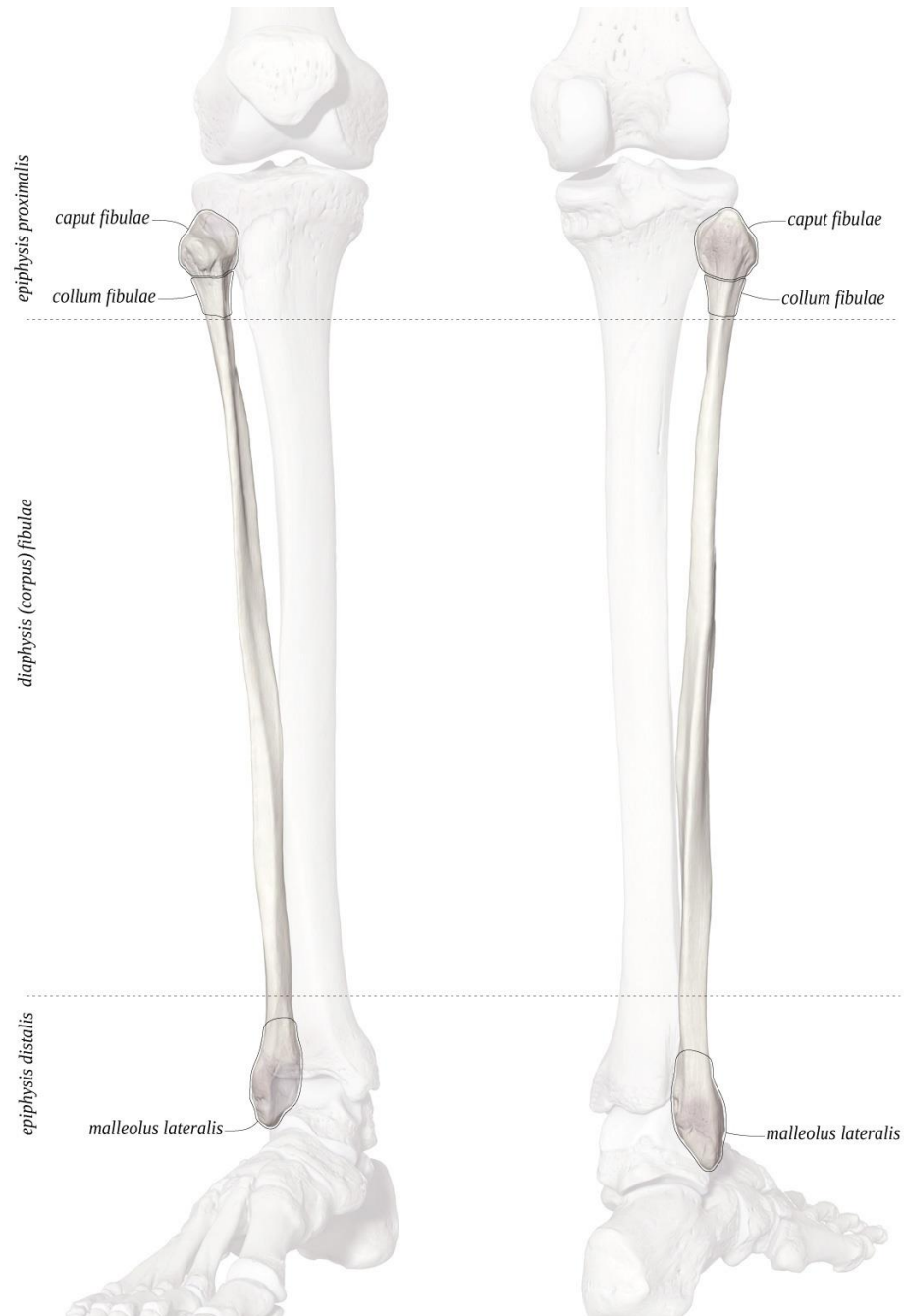distální konec

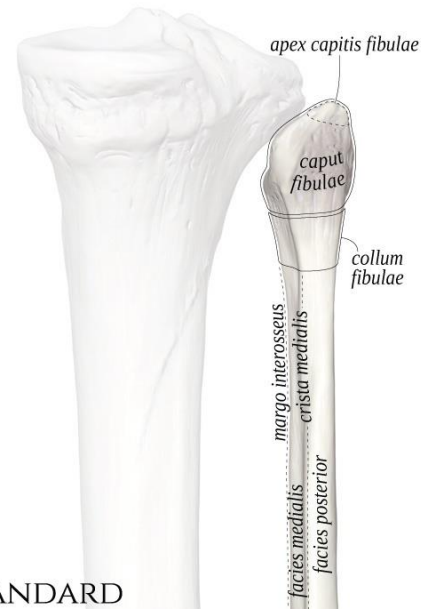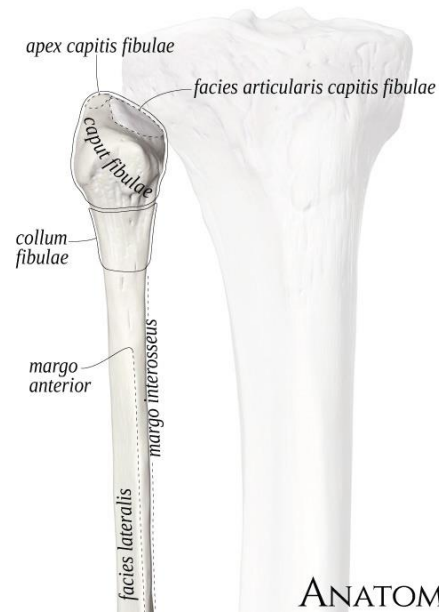
malleolus lateralis

facies articularis malleoli lateralis

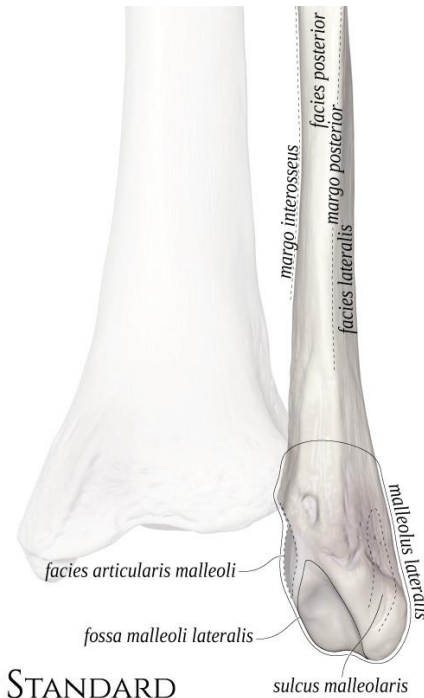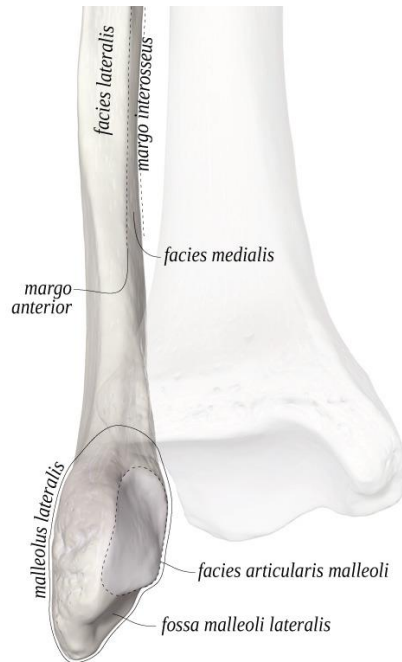
sulcus malleoli lateralis

fossa malleoli lateralis





ANATOMY STANDARD



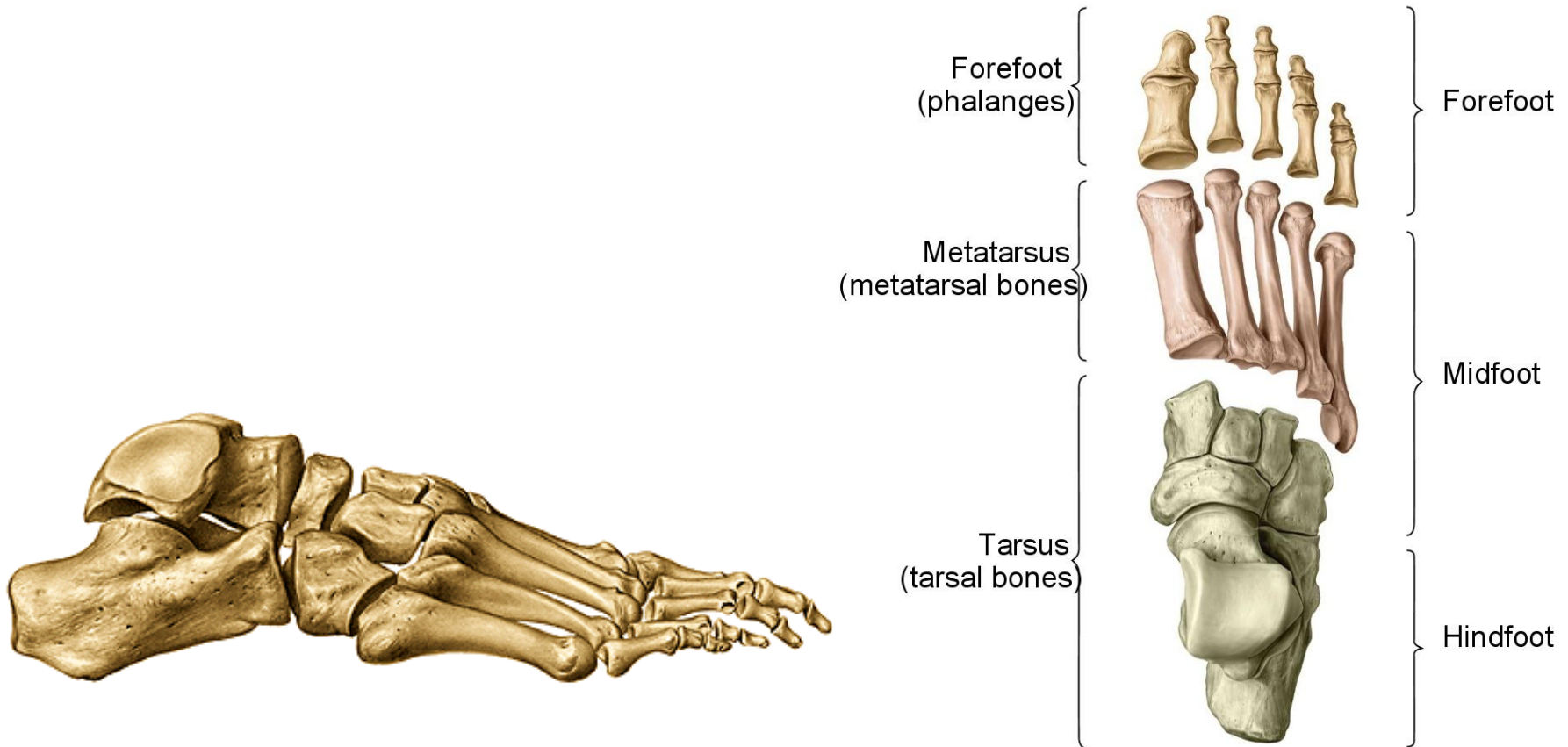
ANATOMY STANDARD

Ossa pedis – kosti nohy

I. *ossa tarsi* (7) - kosti zánártní

II. *ossa metatarsi* (5) - kosti nártní

III. *ossa digitorum pedis* (14) - kosti prstů nohy



Ossa tarsi (kosti zánártní)

talus - kost hlezenní

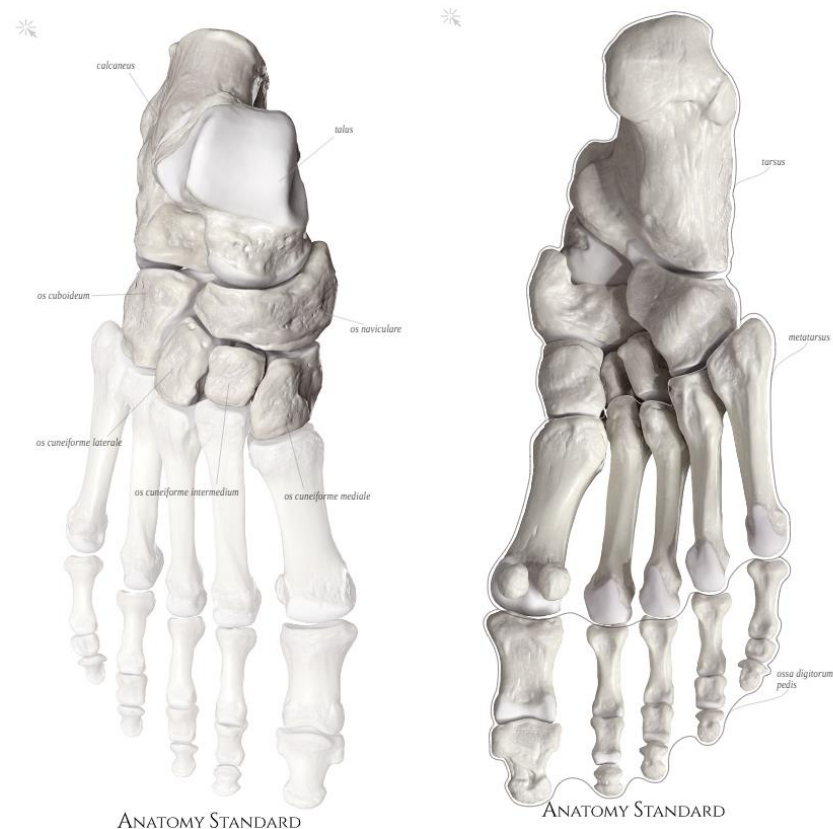
calcaneus - kost patní

os naviculare - kost lod'kovitá

os cuboideum - kost krychlová

ossa cuneiformia - kosti klínové

(mediale, intermedium et laterale)



Talus – kost hlezenní

proximální část

corpus tali

- **dorsálně:** *trochlea tali - facies articularis superior + facies articularis malleolaris lateralis et medialis*
- **plantárně:** *facies articularis calcanea posterior, media et anterior tali*

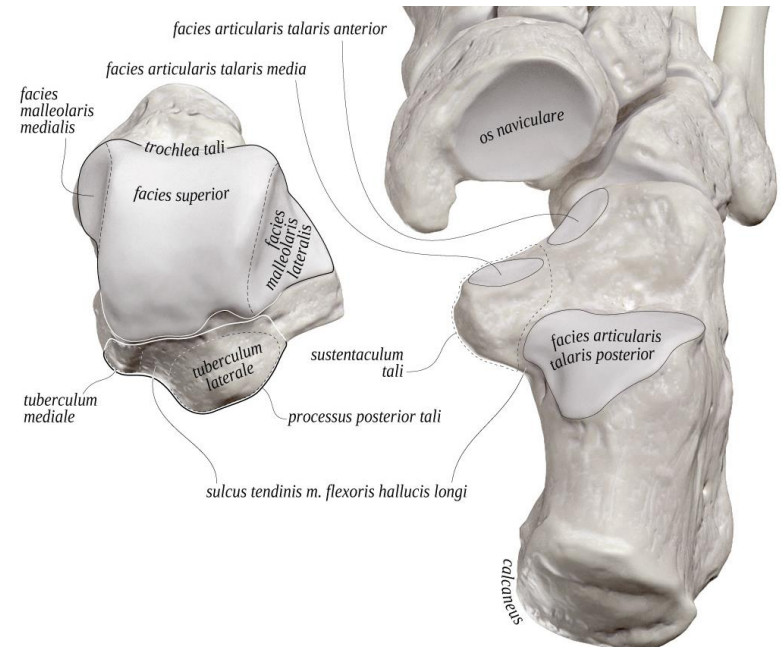
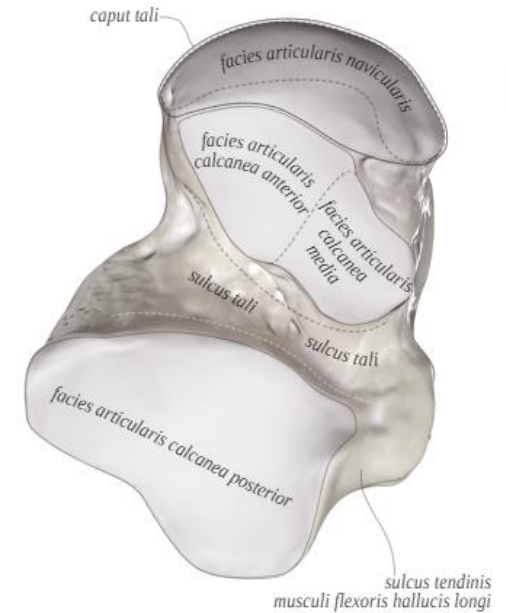
sulcus tali

- **processus lateralis tali**
- **processus posterior tali** - *tuberculum laterale et mediale tali*
sulcus tendinis m. flexoris hallucis longi

collum tali

distální část

caput tali - *facies articularis navicularis*



Calcaneus – patní kost

tuber calcanei (processus medialis et lateralis)

facies articularis talaris calcanei - posterior, media et anterior

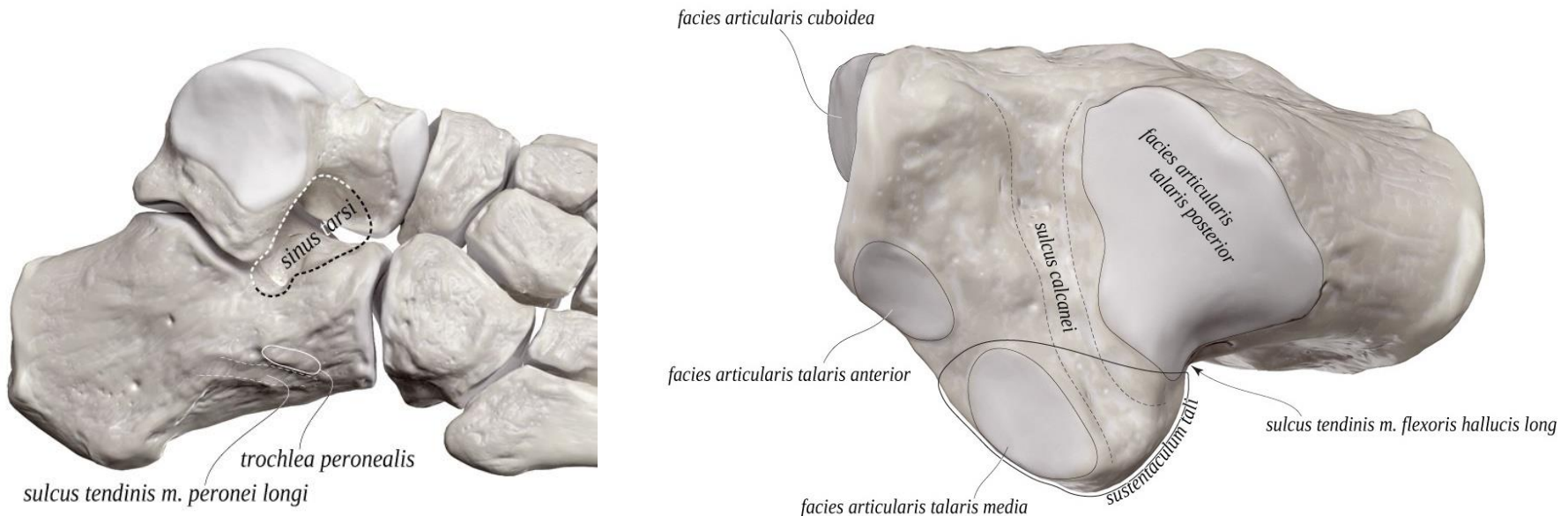
facies articularis cuboidea

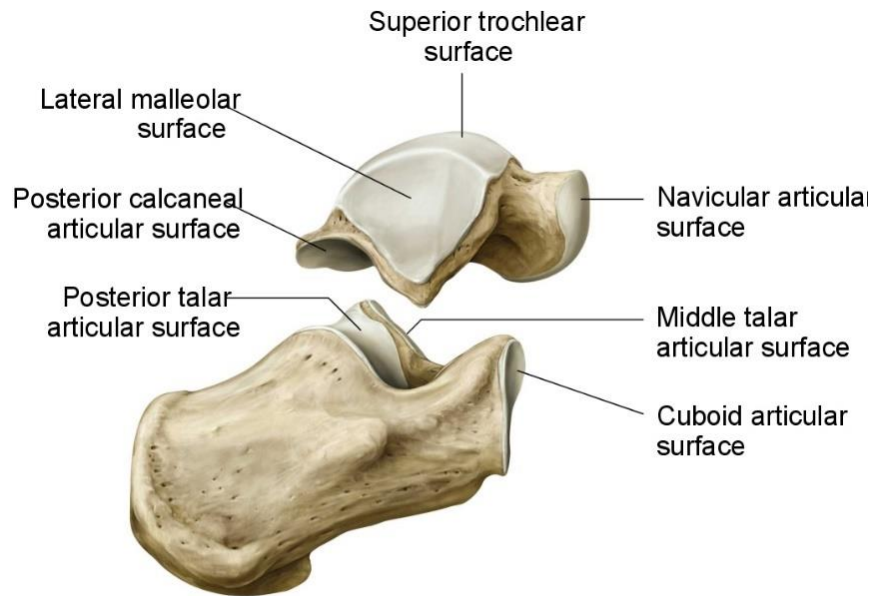
sustentaculum tali (+ sulcus tendinis musculi flexoris hallucis longi)

*trochlea peronealis – **sulcus tendinis musculi peronei longi***

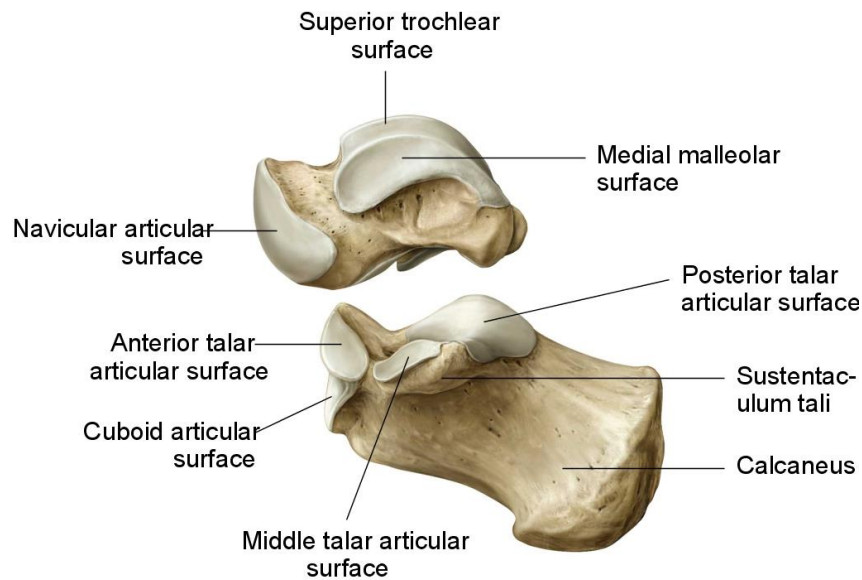
sulcus calcanei

sulcus calcanei + sulcus tali = sinus tarsi

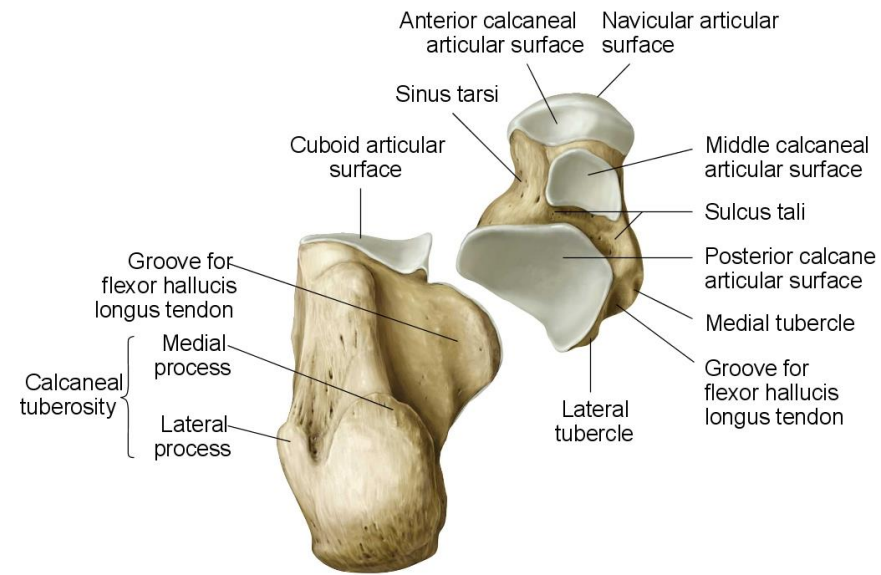




Copyright ©2008 by Thieme. All rights reserved.
Illustrator: Karl Wesker



Copyright ©2008 by Thieme. All rights reserved.
Illustrator: Karl Wesker



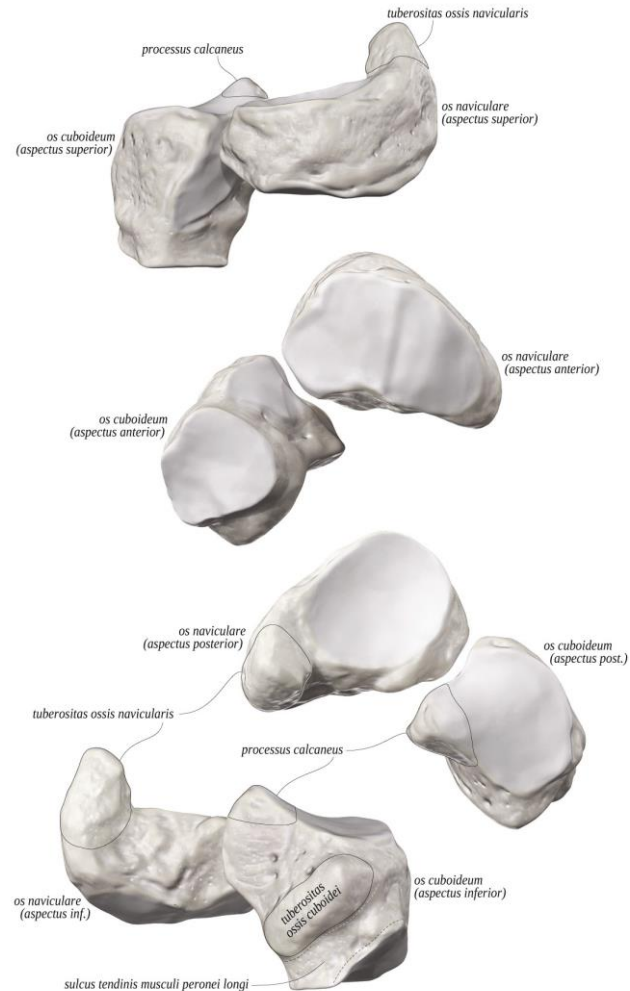
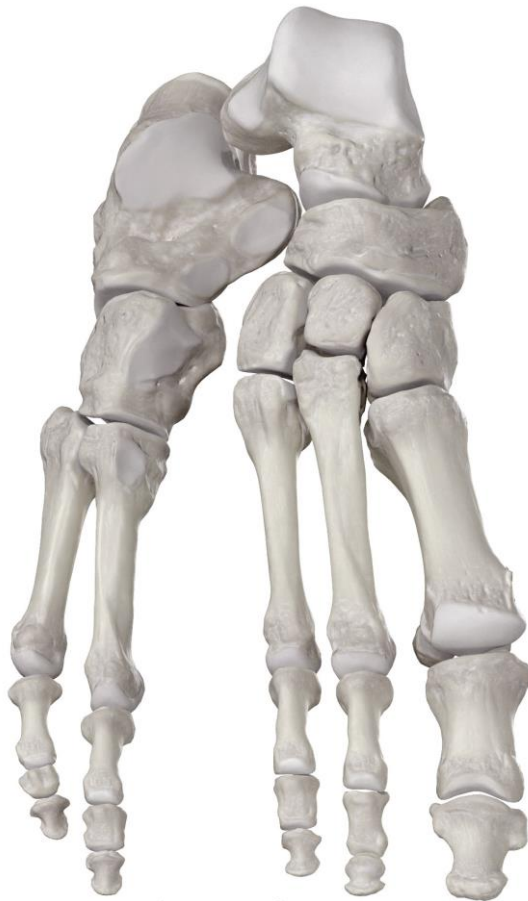Copyright ©2008 by Thieme. All rights reserved.
Illustrator: Karl Wesker

Os naviculare - lod'kovitá kost

tuberositas ossis navicularis (pro úpon m. tibialis posterior)

facies articularis cuneiformis – konvexní, 3 fasety

faceies articularis talaris



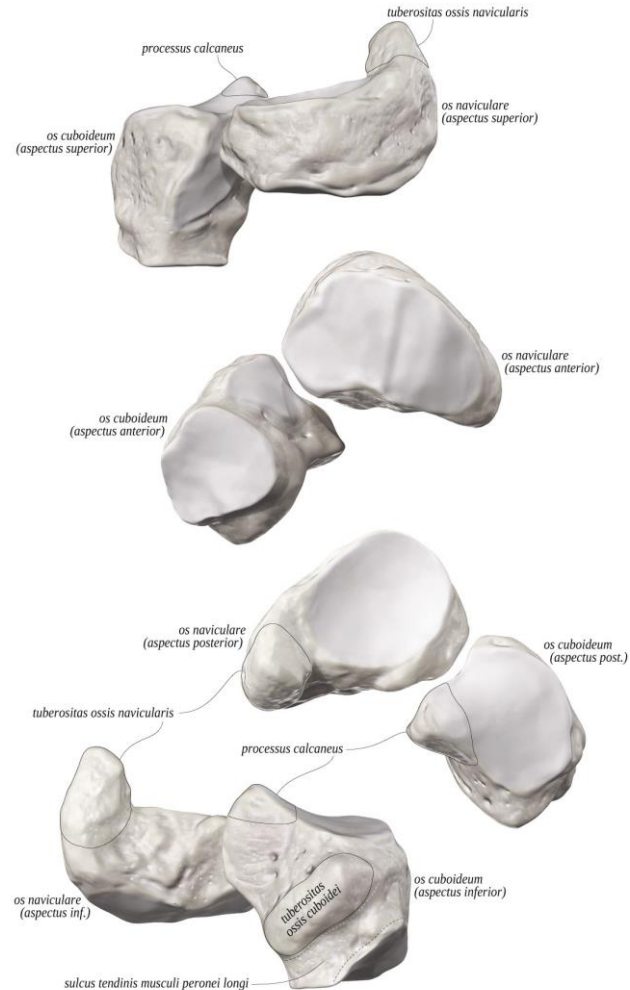
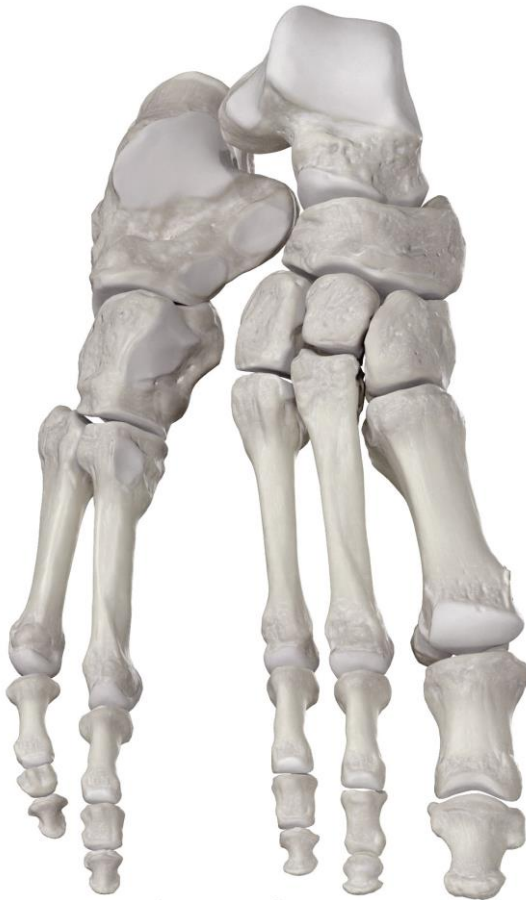Os cuboideum - krychlová kost

facies articularis calcanearis

tuberositas ossis cuboidei

sulcus tendinis musculi fibularis/peronei longi

} plantárně



Ossa cuneiformia - kosti klínové

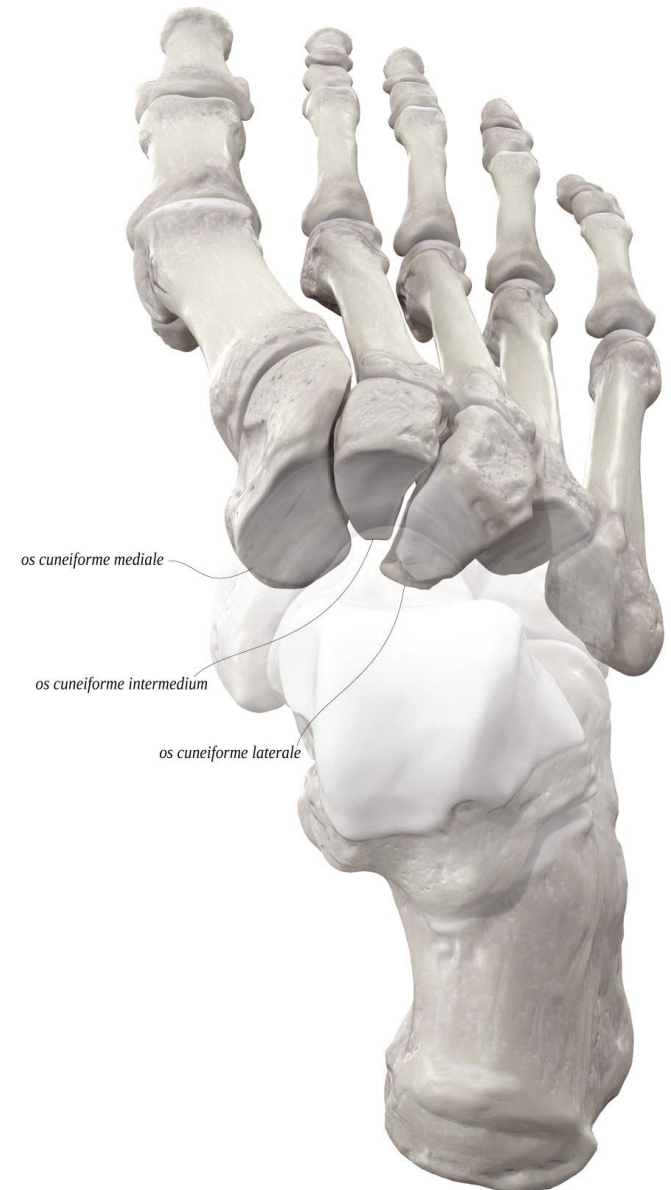
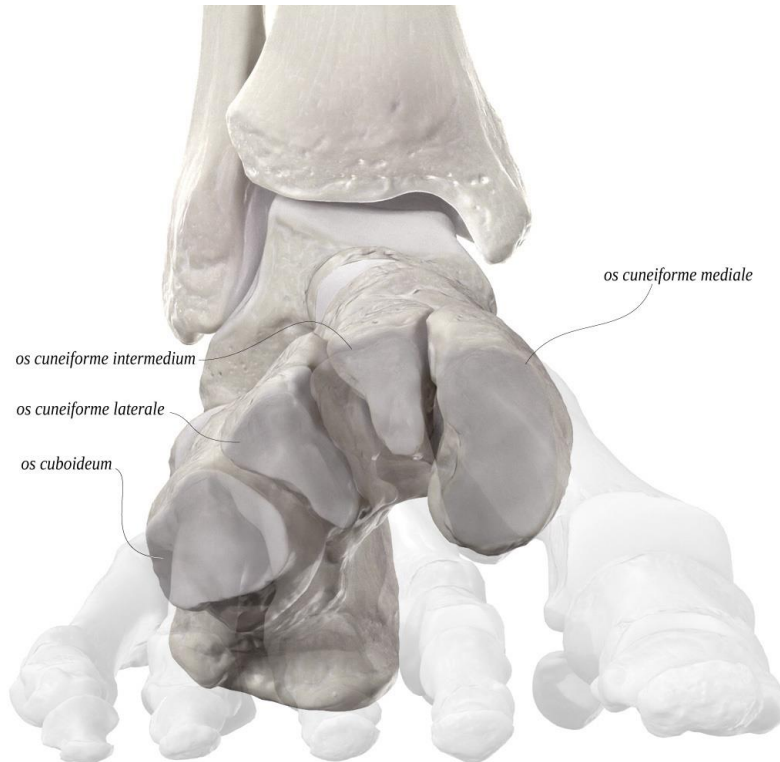mediale, intermedium et laterale

mediale: největší, u place, ostří klínu dorsálně

intermedium: ostří klínu plantárně

laterale: ostří klínu plantárně

podílí se na nožní klenbě

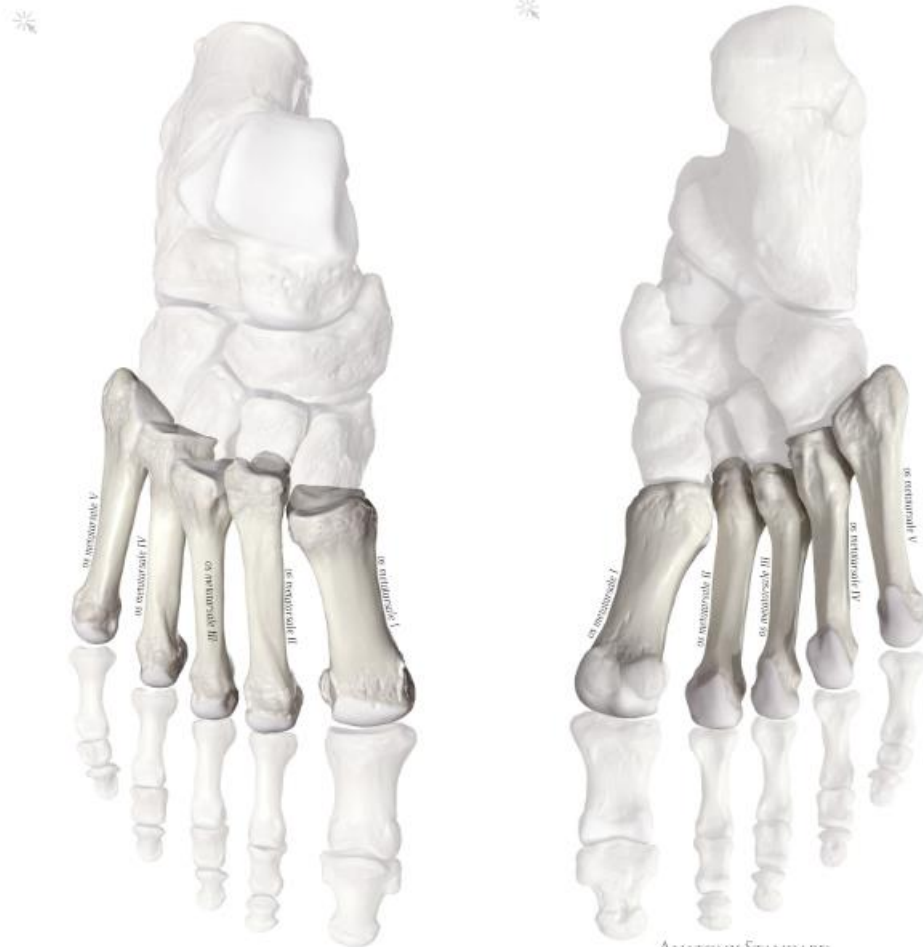

Ossa metatarsi (I. – V.) - nártní kosti

basis (tuberositas ossis metatarsi I. et V. - úpon mm. fibulares)

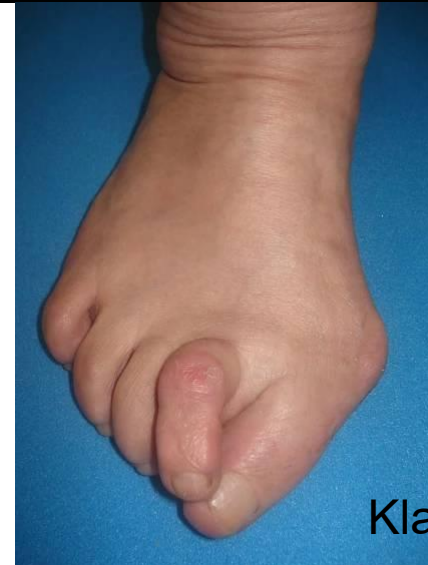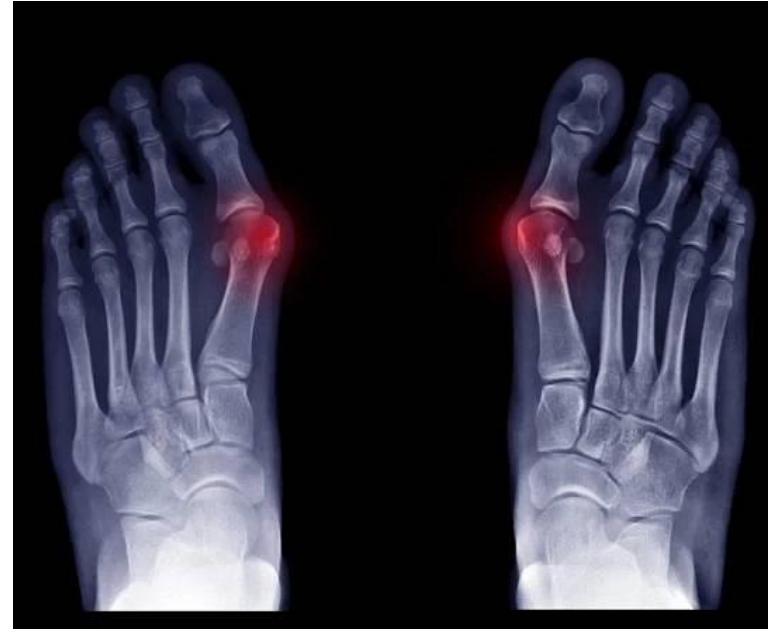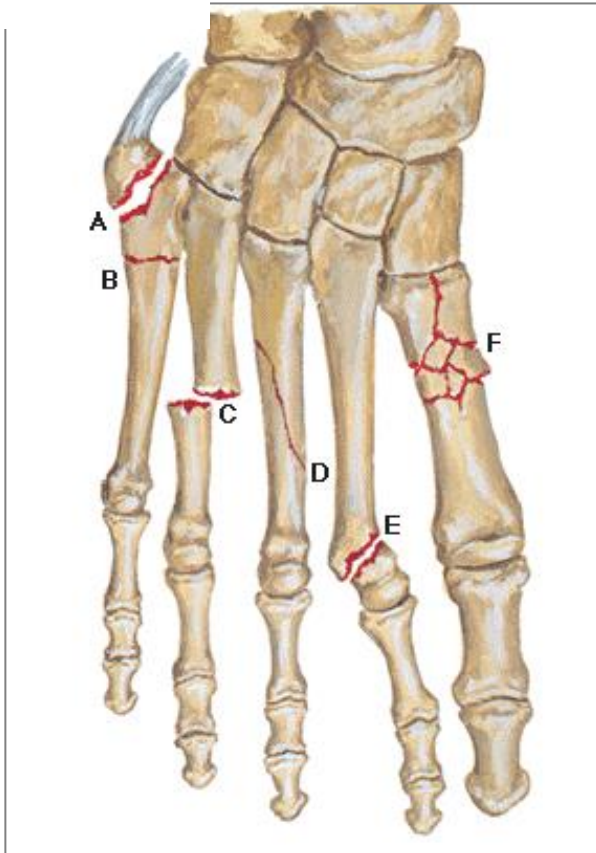
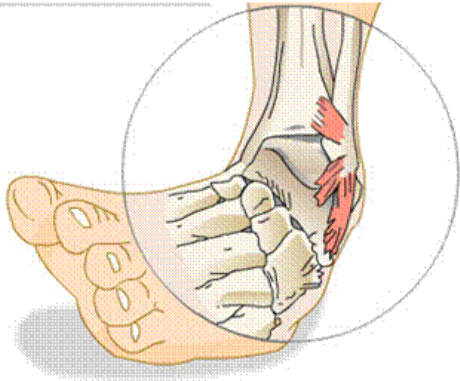
corpus

caput (+ossa sesamoidea u palce)



Fraktury metatarsálních kostí

Hallux valgus



Kladívkovité prsty

Ossa digitorum pedis (*phalanges*) - kosti prstů nohy

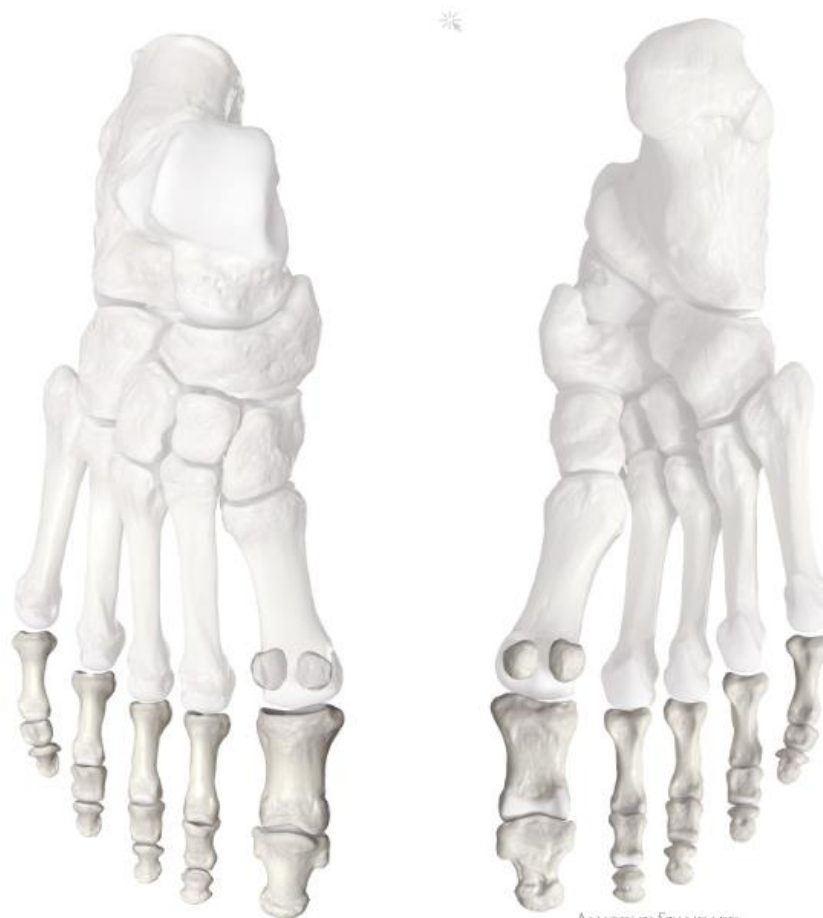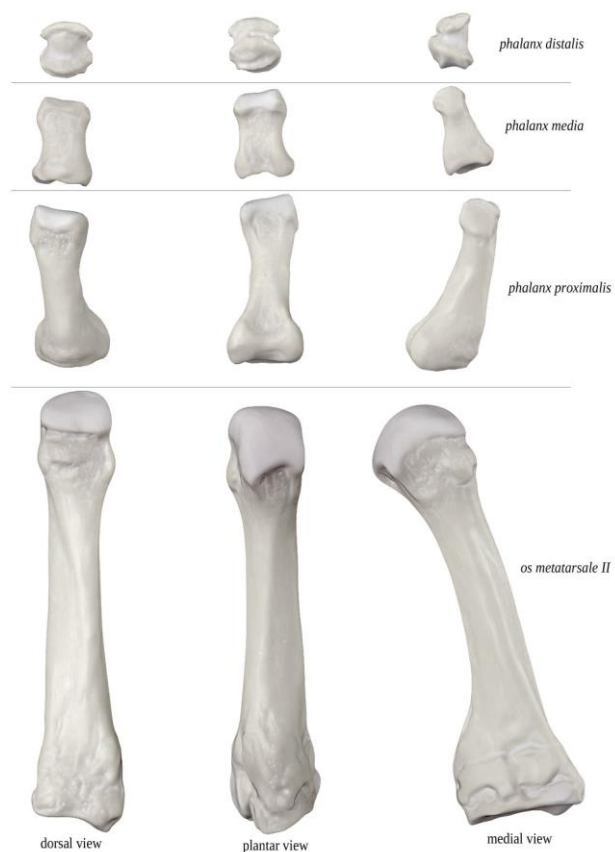palec – *phalanx proximalis et distalis*

II. – V. prst – *phalanx proximalis, media et distalis*

basis phalangis

corpus phalangis

caput/trochlea (u distálního článku – *tuberositas phalangis distalis*)



Typy nohou

- kosti prstů nohy jsou různě dlouhé

1) Egyptská noha

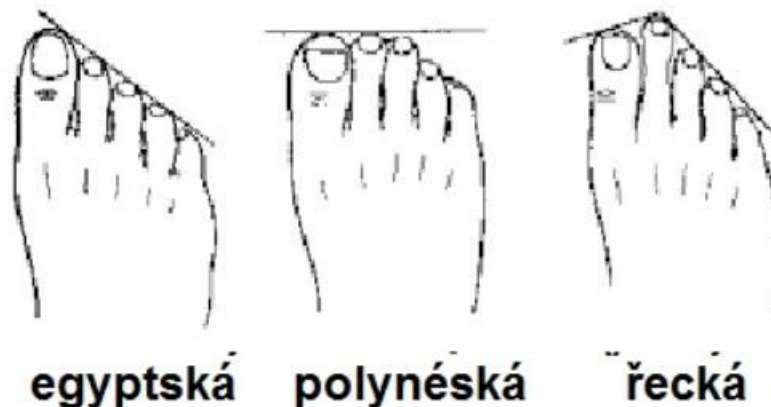
- nejdelší palec
- nejčastější u evropské populace (60%)

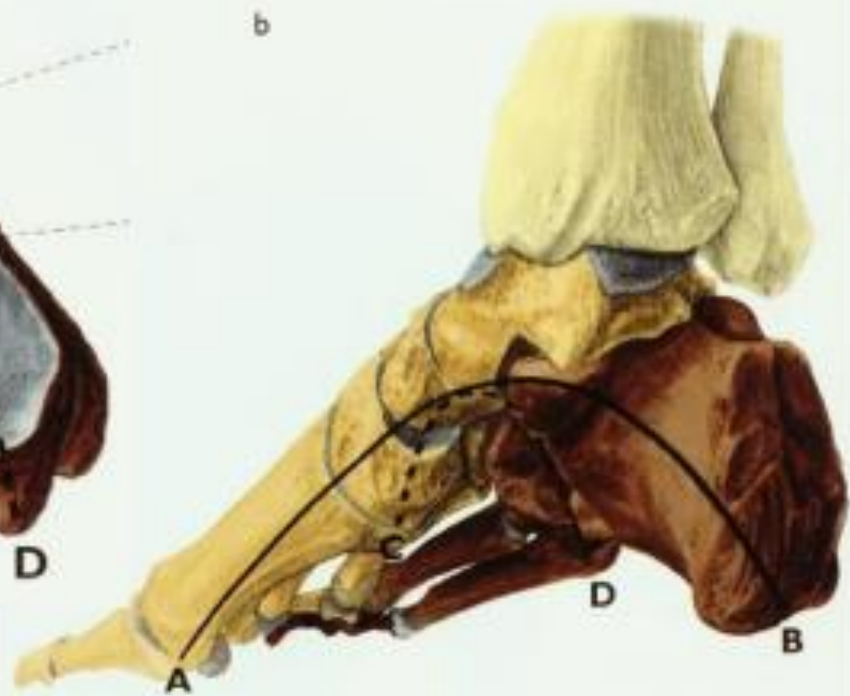
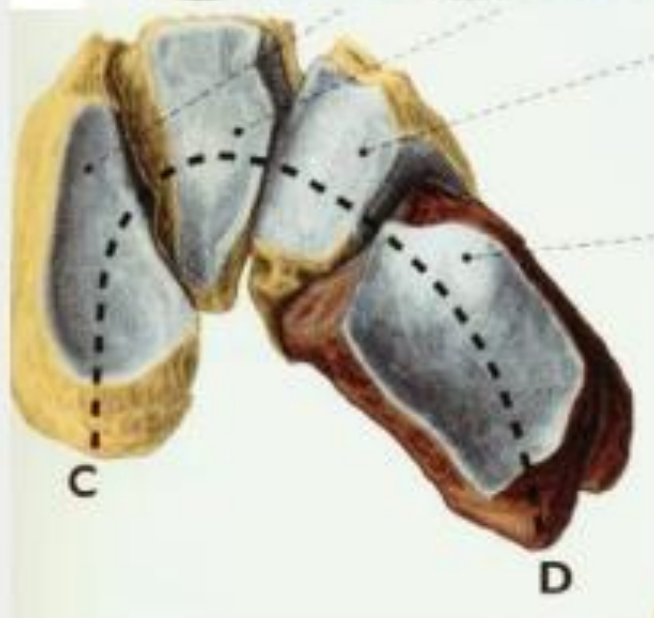
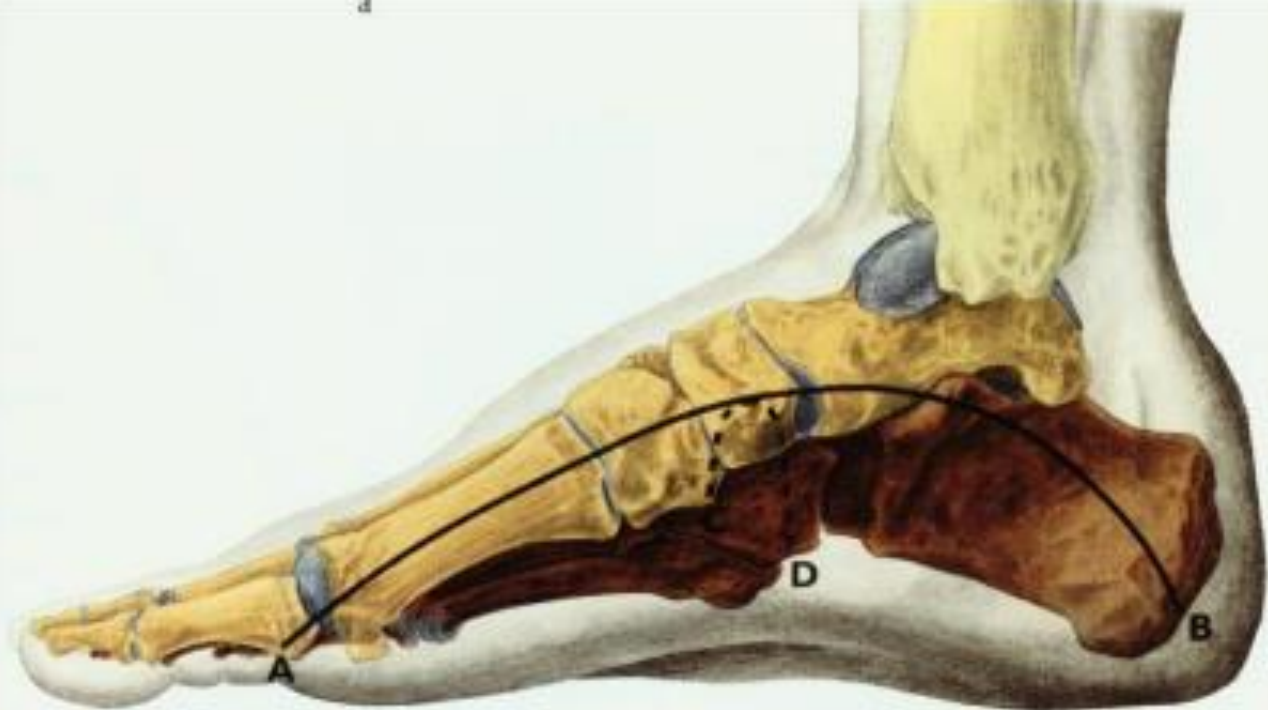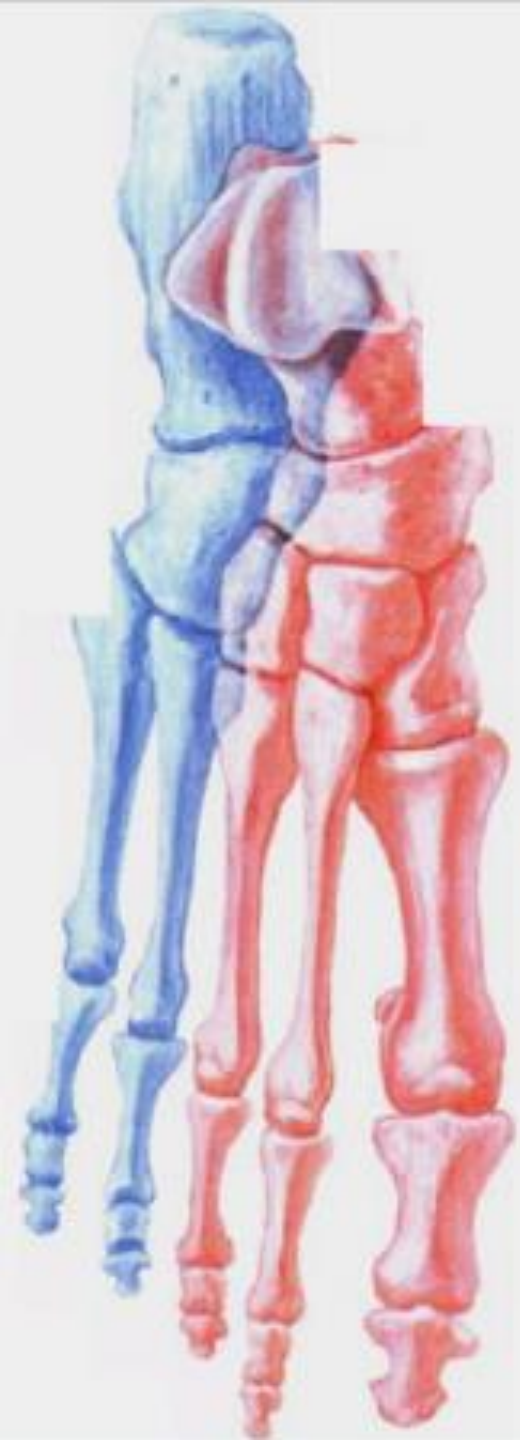2) Řecká noha

- nejdelší je druhý prst, palec a třetí prst jsou stejně dlouhé
- 8-22% populace

3) Polynéská noha

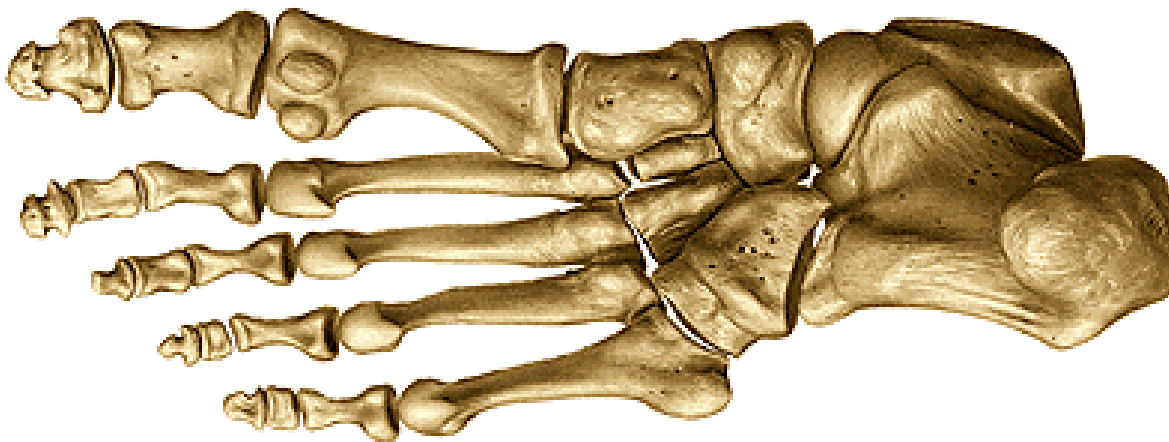
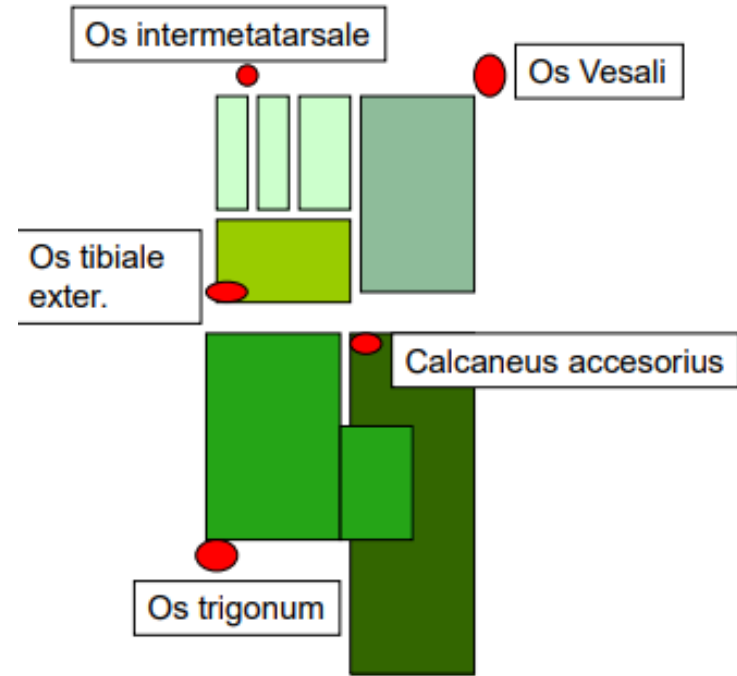
- obdélníkovitý tvar
- první 3 prsty stejně dlouhé
- 9% evropské populace





Ossa sesamoidea

- *patella*
- pod hlavicí placového metatarsu
2 kůstky (laterální a mediální)
u metatarsophalangového kloubu
- občas i pod hlavicí V. a II. metatarsu nebo na plantární ploše os cuboideum ve šlaše m. peroneus/fibularis longus



Děkuji za pozornost!

Použité obrázky byly převzaty z

Čihák, R. (1987): Anatomie 1. Avicenum, Zdravotnické nakladatelství.

Putz, R. (2008): Atlas of Human Anatomy Sobotta. Elsevier Books.

Keith L. Moore, Arthur F. Dalley (2005): Clinically Oriented Anatomy. Williams and Wilkins.

Platzer, W., Kahle, W., Leonhardt H. (1992): Locomotor system. Georg Thieme Verlag, Stuttgart, New York, 4th edition.

Drake et al: Gray's Anatomy for students. 2010

Anatomy Standard