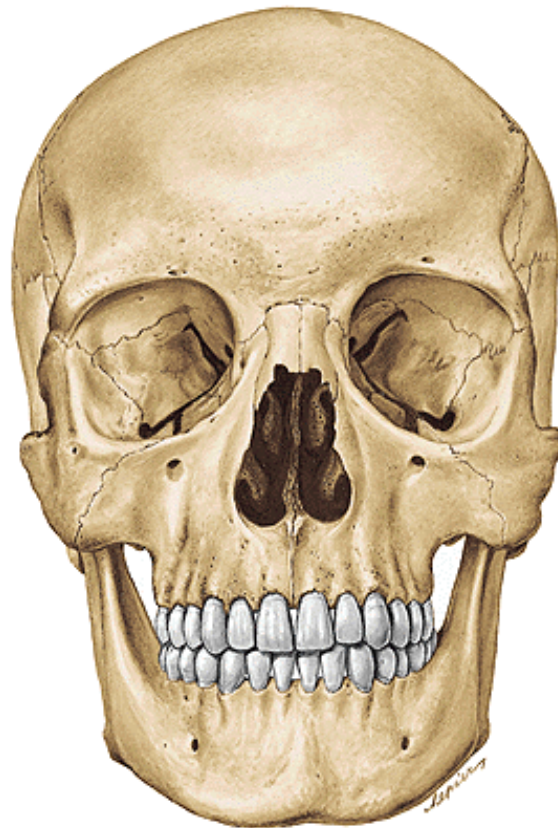
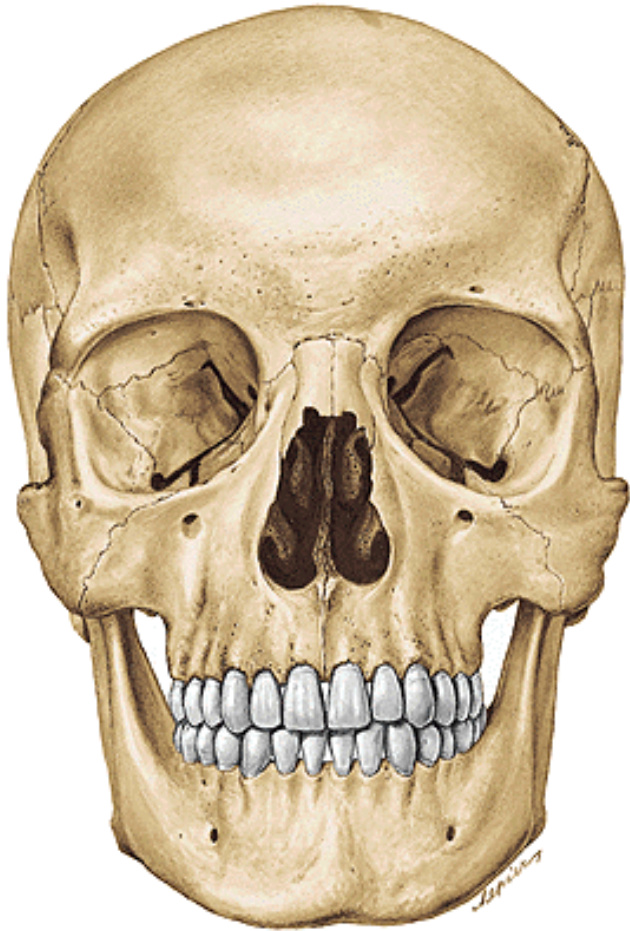


Kosti lebky

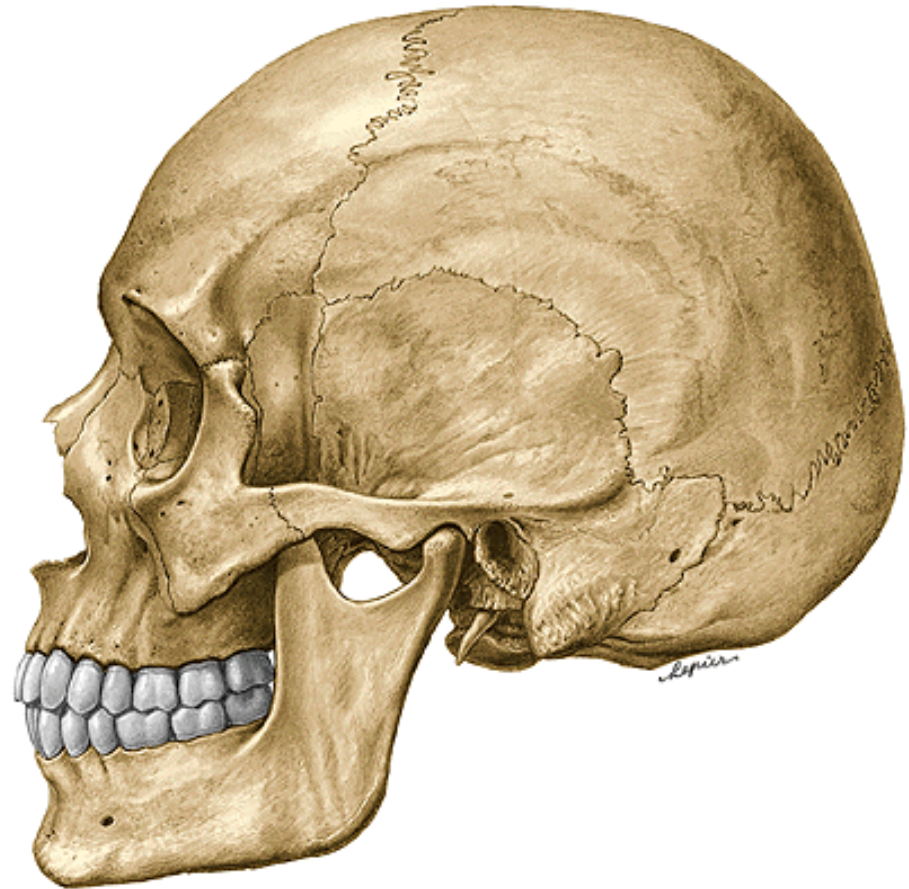


Lebka (*cranium*)

- I. Neurocranium (pouzdro kolem mozku a smyslových orgánů)
- II. Splanchnocranium (obklopuje začátek trávicí a dýchací soustavy)
hranice – od stropu očníce po zevní zvukovod



norma frontalis
(pohled zepředu)



norma lateralis
(pohled z boku)

Mozková část lebky (*Neurocranium*)

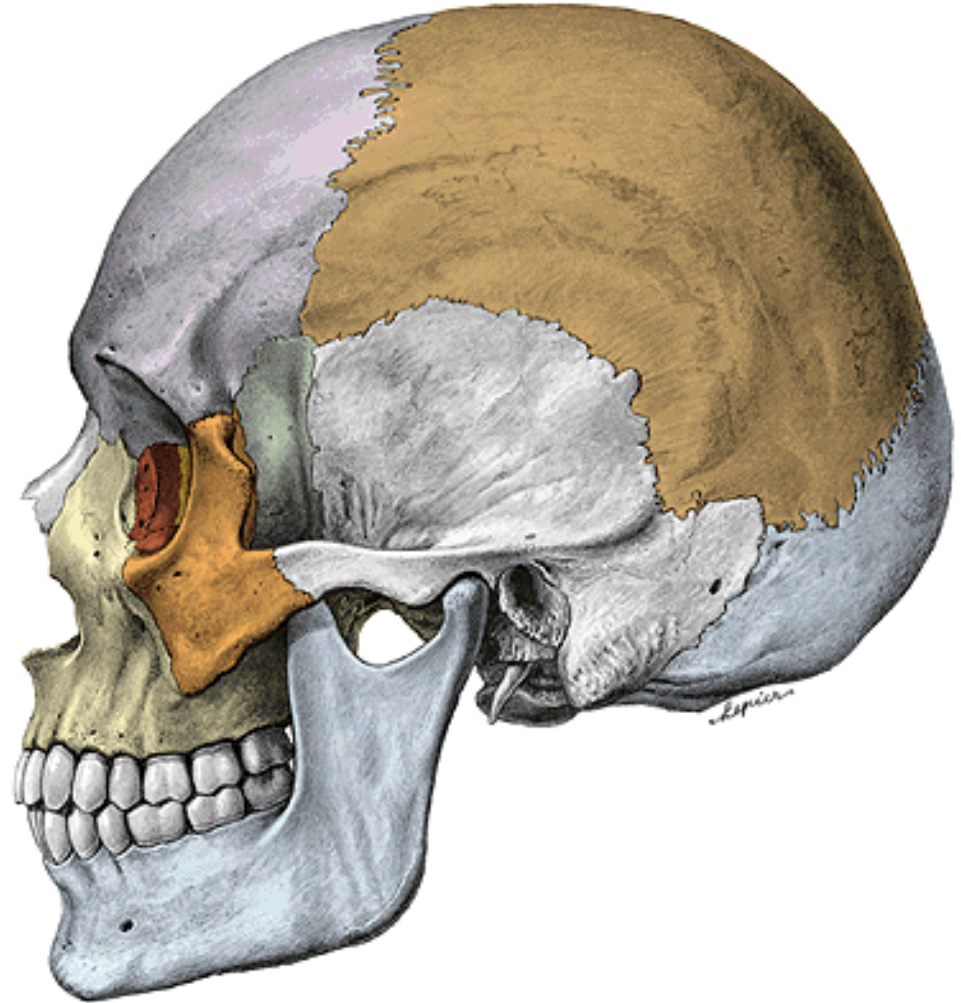
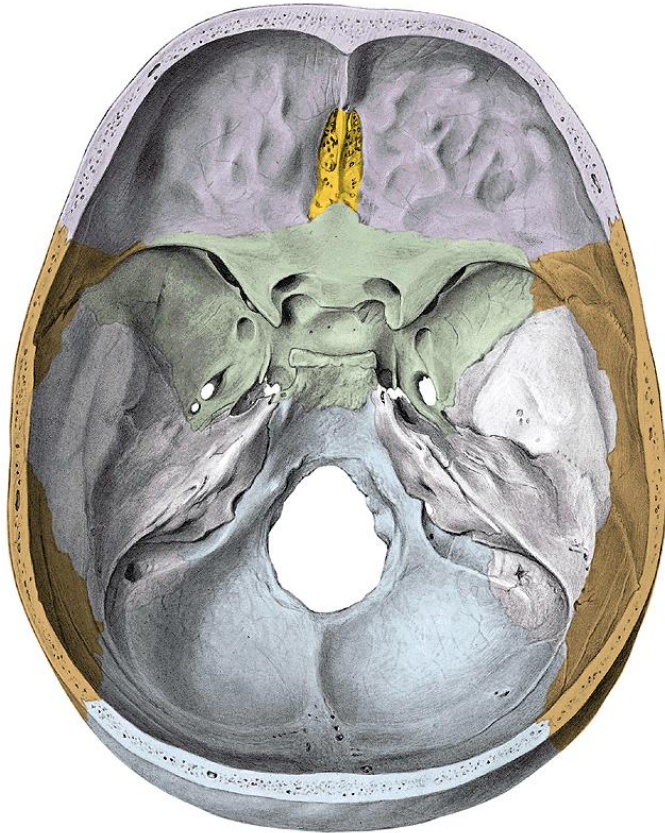
os frontale (čelní kost)

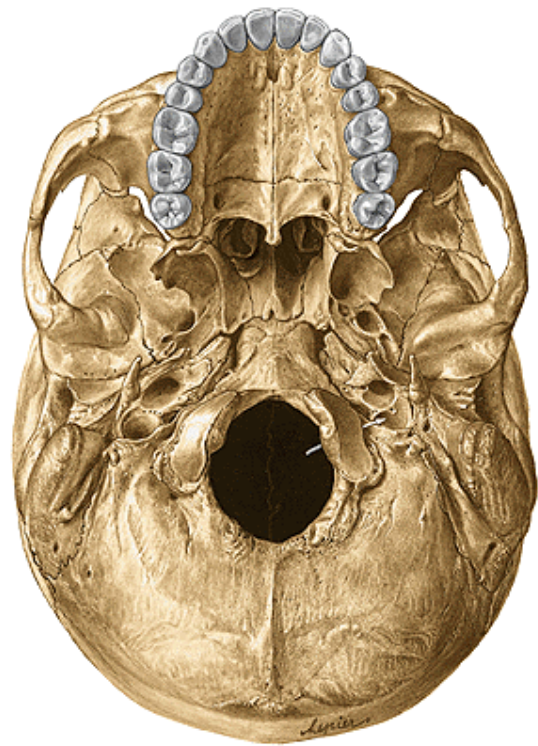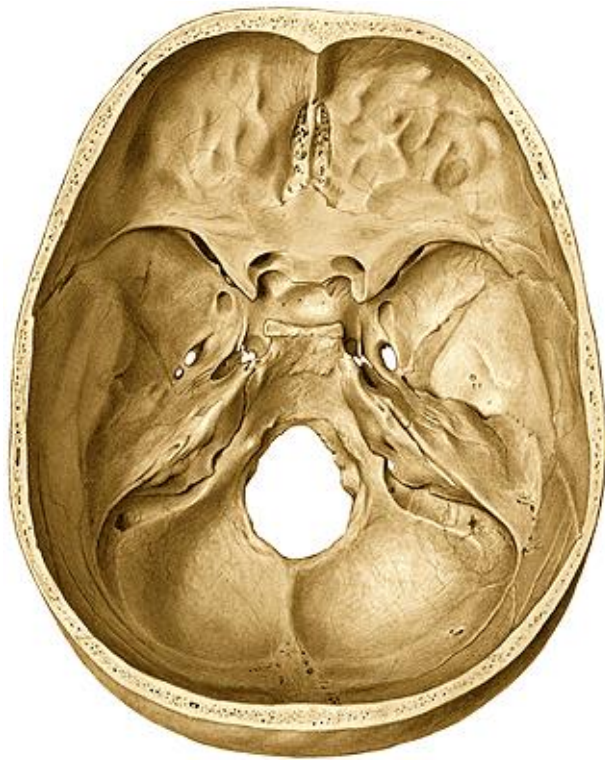
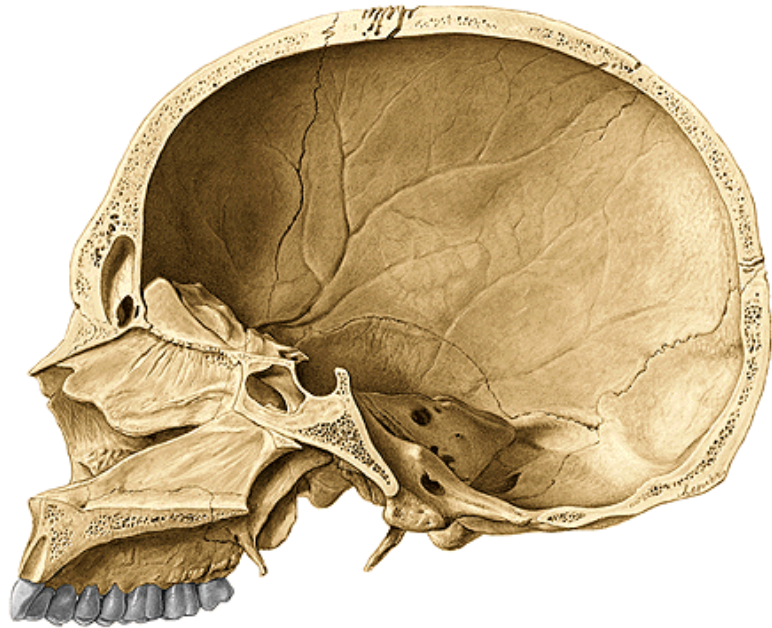
ossa parietalia (temenní kosti)

os occipitale (týlní kost)

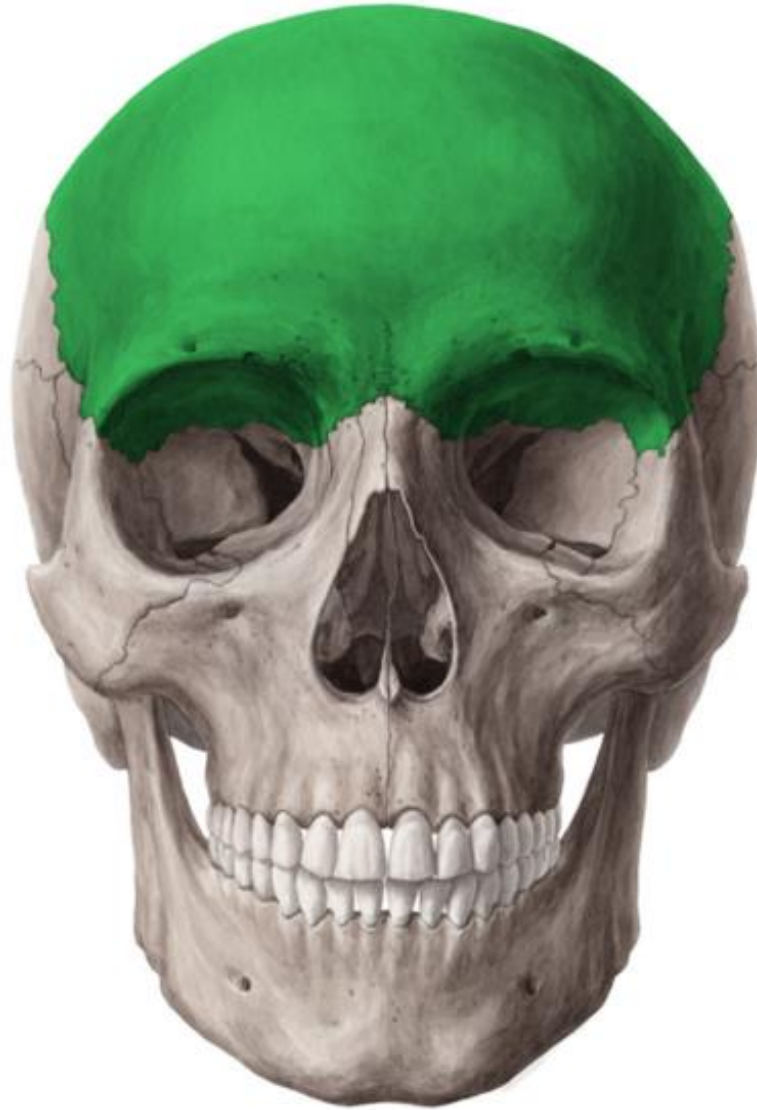os sphenoidale (klínová kost)

ossa temporalia (spánkové kosti)





Os frontale



Os frontale

Squama ossis frontalis (šupina čelní kosti)

sutura coronalis

tubera frontalia

margo supraorbitalis

incisura frontalis

Incisura supraorbitalis

Arcus superciliaris

Glabella

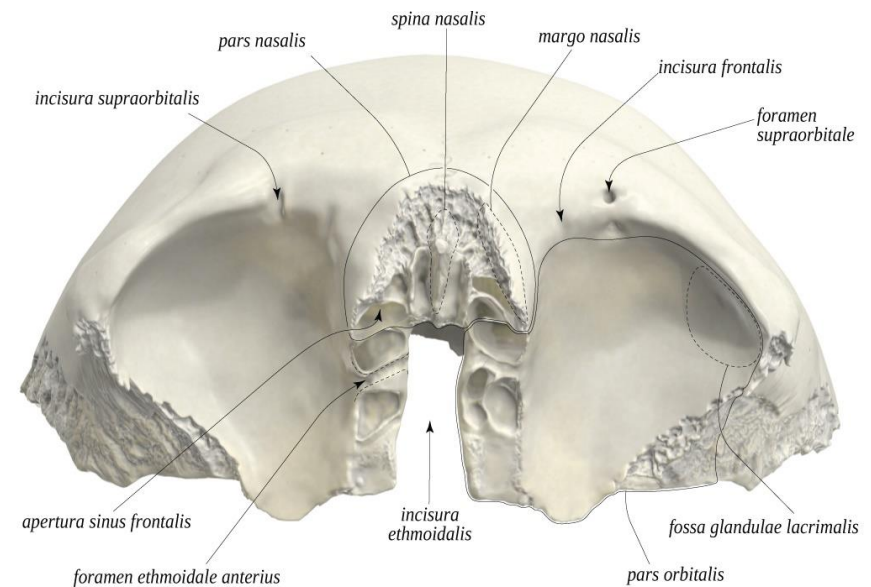
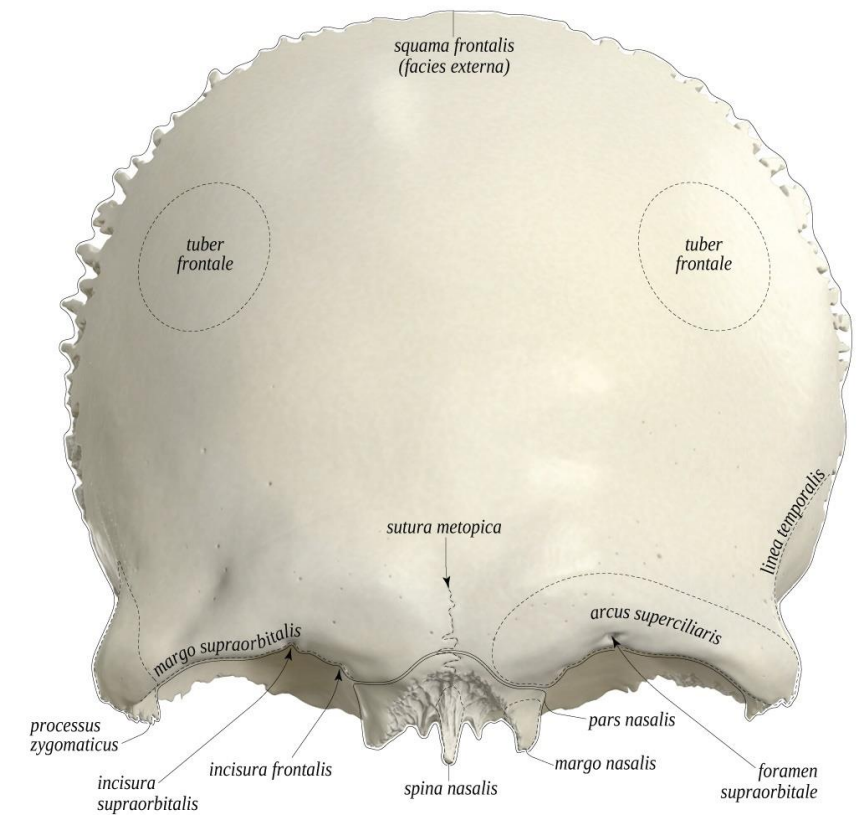
Partes orbitales (očnicové části)

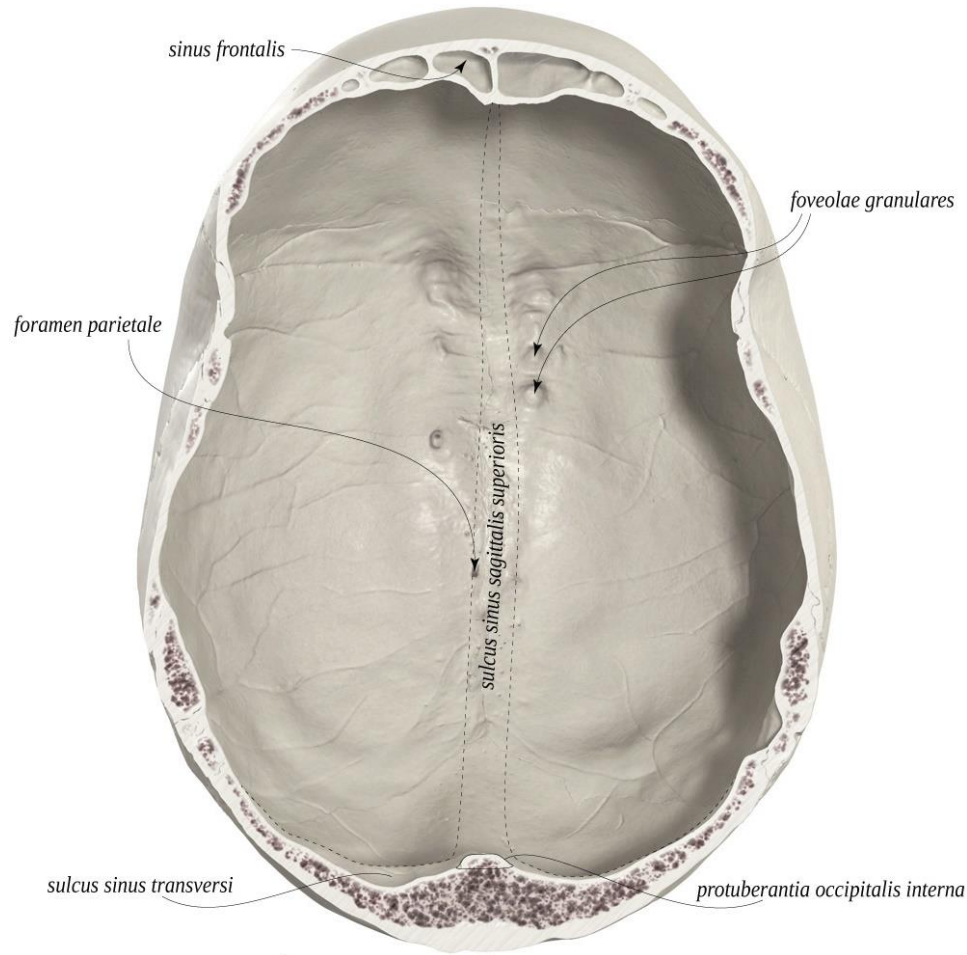
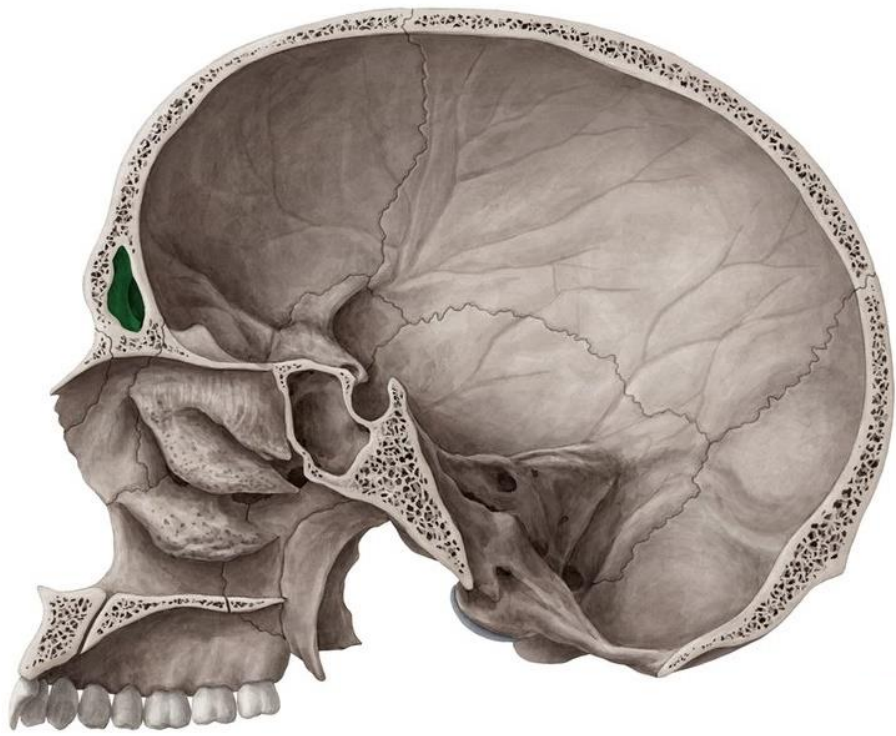
fossa glandulae lacrimalis

foramen ethmoidale anterius et posterius

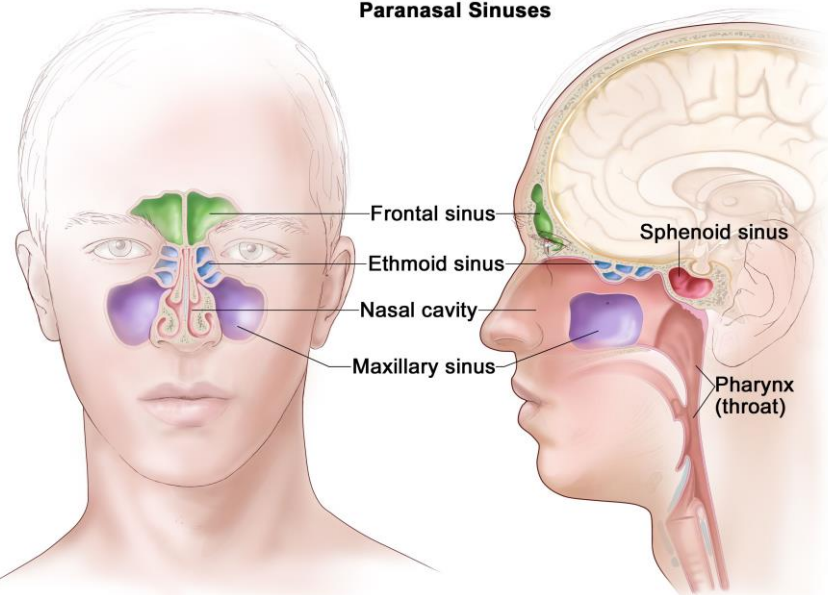
Pars nasalis (nosní část)

sinus frontalis

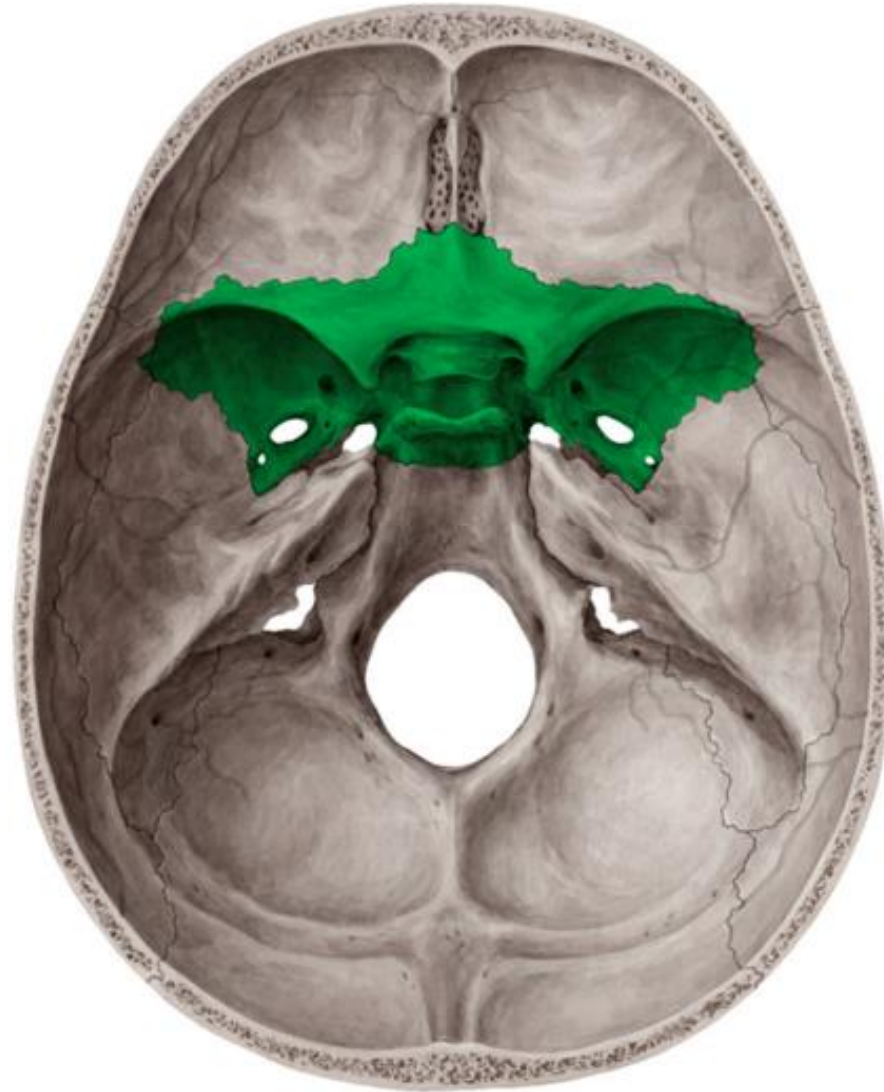



Paranasal Sinuses



Os sphenoidale



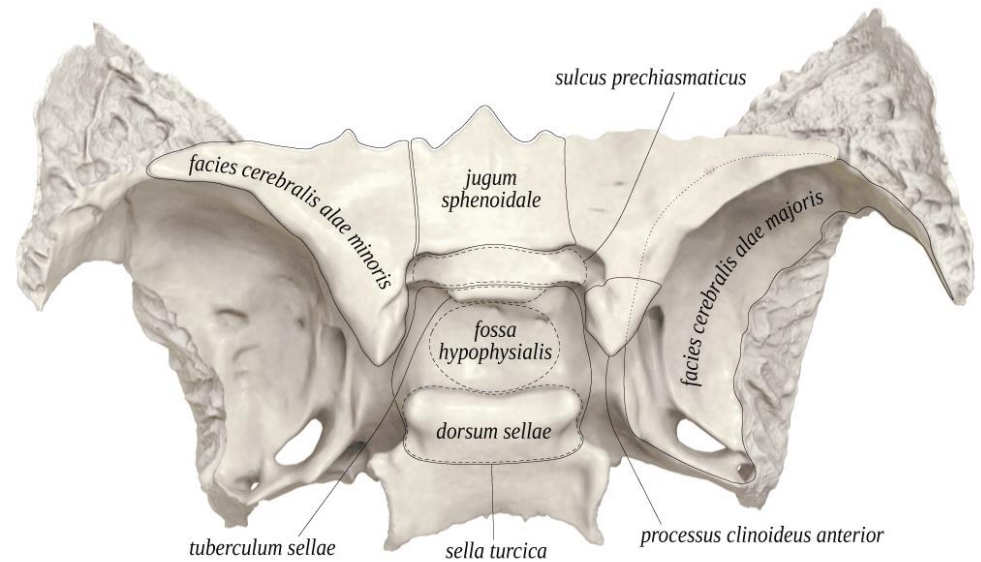
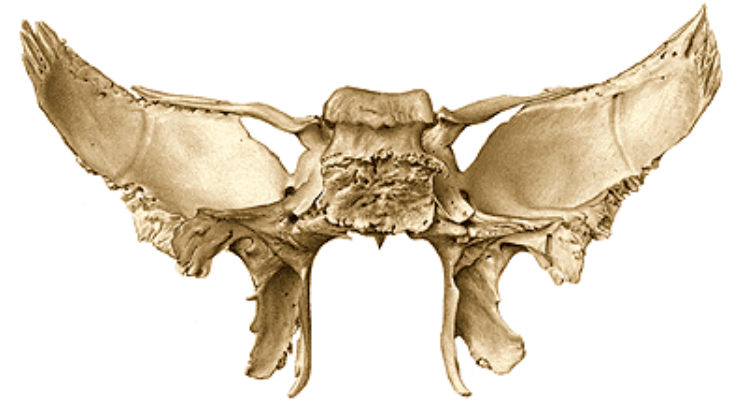
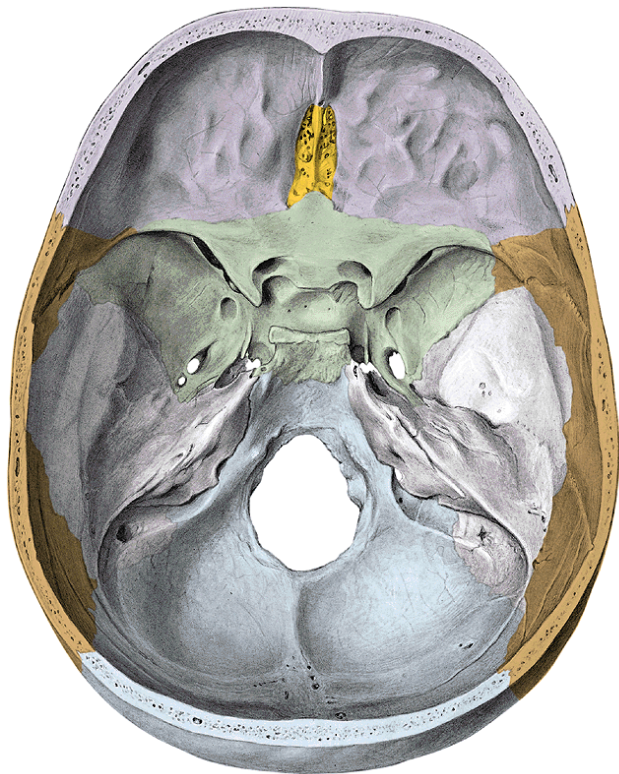

Os sphenoidale

Corpus ossis sphenoidalis (tělo)

Alae minores (malá křídla)

Alae majores (velká křídla)

Processus pterygoidei (křídlaté výběžky)



Corpus ossis sphenoidalis

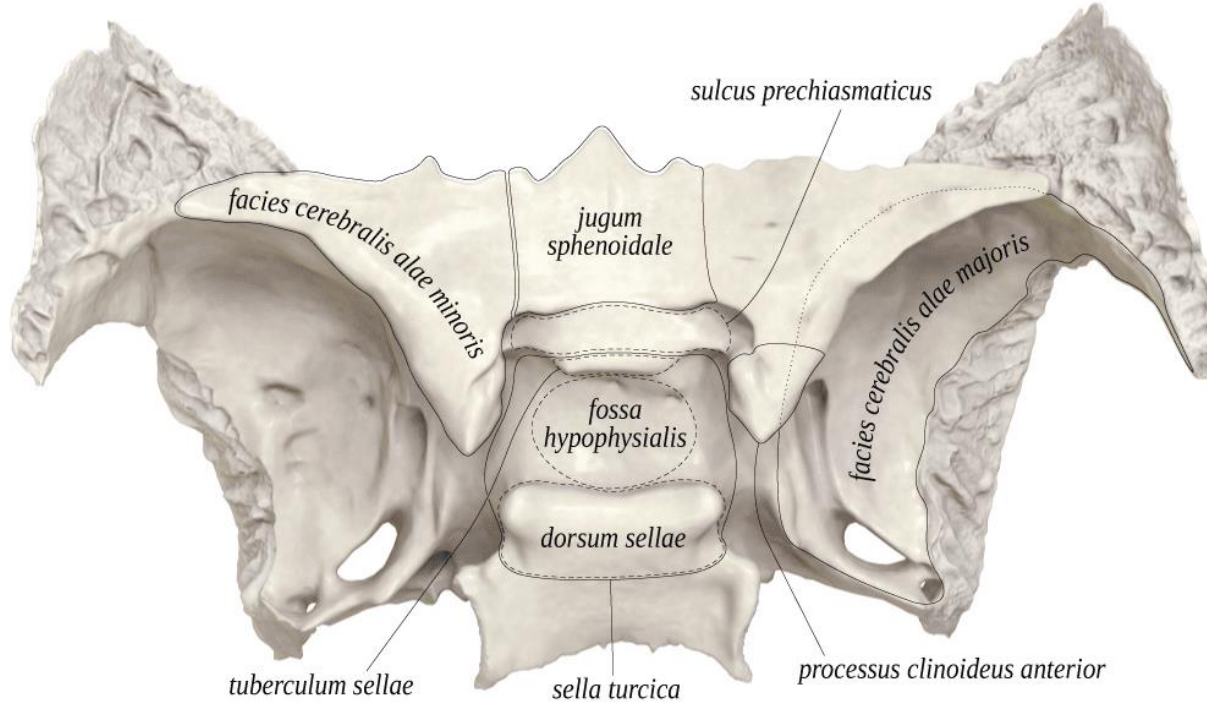
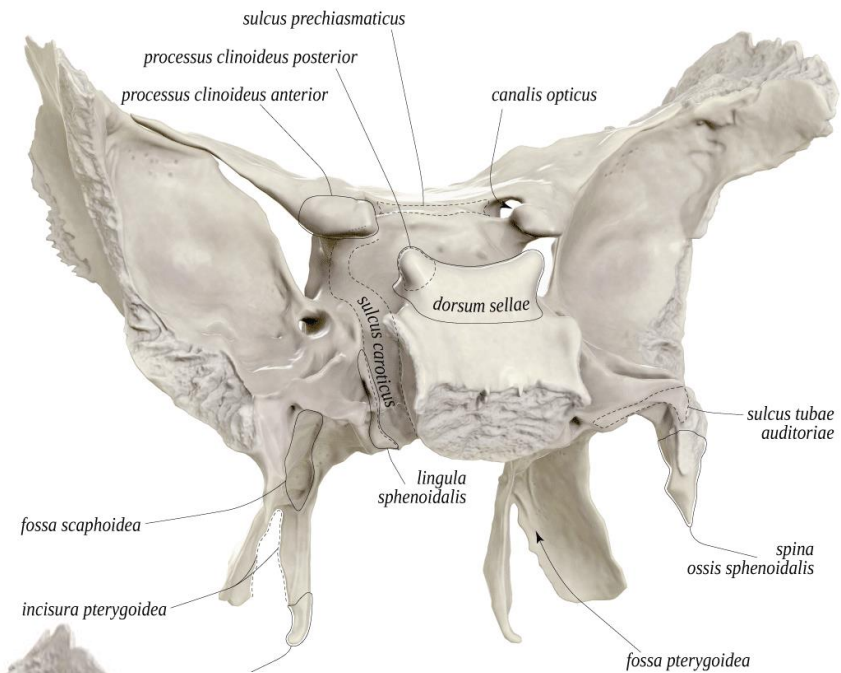
sinus sphenoidalis

sulcus praechiasmaticus

sella turcica - fossa hypophysialis

- dorsum sellae

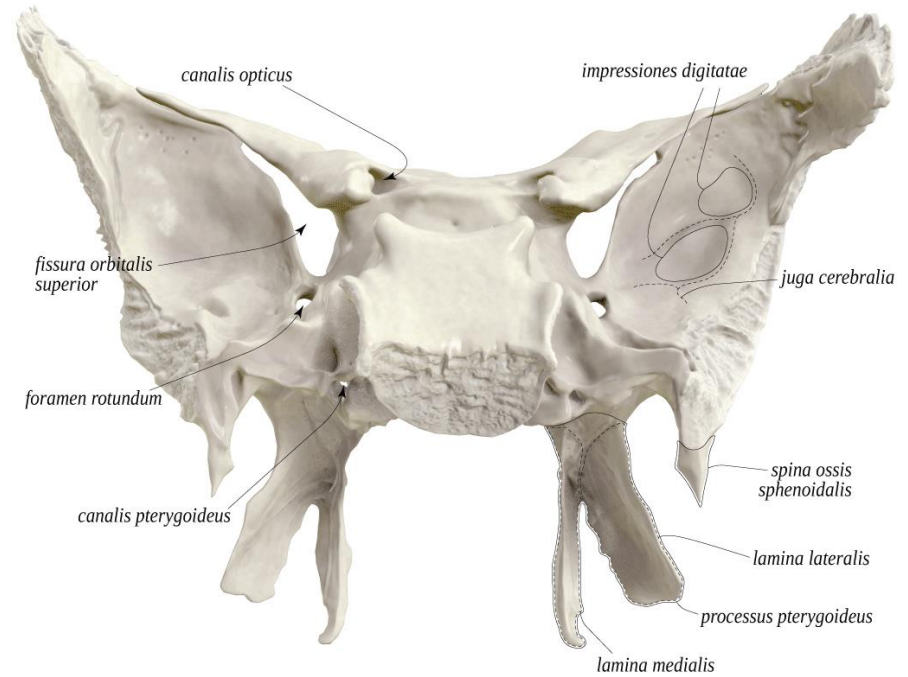
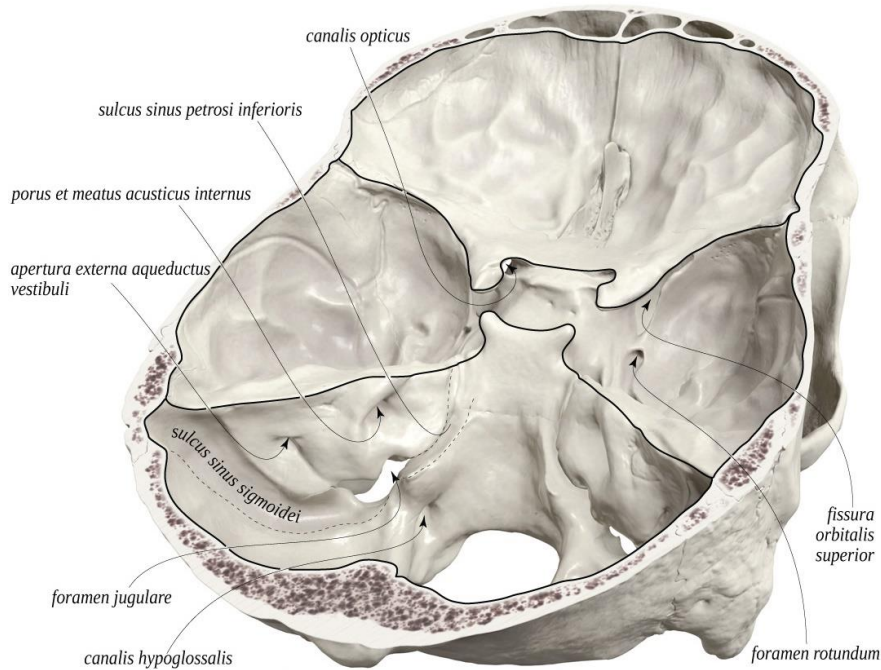
sulcus caroticus



Alae minores ossis sphenoidalis

(malá křídla klínové kosti)

fissura orbitalis superior
canalis opticus
processus clinoides anteriores

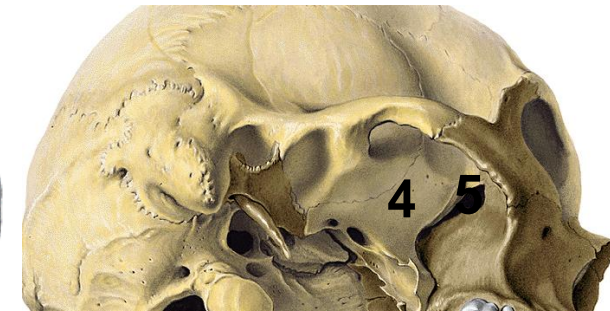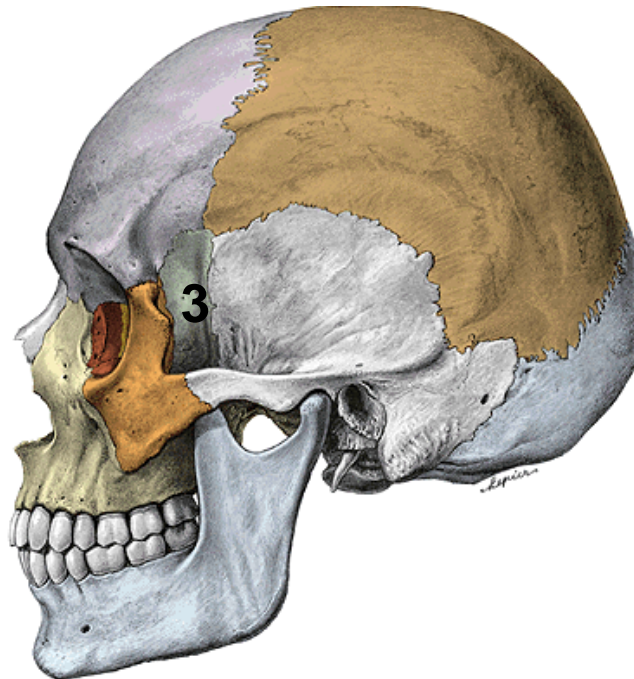
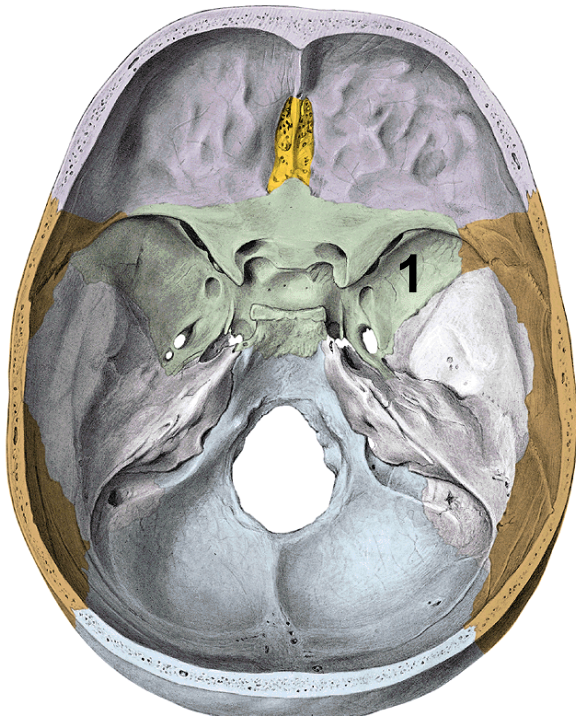
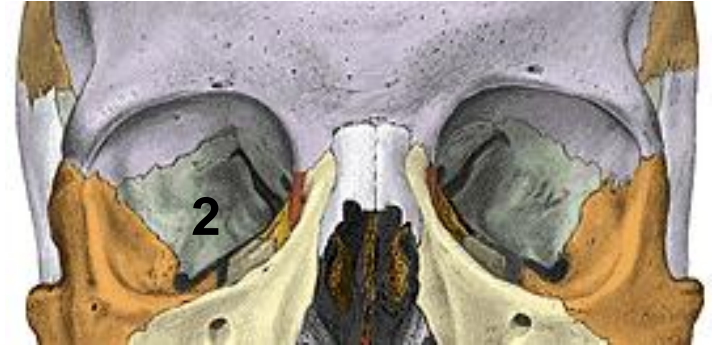


Alae majores ossis sphenoidalis

(velká křídla kosti klínové)

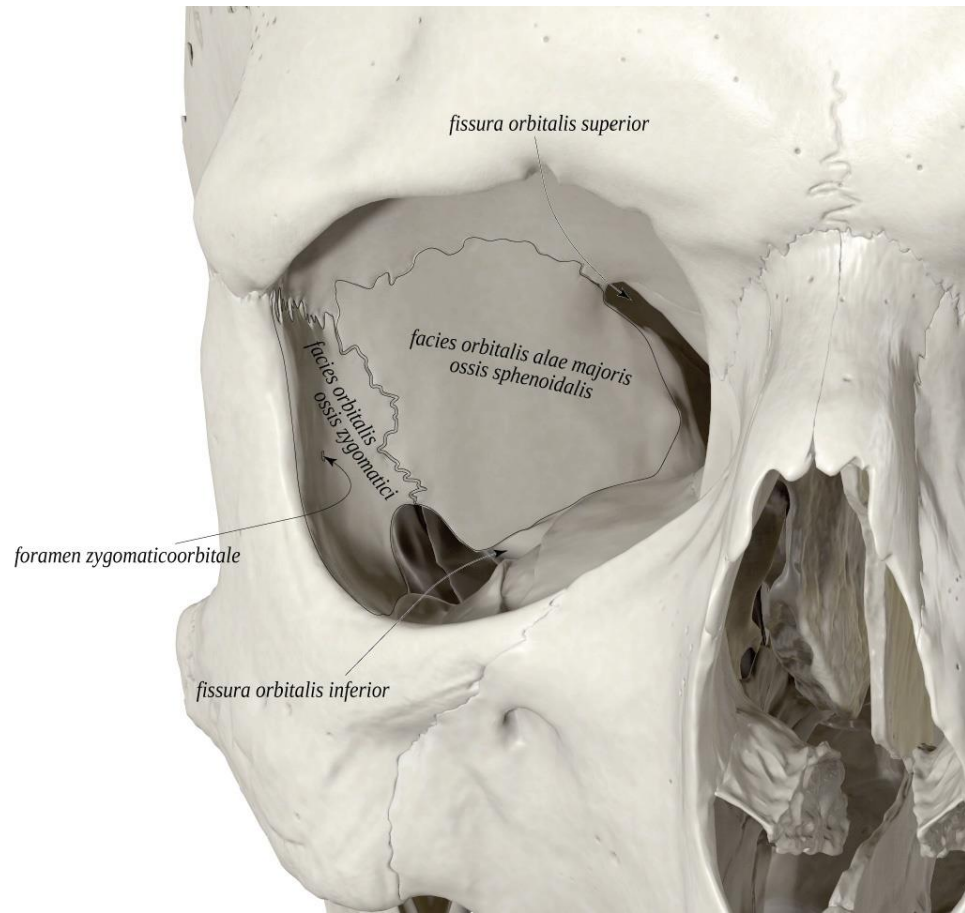
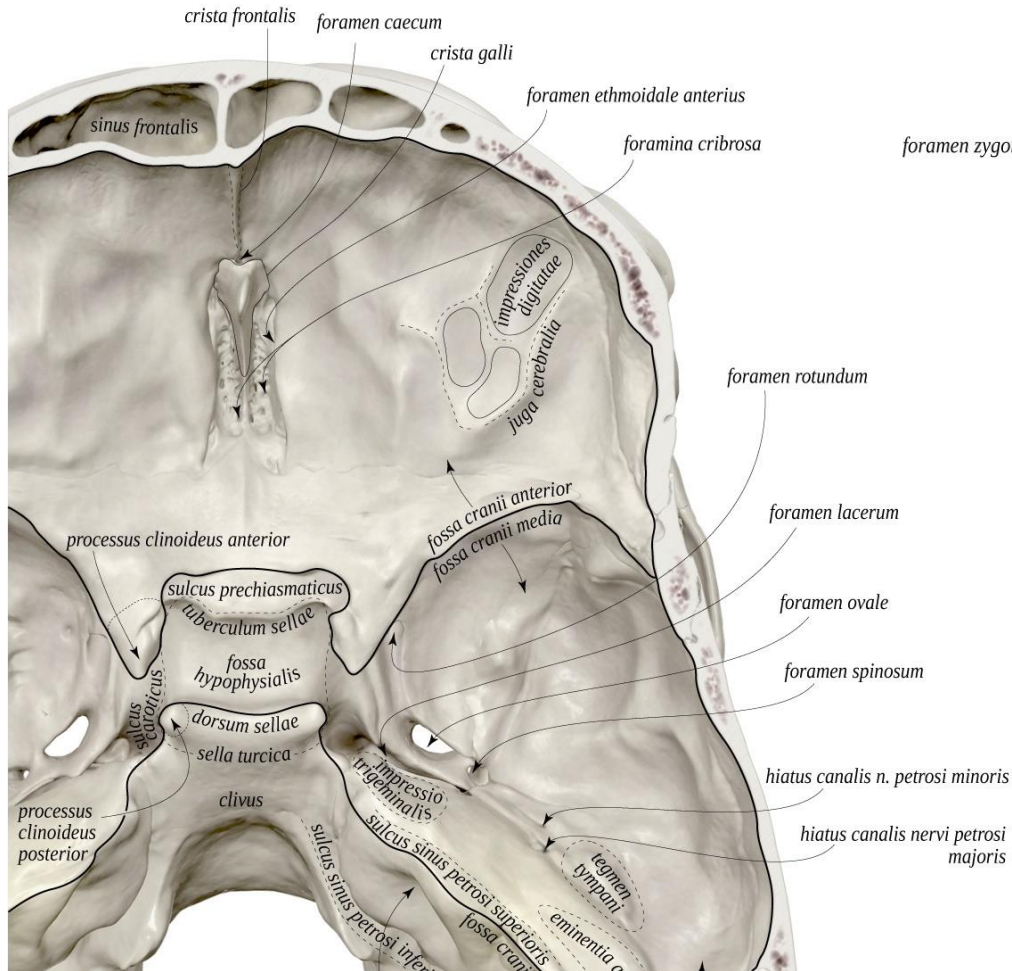
obrací se do: střední jámy lební, očníce, spánkové jámy, infratemporální jámy, fossa pterygopalatina

1. ***Facies cerebralis***
2. ***Facies orbitalis***
3. ***Facies temporalis (crista infratemporalis)***
4. ***Facies infratemporalis***
5. ***Facies maxillaris (na stropu fossa pterygopalatina)***



foramen rotundum (V2)
foramen ovale (V3)
foramen spinosum (pro arterii)

fissura orbitalis superior
fissura orbitalis inferior



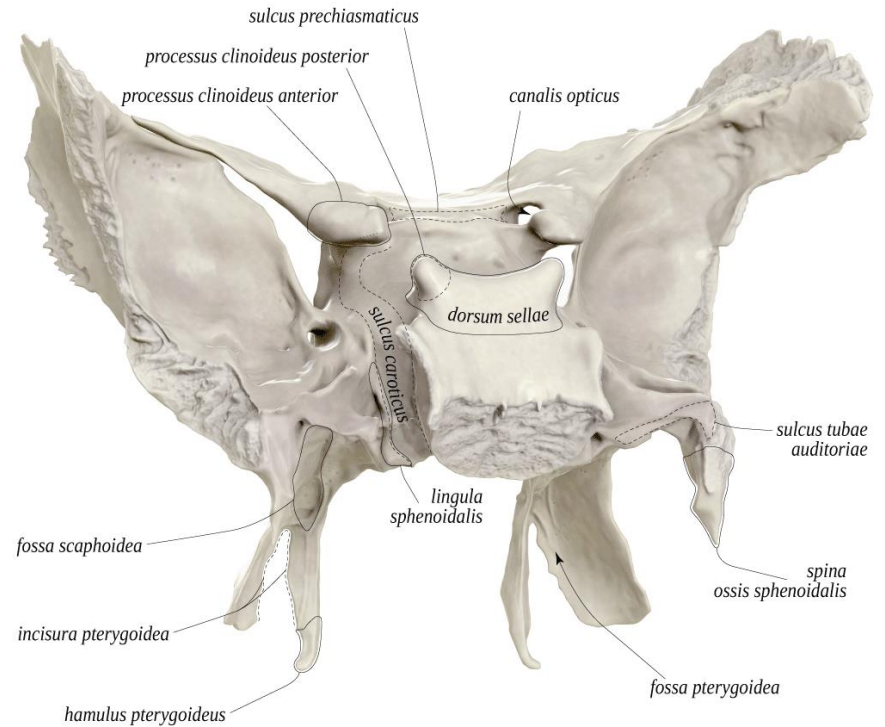
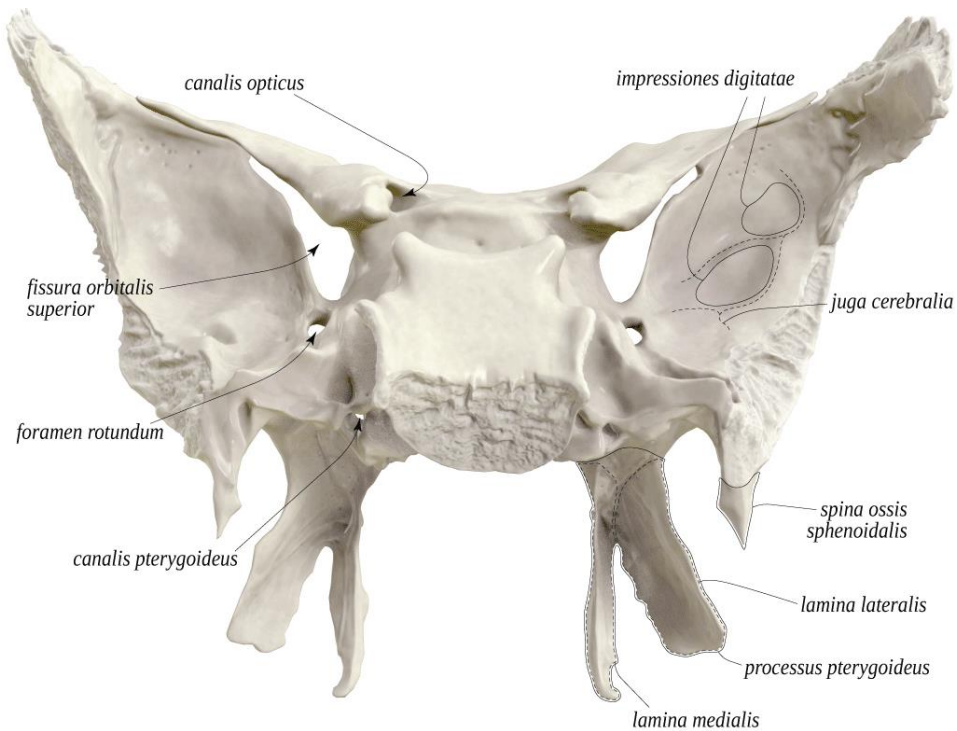
Processus pterygoideus ossis sphenoidalis

lamina medialis (+hamulus pterygoideus)

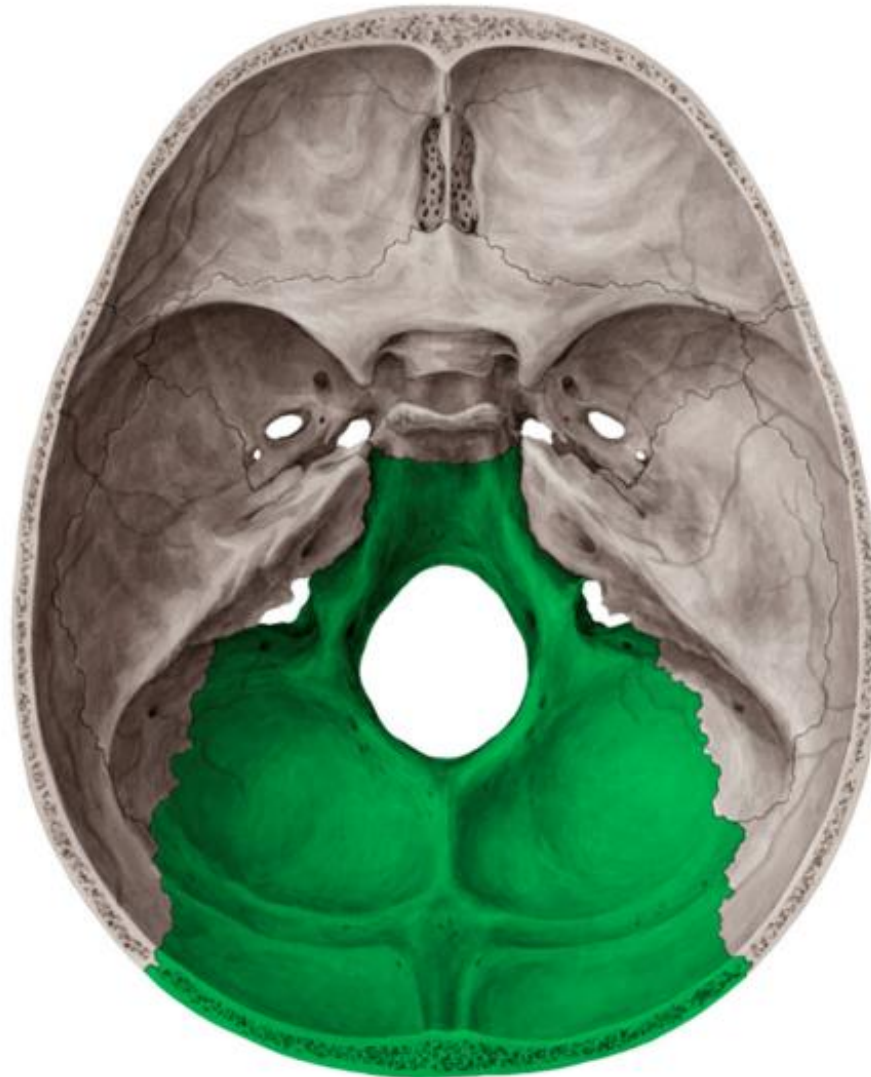
lamina lateralis

fossa pterygoidea

canalis pterygoideus (při bázi)



Os occipitale



Os occipitale

1. partes laterales

condyli occipitales

incisura jugularis

canalis (nervi) hypoglossi

2. pars basilaris

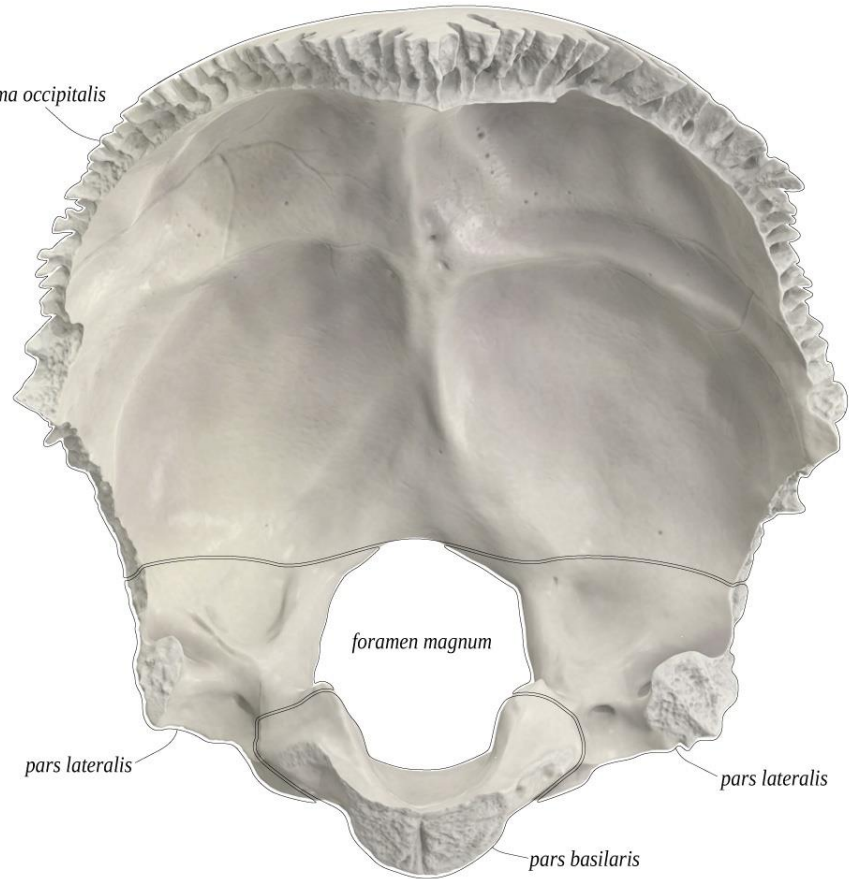
synostosis (synchondrosis)

sphenooccipitalis

clivus (leží na něm mozkový kmen)

tuberculum pharyngeum

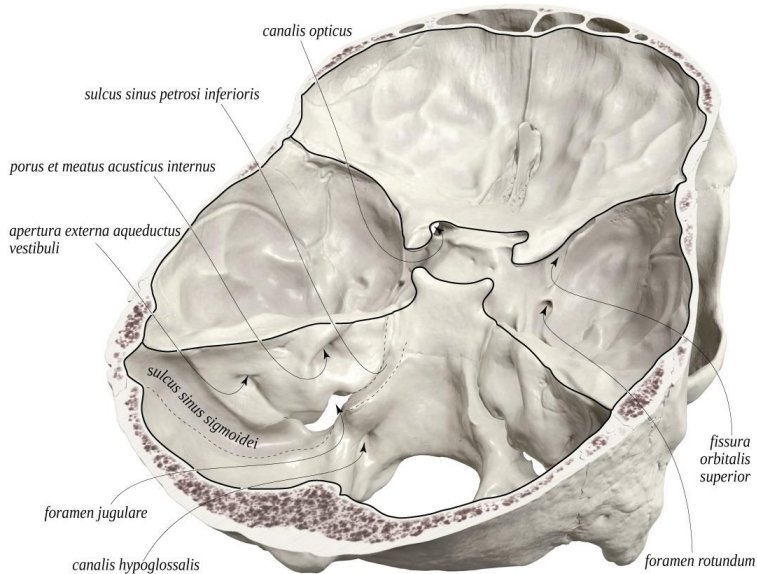
squama occipitalis



pars lateralis

pars lateralis

pars basilaris



canalis opticus

sulcus sinus petrosi inferioris

porus et meatus acusticus internus

apertura externa aqueductus vestibuli

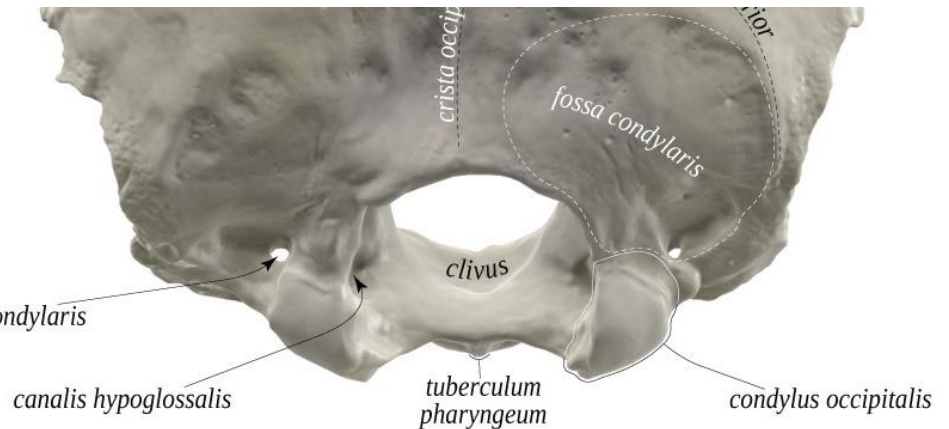
sulcus sinus sigmoidei

foramen jugulare

canalis hypoglossalis

fissura orbitalis superior

foramen rotundum



crista occipitalis superior

fossa condylaris

clivus

tuberculum pharyngeum

condylus occipitalis

canalis hypoglossalis

lis condylaris

3. squama occipitalis

exokraniální povrch:

protuberantia occipitalis externa

crista occipitalis externa

linea nuchae suprema

linea nuchae superior

linea nuchae inferior

endokraniální povrch:

eminentia cruciformis

crista occipitalis interna

sulcus sinus sagitalis superior

sulcus sinus transversi

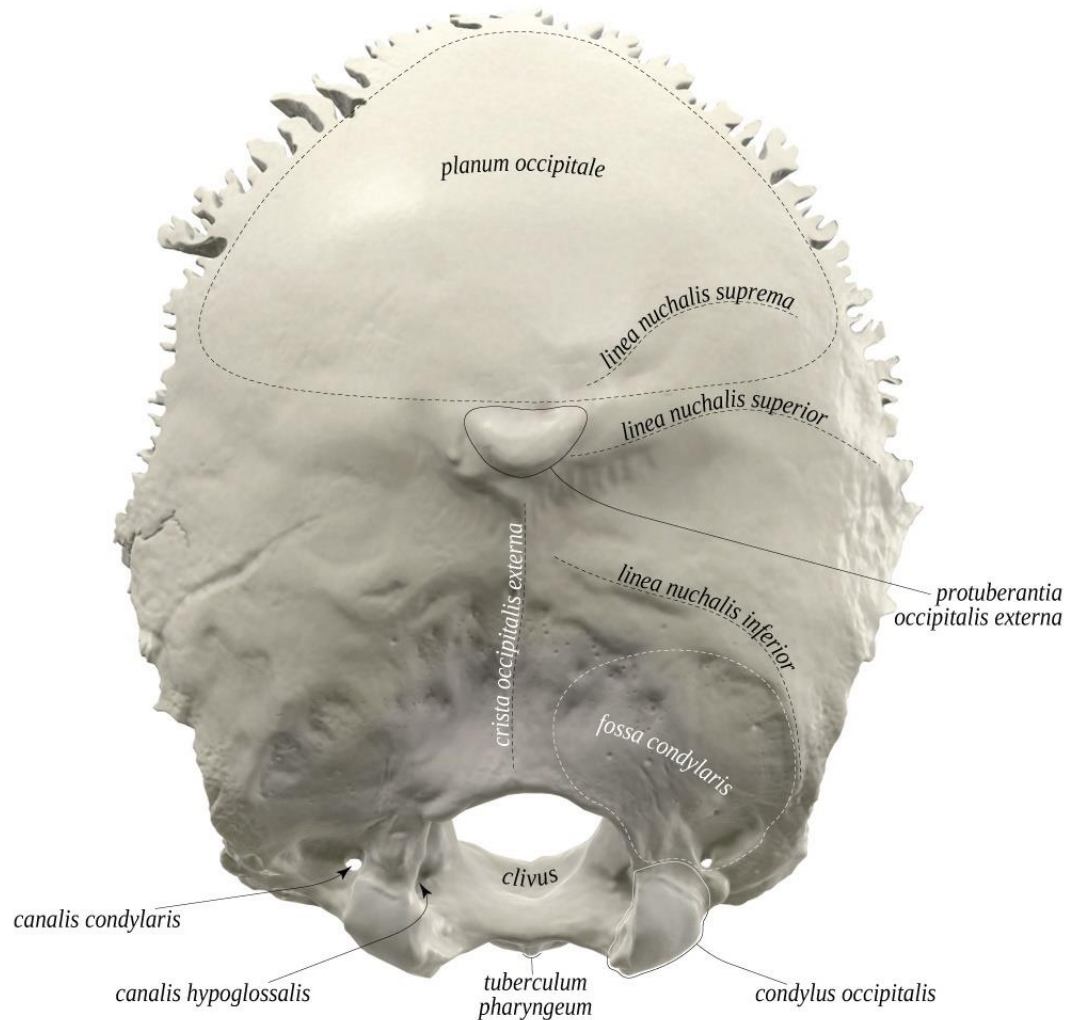
protruberentia occipitalis interna

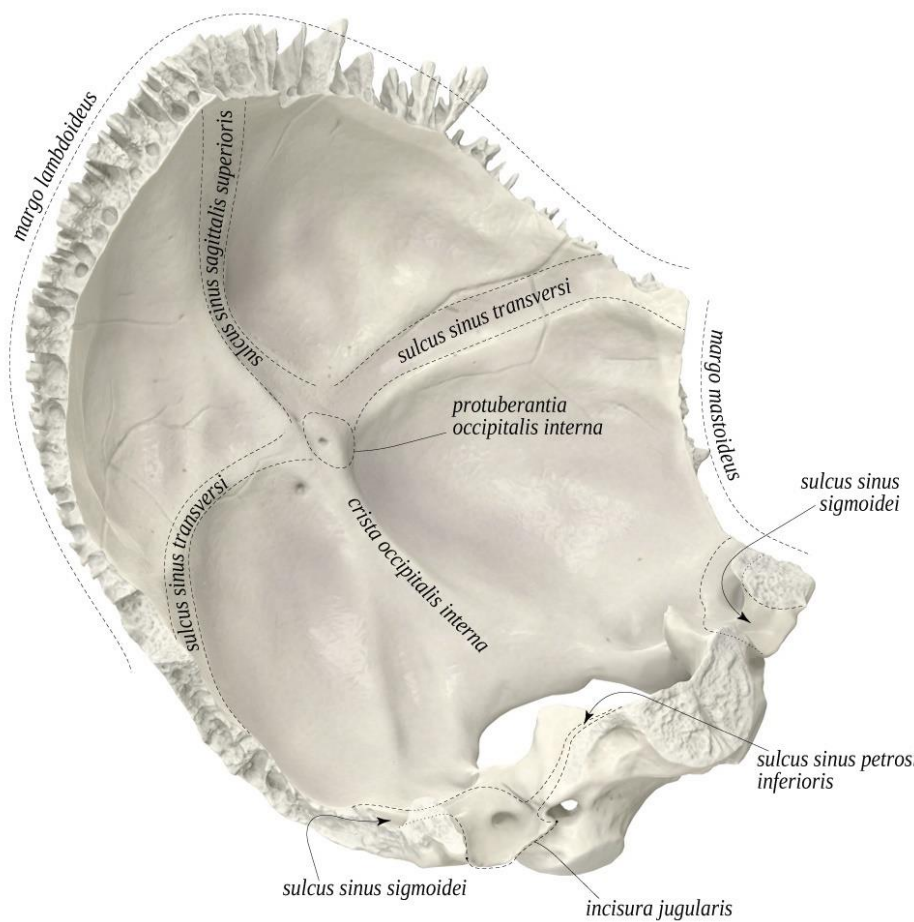
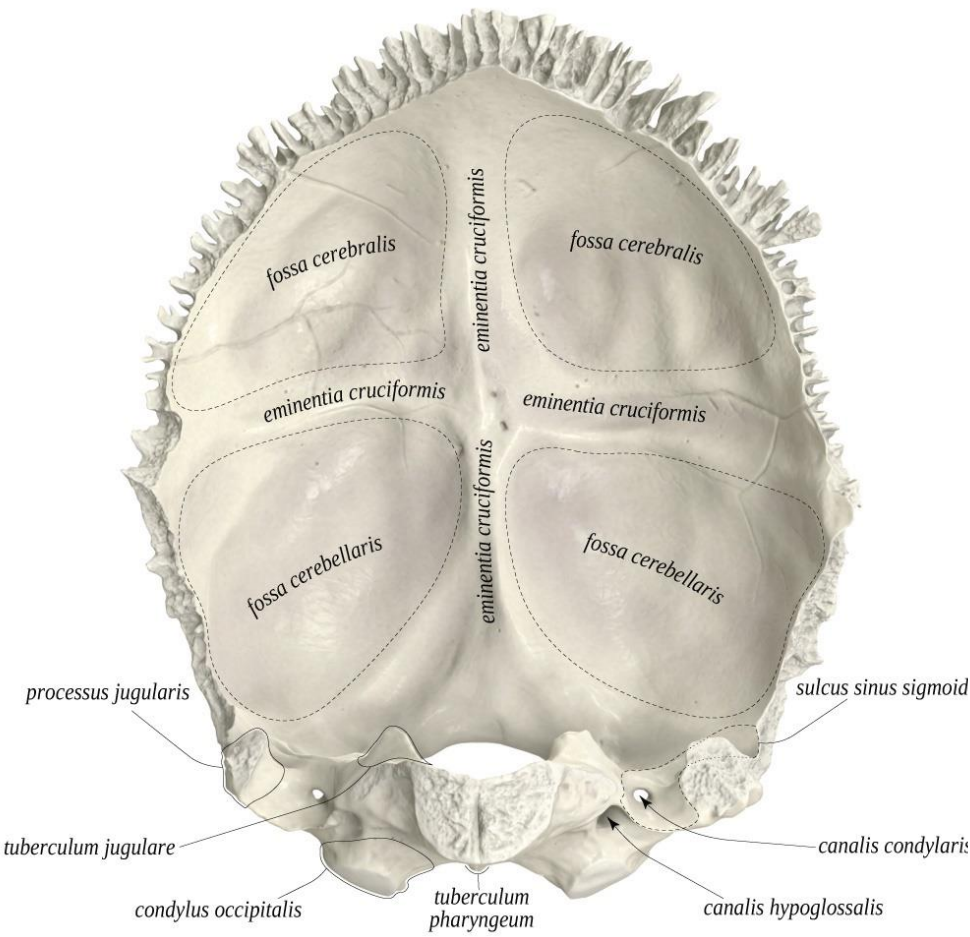
sulcus sinus sigmoidei

fossae cerebrales

fossae cerebellares

formane magnum



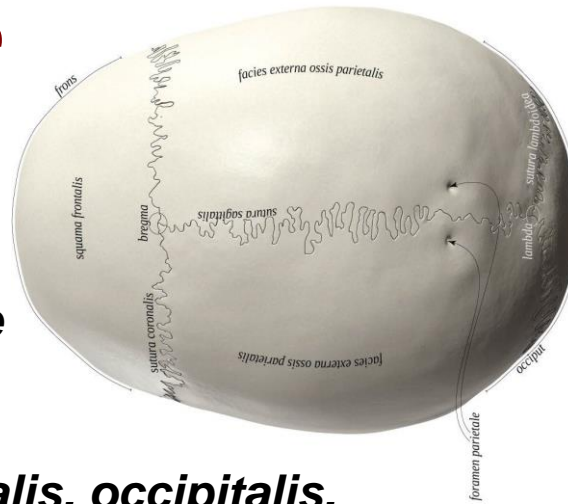


Os parietale



Os parietale

sutura coronalis
sutura sagittalis
sutura lambdoidea
suturae squamosae



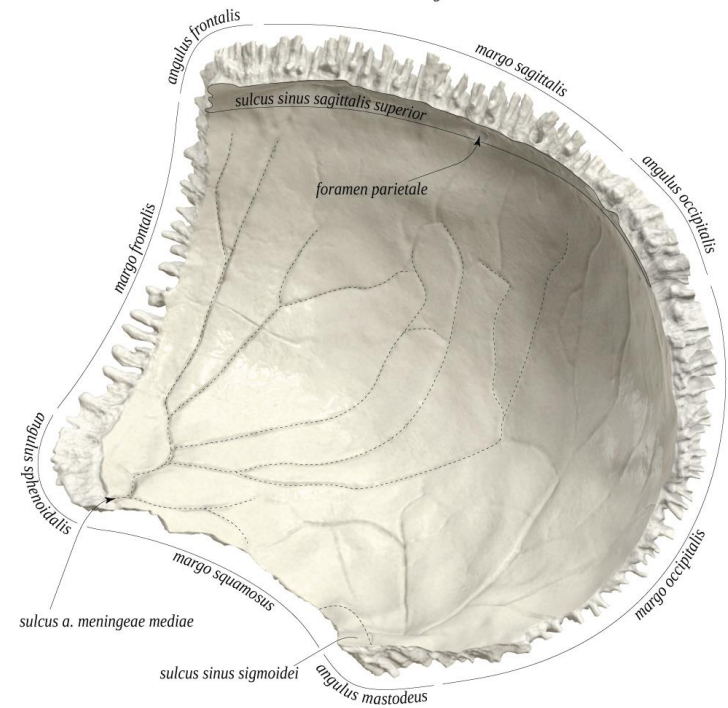
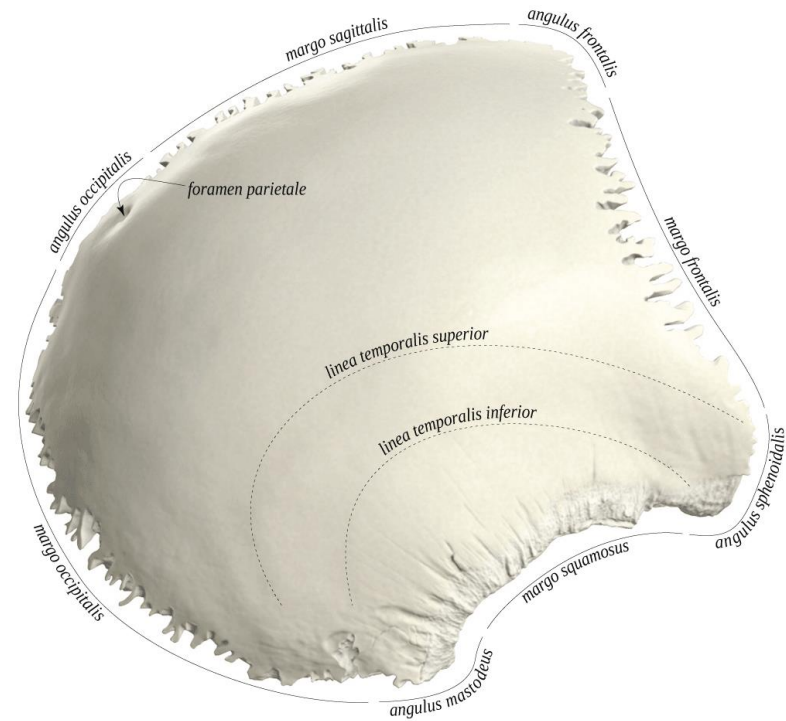
Angulus
frontalis, sphenoidalis, occipitalis,
mastoideus

Exokraniální plocha:

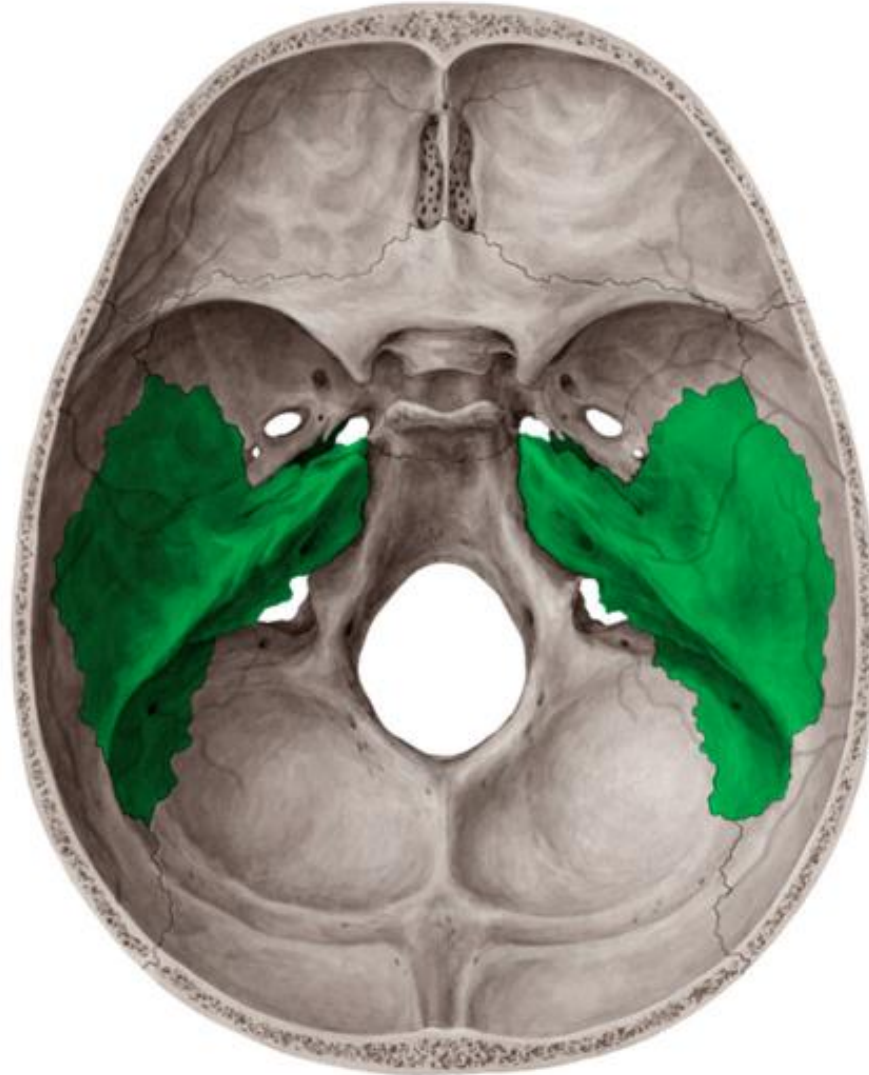
tubera parietalia
linea temporalis superior
linea temporalis inferior
foramen parietale

Endokraniální plocha:

sulcus sinus sagittalis superioris
sulci arteriae meningae mediae

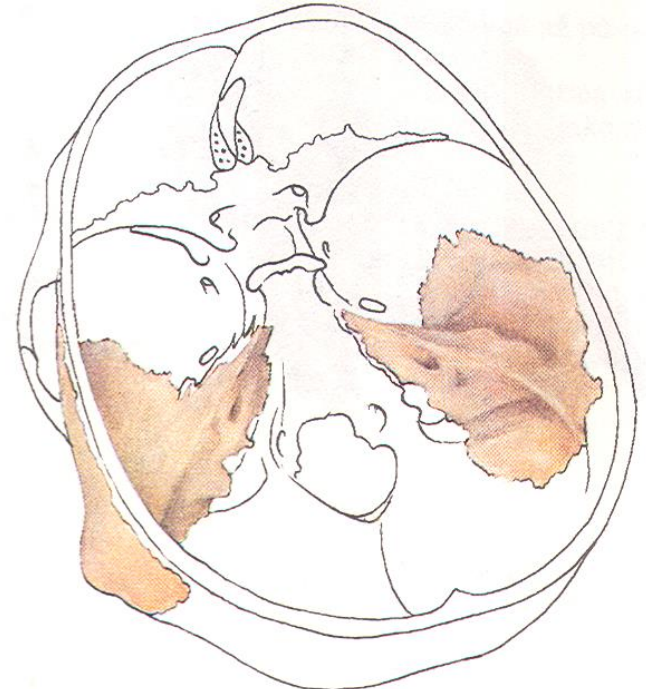
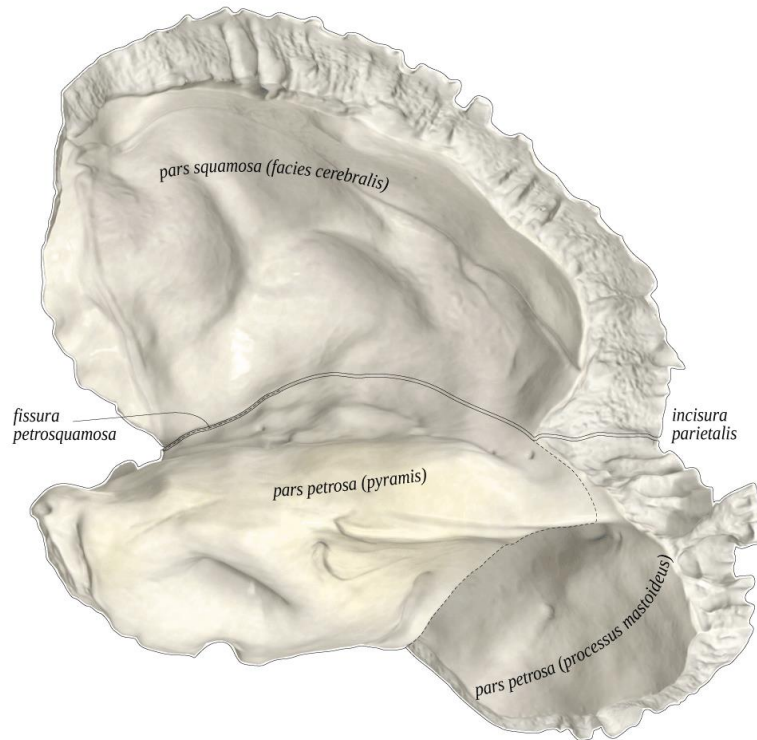
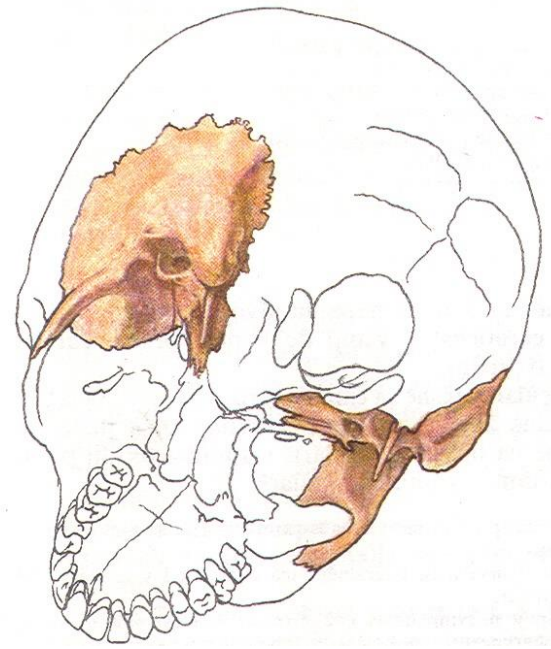
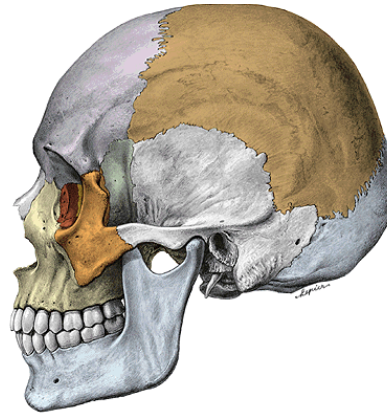


Os temporale



Os temporale

1. *Pars squamosa*
2. *Pars petrosa (pyramis)*
3. *Pars mastoidea*
4. *Pars tympanica*
5. *Processus styloideus*

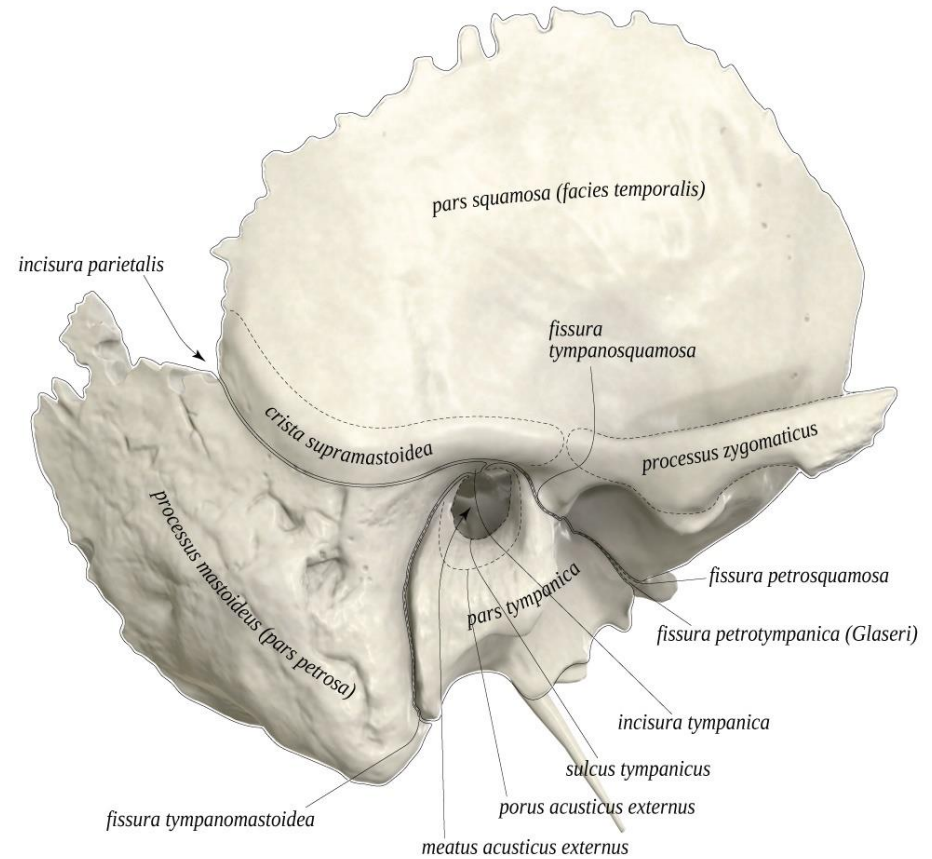
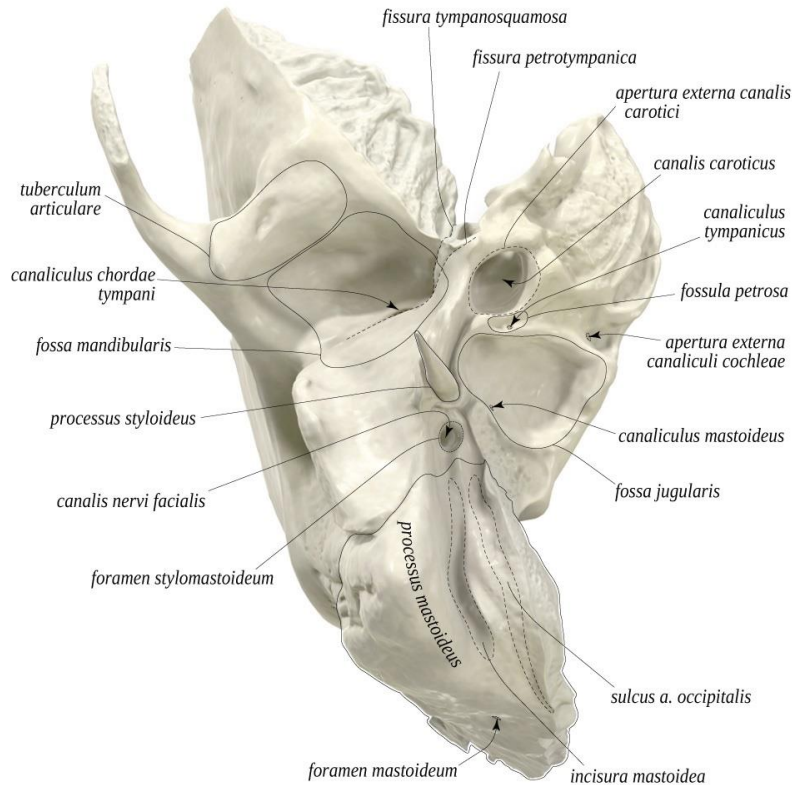


1. Pars squamosa ossis temporalis

processus zygomaticus – arcus zygomaticus

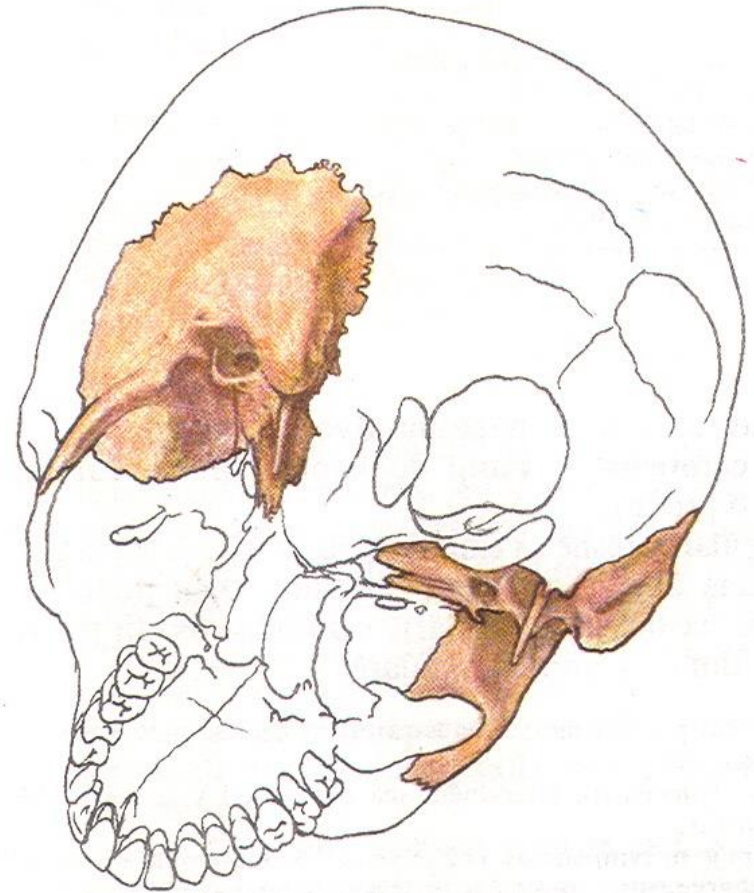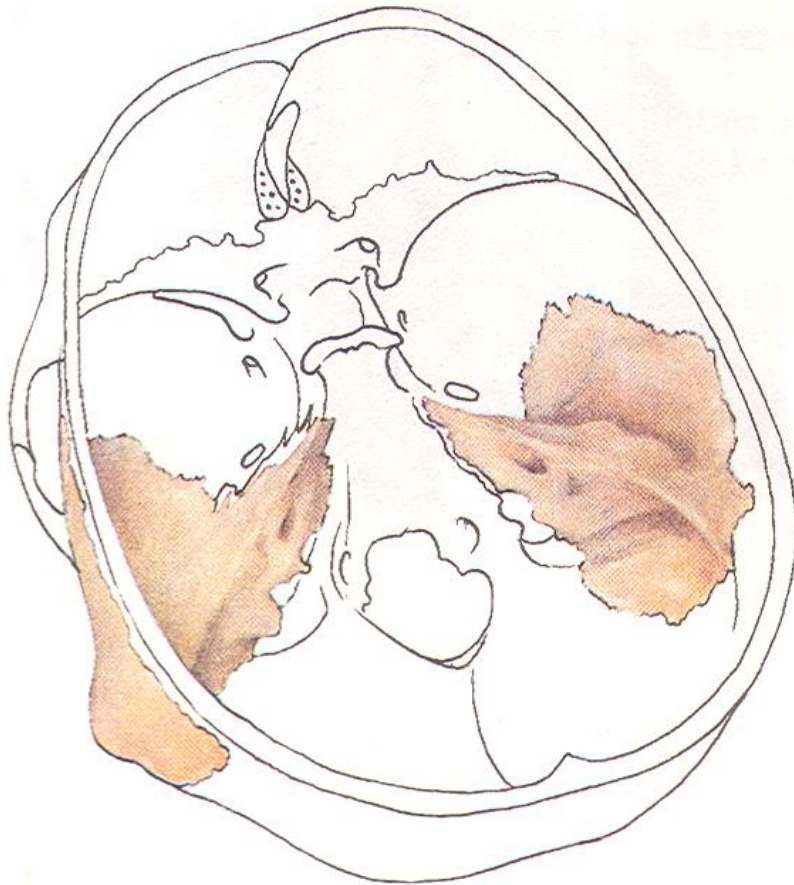
fossa mandibularis

tuberculum articulare



2. Pars petrosa (pyramis)

- a) *Facies anterior (cerebralis) pyramidis*
- b) *Facies posterior*
- c) *Facies inferior*
- d) *Facies ventrobasalis (sluchové ústrojí)*



Facies anterior

apex pyramis

impressio trigeminalis

sulcus nervi petrosi majoris et minoris

canalis musculotubarius

Facies posterior

porus acusticus internus

meatus acusticus internus

fundus meatus acustici interni

(introitus canalis nervi facialis)

incisura jugularis (foramen jugulare)

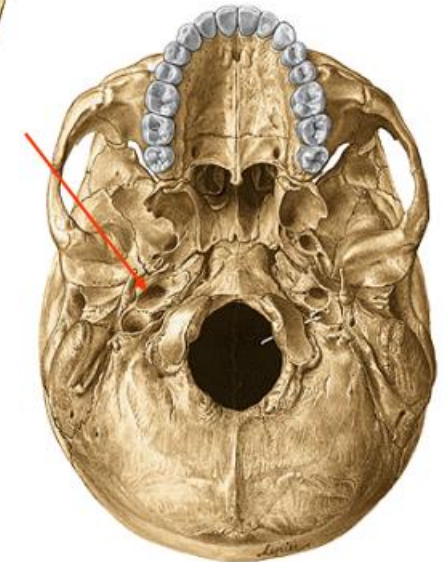
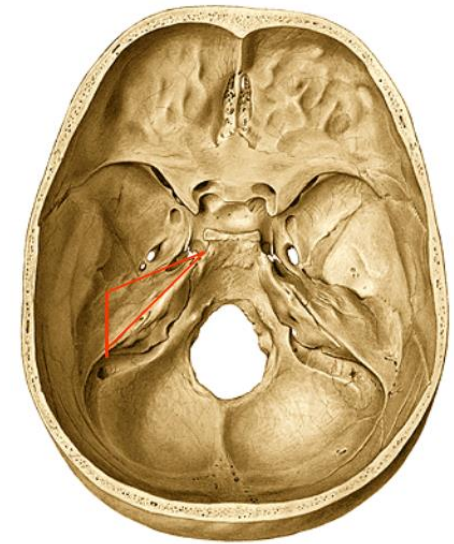
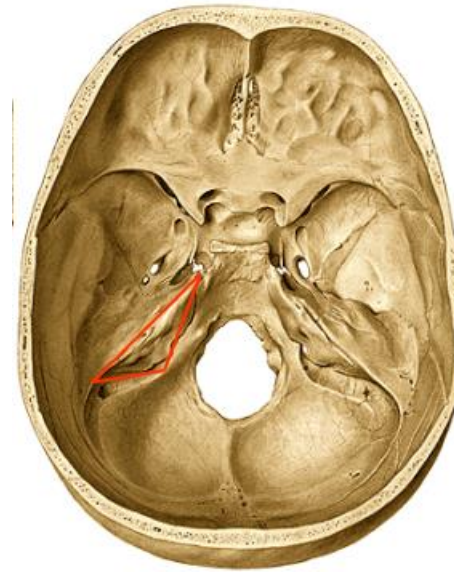
Facies inferior

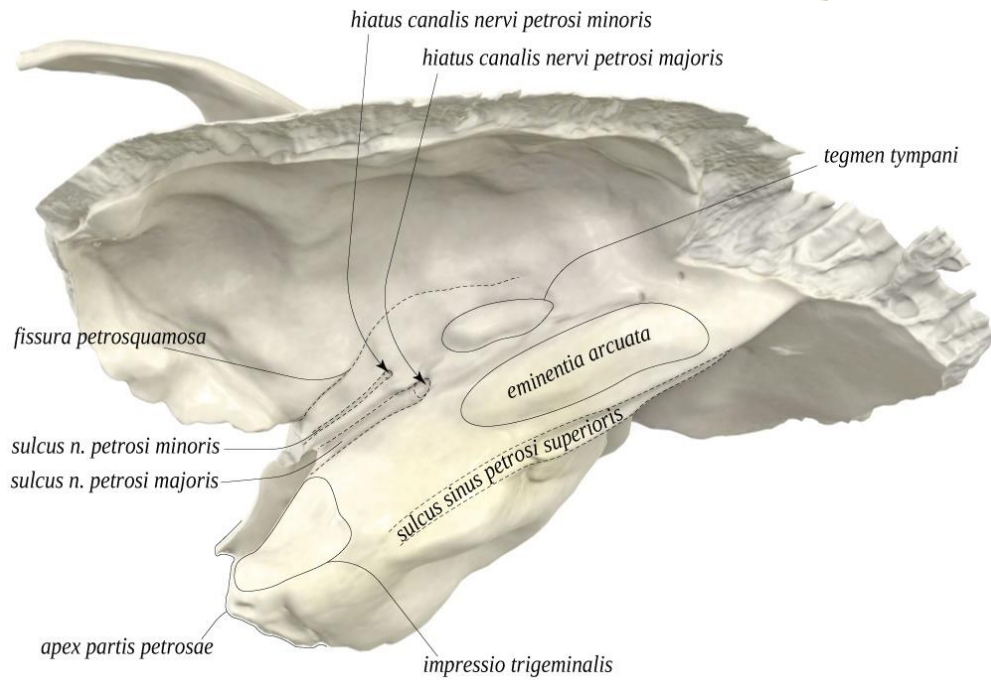
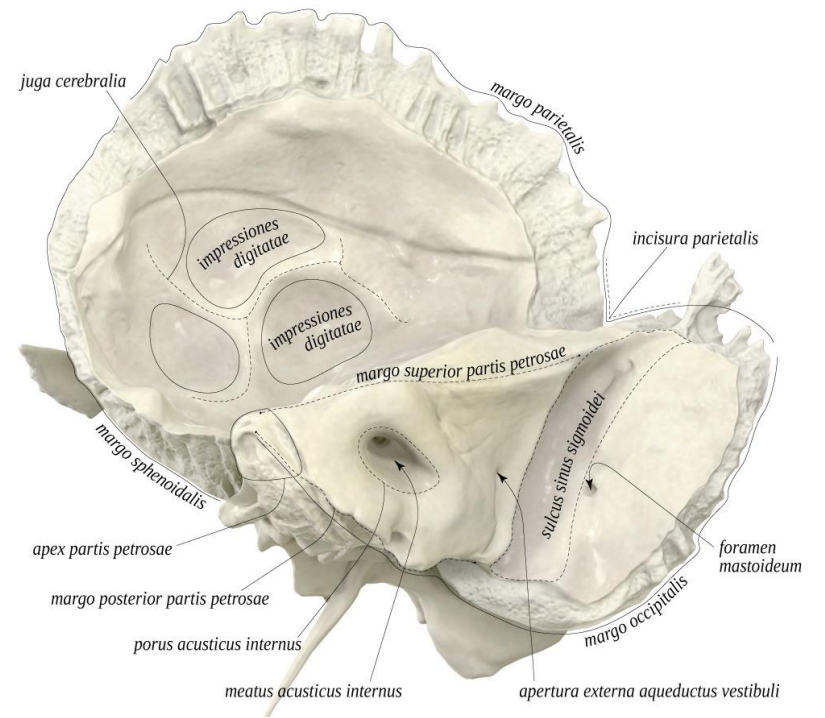
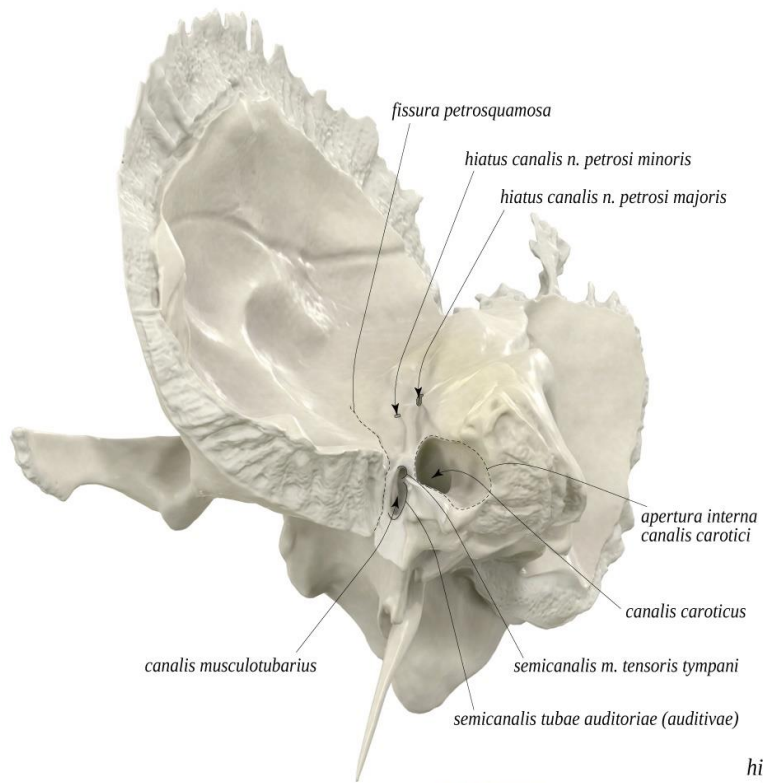
apertura externa canalis carotici

canaliculus mastoideus

apertura externa canaliculi tympanici

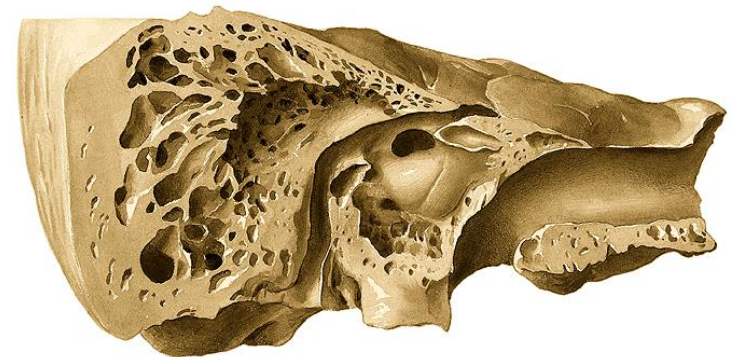
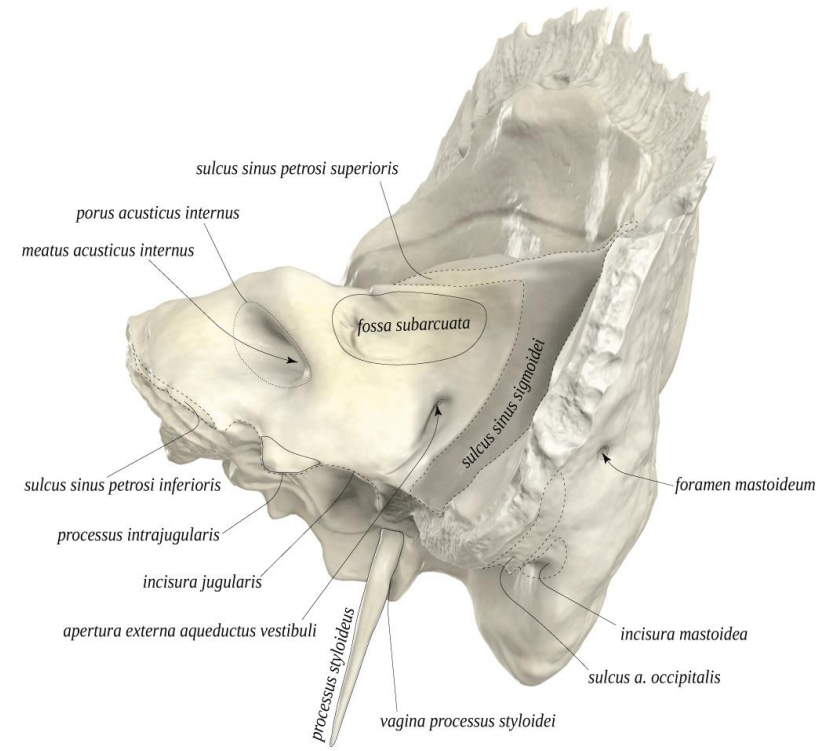
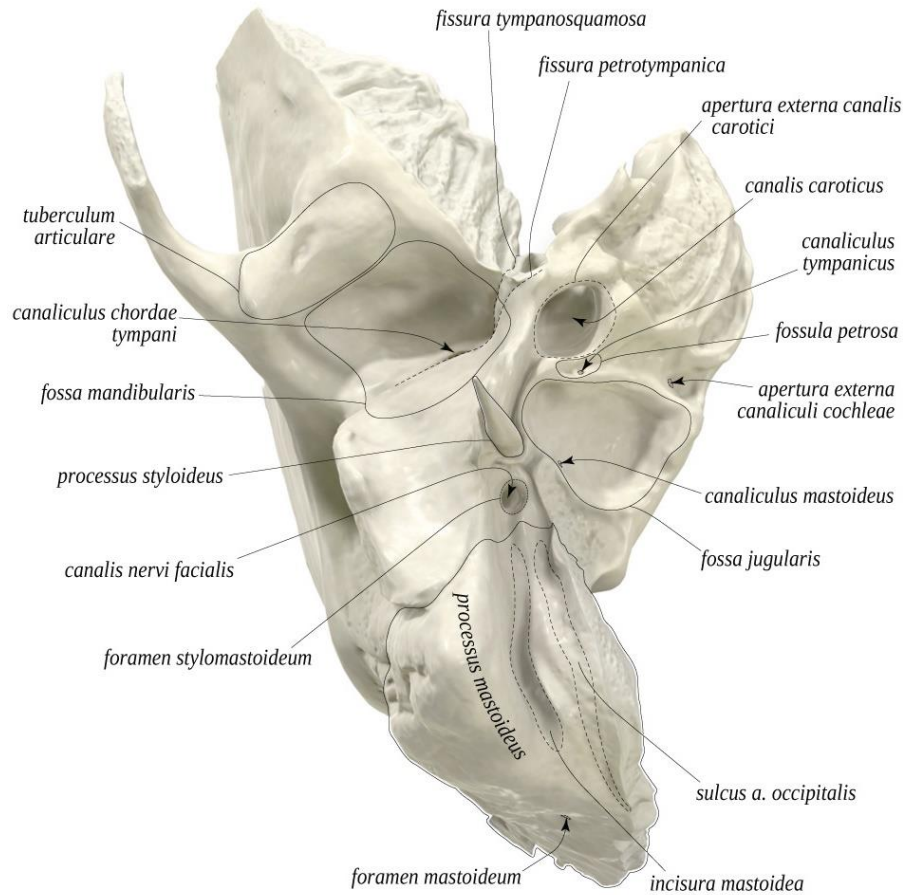
(fossula petrosa)





3. Pars mastoidea ossis temporalis

processus mastoideus
(uvnitř - *cellulae mastoideae*)
incisura mastoidea
sulcus arteriae occipitalis

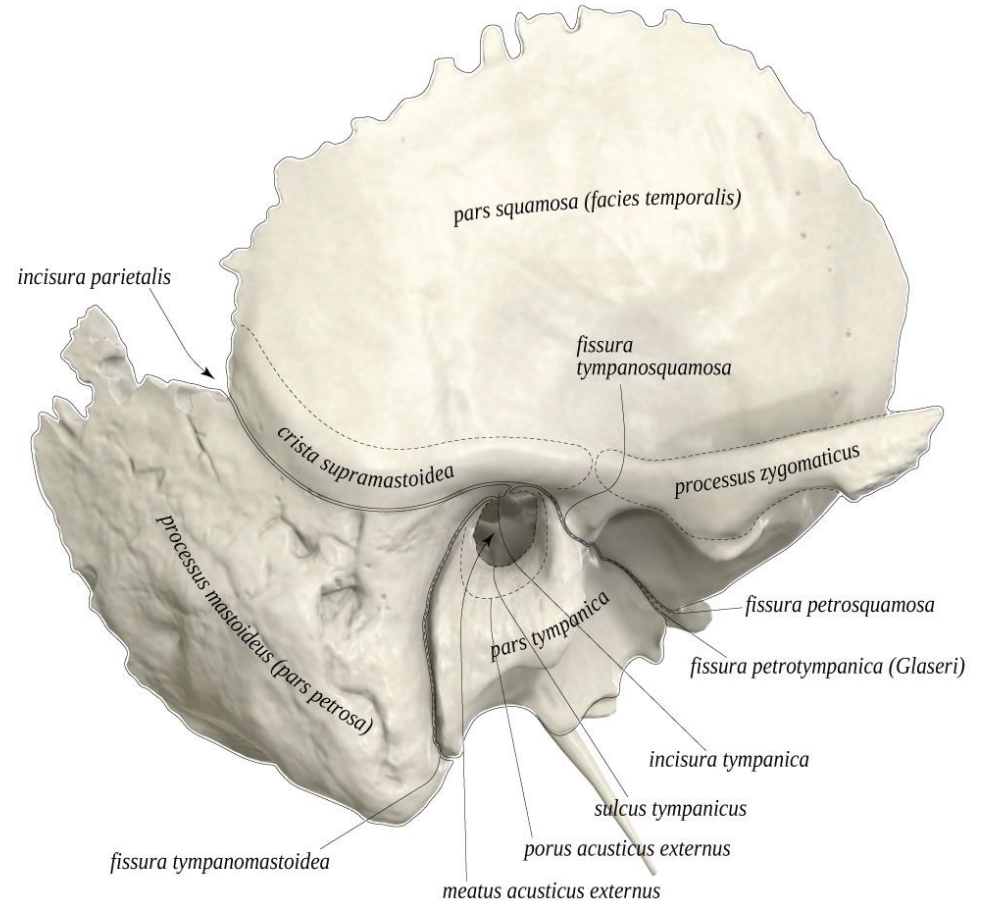
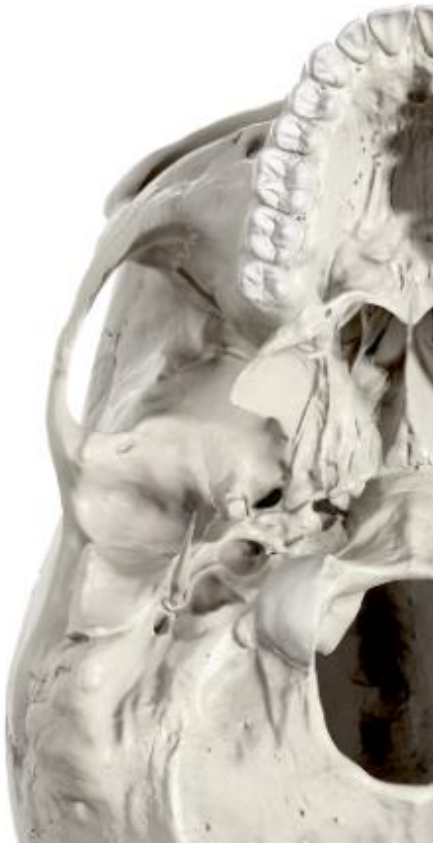

4. Pars tympanica ossis temporalis

porus acusticus externus
meatus acusticus externus

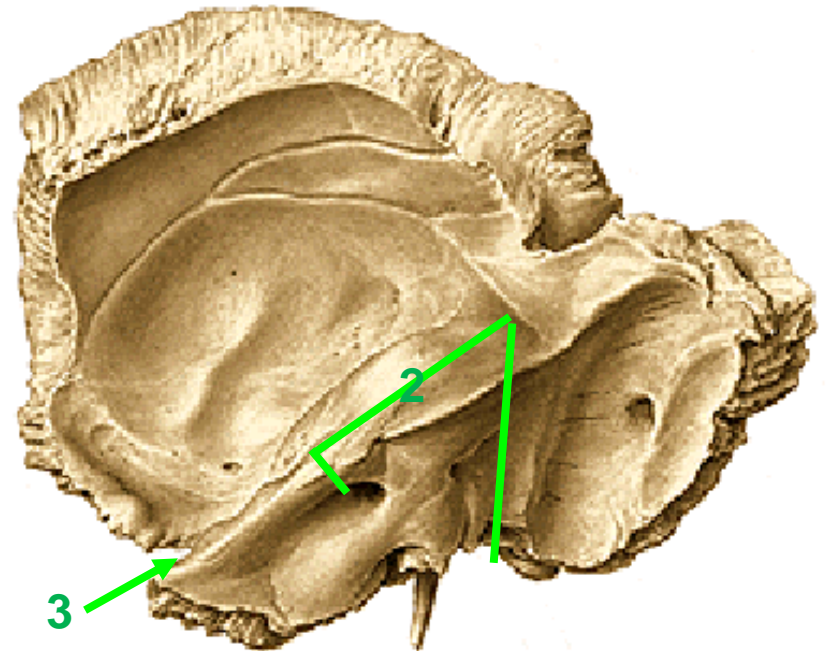
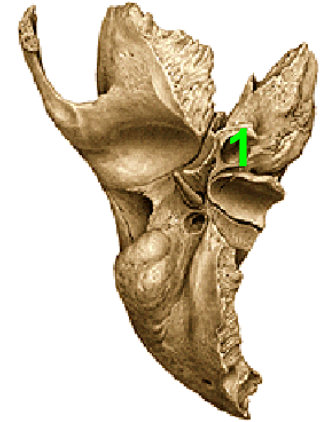
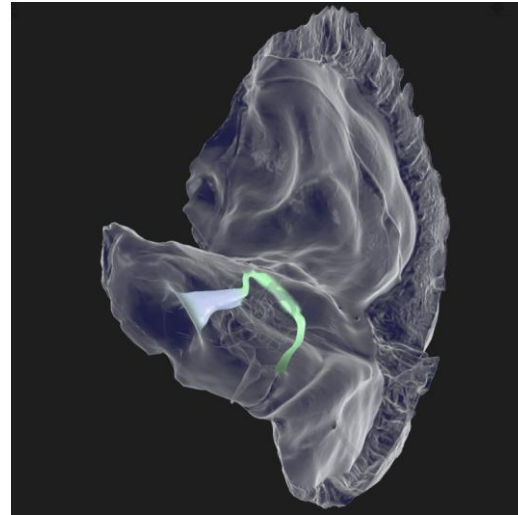
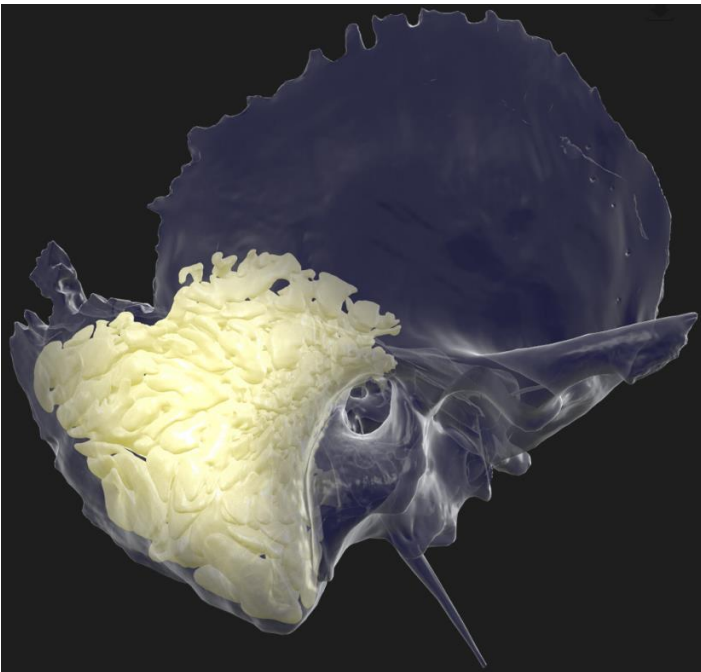
5. Processus styloideus

foramen stylomastoideum



Kanálky v os temporale

1. canalis caroticus
2. canalis nervi facialis
3. canalis musculotubarius



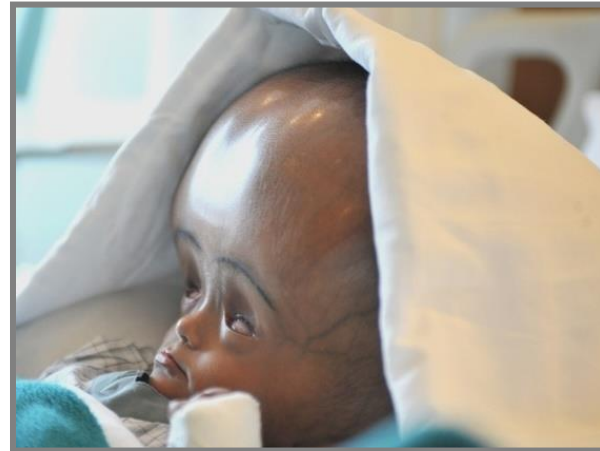
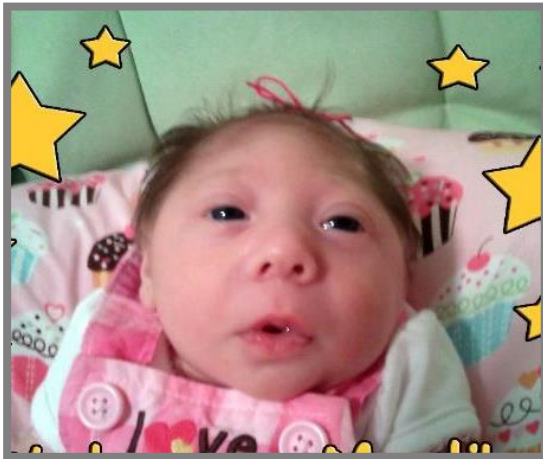Kapacita lebky

Muži asi 1450 ccm

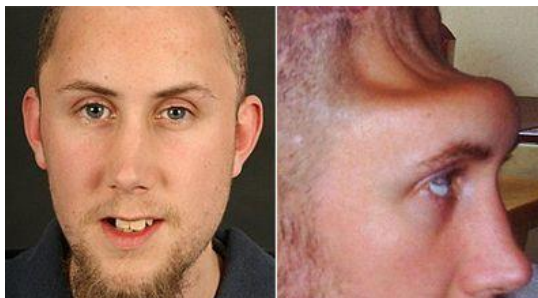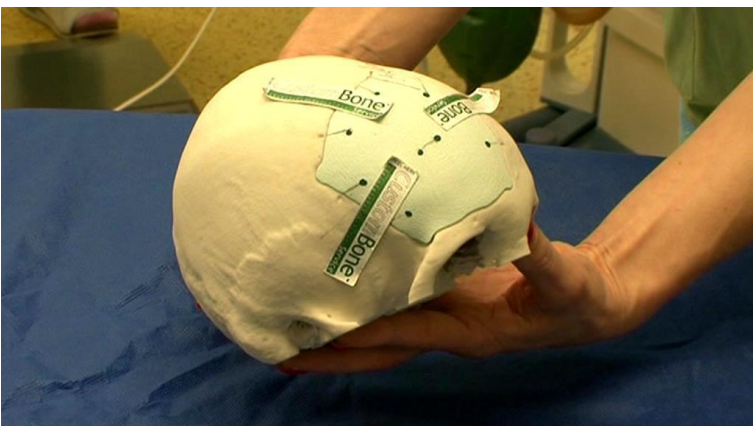

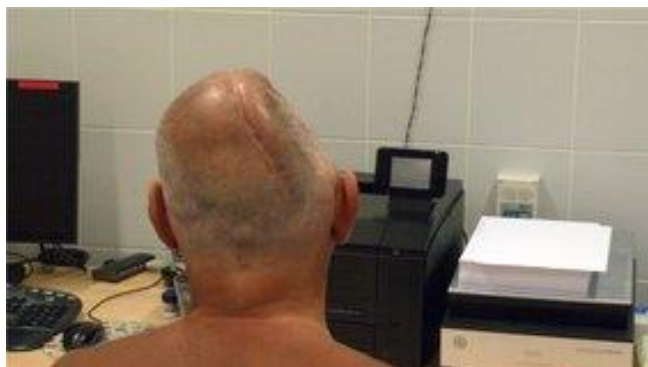Ženy asi 1350 ccm

Microcephalia (méně než 1100 ccm - Anatomické muzeum LF MU)

Macrocephalia

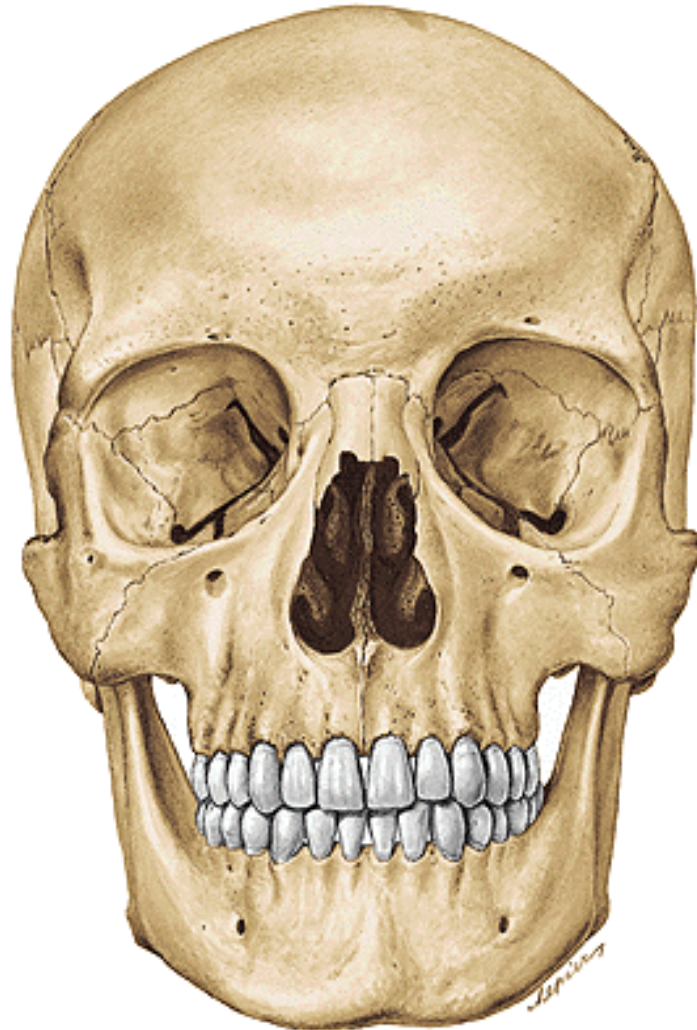

Během 23 hodin se nizozemskému neurochirurgovi Bon Verweijovi z Univerzitního medicínského centra (UMC) v Utrechtu podařilo transplantovat kompletní mozkovou část lebky 22-leté ženě. Nová lebka byla vytištěna z tvrzeného plastu technologií prostorového 3D tisku ve spolupráci s australskou firmou.



SPLANCHNOCRANIUM

(viscerocranium, obličejová část lebky)



Splanchnocranium

Os ethmoidale (kost čichová)

Maxilla (horní čelist)

Os nasale (nosní kost)

Os lacrimale (slzní kost)

Os zygomaticum (lící kost)

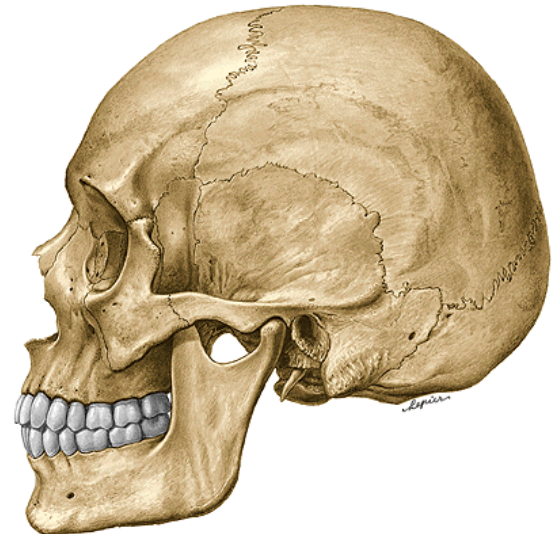
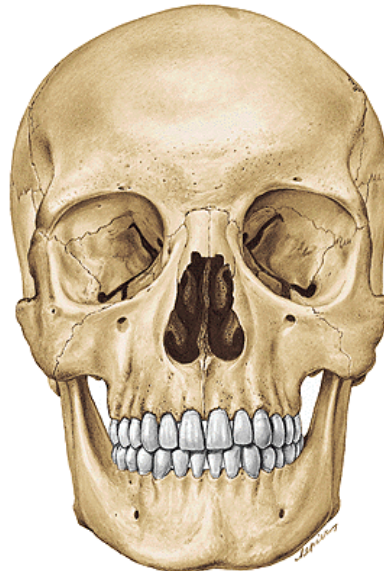
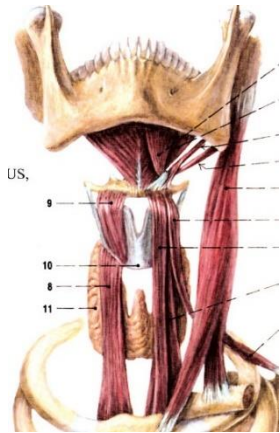
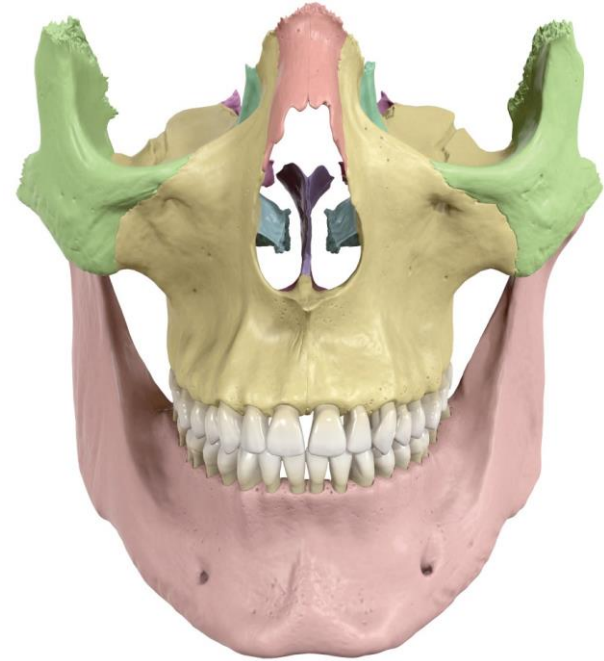Vomer (radličná kost)

Os palatinum (patrová kost)

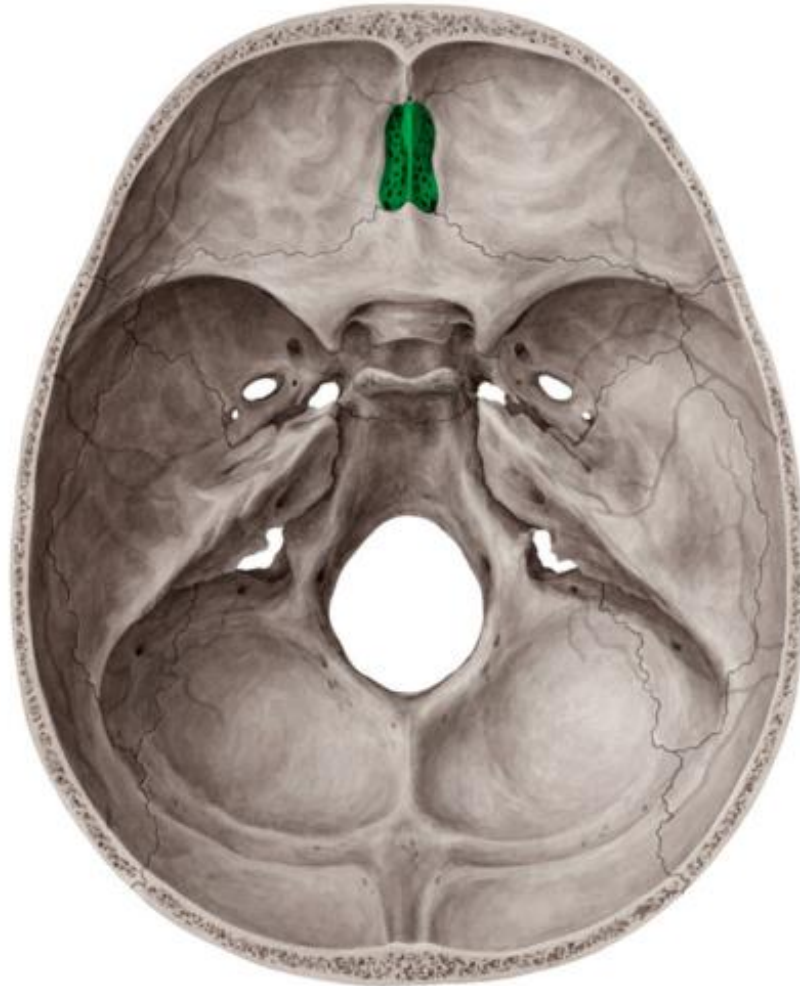
Concha nasalis inferior (dolní skořepa nosní)

Mandibula (dolní čelist)

Os hyoideum (jazyk)



Os ethmoidale



Os ethmoidale

(čichová kost)

1. *Lamina cribrosa*

2. *Lamina perpendicularis*
(součást kostního nosního septa)

crista galli

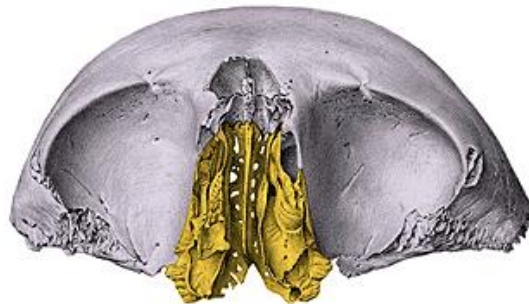
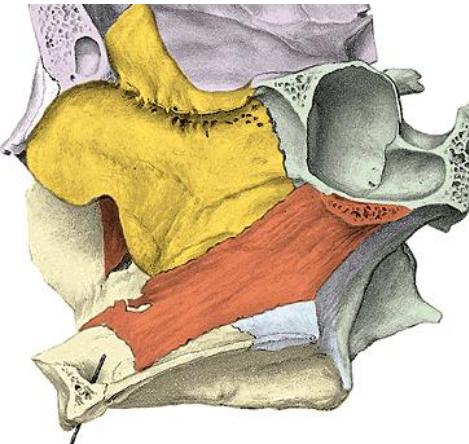
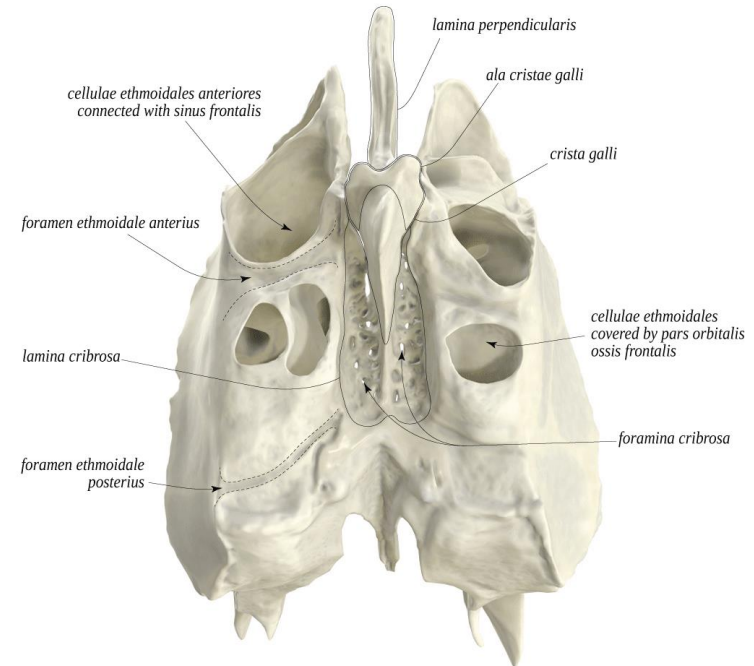
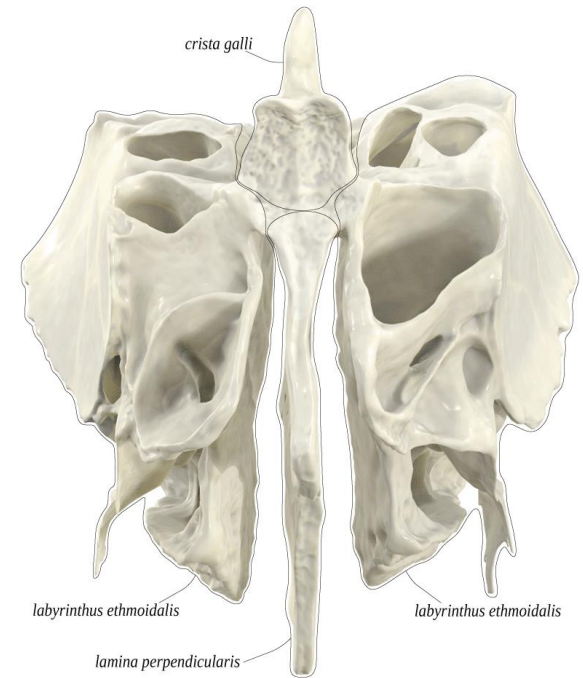
3. *Labyrinthi ethmoidales*

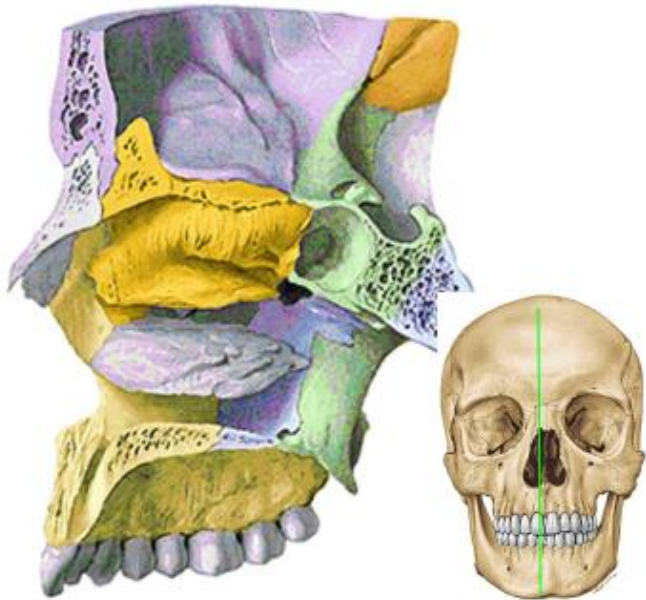
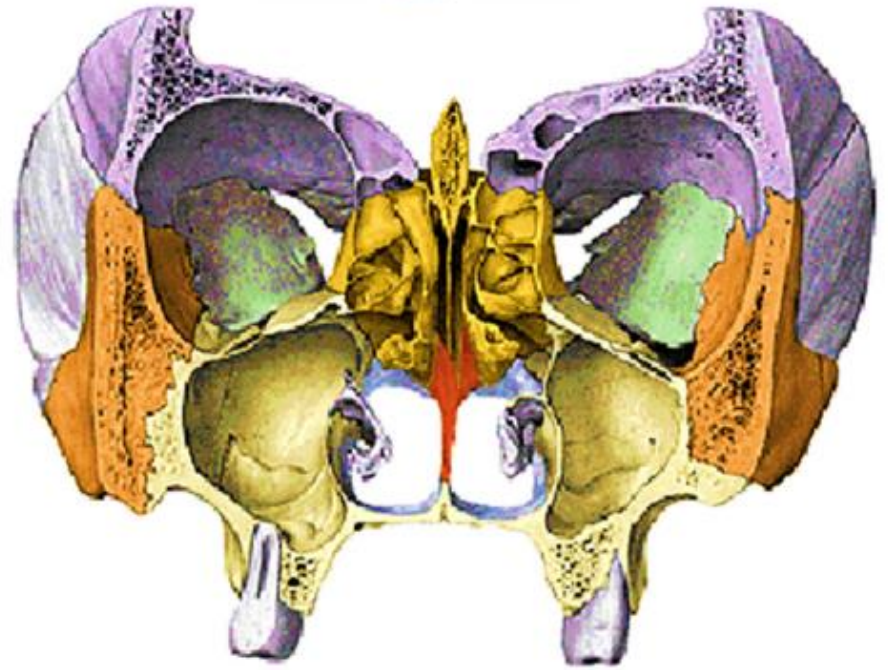
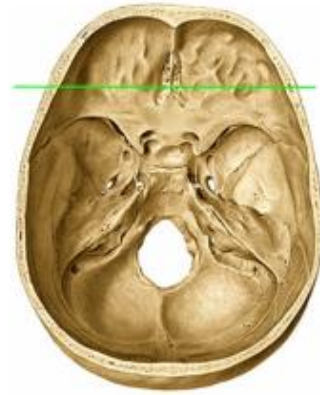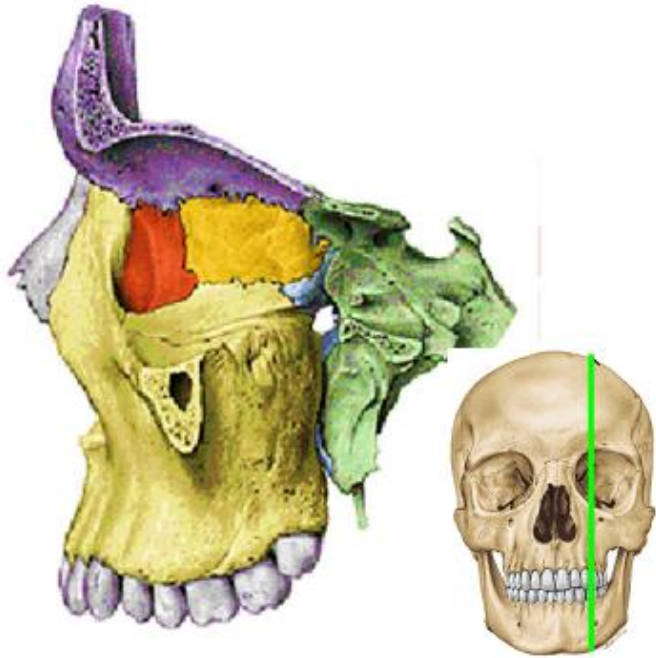
cellulae ethmoidales

lamina orbitalis (hranice s mediální stěnou očníce)

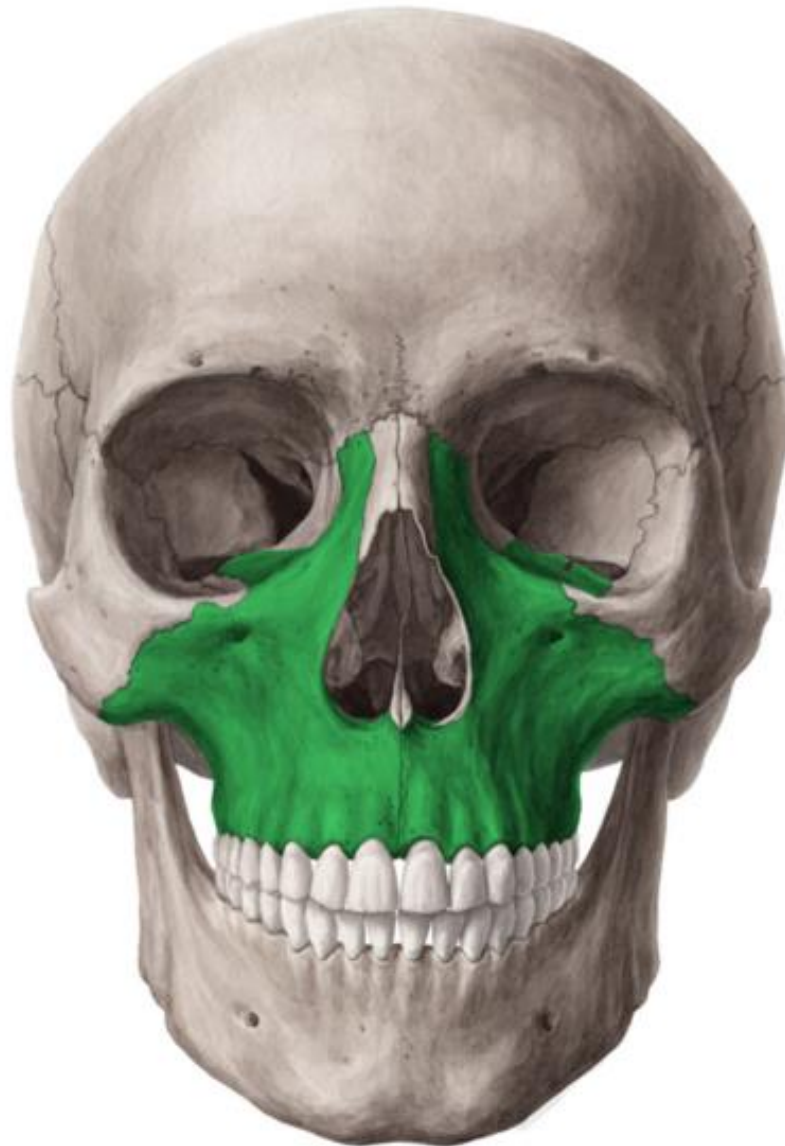- *foramen ethmoidale anterius*
- *foramen ethmoidale posterius*

concha nasalis superior et media





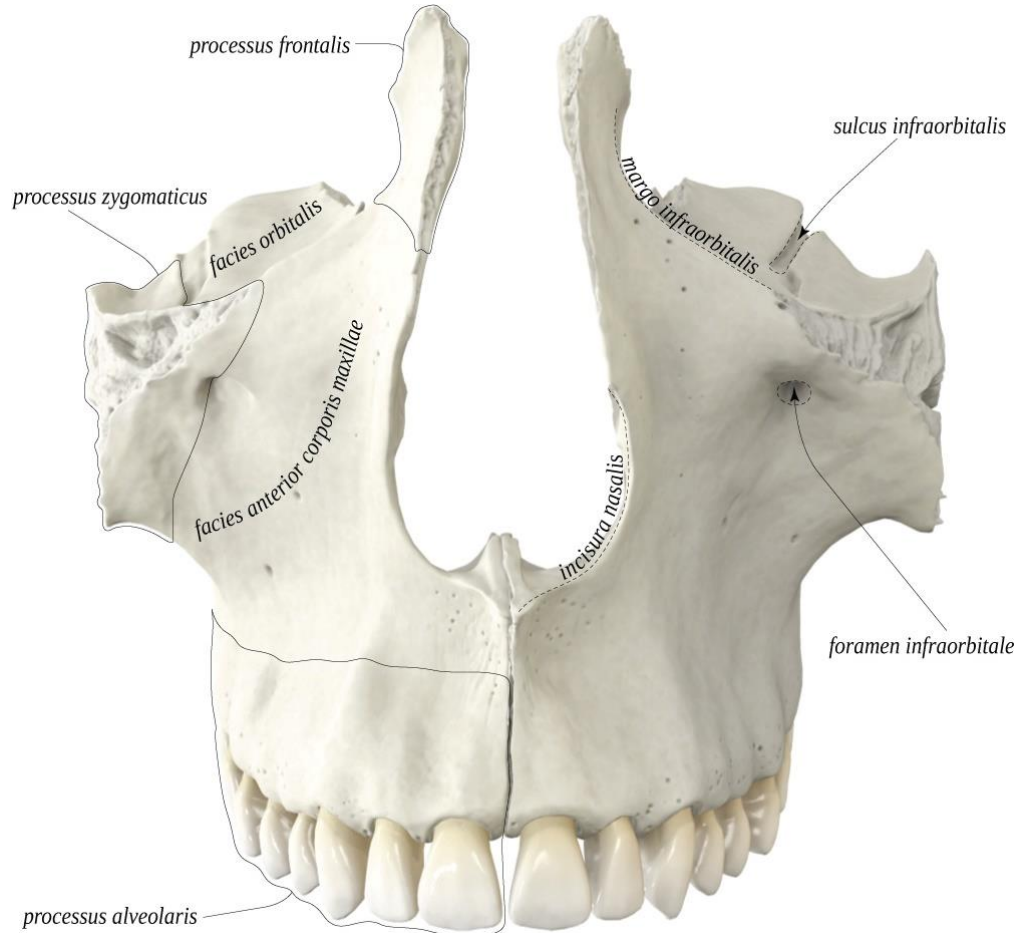
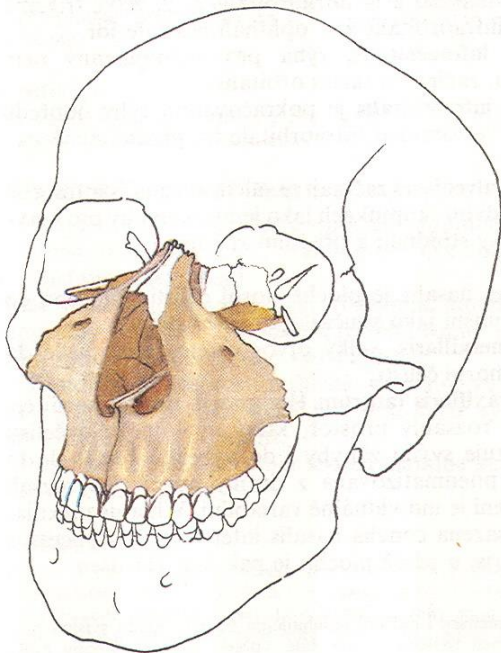
Maxilla



Maxilla (dextra et sinistra!)

Corpus maxillae
sinus maxilaris

Processus maxillae
Processus frontalis
Processus zygomaticus
Processus alveolaris
Processus palatinus



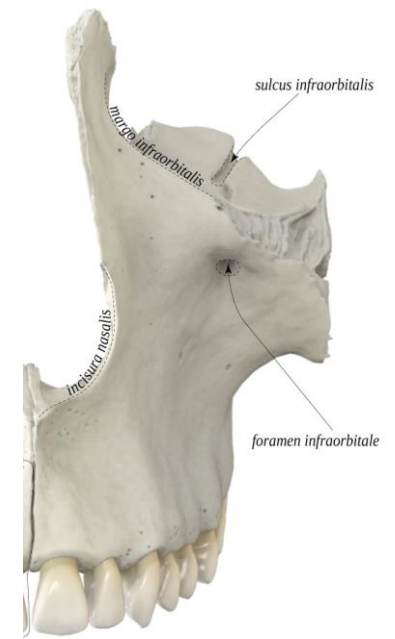
Corpus maxillae

Facies orbitalis
margo infraorbitalis
sulcus infraorbitalis
canalis infraorbitalis

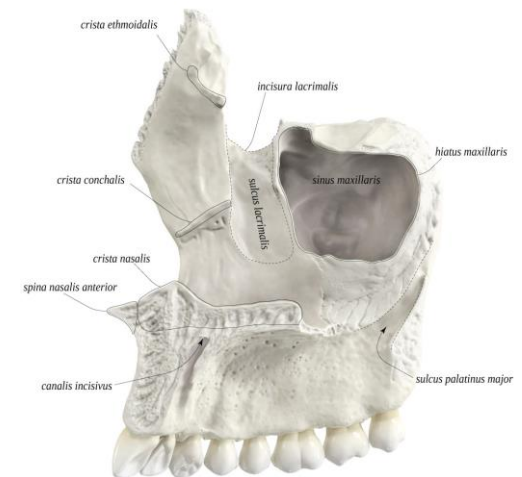
Facies anterior
foramen infraorbitale
incisura nasalis
fossa canina

Facies nasalis
sinus maxillaris
hiatus maxillaris

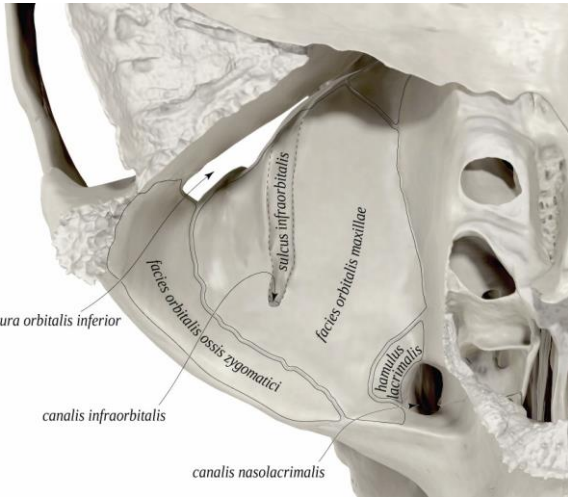
Facies infratemporalis
tuber maxillae



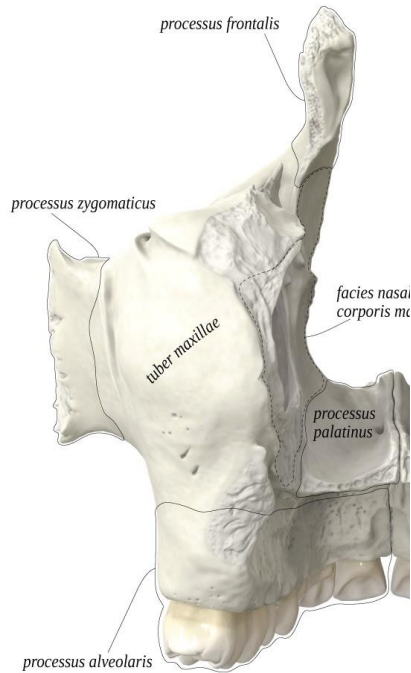
Facies anterior



Facies nasalis



Facies orbitalis

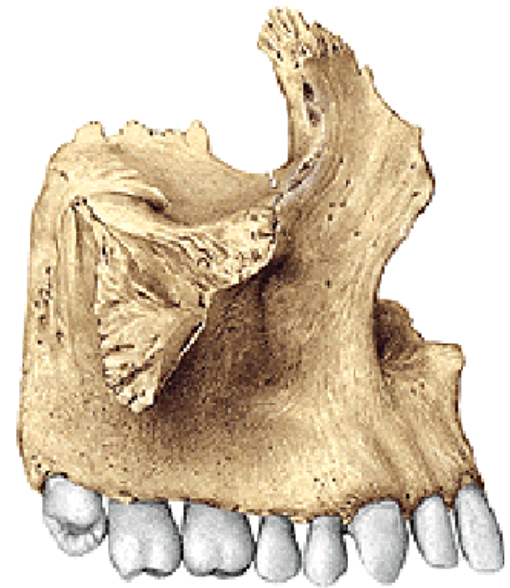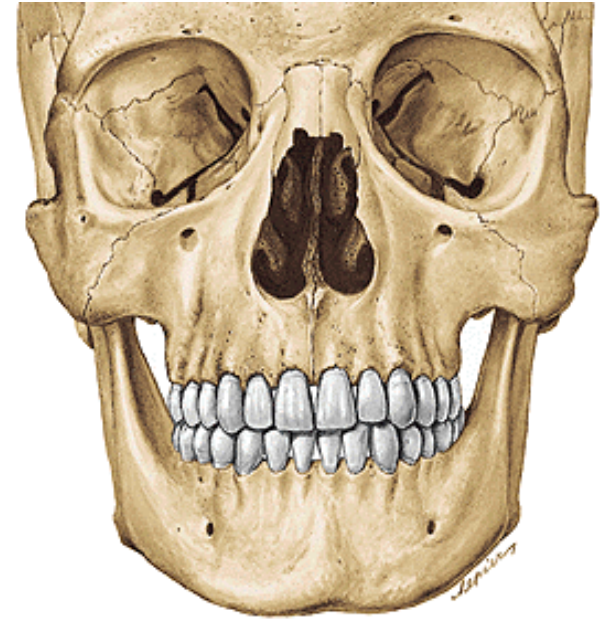
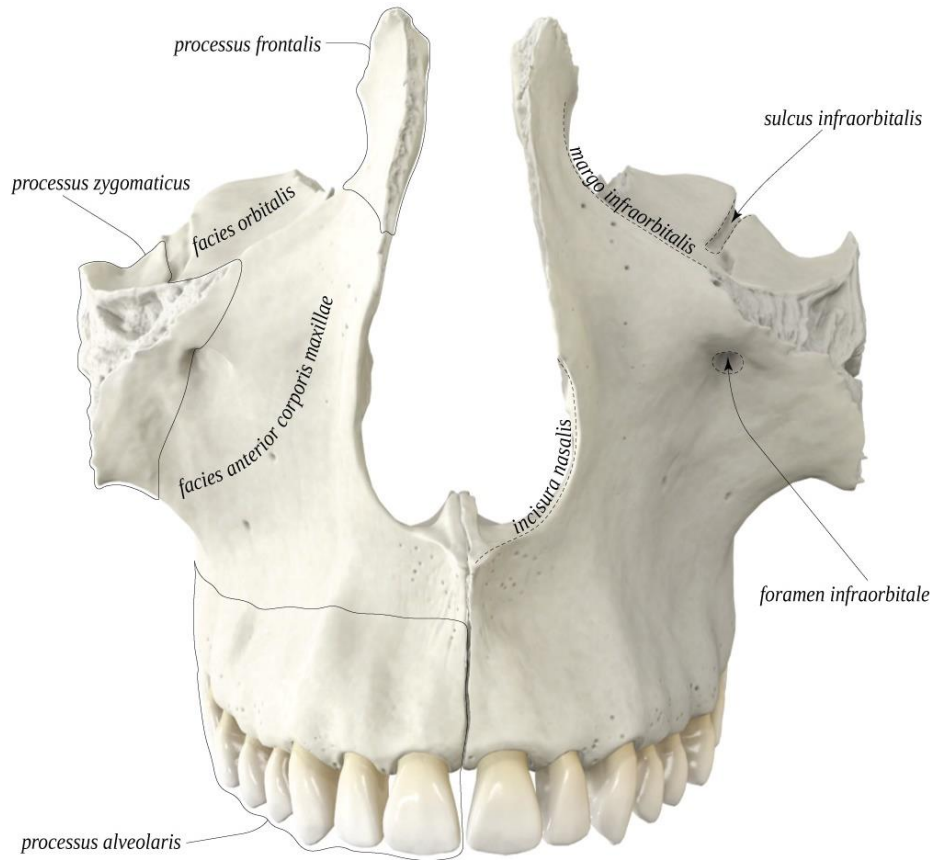


Facies infratemporalis

Processus frontalis

incisura nasalis
(*apertura piriformis*)

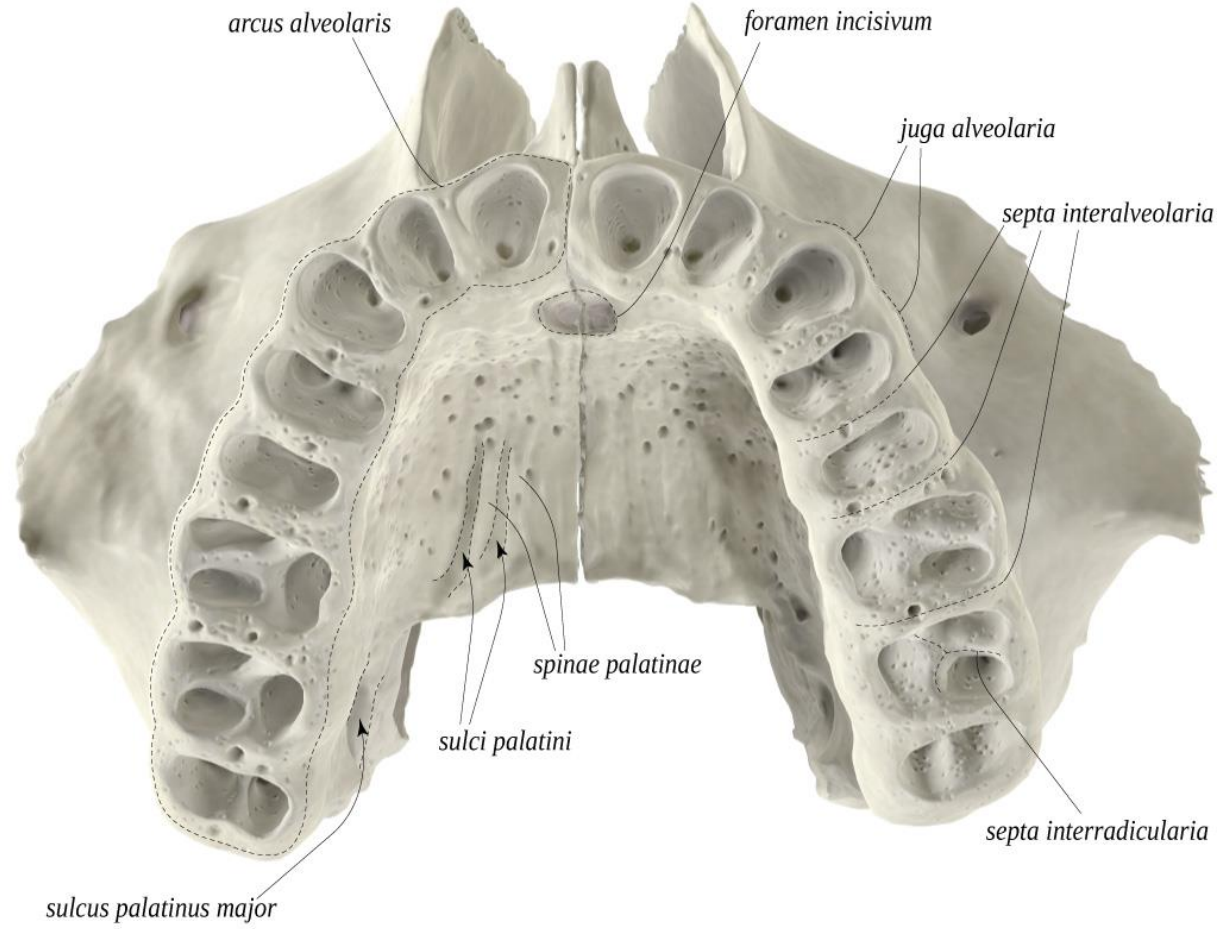
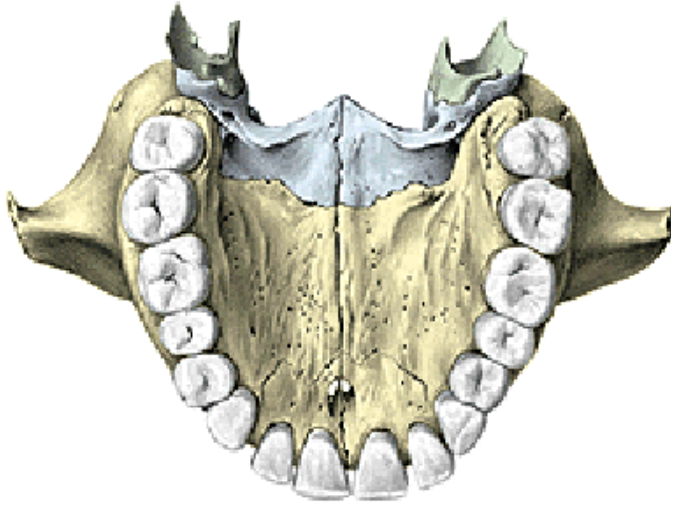
Processus zygomaticus



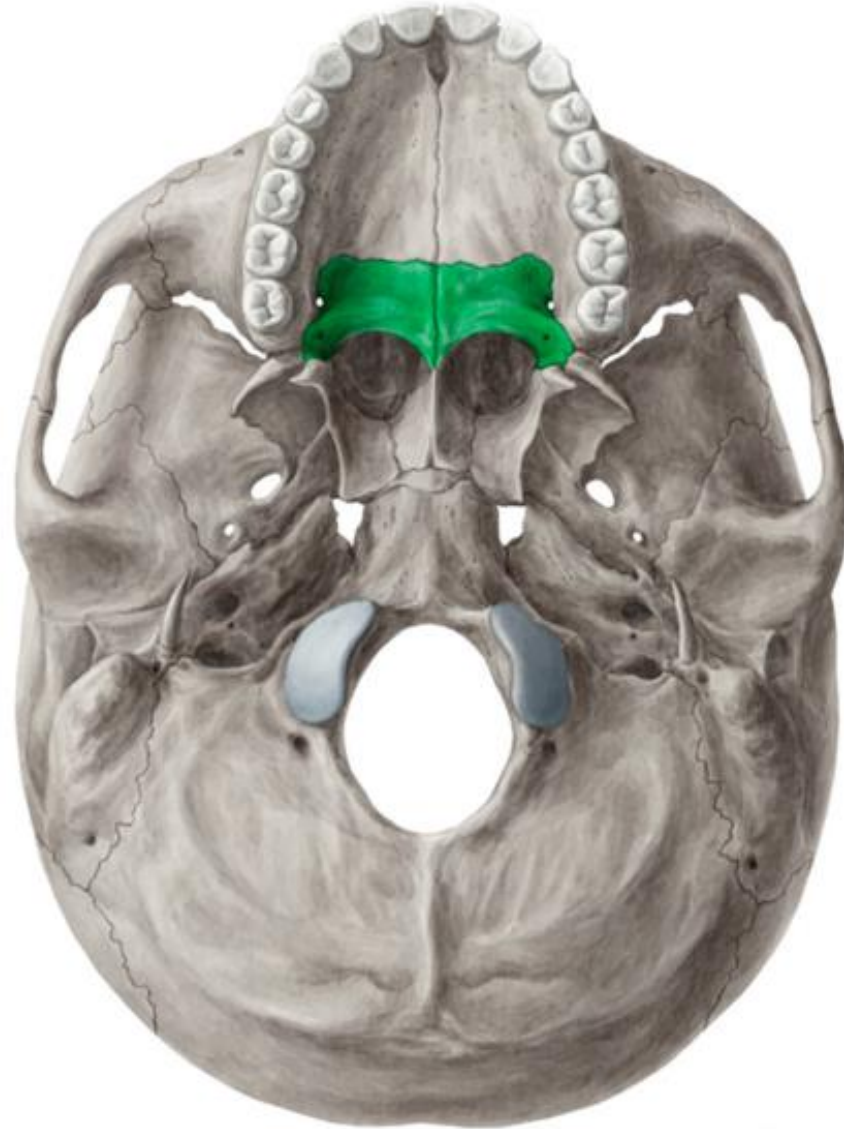Processus alveolaris
alveoli dentales

Processus palatinus
(tvoří ¾ tvrdého patra!)

foramen incisivum
canalis incisivus



Os palatinum



Os palatinum (patrová kost)

(tvoří ¼ tvrdého patra)

Lamina horizontalis

sutura palatina transversa

crista nasalis

foramen palatinum majus

foramina palatina minora

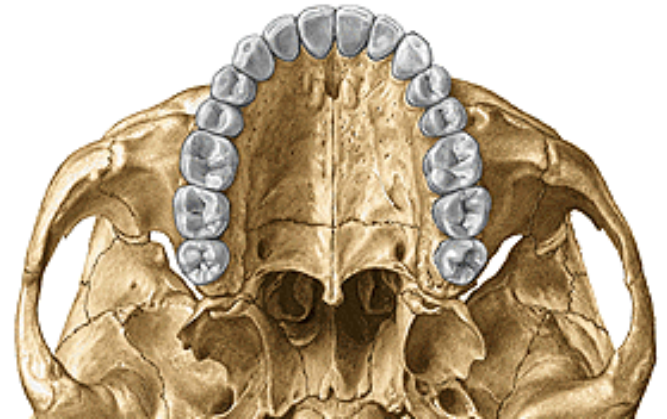
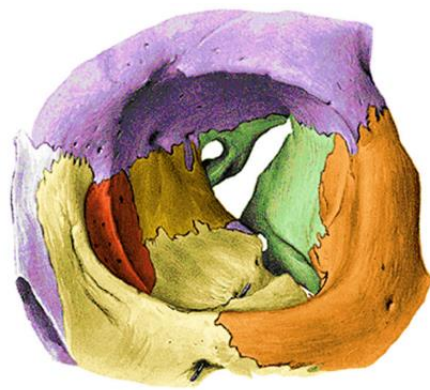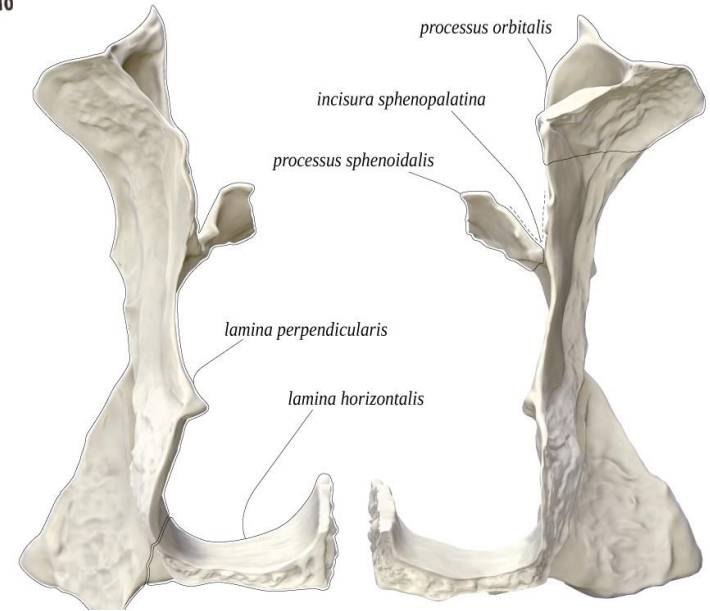
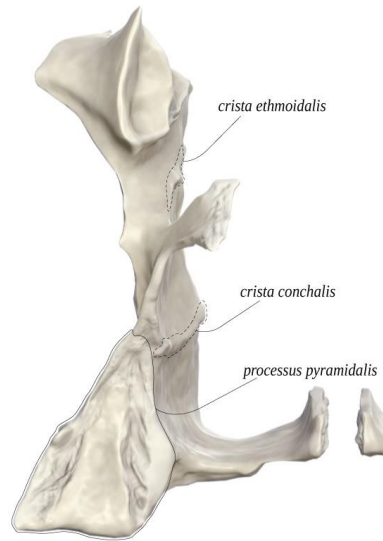
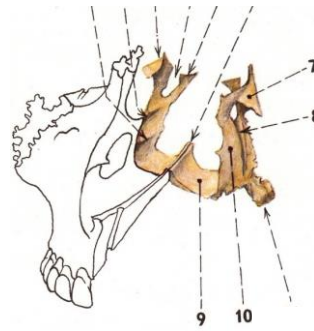
Lamina perpendicularis

*crista ethmoidalis et
conchalis*

foramen sphenopalatinum

*processus orbitalis et
sphenoidalis*

Processus pyramidalis



Palatoschisis (cheilopalatoschisis)

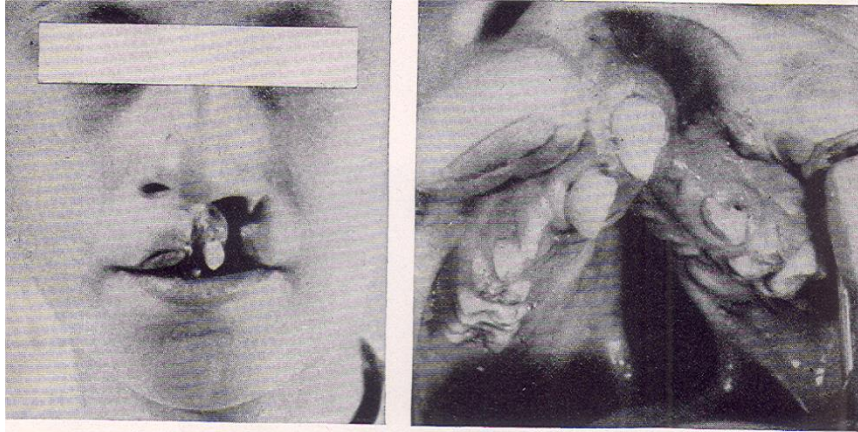
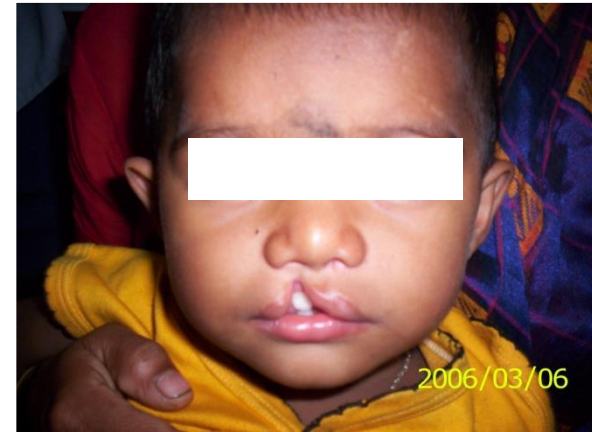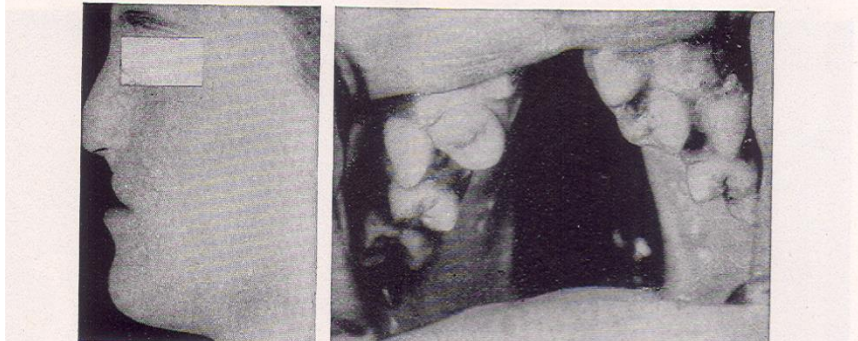
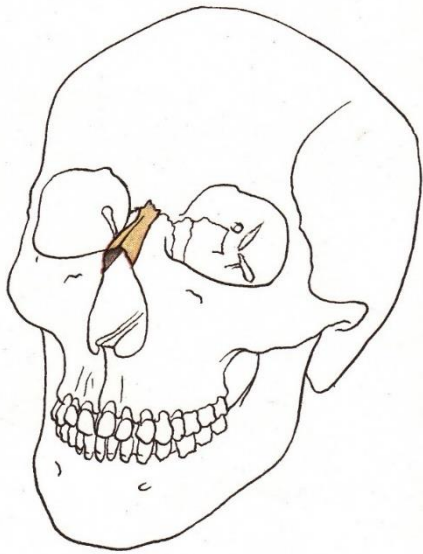


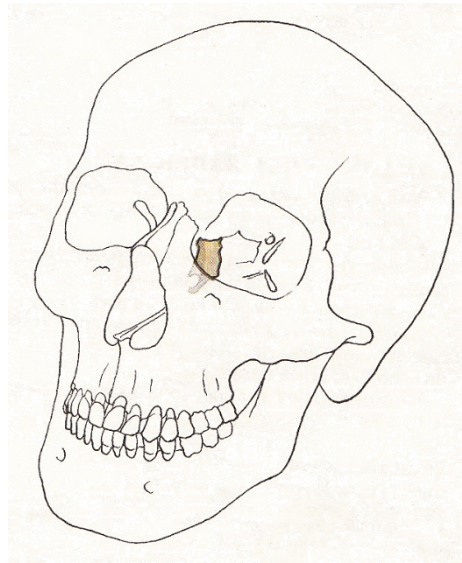
FIG. 55. Photographs of a boy showing unilateral harelip and complete unilateral cleft palate.
(From School of Dental and Oral Surgery, Columbia University.)



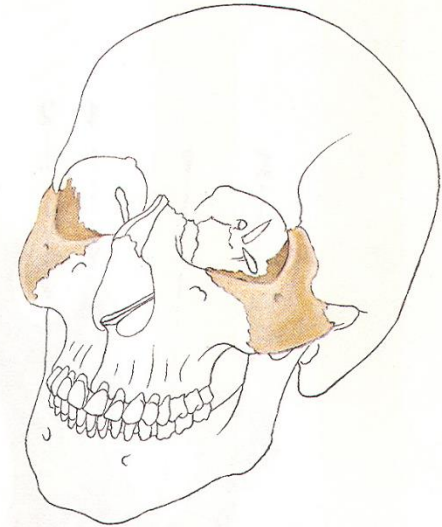
Os nasale



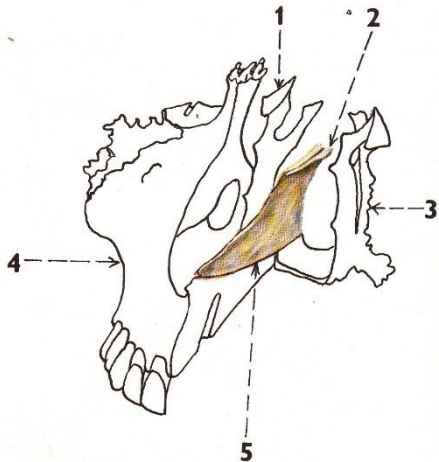
Os lacrimale



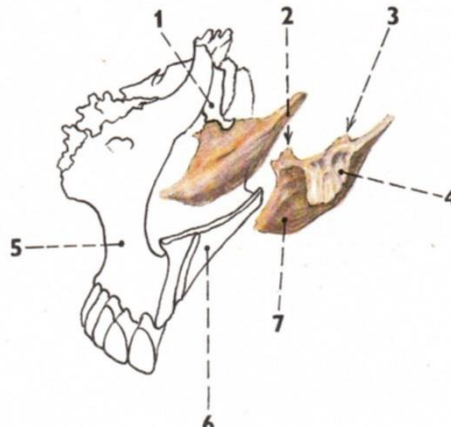
Os zygomaticum



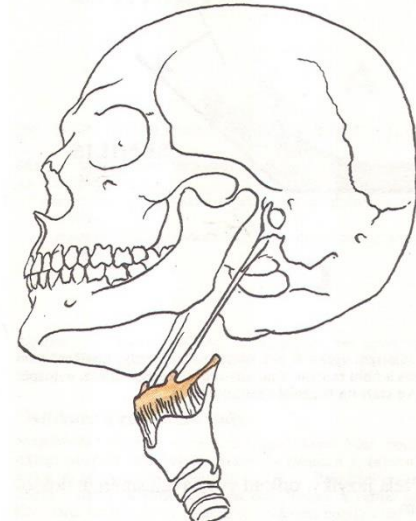
Vomer



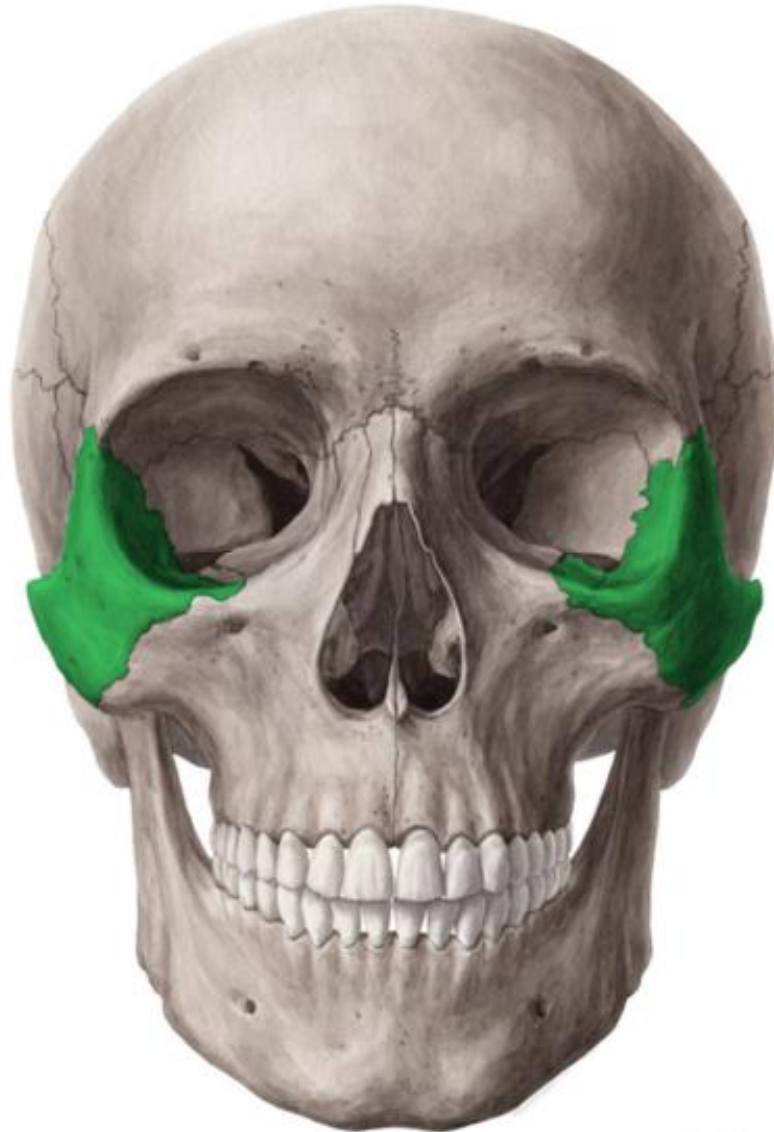Concha nasalis inferior



Os hyoideum



Os zygomaticum



Os zygomaticum

Corpus

facies lateralis

facies orbitalis

facies temporalis

foramen zygomaticofaciale

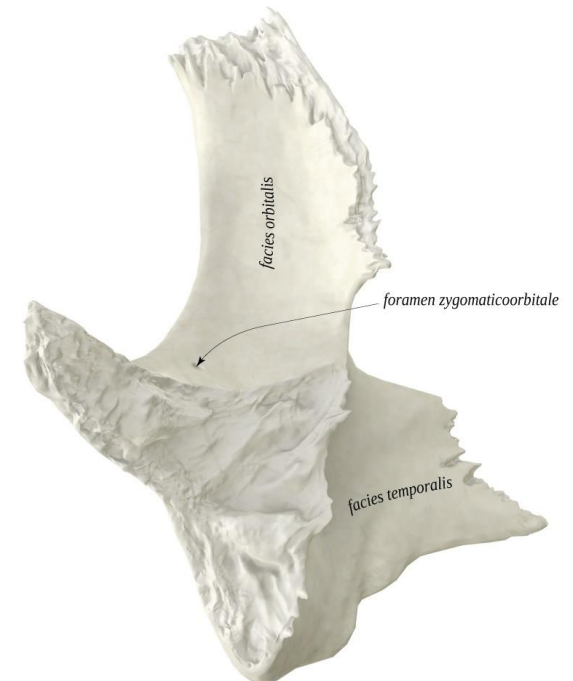
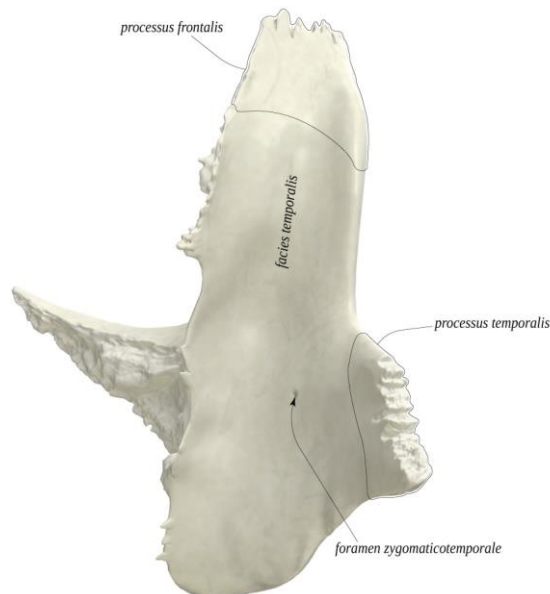
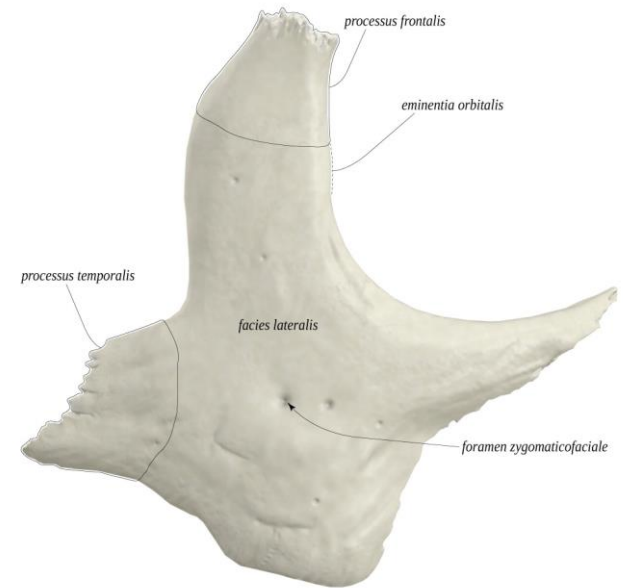
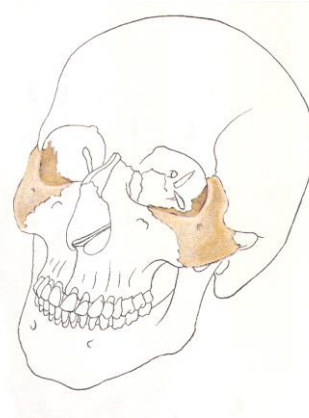
zygomaticoorbitale

zygomaticotemporale

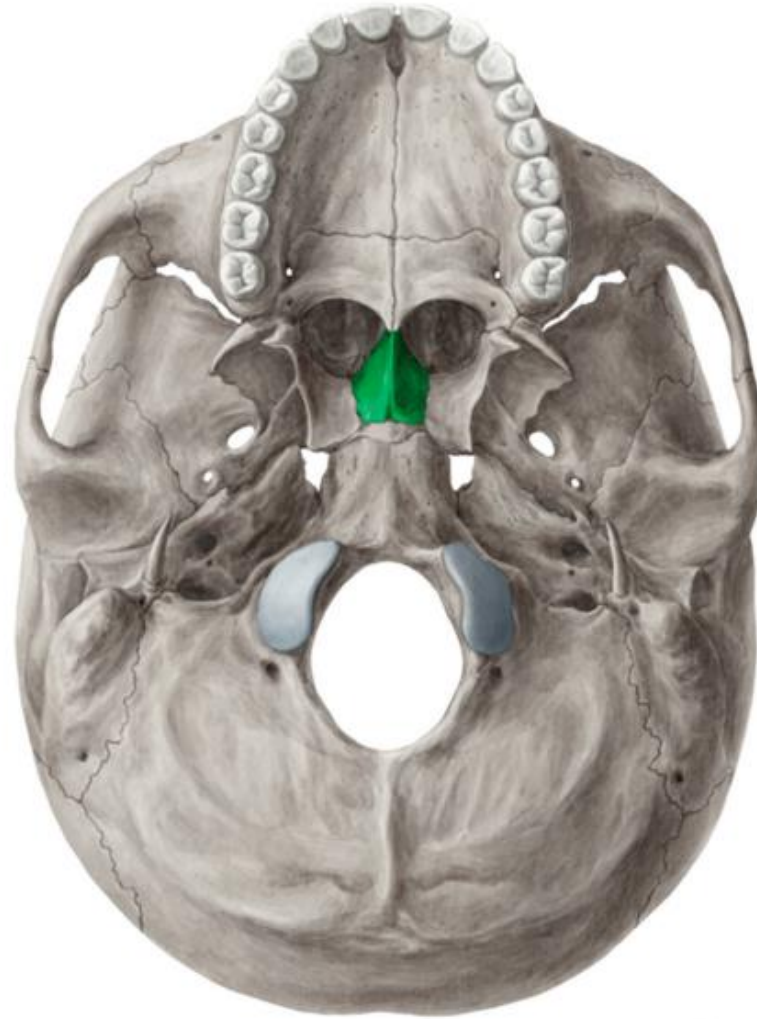
Processus

temporalis, frontalis, maxillaris

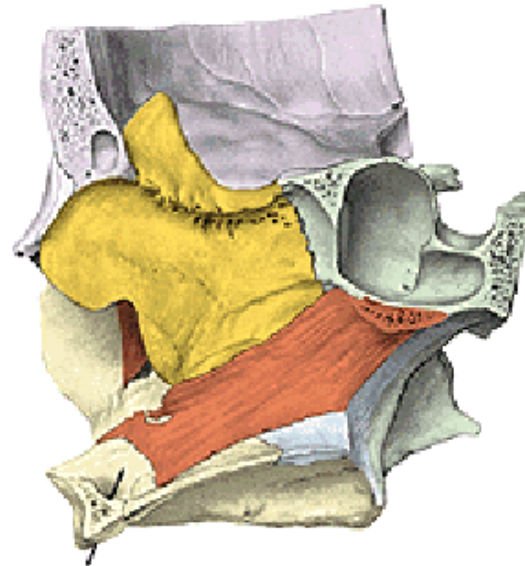
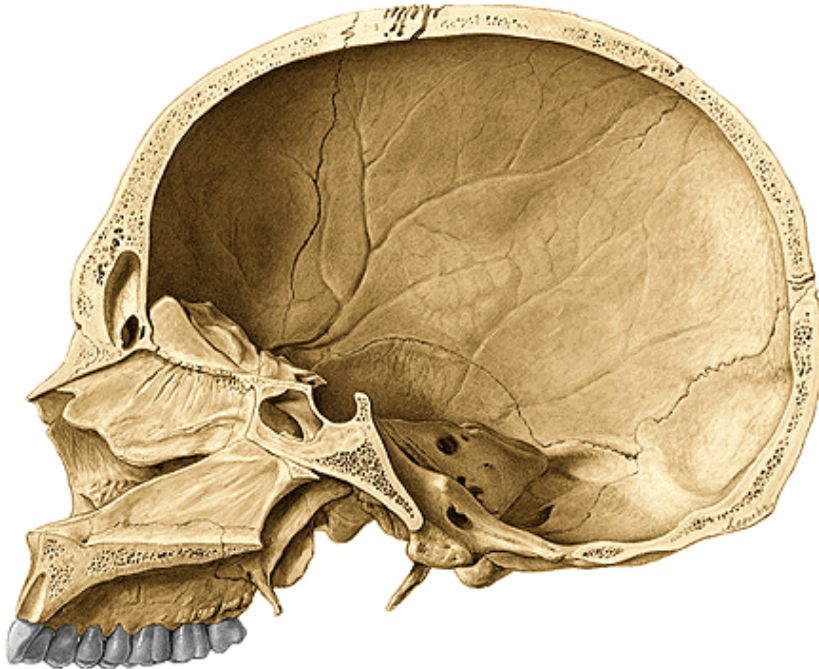
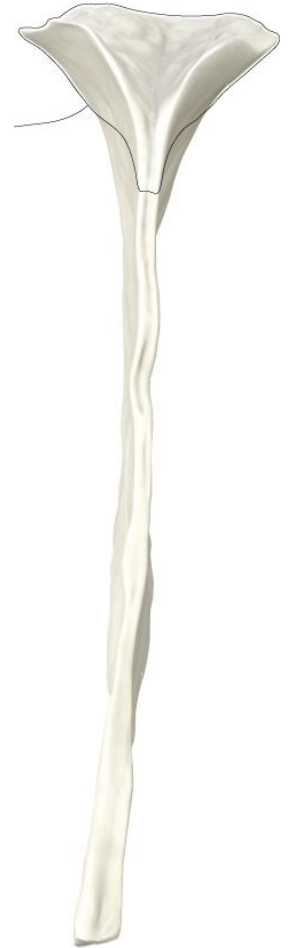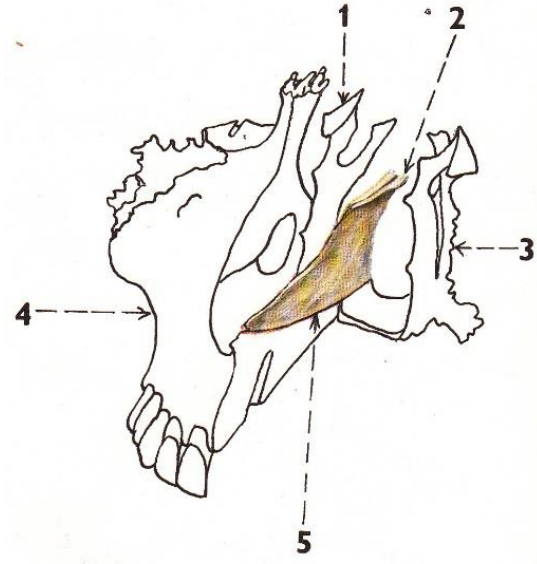
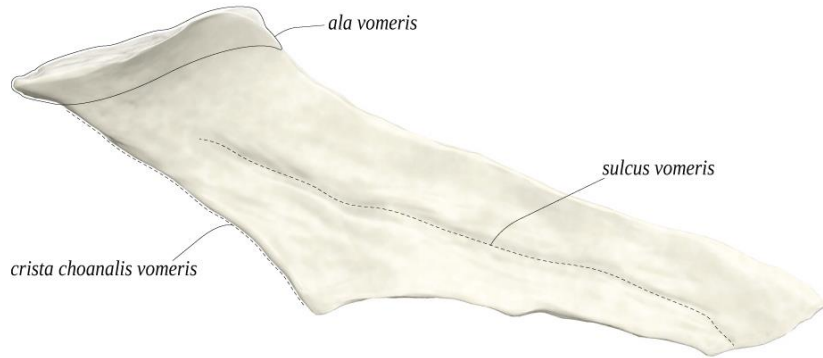
*Arcus zygomaticus = processus temporalis lícní kosti a
processus zygomaticus spánkové kosti*



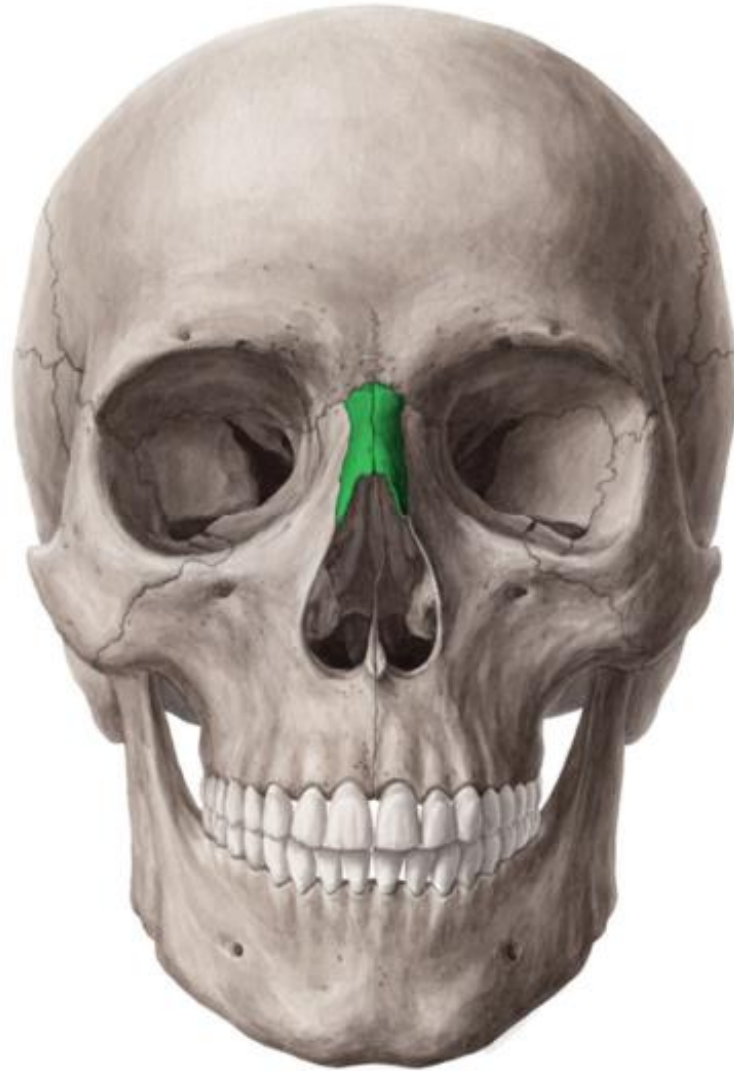Vomer



Vomer

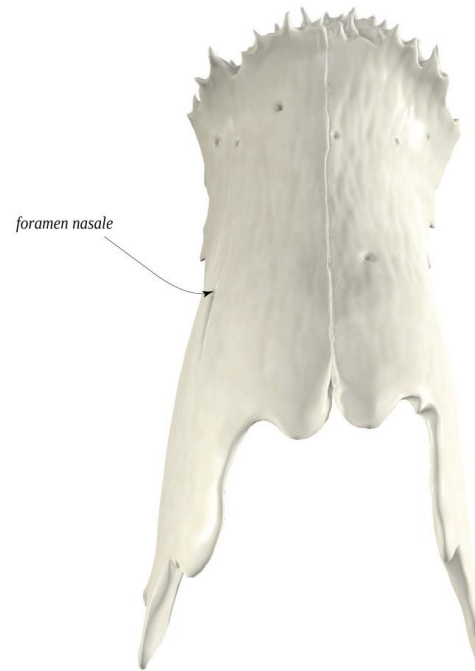
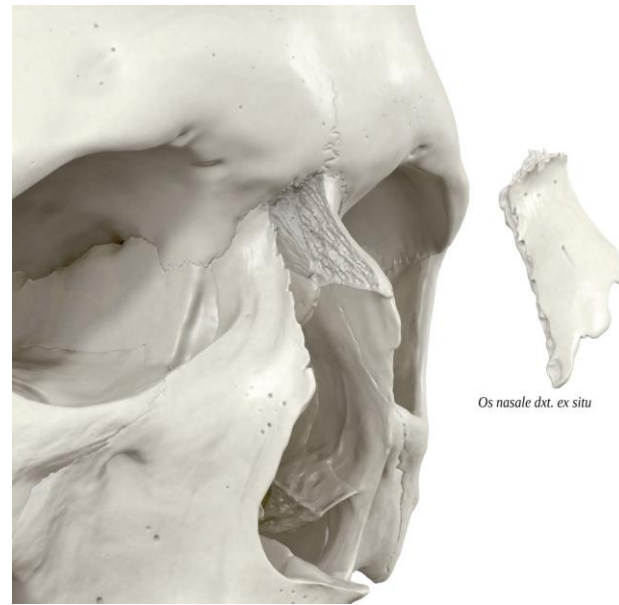
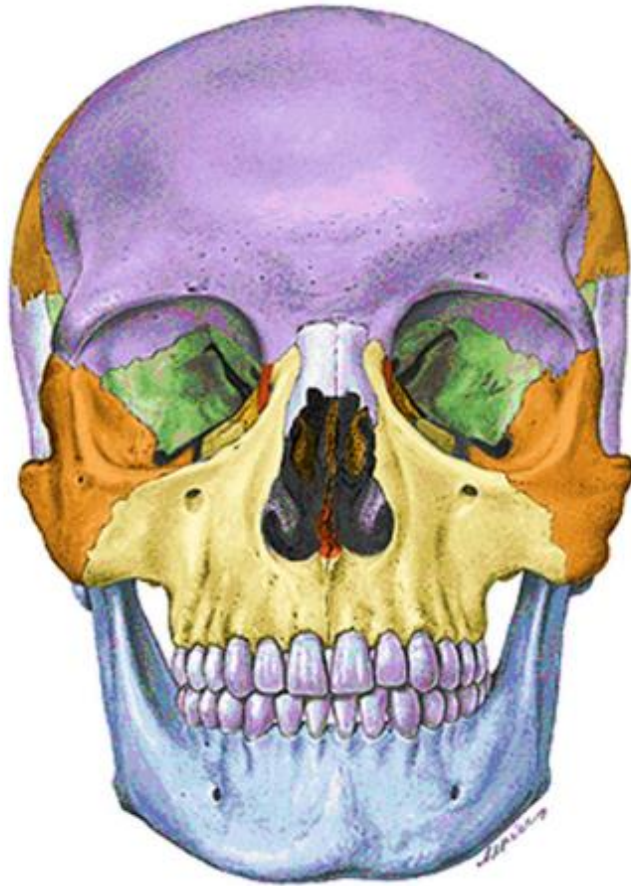


Os nasale

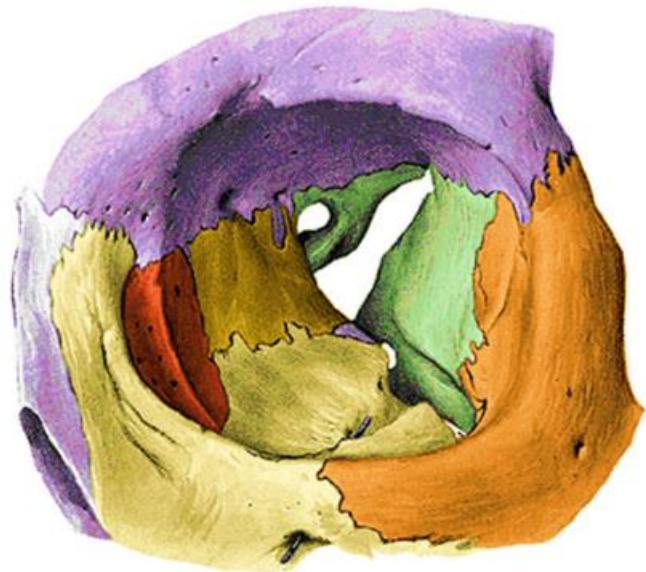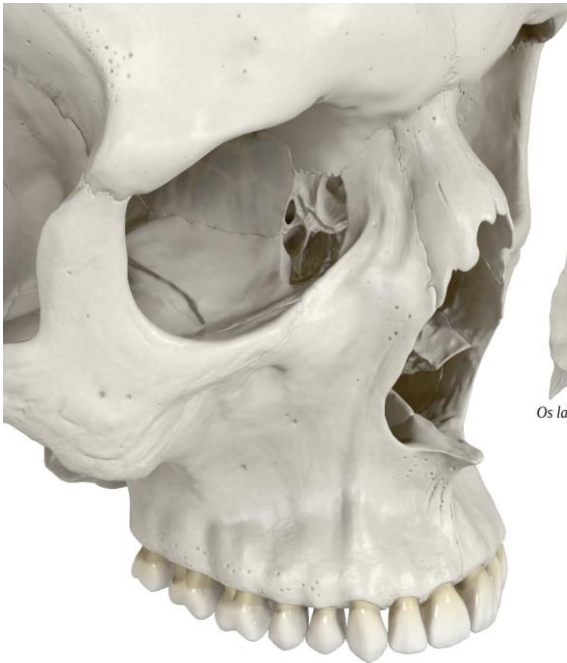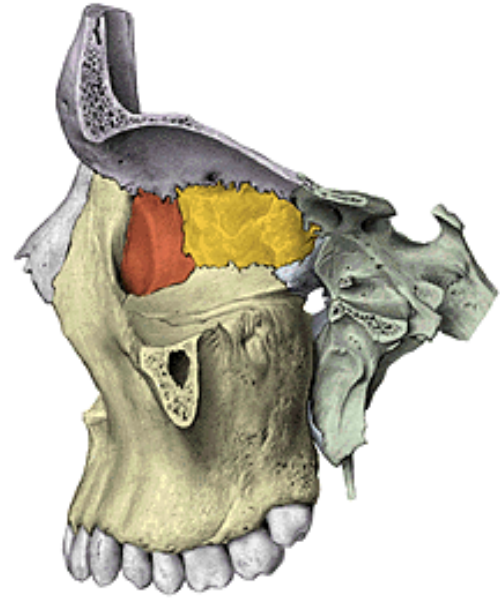
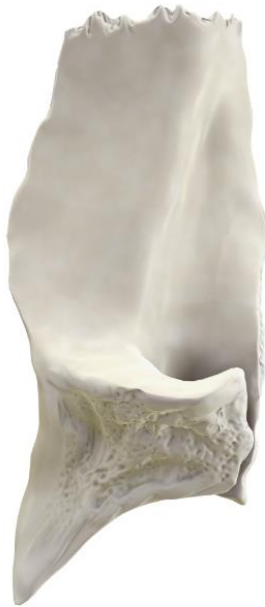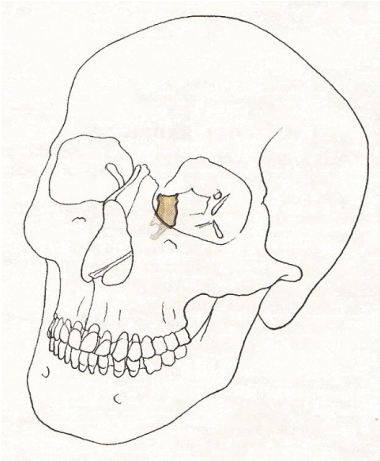


Os nasale

Apertura piriformis

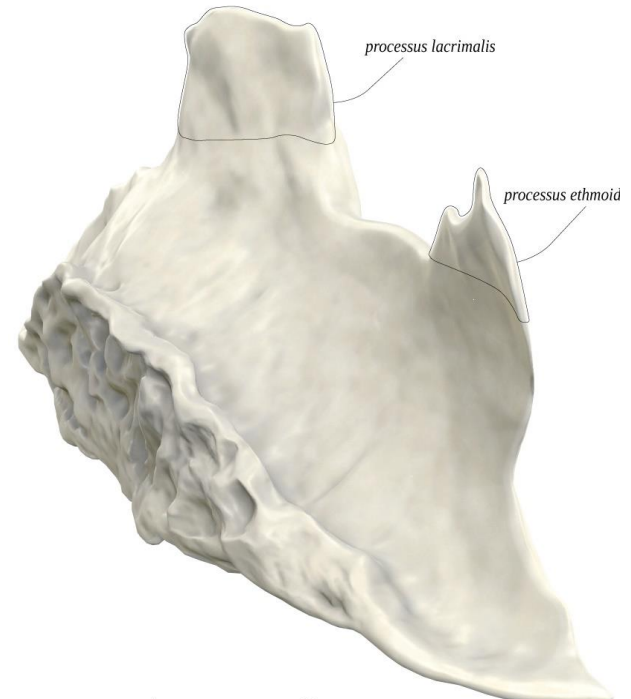
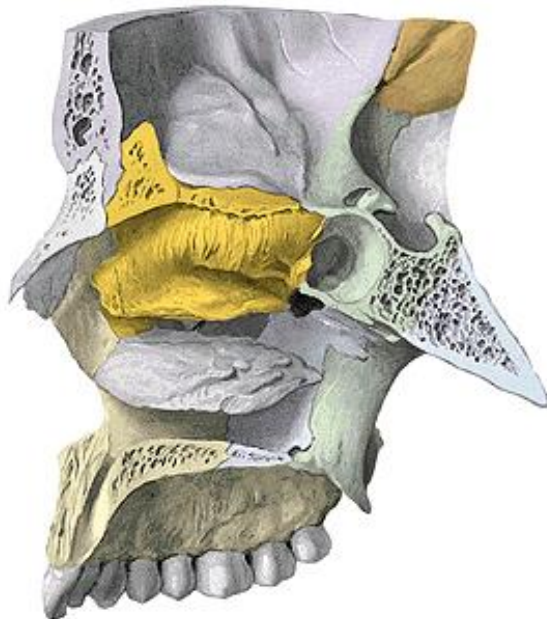
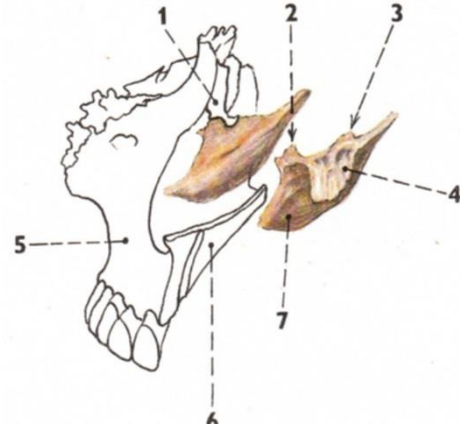
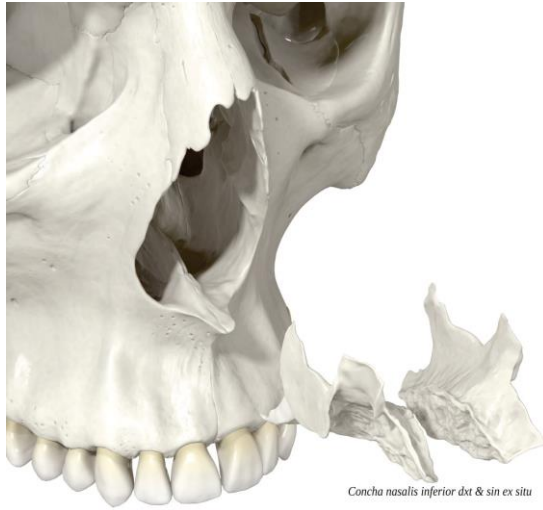

Os lacrimale

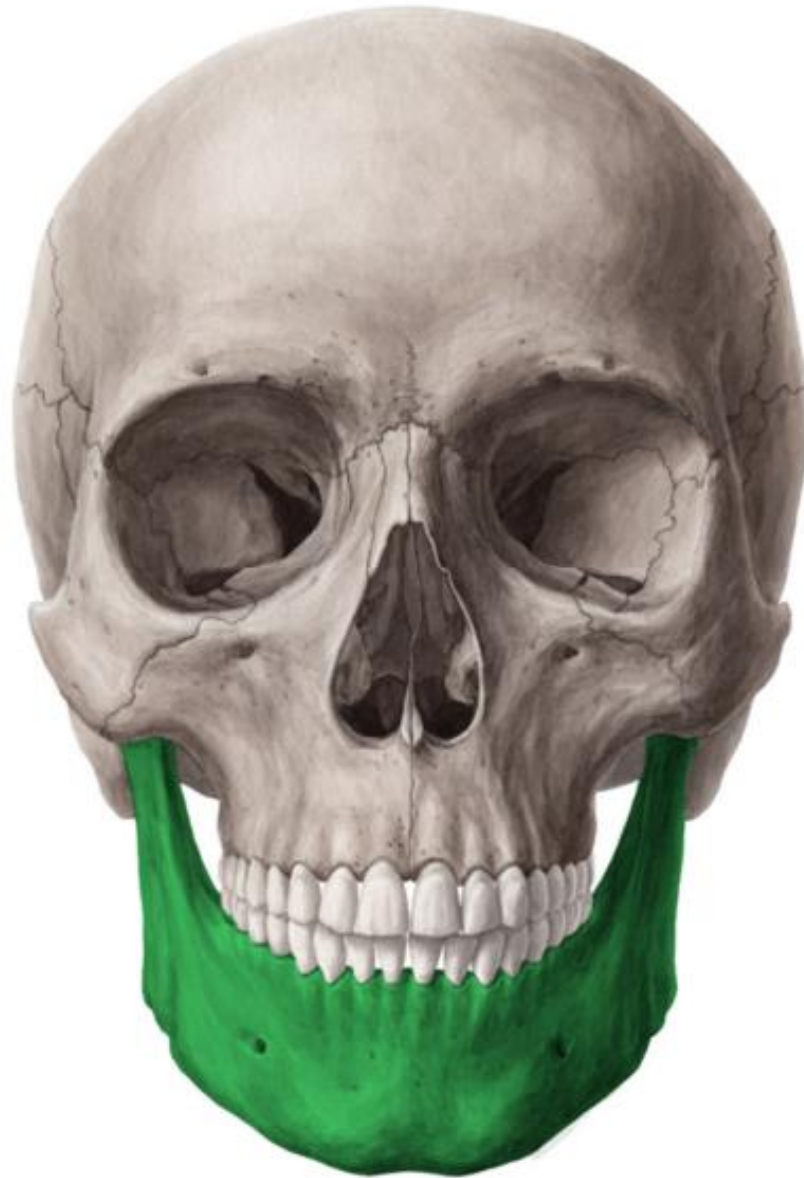

Concha nasalis inferior

(dolní nosní skořepa)



Mandibula

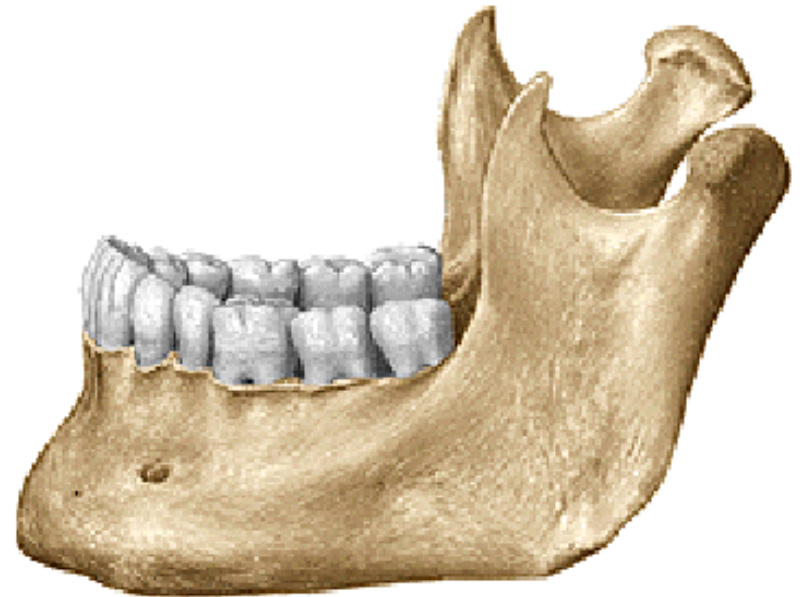
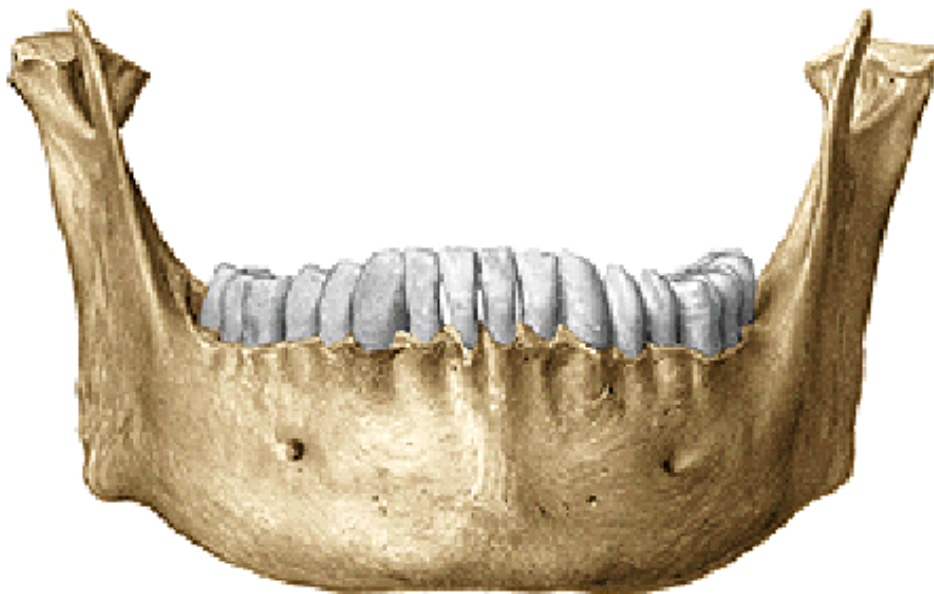
Mandibula

Corpus mandibulae

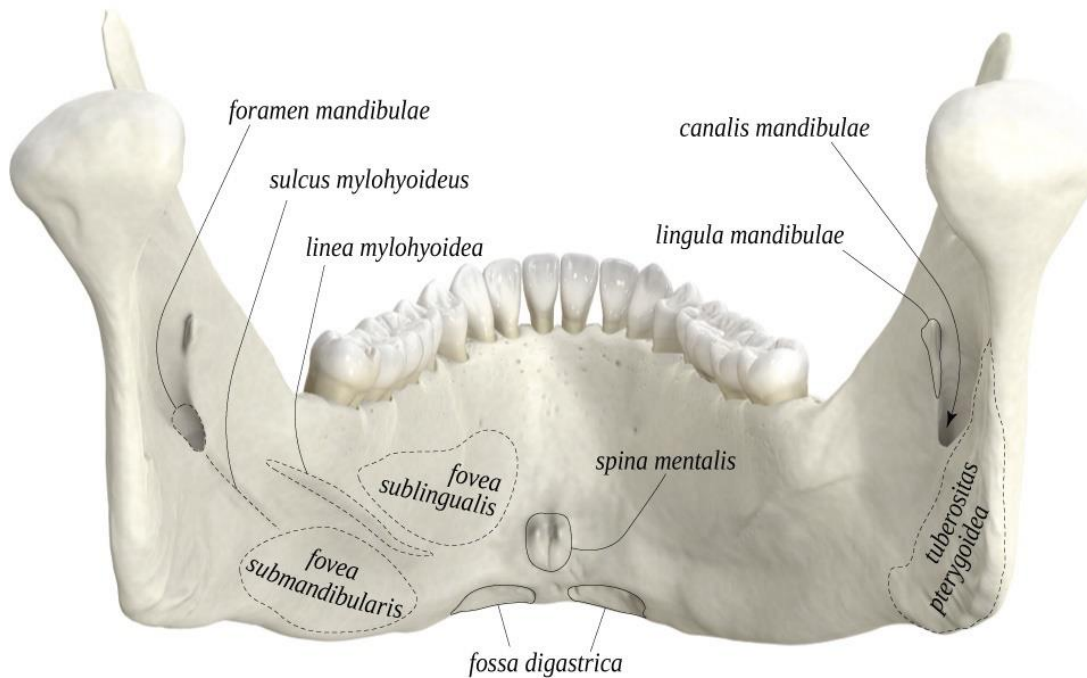
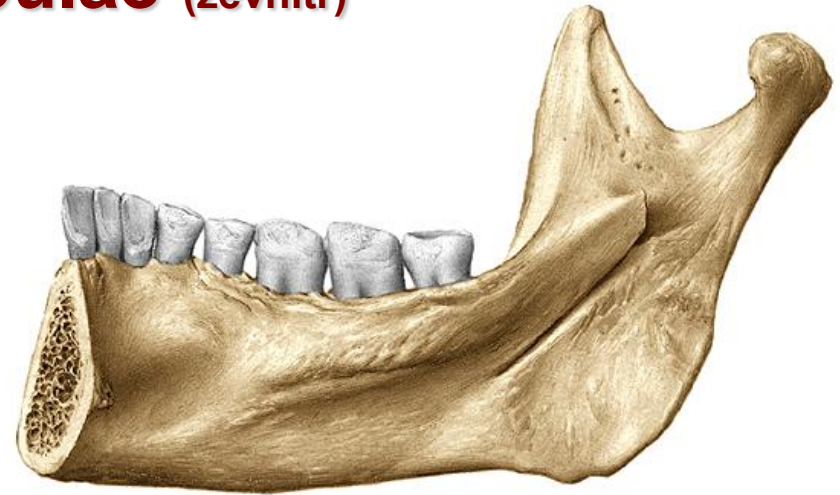Ramus mandibulae dx. et sin.

Angulus mandibulae dx. et sin.



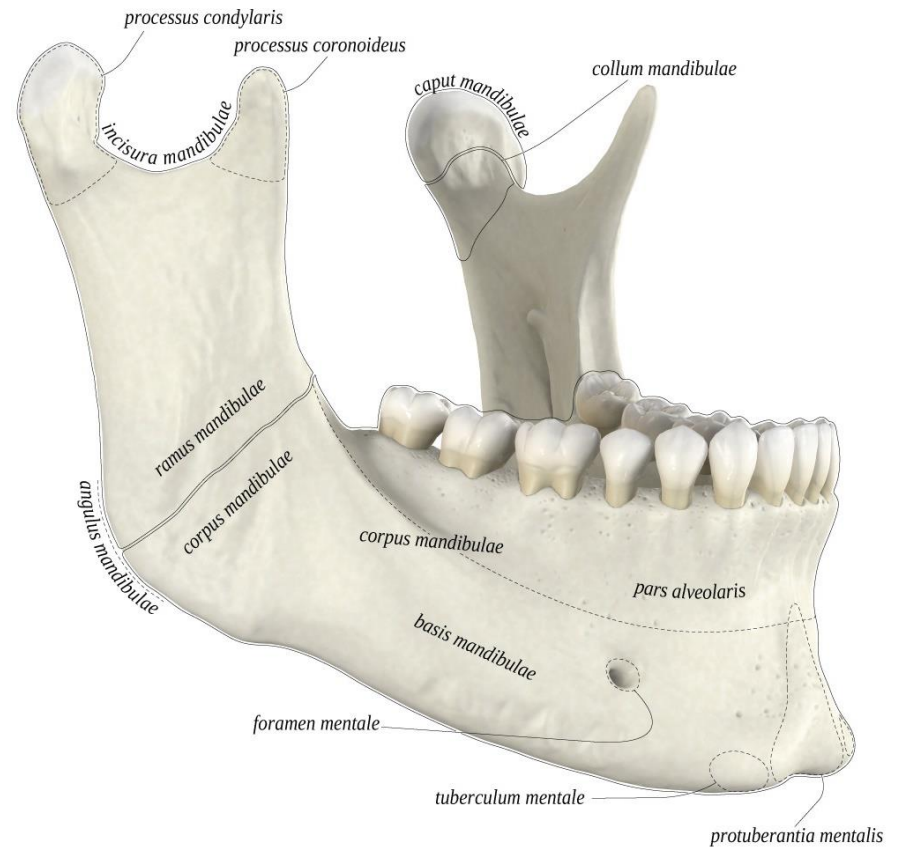
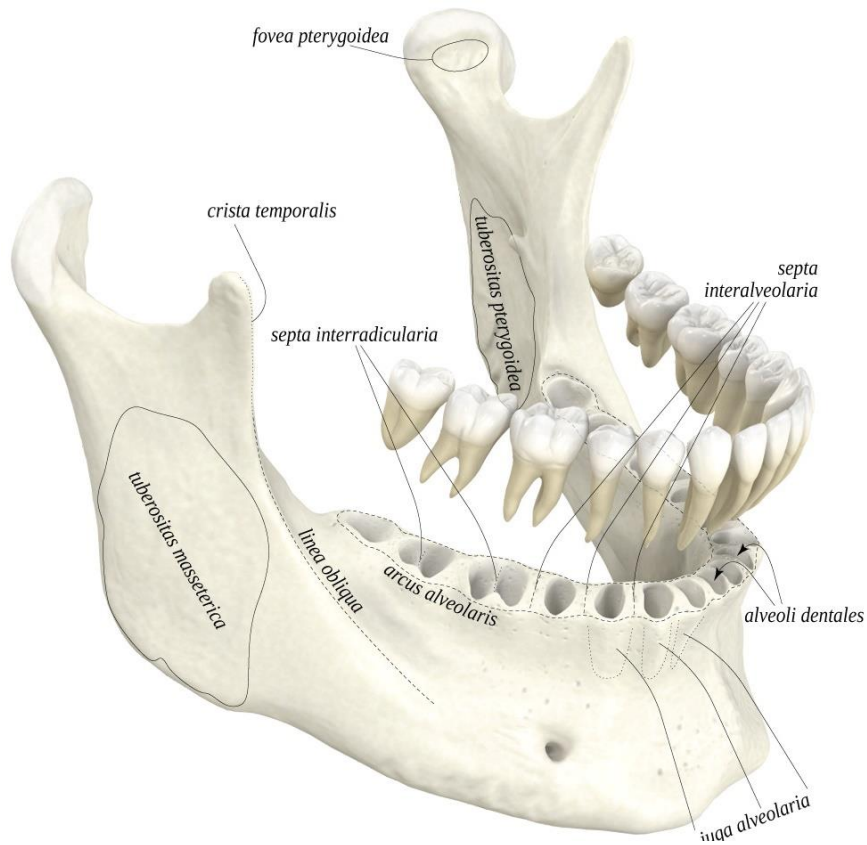
Corpus mandibulae (zevnitř)

fossa digastrica
spina mentalis
linea mylohyoidea
fovea sublingualis
fovea submandibularis



Corpus mandibulae (zevně)

protuberantia mentalis
foramen mentale
alveoli dentales



Ramus mandibulae

processus condylaris

caput, collum s fovea pterygoidea

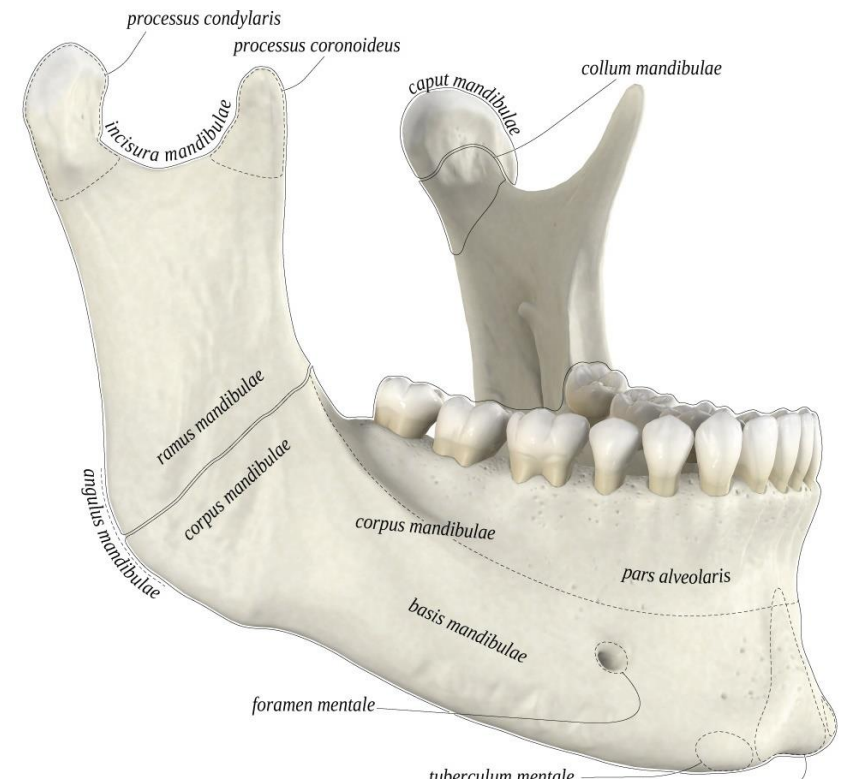
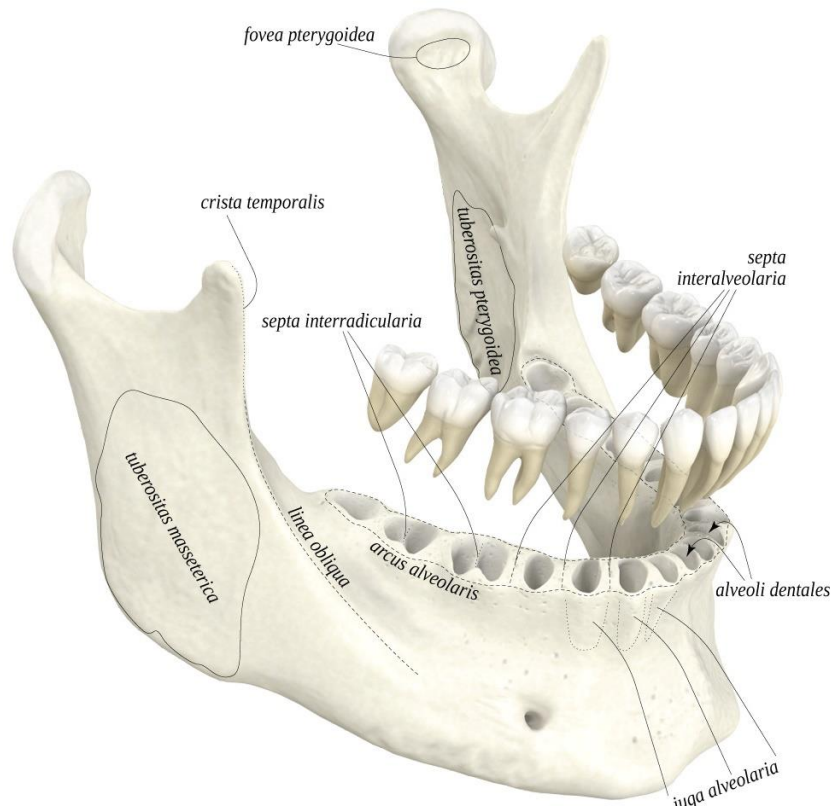
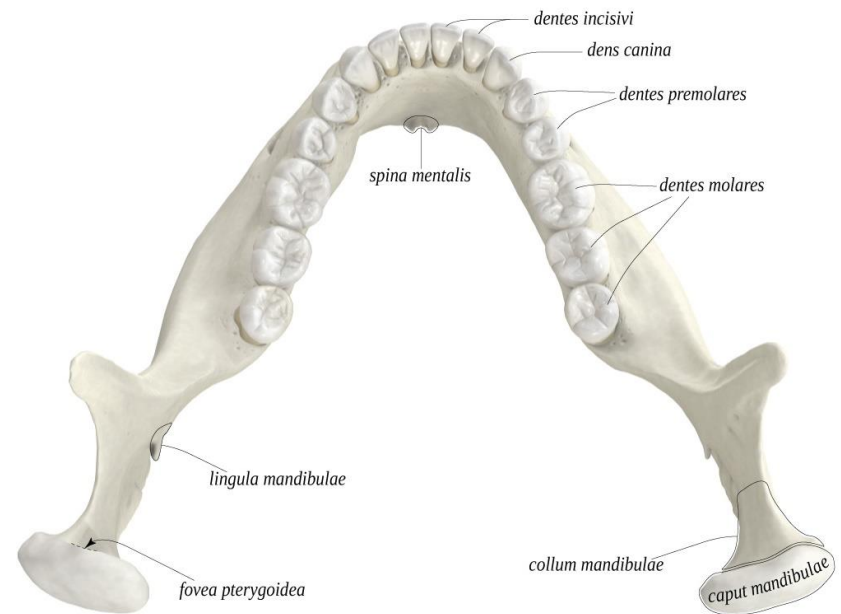
processus coronoideus

foramen mandibulae

canalis mandibulae

tuberositas masseterica

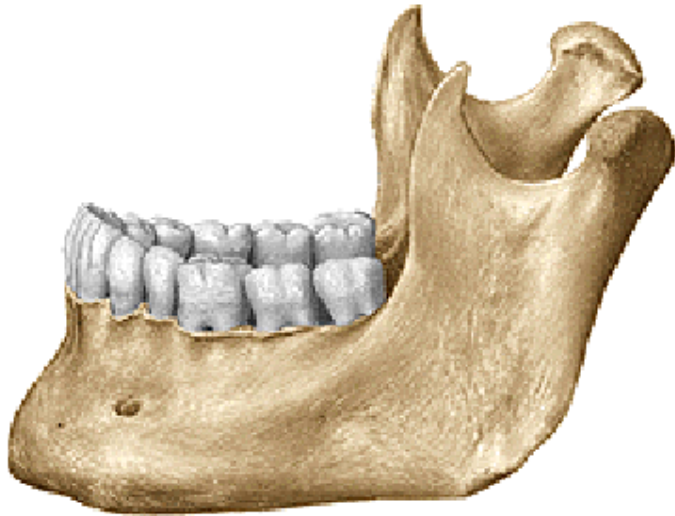tuberositas pterygoidea



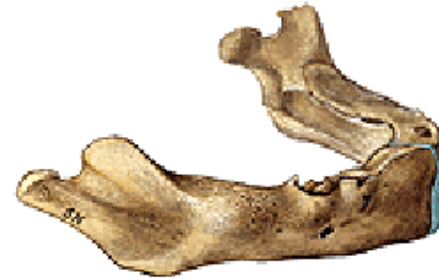Angulus mandibulae (120°-125°)

Tuberositas masseterica (zevně)

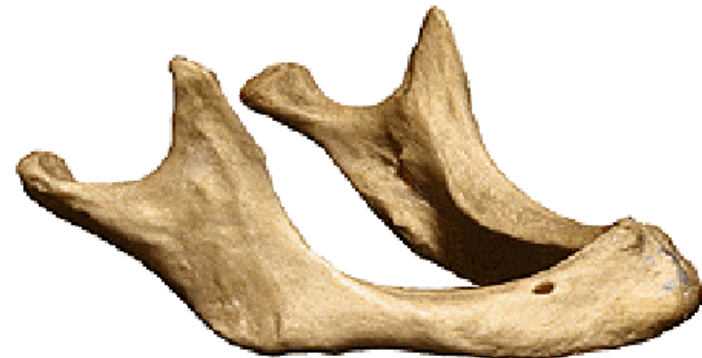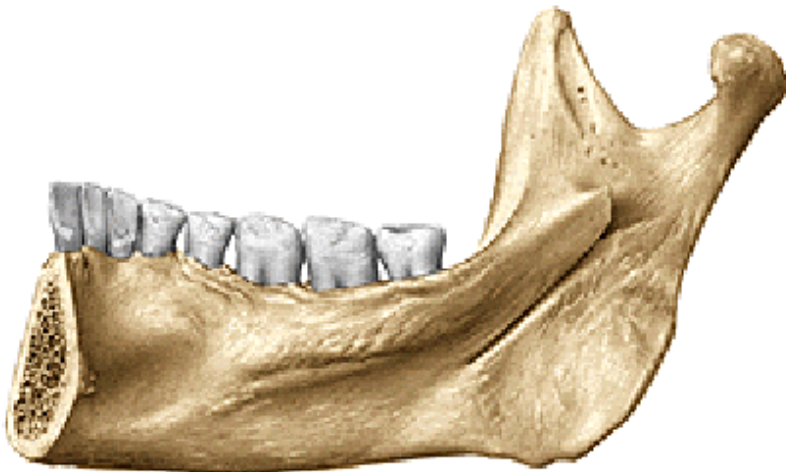Tuberositas pterygoidea (zevnitř)



Mandibula novorozence



Mandibula starého člověka

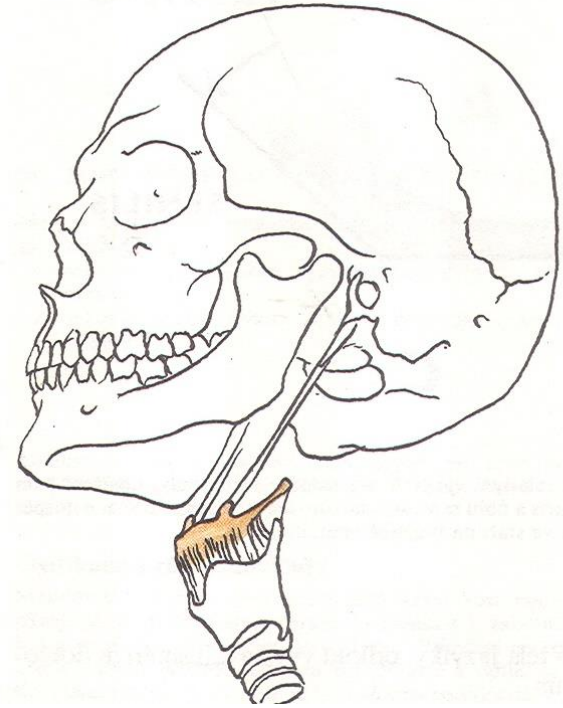
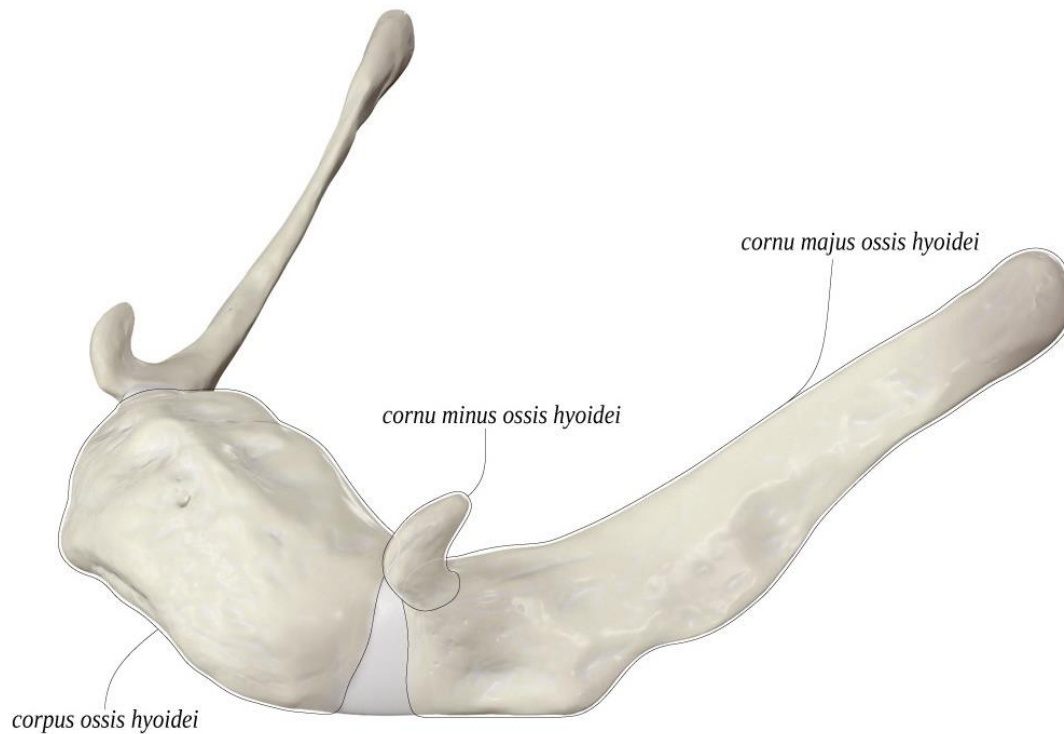


Os hyoideum (jazyłka)

Corpus

Cornua minora ossis hyoidei

Cornua majora ossis hyoidei



Děkuji za pozornost!

Použité obrázky byly převzaty z

Čihák, R. (1987): Anatomie 1. Avicenum, Zdravotnické nakladatelství.

Putz, R. (2008): Atlas of Human Anatomy Sobotta. Elsevier Books.

Keith L. Moore, Arthur F. Dalley (2005): Clinically Oriented Anatomy. Williams and Wilkins.

Platzer, W., Kahle, W., Leonhardt H. (1992): Locomotor system. Georg Thieme Verlag, Stuttgart, New York, 4th edition.

**Drake et al: Gray's Anatomy for students. 2010
Anatomy Standard**