

## DTI Tractography of the Human Brain's Language Pathways

Matthew F. Glasser<sup>1</sup> and James K. Rilling<sup>1,2,3,4</sup>

<sup>1</sup>Department of Anthropology, <sup>2</sup>Department of Psychiatry and Behavioral Sciences, <sup>3</sup>Center for Behavioral Neuroscience and <sup>4</sup>Yerkes National Primate Research Center, Emory University, Atlanta, GA 30322, USA

**Diffusion Tensor Imaging (DTI) tractography has been used to detect leftward asymmetries in the arcuate fasciculus, a pathway that links temporal and inferior frontal language cortices. In this study, we more specifically define this asymmetry with respect to both anatomy and function. Twenty right-handed male subjects were scanned with DTI, and the arcuate fasciculus was reconstructed using deterministic tractography. The arcuate was divided into 2 segments with different hypothesized functions, one terminating in the posterior superior temporal gyrus (STG) and another terminating in the middle temporal gyrus (MTG). Tractography results were compared with peak activation coordinates from prior functional neuroimaging studies of phonology, lexical-semantic processing, and prosodic processing to assign putative functions to these pathways. STG terminations were strongly left lateralized and overlapped with phonological activations in the left but not the right hemisphere, suggesting that only the left hemisphere phonological cortex is directly connected with the frontal lobe via the arcuate fasciculus. MTG terminations were also strongly left lateralized, overlapping with left lateralized lexical-semantic activations. Smaller right hemisphere MTG terminations overlapped with right lateralized prosodic activations. We combine our findings with a recent model of brain language processing to explain 6 aphasia syndromes.**

**Keywords:** aphasia, arcuate fasciculus, asymmetry, lexical-semantic, phonologic, prosody

### Introduction

Human language function was classically thought to be mediated by 2 brain areas in the left hemisphere: Broca's area for speech production (Broca 1861) and Wernicke's area for speech comprehension (Wernicke 1874). The arcuate fasciculus, a prominent fiber pathway that originates in the temporal lobe and curves around the Sylvian fissure to project to the frontal lobe (Dejerine 1895), was thought to connect these 2 areas. Wernicke (1874) hypothesized that interruption of this pathway would disconnect speech comprehension from speech production and thus lead to a specific deficit, called conduction aphasia, where the patient could not repeat what they heard. This syndrome was confirmed clinically when Lichtheim described such a patient in 1885.

The original post-mortem dissections of the arcuate by Dejerine and others have been replicated in vivo using Diffusion Tensor Imaging (DTI) tractography (Catani et al. 2005; Nucifora et al. 2005; Parker et al. 2005; Hagmann et al. 2006; Powell et al. 2006), a neuroimaging technique that allows for the virtual dissection of fiber tracts in the living brain based on the directionally biased diffusion of water in white matter (Beaulieu 2002). Several DTI tractography studies have

demonstrated leftward asymmetry in the arcuate fasciculus as a whole, using a variety of methods (Hagmann et al. 2006; Powell et al. 2006; Barrick et al. 2007; Vernooij et al. 2007). These findings are consistent with known left lateralization of language function in most humans. Other groups have described novel pathways, beyond the classic arcuate fasciculus, which they have included in revised models of the language network (Catani et al. 2005; Parker et al. 2005).

Human language is a complex and multifaceted cognitive capacity. In this paper, we focus on just 3 components of language: phonemes, the basic sounds that make up words, lexical-semantic, the concepts and meanings of words and the vocabulary of words associated with these meanings, and prosody, the modification of the pronunciation of speech to convey additional meaning. Other components of language, for example syntax, morphology, combinatorial semantics, and pragmatics are beyond the scope of this paper; however, any complete account of brain language processing will include these components. Phonologic processing has 2 aspects, receptive processing of phonemes in Wernicke's area (posterior Brodmann's Area [BA] 22) and BA 40 (Binder et al. 1997, 2000; Canestra et al. 2000; Castillo et al. 2001; Jancke et al. 2002; McDermott et al. 2003), and expressive production of phonemes during speech in posterior Broca's area (BAs 44 and 6) (Paulesu et al. 1997; Price 2000; Bookheimer 2002; McDermott et al. 2003; Hickok and Poeppel 2004). Notably, this phonologic system can be entirely disconnected from lexical-semantic and operate independently, allowing patients to repeat what they hear but not comprehend or speak spontaneously in any meaningful way (Geschwind et al. 1968). The lexical-semantic system is thought to involve middle and inferior temporal areas (BAs 21 and 37) (Vandenberghe et al. 1996; Binder et al. 1997, 2000; Canestra et al. 2000; Price 2000; Castillo et al. 2001; Hickok and Poeppel 2004; Poeppel et al. 2004), along with Broca's area and frontal areas more anterior and superior to it (BAs 44, 45, 47, 9) (Binder et al. 1997; Paulesu et al. 1997; Bookheimer 2002; McDermott et al. 2003). Although the phonologic system tends to show bilateral activation in imaging studies (Binder et al. 1997, 2000; Price 2000; Jancke et al. 2002; Hickok and Poeppel 2004; Poeppel et al. 2004), activations of the lexical-semantic system tend to be lateralized to the left (Vandenberghe et al. 1996; Binder et al. 1997, 2000; Price 2000; Ahmad et al. 2003; Hickok and Poeppel 2004; Poeppel et al. 2004).

Studies of speech prosody, however, show the opposite lateralization. Examples of prosody are the rise in pitch at end of a sentence that asks a question (linguistic prosody) or the tone that conveys one's emotional state (emotional or affective prosody) (Wildgruber et al. 2006). Ethofer et al. (2006) found that the posterior right middle temporal gyrus (MTG) is

involved in the representation of meaningful prosodic sequences, and used a dynamic causal model of functional magnetic resonance imaging activations to show that the right MTG is connected to the frontal lobe bilaterally. Linguistic prosodic sequences then selectively activated the left inferior frontal gyrus, whereas emotional prosodic sequences activated the right inferior frontal gyrus (Ethofer et al. 2006). A number of other studies have found right lateralized posterior temporal lobe activations in prosodic processing tasks when compared with nonprosodic processing tasks (Meyer et al. 2002; Riecker et al. 2002; Mitchell et al. 2003; Wildgruber et al. 2005). Additionally, Riecker et al. (2002) found right lateralized activations in the right inferior frontal gyrus and precentral gyrus when prosodic production tasks were contrasted with nonprosodic phonological production tasks suggesting that the right hemisphere homologue of Broca's area is involved in the production of speech prosody.

In this paper, we use DTI to track arcuate fasciculus connections to the cortical regions implicated in phonologic, lexical-semantic and prosodic processing and assess their degree of laterality. Based on the preceding functional neuroimaging findings, we expected to find a relatively bilateral arcuate connection to the superior temporal gyrus (STG), because studies of phonologic processing show bilateral STG activations. Although there is evidence that both left-sided lexical-semantic processing and right-sided prosodic processing involve both MTG and inferior frontal cortex, lexical-semantic activations are distributed over a larger area of the middle and inferior temporal gyri, relative to prosodic activations. Therefore, we expected to find a leftwardly asymmetric connection to MTG. DTI tractography results were then compared with activation coordinates from prior functional neuroimaging studies of phonology, lexical-semantic processing, and prosodic processing. We selected 5 studies each of phonologic (Paulesu et al. 1993; Belin et al. 2002; Jancke et al. 2002; Joanisse and Gati 2003; Specht et al. 2003), lexical-semantic (Vandenberghe et al. 1996; Thompson-Schill et al. 1997; Price et al. 1999; Ahmad et al. 2003; McDermott et al. 2003), and prosodic processing (Meyer et al. 2002; Riecker et al. 2002; Mitchell et al. 2003; Wildgruber et al. 2005; Ethofer et al. 2006) that reported their coordinates in standard space, with which to compare our tractography results. We then interpret our results in the context of a recent model of brain language processing (e.g., Price 2000; Hickok and Poeppel 2004), to which we add prosodic processing, and then test this model against some of the common aphasias and aprosodias reported in the literature.

## Materials and Methods

### Subjects and Image Acquisition

Twenty right-handed male subjects, aged 18–50 (mean: 23.75, SD 7.1), were scanned with a Siemens Trio 3-Tesla MRI scanner. Subjects were restricted to right-handed males (determined by Waterloo Handedness Inventory) (Bryden 1977), as handedness and sex are known to influence language laterality, and could therefore introduce variability into results (Hagmann et al. 2006). All subjects gave written informed consent and the study was approved by the Emory University Institutional Review Board. Diffusion weighted images were collected using a Siemens Standard echo planar imaging single shot DTI sequence (time echo [TE] = 90, time repetition [TR] = 7700) with 12-diffusion directions defined evenly across the sphere with a diffusion weighting of  $b = 1000$  and one volume with  $b = 0$ ,  $1.7 \times 1.7 \times 2.0$  mm voxels, 6 signal averages, and 34 slices. Because 34 slices at 2.0 mm is not

sufficient to cover the whole brain, the FOV was positioned on the localizer to ensure that the middle and inferior frontal, inferior parietal, and middle and inferior temporal cortices were included. A Transverse Electro-Magnetic head coil was used to improve the signal to noise ratio of the images. A  $T_1$ -weighted magnetization prepared rapid gradient echo anatomical scan (TR = 2300 ms, TE = 4 ms, matrix =  $256 \times 256$ , field of view = 256, slice thickness = 1.0 mm) was also collected from each subject for anatomical localization of the fiber tracts. Total scanning time was approximately 30 min per subject including setup time.

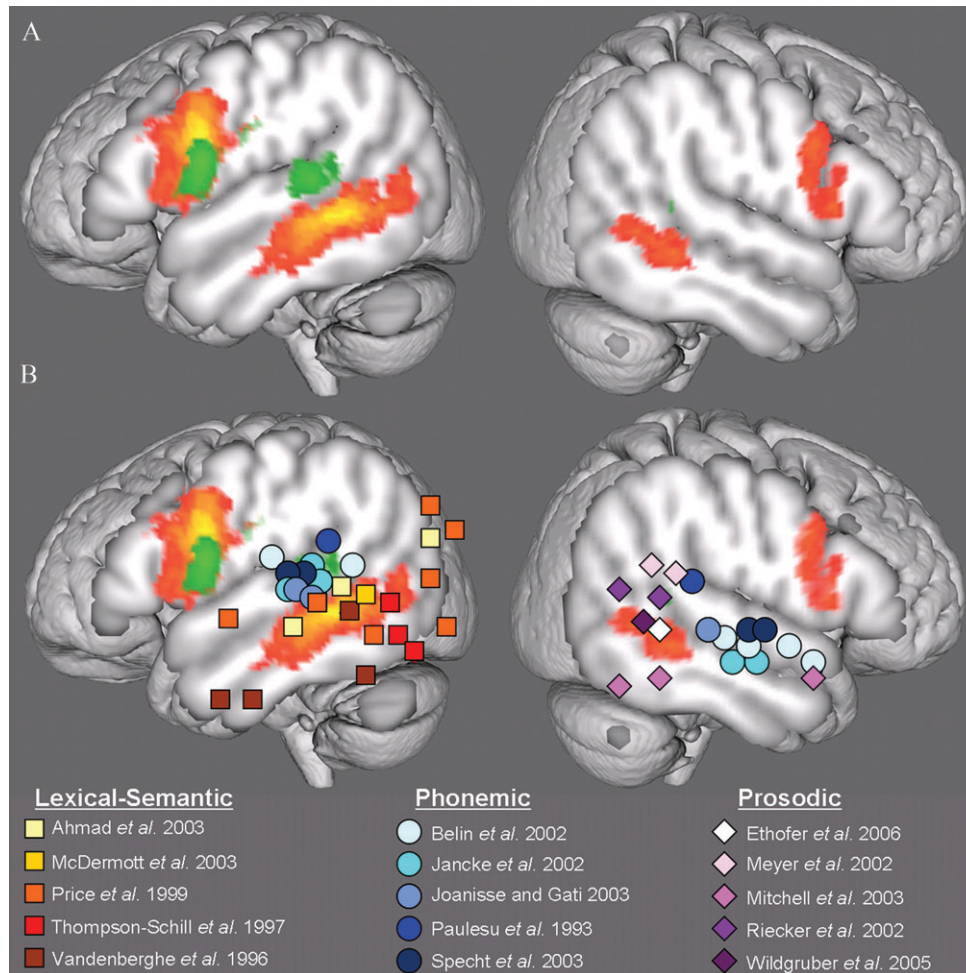
### Image Analysis

Images were analyzed with the Siemens DTI Task Card software (Wang 2006), which uses a deterministic tractography algorithm. The algorithm itself is based on the FACT tractography algorithm (Mori and van Zijl 2002); however, fibers are only initiated from the regions of interest (ROIs), and are not generated across the entire brain. When using a 2 ROI approach, fibers are generated from both ROIs, but retained only if they reach the second ROI. Tractography was conducted using the following parameters set in the DTI Task Card: number of samples per voxel length = 8, minimum fractional anisotropy (FA) threshold = 0.15, maximum turning angle between voxels =  $15^\circ$ , step length between calculations = 0.25 mm.

The arcuate fasciculus was tracked using the following approach: First, a single ROI was drawn on a coronal slice of the DTI color map to select the fibers of the arcuate fasciculus in the left (and right) hemisphere (Supplementary Fig. 1a). This single ROI defines all of the fibers oriented in an anterior–posterior direction, which includes the arcuate and neighboring fibers, such as those in Superior Longitudinal Fasciculus (SLF) II and III (Makris et al. 2005). Because all arcuate fibers must pass through this bottleneck, it is an ideal region to localize the pathway reliably. Tractography from this ROI reveals 2 regions of arcuate terminations within the temporal lobe and additional non-arcuate terminations in the parietal lobe (Supplementary Fig. 1b). Both arcuate and nonarcuate terminations are also found in the frontal lobe. To isolate the arcuate from other tracts and divide it into STG and MTG segments, a 2-ROI approach is required. First, however, the arcuate specific terminations in the frontal lobe must be determined: separate ROIs were defined around the terminations in the posterior STG—Wernicke's area (BA 22)—and around the terminations that lie below the superior temporal sulcus in the MTG (BAs 21 and 37). Tractography was done from each temporal lobe ROI to identify its frontal lobe projections (Supplementary Fig. 1c,d). The combined frontal terminations from these 2 temporal lobe ROIs were used to define a frontal lobe ROI, which includes Broca's area and surrounding cortex (BAs 44, 45, 6, and 9). Finally, a 2 ROI approach involving the combined frontal lobe ROI and each temporal lobe ROI was used to produce 2 segments, a smaller green segment linking posterior STG and Broca's area, and a larger orange pathway linking the MTG (BAs 21 and 37) to Broca's area and surrounding cortex (Fig. 1A). To ensure that no relevant fibers were missed, frontal and temporal ROIs were expanded until there was at least one empty ROI voxel between the pathway and the edge of the ROI.

### Transformation to Structural Space and Anatomical Verification of ROIs

The ROIs and results were moved into structural space to allow for more accurate anatomical localization than is possible in native diffusion space using the DTI Task Card. The raw diffusion data were processed using FSL's FDT package to create a Fractional Anisotropy map. This map was linearly registered to each subject's  $T_1$  image using the  $T_1$  as the reference with FSL's FLIRT tool (Jenkinson et al. 2002), producing a linear transformation between diffusion and structural spaces. Results and ROIs from the DTI Task Card that were processed in diffusion space were then saved in analyze format and transformed into structural space using the transformation matrix calculated in FSL. Upon inspection on each subject's  $T_1$ , ROIs that were found to extend outside the STG, MTG, or frontal lobe were edited in the individual subject's structural space, and then transformed back into diffusion space to be retracked.



**Figure 1.** (A) Average arcuate fasciculus tractography results for the 20-subject data set. Connections linking the STG with the frontal lobe are colored green. Connections linking the regions below the superior temporal sulcus with the frontal lobe are colored orange. Average pathways were thresholded to include voxels in which at least 2 subjects had a pathway. (B) Functional activations overlaid on average tractography results, in standard space. Each study in each hemisphere is represented by a different color. Lexical-semantic tasks are represented as squares, phonemic tasks are represented as circles, and prosodic tasks are represented as diamonds.

### Transformation to Standard Space and Averaging

Because the DTI Task Card program does not allow for comparison of tractography results in standard space, we devised a method to move our results into standard space to permit presentation of group average results. Tractography results were transformed into standard Montreal Neurological Institute (MNI) space and averaged using the following method: each subject's FA image was coregistered to all the others' using first linear and then nonlinear registration with the ITK registration algorithm, included as a part of FSL's TBSS tool (Smith *et al.* 2006). The FA image that required the least warping of all other images was used as a final target and this FA was linearly registered to the MNI 152 standard brain. These registrations produced 2 transformation matrices, a nonlinear matrix between each subject's diffusion space and the target space, and a common linear matrix between the target and the MNI standard brain. Individual subject's tractography results were transformed into standard space using these matrices, and then averaged to produce a group result (Fig. 1A).

### Plotting Functional Activation Coordinates

Peak temporal lobe activation coordinates were derived from 5 studies each of phonologic (Paulesu *et al.* 1993; Belin *et al.* 2002; Jancke *et al.* 2002; Joanisse and Gati 2003; Specht *et al.* 2003), lexical-semantic (Vandenberghe *et al.* 1996; Thompson-Schill *et al.* 1997; Price *et al.* 1999; Ahmad *et al.* 2003; McDermott *et al.* 2003), and prosodic processing (Meyer *et al.* 2002; Riecker *et al.* 2002; Mitchell *et al.* 2003; Wildgruber *et al.* 2005; Ethofer *et al.* 2006) that reported their coordinates in standard space. In studies that reported multiple contrasts, we selected

language component-specific functional contrasts, rather than contrasts of components versus rest, as recommended by (Vigneau *et al.* 2006). In a study of prosody (Mitchell *et al.* 2003), for example, we used the contrast between prosodic and semantic processing, rather than either prosodic or semantic processing versus rest. All coordinates were plotted in MNI space, and those reported in Talairach space were first transformed to MNI space (see <http://imaging.mrc-cbu.cam.ac.uk/imaging/MniTalairach>). To aid in viewing the activation peaks in the figure, coordinates were plotted above the surface of the brain at MNI coordinate ( $x = \pm 75$ ), and thus all coordinates lie in a 2 dimensional plane (Fig. 1B).

### Quantitative and Statistical Analysis

Pathway asymmetry was assessed by recording the volume of each pathway in  $1.7 \times 1.7 \times 2$  mm voxels. In cases where a pathway was not tracked, the volume was considered zero. A paired *t*-test was used to test for pathway asymmetry.

## Results

### The STG Pathway

In the left hemisphere, the pathway connecting the STG to the frontal lobe was found in 17 of 20 subjects. The left hemisphere

STG pathway consistently linked the posterior part of the STG (BA 22) to BAs 44 and 6. In the right hemisphere, the pathway was identified in only 4 of 20 subjects, and connected posterior BA 22 to BAs 6 and 44 in the frontal lobe (Fig. 1A, Supplementary Fig. 2). Pathway volume was highly leftwardly asymmetric (paired  $t = 4.26$ ,  $P < 0.0001$ ), with an average volume of  $2724 \text{ mm}^3$  ( $\pm 438 \text{ mm}^3$ ) on the left and  $516 \text{ mm}^3$  ( $\pm 240 \text{ mm}^3$ ) on the right (Fig. 2, Supplementary Table 1).

### The MTG Pathway

In the left hemisphere, the pathway linking the MTG to the frontal lobe was found in all 20 subjects. The temporal lobe focus of projection included BA 21 and BA 37, whereas the focus of projection in the frontal lobe was BA 44, and also included parts of BAs 6, 9, and 45. In the right hemisphere, the MTG pathway was present in 11 of 20 subjects, and it was smaller than its left hemisphere counterpart in those 11 subjects (Fig. 1A, Supplementary Fig. 2). The focus of the projection in the right hemisphere was more posterior, terminating mainly in BA 37, whereas the left hemisphere pathway extends significantly more anteriorly into BA 21. In the right frontal lobe, the MTG pathway's projection was also more posterior, focusing in BA 6 and posterior BA 44. Pathway volume was highly leftwardly asymmetric (paired  $t = 6.85$ ,  $P < 0.0001$ ), with an average of  $9863 \text{ mm}^3$  ( $\pm 860 \text{ mm}^3$ ) on the left and  $3720 \text{ mm}^3$  ( $\pm 934 \text{ mm}^3$ ) on the right (Fig. 2, Supplementary Table 1).

### Functional Activations Plotted on the Tractography Results

Activations from phonologic studies were bilateral, and overlapped with the termination of the STG pathway in the left hemisphere (Fig. 1B). In the right hemisphere, however, the foci of activation were located more anteriorly in the STG/STS, and did not overlap with the STG pathway in the 4 subjects in which it was detectable. The lexical-semantic activations were found throughout the middle and inferior temporal gyri, along with the angular gyrus, of the left hemisphere; however, they were concentrated over the termination of the left hemisphere MTG pathway. In the right hemisphere, the activations in prosody-processing studies overlapped with both the MTG segment and the STG segment, suggesting that in some subjects, the cortex involved in prosodic processing extends beyond the superior bank of the STS and into a small portion of the posterior STG.

### Discussion

DTI tractography revealed significant leftward asymmetries in the connection between both the STG and the frontal lobe and the MTG and the frontal lobe. Although the absolute difference between left and right volumes was greater for the MTG segment, when considering the number of subjects in which a right hemisphere pathway was present, the STG pathway was more asymmetric. In the left hemisphere, we found that temporal lobe activations in phonologic processing tasks overlapped with the termination of the STG pathway, whereas lexical-semantic activations overlapped with the termination of the MTG pathway. In the right hemisphere, very few subjects had an STG pathway, and, in those who did, it did not overlap with phonologic activations, which in the right

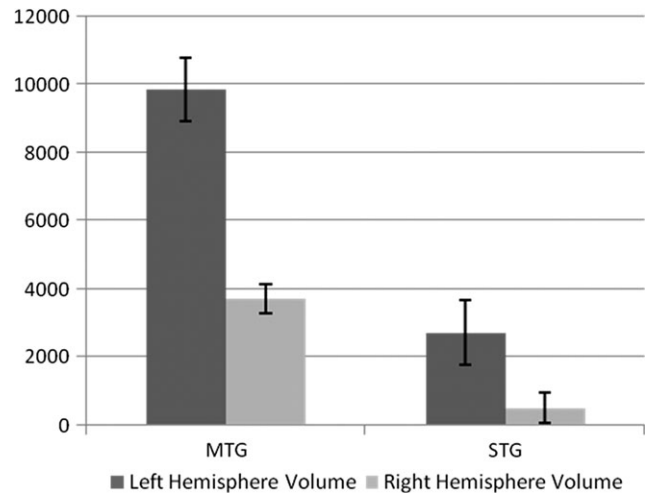


Figure 2. Volumes of the MTG and STG pathways.

hemisphere are located more anteriorly in the mid-STG/STS than they are in the left. When present in the right hemisphere, the MTG pathway overlapped with temporal lobe activations in prosodic tasks. Although we found the MTG pathway in the left hemisphere of all 20 subjects, we found the STG pathway in the left hemisphere of only 17 of 20 subjects. Because it is a much smaller pathway than the MTG pathway, the STG may be more vulnerable to crossing fibers or motion artifacts, which may have prevented its identification in the left hemisphere of some subjects (see Limitation of Method).

The pattern of pathway asymmetry that we found does not always correlate with lateralization of function inferred from functional neuroimaging experiments. Functional imaging studies suggest that the STG is bilaterally involved in phonologic processing (Binder et al. 1997, 2000; Price 2000; Castillo et al. 2001; Jancke et al. 2002), whereas the areas below the superior temporal sulcus, BA 21 and 37, are involved in left lateralized lexical-semantic processing (Vandenberghe et al. 1996; Binder et al. 1997, 2000; Canestras et al. 2000; Price 2000; Castillo et al. 2001; Hickok and Poeppel 2004; Poeppel et al. 2004). Although the STG is bilaterally involved in phonologic processing (Paulesu et al. 1993; Belin et al. 2002; Jancke et al. 2002; Joanisse and Gati 2003; Specht et al. 2003), we found that only the left hemisphere has a strong and consistent connection to the frontal lobe via the arcuate. In addition, we found that, although the pathway connecting the MTG to the frontal lobe is leftwardly asymmetric, a significant number of subjects also had a weaker pathway connecting MTG to the frontal lobe in the right hemisphere. Whereas lexical-semantic processing is left lateralized (Vandenberghe et al. 1996; Thompson-Schill et al. 1997; Price et al. 1999; Ahmad et al. 2003; McDermott et al. 2003), prosodic processing is right lateralized (Meyer et al. 2002; Riecker et al. 2002; Mitchell et al. 2003; Wildgruber et al. 2005; Ethofer et al. 2006), and prosodic activations overlap with the temporal lobe termination of the smaller right MTG pathway.

Our findings can be reasonably interpreted within the framework of the language model of Price (2000) and Hickok and Poeppel (2004) (Fig. 3, Color: Supplementary Fig. 3). According to this model, auditory information first processed in

primary auditory cortex is then decoded phonologically in Wernicke's area (posterior BA 22). From there, it can be conveyed directly on to Broca's area if it is to be repeated immediately, via the STG pathway, or it can be relayed to cortex below the superior temporal sulcus for lexical-semantic comprehension. The lexical-semantic area is strategically located on the boundary between auditory and visual association cortex, receiving inputs from both Wernicke's area and primary auditory cortex, as well as extrastriate visual cortex (Price 2000; Hickok and Poeppel 2004). Thus, the lexical-semantic area receives inputs from both auditory and visual sensory modalities, allowing it to make associations between them. In humans, unlike other primates, it also responds to auditory and visual linguistic stimuli, activating the appropriate modality-specific neurons to reproduce internally whatever concept was represented by the words heard or seen (Barsalou et al. 2003). For example, particular neurons in the lexical-semantic area might respond not only to seeing a cat and hearing a cat, but also hearing someone say the word "cat," or seeing the word "cat" written on a page, and then regenerate images and sounds related to cats. From the lexical-semantic area, information is conveyed to the frontal lobe, including Broca's area during spontaneous speech. The high level lexical-semantic processing required to form logical and coherent speech requires the language areas in the frontal and temporal lobes to communicate through the bi-directional connections (Matsumoto et al. 2004) that comprise the MTG pathway. The same functional studies showing lexical-semantic activation in BAs 21 and 37 also show significant frontal lobe activations in both Broca's area and areas anterior and superior to it (Vandenberghe et al. 1996; Binder et al. 1997, 2000; Ahmad et al. 2003; McDermott et al. 2003; Martin 2005). Posterior Broca's area would then generate the speech output. The direct phonological loop, connecting the posterior STG to Broca's area, might be particularly important during the acquisition of language by children, as it allows decoded phonemes direct access to Broca's area for speech output. It may provide an anatomical substrate for the imitation of speech, a critical part of early language acquisition (Ferguson and Farwell 1975), whereas the MTG pathway might be most important for carrying lexical-semantic information during the spontaneous production of established speech.

The right hemisphere is different, however, in both connectivity and function (Fig. 3, Color: Supplementary Fig. 3). Wildgruber et al. (2006) and Meyer et al. (2002) have suggested that, whereas the left hemisphere auditory cortex is specialized to analyze the segmental aspects of sound, for example the rapid changes in intensity and pitch that make up phonemes, the right hemisphere auditory association cortex is specialized to process the slower changes of the suprasegmental aspects of language, for example the slower variations in melody and intonations of prosody. Unlike in the left hemisphere, however, the right auditory association cortex in the STG that is implicated in phonologic processing does not have a direct connection to the frontal lobe via the arcuate fasciculus. In the 4 subjects who did have a right hemisphere STG pathway, its posterior termination did not line up with the phonologic activations. In contrast to the left hemisphere, the only consistently found right hemisphere temporal-frontal arcuate connection links the posterior MTG and the frontal lobe, and is much weaker than the homologous connection in the left hemisphere. This is the same area that is activated

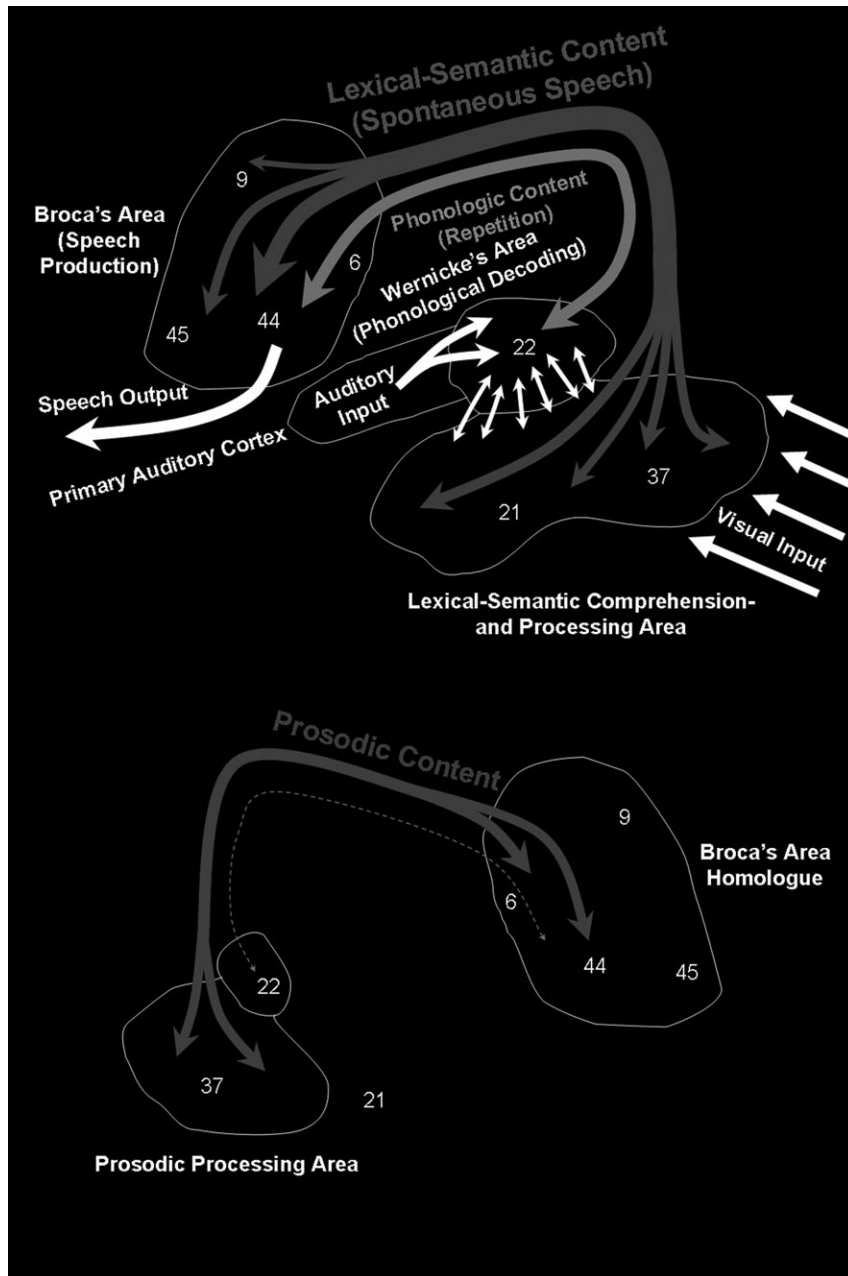
during functional imaging studies that compare affective prosodic processing to linguistic processing (Meyer et al. 2002; Riecker et al. 2002; Mitchell et al. 2003; Wildgruber et al. 2005; Ethofer et al. 2006). In addition, in the 4 subjects who have an STG pathway, its posterior termination also lines up with the prosodic activations, suggesting that the STG and MTG segments may not have distinct functions in the right hemisphere. The right hemisphere pathway then carries prosodic information to the inferior frontal lobe, which is active in the same prosodic tasks as the right temporal lobe (Meyer et al. 2002; Riecker et al. 2002; Mitchell et al. 2003; Wildgruber et al. 2005; Ethofer et al. 2006). Thus, we provide anatomical evidence for one of the pathways predicted by the dynamic causality model of Ethofer et al. (2006). Ethofer et al. (2006) also predicted a parallel pathway whereby prosodic information is integrated with linguistic information in the inferior frontal lobe of the left hemisphere, which has been supported by Ross et al.'s (1997) study of aprosodia caused by callosal lesions.

In summary, we provide anatomical evidence for the phonologic and lexical-semantic pathways postulated in the model of Price (2000) and Hickok and Poeppel (2004). In addition, we provide anatomical evidence for a right hemisphere pathway between the MTG and the frontal lobe that is hypothesized to be involved in prosody (Ethofer et al. 2006). However, can this model, informed by our tractography results, explain the common categories of aphasias and aprosodias?

### ***The Aphasias and Aprosodias: a Post Hoc Test for the Model of the Language Network***

#### ***Broca's and Wernicke's Aphasias***

Broca's aphasia is generally caused by lesions to the left inferior frontal gyrus (BAs 44 and 45) or its subcortical connections (Damasio and Geschwind 1984; Damasio 1992; Kreisler et al. 2000; Dronkers et al. 2007). Moreover, to have the permanent Broca's aphasia syndrome, and not a more transient condition, requires damage to the premotor cortex of the precentral gyrus (BA 6) and the frontal operculum (Naeser 1978; Kertesz et al. 1979) and often the left basal ganglia (Lieberman 2002). Patients with Broca's aphasia have great difficulty producing fluent grammatical speech both spontaneously and when repeating. Although Broca's aphasics can generally still communicate, their speech is halting and slow and lacks many of the grammatical words, such as prepositions, conjunctions, and pronouns, and they have difficulty producing and discriminating between some phonemes. They also have impaired comprehension of grammatically complex sentences, such as those in the passive voice (Damasio 1992). The symptoms of Broca's aphasia give us some clue of the functions of the damaged cortex. Damage to the inferior motor and premotor cortex in the left hemisphere likely causes the dysarthria of Broca's aphasia. The agrammatism of Broca's aphasia probably results from the destruction of BAs 44 and 45, which are thought to be heavily involved in grammar and syntax (Bookheimer 2002; Sakai 2005). The lesions that cause Broca's aphasia destroy the frontal cortical terminations of both the STG and the MTG pathways. Damage to these areas likely causes both phonologic discrimination and production deficits, and deficits in comprehension of complex grammatical material. The last of these likely arises from the failure of the



**Figure 3.** The functions of the STG and MTG pathways according to the model of Hickok and Poeppel (2004) and Price (2000) in the left hemisphere (top), and the right hemisphere (bottom). Color figure: Supplementary Figure 3.

posterior lexical-semantic comprehension area to access the frontal cortex involved in grammatical analysis when syntactically complex linguistic material is encountered.

Wernicke's aphasia is generally caused by lesions to the left STG or its subcortical connections (Damasio and Geschwind 1984; Damasio 1992; Kreisler et al. 2000). Patients often also have damage to inferior parietal cortex and middle and inferior temporal cortex (Damasio and Geschwind 1984), and middle and inferior temporal cortical damage is associated with a particularly poor prognosis for functional recovery (Naeser et al. 1987). Wernicke's aphasics speak fluently, but with frequent phonologic and semantic errors. These deficits occur during both spontaneous and repetition, often making their speech unintelligible or meaningless. Wernicke's aphasics

also have great difficulty understanding speech and naming objects (Damasio 1992), making their deficit more devastating than Broca's aphasia. Patients with smaller lesions limited to Wernicke's area (the phonologic cortex of posterior BA 22) often show marked improvement, in contrast to patients with larger lesions including the lexical-semantic cortex of the middle and inferior temporal gyri (Kertesz et al. 1979; Naeser et al. 1987). The improvement shown by patients with the smaller lesions may be due to the right hemisphere homologue taking over phonologic processing functions, whereas the more devastating cases include damage to left lateralized lexical-semantic cortex, for which the right hemisphere counterpart cannot effectively compensate. Thus, Wernicke's aphasia can be understood as a disruption of the phonologic

processing in the left STG, impeding phonologic decoding of heard speech so that it never reaches the lexical-semantic comprehension areas. In more serious and permanent cases, the lexical-semantic comprehension areas are also damaged, resulting in semantic paraphasias and anomias. In addition, the destruction of Wernicke's area impairs speech production by disrupting the posterior portion of the phonologic circuit, resulting in phonemic paraphasias. Although these 2 aphasia syndromes are thought to be explained by classic model of the language network (Wernicke 1874; Lichtheim 1885; Geschwind 1965), the model of Hickok and Poeppel (2004) and Price (2000) combined with our tractography results effectively explains some nuances that were not previously clear, such as the difficulties Broca's aphasics have in comprehending syntactically complex linguistic content, and the worse prognosis for Wernicke's aphasics with lesions that include the MTG.

### *Conduction Aphasia*

Conduction aphasia shares with Broca's and Wernicke's aphasias the deficit in repetition, but both comprehension and spontaneous speech are largely preserved. Classically, conduction aphasia was thought to be caused by a lesion to the arcuate fasciculus, disconnecting Wernicke's and Broca's areas (Wernicke 1874; Lichtheim 1885; Geschwind 1965). Lesions that cause conduction aphasia are typically located in the left supermarginal gyrus (BA 40) and involve the underlying white matter (Warrington et al. 1971; Damasio and Damasio 1980; Damasio and Geschwind 1984; McCarthy and Warrington 1984). However, cases have been reported that involved only the insula and nearby extreme capsular white matter (Damasio and Geschwind 1984; Damasio 1992), suggesting the possibility of another route between Wernicke's and Broca's areas. Along with their difficulty repeating, patients with conduction aphasia often produce phonologic errors in their speech, and may have difficulty naming (Damasio 1992). Damage to the phonologic language circuit is the most likely cause of the disruption of phonologic tasks like repetition that rely on communication of phonologic information between the anterior and posterior language areas. The STG pathway we describe here passes superficially through the white matter under the supramarginal gyrus, and is highly leftwardly asymmetric, which correlates with the fact that conduction aphasia occurs with left hemisphere lesions. Furthermore, recent work (Parker et al. 2005; Friederici et al. 2006; Anwander et al. 2007) suggests the existence of an additional pathway between the STG and Broca's area that travels a ventral route, medial to the insula, via the extreme capsule. Damage to either or both of these pathways caused by lesions in the immediate perisylvian area could result in conduction aphasia, and the existence of 2 separate pathways may explain cases where arcuate fasciculus lesion does not result in conduction aphasia or where conduction aphasia does not result from arcuate lesion. The MTG pathway might also be damaged in some cases of conduction aphasia, which would account for the naming difficulties.

More recently, there has been debate as to whether or not an arcuate fasciculus lesion is necessary or sufficient to cause conduction aphasia (Damasio and Damasio 1980; Kempler et al. 1988; Damasio 1992; Anderson et al. 1999). The lesions tend to involve cortex immediately surrounding the Sylvian fissure, including primary auditory cortex and the supramarginal gyrus,

which is thought to participate in phonologic working memory (Baddeley 2003; Woodward et al. 2006). At the same time, the white matter beneath this cortex contains connections between the STG and Broca's area, which run both dorsally and ventrally (Parker et al. 2005). Thus, lesions in this area would damage the phonologic circuit, either by damaging the phonologic cortex or the relatively shallow white matter connections between anterior and posterior phonologic areas. For an arcuate fasciculus lesion to cause only conduction aphasia with deficits in repetition and without lexical-semantic deficits, it would need to be relatively superficial to avoid significantly damaging the MTG pathway, which makes up the medial portion of the arcuate fasciculus. A deeper lesion to the arcuate fasciculus would not necessarily cause conduction aphasia symptoms: Selnes et al. (2002) presented the case of a 55-year-old right-handed man who suffered from a left middle cerebral artery stroke that damaged the arcuate fasciculus. In the acute phase of the stroke, the patient had severe difficulties with spontaneous speech, naming, and comprehension of grammatically complex material. The patient retained relatively normal repetition function, however. Structural and DTI imaging showed a large lesion including the arcuate fasciculus. The majority of the arcuate fasciculus is the MTG pathway, in the left hemisphere, and the patient's acute symptoms match transcortical motor aphasia (difficulty with spontaneous speech, naming, and comprehension of complex grammatical content without a loss of repetition) very well (Freedman et al. 1984), a syndrome that will be discussed in more detail shortly. Given the patient's retention of repetition, the lesion likely did not damage both the dorsal and the ventral (Parker et al. 2005; Friederici et al. 2006; Anwander et al. 2007) connections between STG and Broca's area. Two years later, the patient had lingering deficits of speech expression, including naming, and of comprehension of complex grammatical material; however, much of his aphasia had resolved (Selnes et al. 2002). In this case, the classic model of the language network would predict impairment of repetition and would not explain the impairment of spontaneous speech, naming, or comprehension of grammatically complex material; however, the model of Hickok and Poeppel (2004) and Price (2000) combined with our tractography results addresses these findings. Moreover, repetition in patients with conduction aphasia is often improved by forcing them to focus on the semantic content of the sentences they are to repeat (McCarthy and Warrington 1984), thereby using the mostly intact MTG pathway to bypass the damaged STG pathway, whereas patients with transcortical motor aphasia are impaired by focusing on the semantic content of sentences they are to repeat (McCarthy and Warrington 1984). Thus, the deficits present in conduction aphasia can be best explained by damage to the relatively superficial STG and extreme capsule pathways and/or the surrounding phonologic cortex, rather than a deeper lesion that damages mostly the more medial MTG pathway of the arcuate fasciculus, as argued by the classic model.

### *The Transcortical Aphasias*

Transcortical motor aphasia is an expressive language disorder characterized by limited spontaneous speech, impaired naming, intact repetition, normal articulation, and relatively good auditory comprehension (with the exception of complex grammatical sentences) (Freedman et al. 1984). Patients with

transcortical motor aphasia often have lesions to the cortex anterior to and superior to classic Broca's area (Damasio 1992) and to the underlying white matter (Damasio and Geschwind 1984; Freedman et al. 1984), in the location of the termination of the MTG pathway. Transcortical motor aphasia has also been reported from purely subcortical white matter lesions (Naeser et al. 1982), and deep lesions affecting the supramarginal gyrus (BA 40) and its underlying white matter (McCarthy and Warrington 1984). If the more anterior and superior cortical terminations of the MTG pathway or the white matter of the pathway itself is damaged, it seems reasonable that the symptoms of transcortical motor aphasia would result. Although lexical-semantic content would have difficulty reaching the frontal lobe, phonologic content would not, as the speech production area itself and the phonologic pathway, both located inferior and lateral to the lesion, would be spared. Thus, the patient would have normal articulation and repetition, but impaired spontaneous speech, naming, and comprehension of material requiring significant grammatical processing. Therefore, lesions all along the MTG pathway would produce transcortical motor aphasia with relatively similar symptoms (Naeser et al. 1982; Freedman et al. 1984; McCarthy and Warrington 1984). The model of Hickok and Poeppel (2004) and Price (2000) combined with our tractography results accounts for transcortical motor aphasia, whereas the classic model does not predict an aphasia that impairs spontaneous speech while sparing repetition (transcortical motor aphasias from lesions in the supplementary motor area act via a different mechanism and would not cause some of the above language deficits; Freedman et al. 1984).

The receptive transcortical aphasia, transcortical sensory aphasia, is a perceptual language disorder of lexical-semantic comprehension. Patients with transcortical sensory aphasia are able to repeat what they hear without impairment, though they have no understanding of its meaning (Kertesz et al. 1982; Damasio and Geschwind 1984; Boatman et al. 2000). Transcortical sensory aphasia is a relatively rare condition resulting from a left temporal lobe lesion that spares classic Wernicke's area. Transcortical sensory aphasia typically is caused by a large lesion in the lexical-semantic cortex of the middle and inferior temporal lobe, sometimes extending into the angular gyrus and the occipital lobe (Kertesz et al. 1982; Damasio and Geschwind 1984; Alexander et al. 1989; Damasio 1992). Patients with transcortical sensory aphasia often have markedly reduced spontaneous speech (Damasio 1992) very much resembling semantic dementia, caused by atrophy of the left middle and inferior temporal lobe (Garrard and Hodges 2000).

Perhaps the most famous case of transcortical aphasia was presented in 1968 by Geschwind et al. as the isolation of the speech area: A 22-year-old woman was found unconscious in her kitchen suffering from carbon monoxide poisoning and remained in a coma for 17 days. When she awoke, she would sing songs and repeat whatever questions her examiners asked her, but showed a complete lack of lexical-semantic comprehension and had almost no spontaneous speech. Occasionally, she would complete conventional sayings, such as when the examiner would say "ask me no questions" she would say "tell me no lies." Her condition changed little over the last 9 years of her life, though she proved able to learn new songs that she heard on TV. When she died, the authors examined the locations of her brain damage. In the left hemisphere, she had severe lesions of BAs 21 and 37 (and also 39, 38, and 20 in the

anterior and inferior temporal cortex and the angular gyrus) but intact posterior 22, 40, and Broca's area (Fig. 4). Thus, this patient's lesions were well demarcated for pure transcortical aphasia, without a deficit in repetition, and her condition remained remarkably stable. That her condition did not improve during 9 years of treatment suggests that these temporal lobe areas in the left hemisphere are critical for lexical-semantic comprehension, and, if they are severely and completely damaged, lexical-semantic processing ability is permanently lost. Rarely does a lesion so neatly destroy the lexical-semantic comprehension area while sparing the entire phonologic circuit: Wernicke's area, Broca's area, and the supramarginal gyrus. There is, however, at least one other example of this in the literature, also caused by carbon monoxide poisoning (Heilman 2002). Transcortical sensory aphasia, and this case of pure transcortical aphasia in particular, would not be predicted by the classical model, as it does not explain how damage to areas beyond Wernicke's, Broca's and the arcuate fasciculus will cause aphasia, but these findings are accounted for by the model of Hickok and Poeppel (2004) and Price (2000) combined with our tractography results. A summary of the aphasias and their locations is shown in Figure 5 (Color: Supplementary Fig. 4).

#### *Transiently Induced Aphasias*

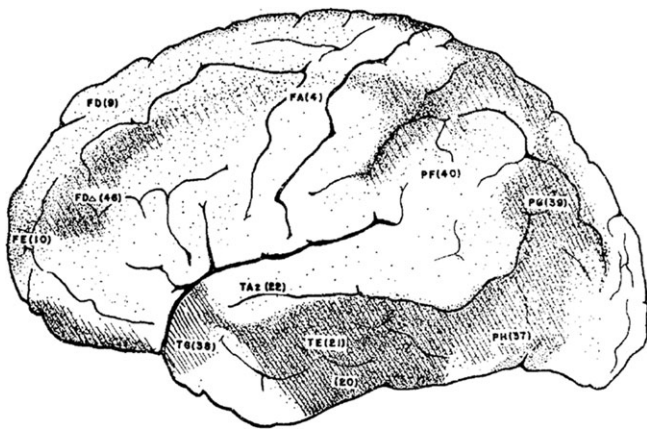
A final line of evidence that supports the model of Hickok and Poeppel (2004) and Price (2000) combined with our tractography results is aphasia induced interoperatively during functional mapping of language structures so that they may be spared during surgical resection. Electrical stimulation of the left middle and inferior temporal gyri causes transient transcortical sensory aphasia, as reported by Boatman et al. (2000), or anomia as reported by Duffau et al. (2005). Additionally, electrocortical stimulation studies have induced anomia when stimulating premotor cortex in the area of the superior part of the frontal termination of the MTG pathway (Duffau et al. 2003, 2005). Electrical stimulation of the white matter near the arcuate above the superior temporal sulcus, where the STG pathway projects laterally to the cortex, causes phonemic paraphasias, whereas stimulation below the sulcus, where the MTG pathway projects laterally to cortex, causes anomias and semantic paraphasias (Mandonnet et al. 2007). Another group finds that stimulation of the medial arcuate fasciculus leads to anomias and a reduction in spontaneous speech (Bello et al. 2007), similar to what happens in transcortical motor aphasia.

#### *Aprosodias*

The literature on aprosodias is not as clear as the literature on the aphasias. After Heilman et al. (1975) reported that patients with right temporoparietal lesions often suffered from defects in the comprehension of emotional prosody, Ross (1981) proposed that the right hemisphere contained a prosody-processing network that mirrored the left hemisphere prepositional language network. Based on case studies, he argued for the existence of a spectrum of aprosodias analogous to the aphasias, including motor, sensory, global, conduction, and transcortical sensory aprosodia (Ross 1981; Gorelick and Ross 1987). Other studies contradicted this schema, however (Cancelliere and Kertesz 1990; Bradvik et al. 1991). Although additional investigations have found that lesions to the right middle and superior temporal gyri caused difficulties



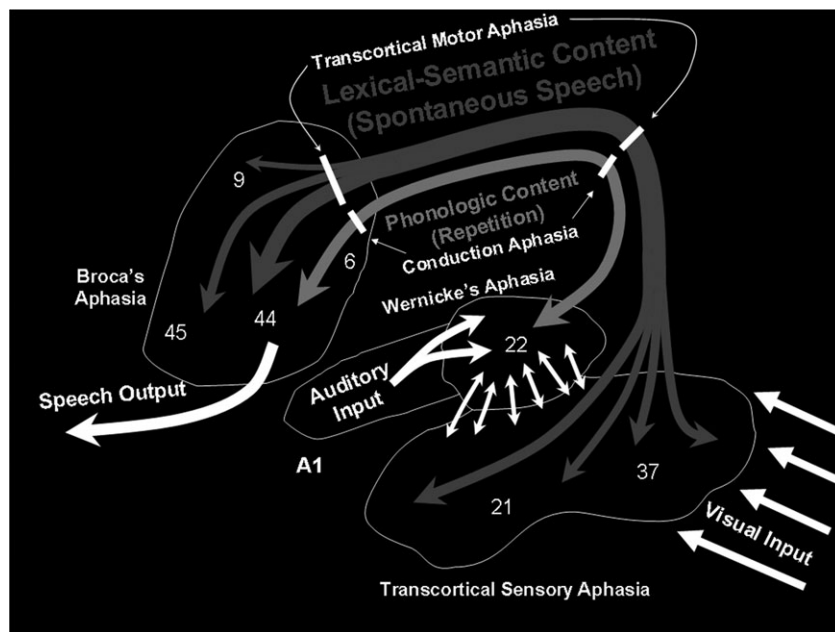
comprehending prosody (Darby 1993; Starkstein 1994; Ross 2000), purely subcortical lesions have been found to cause similar difficulties (Cancelliere and Kertesz 1990). A possible explanation for this discrepancy is that both the right posterior temporal lobe and its white matter connections to the left and right inferior frontal lobes are required for proper comprehension of prosody and that these pathways are damaged by subcortical lesions. Indeed bilateral inferior frontal activations were reported in a prosodic comprehension task (Ethofer et al. 2006), though right lateralized frontal activations are found even more commonly (Meyer et al. 2002; Riecker et al. 2002; Mitchell et al. 2003; Wildgruber et al. 2005). Thus, it would appear that either lesions that damage the right superior and middle temporal gyri or those that damage the right MTG pathway would cause difficulties with prosodic processing.



**Figure 4.** A case of pure transcortical aphasia. Lesioned areas are shaded. Reproduced from Geschwind et al. (1968) with permission.

**Comparison of the Model Presented Here to the Model of Catani et al.**

Catani et al. (2005) proposed a model of the language network based on DTI tractography results that included a direct phonetic pathway (via the arcuate) and an indirect semantic pathway (via 2 segments that connected the inferior parietal lobe to both the temporal and frontal lobes). Thus the main differences between their model and our model are that their model involves a “Geschwind’s” territory for semantic processing, encompassing much of the inferior parietal lobe, and that they combine the STG and MTG pathways of the arcuate into a single segment, arguing that the entire pathway conveys phonetic information directly to the frontal lobe. We favor our model for the following reasons: 1) Although Catani et al assert that the entire inferior parietal lobe is involved in semantic processing, Price (2000), indicates that this is only true of the posterior inferior parietal lobe, i.e. the angular gyrus (BA 39; which can be appreciated from our Fig. 4). In contrast, it is apparent from Catani et al.’s figures (e.g., Figure 2 in Catani et al. [2005] or Figure 7 in Catani and Ffytche [2005]) that the focus of their parietal projection is in anterior inferior parietal cortex, i.e. the supramarginal gyrus (BA 40). BA 40 is more likely to be involved in phonetic working memory than semantic processing (Binder et al. 1997, 2000; Canestra et al. 2000; Baddeley 2003; McDermott et al. 2003; Martin 2005; Woodward et al. 2006), and semantic processing is found far more often in the temporal lobe (Vandenberghe et al. 1996; Binder et al. 1997, 2000; Canestra et al. 2000; Price 2000; Castillo et al. 2001; Hickok and Poeppel 2004; Poeppel et al. 2004). 2) As we show in Figure 4, the STG and MTG terminations of the arcuate connect cortices of different function, and therefore we feel it is more appropriate to treat them as 2 separate pathways. 3) We also interpret the McCarthy and Warrington (1984) study of 2 patients with conduction aphasia and 1 with transcortical motor aphasia differently than Catani et al. They interpret the differential



**Figure 5.** Common locations of the aphasias. Color figure: Supplementary Figure 4.

symptoms from lesions that affected the white matter beneath the inferior parietal cortex as resulting from differential destruction of direct and indirect pathways; however, much like the case presented in Selnes et al. (2002), a lesion to the MTG pathway could explain the transcortical motor aphasia of the patient in McCarthy and Warrington, whereas lesions to the STG pathway could explain the conduction aphasias of the other 2 patients. 4) The left inferior parietal lobe has recently been implicated in the planning of tool use gestures with functional neuroimaging (Johnson-Frey et al. 2005), and is a common site for lesions causing representational ideomotor apraxia (Buxbaum 2001), a disorder of the production and recognition of tool use gestures. Conceptual or ideational apraxia, a deficit of the semantic knowledge of tools, is caused by lesions of the temporal lobe (Buxbaum 2001). Thus, we believe that the Geschwind's Territory and the indirect pathway are not primarily involved in semantic language processing, but rather in another major human specific cognitive specialization, complex tool use.

#### **Note on Limitations of the Method Used Here**

Although DTI tractography is a potentially very informative technique, it has several limitations that must be kept in mind. Although we were unable to identify the MTG pathways in the right hemispheres of 9 of the subjects, and the left hemisphere STG pathway in 3 of the subjects, it is likely that these pathways are actually present. In a separate study (Rilling et al., submitted for publication) that used a more sensitive probabilistic crossing fiber algorithm (Behrens et al. 2007) to detect all of the temporoparietal pathways to the frontal cortex anterior to the precentral sulcus, the MTG pathway was identified in the right hemisphere of all subjects and the STG pathway was identified in the left hemisphere of all of subjects. In Supplementary Figure 5, we show the average deterministic results from this study in standard space, along with the average probabilistic results (Supplementary Fig. 5). The average probabilistic results show a similar pattern of asymmetry to the deterministic results and in posterior temporal cortex, the locations of terminations are also similar. The MTG pathway is larger on the left than on the right, and the left hemisphere pathway extends more anteriorly into BA 21 than it does in the right. The STG pathway is highly leftwardly asymmetric in both studies, and, when present in the right, it is posterior to the phonetic activations in both studies. The deterministic tractography algorithm used here is unable to track through areas of crossing fibers when a competing pathway is significantly stronger, or when subject motion reduces the quality of the dataset, which may explain the lack of a right hemisphere MTG pathway or a left hemisphere STG pathway in some subjects presented here. Weak pathways are more reliably found with the crossing fiber, or 2 direction, probabilistic algorithm (Behrens et al. 2007), which calculates a secondary fiber direction, in addition to the primary one, and can use this fiber direction to continue tracking when the principle diffusion angle changes abruptly.

Our study generated 2 unexpected findings. First, projections of both the lexical-semantic and the STG pathways were found to BA 6; however, one would not necessarily expect language areas to project directly to premotor cortex. Nevertheless, when the more dorsal premotor cortex of the superior terminations of the MTG pathway are stimulated, anomias result (Duffau et al. 2003, 2005), suggesting that the

MTG pathway may in fact project to this location. A second unexpected finding is fewer projections to BAs 45 and 47 than we found in the probabilistic study (Rilling et al., submitted for publication). Although the location of the posterior terminations of the pathways and the magnitude of the asymmetries are very similar, the results differ in that the focus of the frontal terminations is more anterior in the probabilistic, crossing fiber results. A plausible explanation for these unexpected findings is that when the arcuate joins with pathways that connect parietal areas to premotor cortex that run parallel to it such as the SLF (Petrides and Pandya 2002; Makris et al. 2005), the tractography algorithm has difficulty keeping the arcuate separate from these other pathways. Thus, more terminations are found posteriorly in premotor cortex, the putative target of SLF III (Makris et al. 2005), whereas fewer are found in anterior inferior prefrontal cortex (Rilling et al. submitted for publication).

#### **Conclusion**

We have demonstrated a leftward asymmetry of the arcuate fasciculus connections linking both STG and MTG with the inferior frontal lobe. Comparison with activations from functional neuroimaging experiments suggests that the left STG and MTG pathways are involved in phonologic and lexical-semantic processing, respectively, whereas the right MTG pathway is involved in prosodic processing. We integrate our tractography findings into the language model of Hickok and Poeppel (2004) and Price (2000) and then test this model, post hoc, against various aphasia syndromes and the lesions that cause them. This model shows greater explanatory power, when combined with our tractography results, than either the classic model or other recently proposed revised models based on DTI tractography. However, as is true of all models, we realize that ours is a simplification of reality. Although we describe a single lexical-semantic area along the length of the MTG, the cortex is likely to be heterogeneous in function. In addition, we neglect other components of language, for example syntax, morphology, combinatorial semantics, and pragmatics that are beyond the scope of this paper. One topic for future study would be to look in more detail at the connectivity of the MTG segment with the frontal lobe. For example, are there differences in the connectivity of BAs 21 and 37 with the frontal lobe? We found that in the left hemisphere, the MTG pathway extended much more anteriorly into BA 21 than it did in the right hemisphere, but to which frontal lobe areas specifically does each of these temporal areas connect? Also, does this work help explain other clinical cases when evaluated using DTI, such as the one presented by Selnes et al. (2002). Our hope is that the work presented here will help in understanding language processing in both normal and abnormal subjects.

#### **Supplementary Material**

Supplementary material can be found at: <http://www.cercor.oxfordjournals.org/>

#### **Funding**

Scholarly Inquiry and Research at Emory; The Center for Behavioral Neuroscience under the STC Program of the National Science Foundation under Agreement No. IBN-9876754; and the Emory University Research Committee.

## Notes

We would like to thank Dr Todd Preuss and Dr Argye Hillis for their helpful comments on the manuscript and model, respectively, and Dr David Friedes for his thoughts and inspiration. *Conflict of Interest:* None declared.

Address correspondence to James K. Rilling, PhD, Department of Anthropology, Department of Psychiatry and Behavioral Sciences, Emory University, 1557 Dickey Drive, Atlanta, GA 30322, USA. Email: jrilling@emory.edu.

## References

- Ahmad Z, Balsamo LM, Sachs BC, Xu B, Gaillard WD. 2003. Auditory comprehension of language in young children: neural networks identified with fMRI. *Neurology*. 60:1598-1605.
- Alexander MP, Hiltbrunner B, Fischer RS. 1989. Distributed anatomy of transcortical sensory aphasia. *Arch Neurol*. 46:885-892.
- Anderson JM, Gilmore R, Roper S, Crosson B, Bauer RM, Nadeau S, Beversdorf DQ, Cibula J, Rogish M, Kortencamp S. 1999. Conduction aphasia and the arcuate fasciculus: a reexamination of the Wernicke-Geschwind model. *Brain Lang*. 70:1-12.
- Anwander A, Tittgemeyer M, von Cramon DY, Friederici AD, Knosche TR. 2007. Connectivity-based parcellation of Broca's area. *Cereb Cortex*. 17:816.
- Baddeley A. 2003. Working memory: looking back and looking forward. *Nat Rev Neurosci*. 4:829-839.
- Barrick TR, Lawes IN, Mackay CE, Clark CA. 2007. White matter pathway asymmetry underlies functional lateralization. *Cereb Cortex*. 17:591.
- Barsalou LW, Simmons WK, Barbey AK, Wilson CD. 2003. Grounding conceptual knowledge in modality-specific systems. *Trends Cogn Sci*. 7:84-91.
- Behrens TE, Berg HJ, Jbabdi S, Rushworth MF, Woolrich MW. 2007. Probabilistic diffusion tractography with multiple fibre orientations: what can we gain. *Neuroimage*. 34:144-155.
- Belin P, Zatorre RJ, Ahad P. 2002. Human temporal-lobe response to vocal sounds. *Cogn Brain Res*. 13:17-26.
- Bello L, Gallucci M, Fava M, Carrabba G, Giussani C, Acerbi F, Baratta P, Songa V, Conte V, Branca V. 2007. Intraoperative subcortical language tract mapping guides surgical removal of gliomas involving speech areas. *Neurosurgery*. 60:67-80.
- Binder JR, Frost JA, Hammeke TA, Bellgowan PS, Springer JA, Kaufman JN, Possing ET. 2000. Human temporal lobe activation by speech and nonspeech sounds. *Cereb Cortex*. 10:512-528.
- Binder JR, Frost JA, Hammeke TA, Cox RW, Rao SM, Prieto T. 1997. Human brain language areas identified by functional magnetic resonance imaging. *J Neurosci*. 17:353-362.
- Boatman D, Gordon B, Hart J, Selnes O, Miglioretti D, Lenz F. 2000. Transcortical sensory aphasia: revisited and revised. *Brain*. 123(Pt 8):1634-1642.
- Bookheimer S. 2002. Functional MRI of language: new approaches to understanding the cortical organization of semantic processing. *Annu Rev Neurosci*. 25:151-188.
- Bradvik B, Dravins C, Holtas S, Rosen I, Ryding E, Ingvar DH. 1991. Disturbances of speech prosody following right hemisphere infarcts. *Acta Neurol Scand*. 84:114-126.
- Broca P. 1861. Remarks on the seat of the faculty of articulated language, following an observation of aphemia (loss of speech). *Bull Soc Anat*. 6:330-357.
- Bryden MP. 1977. Measuring handedness with questionnaires. *Neuropsychologia*. 15:617-624.
- Buxbaum LJ. 2001. Ideomotor apraxia: a call to action. *Neurocase*. 7:445-458.
- Cancelliere AE, Kertesz A. 1990. Lesion localization in acquired deficits of emotional expression and comprehension. *Brain Cogn*. 13: 133-147.
- Cannestra AF, Bookheimer SY, Pouratian N, O'Farrell A, Sicotte N, Martin NA, Becker D, Rubino G, Toga AW. 2000. Temporal and topographical characterization of language cortices using intraoperative optical intrinsic signals. *Neuroimage*. 12:41-54.
- Castillo EM, Simos PG, Davis RN, Breier J, Fitzgerald ME, Papanicolaou AC. 2001. Levels of word processing and incidental memory: dissociable mechanisms in the temporal lobe. *Neuroreport*. 12:3561-3566.
- Catani M, Ffytche DH. 2005. The rises and falls of disconnection syndromes. *Brain*. 128:2224-2239.
- Catani M, Jones DK, Ffytche DH. 2005. Perisylvian language networks of the human brain. *Ann Neurol*. 57:8-16.
- Damasio AR. 1992. Aphasia. *N Engl J Med*. 326:531-539.
- Damasio AR, Geschwind N. 1984. The neural basis of language. *Annu Rev Neurosci*. 7:127-147.
- Damasio H, Damasio AR. 1980. The anatomical basis of conduction aphasia. *Brain*. 103:337-350.
- Darby DG. 1993. Sensory aprosodia: a clinical clue to lesions of the inferior division of the right middle cerebral artery? *Neurology*. 43:567-572.
- Dejerine J. 1895. Anatomy of central nervous system. Paris: Masson.
- Dronkers NF, Plaisant O, Iba-Zizen MT, Cabanis EA. 2007. Paul Broca's historic cases: high resolution MR imaging of the brains of Leborgne and Lelong. *Brain*. 130:1432-1441.
- Duffau H, Capelle L, Denvil D, Gatignol P, Sichez N, Lopes M, Sichez JP, Van Effenterre R. 2003. The role of dominant premotor cortex in language: a study using intraoperative functional mapping in awake patients. *Neuroimage*. 20:1903-1914.
- Duffau H, Gatignol P, Mandonnet E, Peruzzi P, Tzourio-Mazoyer N, Capelle L. 2005. New insights into the anatomo-functional connectivity of the semantic system: a study using cortico-subcortical electrostimulations. *Brain*. 128:797.
- Ethofer T, Anders S, Erb M, Herbert C, Wiethoff S, Kissler J, Grodd W, Wildgruber D. 2006. Cerebral pathways in processing of affective prosody: a dynamic causal modeling study. *Neuroimage*. 30:580-587.
- Ferguson CA, Farwell CB. 1975. Words and sounds in early language acquisition. *Language*. 51:419-439.
- Freedman M, Alexander MP, Naeser MA. 1984. Anatomic basis of transcortical motor aphasia. *Neurology*. 34:409-417.
- Friederici AD, Bahlmann J, Heim S, Schubotz RI, Anwander A. 2006. The brain differentiates human and non-human grammars: functional localization and structural connectivity. *Proc Natl Acad Sci USA*. 103:2458-2463.
- Garrard P, Hodges JR. 2000. Semantic dementia: clinical, radiological and pathological perspectives. *J Neurol*. 247:409-422.
- Geschwind N. 1965. Disconnexion syndromes in animals and man. I&II. *Brain*. 88:237-294/585-643.
- Geschwind N, Quadfasel FA, Segarra JM. 1968. Isolation of the speech area. *Neuropsychologia*. 6:327-340.
- Gorelick PB, Ross ED. 1987. The aprosodias: further functional-anatomical evidence for the organisation of affective language in the right hemisphere. *J Neurol Neurosurg Psychiatry*. 50: 553-560.
- Hagmann P, Cammoun L, Martuzzi R, Maeder P, Clarke S, Thiran JP, Meuli R. 2006. Hand preference and sex shape the architecture of language networks. *Hum Brain Mapp*. 27:828-835.
- Heilman KM. 2002. Matter of mind: a neurologist's view of brain-behavior relationships. New York: Oxford University Press.
- Heilman KM, Scholes R, Watson RT. 1975. Auditory affective agnosia. Disturbed comprehension of affective speech. *Bri Med J*. 38:69.
- Hickok G, Poeppel D. 2004. Dorsal and ventral streams: a framework for understanding aspects of the functional anatomy of language. *Cognition*. 92:67-99.
- Jancke L, Wustenberg T, Scheich H, Heinze HJ. 2002. Phonetic perception and the temporal cortex. *Neuroimage*. 15:733-746.
- Jenkinson M, Bannister P, Brady M, Smith S. 2002. Improved optimization for the robust and accurate linear registration and motion correction of brain images. *Neuroimage*. 17:825-841.
- Joanisse MF, Gati JS. 2003. Overlapping neural regions for processing rapid temporal cues in speech and nonspeech signals. *Neuroimage*. 19:64-79.
- Johnson-Frey SH, Newman-Norlund R, Grafton ST. 2005. A distributed left hemisphere network active during planning of everyday tool use skills. *Cereb Cortex*. 15:681-695.

- Kempler D, Metter EJ, Jackson CA, Hanson WR, Riege WH, Mazziotta JC, Phelps ME. 1988. Disconnection and cerebral metabolism. The case of conduction aphasia. *Arch Neurol.* 45:275-279.
- Kertesz A, Harlock W, Coates R. 1979. Computer tomographic localization, lesion size, and prognosis in aphasia and nonverbal impairment. *Brain Lang.* 8:34-50.
- Kertesz A, Sheppard A, MacKenzie R. 1982. Localization in transcortical sensory aphasia. *Arch Neurol.* 39:475-478.
- Kreisler A, Godefroy O, Delmaire C, Debachy B, Leclercq M, Pruvo JP, Leys D. 2000. The anatomy of aphasia revisited. *Neurology.* 54:1117-1123.
- Lichtheim L. 1885. On aphasia. *Brain.* 7:433-484.
- Lieberman P. 2002. On the nature and evolution of the neural bases of human language. *Am J Phys Anthropol. Suppl.* 35:36-62.
- Makris N, Kennedy DN, McInerney S, Sorensen AG, Wang R, Caviness VS, Jr, Pandya DN. 2005. Segmentation of Subcomponents within the Superior Longitudinal Fascicle in humans: a quantitative, in vivo, DT-MRI study. *Cereb Cortex.* 15:854-869.
- Mandonnet E, Nouet A, Gatignol P, Capelle L, Duffau H. 2007. Does the left inferior longitudinal fasciculus play a role in language? A brain stimulation study. *Brain.* 130:623.
- Martin RC. 2005. Components of short-term memory and their relation to language processing. *Curr Dir Psychol Sci.* 14:204.
- Matsumoto R, Nair DR, LaPresto E, Najm I, Bingaman W, Shibasaki H, Lüders HO. 2004. Functional connectivity in the human language system: a cortico-cortical evoked potential study. *Brain.* 127:2316-2330.
- McCarthy R, Warrington EK. 1984. A two-route model of speech production. Evidence from aphasia. *Brain.* 107(Pt 2):463-485.
- McDermott KB, Petersen SE, Watson JM, Ojemann JG. 2003. A procedure for identifying regions preferentially activated by attention to semantic and phonological relations using functional magnetic resonance imaging. *Neuropsychologia.* 41:293-303.
- Meyer M, Alter K, Friederici AD, Lohmann G, von Cramon DY. 2002. fMRI reveals brain regions mediating slow prosodic modulations in spoken sentences. *Hum Brain Mapp.* 17:73-88.
- Mitchell RL, Elliott R, Barry M, Cruttenden A, Woodruff PW. 2003. The neural response to emotional prosody, as revealed by functional magnetic resonance imaging. *Neuropsychologia.* 41:1410-1421.
- Mori S, van Zijl PCM. 2002. Fiber tracking: principles and strategies—a technical review. *NMR Biomed.* 15:468-480.
- Naeser MA. 1978. Lesion localization in aphasia with cranial computed tomography and the Boston Diagnostic Aphasia Exam. *Neurology.* 28:545-551.
- Naeser MA, Alexander MP, Helm-Estabrooks N, Levine HL, Laughlin SA, Geschwind N. 1982. Aphasia with predominantly subcortical lesion sites: description of three capsular/putaminal aphasia syndromes. *Arch Neurol.* 39:2-14.
- Naeser MA, Helm-Estabrooks N, Haas G, Auerbach S, Srinivasan M. 1987. Relationship between lesion extent in 'Wernicke's area' on computed tomographic scan and predicting recovery of comprehension in Wernicke's aphasia. *Arch Neurol.* 44:73-82.
- Nucifora PG, Verma R, Melhem ER, Gur RE, Gur RC. 2005. Leftward asymmetry in relative fiber density of the arcuate fasciculus. *Neuroreport.* 16:791-794.
- Parker GJ, Luzzi S, Alexander DC, Wheeler-Kingshott CA, Ciccarelli O, Lambon Ralph MA. 2005. Lateralization of ventral and dorsal auditory-language pathways in the human brain. *Neuroimage.* 24:656-666.
- Paulesu E, Frith CD, Frackowiak RSJ. 1993. The neural correlates of the verbal component of working memory. *Nature.* 362:342-345.
- Paulesu E, Goldacre B, Scifo P, Cappa SF, Gilardi MC, Castiglioni I, Perani D, Fazio F. 1997. Functional heterogeneity of left inferior frontal cortex as revealed by fMRI. *Neuroreport.* 8:2011-2017.
- Petrides M, Pandya DN. 2002. Association pathways of the prefrontal cortex and functional observations. In: Stuss DT, Knight RT, editors. *Principles of frontal lobe function.* New York: Oxford University Press. p. 31-50.
- Poeppel D, Guillemin A, Thompson J, Fritz J, Bavelier D, Braun AR. 2004. Auditory lexical decision, categorical perception, and FM direction discrimination differentially engage left and right auditory cortex. *Neuropsychologia.* 42:183-200.
- Powell HW, Parker GJ, Alexander DC, Symms MR, Boulby PA, Wheeler-Kingshott CA, Barker GJ, Noppeny U, Koepp MJ, Duncan JS. 2006. Hemispheric asymmetries in language-related pathways: a combined functional MRI and tractography study. *Neuroimage.* 32:388-399.
- Price CJ. 2000. The anatomy of language: contributions from functional neuroimaging. *J Anat.* 197(Pt 3):335-359.
- Price CJ, Mummery CJ, Moore CJ, Frackowiak RSJ, Friston KJ. 1999. Delineating necessary and sufficient neural systems with functional imaging studies of neuropsychological patients. *J Cogn Neurosci.* 11:371-382.
- Riecker A, Wildgruber D, Dogil G, Grodd W, Ackermann H. 2002. Hemispheric lateralization effects of rhythm implementation during syllable repetitions: an fMRI study. *Neuroimage.* 16:169-176.
- Ross ED. 1981. The aprosodias. Functional-anatomic organization of the affective components of language in the right hemisphere. *Arch Neurol.* 38:561-569.
- Ross ED. 2000. Affective prosody and the aprosodias. In: Mesulam M, editor. *Principles of behavioral and cognitive neurology.* New York: Oxford University Press. p. 316-331.
- Ross ED, Thompson RD, Yenkosky J. 1997. Lateralization of affective prosody in brain and the callosal integration of hemispheric language functions. *Brain Lang.* 56:27-54.
- Sakai KL. 2005. Language acquisition and brain development. *Science.* 310:815-819.
- Selnes OA, van Zijl PCM, Barker PB, Hillis AE, Mori S. 2002. MR diffusion tensor imaging documented arcuate fasciculus lesion in a patient with normal repetition performance. *Aphasiology.* 16:897-902.
- Smith SM, Jenkinson M, Johansen-Berg H, Rueckert D, Nichols TE, Mackay CE, Watkins KE, Ciccarelli O, Cader MZ, Matthews PM. 2006. Tract-based spatial statistics: voxelwise analysis of multi-subject diffusion data. *Neuroimage.* 31:1487-1505.
- Specht K, Holtel C, Zahn R, Herzog H, Krause BJ, Mottaghy FM, Radermacher I, Schmidt D, Tellmann L, Weis S. 2003. Lexical decision of nonwords and pseudowords in humans: a positron emission tomography study. *Neurosci Lett.* 345:177-181.
- Starkstein SE. 1994. Neuropsychological and neuroradiologic correlates of emotional prosody comprehension. *Neurology.* 44:515-522.
- Thompson-Schill SL, D'Esposito M, Aguirre GK, Farah MJ. 1997. Role of left inferior prefrontal cortex in retrieval of semantic knowledge: a reevaluation. *Proc Natl Acad Sci USA.* 94:14792-14797.
- Vandenberghe R, Price C, Wise R, Josephs O, Frackowiak RS. 1996. Functional anatomy of a common semantic system for words and pictures. *Nature.* 383:254-256.
- Vernooij MW, Smits M, Wielopolski PA, Houston GC, Krestin GP, van der Lugt A. 2007. Fiber density asymmetry of the arcuate fasciculus in relation to functional hemispheric language lateralization in both right- and left-handed healthy subjects: a combined fMRI and DTI study. *Neuroimage.* 35:1064-1076.
- Vigneau M, Beaucousin V, Hervé PY, Duffau H, Crivello F, Houdé O, Mazoyer B, Tzourio-Mazoyer N. 2006. Meta-analyzing left hemisphere language areas: phonology, semantics, and sentence processing. *Neuroimage.* 30:1414-1432.
- Wang R. 2006. DTI Task Card. 1.70 ed. Charlestown (MA): Siemens. Martinos Center for Biomedical Imaging, MGH.
- Warrington EK, Logue V, Pratt RT. 1971. The anatomical localisation of selective impairment of auditory verbal short-term memory. *Neuropsychologia.* 9:377-387.
- Wernicke C. 1874. The aphasic symptom complex: a psychological study on a neurological basis. *Boston Stud Philos Sci.* 4.
- Wildgruber D, Ackermann H, Kreifelts B, Ethofer T. 2006. Chapter 13 Cerebral processing of linguistic and emotional prosody: fMRI studies. *Prog Brain Res.* 156:249-268.
- Wildgruber D, Riecker A, Hertrich I, Erb M, Grodd W, Ethofer T, Ackermann H. 2005. Identification of emotional intonation evaluated by fMRI. *Neuroimage.* 24:123.
- Woodward TS, Cairo TA, Ruff CC, Takane Y, Hunter MA, Ngan ET. 2006. Functional connectivity reveals load dependent neural systems underlying encoding and maintenance in verbal working memory. *Neuroscience.* 139:317-325.