

Ventral occipital lesions impair object recognition but not object-directed grasping: an fMRI study

Thomas W. James,¹ Jody Culham,² G. Keith Humphrey,² A. David Milner³ and Melvyn A. Goodale²

¹Vanderbilt Vision Research Center, Vanderbilt University, Nashville, USA, ²CIHR Group on Action and Perception, University of Western Ontario, London, Canada and ³Wolfson Research Institute, University of Durham, Durham, UK

Correspondence to: Thomas W. James, Psychology Department, 111 21st Street S., Nashville, TN 37203, USA
Email: tom.james@vanderbilt.edu

Summary

D.F., a patient with severe visual form agnosia, has been the subject of extensive research during the past decade. The fact that she could process visual input accurately for the purposes of guiding action despite being unable to perform visual discriminations on the same visual input inspired a novel interpretation of the functions of the two main cortical visual pathways or ‘streams’. Within this theoretical context, the authors proposed that D.F. had suffered severe bilateral damage to her occipitotemporal visual system (the ‘ventral stream’), while retaining the use of her occipitoparietal visual system (the ‘dorsal stream’). The present paper reports a direct test of this idea, which was initially derived from purely behavioural data, before the advent of modern functional neuroimaging. We used functional MRI to examine activation in her ventral and dorsal streams during object recognition and object-directed grasping tasks. We found that D.F. showed no difference in activation when presented with line drawings of common objects compared with scrambled line drawings in the lateral occipital cortex (LO) of the ventral stream, an area that responded differentially to these stimuli in healthy individuals. Moreover, high-

resolution anatomical MRI showed that her lesion corresponded bilaterally with the location of LO in healthy participants. The lack of activation with line drawings in D.F. mirrors her poor performance in identifying the objects depicted in the drawings. With coloured and greyscale pictures, stimuli that she can identify more often, D.F. did show some ventral-stream activation. These activations were, however, more widely distributed than those seen in control participants and did not include LO. In contrast to the absent or abnormal activation observed during these perceptual tasks, D.F. showed robust activation in the expected dorsal stream regions during object grasping, despite considerable atrophy in some regions of the parietal lobes. In particular, an area in the anterior intraparietal sulcus was activated more for grasping an object than for just reaching to that object, for both D.F. and controls. In conclusion, we have been able to confirm directly that D.F.’s visual form agnosia is associated with extensive damage to the ventral stream, and that her spared visuomotor skills are associated with visual processing in the dorsal stream.

Keywords: visual form agnosia; visual streams; fMRI; object recognition; visuomotor control

Abbreviations: BA = Brodmann area; fMRI = functional MRI; AIP = anterior intraparietal sulcus; LOC = lateral occipital complex; LO = lateral occipital area; IT = monkey inferotemporal cortex; ITI = intertrial interval

Introduction

In the primate cerebral cortex, there are two prominent sets of visual projections: the ventral stream, which arises in area V1 and projects to the inferotemporal cortex, and the dorsal stream, which also arises in area V1 but projects instead to the posterior parietal cortex (Ungerleider and Mishkin, 1982; Morel and Bullier, 1990; Baizer *et al.*, 1991; Young, 1992). Subsequent to Ungerleider and Mishkin’s discovery of two cortical visual processing streams, Goodale and Milner

(Goodale and Milner, 1992; Milner and Goodale, 1995), on the basis of a broad range of evidence, including neurophysiological and anatomical studies in the monkey and neuropsychological and neuroimaging studies in humans, argued that the ventral stream plays the major role in constructing our perceptual representation of the visual world and the objects within it, while the dorsal stream mediates the visual control of actions that we direct at those objects.

Processing within the ventral stream allows us to recognize an object, such as a banana in a bowl of fruit, for example, while processing within the dorsal stream provides critical information about the location, orientation, size and shape of that banana so that we can reach out and pick it up. Note that this proposal is a departure from the earlier distinction between 'what' and 'where' (object vision and spatial vision) that was put forward in 1982 by Ungerleider and Mishkin. In the Goodale and Milner model, the structural and spatial attributes of the goal object are being processed by both streams, but for different purposes. In the case of the ventral stream, information about a broad range of object parameters is being transformed for perceptual purposes; in the case of the dorsal stream, some of these same object parameters are being transformed for the control of actions. This is not to say that the distribution of subcortical visual inputs does not differ between the two streams, but rather that the main difference lies in the nature of the transformations that each stream performs on those two sets of inputs.

Some of the most compelling evidence for the perception-action hypothesis has come from studies of patient D.F., a young woman who suffered irreversible brain damage in 1988 as a result of hypoxia from carbon monoxide poisoning (Milner *et al.*, 1991). D.F. is rare among the small group of patients afflicted with 'visual form agnosia', a profound loss of visual form perception (Heider, 2000), in that her well-preserved motor system has allowed very extensive research to be done on her capacity for visuomotor control (Milner and Goodale, 1995). These studies have shown that though D.F. is unable to indicate the size, shape and orientation of an object, either verbally or manually, she shows normal preshaping and rotation of her hand when reaching out to grasp that object. In other words, D.F. is able to use visual information about the location, size, shape and orientation of objects to control her grasping movements (and other visually guided movements) despite the fact that she is unable to perceive those same object features.

Goodale and Milner suggested that the brain damage suffered by D.F. as a consequence of her hypoxia interrupted the normal flow of shape and contour information into her perceptual system without affecting the processing of shape and contour information by her visuomotor control systems. In fact, structural MRI of D.F.'s brain carried out just over a year after her accident revealed damage in the ventrolateral regions of the occipital cortex, a region containing visual areas that constitute what is considered the human homologue of the ventral stream of processing. At the same time, her primary visual cortex, which provides input for both the dorsal and ventral streams, appeared to be largely intact. Goodale and Milner inferred that while input from primary visual cortex to the ventral stream had been compromised in D.F., input from this structure to the dorsal stream remained essentially intact. Because the dorsal stream also receives input from the superior colliculus via the pulvinar, both of the major visual input pathways could thus continue to the mediation of D.F.'s well-formed visuomotor responses.

But all of this was essentially conjecture. Here we present evidence from high-resolution structural MRI that the lateral occipital complex (LOC), a structure in the ventral stream that has been implicated in object recognition (Malach *et al.*, 1995; Kanwisher *et al.*, 1996; James *et al.*, 2000, 2002; Kourtzi and Kanwisher, 2000; Grill-Spector *et al.*, 2001), is indeed severely damaged in D.F. The damage is largely localized bilaterally to the lateral occipital (LO) aspect of the LOC (Malach *et al.*, 1995). In addition, with the use of functional MRI (fMRI), we show that none of the LOC, even the portion outside the lesion in area LO, is activated when D.F. is presented with line drawings of common objects, even though healthy participants show robust activation in the same area. The structural MRI also revealed shrinkage of cortical tissue within the intraparietal sulcus, a dorsal-stream region that has been implicated in visuomotor control (Goodale and Humphrey, 1998; Culham and Kanwisher, 2001; Andersen and Buneo, 2002; James *et al.*, 2002). Nevertheless, fMRI showed that when D.F. grasped objects that varied in size and orientation, she displayed relatively normal activation in the anterior intraparietal sulcus (AIP), an area that has been shown to play a critical role in the visual control of grasping (Binkofski *et al.*, 1988; Culham and Kanwisher, 2001; Culham, 2003). This result underscores the important role that fMRI can play in revealing intact function (or not) in brain regions that appear damaged in conventional structural MRI. Finally, the findings provide additional support for the idea that visual perception and the visual control of action depend on separate visual pathways in the cerebral cortex, and confirm the respective roles of the ventral and dorsal visual streams in these functions.

Material and methods

Participants

D.F. has a profound visual form agnosia and is incapable of discriminating even the simplest geometric forms (Milner *et al.*, 1991). As is typical in apperceptive visual agnosia, she is not able to copy objects, but is able to draw them from memory. Her deficit appears to be largely with the processing of shape information as opposed to surface information (e.g. colour, shading), for she is able to recognize coloured and greyscale pictures of objects with much greater accuracy (>65%) than line drawings of objects (<12%) (Humphrey *et al.*, 1994, 1996). D.F. was 47 years old at the time of the present testing. D.F. has no metal implants, an important consideration when conducting MRI research.

D.F. participated voluntarily in a high-resolution anatomical MRI scan and two functional MRI experiments. Several healthy control participants voluntarily participated in Experiment 1 and/or Experiment 2. All participants were right-handed and reported normal or corrected-to-normal visual acuity. The healthy participants had no known neurological or visual disorders. The healthy participants were graduate students, research assistants or postdoctoral




Fig. 1 Examples of intact and scrambled images of common objects in colour, greyscale and line drawing formats.

fellows studying visual neuroscience at the University of Western Ontario. The age of the healthy participants ranged between 25 and 32 years. The ethical review boards of both the University of Western Ontario and the Robarts Research Institute approved protocols for the procedures, and the participants' consent was obtained according to the Declaration of Helsinki.

Procedures

The study was divided into two experiments; Experiment 1 investigated D.F.'s ventral stream function, while Experiment 2 investigated D.F.'s dorsal stream function. The procedures for these two experiments were optimized for measuring either dorsal or ventral stream function in healthy controls and therefore used quite different stimulus presentation techniques. For instance, in Experiment 1 two-dimensional images of objects from a large assortment of categories in colour, greyscale and line drawing formats were used, whereas in Experiment 2 a set of simple three-dimensional geometric forms that could be grasped were the objects. Although the two experiments were quite different in design and used quite different stimuli, they allowed us to compare D.F.'s pattern of dorsal- and ventral-stream activation with that of healthy controls using well-established protocols.

Experiment 1

In an event-related design, participants were presented with one image at a time for 4 s with a 12-s interstimulus interval. Images were colour, greyscale and line drawing versions of the same 30 pictures of living and non-living objects (for




Fig. 2 Experimental setup for reaching and grasping experiment. (A) The participant lay supine in the magnet with the torso and head tilted to view illuminated shapes directly on an adjustable rotating drum, the 'grasparatus'. The participant's right arm was restrained to allow movement of the wrist and limited movement of the elbow, but no movement at the shoulder, which could be translated into head motion. (B) During reaching trials, participants extended their arm to touch the target object, an elongated translucent rectangle, with the knuckles. (C) During grasping trials, the participant used a precision grip with the index finger and thumb positioned along the long axis of the object.

examples, see Fig. 1). There were also 15 scrambled versions of each colour, greyscale and line drawing. The 135 total stimuli were presented in nine runs of 15 pictures each. Participants were asked to press a button if they were able to silently name the picture and to make no response if they did not recognize the picture, or if the picture was scrambled. All participants, including D.F., were able to distinguish the intact from the scrambled pictures. Pictures were projected onto a rear-projection screen that straddled the participant's waist. Participants viewed the screen through a mirror that was fixed within the head coil above their eyes. Total distance from the screen to the participant's eye was ~60 cm.

Experiment 2

Participants performed reaching and grasping movements within the MRI scanner in a paradigm designed to allow them to see the stimuli directly (without mirrors) and perform simple hand actions that would not be translated to head motion (for full details see Culham *et al.*, 2003). Objects were presented by means of a pneumatic drum, the 'grasparatus', that rotated between trials, allowing three-dimensional rectangular objects of varied length and orientation to be presented in each trial (Fig. 2A). The experiment was completed in the dark, and objects were briefly illuminated from within using light-emitting diodes. During reaching

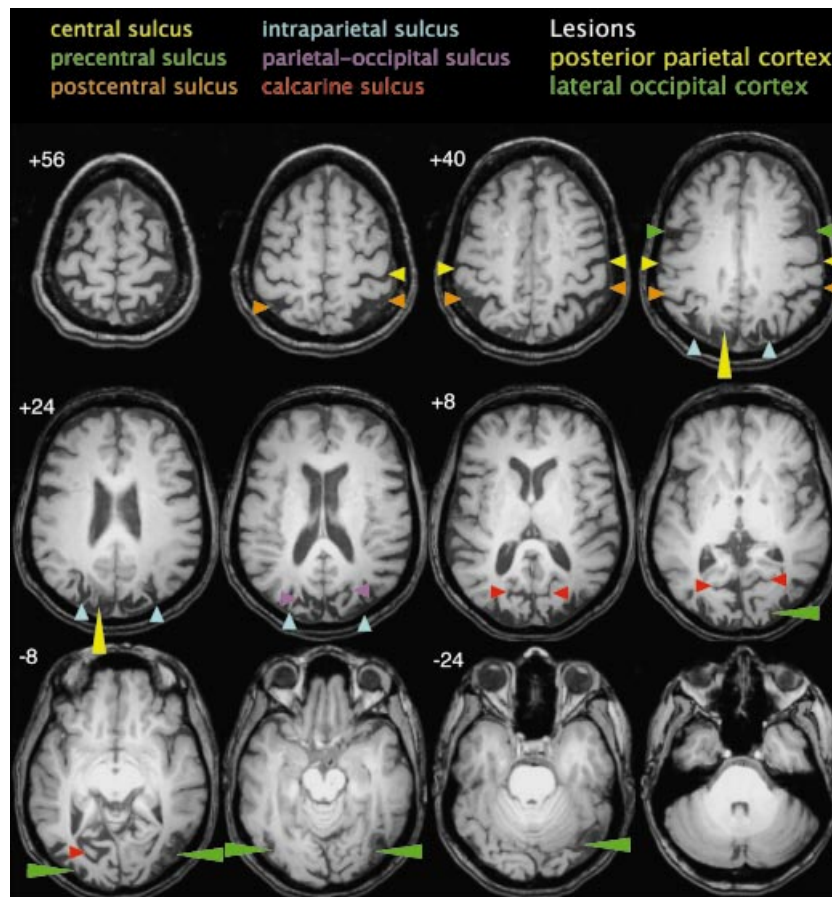


Fig. 3 High-resolution structural MRI from Patient D.F. The left side of the brain appears on the left side of the image. Numbers represent deviations (mm) from the anterior commissure–posterior commissure plane (z value in Talairach space). Small arrowheads indicate areas of atrophy and long arrowheads indicate lesioned areas. Small arrowhead colours identify the regions of atrophy: yellow = postcentral sulcus; orange = central sulcus; green = precentral sulcus; blue = intraparietal sulcus; magenta = parietal-occipital sulcus; red = calcarine sulcus. Long arrowhead colours identify the lesions: yellow = posterior parietal cortex; green = lateral occipital cortex.

movements, the participant transported the hand to the object location to touch the object with the knuckles without forming a grip (Fig. 2B). During grasping movements, the participant not only transported the hand but also preshaped the finger and thumb to form a precision grip along the long axis of the object (Fig. 2C). An event-related design was used to minimize motion artefacts. Trials were presented every 14 s in three runs of 20 trials each, for a total of 60 trials. These were split into 36 reaching trials and 24 grasping trials. Four exemplars of the same trial type were always presented in sequence to limit task switching. To verify that D.F. was accurately reaching and grasping, an experimenter monitored her movements. Three grasping trials and two reaching trials were not used in the analysis due to motion artefacts during those trials.

Imaging parameters and analysis

All imaging was done using a 4 tesla, whole-body MRI system (Varian, Palo Alto, USA/Siemens, Munich, Germany)

and a quadrature head coil located at the Robarts Research Institute (London, ON, Canada). The field of view was $19.2 \times 19.2 \times 7.8$ cm (Experiment 1) or $20.0 \times 20.0 \times 7.8$ cm (Experiment 2), with an in-plane resolution of 64×64 pixels and 13 contiguous scan planes per volume, resulting in a voxel size of $3.0 \times 3.0 \times 6.0$ mm (Experiment 1) or $3.13 \times 3.13 \times 6.0$ mm (Experiment 2). For Experiment 1, the 13 scan planes were coronal in orientation and extended from the occipital pole to approximately the centre of the corpus callosum. For Experiment 2, the 13 scan planes were oriented parallel to the calcarine sulcus, allowing more coverage of the parietal cortex. Images were collected using a T_2^* -weighted, segmented (navigator corrected), interleaved echoplanar imaging (EPI) acquisition [echo time (TE) = 15 ms, flip angle (FA) = 30° , 2 segments/plane) for blood oxygen level-dependent-based imaging (Ogawa *et al.*, 1993). Each volume (13 scan planes) required either 1.25 s (Experiment 1; TR = 625 ms) or 2.0 s [Experiment 2; repetition time (TR) = 1000 ms] to acquire. High-resolution T_1 -weighted anatomical volumes were also acquired using a 3D magnetization

prepared (MP) turbo FLASH acquisition (TI = 600 ms, TE = 5.2 ms, TR = 10 ms, FA = 15°). For D.F., this anatomical volume was acquired with 256 slices 1 mm thick, resulting in a voxel size of $0.75 \times 0.75 \times 1$ mm.

The imaging data were preprocessed using the Brain Voyager™ 3D (Brain Innovation, Maastricht, Netherlands) analysis tools. The anatomical volumes were transformed into a common stereotaxic space (Talairach and Tournoux, 1988). Functional volumes for each participant underwent 3D motion correction. For Experiment 1, 3D spatial frequency filtering with a frequency window between 2 and 24 cycles and temporal frequency filtering with a frequency window between 2 and 60 cycles were also performed. All preprocessed functional volumes were aligned to the transformed anatomical volumes, thereby transforming the functional data into a common brain space across scanning sessions and across participants.

The imaging data were analysed using the Brain Voyager multi-study GLM (general linear model) procedure. This procedure allows the correlation of predictor variables or functions with the recorded activation data (criterion variables) across scanning sessions. The predictor functions that were used were a series of gamma functions ($\Delta = 2.5$, $\tau = 1.25$) spaced in time on the basis of the event-related stimulus presentation paradigm for the particular run (Boynton *et al.*, 1996). For Experiment 1, predictors were generated for colour, greyscale and line drawing versions of the objects and their scrambled counterparts, totalling six predictors. For Experiment 2, predictors were generated for grasping trials and reaching trials, totalling two predictors. Fixed-effects GLMs were performed on individual participant data sets with a correction for serial correlations in the time courses. Random-effects GLMs were performed on grouped data sets. *A priori* contrasts between predictors of interest were then performed, creating activation maps of statistical *t*-values.

Results

Anatomical MRI

New high-resolution MRI images collected during this testing (Fig. 3) confirmed an earlier assessment made from MRI scans carried out 1 year after trauma (Milner *et al.*, 1991). Thus, the pattern of cortical brain damage was diffuse, which is common for hypoxic episodes, but with a concentration of damage in bilateral ventral lateral-occipital cortex [including parts of Brodmann areas (BA) 18 and 19]. The size of this lesion appeared larger in the right hemisphere than in the left hemisphere. Of interest is the confirmation that the primary visual cortex (BA 17) and the fusiform gyrus (BA 19, 37) appeared to be spared. The new MRI images also revealed anatomical abnormalities outside the ventral stream. First, a previously undetected lesion of smaller size than the occipital lesion could be seen in the left posterior parietal cortex. Secondly, throughout the brain there was evidence of atrophy,

as indicated by enlarged sulci and ventricles. Whereas in most neurologically intact individuals the gyri abut one another with little space (<2 mm) in between, many sulci in D.F.'s brain were enlarged, particularly the intraparietal sulcus bilaterally (3–10 mm), the postcentral sulcus bilaterally (3–4 mm), the inferior precentral sulcus bilaterally (4–6 mm), the parieto-occipital sulcus bilaterally (2–5 mm) and the left calcarine sulcus (2–4 mm). Despite the abnormal appearance of the regions outside the three lesions, the functional data from our two experiments below indicate that these areas remain functional.

Strikingly, a comparison of the location of D.F.'s ventral lesion sites with the known functional activation in healthy individuals (Culham, 2003) revealed that the lesion was restricted to 'object-selective' cortex (Fig. 4). That is, area LO, which responded more with intact rather than scrambled images of objects in healthy individuals (Malach *et al.*, 1995; Kanwisher *et al.*, 1996; James *et al.*, 2000, 2002; Kourtzi and Kanwisher, 2000; Grill-Spector *et al.*, 2001), overlapped completely with D.F.'s lesion site. This is not to say that the lesion included all object-selective cortical regions. On the contrary, as we show below, D.F.'s capacity to recognize colour and greyscale pictures of objects is dependent on spared regions of the ventral cortex, including the primary visual cortex and extensive areas of the lingual and fusiform gyri. Furthermore, other work from our laboratory (Steeves *et al.*, 2002) demonstrates a sparing of face-selective cortex in the fusiform gyrus (Kanwisher *et al.*, 1997; Halgren *et al.*, 1999). This evidence suggests that, as previously hypothesized (Goodale and Milner, 1992; Milner and Goodale, 1995), D.F.'s deficits are a result of a disconnection of functioning high-level visual processing centres from functioning low-level visual processing centres.

Experiment 1: object recognition

During the silent naming task, the healthy participants responded on nearly every trial showing an intact object, reflecting the fact that they were able to identify virtually all of the images. Patient D.F.'s responses indicated that she believed she could identify 67% of the intact coloured images, 67% of the greyscale images, but only 10% of the line drawings. Her pattern of responses was similar to the pattern seen during previous testing with objects presented in these formats in which she had to say the name of the object out loud (Humphrey *et al.*, 1994). Interestingly, D.F. had no trouble discriminating scrambled images from the intact images, even for the line drawing format. Scrambled images are a good control stimulus for intact images because every pixel from the intact image is duplicated in the scrambled image. The scrambling process, however, tends to introduce extra high spatial frequency information into the image. Subjectively, scrambled images sometimes appear to be texture patterns. It is likely that D.F.'s visual system can distinguish between intact and scrambled images at a categorical level by detecting differences in surface proper-

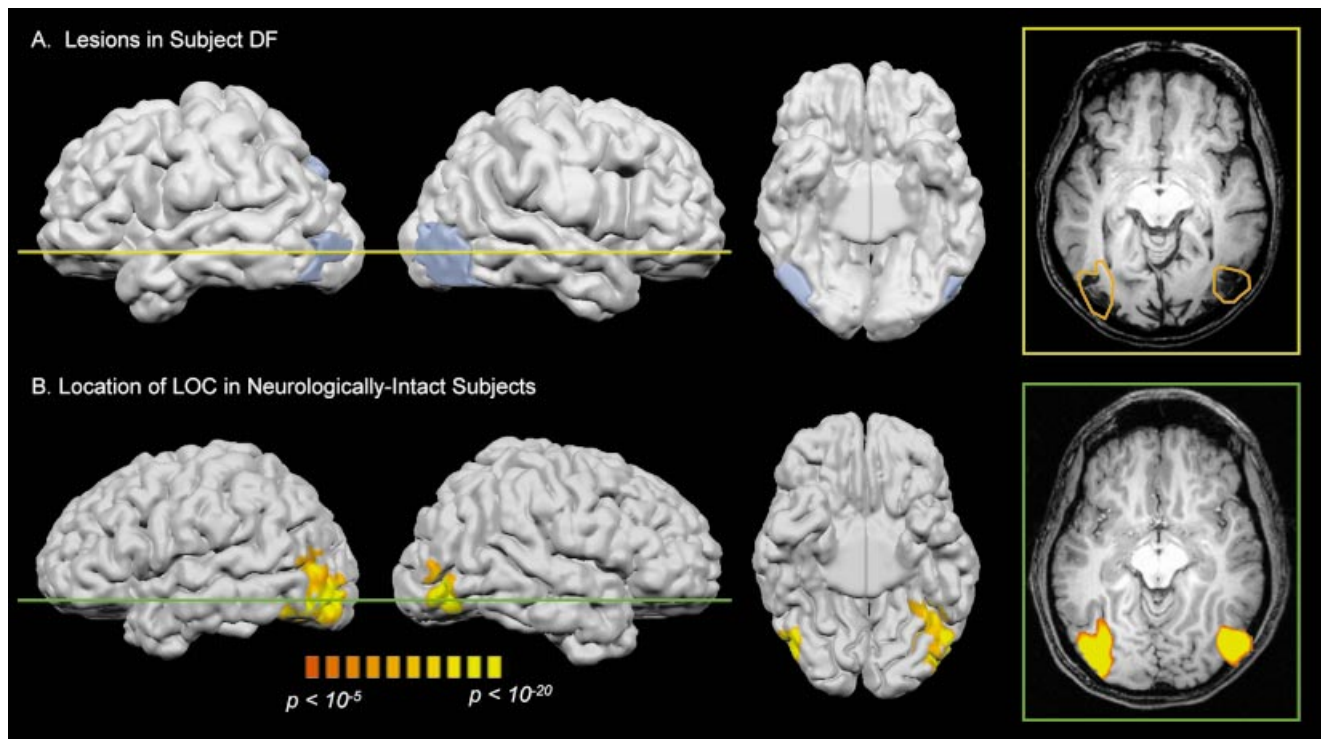


Fig. 4 Ventral stream lesions in D.F. shown in comparison with the expected location of the lateral occipital complex in healthy participants. **(A)** D.F.'s brain has been rendered at the pial surface (outer grey matter boundary). Lesions were traced on slices that indicated tissue damage and rendered on the pial surface in pale blue. Lateral views of the left and right hemispheres are shown, as is a ventral view of the underside of the brain. The rightmost image shows a slice through the lesions ($z = -8$). **(B)** The expected location of LOC based on group data from seven neurologically intact participants (Culham, 2003) is shown on one individual's pial surface and on a slice through the $z = -8$ plane. The activation in the slice is outlined in orange in panel **A** for comparison with the lesions in D.F.'s brain.

ties. Although this surface information allows her to categorize the images unerringly as intact or scrambled, it provides only some help with determining the identity of colour and greyscale objects and provides no assistance with identifying line drawings.

Two types of activation maps were calculated for individual participants from the neuroimaging data. The first activation map (Fig. 5A) contrasted the activation produced when viewing intact line drawings with the activation produced when viewing scrambled line drawings. This comparison produced reliable activation in the healthy participants, in regions that have been reported in other studies using similar stimuli (Kanwisher *et al.*, 1996; Martin *et al.*, 1996). For D.F., however, this comparison produced negligible activation. Thus, the type of stimulus that D.F. found extremely difficult to recognize (intact line drawings) did not produce any more activation than a scrambled image. This result may seem paradoxical in the light of D.F.'s ability to discriminate intact from scrambled line drawings. We liken this effect, however, to the categorization of textured patterns; it is reasonable to expect that two sets of textured patterns would produce essentially the same pattern of activation in healthy individuals.

The second activation map (Fig. 5B) contrasted the activation produced when viewing intact colour and

greyscale images with the activation produced when viewing scrambled versions of those images. Again, the healthy participants produced reliable activation in regions that have been reported in other studies using similar stimuli (Malach *et al.*, 1995; James *et al.*, 2002). D.F. also produced reliable activation, but her pattern of activation was different from that of the healthy participants. As demonstrated in Fig. 4, activation in area LO in the healthy participants fell directly within D.F.'s lesion site. D.F., of course, produced no activation in this region (green panel). Healthy participants sometimes show greater activation with scrambled than intact images in the striate and peristriate cortex. This reverse pattern can be explained by the higher spatial frequency, content (extra edges and end-stops) in the scrambled images, to which early visual areas are sensitive (Hubel and Wiesel, 1968; Grill-Spector *et al.*, 1998). This reverse pattern was seen quite strongly in D.F.'s activation map as well. There are two alternative explanations for this finding in D.F. It could be the case that, in D.F. (as in the healthy participants), these spared early visual processing regions are heavily recruited for the processing of the scrambled objects (by virtue of their high spatial frequency content), or that these areas in D.F. are somehow under-engaged by the intact objects. Of course, these explanations are not mutually exclusive.

D.F. also showed strong activation in the intraparietal sulcus with coloured and greyscale images, a pattern of activation that was also seen in some of the healthy participants (yellow panel). But in addition, D.F. showed high levels of activation throughout the peristriate cortex (BA 18 and 19), a pattern of activation that was not seen in the healthy participants. Finally, the fusiform gyrus was highly active in D.F., but showed the same pattern of activation as that seen in healthy participants (red panel).

To gain further insight into how D.F.'s damaged brain was processing the colour and greyscale objects, we analysed the time course of activation in the fusiform gyrus and peristriate regions described above. In particular, we were interested in comparing objects that were named successfully by D.F. during scanning with those that were not. These time courses are shown in Fig. 6. The fusiform gyrus and peristriate regions produced similar patterns of activation; i.e. negligible activation to scrambled objects, strong activation to named objects, and activation to non-named objects that was less than that of the named objects. Thus, activation in the fusiform gyrus and peristriate regions was dependent on whether the object was intact or scrambled, and was then further modulated by whether the object could be named or not. A parallel finding, that successful identification is associated with increased activation in area LO, has been reported previously in healthy individuals (Malach *et al.*, 1995; George *et al.*, 1999; Grill-Spector *et al.*, 2000). In these experiments, however, the stimuli were degraded, because otherwise accuracy would be at ceiling. Experience with non-degraded versions of the objects led to increased accuracy when identifying the degraded versions, and led to increased activation in area LO. In D.F. we did not have to manipulate stimulus familiarity, because she makes errors with non-degraded stimuli. Yet finding a correlation between identification success and activation in her fusiform gyrus and peristriate cortex strongly suggests that these areas are acting, like LO in healthy subjects, as a mechanism for object recognition. It remains to be seen whether this correlation exists in healthy participants in these areas as well.

Experiment 2: object grasping

D.F., like seven neurologically intact control participants, showed clear activation in dorsal-stream action areas during reaching and grasping (Fig. 7). During both reaching and grasping with the right hand, compared with the intertrial interval, D.F., like others, displayed bilateral activation in the postcentral and anterior intraparietal sulci, the frontal eye fields, the motor areas in the central sulcus (particularly in the contralateral, left hemisphere), the insula, and the midline supplementary motor area.

More importantly, when we subtracted reaching activation from grasping activation to identify the 'grip' component of the grasp with the 'transport' component removed, we found that D.F., like others, showed activation at the junction of the anterior intraparietal sulcus and the postcentral sulcus. Based

on studies of healthy individuals, we and others have proposed (Binkofski *et al.*, 1988; Culham, 2003; Culham *et al.*, 2003) that this area has similar properties to the AIP area of the macaque monkey, which contains neurons activated by hand manipulation under the guidance of vision (Sakata *et al.*, 1992). Grasping activation appeared primarily in the ipsilateral (right) hemisphere and is probably not due to somatosensory factors, which largely activate the contralateral (left) hemisphere. Grasping activation was also observed in D.F.'s contralateral (left) inferior postcentral sulcus, which probably does reflect somatosensory input.

Unlike the other participants, D.F. did not show activation in the superior parieto-occipital sulcus. In normal participants, activation is observed in the superior parieto-occipital sulcus during reaching and grasping [versus the intertrial interval (ITI)] and for grasping (versus reaching). D.F. showed no such activity in either the grasping minus ITI subtraction or the grasping minus reaching subtraction, although reaching and grasping did activate a segment of the right parieto-occipital sulcus ~1 cm inferior to the typical location. The superior parieto-occipital sulcus has been shown by others to be activated during arm movement tasks and has been suggested as a possible homologue (Connolly *et al.*, 2003) of the macaque parietal reach region (Snyder *et al.*, 1997). The posterior parietal lesion in D.F.'s left hemisphere is in this vicinity and may have led to reorganization of reach-related functions, and possibly grasp-related functions in the left hemisphere (given the absence of grasping activation in left AIP). Nevertheless, despite the posterior parietal lesion and the considerable atrophy observed in parietal cortex, grasp-related functions remain robust in the right hemisphere AIP.

Other work in our laboratory has found that, in healthy control participants, AIP grasping-related activation is largely bilateral, with a somewhat stronger response in the hemisphere contralateral to the hand being used (Culham *et al.*, 2001; Society for Neuroscience Abstract). Because D.F. was using her right hand, we would have predicted similar bilateral activation of AIP, with stronger activation in the left hemisphere. Instead, we found significant activation only in the right hemisphere. One possible explanation is that D.F.'s left-hemisphere grasping functions may be disrupted by the parietal lesion in the vicinity of the putative parietal reach region.

Discussion

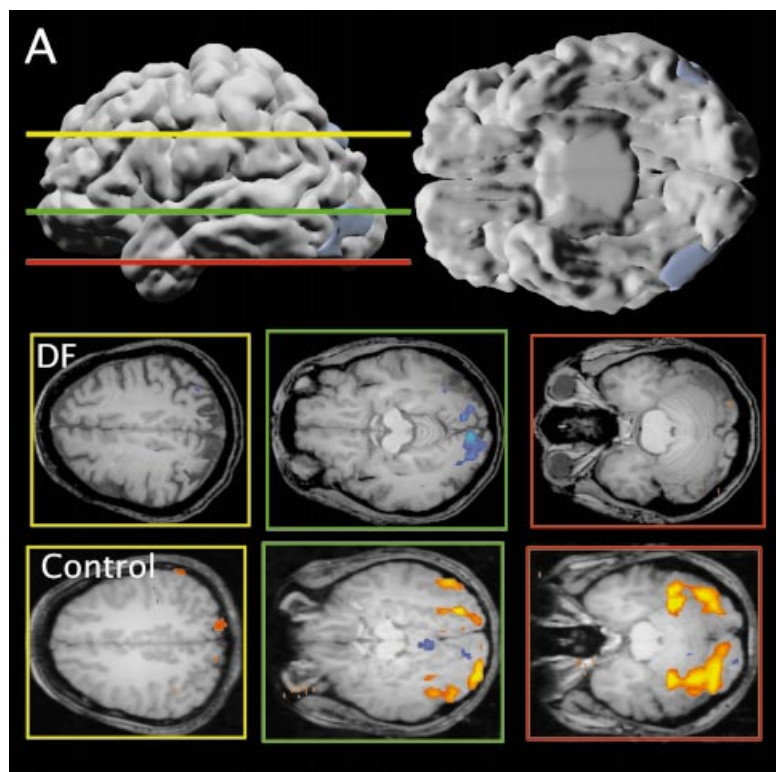
On the basis of behavioural data alone, Goodale and Milner hypothesized several years ago that D.F.'s visual form agnosia was the result of extensive damage to the occipitotemporal cortex, and that her spared visuomotor skills reflected intact processing in the occipitoparietal cortex and associated structures (Goodale and Milner, 1992; Milner and Goodale, 1995). The results we describe in the present report provide, for the first time, converging evidence that those interpretations were correct. Moreover, the results also

provide a compelling demonstration of the powerful role fMRI can play in revealing the pattern of spared and compromised functions in neurological patients—particularly in hypoxia patients like D.F., in whom the damage can often be quite diffuse.

At the time when D.F. was first tested, the prevailing view in neuroscience and psychology was that all of the visual processing areas in the primate cortex, despite their being clustered into at least two groupings (the ventral and dorsal visual streams), worked in concert to deliver a single perceptual representation of the visual world, which could then guide a range of possible responses. The fact that D.F. exhibited a dissociation between loss of visual form perception on the one hand and good visuomotor control on the other (Goodale *et al.*, 1991) provided strong presumptive evidence against that view, supporting instead the idea that these two aspects of vision were served by separate cortical systems (Perenin and Vighetto, 1988; Milner *et al.*, 1991; Jeannerod *et al.*, 1994). The next step, of relating D.F.'s dissociation to the ventral and dorsal visual streams, was based on a range of evidence from visual neuroscience, including the fact that damage to the human posterior parietal cortex often results in optic ataxia, a condition characterized by disordered visuomotor control. Although patients with optic ataxia have problems in reaching accurately for objects and in forming the size and orientation of their grip to take hold of them, some of them can still make good perceptual discriminations within those same visual attributes. Goodale and Milner argued that these two opposite dissociations, seen

respectively in D.F. and in patients with optic ataxia, were each dependent on damage that devastated one of the two visual streams while leaving the other relatively intact.

The high-resolution structural MRI (Fig. 3) performed on D.F. reveals that her brain damage includes dense bilateral damage in area LO, as defined by a comparison of intact and scrambled objects in healthy participants. In addition, the Talairach coordinates of the centre of D.F.'s ventral lesions are $\pm 41, -71, -10$, well within the range of the coordinates of LO reported elsewhere ($\pm 39 \pm 6, -71 \pm 7, -5 \pm 6$) (Grill-Spector *et al.*, 1999). Milner and Goodale's original hypothesis (Goodale and Milner, 1992; Milner and Goodale, 1995) was that D.F.'s visual form agnosia was the result of severe damage to early visual areas within her ventral stream (corresponding to area VP or V4), which *ipso facto* would have deafferented higher-level processing areas in the temporal lobe. The present evidence, however, shows that her ventral-stream damage is largely localized in area LO, an area that is anterior to V4 (coordinates $\pm 32, -87, -16$) (Hadjikhani *et al.*, 1998) and 'later' in the processing hierarchy of the visual system than we had suggested for the site of her lesion. In fact, some authors have argued that area LO may be homologous with the inferotemporal region (IT) of the monkey brain (Malach *et al.*, 1995; Halgren *et al.*, 1999), although, as discussed below, this hypothesis is not completely in line with D.F.'s case. Putting together the behavioural and neuroimaging evidence suggests that D.F. has lost the use of the visual brain region that is associated with the normal recognition of objects based on contour



information. Not surprisingly, therefore, a comparison of brain activation elicited by real and scrambled line drawings yielded no detectable activity in D.F.'s occipitotemporal region. These results provide powerful confirmation of Milner and Goodale's guiding hypothesis, that the form-processing network in D.F.'s ventral stream has been all but destroyed.

It is obvious, though, that D.F.'s damage to area LO is not the same as complete destruction of the ventral visual stream. D.F. can still process objects based on other, non-form

information. This has always been apparent from the fact that D.F. has retained relatively good, though not normal, colour and texture discrimination (Milner *et al.*, 1991). In fact, she is considerably better at discriminating between fine shades of colour than between comparably fine shades of grey (Milner and Heywood, 1989). Because her perception of colour and visual texture is relatively intact, D.F. is also able to identify the surface properties of objects and the material from which they are made, even though she remains perceptually oblivious to their form (Humphrey *et al.*, 1994). In fact,

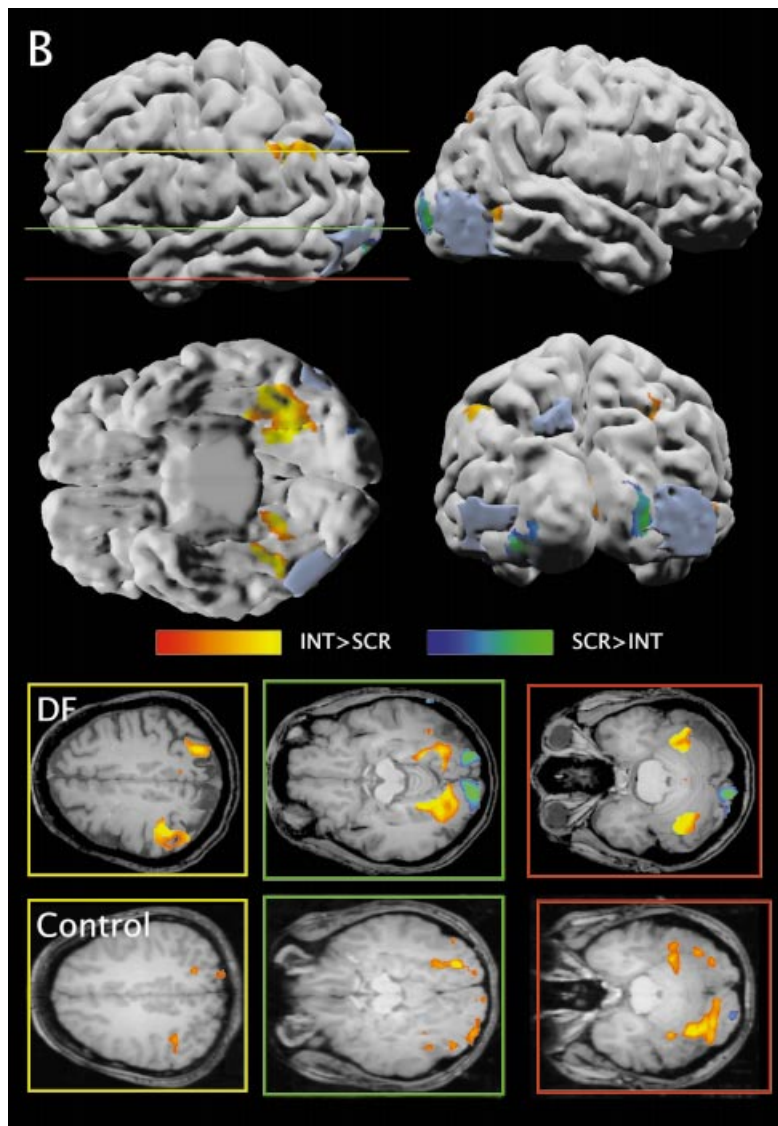


Fig. 5 Activation maps from the comparison of intact objects with scrambled objects. At the top of each panel, D.F.'s brain is shown on a 3D rendered pial surface (as in Fig. 4). At the bottom of each panel, slices from D.F. are compared with slices from a control participant. For both panels, slices are shown at +36, -18 and -24 mm deviations from the anterior commissure–posterior commissure plane. The colour scales represent statistical values of $10^{-3} < P < 10^{-9}$. (A) Comparison of intact and scrambled line drawings only. Pial surfaces are views of the left-hemisphere lateral surface and the ventral surface. (B) Comparison of intact and scrambled colour and greyscale images combined. Starting at the upper left (clockwise), pial surfaces are views of the left-hemisphere lateral surface, the right-hemisphere lateral surface, the ventral surface and the posterior surface.

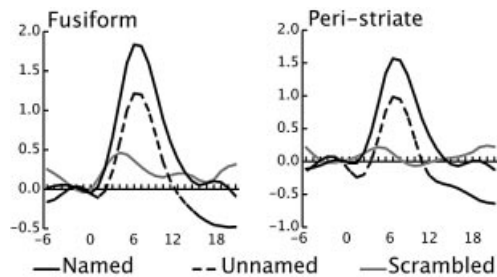


Fig. 6 Activation time courses as a function of image type and naming performance. Each graph represents event-related averages of activation produced while D.F. viewed colour or greyscale intact and scrambled images. Activation for intact images is shown separately for images that were named and those that were not named.

D.F. does succeed in recognizing objects when colour or greyscale information is present (Humphrey *et al.*, 1994), a result that was confirmed in the present study. Yet bilateral ablations of IT (including area TEO, i.e. the inferior occipitotemporal cortex) in the monkey not only disrupt form discrimination, but also interfere with colour discrimination (Heywood *et al.*, 1995). Based on these findings, our original suggestion was that D.F.'s ventral-stream damage, though severe, was selective: specifically, that her 'blob' channel retained relatively intact connections right through from V1 and V2 to V4 and the human equivalent of IT. This proposal was driven by a suggestion that the blob channel may be selectively spared in hypoxia (Allman and Zucker, 1990), because the blobs, which are rich in cytochrome oxidase (mitochondria), are more capable of anaerobic metabolism than the inter-blob regions, which do not contain so many mitochondria. But while the blob channel can provide sufficient wavelength information for colour perception, it cannot furnish the necessary contour information needed for shape perception (Milner and Goodale, 1995, p. 135). The new structural MRI result showing that D.F.'s lesion is in fact in area LO, the purported homologue of monkey area IT, presents a serious question: why does D.F. not show a deficit in colour vision?

Recently, a region of high colour responsiveness (V8) has been identified just inferior and anterior to area LO in humans (Hadjikhani *et al.*, 1998). This area seems to have been relatively spared in D.F.'s brain, and its coordinates (± 33 , -65 , -14) (Hadjikhani *et al.*, 1998) place it just inferior and anterior to D.F.'s lesion. We observed more activation in this area and several other peristriate regions in D.F.'s brain than in our healthy participants during the object recognition tasks in which colour or greyscale information was available. It may be that D.F.'s perception of colour and visual texture and her use of these surface qualities to aid her object recognition owe a great deal to the sparing of V8 and to other processing regions in the blob channel, including V4, V2 and V1. Furthermore, D.F.'s pattern of spared and compromised abilities and our new neuroimaging data suggest that area LO does not represent a level of the visual system at which all

modes of visual information combine. Form information appears to take priority in area LO, suggesting that a region later in the hierarchy (perhaps the fusiform gyrus) may be the site of the confluence of visual form and visual surface properties. In fact, we speculate that the blob/thin stripe and inter-blob/inter-stripe channels that originate in areas V1 and V2 and that process surface properties and contour information, respectively, may remain as separate channels, at least to the location of D.F.'s lesion, area LO. Moreover, we would argue that human areas LO and V8 respectively are higher-level projection sites of the separate low-level channels for contour information and surface properties, and that the homologues of both areas may have been included in the monkey 'inferotemporal' lesions (Heywood *et al.*, 1995). In D.F., as suggested earlier, the blob channel to V8 appears to have survived the hypoxic episode whereas the inter-blob channel to LO did not. Although speculative, these ideas are supported by data from tracer experiments in monkeys, which suggest that the separation of contour and surface properties channels extends beyond V1 and V2 into V4 and posterior IT (Felleman *et al.*, 1997).

As stated above, D.F.'s brain showed more widespread activity than that of healthy controls when presented with coloured and greyscale images (compared with scrambled images). The highest peak of activation in healthy individuals with these stimuli is in area LO, with smaller peaks in other cortical regions; this peak is also consistent across coloured and greyscale images and line drawings (Kanwisher *et al.*, 1996; Kourtzi and Kanwisher, 2000). In contrast, D.F. showed no activation in area LO (the site of her lesion), and robust activation peaks in the peristriate, fusiform and parietal cortex with coloured and greyscale images; she also showed no reliable activation with line drawings. Our interpretation of these data is that, in the intact brain, area LO processes form information for recognizing objects whether or not colour or greyscale information is present. D.F.'s area LO, however, is so badly damaged that form information cannot be used to achieve object recognition. Instead, colour and greyscale information are given higher priority, thus recruiting visual areas that process surface information, including area V8 and several other early visual areas, to achieve some degree of successful object identification. In fact, even when D.F. cannot identify an object, she is still good at identifying the material from which it is made (Humphrey *et al.*, 1994).

The activation seen in D.F.'s intraparietal sulcus with coloured and greyscale objects is consistent with the findings of a number of fMRI studies of object recognition that have found activation in the intraparietal sulcus (for review, see James *et al.*, 2002). It has been argued that this activation may represent some sort of processing relating to action (James *et al.*, 2002). The robust activation in this region in D.F. could reflect her attempts to invoke motor imagery to assist in the identification of objects whose surface and material properties she recognizes. Behavioural experiments have shown that she sometimes employs such strategies to compensate for the

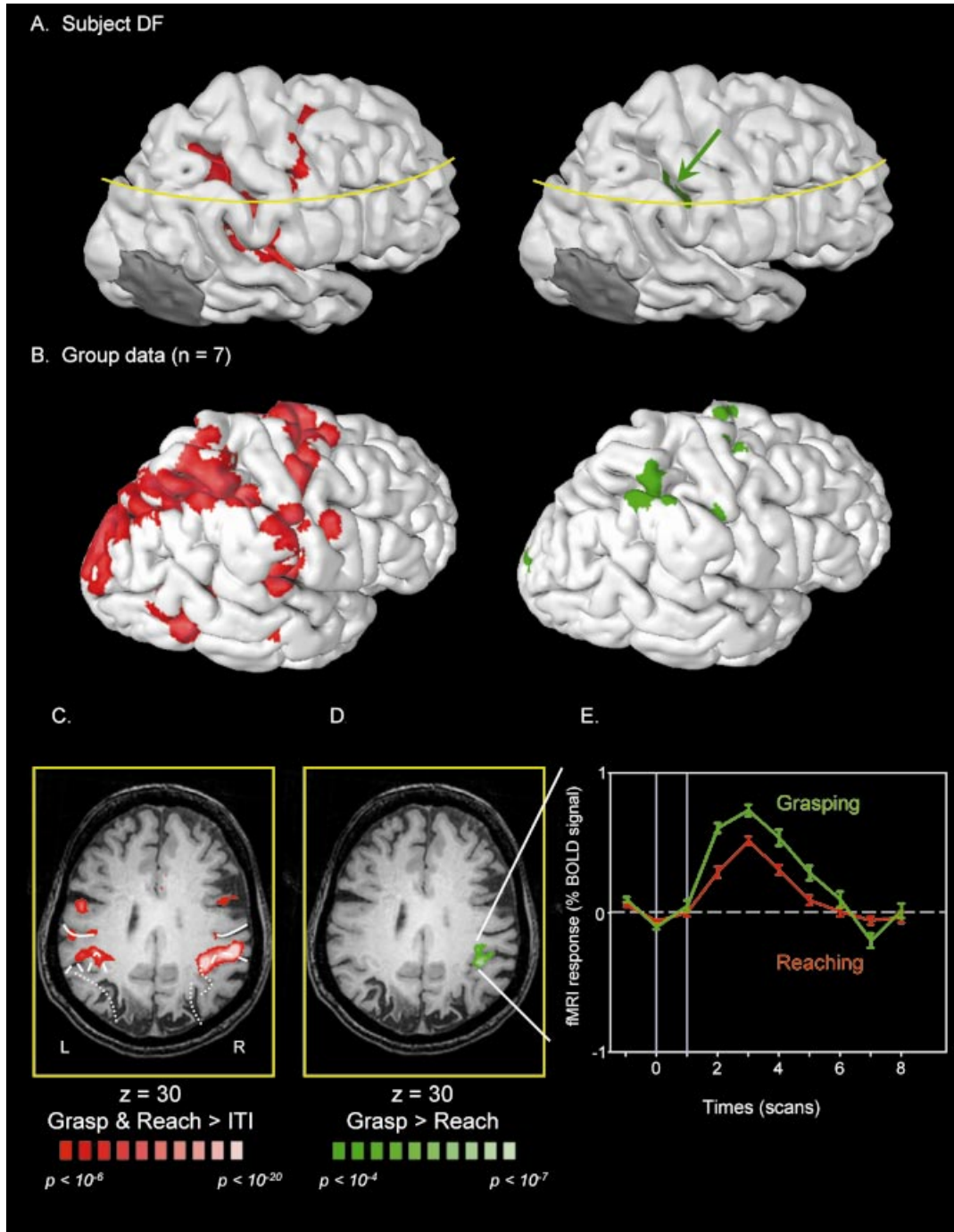


Fig. 7 Activation during reaching and grasping in D.F. and in normal control participants. (A) Activation for reaching and grasping (versus the intertrial interval, ITI) is shown in red and activation for grasping versus reaching is shown in green in the left hemisphere for D.F. (B) Activation for reaching and grasping and for grasping versus reaching is shown in the left hemisphere, based on the group data of seven participants rendered on a single participant's pial surface. Note that the group activation is more robust than in D.F. due to the greater statistical power of a larger sample size. (C) Reaching and grasping (versus ITI) activation shown on a single slice through D.F.'s brain. The plane of the slice is indicated by the yellow line in A. (D) Grasping (versus reaching) activation in D.F.'s brain. (E) The averaged time course of activation for grasping and reaching trials in the anterior intraparietal area indicated in D. Note that the activation occurs after an appropriate haemodynamic lag and shows no evidence of motion artefacts.

loss of normal ventral-stream processing (Dijkerman and Milner, 1997).

In contrast to the evident dysfunction in her ventral stream, D.F.'s dorsal stream appears to be functioning remarkably

well, despite the fact that it too shows evidence of damage from the hypoxic episode that precipitated her agnosia. As Experiment 2 demonstrated, the region identified in our healthy controls as homologous to the monkey area AIP

(Culham, 2003; Culham *et al.*, 2003) was activated reliably during object grasping, relative to a reaching task in which D.F. simply touched the object. This activation was particularly clear in D.F.'s right hemisphere, probably because of the greater damage sustained by her left posterior parietal region. This result, too, provides strong confirmation of Milner and Goodale's initial hypothesis. There can no longer be any serious doubt that D.F. has retained the use of her dorsal stream for mediating visually guided prehension, and that this system is able to function well despite the devastating loss of the form-processing network vested in area LO in the ventral stream. Indeed, the data suggest that area LO normally plays no role whatever in mediating object-directed grasping movements. We can, therefore, conclude that the shape, size and orientation processing needed for accurate visual grasping must take place within the dorsal stream itself, in parallel with and independent of the ventral stream.

Acknowledgements

This research was supported by grants from the Wellcome Trust (A.D.M.), Canadian Institutes of Health Research (M.A.G., T.W.J.), the Canada Research Chairs program (M.A.G.) and the Natural Sciences and Engineering Research Council of Canada (J.C.). We wish to thank Kenneth Valyear for assistance with brain segmentation and preparation of the figures, Martyn Klassen, Joseph Gati, Ravi Menon, Brad MacIntosh, James Danckert, Stacey Danckert and Derek Quinlan for their assistance in collecting the fMRI data, and Karin James, Isabel Gauthier and two anonymous reviewers for their comments on the manuscript. Most of all we wish to thank D.F. for her willing and wholehearted cooperation in the research.

References

- Allman J, Zucker S. Cytochrome oxidase and functional coding in primate striate cortex: a hypothesis. *Cold Spring Harb Symp Quant Biol* 1990; 55: 979–82.
- Andersen RA, Buneo CA. Intentional maps in posterior parietal cortex. *Annu Rev Neurosci* 2002; 25: 189–220.
- Baizer JS, Ungerleider LG, Desimone R. Organization of visual inputs to the inferior temporal and posterior parietal cortex in macaques. *J Neurosci* 1991; 11: 168–90.
- Binkofski F, Dohle C, Posse S, Stephan KM, Hefter H, Seitz RJ, et al. Human anterior intraparietal area subserves prehension: a combined lesion and functional MRI activation study. *Neurology* 1988; 50: 1253–9.
- Boynton GM, Engel SA, Glover GH, Heeger DJ. Linear systems analysis of functional magnetic resonance imaging in human V1. *J Neurosci* 1996; 16: 4207–21.
- Connolly JD, Andersen RA, Goodale MA. FMRI evidence for a 'parietal reach region' in the human brain. *Exp Brain Res*. In press 2003.
- Culham JC. Human brain imaging reveals a parietal area specialized for grasping. In: Kanwisher N, Duncan J, editors. *Functional brain imaging of visual cognition*. Oxford: Oxford University Press. In press 2003.
- Culham JC, Kanwisher N. Neuroimaging of cognitive functions in human parietal cortex. *Curr Opin Neurobiol* 2001; 11: 157–63.
- Culham JC, Danckert SL, Desouza JFX, Gati JS, Menon RS, Goodale MA. Visually-guided grasping produces activation in dorsal but not ventral stream brain areas. *Exp Brain Res*. In press 2003.
- Dijkerman HC, Milner AD. Copying without perceiving: motor imagery in visual form agnosia. *Neuroreport* 1997; 8: 729–32.
- Felleman DJ, Xiao Y, McClendon E. Modular organization of occipitotemporal pathways: cortical connections between visual area 4 and visual area 2 and posterior inferotemporal ventral area in macaque monkeys. *J Neurosci* 1997; 17: 3185–200.
- George N, Dolan RJ, Fink G, Baylis GC, Russell C, Driver J. Contrast polarity and face recognition in the human fusiform gyrus. *Nat Neurosci* 1999; 2: 574–80.
- Goodale MA, Humphrey GK. The objects of action and perception. *Cognition* 1998; 67: 181–207.
- Goodale MA, Milner AD. Separate visual pathways for perception and action. *Trends Neurosci* 1992; 15: 20–5.
- Goodale MA, Milner AD, Jakobson LS, Carey DP. A neurological dissociation between perceiving objects and grasping them. *Nature* 1991; 349: 154–6.
- Grill-Spector K, Kushnir T, Hendler T, Edelman S, Itzhak Y, Malach R. A sequence of object-processing stages revealed by fMRI in the human occipital lobe. *Hum Brain Mapp* 1998; 6: 316–28.
- Grill-Spector K, Kushnir T, Edelman S, Avidan G, Itzhak Y, Malach R. Differential processing of objects under various viewing conditions in the human lateral occipital complex. *Neuron* 1999; 24: 187–203.
- Grill-Spector K, Kushnir T, Hendler T, Malach R. The dynamics of object-selective activation correlate with recognition performance in humans. *Nat Neurosci* 2000; 3: 837–843.
- Grill-Spector K, Kourtzi Z, Kanwisher N. The lateral occipital complex and its role in object recognition. *Vision Res* 2001; 41: 1409–22.
- Hadjikhani N, Liu AK, Dale AM, Cavanagh P, Tootell RB. Retinotopy and color sensitivity in human visual cortical area V8. *Nat Neurosci* 1998; 1: 235–41.
- Halgren E, Dale AM, Sereno MI, Tootell RB, Marinkovic K, Rosen BR. Location of human face-selective cortex with respect to retinotopic areas. *Hum Brain Mapp* 1999; 7: 29–37.
- Heider B. Visual form agnosia: neural mechanisms and anatomical foundations. *Neurocase* 2000; 6: 1–12.
- Heywood CA, Gaffan D, Cowey A. Cerebral achromatopsia in monkeys. *Eur J Neurosci* 1995; 7: 1064–73.
- Hubel DH, Wiesel TN. Receptive fields and functional architecture of monkey striate cortex. *J Physiol* 1968; 195: 215–43.
- Humphrey GK, Goodale MA, Jakobson LS, Servos P. The role of

surface information in object recognition: studies of a visual form agnosic and normal subjects. *Perception* 1994; 23: 1457–81.

Humphrey GK, Symons LA, Herbert AM, Goodale MA. A neurological dissociation between shape from shading and shape from edges. *Behav Brain Res* 1996; 76: 117–25.

James TW, Humphrey GK, Gati JS, Menon RS, Goodale MA. The effects of visual object priming on brain activation before and after recognition. *Curr Biol* 2000; 10: 1017–24.

James TW, Humphrey GK, Gati JS, Menon RS, Goodale MA. Differential effects of viewpoint on object-driven activation in dorsal and ventral streams. *Neuron* 2002; 35: 793–801.

Jeannerod M, Decety J, Michel F. Impairment of grasping movements following a bilateral posterior parietal lesion. *Neuropsychologia* 1994; 32: 369–80.

Kanwisher N, Chun MM, McDermott J, Ledden PJ. Functional imaging of human visual recognition. *Brain Res Cogn Brain Res* 1996; 5: 55–67.

Kanwisher N, McDermott J, Chun MM. The fusiform face area: a module in human extrastriate cortex specialized for face perception. *J Neurosci* 1997; 17: 4302–11.

Kourtzi Z, Kanwisher N. Cortical regions involved in perceiving object shape. *J Neurosci* 2000; 20: 3310–8.

Malach R, Reppas JB, Benson RR, Kwong KK, Jiang H, Kennedy WA, et al. Object-related activity revealed by functional magnetic resonance imaging in human occipital cortex. *Proc Natl Acad Sci USA* 1995; 92: 8135–9.

Martin A, Wiggs CL, Ungerleider LG, Haxby JV. Neural correlates of category-specific knowledge. *Nature* 1996; 379: 649–52.

Milner AD, Goodale MA. *The visual brain in action*. Oxford: Oxford University Press; 1995.

Milner AD, Heywood CA. A disorder of lightness discrimination in a case of visual form agnosia. *Cortex* 1989; 25: 489–94.

Milner AD, Perrett DI, Johnston RS, Benson RS, Jordan PJ, Heeley

TR, et al. Perception and action in visual form agnosia. *Brain* 1991; 114: 405–28.

Morel A, Bullier J. Anatomical segregation of two cortical visual pathways in the macaque monkey. *Vis Neurosci* 1990; 4: 555–78.

Ogawa S, Menon RS, Tank DW, Kim SG, Merkle H, Ellermann JM, et al. Functional brain mapping by blood oxygenation level-dependent contrast magnetic resonance imaging. A comparison of signal characteristics with a biophysical model. *Biophys J* 1993; 64: 803–12.

Perenin MT, Vighetto A. Optic ataxia: a specific disruption in visuomotor mechanisms. I. Different aspects of the deficit in reaching for objects. *Brain* 1988; 111: 643–74.

Sakata H, Taira M, Mine S, Murata A. Hand-movement-related neurons of the posterior parietal cortex of the monkey: their role in visual guidance of hand movements. In: Caminiti R, Johnson PB, Burnod Y, editors. *Control of arm movement in space: neurophysical and computational approaches*. Berlin: Springer-Verlag; 1992. p. 185–98.

Snyder LH, Batista AP, Andersen RA. Coding of intention in the posterior parietal cortex. *Nature* 1997; 386: 167–70.

Steeves JKE, Humphrey GK, Culham JC, Menon RS, Goodale MA. Scene classification and parahippocampal place area activation in an individual with visual form agnosia. *J Vis* 2002; 2: 495a.

Talairach J, Tournoux P. *Co-planar stereotaxic atlas of the human brain*. Stuttgart: Thieme; 1988.

Ungerleider LG, Mishkin M. Two cortical visual systems. In: Ingle DJ, Goodale MA, Mansfield RJ, editors. *Analysis of visual behavior*. Cambridge (MA): MIT Press; 1982. p. 549–86.

Young MP. Objective analysis of the topological organization of the primate cortical visual system. *Nature* 1992; 358: 152–5.

Received March 19, 2003. Revised May 16, 2003.

Accepted May 31, 2003