

Review

Ideomotor apraxia: A review

Lewis A. Wheaton^{a,b}, Mark Hallett^{a,*}

^a Human Motor Control Section, Medical Neurology Branch, National Institute of Neurological Disorders and Stroke, National Institutes of Health, Bethesda, MD, United States

^b Division of Gerontology, Geriatric Research Education and Clinical Center, Veterans Affairs Medical Center, Baltimore, MD, United States

Received 3 January 2007; accepted 3 April 2007

Available online 16 May 2007

Abstract

Ideomotor apraxia (IMA) is a disorder traditionally characterized by deficits in properly performing tool-use pantomimes (e.g., pretending to use a hammer) and communicative gestures (e.g., waving goodbye). These deficits are typically identified with movements made to verbal command or imitation. Questions about this disorder relate to its diagnosis, anatomical correlates, physiological mechanisms involved, and the patients in whom IMA is best characterized. In this review, utilizing information presented at an international workshop, we summarize the present state of knowledge about IMA. We include insights on how to distinguish IMA from the other motor apraxias and confounding disorders. We discuss testing for IMA and the need for more rigorous tests that examine more elements, such as imitation, actual use, task selection, and recognizing proper use. From neurophysiological insights, we propose hypotheses of the necessity of networks in praxis performance. We also point out that more neurophysiological knowledge in humans might lead to a better understanding of how different brain structures may aid in the rehabilitation of praxis. While little is known about exactly how rehabilitation may be pursued, biological evidence warrants the further exploration of this issue.

© 2007 Elsevier B.V. All rights reserved.

Keywords: Ideomotor apraxia; Motor control; Rehabilitation; Parietofrontal; Apraxia; Higher-order motor control

Contents

| | |
|---|---|
| 1. Introduction | 2 |
| 2. Clinical definitions of the apraxias | 2 |
| 3. IMA diagnosis | 3 |
| 4. Testing for IMA | 3 |
| 5. Lesions that produce IMA | 4 |
| 5.1. Left vs. right hemisphere lesions | 4 |
| 5.2. Basal ganglia lesions | 4 |
| 5.3. Callosal, cortical, and subcortical lesions | 4 |
| 6. Clinical and theoretical models of IMA | 5 |
| 7. Physiology of parietal, premotor, and subcortical structures | 5 |
| 7.1. Parietal action coding | 5 |
| 7.2. Premotor action coding | 6 |
| 7.3. Networks of parietal and premotor areas for praxis | 6 |
| 8. Rehabilitation of IMA patients | 7 |
| 9. Linking physiology and pathophysiology | 8 |

* Corresponding author. Human Motor Control Section, Medical Neurology Branch, National Institute of Neurological Disorders and Stroke, National Institutes of Health, Building 10, Room 5N244, 10 Center Drive, MSC 1428, Bethesda, MD 20892-1428, United States. Tel.: +1 301 4969526.

E-mail address: hallettm@ninds.nih.gov (M. Hallett).

| | |
|---------------------------|---|
| Acknowledgments | 8 |
| References | 8 |

1. Introduction

Ideomotor apraxia (IMA) has been studied since the early 1900s. Early investigations of the disorder focused on patients who had lesions resulting from a stroke. These patients are unable to perform communicative gestures and properly pantomime tool use, and have other cognitive and motor problems. Tool-use movements are more often impaired than communicative gestures [1]. Deficits in actual tool use may also be observed [2], and this makes the disorder practically relevant. IMA is commonly seen in patients with stroke involving the left hemisphere, and is also present in conditions such as corticobasal degeneration (CBD), Parkinson's disease (PD), Alzheimer's disease (AD), progressive supranuclear palsy (PSP), and Huntington's disease (HD) [3–6].

In accord with the pioneering proposal of Hugo Liepmann, Norman Geschwind [7,8] posited that IMA was a result of a disconnection of anatomically separate cortical regions. While Liepmann suggested that parietal and premotor areas were mainly affected, Geschwind proposed a more specific model based on the disconnection of Wernicke's area and the convexity of the premotor cortex. The theory of a disconnection has remained fairly strong over the years. It is known that lesions of the periventricular white matter, which can create a disconnection of the parietal and premotor cortices, may cause apraxia [9]. Gray matter lesions may also result in disconnections, since the gray matter is the source of white matter tracts. Clinicoanatomical correlates are most commonly lesions of the parietal or premotor cortices, or both [10]. However, lesions of these areas do not always produce apraxia [10]. Apraxia is present in at least one third of patients with left hemisphere stroke [11], but the exact percentage is unclear since there is no standard test for apraxia, and many neurologists do not routinely test for the deficit. Additionally, there is some ambiguity in distinguishing IMA from other motor apraxias. Current research in IMA should begin with a better delineation of the disorder.

2. Clinical definitions of the apraxias

The term apraxia is used to describe a variety of phenomena involving different functions of the body (e.g., buccolingual apraxia, construction apraxia, dressing apraxia, and gait apraxia), but there are six main, recognized types of apraxia involving the upper limb (Table 1). The precise definitions of these apraxias are a focus of considerable debate, probably because clinical reports of each apraxia type in similar patient groups are inconsistent or insufficient. However, we define the core deficits in each of the six apraxia subtypes:

1. Limb-kinetic apraxia involves deficits mainly in fine and precise finger movements, such as those used in picking

up a small coin or paper clip. Grasping with the full hand may also be affected. It is a basic motor coordination deficit, not explainable by more elemental deficits implicating areas such as the cerebellum or corticospinal tract.

2. Conceptual apraxia relates to the inability to solve tool/mechanical problems. The distinguishing feature of the deficit is the loss of tool–object associations, actions associated with tools, and the mechanical advantage of using tools. This deficit is more representative of a loss of knowledge of proper performance than loss of motor function.
3. Ideational apraxia is commonly confused with conceptual apraxia. It is characterized as a failure to sequence task elements correctly. Conceptual problems are not the main issue. The distinguishing factor is that patients can convey knowledge of how to perform a sequence task (e.g., making a ham sandwich), but they fail to properly order the elements of the task, such as missing steps or doing steps out of order.
4. In verbal–motor dissociation apraxia, patients fail to respond to verbal commands to make movements. Dissociation apraxia has also been referred to as *disassociation* apraxia, but dissociation is the preferred term. (Heilman, K., personal communication). This disorder may be more involved with speech processing than motor performance.
5. Tactile apraxia is a selective disturbance of active touch. Hand skills not related to object exploration and manipulation are left intact. The disturbance is not specific for tool use, but affects any use of the hand as a sense organ.
6. IMA, the focus of this review, is the inability to pantomime, imitate, and, sometimes, use tools properly. The movements are spatially incorrect, and may be abnormally slow and deliberate. This deficit may extend into communicative gestures as well, but is more often seen in tool-use pantomime. The deficits commonly include

Table 1
The six main types of apraxia that affect the hand and arm

| Apraxia | Deficit |
|---------------------------|--|
| Ideomotor | Deficit in pantomiming tool use and gestures specifically. Knowledge of tasks is still present. |
| Limb-kinetic | Loss of hand and finger dexterity generally contralateral to the lesion. Mainly affects “manipulative” movements. |
| Ideational | Failure to carry out a series of tasks using multiple objects for an intended purpose. Tools are identifiable, but no coherent action is made. |
| Conceptual | Loss of tool knowledge and inappropriate use of tools and objects. |
| Verbal–motor dissociation | Inability to respond properly to verbal commands to make movements. |
| Tactile | Disruption of use of the hand as a sense organ, in which object exploration and manipulation are impaired. |

orientation errors (e.g., holding a comb upside down on top of the head) and spatial and temporal errors (e.g., carving a turkey with jerky vertical movements instead of smooth anterior–posterior movements). Other deficits include movement errors (e.g., patients make extra and unnecessary movements or move the wrong joints). Use of an object or tool in real-life situations may be impaired as well. Patients may also perform “body part as object” errors (e.g., when instructed to cut a slice of bread, they will use the arm as if it were a knife instead of holding a knife). An important distinction is that patients with IMA must know what they are told to do. Thus, patients with Wernicke’s aphasia, agnosia, and asymbolia must be excluded as confounds in any diagnosis. Aphasia, in particular, must be excluded, as apparent apraxia often coexists with language impairment. The coexistence occurs for several reasons. One, brain areas that process language for communication may overlap with brain areas that process language to drive movement. Two, frontal areas involved in language are also involved in complex movement, perhaps because those brain areas devoted to the hand communication gesturing of ancestral humans have been co-opted for verbal communication of modern humans.

3. IMA diagnosis

It is important to have a sense of confounding elements that may lead to a misdiagnosis of IMA. IMA is seen in various disorders, including stroke, PD, PSP, and CBD. While degraded spatial and temporal features of movements are clearly indicative of IMA, subcortical signs such as bradykinesia or dystonia may also be present, and these might prevent a firm diagnosis. For example, pantomiming “brushing your hair” in a patient with IMA might include large circular arcs above the head, or incorrect orientation of the hand for brushing the hair. Such errors cannot be attributed to more elemental movement disorders, and thus it is possible to make a bona fide diagnosis of apraxia in a bradykinetic patient. It must be clear that the deficits occur only for complex apraxia-specific tasks. If the deficits are generalized to even simple movements, then it is difficult to clearly make a case for IMA. It is expected that testing results for these elemental motor disorders would appear normal in patients with apraxia. However, a patient with PD, for example, may have spatial and temporal deficits for all types of movements. Thus, the problem is not related to lost or damaged representations of motor programs, but to confounding motor elements that prevent proper execution of all movements. Clearly, typical IMA is best described as a motor problem that cannot be attributed to other movement or cognitive disorders, [12] as is certainly the case in CBD.

Patients with CBD may have many clinical features that could contribute to a diagnosis of IMA. Corticobasal syndrome (CBS), which is defined as a syndrome that has the movement disorder features of CBD but with more cognitive and perceptual abnormalities, may be more com-

monly related to apraxia [13]. CBD (or CBS) can only be confirmed upon post-mortem examination of the brain, revealing the presence of tau + tangles, which correlate with the clinical difficulties. Post-mortem findings show that the clinical CBD syndrome is often misdiagnosed as AD, PSP, Pick’s disease, nonspecific degenerative changes, or Creutzfeldt–Jakob disease, even in patients who have apraxia, which is sometimes thought to be a hallmark of CBD [14]. Many investigators only study IMA in cases of relatively focal stroke and avoid the confounds of degenerative cases, in which the lesions are likely more widespread and present with complex pathologies, unless adequately evaluated before testing [3–6,15].

4. Testing for IMA

There is little consensus on the proper way to test for IMA. As a result, reports may refer to “apraxia” without details of the testing strategy, which makes interpretation of the findings difficult. This issue directly relates to the definition of apraxia. The traditional definition is one of a disorder of learned, skilled movements. However, what the “disorder” looks like is debatable. Differences in distinguishing and testing the nature of the deficit arise from distinctions between recognition or imitation, single object use tests and multiple object use tests, pantomime only deficits and real-life scenario deficits [16]. Additionally, when testing for IMA is done carefully, a patient may have multiple apraxias, which may present problems in interpreting the findings.

Many tests have been developed to characterize IMA. While the tests meet the goal of capturing the most sensitive deficits, they have become highly selective. This is justifiable, but not entirely appropriate, as further research shows that multiple deficits can occur in IMA. Testing should be done bilaterally, if possible, as apraxia can affect both limbs equally. In the event of a paretic limb, however, testing may be done in the nonparetic (usually ipsilesional) limb. Many studies rely on this standard [3,5,10].

Of the many tests used, two are particularly common. The Test of Oral and Limb Apraxia (TOLA) is used [4], but is incomplete because it ignores performance when the patient sees or uses tools. While the Florida Apraxia Battery is also used [17,18], it only assesses gestures to verbal command. The scores of four different apraxia batteries were poorly correlated, indicating that they all tested different features of the deficit [19]. Apparently, investigators cannot entirely rely on the most apparent features, but must assess the broad spectrum of deficits occurring in patients with apraxia.

Assessing the activities of daily living is thought to be a good way to test patients, but it is unclear to what extent IMA affects such activities in each patient [19,20]. Analyzing the motion of patients as they make specified movements may be most reliable [21], because it clearly reveals different characteristics of spatial abnormalities in IMA, based on lesion location and clinical signs and symptoms [15]. In one study, testing of pantomime to verbal command, imitation,

performance upon seeing the tool, and performance with the tool showed high inter-rater reliability and may have accounted for other possible cognitive deficits, which could be useful [22], but the patient population was small.

An ideal assessment of IMA for tool-use movements should likely include at least the four factors related to IMA: pantomime to verbal command, imitation, performance upon seeing the tool, and performance with the tool. For gestures, testing should include pantomime, imitation, and performance in “real” situations (e.g., choosing to wave goodbye when presented with a scene prompting this particular action). Deficits in these actions are commonly seen in patients with apraxia. In addition, recognition and discrimination of correct pantomimes, performance of nonsense gestures, and tool selection tasks are all valuable. Demonstration of intact basic motor control should be an essential element of testing.

5. Lesions that produce IMA

5.1. Left vs. right hemisphere lesions

Continued debate concerns the precise cortical areas involved in apraxia. Early studies of IMA and lesion location suggested that subcortical damage to white matter tracts was most critical [7]. However, white matter lesions are not more common in IMA patients [23]. In fact, lesions in deeper brain areas (e.g., white matter, thalamus, and basal ganglia) are more common in nonapraxia groups. However, white matter damage found in several other studies shows that subcortical disconnection of the parietal and premotor areas may cause apraxia [9,10]. In addition, damage to cortical structures, particularly the angular gyrus or the supramarginal gyrus, has been observed in cases of apraxia [12]. Generally, in stroke patients, left hemisphere lesions of the parietal and premotor areas are implicated in apraxia. Anterior lesions may produce aphasia (e.g., ventrolateral premotor cortical lesions extending into Broca’s area) or paresis (e.g., SMA lesions extending to the adjacent motor cortex), which make the determination of IMA difficult or impossible. As well, anterior lesions may produce disturbances in postural and force control, while parietal lesions produce more severe deficits of cognitive motor behavior, which is more characteristic of IMA [24]. However, there are patients with IMA apparently caused by SMA damage [25]. Other patients have been reported to have IMA from lateral anterior frontal lesions [10]. While the extent of premotor lesion effects needs further study, it is clear that left-sided parietal lesions commonly produce bilateral deficits on pantomiming tool-use movements [26]. Because apraxia deficits are clearly caused by lesions in nonprimary motor areas, it is unlikely that the deficit is limited to execution only. There must be a relationship to not only planning and execution, but also the notion of the correct movement to make.

Lesions of the left hemisphere have been largely regarded as the main cause of apraxia, but the right hemisphere has also been implicated. In a study comparing left and right hemisphere-

damaged patients, patients with left hemisphere impairment performed worse on pantomime of tool-use, but there was no difference in deficits of gestures, indicating that both the left and right hemispheres may store gesture representations [27].

5.2. Basal ganglia lesions

Patients with basal ganglia lesions apparently may also have apraxia. Generally, the left basal ganglia is involved in control of spatial and temporal features of learned movements, sequence learning, and response inhibition [28,29]. A skilled, cognitively based movement (e.g., praxis) requires smooth timing of the movement elements for it to be correct [30,31]. Again, it is essential in any case of IMA that elemental motor problems do not confound otherwise normal praxis. Such deficits are commonly seen in patients with damage to the basal ganglia.

With the avoidance of the confounding elementary motor deficits, a diagnosis of IMA was made in patients with PD and PSP [3]. A case study concluded that both IMA and ideational apraxia were the result of basal ganglia damage in a patient with CBD [32]. However, CBD has widespread pathological effects that involve cortical structures. A patient with basal ganglia and external capsule lesions produced normal tool-use and communicative gestures on command and imitation, but had low scores in performing intended gestures appropriately based on the presented scenes [33]. While this is an expected deficit in apraxia, abnormally produced pantomimes have been long considered a hallmark of IMA. IMA is uncommon in HD when damage is limited to the basal ganglia, but is more likely to occur when the cortex or its interconnections are damaged [5].

It is still debated whether damage to the basal ganglia alone can result in IMA. Qualitative evidence suggests that there are apraxia patients with ischemic lesions of the left basal ganglia only. However, the types of errors differed from those in patients with cortical stroke [34]. In PD patients, dopaminergic medication does not improve the initial performance of an apraxic motor task (it does assist in incremental learning of a motor command over time) [35]. The conclusion of this work is that the basal ganglia themselves may not play a major role in the performance of praxis movements, but they may play a role in apraxia recovery. This highlights the importance of rigorous assessment and identification of specific features critical to the diagnosis of IMA. The clinical symptoms occurring with basal ganglia damage should be better evaluated. The mechanisms that might lead to apraxia in patients with basal ganglia lesions also need to be studied.

5.3. Callosal, cortical, and subcortical lesions

Other types of lesions have been reported to cause IMA, but they are not well studied. Callosal lesions were studied in patients with complete callosotomy by having them pantomime to visually presented objects [36]. The right (dominant) hand

performed correctly, but the left hand performed poorly, indicating that left hemisphere networks relevant for praxis may have limited control of the left hand. In a case study of a patient with a lesion of the trunk and splenium of the corpus callosum, apraxia was present with pantomime of object use, but not imitation [37]. Such lesions evidently interfere with the capacity of the left hand to retrieve the required representations from the left hemisphere to control praxis. However, it is likely that callosal patients with IMA will serve as an important study group to learn more about the information stored within the left and right hemispheres related to performance of pantomime and tool use (as will be discussed in the Rehabilitation of IMA patients section). In addition, cortical and subcortical lesions can cause ipsilateral IMA, such as in the case of sympathetic apraxia. This has been shown with a patient with right-sided hemiplegia and left-sided pantomiming deficits without comprehension difficulties [38].

6. Clinical and theoretical models of IMA

Consideration of how the deficit manifests itself from lesions in various locations has been of key interest to many researchers, because lesions at different cortical and subcortical processing levels may cause different deficits. Early models hypothesized that IMA results from damage to white matter tracts connecting higher level parietal areas, which formulated ideas of a task, with lower level motor areas, which executed the task [9]. This is the “disconnection” hypothesis [8], which emphasizes cortico-cortical projections as the main culprit. Evidence suggests that the left parietal cortex (specifically, the inferior parietal lobule) stores motor representations, or “engrams,” that, if damaged, would affect not only performance, but also recognition of pantomimes [39–44]. Damage to these engrams was initially thought to explain the deficit [45]. Clearly, not all apraxic patients have recognition deficits and white matter damage, so both hypotheses (IMA resulting from white matter lesions or particular parietal cortex lesions) can only be partially true.

A recent paper rejects the notion that failure of normal tool-use pantomime, most common in IMA, is representative of natural movement. Because tool-use pantomime is rarely done, the deficit may be most easily explained by the patient’s inability to create a new movement (tool-use pantomime) that represents a familiar (actual tool use) movement [33]. Thus, the patient would likely be impaired only on pantomime, while real object use is intact. To substantiate this, it is pointed out that posterior parietal lesions may impair the patient’s ability to position the hand to use objects in accordance with knowledge of stored motor representations, while grasping the objects and recognition of appropriate hand postures for new tools remains intact [46,47]. This further elaborates the role of the parietal cortex and apraxia to additionally involve degraded hand postures associated with familiar tools, and even global errors on reproduction of complex hand configurations [48].

It has been thought that damage to different brain areas may cause different types of apraxia [16], a concept coming mainly from the theoretical notion of hierarchical processing involved in apraxia (Fig. 1A). As input is delivered to prompt a particular movement, this information must be taken in and processed within a cortical network. Briefly, for tool-use pantomime, this involves identification of the movement and the knowledge of appropriate action based on prior experiences with the tool or object. Implementation of this knowledge into a motor formula representative of the intended action follows. Afterwards, the motor command should be correctly employed. Thus, damage to areas critical for abstract knowledge, which control appropriate actions in various situations (parietal cortex), may lead to conceptual or ideational apraxias. Damage to knowledge of action in the sensorimotor form (connections between parietal and premotor cortices), which would affect spatial and temporal processing, would lead to higher level production deficits, characteristic of IMA. Damage to purely motor mechanisms (motor cortex) would largely cause production deficits, such as limb-kinetic apraxia.

Computational modeling of the anatomical aspects of motor control has been proposed [49,50]. Modeling of the bread slicing gesture in patients in a parkinsonian network of reduced basal ganglia output revealed reduced spatial and temporal accuracy of the movement, characteristic of the deficit seen in IMA patients [51]. These findings could support the role of the basal ganglia in praxis and IMA. However, research has yet to firmly determine whether the form of IMA reported in basal ganglia lesion studies is typical, or what lesion profile could cause the deficit [21]. Modeling parietofrontal networks, including possible subcortical components, will also contribute to our understanding of the deficit.

7. Physiology of parietal, premotor, and subcortical structures

Much of the evidence for the physiological function of the parietal and premotor cortices comes from work in monkeys. Extrapolating this information to human behavior is not completely direct, as movement types and errors in IMA are largely impossible to replicate in monkeys. However, insight can be gained from these studies and hypotheses developed from the findings.

7.1. Parietal action coding

Intensive investigation of the posterior parietal cortex shows that it is involved in the preparation and execution of eye movement, reach, grasp, and hand position. Stimulation studies reveal that the ventral intraparietal area is involved in many types of complex movements [52]. This work relates to areas that are considered to be phylogenetically similar to those regions in humans that mediate praxis. Coding complex movements within these regions is of interest, even in

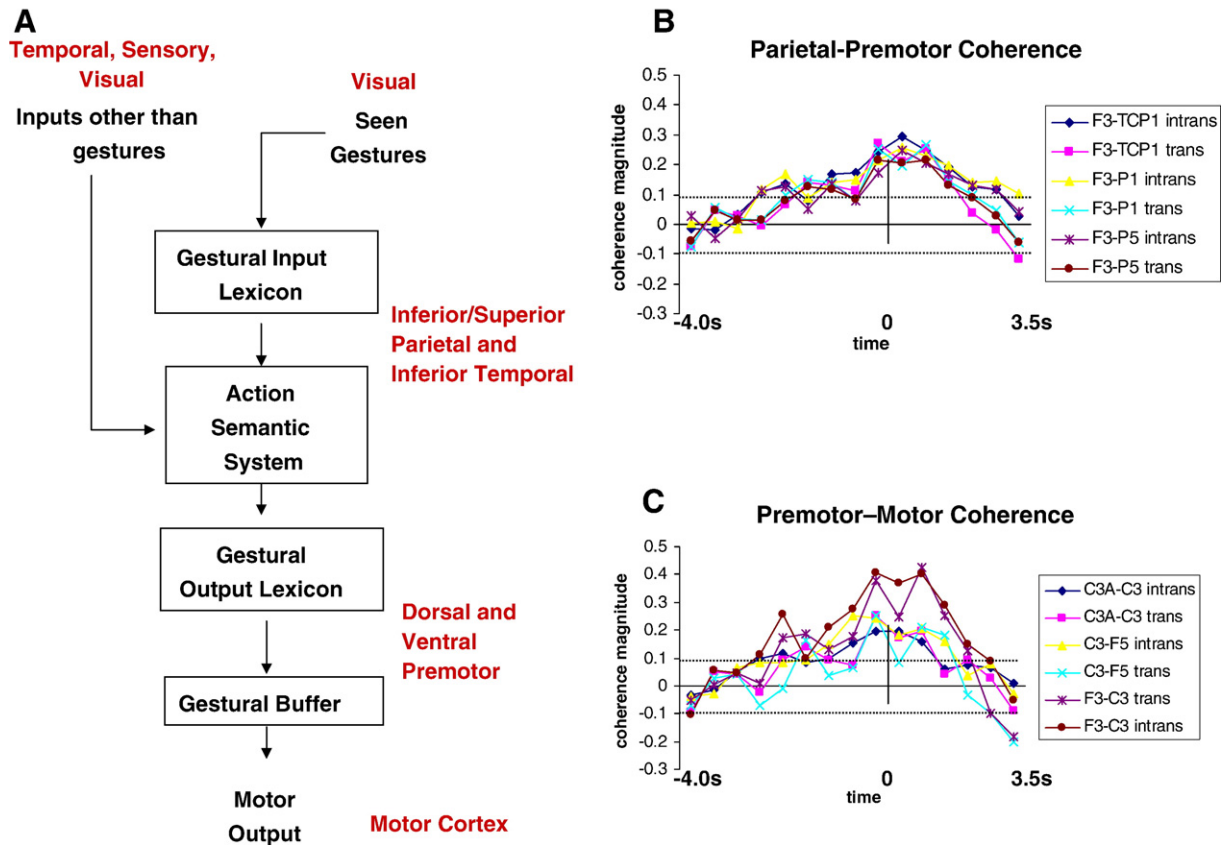


Fig. 1. (A) Hypothesized network involved in praxis, utilizing the left parietal, premotor, and motor cortices, with the brain areas that may correspond to that particular function (in red) (adapted, see [32]). (B and C) EEG coherence analysis of activity related to the preparation and execution of self-paced transitive and intransitive praxis in normal right-handed subjects, which verifies parts of the network shown in (A). Coherence increases are shown between electrodes over the left parietal and premotor electrodes (B) and the left premotor and motor electrodes (C). Time (s) is relative to the movement onset (0 s) (see [72]).

the midst of convincing evidence supporting the generation of complex movements from motor cortex stimulation alone [53]. However, these movements are not as complex as praxis movements. The medial intraparietal area has shown regions of activity that can be decoded to position a cursor in the direction of a movement before the movement begins [54], and this has direct application to the functioning of neuronal-based prosthetic devices [55]. If parietal activity can be decoded, the development of robotic prosthetic devices could be a possible rehabilitation strategy for patients with apraxia. Such premovement activity is similar to intention activity in the posterior parietal area [56].

7.2. Premotor action coding

Coding for complex action is also represented in the premotor cortex [44]. Divisions of the lateral premotor cortex have a role in movement planning. Specifically, the dorsal part of the lateral premotor cortex has much in common with the SMA in that they both project to the spinal cord and both are involved in motor control [57]. It is thought that the SMA together with its connection in the parietal lobe plays an important role in movement onset and specific sequences of multiple joint movements [58]. The

pre-SMA receives a modest connection from the parietal lobe. This area controls actions encoded in the lateral parietofrontal circuits, possibly through motivation or cognition [59–61]. Cells having connections from the parietal cortex to the caudal region of the dorsal premotor cortex (PMd) are more active during a limb movement task [62]. However, the rostral PMd seems to have more of a role in cognitive processes related to motor control [61].

7.3. Networks of parietal and premotor areas for praxis

Activities in different brain regions do not occur independently, but are part of networks. Thus, for pantomime of meaningful praxis movements, a functional network may include V5, the inferior parietal lobule and inferotemporal cortex, and the lateral premotor cortex. Involvement of the basal ganglia is also certainly possible, particularly because some connections of the parietal lobe to the premotor cortex pass through the basal ganglia [63–65]. Since the critical brain areas for apraxia (parietal lobe, basal ganglia, and premotor cortex) are anatomically distinct, one must consider how functional activity in separate areas influences activity in other regions. There is evidence for cortical processing (ventral or dorsal streams) and subcortical pathways in guiding goal-

directed behavior. While movements are made during visuomotor paradigms, it is conceivable that different brain networks are functioning, perhaps a temporal–striatal–premotor pathway initially when defining a motor command and a parietal–premotor pathway after learning has been established [66–68]. Subcortical structures are involved in the initial learning of motor actions compared with actual performance [69]. This suggests that if a task is over-learned (e.g., communicative gestures), a parietal–premotor network is active, whereas, if a novel tool-use pantomime is performed [29], the relevant pathway might be mediated by subcortical structures. This view is substantiated clinically by the finding that patients with CBD and basal ganglia lesions had no deficit in communicative gestures, but tool-use pantomime and meaningless gesture pantomime were impaired [70].

With regard to praxis performance, anatomical and physiological studies have substantiated the hypothesis that parietal and premotor areas are involved in praxis preparation and execution [71–73]. When subjects make these movements in a self-paced paradigm, EEG activity related to praxis movements is seen in the parietal cortex 3.0 s before movement onset [73,74]. Moreover, evidence suggests a coherent left hemisphere parietal–premotor–motor network engaged in self-paced praxis that is active before and during movement onset [75]. This evidence is in anatomical accord with cortical lesion data in apraxia patients, and suggests that praxis is not defined best by discrete areas of activation but rather by dynamic relationships across multiple areas. Not only activation, but also binding of the activity in these distinct cortical areas is imperative for proper execution of these motor commands. These studies also support the existing models of praxis performance (Fig. 1). While there is some disagreement on the specifics of the models, the core idea is that the parietal cortex stores the concept of the movements and the premotor cortex modifies the concept to a specific motor plan for motor cortex implementation. Therefore, there must be communication between each of these structures to successfully generate a plan for the movement. Existing studies in humans clearly show convincing anatomical correlates and functional coupling that match what has been proposed in models and in monkeys.

EEG studies point to the presence of early parietal activity that eventually spreads to the sensorimotor areas before praxis movements, which differs from the confined premotor and sensorimotor activity seen before simple movements [74]. In addition, fMRI evidence supports premovement posterior parietal activity extending to the anterior parietal cortex from planning to execution of praxis [72]. There is a critical need for more knowledge of the human physiological function of networks of parietal and premotor areas for praxis. The results will directly apply to patient care. One such aspect is the possible role of the mirror neuron framework for the disturbance of imitative motor behavior in apraxic patients.

Experimental and human studies have shown that parietal–premotor circuits are instrumental for vision-to-action translation and for observation–action matching. Whereas the pre-

motor cortex is generally involved in such tasks, the parietal cortex is specifically recruited when the motor behavior is object related [76]. Since damage of these areas is known to interfere with the pragmatic aspects of goal-oriented movements, disturbance of this capacity may provide interesting new approaches to the investigation of apraxia. Understanding behavioral effects and brain activations during observation and imitation in apraxic patients can help in understanding this process and improve therapy. It does appear that focusing rehabilitation to apraxic deficits can improve function [77].

8. Rehabilitation of IMA patients

IMA has historically been viewed as a deficit only manifested in clinical settings [78], but recent evidence has supported the notion that IMA affects daily living [79,80]. Such evidence is important, as it emphasizes the necessity of rehabilitation in patients with deficits in activities of daily living. The impact of cognitive disabilities, such as apraxia, is seen in attempts to rehabilitate stroke patients [81]. Deficits in IMA must be better evaluated so that the scope of necessary therapies can be completely defined. In addition, some subacute patients spontaneously recover from apraxia. Understanding this recovery process should be useful in understanding the relevant processes of brain plasticity. Unfortunately, there has been very little progress in this area.

While rehabilitation literature is scarce, several biological principles help to explain how recovery may occur. After left hemisphere lesions impair basic motor function, homologous right hemisphere structures begin to compensate over time [82]. Learning (or relearning) the playing of a stringed instrument leads to an experience-based reorganization of the left parietal and premotor cortices [83]. Activity related to spatial processing in a patient with a parietal lesion shifts from the left to right parietal lobe, suggesting plasticity of higher level processes as well [84]. Early evidence suggests that this may also be true for apraxia [85]. The mechanisms of this hemispheric shift of activity are unknown. One mechanism for re-establishing motor control in an impaired limb is the release of intracortical inhibition [86]. The premotor cortex of the lesioned hemisphere may reorganize to control movement in the event of cortical damage [87]. The question of whether these mechanisms can extend to include the parietal and premotor cortices for praxis should be investigated. If the left perilesional parietal cortex or the right parietal lobe stores copies of the engrams used to perform praxis, then it is possible to restore normal function. However, this speculation is criticized, as it has been suggested that the right hemisphere may not store praxis representations [88]. Work in patients with complete callosotomy shows apraxic errors only with the left hand (right hemisphere control) during pantomime of visually presented objects but not during actual object manipulation, suggesting right hemisphere indeed stores representations for movement concepts but has limited perceptual object representations [89]. However, it is additionally shown that split-

brain patients may imitate nonsense head–hand gestures correctly so long as visual feedback of the imitating hand is available, suggesting a heavy reliance of vision for proper gesture performance [90]. It is encouraging though, to consider that the right hemisphere may be able to utilize some limited representations that it stores to mediate praxis performance, and this might be helpful in recovery of function.

9. Linking physiology and pathophysiology

There is insufficient understanding of what lesions will produce precisely what deficits. Advances are now possible primarily due to the relatively recent emergence of data relating specific cortical areas to particular functions in monkeys [91,92]. It is difficult to properly assess normal function of the brain based on lesions and the resulting deficit [93]. This is even more difficult for apraxia, since there are variable manifestations from apparently similar lesions [10,94]. Progress should be possible by studying the physiology and active anatomical areas related to praxis movements in normal subjects. Investigators will then be able to form better hypotheses related to brain-damaged patients. In the clinic, we need an improved apraxia battery for comparison of normal subjects and patients, which should lead to clearer clinicoanatomical correlates. The efforts made so far indicate that the different facets of complex dysfunctions such as the apraxias may be better attributed to networks than to circumscribed modules.

Acknowledgments

The meeting which engendered this review, the International Workshop on Ideomotor Apraxia, held in Bethesda, Maryland, on September 20–22, 2004, was sponsored by the Office of Rare Diseases and the National Institute of Neurological Disorders and Stroke at the National Institutes of Health, and the Movement Disorder Society. The authors thank the following persons for their participation and for their insight during and after the meeting in the writing of this review: Richard Andersen, Stephan Bohlhalter, Laurel Buxbaum, Leonardo Cohen, Jose L. Contreras-Vidal, Hans Joachim Freund, Scott Grafton, Michael Graziano, Kathleen Haaland, Brenda Hanna-Pladdy, Edward B. Heaton, Kenneth Heilman, Anthony E. Lang, Ramon Leiguarda, Jay P. Mohr, Hiroshi Shibasaki, Angela Sirigu, Alan Sunderland, Ivan Toni, and Steven Wise.

We also thank Devera Schoenberg and B.J. Hesse for skillful editing.

References

- [1] Haaland KY, Flaherty D. The different types of limb apraxia errors made by patients with left vs. right hemisphere damage. *Brain Cogn* 1984;3:370–84.
- [2] Poizner H, Clark MA, Merians AS, Macauley B, Gonzalez Rothi LJ, Heilman KM. Joint coordination deficits in limb apraxia. *Brain* 1995;118:227–42.
- [3] Leiguarda RC, Pramstaller PP, Merello M, Starkstein S, Lees AJ, Marsden CD. Apraxia in Parkinson's disease, progressive supranuclear palsy, multiple system atrophy and neuroleptic-induced parkinsonism. *Brain* 1997;120:75–90.
- [4] Pharr V, Uttl B, Stark M, Litvan I, Fantie B, Grafman J. Comparison of apraxia in corticobasal degeneration and progressive supranuclear palsy. *Neurology* 2001;56:957–63.
- [5] Hamilton JM, Haaland KY, Adair JC, Brandt J. Ideomotor limb apraxia in Huntington's disease: implications for corticostriate involvement. *Neuropsychologia* 2003;41:614–21.
- [6] Parakh R, Roy E, Koo E, Black S. Pantomime and imitation of limb gestures in relation to the severity of Alzheimer's disease. *Brain Cogn* 2004;55:272–4.
- [7] Geschwind N. Disconnexion syndromes in animals and man. I. *Brain* 1965;88:237–94.
- [8] Geschwind N. Disconnexion syndromes in animals and man. II. *Brain* 1965;88:585–644.
- [9] Kertesz A, Ferro JM. Lesion size and location in ideomotor apraxia. *Brain* 1984;107:921–33.
- [10] Haaland KY, Harrington DL, Knight RT. Neural representations of skilled movement. *Brain* 2000;123:2306–13.
- [11] Donkervoort M, Dekker J, van den Ende E, Stehmann-Saris JC, Deelman BG. Prevalence of apraxia among patients with a first left hemisphere stroke in rehabilitation centres and nursing homes. *Clin Rehabil* 2000;14:130–6.
- [12] Heilman KM, Gonzalez Rothi LJ. Apraxia. In: Heilman KM, Valenstein E, editors. *Clinical Neurophysiology*. 4 ed. New York: Oxford University Press; 2003. p. 215–35.
- [13] Lang AE. Corticobasal degeneration: selected developments. *Mov Disord* 2003;18(Suppl 6):S51–6.
- [14] Boeve BF, Maraganore DM, Parisi JE, Ahlskog JE, Graff-Radford N, Caselli, et al. Pathologic heterogeneity in clinically diagnosed corticobasal degeneration. *Neurology* 1999;53:795–800.
- [15] Leiguarda R, Merello M, Balej J, Starkstein S, Noguez M, Marsden CD. Disruption of spatial organization and interjoint coordination in Parkinson's disease, progressive supranuclear palsy, and multiple system atrophy. *Mov Disord* 2000;15:627–40.
- [16] Buxbaum LJ. Ideomotor apraxia: a call to action. *Neurocase* 2001;7:445–58.
- [17] Hanna-Pladdy B, Daniels SK, Fieselmann MA, Thompson K, Vasterling JJ, Heilman KM, Foundas AL. Praxis lateralization: errors in right and left hemisphere stroke. *Cortex* 2001;37:219–30.
- [18] Rothi LJ, Raymer AM, Maher L, Greenwald M, Morris M. Assessment of naming failures in neurological communication disorders. *Clin Commun Disord* 1991;1:7–20.
- [19] Butler JA. How comparable are tests of apraxia? *Clin Rehabil* 2002;16:389–98.
- [20] van Heugten CM, Dekker J, Deelman BG, Stehmann-Saris JC, Kinebanian A. Rehabilitation of stroke patients with apraxia: the role of additional cognitive and motor impairments. *Disabil Rehabil* 2000;22:547–54.
- [21] Elble RJ. Motion analysis to the rescue? *Mov Disord* 2000;15:595–7.
- [22] Zwinkels A, Geusgens C, van de Sande P, Van Heugten C. Assessment of apraxia: inter-rater reliability of a new apraxia test, association between apraxia and other cognitive deficits and prevalence of apraxia in a rehabilitation setting. *Clin Rehabil* 2004;18:819–27.
- [23] Basso A, Luzzatti C, Spinnler H. Is ideomotor apraxia the outcome of damage to well-defined regions of the left hemisphere? Neuropsychological study of CAT correlation. *J Neurol Neurosurg Psychiatry* 1980;43:118–26.
- [24] Freund HJ. Clinical aspects of premotor function. *Behav Brain Res* 1985;18:187–91.
- [25] Watson RT, Fleet WS, Gonzalez-Rothi L, Heilman KM. Apraxia and the supplementary motor area. *Arch Neurol* 1986;43:787–92.
- [26] Halsband U, Schmitt J, Weyers M, Binkofski F, Grutzner G, Freund HJ. Recognition and imitation of pantomimed motor acts after unilateral parietal and premotor lesions: a perspective on apraxia. *Neuropsychologia* 2001;39:200–16.

- [27] Roy EA, Heath M, Westwood D, Schweizer TA, Dixon MJ, Black SE, et al. Task demands and limb apraxia in stroke. *Brain Cogn* 2000;44:253–79.
- [28] Boyd LA, Winstein CJ. Impact of explicit information on implicit motor-sequence learning following middle cerebral artery stroke. *Phys Ther* 2003;83:976–89.
- [29] Seiss E, Praamstra P. The basal ganglia and inhibitory mechanisms in response selection: evidence from subliminal priming of motor responses in Parkinson's disease. *Brain* 2004;127:330–9.
- [30] Harrington DL, Haaland KY. Sequencing and timing operations of the basal ganglia. In: Rosenbaum DA, Collyer CE, editors. *Timing of Behavior: Neural, Psychological and Computational Perspectives*. Cambridge: MIT Press; 1998. p. 35–61.
- [31] Harrington DL, Haaland KY, Hermanowicz N. Temporal processing in the basal ganglia. *Neuropsychology* 1998;12:3–12.
- [32] Chainay H, Humphreys GW. Ideomotor and ideational apraxia in corticobasal degeneration: a case study. *Neurocase* 2003;9:177–86.
- [33] Bartolo A, Cubelli R, Della Sala S, Drei S. Pantomimes are special gestures which rely on working memory. *Brain Cogn* 2003;53:483–94.
- [34] Hanna-Pladdy B, Heilman KM, Foundas AL. Cortical and subcortical contributions to ideomotor apraxia: analysis of task demands and error types. *Brain* 2001;124:2513–27.
- [35] Hanna-Pladdy B, Heilman KM. The role of dopamine in motor learning. Thirteenth Annual International Neuropsychological Society Conference, 2002. Toronto, Canada. Cambridge University Press; 2002. p. 204.
- [36] Lausberg H, Kita S, Zaidel E, Ptito A. Split-brain patients neglect left personal space during right-handed gestures. *Neuropsychologia* 2003;41:1317–29.
- [37] Goldenberg G, Laimgruber K, Hermsdorfer J. Imitation of gestures by disconnected hemispheres. *Neuropsychologia* 2001;39:1432–43.
- [38] Geschwind N. Sympathetic dyspraxia. *Trans Am Neurol Assoc* 1963;88:219–20.
- [39] Kalaska JF, Scott SH, Cisek P, Sergio LE. Cortical control of reaching movements. *Curr Opin Neurobiol* 1997;7:849–59.
- [40] Kertzman C, Schwarz U, Zeffiro TA, Hallett M. The role of posterior parietal cortex in visually guided reaching movements in humans. *Exp Brain Res* 1997;114:170–83.
- [41] Moll J, De Oliveira-Souza R, De Souza-Lima F, Andreiuolo PA. Activation of left intraparietal sulcus using a fMRI conceptual praxis paradigm. *Arq Neuropsiquiatr* 1998;56:808–11.
- [42] Moll J, de Oliveira-Souza R, Passman LJ, Cunha FC, Souza-Lima F, Andreiuolo PA. Functional MRI correlates of real and imagined tool-use pantomimes. *Neurology* 2000;54:1331–6.
- [43] Rizzolatti G, Fogassi L, Gallese V. Parietal cortex: from sight to action. *Curr Opin Neurobiol* 1997;7:562–7.
- [44] Rushworth MF, Johansen-Berg H, Gobel SM, Devlin JT. The left parietal and premotor cortices: motor attention and selection. *Neuroimage* 2003;20(Suppl 1):S89–S100.
- [45] Heilman KM, Rothi LJ, Valenstein E. Two forms of ideomotor apraxia. *Neurology* 1982;32:342–6.
- [46] Buxbaum LJ, Sirigu A, Schwartz MF, Klatzky R. Cognitive representations of hand posture in ideomotor apraxia. *Neuropsychologia* 2003;41:1091–113.
- [47] Sirigu A, Cohen L, Duhamel JR, Pillon B, Dubois B, Agid Y. A selective impairment of hand posture for object utilization in apraxia. *Cortex* 1995;31:41–55.
- [48] Sunderland A, Sluman SM. Ideomotor apraxia, visuomotor control and the explicit representation of posture. *Neuropsychologia* 2000;38:923–34.
- [49] Burnod Y, Baraduc P, Battaglia-Mayer A, Guigon E, Koechlin E, Ferraina S, et al. Parieto-frontal coding of reaching: an integrated framework. *Exp Brain Res* 1999;129:325–46.
- [50] Contreras-Vidal JL, Kerick SE. Independent component analysis of dynamic brain responses during visuomotor adaptation. *Neuroimage* 2004;21:936–45.
- [51] Contreras-Vidal JL. Computer modeling in basal ganglia disorders. In: Litvan I, editor. *Atypical Parkinsonian Disorders: Clinical and Research Aspects*. Totowa: Humana Press; 2004. p. 95–108.
- [52] Cooke DF, Taylor CS, Moore T, Graziano MS. Complex movements evoked by microstimulation of the ventral intraparietal area. *Proc Natl Acad Sci U S A* 2003;100:6163–8.
- [53] Graziano MS, Taylor CS, Moore T, Cooke DF. The cortical control of movement revisited. *Neuron* 2002;36:349–62.
- [54] Musallam S, Corneil BD, Greger B, Scherberger H, Andersen RA. Cognitive control signals for neural prosthetics. *Science* 2004;305:258–62.
- [55] Andersen RA, Burdick JW, Musallam S, Pesaran B, Cham JG. Cognitive neural prosthetics. *Trends Cogn Sci* 2004;8:486–93.
- [56] Andersen RA, Buneo CA. Intentional maps in posterior parietal cortex. *Annu Rev Neurosci* 2002;25:189–220.
- [57] Geyer S, Matelli M, Luppino G, Zilles K. Functional neuroanatomy of the primate isocortical motor system. *Anat Embryol (Berl)* 2000;202:443–74.
- [58] Tanji J, Shima K, Mushiaki H. Multiple cortical motor areas and temporal sequencing of movements. *Brain Res Cogn Brain Res* 1996;5:117–22.
- [59] Picard N, S.P. Imaging the premotor areas. *Curr Opin Neurobiol* 2001;11:663–72.
- [60] Rizzolatti G, Luppino G, Matelli M. The organization of the cortical motor system: new concepts. *Electroencephalogr Clin Neurophysiol* 1998;106:283–96.
- [61] Picard N, Strick PL. Imaging the premotor areas. *Curr Opin Neurobiol* 2001;11:663–72.
- [62] Boussaoud D. Attention versus intention in the primate premotor cortex. *Neuroimage* 2001;14:S40–5.
- [63] Petrides M, Pandya DN. Projections to the frontal cortex from the posterior parietal region in the rhesus monkey. *J Comp Neurol* 1984;228:105–16.
- [64] Glickstein M. Subcortical projections of the parietal lobes. *Adv Neurol* 2003;93:43–55.
- [65] Geyer S, Matelli M, Luppino G, Zilles K. Functional neuroanatomy of the primate isocortical motor system. *Anat Embryol (Berl)* 2000;202:443–74.
- [66] Toni I, Shah NJ, Fink GR, Thoenissen D, Passingham RE, Zilles K. Multiple movement representations in the human brain: an event-related fMRI study. *J Cogn Neurosci* 2002;14:769–84.
- [67] Thoenissen D, Zilles K, Toni I. Differential involvement of parietal and precentral regions in movement preparation and motor intention. *J Neurosci* 2002;22:9024–34.
- [68] Toni I, Rowe J, Stephan KE, Passingham RE. Changes of corticostriatal effective connectivity during visuomotor learning. *Cereb Cortex* 2002;12:1040–7.
- [69] Gerardin E, Sirigu A, Lehericy S, Poline JB, Gaymard B, Marsault C, et al. Partially overlapping neural networks for real and imagined hand movements. *Cereb Cortex* 2000;10:1093–104.
- [70] Salter JE, Roy EA, Black SE, Joshi A, Almeida Q. Gestural imitation and limb apraxia in corticobasal degeneration. *Brain Cogn* 2004;55:400–2.
- [71] Johnson-Frey SH, Newman-Norlund R, Grafton ST. A distributed left hemisphere network active during planning of everyday tool use skills. *Cereb Cortex* 2004;15:681–95.
- [72] Fridman E, Immisch I, Hanakawa T, Bohlhalter S, Waldvogel D, Kansaku K, et al. The role of the dorsal stream for gesture production. *Neuroimage* 2006;29:417–28.
- [73] Wheaton LA, Shibasaki H, Hallett M. Temporal activation pattern of parietal and premotor areas related to praxis movements. *Clin Neurophysiol* 2005;116:1201–12.
- [74] Wheaton LA, Yakota S, Hallett M. Posterior parietal negativity preceding self-paced praxis movements. *Exp Brain Res* 2005;163:535–9.
- [75] Wheaton LA, Nolte G, Bohlhalter S, Fridman E, Hallett M. Synchronization of parietal and premotor areas during preparation and execution of praxis hand movements. *Clin Neurophysiol* 2005;116:1382–90.
- [76] Buccino G, Vogt S, Ritzl A, Fink GR, Zilles K, Freund HJ, et al. Neural circuits underlying imitation learning of hand actions: an event-related fMRI study. *Neuron* 2004;42:323–34.

- [77] Smania N, Aglioti SM, Girardi F, Tinazzi M, Fiaschi A, Cosentino A, et al. Rehabilitation of limb apraxia improves daily life activities in patients with stroke. *Neurology* 2006;67:2050–2.
- [78] Liepmann H. Ein Fall von linksseitiger Agraphie und Apraxie bei rechtsseitiger Lahmung. *J Psychol Neurol* 1907;10:214–27.
- [79] Hanna-Pladdy B, Heilman KM, Foundas AL. Ecological implications of ideomotor apraxia: evidence from physical activities of daily living. *Neurology* 2003;60:487–90.
- [80] Foundas AL, Macauley BL, Raymer AM, Maher LM, Heilman KM, Gonzalez Rothi LJ. Ecological implications of limb apraxia: evidence from mealtime behavior. *J Int Neuropsychol Soc* 1995;1:62–6.
- [81] Walker CM, Sunderland A, Sharma J, Walker MF. The impact of cognitive impairment on upper body dressing difficulties after stroke: a video analysis of patterns of recovery. *J Neurol Neurosurg Psychiatry* 2004;75:43–8.
- [82] Luft AR, Waller S, Forrester L, Smith GV, Whittall J, Macko RF, et al. Lesion location alters brain activation in chronically impaired stroke survivors. *Neuroimage* 2004;21:924–35.
- [83] Kim DE, Shin MJ, Lee KM, Chu K, Woo SH, Kim YR, et al. Musical training-induced functional reorganization of the adult brain: functional magnetic resonance imaging and transcranial magnetic stimulation study on amateur string players. *Hum Brain Mapp* 2004;23:188.
- [84] Zacks JM, Michelon P, Vettel JM, Ojemann JG. Functional reorganization of spatial transformations after a parietal lesion. *Neurology* 2004;63:287–92.
- [85] Bohlhalter S, Fridman E, Wheaton L, Hattori N, Grafman J, Hallett M. Hemispheric lateralization of normal and impaired praxis movements: an event-related functional MRI study. *Mov Disord* 2005;20:S39.
- [86] Murase N, Duque J, Mazzocchio R, Cohen LG. Influence of interhemispheric interactions on motor function in chronic stroke. *Ann Neurol* 2004;55:400–9.
- [87] Fridman EA, Hanakawa T, Chung M, Hummel F, Leiguarda RC, Cohen LG. Reorganization of the human ipsilesional premotor cortex after stroke. *Brain* 2004;127:747–58.
- [88] Colvin MK, Handy TC, Gazzaniga MS. Hemispheric asymmetries in the parietal lobes. *Adv Neurol* 2003;93:321–34.
- [89] Lausberg H, Cruz RF, Kita S, Zaidel E, Ptito A. Pantomime to visual presentation of objects: left hand dyspraxia in patients with complete callosotomy. *Brain* 2003;126:343–60.
- [90] Lausberg H, Cruz RF. Hemispheric specialisation for imitation of hand-head positions and finger configurations: a controlled study in patients with complete callosotomy. *Neuropsychologia* 2004;42:320–34.
- [91] Rizzolatti G, Luppino G. The cortical motor system. *Neuron* 2001;31:889–901.
- [92] Fogassi L, Gallese V, Buccino G, Craighero L, Fadiga L, Rizzolatti G. Cortical mechanism for the visual guidance of hand grasping movements in the monkey: a reversible inactivation study. *Brain* 2001;124:571–86.
- [93] Rorden C, Karnath HO. Using human brain lesions to infer function: a relic from a past era in the fMRI age? *Nat Rev Neurosci* 2004;5:813–9.
- [94] Goldenberg G. Pantomime of object use: a challenge to cerebral localization of cognitive function. *Neuroimage* 2003;20:S101–6.