

Stroke

American Stroke
AssociationSM

JOURNAL OF THE AMERICAN HEART ASSOCIATION

A Division of American
Heart Association



Functional Imaging in Stroke Recovery Steven C. Cramer

Stroke 2004, 35:2695-2698: originally published online September 23, 2004
doi: 10.1161/01.STR.0000143326.36847.b0

Stroke is published by the American Heart Association, 7272 Greenville Avenue, Dallas, TX 75214
Copyright © 2004 American Heart Association. All rights reserved. Print ISSN: 0039-2499. Online
ISSN: 1524-4628

The online version of this article, along with updated information and services, is
located on the World Wide Web at:
http://stroke.ahajournals.org/content/35/11_suppl_1/2695

Subscriptions: Information about subscribing to *Stroke* is online at
<http://stroke.ahajournals.org/subscriptions/>

Permissions: Permissions & Rights Desk, Lippincott Williams & Wilkins, a division of Wolters
Kluwer Health, 351 West Camden Street, Baltimore, MD 21202-2436. Phone: 410-528-4050. Fax:
410-528-8550. E-mail:
journalpermissions@lww.com

Reprints: Information about reprints can be found online at
<http://www.lww.com/reprints>

Functional Imaging in Stroke Recovery

Steven C. Cramer, MD

Abstract—Assessing neurobiology of brain systems can provide information not available from anatomic or behavioral assessment. Such information may be of value in understanding, defining, and prescribing potential therapeutic interventions that target restorative brain events after stroke. A number of methods have been used to study stroke recovery, each with its relative merits and limitations. Several studies suggest that greater injury is associated with reduced laterality of brain activity. This might be in relation to changes in interhemispheric inhibition and is a phenomenon that is likely useful for functional gains in some patients. Many other features of brain activity change in the months after a stroke, including the site and size of activation in relevant brain network nodes. While there is incomplete agreement regarding which features of altered brain activity predict and parallel better behavioral outcome, studies converge on the conclusion that best outcome is achieved by activating the brain in a pattern that most resembles the normal state. (*Stroke*. 2004;35[suppl I]:2695-2698.)

Key Words: human brain mapping ■ plasticity ■ recovery of function ■ stroke

The changes that arise in the brain over the weeks after a stroke have been described at multiple levels. Cellular and molecular studies in animals undergoing an experimental unilateral infarct have characterized numerous bilateral events, but molecular data are often difficult to measure in human patients. At the other end of the spectrum, numerous studies have characterized the behavioral evolution after stroke. A wide range of brain events can produce the same behavioral phenotype, however. The best approach to treatment might arise from a more precise understanding of stroke physiology than is available from behavioral assessment. Functional imaging, between the molecular and behavioral levels, provides insights into brain changes at the systems level.

In some cases, functional imaging data provide biological insights when behavioral examination or anatomic brain imaging does not. For example, when neurological examination is normal, genetic risk for dementia is described by functional magnetic resonance imaging (fMRI) results.¹ The brain effects of HIV infection can be measured with fMRI even when behavioral examination is normal.² In patients with neurological deficits after traumatic brain injury and normal anatomic MRI scans, positron emission tomography (PET) scanning measures related changes in cortical function.³ When stroke renders a patient hemiplegic and examination is thus silent, fMRI permits measurement of activity across brain motor networks.⁴ Even in patients without a neurological diagnosis, functional brain imaging studies can measure differences in cognitive reserve.

Studies suggest that a number of therapeutic approaches to improving recovery are on the horizon, including cells, small molecules, growth factors, robotic interventions, and intensive physiotherapy. The details of therapeutic administration (How will therapy be administered? To which subgroups will therapy be administered? When will therapy be started, and for how long?) will

come from understanding the biological targets. Functional brain imaging after stroke has the potential to provide such data.

Key Questions Raised in Considering Functional Imaging of Stroke Recovery

Imaging brain function in the setting of stroke recovery raises certain questions: (1) Which features of brain function change after a stroke? (2) What is the relationship between stroke-related changes in brain function and behavioral outcome? These 2 questions are considered below, although precise answers require further study. (3) How might key functional imaging information from stroke patients be used to improve clinical outcome and reduce disability?

The third question seeks to extract key physiological data to improve clinical decision making and has precedence in medical practice. When a patient presents with a ventricular tachyarrhythmia or a refractory epileptic disorder, current practice often incorporates electrophysiological data to guide specific decisions in treatment. PET scanning of the brain is used to guide decision making in treatment of brain tumors and for surgical planning. Note that much of the enthusiasm for this goal is predicated on the assumption that interventions will be clearly identified that can improve patient outcomes.

Multiple Methods Used to Study Brain Function After Stroke

No single method is sufficient to measure all aspects of brain function; each has its relative advantages and limitations. Many studies use fMRI with blood oxygenation level-dependent contrast. This method has good temporal and excellent spatial resolution, and fMRI data can be acquired in

Received June 11, 2004; accepted August 5, 2004.

From the Department of Neurology and the Department of Anatomy and Neurobiology, University of California, Irvine.

Correspondence to Dr Steven C. Cramer, University of California Irvine Medical Center, 101 The City Dr S, Bldg 53, Room 203, Orange, CA 92868-4280. E-mail scramer@uci.edu

© 2004 American Heart Association, Inc.

Stroke is available at <http://www.strokeaha.org>

DOI: 10.1161/01.STR.0000143326.36847.b0

the same session as scans for brain anatomy, tractography, perfusion, injury, and spectroscopy. However, this method measures shifts in blood flow as they are linked to neuronal activity. Vascular pathology and altered cerebral blood flow might influence some findings, although we have found that stroke hemisphere cerebral blood flow can be reduced an average of 21% with no reduction in brain activation.⁵

PET scanning has limited temporal resolution, but spatial resolution has improved to be comparable to fMRI. Signal change with brain activation is typically 10-fold greater than with fMRI. Some PET scans measure flow and thus may share the perfusion-related concerns that are raised with fMRI in the setting of stroke. An advantage of PET scanning is the ability to measure tissue metabolism, viability of ischemic tissue, neurochemistry, and receptor kinetics.

Transcranial magnetic stimulation (TMS) provides insights into neurophysiology of the motor system, including conduction velocity, motor-evoked potentials, cortical inhibition, and cortical excitability. Although spatial resolution is limited, temporal resolution is at the millisecond level. The cost of setting up TMS and then studying patients is less expensive than the costs associated with fMRI and PET. TMS is also capable of producing a virtual lesion in nonmotor brain areas. TMS is generally used to study a limited portion of the brain, whereas fMRI and PET scanning generally study most or all of the brain at once.

Brain mapping methods such as electroencephalography, magnetoencephalography, near-infrared spectroscopy, and optical imaging have been used less frequently to date in the study of stroke recovery. These methods generally provide millisecond temporal resolution with somewhat limited spatial resolution.

A few studies have used multiple brain mapping modalities during patient examination. Such combinations can provide a powerful approach, for example, constraining neurophysiological measurements to specific brain areas that show task-related activation.

Factors Limiting the Current Understanding of Events Underlying Stroke Recovery

Many patterns of altered brain function have been described during the study of patients with stroke. The present review is not intended to be exhaustive. The reader is referred elsewhere for such treatments in the literature.⁶⁻⁸

Initial functional imaging studies were small and cross-sectional. Subsequent studies have examined stroke patient subpopulations, increased sample size, correlated features of brain activation with clinical measures, and monitored patients over time. These studies have provided insights into changes in the brain after stroke and have generated hypotheses for subsequent investigations. However, the overall understanding of changes in brain function after stroke, as well as the relationship between these changes and clinical measures, remains limited, in part because of the relative dearth of such investigations. However, 2 other factors limit the pace with which the literature clarifies the current understanding of poststroke restorative events in humans.

First, numerous covariates likely modify brain function after stroke (Table). Some of these are also important to the study of brain function in health, while others are important to the study of brain

Clinical Variables That Potentially Influence Stroke Recovery and Its Measurement by Functional Imaging

Stroke topography
Time after stroke
Age
Hemispheric dominance
Side of brain affected
Depression
Injury to other brain network nodes
Infarct volume
Initial stroke deficits
Arterial patency
Medical comorbidities
Prestroke disability
Prestroke experience and education
Type of poststroke therapy
Amount of poststroke therapy
Acute stroke interventions
Medications during stroke recovery period
Medications at time of brain mapping
Final clinical status
Stroke mechanism

function in the setting of acute stroke. Additional study is required to understand the effects and interactions arising from variables such as those listed in the Table.

A second issue complicating the field of functional imaging in stroke recovery is the divergence of investigative approaches and reporting. Small differences in attention or in the method used to activate the brain can have a major effect on findings. However, poststroke functional imaging studies rarely use identical brain activation methods. This is further complicated by variability in methods used to analyze, define the significance of, and report functional imaging results.

A related issue is the variability in clinical reporting methods for stroke recovery. This contrasts with research reports in multiple sclerosis, in which the Multiple Sclerosis Functional Composite is routinely included, and in spinal cord injury, in which the American Spinal Injury Association scores and Impairment Scale are routinely reported.

It is true that acute stroke studies have been somewhat consistent in incorporation of certain global stroke outcome scales, but stroke recovery studies will likely need system-specific scales for 2 reasons. First, for a compound to be effective in improving stroke recovery, abundant data suggest that it must be coupled with relevant experience. Restorative interventions will therefore likely focus on one or a few brain systems such as motor or language. Appropriate scales for each system are needed to detect treatment effects because global scales would not likely have adequate sensitivity. Second, functional imaging studies generally use a specific behavior to activate the brain and thus are also focused on specific brain systems. While specific approaches are sometimes needed to answer hypothesis-based research, it is also true that adoption of standardized approaches to some aspects of clinical assessment and functional

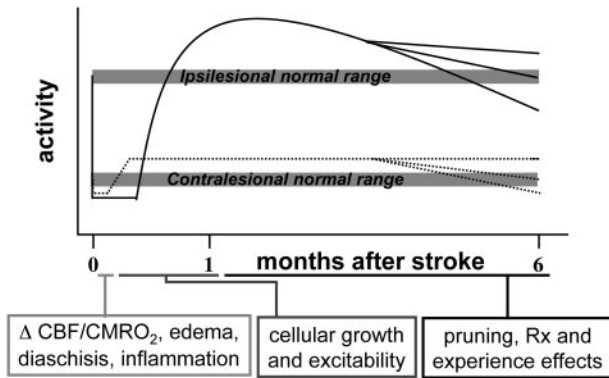


Figure 1. Changes in bilateral brain areas after unilateral stroke have been grouped into 3 time periods. First, in the initial hours/days after a stroke, brain function and behavior can be globally deranged, and few restorative structural changes have started. Second, a period of growth then begins, lasting several weeks. Structural and functional changes in the contralateral hemisphere precede those of the ipsilesional hemisphere, and at such times activity in relevant contralateral areas can even exceed activity in the lesion hemisphere. This growth-related period may be a key target for certain restorative therapies. Third, subsequently, there is pruning, reduction in functional overactivation, and establishment of a static pattern of brain activity and behavior. The final pattern may nevertheless remain accessible to plasticity-inducing, clinically meaningful interventions. An excess of growth followed by pruning has precedence in human neurobiology, being a recapitulation of normal developmental events. Supranormal and subnormal activity levels in the ipsilesional and contralateral hemispheres correlate with features of behavioral outcome in specific patient populations, as described above. CBF indicates cerebral blood flow; CMRO₂, cerebral metabolic rate of oxygen; and Rx, treatment.

imaging in stroke recovery might facilitate a broader understanding of the issues.

Changes in Brain Function Described After Stroke

Despite these factors, a number of findings emerge from an overview of functional imaging studies after stroke. The earliest finding, which has been replicated repeatedly, was a change in multiple nodes within relevant distributed networks. Clearly, ischemic injury to one area changes function in numerous connected brain regions.

One finding that might be of particular importance to understanding stroke recovery in humans is a reduction in the laterality of brain activity. Figure 1 presents a model that compiles some results from animal and human studies. This issue has also received considerable attention in the study of normal aging. Early reports emphasized a less lateralized pattern of activation after stroke than normal, ie, the effect of stroke is to increase the extent to which both hemispheres are recruited rather than just the contralateral hemisphere. Increasing evidence emphasizes the importance of measuring laterality across specific homologous brain areas, eg, changes in laterality of primary motor cortex may be most informative when measurements are restricted to this brain region rather than combined with premotor cortex.

A number of factors modify the extent to which stroke is associated with reduced laterality. Examples include time after stroke, injury to dominant versus nondominant hemisphere, and depth of injury. Other factors relevant to laterality

in normal subjects are also likely important after stroke, such as task complexity, age, task familiarity, proximal versus distal movement, and perhaps sex.

Several studies suggest that increased activity in the nonstroke hemisphere after stroke, ie, reduced laterality, reflects greater injury and/or deficits (Figure 2b). TMS studies have further suggested possible mechanisms for this finding. In primary motor cortex, stroke hemisphere inhibition on the nonstroke hemisphere is reduced, and nonstroke hemisphere inhibition on the stroke hemisphere is increased.

Reduced laterality might not merely reflect more severe stroke or passive changes in inhibition, however. Some studies suggest that changes in laterality of brain function might nonetheless be important to whatever behavioral recovery is achieved after stroke, even if the final behavior is subnormal.⁹ Indeed, a number of cases have been published in which brain activity is virtually restricted to the nonstroke hemisphere, contralateral to results in controls for motor tasks. Figure 2b provides an additional example.

Shifts in the site of activation have also been reported after stroke in all directions. The most common changes described in the motor system have been a ventral or a posterior shift in the contralateral (stroke hemisphere) activation site during task performance by the stroke-affected hand. Some data suggest that, at least for hand motor recovery, a ventral shift might be associated with better recovery of function. A posterior shift in activation site has been described in motor studies of stroke recovery across multiple imaging modalities and has also been described in the motor system of patients with multiple sclerosis or spinal cord injury, but its clinical significance remains to be defined.

Studies have described changes in activation size in many brain areas in the setting of stroke recovery. TMS studies converge on the conclusion that progressive expansion in the area of excitable primary motor cortex within the stroke hemisphere during the period of stroke recovery is a feature of patients with superior motor outcomes. In some serial functional imaging studies, the correlate of better clinical outcome has been increased activation in key stroke-hemisphere areas (Figure 2a), but in other studies, the correlate has been reduction in such activation. These differences across fMRI studies might arise from divergence in time after stroke at which investigations are performed, in the task used to activate the brain, in the patient populations enrolled, or in other variables. One unifying conclusion across these studies is that the best outcomes are associated with the greatest return to the normal state of brain function.

Indeed, when our laboratory applied the very same fMRI probe (tapping the affected index finger at 2 Hz across a 25-degree range of motion with eyes closed in a 1.5-T magnet), we found that, compared with age-matched controls, activation volume is decreased with stroke¹⁰ and increased with spinal cord injury.¹¹ Together, these observations suggest that a particular brain mapping method will have the best clinical validity when applied to a specific patient population.

Increased activity along the rim of a cortical infarct has been described in fMRI and PET studies. These observations might correspond to several physiological events or to the

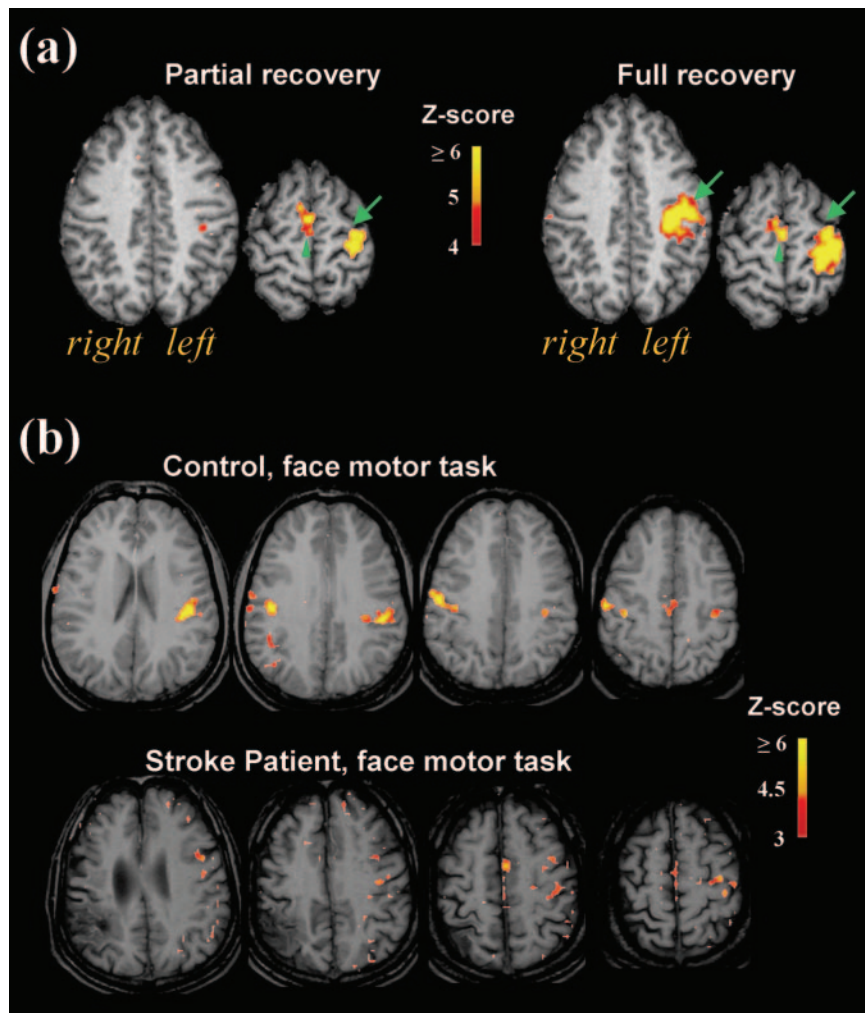


Figure 2. fMRI activation maps are superimposed on brain anatomy, with significance of activation indicated on the color bar. Images are in radiological convention. a, Activation volume in the stroke hemisphere during movement of a stroke-affected limb is related to degree of behavioral recovery. Patients with chronic stroke underwent fMRI scanning while alternating rest with tapping the index finger on the right, affected hand.¹⁰ Six patients had full recovery, and 5 had excellent but only partial motor recovery. Note that activation volume in the supplementary motor area (green arrowheads) was independent of degree of recovery. However, the patients with partial recovery showed activation volume in the left primary sensorimotor-premotor cortex (green arrows) that was 37% of the volume activated in patients with full recovery. Each pair of slices is at the level of Talairach $z=40$ and $z=57$. b, After stroke, activation can shift almost entirely to the nonstroke hemisphere, especially for larger strokes. Top row shows a control subject alternating rest with unilateral (right) contraction of the risorius, a lower face muscle. Activation is approximately equal in the right and left primary sensorimotor cortex. Bottom row shows a patient with a moderate to large infarct (70 cm^3) that destroyed 52% of the normal contralateral face motor representation. The patient alternated rest with unilateral (left) risorius contraction. Activation is almost entirely in the left (nonstroke) hemisphere, ipsilateral to movement. This change in brain activation pattern reflects greater injury but may nevertheless be important to maintenance of function.

increased levels of growth-related proteins measured along the rim of experimental infarcts introduced into animals.

Diaschisis may also be an important process related to behavioral recovery after stroke. Brain areas connected to, but spatially distant from, the region of infarction show numerous changes after stroke. For example, we found several patients with a behavioral deficit early after stroke associated with failure to activate the brain area underlying that behavior despite normal resting cerebral blood flow in the area and lack of injury to the area; behavioral recovery was associated with restitution of brain activity.¹² While numerous methods have been used to describe diaschisis, this process may be measured directly with the use of [^{18}F]fluorodeoxyglucose PET.

Summary

Functional imaging of stroke recovery is a unique source of information that might be useful in the development of restorative treatments. A number of features of brain function change after stroke. Current studies have defined many of the most common events. Key challenges for the future are to develop standardized approaches to help address certain questions, determine the psychometric qualities of these measures, and define the clinical utility of these methods.

References

- Bookheimer S, Strojwas M, Cohen M, Saunders A, Pericak-Vance M, Mazziotta J, Small G. Patterns of brain activation in people at risk for Alzheimer's disease. *N Engl J Med*. 2000;343:450–456.
- Ernst T, Chang L, Jovicich J, Ames N, Arnold S. Abnormal brain activation on functional MRI in cognitively asymptomatic HIV patients. *Neurology*. 2002;59:1343–1349.
- Fontaine A, Azouvi P, Remy P, Bussel B, Samson Y. Functional anatomy of neuropsychological deficits after severe traumatic brain injury. *Neurology*. 1999;53:1963–1968.
- Cramer S, Mark A, Barquist K, Nhan H, Stegbauer K, Price R, Bell K, Odderson I, Esselman P, Maravilla K. Motor cortex activation is preserved in patients with chronic hemiplegic stroke. *Ann Neurol*. 2002;52:607–616.
- Cramer S, Mark A, Maravilla K. Preserved cortical function with reduced cerebral blood flow after stroke. *Stroke*. 2002;33:418.
- Calautti C, Baron J. Functional neuroimaging studies of motor recovery after stroke in adults: a review. *Stroke*. 2003;34:1553–1566.
- Chen R, Cohen L, Hallett M. Nervous system reorganization following injury. *Neuroscience*. 2002;111:761–773.
- Rijntjes M, Weiller C. Recovery of motor and language abilities after stroke: the contribution of functional imaging. *Prog Neurobiol*. 2002;66:109–122.
- Johansen-Berg H, Rushworth M, Bogdanovic M, Kischka U, Wimalaratna S, Matthews P. The role of ipsilateral premotor cortex in hand movement after stroke. *Proc Natl Acad Sci U S A*. 2002;99:14518–14523.
- Zemke A, Heagerty P, Lee C, Cramer S. Motor cortex organization after stroke is related to side of stroke and level of recovery. *Stroke*. 2003;34:E23–E28.
- Cramer S, Fray E, Tievsky A, Parker R, Riskind P, Stein M, Wedeen V, Rosen B. Changes in motor cortex activation after recovery from spinal cord inflammation. *Mult Scler*. 2001;7:364–370.
- Nhan H, Barquist K, Bell K, Esselman P, Odderson I, Cramer S. Brain function early after stroke in relation to subsequent recovery. *J Cereb Blood Flow Metab*. 2004;24:756–763.