




RTG zubů a čelistí

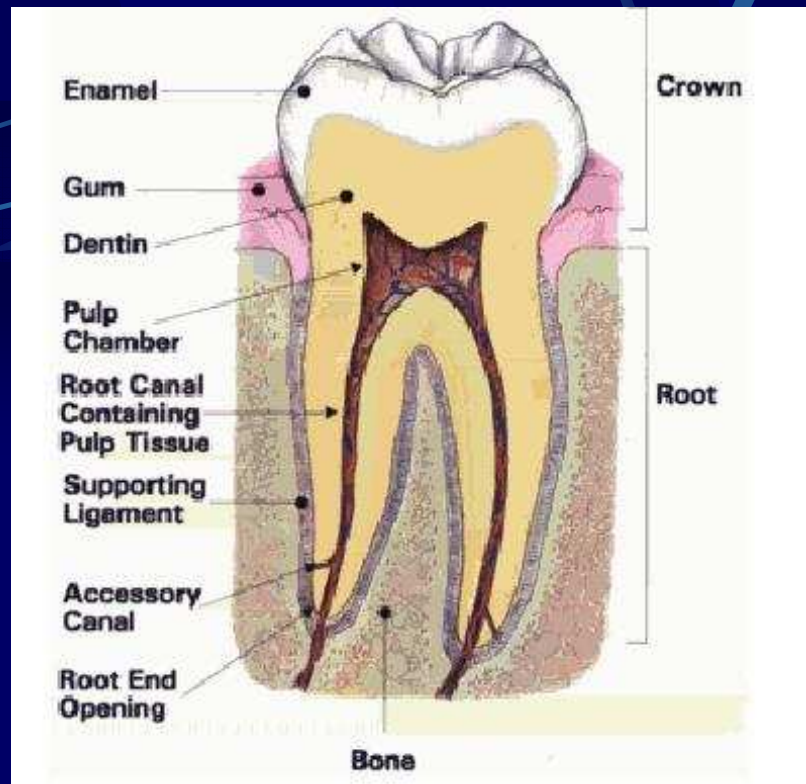
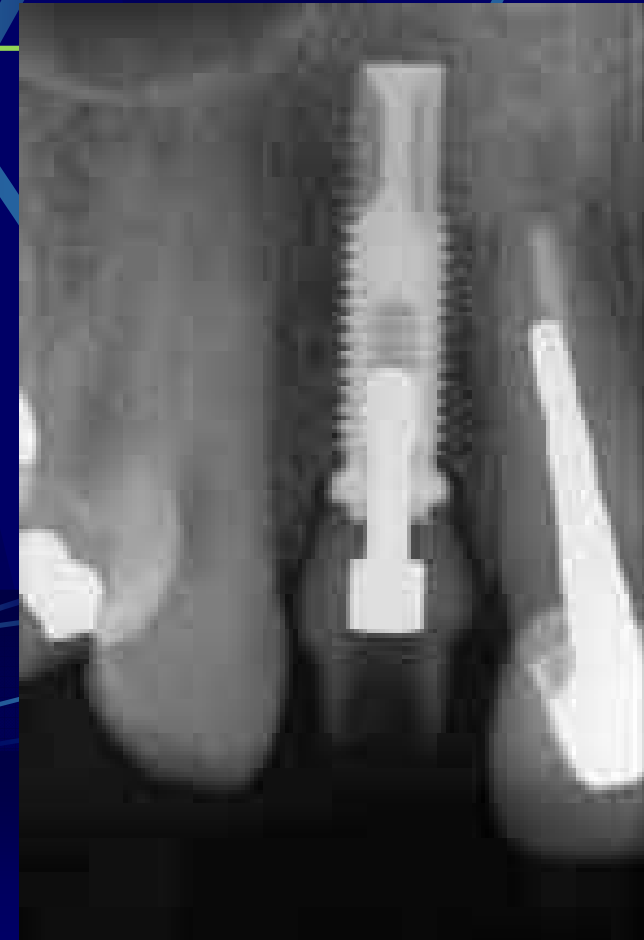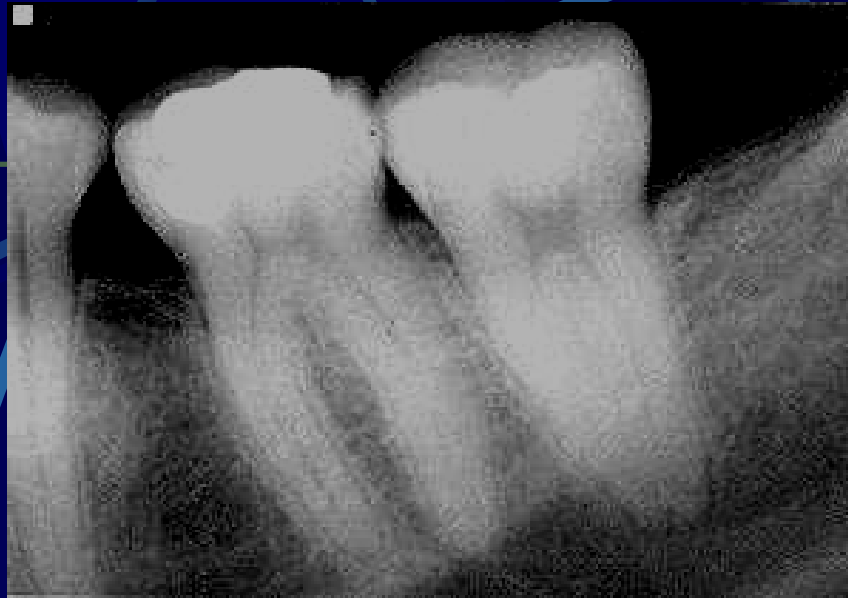Válek V. A.
Radiologická klinika LF, MOU Brno




Anatomie

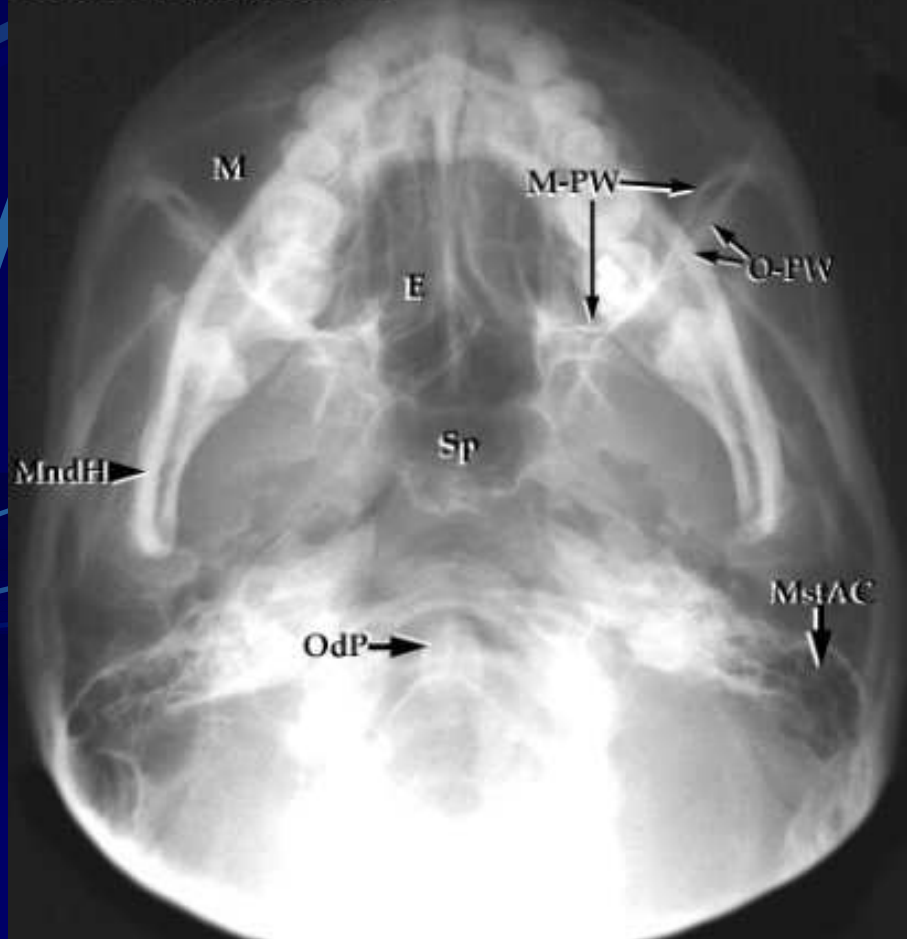


Anatomie

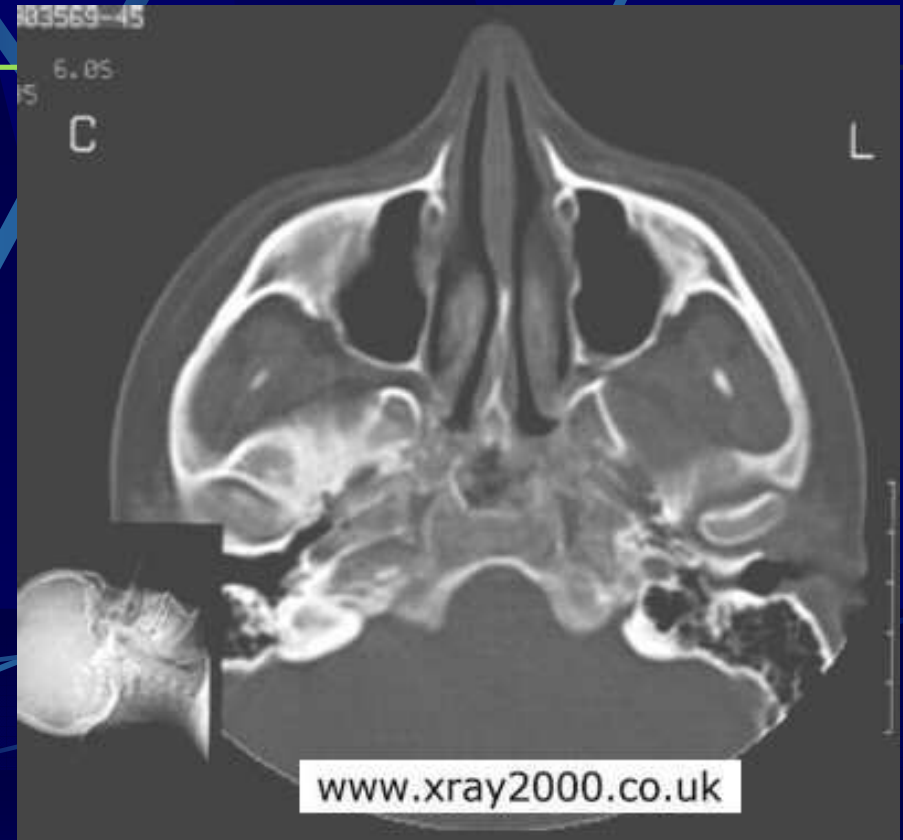




Base of the Skull

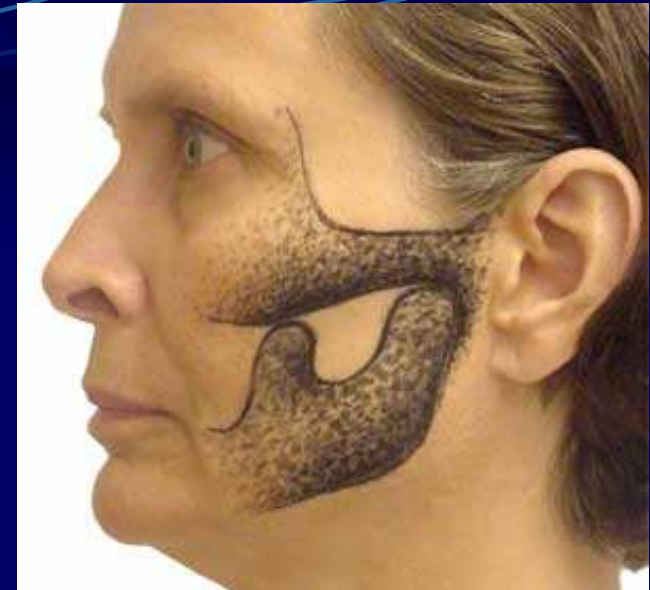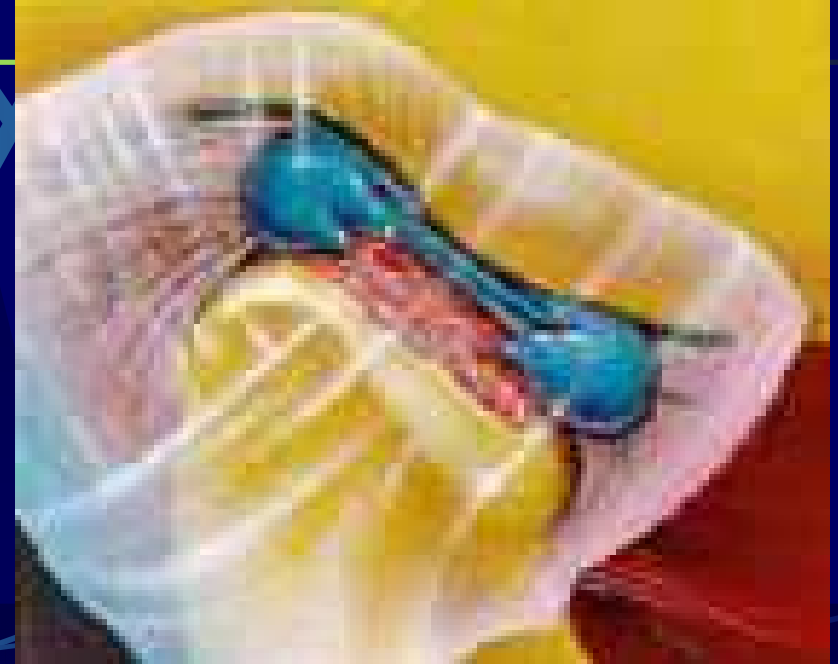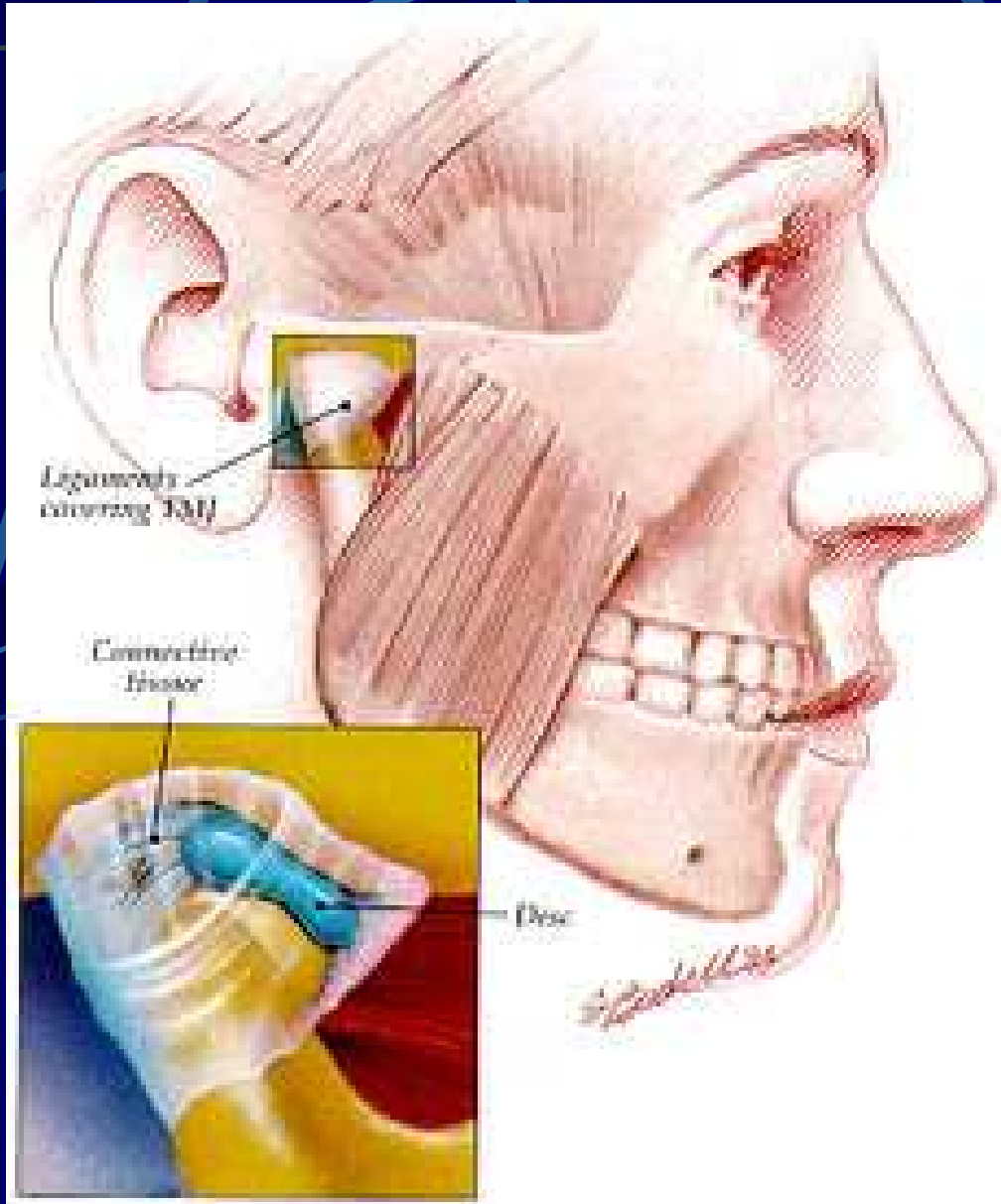


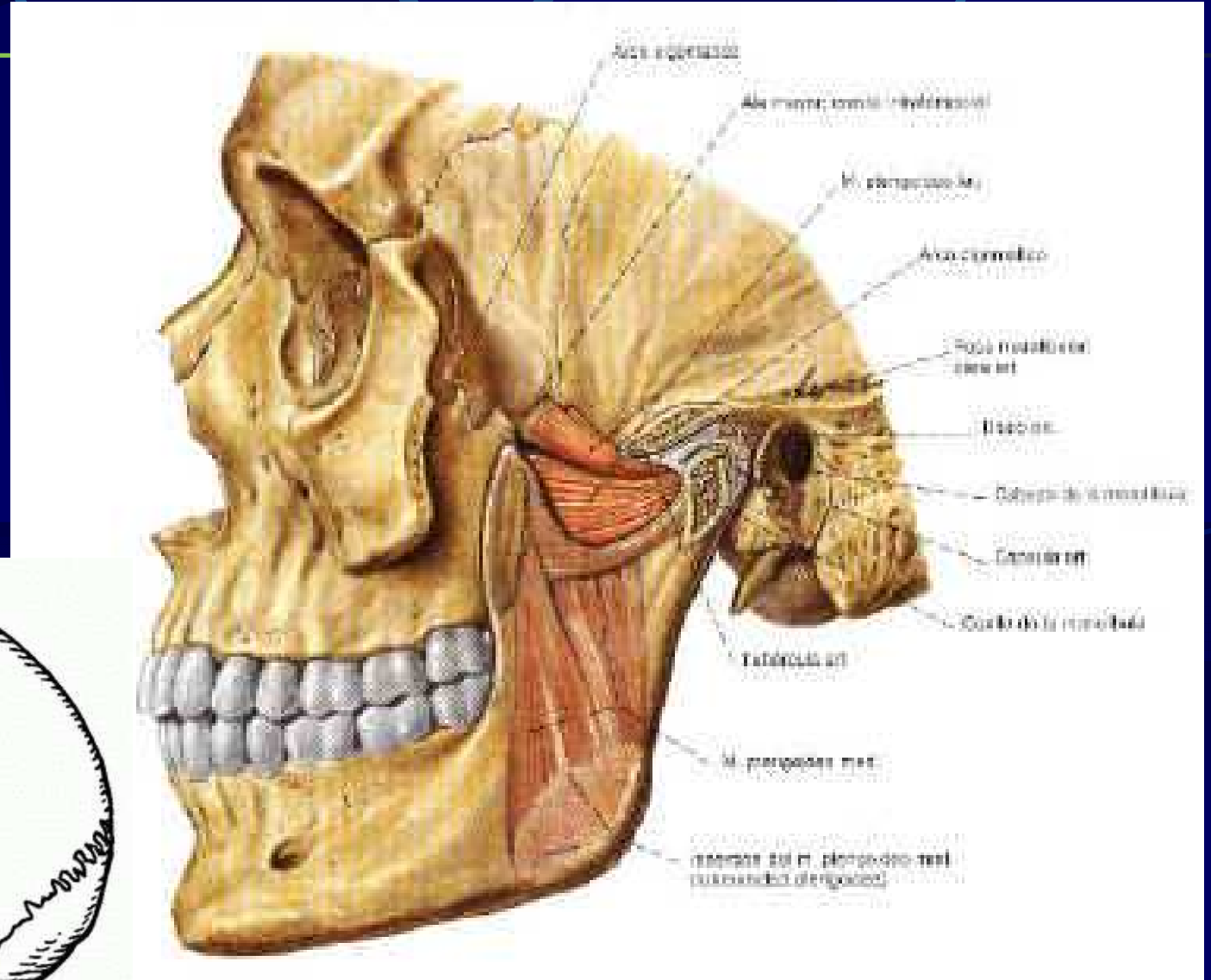
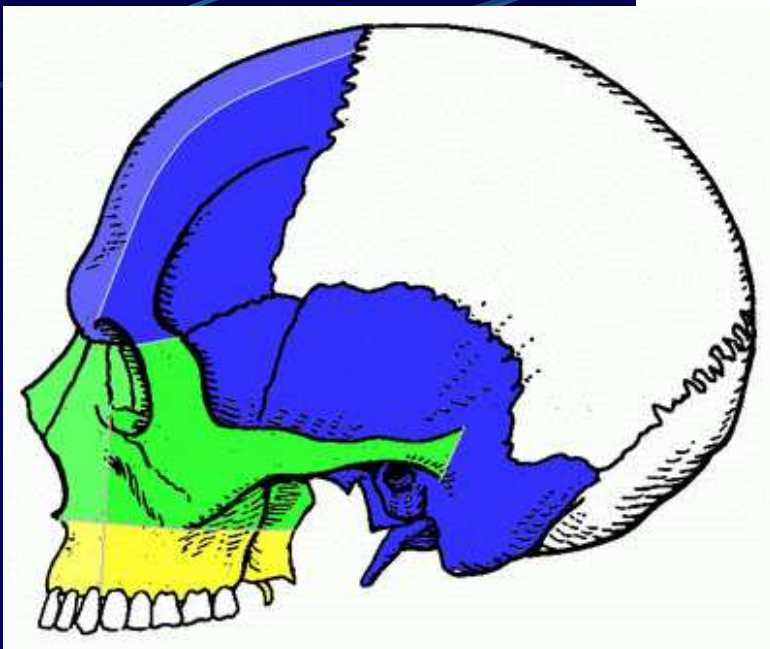

MstAC=Mastoid Air Cells	Sp=Sphenoid Sinus
E=Ethmoid Sinus (Air Cells)	M=Maxillary Sinus
O-PW=Posterior Wall of Orbit	MndH=Head of Mandible
M-PW=Posterior Wall of Maxillary Sinus	OdP=Odontoid Process



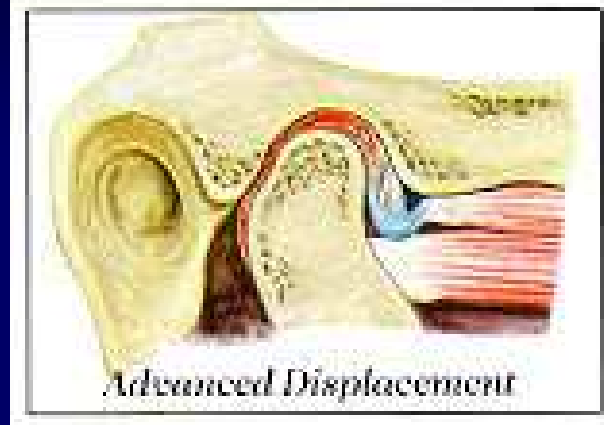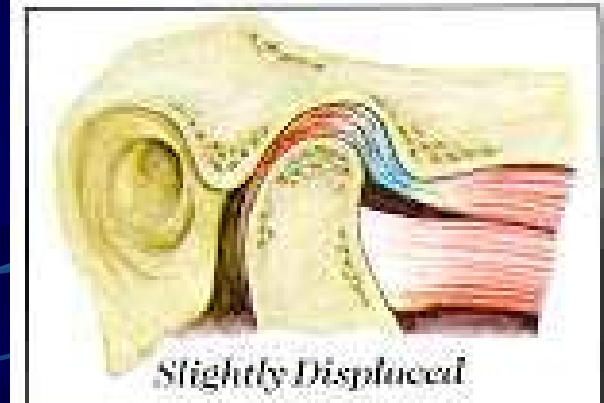
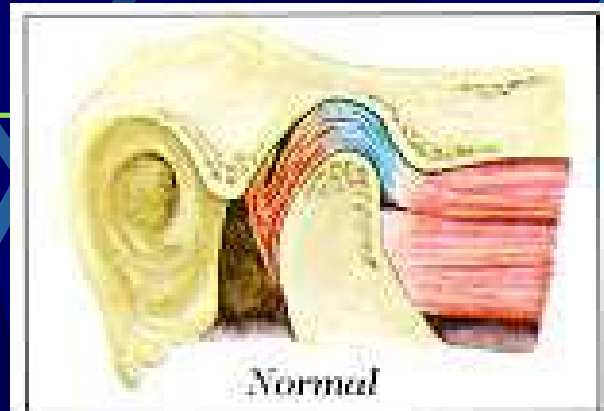



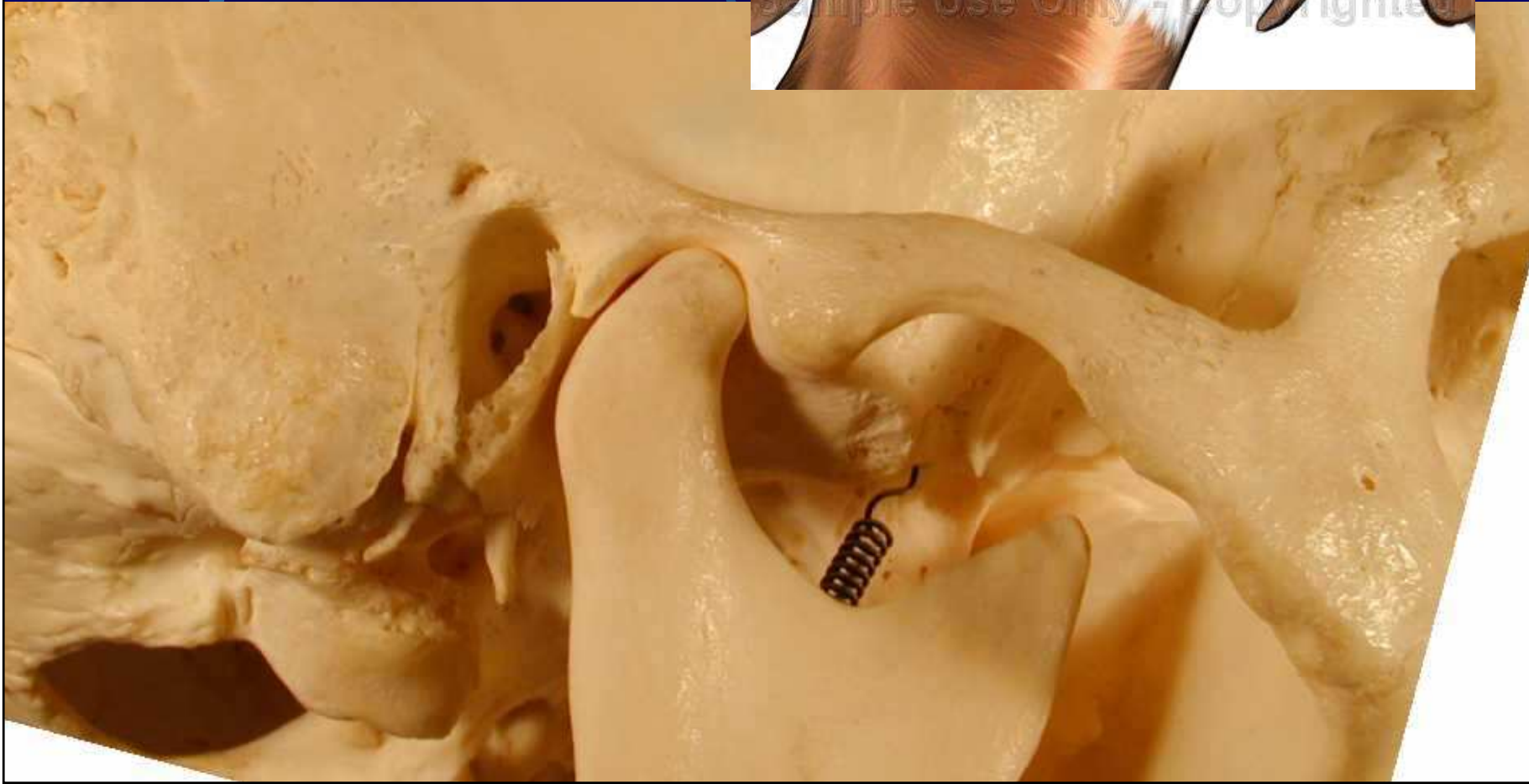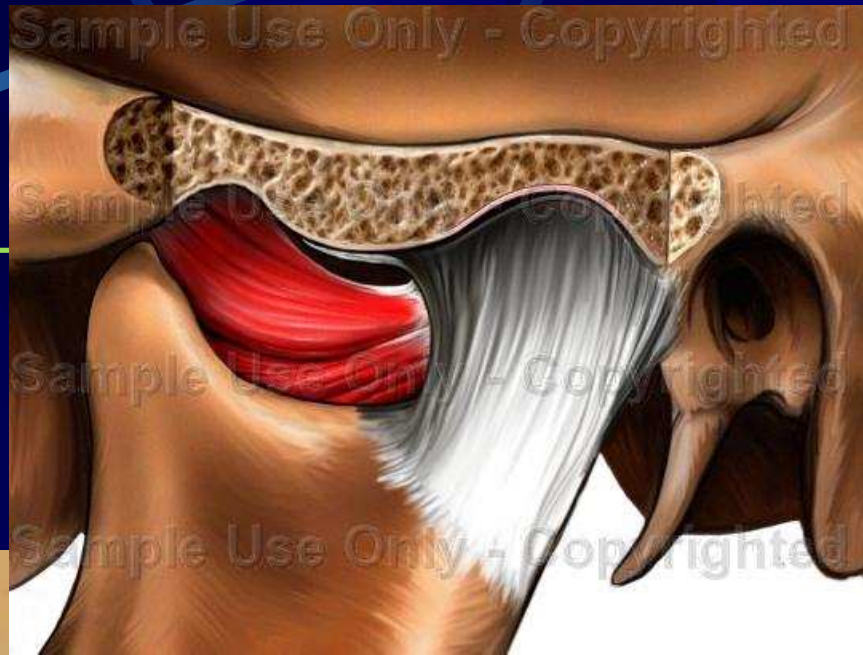
Anatomie



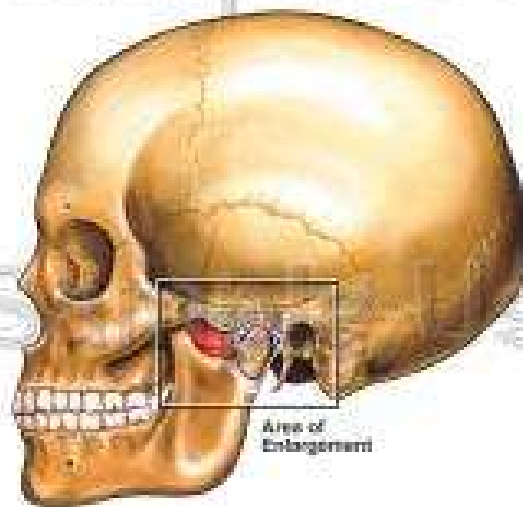


Anatomie





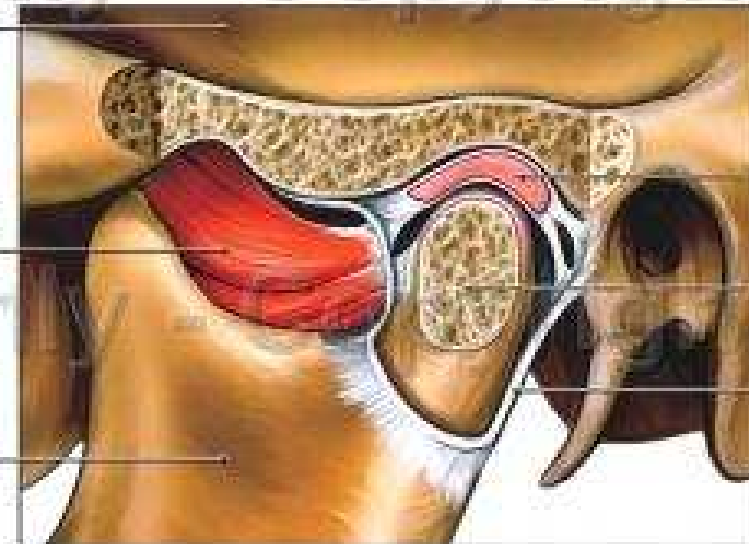
Anterior Displacement of the Left Temporomandibular Joint (TMJ)



Temporal bone

Pterygoid muscle

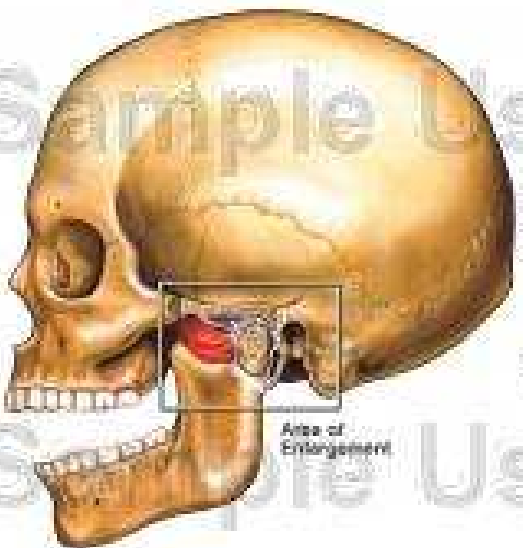
Mandible



Meniscus

Condyle

Joint capsule

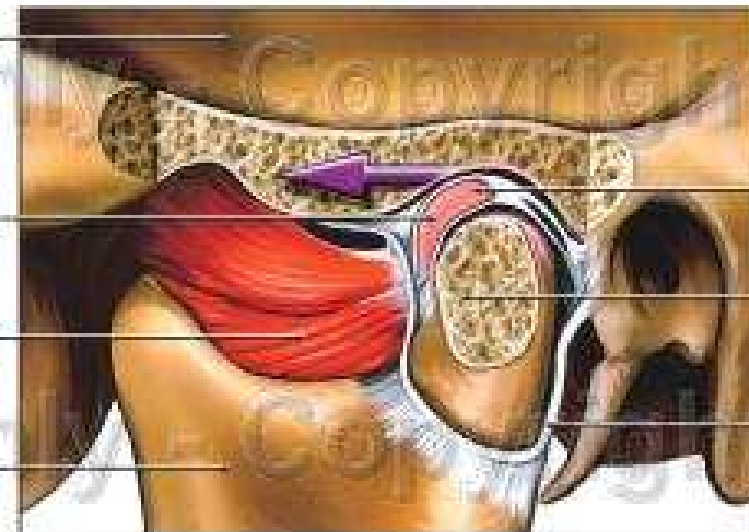


Temporal bone

Anterior displacement of TMJ meniscus

Pterygoid muscle

Mandible




Meniscus

Condyle

Joint capsule

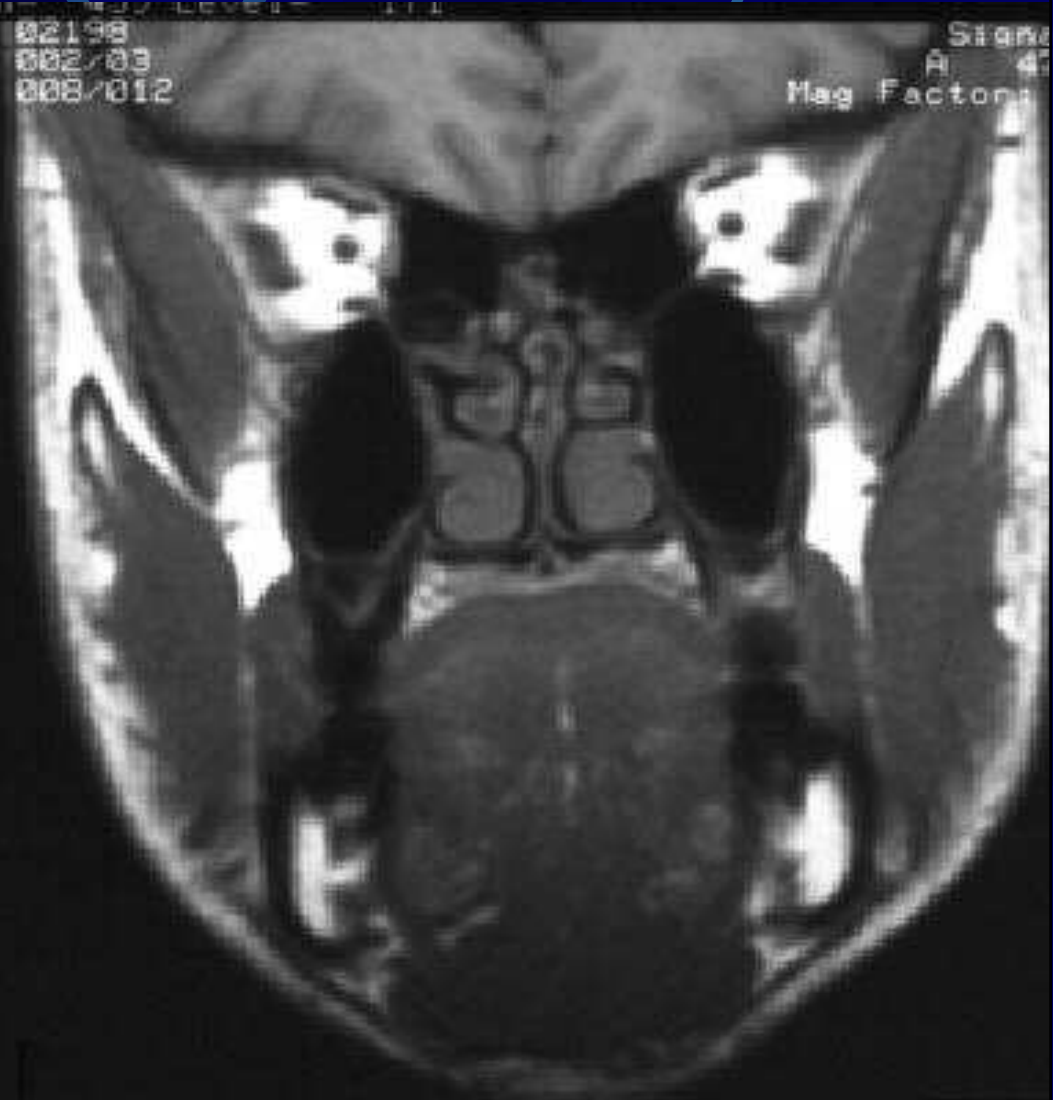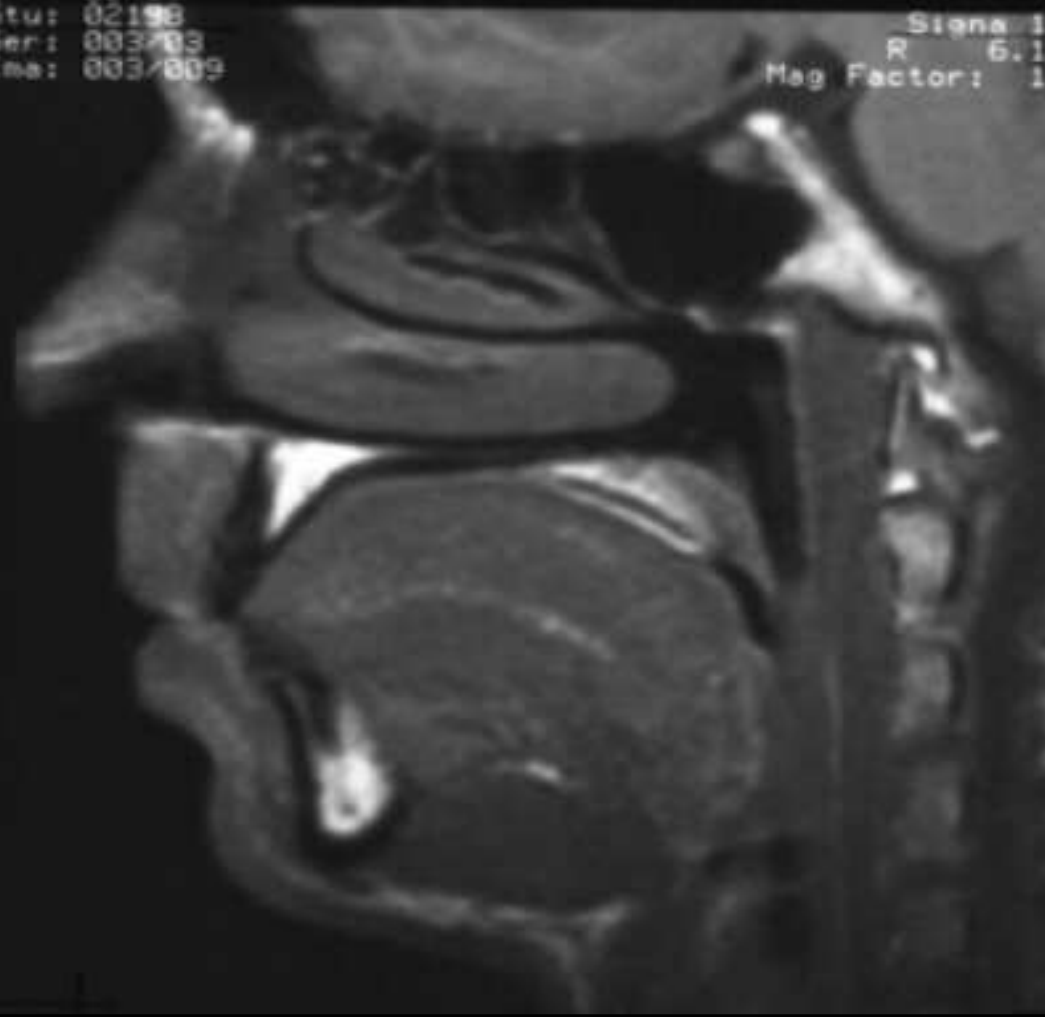


Anatomie



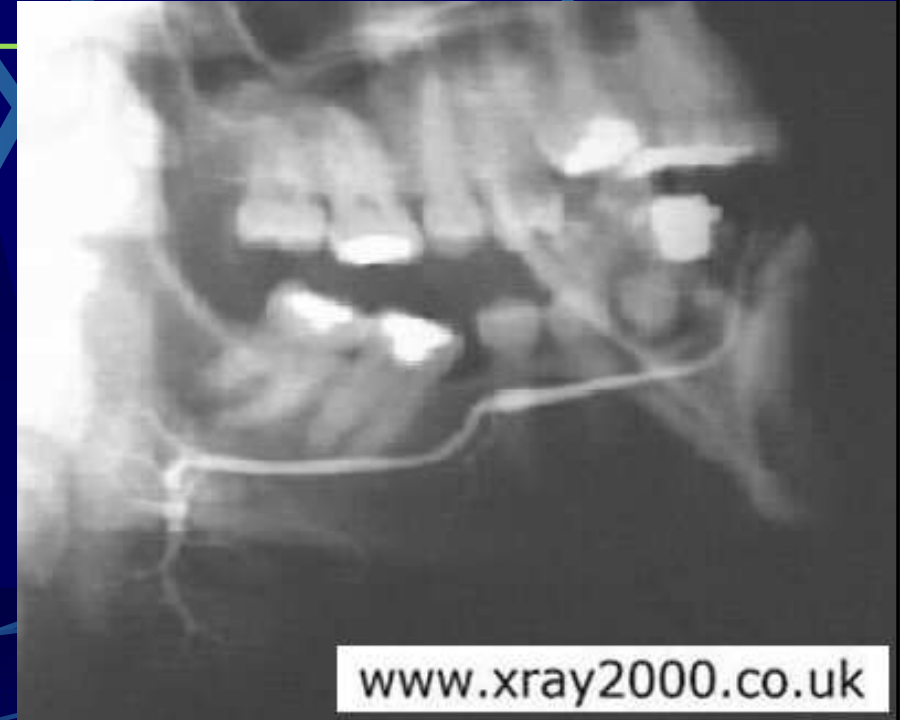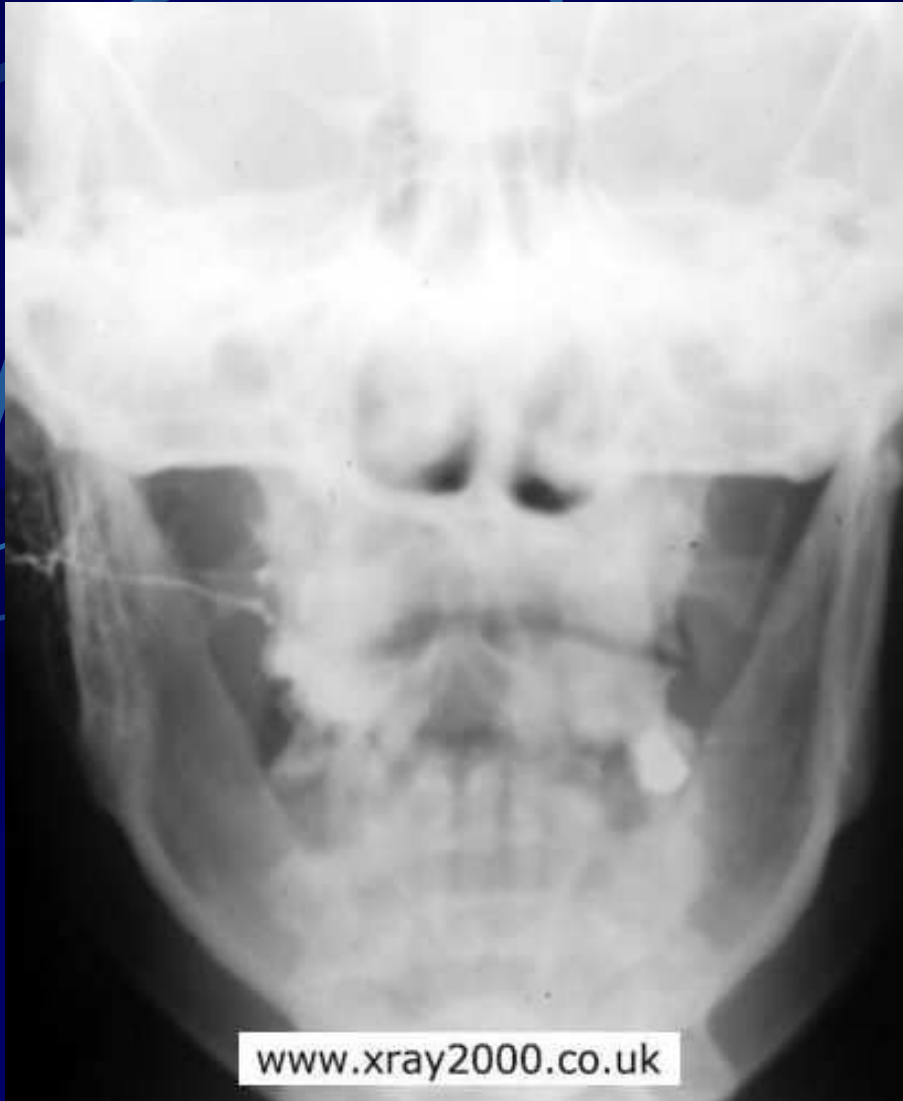tu: 02198
er: 003/03
na: 003/009

Signa: 1
R: 6.1
Mag Factor: 1



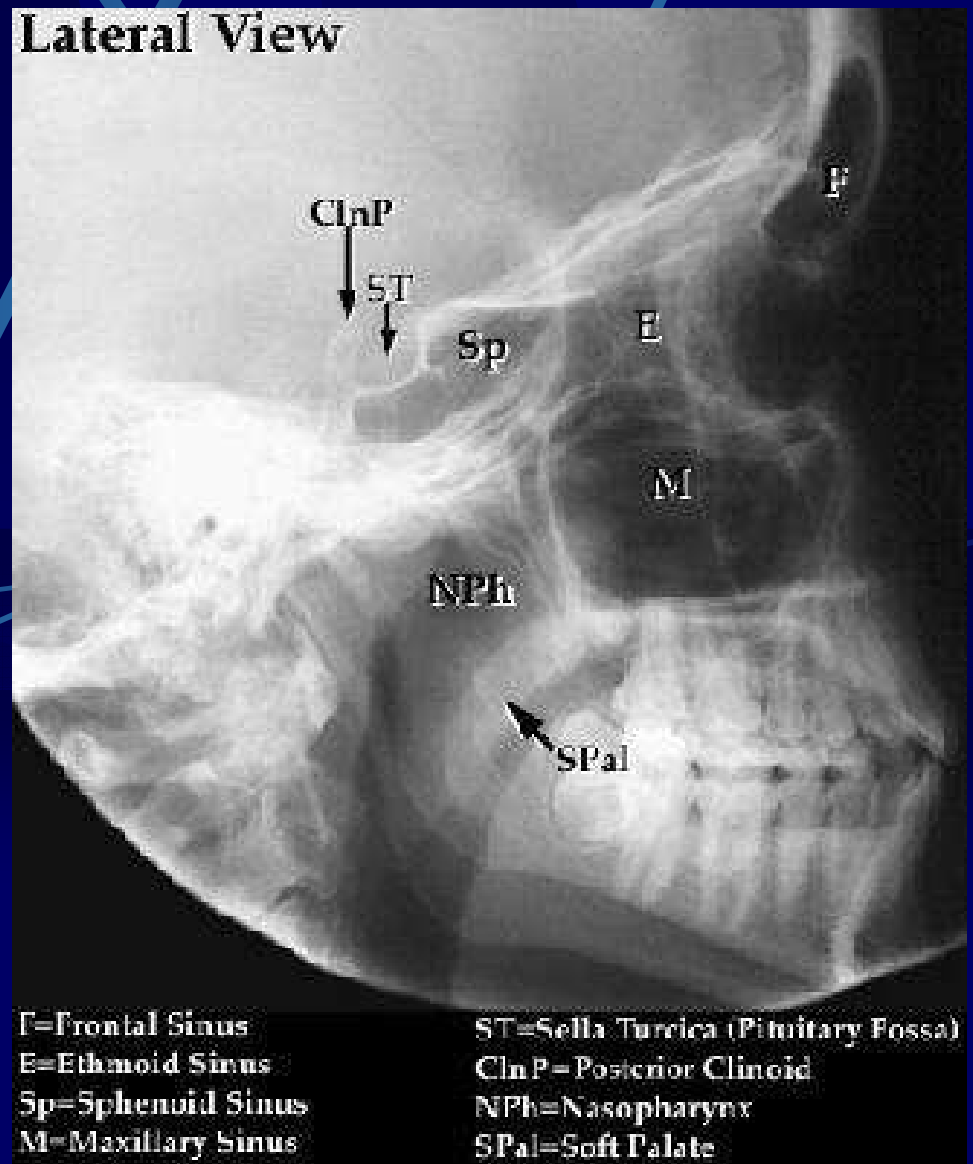
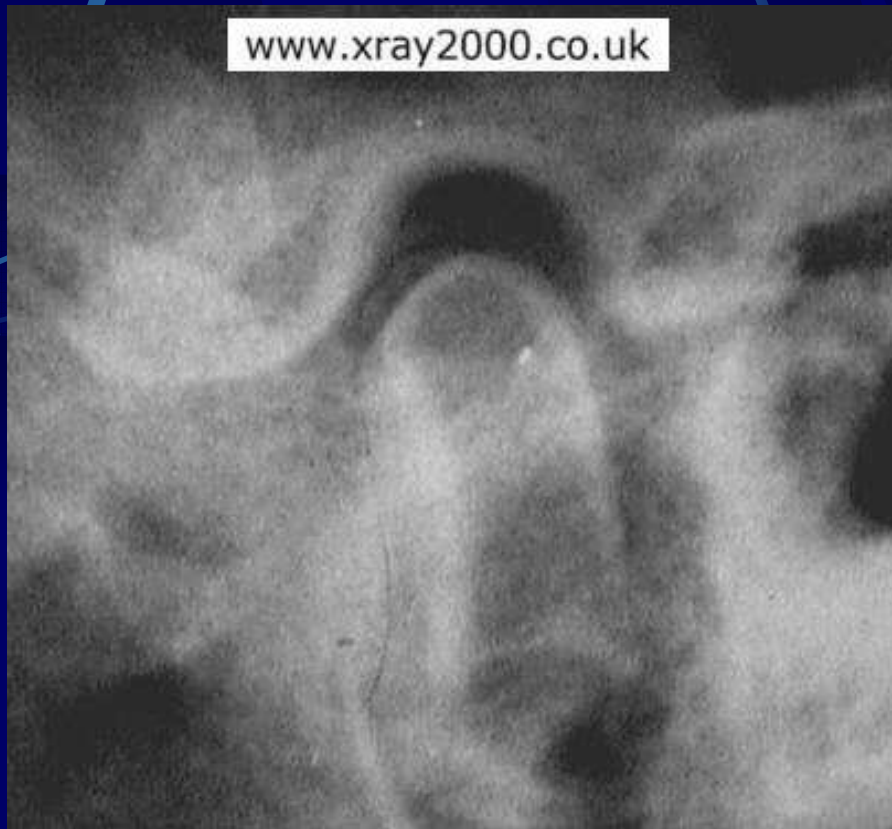


Anatomie





Anatomie

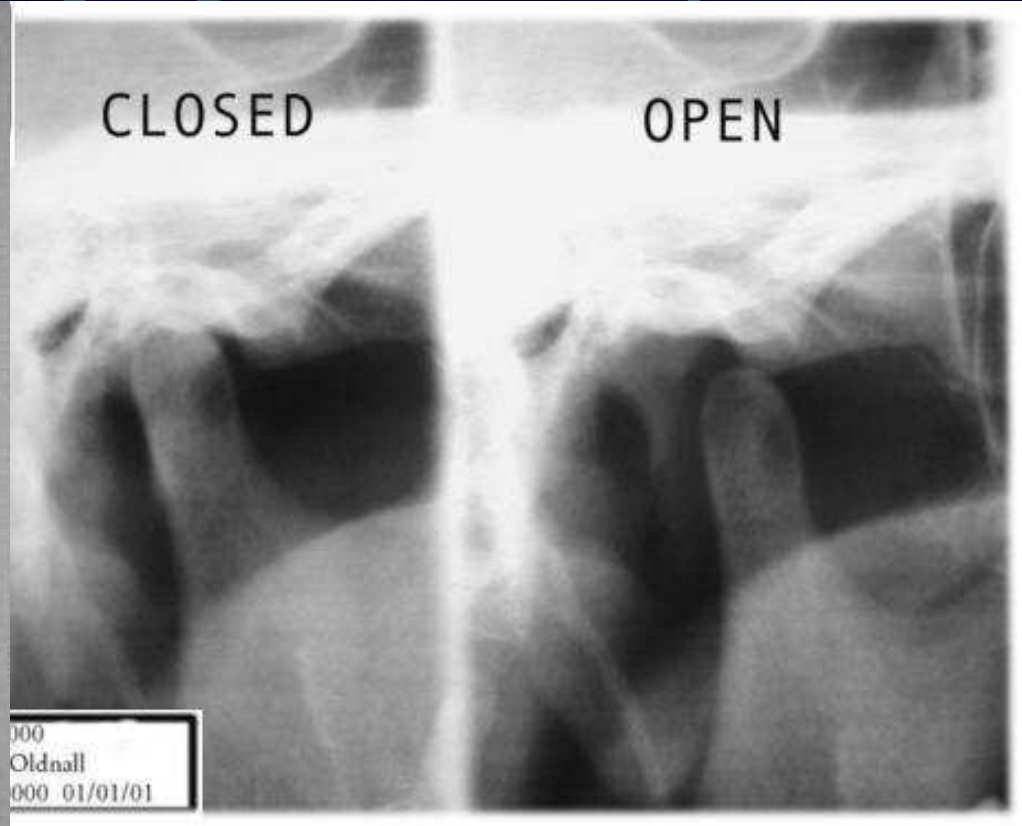
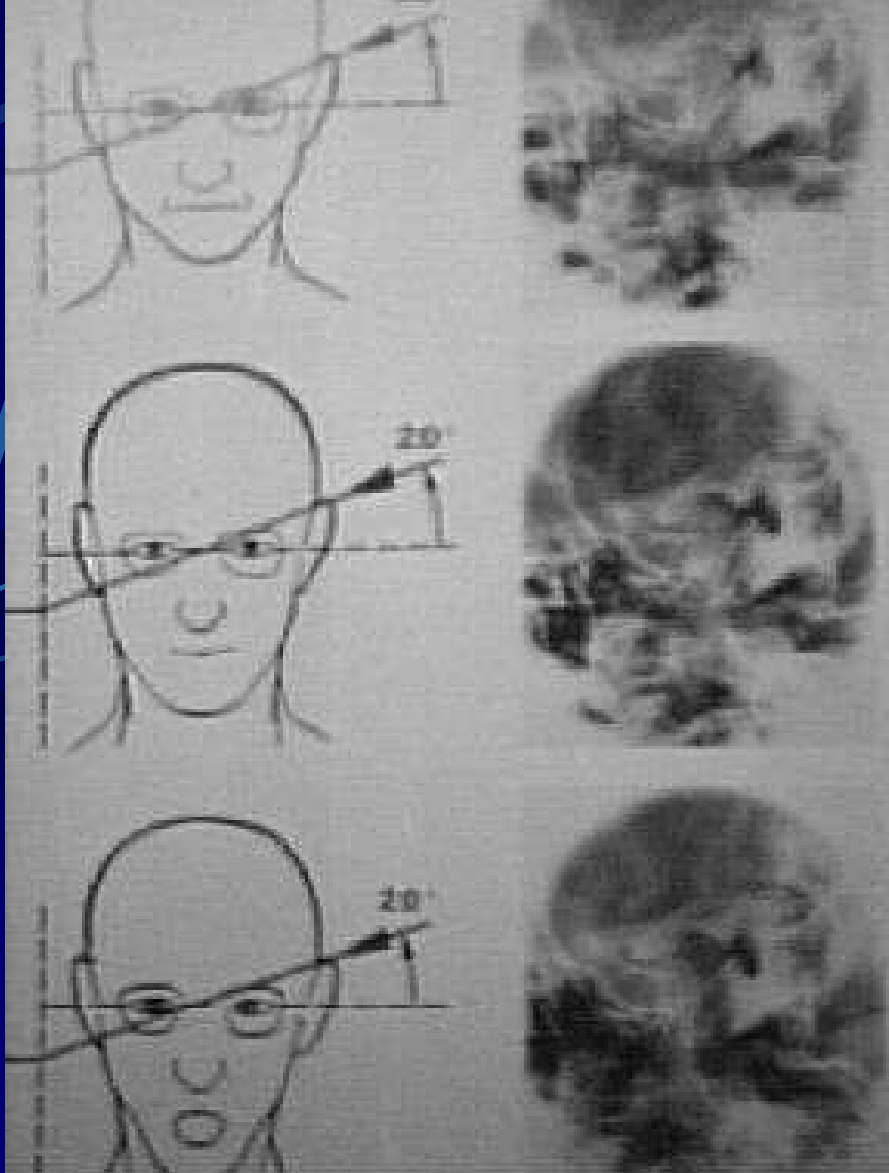




Anatomie

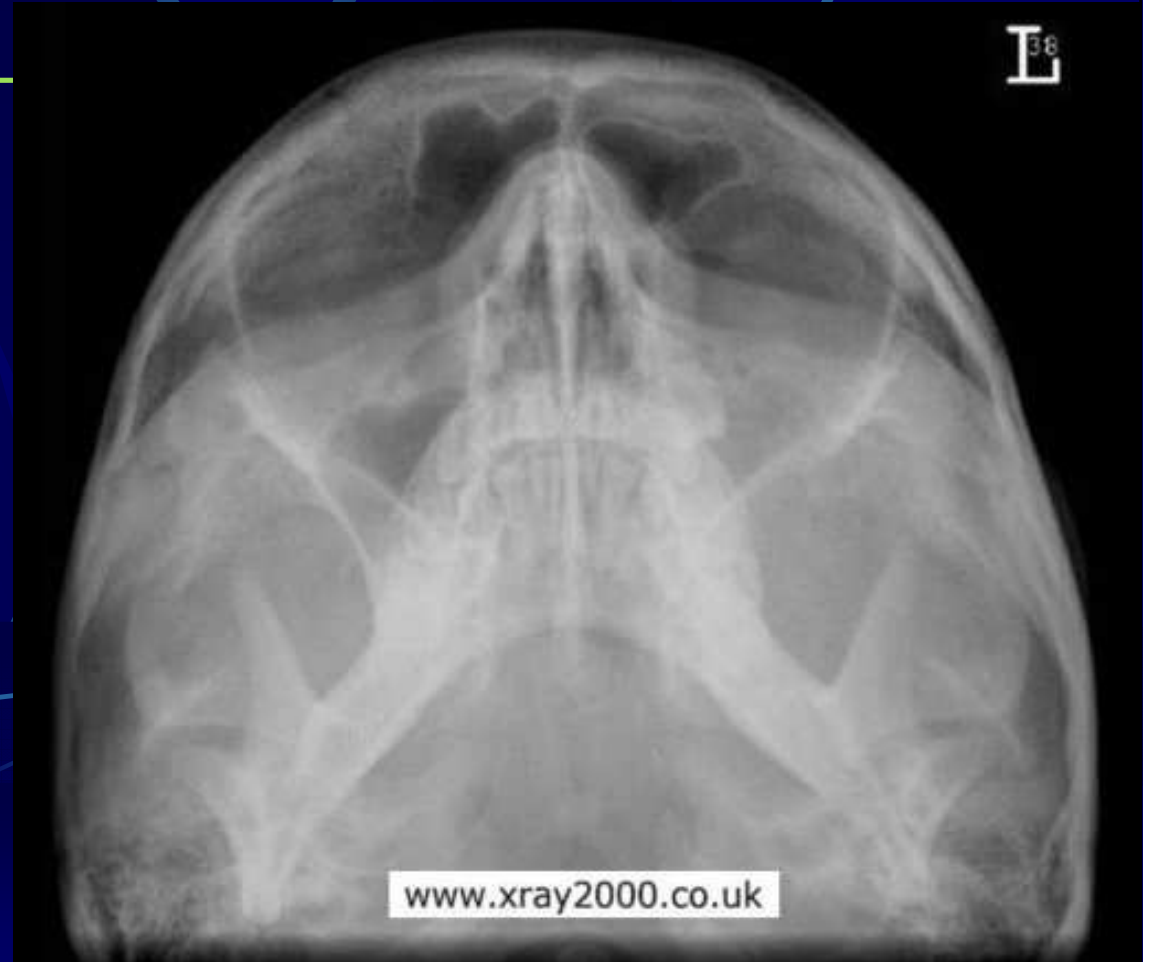

Anders Movin Karlison



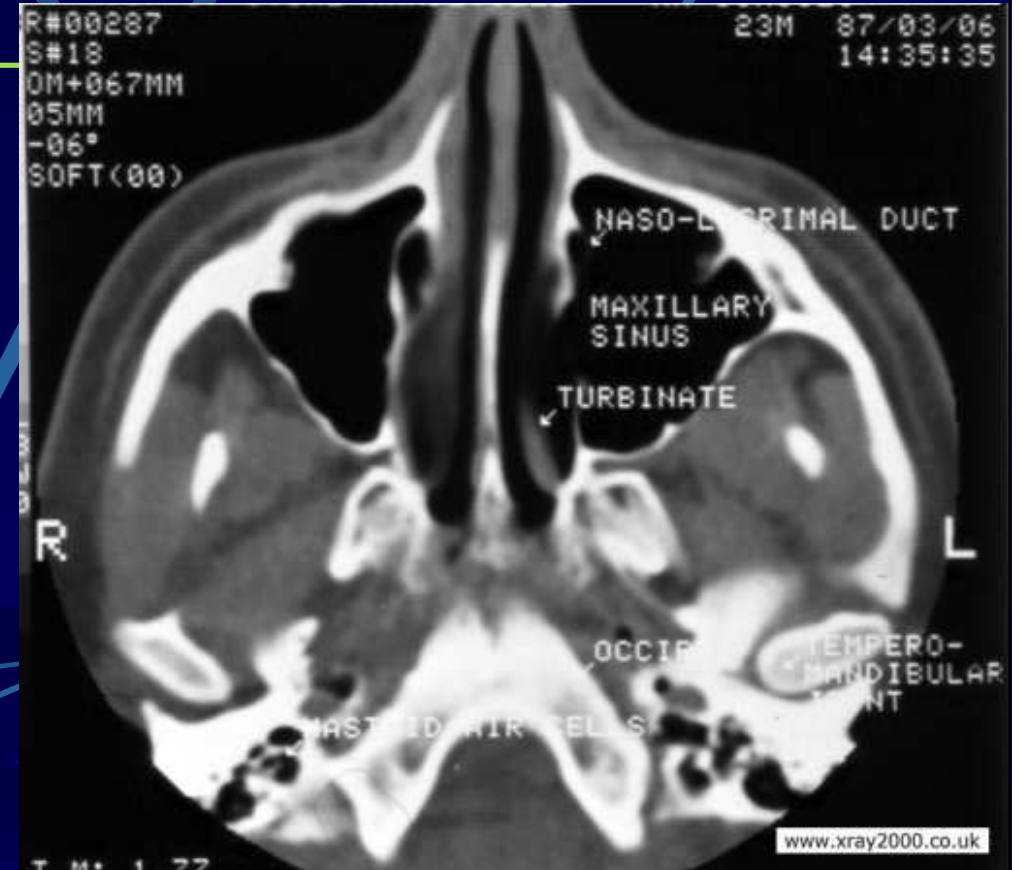
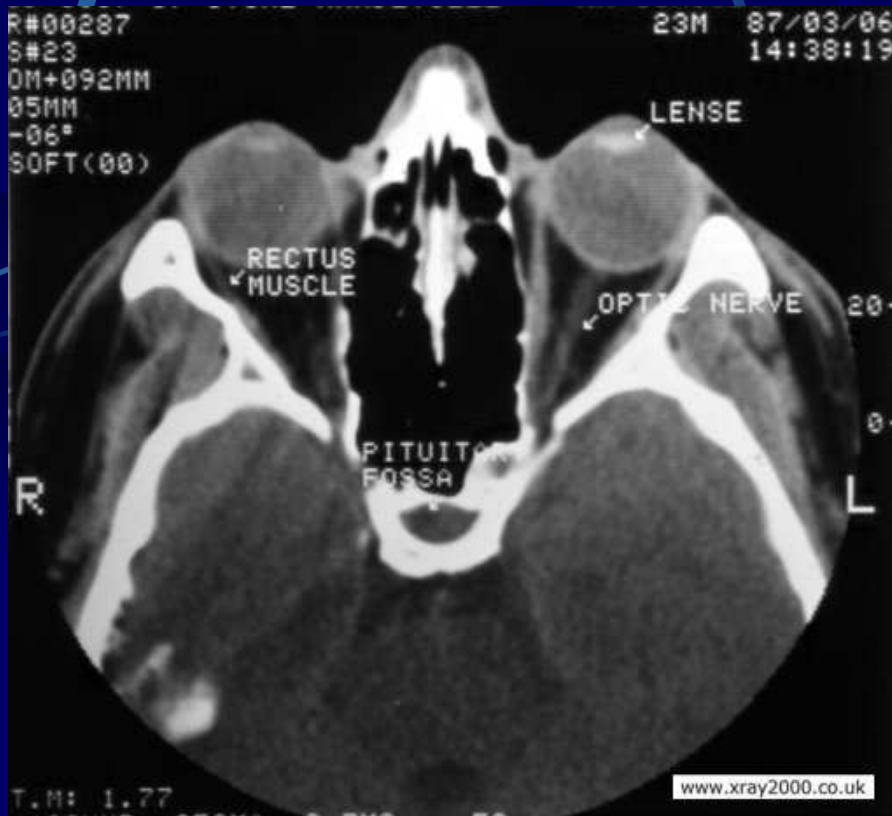


Anatomie





Anatomie

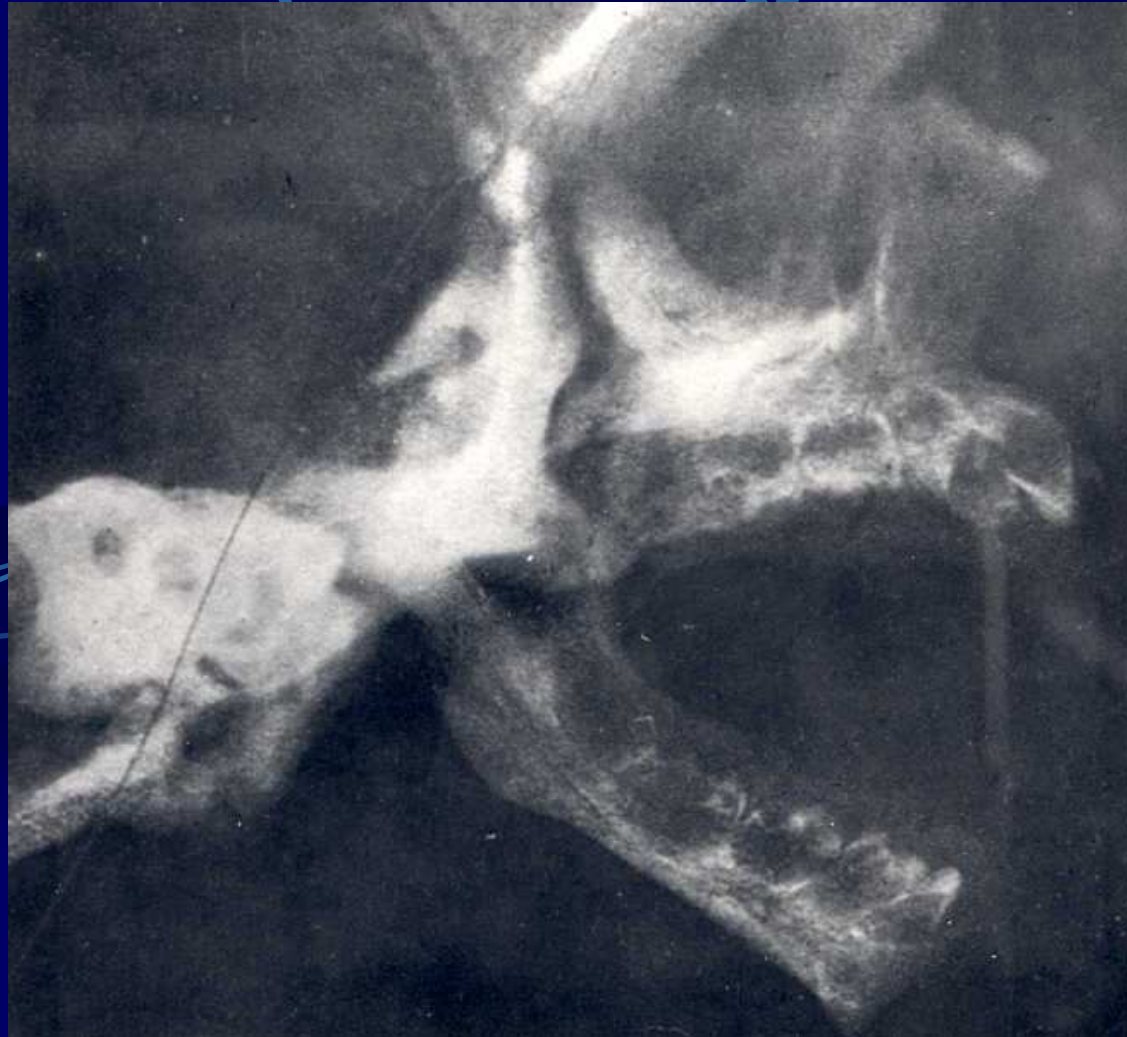




Vývoj zubu

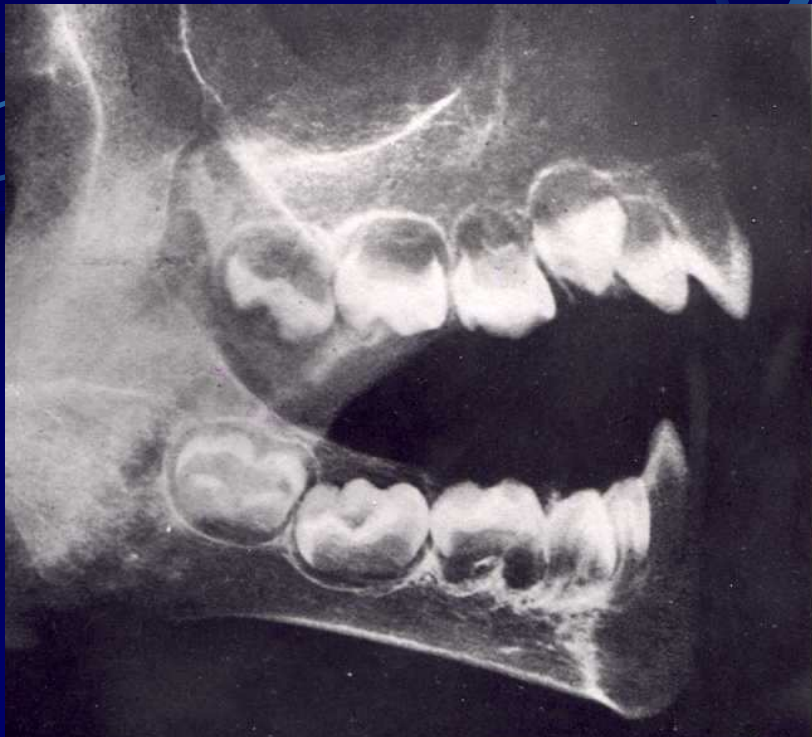
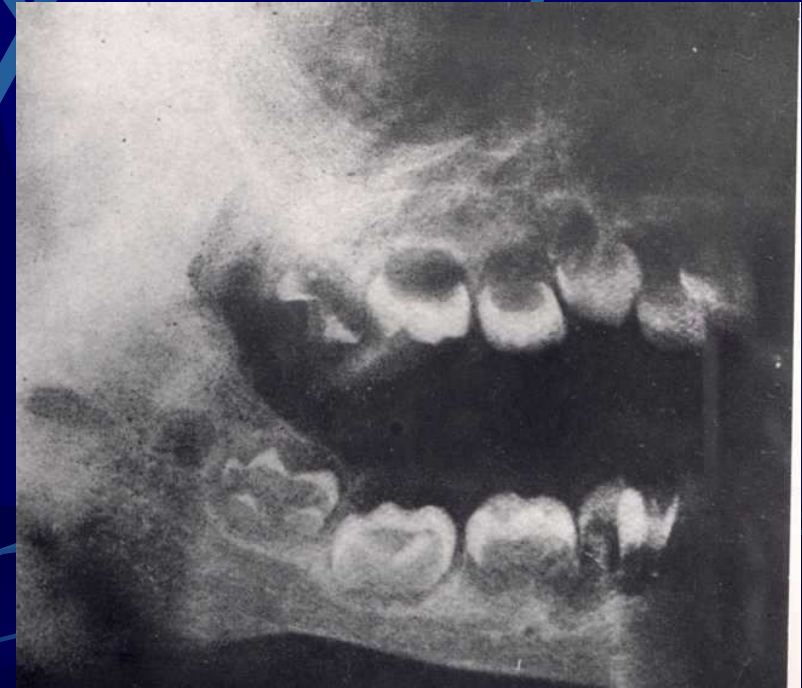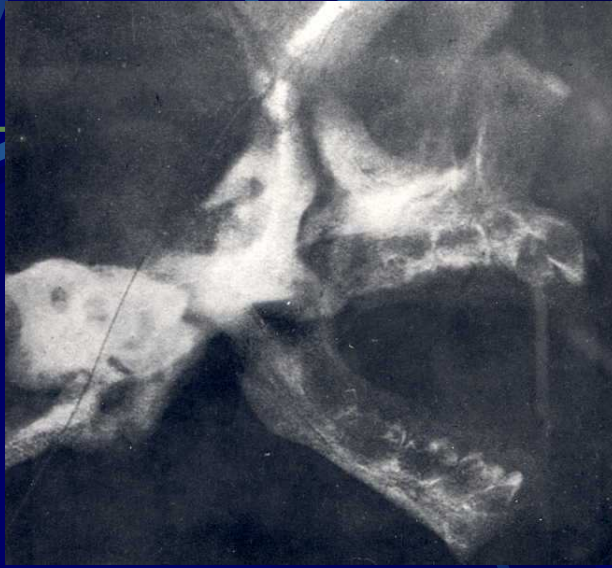



Zuby – vývoj - novorozenec

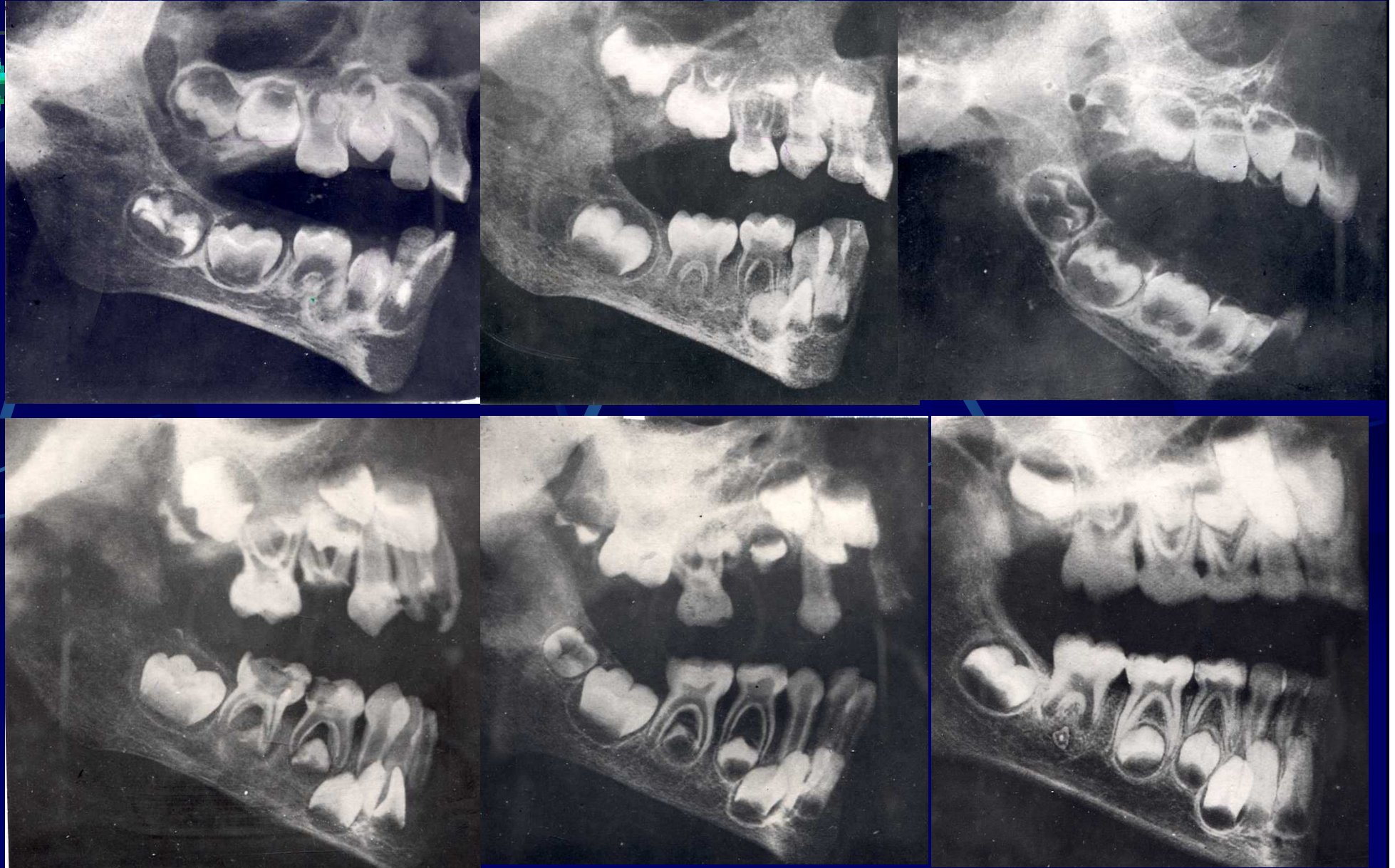




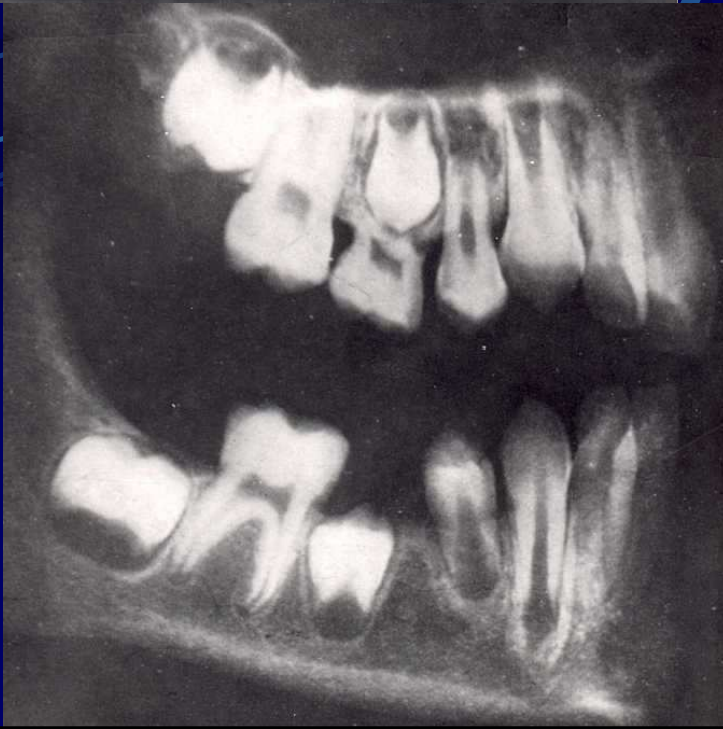
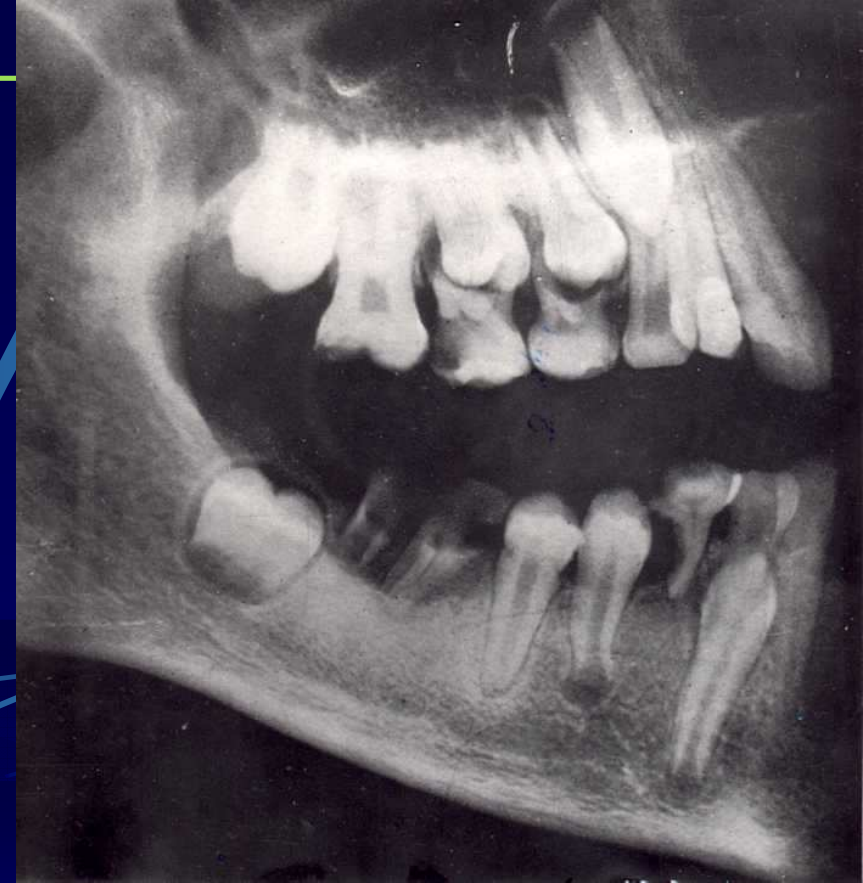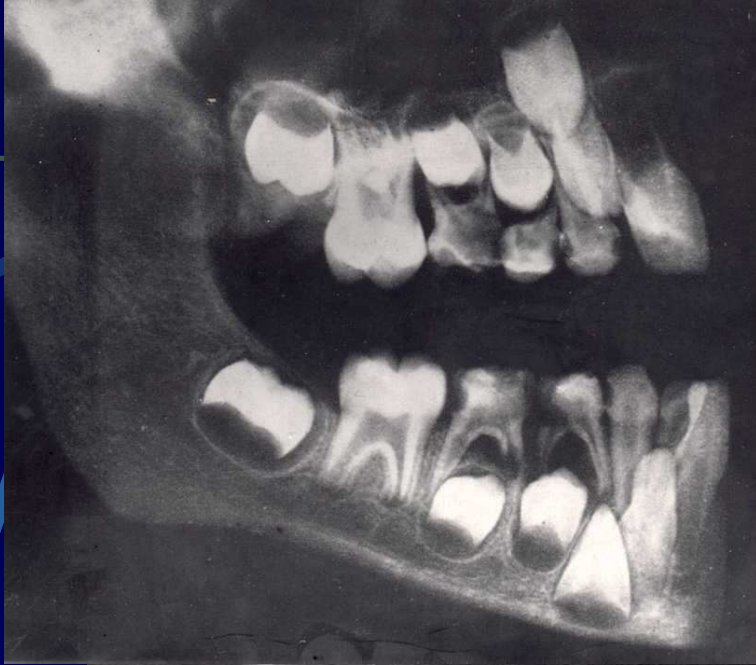
Zuby – vývoj – 6 a 9 měsíc



Zuby – vývoj – 1 – 6 rok



Zuby – vývoj – 7-10 let

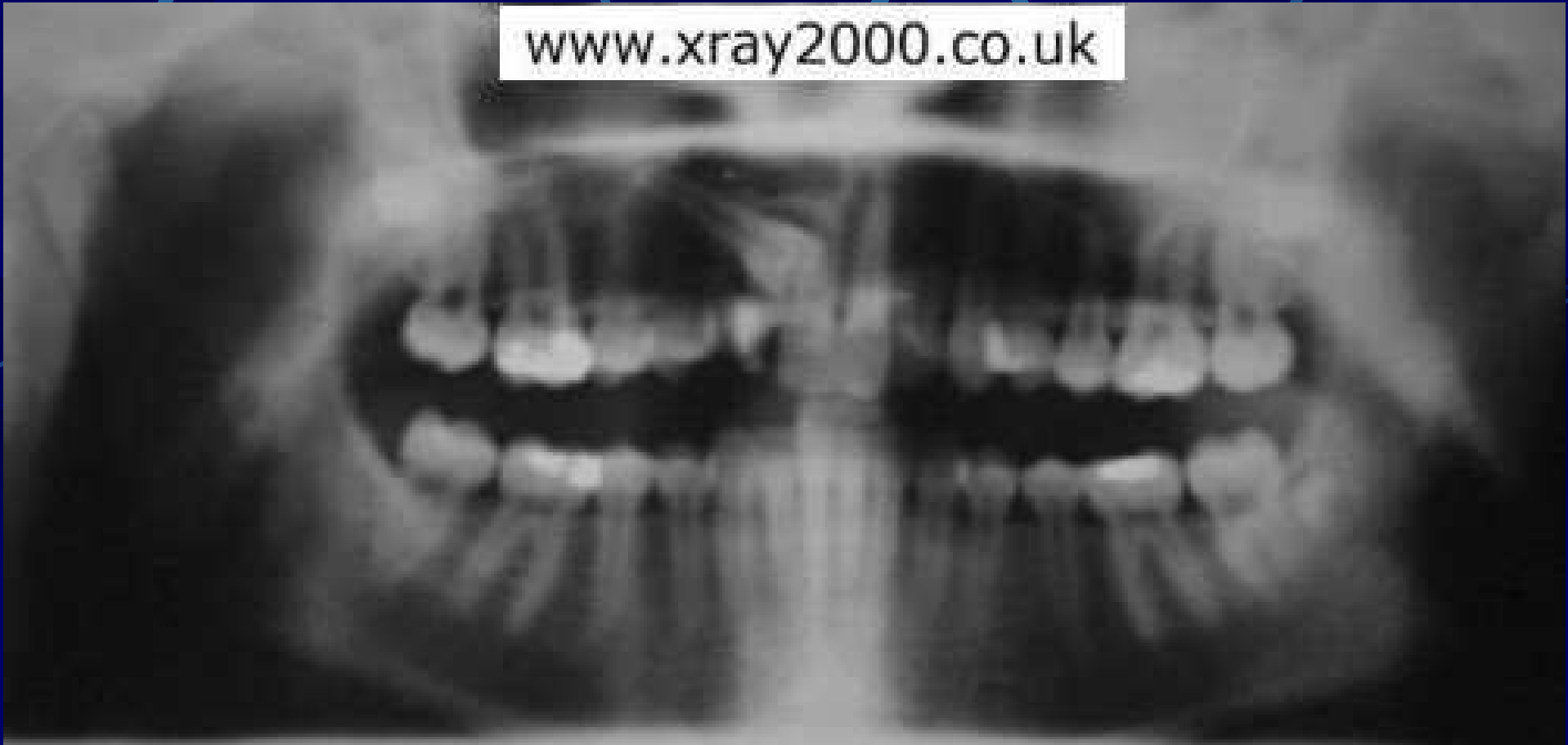



Zuby – vývoj – ektopický zub



www.xray2000.co.uk

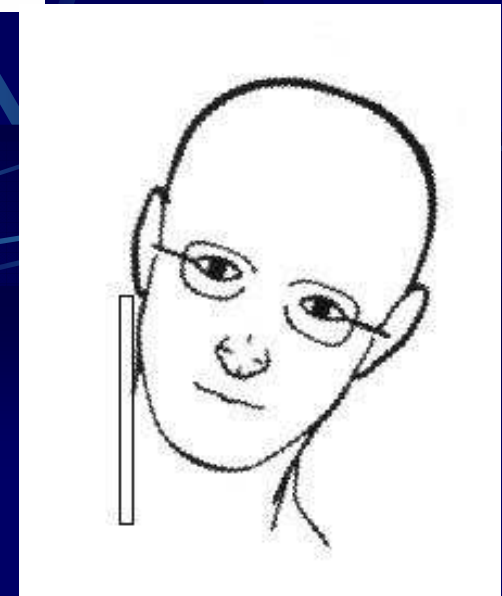
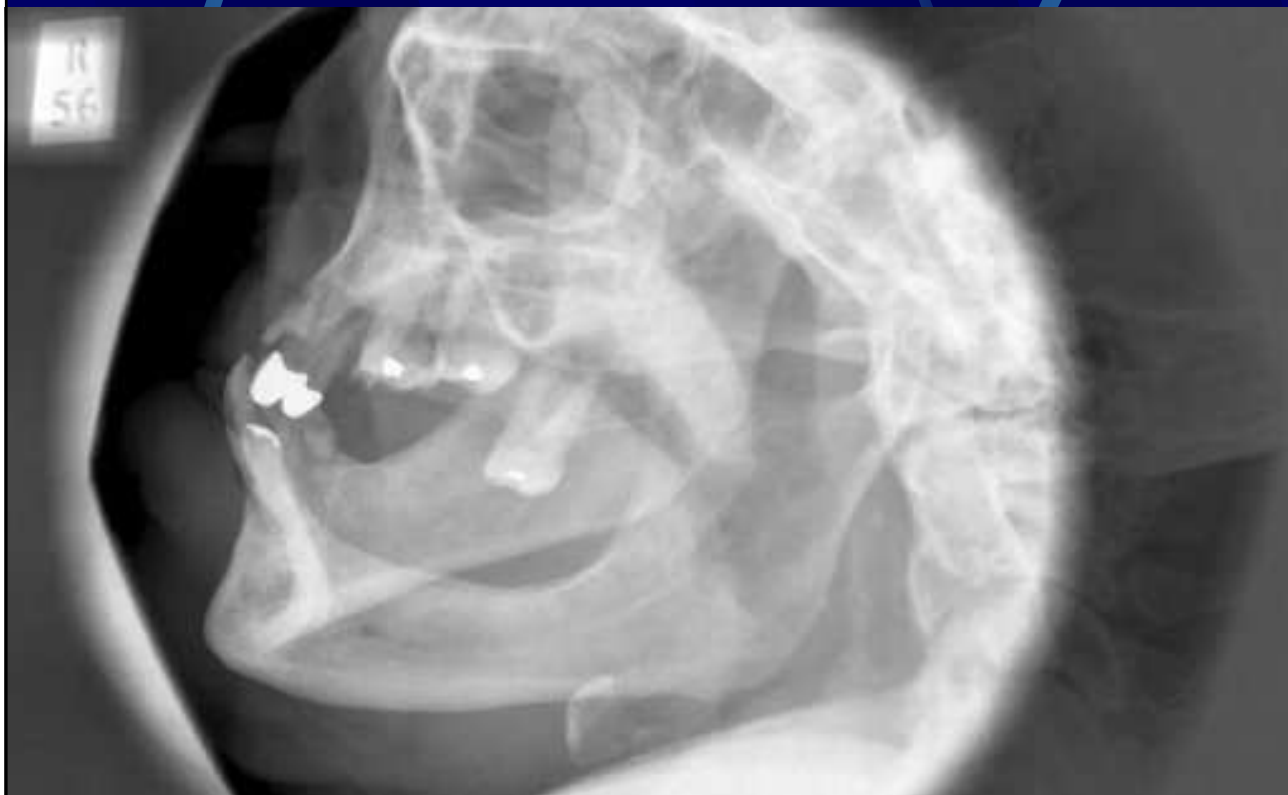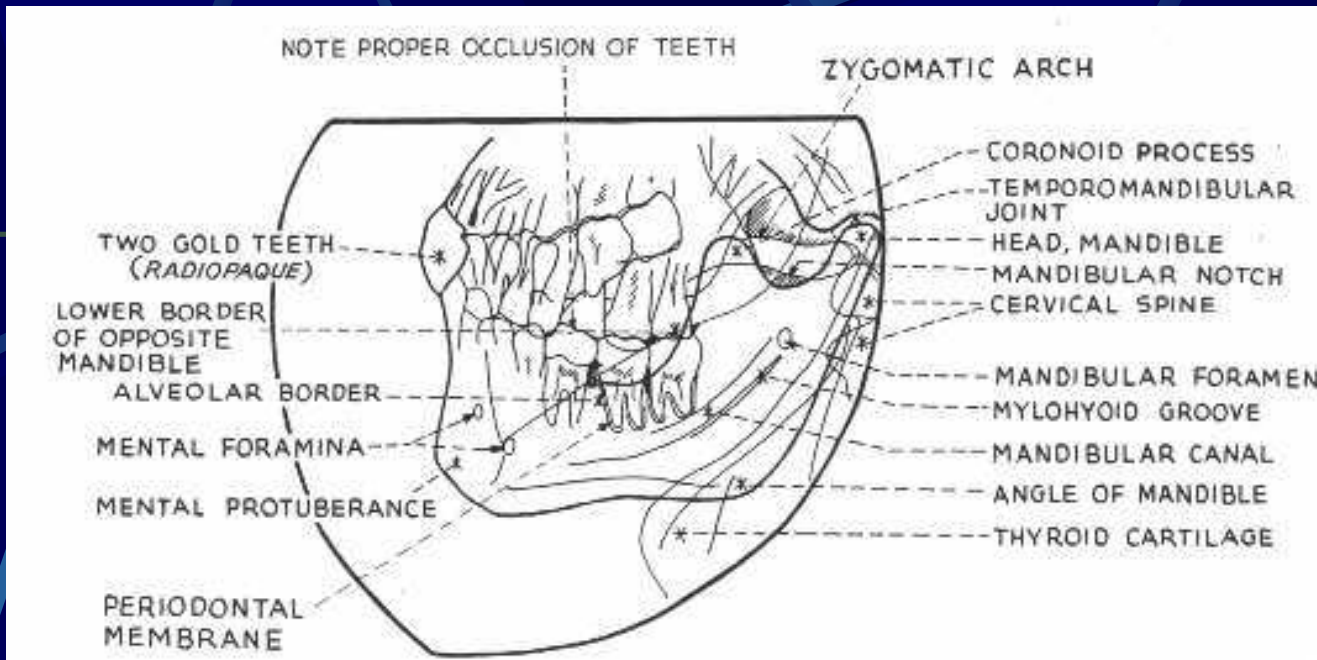




Projekce

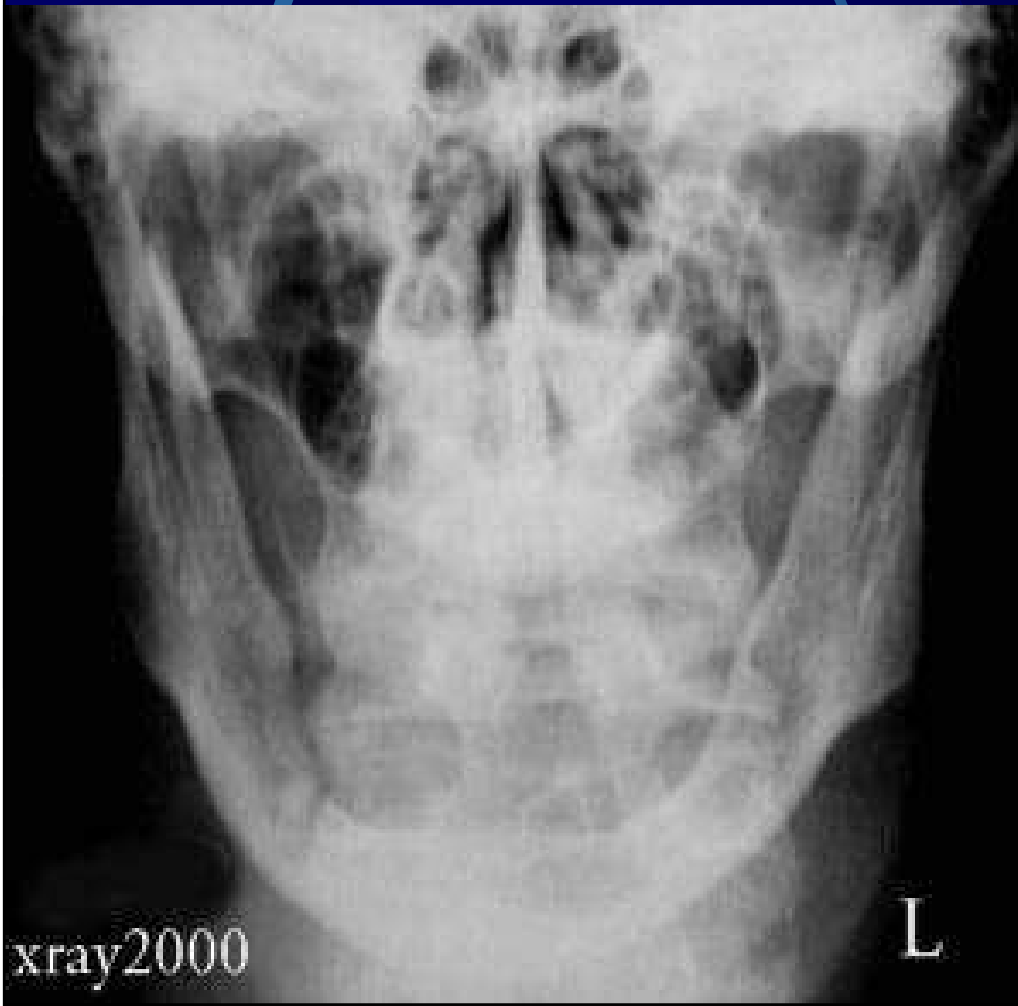



Šikmá projekce mandibula – faciomaxilární



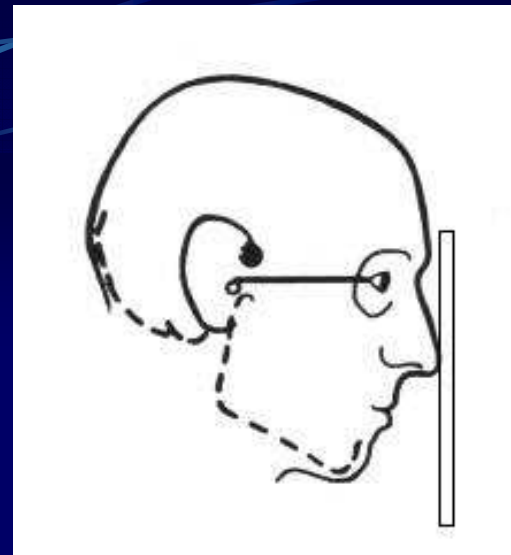
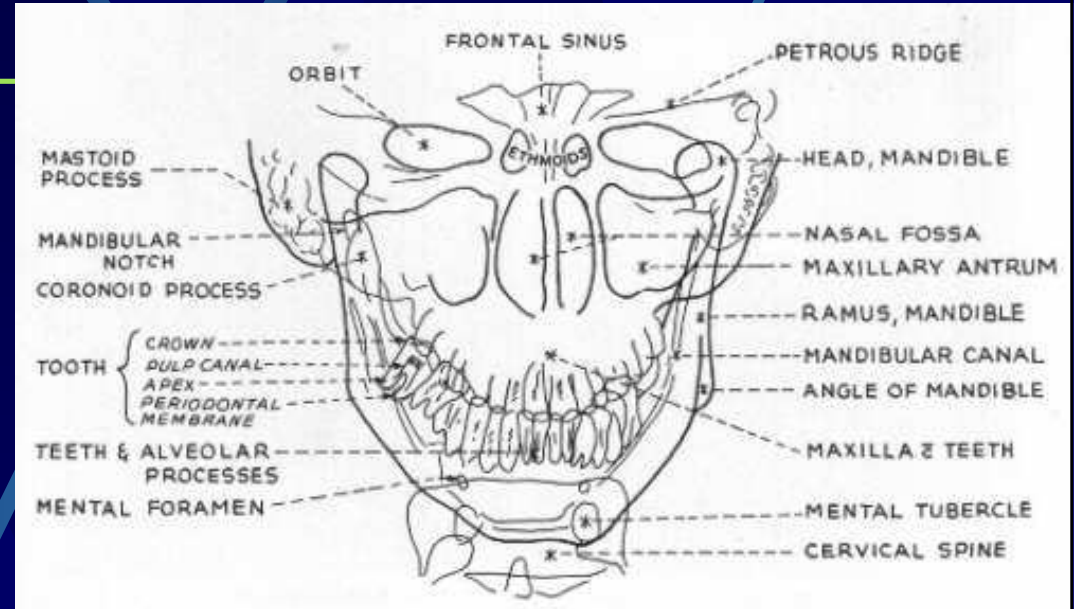


Mandibula PA



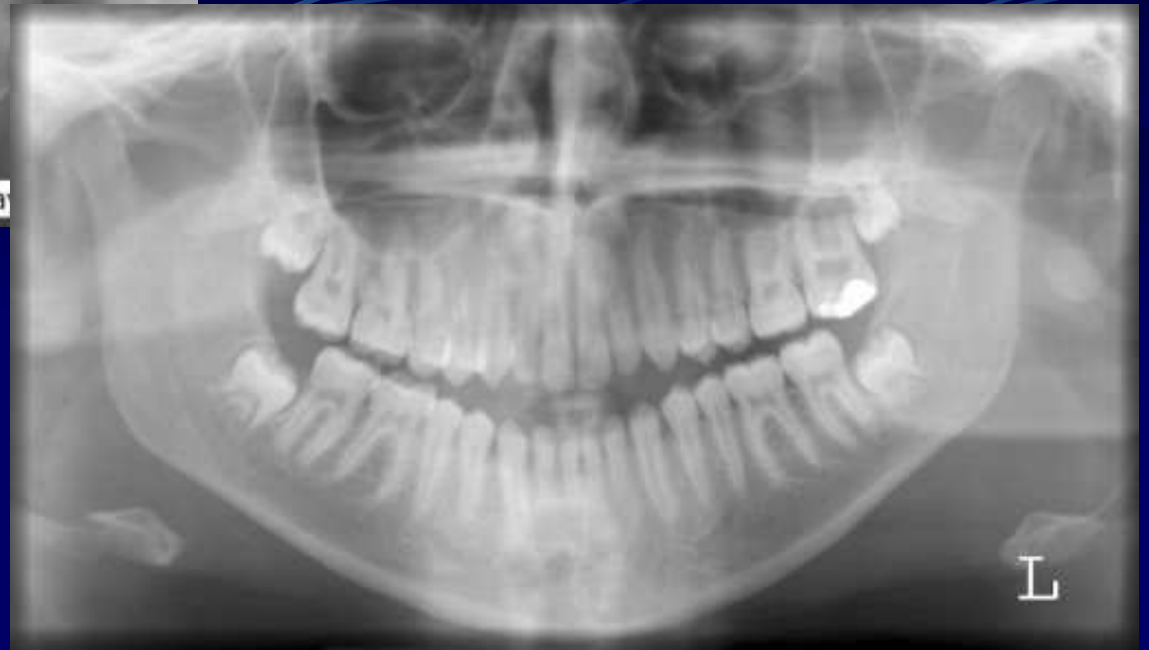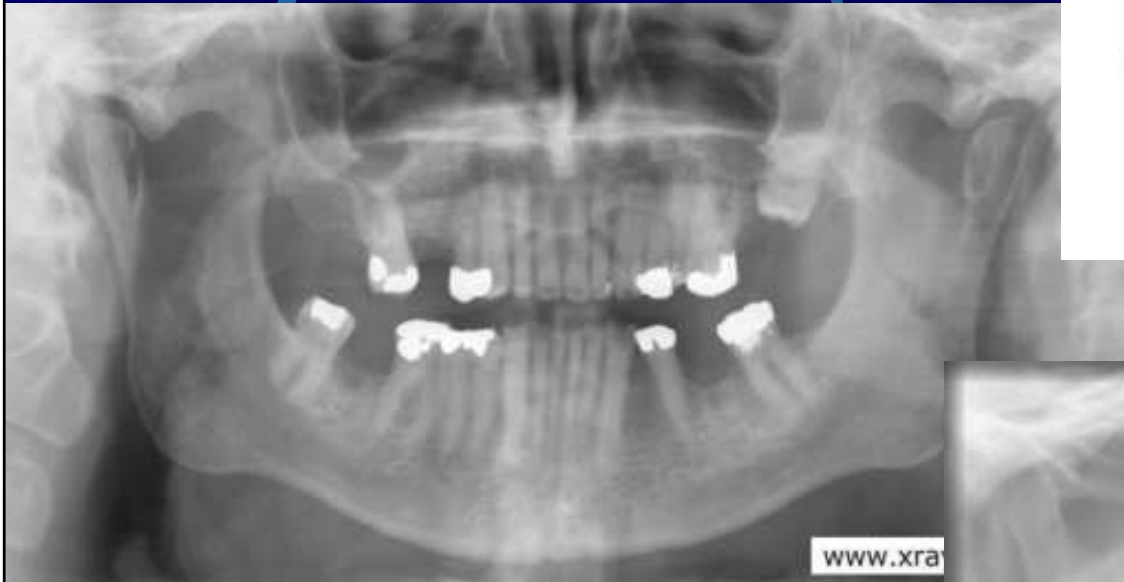
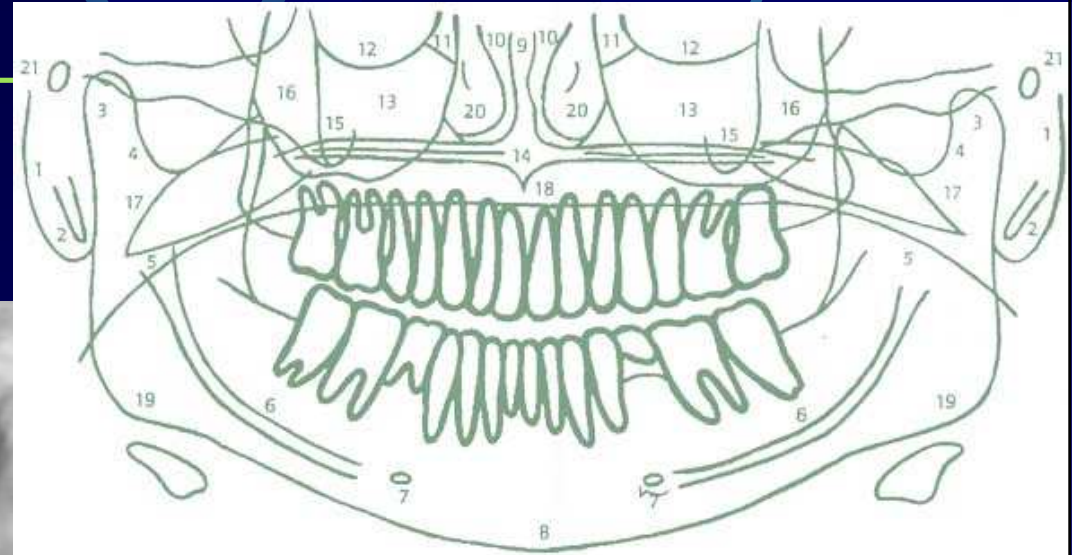

xray2000

L



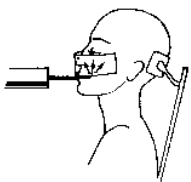
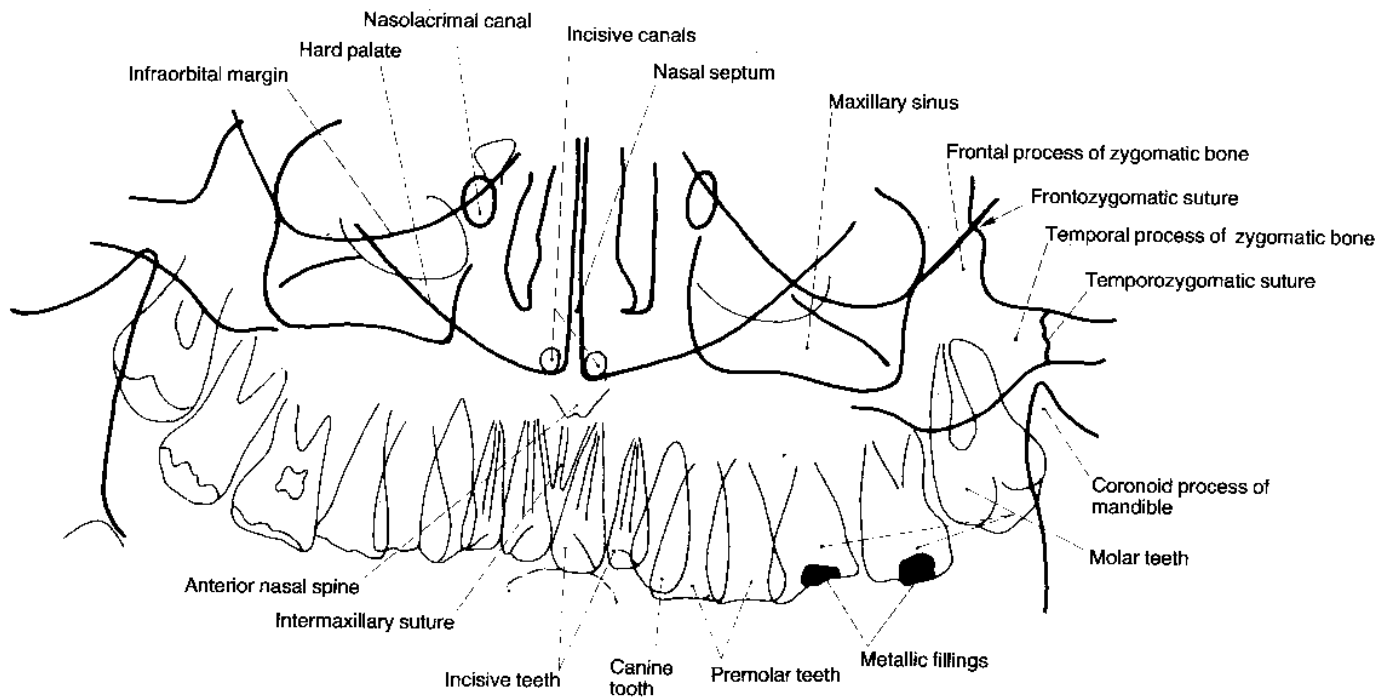
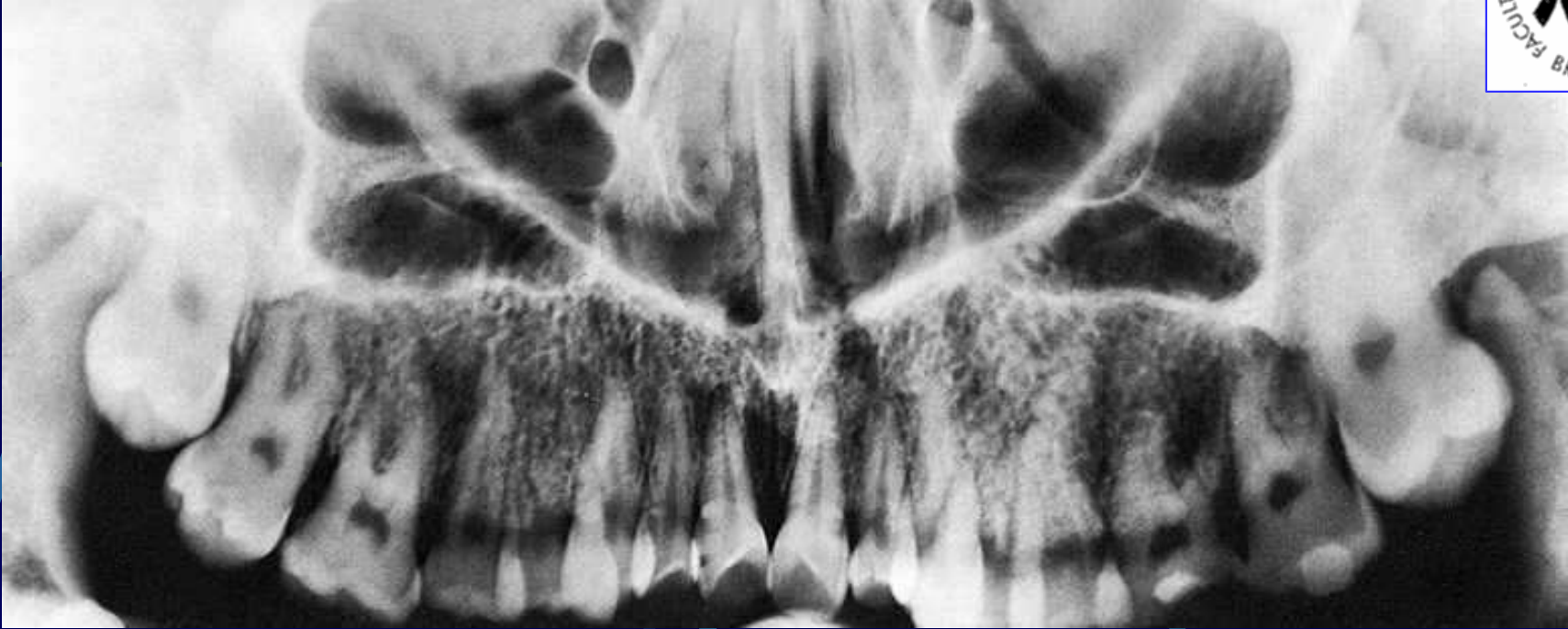


Projekce



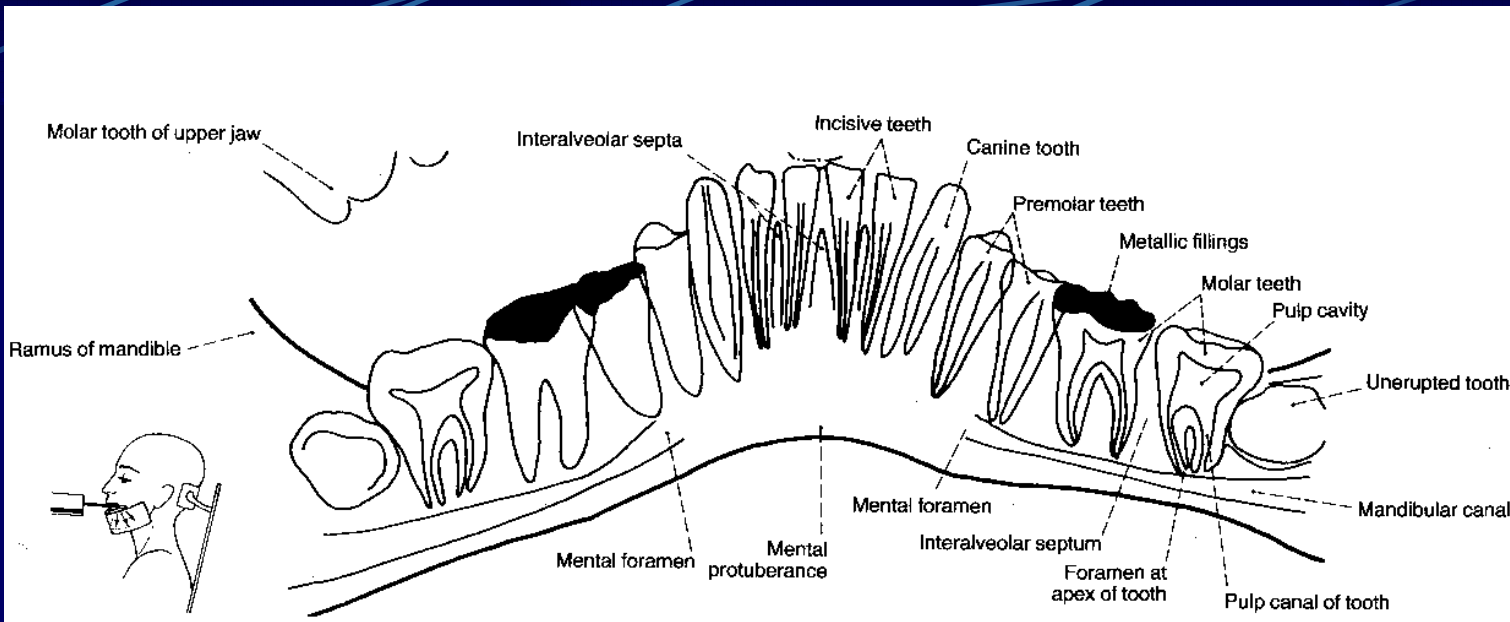
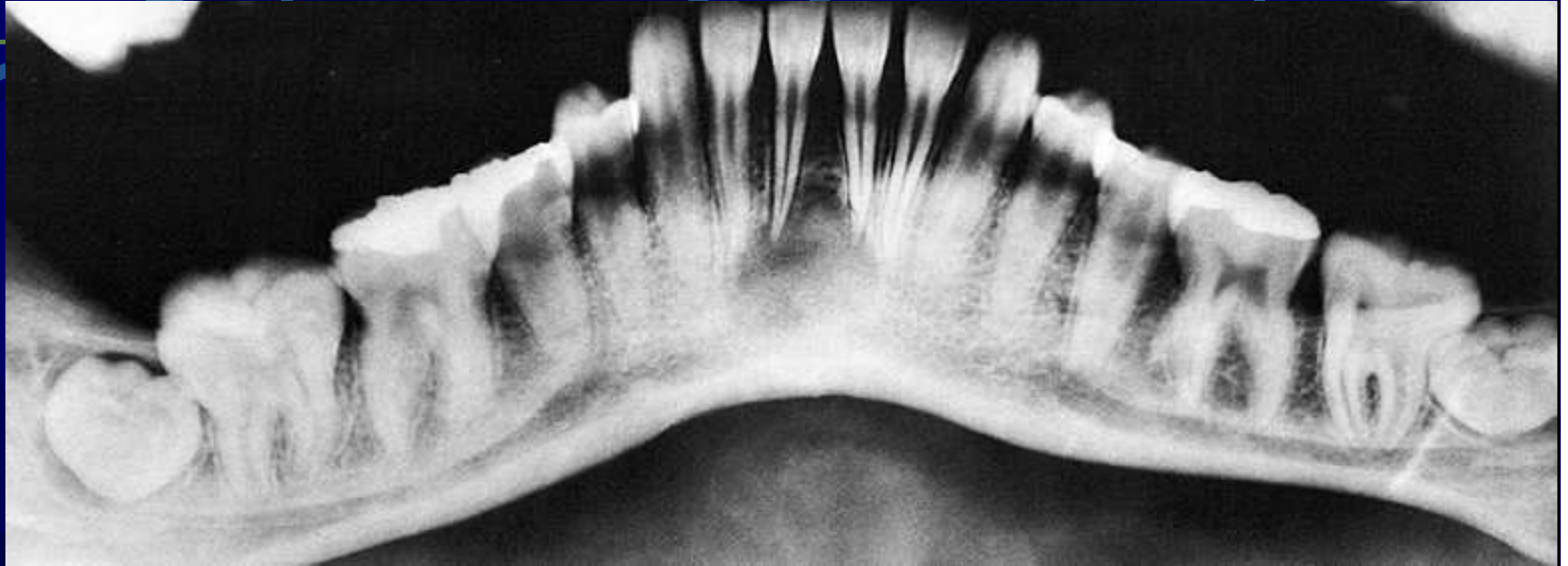


Projekce



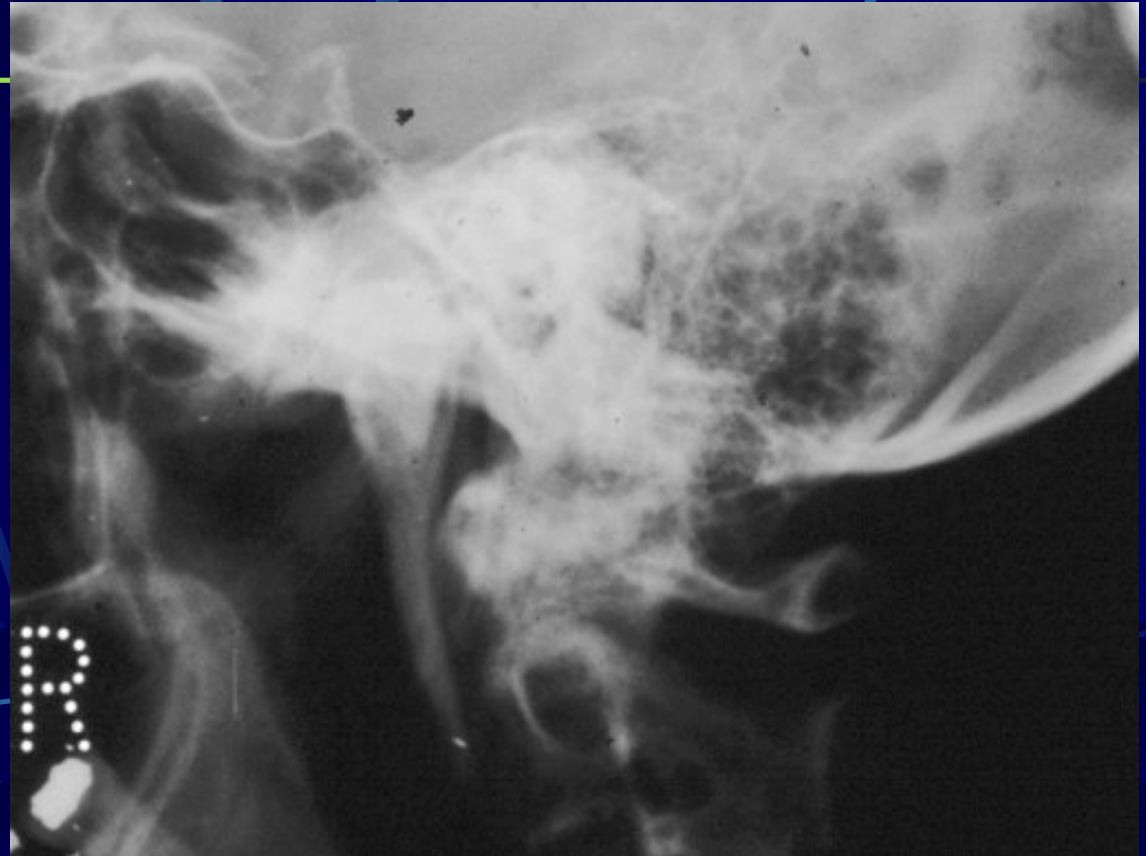
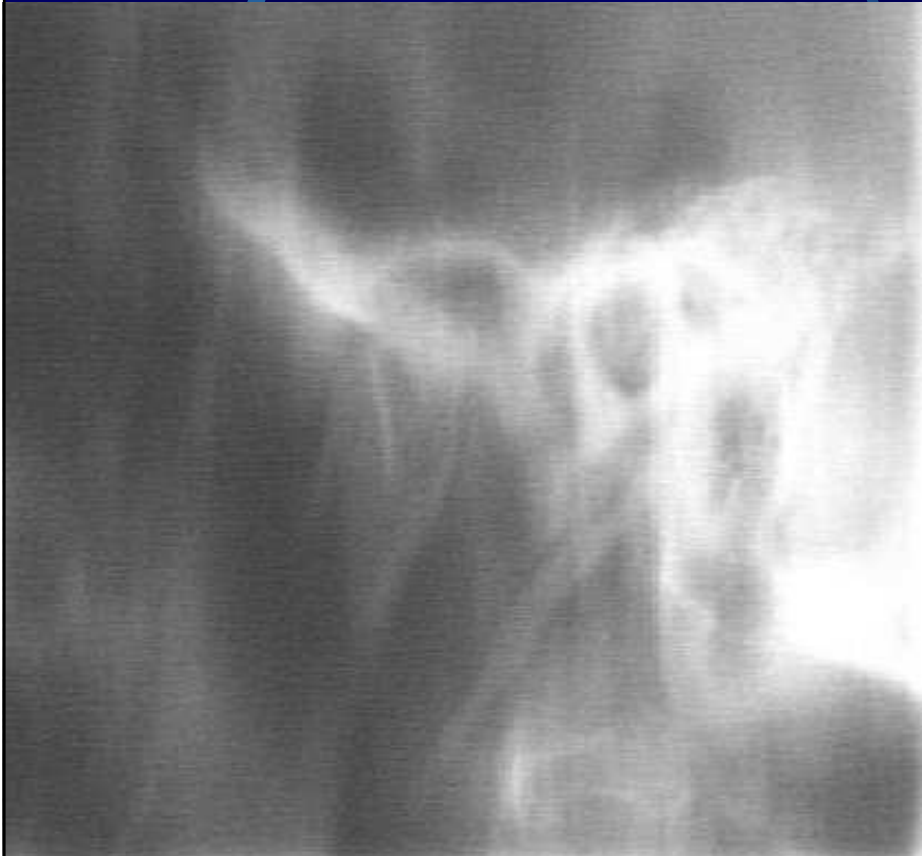



Projekce



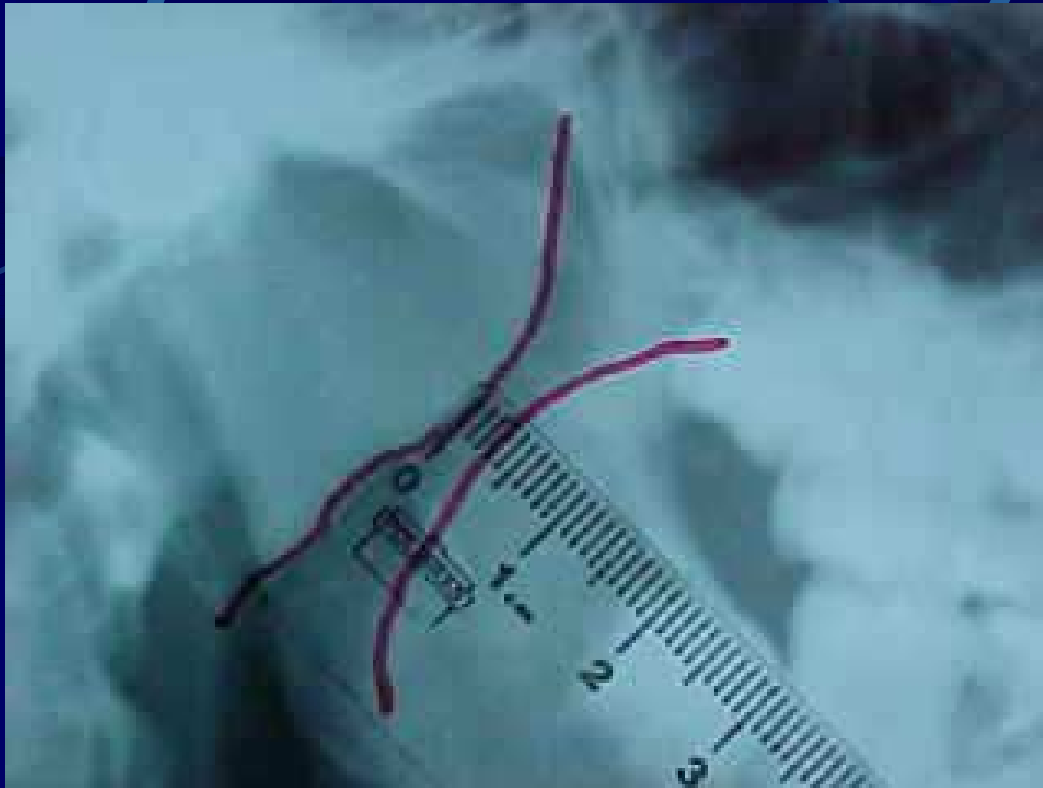
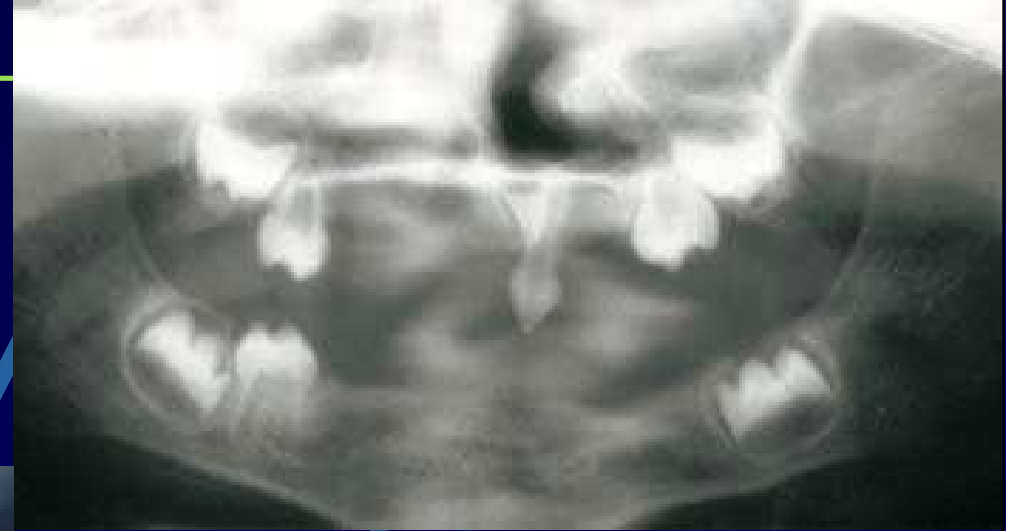


Projekce



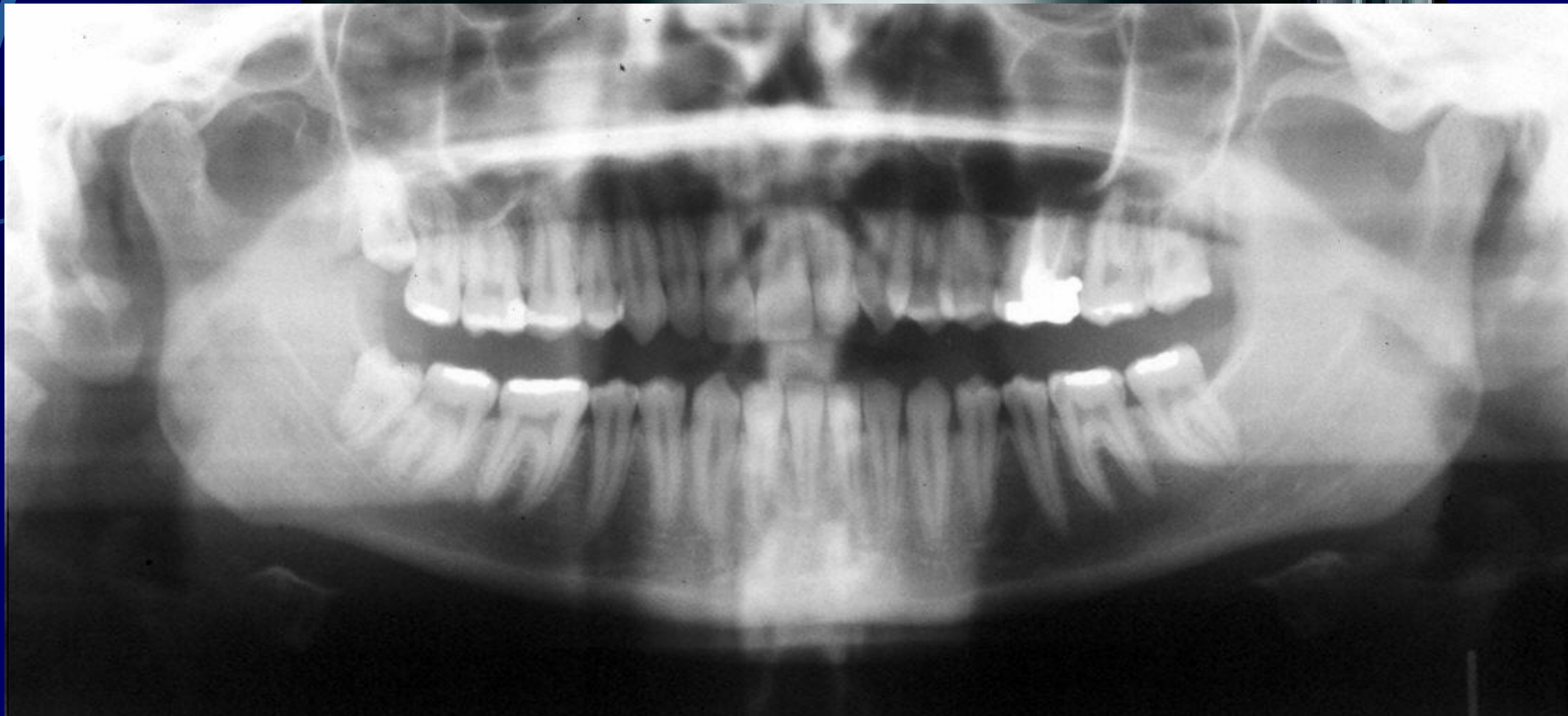
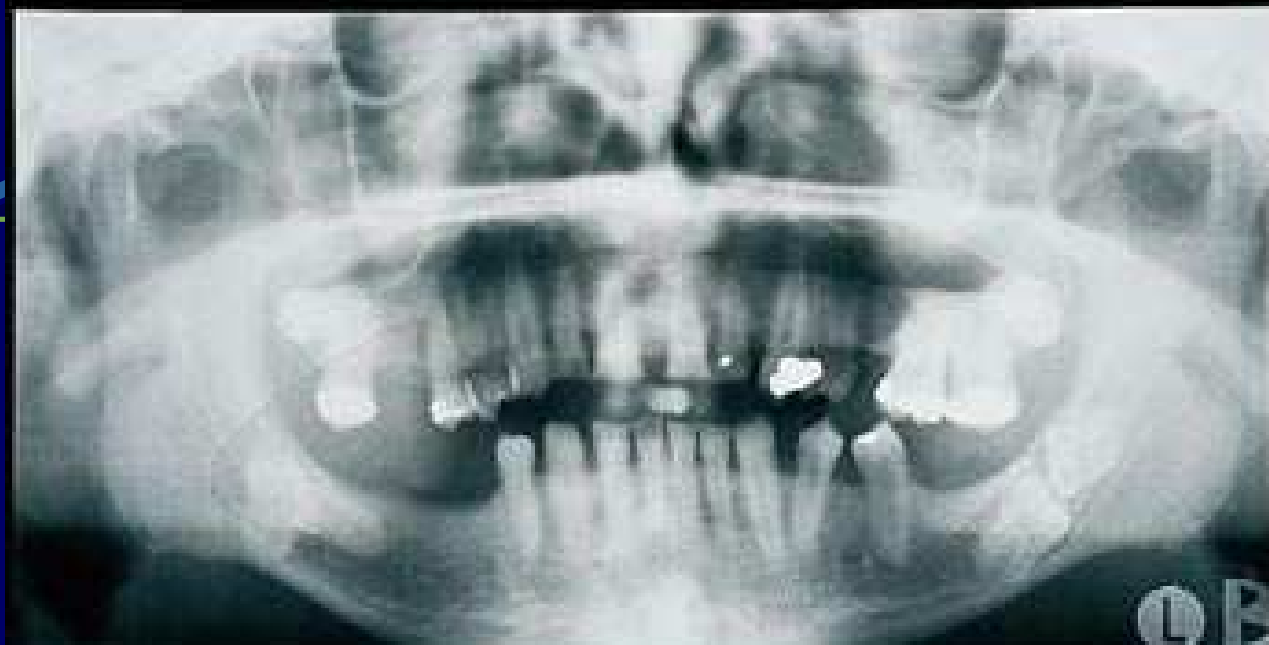
Projekce



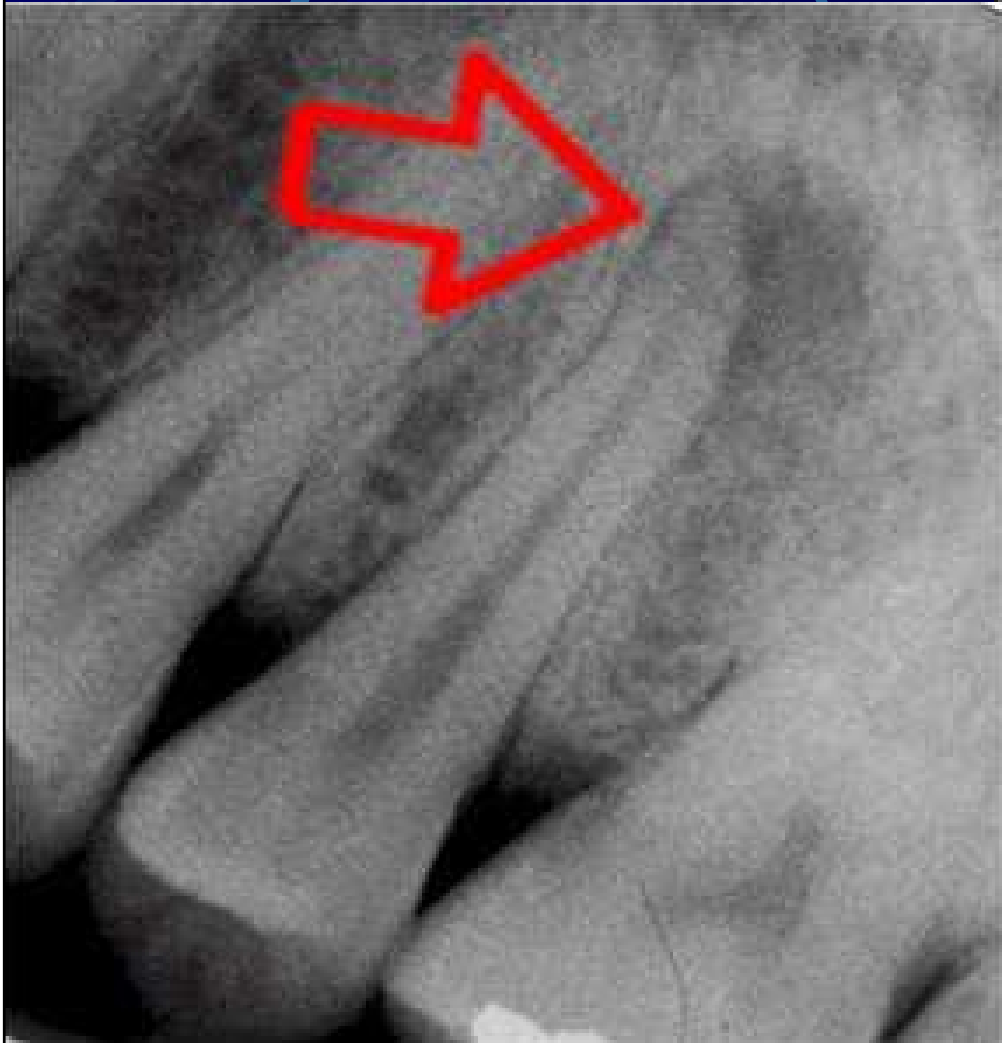


Projekce



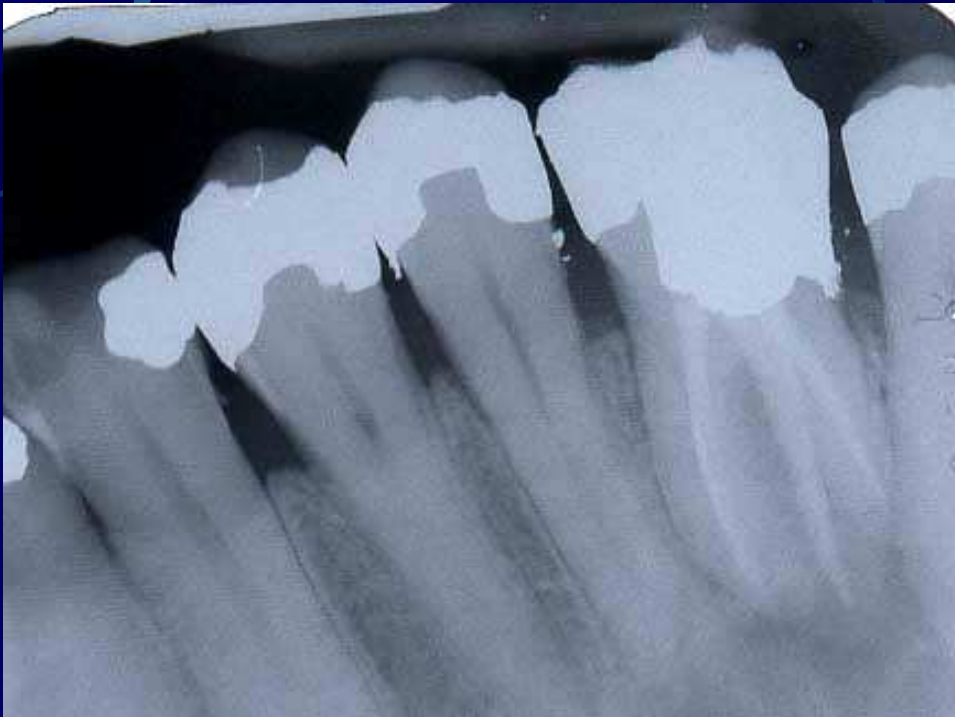
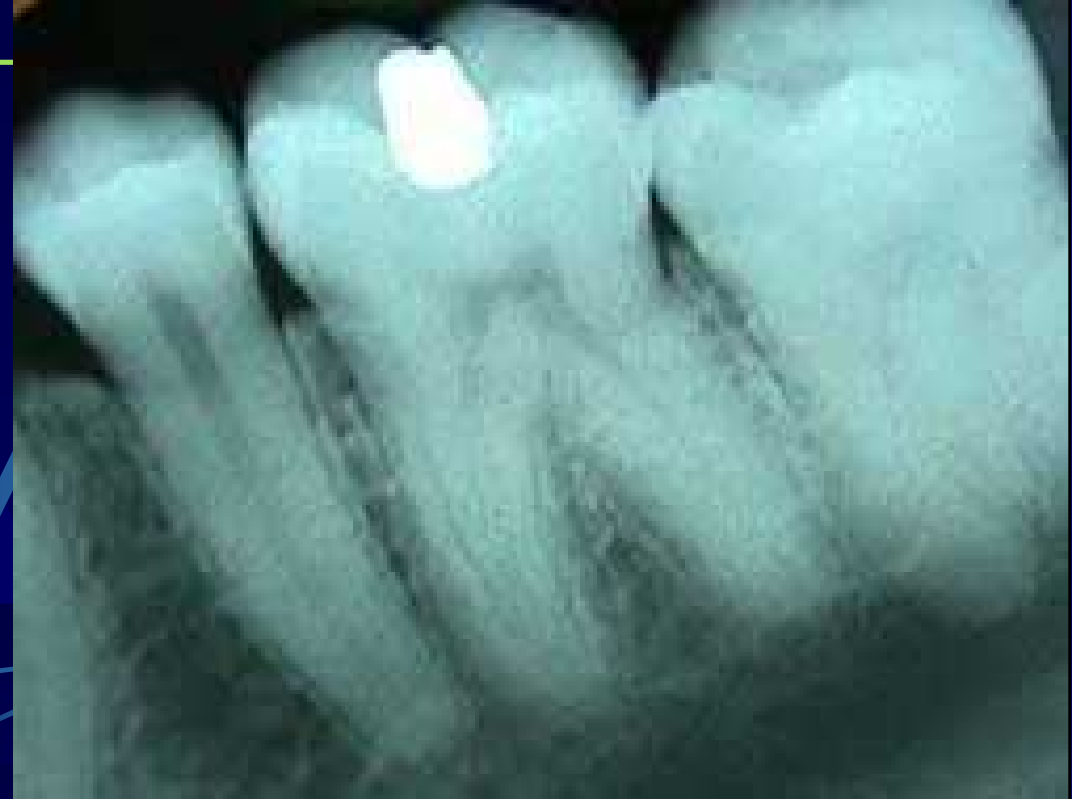

Projekce



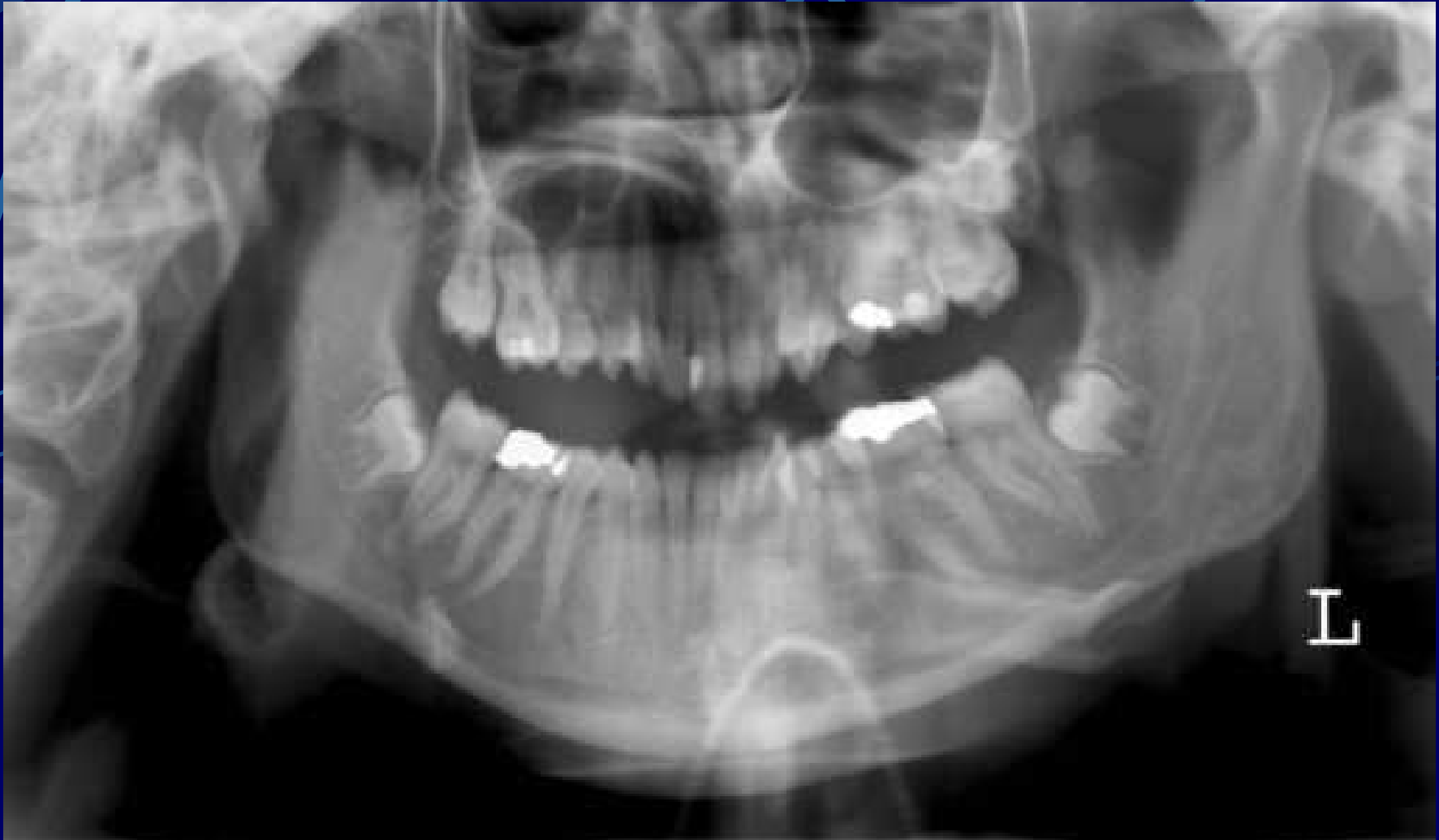


Projekce





Zuby - artefakt

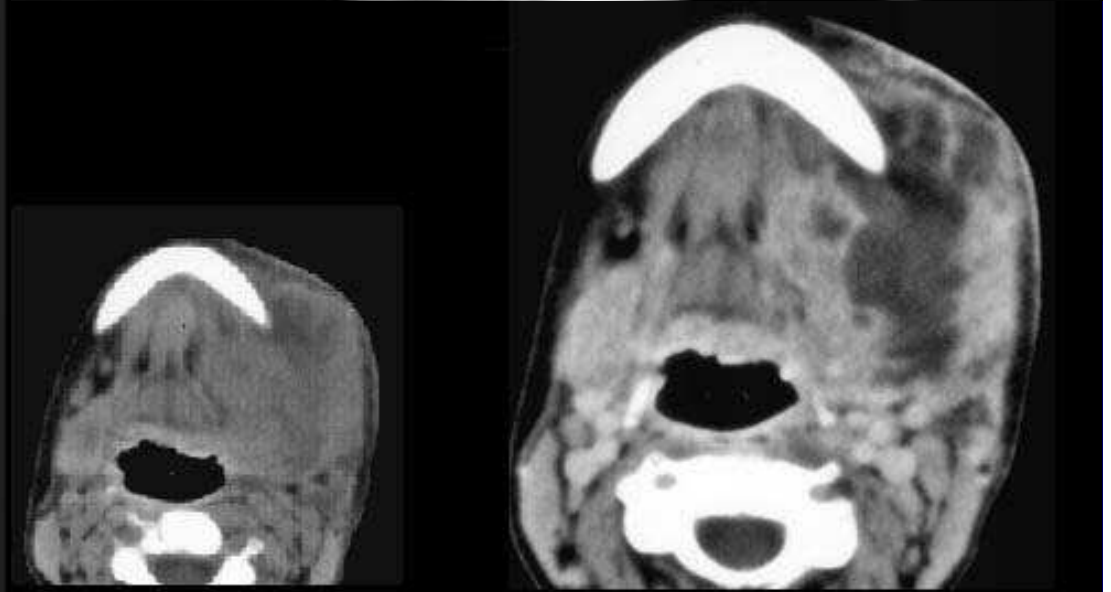
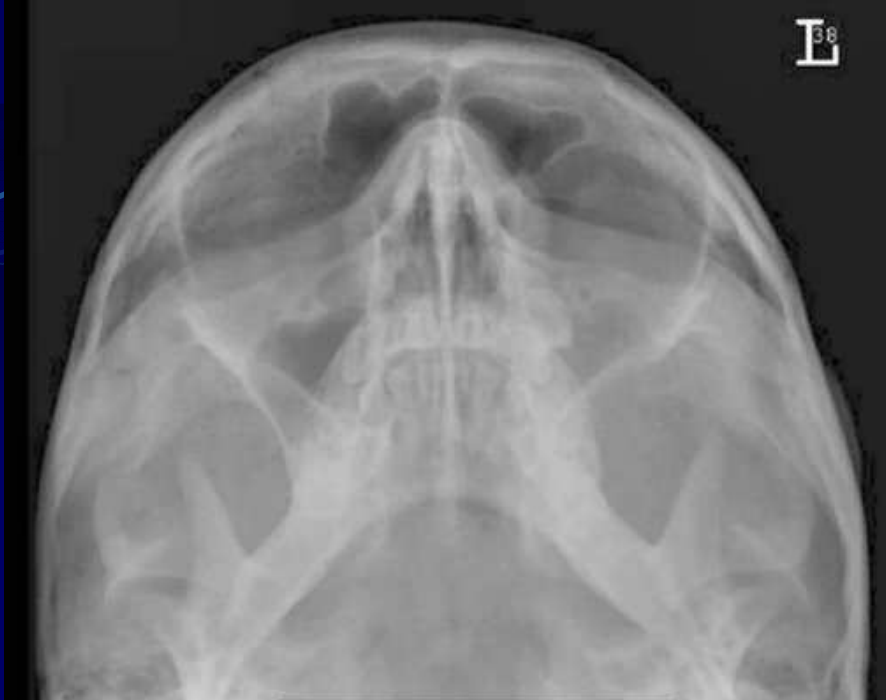
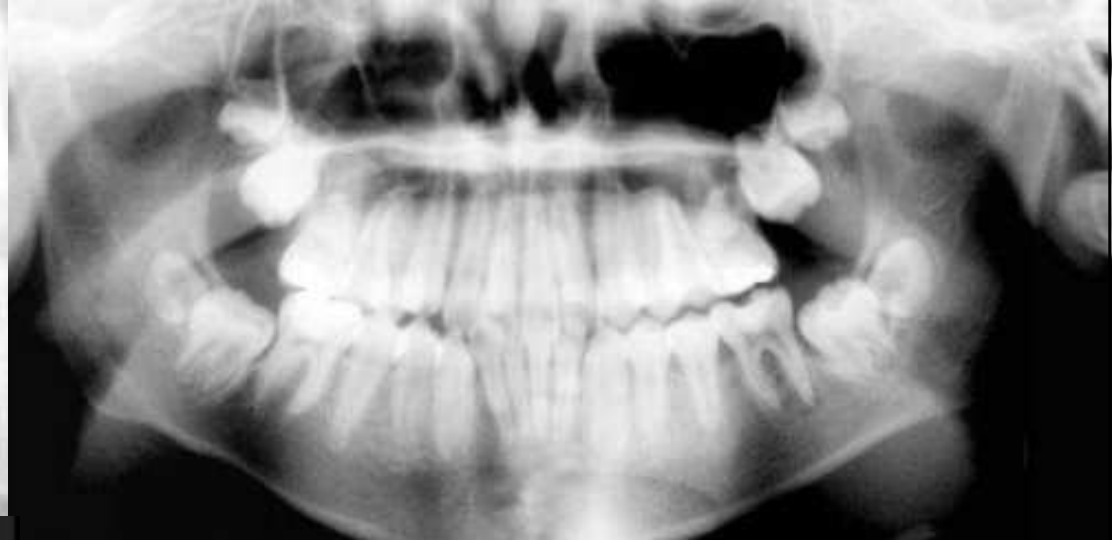
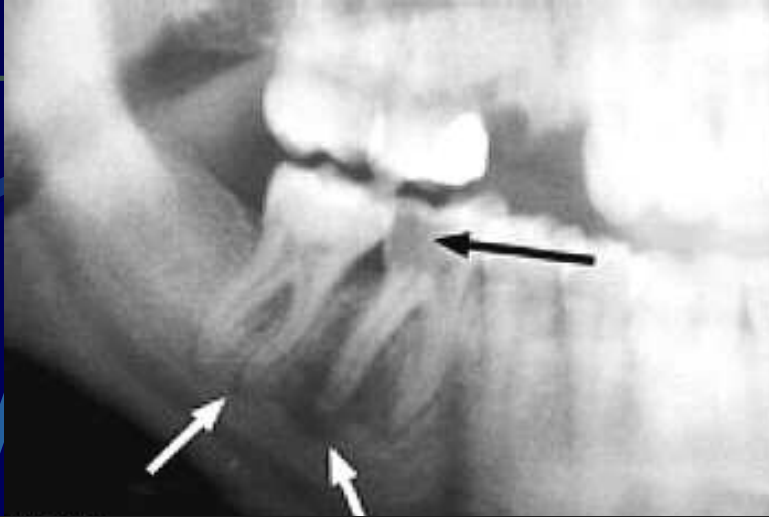

Patologie

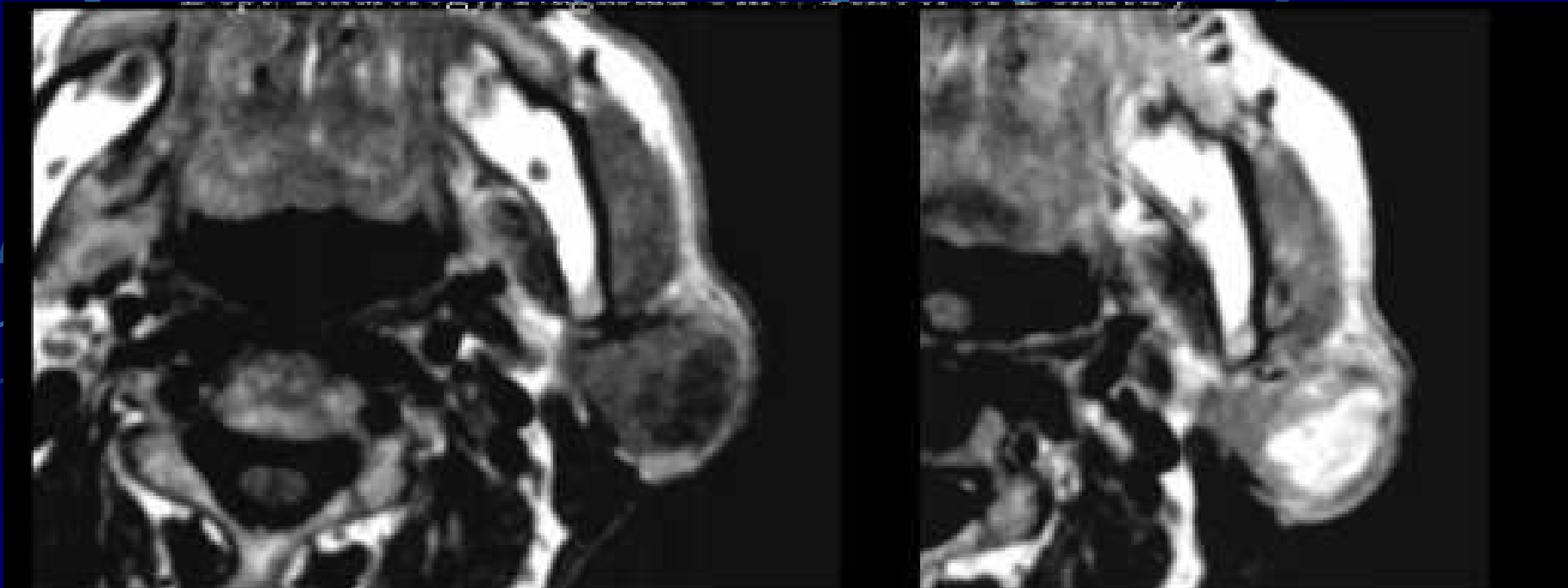



Absces



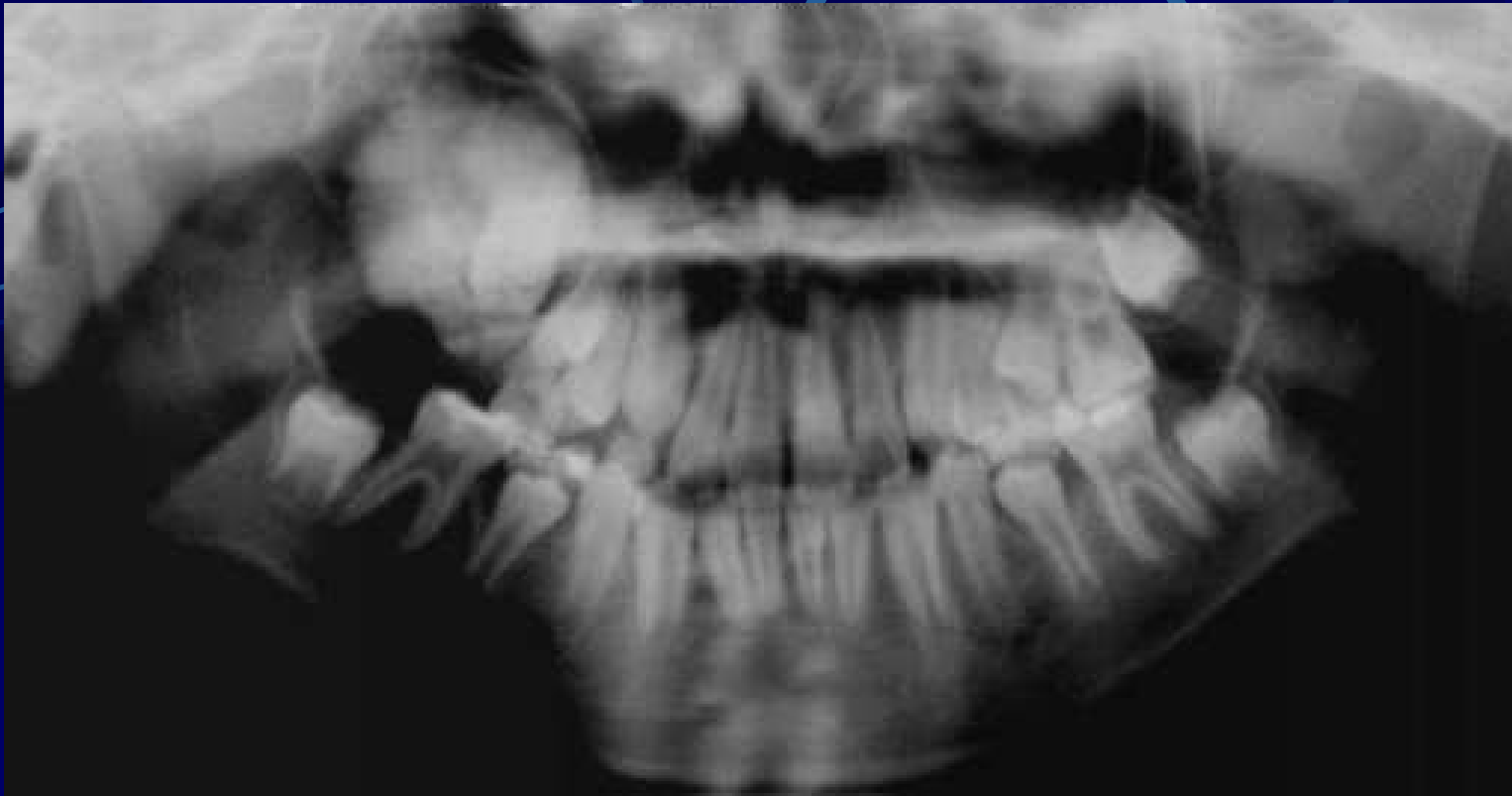
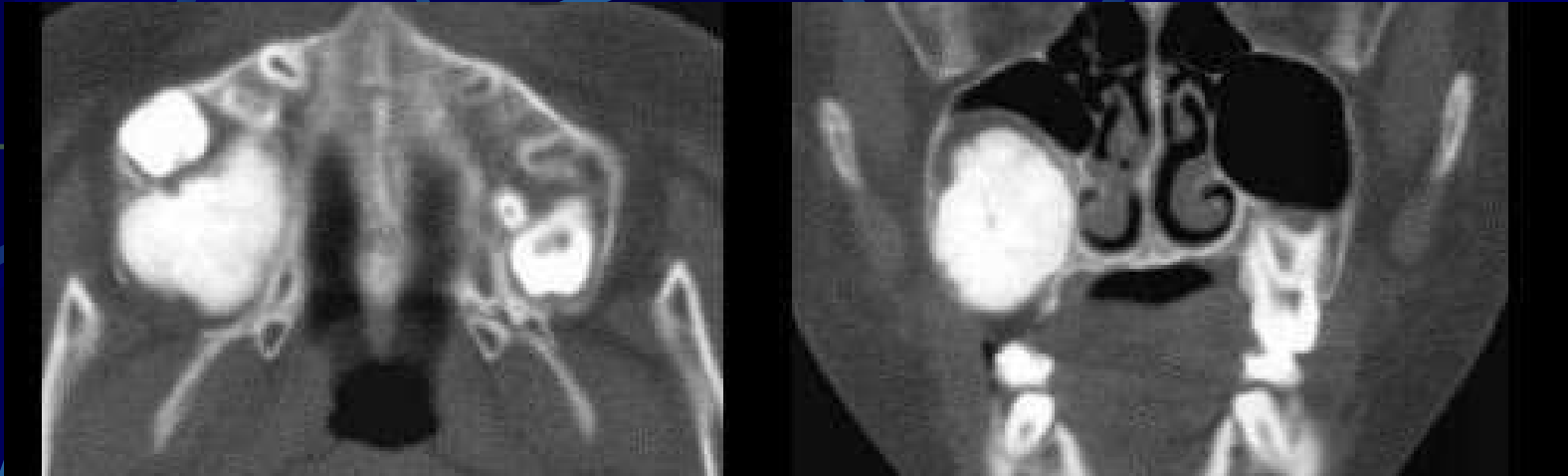


Adenolymfoma




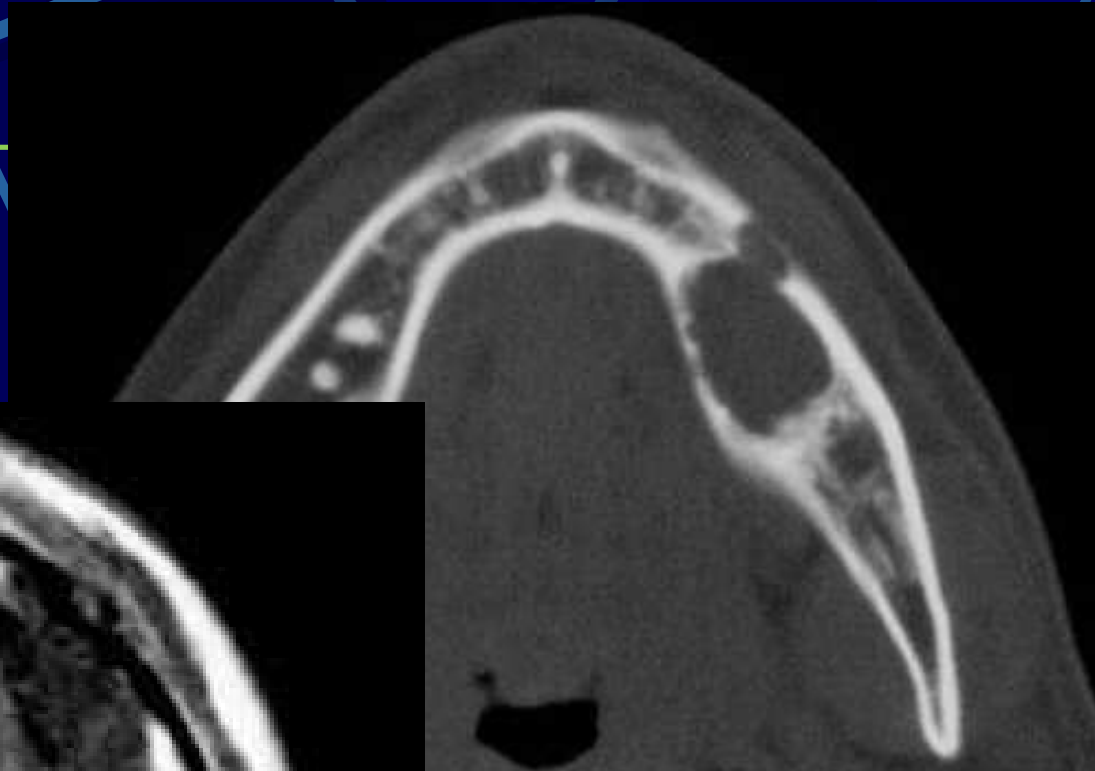
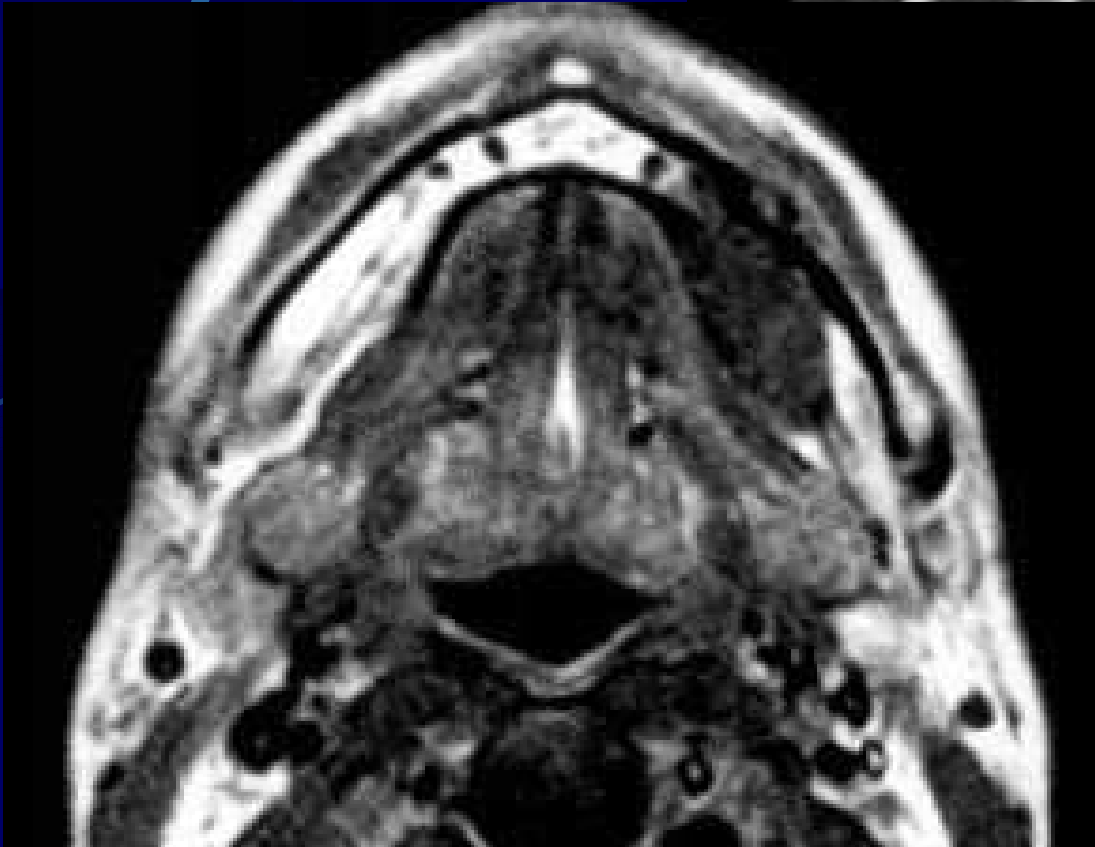


Facionmaxilární ameloblastický fibrom



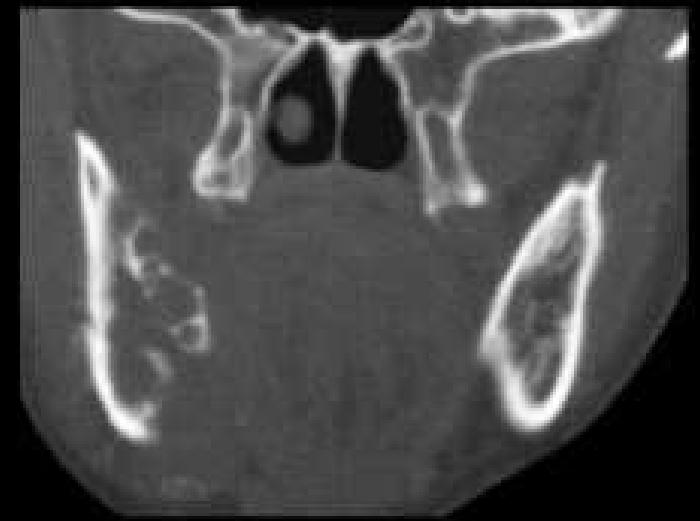
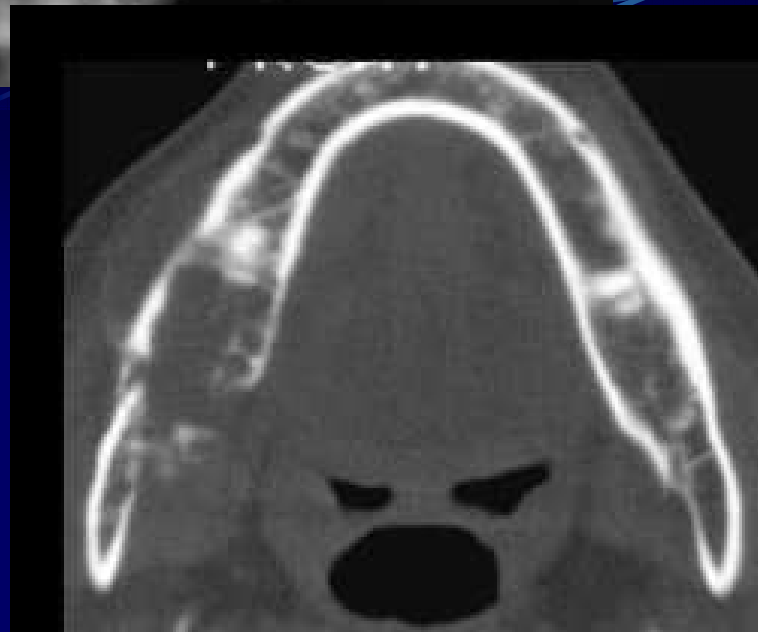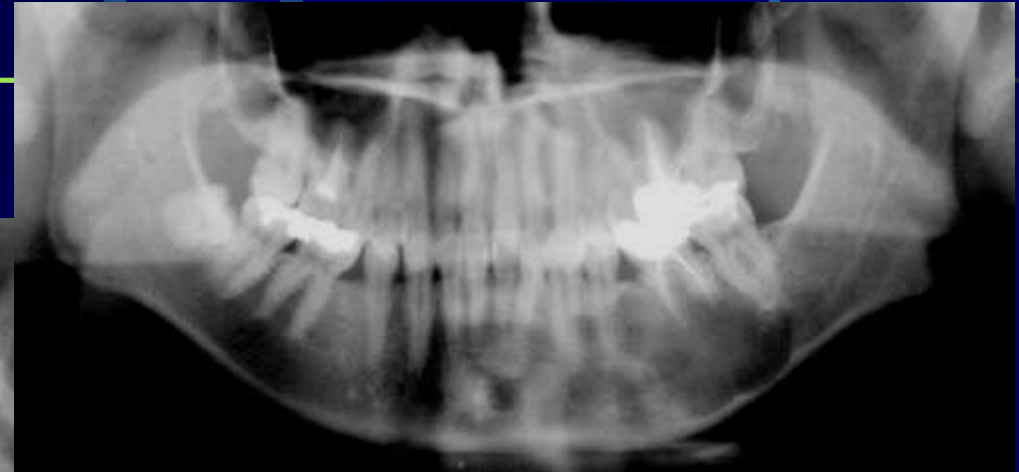

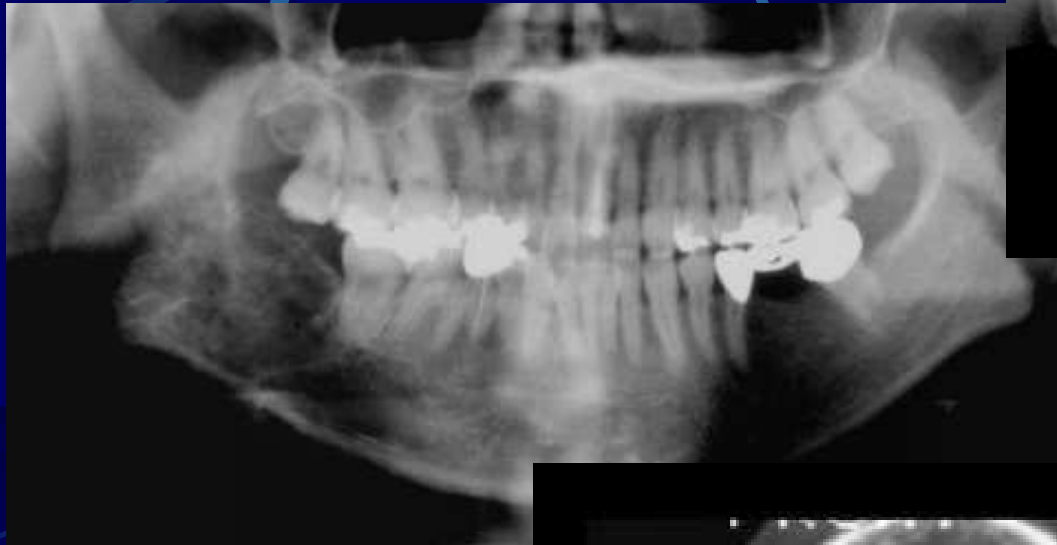
Fibrom



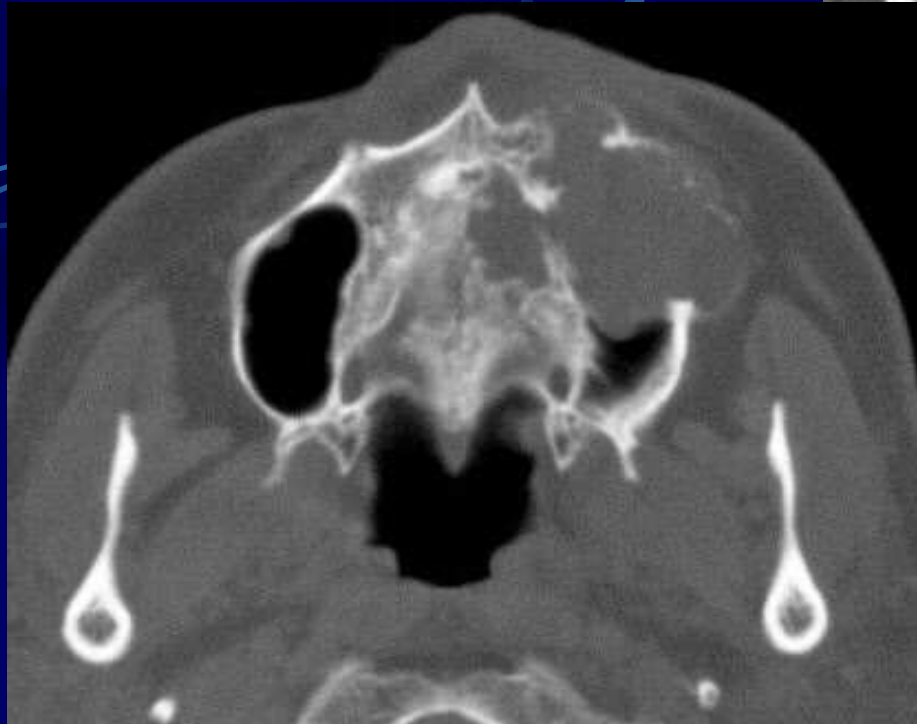
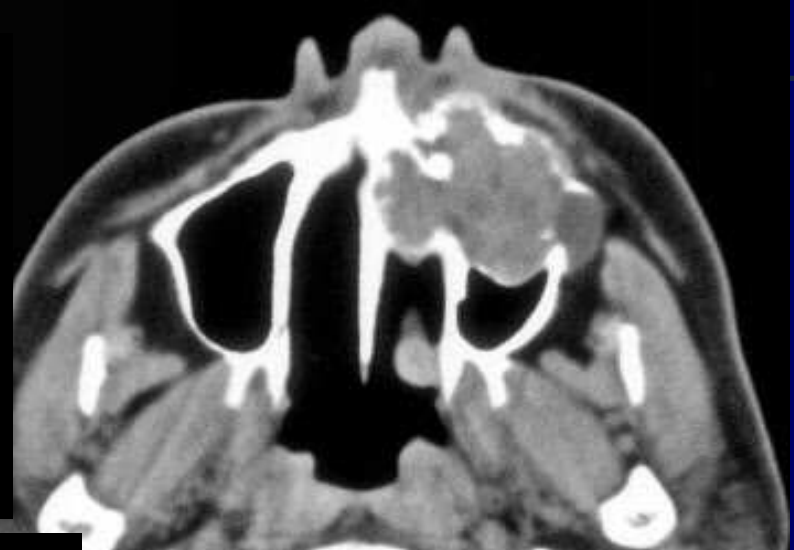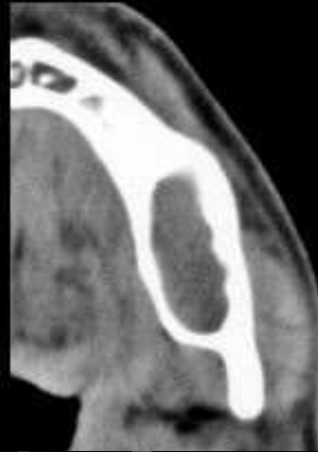
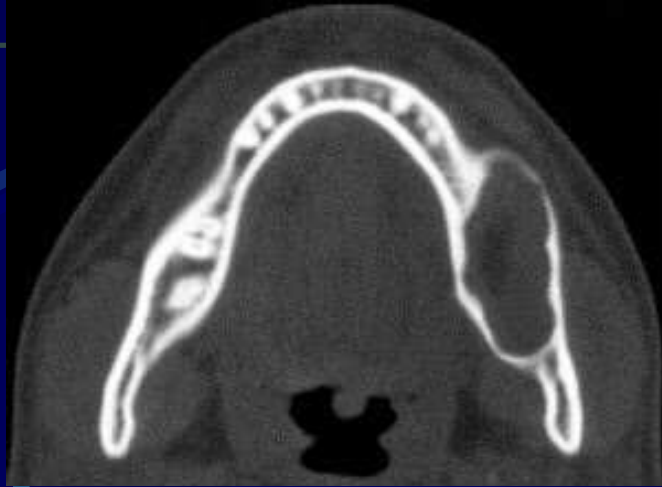



Facionmaxilární ameloblastický fibrosarkom



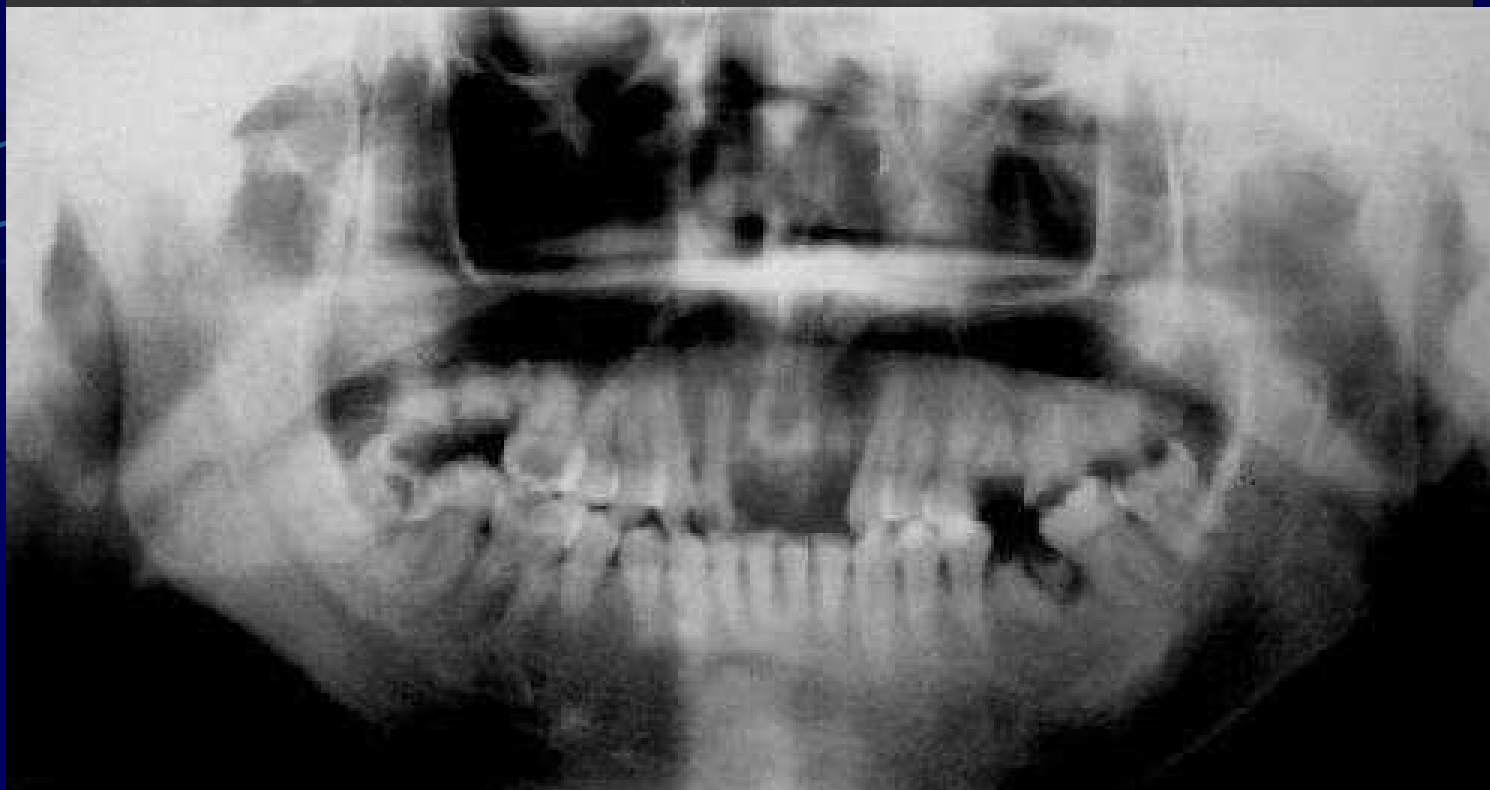
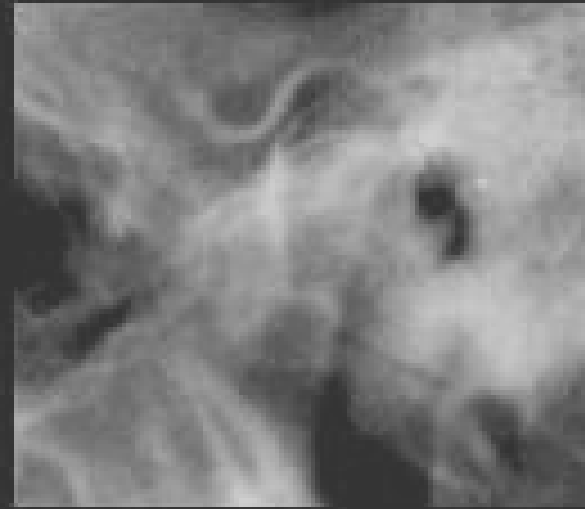
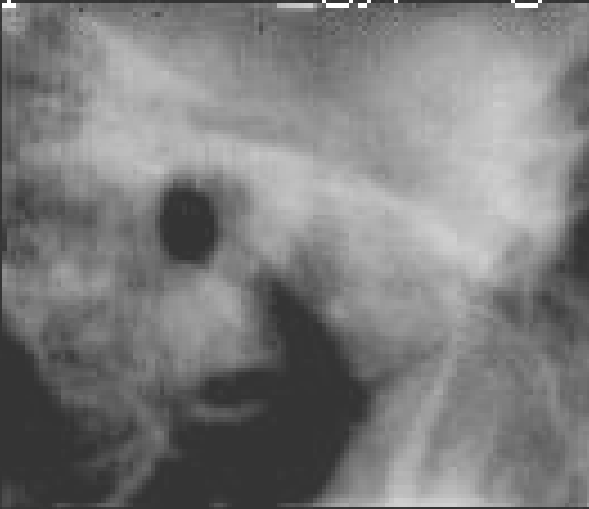
Ameloblastom



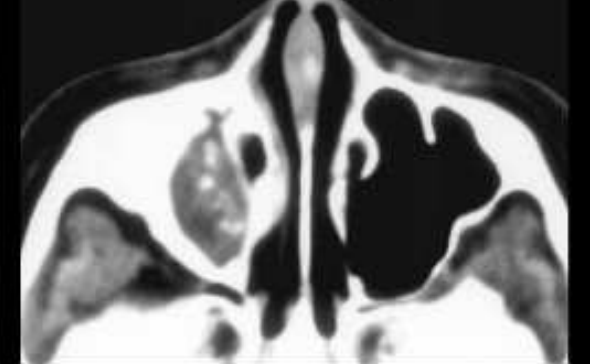
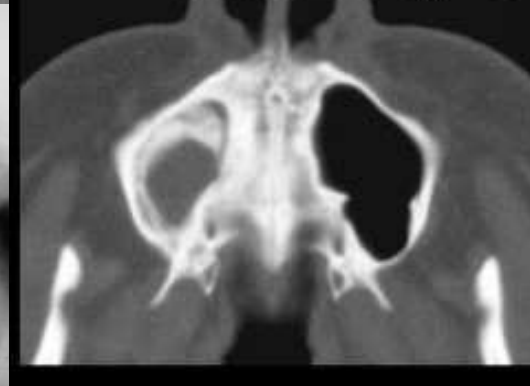
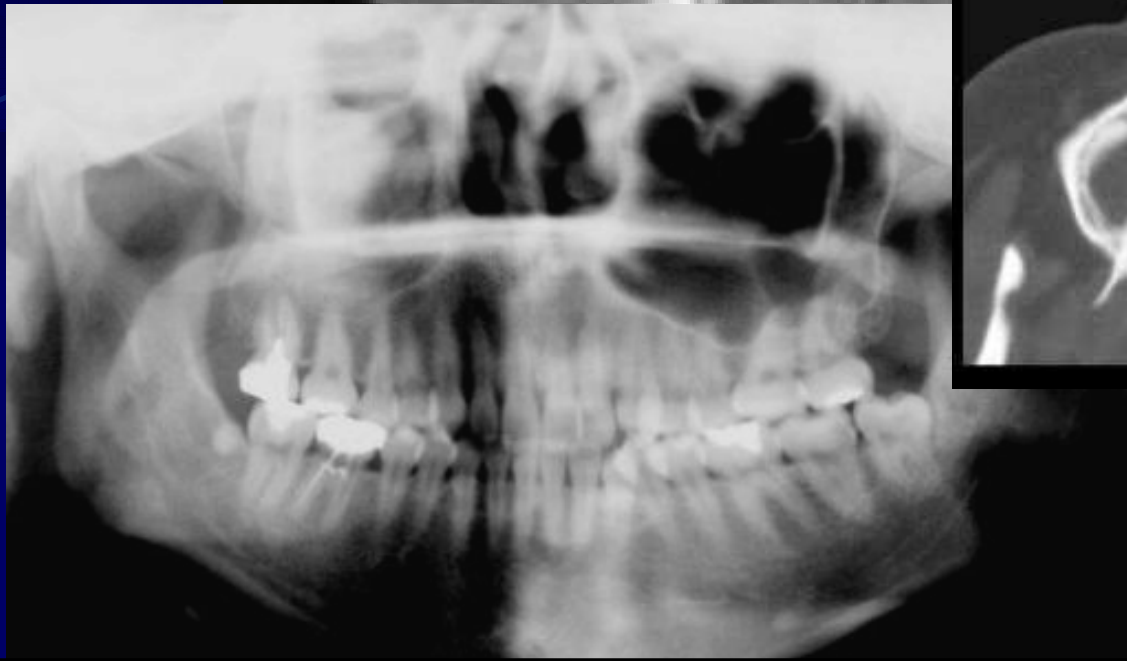
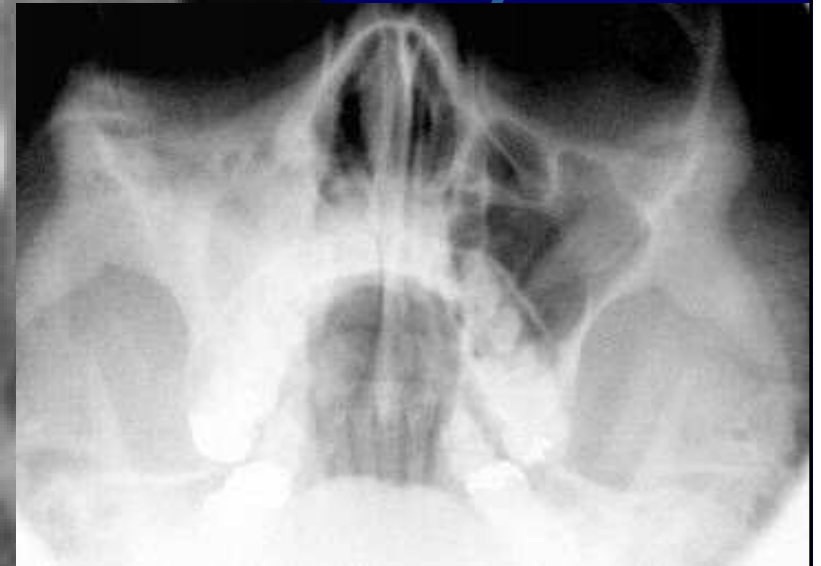
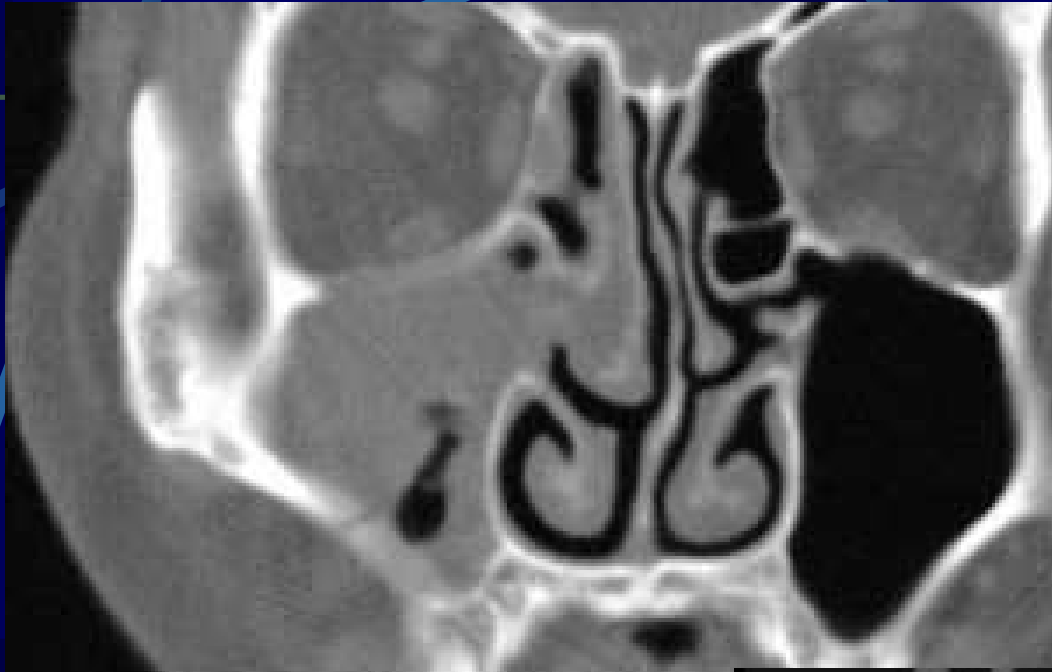
Ankylozující artritida



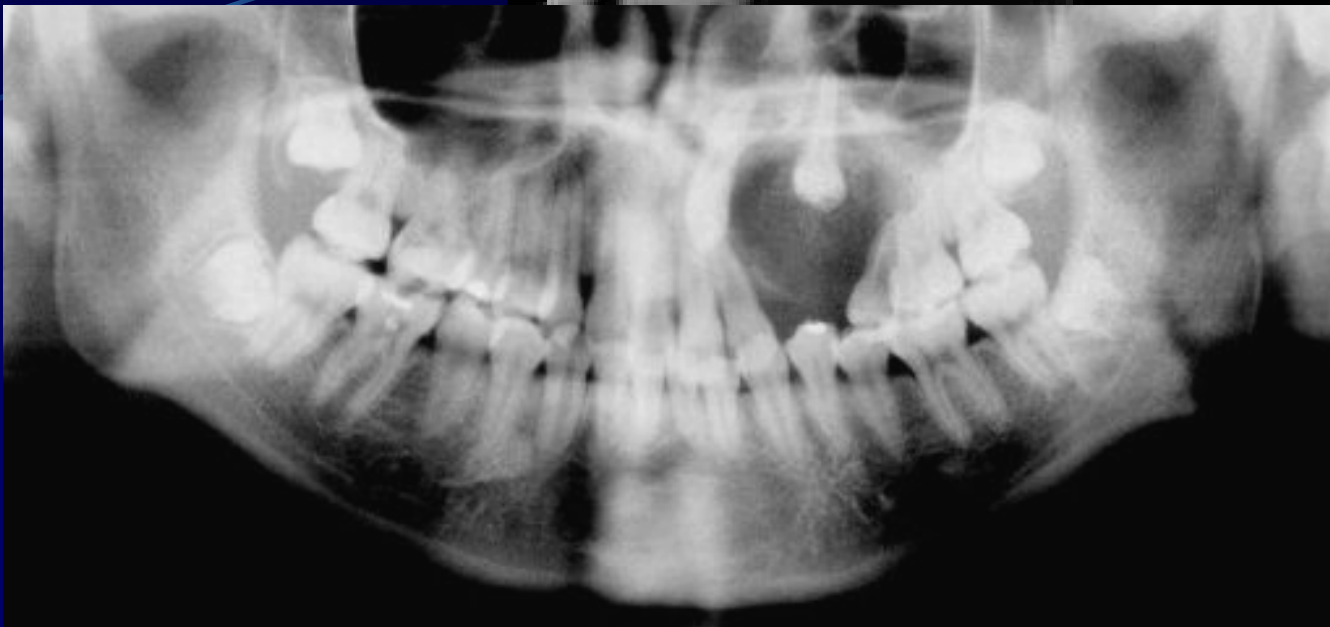
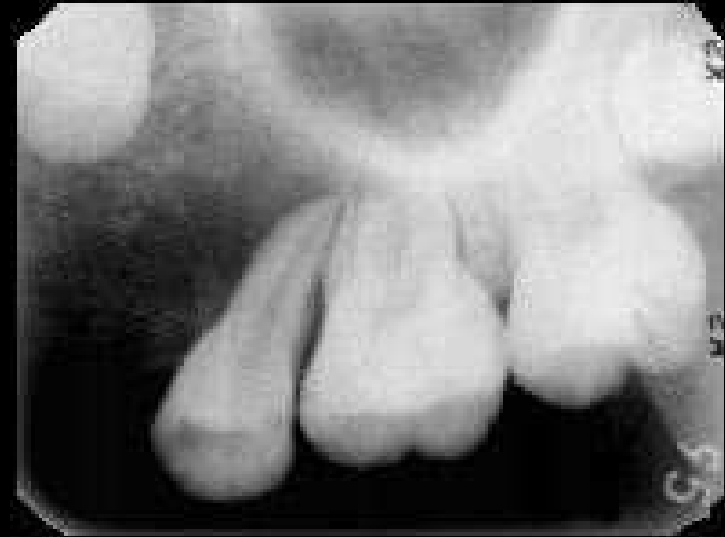
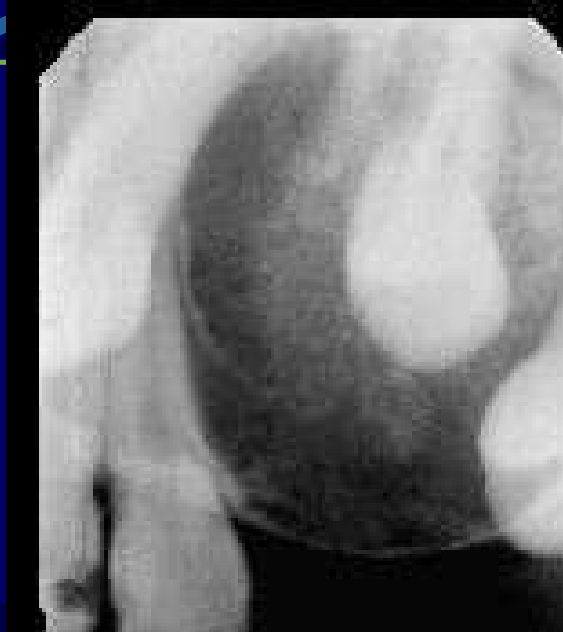Aspergilóza



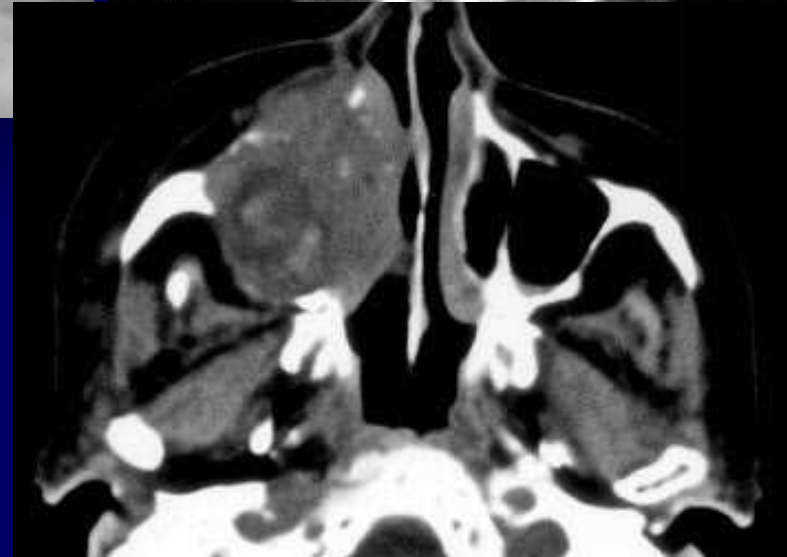
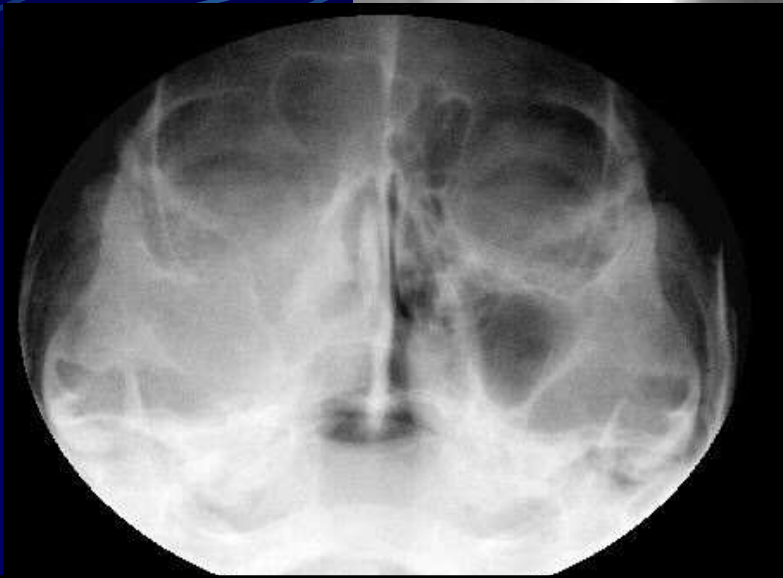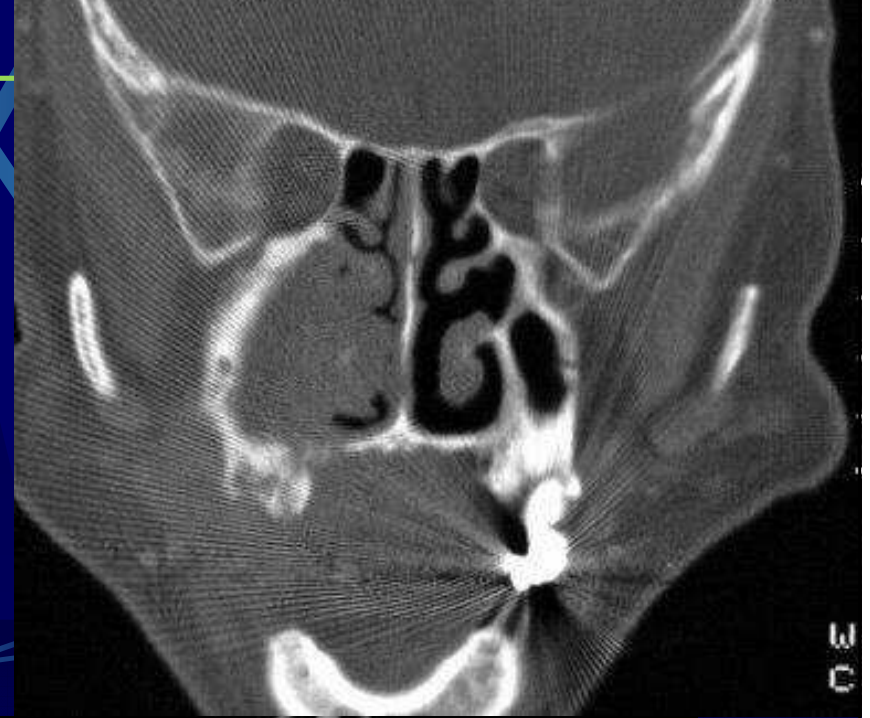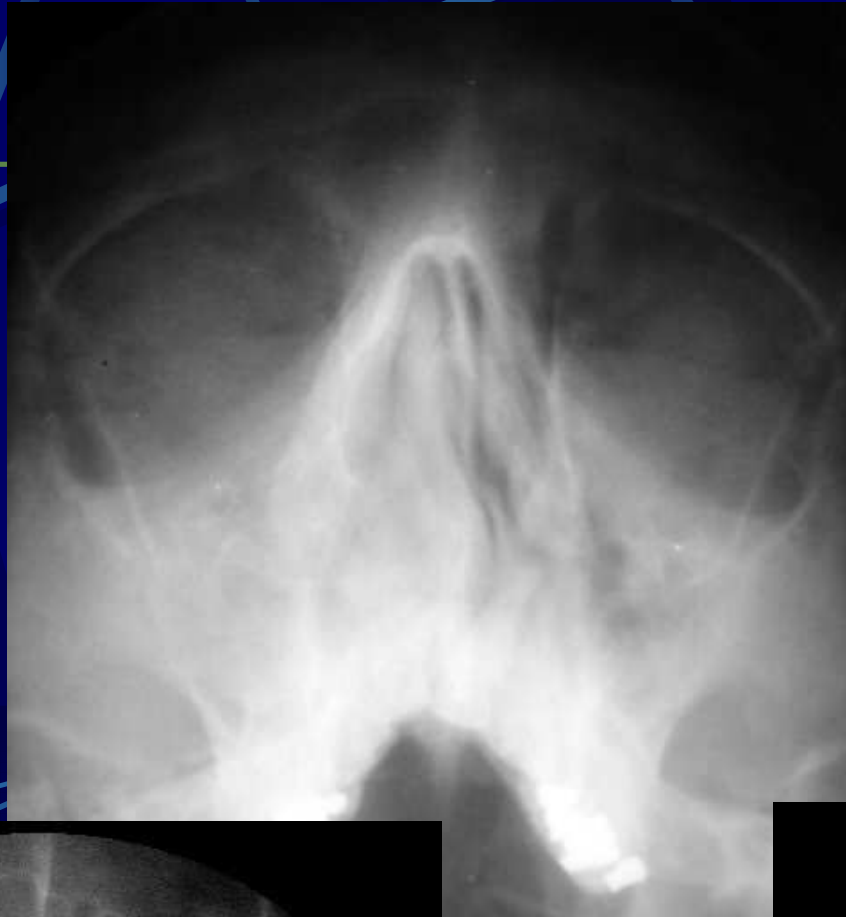



Ca – odontogenní tumor



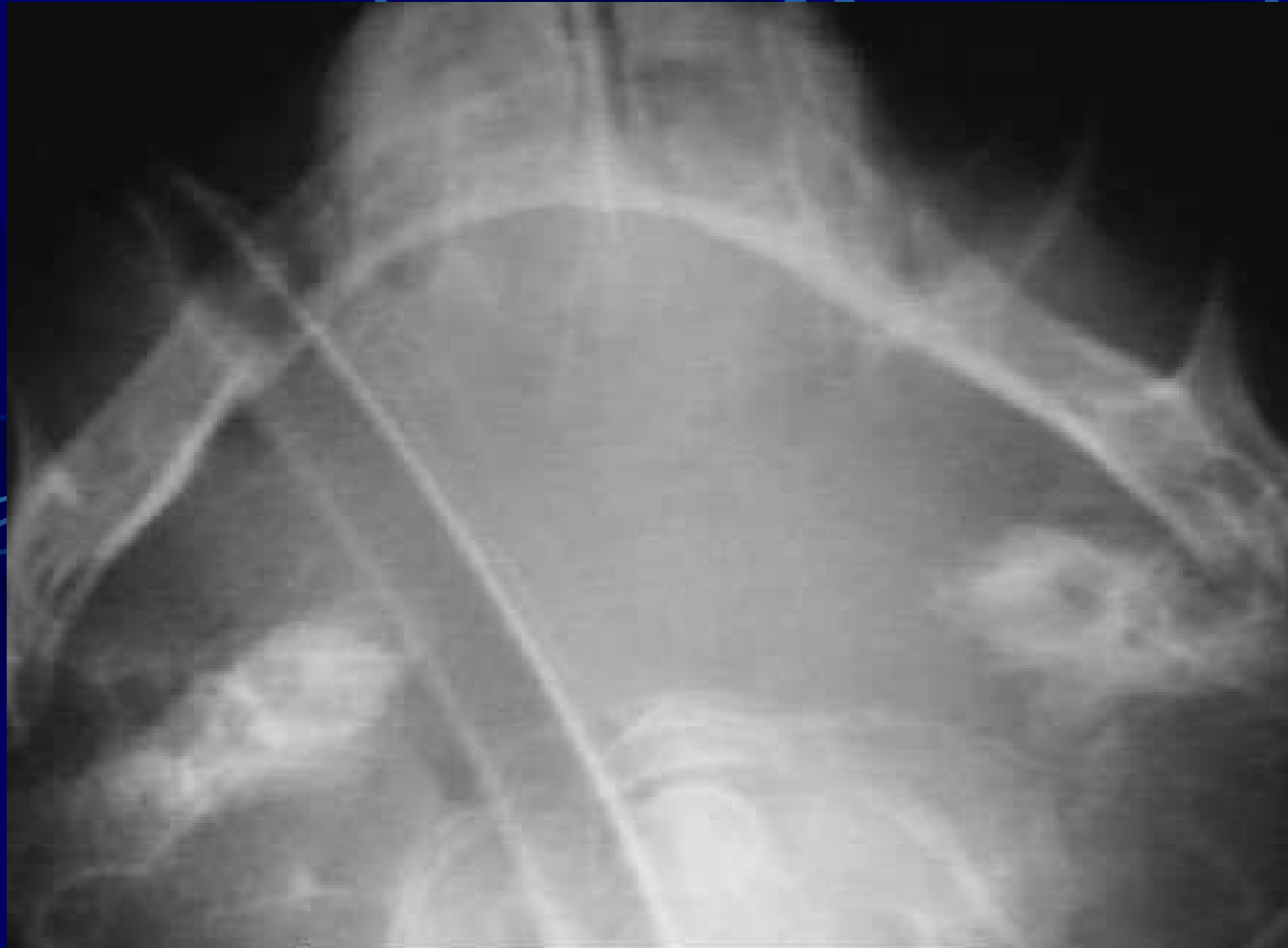


Ca maxilly



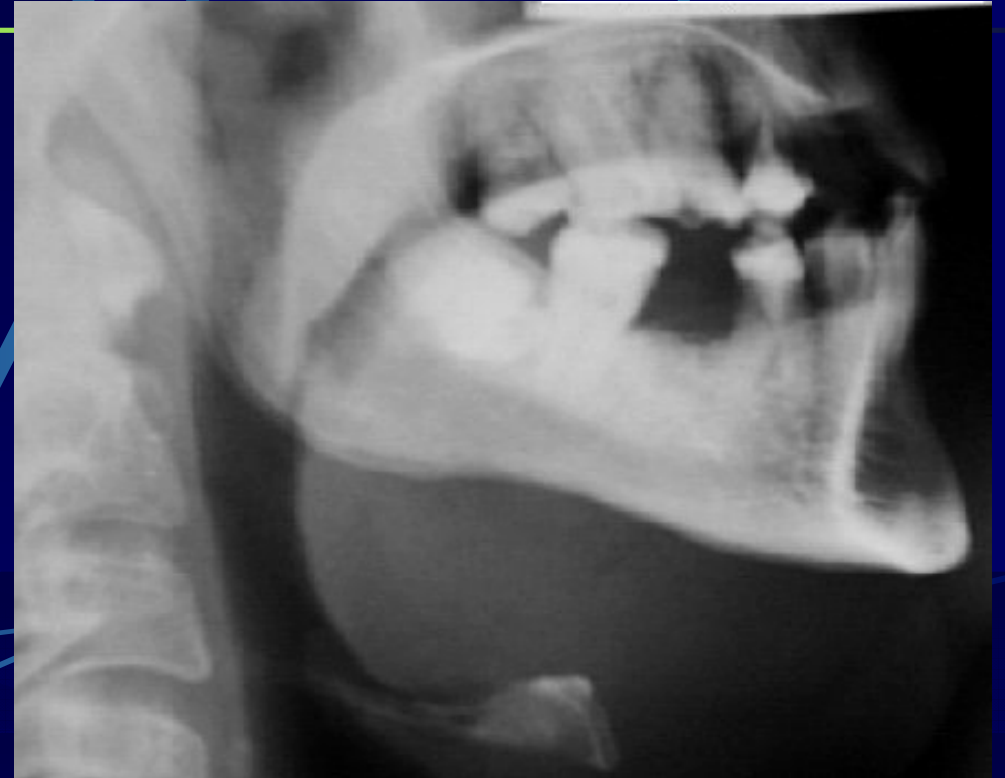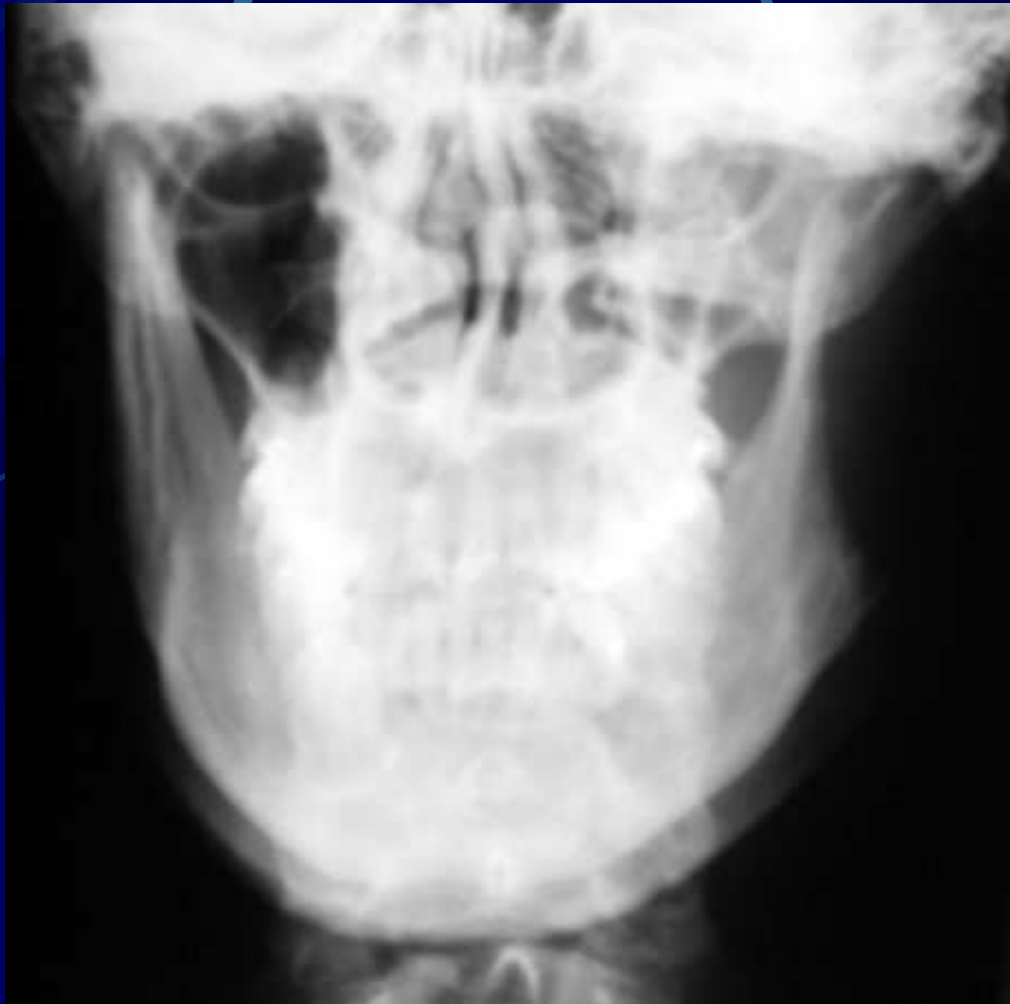


Ca nasopharyngu



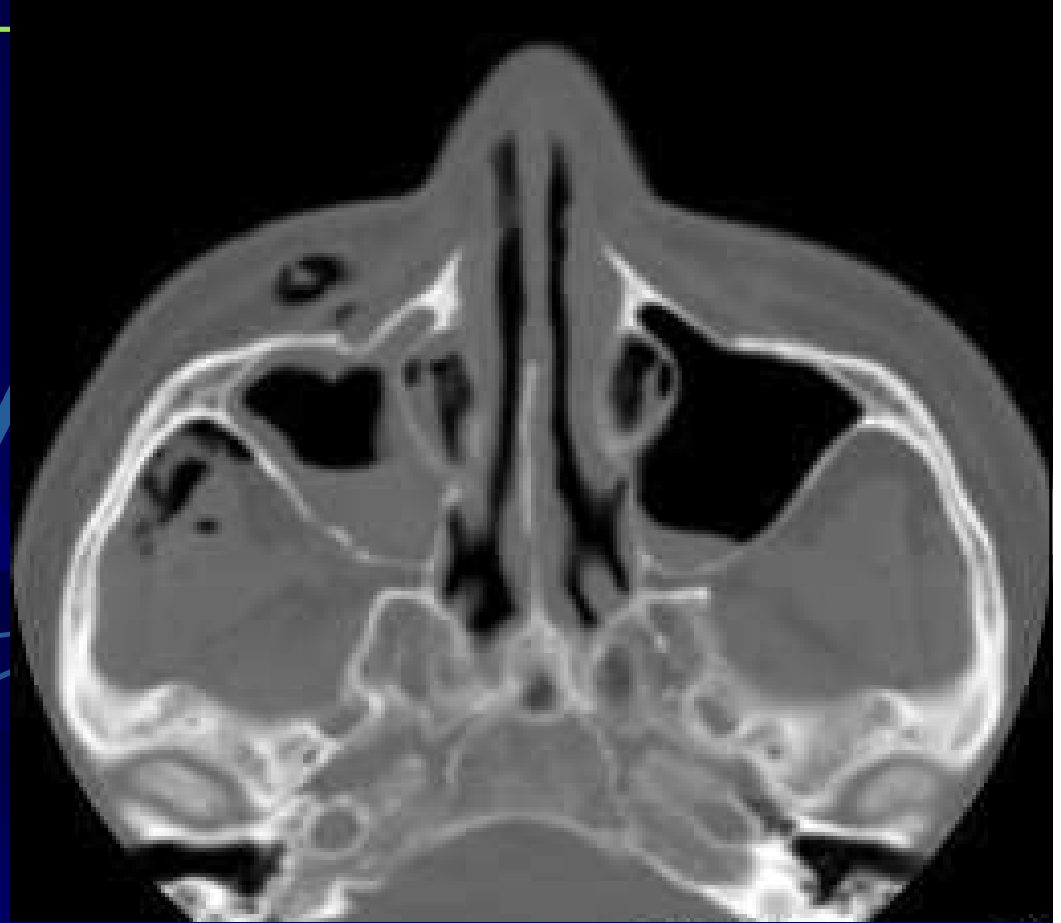
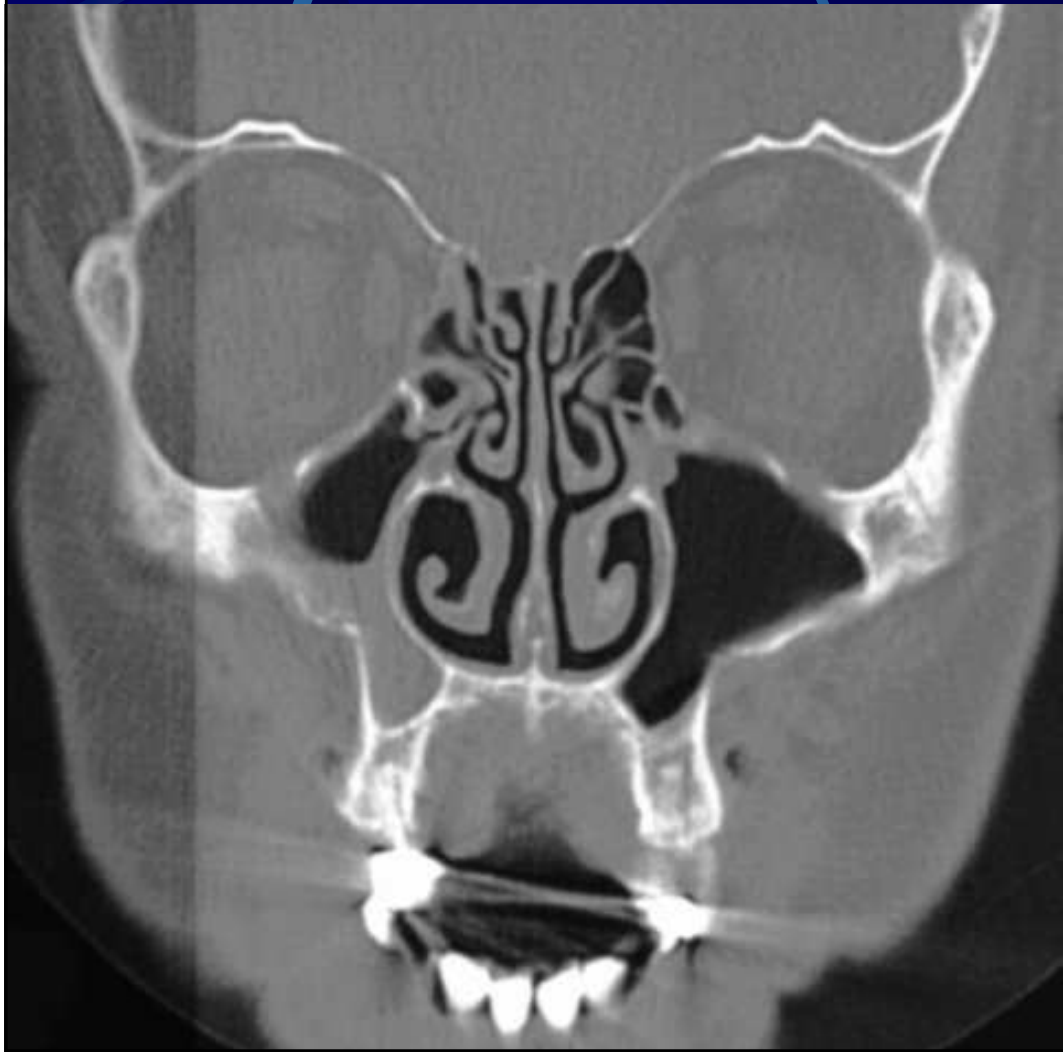


Sarcom mandibuly



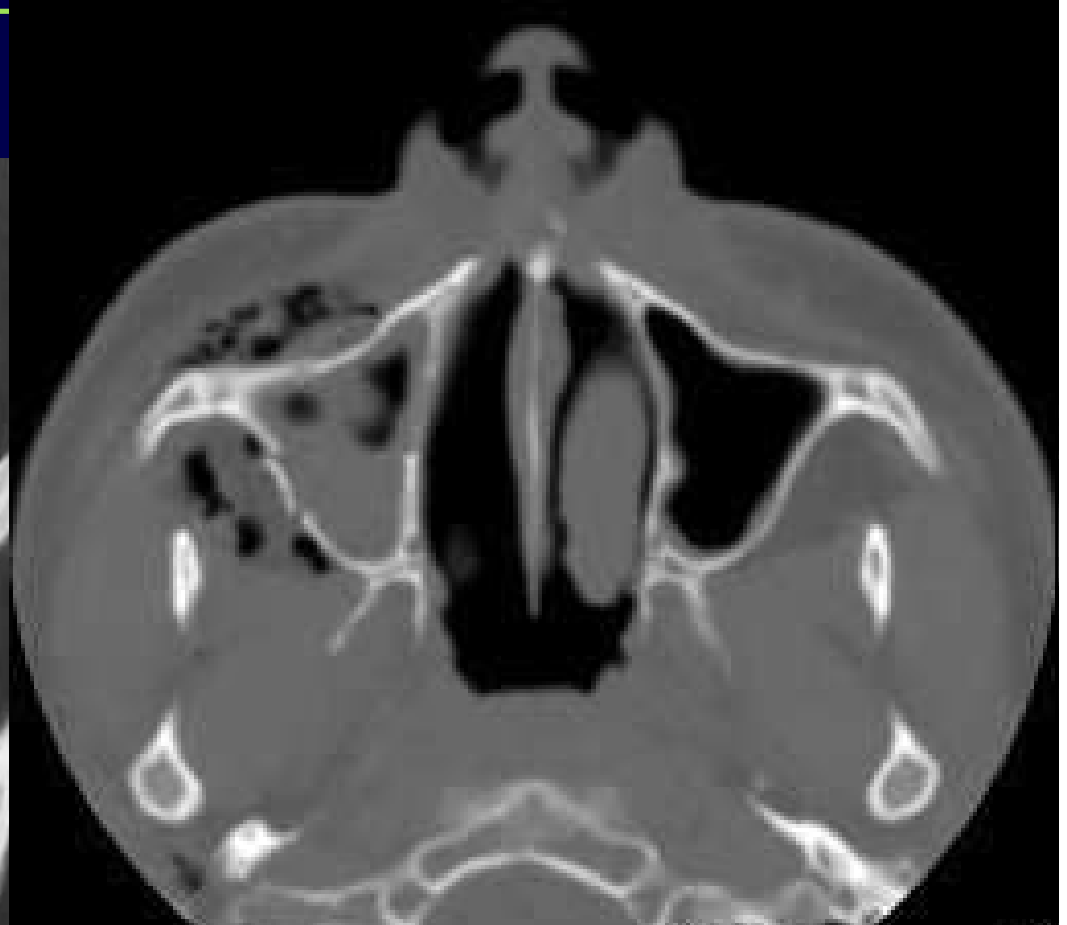
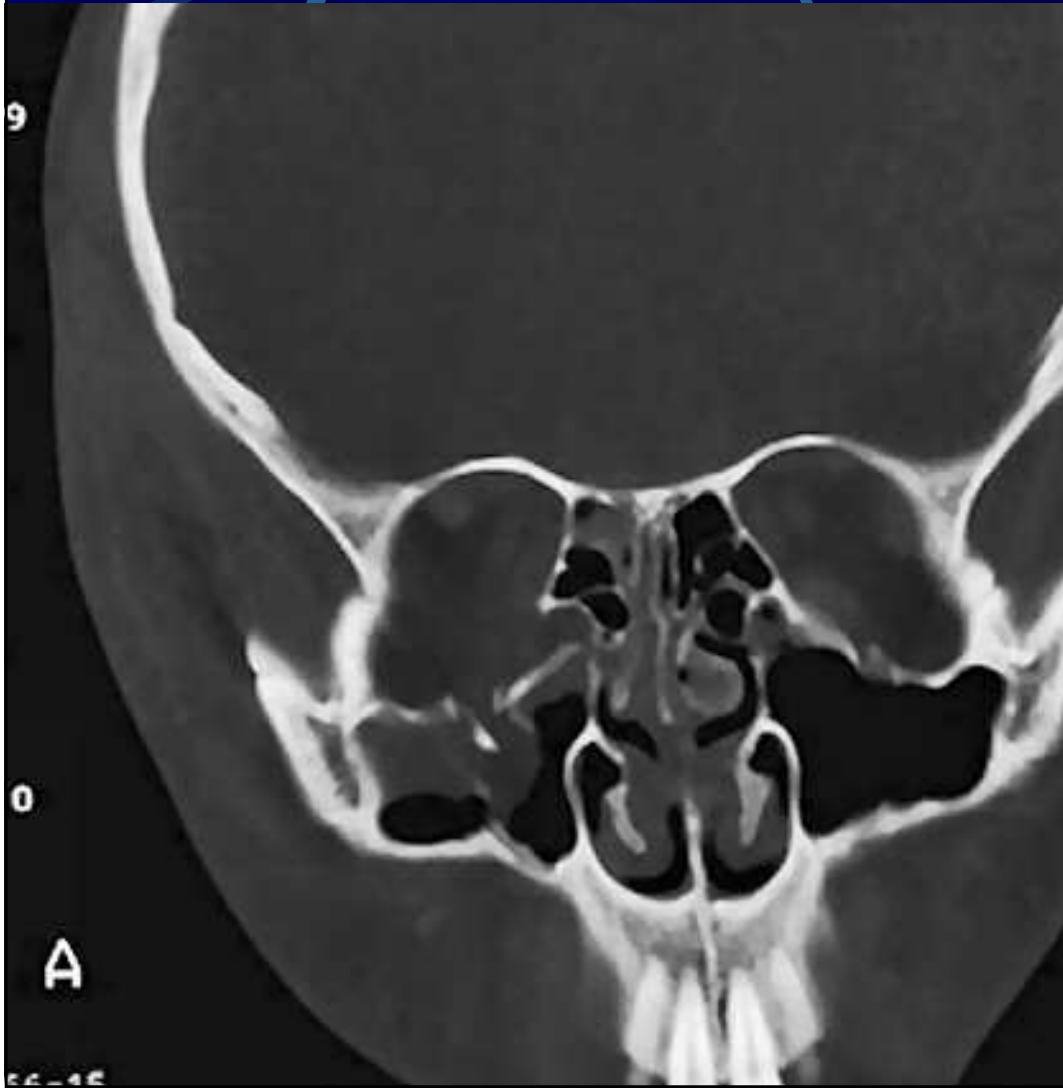

Fraktura



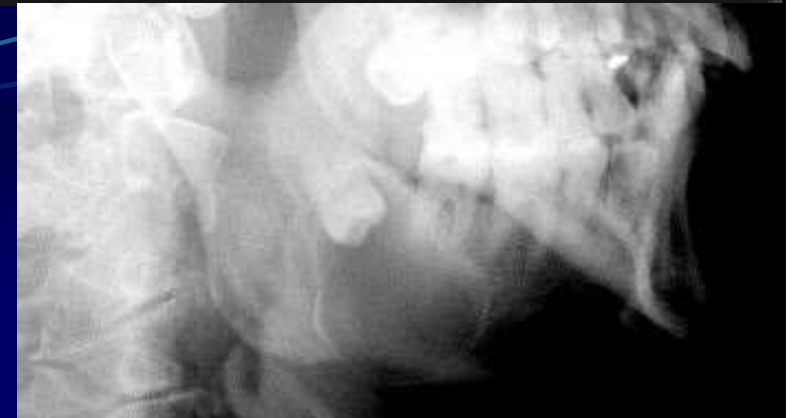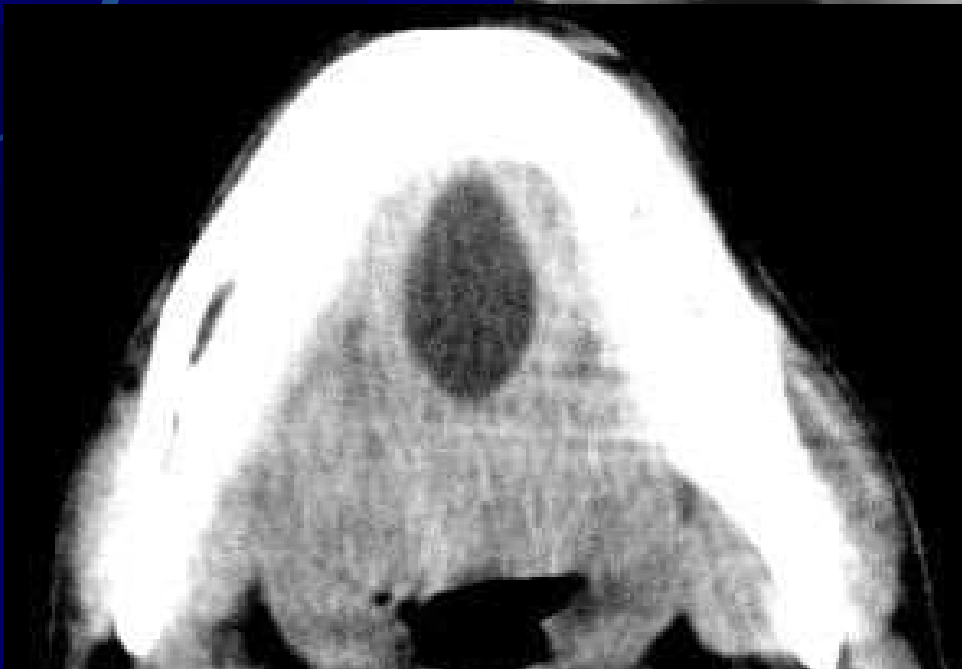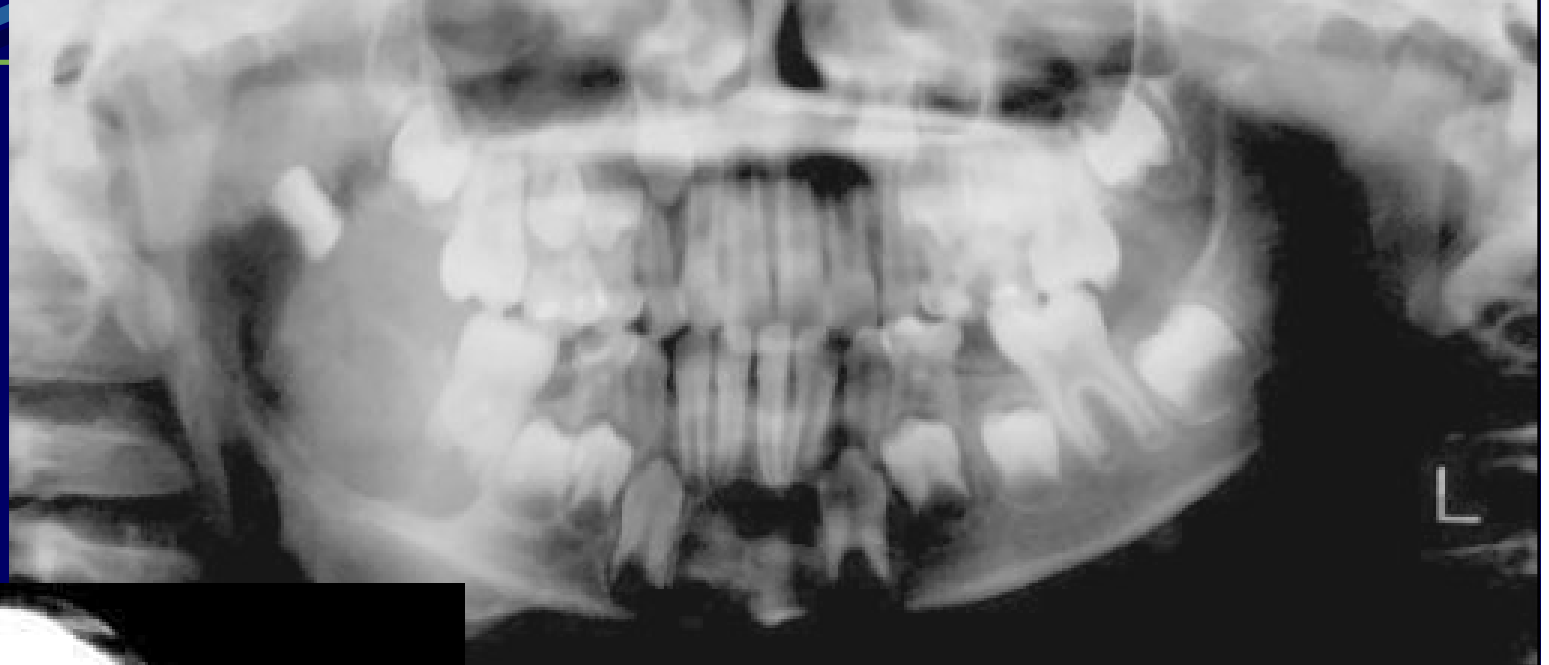



Fraktura



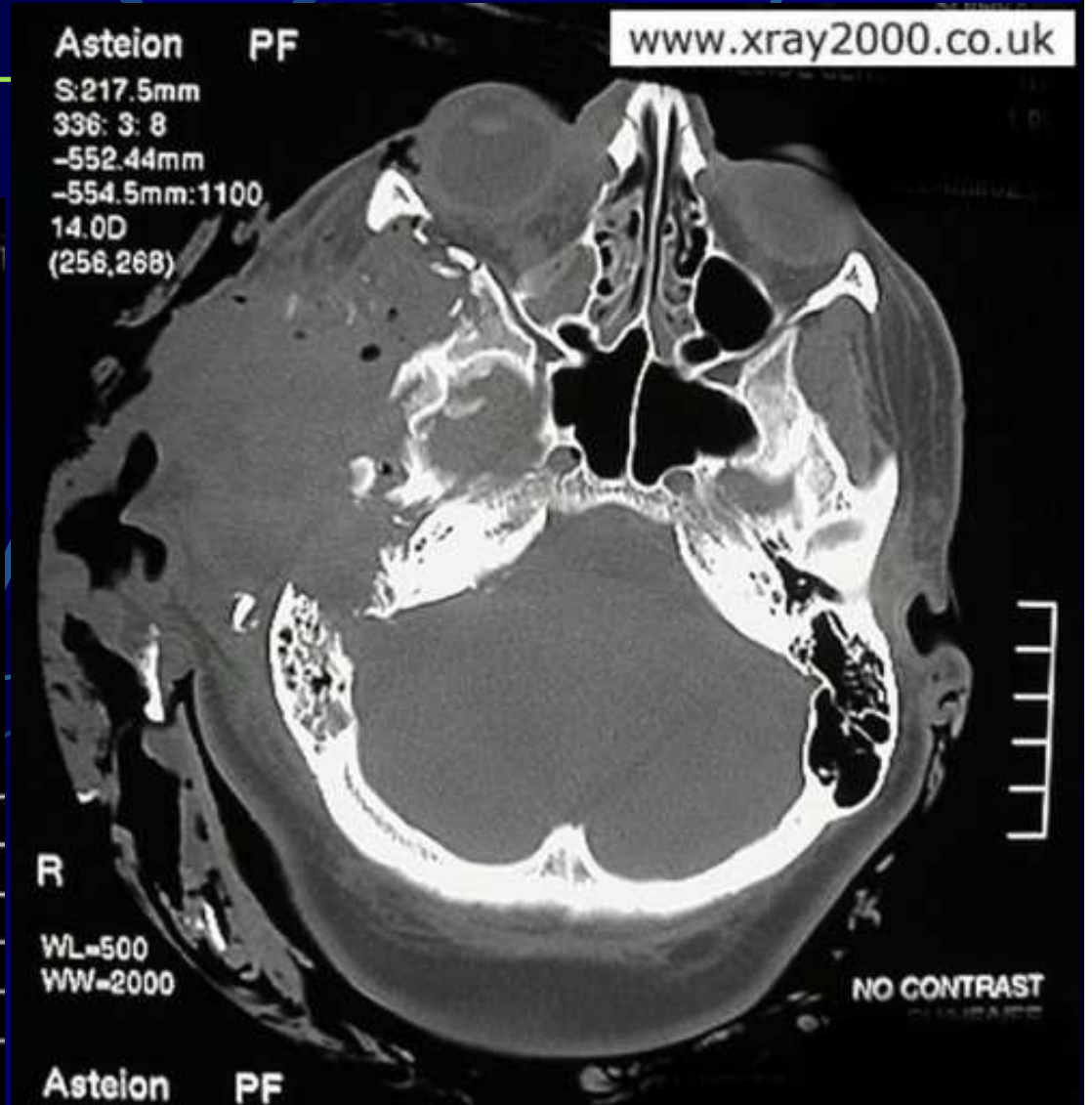
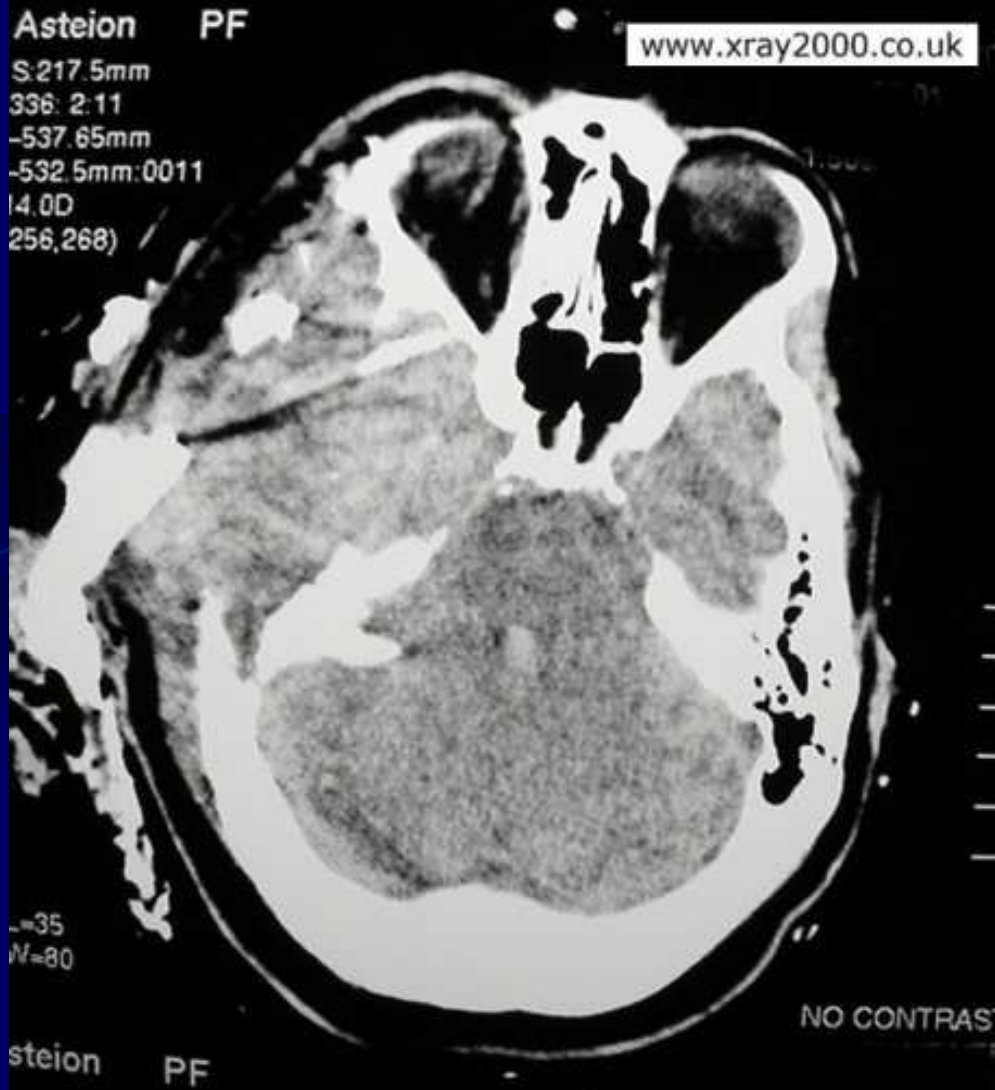


Cysta





Frantura

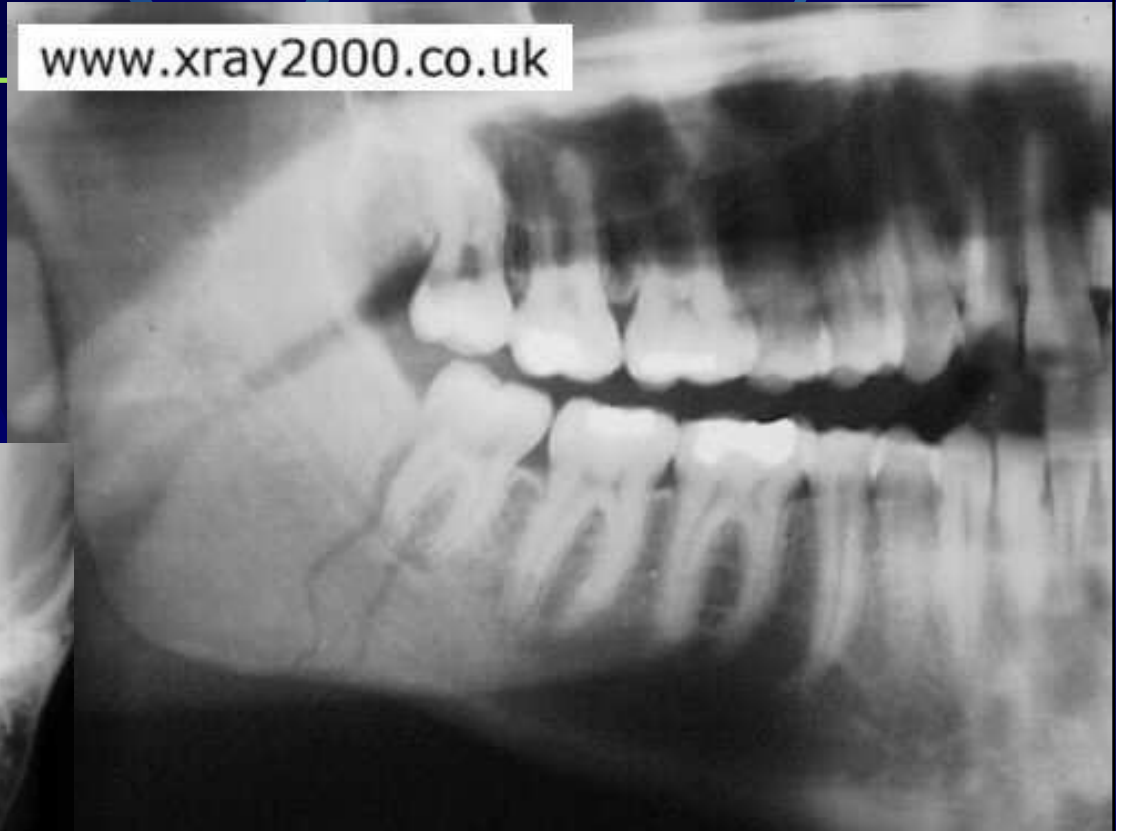



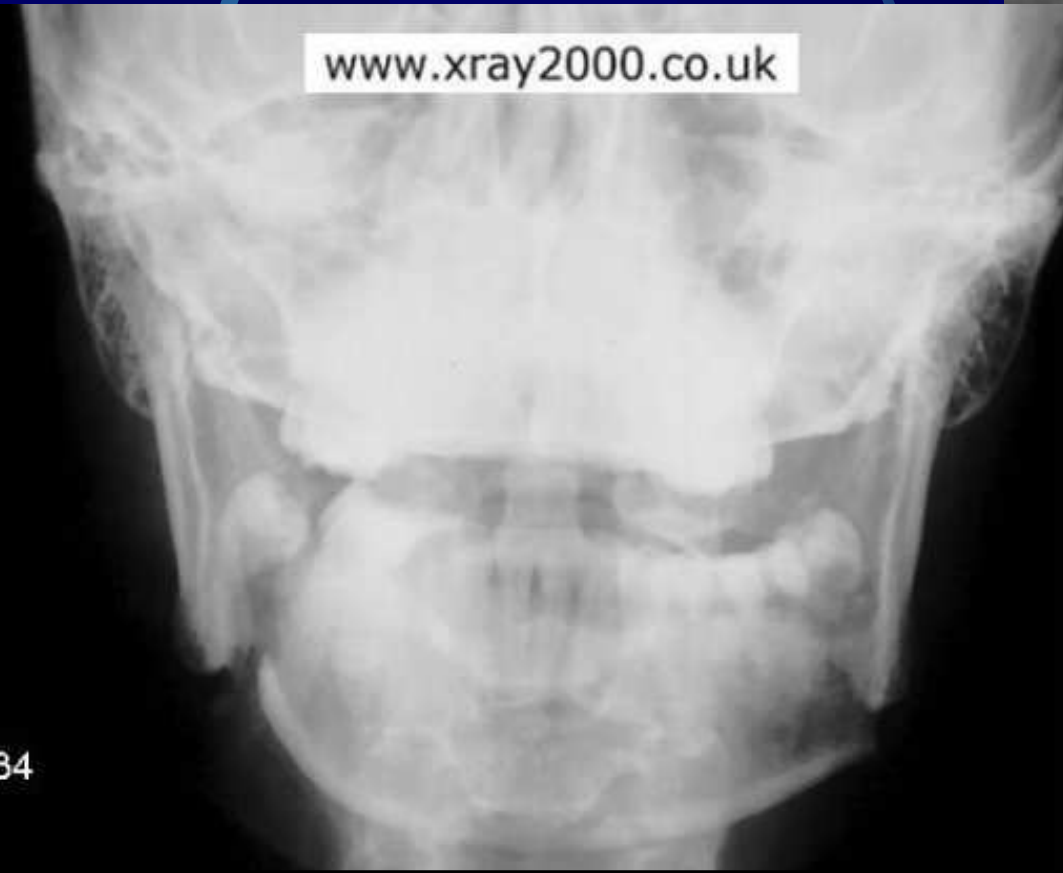Frantura



www.xray2000.co.uk



www.xray2000.co.uk

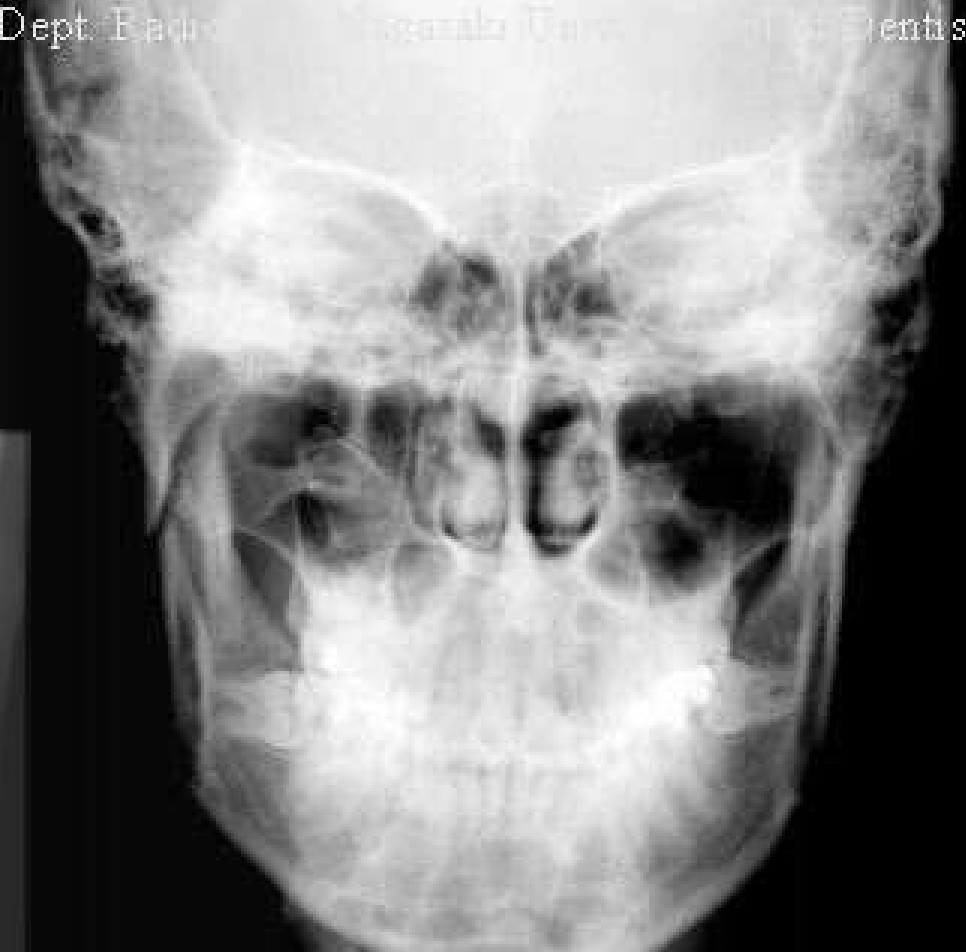



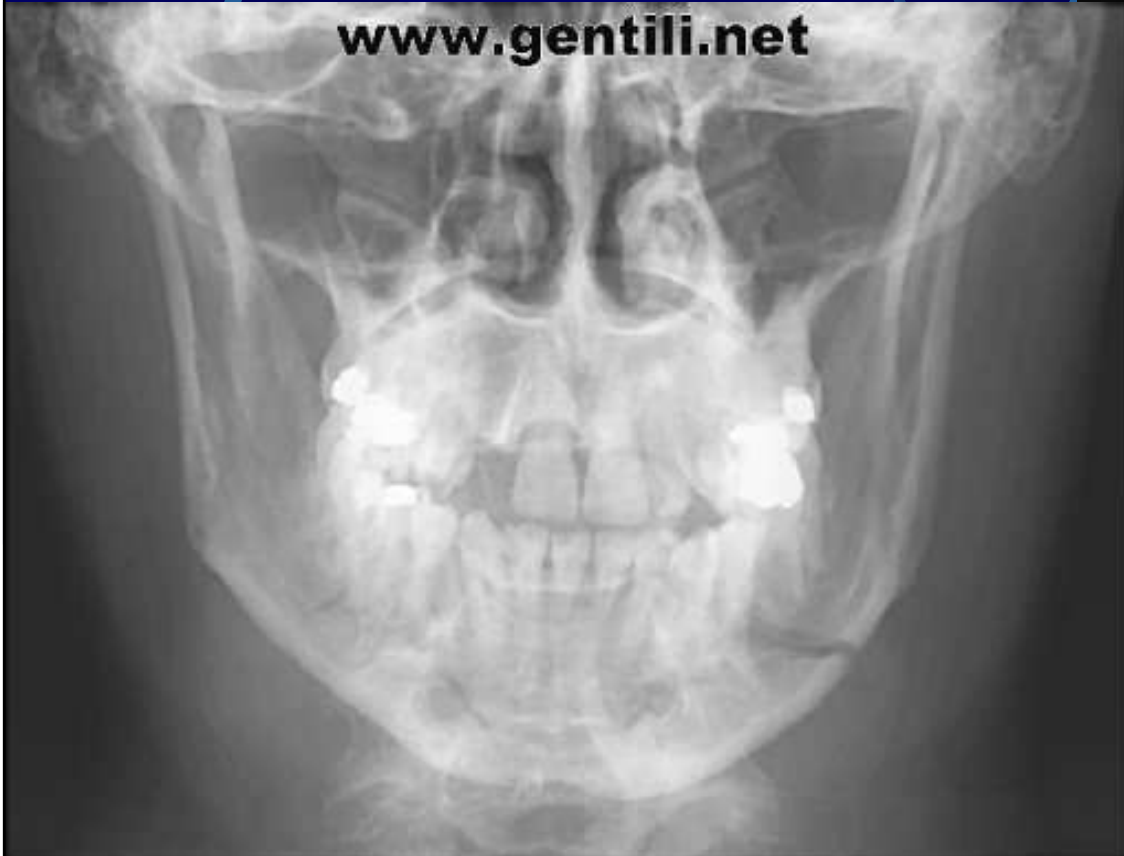Frantura



Dept. Radiology, Masaryk University Brno, Faculty of Medicine, Brno, Czech Republic



www.gentili.net

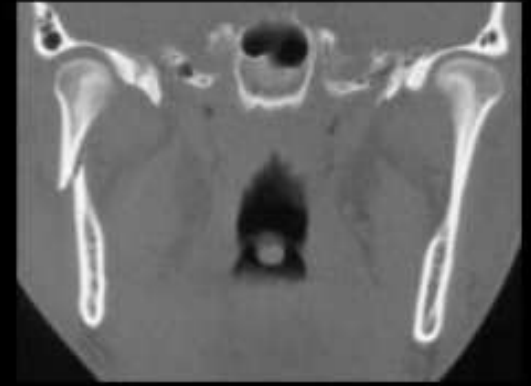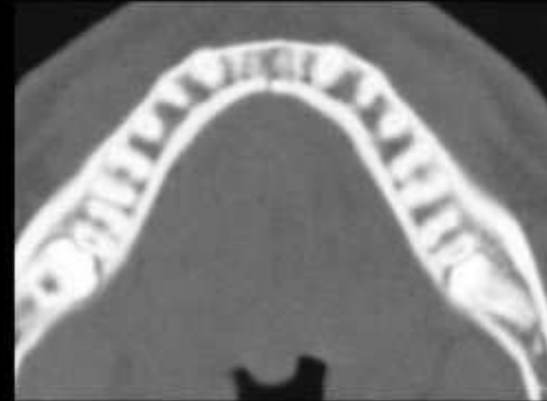

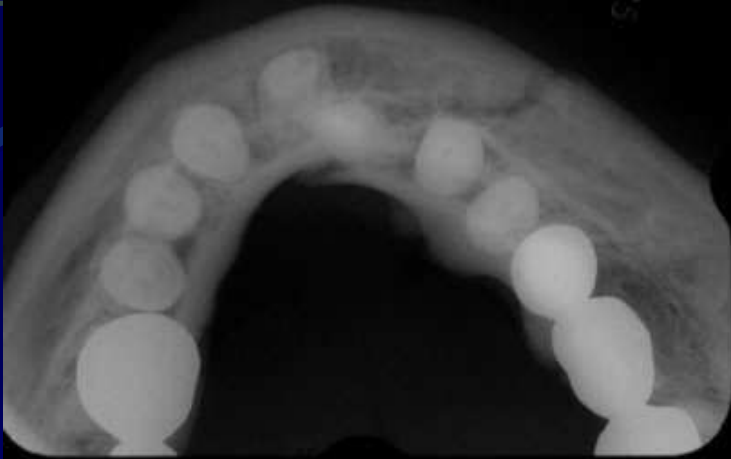


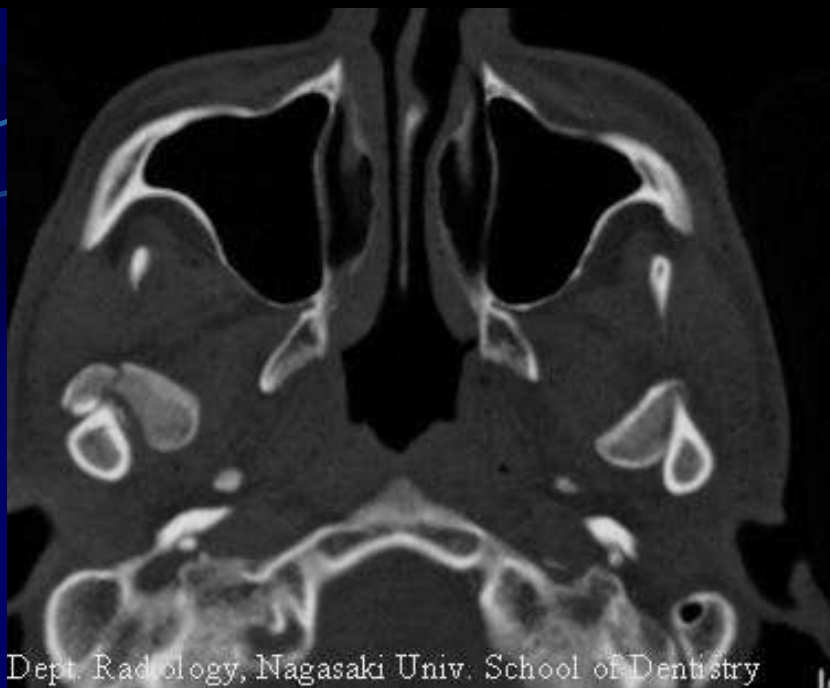
Frantura



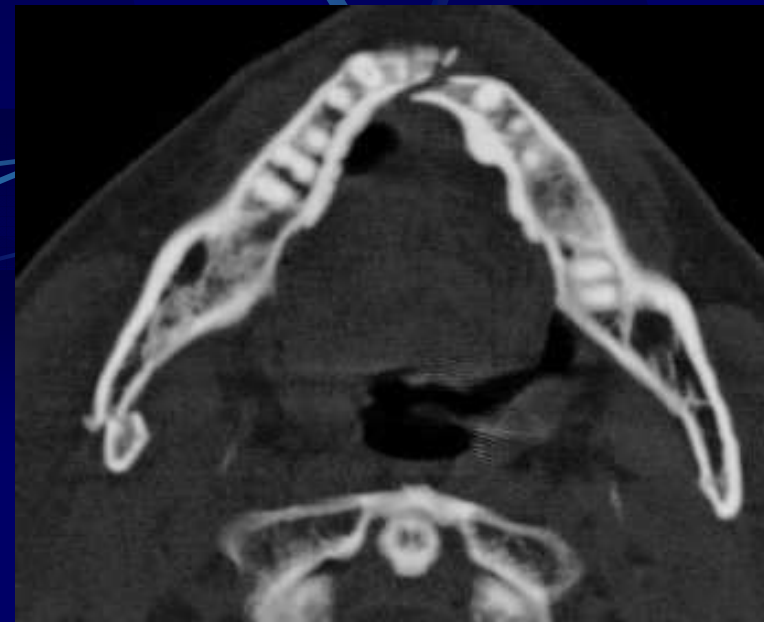
Dept. Radiology, Nagasaki Univ. School of Dentistry




Dept. Radiology, Nagasaki Univ. School of Dentistry



Dept. Radiology, Nagasaki Univ. School of Dentistry

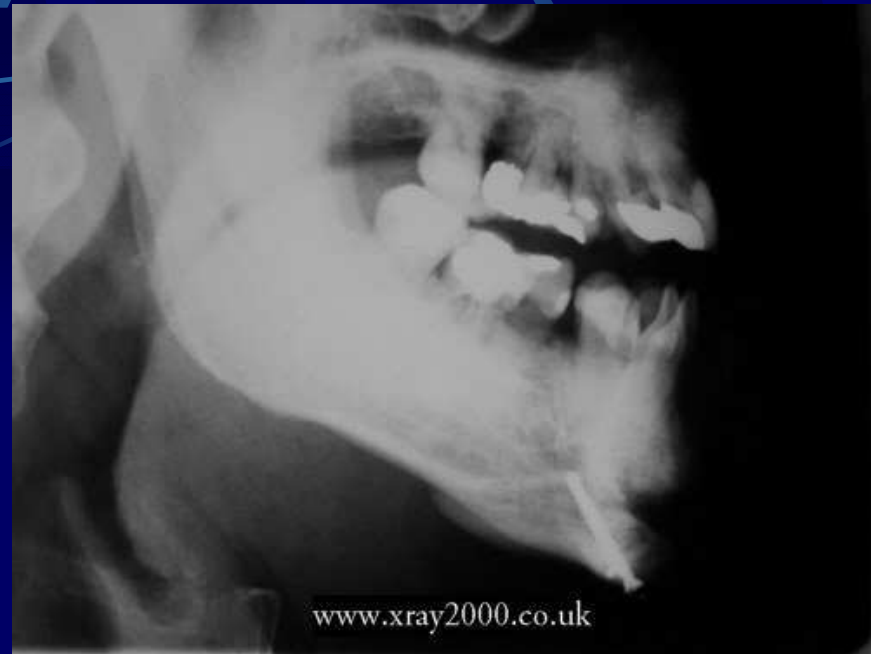
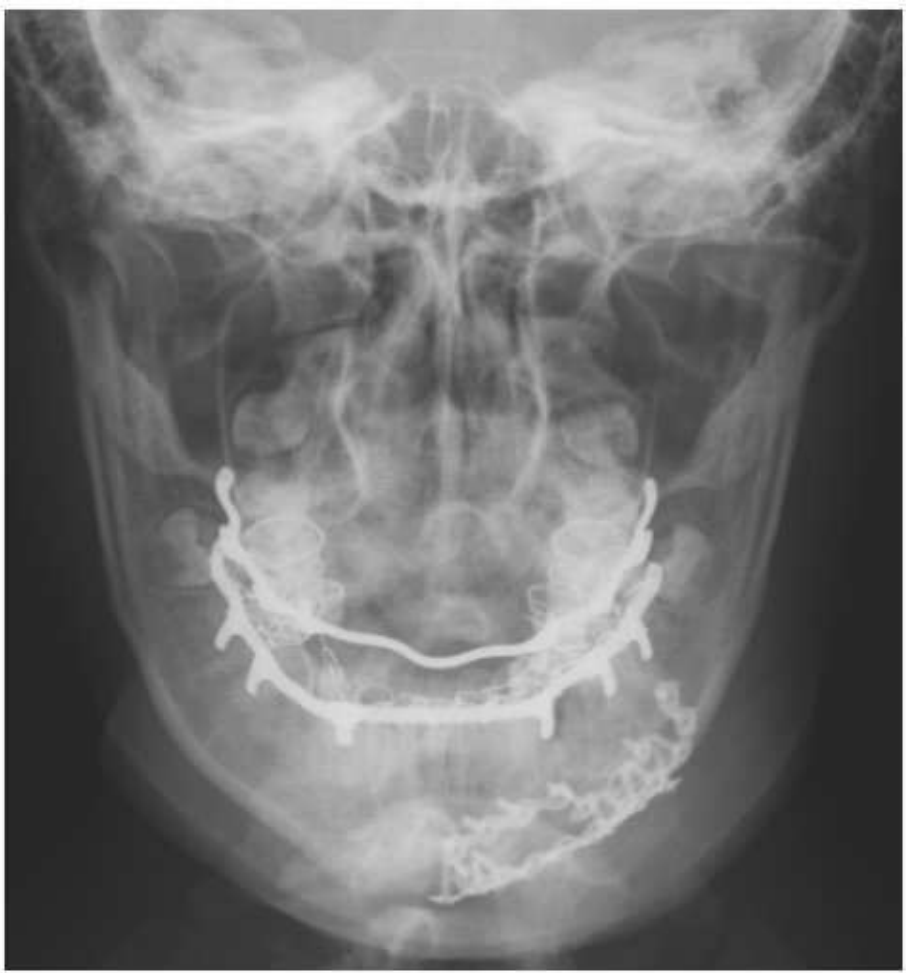
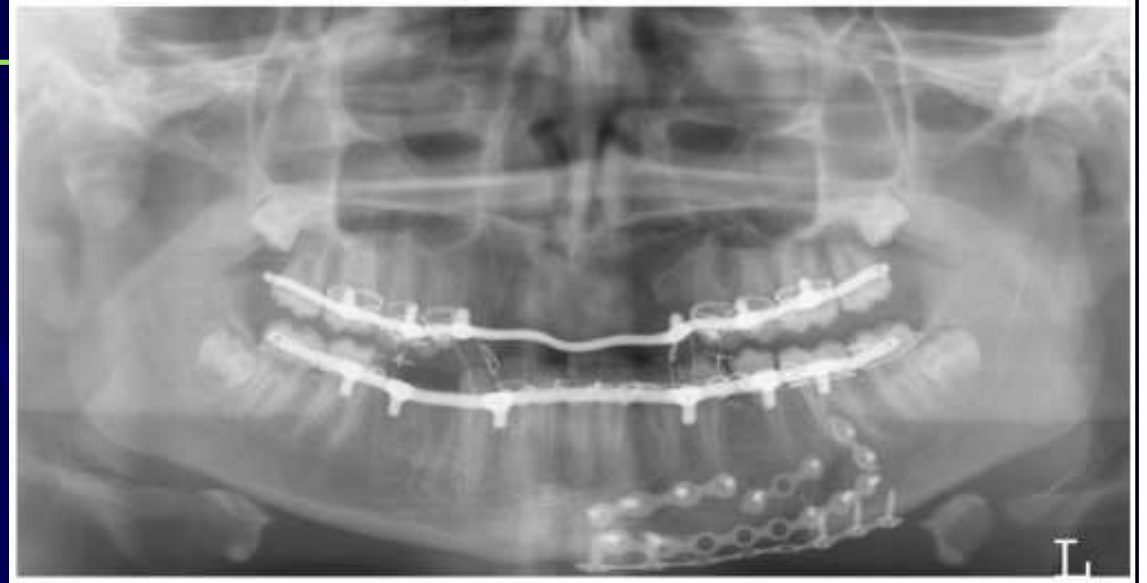Dept. Radiology, Nagasaki Univ. School of Dentistry





Frantura

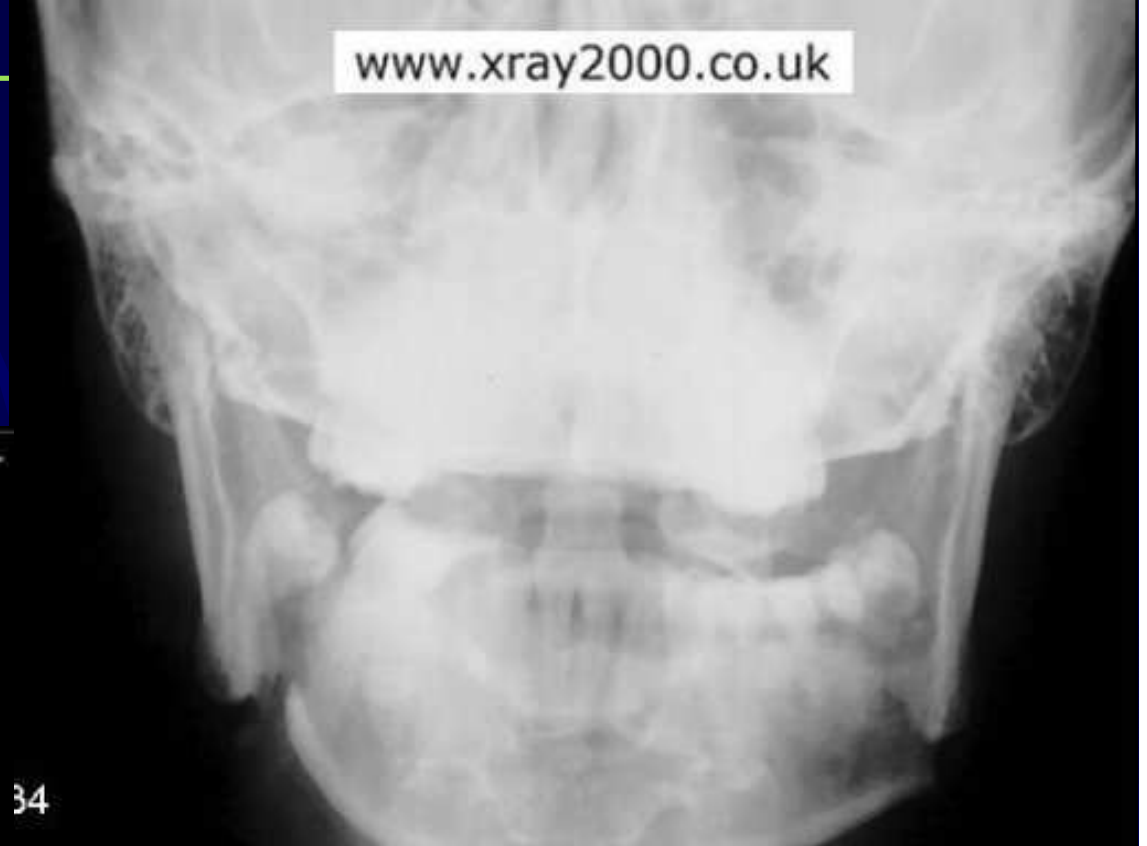



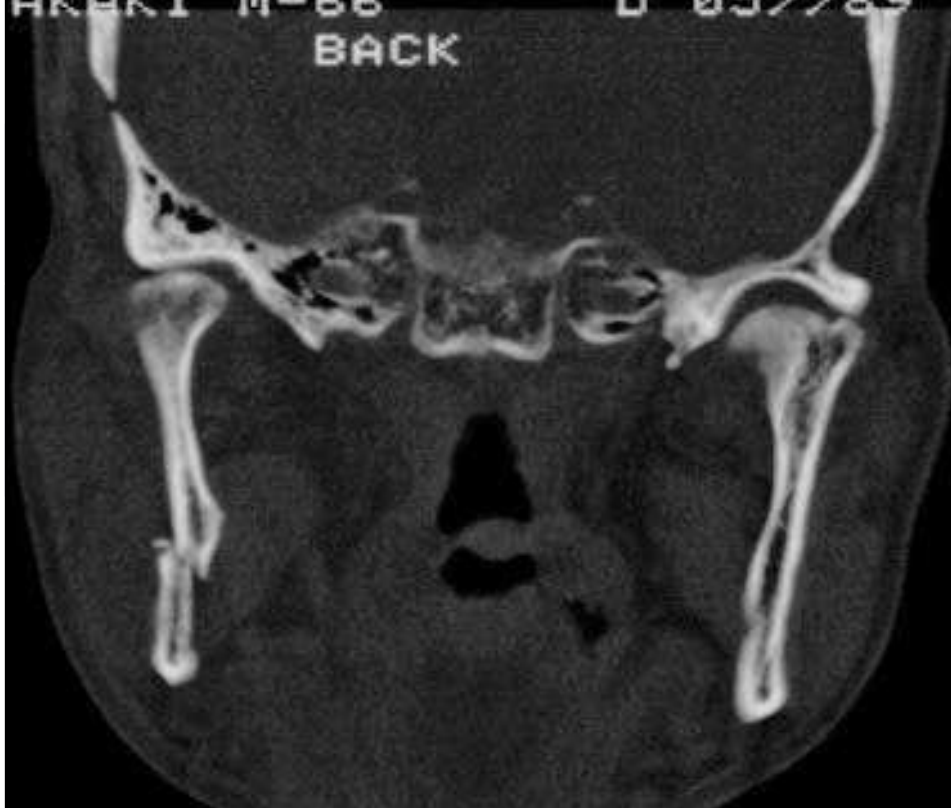Frantura



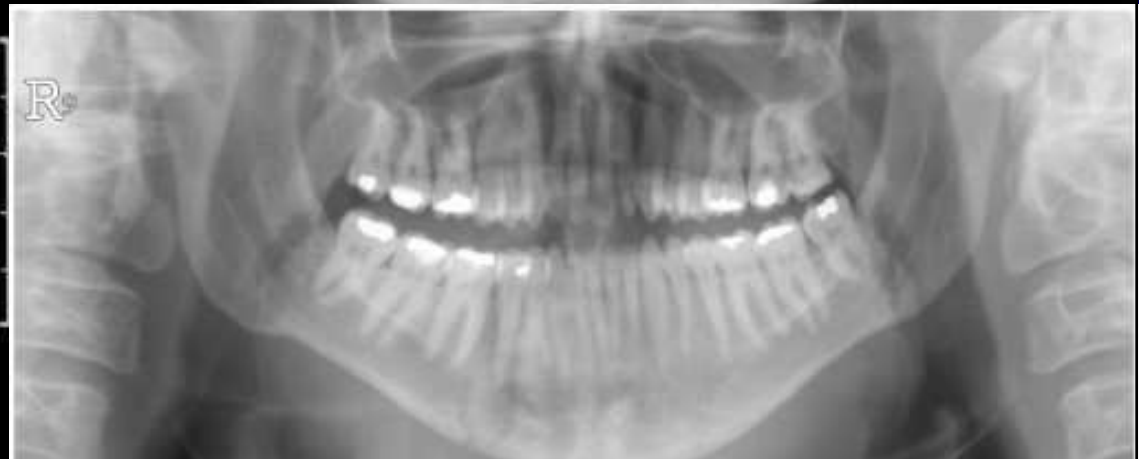www.xray2000.co.uk



R-H NAGASAKI UNIV. DENTAL
AKAKI M-66 D 057789
BACK

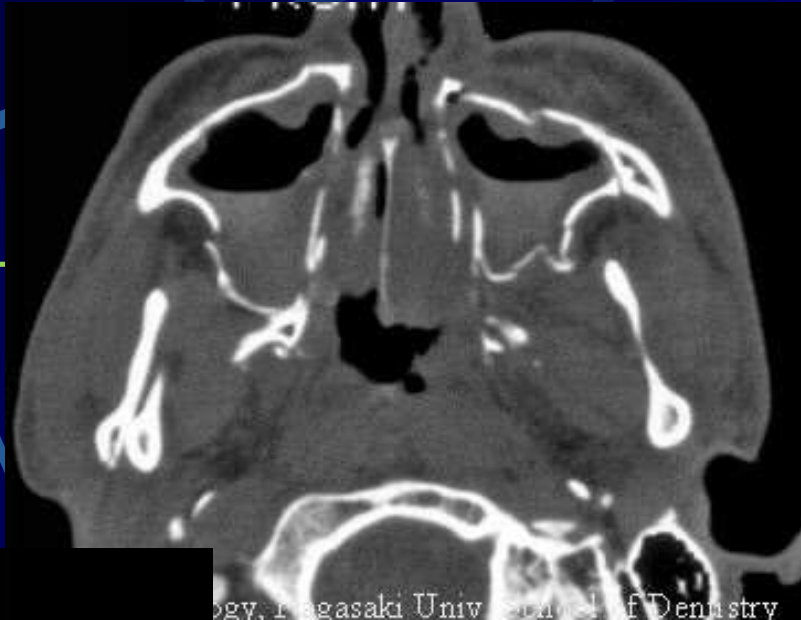



34

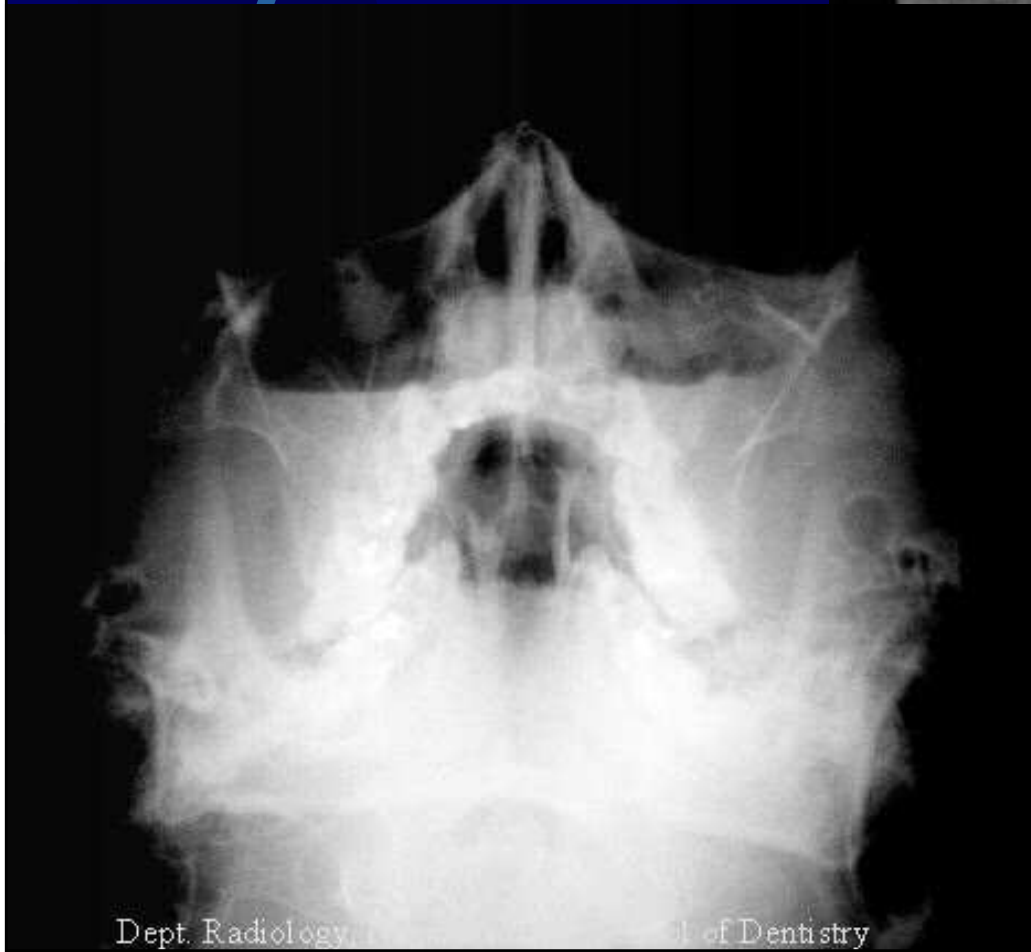



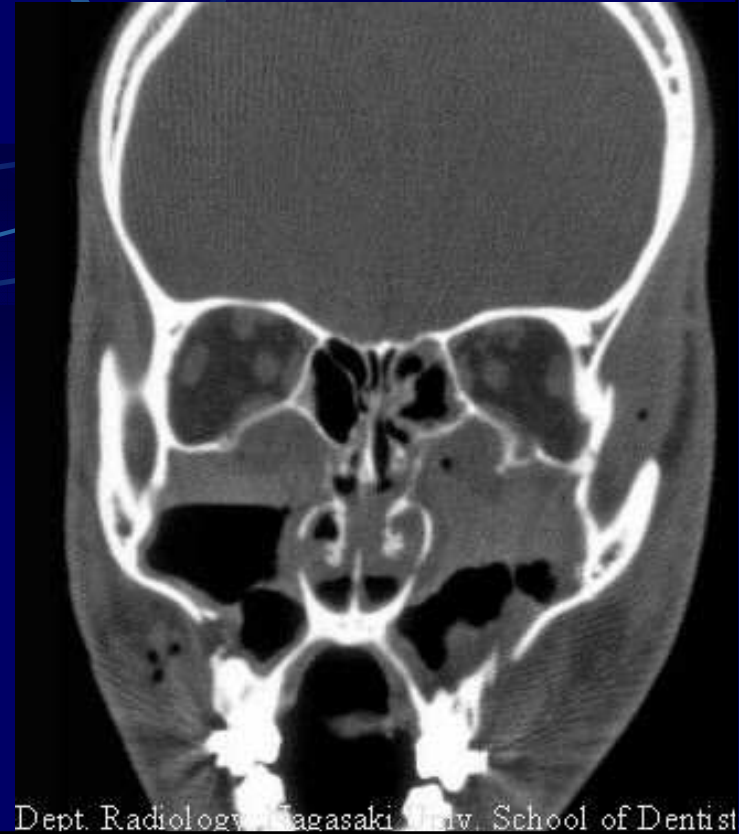Frantura



Dept. Radiology, Masaryk Univ. School of Dentistry



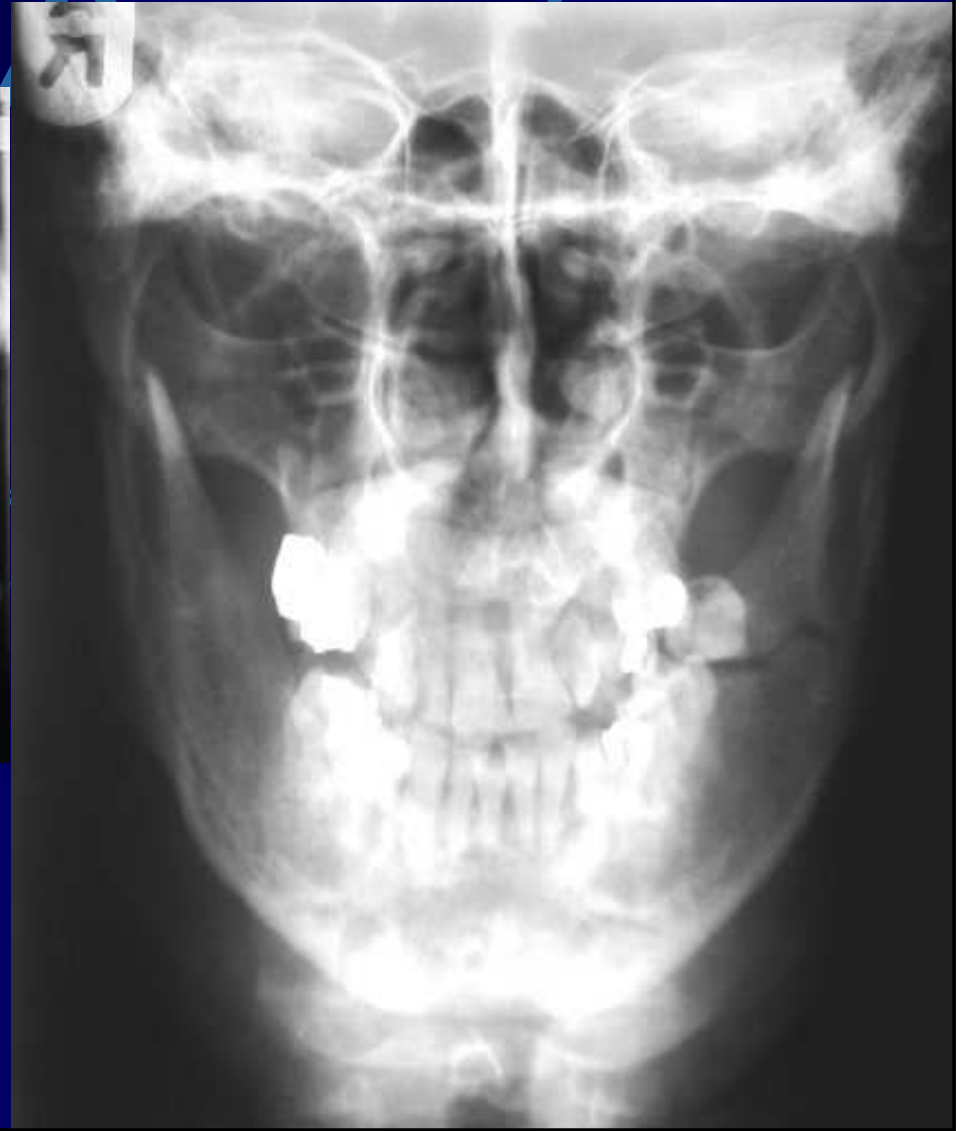
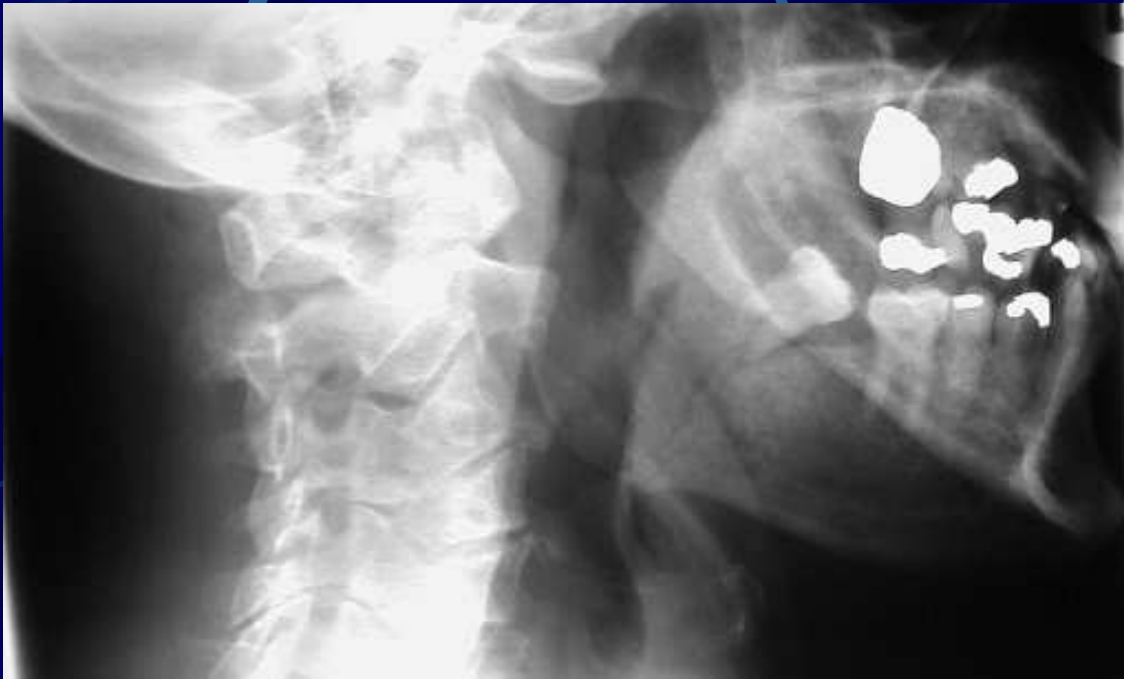Dept. Radiology, Masaryk Univ. School of Dentistry



Dept. Radiology, Masaryk Univ. School of Dentistry

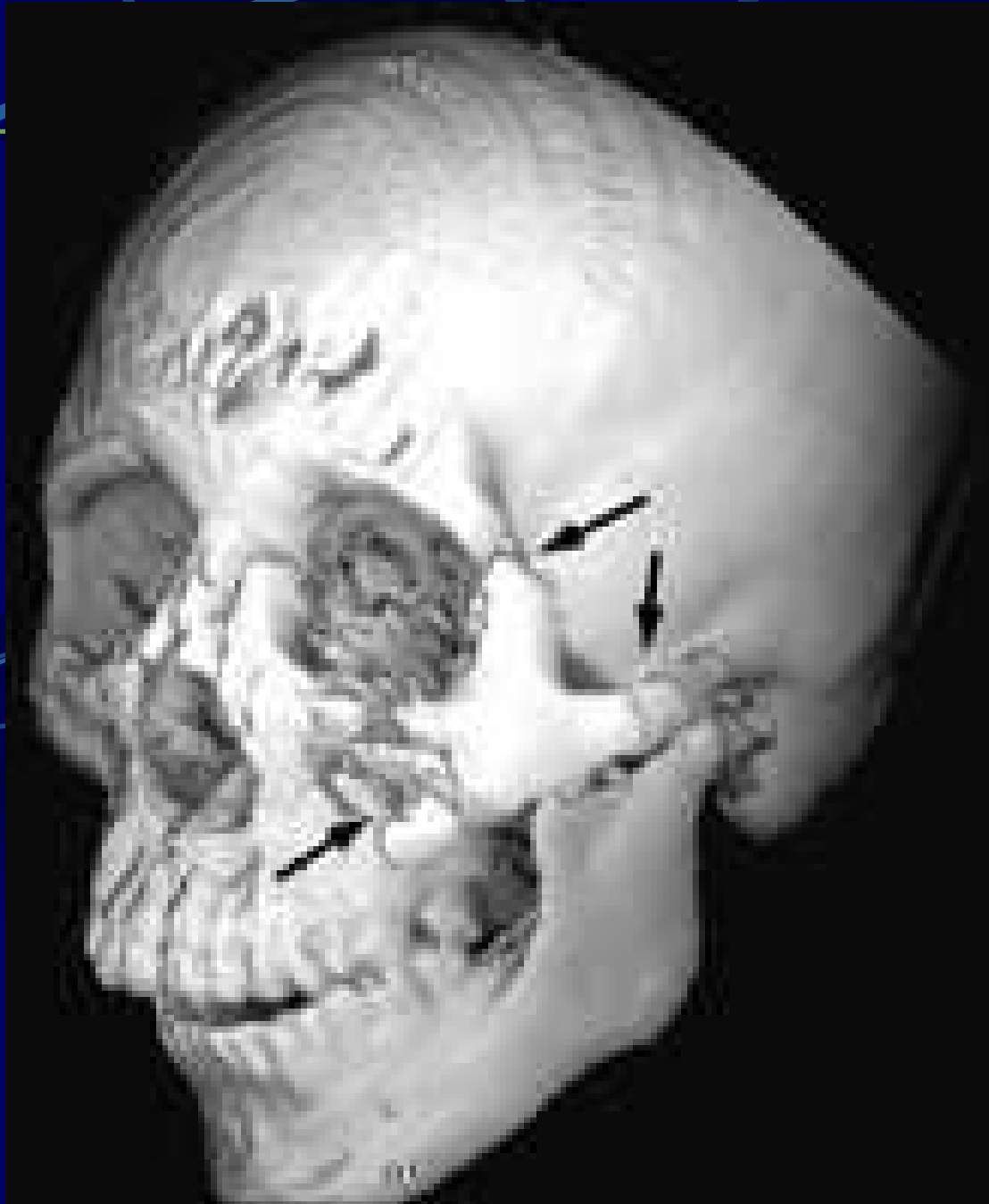


Frantura





Frantura





Zuby – náhrada

