



# RTG zubů a čelistí

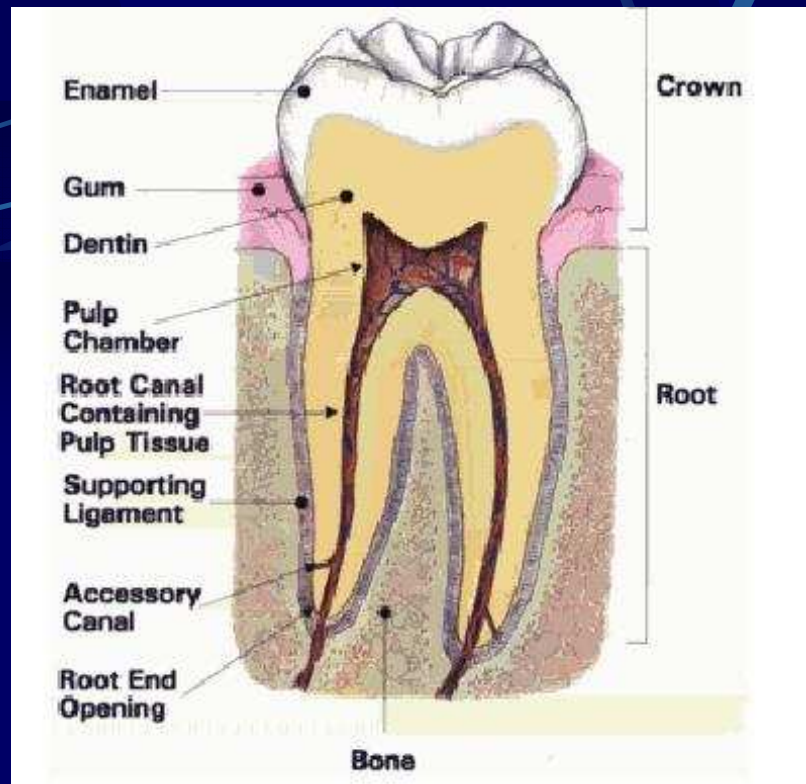
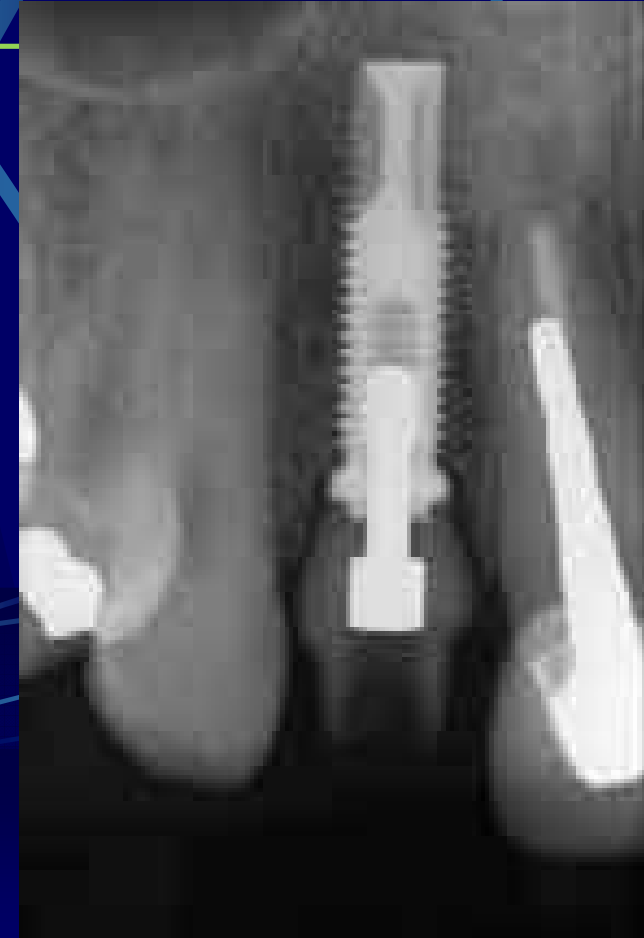
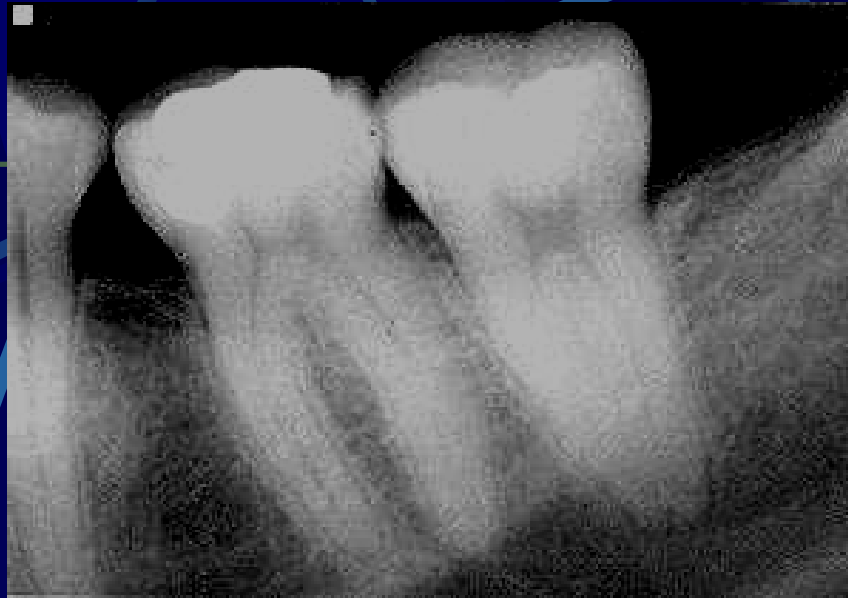**Válek V. A.**  
**Radiologická klinika LF, MOU Brno**




# Anatomie

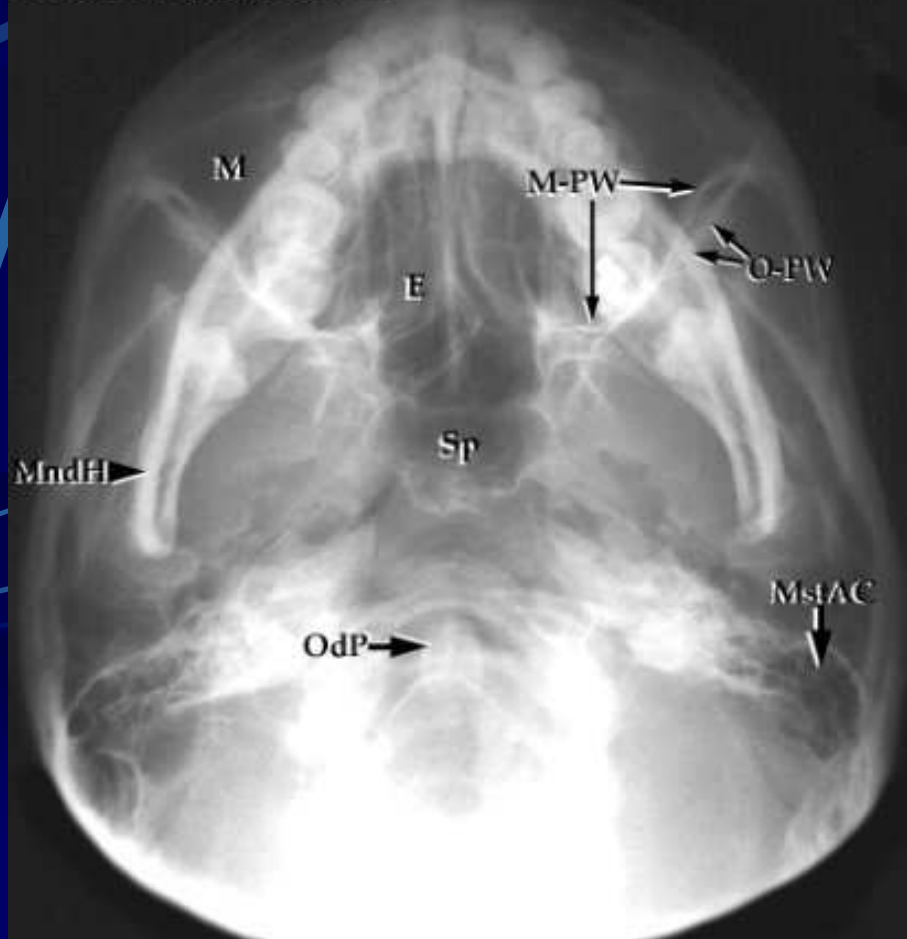


# Anatomie

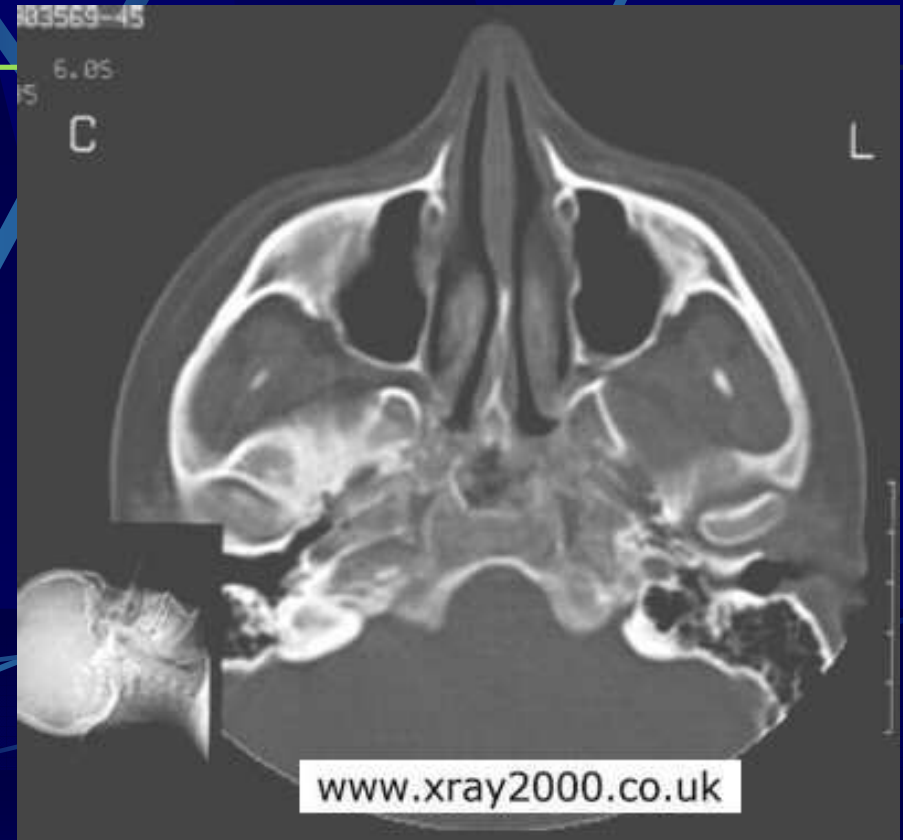




## Base of the Skull

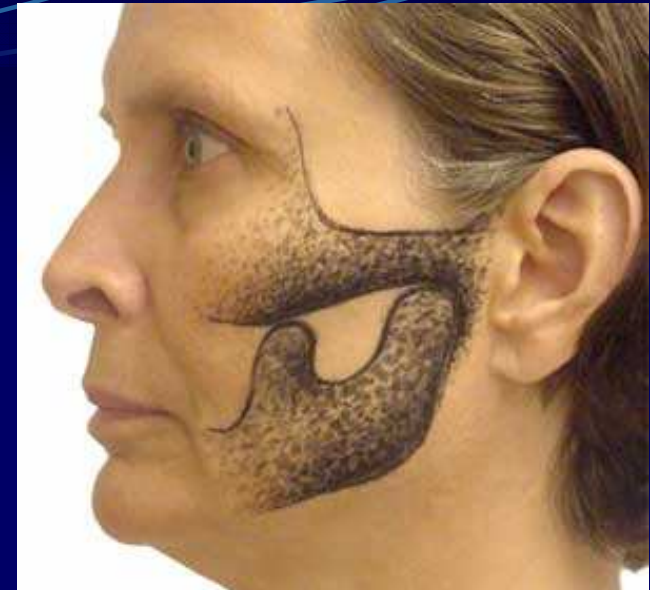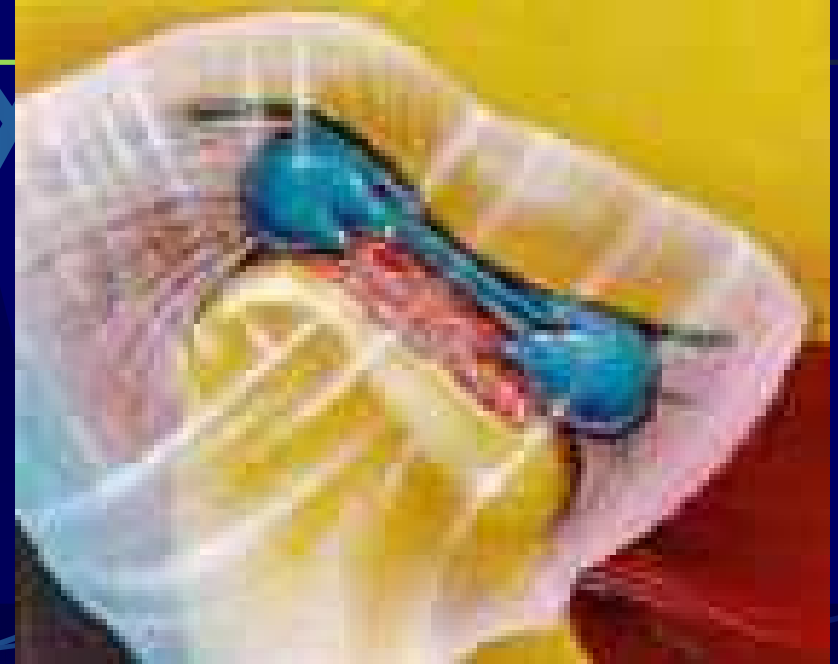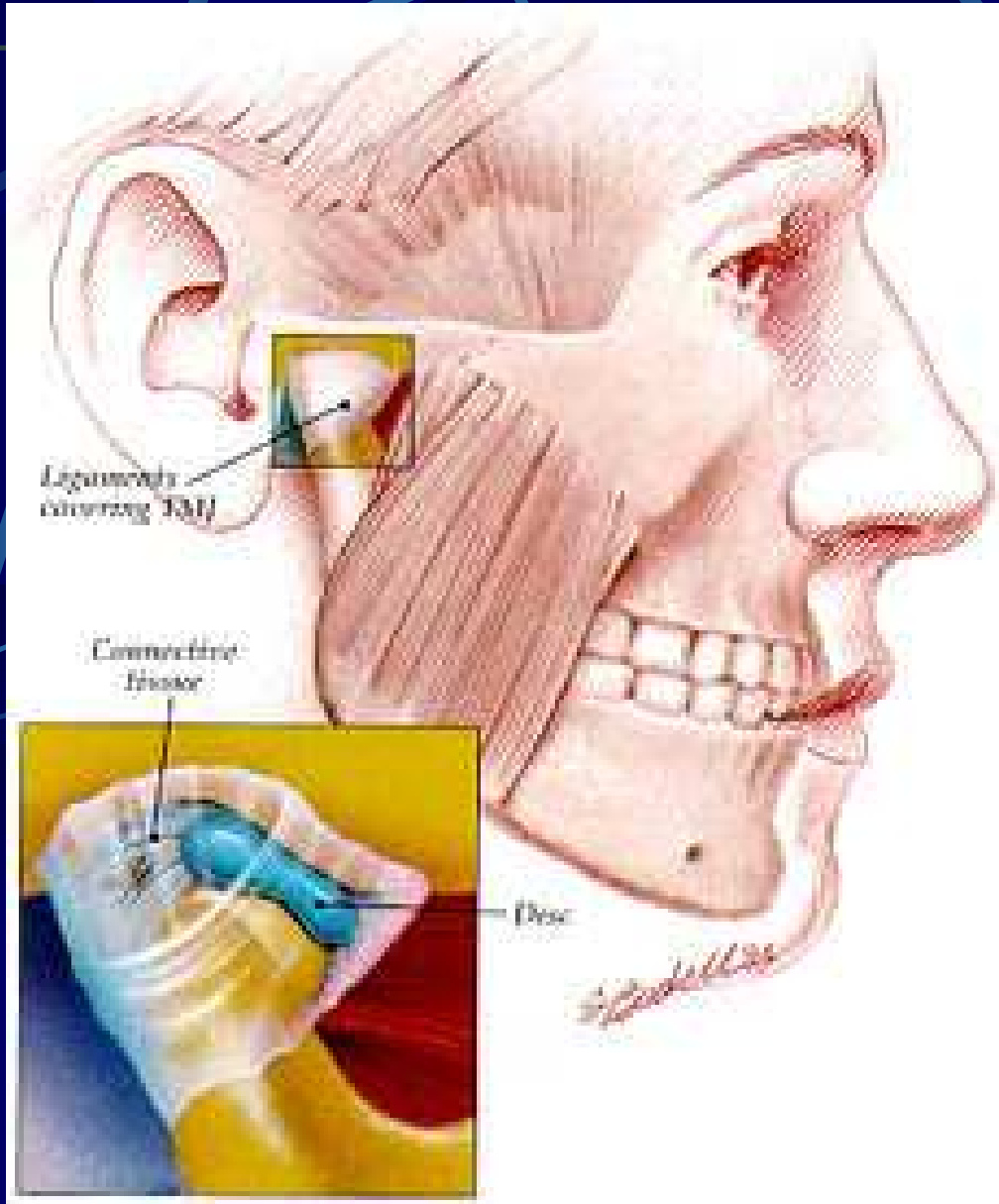


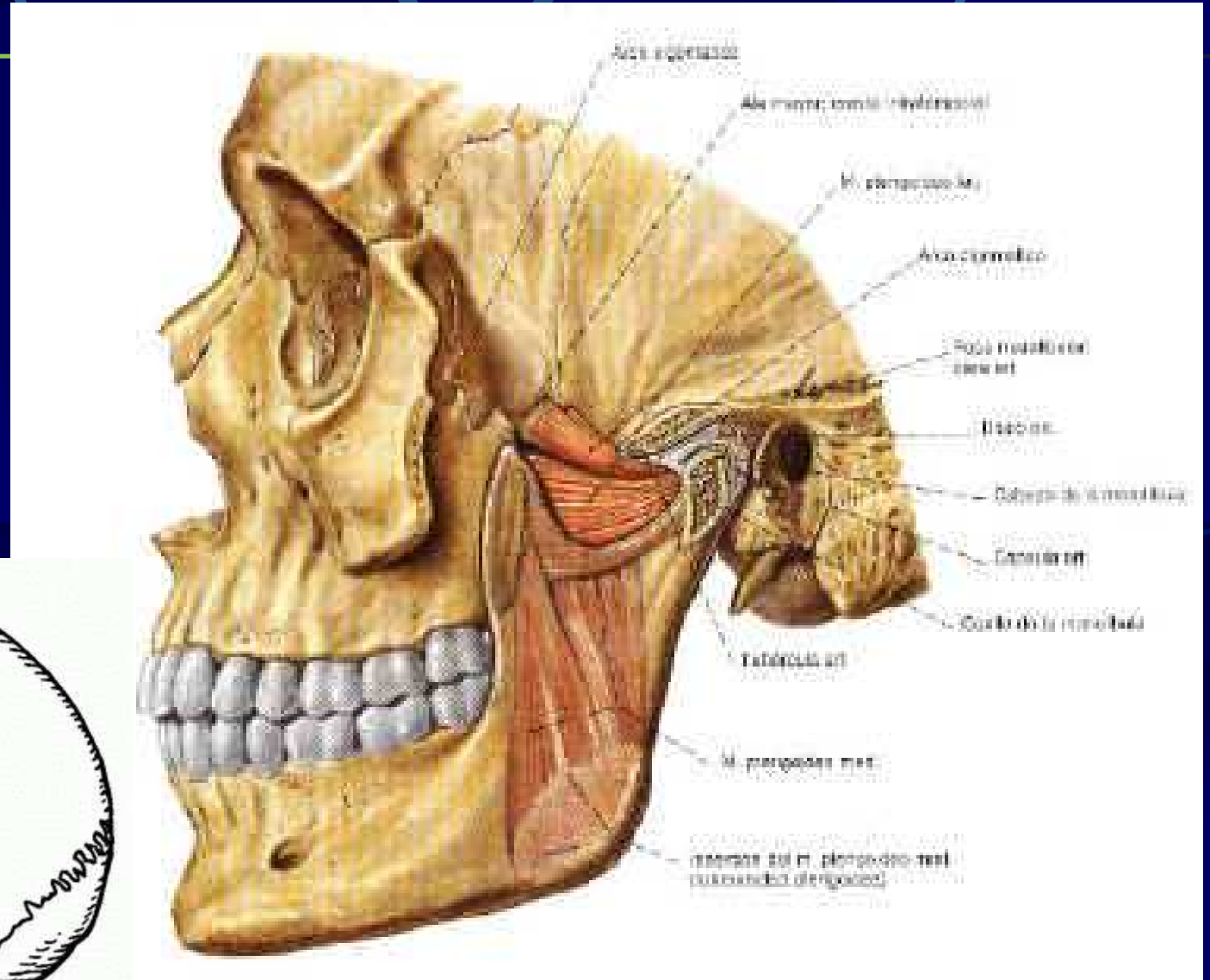
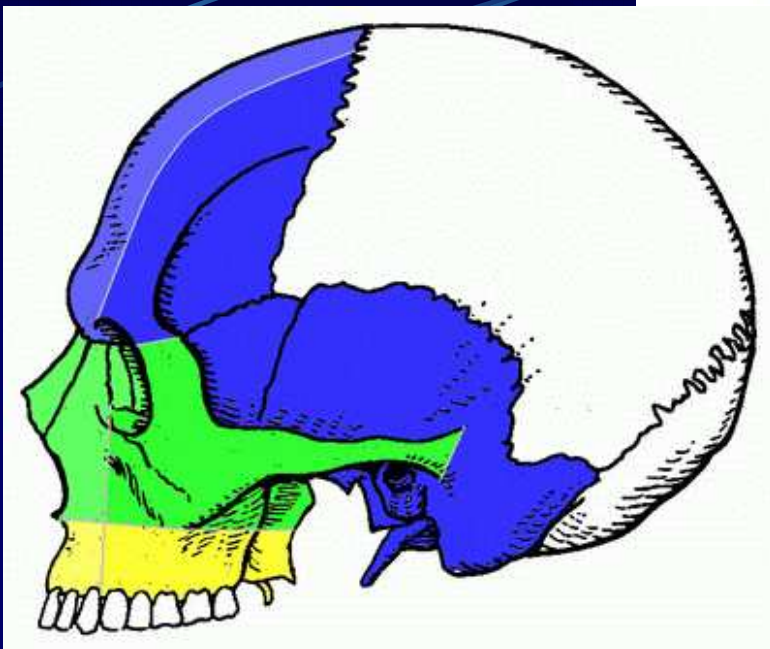

MstAC=Mastoid Air Cells	Sp=Sphenoid Sinus
E=Ethmoid Sinus (Air Cells)	M=Maxillary Sinus
O-PW=Posterior Wall of Orbit	MndH=Head of Mandible
M-PW=Posterior Wall of Maxillary Sinus	OdP=Odontoid Process





# Anatomie

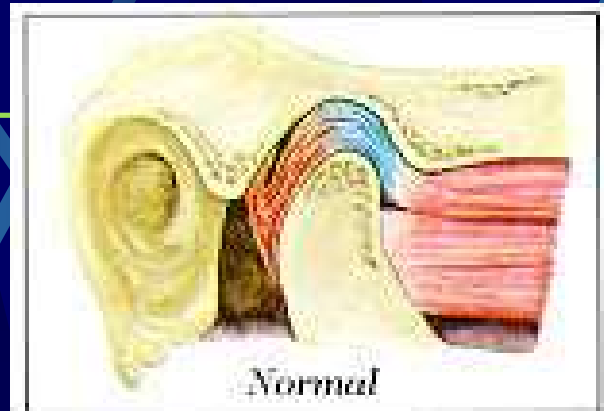




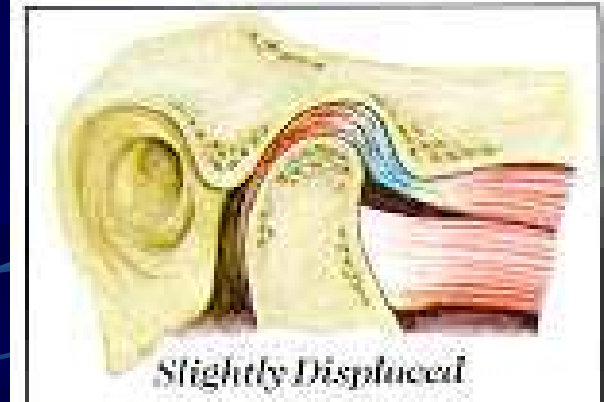




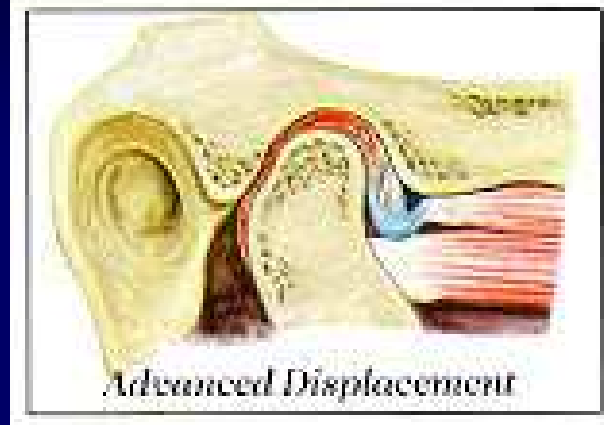# Anatomie



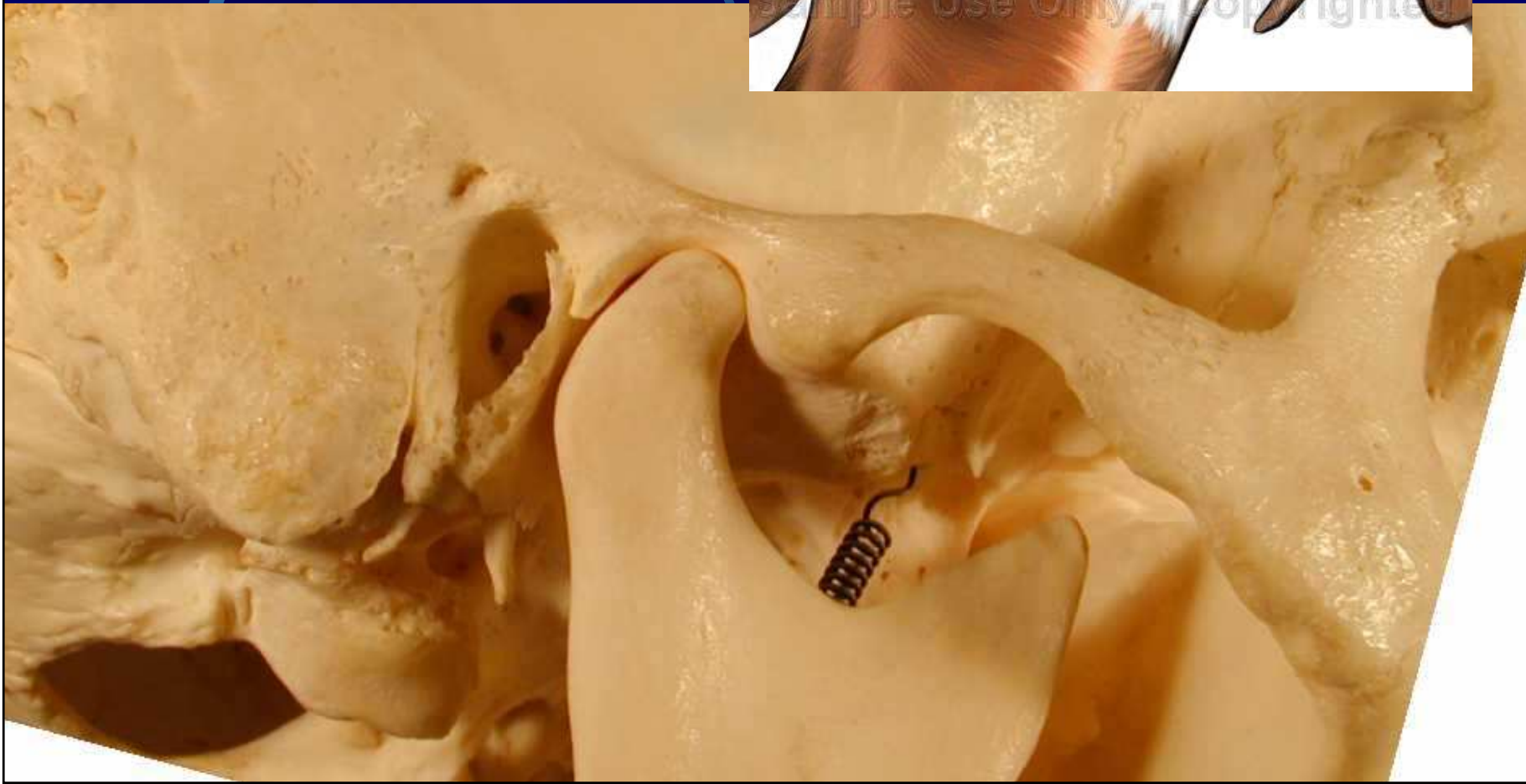
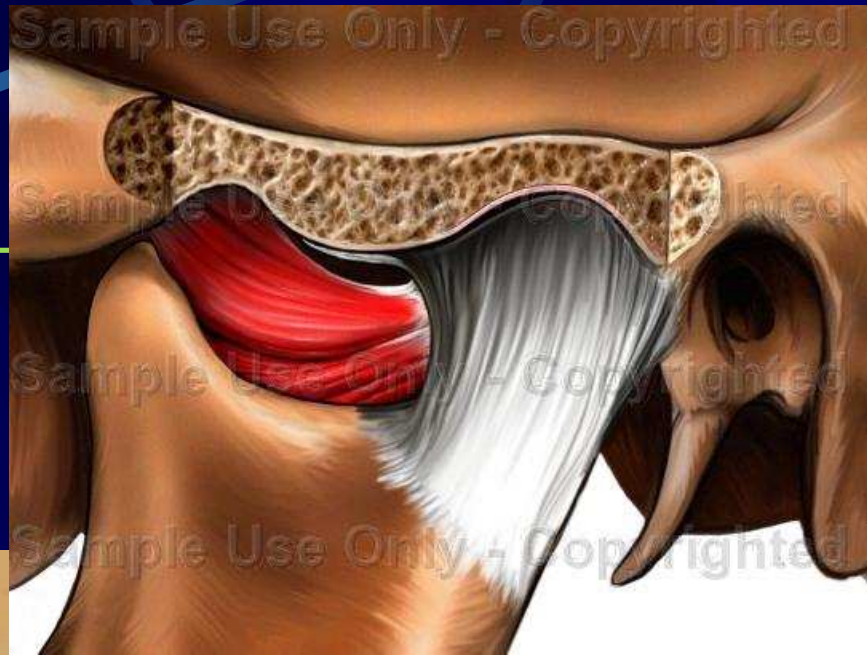
*Normal*



*Slightly Displaced*

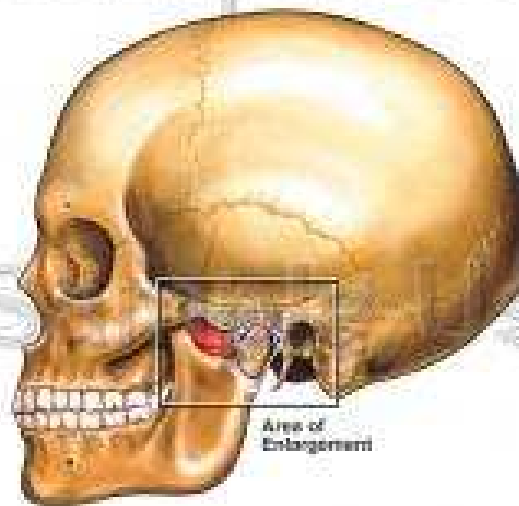


*Advanced Displacement*





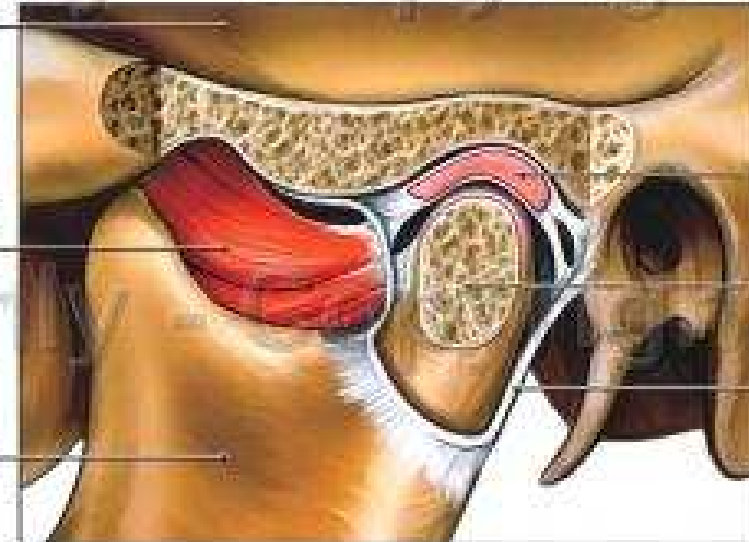
## Anterior Displacement of the Left Temporomandibular Joint (TMJ)



Temporal bone

Pterygoid muscle

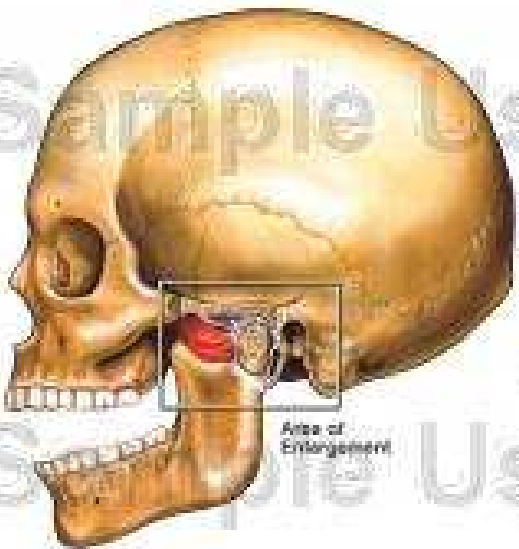
Mandible



Meniscus

Condyle

Joint capsule

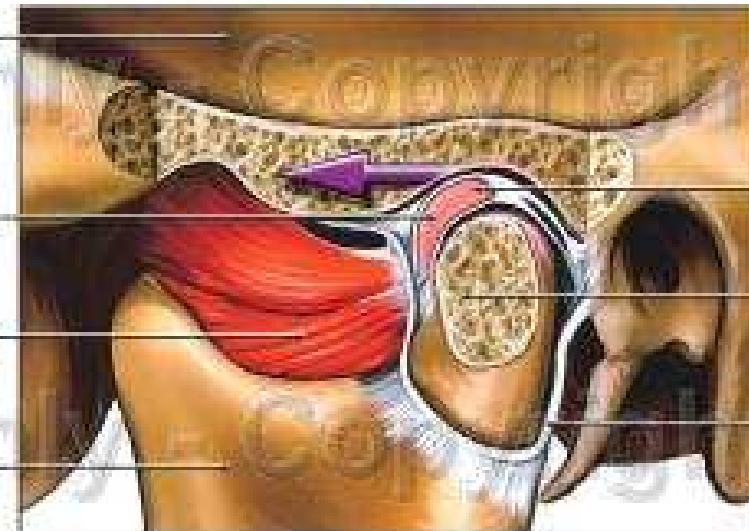


Temporal bone

Anterior displacement of TMJ meniscus

Pterygoid muscle

Mandible




Meniscus

Condyle

Joint capsule

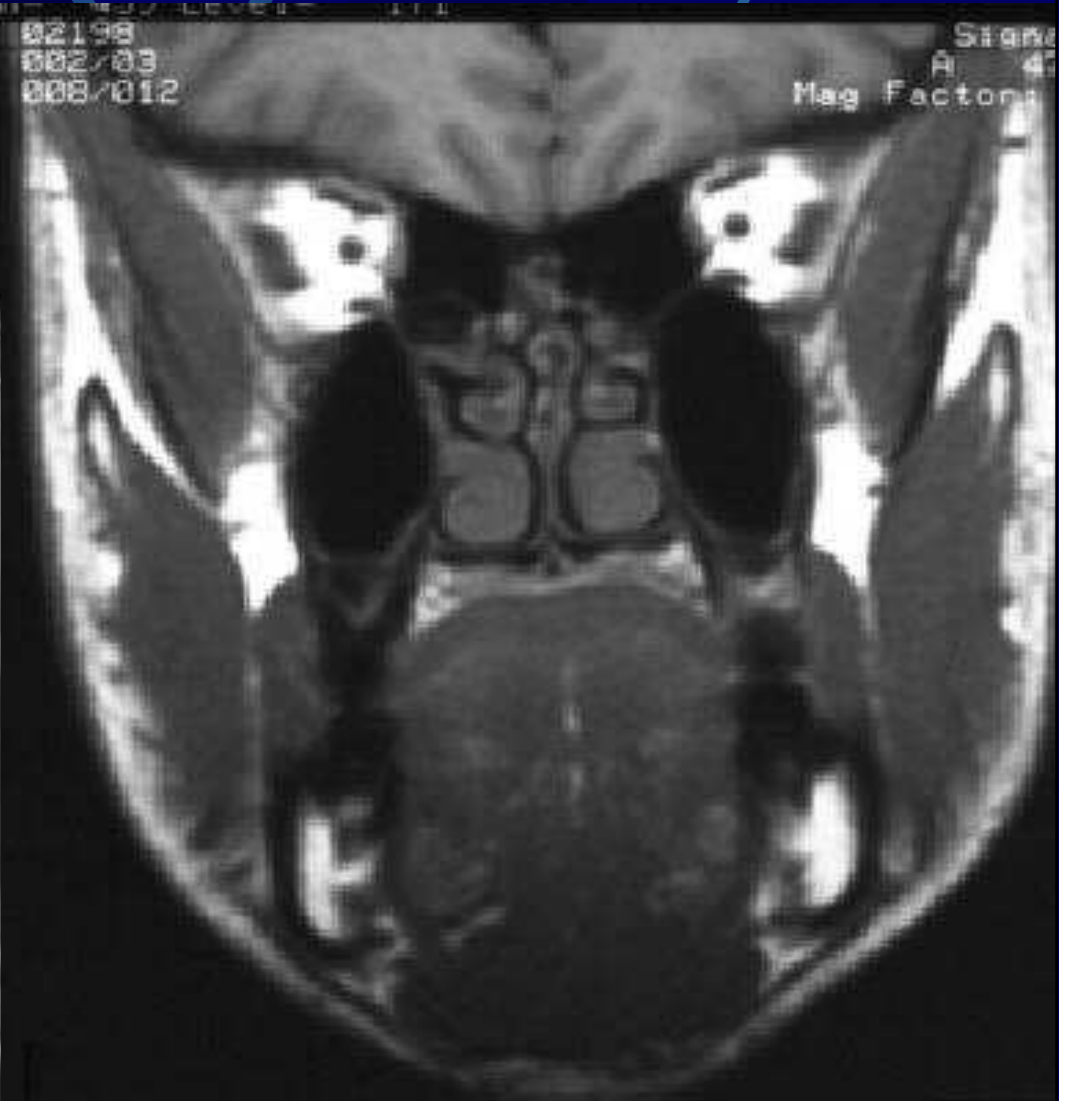
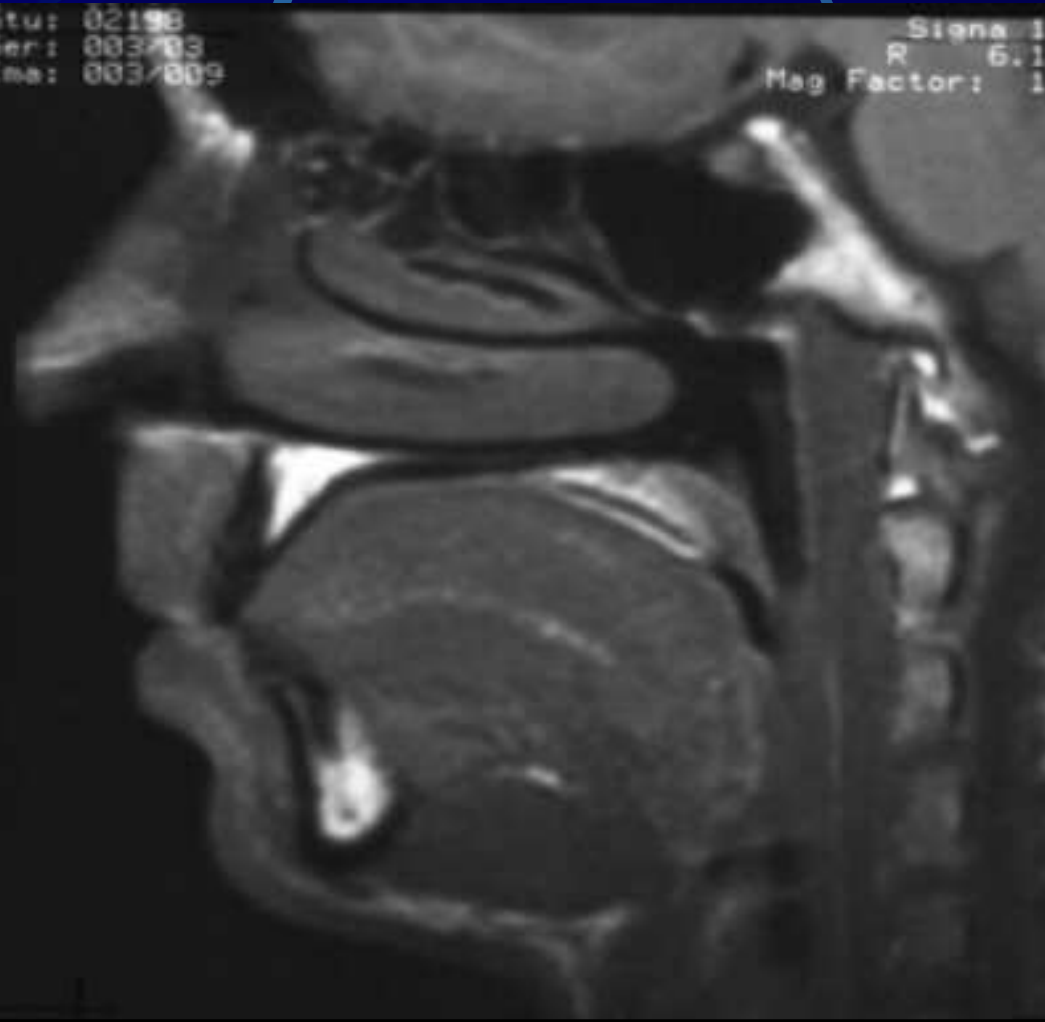
# Anatomie



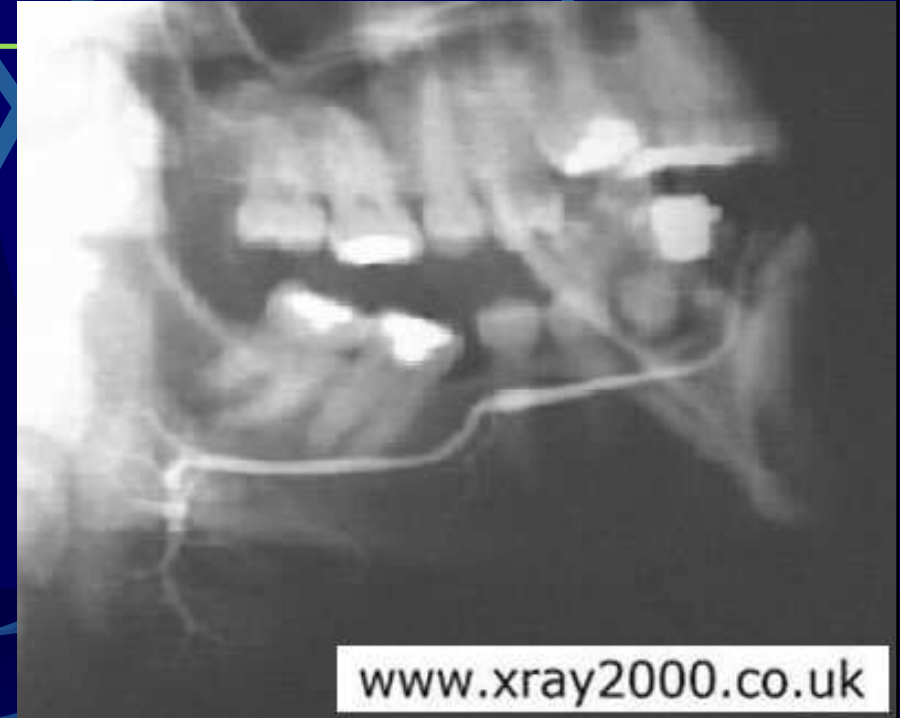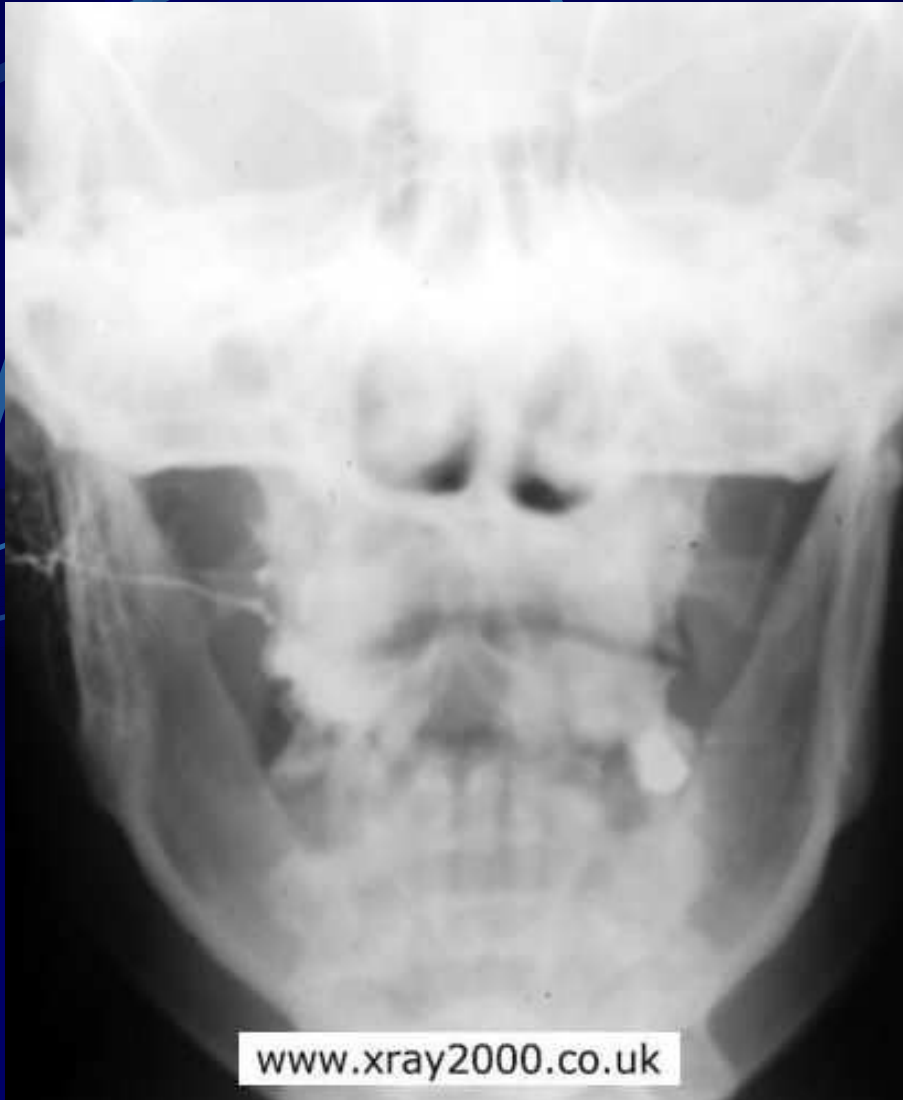
tu: 02198  
er: 003/03  
na: 003/009

Signa: 1  
R: 6.1  
Mag Factor: 1






# Anatomie

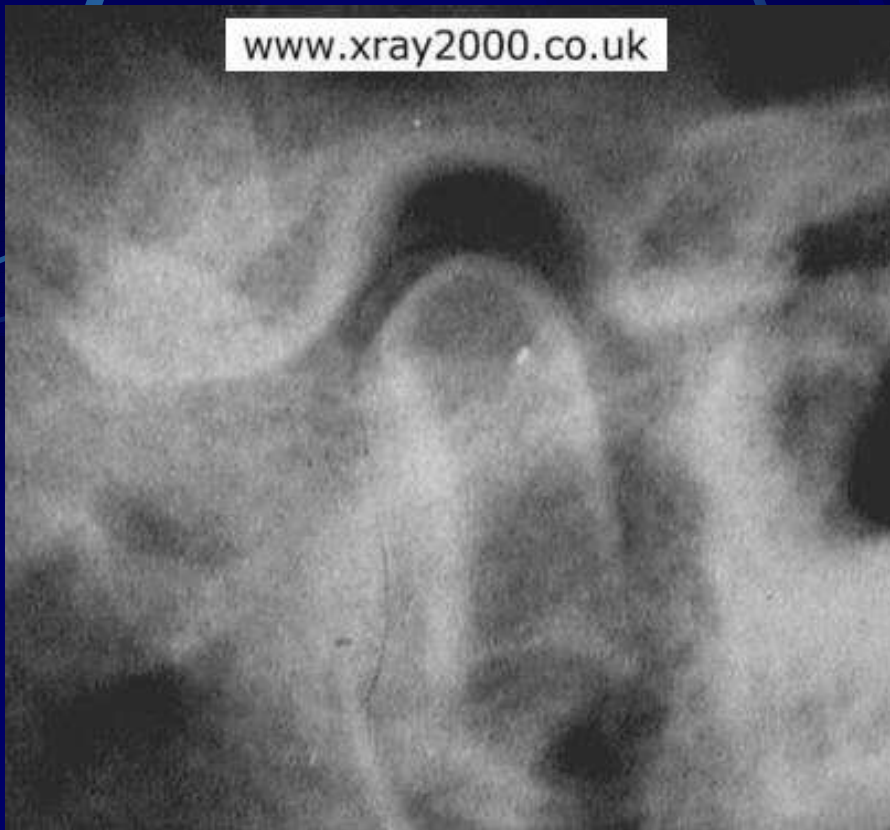



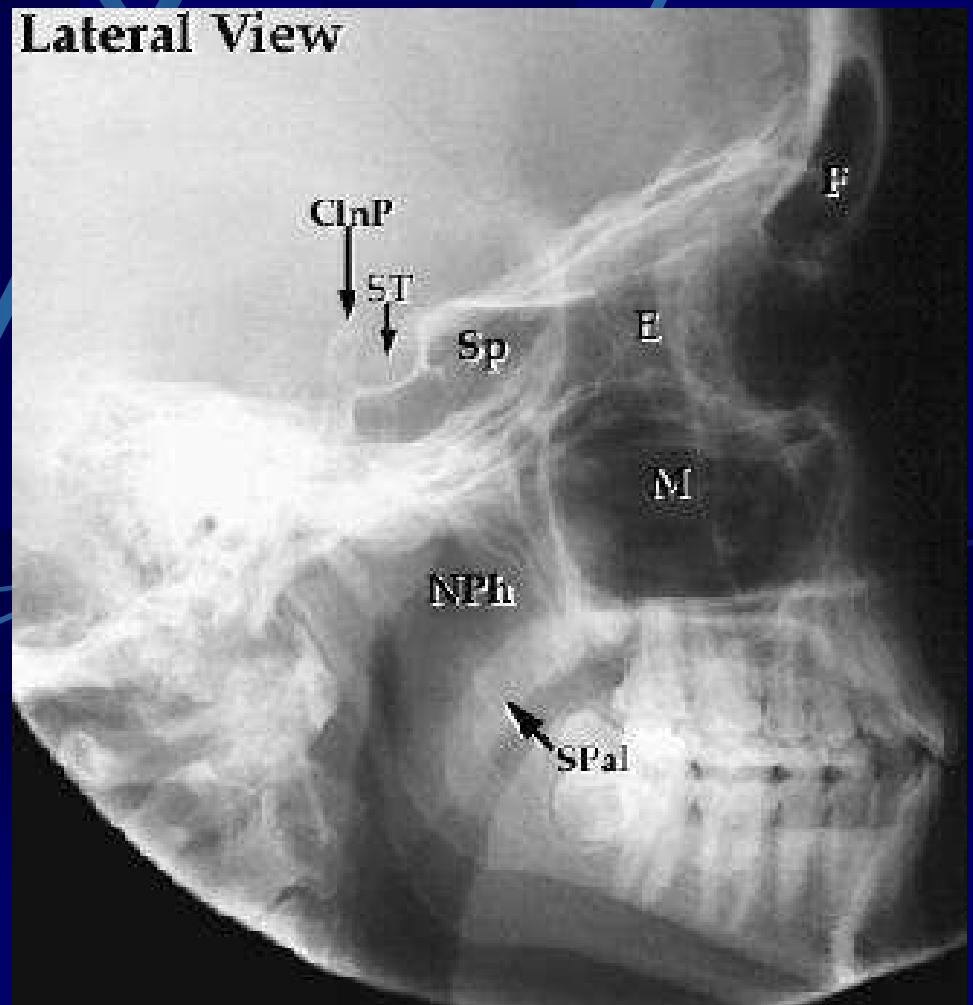
# Anatomie



[www.xray2000.co.uk](http://www.xray2000.co.uk)



## Lateral View



F=Frontal Sinus  
E=Ethmoid Sinus  
Sp=Sphenoid Sinus  
M=Maxillary Sinus

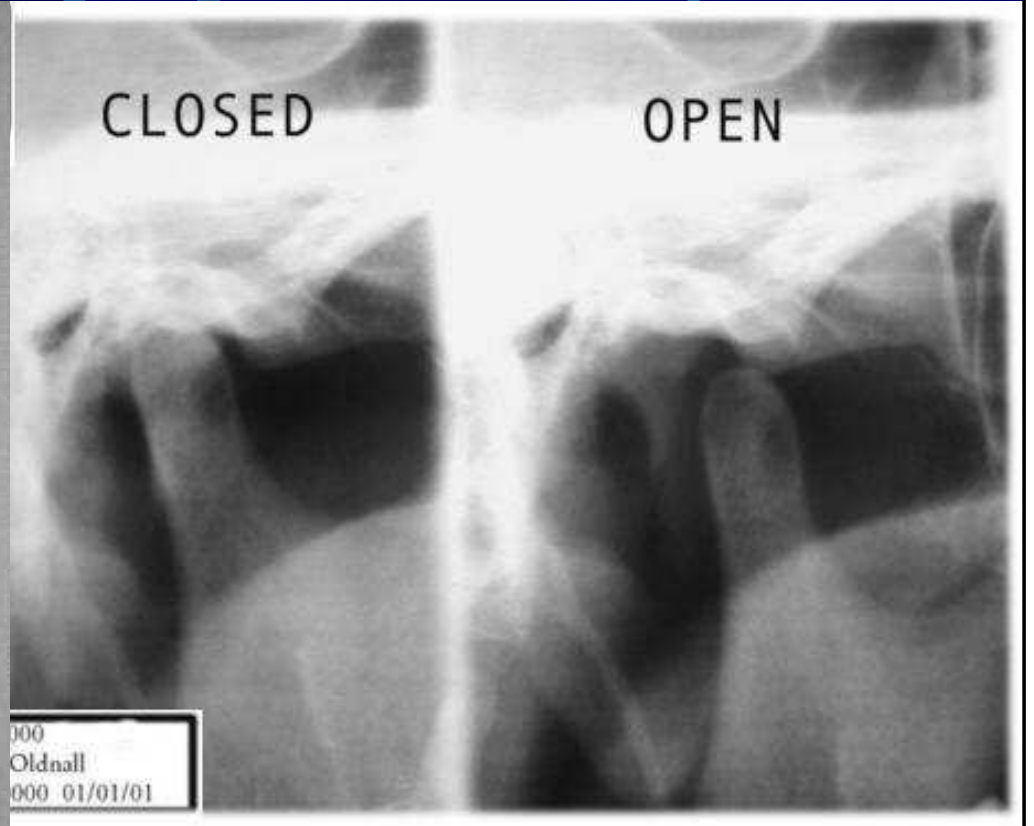
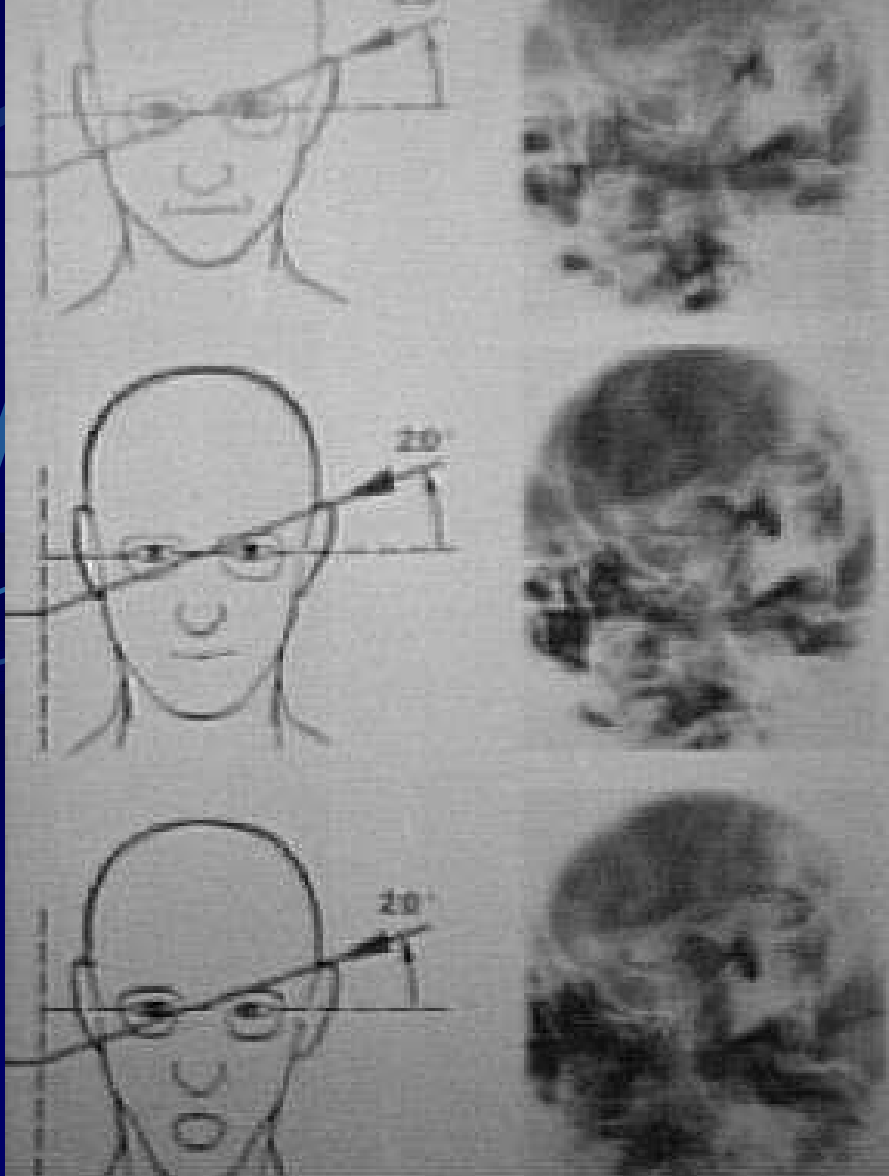
ST=Sella Turcica (Pituitary Fossa)  
ClnP=Posterior Clinoid  
NPh=Nasopharynx  
SPal=Soft Palate



# Anatomie



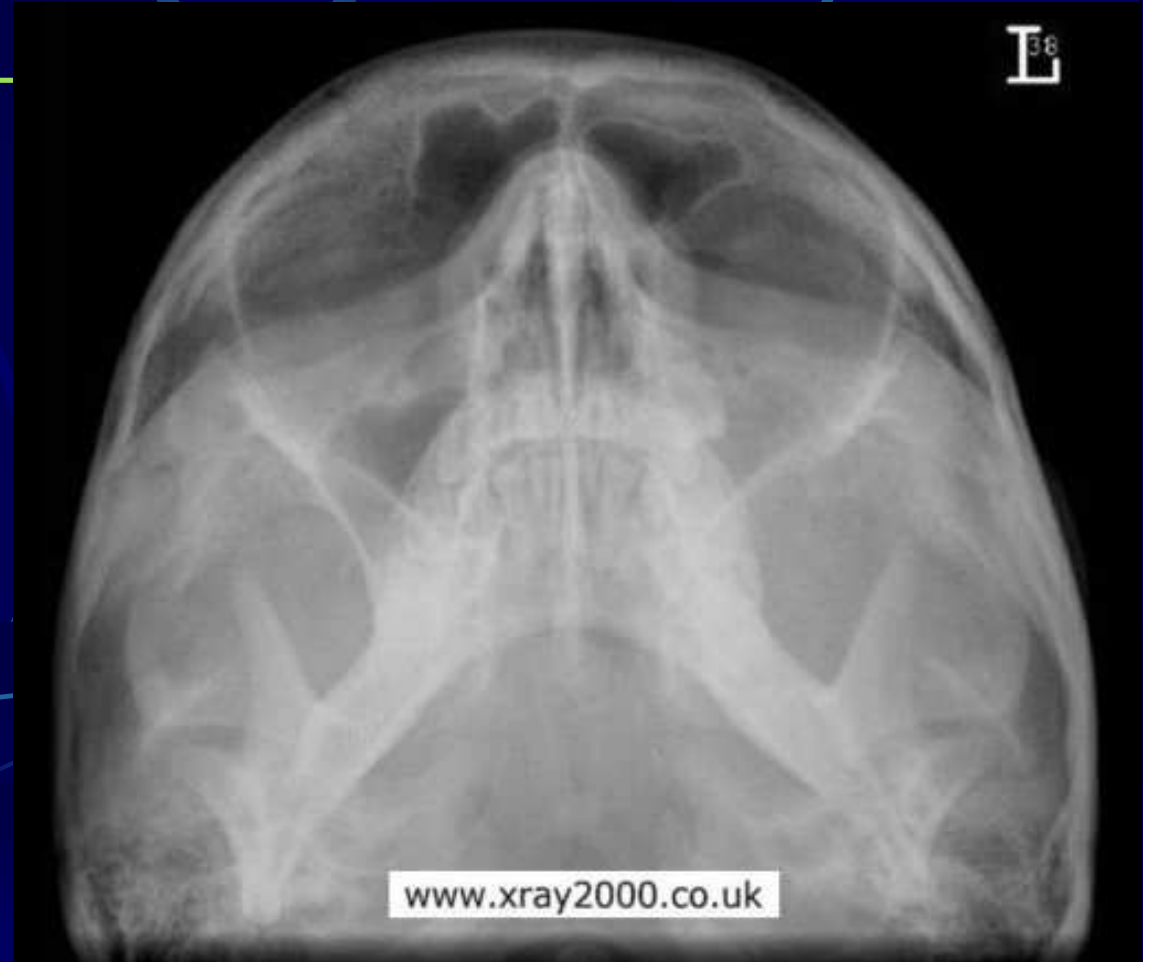
Anders Movin Karlison





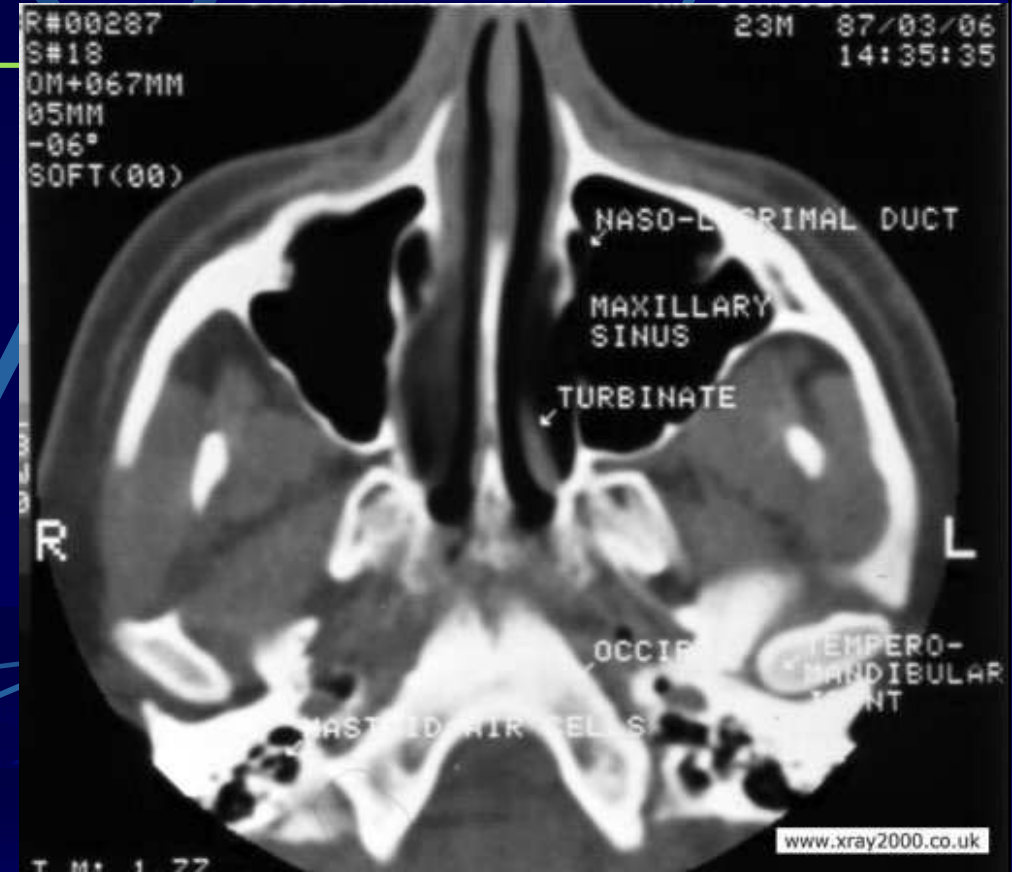
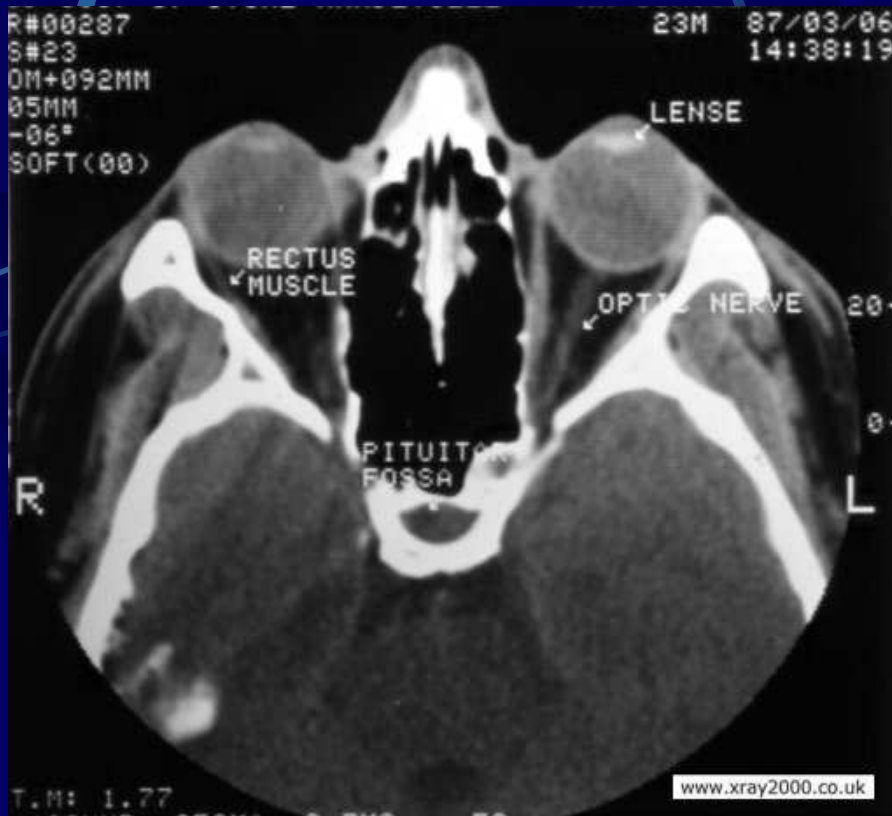


# Anatomie





# Anatomie

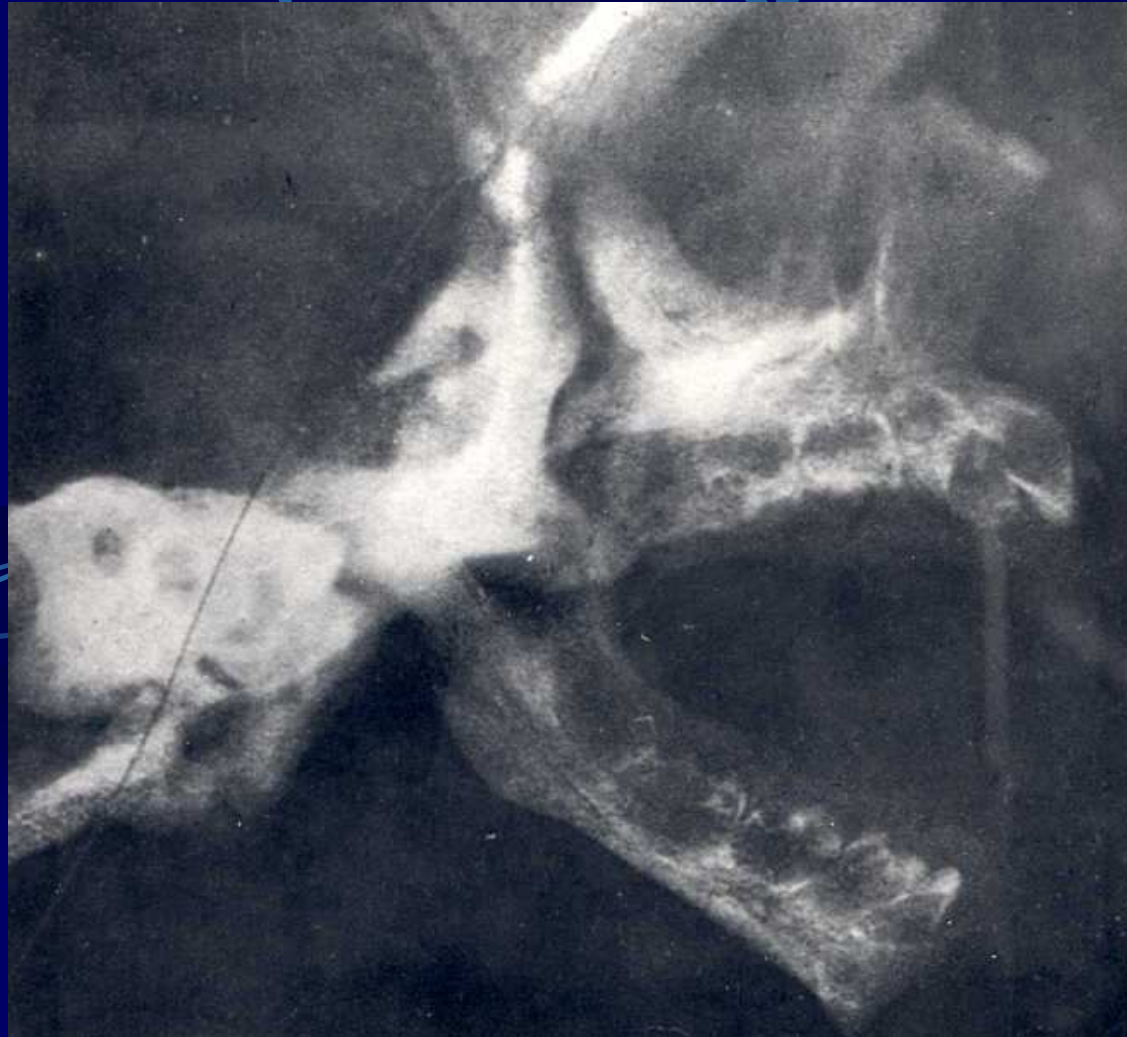




# Vývoj zubu



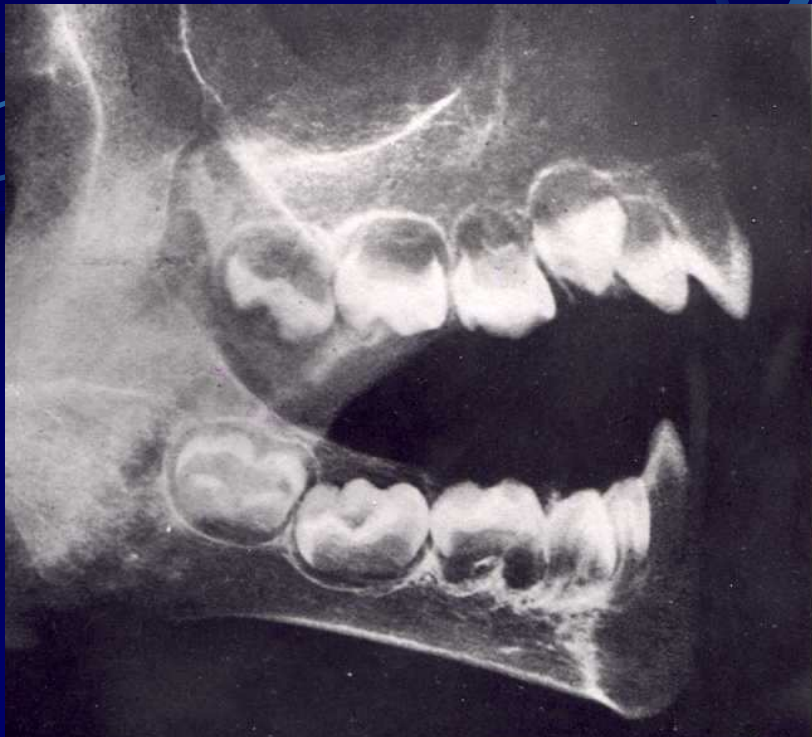
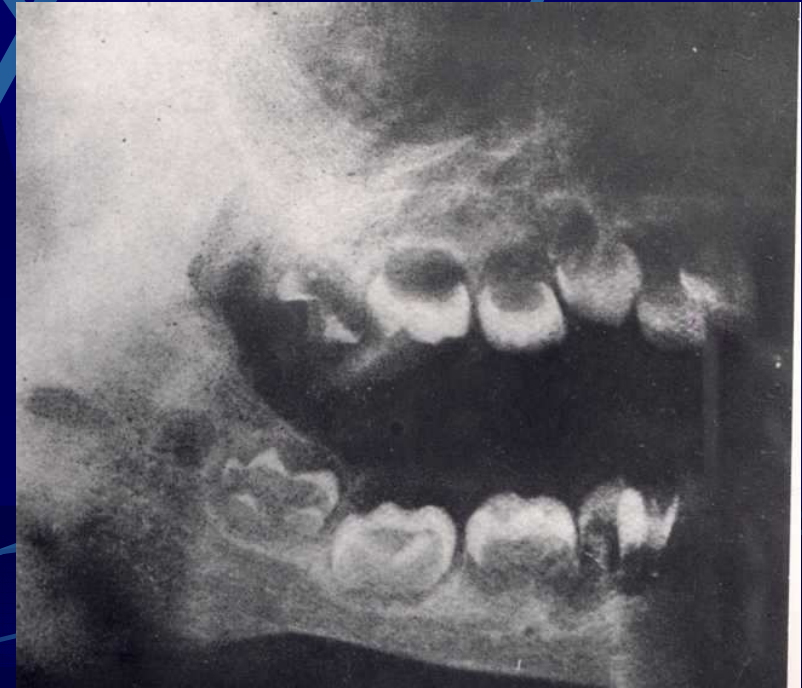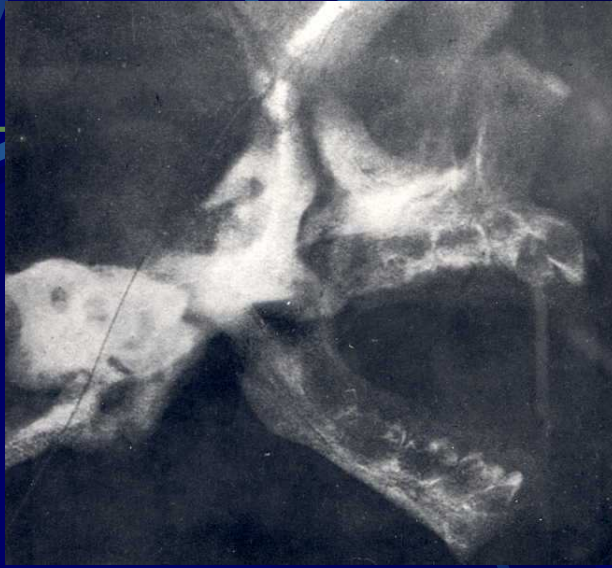

# Zuby – vývoj - novorozenec





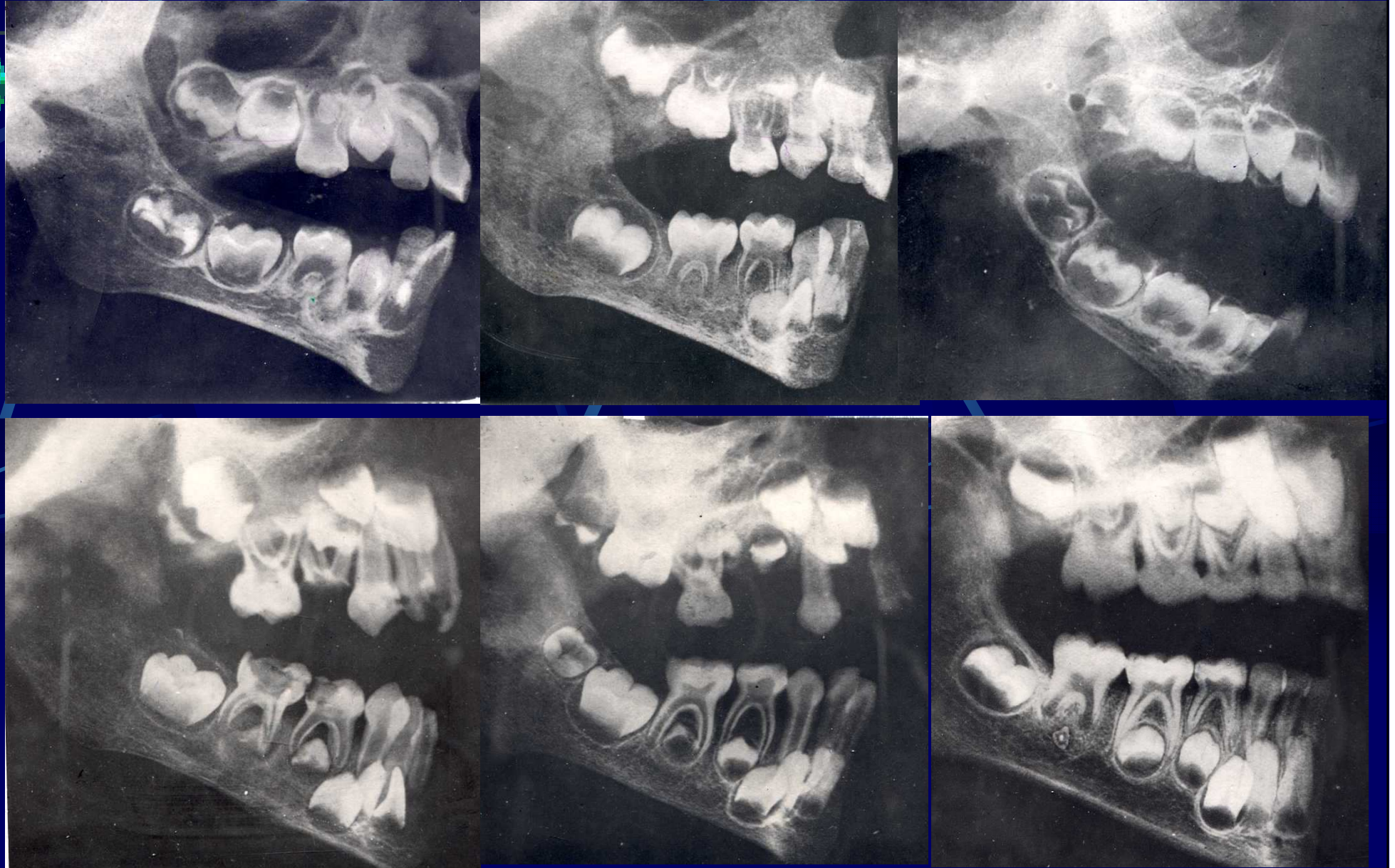


# Zuby – vývoj – 6 a 9 měsíc

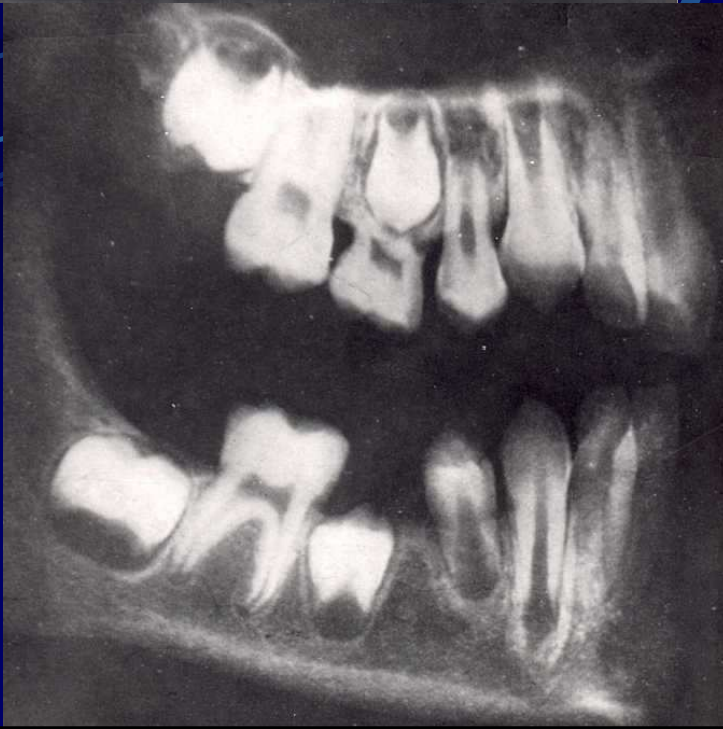
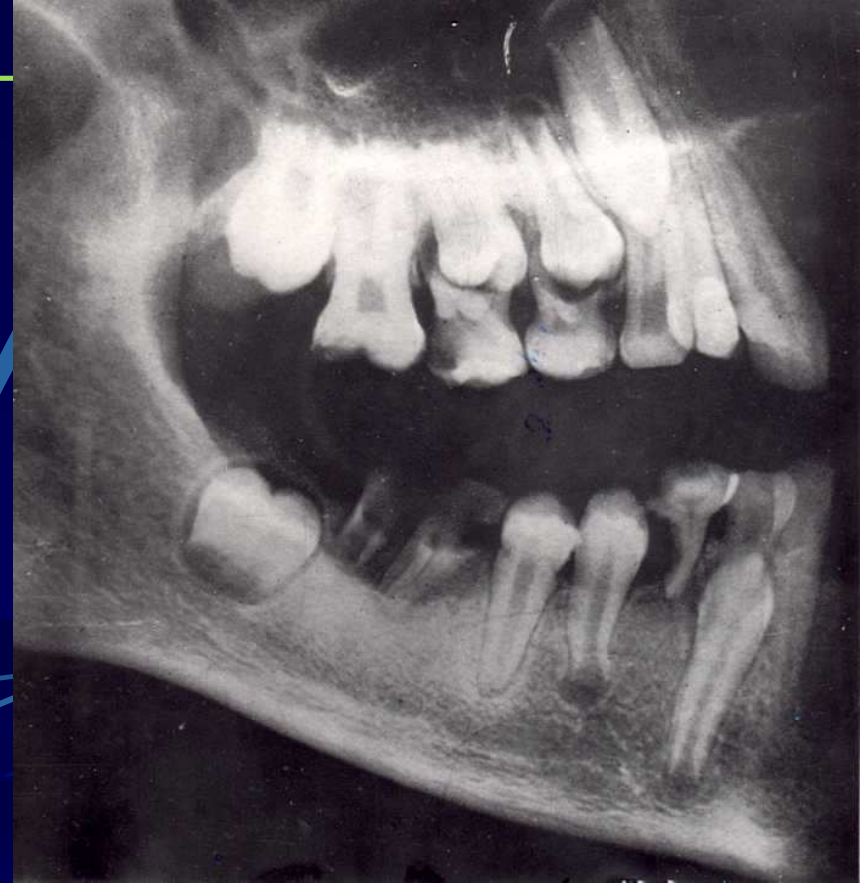
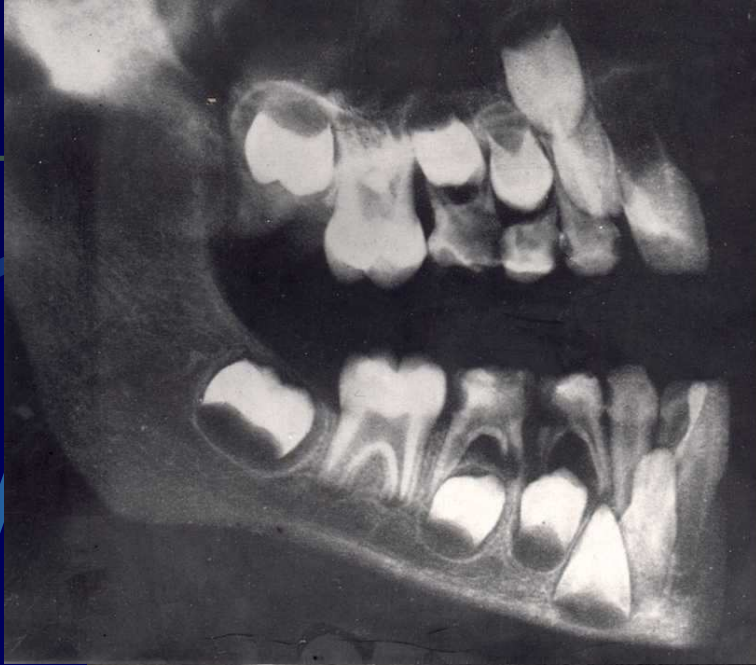




# Zuby – vývoj – 1 – 6 rok



# Zuby – vývoj – 7-10 let



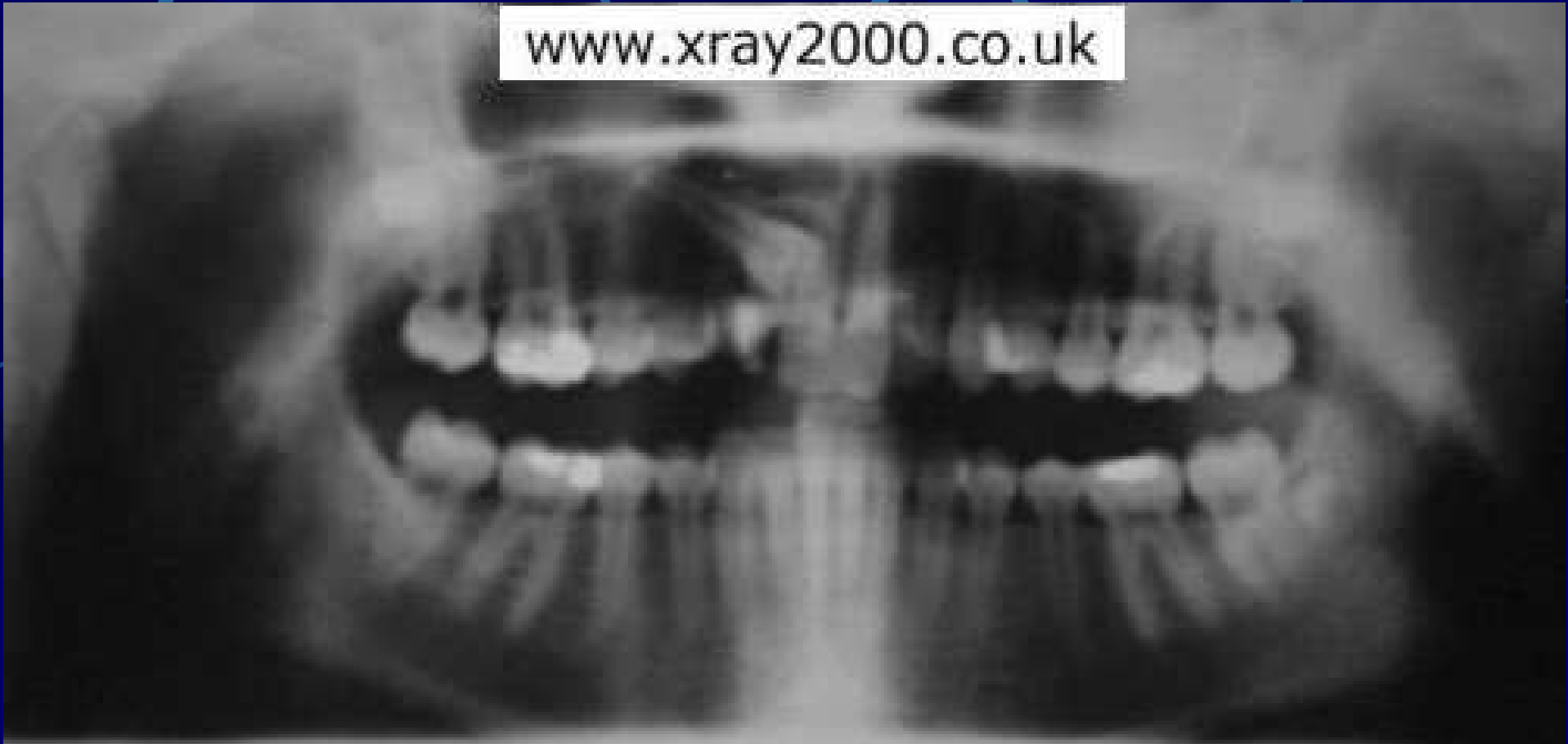




# Zuby – vývoj – ektopický zub



[www.xray2000.co.uk](http://www.xray2000.co.uk)

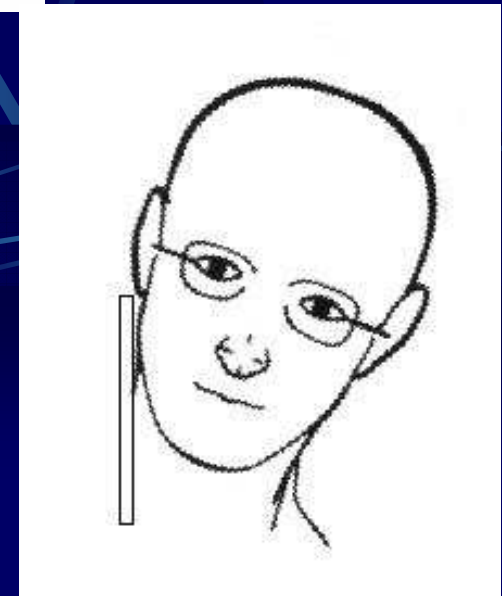
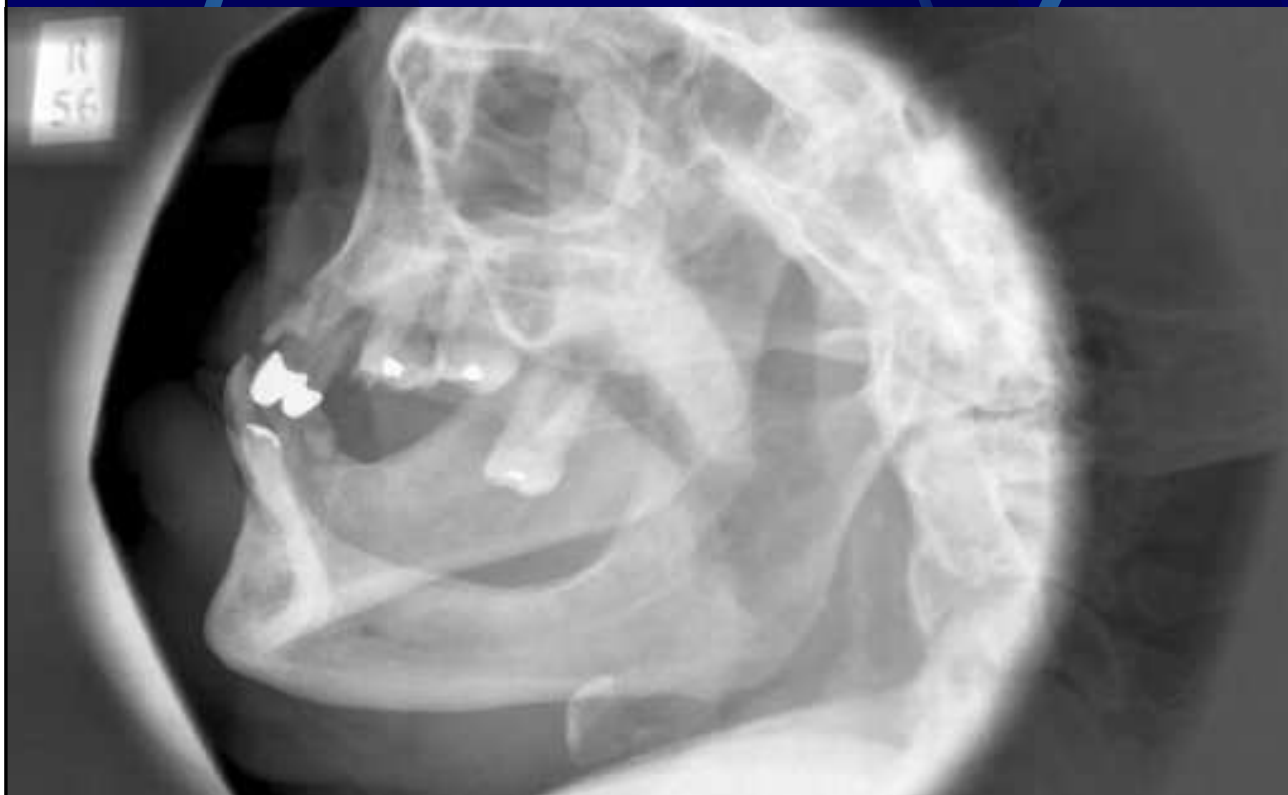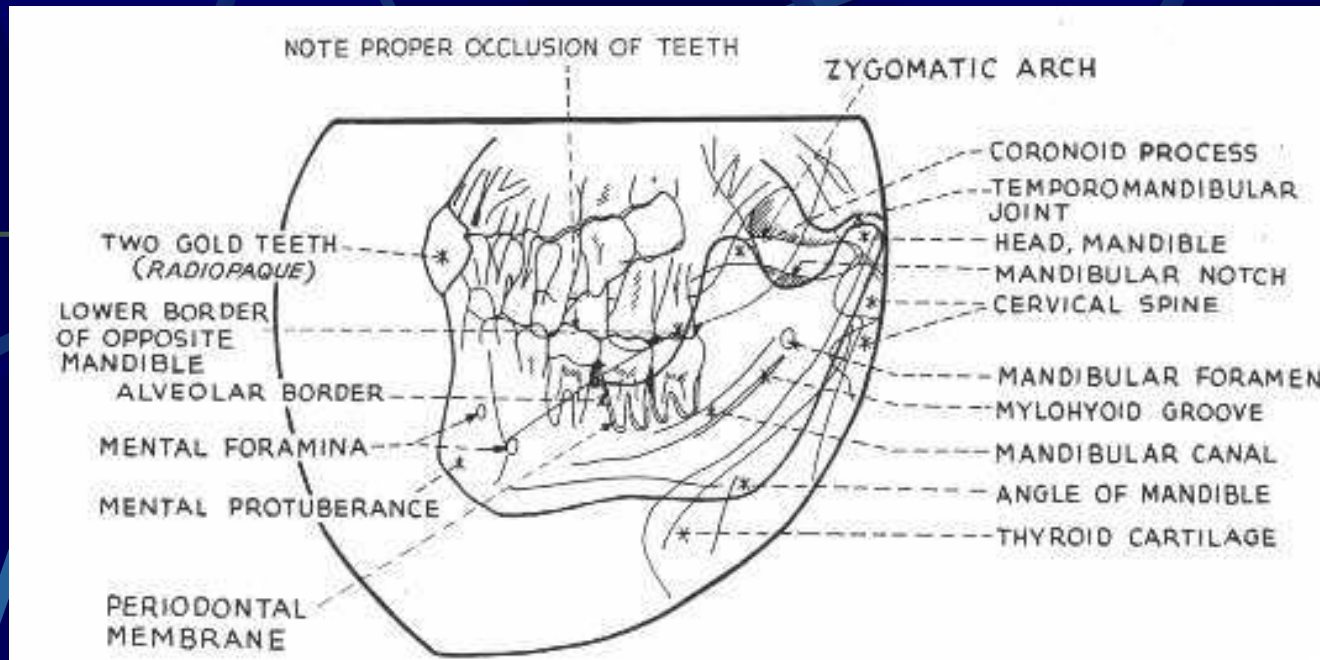




# Projekce



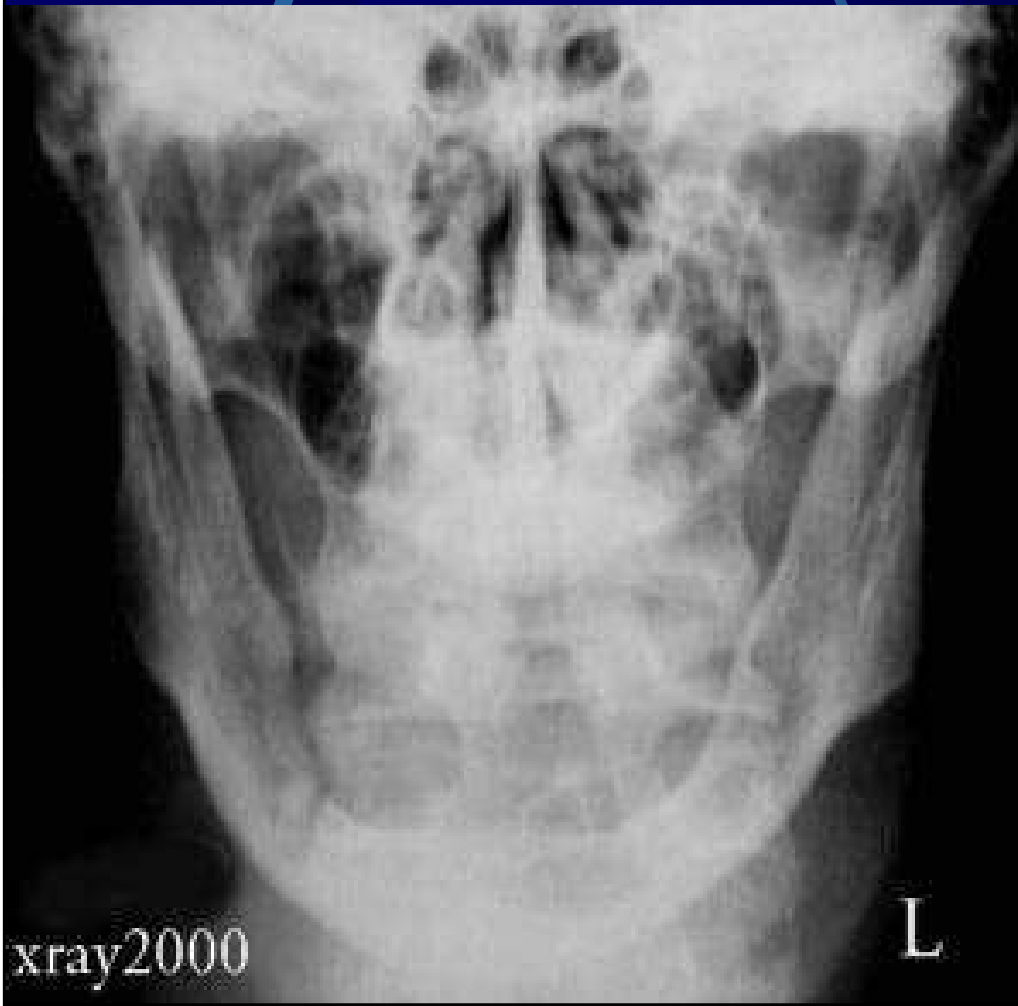

# Šikmá projekce mandibula – faciomaxilární





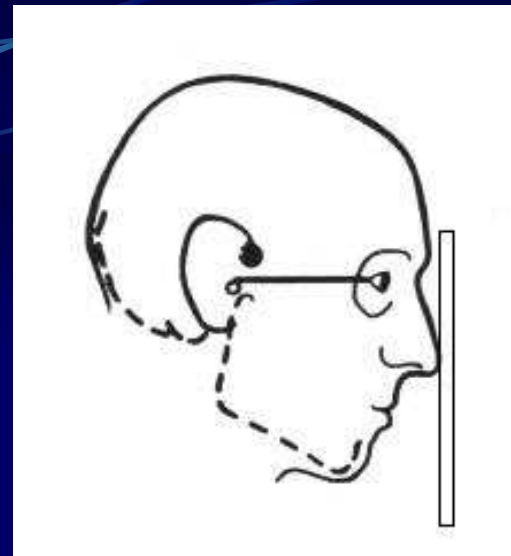
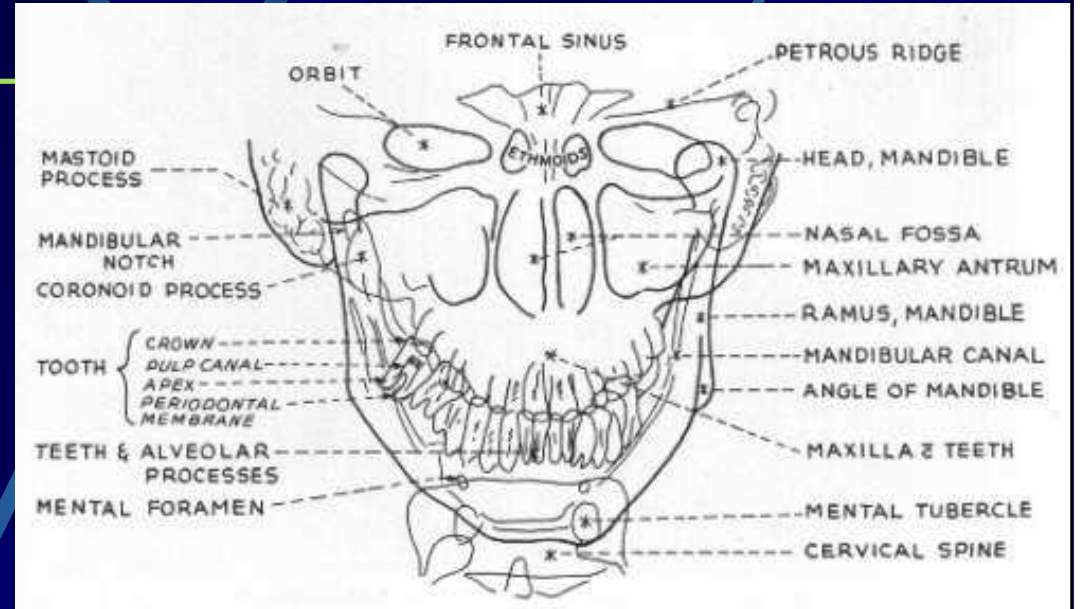


# Mandibula PA



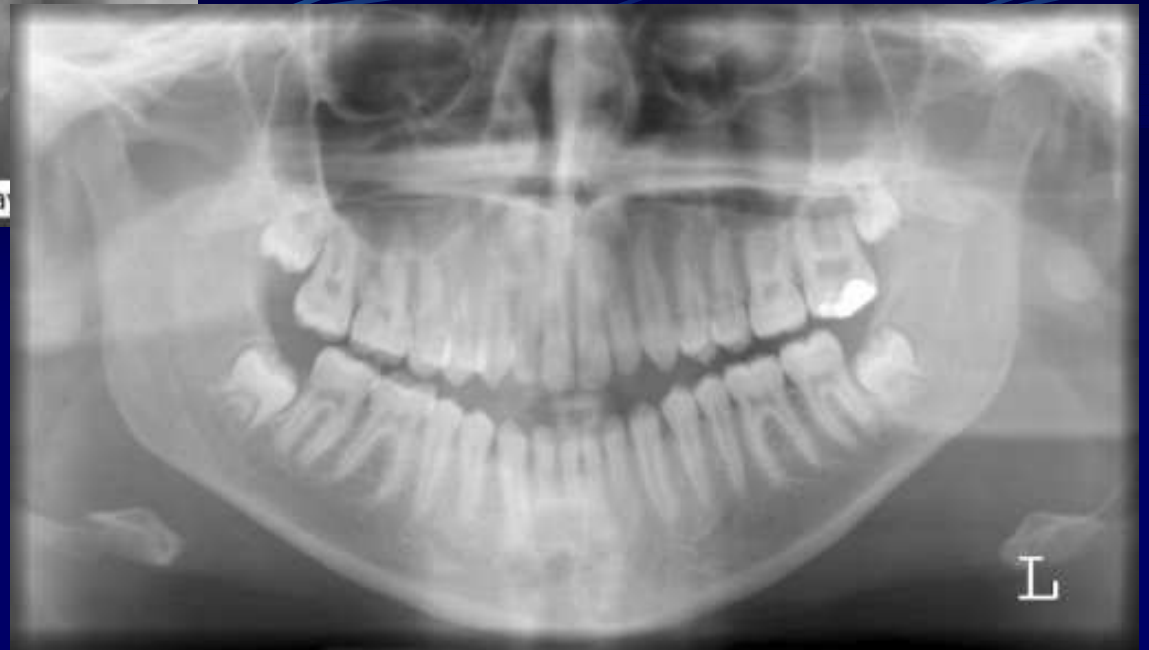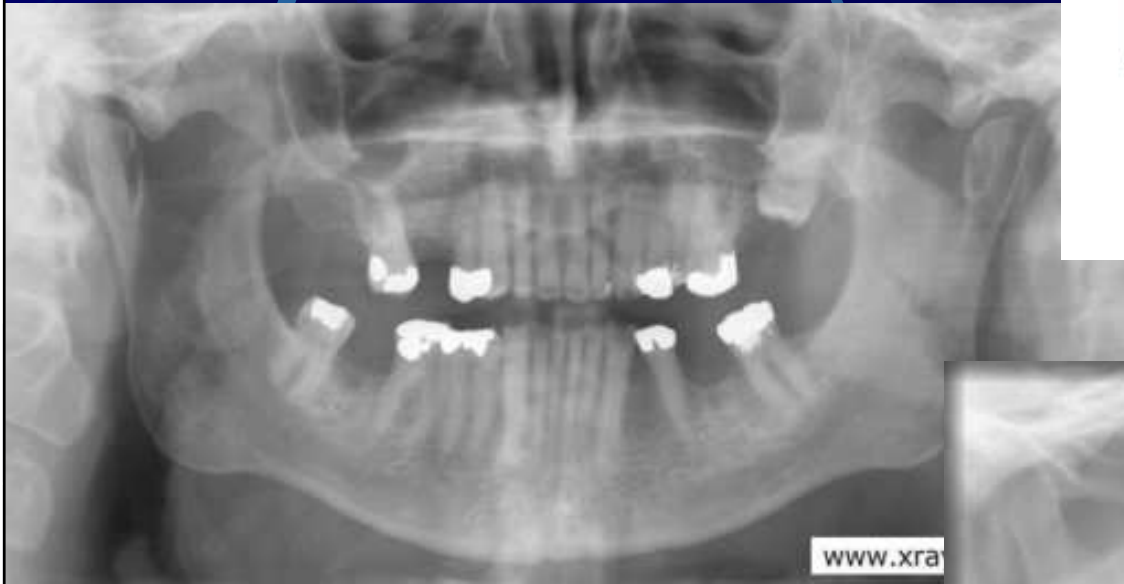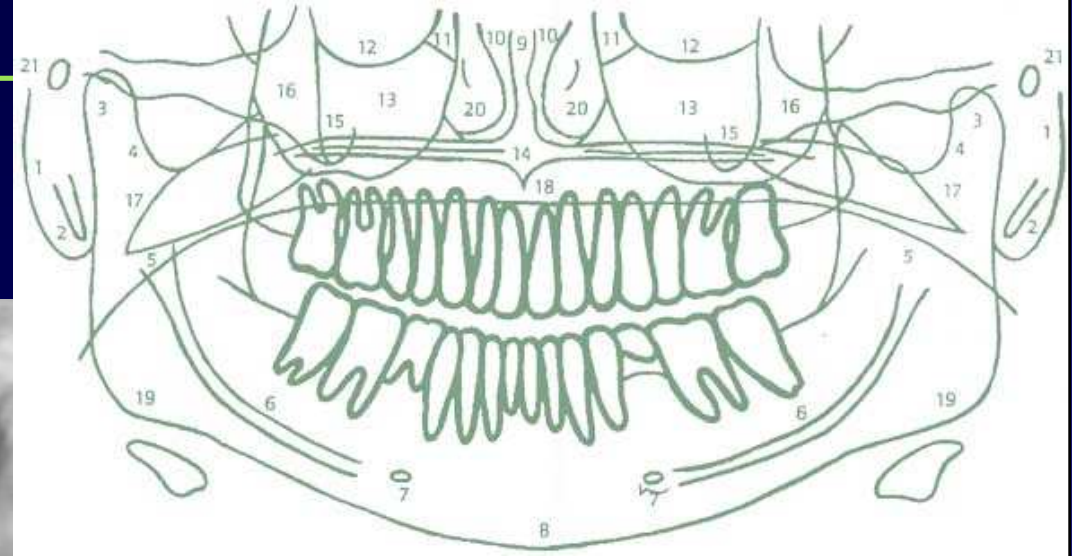

xray2000

L



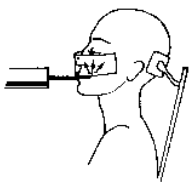
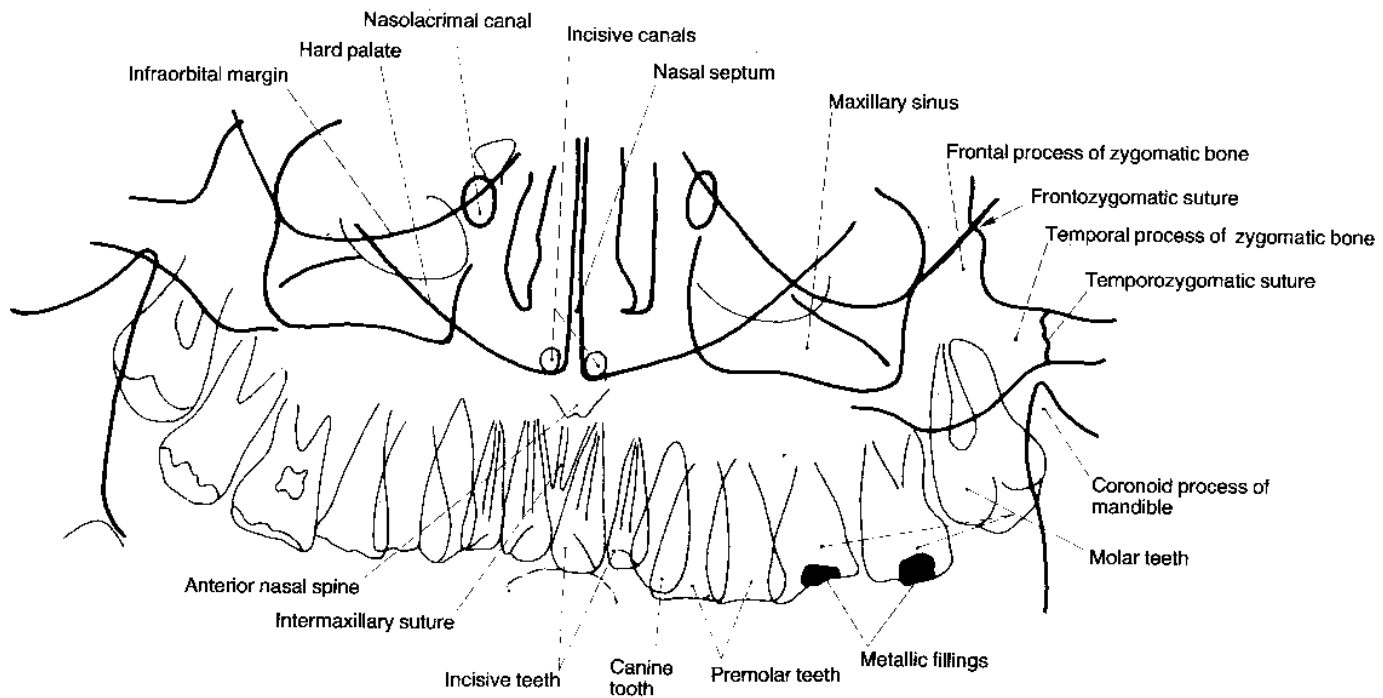
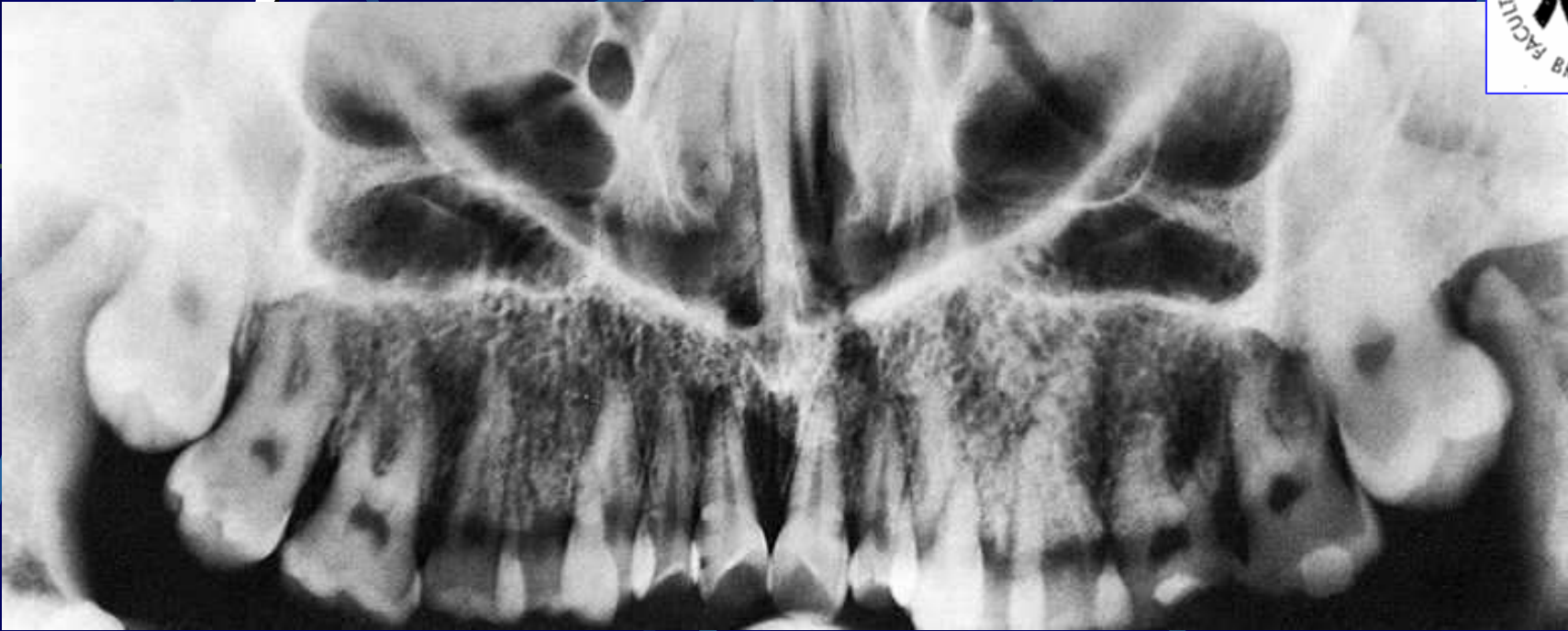


# Projekce





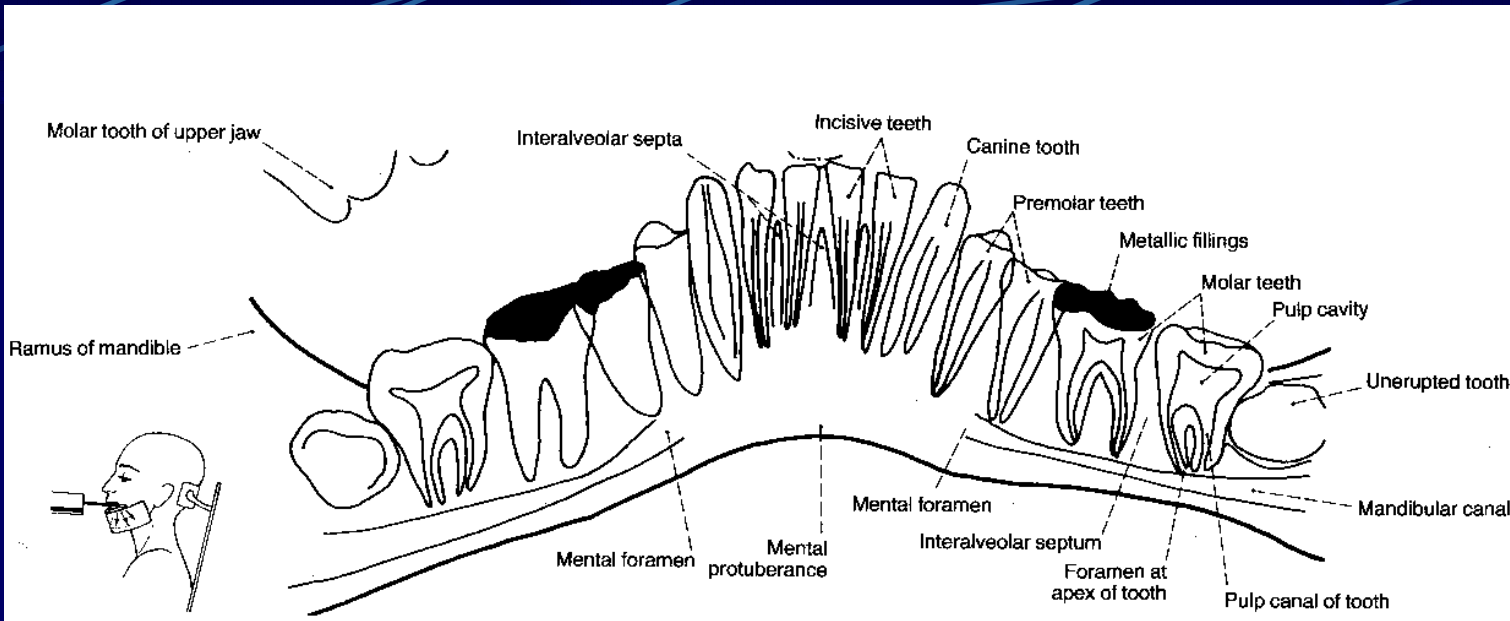
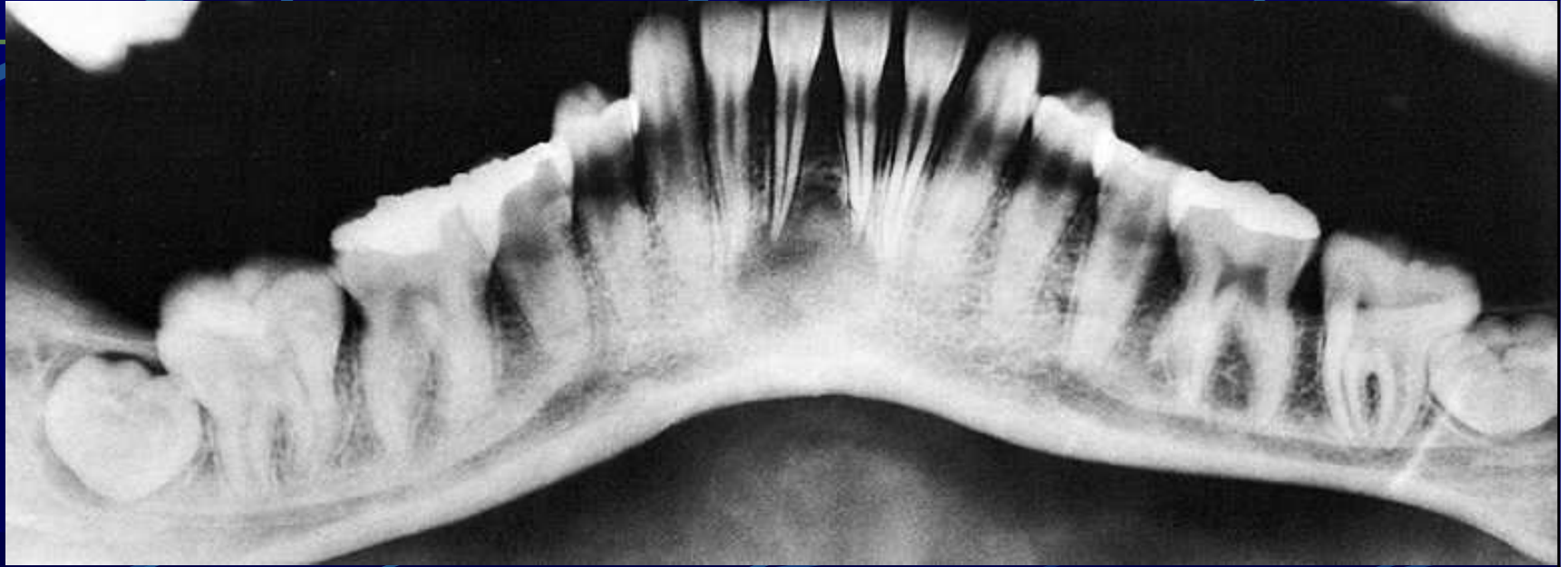
# Projekce





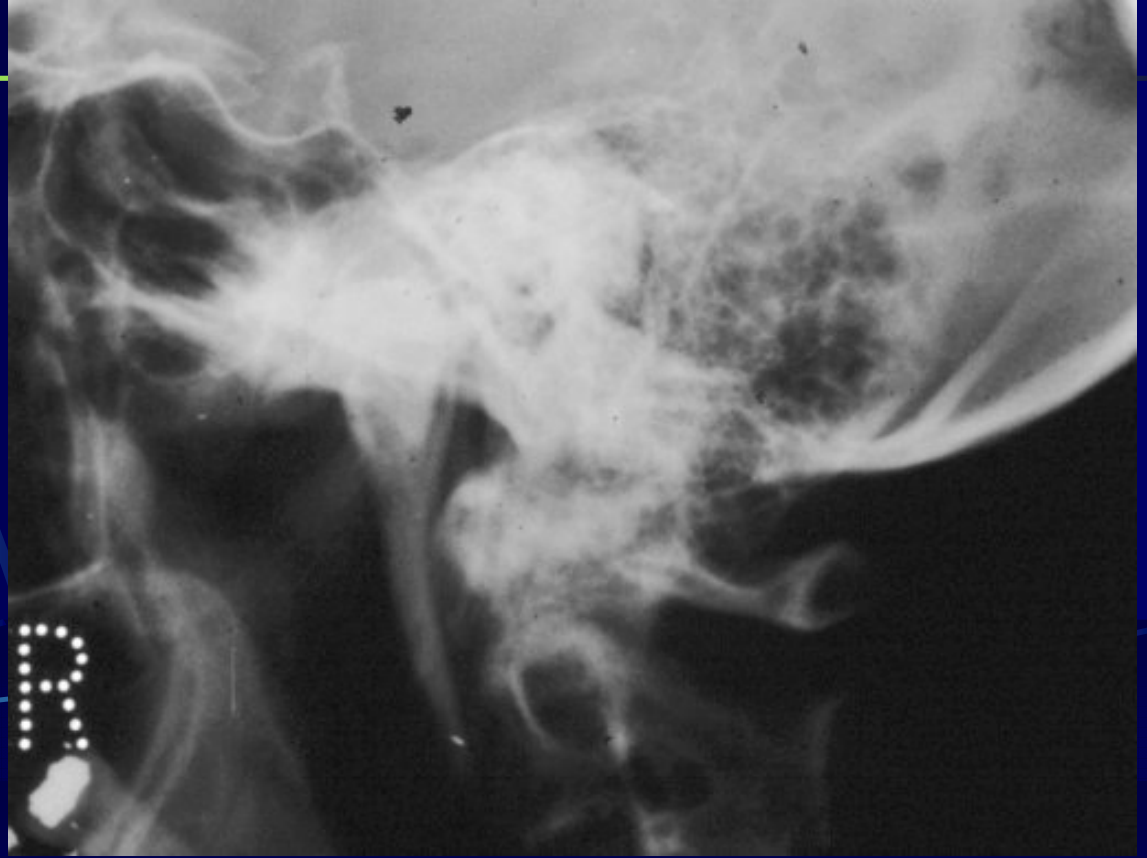
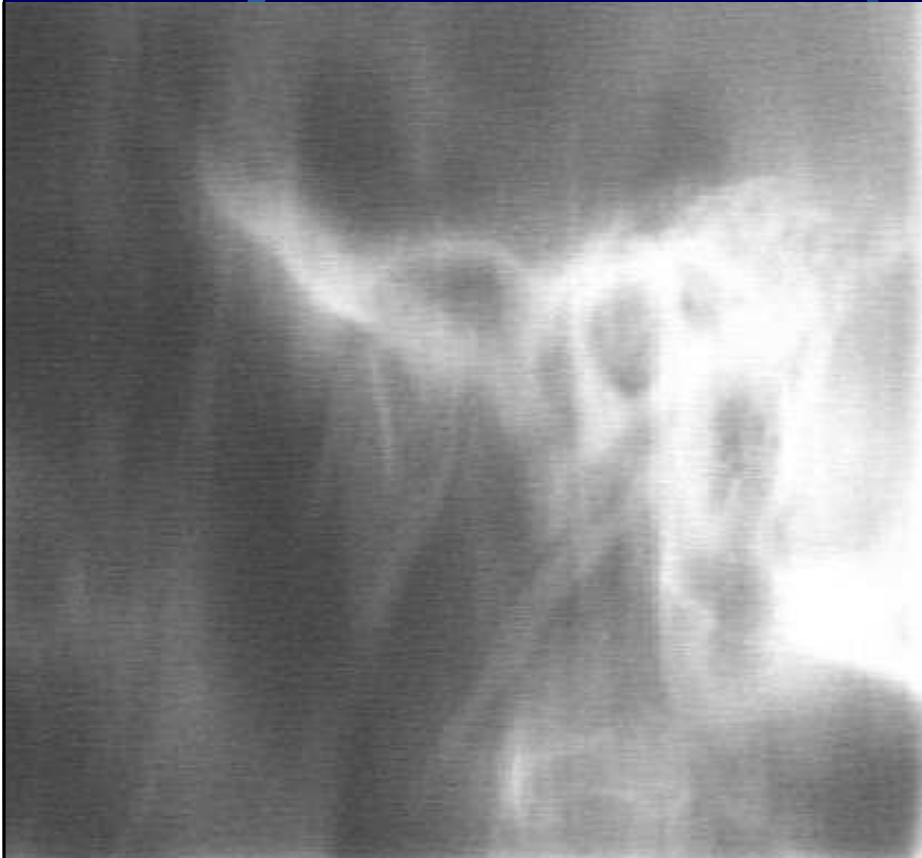


# Projekce





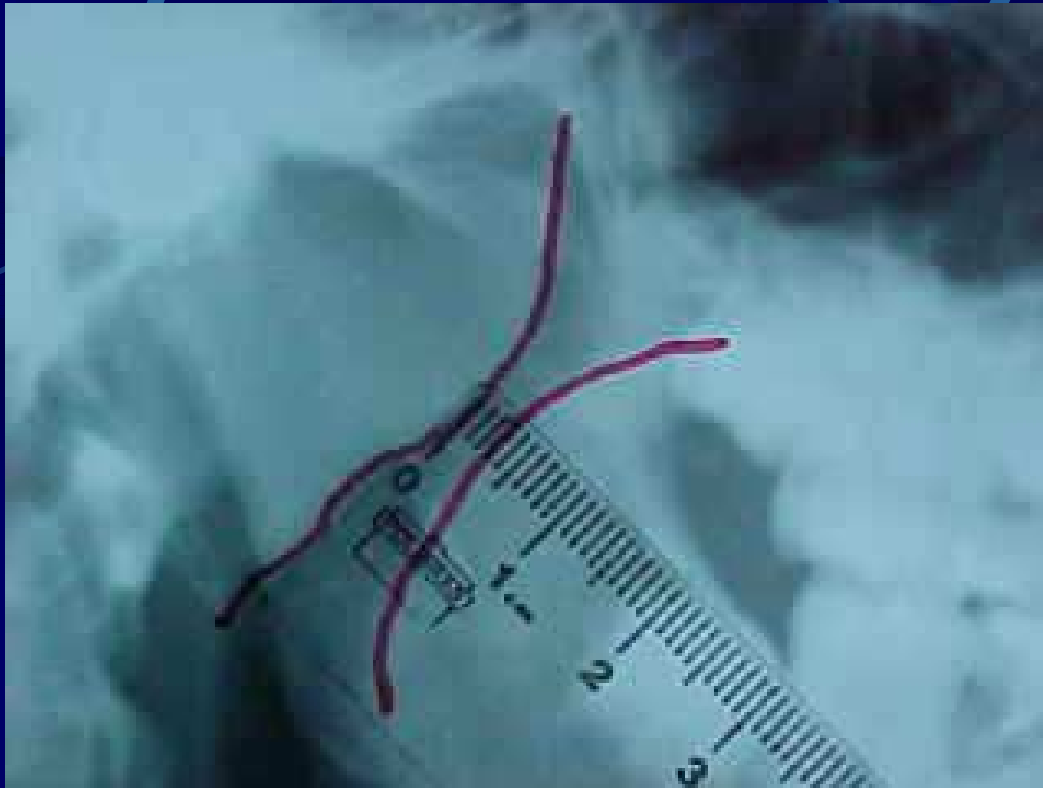
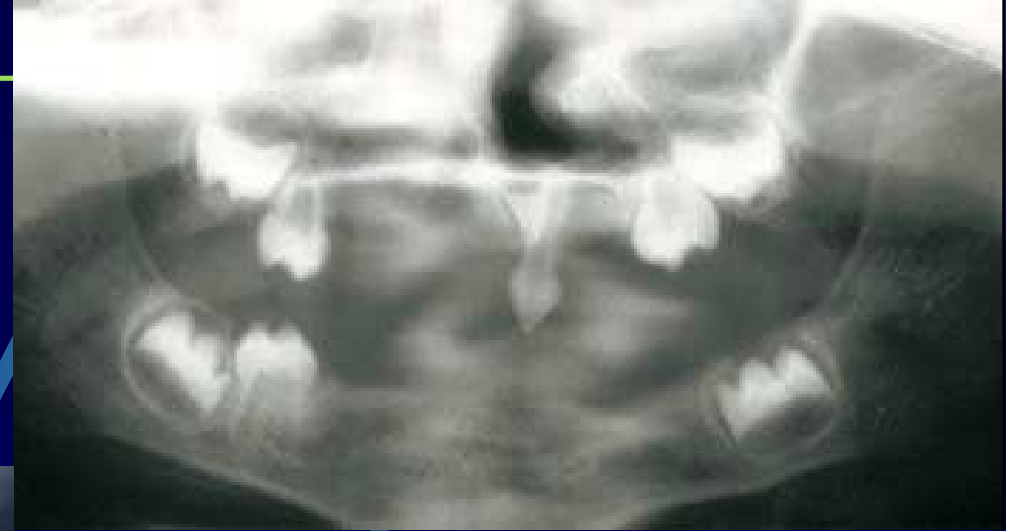
# Projekce





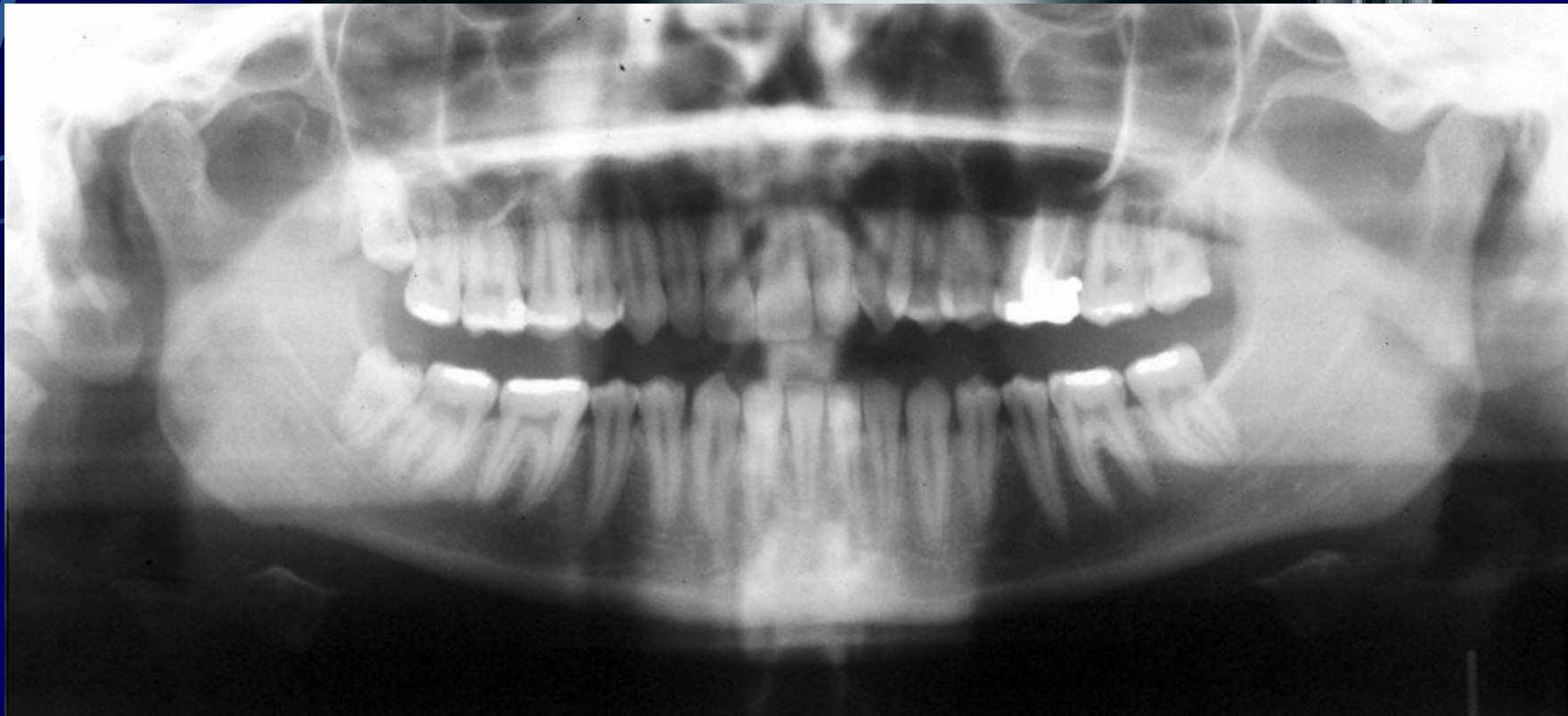
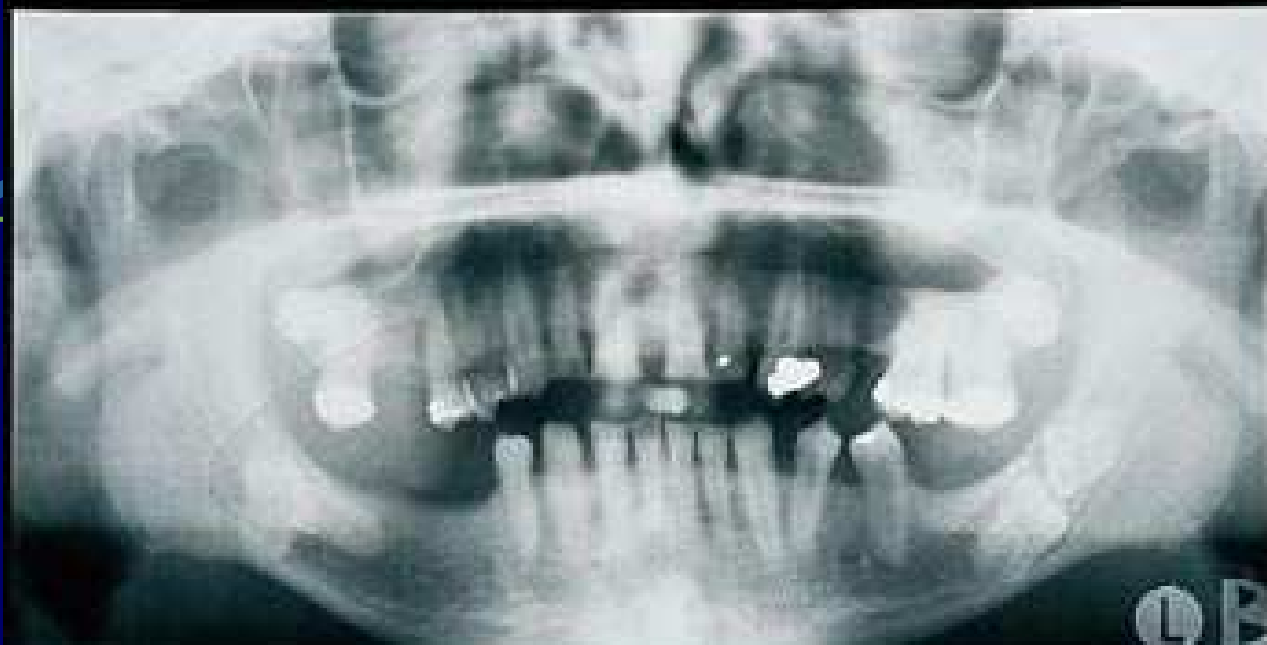
# Projekce



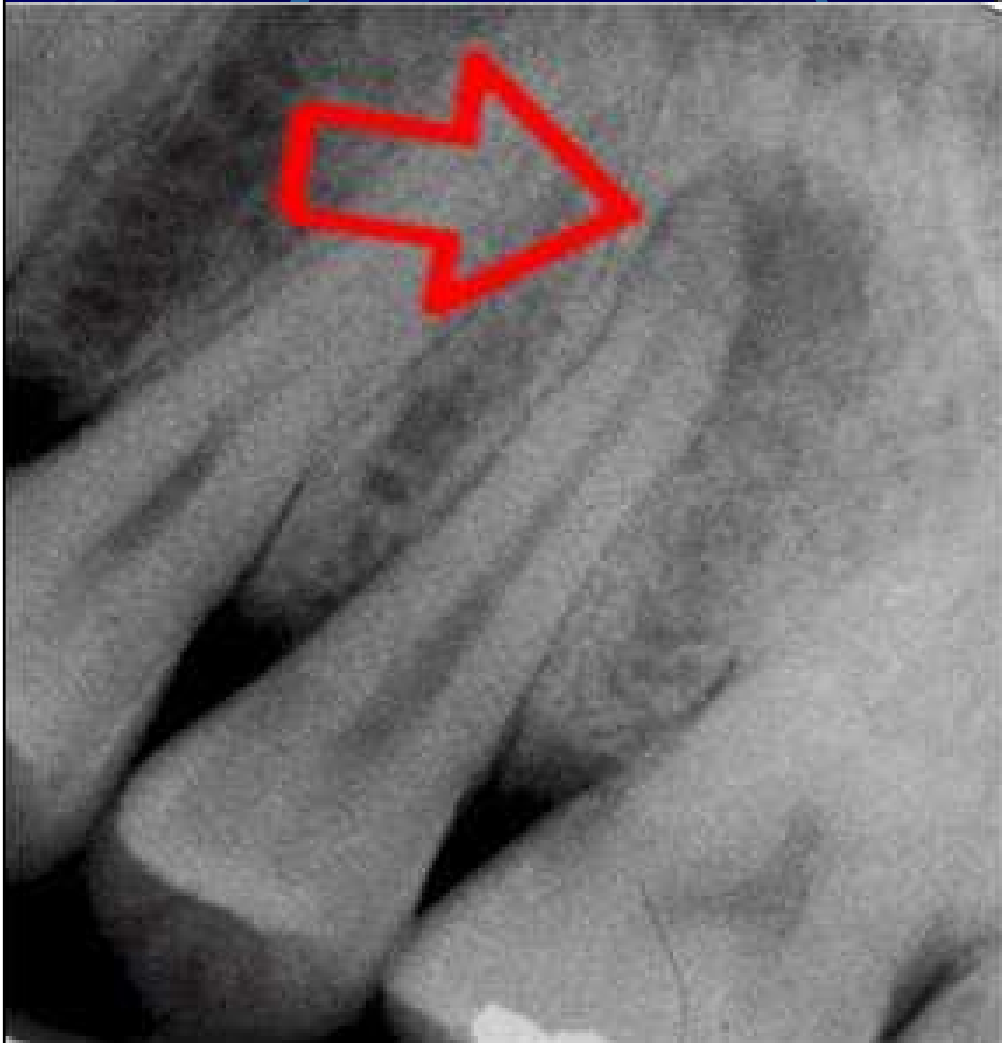


# Projekce



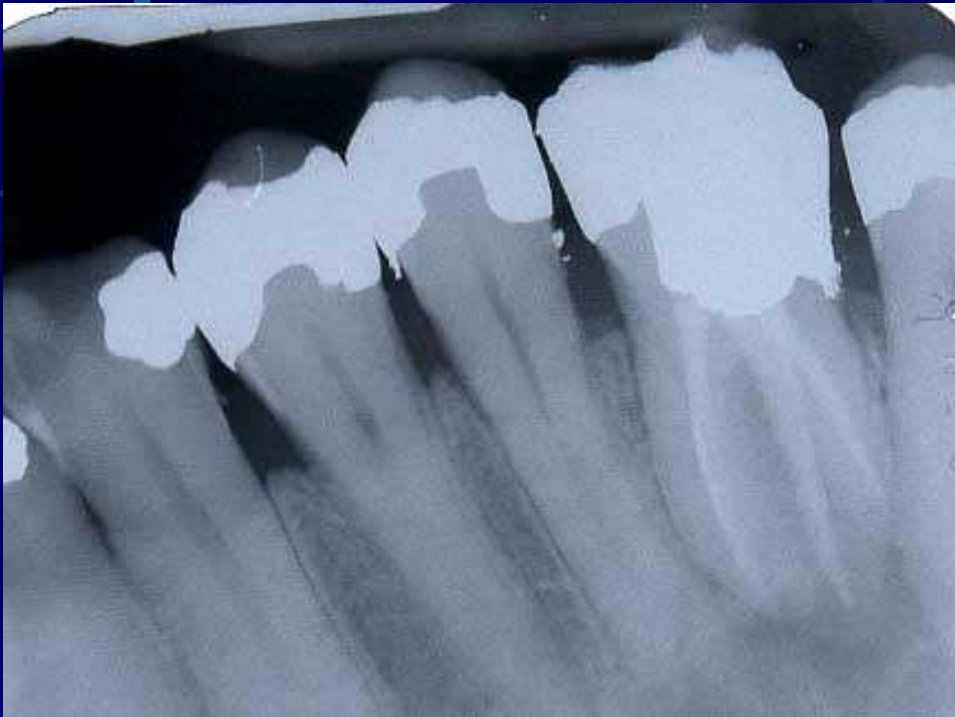
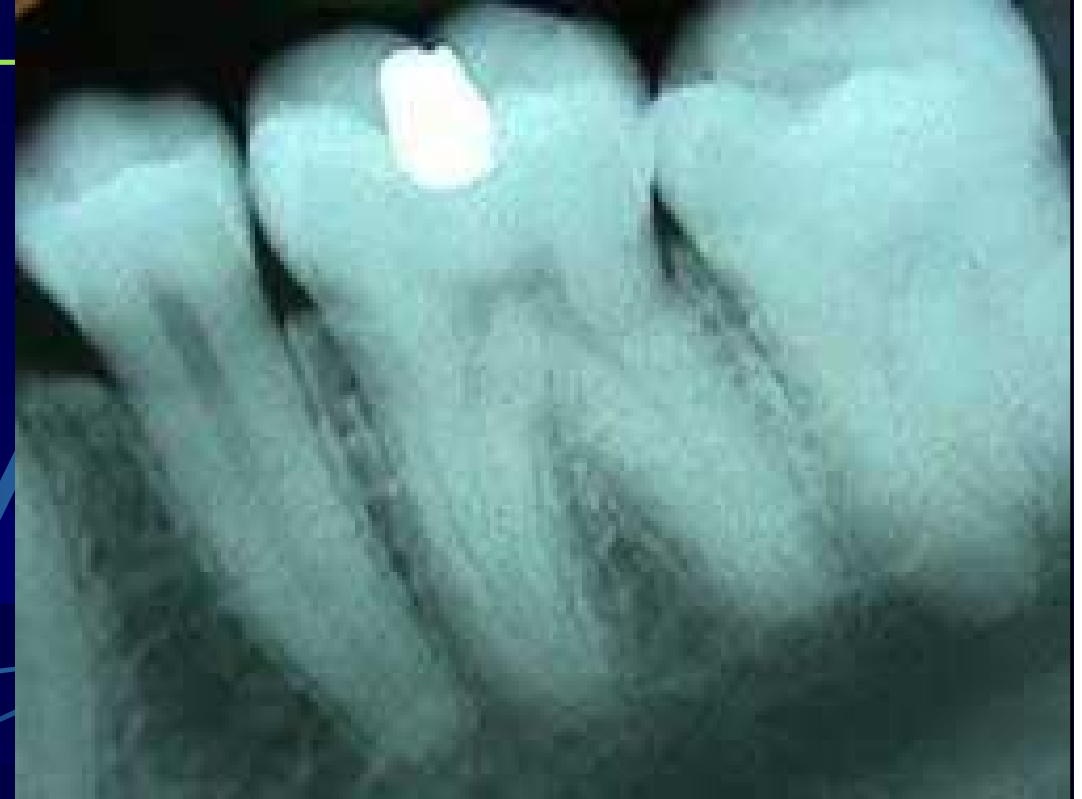

# Projekce





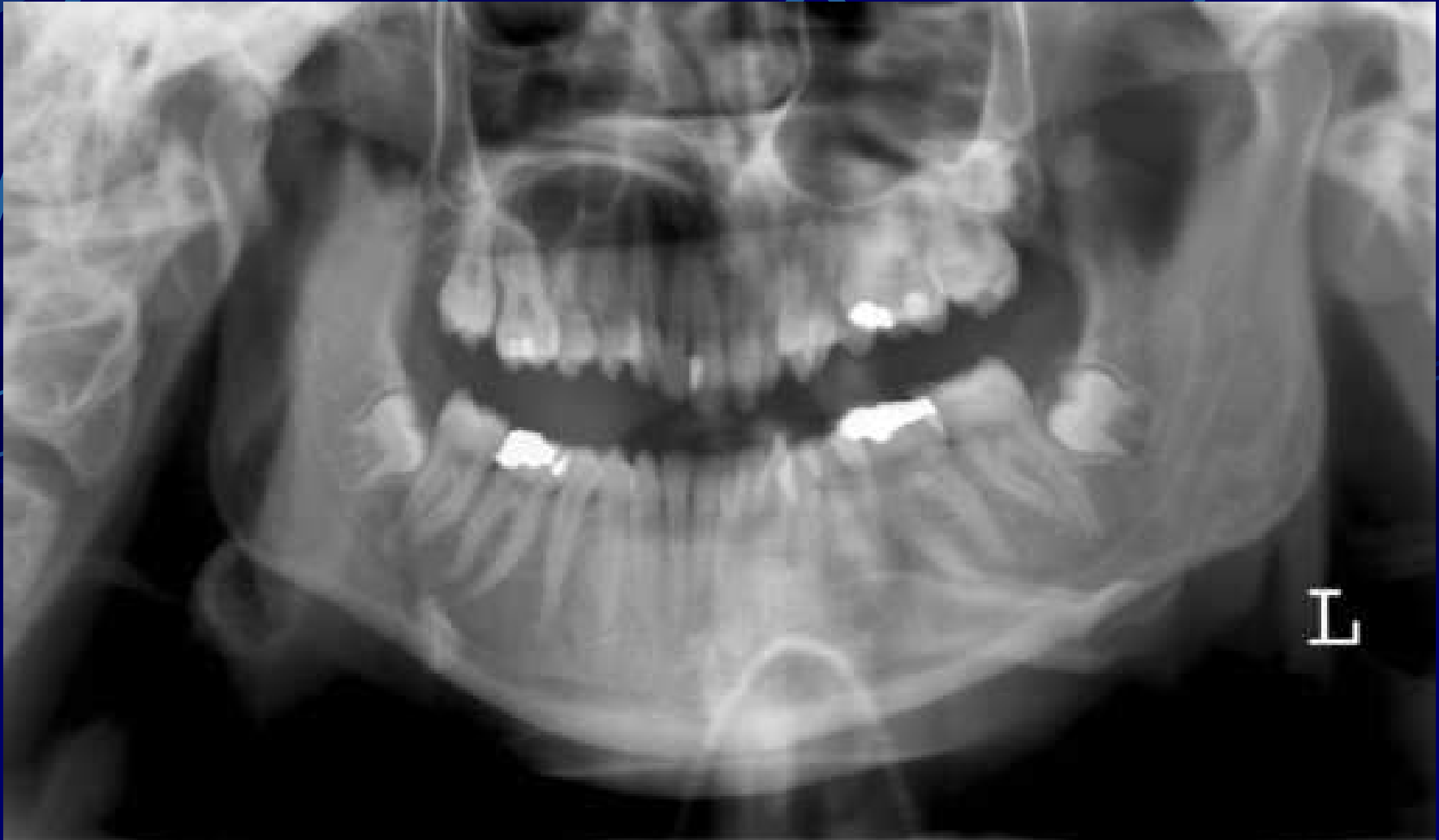
# Projekce








# Zuby - artefakt

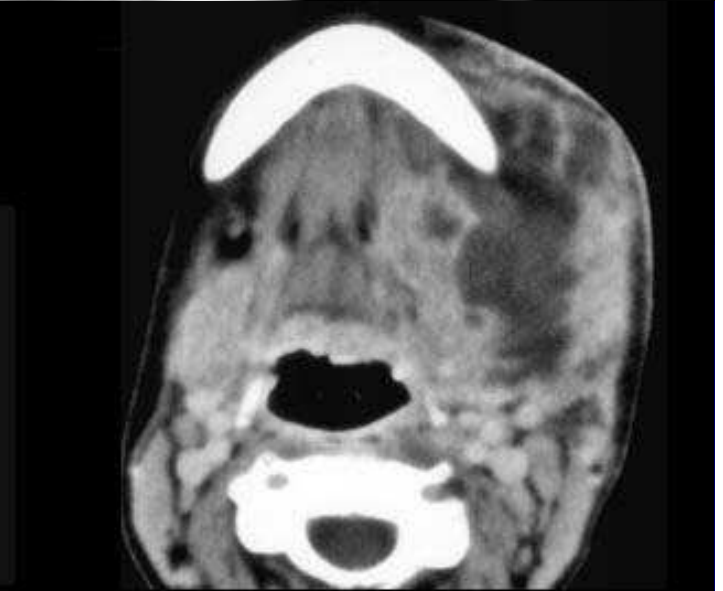
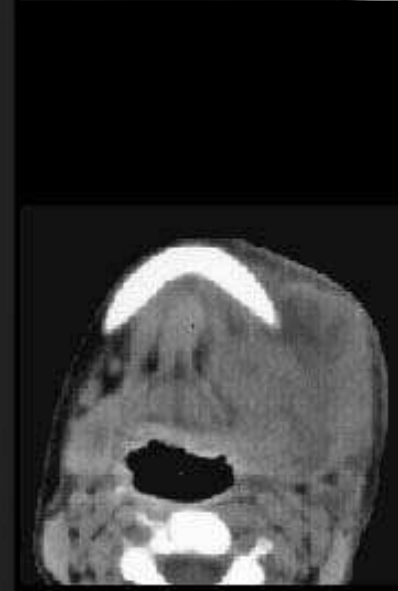
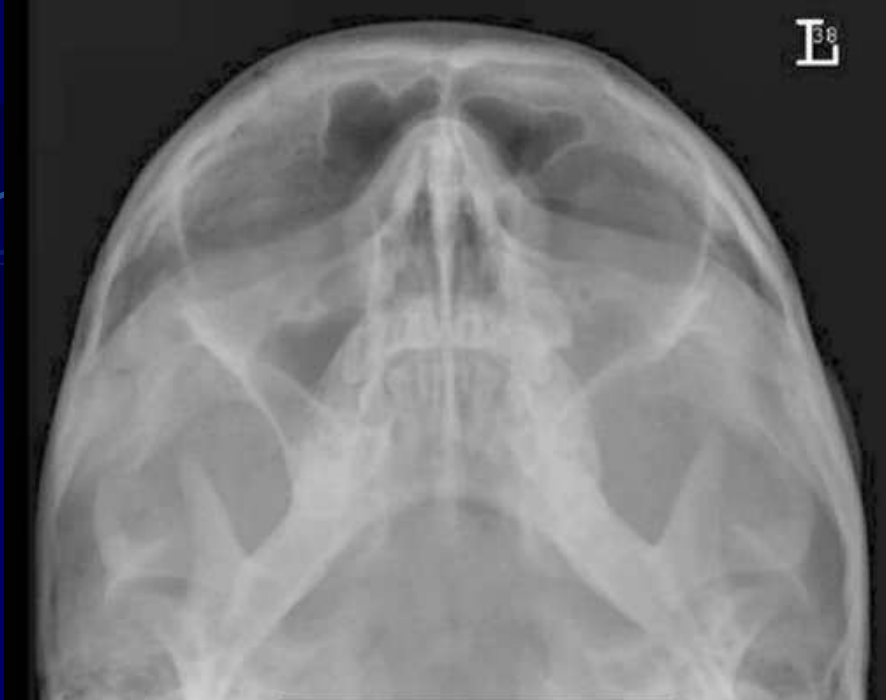
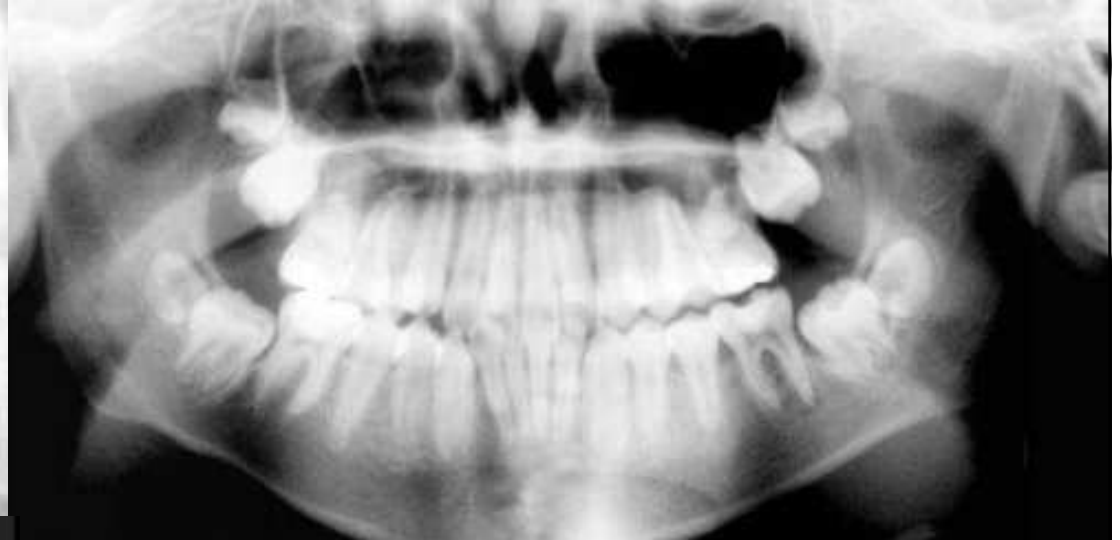
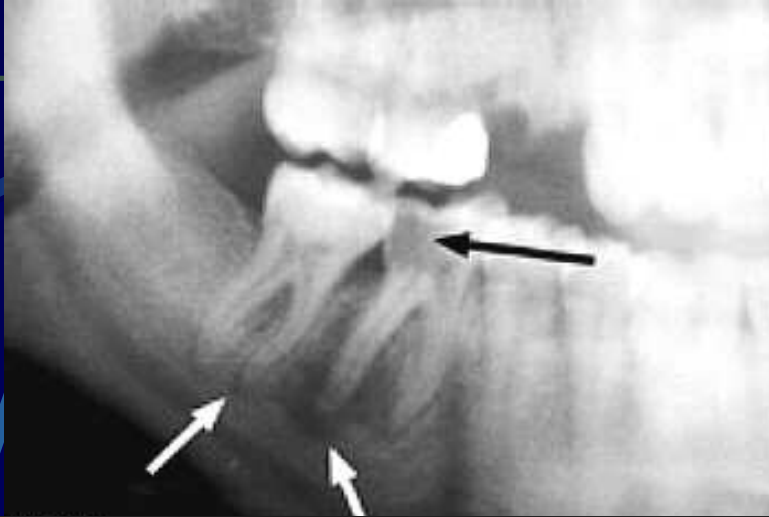


# Patologie

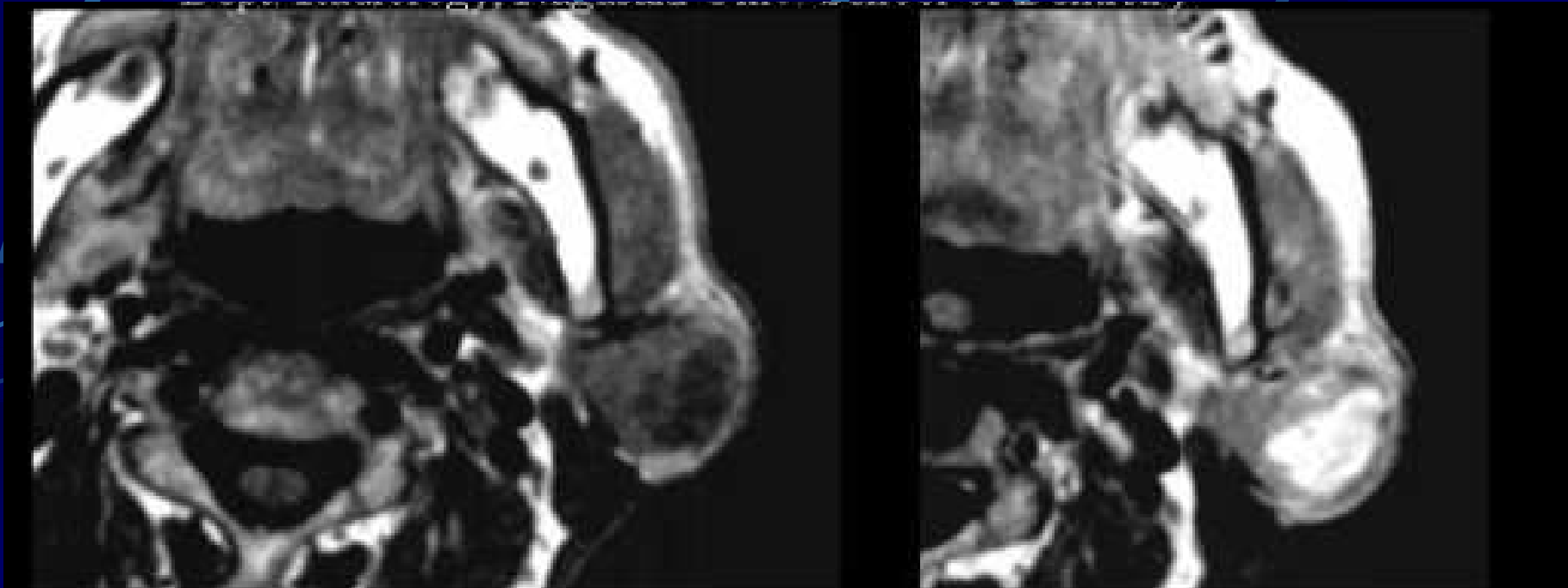


# Absces





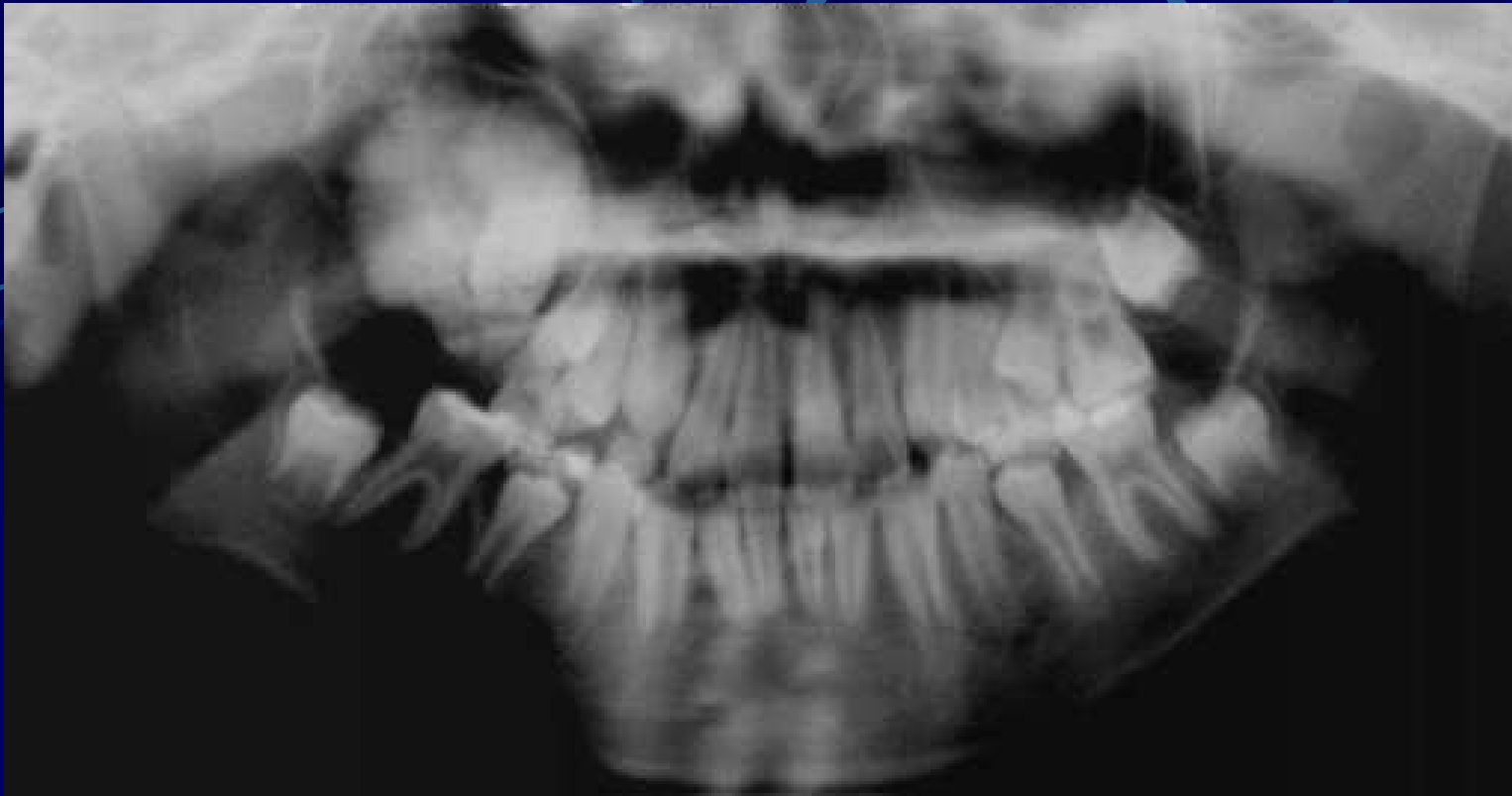
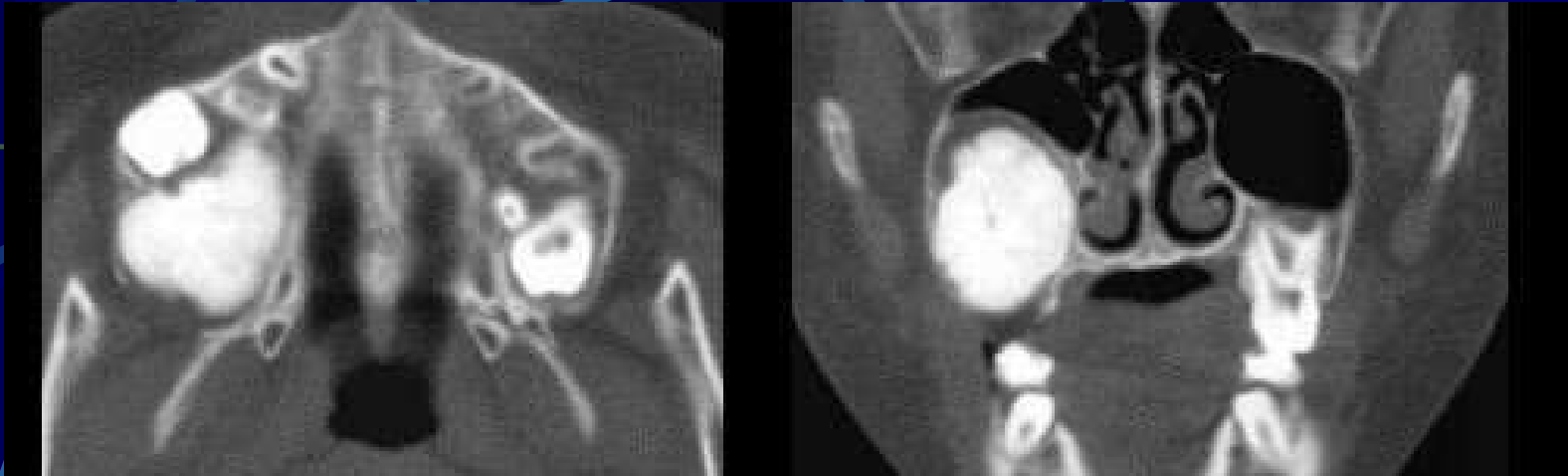
# Adenolymfoma





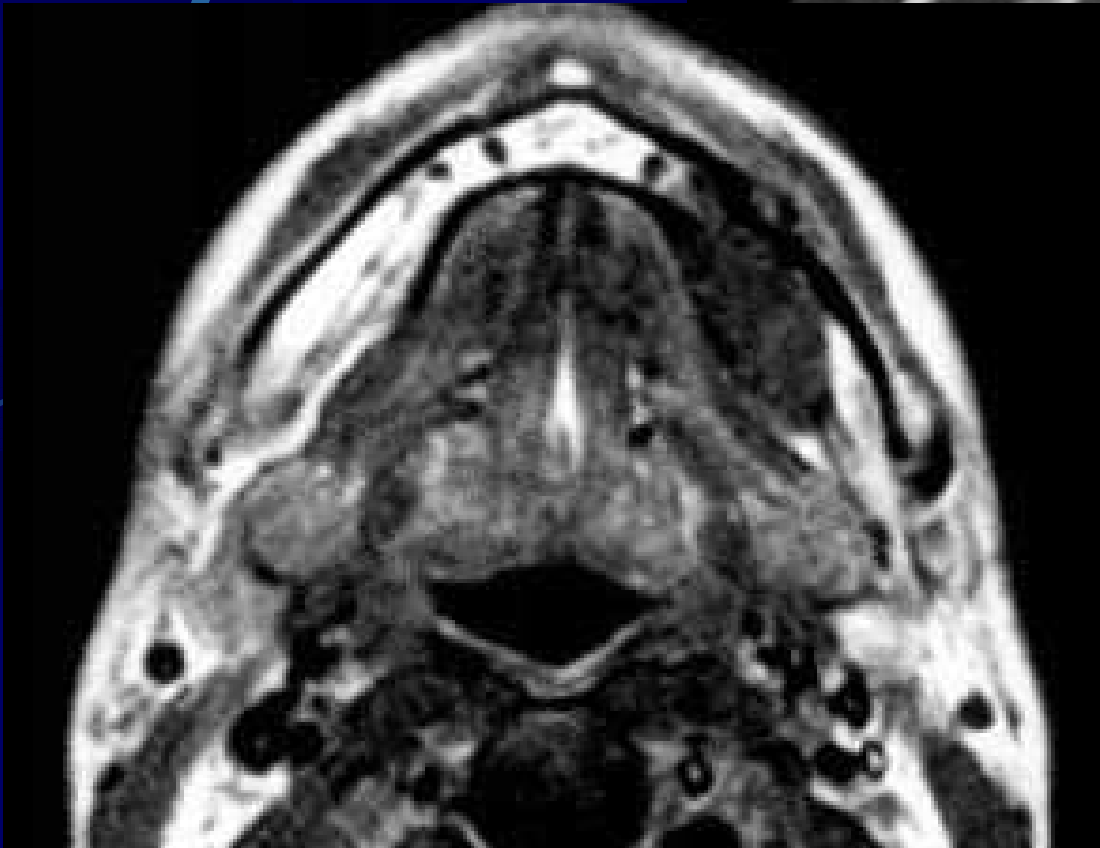
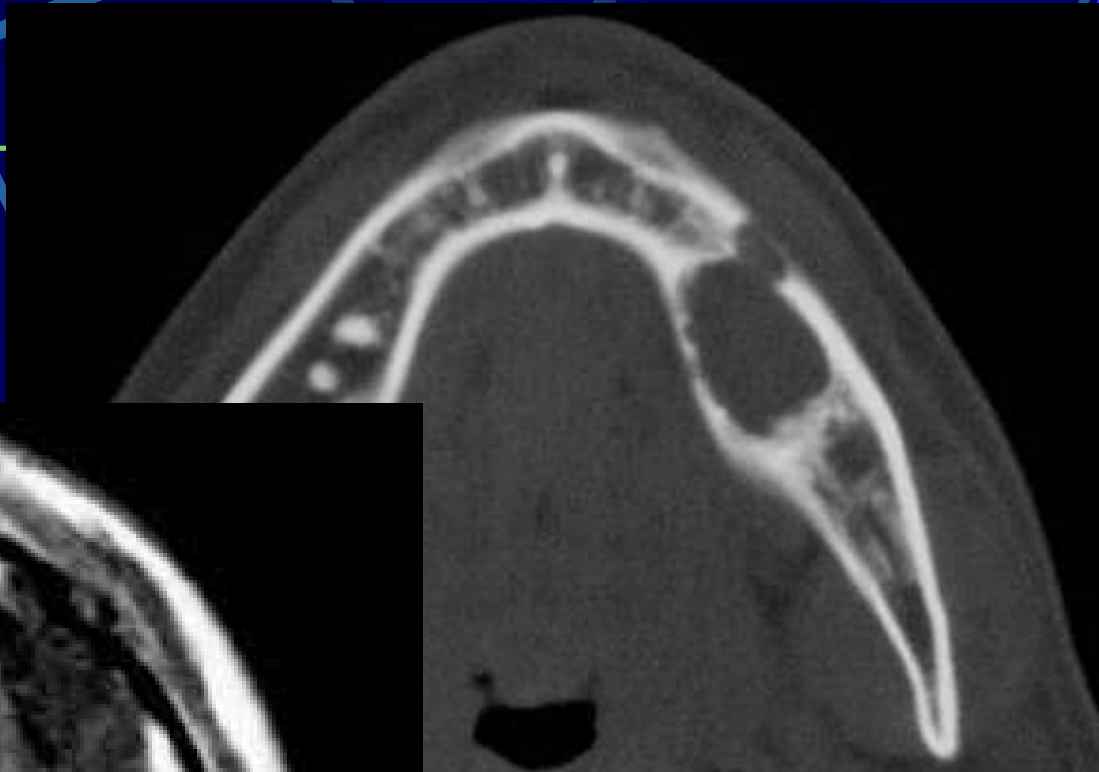



# Facionmaxilární ameloblastický fibrom



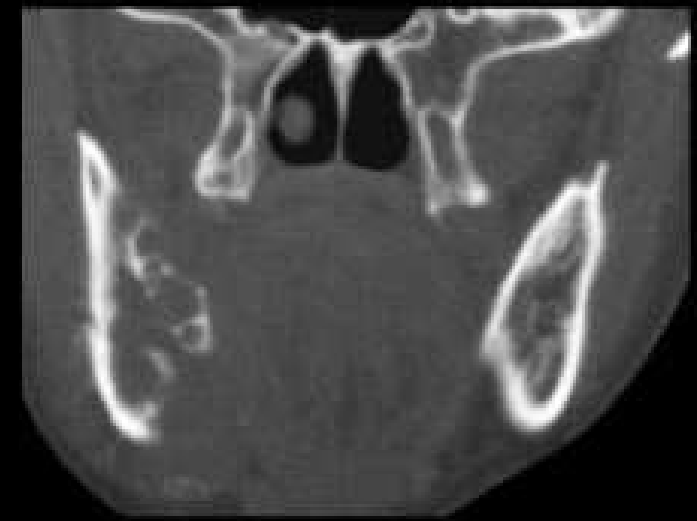
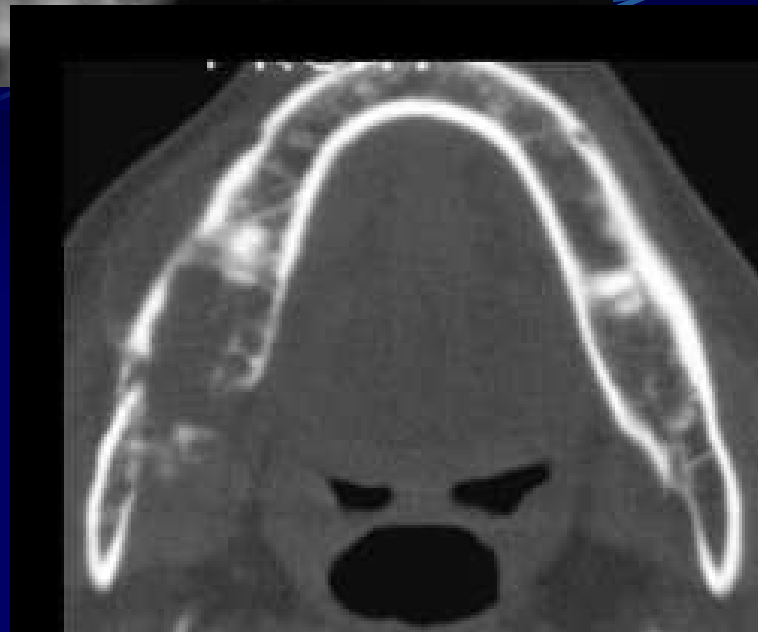
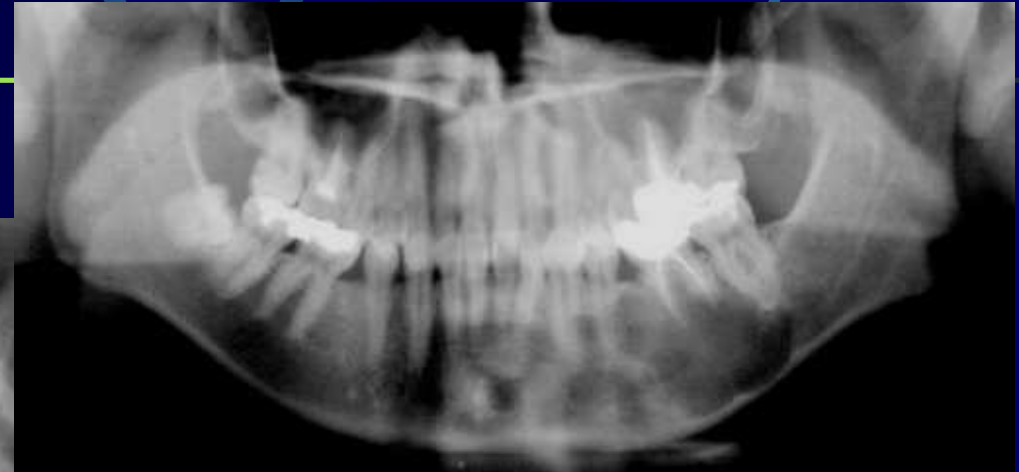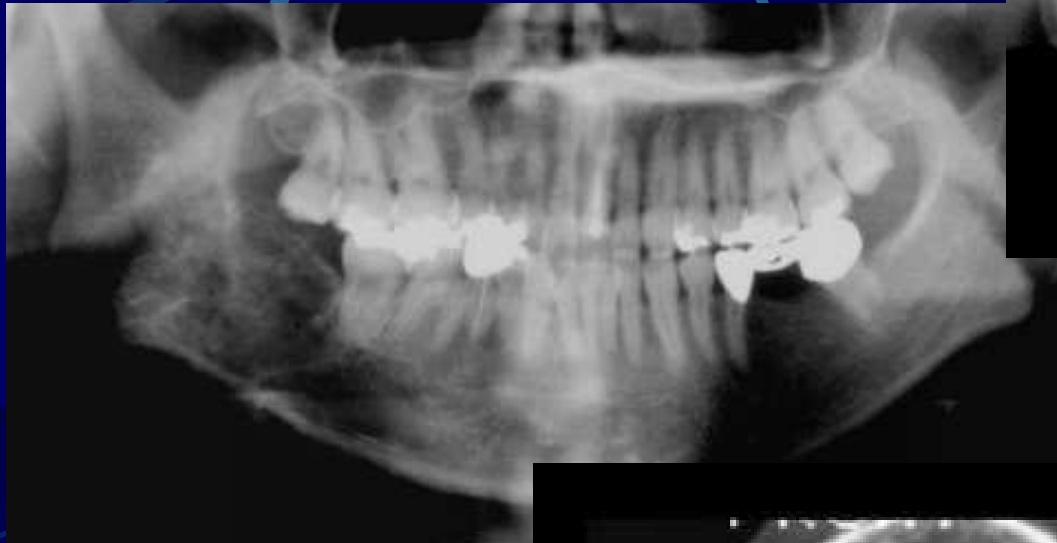# Fibrom



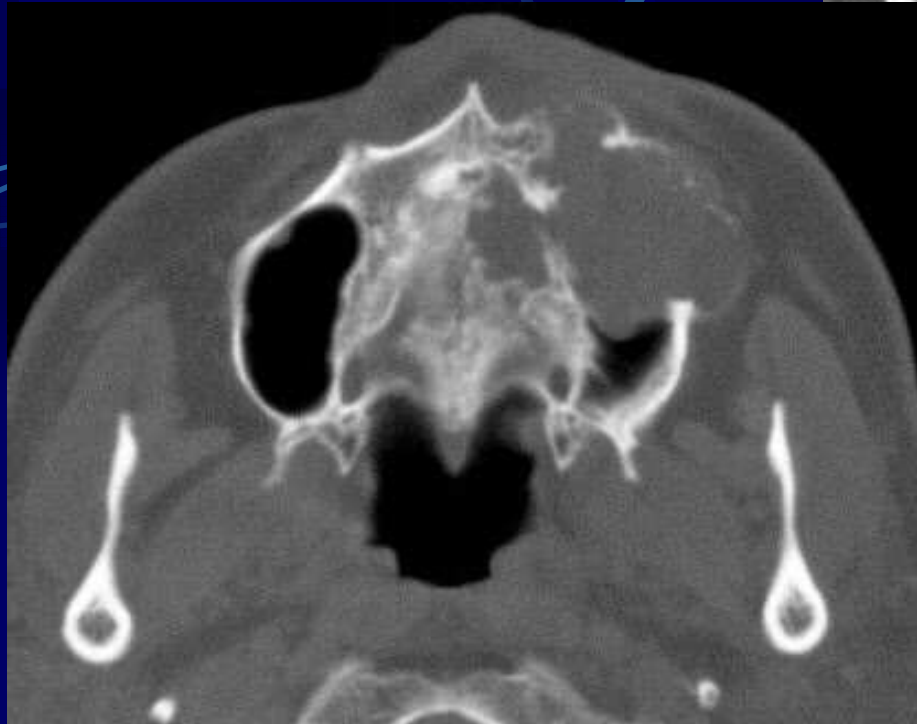
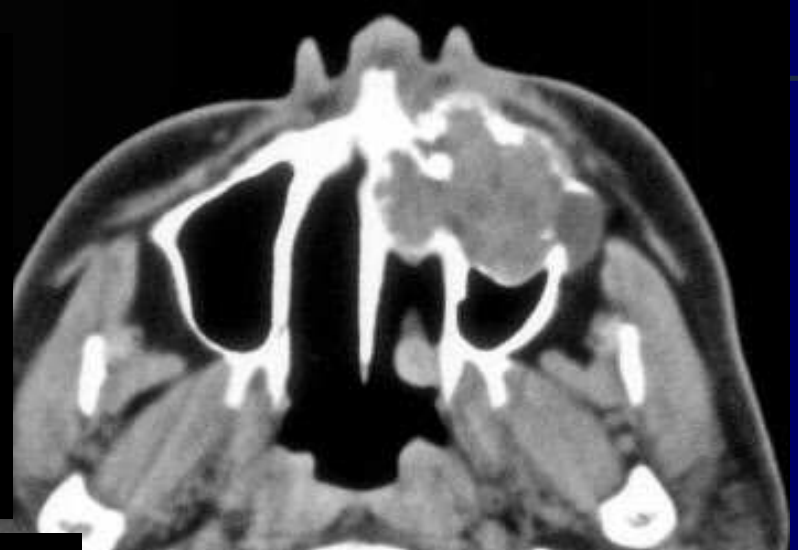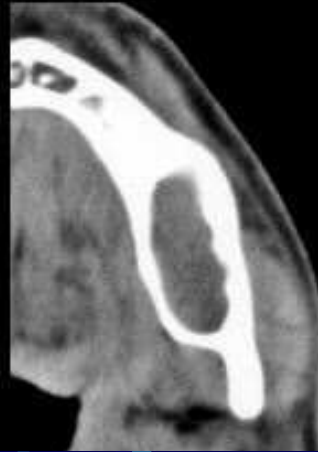
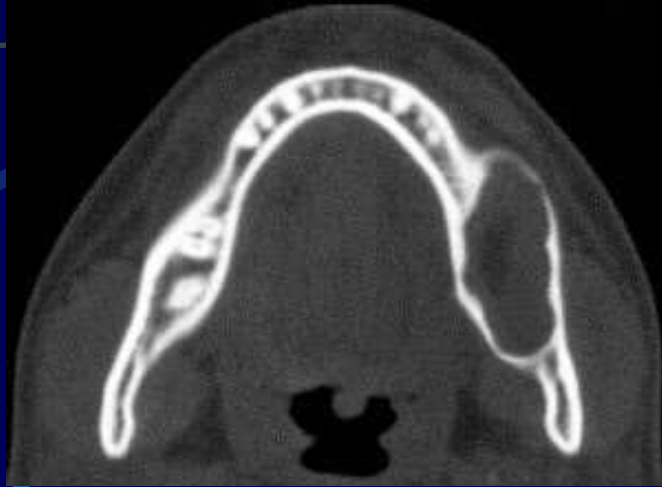



# Facionmaxilární ameloblastický fibrosarkom





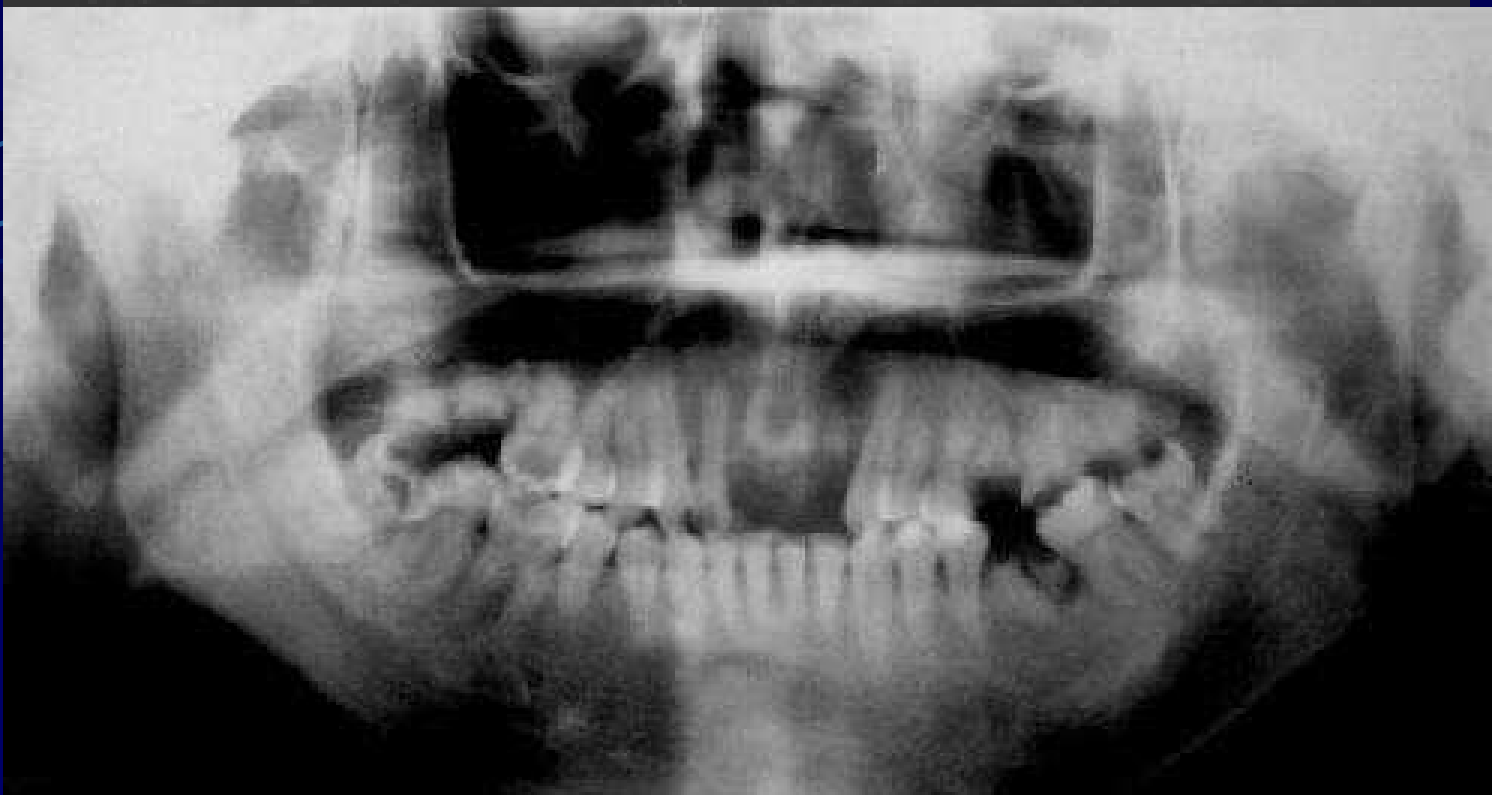
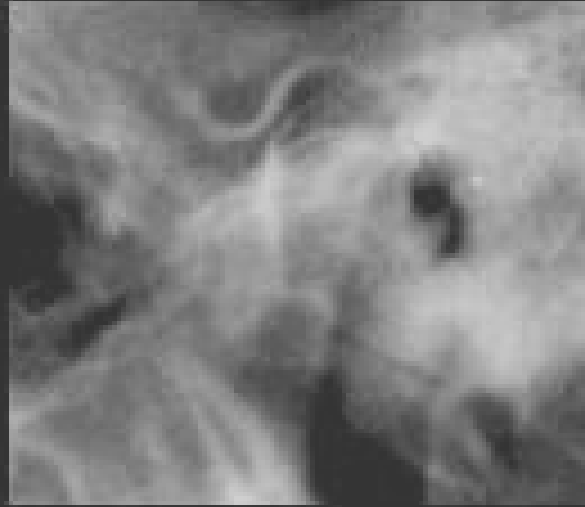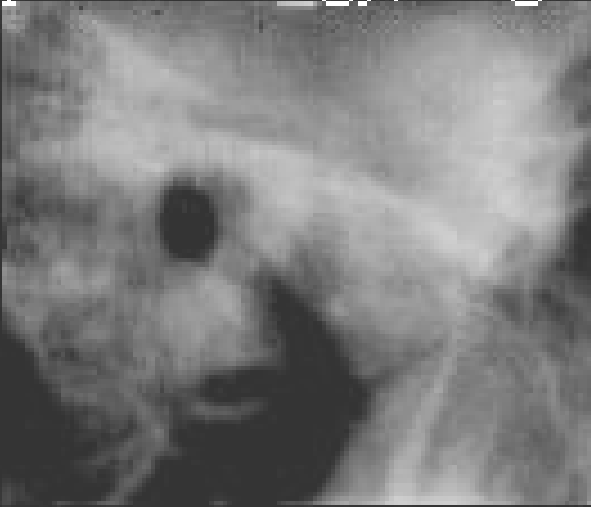# Ameloblastom





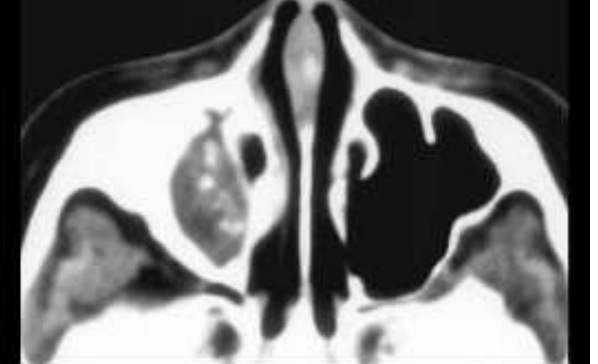
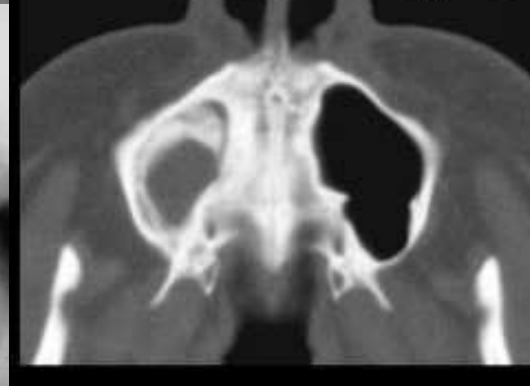
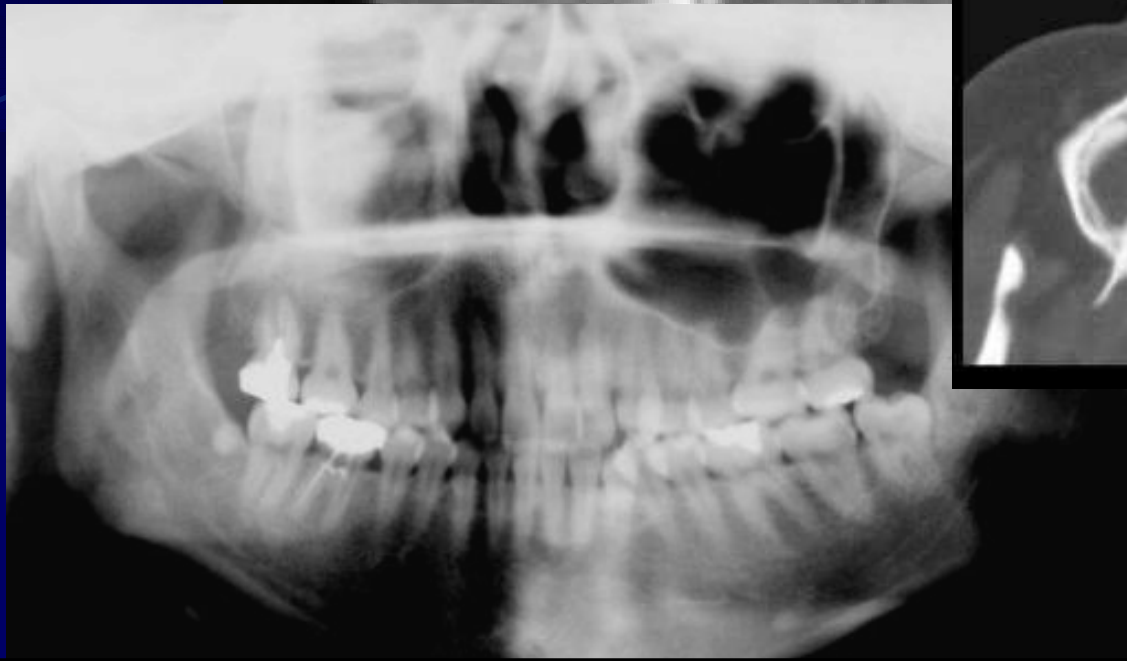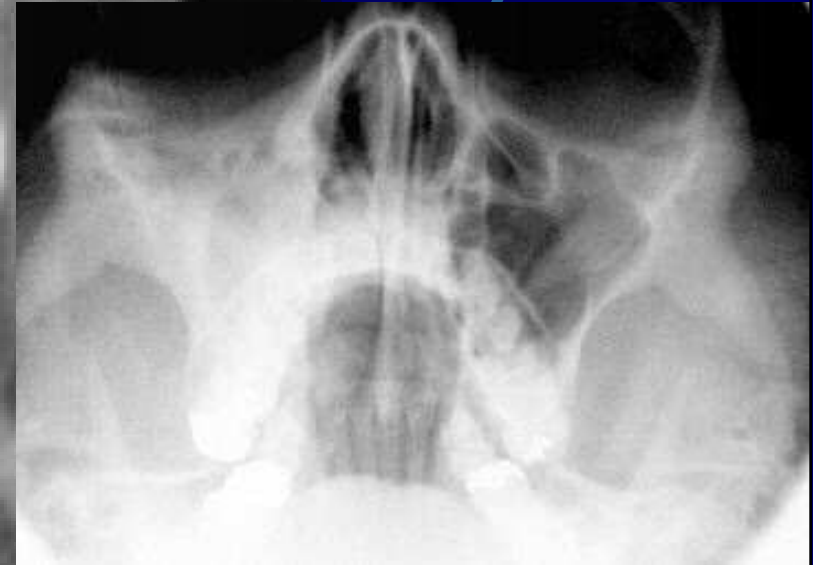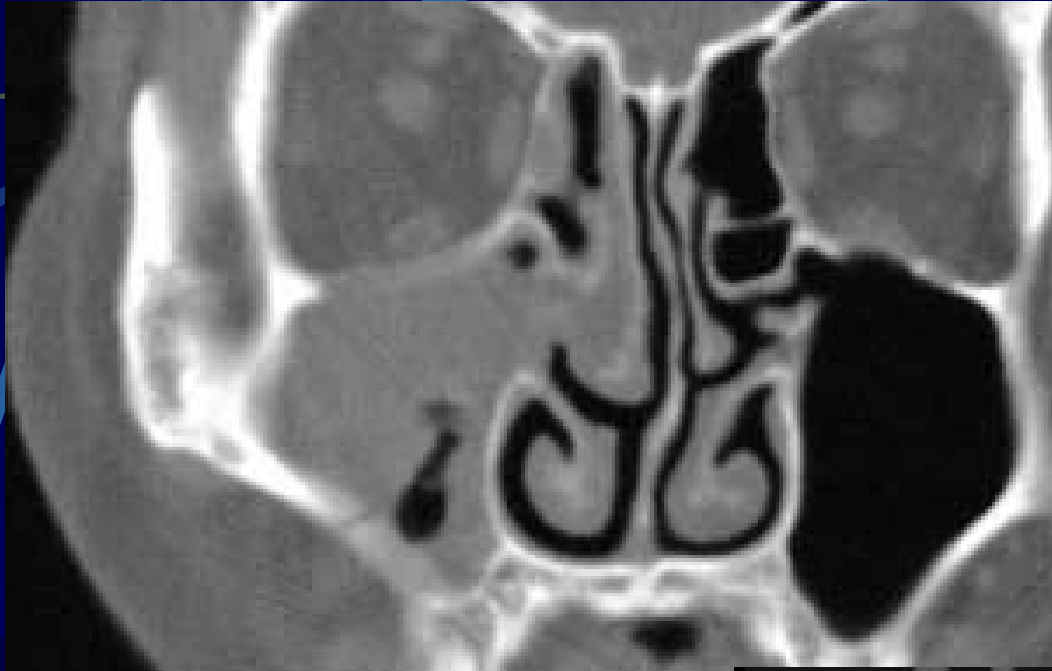



# Ankylozující artritida



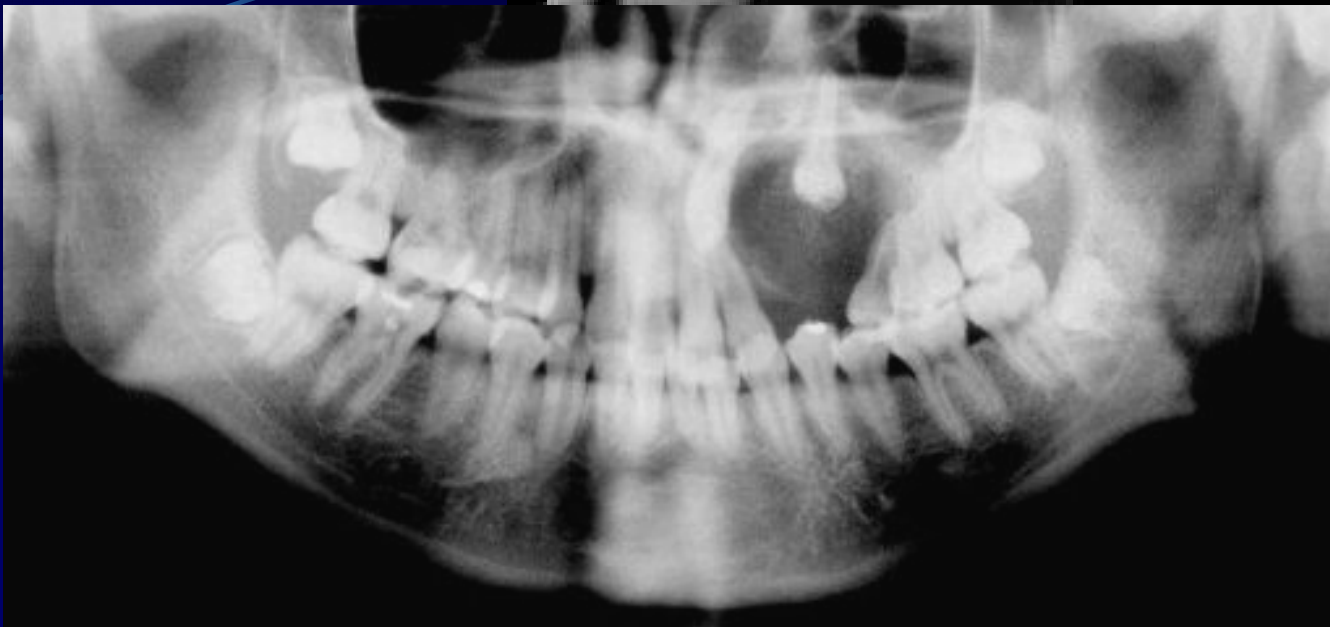
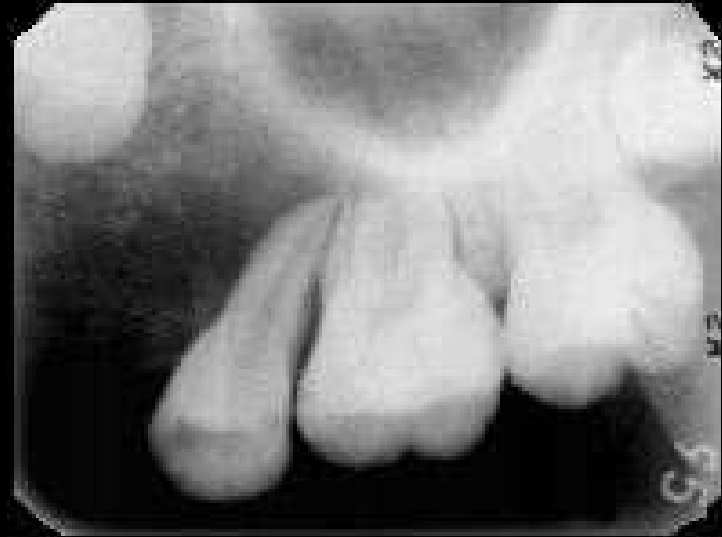
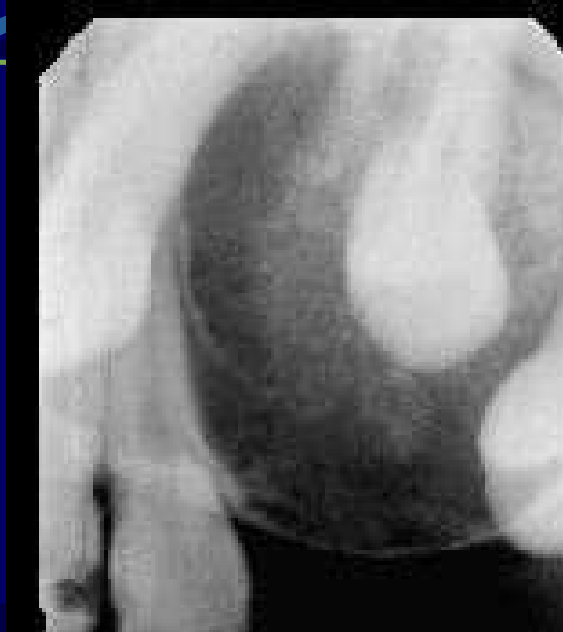# Aspergilóza



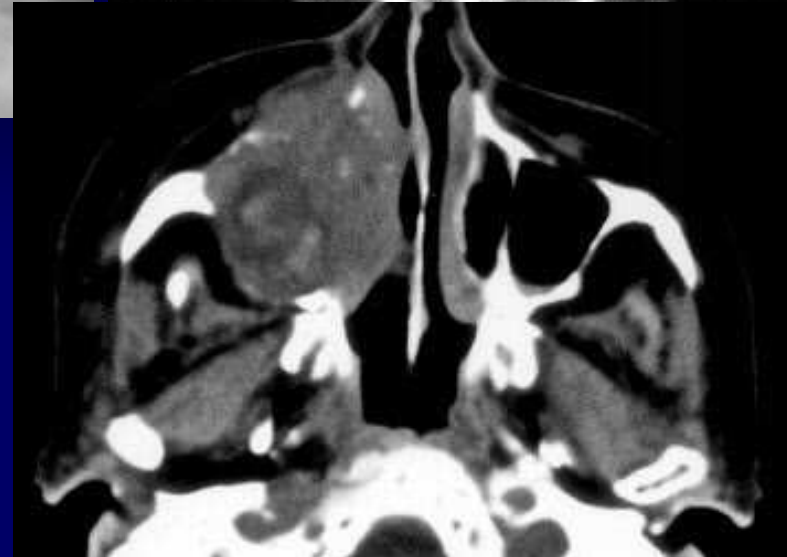
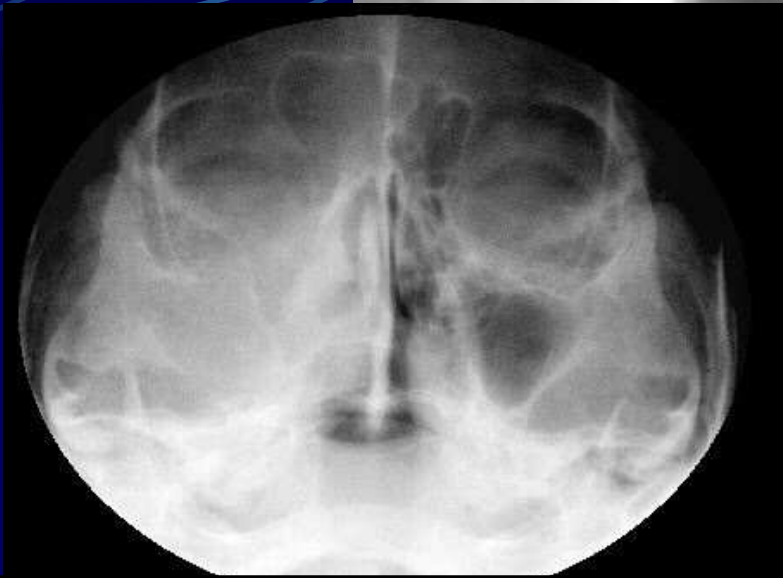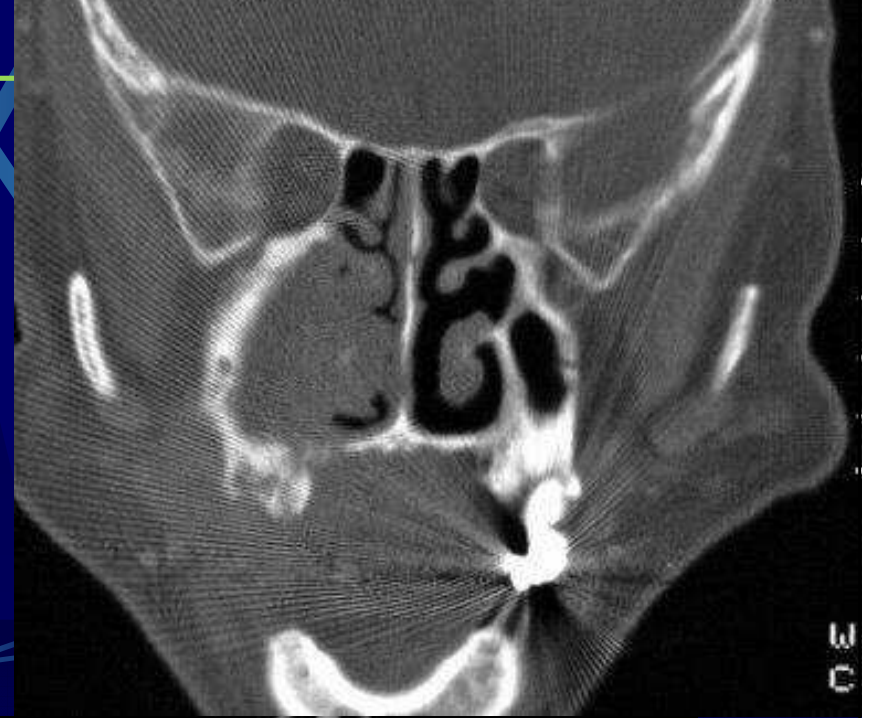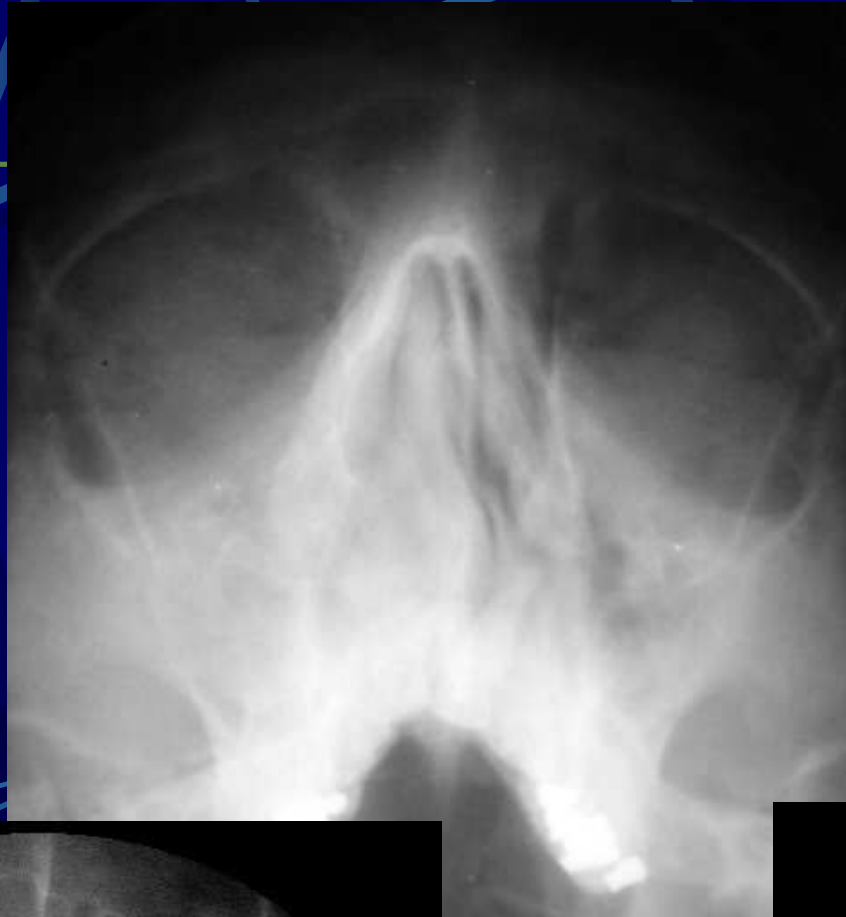



# Ca – odontogenní tumor



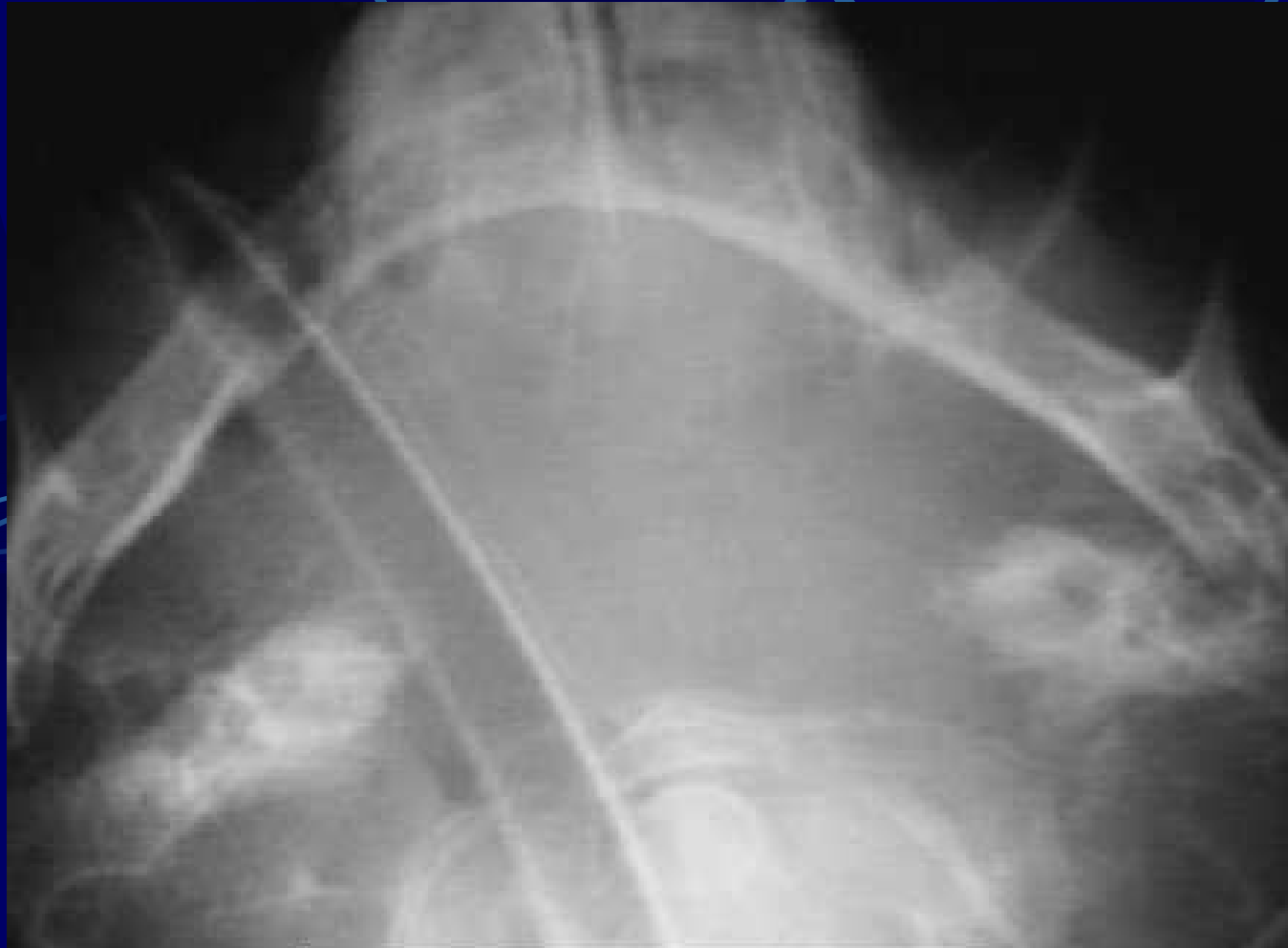

# Ca maxilly





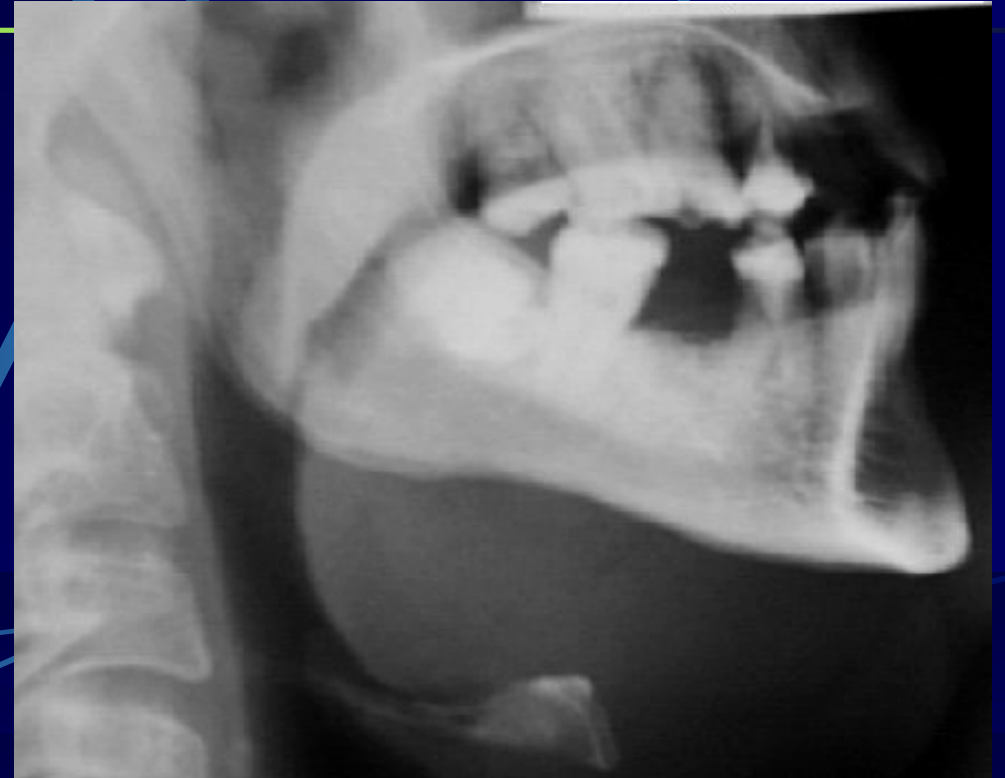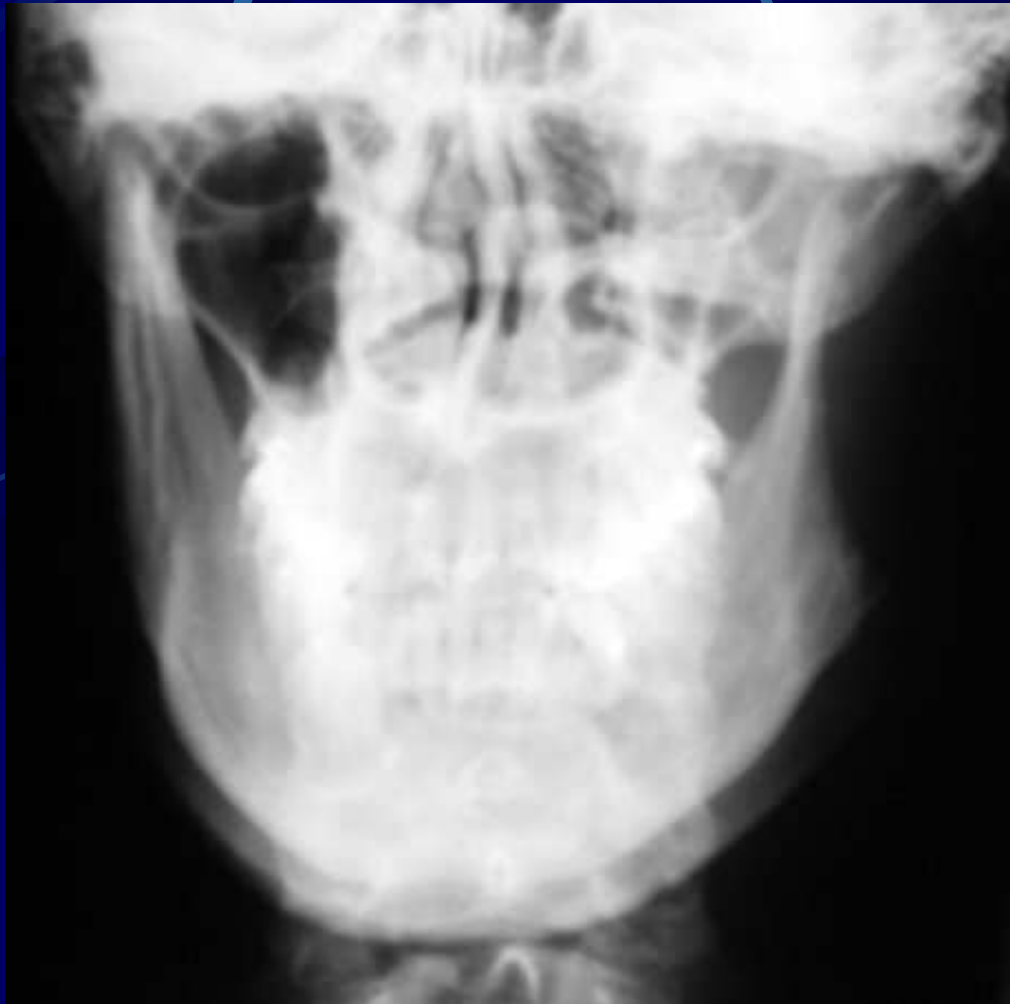
# Ca nasopharyngu





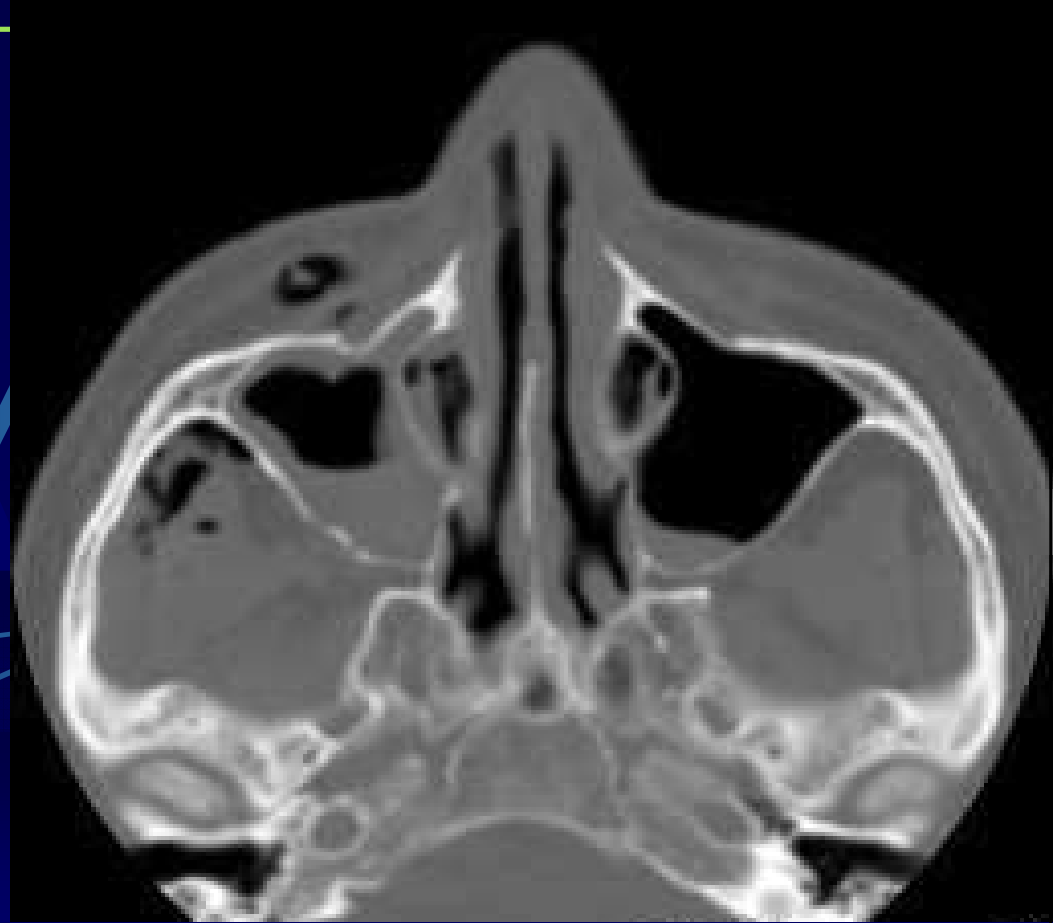
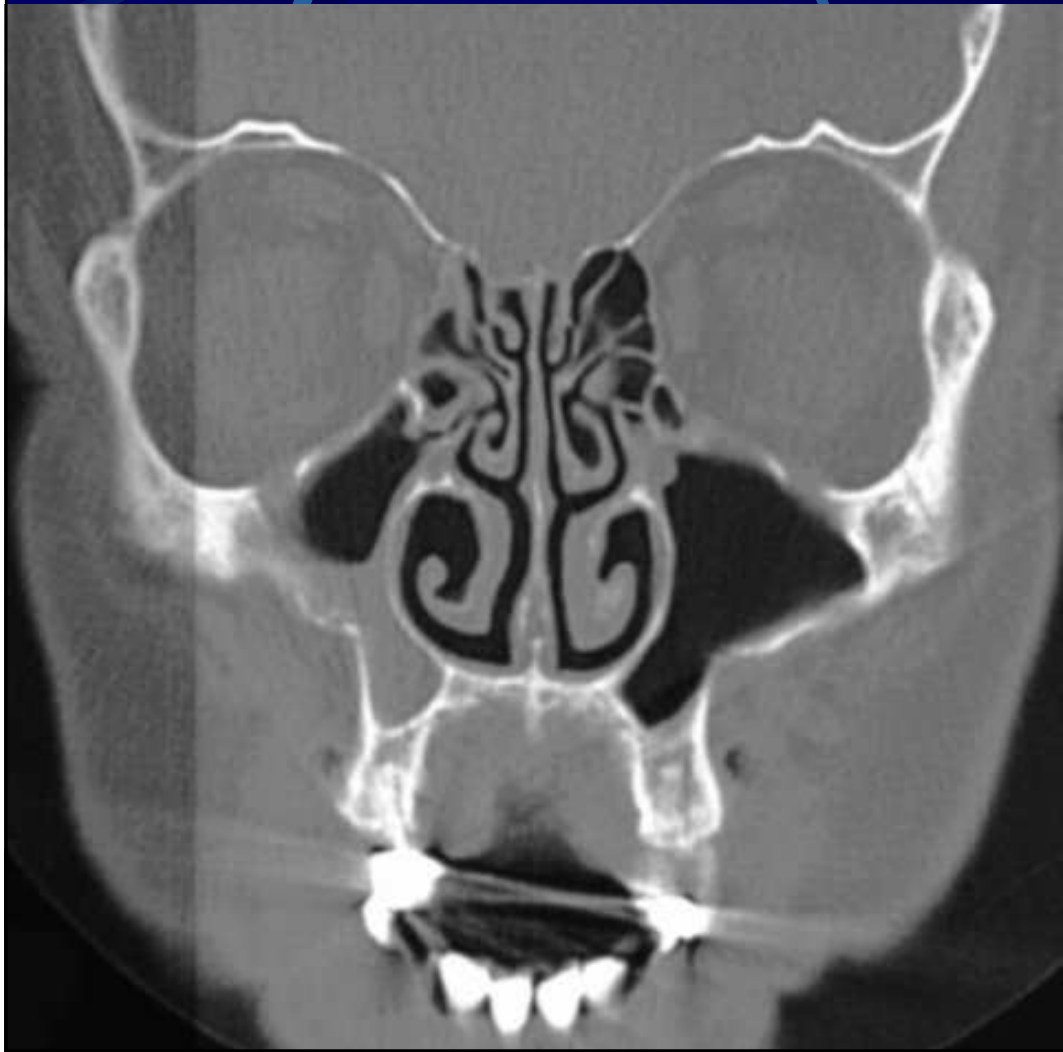

# Sarcom mandibuly



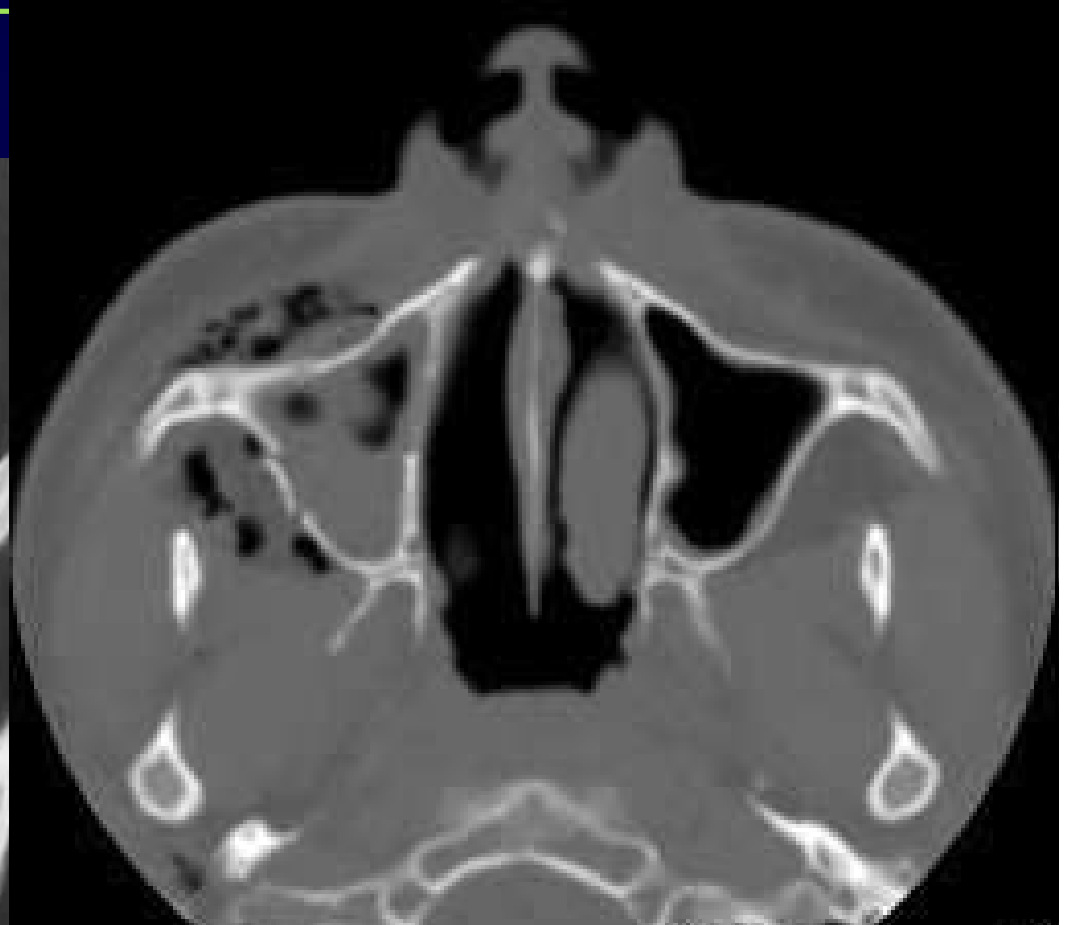
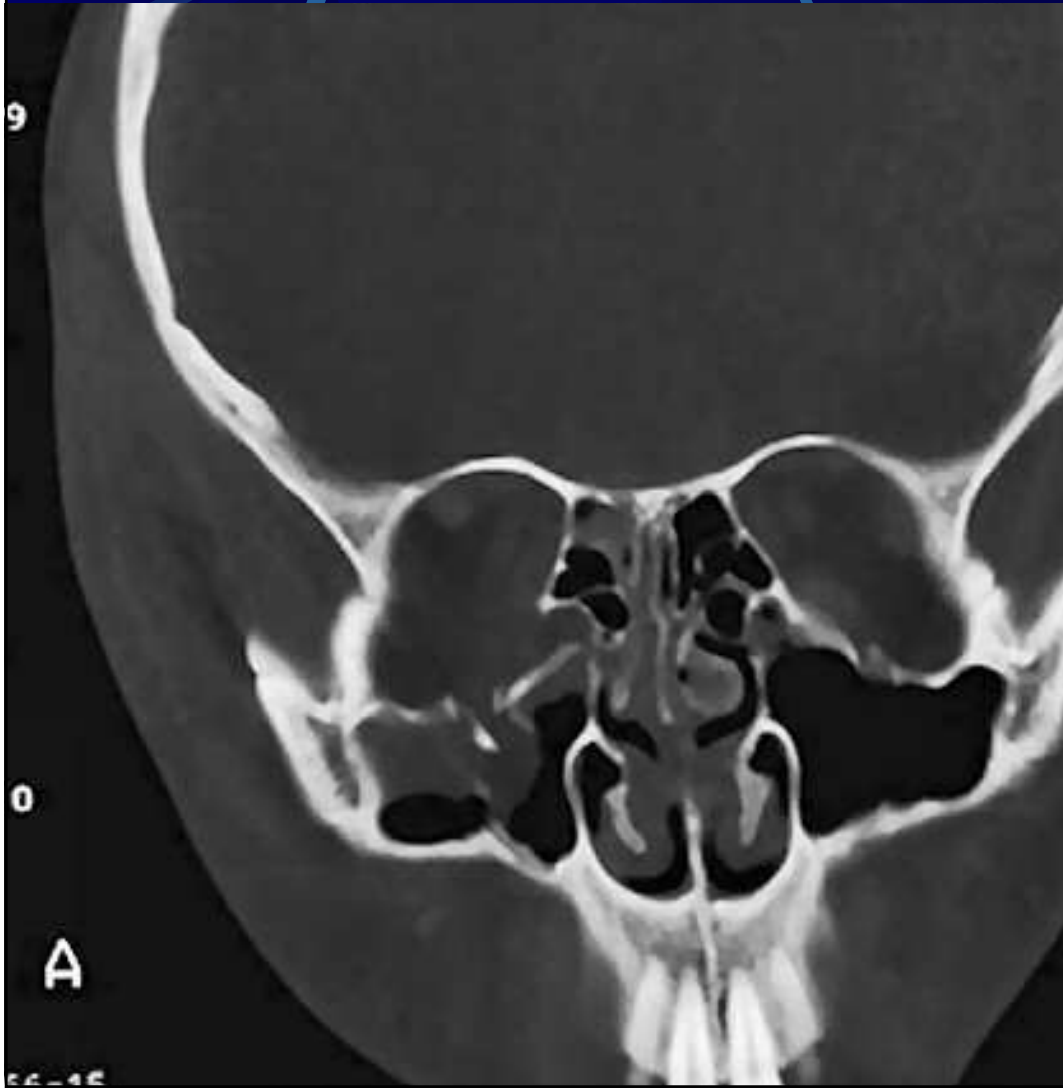
# Fraktura



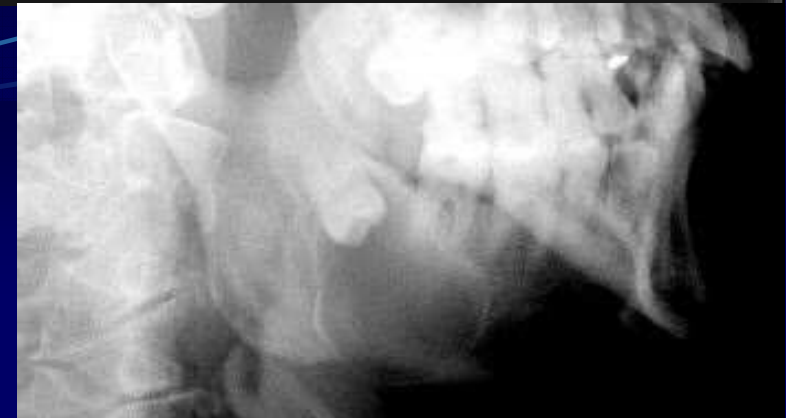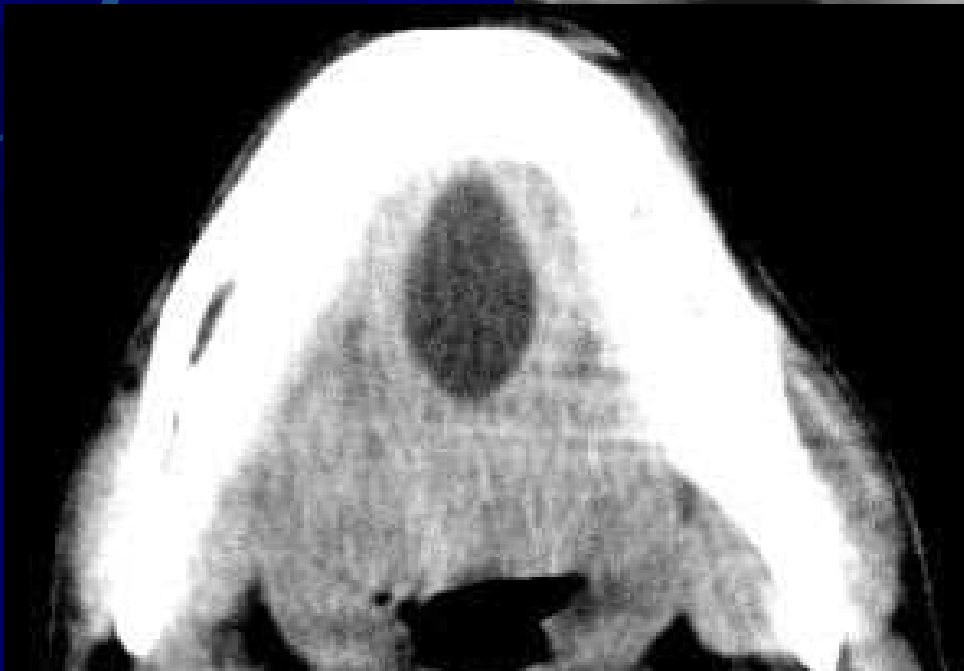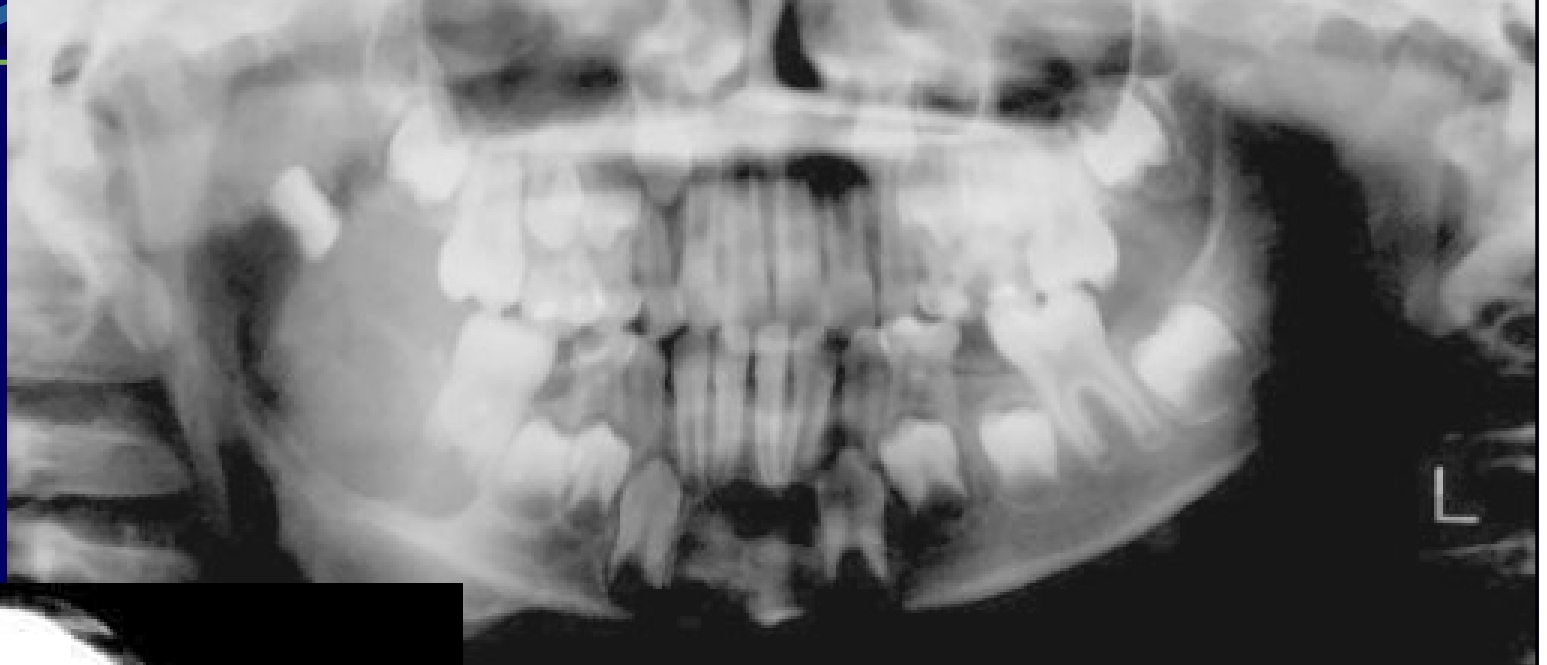



# Fraktura



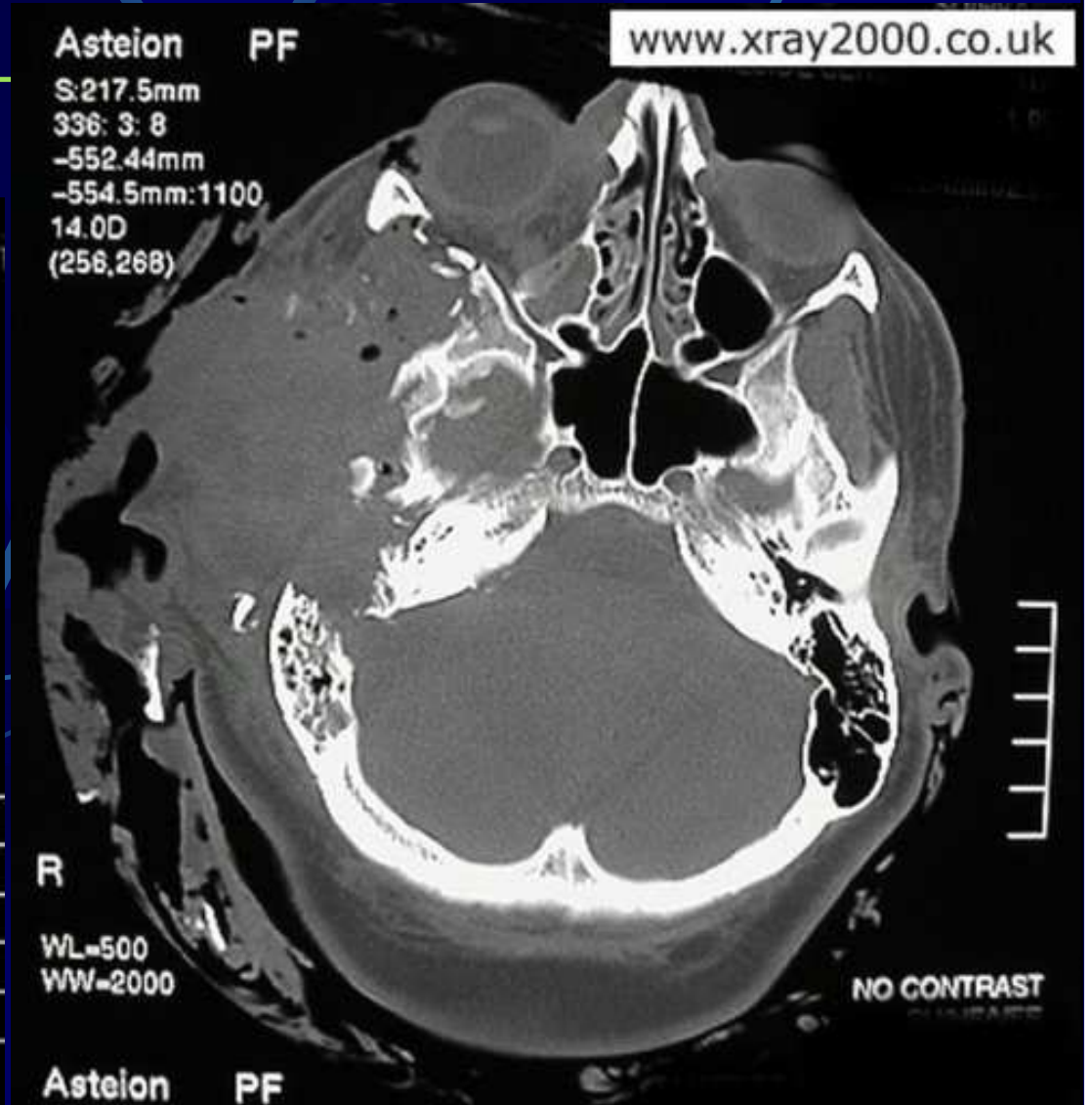
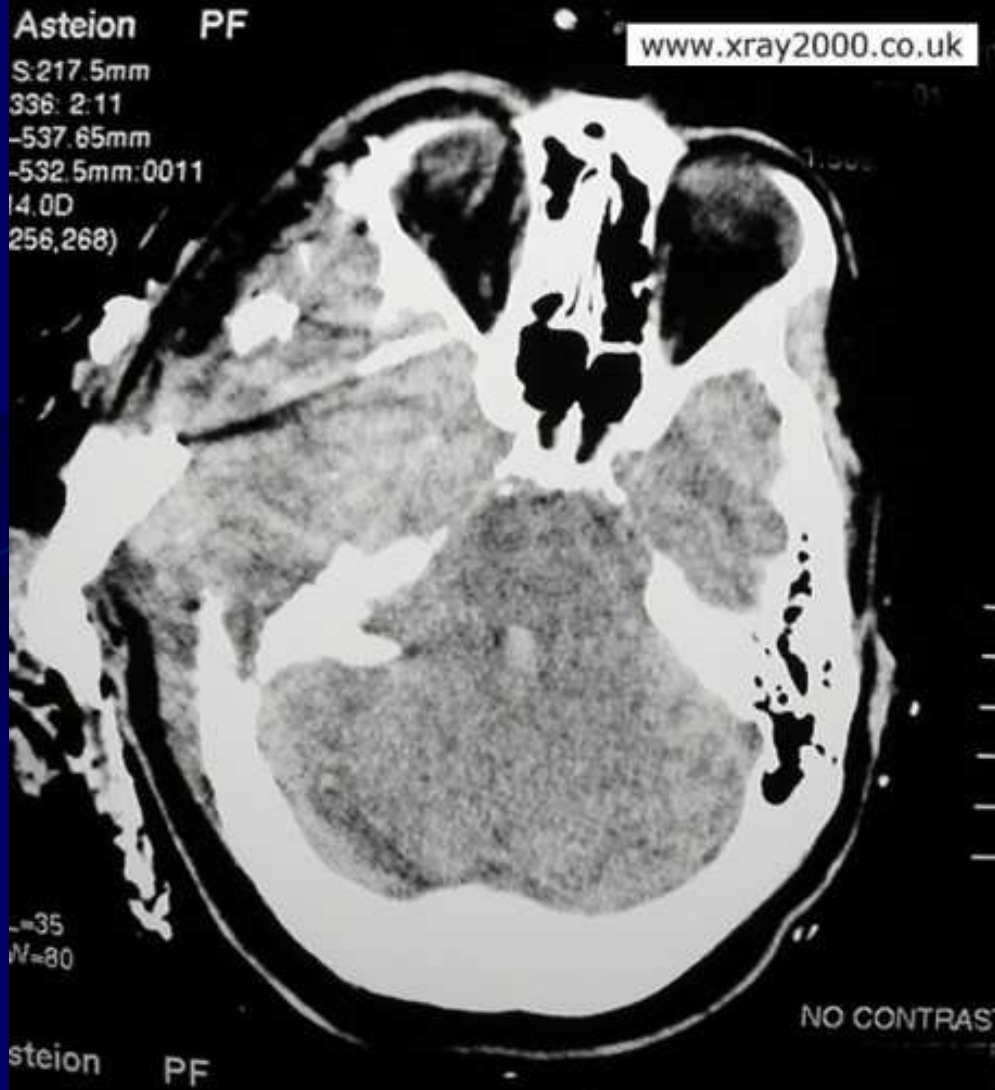


# Cysta





# Frantura



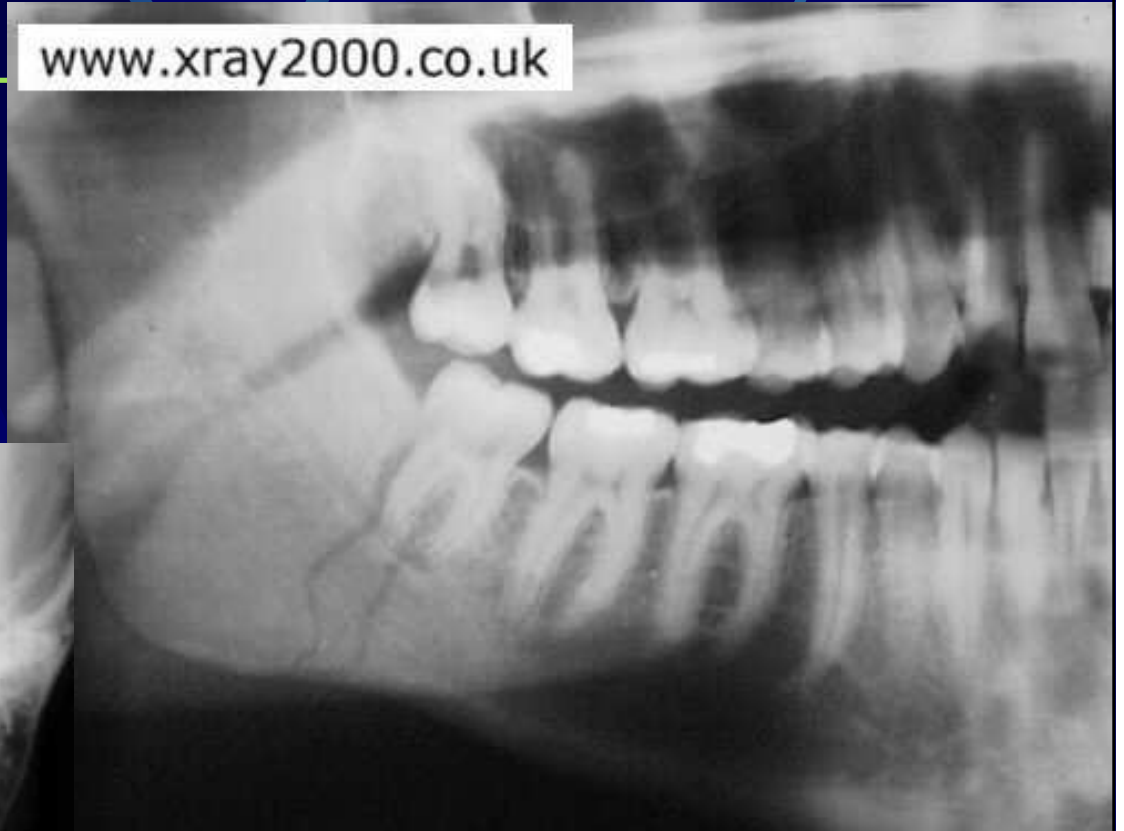



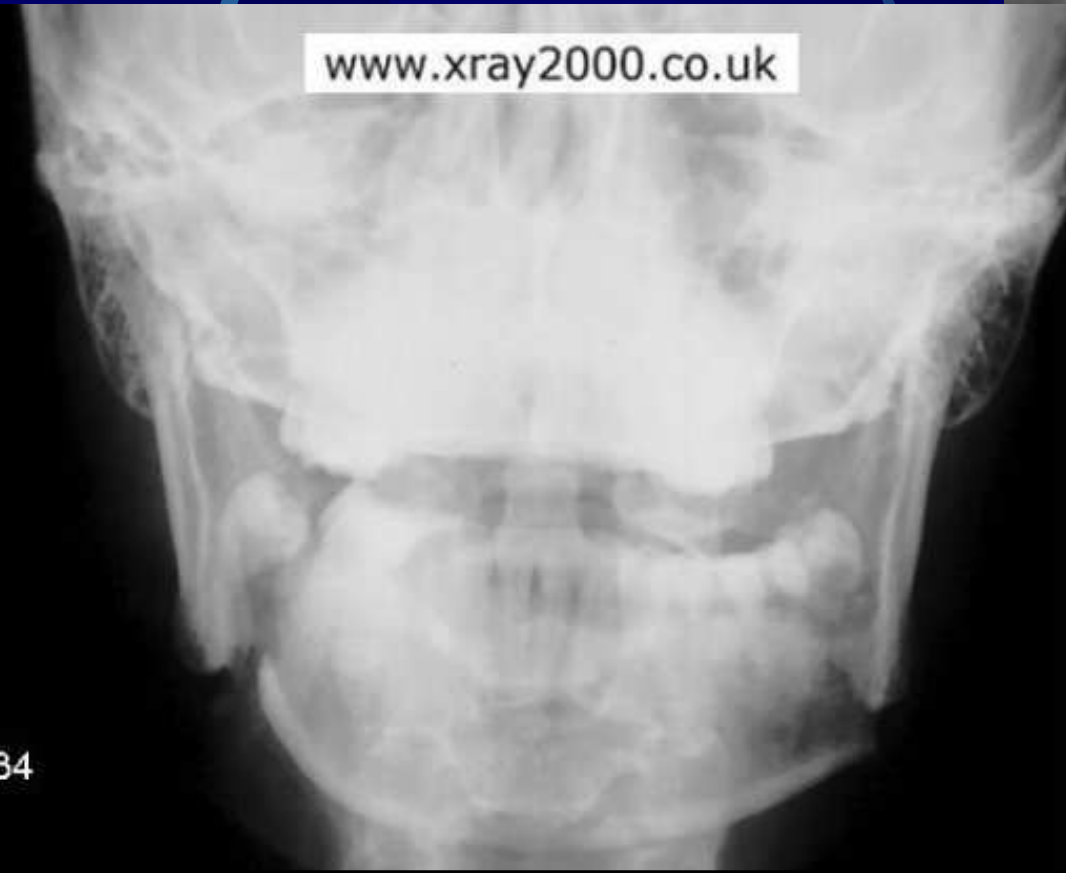# Frantura



[www.xray2000.co.uk](http://www.xray2000.co.uk)



[www.xray2000.co.uk](http://www.xray2000.co.uk)

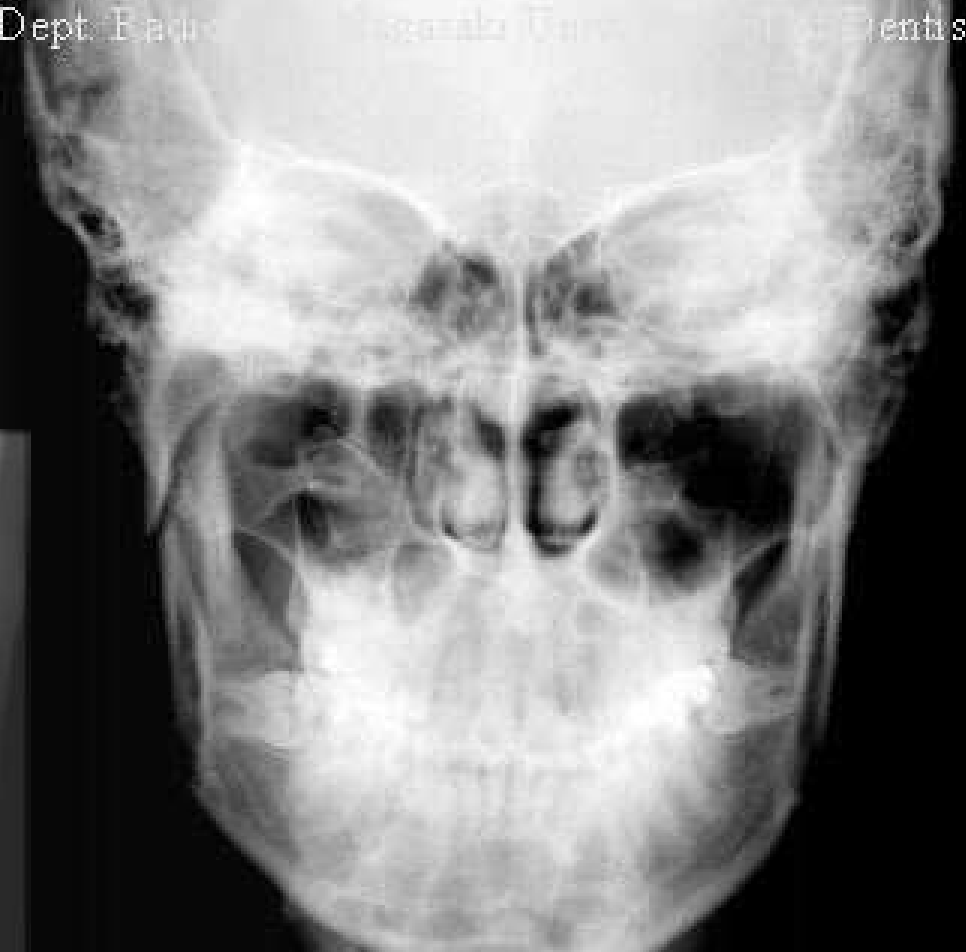



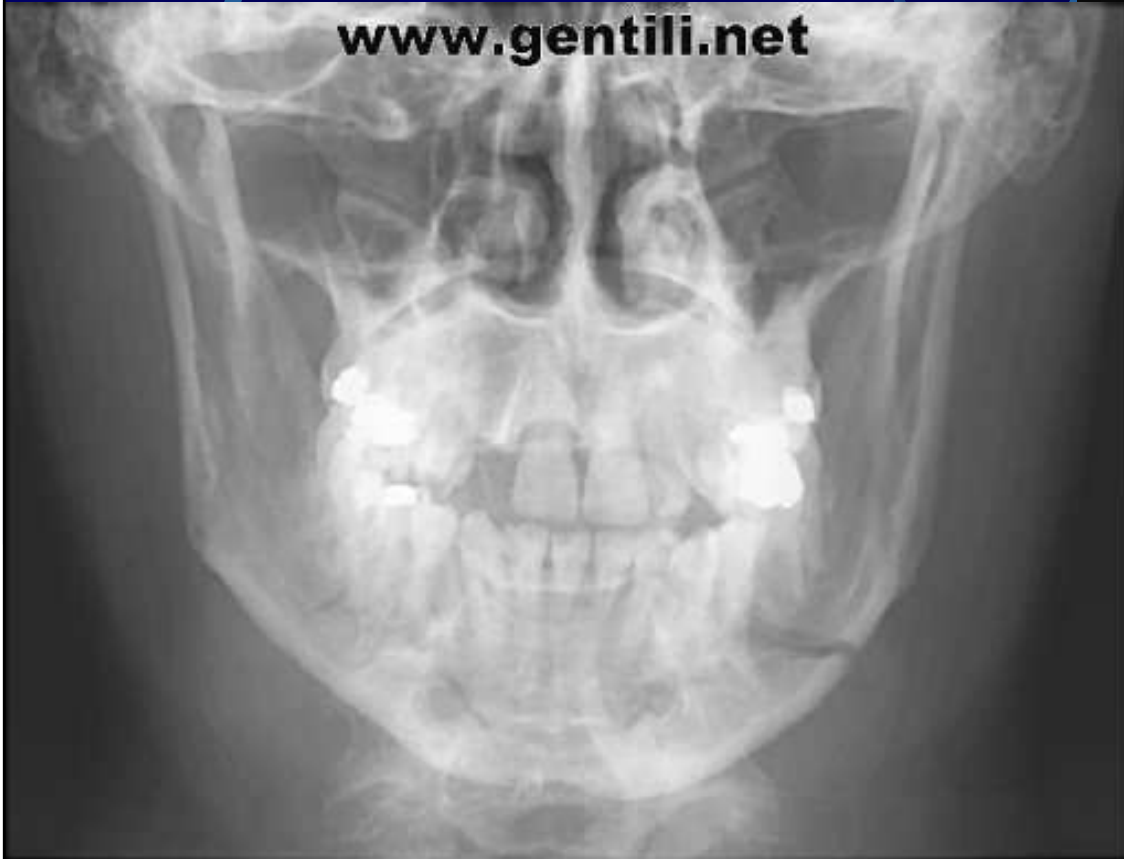# Frantura



Dept. Radiology, Masaryk University Brno, Faculty of Medicine, Brno, Czech Republic



[www.gentili.net](http://www.gentili.net)

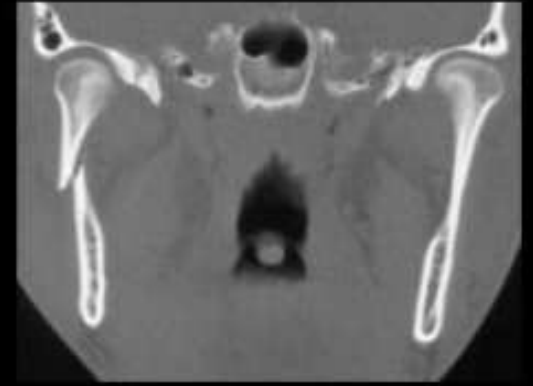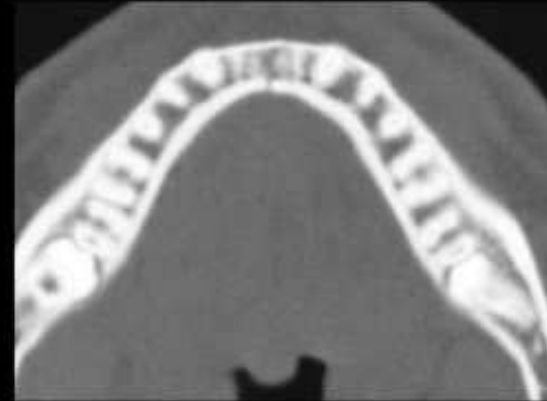

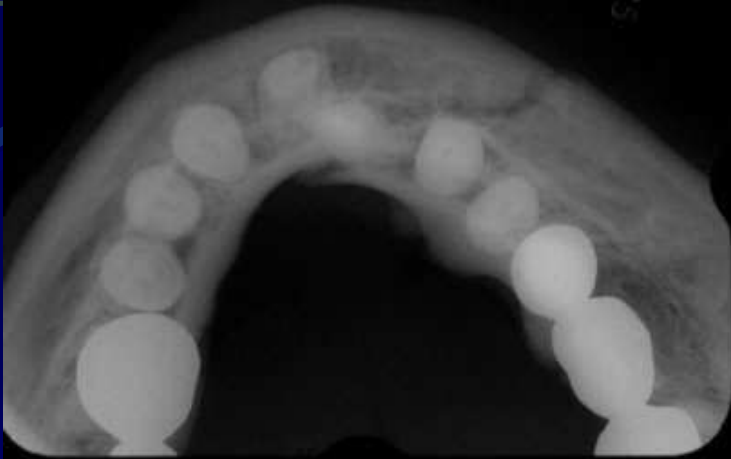


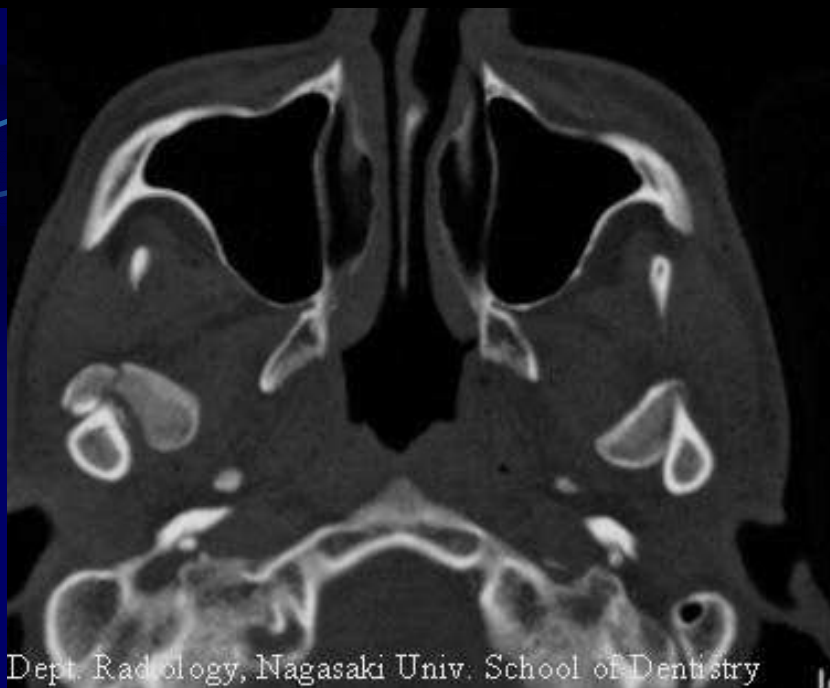
# Frantura



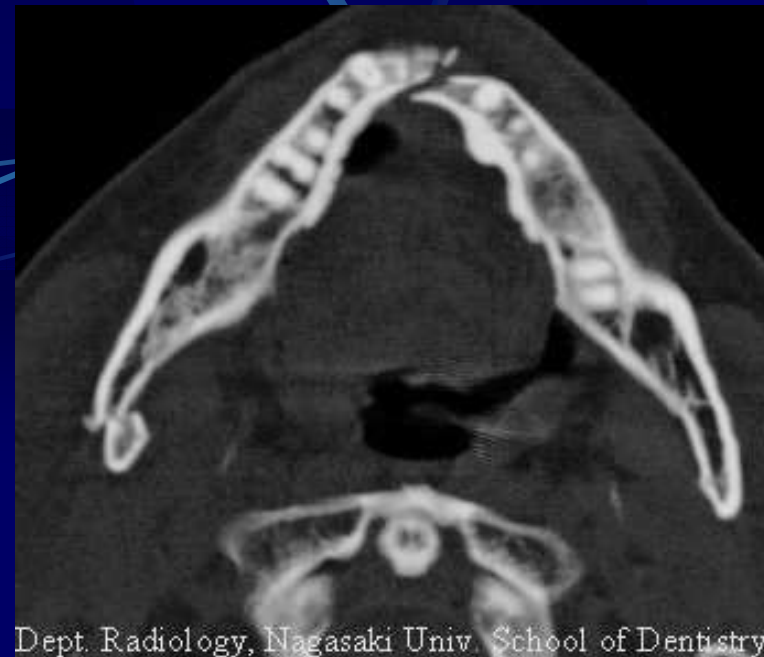Dept. Radiology, Nagasaki Univ. School of Dentistry




Dept. Radiology, Nagasaki Univ. School of Dentistry



Dept. Radiology, Nagasaki Univ. School of Dentistry

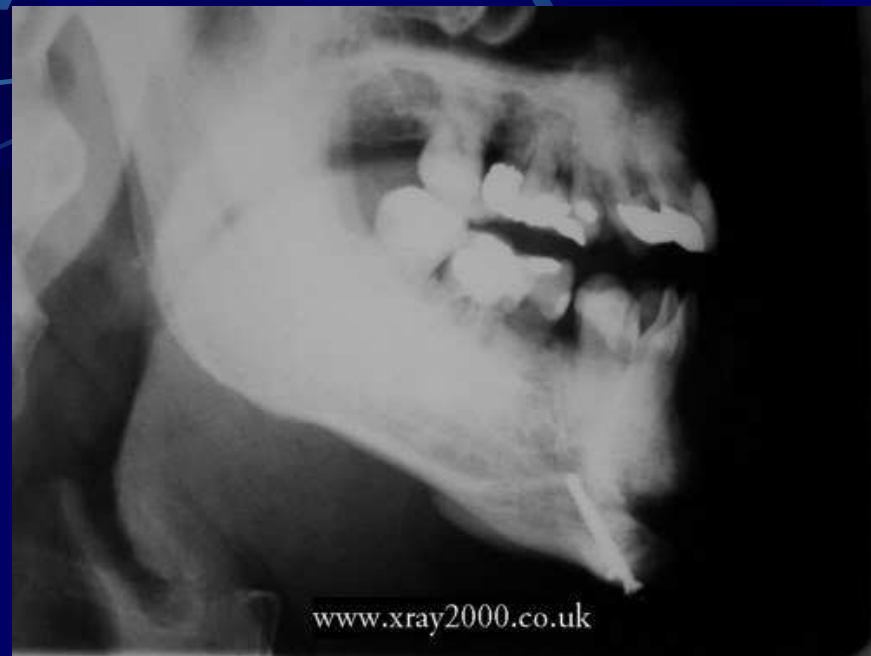
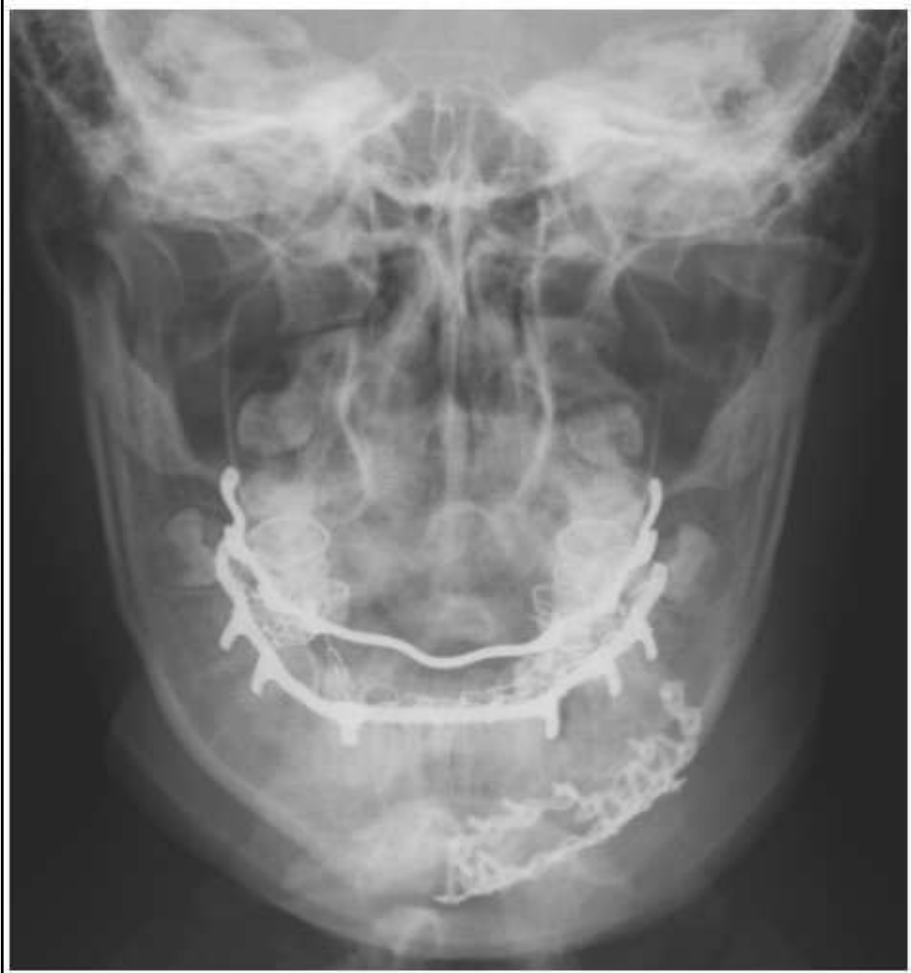
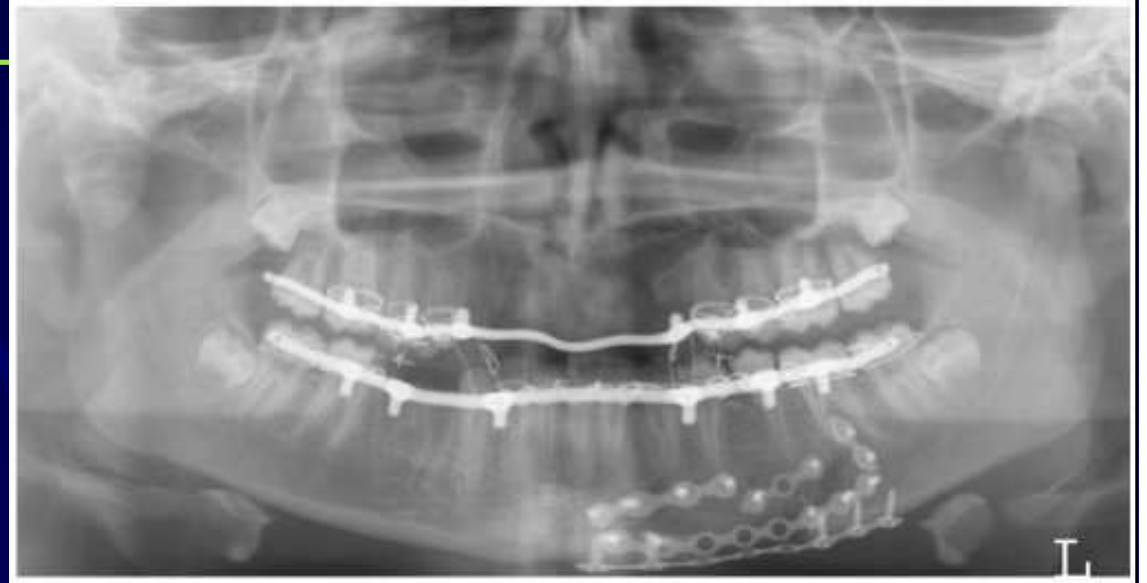Dept. Radiology, Nagasaki Univ. School of Dentistry





# Frantura



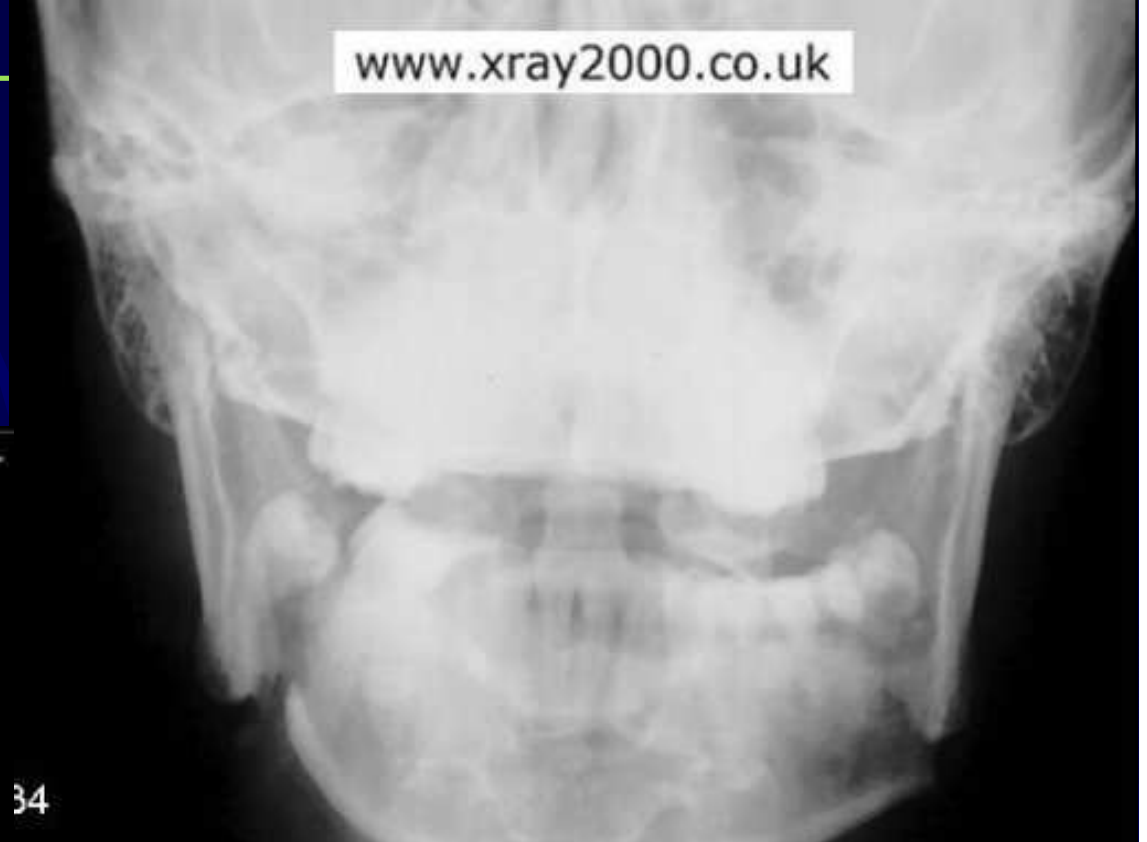



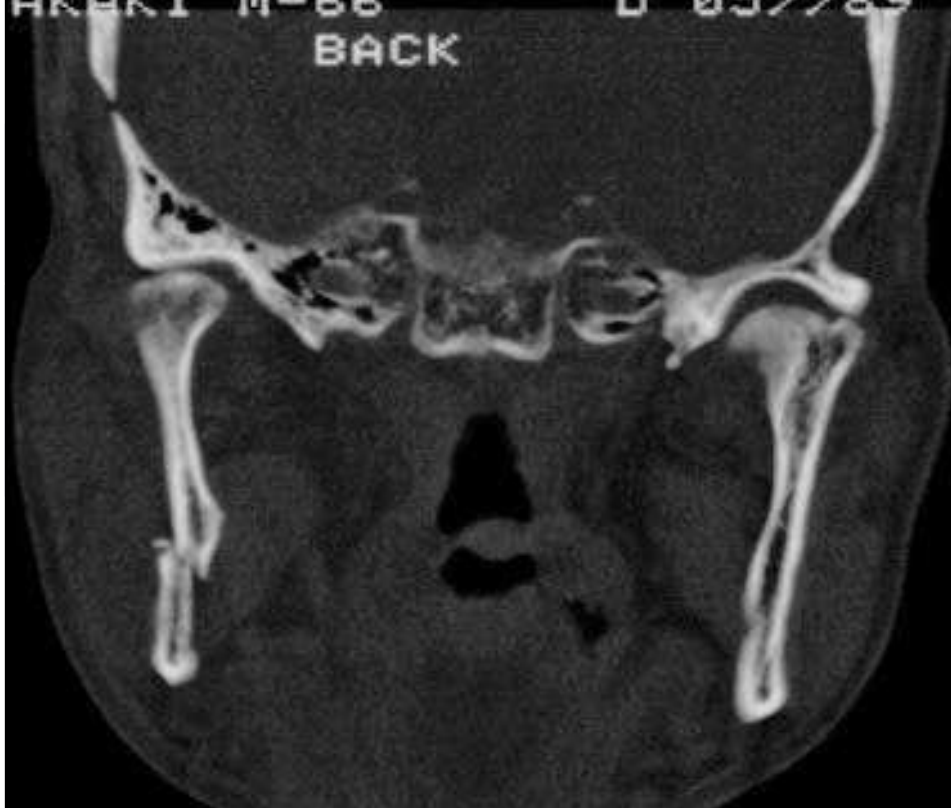# Frantura



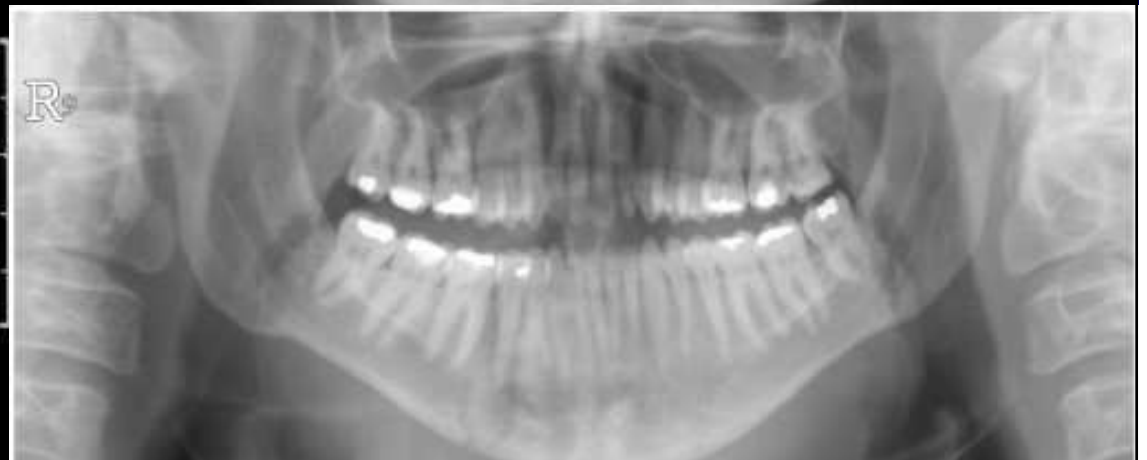[www.xray2000.co.uk](http://www.xray2000.co.uk)



R-H NAGASAKI UNIV. DENTAL  
AKAKI M-66 D 057789  
BACK



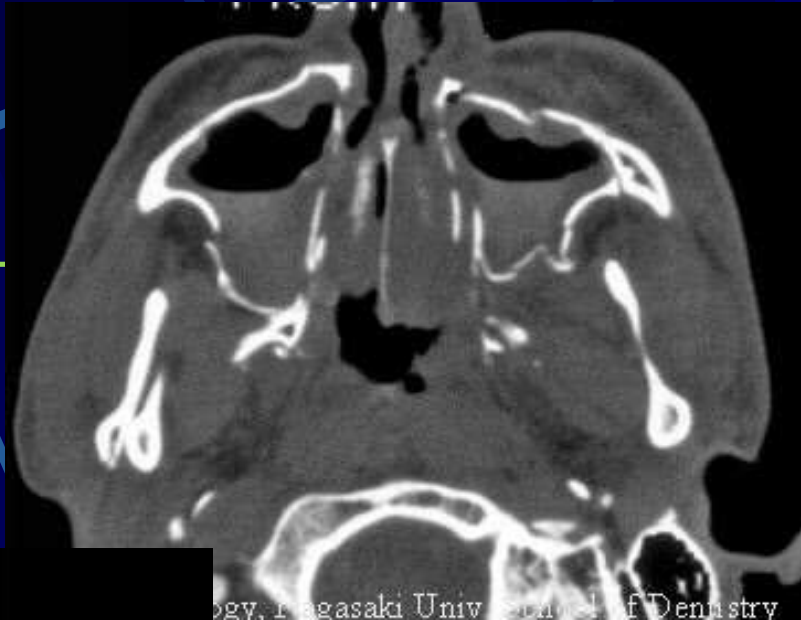
34



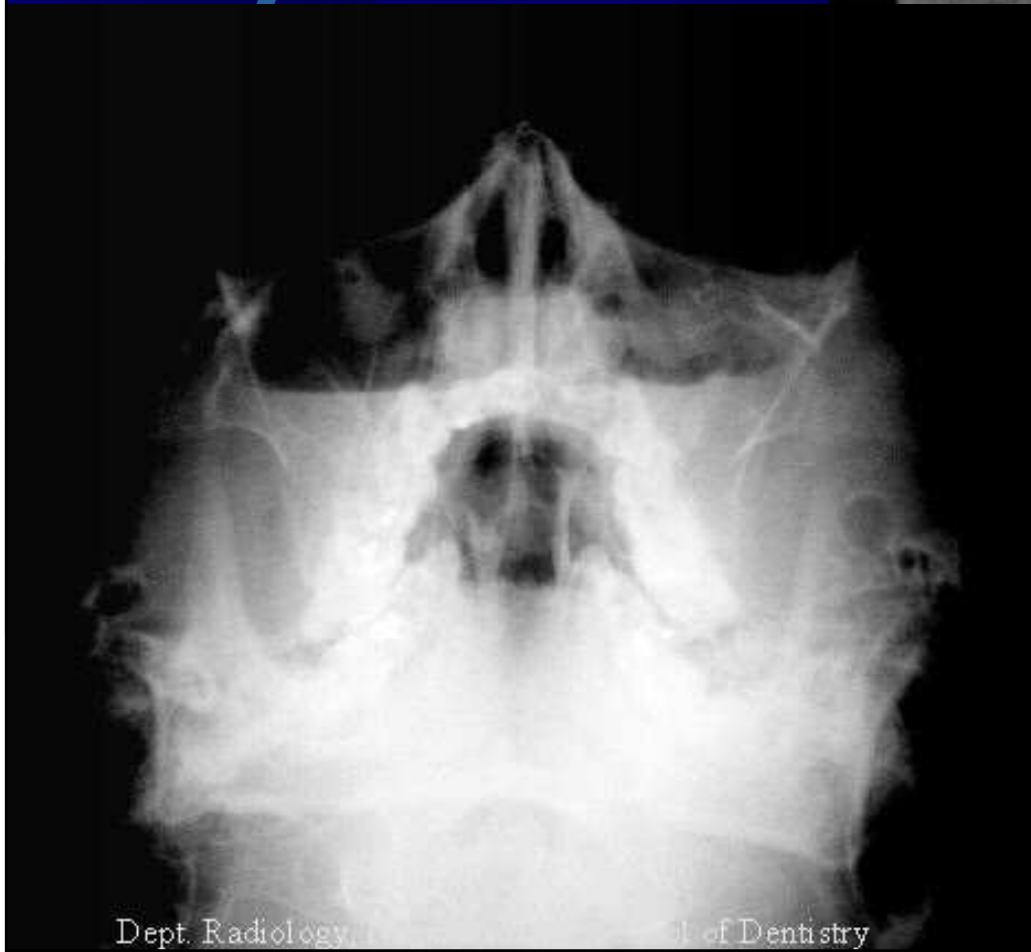



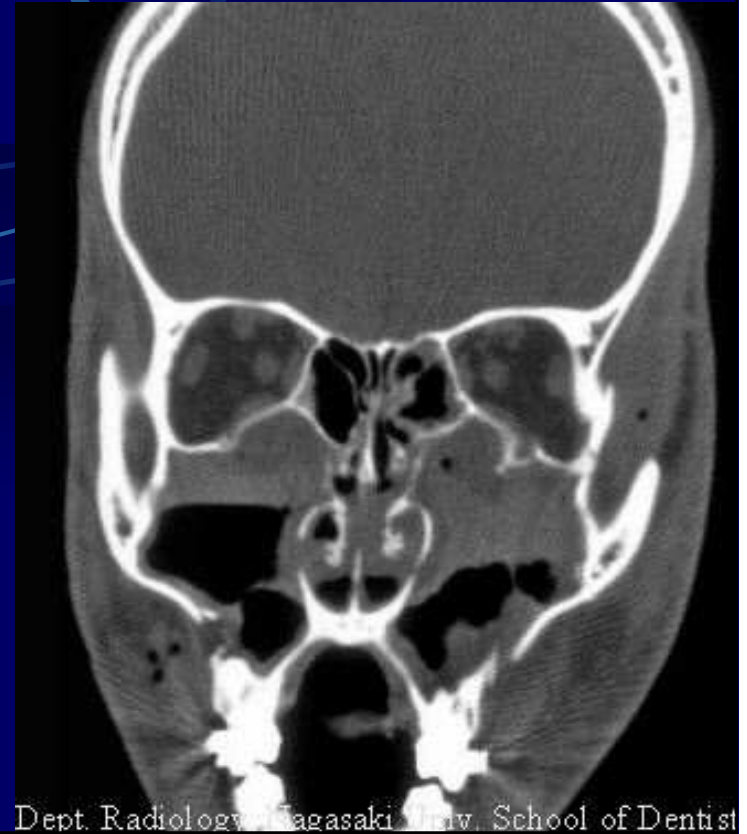# Frantura



Dept. Radiology, Nagasaki Univ. School of Dentistry



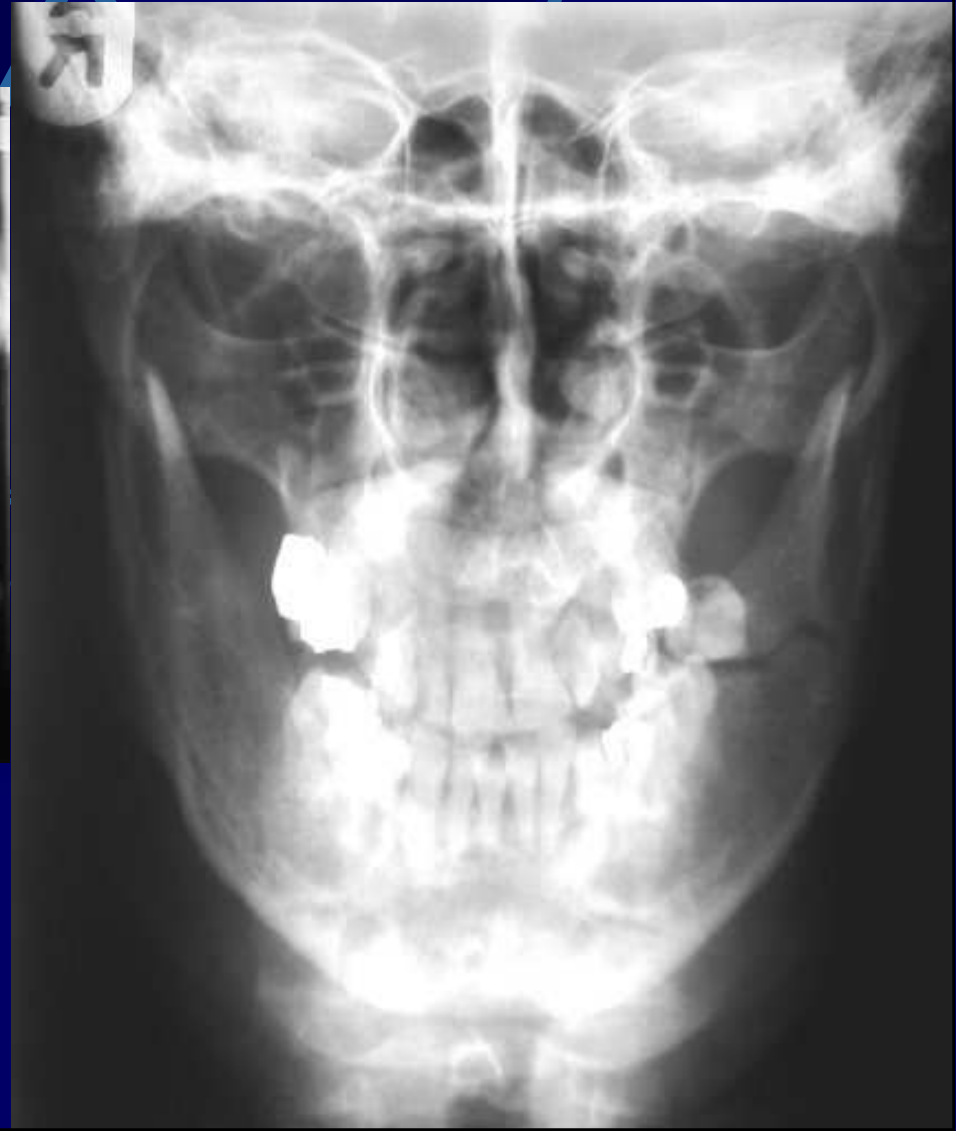
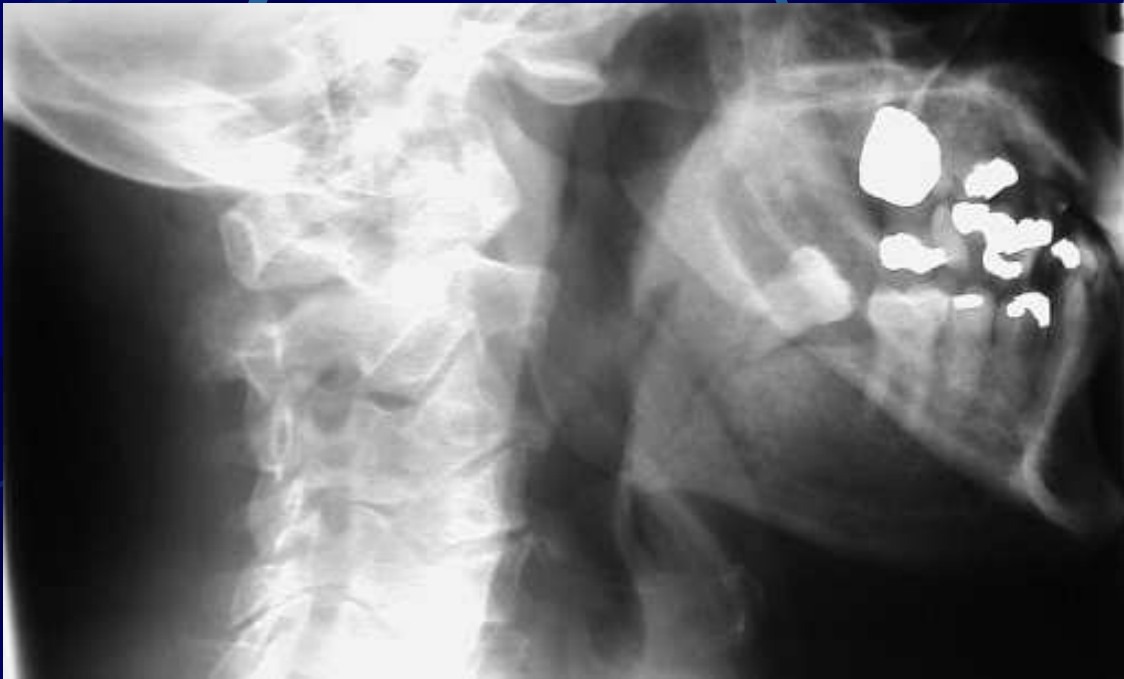Dept. Radiology, Nagasaki Univ. School of Dentistry



Dept. Radiology, Nagasaki Univ. School of Dentistry

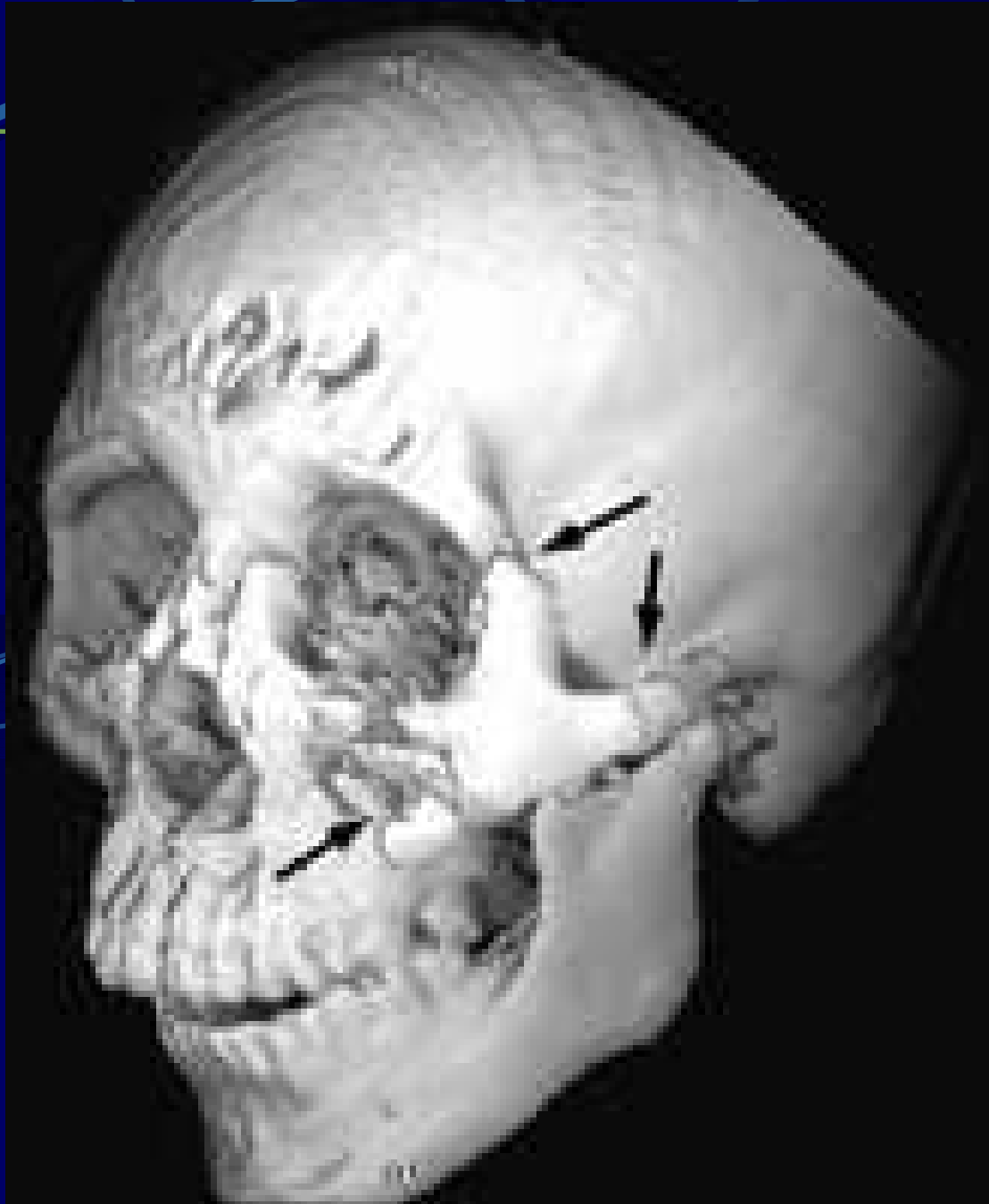

# Frantura





# Frantura





# Zuby – náhrada

