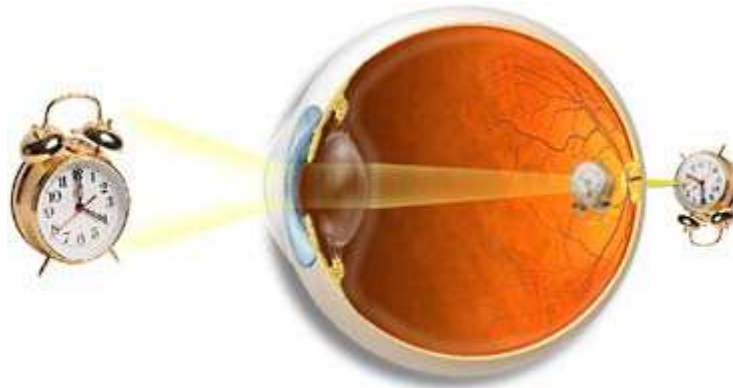


## Farsightedness (Hyperopia)

**Farsightedness** or **hyperopia**, occurs when light entering the eye focuses behind the **retina**, instead of directly on it. This is caused by a **cornea** that is flatter, or an eye that is shorter, than a normal eye. Farsighted people usually have trouble seeing up close, but may also have difficulty seeing far away as well.



Farsighted Eye

Young people with mild to moderate hyperopia are often able to see clearly because their natural **lens** can adjust, or **accommodate** to increase the eye's focusing ability. However, as the eye gradually loses the ability to accommodate (beginning at about 40 years of age), blurred vision from hyperopia often becomes more apparent.

### Signs and Symptoms

- Difficulty seeing up close
- Blurred distance vision (occurs with higher amounts of hyperopia)
- Eye fatigue when reading
- Eye strain (headaches, pulling sensation, burning)
- **Crossed eyes** in children

### Detection and Diagnosis

Hyperopia is detected with a vision test called a **refraction**. Young patients' eyes are **dilated** for this test so they are unable to mask their farsightedness with accommodation. This is called a wet refraction.

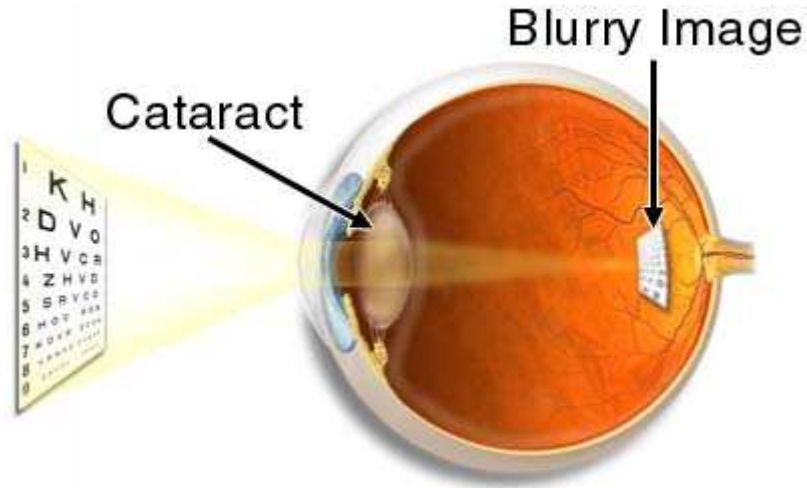
### Treatment

The treatment for hyperopia depends on several factors such as the patient's age, activities, and occupation. Young patients may or may not require glasses or contact lenses, depending on their ability to compensate for their farsightedness with accommodation. Glasses or contact lenses are required for older patients.

**Refractive surgery** is an option for adults who wish to see clearly without glasses. **LASIK, Clear Lens Extraction And Replacement, LTK** and **intraocular contact lenses** are all procedures that can be performed to correct hyperopia.

## Cataract

When cataracts are mentioned, people often think of a film that grows on their eyes causing them to see double or blurred images. However, a cataract does not form on the eye, but rather within the eye.



A cataract is a clouding of the natural lens, the part of the eye responsible for focusing light and producing clear, sharp images. The lens is contained in a sealed bag or capsule. As old cells die they become trapped within the capsule. Over time, the cells accumulate causing the lens to cloud, making images look blurred or fuzzy. For most people, cataracts are a natural result of aging.

In fact, they are the leading cause of visual loss among adults 55 and older. Eye injuries, certain medications, and diseases such as diabetes and alcoholism have also been known to cause cataracts.

## Color Blindness

Color blindness may be a hereditary condition or caused by disease of the **optic nerve** or **retina**. Acquired color vision problems only affect the eye with the disease and may become progressively worse over time. Patients with a color vision defect caused by disease usually have trouble discriminating blues and yellows.

Inherited color blindness is most common, affects both eyes, and does not worsen over time. This type is found in about 8% of males and 0.4% of females. These color problems are linked to the X chromosome and are almost always passed from a mother to her son.

Color blindness may be partial (affecting only some colors), or complete (affecting all colors). Complete color blindness is very rare. Those who are completely color blind often have other serious eye problems as well.

Photoreceptors called cones allow us to appreciate color. These are concentrated in the very center of the retina and contain three photosensitive pigments: red, green and blue. Those with defective color vision have a deficiency or absence in one or more of these pigments. Those with normal color vision are referred to as trichromats. People with a deficiency in one of the pigments are called anomalous trichromats (the most common type of color vision problem.) A dichromat has a complete absence in one cone pigment.

### Signs and Symptoms

The symptoms of color blindness are dependent on several factors, such as whether the problem is congenital, acquired, partial, or complete.

- Difficulty distinguishing reds and greens (most common)
- Difficulty distinguishing blues and greens (less common)

The symptoms of more serious inherited color vision problems and some types acquired problems may include:

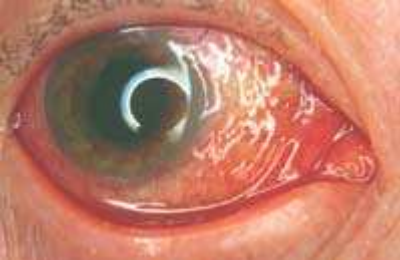- Objects appear as various shades of gray (this occurs with complete color blindness and is very rare)
- Reduced vision
- Nystagmus

### Detection and Diagnosis

Color vision deficiency is most commonly detected with special colored charts called the Ishihara Test Plates. On each plate is a number composed of colored dots. While holding the chart under good lighting, the patient is asked to identify the number. Once the color defect is identified, more detailed color vision tests may be performed.

### Treatment

There is no treatment or cure for color blindness. Those with mild color deficiencies learn to associate colors with certain objects and are usually able to identify color as everyone else. However, they are unable to appreciate color in the same way as those with normal color vision.



## Conjunctivitis (Pink Eye)

**Conjunctivitis**, commonly known as **pink eye**, is an infection of the **conjunctiva** (the outer-most layer of the eye that covers the **sclera**). The three most common types of conjunctivitis are: **viral**, **allergic**, and **bacterial**. Each requires different treatments. With the exception of the allergic type, conjunctivitis is typically contagious.

The viral type is often associated with an upper respiratory tract infection, cold, or sore throat. The allergic type occurs more frequently among those with allergic conditions. When related to allergies, the symptoms are often seasonal. Allergic conjunctivitis may also be caused by intolerance to substances such as cosmetics, perfume, or drugs. Bacterial conjunctivitis is often caused by bacteria such as staphylococcus and streptococcus. The severity of the infection depends on the type of bacteria involved.

### Signs and Symptoms

#### Viral conjunctivitis

- Watery discharge
- Irritation
- Red eye
- Infection usually begins with one eye, but may spread easily to the fellow eye

#### Allergic conjunctivitis

- Usually affects both eyes
- Itching
- Tearing
- Swollen **eyelids**

#### Bacterial conjunctivitis

- **Stringy discharge that may cause the lids to stick together, especially after sleeping**
- Swelling of the conjunctiva
- Redness
- Tearing
- Irritation and/or a gritty feeling
- Usually affects only one eye, but may spread easily to the fellow eye

### Diagnosis

Conjunctivitis is diagnosed during a routine eye exam using a **slit lamp microscope**. In some cases, cultures are taken to determine the type of bacteria causing the infection.

### Treatment

Conjunctivitis requires medical attention. The appropriate treatment depends on the cause of the problem.

For the **allergic type**, cool compresses and artificial tears sometimes relieve discomfort in mild cases. In more severe cases, non-steroidal anti-inflammatory medications and antihistamines may be prescribed. **Some patients with persistent allergic conjunctivitis may also require topical steroid drops.**

**Bacterial conjunctivitis** is usually treated with antibiotic eye drops or ointments that cover a broad range of bacteria.

Like the common cold, there is no cure for **viral conjunctivitis**; however, the symptoms can be relieved with cool compresses and artificial tears (found in most pharmacies). For the worst cases, topical steroid drops may be prescribed to reduce the discomfort from inflammation. Viral conjunctivitis usually resolves within 3 weeks.

To avoid spreading infection, take these simple steps:

- Disinfect surfaces such as doorknobs and counters with diluted bleach solution
- Don't swim (some bacteria can be spread in the water)
- Avoid touching the face
- Wash hands frequently
- Don't share towels or washcloths
- Do not reuse handkerchiefs (using a tissue is best)
- Avoid shaking hands

## Glaucoma

**Glaucoma** is a disease caused by increased **intraocular pressure** (IOP) resulting either from a malformation or malfunction of the **eye's drainage structures**. Left untreated, an elevated IOP causes irreversible damage to the **optic nerve** and retinal fibers resulting in a progressive, permanent loss of vision. However, early detection and treatment can slow, or even halt the progression of the disease.

### What causes glaucoma?

The eye constantly produces **aqueous**, the clear fluid that fills the anterior chamber (the space between the **cornea** and **iris**). The aqueous filters out of the anterior chamber through a complex drainage system. The delicate balance between the production and drainage of aqueous determines the eye's intraocular pressure (IOP). Most people's IOPs fall between 8 and 21. However, some eyes can tolerate higher pressures than others. That's why it may be normal for one person to have a higher pressure than another.

### Signs and Symptoms

**Glaucoma is an insidious disease because it rarely causes symptoms.** Detection and prevention are only possible with routine eye examinations. However, certain types, such as angle closure and congenital, do cause symptoms.

#### Angle Closure (emergency)

- Sudden decrease of vision
- Extreme eye pain
- Headache
- Nausea and vomiting
- Glare and light sensitivity

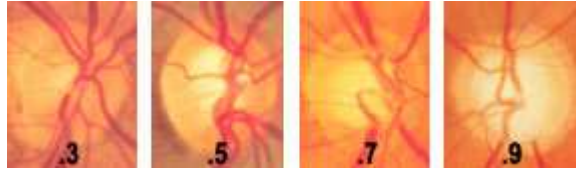
#### Congenital

- Tearing
- Light sensitivity
- Enlargement of the cornea

### Detection and Diagnosis

Because glaucoma does not cause symptoms in most cases, those who are 40 or older should have an annual examination including a measurement of the intraocular pressure. Those who are glaucoma suspects may need additional testing.

The glaucoma evaluation has several components. In addition to measuring the intraocular pressure, the doctor will also evaluate the health of the optic nerve (**ophthalmoscopy**), test the peripheral vision (**visual field test**), and examine the structures in the front of the eye with a special lens (**gonioscopy**) before making a diagnosis.



The above photos show progressive optic nerve damage (indicated by the cup to disc ratio) caused by glaucoma. Notice the pale appearance of the nerve with the 0.9 cup as compared to the nerve with the 0.3 cup.

The doctor evaluates the optic nerve and grades its health by noting the cup to disc ratio. This is simply a comparison of the cup (the depressed area in the center of the nerve) to the entire diameter of the optic nerve. As glaucoma progresses, the area of cupping, or depression, increases. Therefore, a patient with a higher ratio has more damage.

The progression of glaucoma is monitored with a visual field test. This test maps the peripheral vision, allowing the doctor to determine the extent of vision loss from glaucoma and a measure of the effectiveness of the treatment. The visual field test is periodically repeated to verify that the intraocular pressure is being adequately controlled.

The structures in the front of the eye are normally difficult to see without the help of a special gonioscopy lens. This special mirrored contact lens allows the doctor to examine the anterior chamber and the eye's drainage system.

At St. Luke's, another test called the **Arden Screening Test** is used to confirm the diagnosis of glaucoma. This color test may show vision changes that occur before problems appear on the visual field test.

## **Treatment**

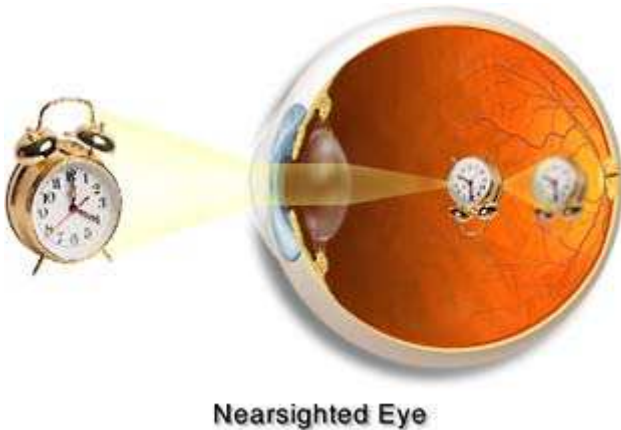
Most patients with glaucoma require only medication to control the eye pressure. Sometimes, several medications that complement each other are necessary to reduce the pressure adequately.

Surgery is indicated when medical treatment fails to lower the pressure satisfactorily. There are several types of procedures, some involve laser and can be done in the office, others must be performed in the operating room. The objective of any glaucoma operation is to allow fluid to drain from the eye more efficiently.

## Nearsightedness (Myopia)

Nearsightedness or myopia, occurs when light entering the eye focuses in front of the **retina** instead of directly on it. This is caused by a **cornea** that is steeper, or an eye that is longer, than a normal eye. Nearsighted people typically see well up close, but have difficulty seeing far away.

This problem is often discovered in school-age children who report having trouble seeing the chalkboard. Near-sightedness usually becomes progressively worse through adolescence and stabilizes in early adulthood. It is an inherited problem.



### Signs and Symptoms

- Blurry distance vision
- Vision seems clearer when squinting

### Detection and Diagnosis

Nearsightedness is detected with a **vision test** and **refraction**.

### Treatment

The treatment for nearsightedness depends on several factors such as the patient's age, activities, and occupation. Vision can be corrected with glasses, contacts, or surgery. **Refractive procedures** such as **LASIK** can be considered for adults when the prescription has remained stable for at least one year.



## Presbyopia

Presbyopia, also known as the “short arm syndrome,” is a term used to describe an eye in which the natural lens can no longer accommodate. **Accommodation** is the eye’s way of changing its focusing distance: the **lens** thickens, increasing its ability to focus close-up. At about the age of 40, the lens becomes less flexible and accommodation is gradually lost. It’s a normal process that everyone eventually experiences.

Most people first notice difficulty reading very fine print such as the phone book, a medicine bottle, or the stock market page. Print seems to have less contrast and the eyes become easily fatigued when reading a book or computer screen. Early on, holding reading material further away helps for many patients. But eventually, reading correction in the form of reading glasses, bifocals, or contact lenses is needed for close work. However, **nearsighted** people can simply take their glasses off because they see best close-up.

### Signs and Symptoms

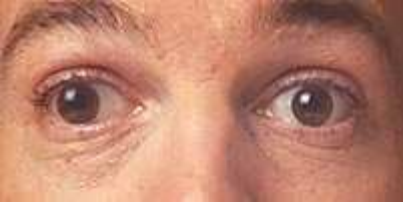- Difficulty seeing clearly for close work
- Print seems to have less contrast
- Brighter, more direct light required for reading
- Reading material must be held further away to see (for some)
- Fatigue and eyestrain when reading

### Detection and Diagnosis

Presbyopia is detected with vision testing and a refraction.

### Treatment

The treatment for presbyopia is very simple, but is entirely dependent on the individual’s age, lifestyle, occupation, and hobbies. If the patient has good distance vision and only has difficulty seeing up close, reading glasses are usually the easiest solution. For others, bifocals (glasses with reading and distance correction) or separate pairs of reading and distance glasses are necessary. Another option is monovision: adjusting one eye for distance vision, and the fellow eye for reading vision. This can be done with contact lenses or permanently with refractive surgery.



## Strabismus (Crossed or turned eye)

Strabismus is a problem caused by one or more improperly functioning **eye muscles**, resulting in a misalignment of the eyes. Normally, each eye focuses on the same spot but sends a slightly different message to the brain. The brain superimposes the two images, giving vision depth and dimension. Here's an easy way to see how the eyes work together: hold your finger at arm's length. While looking at your finger, close one eye, then the other. Notice how your finger changes position. Even though the images are slightly different, the brain interprets them as one.

Each eye has six muscles that work in unison to control movements. The brain controls the eye muscles, which keep the eyes properly aligned. It is critical that the muscles function together for the brain to interpret the image from each eye as a single one.

Strabismus must be detected early in children because they are so adaptable. If a child sees double, his or her brain quickly learns to suppress or block out one of the images to maintain single vision. In a very short time, the brain permanently suppresses vision from the turned eye, causing a weak or **amblyopic** eye. Children may also develop a head tilt or turn to compensate for the problem and eliminate the double image. Unlike children, adults with a newly acquired strabismus problem typically see double.

There are many causes of strabismus. It can be inherited, or it may be caused by trauma, certain diseases, and sometimes eye surgery.

### Signs and Symptoms

Adults are much more likely to be bothered by symptoms from strabismus than young children. It is unusual for a child to complain of double vision. Children should undergo vision screening exams to detect problems early. The younger the child is when strabismus is detected and treated, the better the chance of normal vision. The following are common signs and symptoms:

- Turned or crossed eye
- Head tilt or turn
- Squinting
- Double vision (in some cases)

### Detection and Diagnosis

Strabismus is detected with a comprehensive eye exam and special tests used to evaluate the alignment of the eyes such as: the Krimsky test and **prism testing**.

### Treatment

The appropriate treatment for strabismus is dependent on several factors including the patient's age, the cause of the problem, and the type and degree of the eye turn. Treatment may include patching, corrective glasses, prisms, or surgery.

With patching, the better eye is covered, forcing the child to use the weaker eye. Over time, the brain adjusts to using the weaker eye and vision gradually improves. For this treatment to be effective, it must be done at a young age before the child can develop amblyopia.

Surgery is sometimes performed for both adults and children to straighten a crossed eye. The procedure may be done with local or general anesthesia. There are several different surgical techniques used to correct strabismus. The appropriate one is dependent on the muscle involved and the degree of the eye turn.



## Retinal Tear and Detachment

### Retinal Tear

Retinal tears commonly occur when there is traction on the **retina** by the **vitreous gel** inside the eye. In a child's eye, the vitreous has an egg-white consistency and is firmly attached to certain areas of the retina. Over time, the vitreous gradually becomes thinner, more liquid and separates from the retina. This is known as a **posterior vitreous detachment** (PVD).

PVDs are typically harmless and cause floaters in the eye; but in some cases, the traction on the retina may create a tear. Retinal tears frequently lead to detachments as fluids seep underneath the retina, causing it to separate and detach.

### Retinal Detachment

A retinal detachment occurs when the retina's sensory and pigment layers separate. Because it can cause devastating damage to the vision if left untreated, retinal detachment is considered an ocular emergency that requires immediate medical attention and surgery. It is a problem that occurs most frequently in the middle-aged and elderly.

There are three types of retinal detachments. The most common type occurs when there is a break in the sensory layer of the retina, and fluid seeps underneath, causing the layers of the retina to separate. Those who are very **nearsighted**, have undergone eye surgery, or have experienced a serious eye injury are at greater risk for this type of detachment. Nearsighted people are more susceptible because their eyes are longer than average from front to back, causing the retina to be thinner and more fragile.

The second most common type occurs when strands of vitreous or scar tissue create traction on the retina, pulling it loose. Patients with diabetes are more likely to experience this type.

The third type happens when fluid collects underneath the layers of the retina, causing it to separate from the back wall of the eye. This type usually occurs in conjunction with another disease affecting the eye that causes swelling or bleeding.

### Signs and Symptoms

- Light flashes
- "Wavy," or "watery" vision
- Veil or curtain obstructing vision
- Shower of floaters that resemble spots, bugs, or spider webs
- Sudden decrease of vision

### Detection and Diagnosis

Retinal detachments are usually found because the patient calls the doctor's office with a symptom listed above. It is critical that these problems are reported early, because early treatment can greatly improve the chance of restoring vision.

The doctor makes the diagnosis of a retinal detachment after thoroughly examining the retina with **ophthalmoscopy**. The retinal surgeon's first concern is to determine

whether the **macula** (the center of the retina) is attached. This is critical because the macula is responsible for the central vision. Whether or not the macula is attached determines the type of corrective surgery required and the patient's chances of having functional vision after the operation.

Ultrasound imaging of the eye is also very useful for the doctor to see additional detail of the condition of the retina from several angles.

## **Treatment**

There are a number of ways to treat retinal detachment. The appropriate treatment depends on the type, severity and location of the detachment.

Pneumatic retinopexy is one type of procedure to reattach the retina. After numbing the eye with a local anesthesia, the surgeon injects a small gas bubble into the vitreous cavity. The bubble presses against the retina, flattening it against the back wall of the eye. Since the gas rises, this treatment is most effective for detachments located in the upper portion of the eye. In order to manipulate the bubble into the ideal location, the surgeon may ask the patient to keep his or her head in a specific position.

The gas bubble slowly absorbs over the next 1-2 weeks. At that time, an additional procedure is usually performed to "tack down" the retina. This can be done either with cryotherapy, a procedure that uses nitrous oxide to freeze the retina, sealing it in place, or with laser. Local anesthesia is used for both procedures.

Some types of retinal detachments, because of their location or size, are best treated with a procedure called a scleral buckle. With this technique, a tiny sponge or band made of silicone is attached to the outside of the eye, pressing inward and holding the retina in position. After removing the vitreous gel from the eye with a procedure called a **vitrectomy**, the surgeon usually seals a few areas of the retina into position with laser or cryotherapy. The scleral buckle is not visible and remains permanently attached to the eye. This technique of reattaching the retina may elongate the eye, causing nearsightedness.

In rare cases where other types of retinal detachment surgeries are either inappropriate or unsuccessful, silicone oil may be used to reattach the retina. The vitreous gel is removed and replaced with silicone oil, which presses the retina into place. While the oil is inside the eye, the vision is extremely poor. After the retina has resealed itself against the back of the eye, a second procedure may be performed to remove the oil.

## **What you can do...**

Early detection is key in successfully treating retinal detachments and tears. Awareness of the quality of your vision in each eye is extremely important, especially if you are in a higher-risk group such as those who are nearsighted or diabetic. Compare the vision of your eyes daily by looking straight ahead and covering one eye and then the other.

Notify your doctor immediately if you notice any of the following:

- An obstruction of your peripheral vision (veil, shadow, or curtain)
- Sudden shower of floaters
- Light flashes
- Spider webs

Source: <http://www.stlukeseye.com/Conditions/Default.asp>