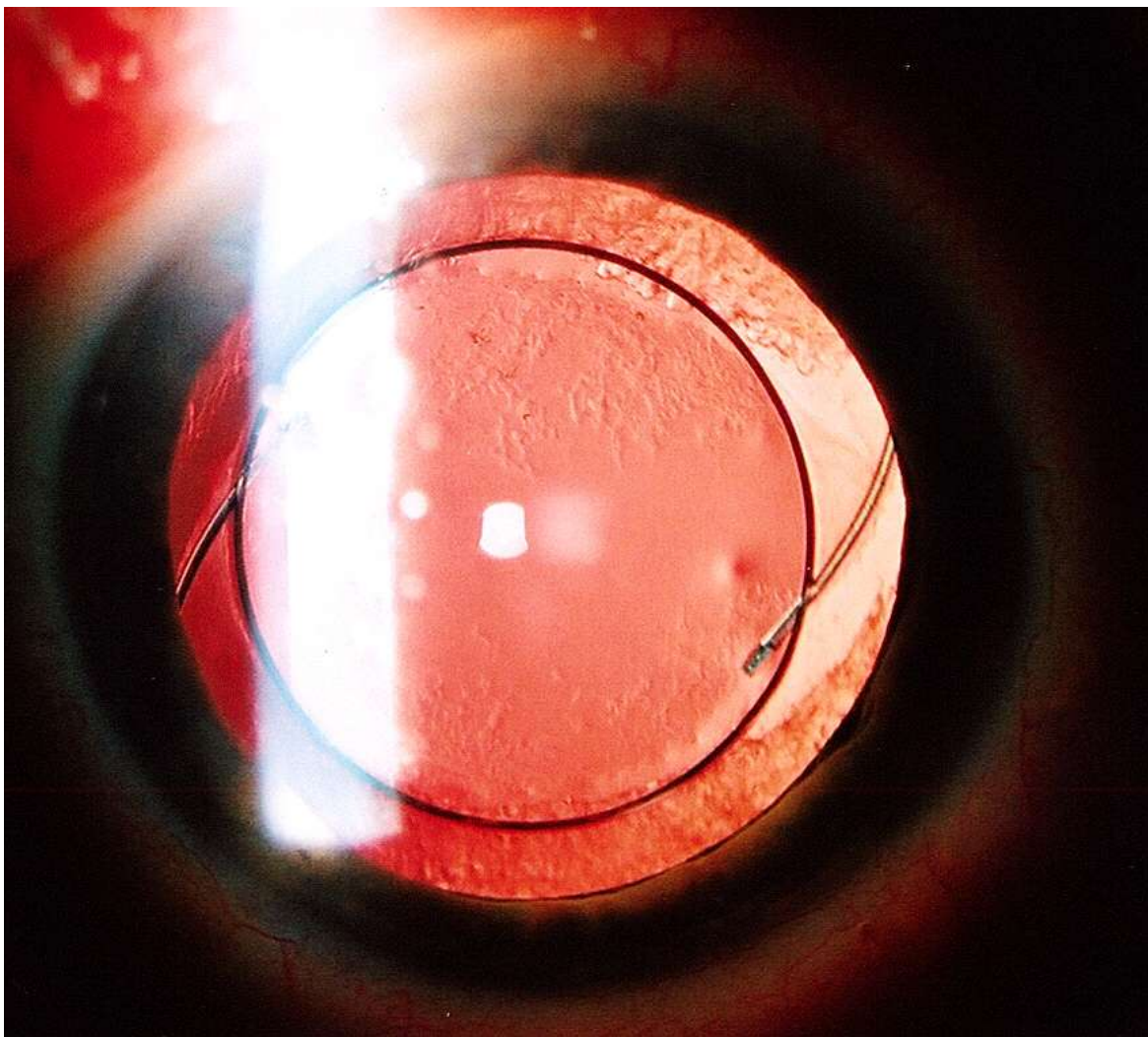


Onemocnění čočky

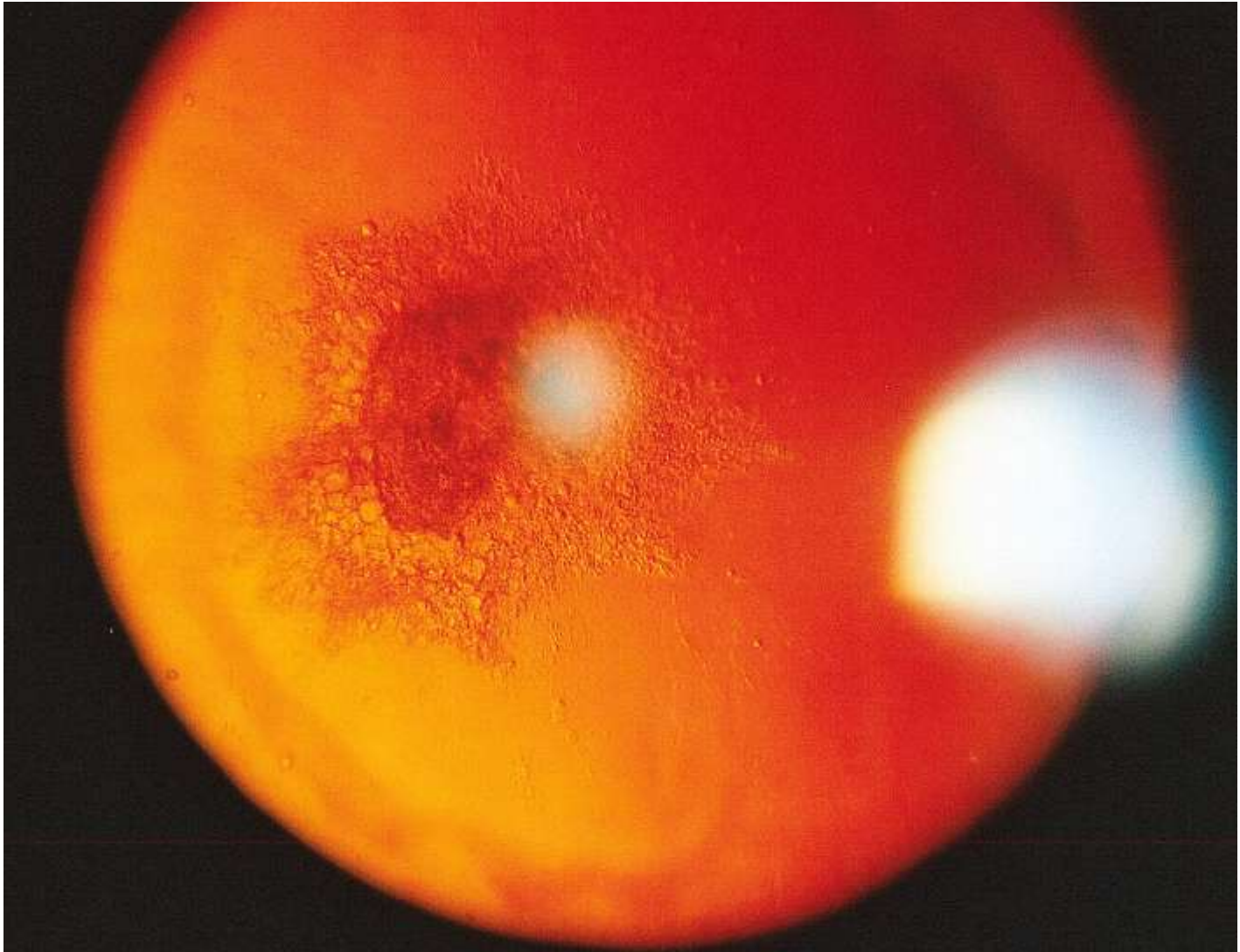
Klinika nemocí oční a optometrie

Doc. Synek, as. Jurečka

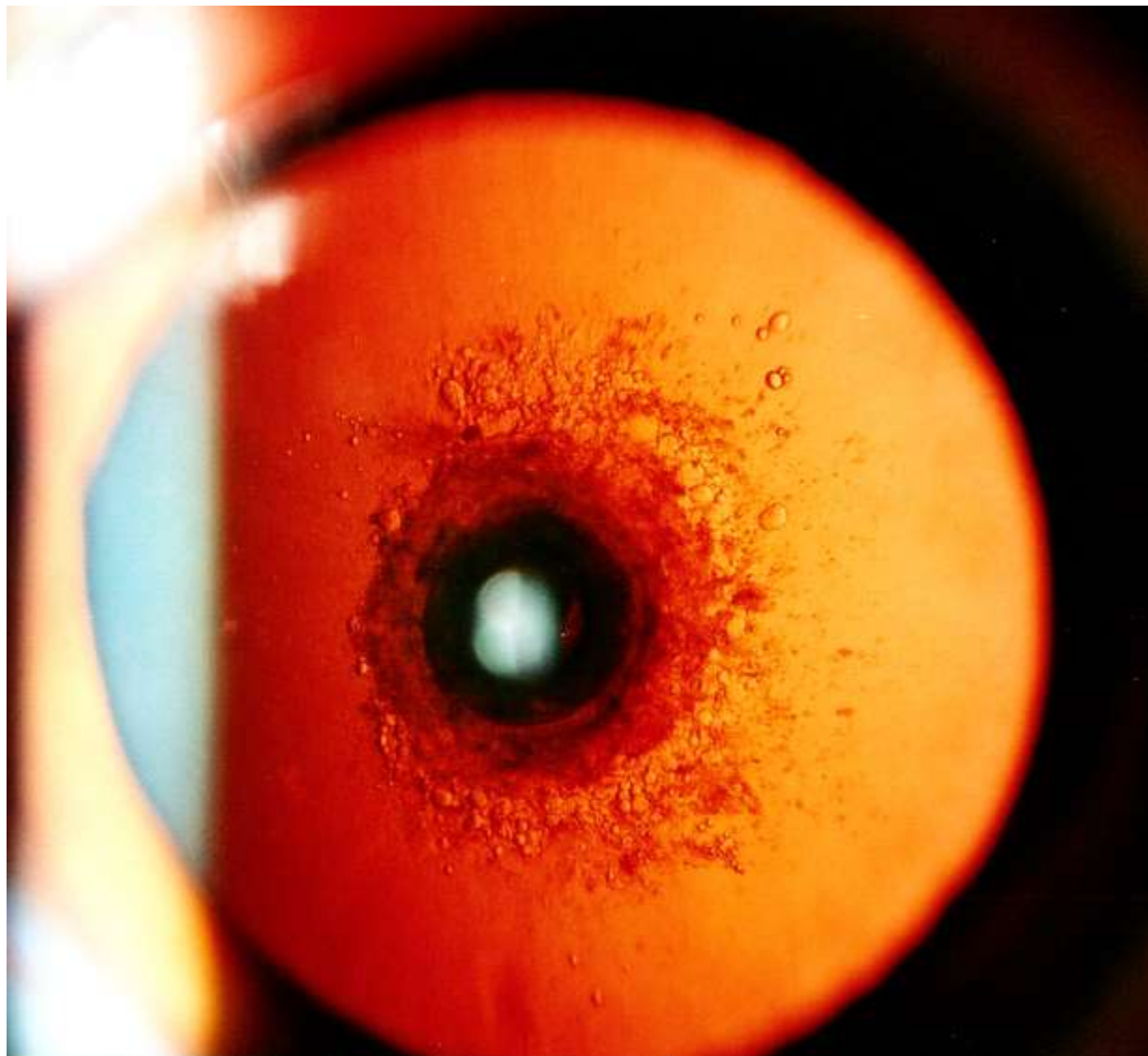
Artefakia, začínající následná katarakta



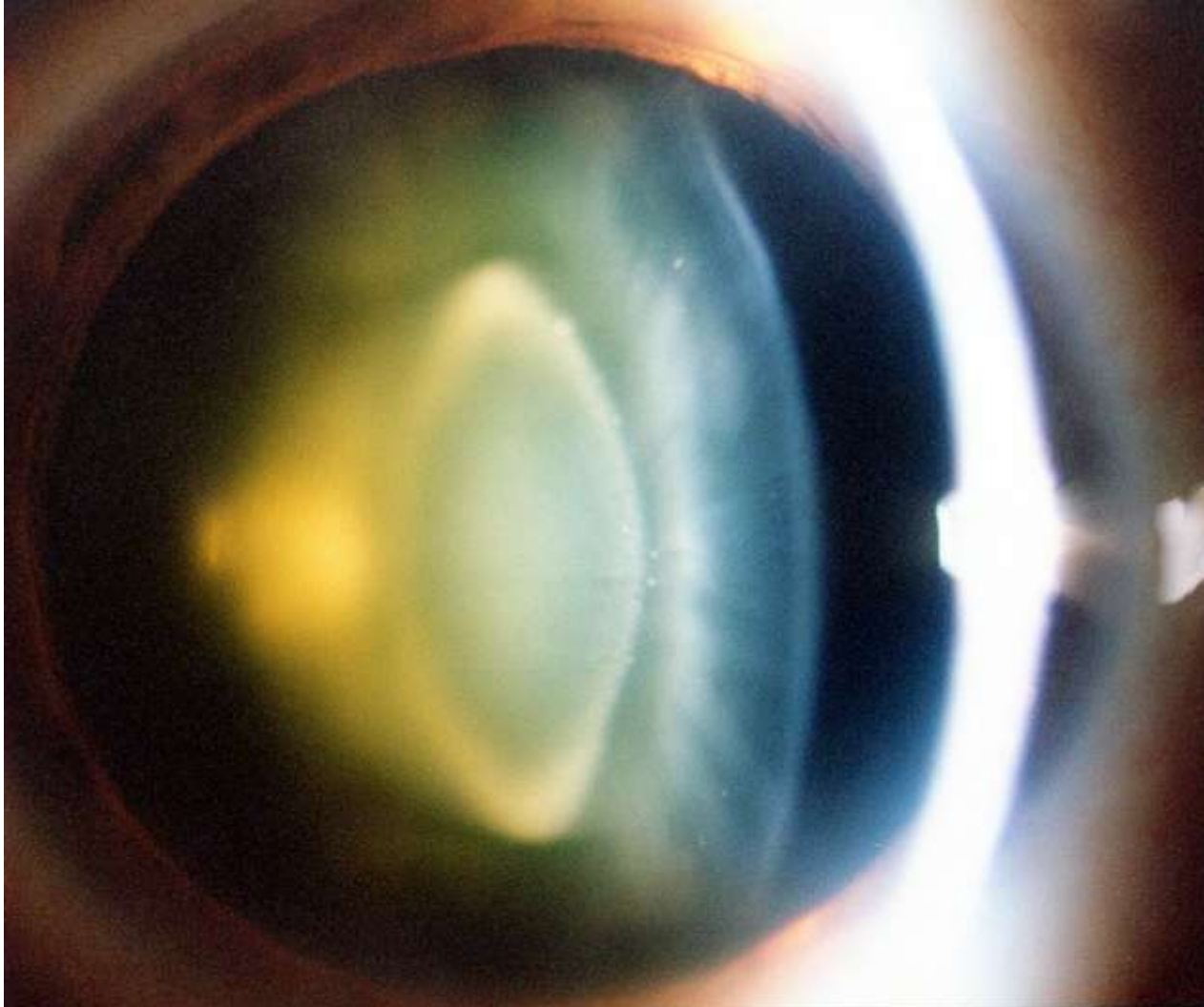Zadní miskovitá katarakta



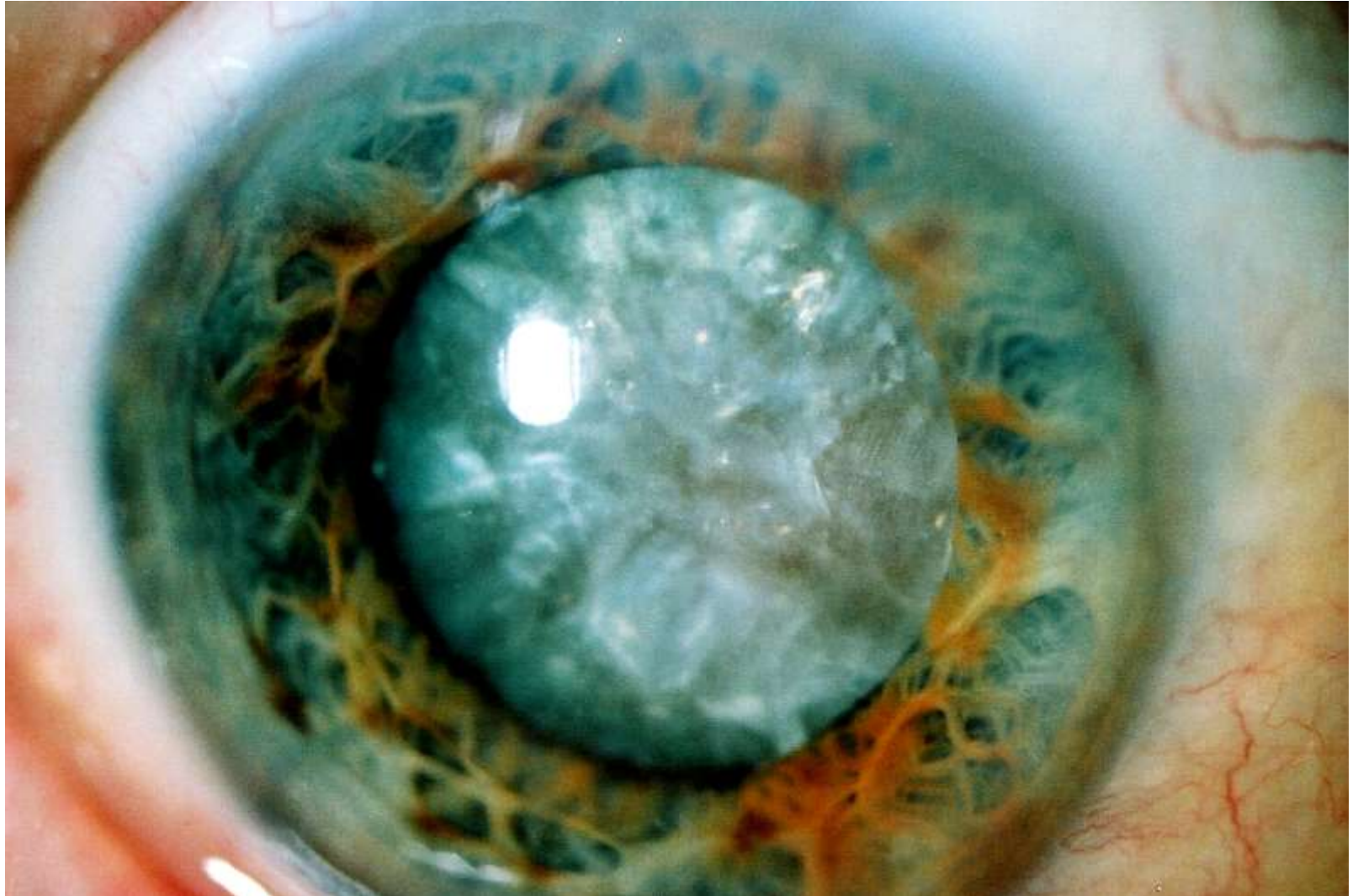
Zadní polární katarakta



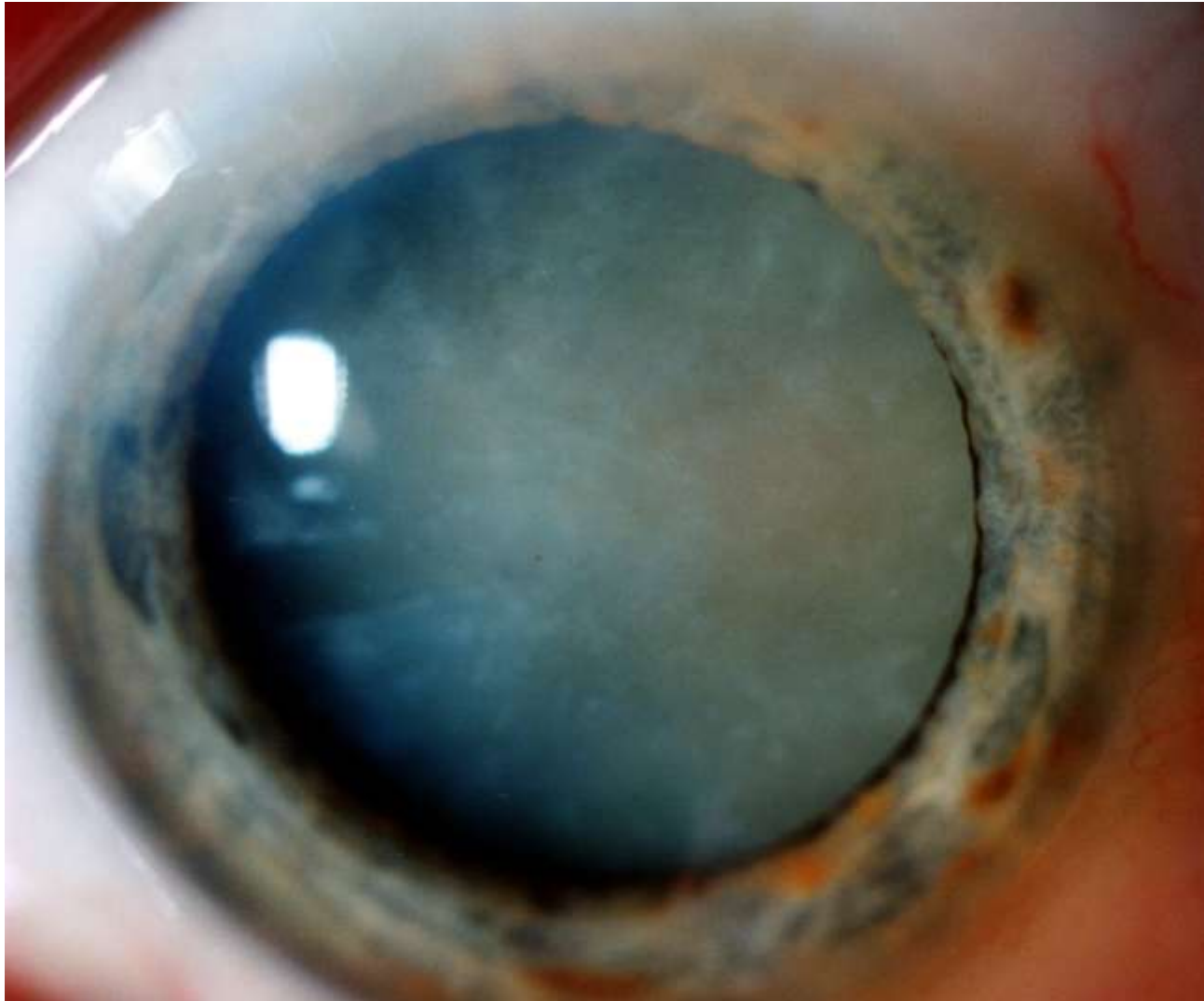
Nukleární katarakta



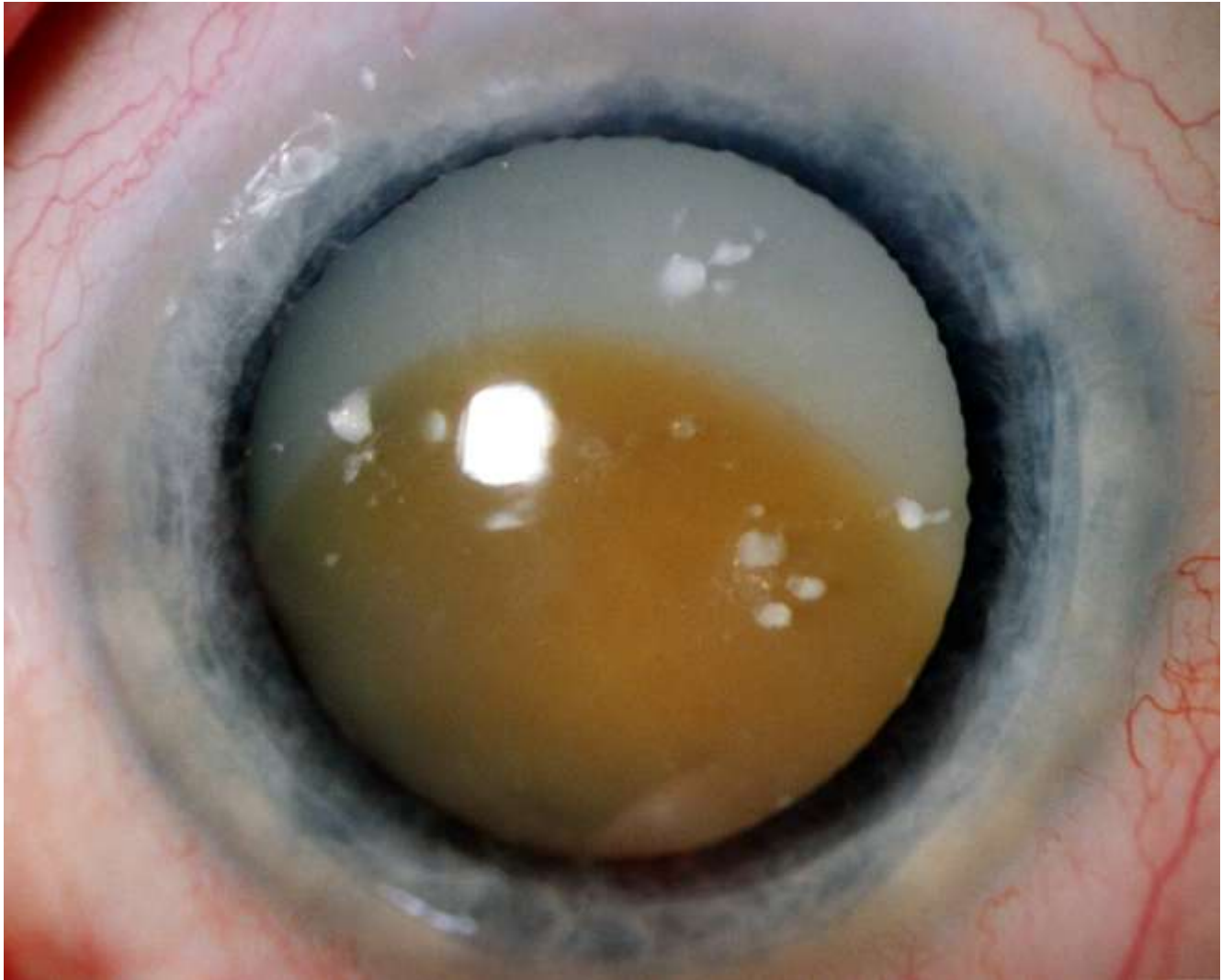
Intumescentní katarakta



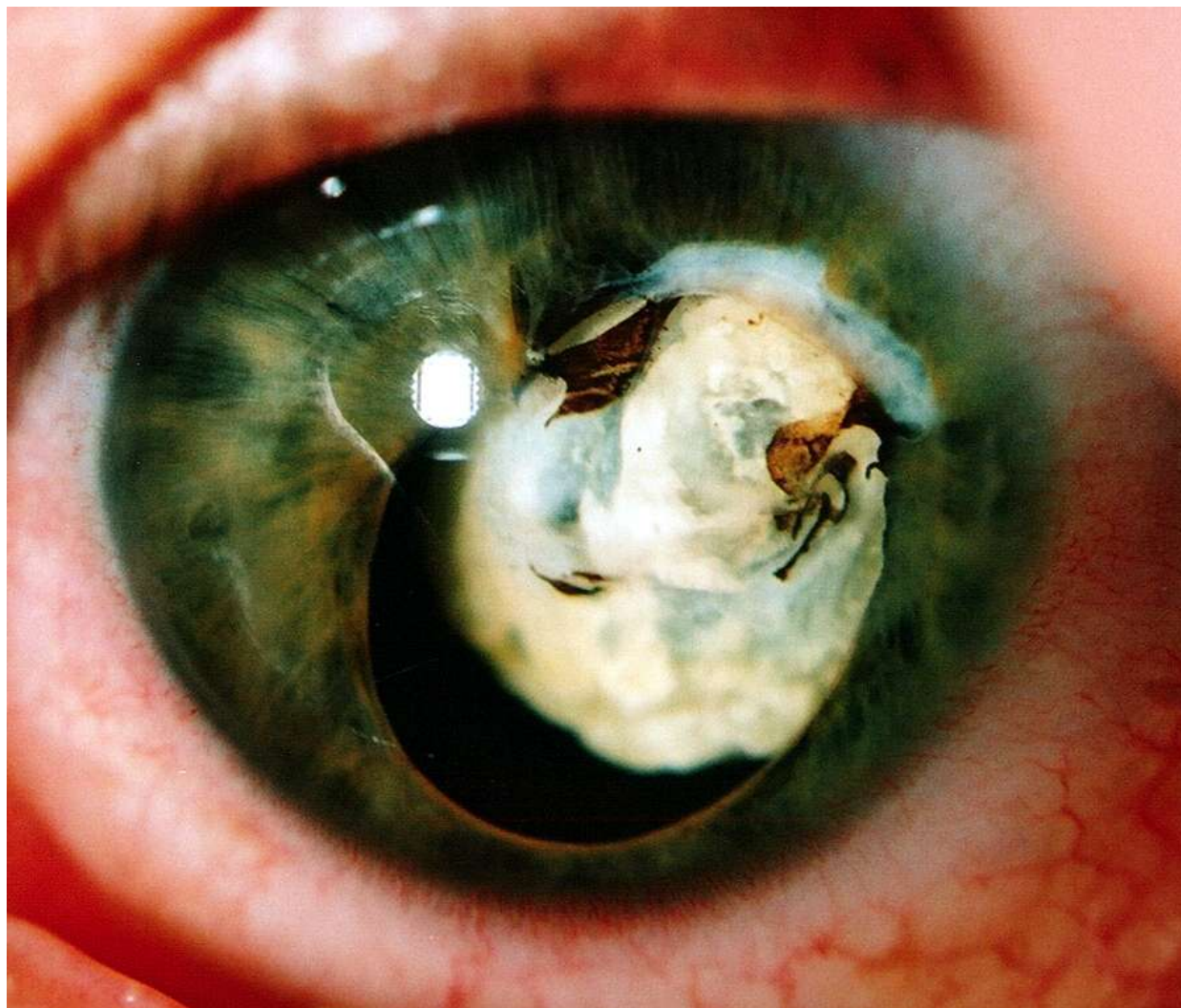Maturní katarakta



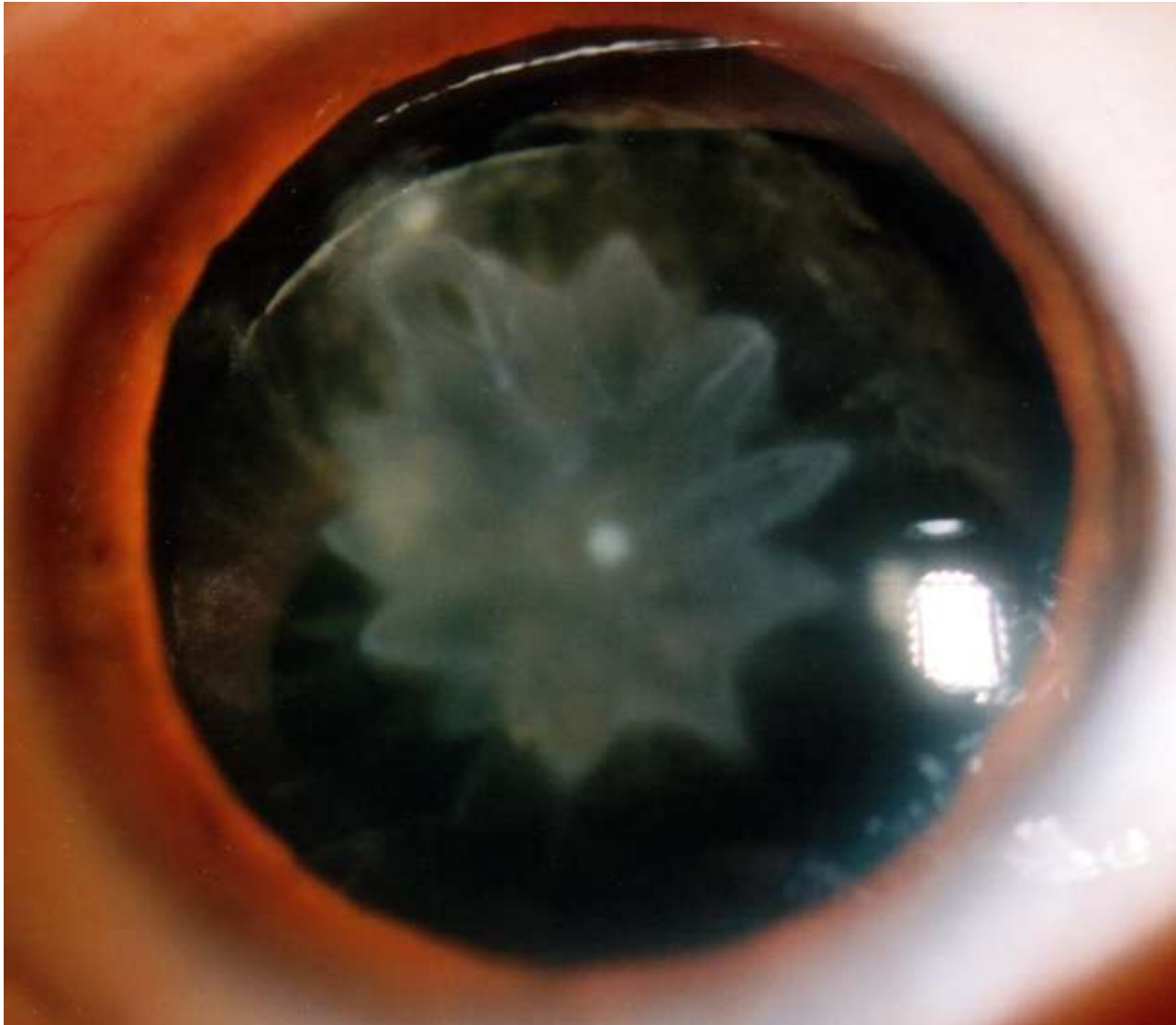
Přezrálá katarakta Morgagniana



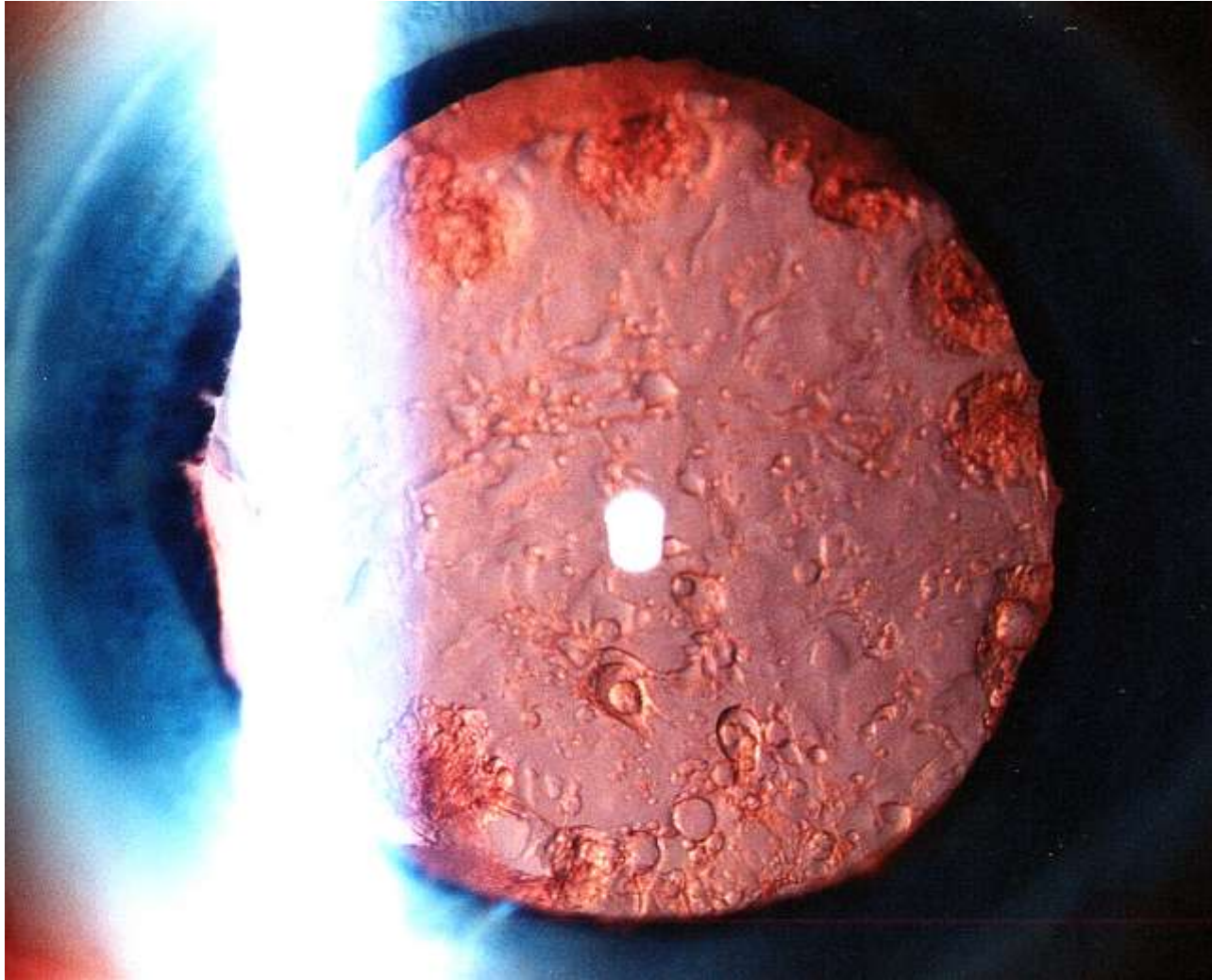
Zvápenatělá částečně resorbovaná hypermaturní katarakta



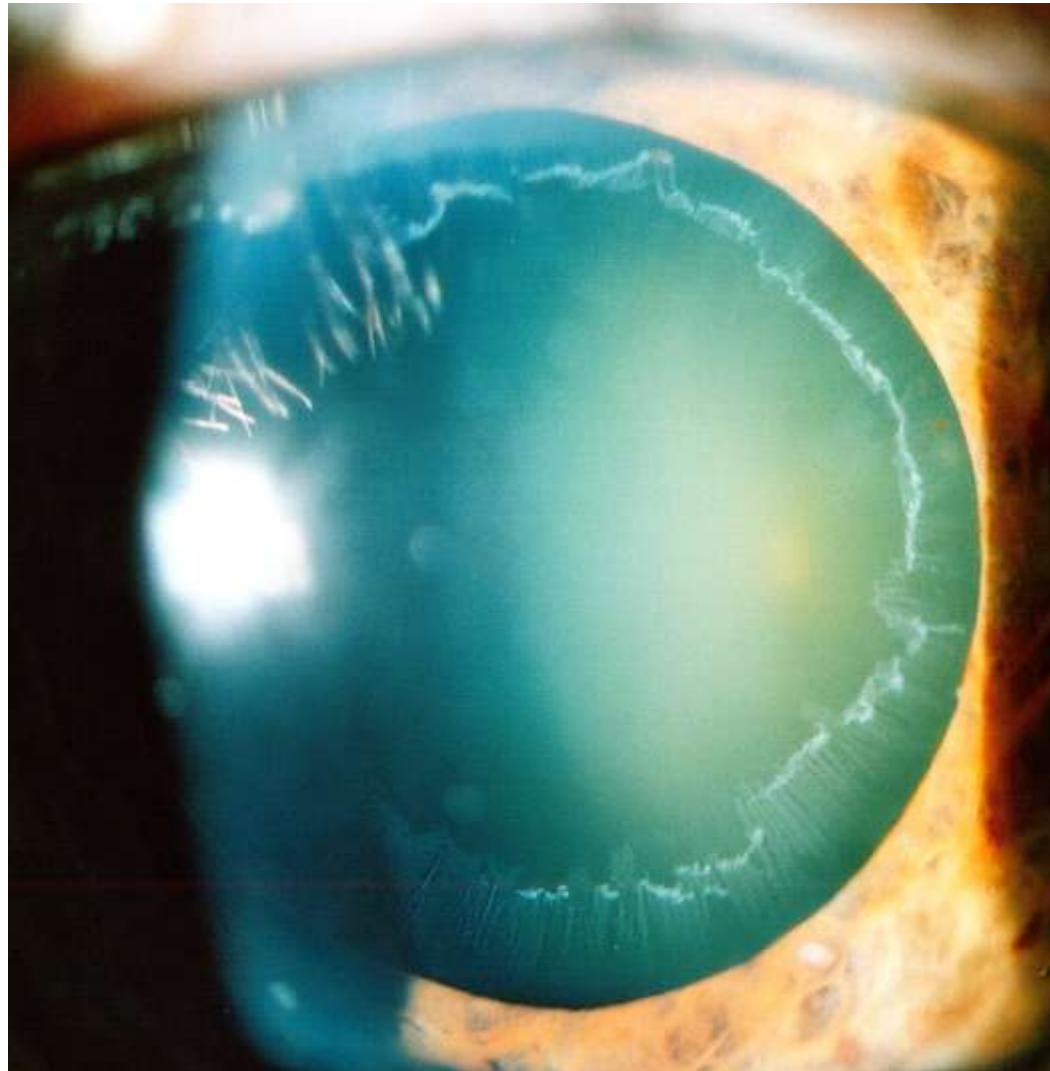
Traumatická katarakta



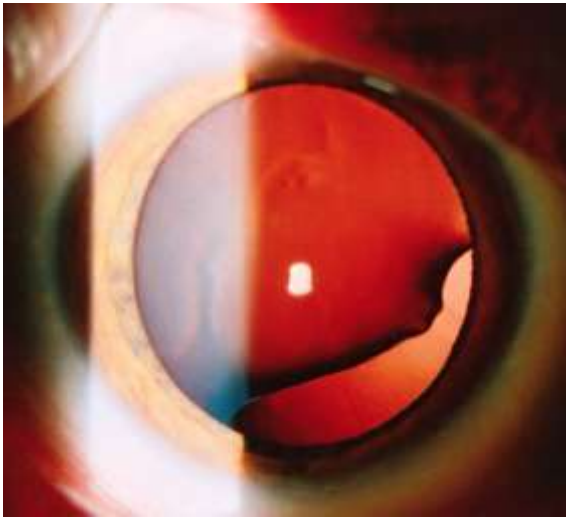
Sekundární katarakta



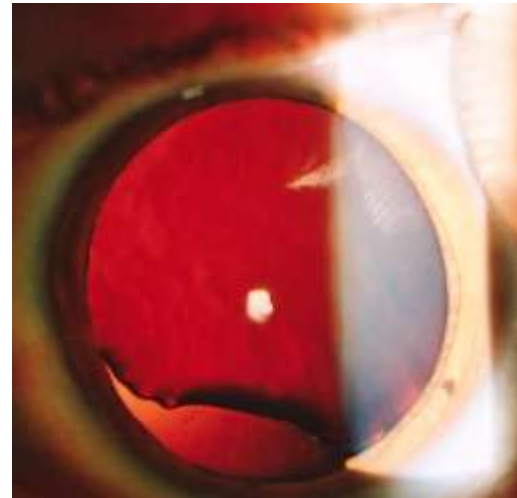
Pseudoexfoliace



Kolobom čočky



OD



OS

Nitrooční pupilární čočka- sputnik

