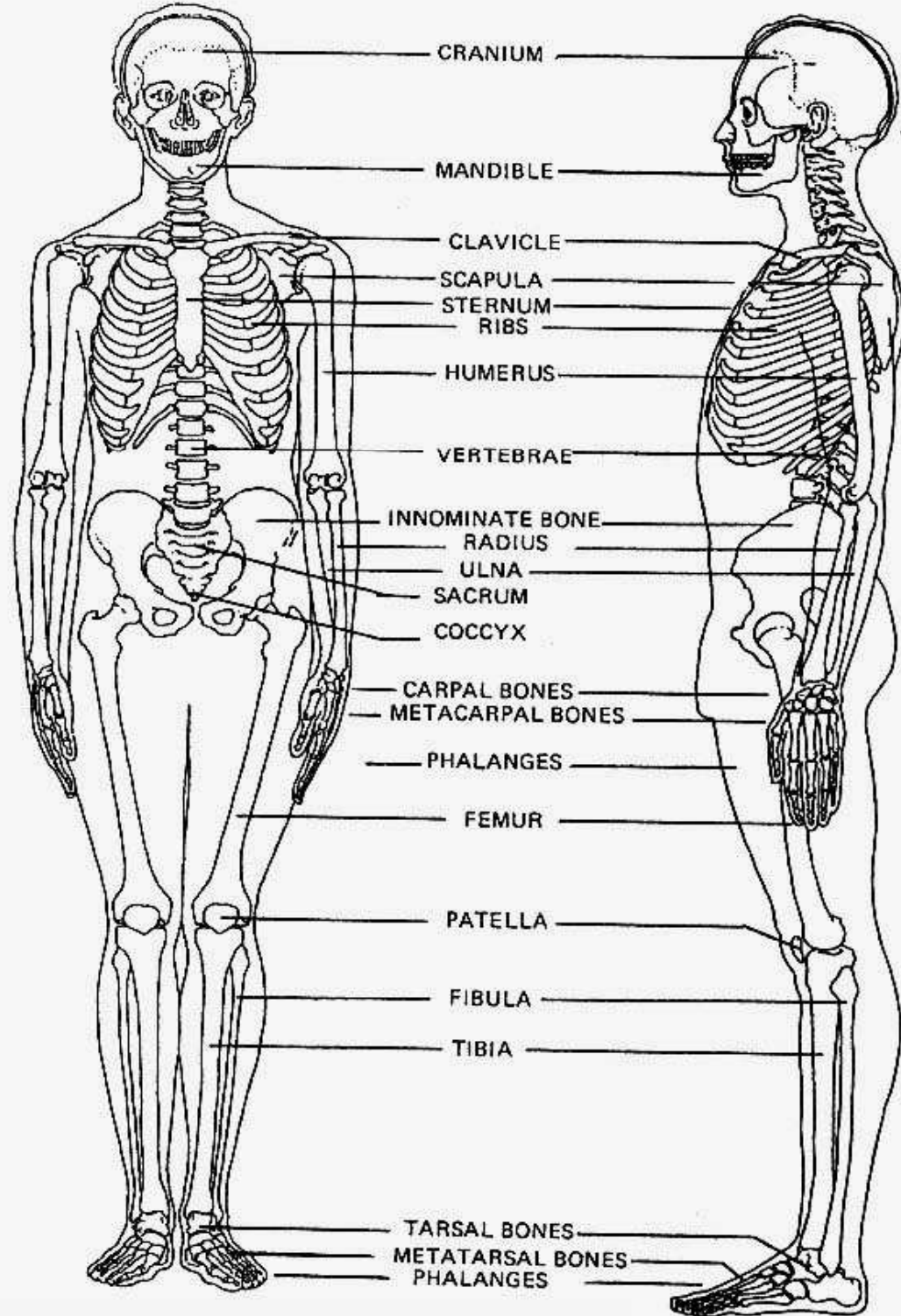




Proč studovat kosti ?



studium prehistorického člověka



biologické porovnání prehistorických lidí s lidmi dnes žijícími



pohřební rituály



*prehistorická onemocnění,
příčiny smrti*



forenzní případy

Fyzická antropologie

variace

evoluce

Forenzní antropologie

soudní lékaři

soudní zubaři

orgány činné v trestním řízení

pozitivní identifikace

Antropometrie




Somatometrie



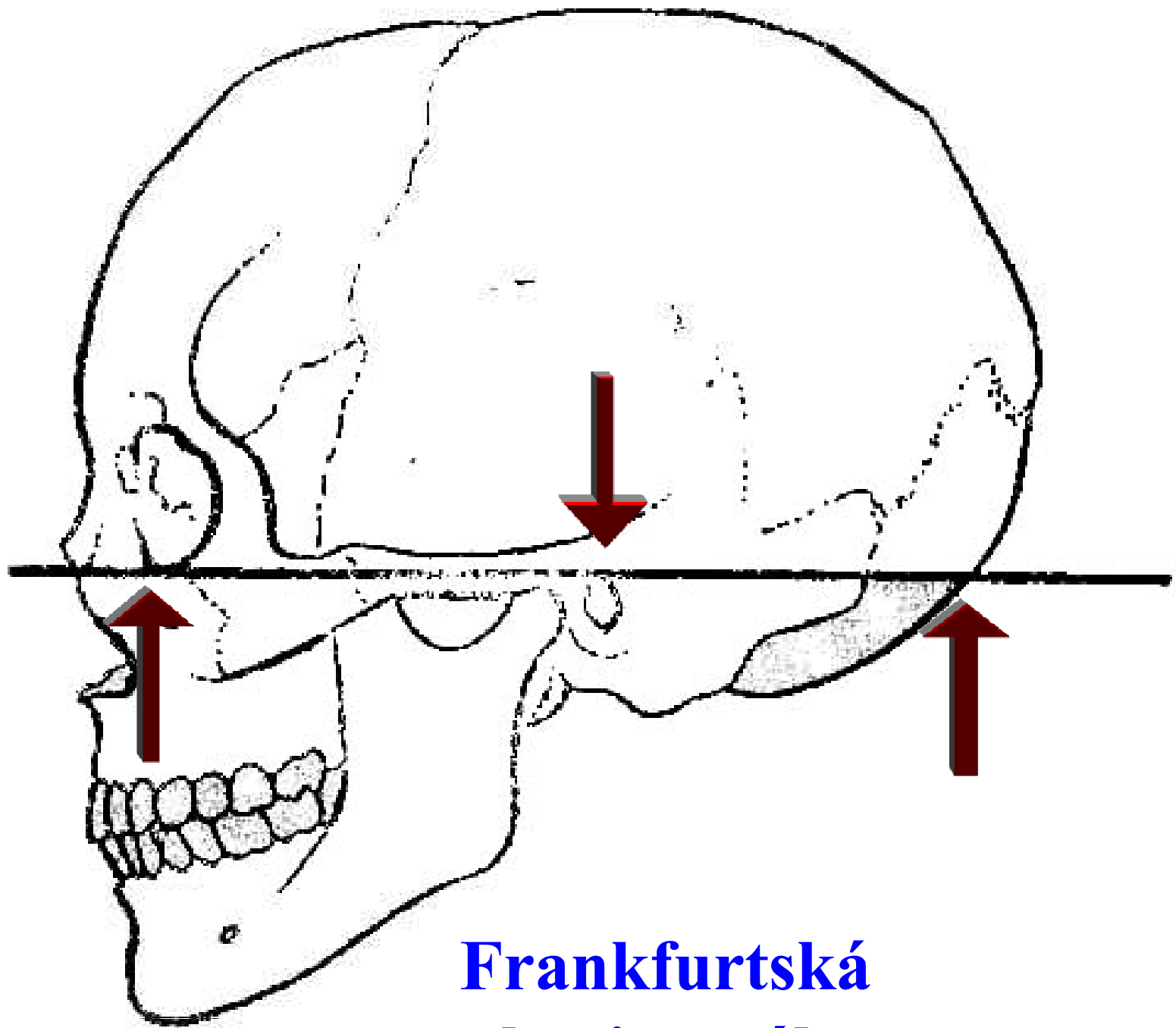
Cephalometrie



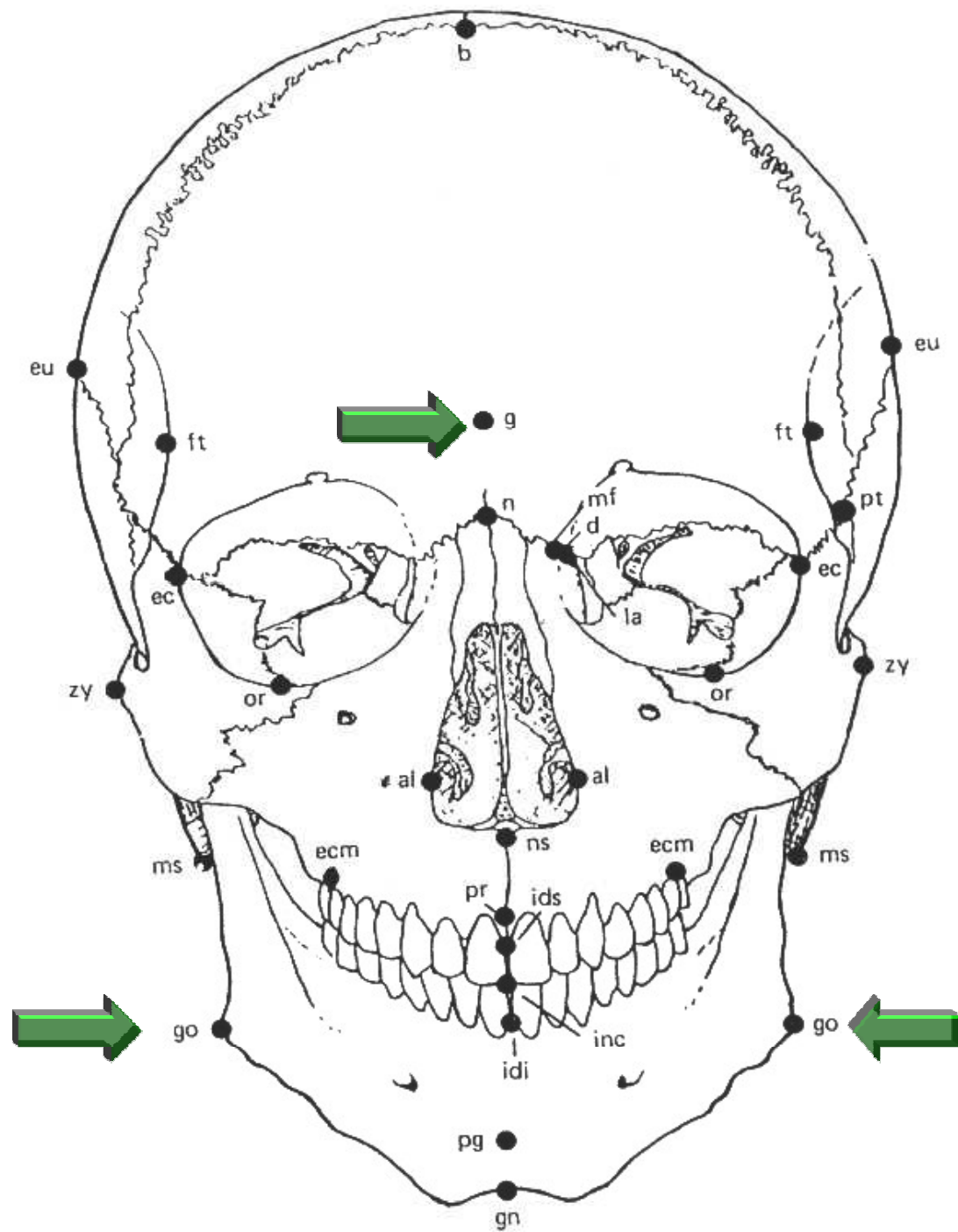
Osteometrie



Kraniometrie

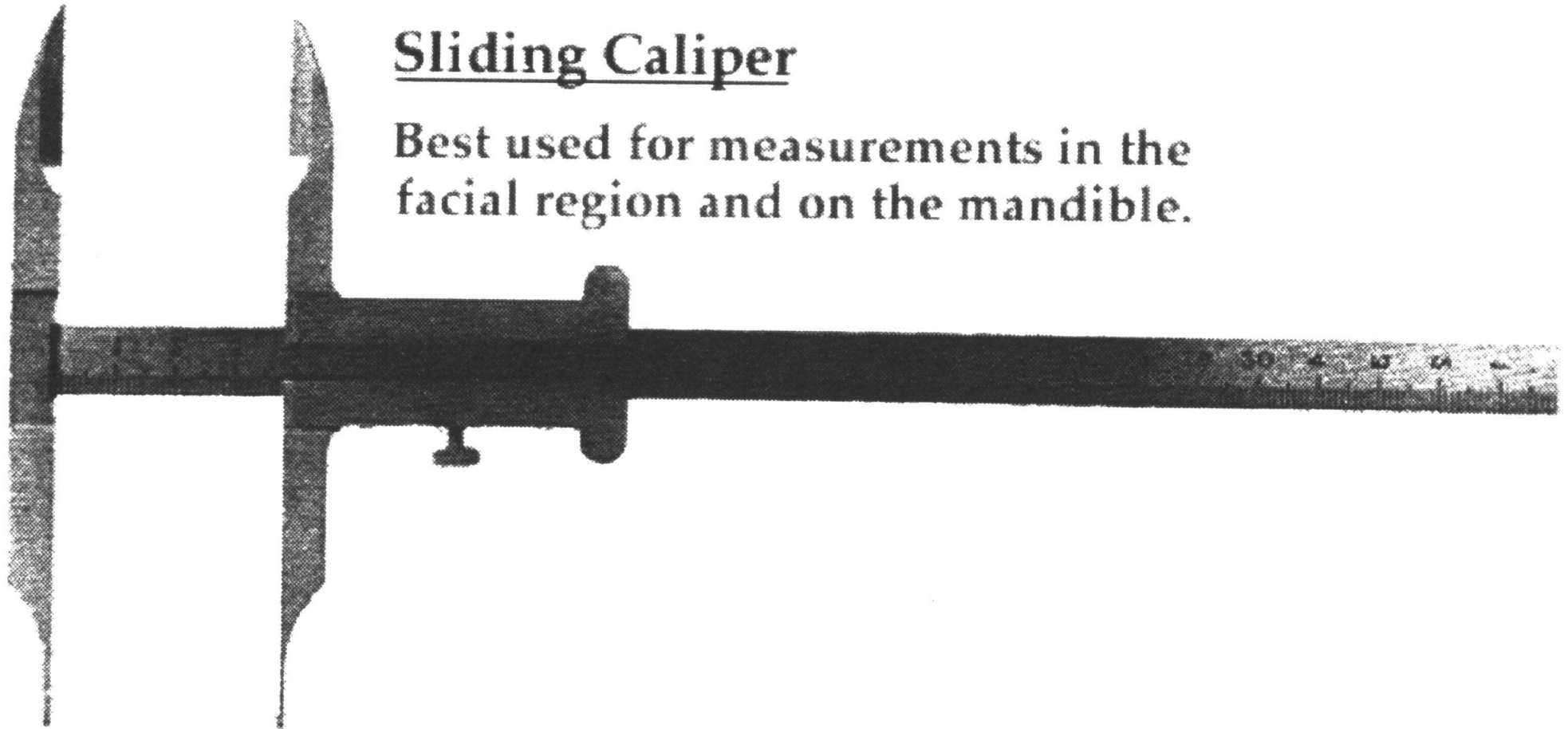


**Frankfurtská
horizontála**



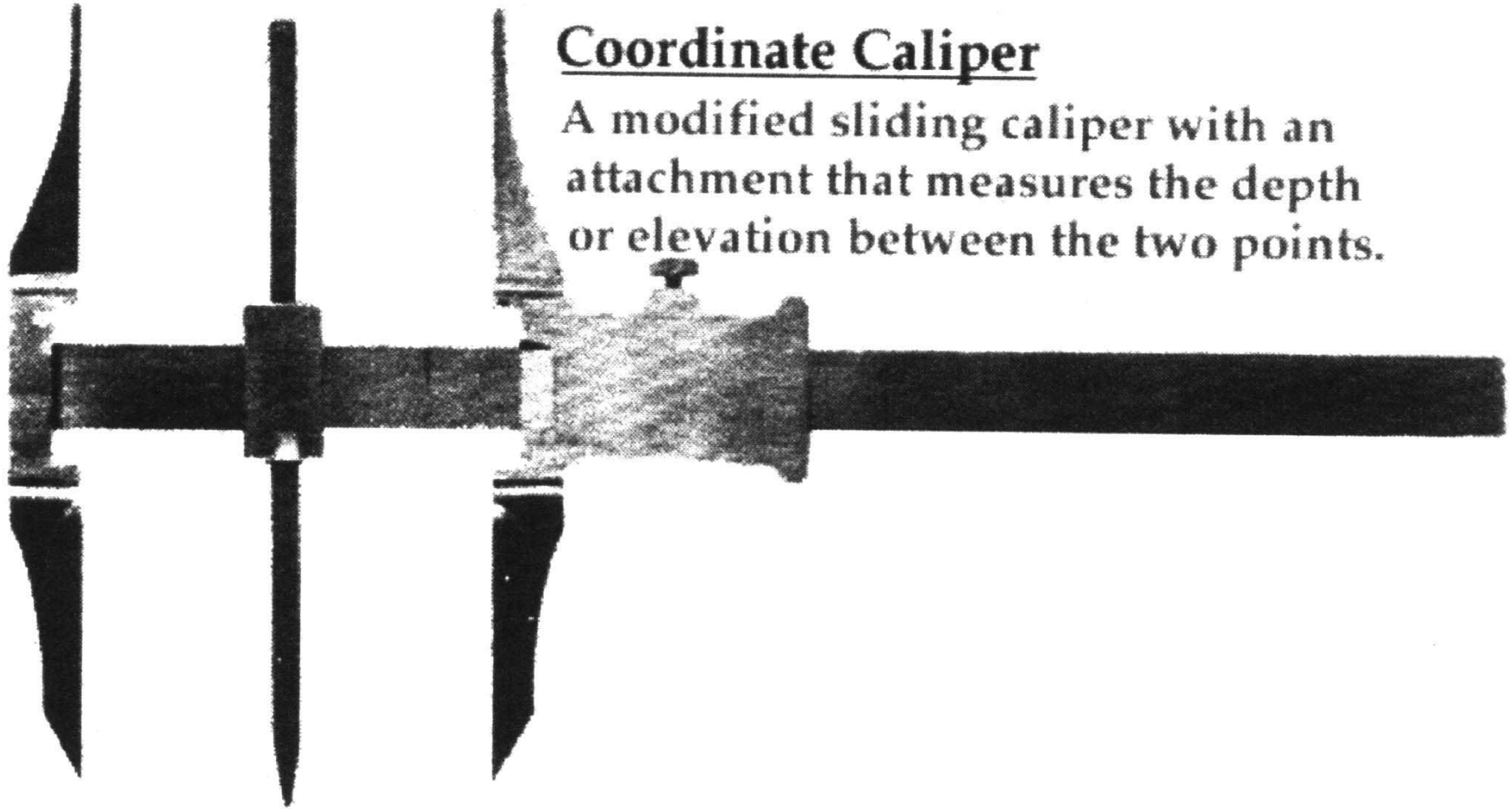
Sliding Caliper

Best used for measurements in the facial region and on the mandible.



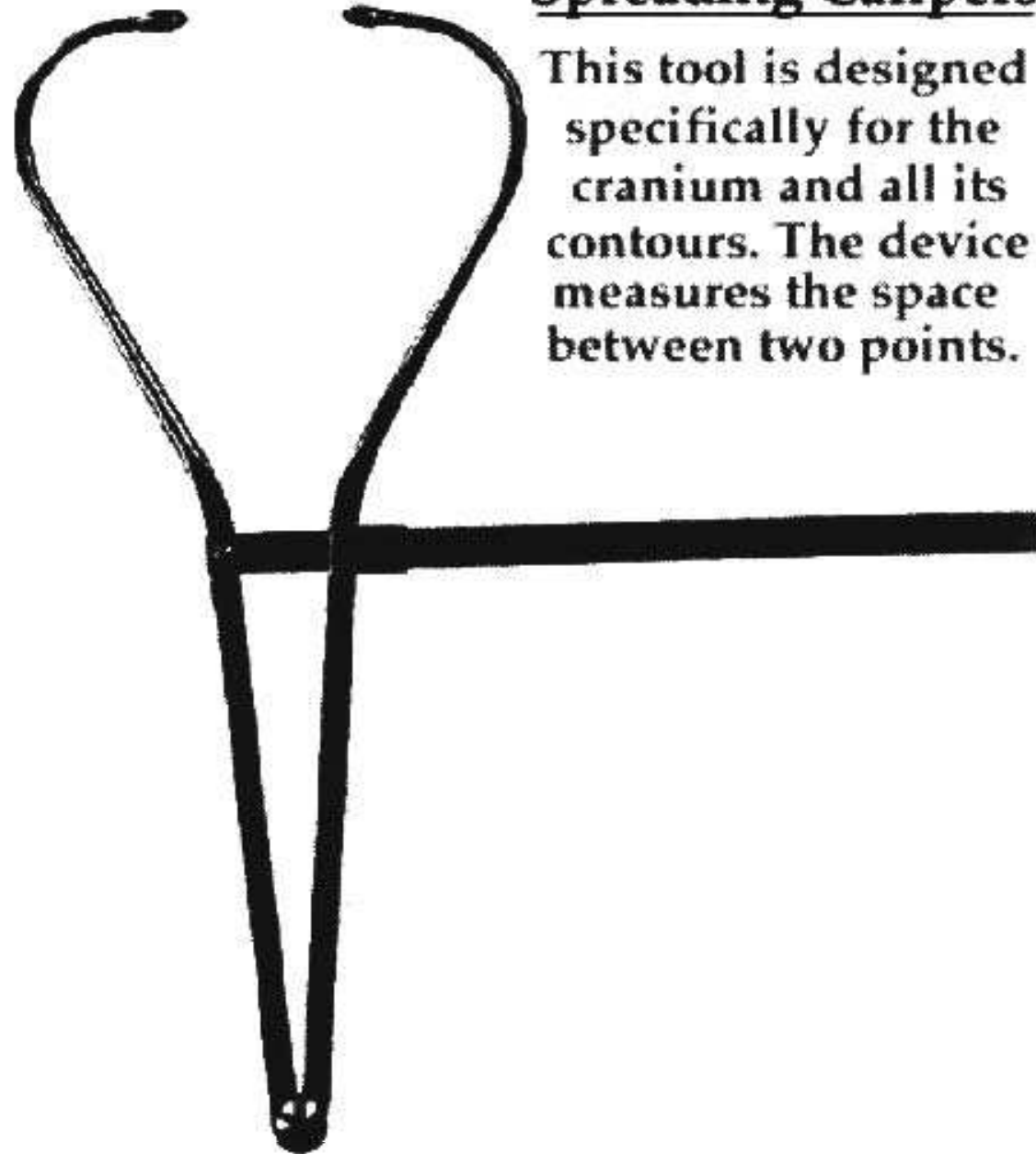
Coordinate Caliper

A modified sliding caliper with an attachment that measures the depth or elevation between the two points.



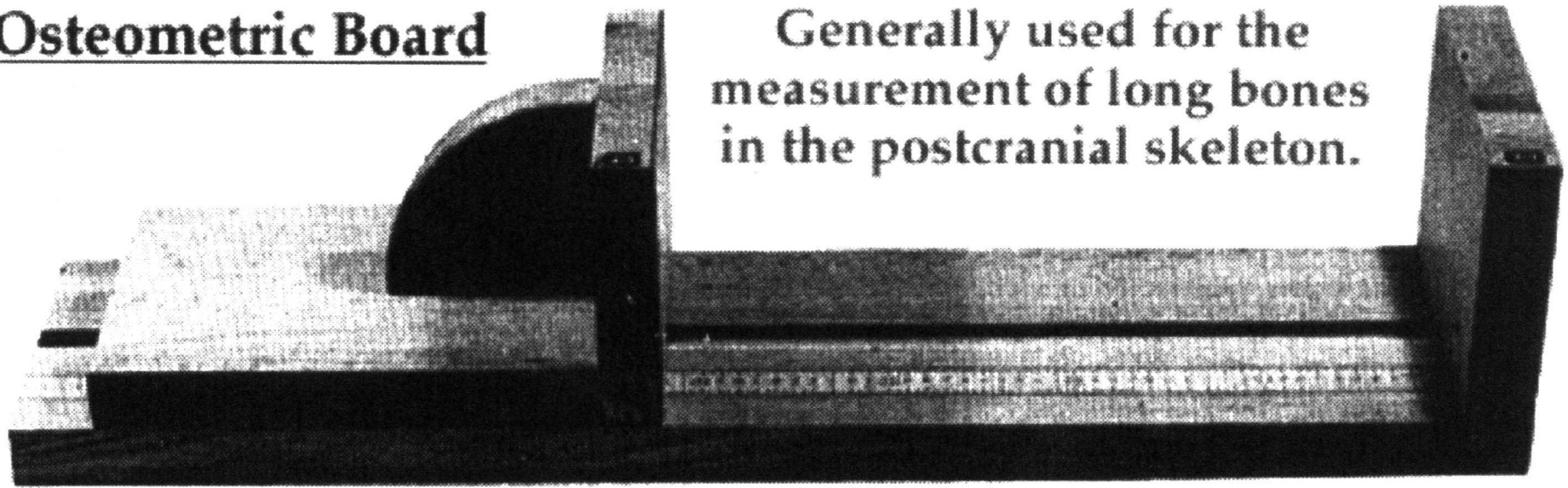
Spreading Calipers

This tool is designed specifically for the cranium and all its contours. The device measures the space between two points.



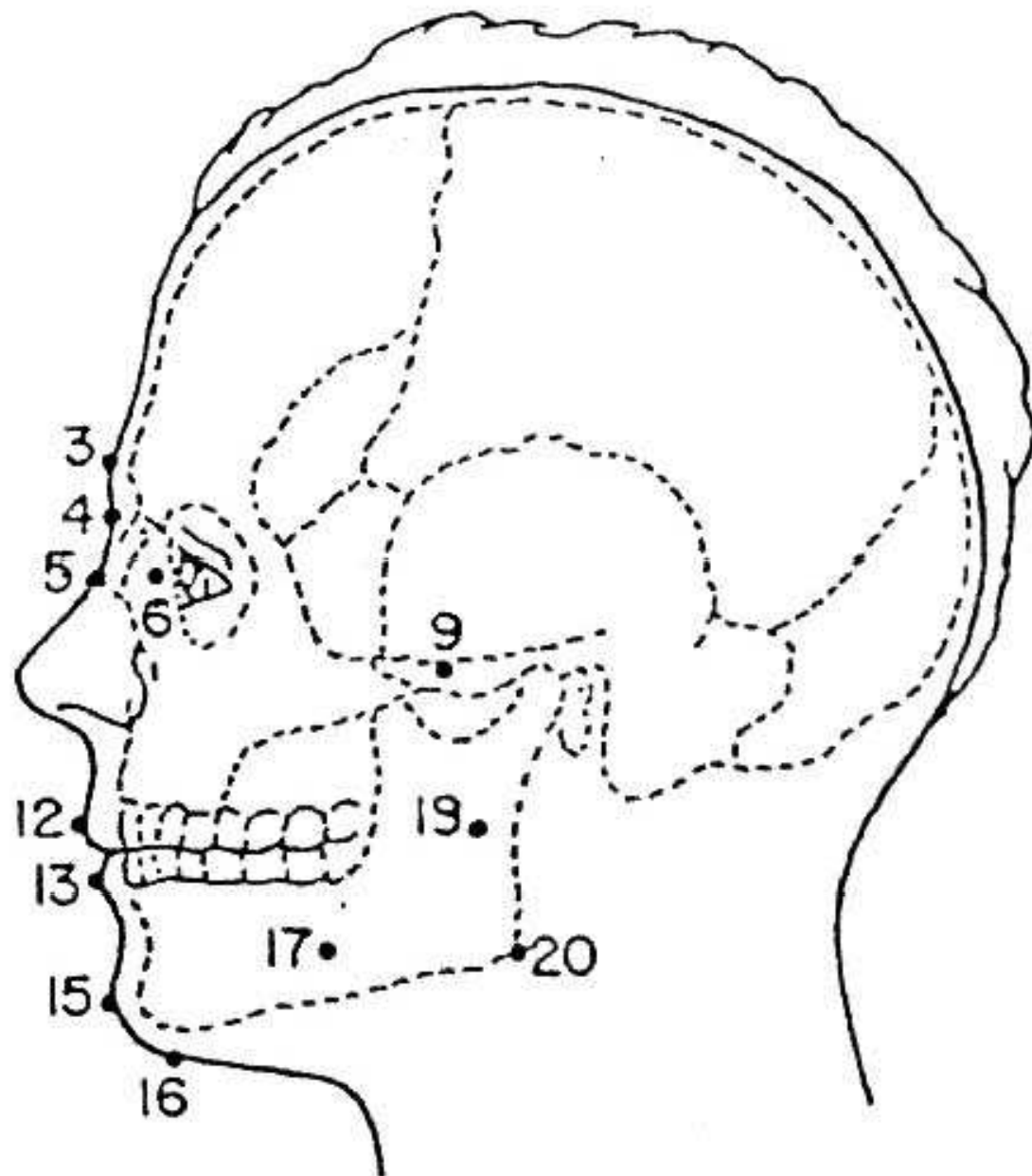
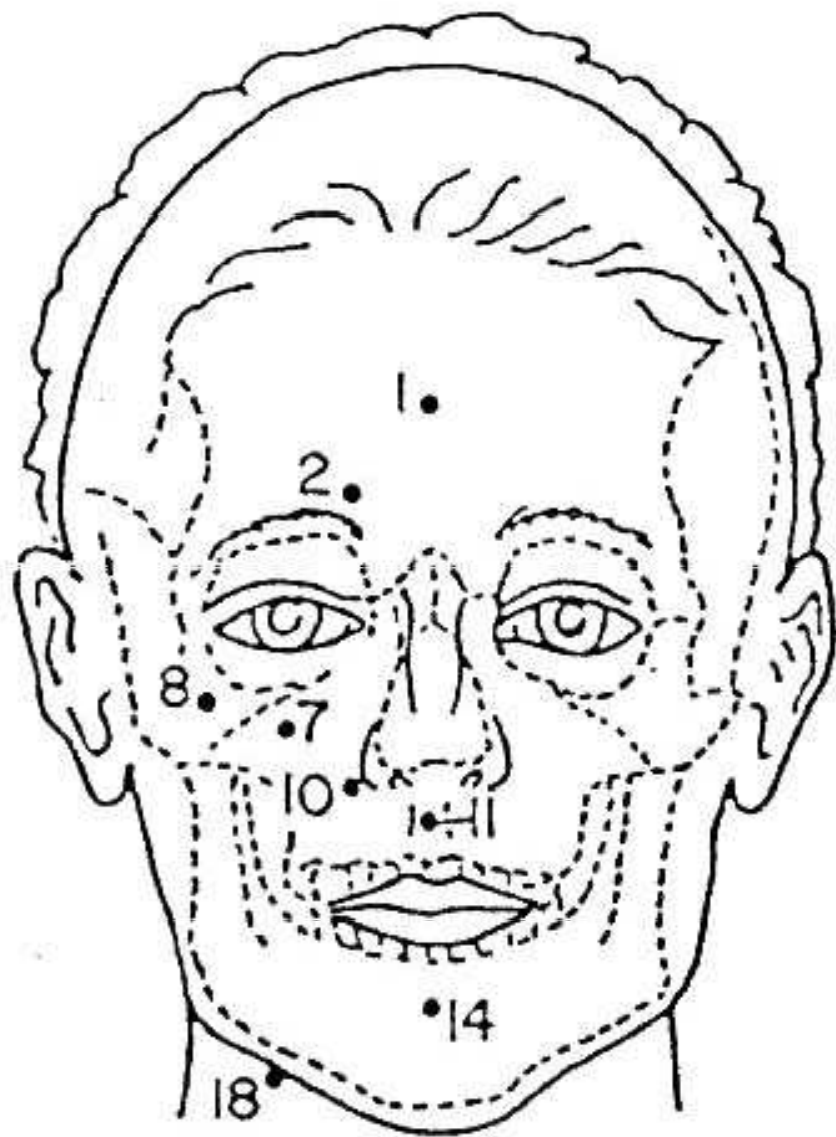
Osteometric Board

Generally used for the measurement of long bones in the postcranial skeleton.

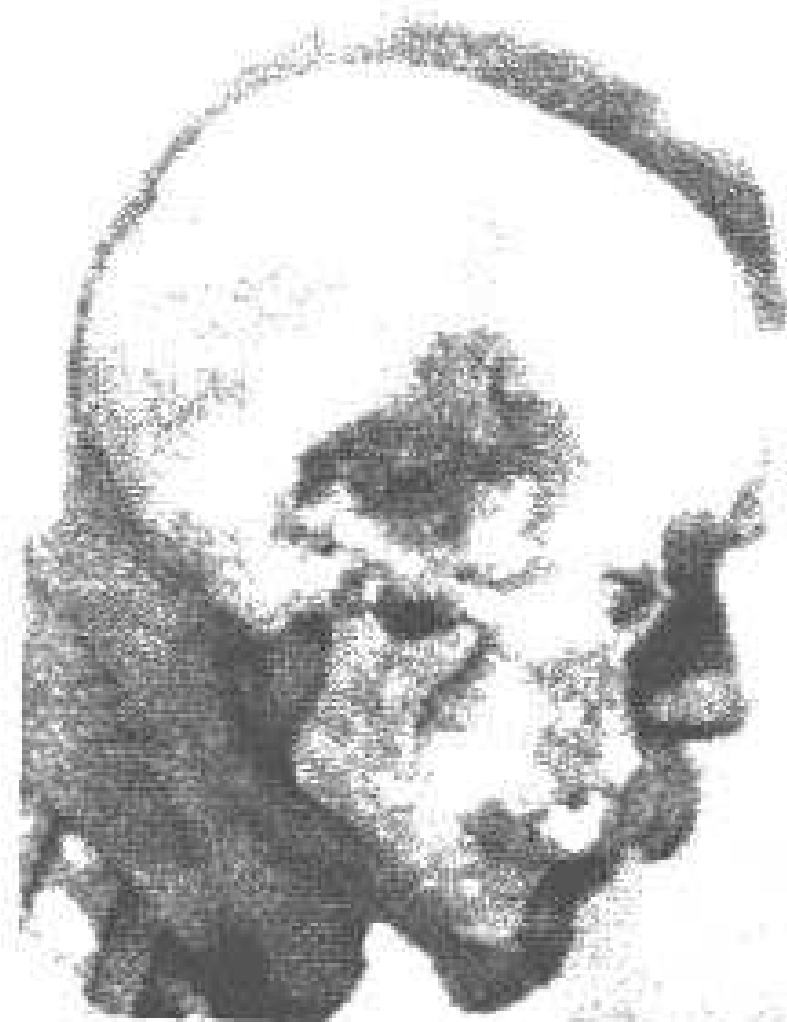

*Rentgenové
snímky*

*Rekonstrukce
obličeje*

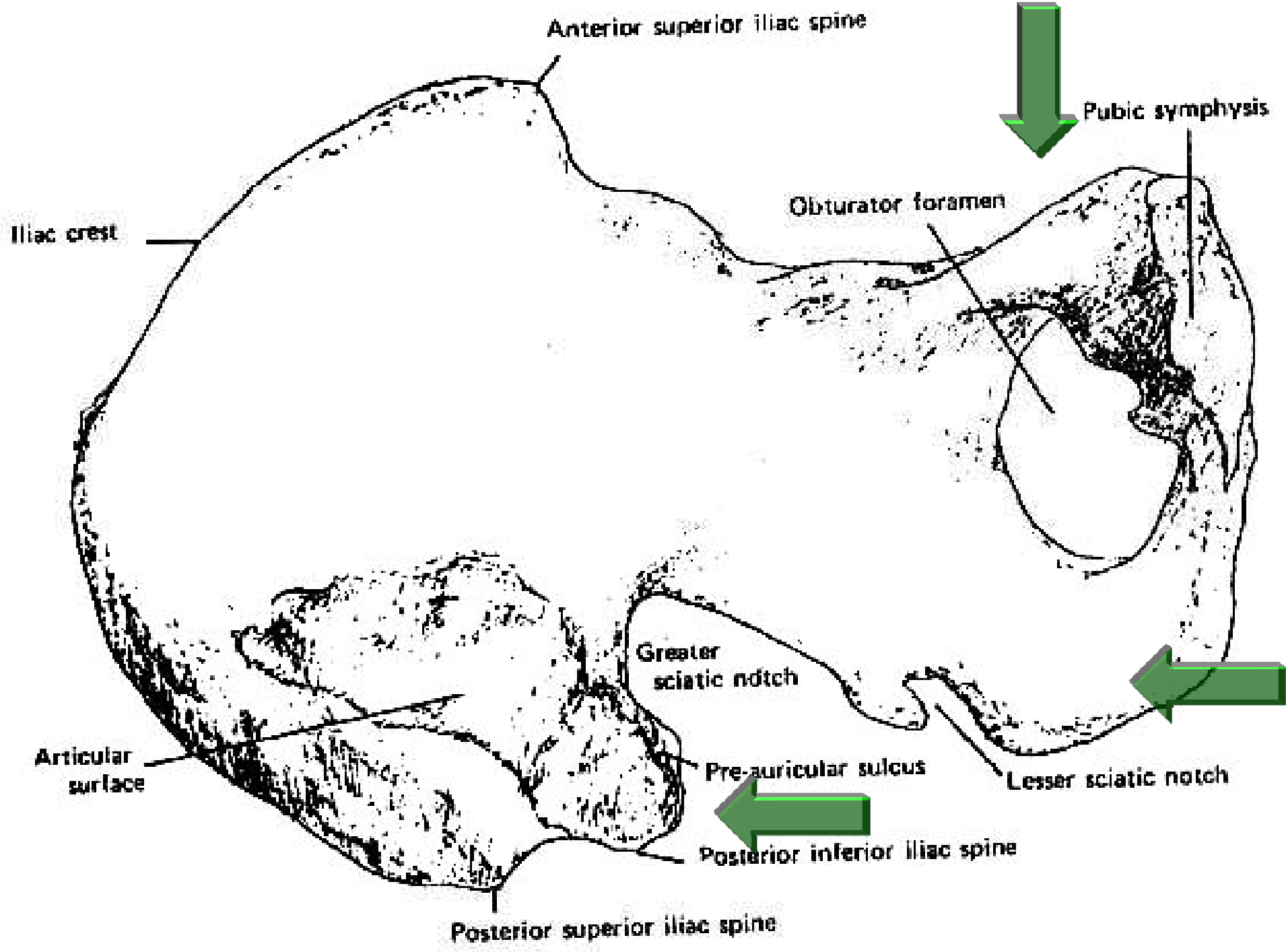


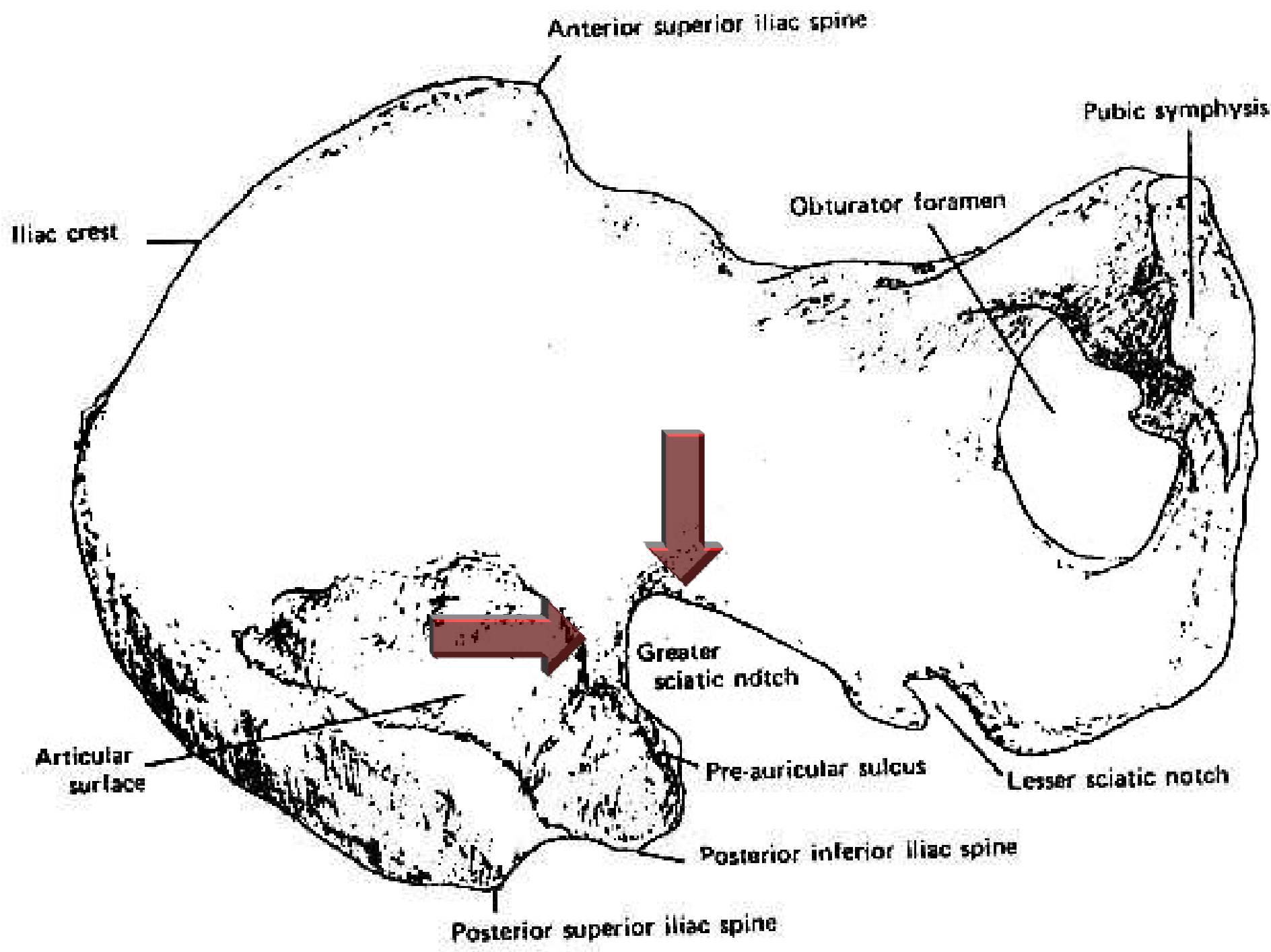
Superprojekce
(superimpozice)



***Results of subprojection of the skull N 4 and
two photographic portraits of Nikolai II***

Určování pohlaví





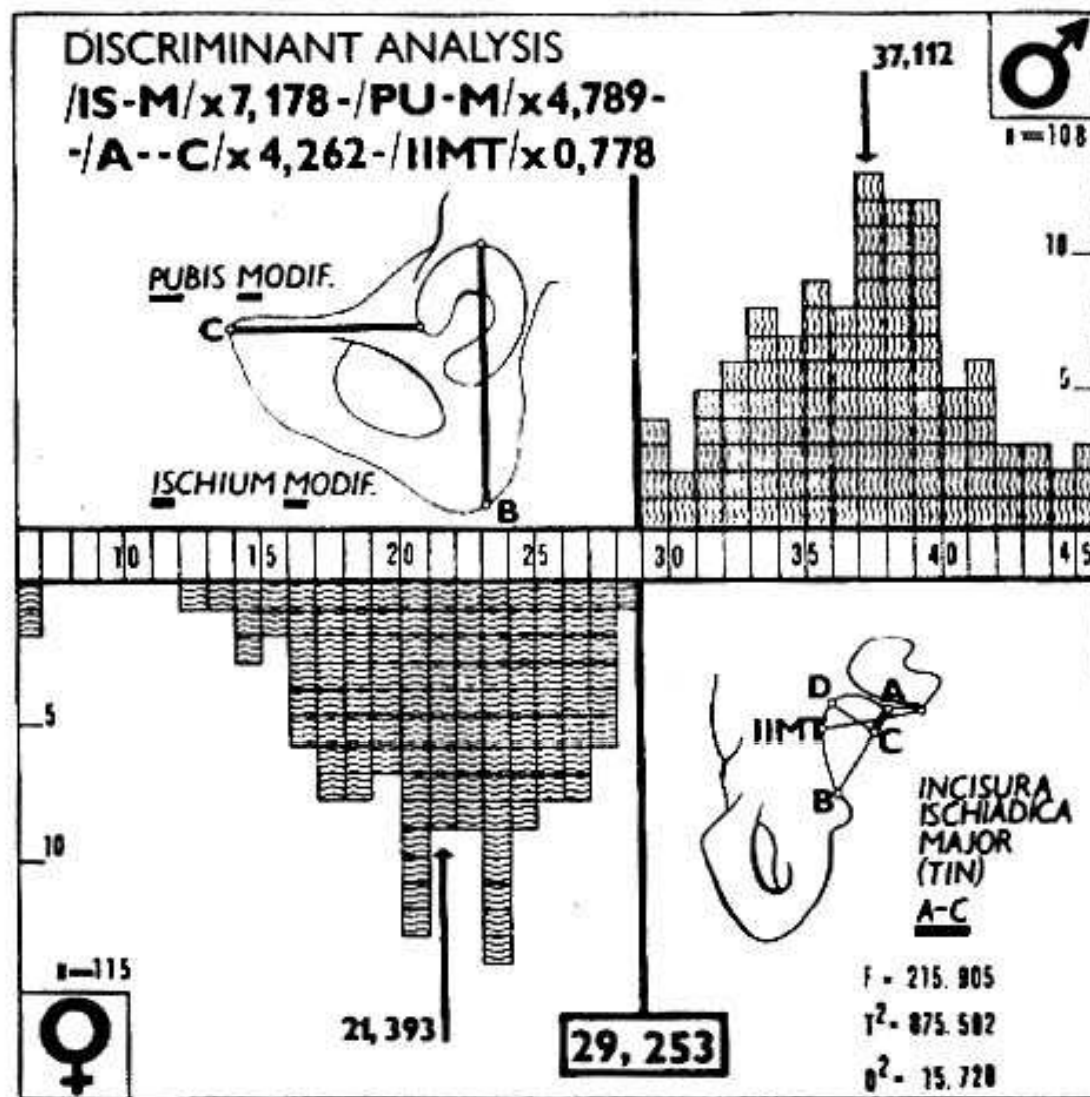


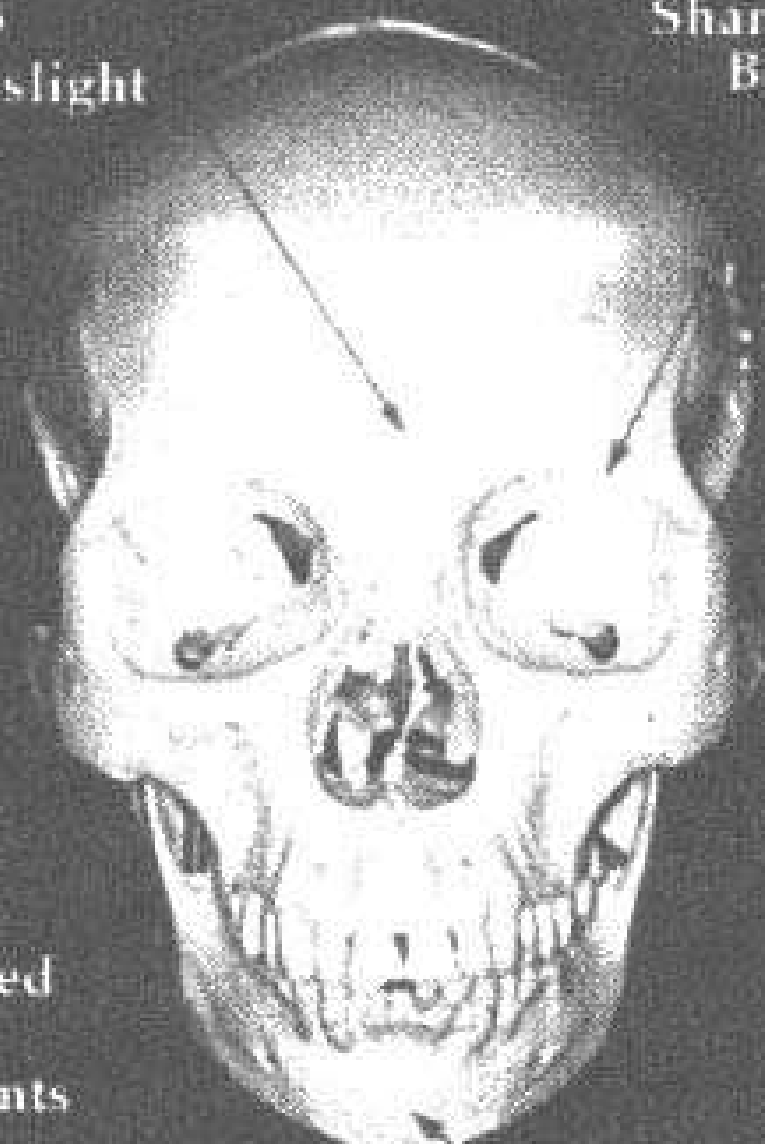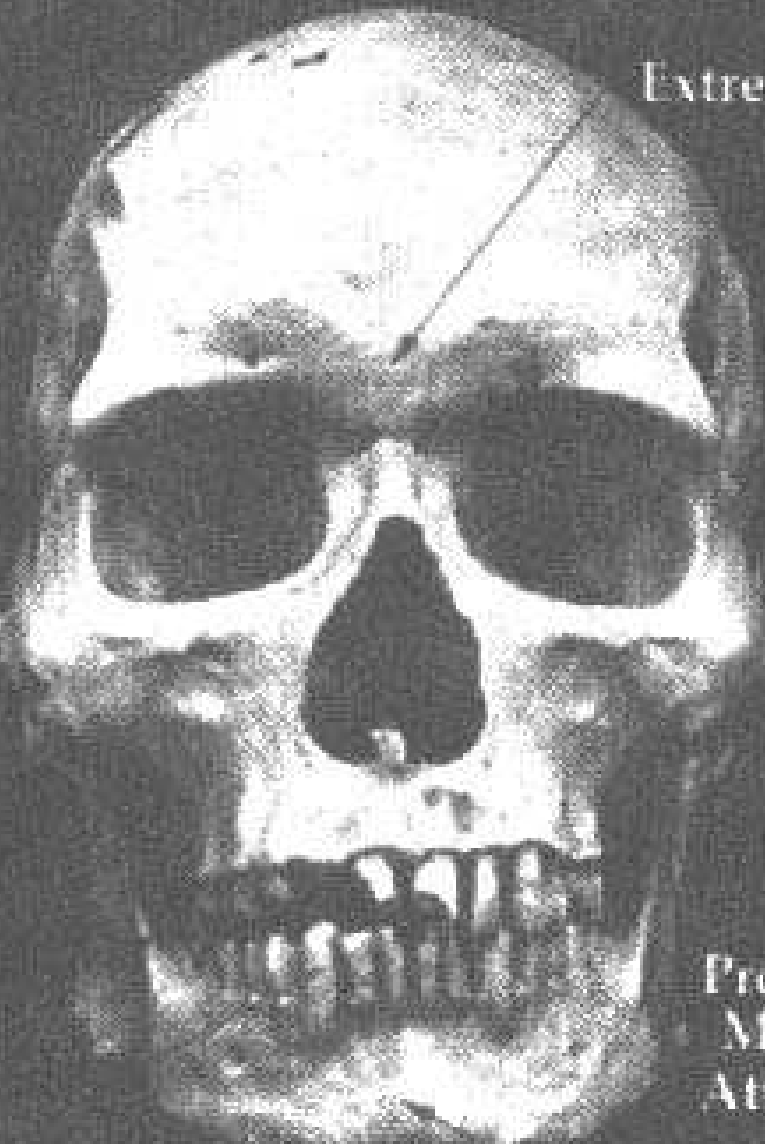Fig. 3. Discriminant analysis based on the ischium-length (IS-M), the pubis-length (PU-M), the upper part of the breadth (A-C) and the height (IIMT) of "incisura ischiadica major" (Novotný 1975). Measuring - see "Recommendations for Age and Sex Diagnoses of Skeletons". *Journal of Human Evolution* 9: 517-549, 1980.

Male

Female

Supraorbital
Ridges
Extreme slight

Sharp Orbital
Border

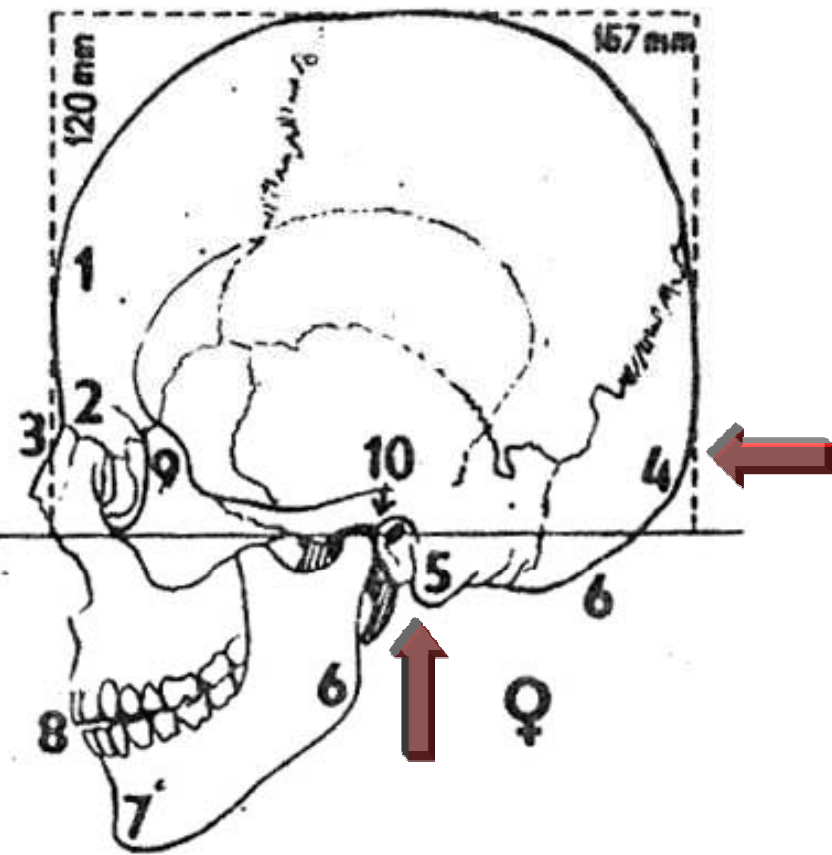
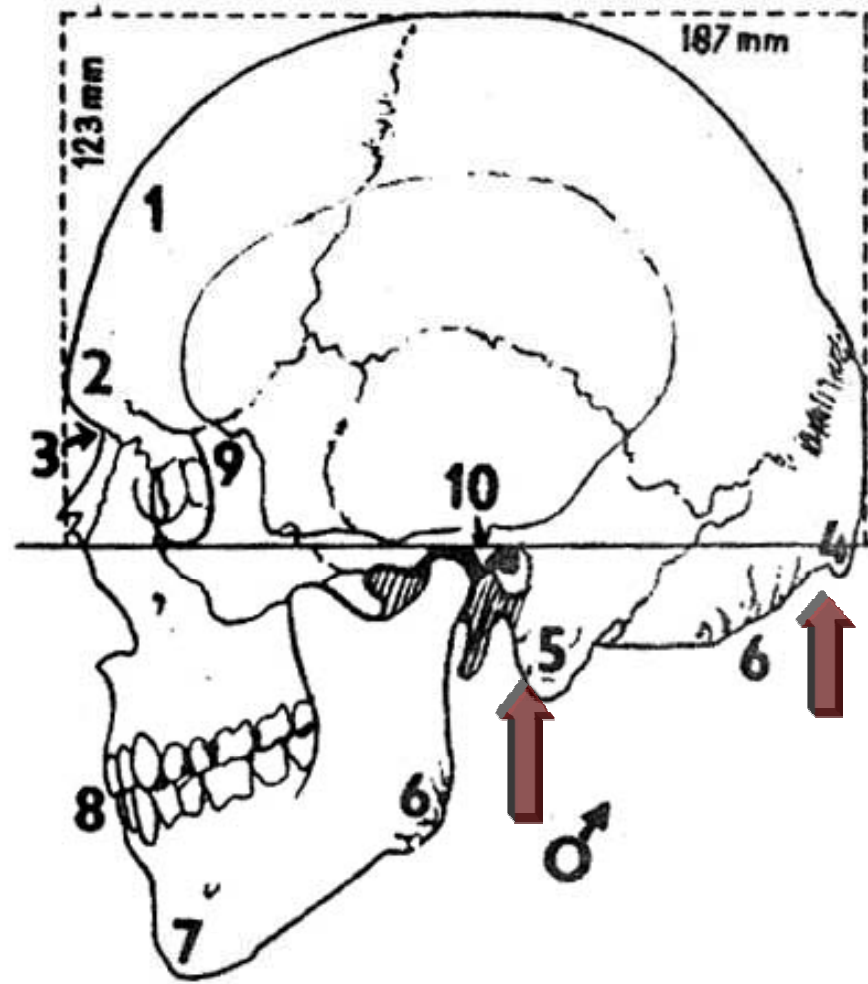


Pronounced
Muscle
Attachments

Large
Canines

Square Chin

Round Chin



Určování "rasy"

Určování výšky postavy

Odhad věku

Subadultní odhad věku:



Erupce zubů



Uzavírání epifyzárních štěrbin



**Délka dlouhých kostí bez
epifýz**

Adultní odhad věku:



Symfýza kosti stydké



Rentgenové snímky



Sternální konec klíční kosti

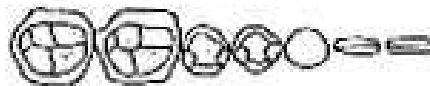
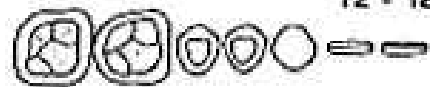
Lebeční švy

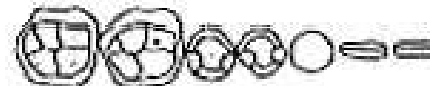

Abráze zubních korunek

A 12 - 18



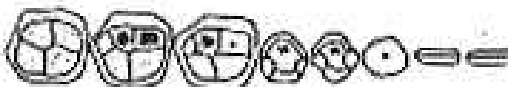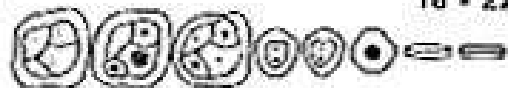B₁ 16 - 20



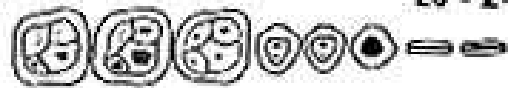
B₂ 16 - 20



C 18 - 22



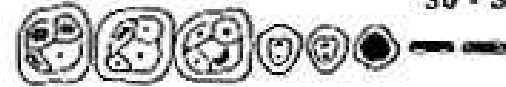
D 20 - 24



E 24 - 30



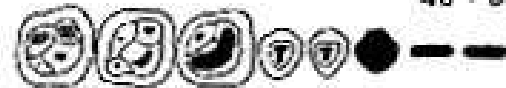F 30 - 35



G 35 - 40



H 40 - 50



I 45 - 55





Výbrusy zubů



Zkracování telomer

Nevýhody "klasické" antropologie



Velká variabilita



*Neschopnost identifikovat
fragment. kost. nálezy*



Velká subjektivita