

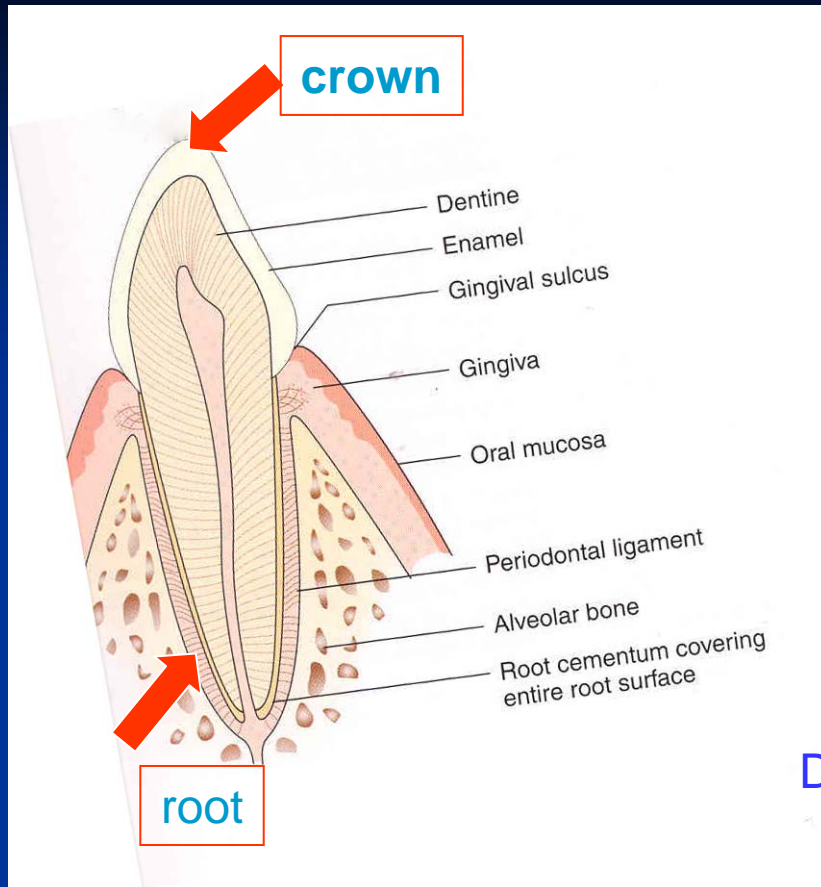
Periodontology

Periodontology

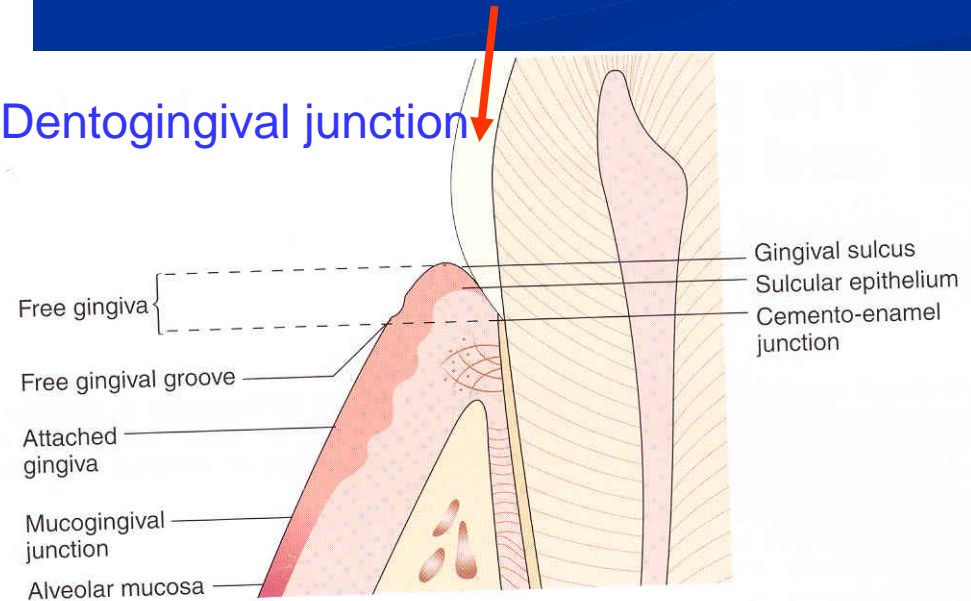
- Periodontal tissues
 - alveolar bone
 - cementum
 - periodontal ligament
 - gingiva

Morphology

Supportive tissues



Dentogingival junction



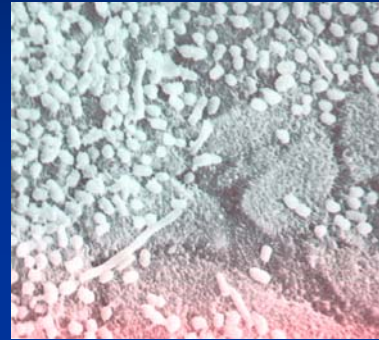
Periodontal diseases

- Inflammation at most!!!!
- The most important ethiological factor?

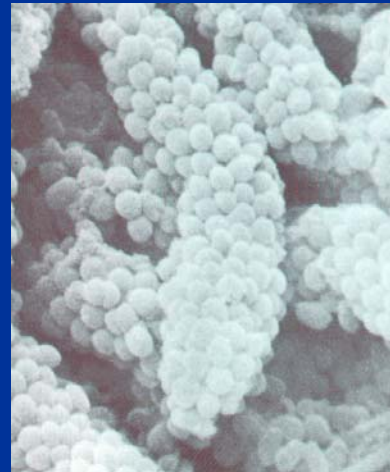
 **Dental plaque!!!!** 
BIOFILM

Biofilm

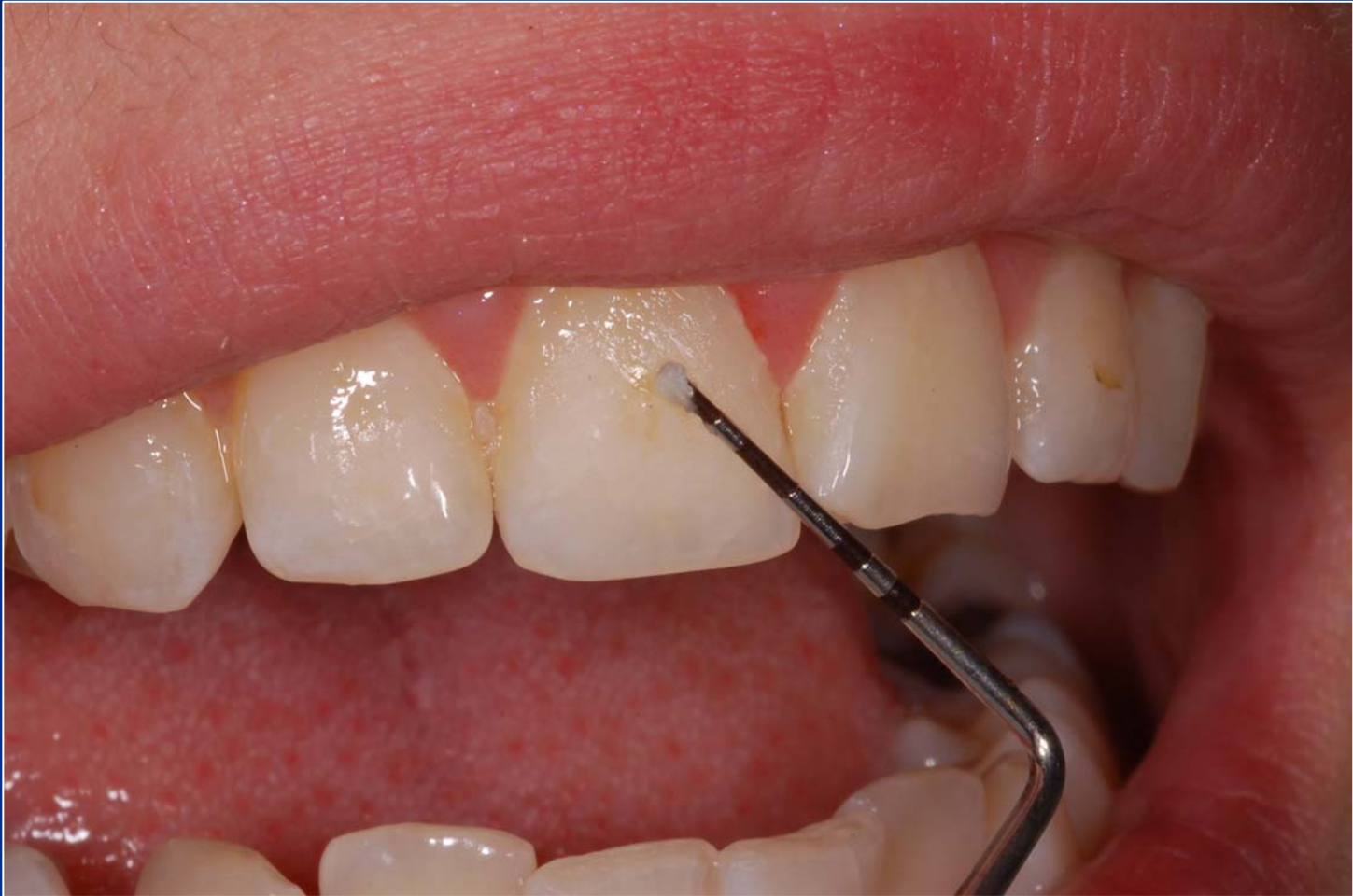- Adherence



- Colonisation

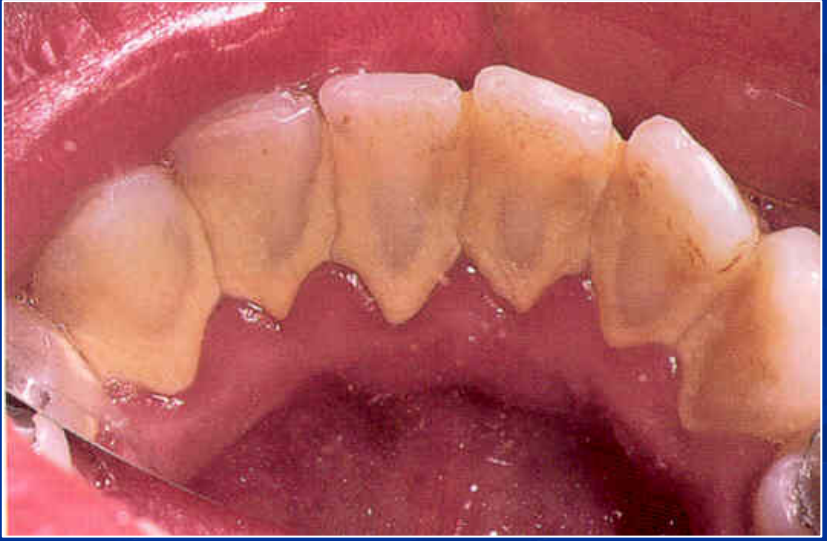
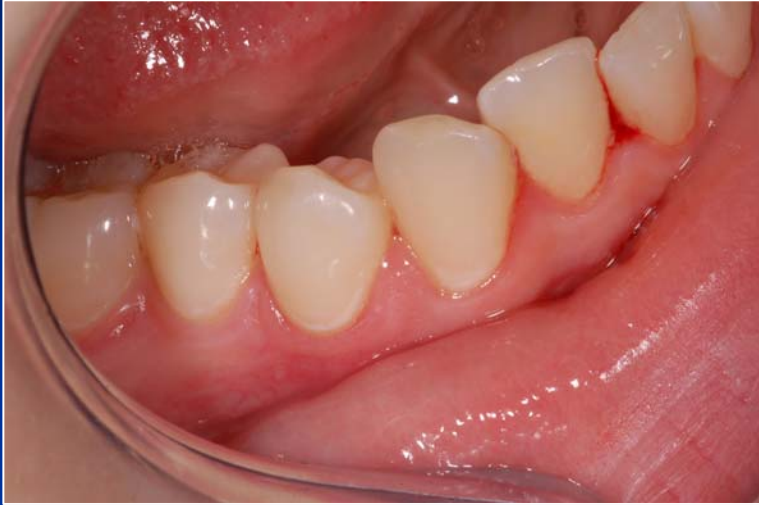
- Maturation



Other aethiological factors

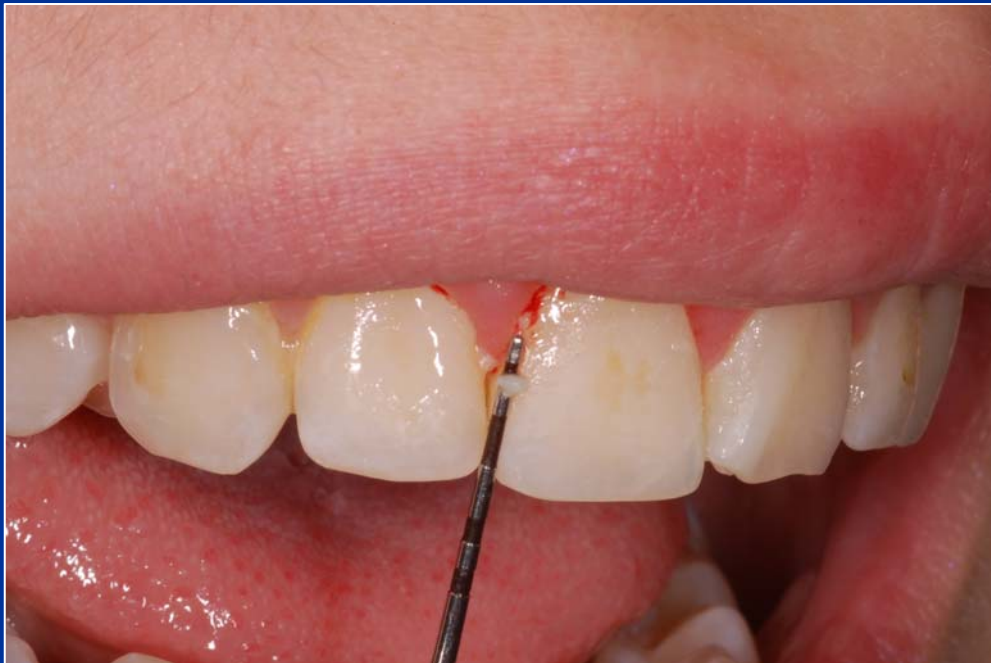- Calcified deposit on teeth, plaque on the surface
- Overhangs, crowns, dentures
- Genetic factors – gen polymorphism



Parodontopathies

Gingivitis

■ Plaque associated gingivitis



Chronic form

Erythema

No pain

Easy bleeding

Plaque on the tooth

Acute form

Erythema

Pain

Easy bleeding

Plaque on the
tooth

Acute necrotisans gingivitis - ANUG

- Necrotizing ulcerative gingivitis

Aetiology

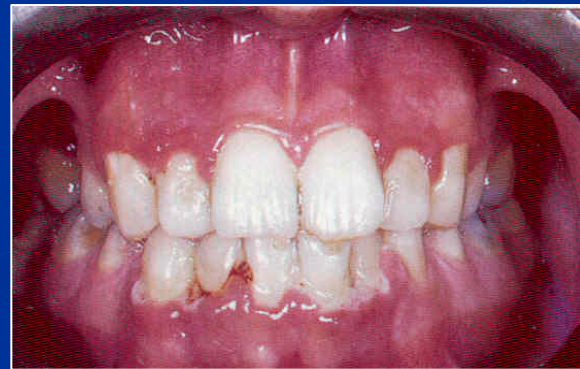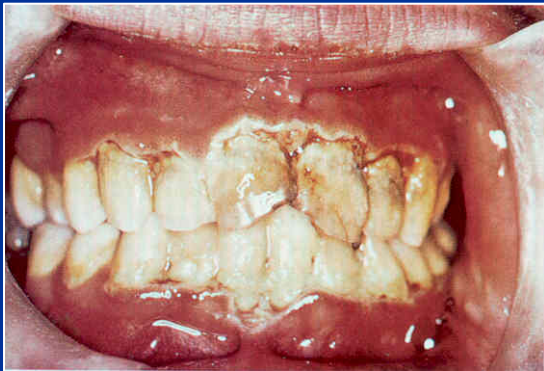Special microbes - anaerobs

The clinical picture

- Gingival inflammation and destruction



Severe pain, bleeding gums, halitosis



Diferential diagnosis

- Herpetic gingivostomatitis
 - Young people
 - Prodroms
 - Pyrexia
 - Lymphadenopathy
 - Lesions more widespread and diffuse

Diferential diagnosis

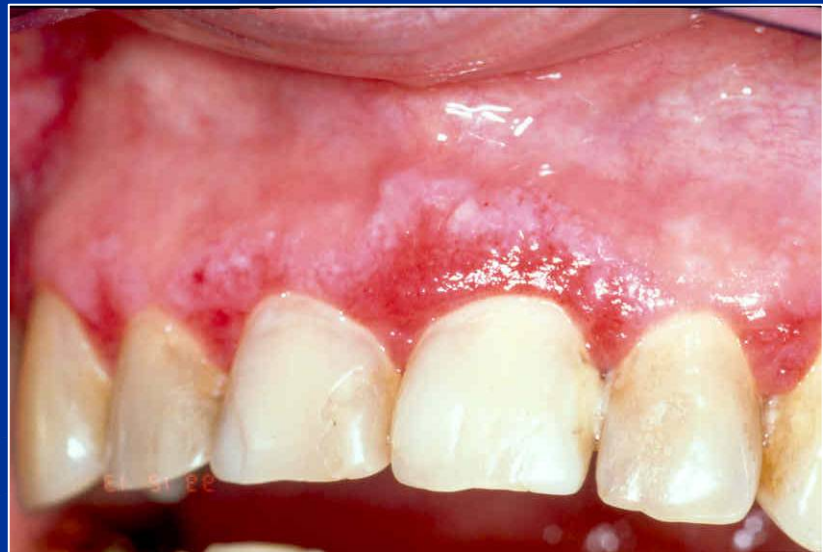- If ANUG does not tend to recover in 10 days – check the blood picture!



Atrophic or desquamative gingivitis

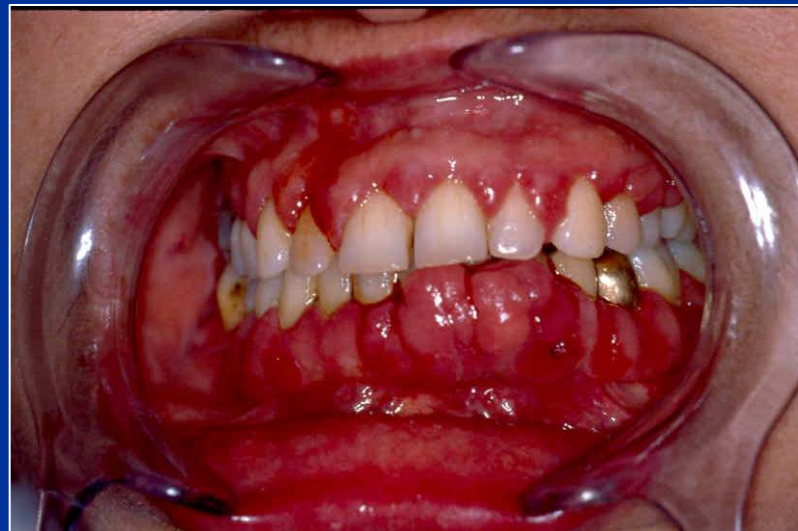
symptoms

- Erythema on free gingiva – loss of the epithelium
- Variety of symptoms: itching, tenderness of eating, burning.



Hyperplastic gingivitis

- High standard of oral hygiene must be achieved!
- Gingivectomy (drugs induced)



Parodontopathies

Periodontitis

- Chronic periodontitis.
- Aggressive periodontitis.
- Periodontitis as a manifestation of systemic disease.
- Necrotizing periodontal diseases.
- Abscesses of the periodontium.
- Periodontitis associated with endodontic lesions.
- Development or acquired deformities and conditions.

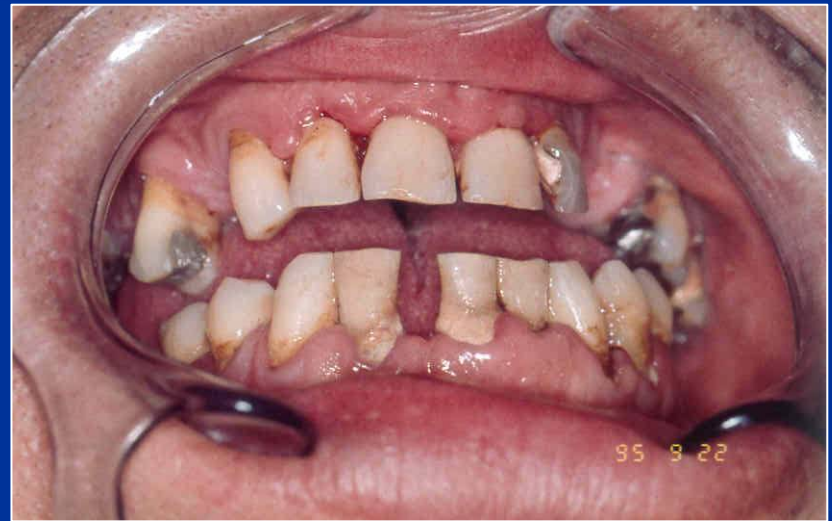Parodontopathies

Periodontitis

- Chronic periodontitis.
- Aggressive periodontitis.
- Periodontitis as a manifestation of systemic disease.
- Necrotizing periodontal diseases.
- Abscesses of the periodontium.
- Periodontitis associated with endodontic lesions.
- Development or acquired deformities and conditions.

Periodontitis

- Gingivitis
- Pocketing
- Loss of alveolar bone
- Drifting and mobility
- Furcation exposures
- Recession

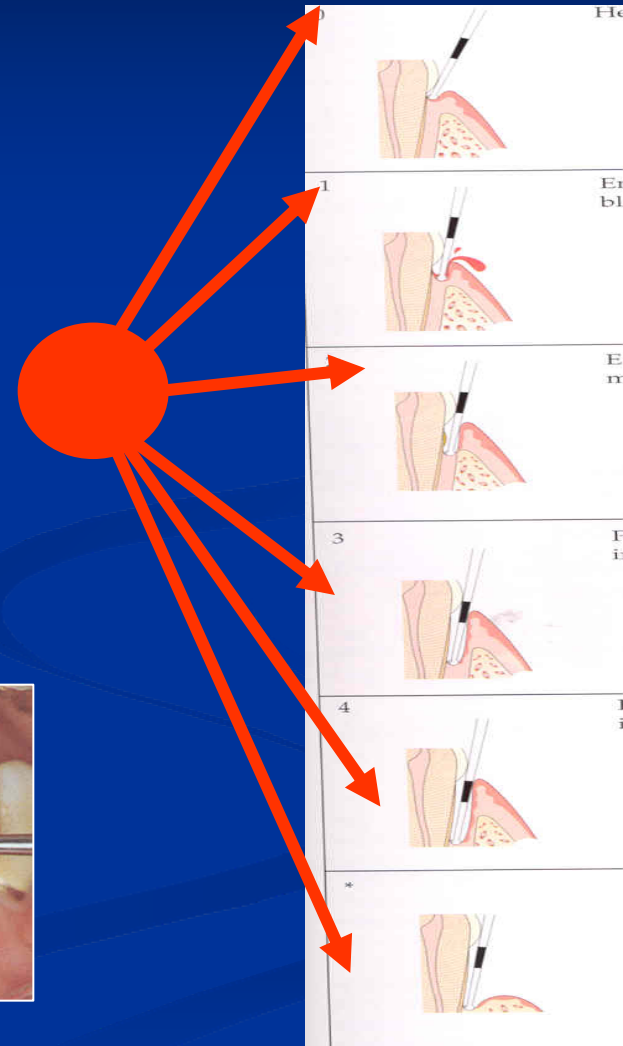
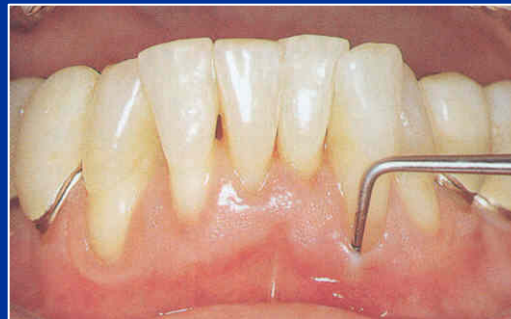

Periodontitis

- Gingivitis
- Pocketing
- Loss of alveolar bone
- Drifting and mobility
- Furcation exposures
- Recession

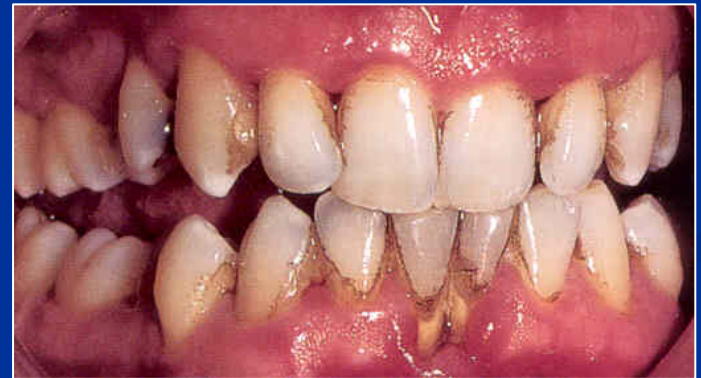Periodontitis

- Gingivitis
- Pocketing
- Loss of alveolar bone
- Drifting and mobility
- Furcation exposures
- Recession



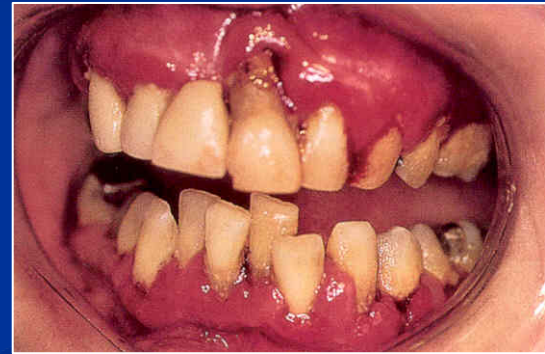
Periodontitis

- Gingivitis
- Pocketing
- Loss of alveolar bone
- Drifting and mobility
- Furcation exposures
- Recession



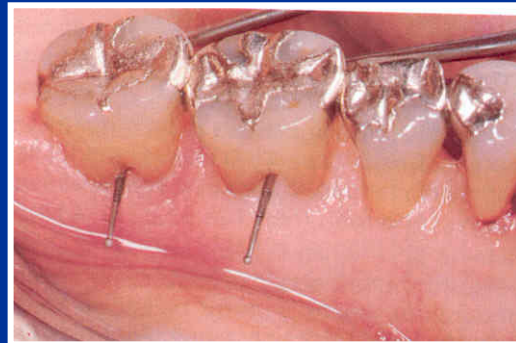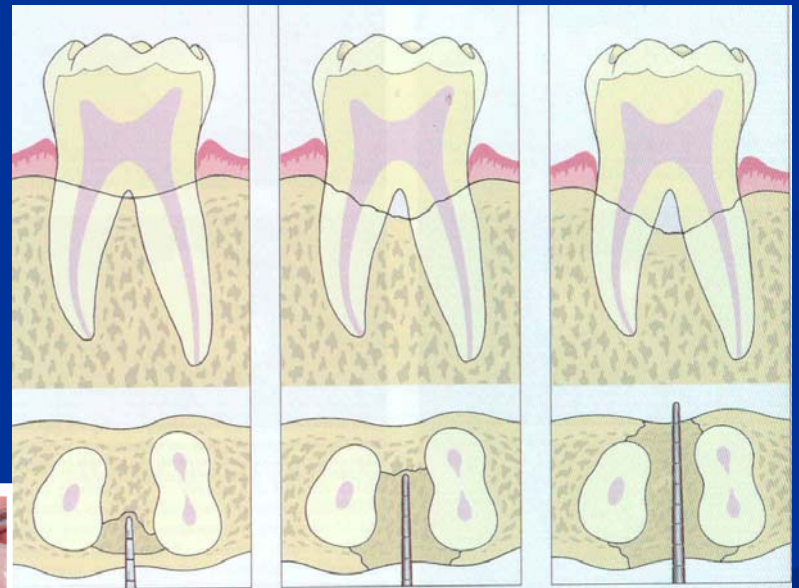

Periodontitis

- Gingivitis
- Pocketing
- Loss of alveolar bone
- Drifting and mobility
- Furcation exposures
- Recession



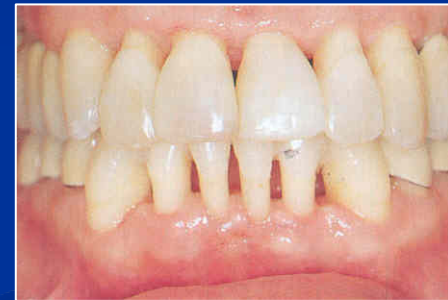Periodontitis

- Gingivitis
- Pocketing
- Loss of alveolar bone
- Drifting and mobility
- Furcation exposures
- Recession



Periodontitis

- Gingivitis
- Pocketing
- Loss of alveolar bone
- Drifting and mobility
- Furcation exposures
- Recession




Periodontitis

- Chronic adult periodontitis
- Aggressive periodontitis
- Early onset periodontitis

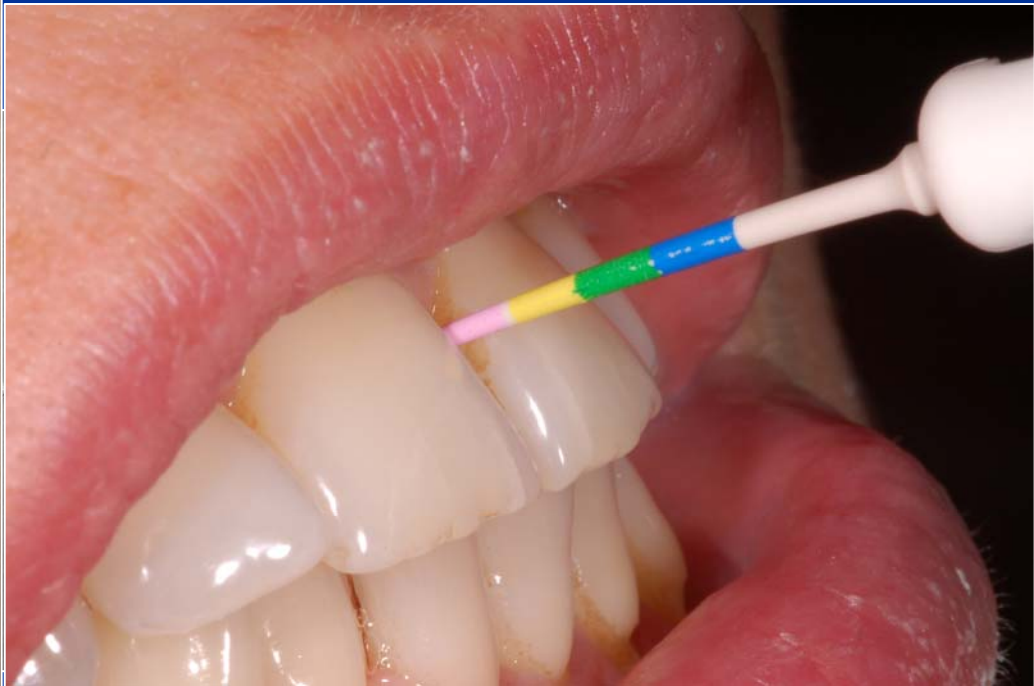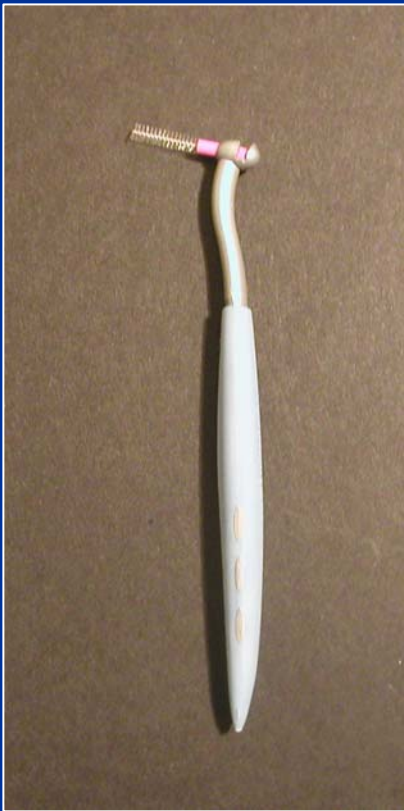Therapy

- 1. Oral hygiene - professional, home care
INDIVIDUAL





Therapy

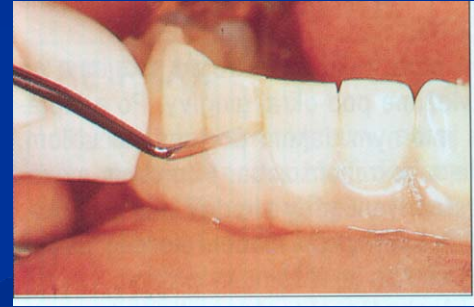
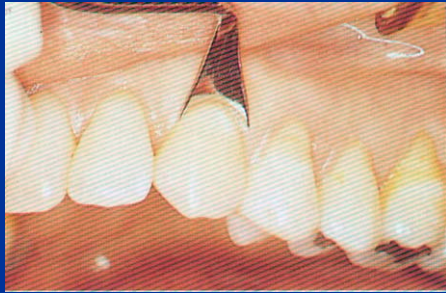
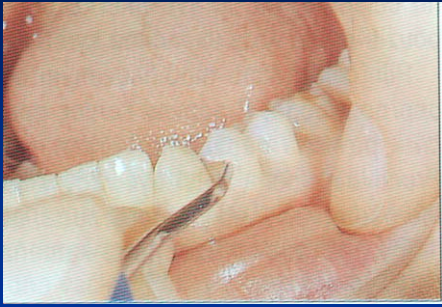- 1. Oral hygiene - professional, home care
INDIVIDUAL

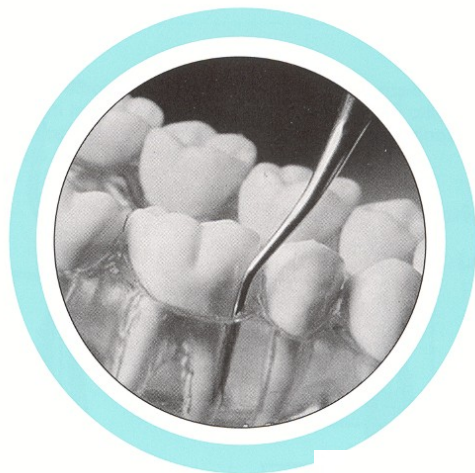
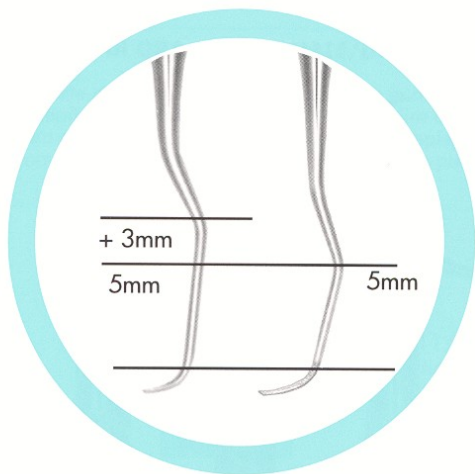
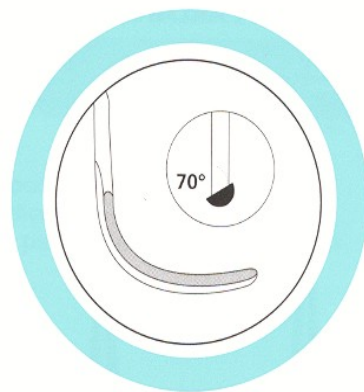
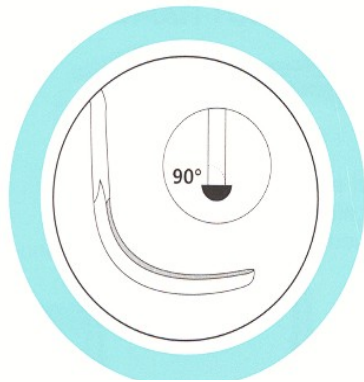


Therapy

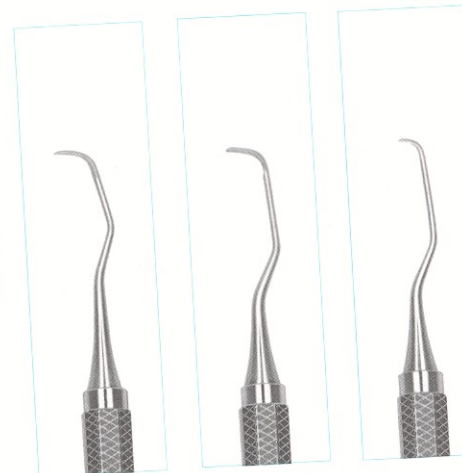
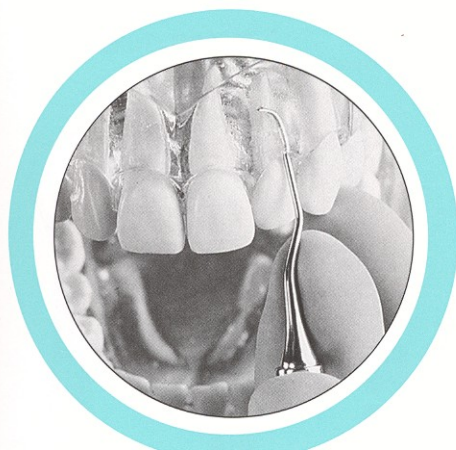
- 1. Oral hygiene - professional, home care
INDIVIDUAL

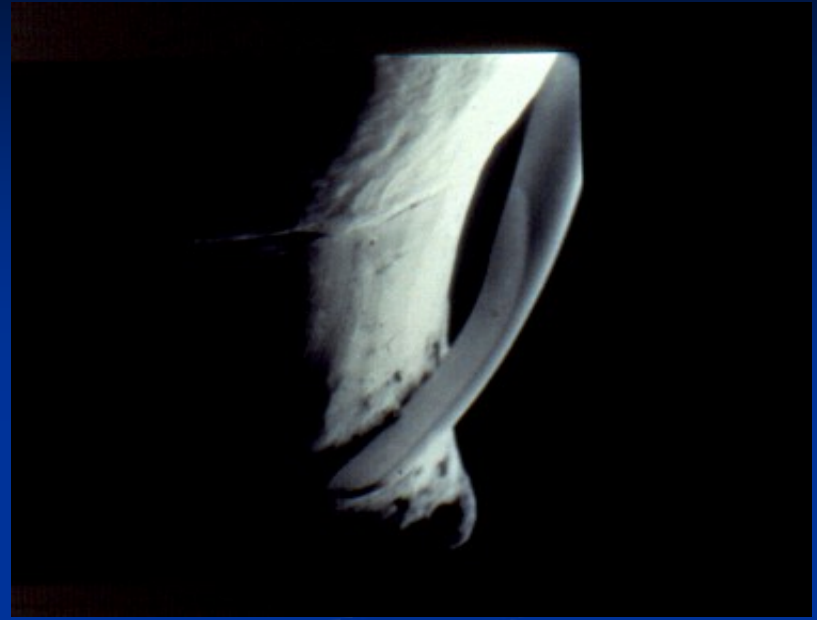
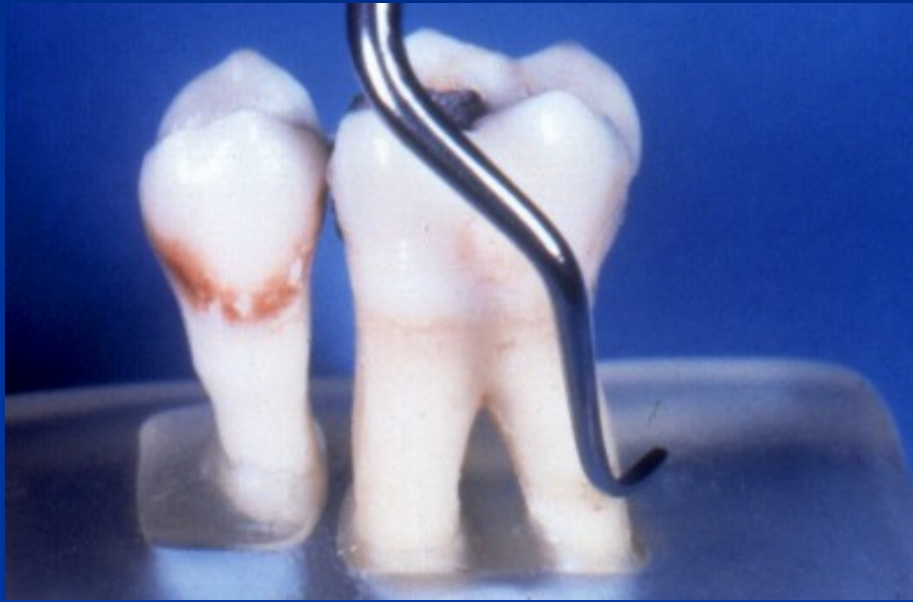


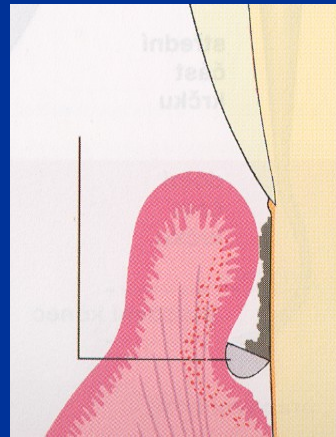
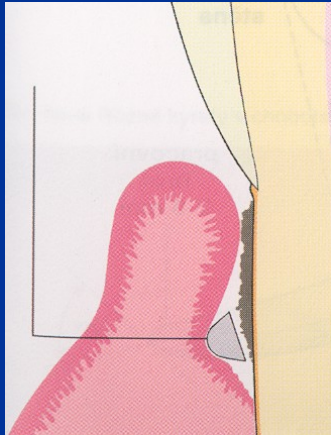


Možnosti kyret



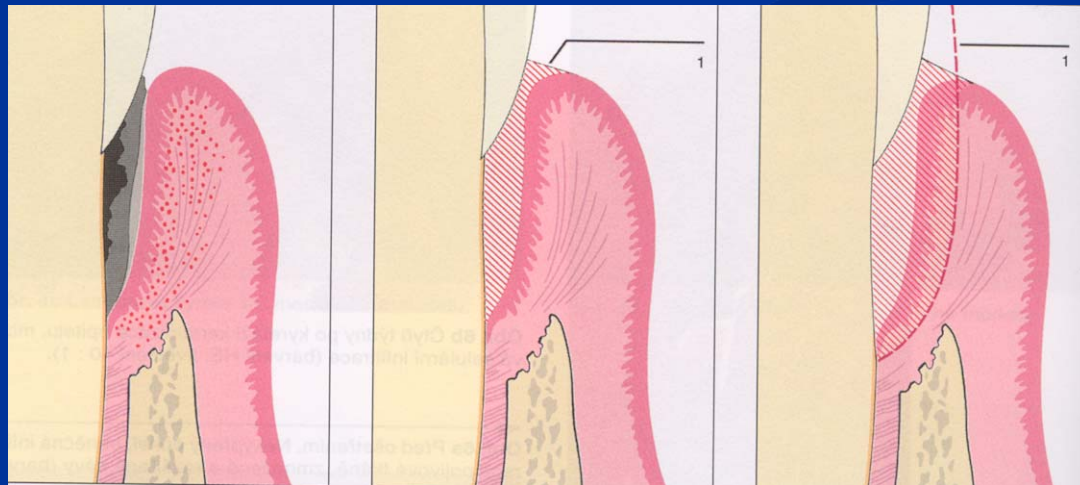



Scaling, root planning



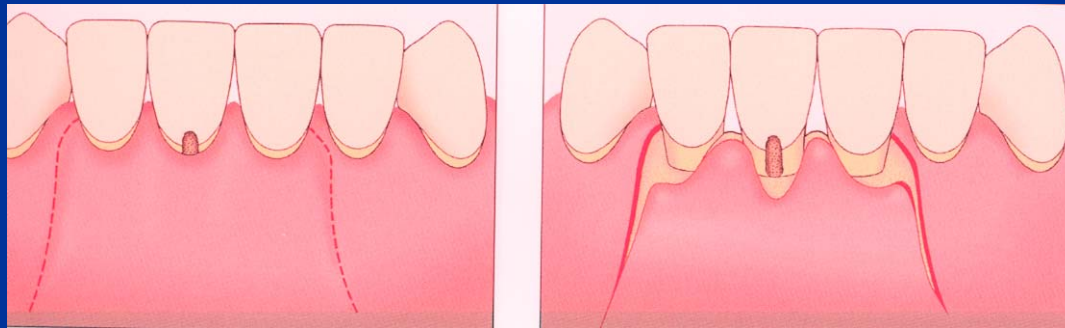
Therapy

- 2. Subgingival treatment – scaling root planing, curettage



Therapy

- 3. Periodontal surgery



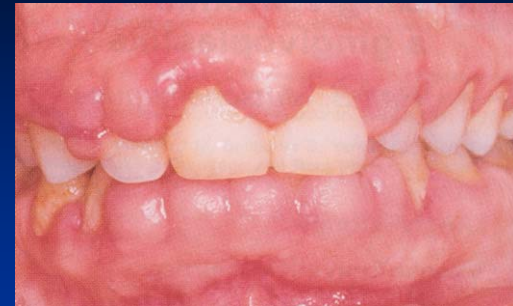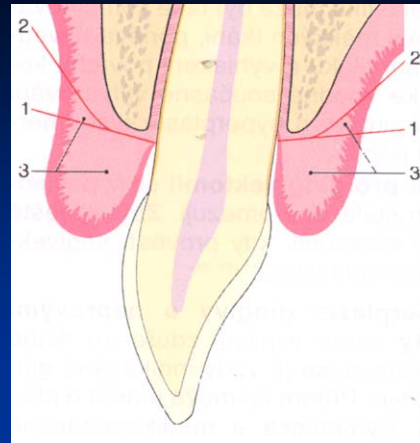
Gingivectomy, gingivoplasty

Principle:

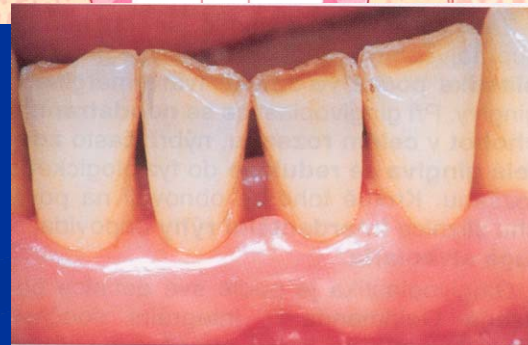
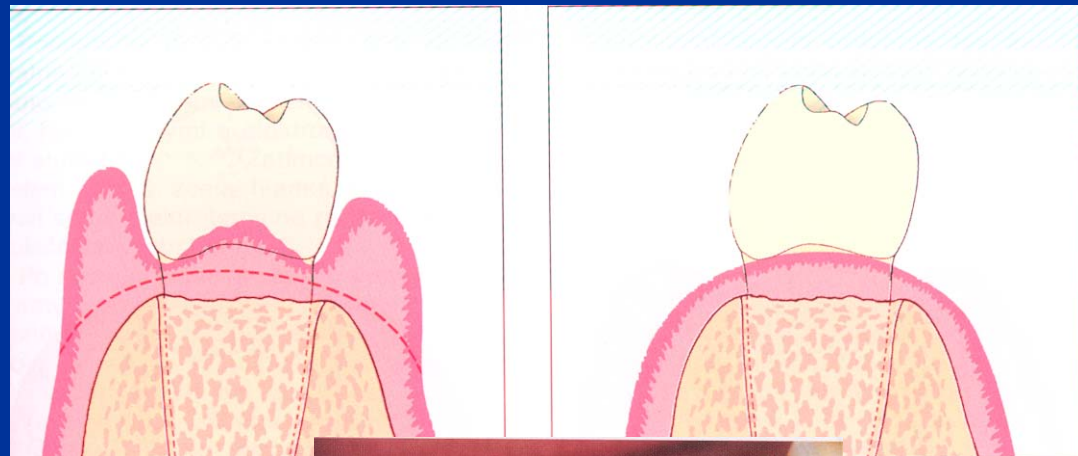
Removal of hyperplastic (overgrowing) gingiva

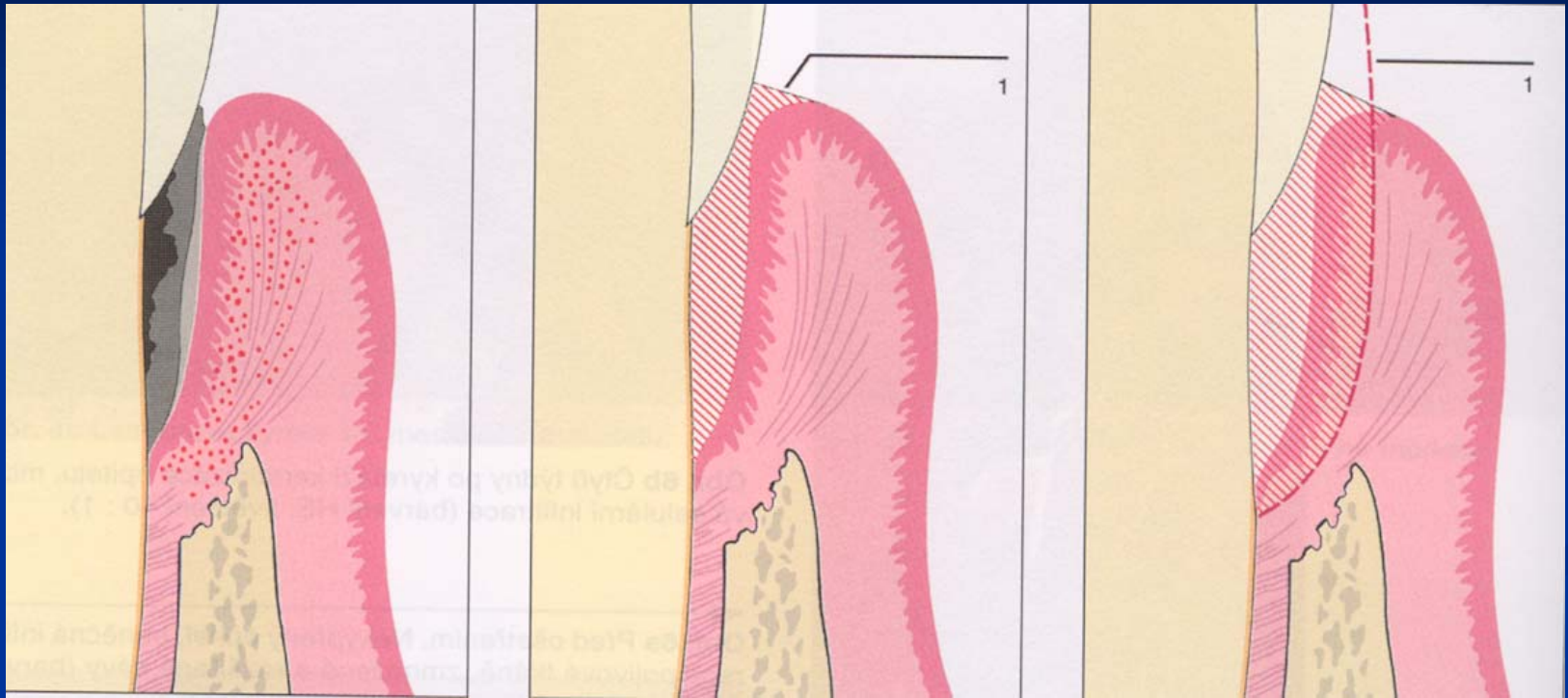
Improving of configuration of gingiva

Gingivectomy



Gingivoplasty





Closed curettage

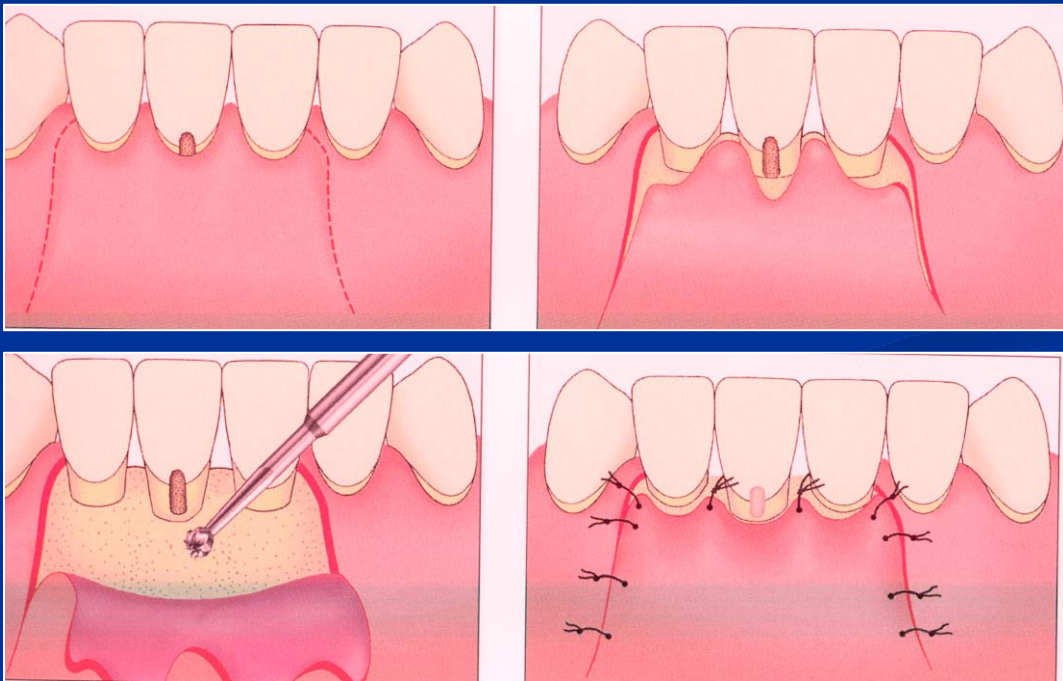
Flap operation

Principle:

Raising of the flap (mucosa and periost together),
cleaning of pockets, osteoplasty, regeneration).

Apical flap

Replaced flap



Mucogingival surgery

- Enlargement of attached gingiva
 - Frenulectomy
 - Vestibuloplastic

The principle is removal of fibrous tissues which are pulling the gingiva out during eating, speaking etc.

- Plastic of recessus

The principle is to cover the denudated dental necks with gingiva using flap or graft.