

Preclinical dentistry - Endodontics

Morphology:

Dental pulp, pulp chamber, root canal.

Endodont is a complex of dentin and dental pulp

It is morphological and functional unit.

Healing potential of dental pulp:

Tertiary (reparative dentin) – produced by odontoblasts as reaction on irritation (dental caries)

Dentinal sclerosis – intratubular dentin

Dentin bridge – new dentin formation when dental pulp is exposed (perforation due to preparation or trauma).

Vital methods – methods keeping the dental pulp vital:

Direct pulp capping
Indirect pulp capping
Pulpotomy
Importance of calcium hydroxide

Endodontic treatment
Diagnosis (patient)s history, inspection,
percussion, r"thermal rraction, x- ray)
Treatment
Access to the pulp chamber
Opening of root canals
Root canal shaping
Root canal celaning
Rootcanal filling
Final control – x- ray
Postendodontic treatment

Diseases of dental pulp and apical periodontal tissues

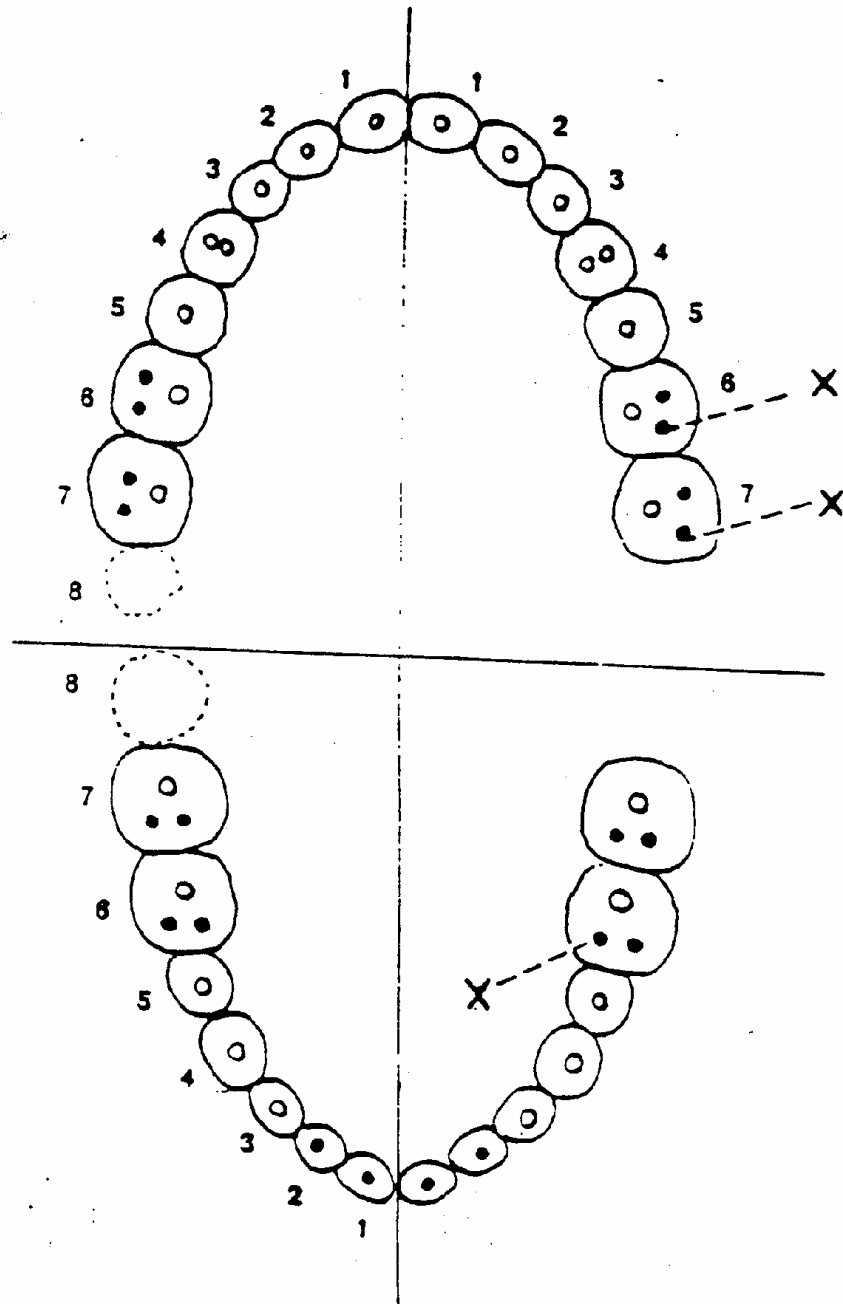
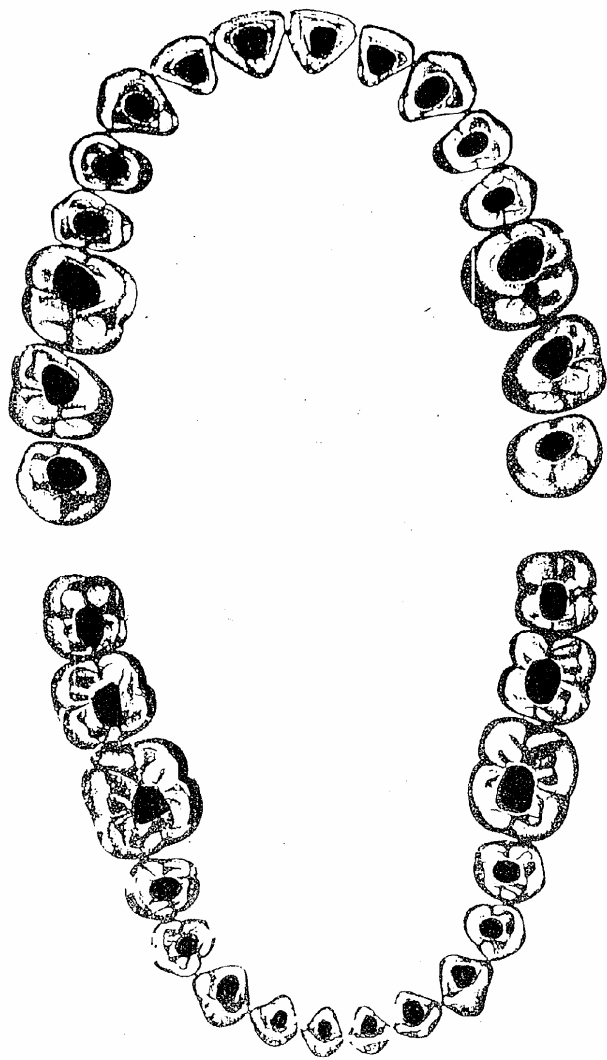
Pulpitis – reversible (dental pulp can be kept vital)

- irreversible (dental pulp must be removed and the rct must be done)

Necrosis – dental pulp is non vital

Gangraena – dental pulp is non vital, infected

Periodontitis – the apical part of periodontal ligament is affected (chronic, acute)



Stav po trepanaci dřevné dutiny a rozšíření vchodu

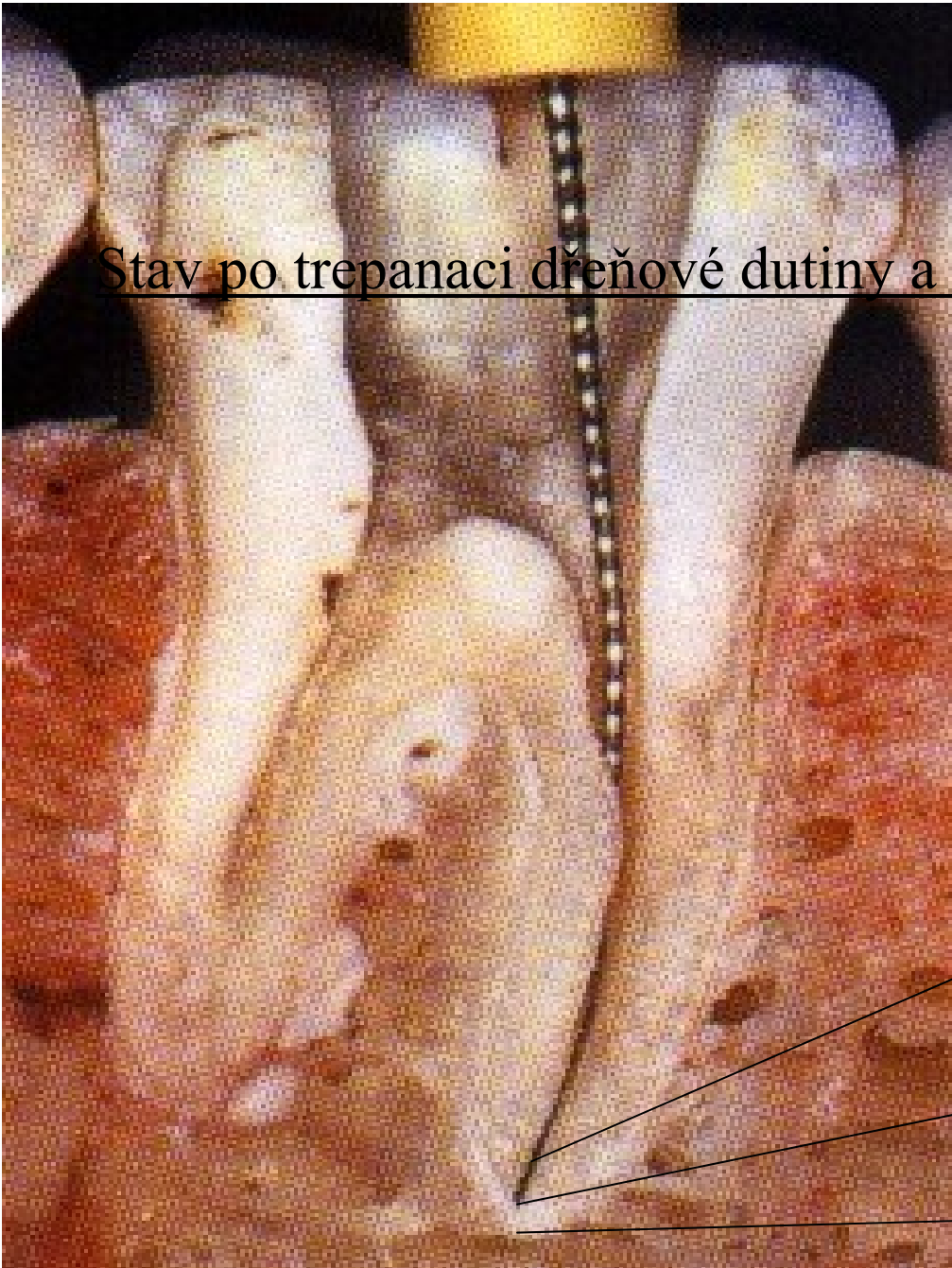
Correct access

And apical morphology:

Apical constriction

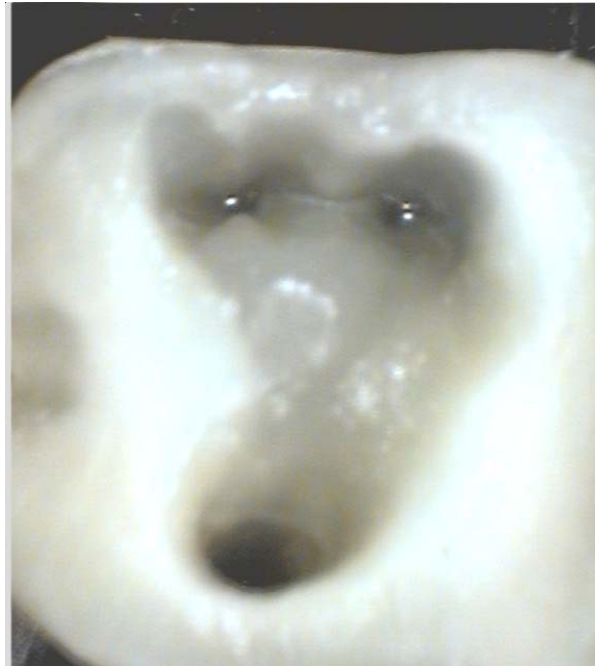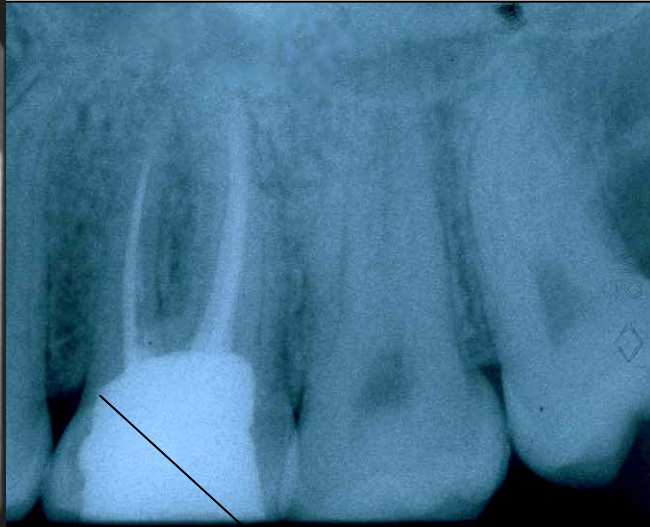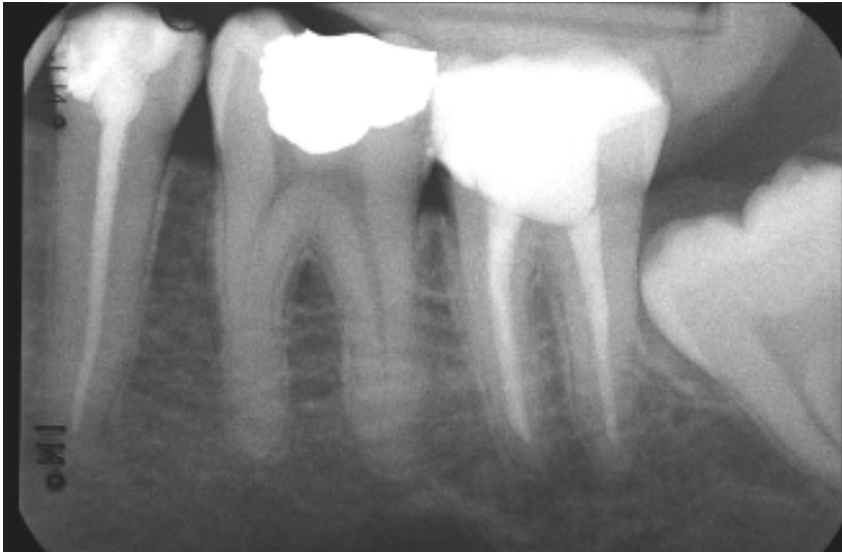Apical foramen

Apex



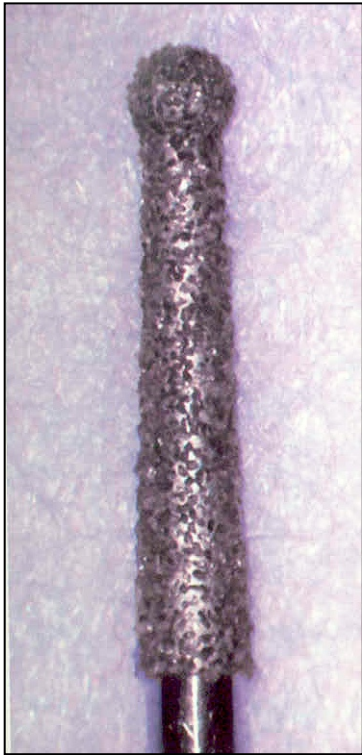
Access

- Prepare cavity on occlusal or oral surface
- Open the pulp chamber
- Find the root canals
- Do the root canal shaping, cleaning
- Filling.

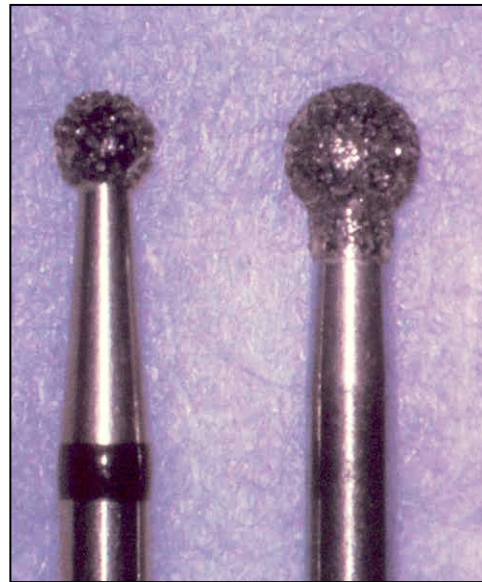

The wall is too thin

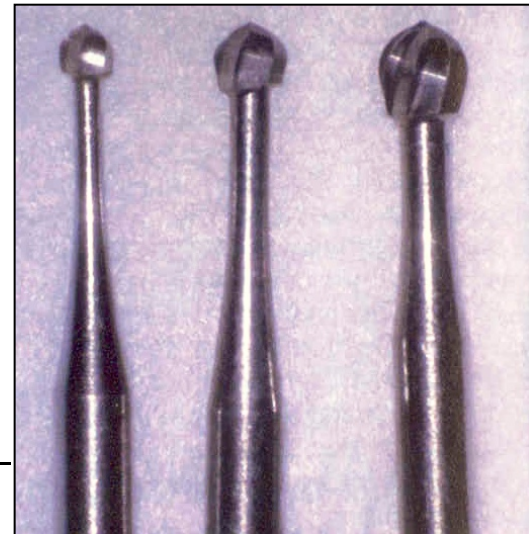Opening of the pulp chamber




Dia trepan



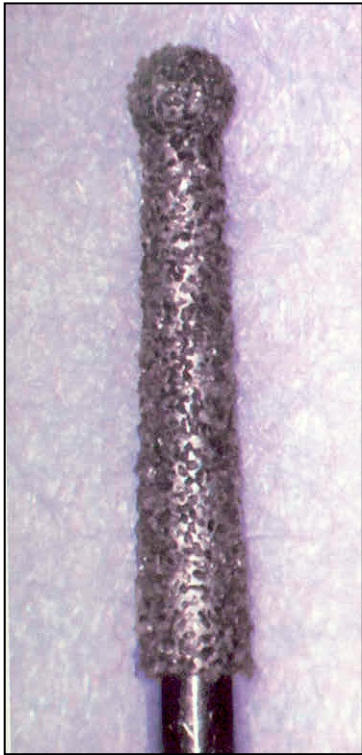
Dia round burs —
balls



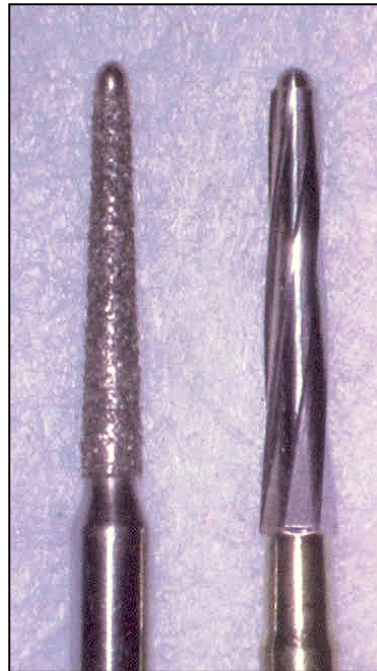Steel round burs



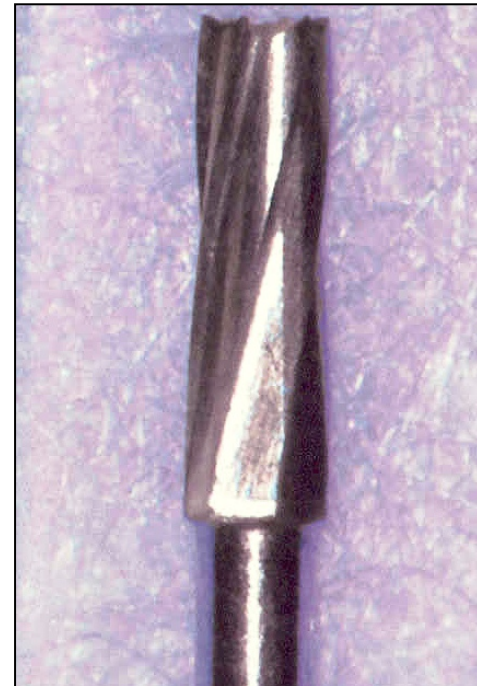Removal of the roof of the pulp chamber



Dia trepan

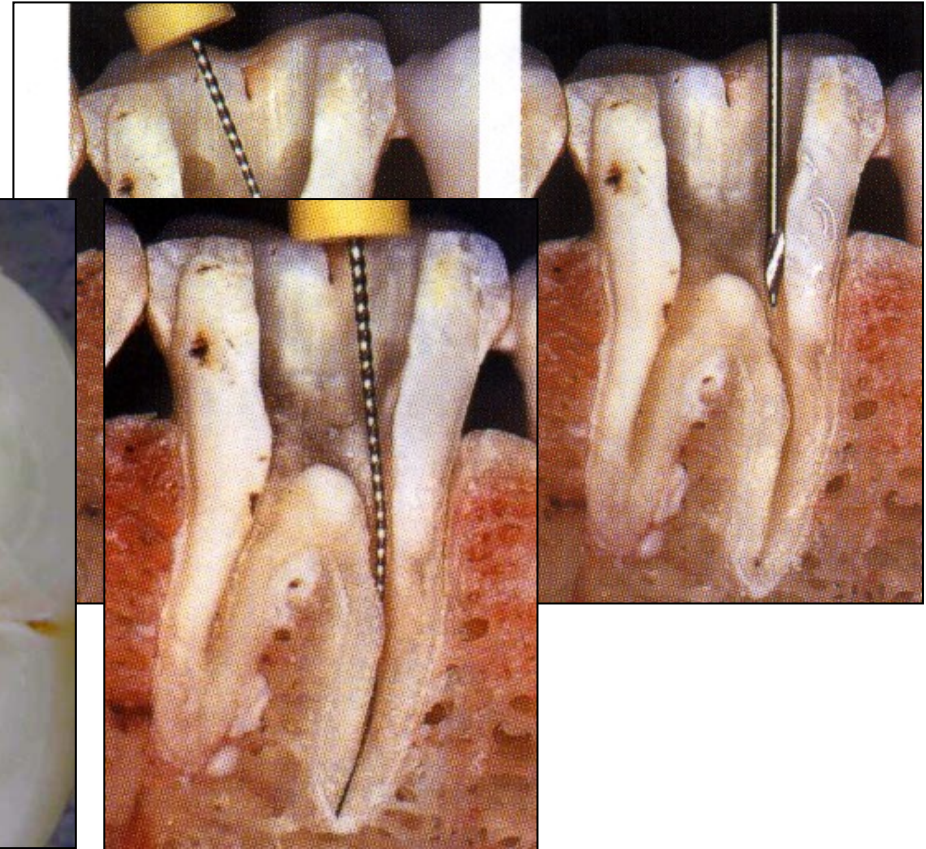
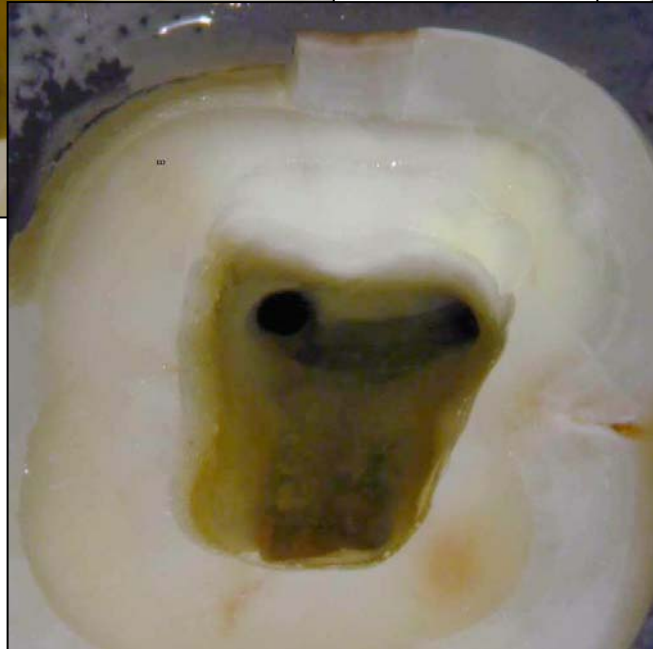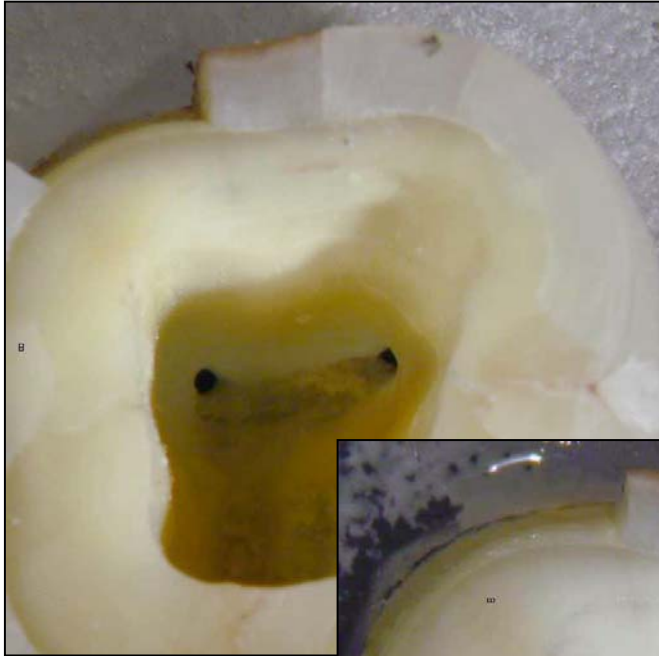


Safe ended tips
Batt's instruments

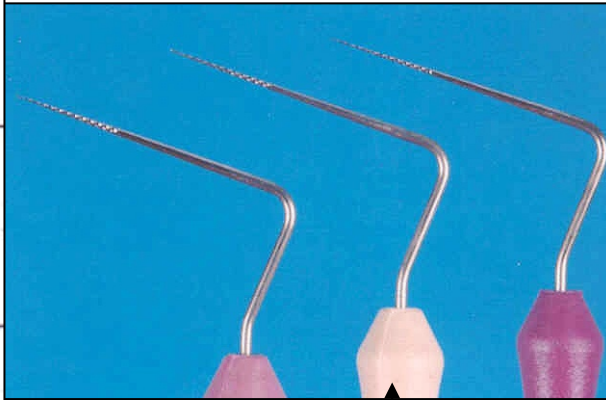



Fissur bur

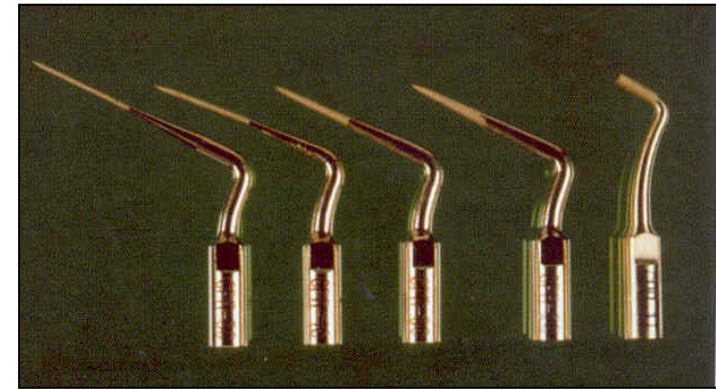
Finding of the root canal orifice



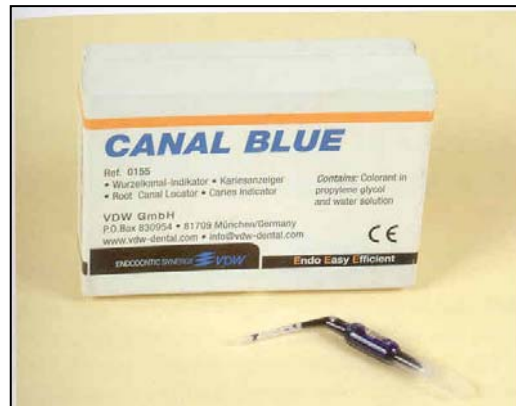Finding and opening of rot canal orifices



Endodontic probes
Microopeners

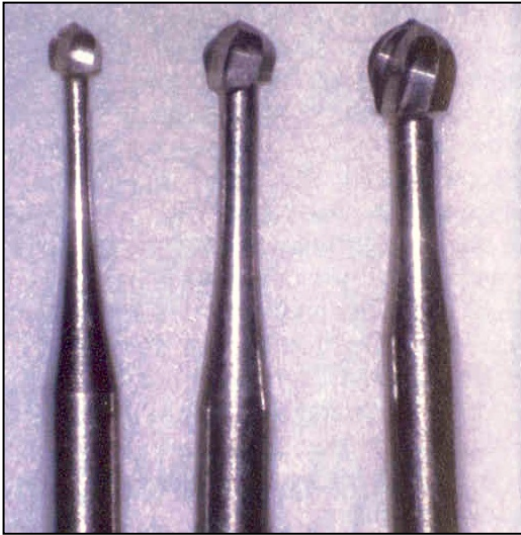


Ultrasound tips

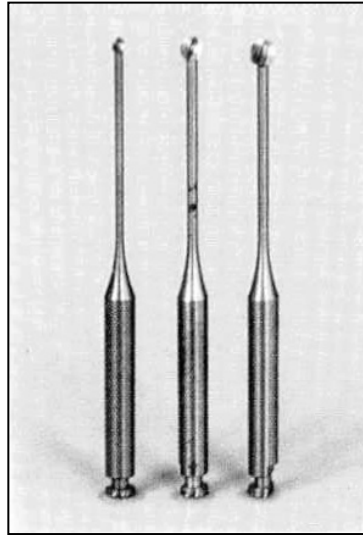


Dye

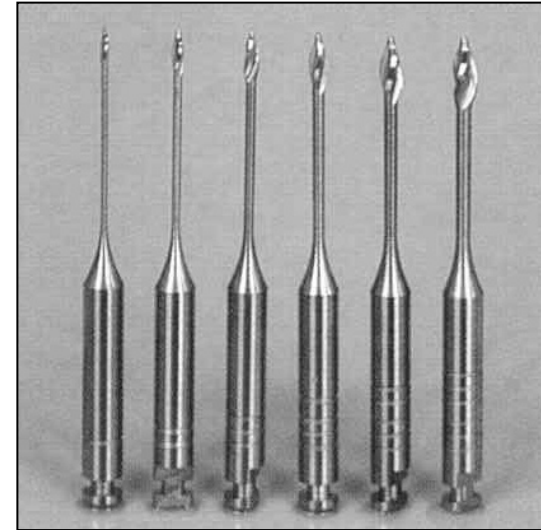
Finding and opening of root canal orifices



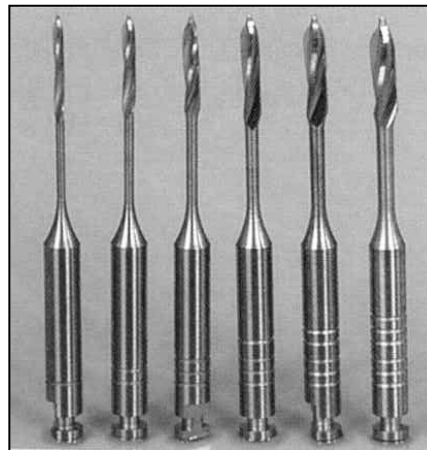
Rounded burs - balls



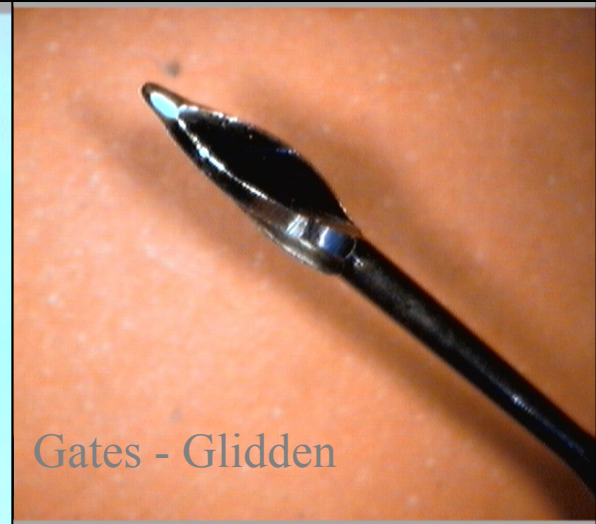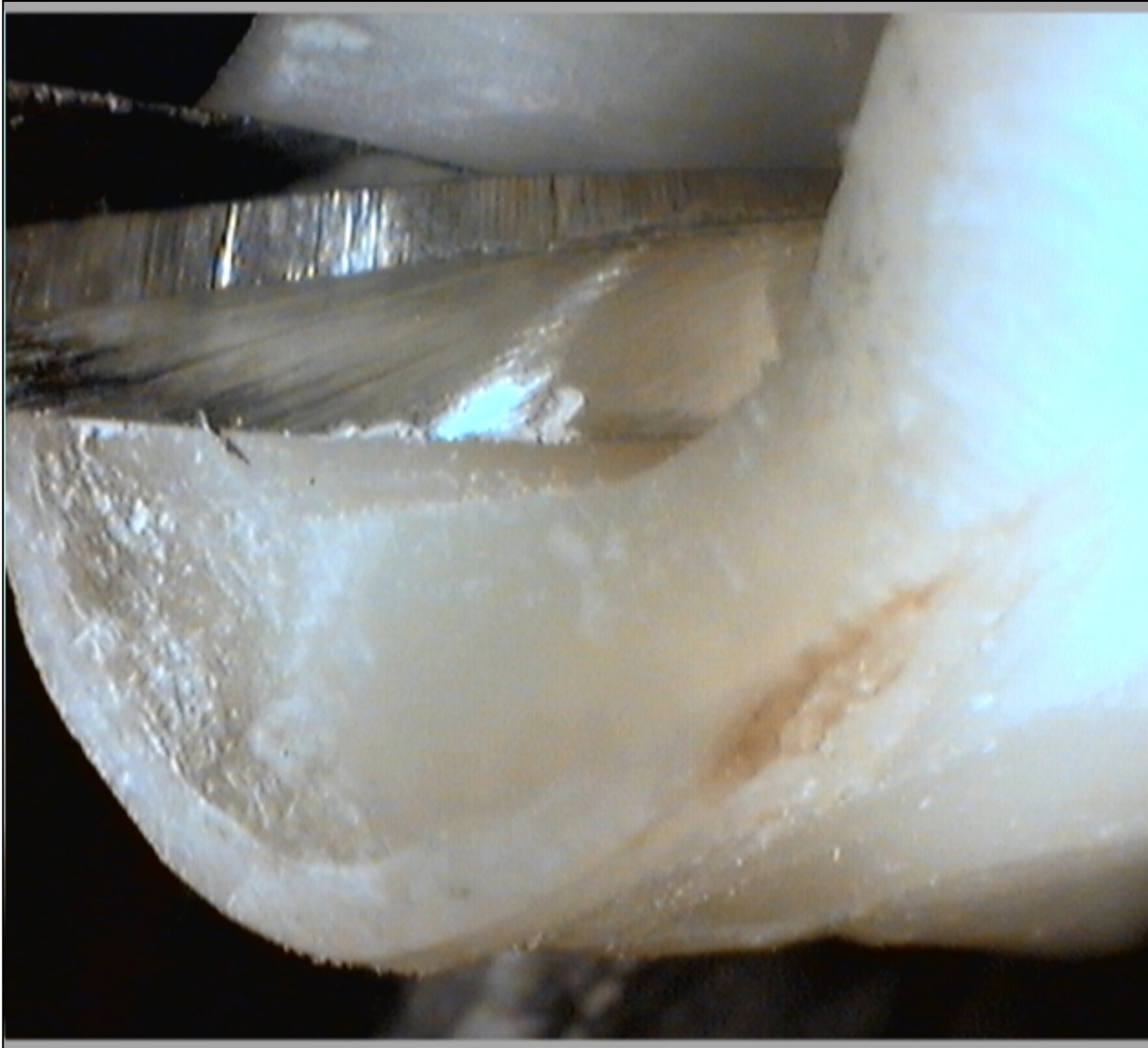Miller's burs

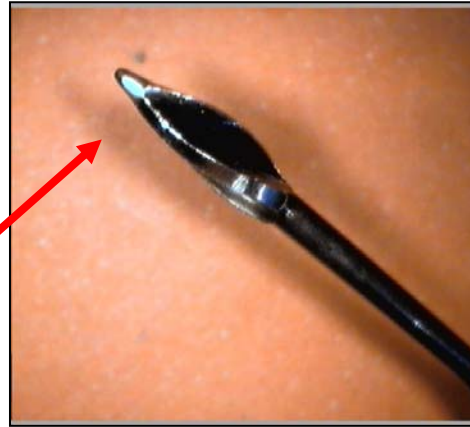


Gates Glidden's burs

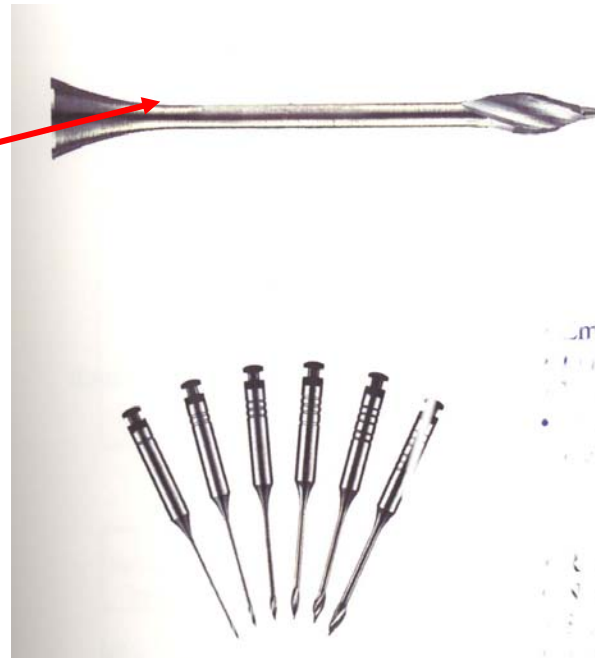


Peeso - Largo

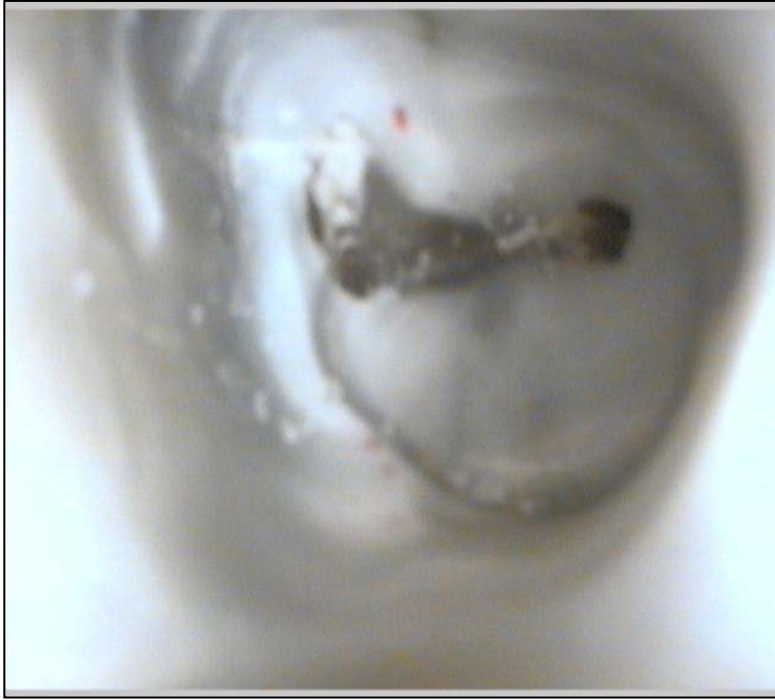



Gates – Glidden:
Blunt, non active tip

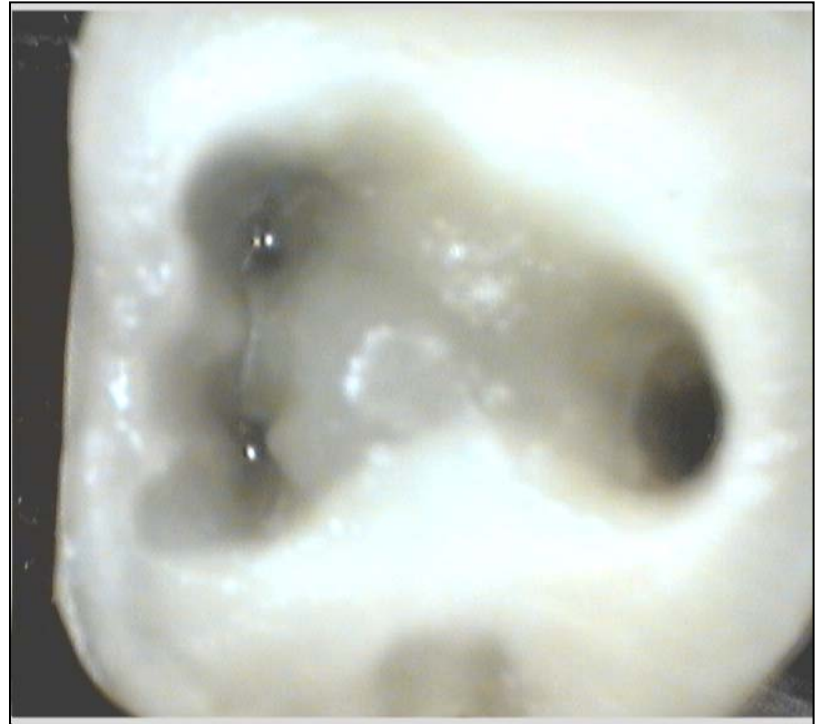


Programm point of breakage




Bad

Correct



Removal dental pulp from the root canal


Pulpextractor



*Removal of soft content
– pulp, cotton, paper point*

Wider canals only!!!

*Risks: breakage of the instrument
Breaking of spurs and their pushing out*



Canal shaping


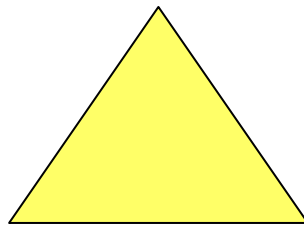
- Reamers (penetration)
- Files (enlargement)

Reamer


K -reamer

Triangl or square wire spun

Symbol



Reamer




Bladed part

Shank

Stopper

Grip



Blades


Space for dentin chips

Reamer

Blades

Space for dentin chips

Rotation – reaming action - penetration



Reamer


Rotation (clockwise) – penetration

**Application of plastic material
(counterclockwise)**

K file

Wire trianagl or square

Symbol is always square




K-file

Filing


Also rotation

45° – 90°



K-flexofile, flexicut, flex-R

- Triangle wire always



Flexibility

K- flexofile a flex – R file: non cutting tip
and first blades are blunt

Like K-file



K-file x reamer



H-file

= Hedstroem file

Ring





H- file

No rotation!!

Pull motion only!!

Risk of breakage in small sizes



ISO

- Diameter of the tip
- Length of the cutting part
- Taper



ISO norma

06

08

10

20

25

30

35

50


55

60

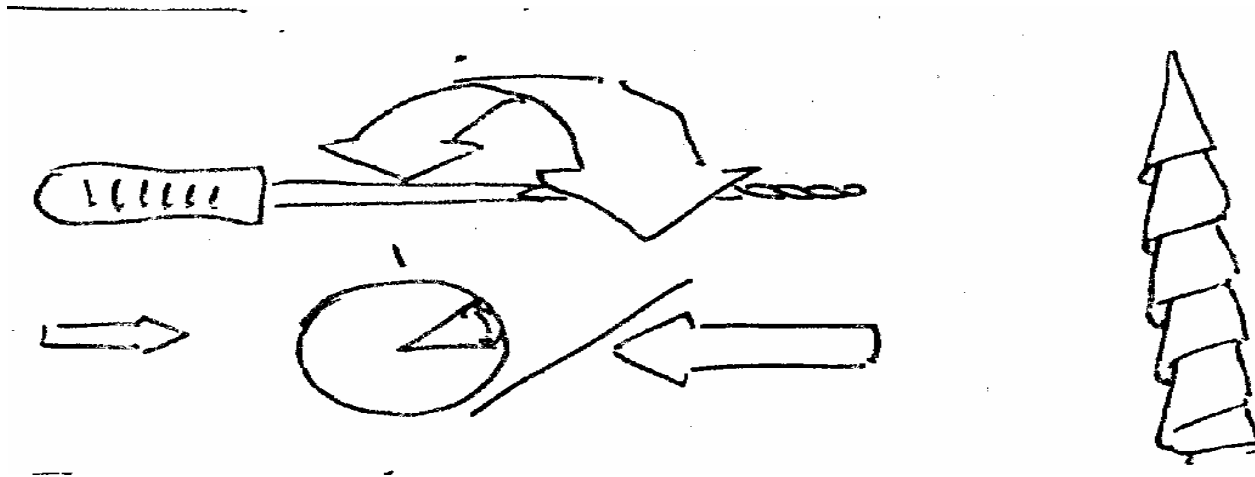
70

Root canal shaping


Reaming action



Filing – circumferential filing

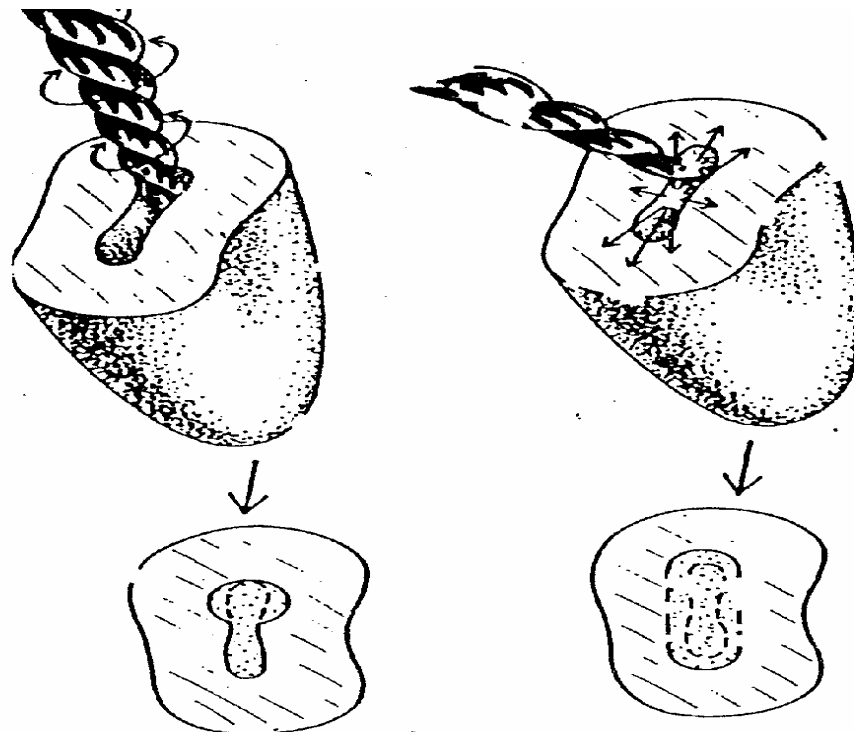


Balanced force technique

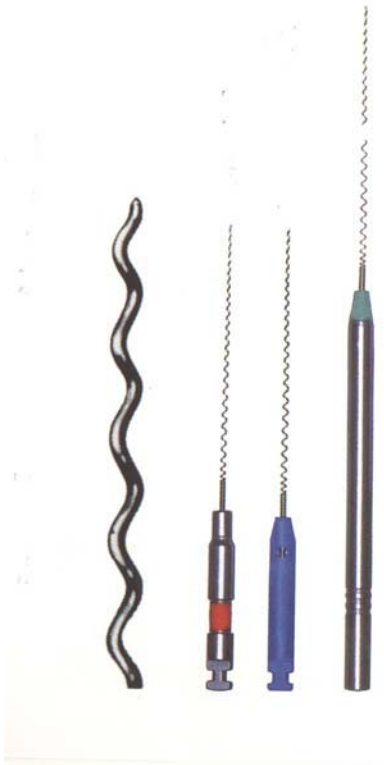


Without any pressure in – rotation 90° (lze i 180°) clockwise
 $180 - 270^\circ$ contraclockwise – slightly press forward
Clockwise and out

Efekt rotace a cirkumferentního pilování




Lentulo – paste carrier



- delivers pastes
- 1,5 – 2 mm ahead
- at most for $\text{Ca}(\text{OH})_2$

Compactors

Spreader



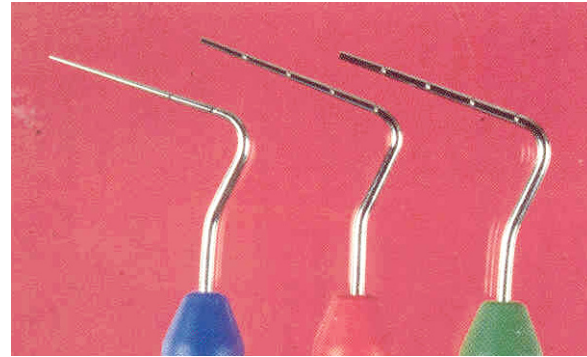Pointed

Vertical introduction

Lateral condensation
technique ↓

Compactors

Plugger



Not pointed


Vertical introduction

*Vertical condensatuion
- compaction*

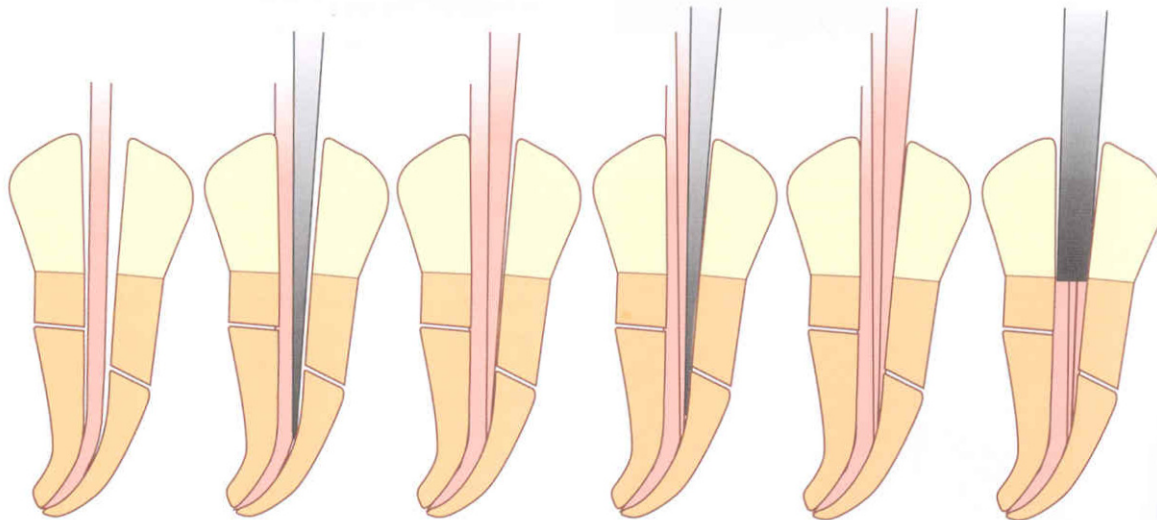
Filling techniques

Cold

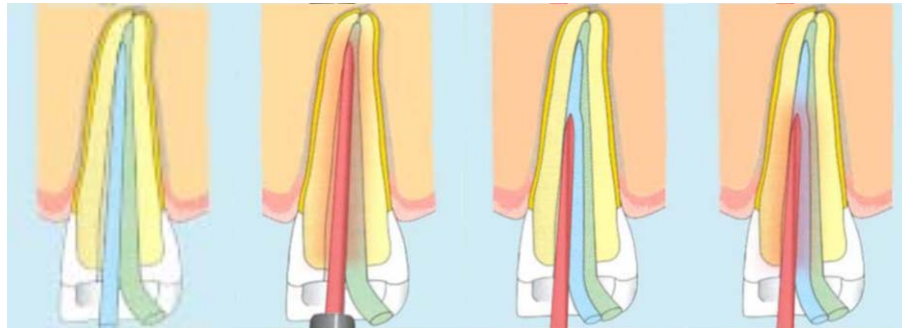
Warm



A

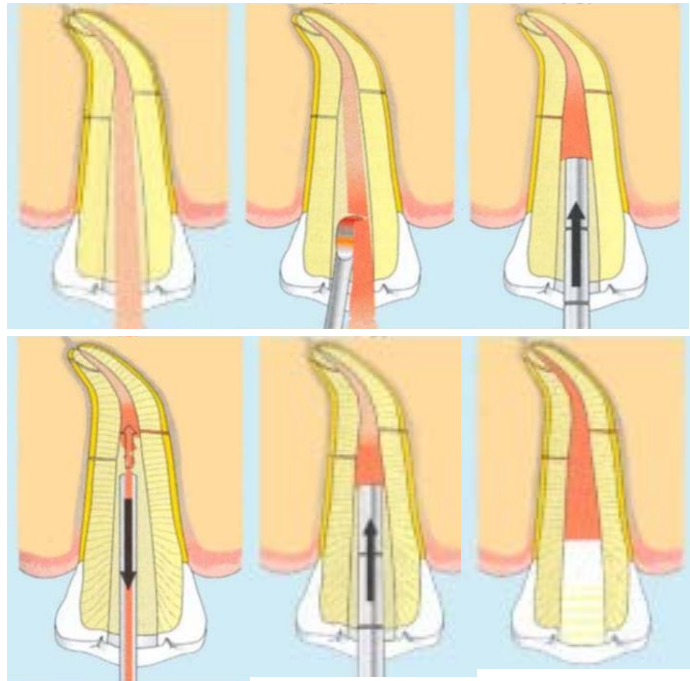


Warm lateral condensation (compaction)



Vertical compaction

- Difficult control of the working length
- Possible extrusion of the sealer
- Warm



Injection of heated guttapercha

- Fast
- Possible extrusion
- Warm

