

Class V. Cavity Preparation

Anatomical x clinical crown

- Anatomical crown - cementum- enamel junction
- Clinical crown – gingival border

Cervical area

- Predictable dirty place
- Nearness of gingiva - possibility of its injury, bleeding, inflammation
- Flow of the sulcular liquid
 - Difficulties with the maintenance of the dry field
- Specific ordering of the hard dental tissues
 - Také into account

Access Into The Cavity

- Elimination of the undermined enamel
 - Burs or diamonds (pear), tapered fissure bur
- Separation of the gingiva – temporary filling guttapercha, fermit, clip, zinkoxidsulfate cement, cavit, provimat).
- Ablation of ingrown gingiva – surgical (scalpel, laser, high frequency current)

V.Class Amalgam

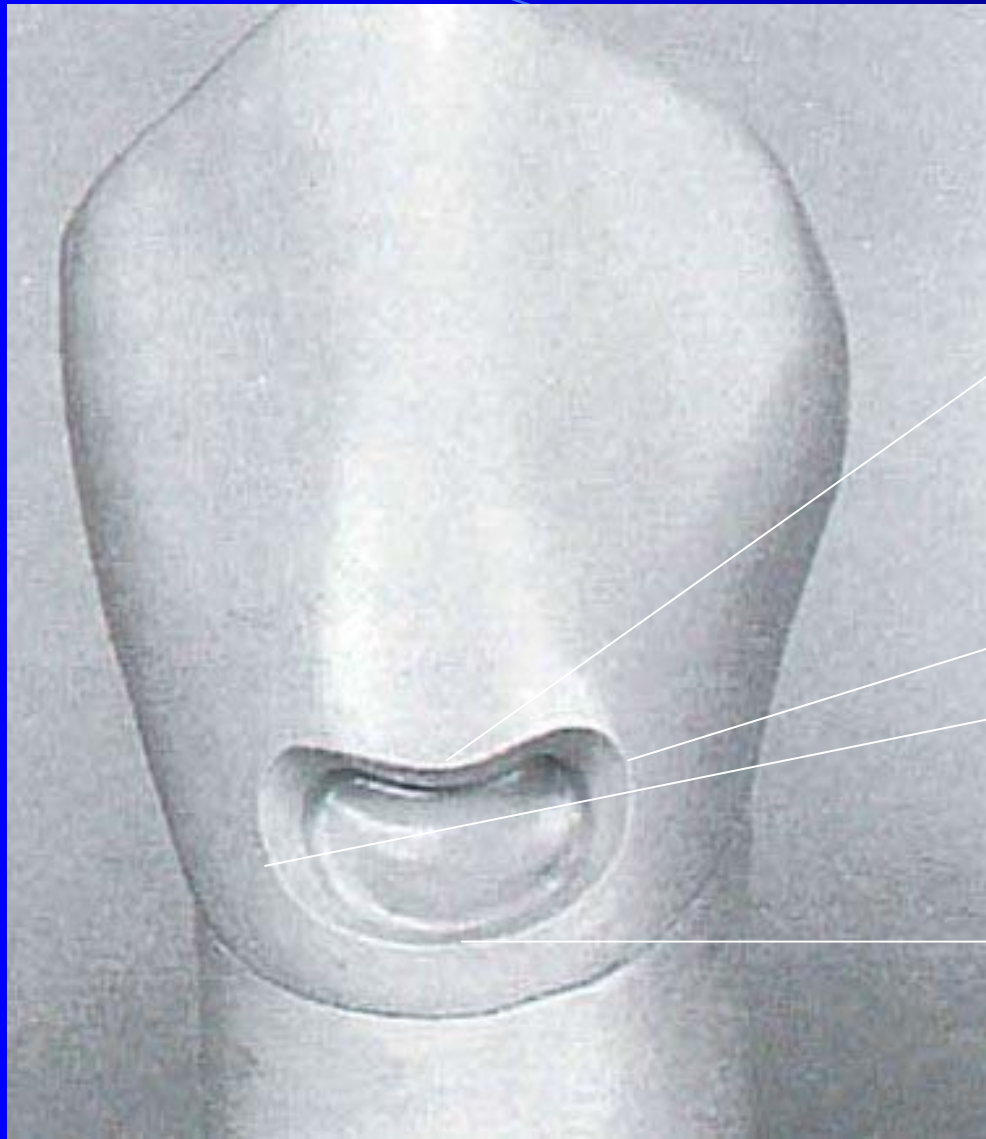
- Posterior area

Determination of cavity borders and extension for prevention

We do not follow Black's rules exactly!

Gingival: axial depth of 0,5 mm inside the DEJ.

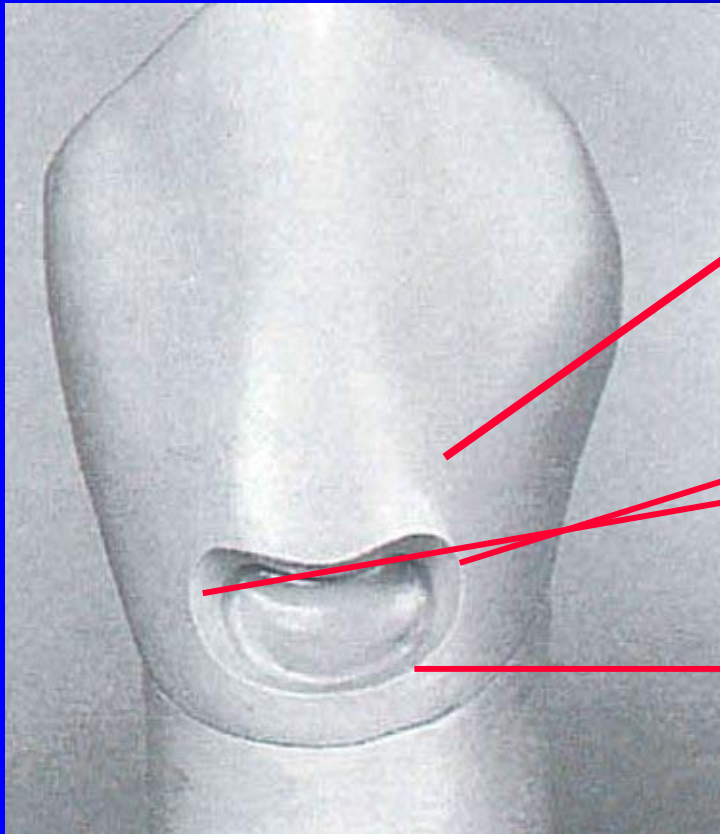
Extension of the preparation incisally, gingivally, mesially and distally until the cavosurface margins are positioned in sound dental structure. Total depth: 1 – 1.25 mm. If on root surface -0,75 mm



Incisal border

Mesial
and distal
border

Gingival border



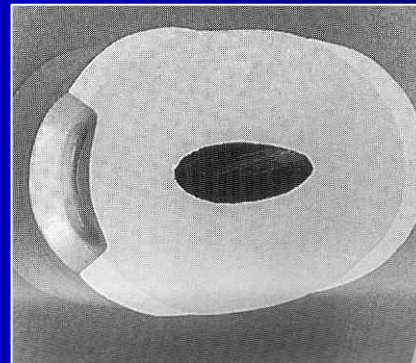

Okluzální okraj kavity
Pod maximální
konvexitou zubu

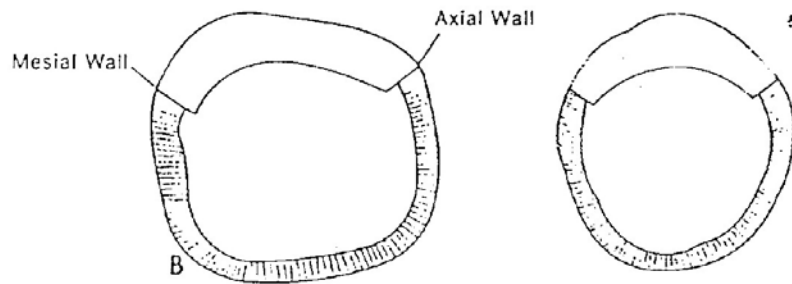
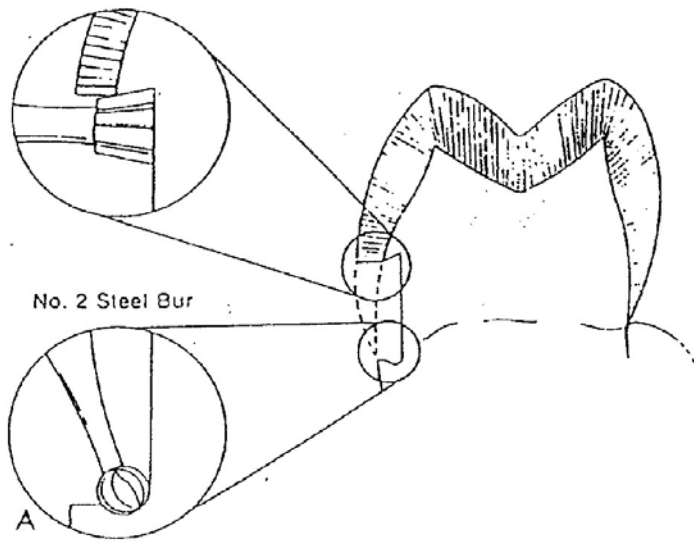
Mesiální
a distální
okraj kavity
Do axiálních
hran

Gingivální
okraj kavity
Pod okraj gingivy,
ale i supragingiválně

Retention


- Box 0,75 – 1,25 mm deep, undercuts, coves (larger cavities)





Resistance

Elastic deformation during the biting



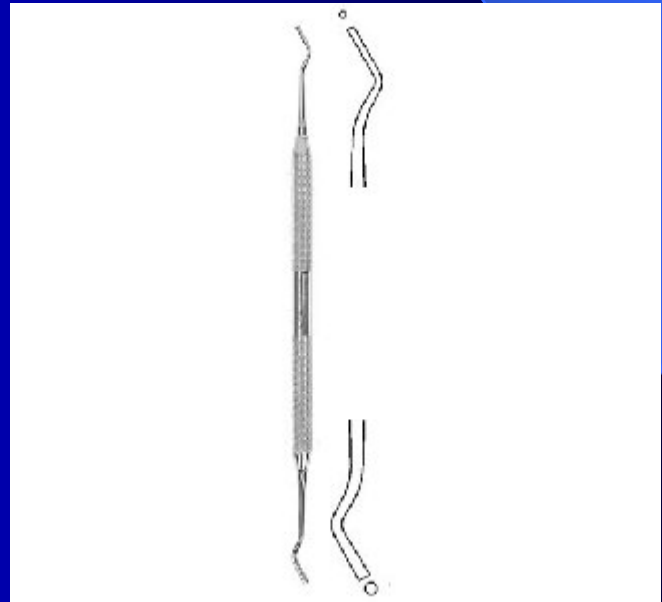
Excavation of carious dentin

Round bur

Excavator

Finishing of cavity borders

- Fine diamond bur of a chisel



Filling

- Portion of amalgam are condensed using a condensor (stamen) and finished using a spatula or a carver.

Class five - composite

- Aesthetic reasons

Access Into The Cavity

- Elimination of the undermined enamel
 - Burs or diamonds (pear), tapered fissure bur
 - Separation of the gingiva— temporary filling guttapercha, fermit, clip, zinkoxidsulfate cement, cavit, provimat).
 - Ablation of ingrown gingiva – surgical (scalpel, laser, high frequency current)
- Composite must not be subgingival!!!!

Determination of cavity borders

Cavity is limited on the caries defect only –
no extention!!!!

The depth usually 1 mm

Retention

➤ Micromechanical retention

Enamel: Retentive border – 1 – 2 mm wide
and the angle 45°

Cementum: only finishing with the fine
diamond bur.

Retention

Retentive border:

- removing of the aprismatic enamel



- better condition for micromechanical retention

- better aesthetics

Retention

Acid etching (phosphoric acid): 30 s dentin,
30 s enamel

Rinsing (washing off) 30s

Priming, bonding, light curing.

Filling

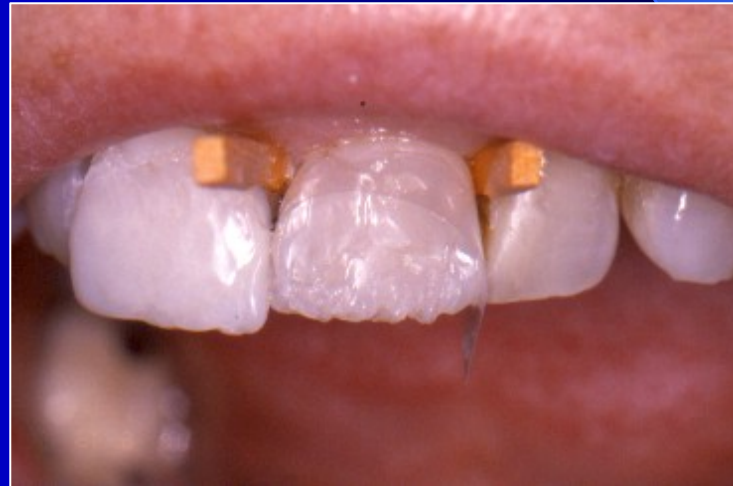Spatula

Matrix

- Polyester strip, wooden wedges
- Special cervical matrix

Matrix

Anatomical form



Class five - glasionomer

- Cavity outside of enamel

Properties

- Chemical fixation to tooth structure
- Fluoride release
- Favorable thermal expansion
- Acceptable aesthetics

Determination of cavity borders

Cavity is limited on the caries defect only –
no extention!!!!

The depth usually 1 mm

Retention

- Box

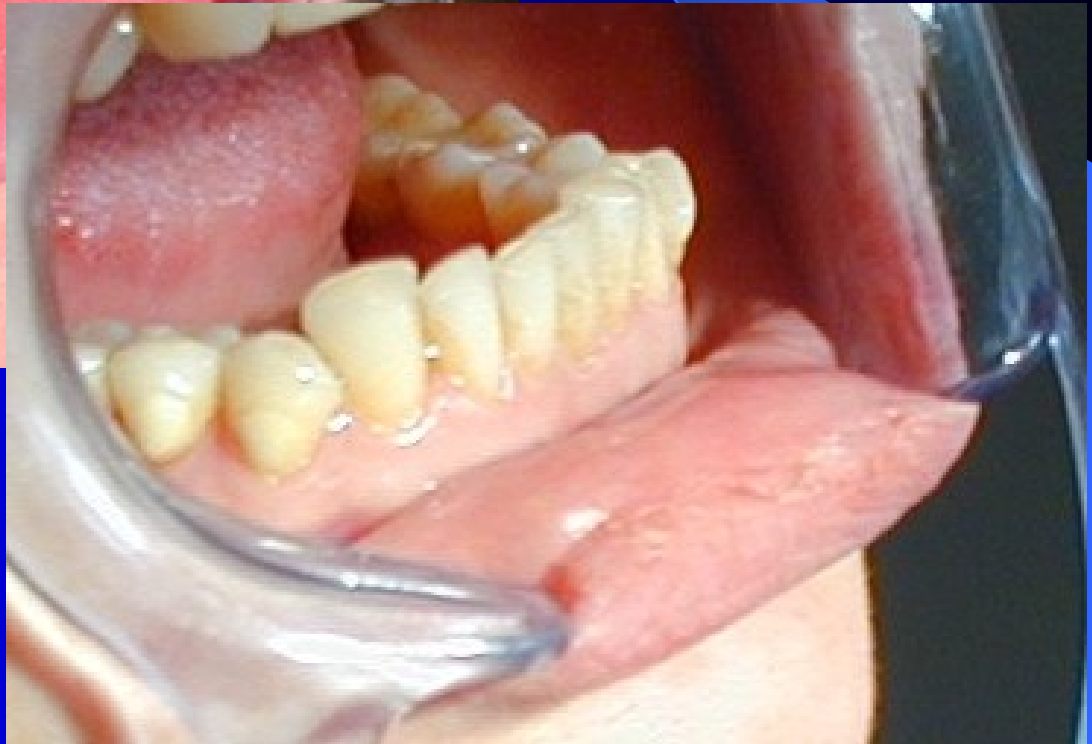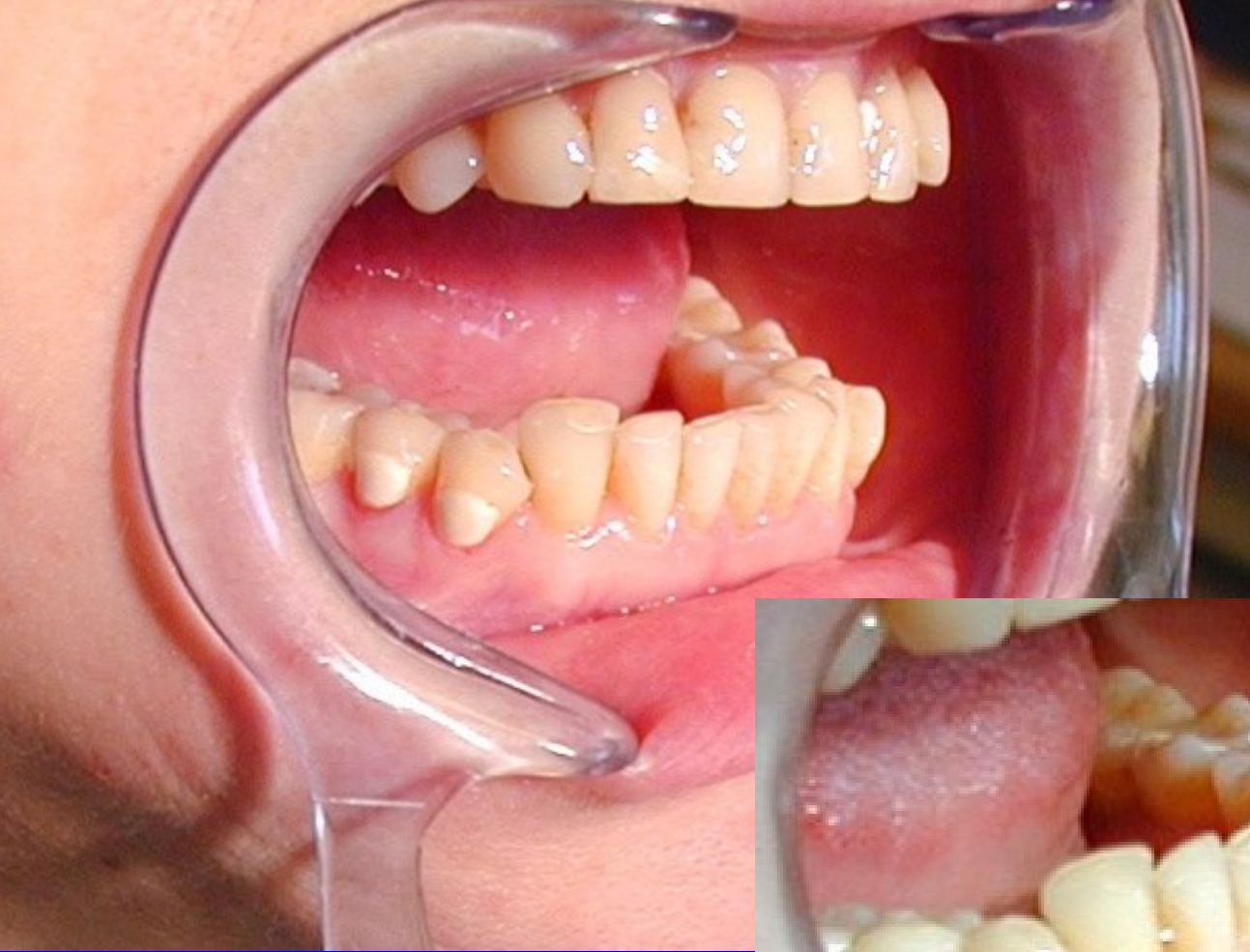- Chemical

Finishing of cavity borders

Fine diamond bur

Filling

- Conditioner 20 s
- Washing off
- Wet cavity
- Filling material
- Matrix
- Varnish



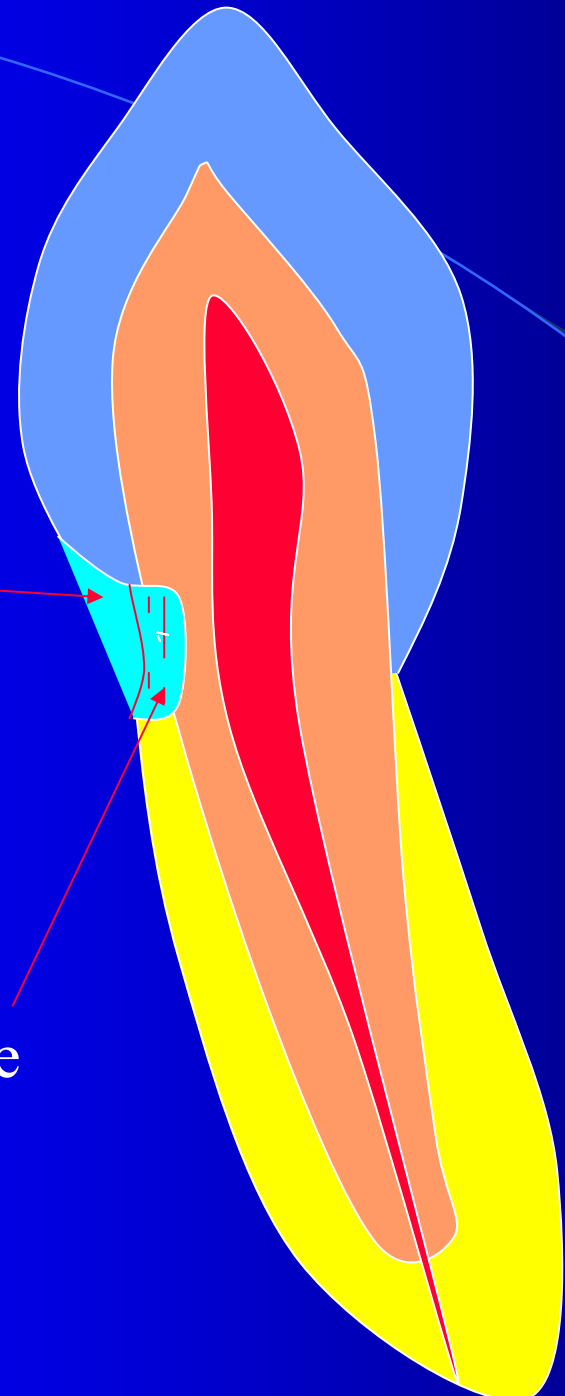
Class V. – Sandwich principle

Base of galsionomer – replace of the lost dentin

Thin layer of composite – replace of the lost enamel

Composite

Base



Bond:
GIC - Tooth
Chemical

Composite – Tooth
Micromechanical

Composite - GIC
Micromechanical

