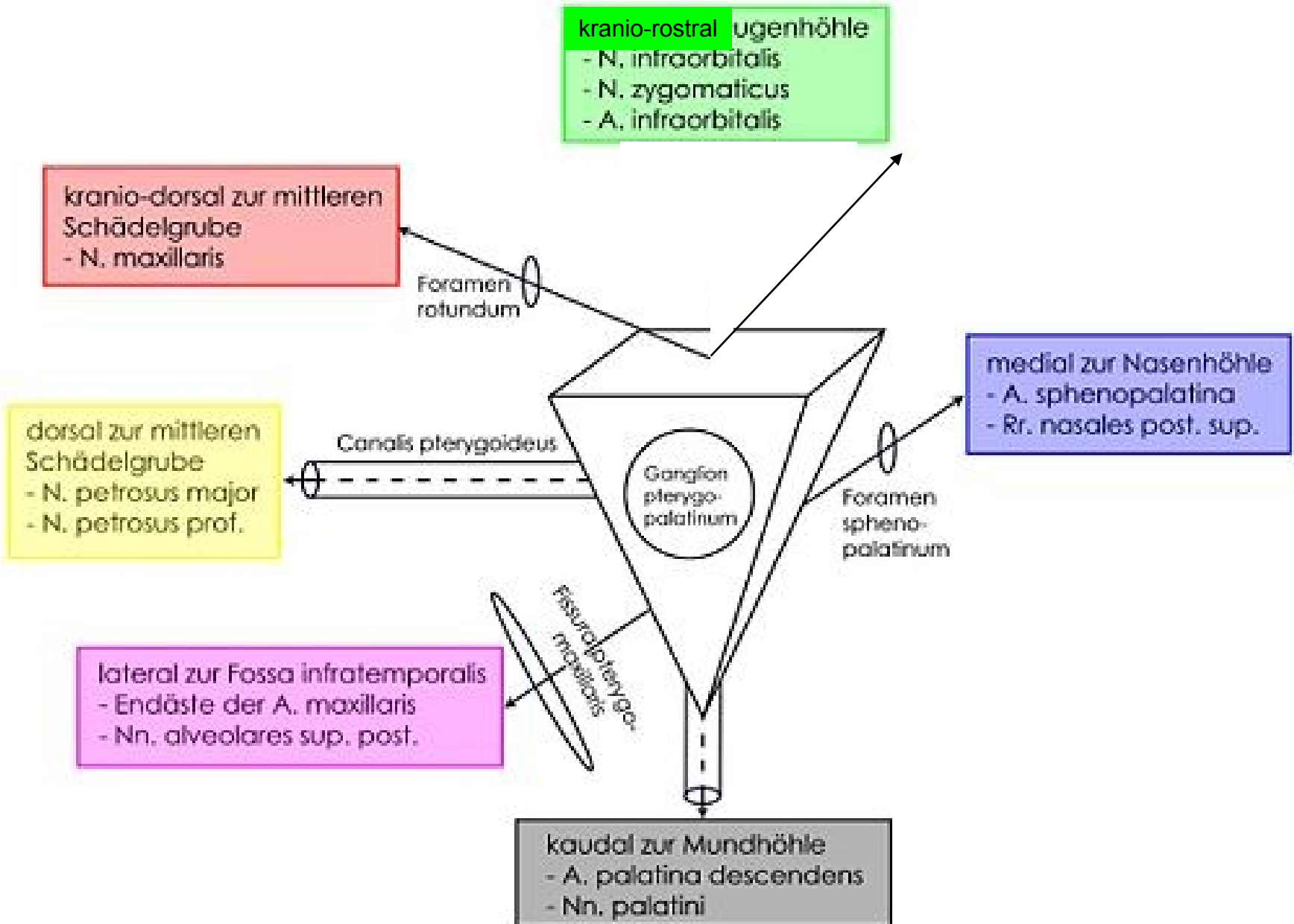


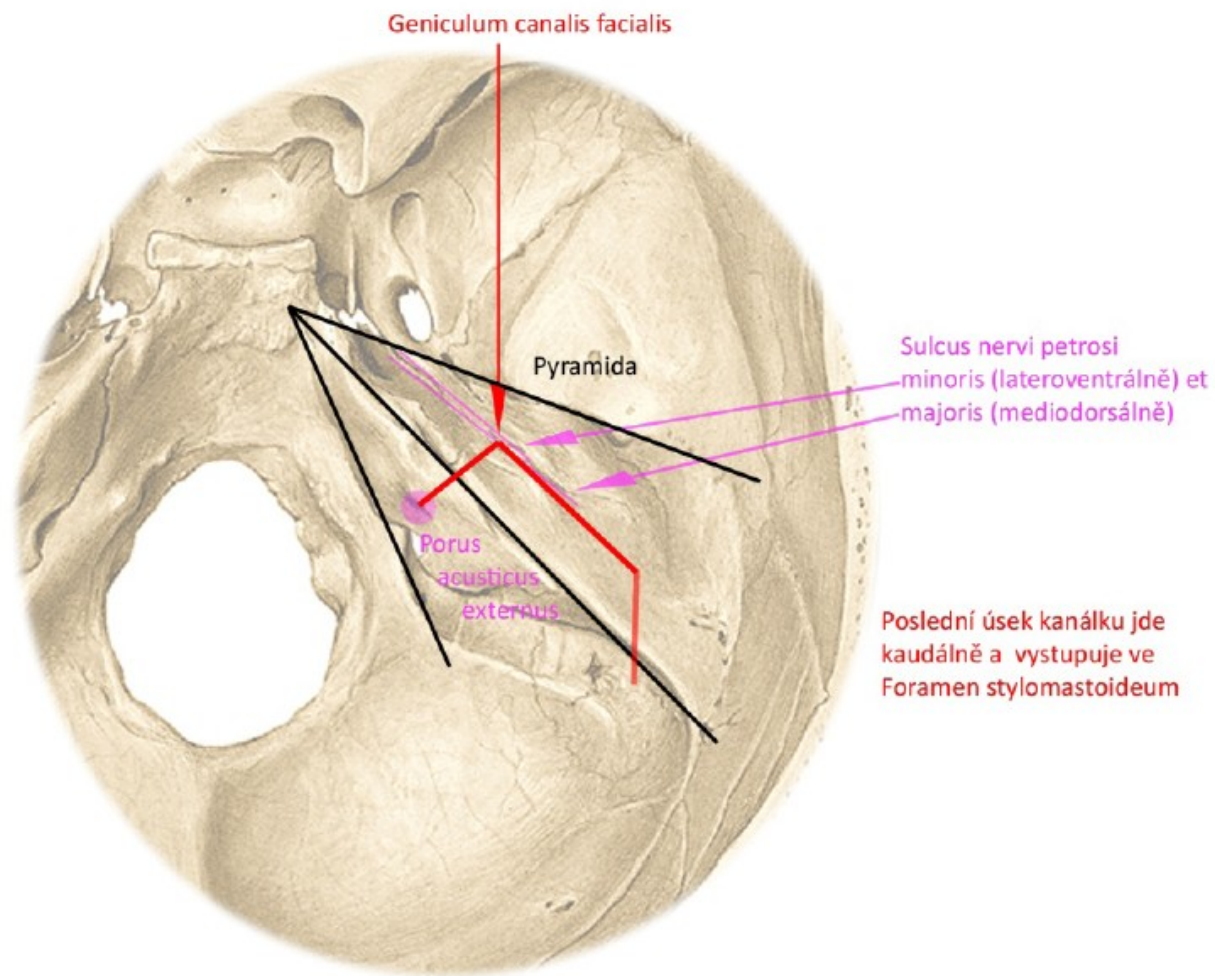
SCHÉMATA 1. SEMESTR

Fossa pterygopalatina

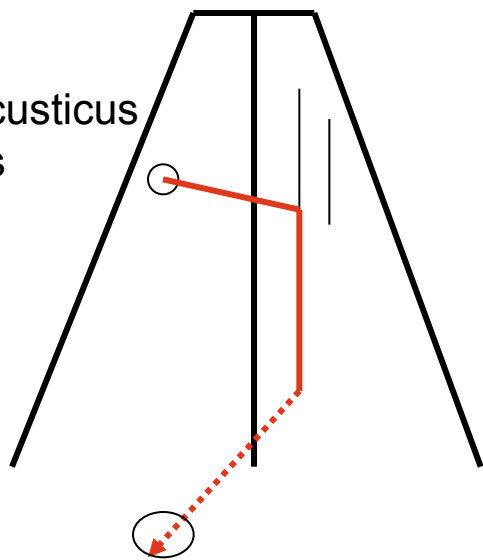


PRŮBĚH CANALIS NERVI FACIALIS V PYRAMIDĚ

Pohled shora

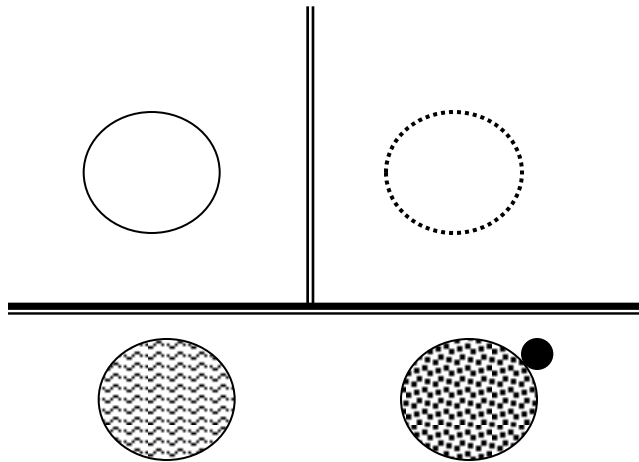
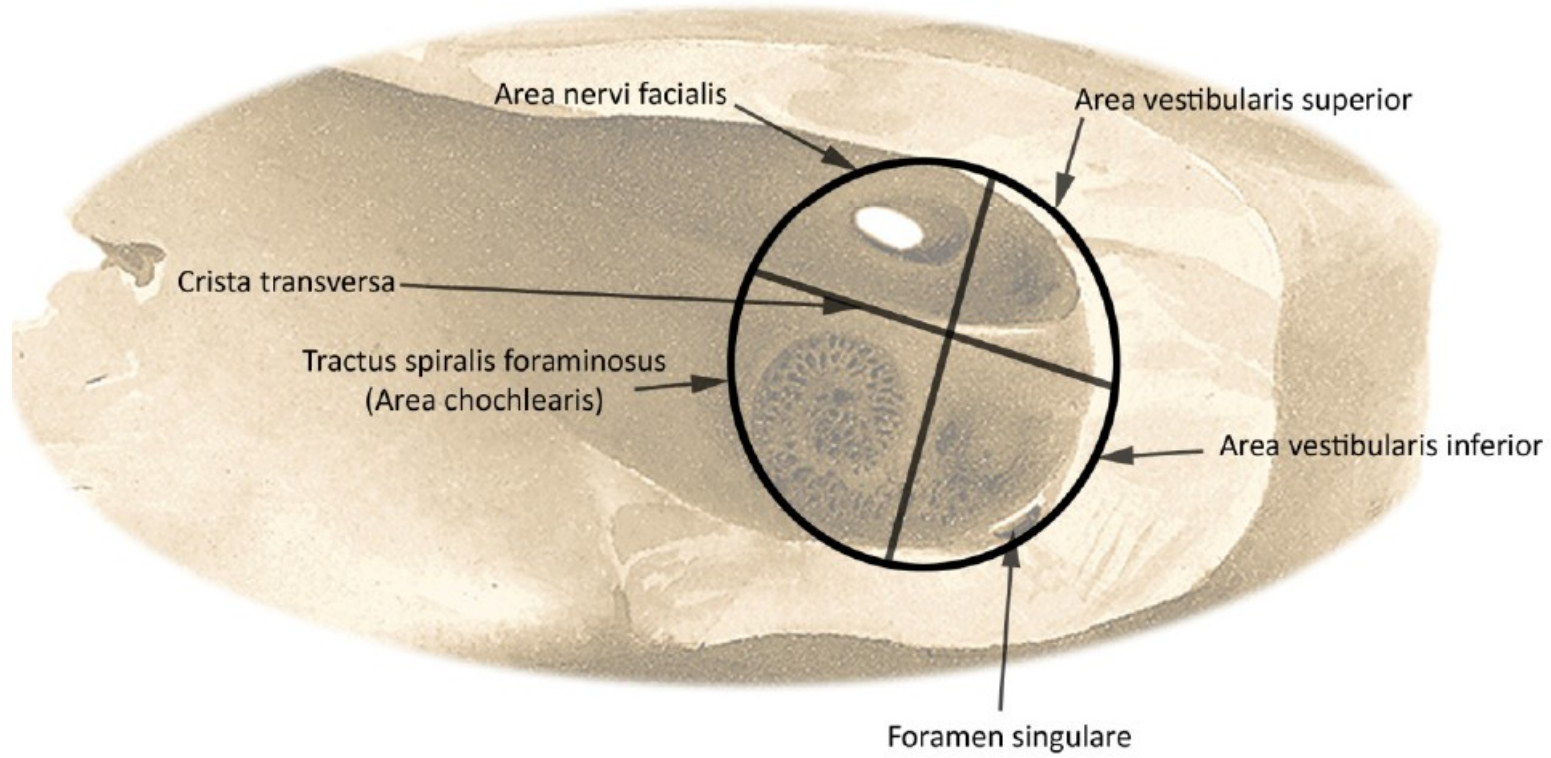


porus acusticus internus

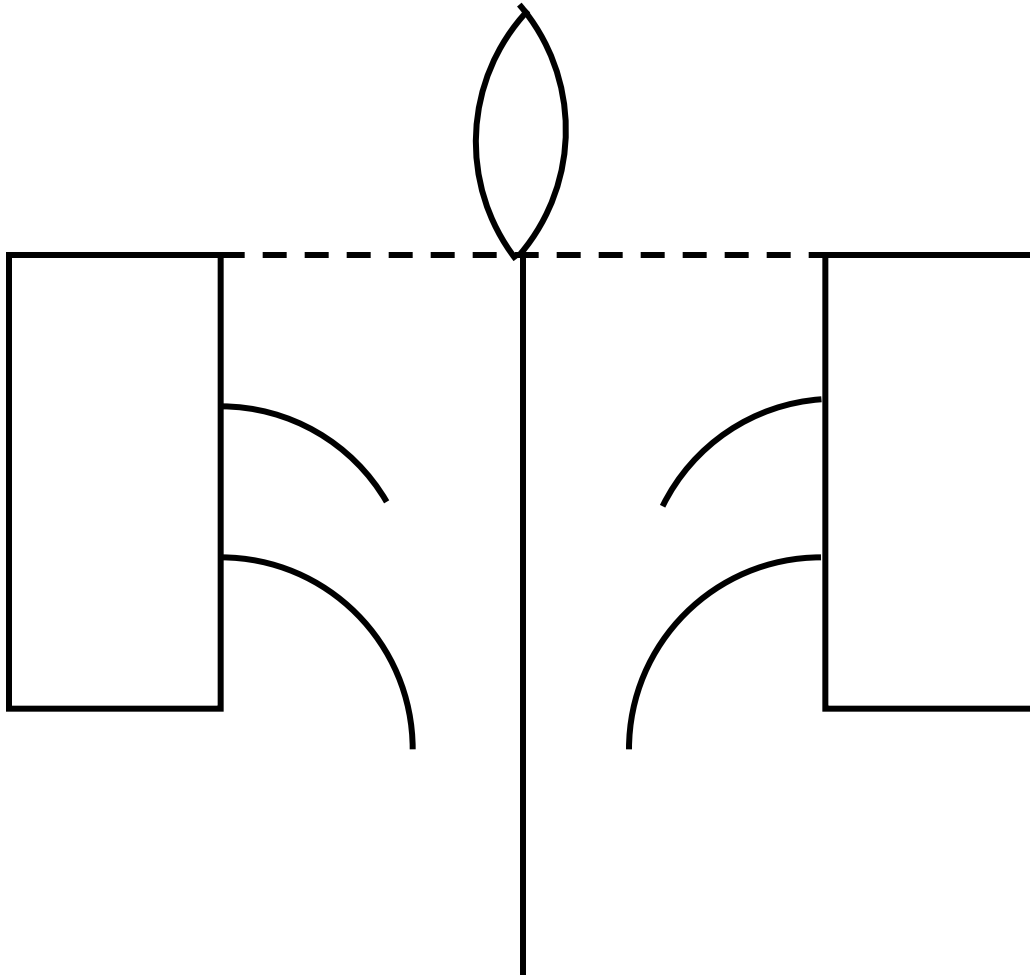


foramen stylomastoideum

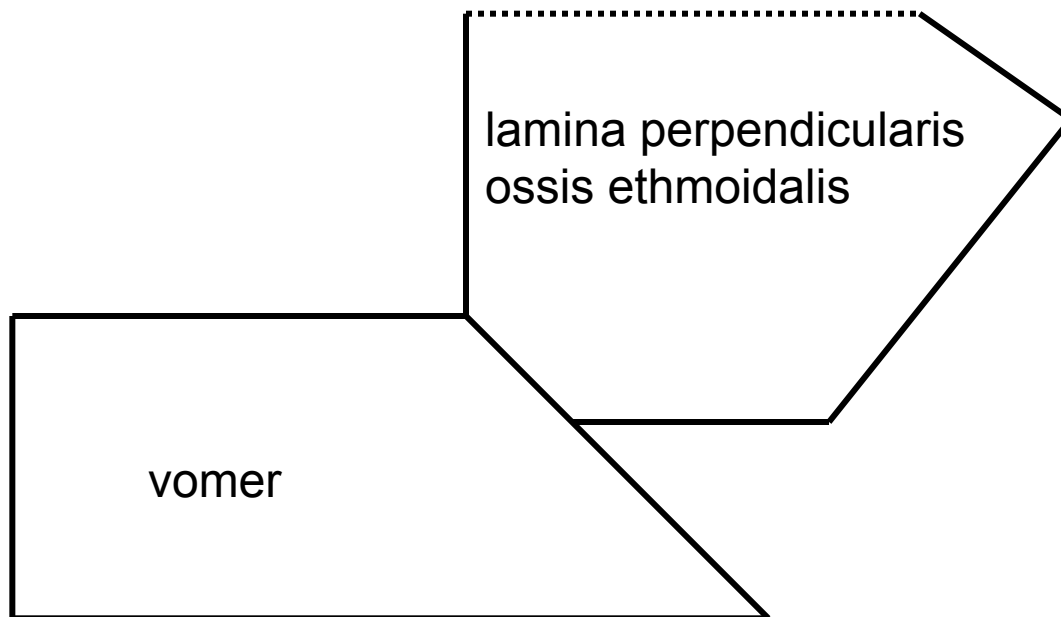
ROZDĚLENÍ FUNDUS MEATUS ACUSTICUS INTERNUS



Os ethmoidale



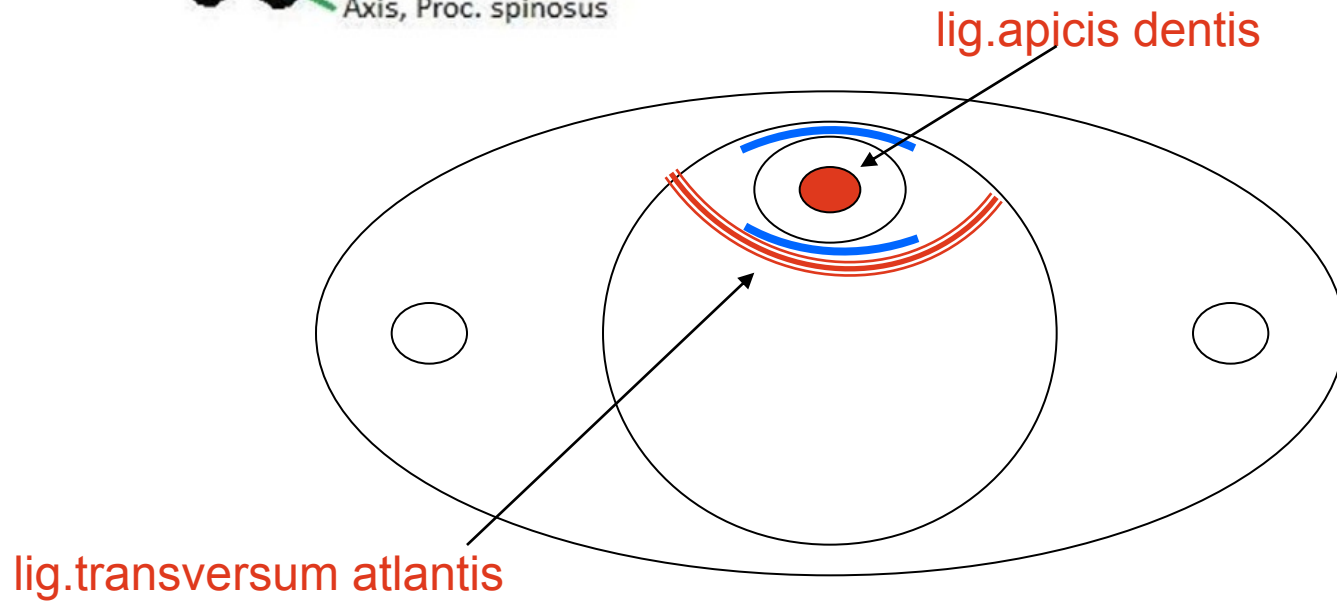
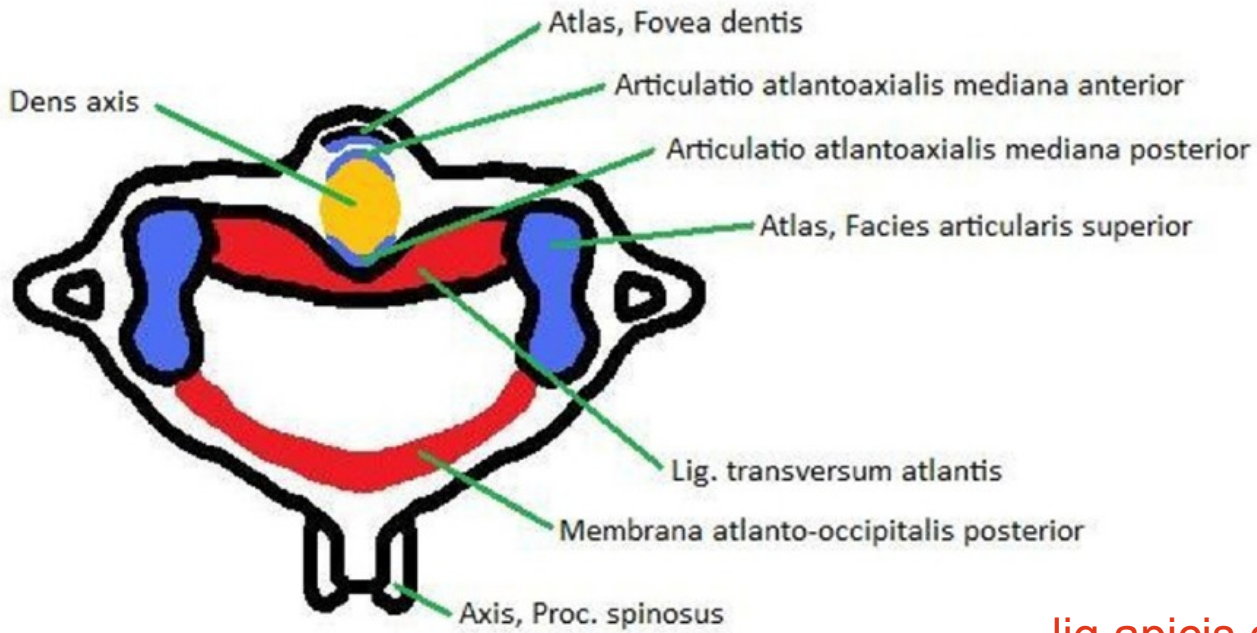
Kostěná nosní přepážka



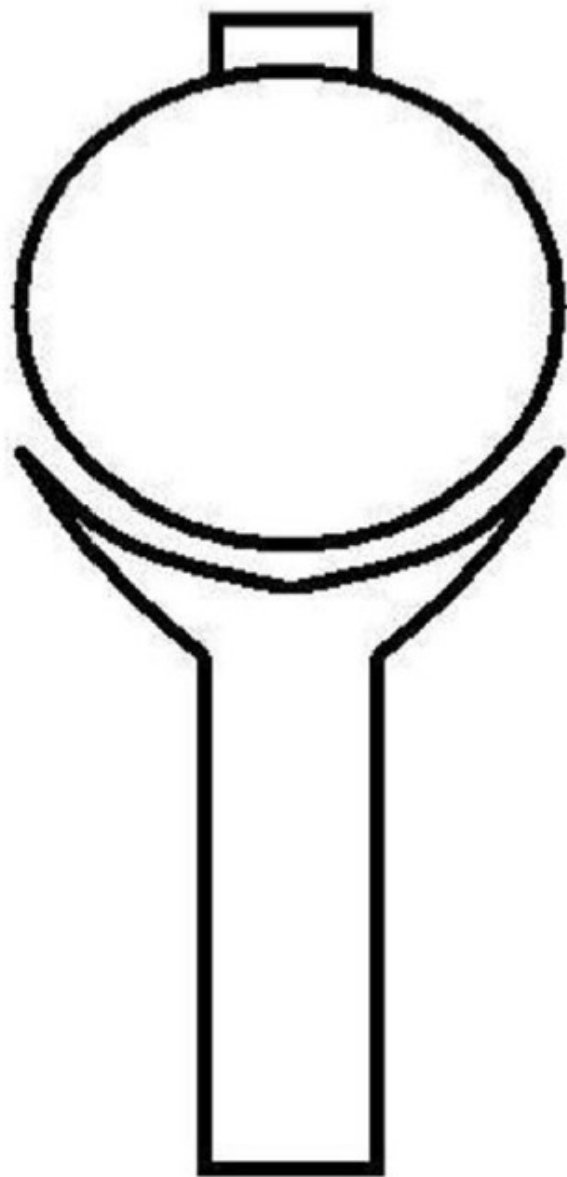
Rozdíl mezi diskem a meniskem na příčném řezu



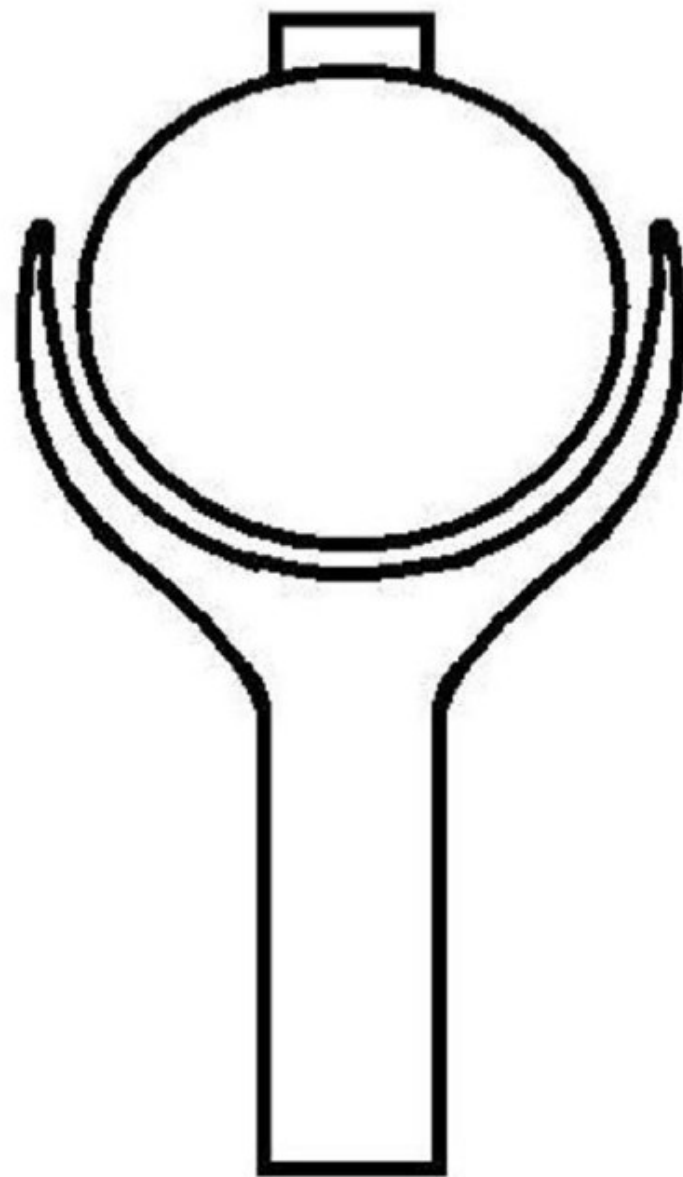
Vazy atlanto-axiálního spojení, pohled shora



Kloub kulový volný (arthrodia)

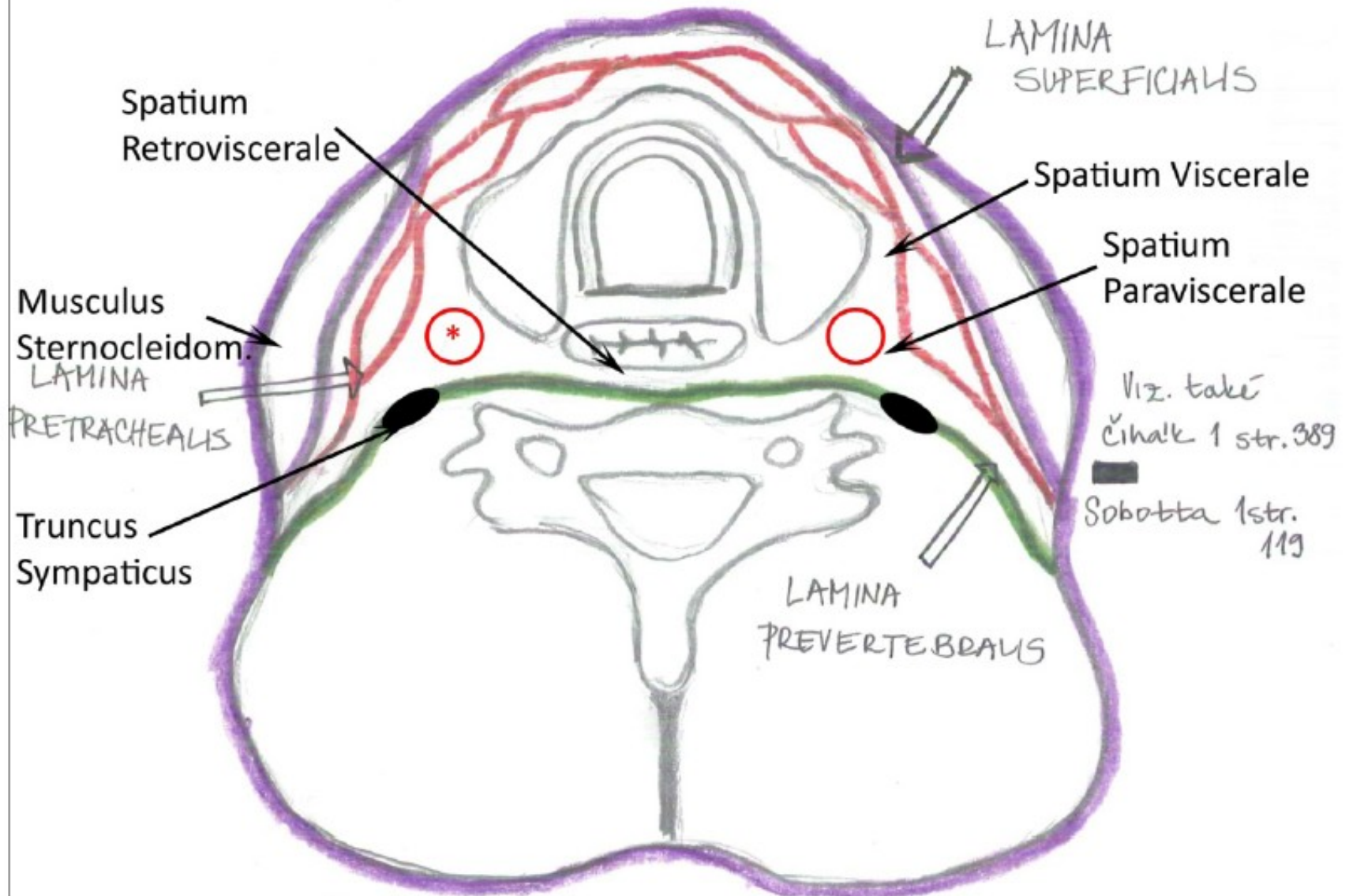


Kloub kulový omezený (enarthrosis)

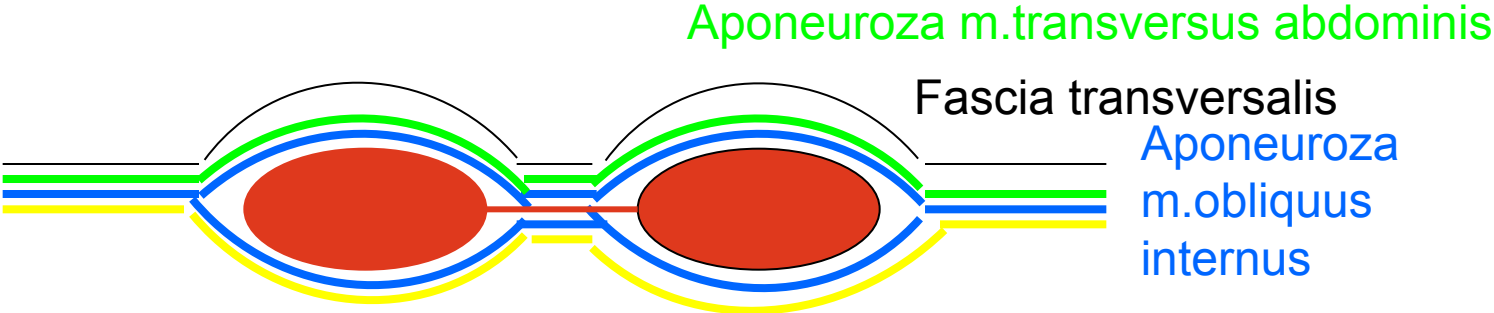


Fasciae colli (horizontální řez)

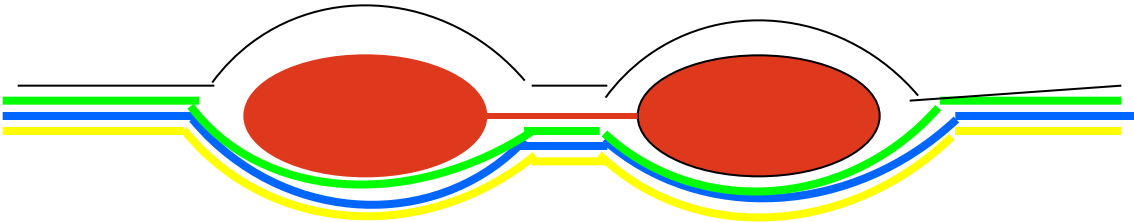
* A. carotis communis, v. jugularis interna, n. vagus



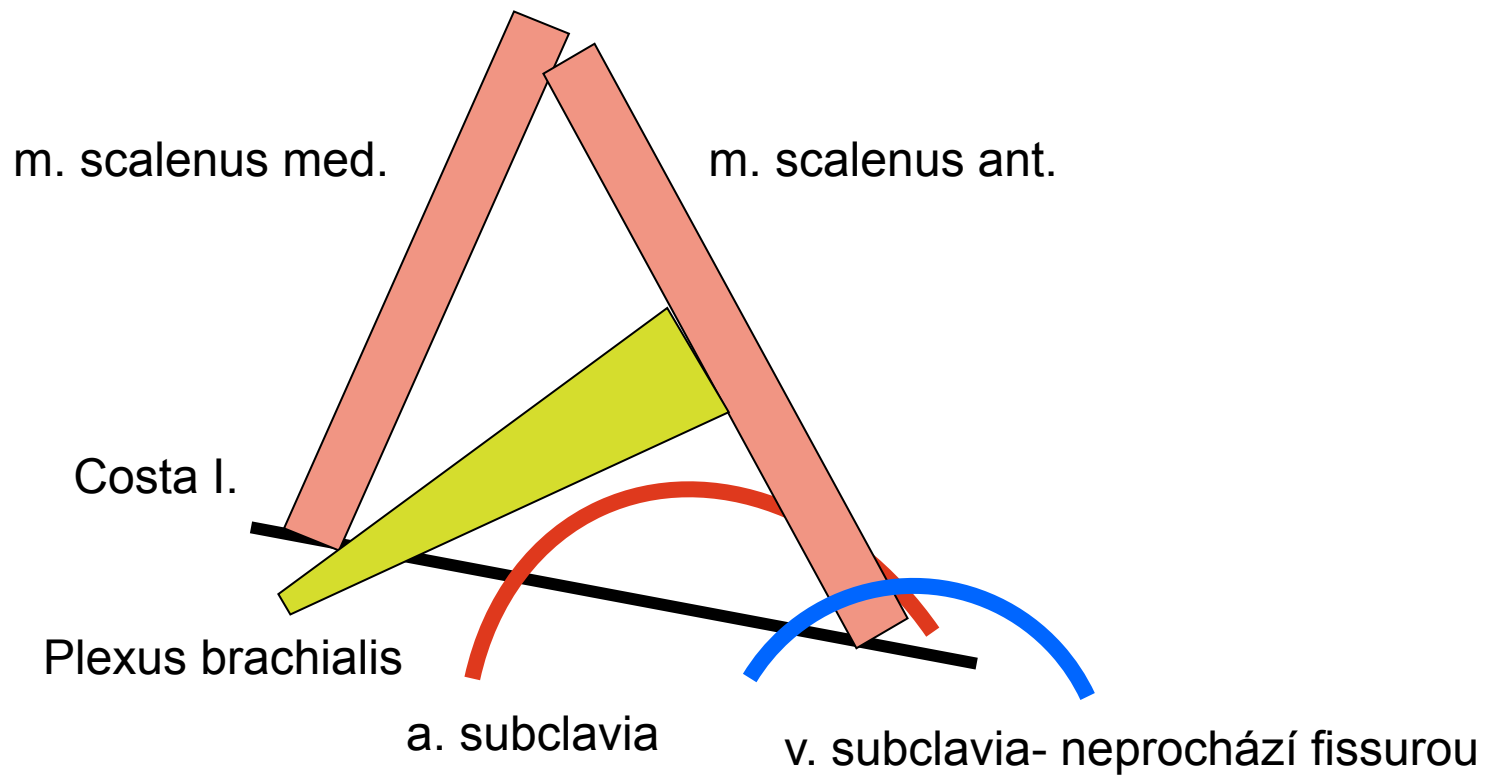
Vagina m.recti abd.



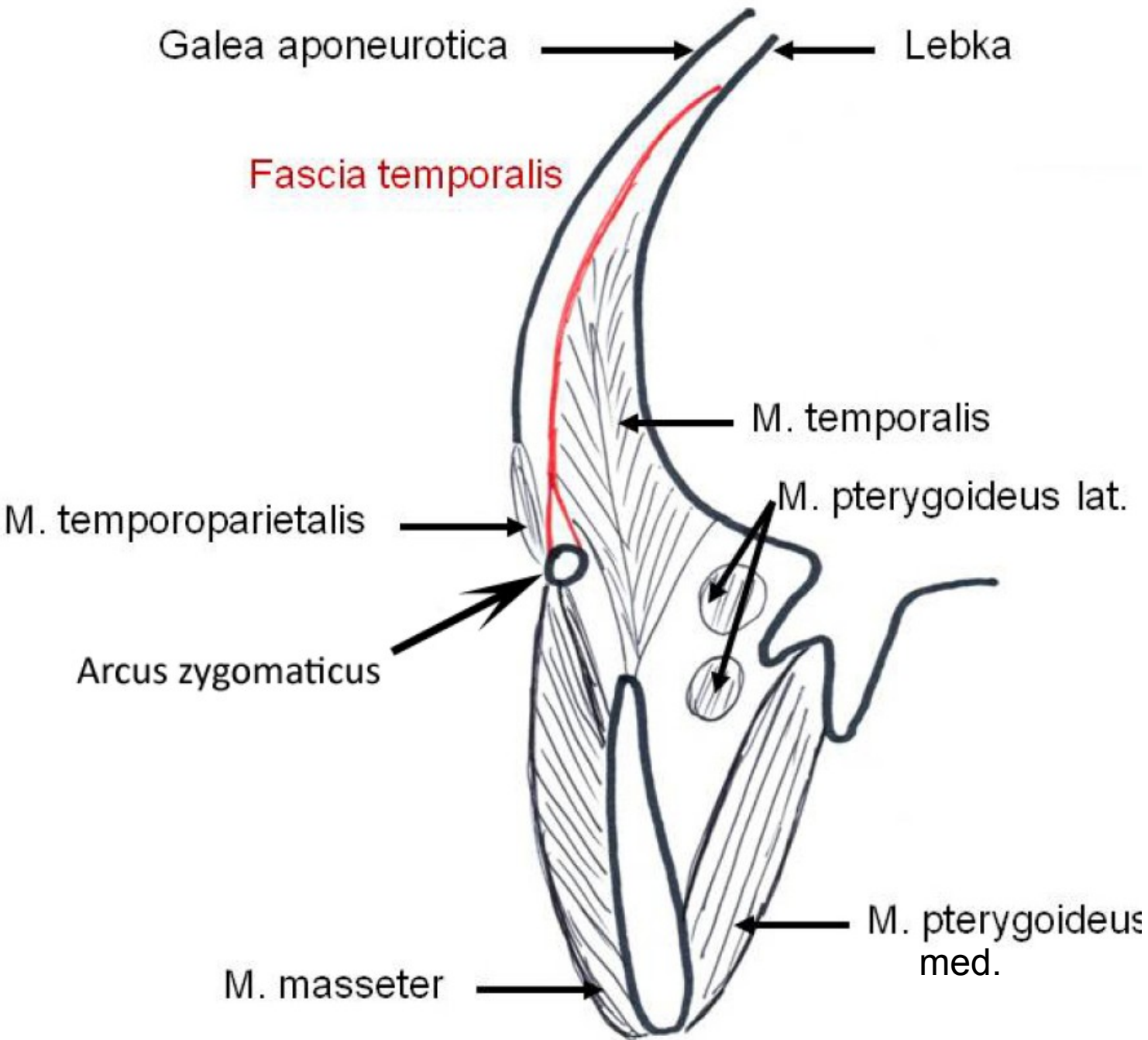
Aponeuroza m.obliquus externus

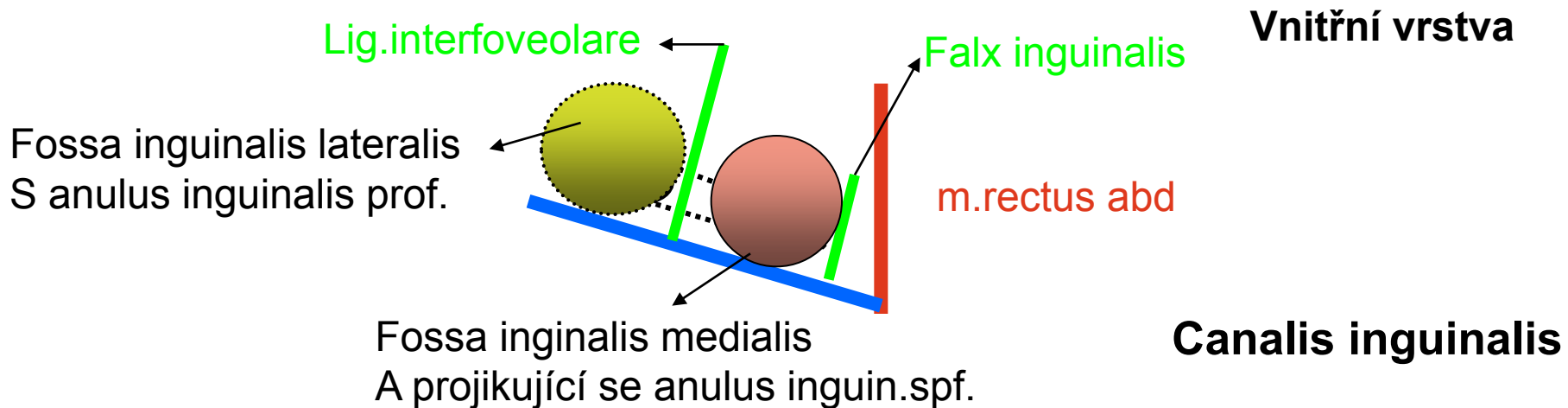
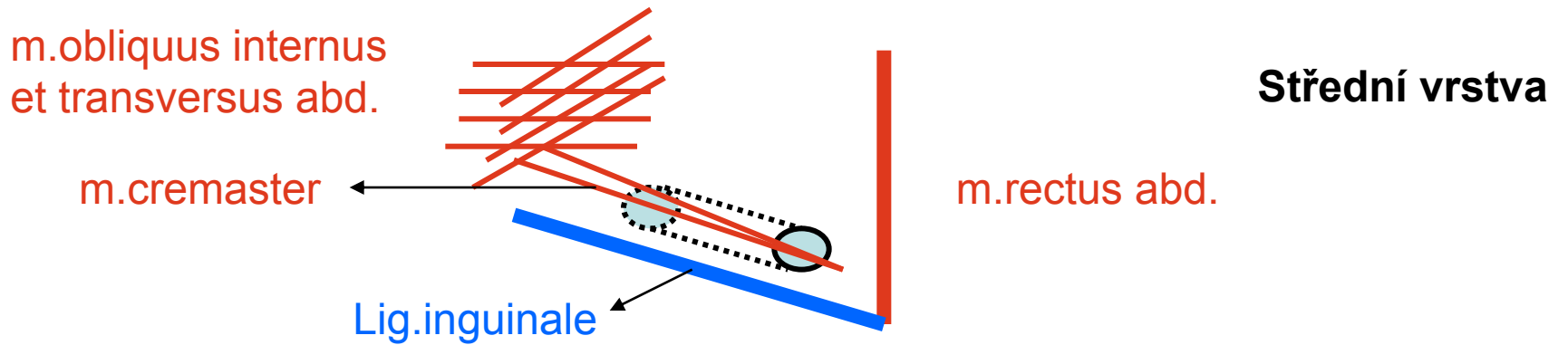
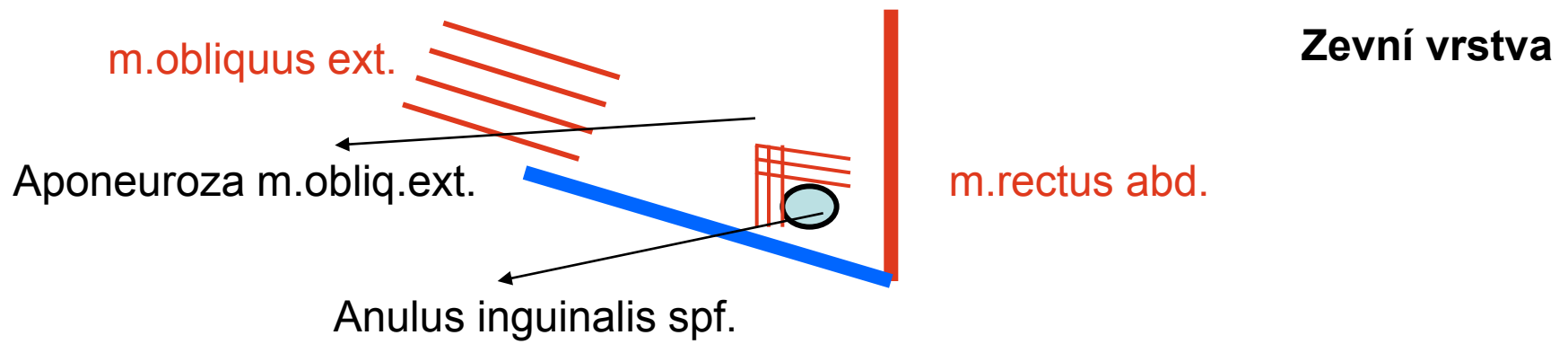


Fissura scalenorum

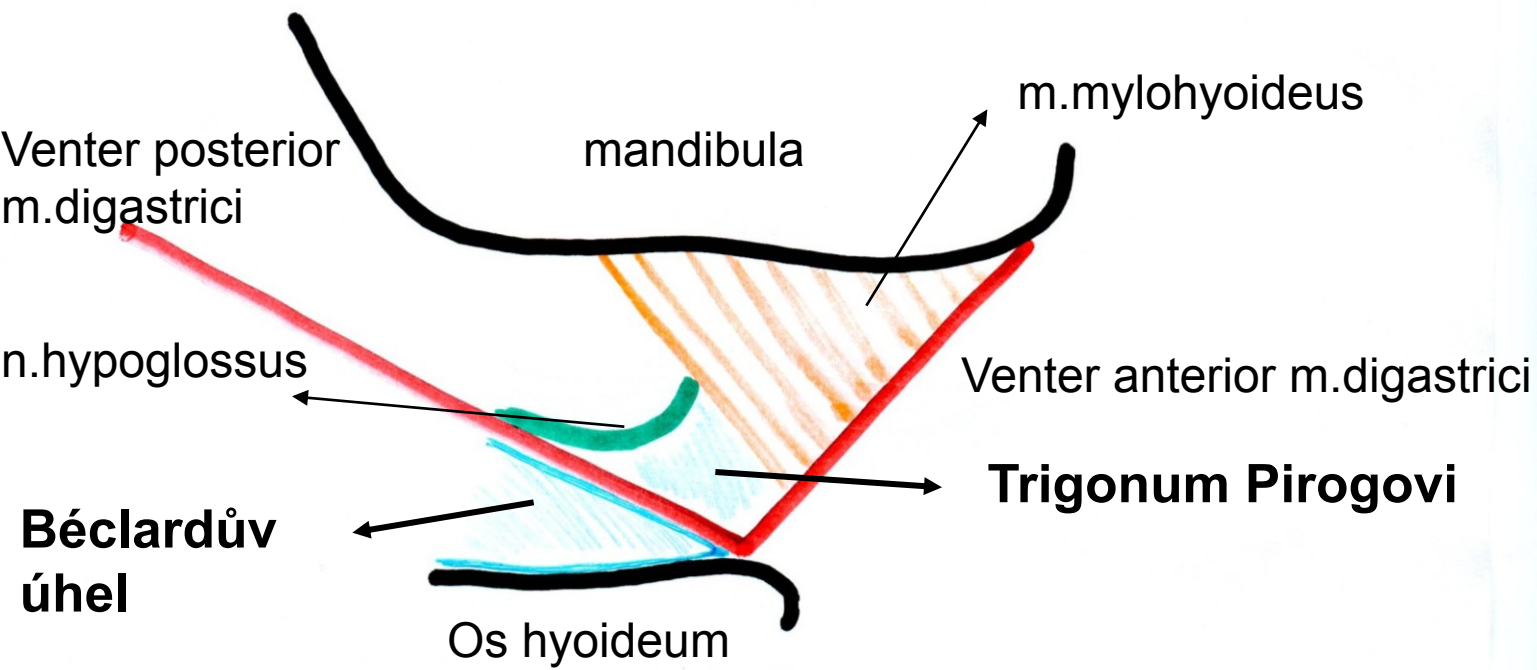
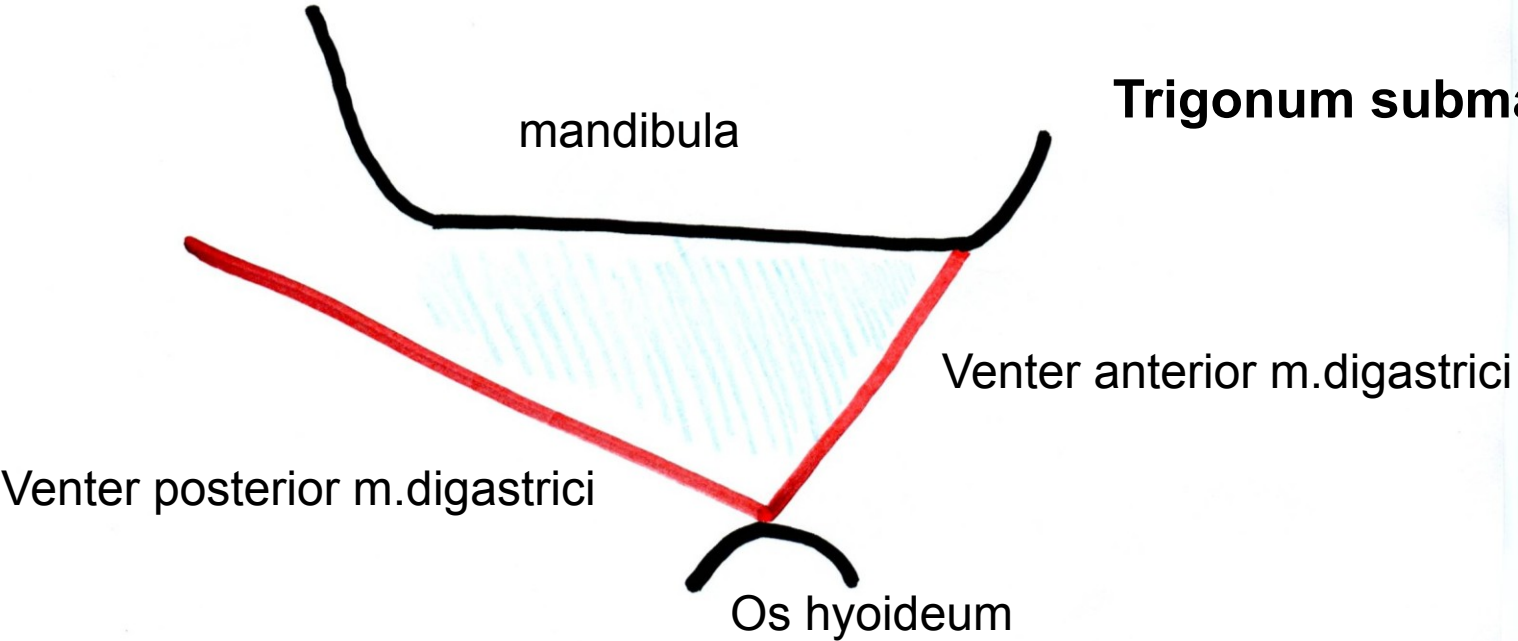


Fossa temporalis na frontálním řezu, úpon fascie





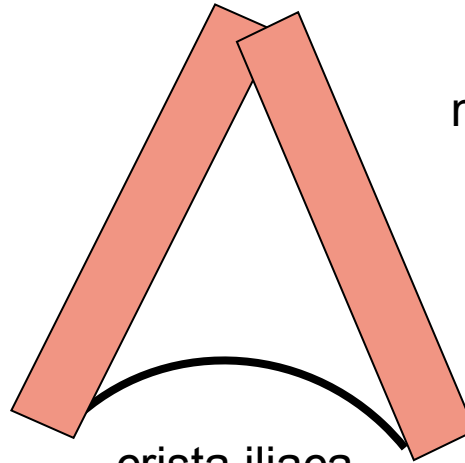
Trigonum submandibulare



Trigonum lumbale- Petiti

m.latissimus dorsi

m.obliquus externus



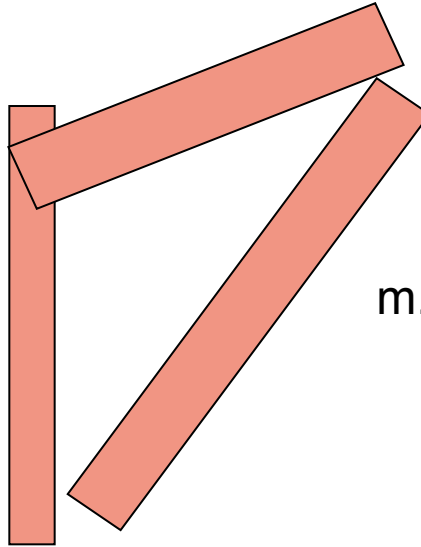
crista iliaca

Trigonum Grynfelti

m.erector spinae

m.serratus posterior infer.

m.obliquus internus



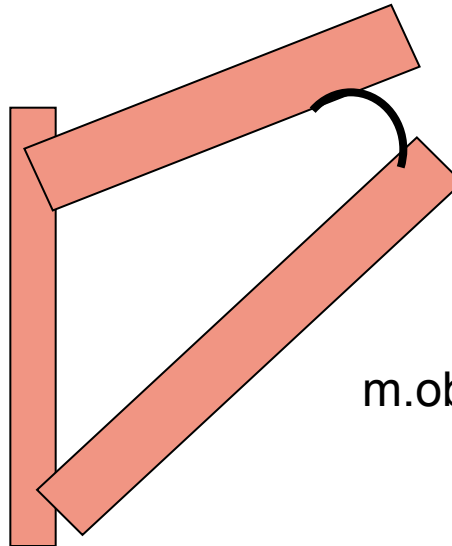
Tetragon Krausei

m.erector spinae

m.serratus posterior infer.

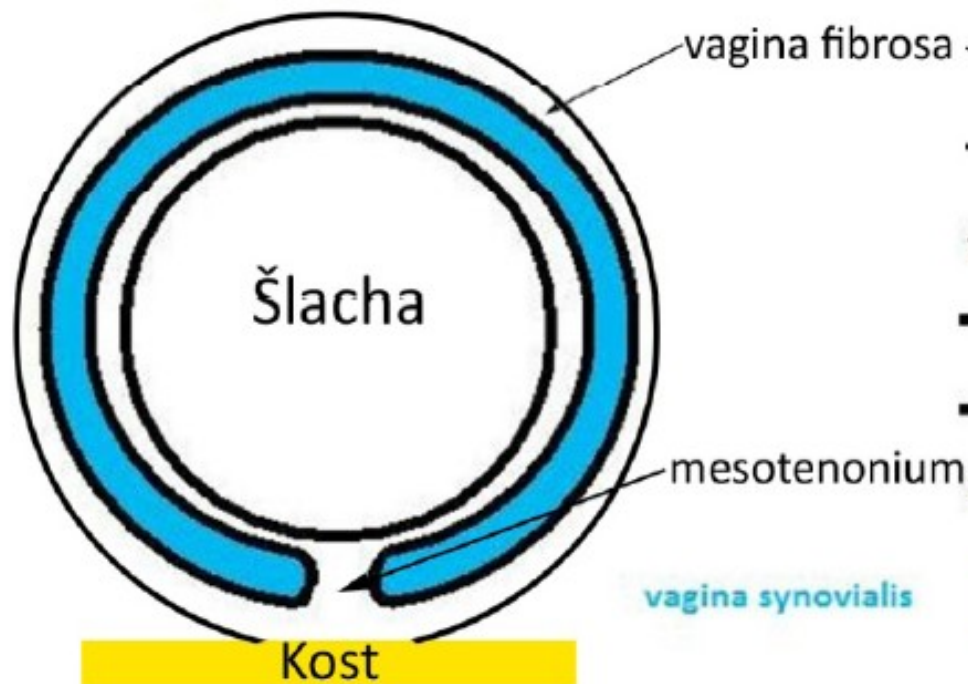costa I.

m.obliquus internus

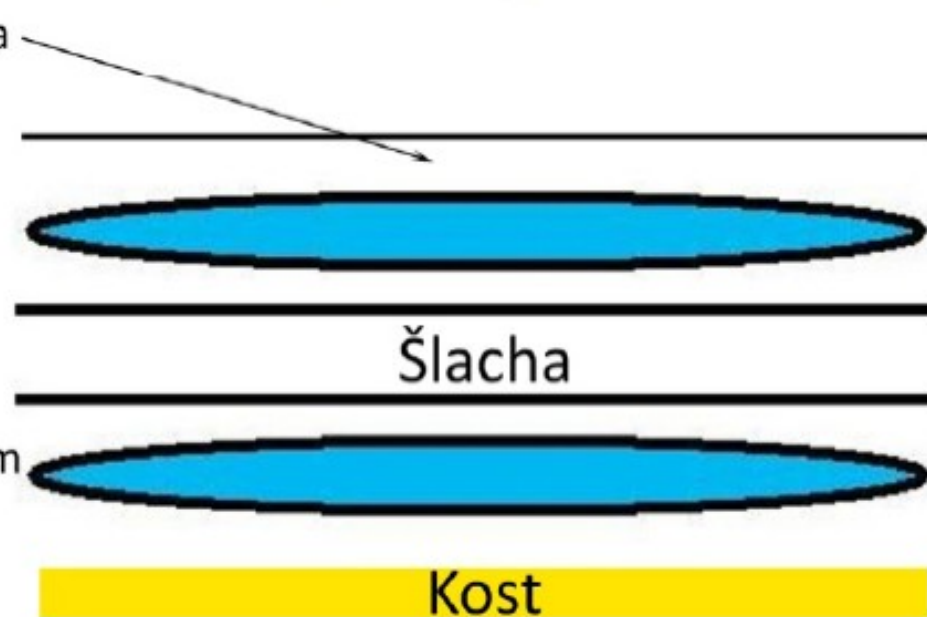


Vagina synovialis na podélném příčném řezu

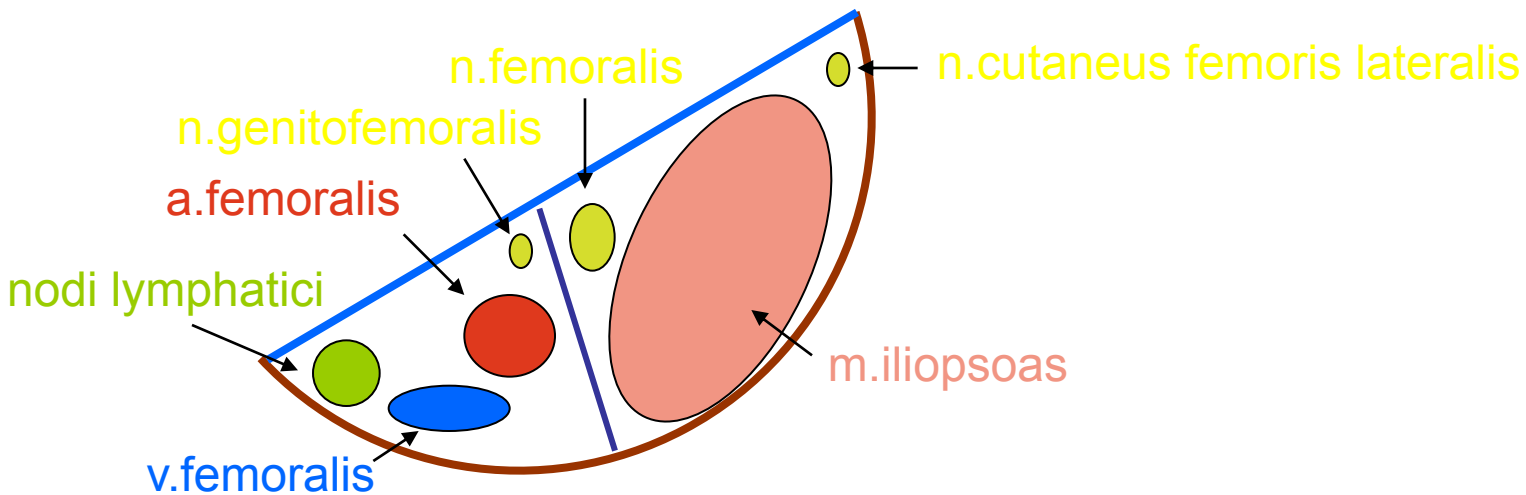
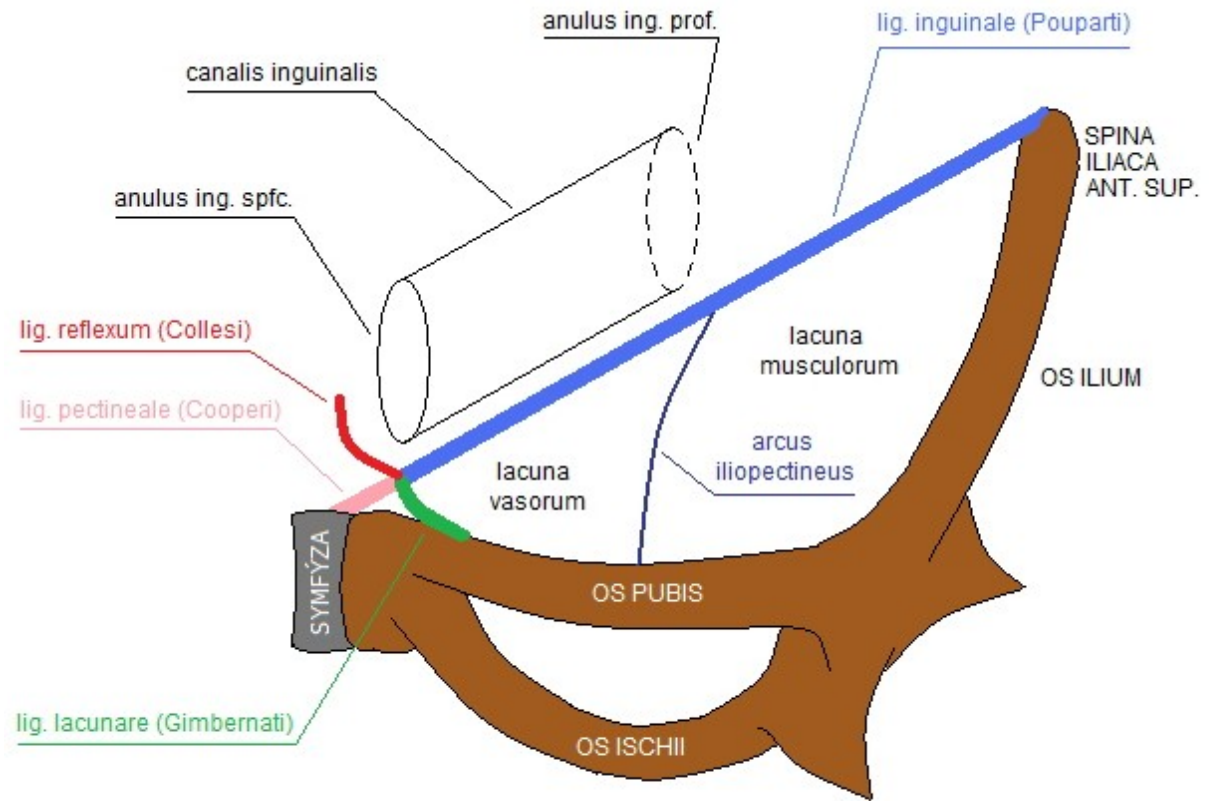
příčný řez



podélný řez



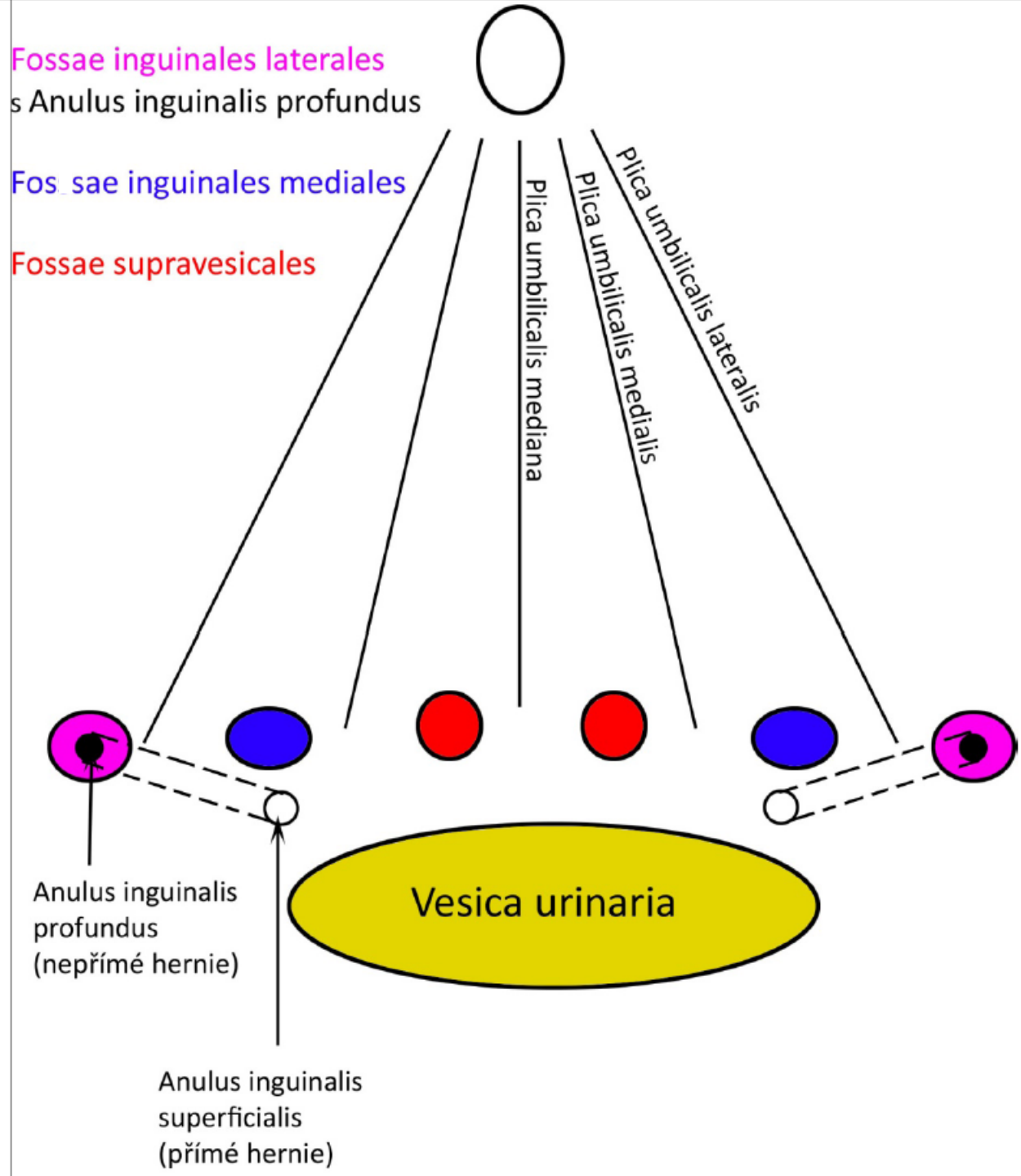
Lacuna musculorum et vasorum



Plica umb.**mediana**=
Lig.umb.**mediale**=
obliterovaný urachus

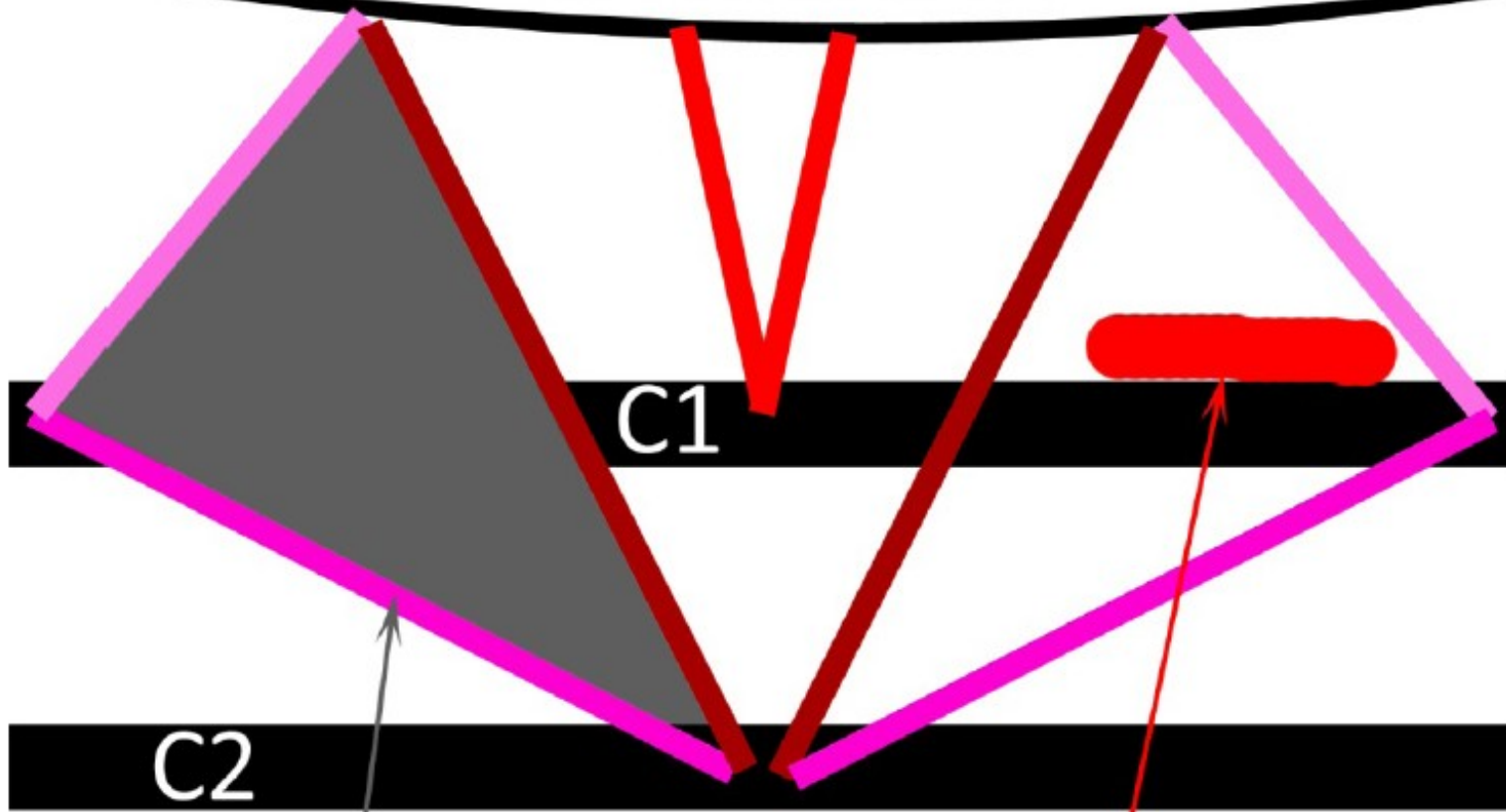
Plica umb.**medialis**=
Lig.umb.**laterale**=
obliterovaná a.umbilicalis

Plica umb.**lateralis**=
Lig.interfoveolare=
vasa epigastrica inferiora



Trigonum suboccipitale

Linea nuchae inferior



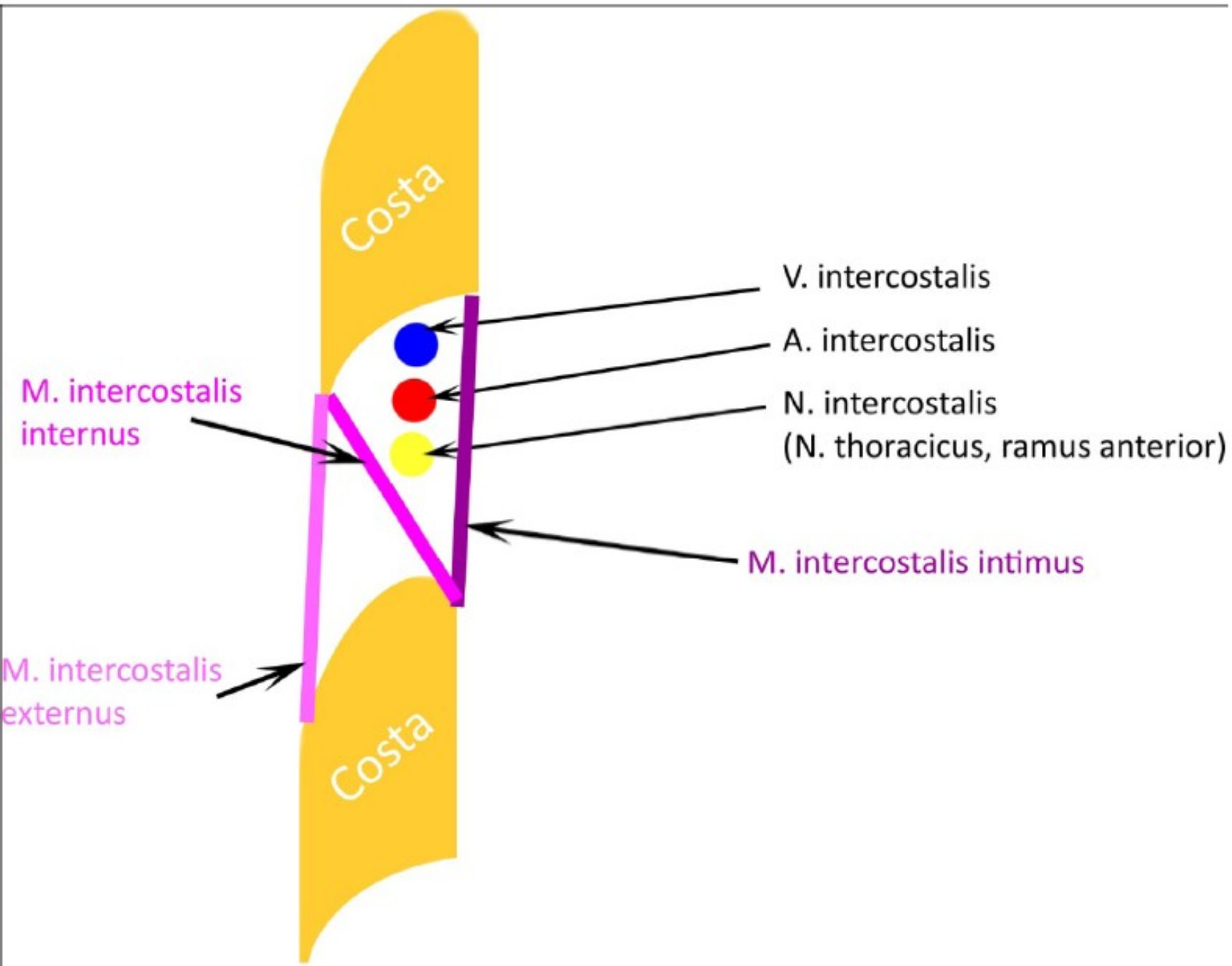
C1

C2

Trigonum suboccipitale

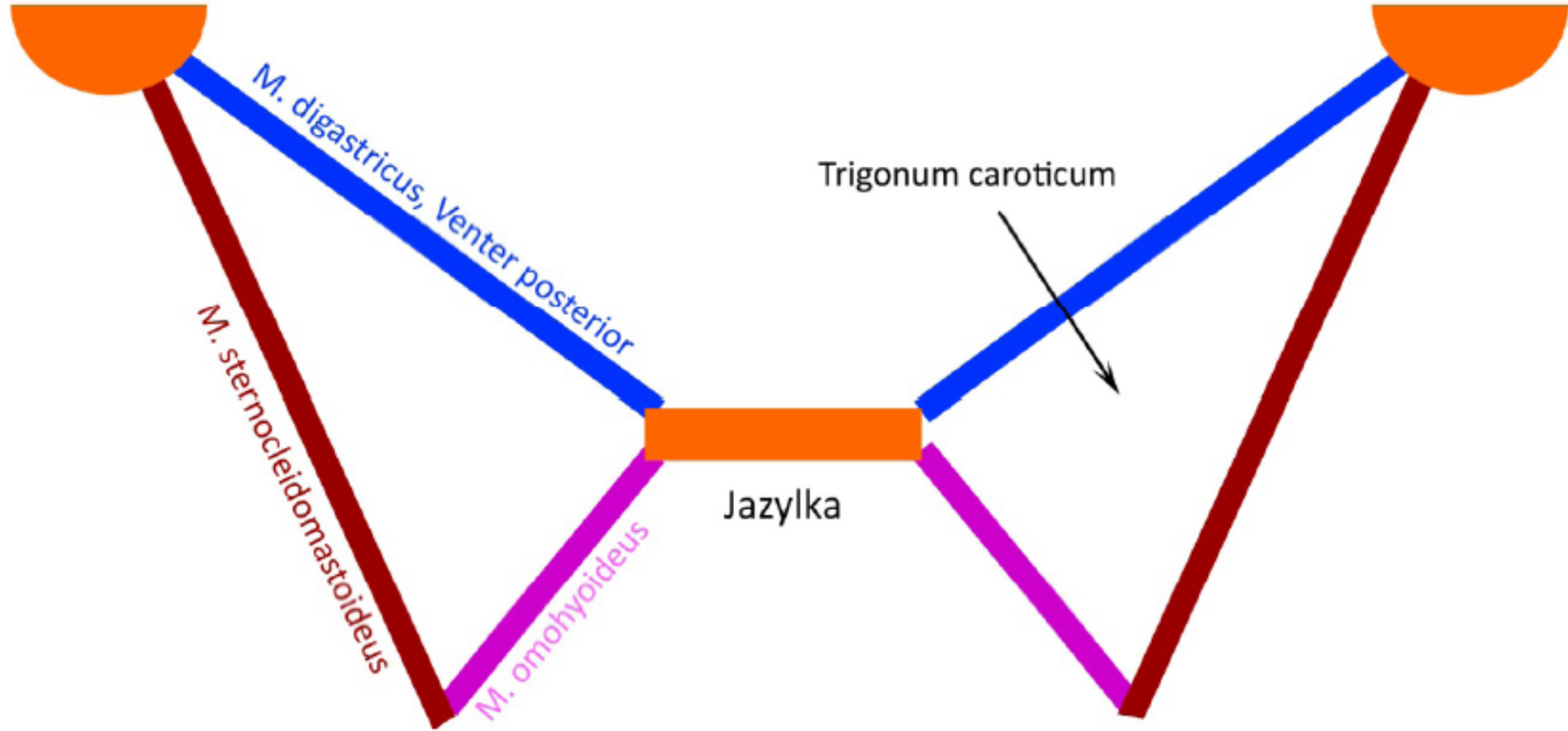
Arteria vertebralis

Průběh nervů a cév v mezižebří



Trigonum caroticum

processus mastoideus



Trojúhelníky na krku

