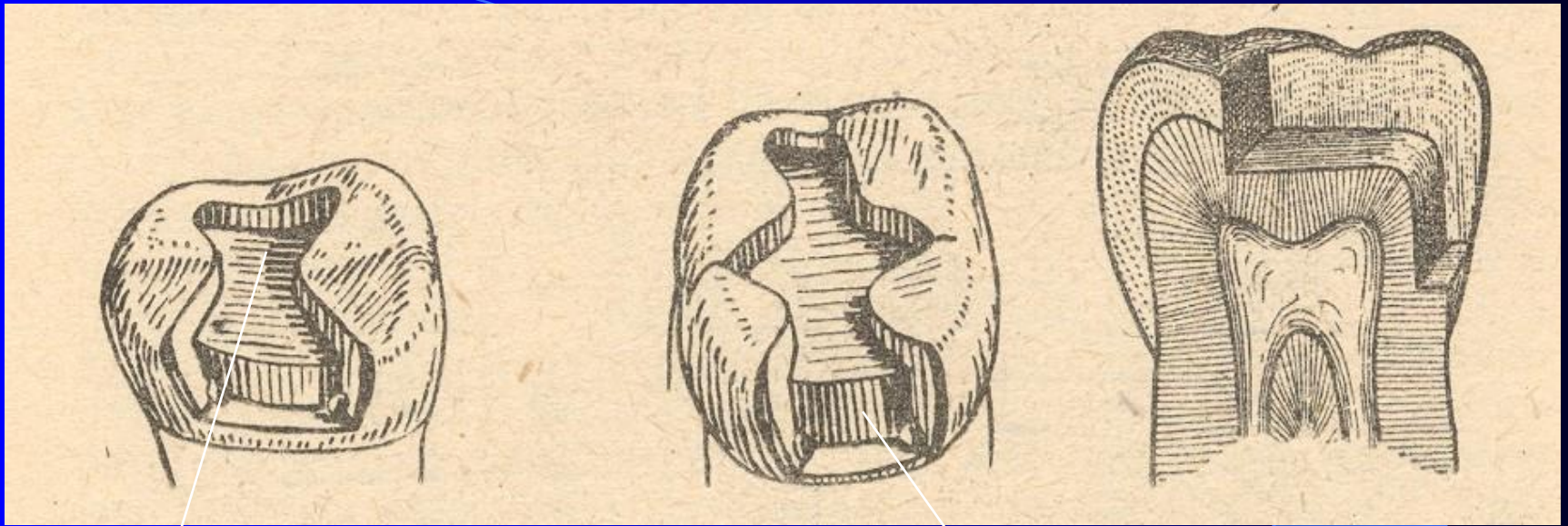


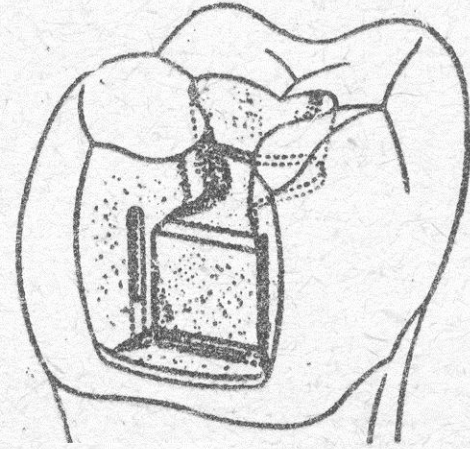
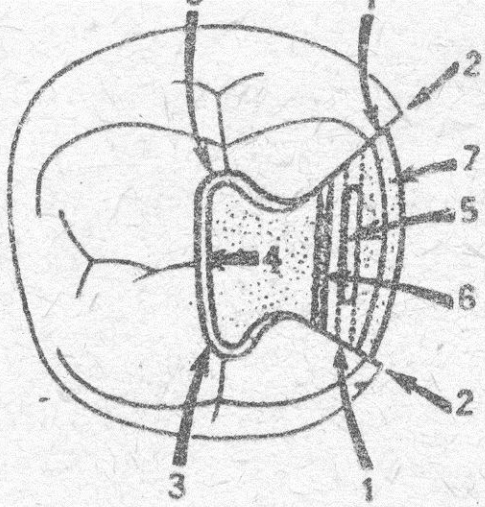
Class II. – modifications for amalgam

- Compound cavity
- Slot
- Large defects - restoration with the replacement of cusps

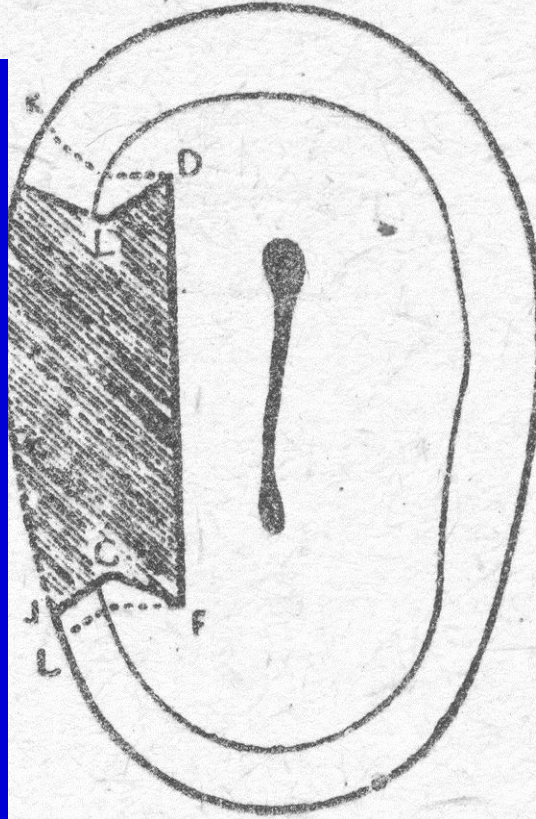


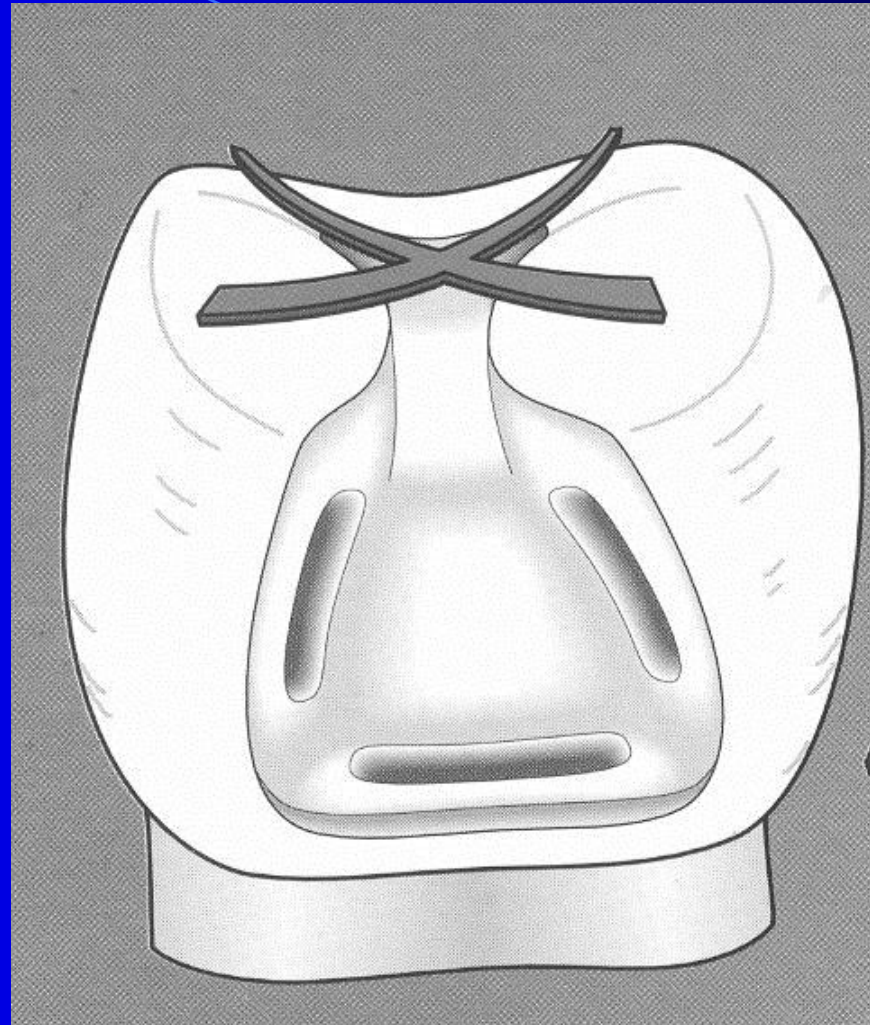
Occlusal cavity

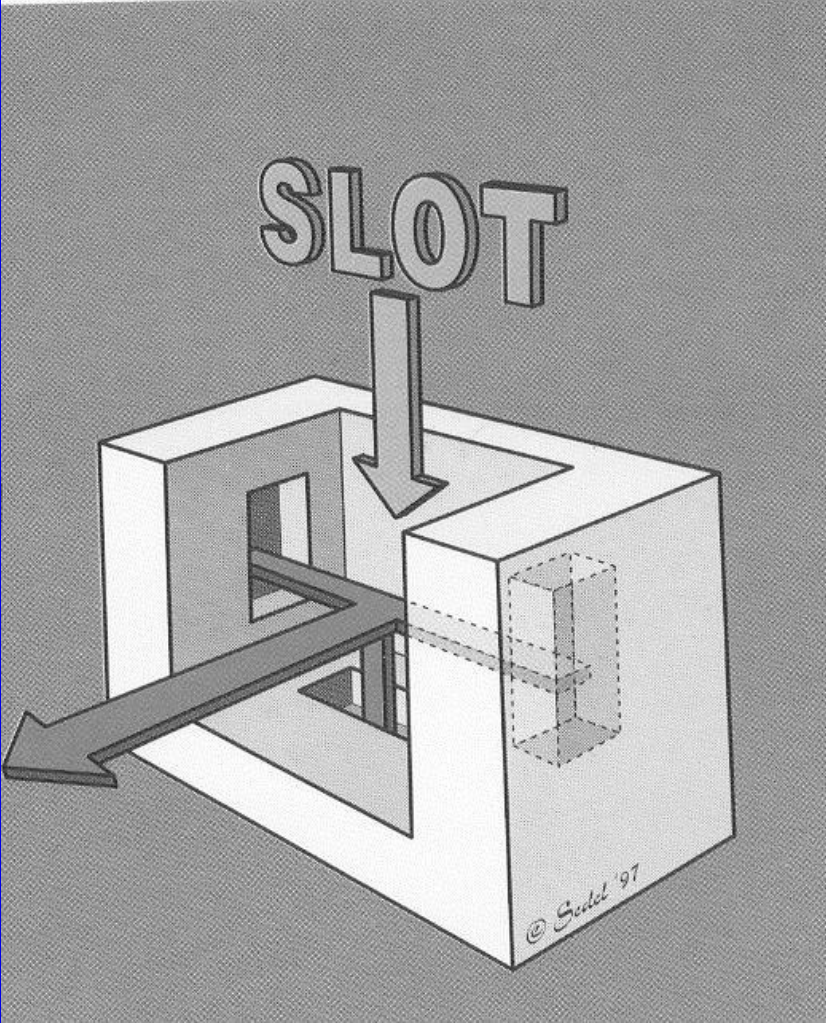
Proximal cavity



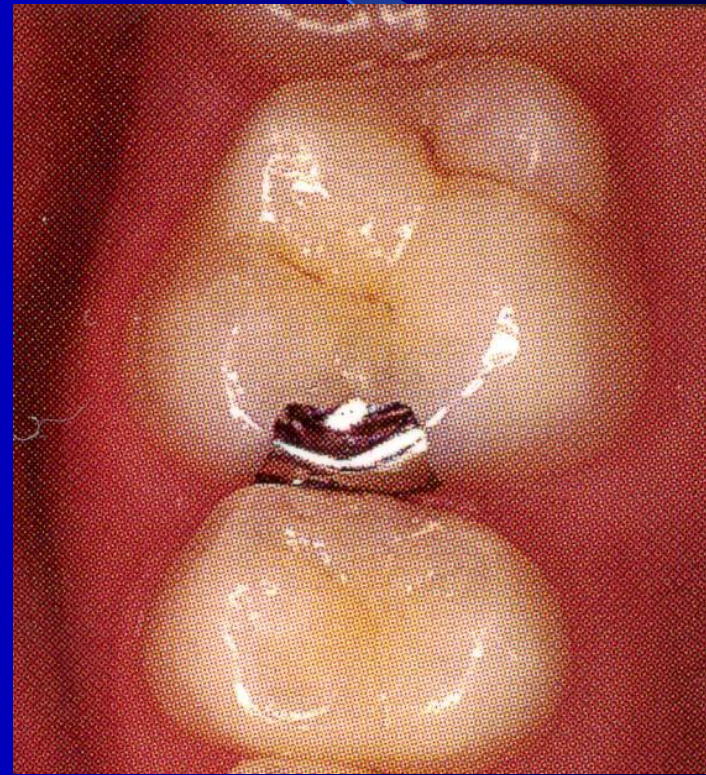Obv. 114. W. 1







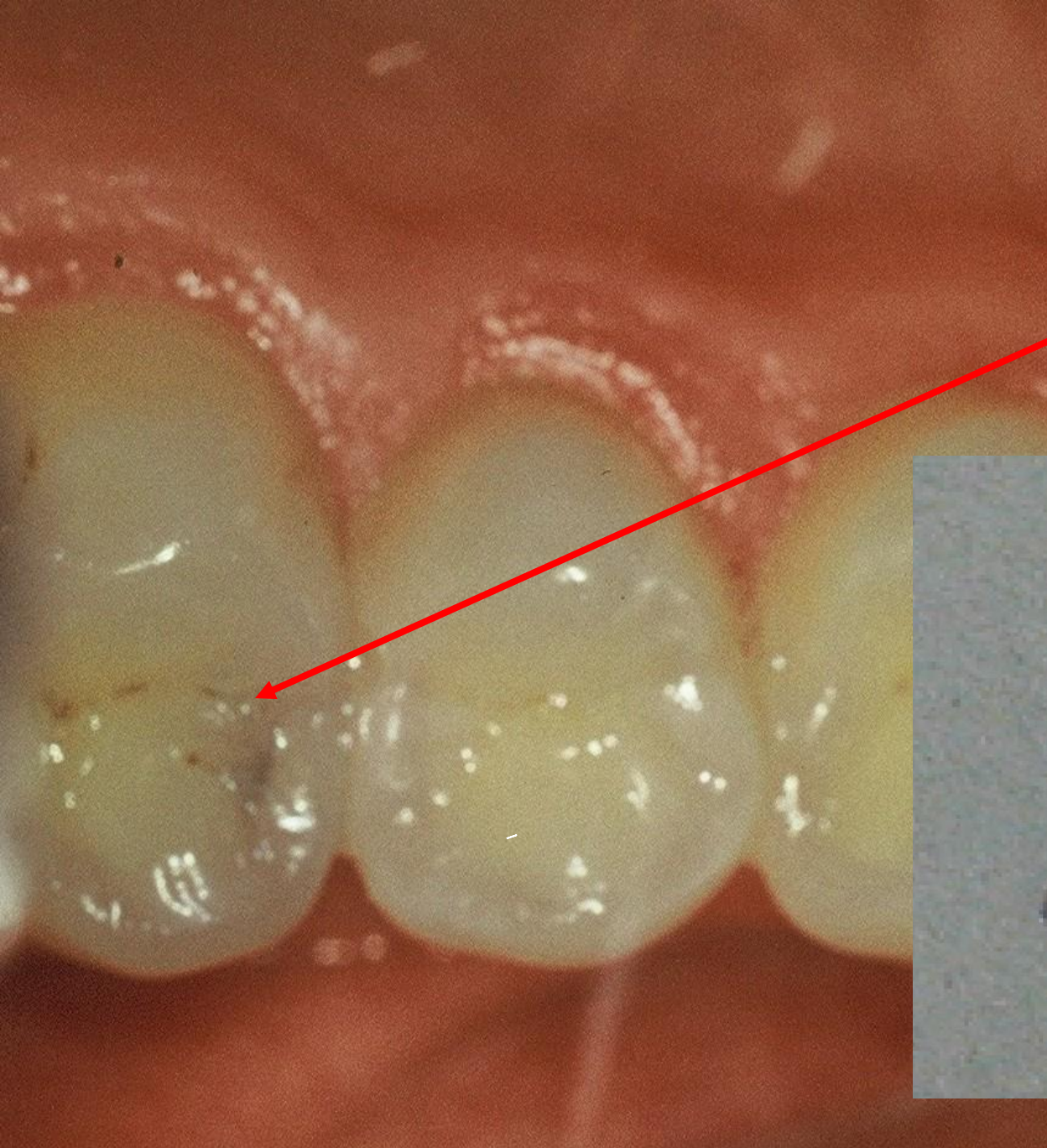
Slot is a cavity that is open on occlusal surface only in proximal ridge.

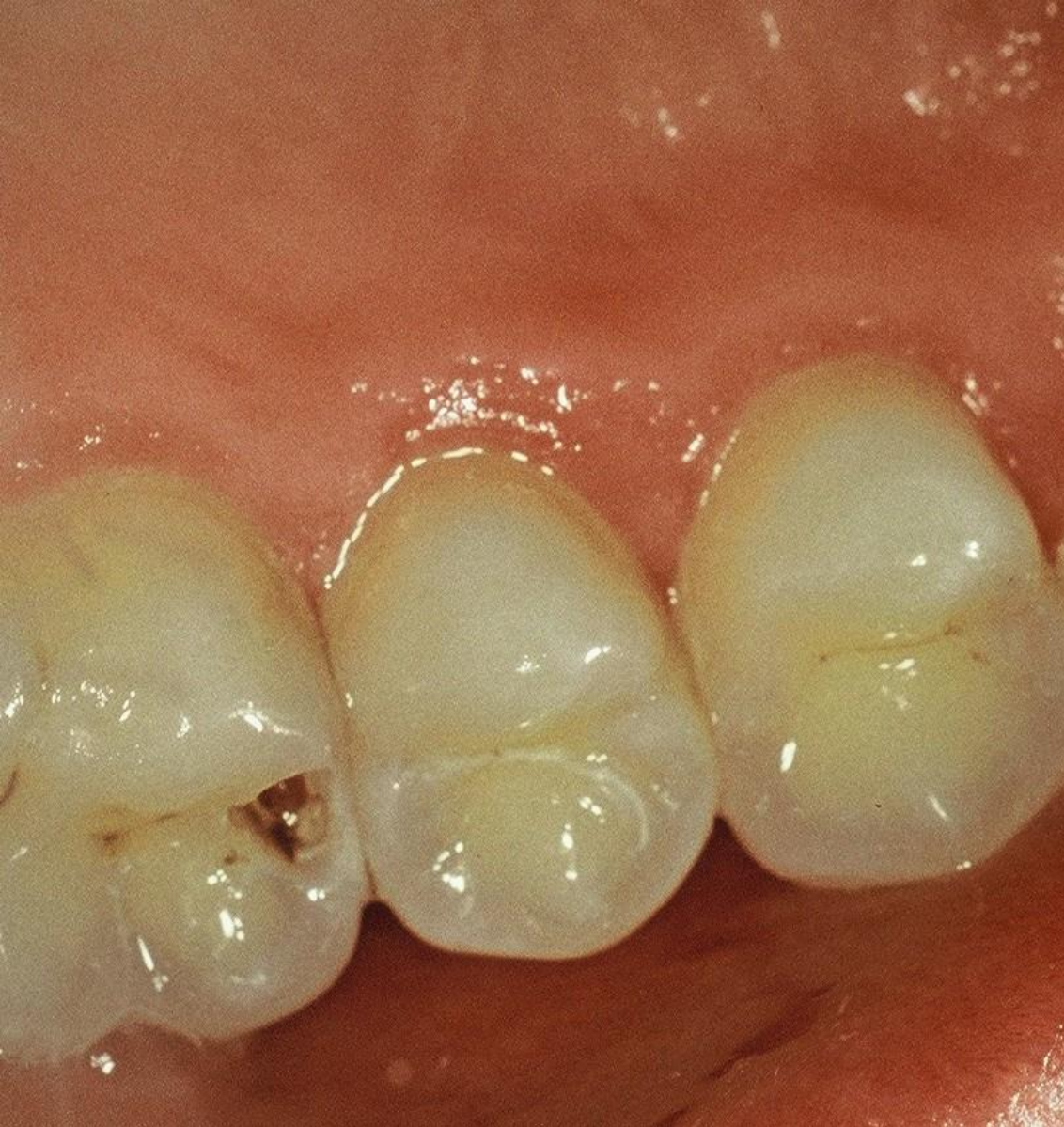


Slot for amalgam

- Access to the caries lesion
 - go through the enamel wall
 - breaking out of the enamel lamella
 - excavation of carious dentin

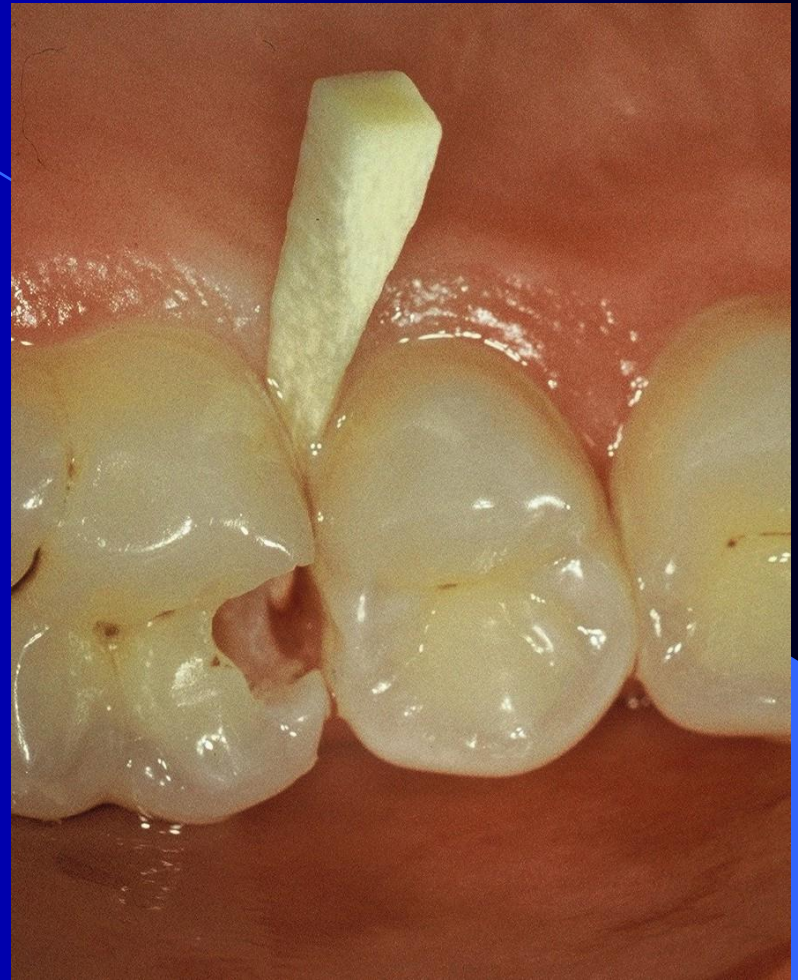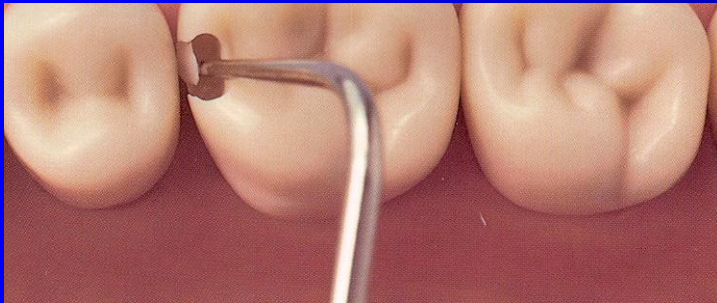Pre op





Access to the cavity

lroubal@med.muni.cz



Slot for amalgam

- Autoretention
 - Grooves
 - Divergency towards gingiva
 - Convergency and divergency of axial walls in horizontal plane
- Rule of the gingival wall

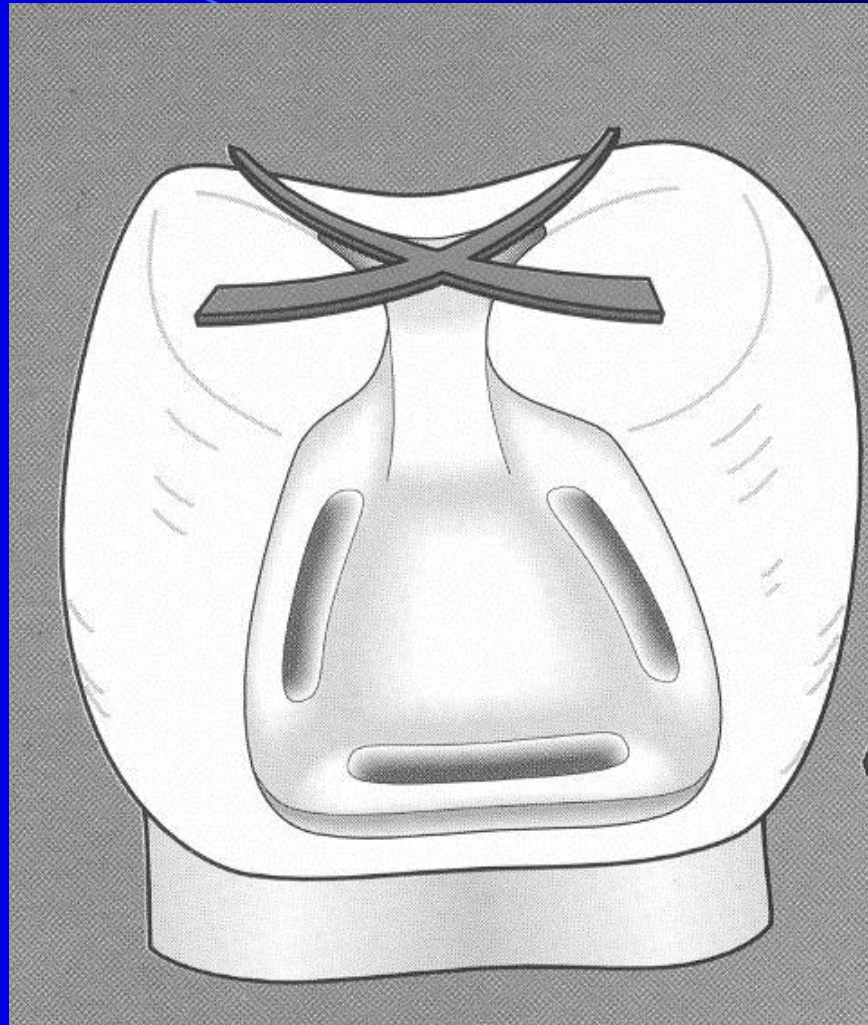
Slot for amalgam

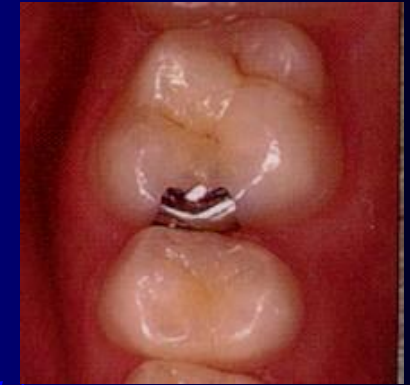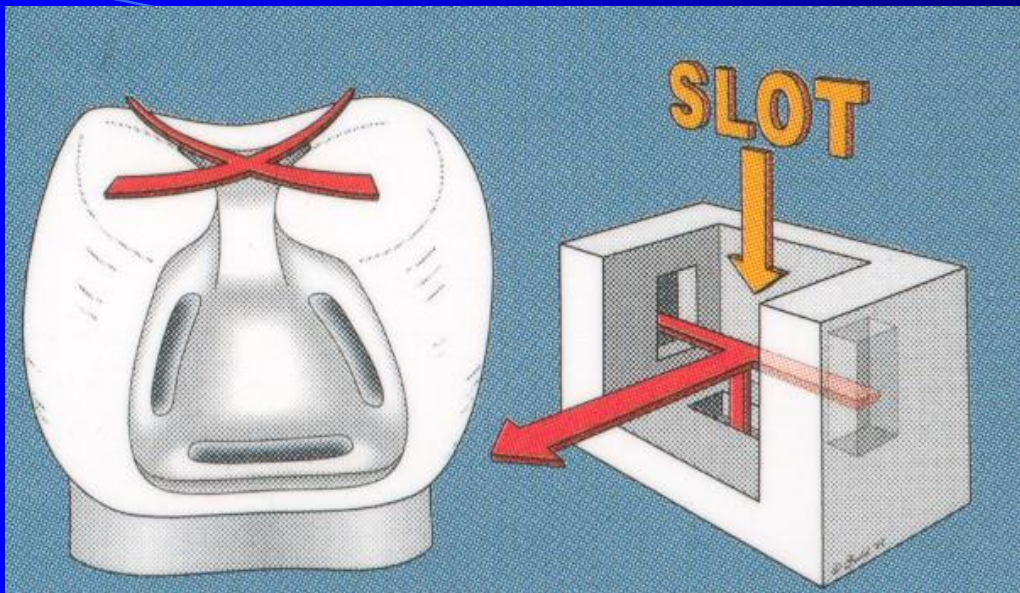
- Rule of the gingival wall

90° angle towards the pulpal wall

outer line beveled if in enamel

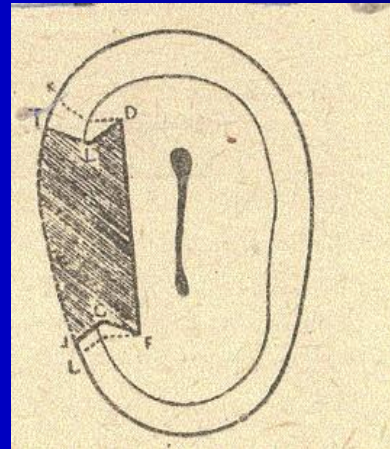
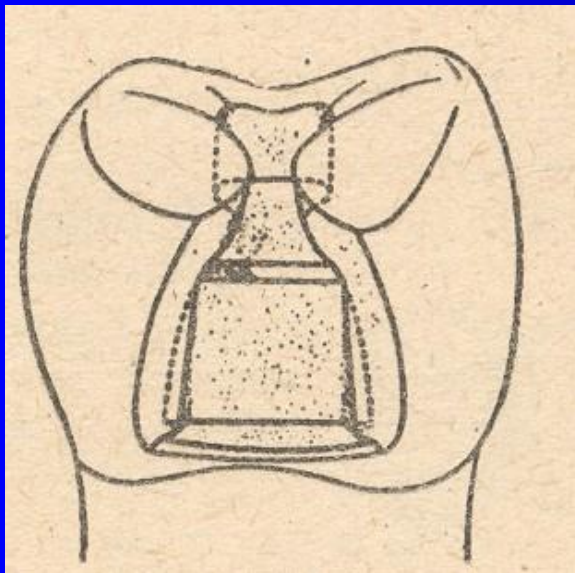
horizontal groove





Sedelmayer

*Sedelmayer J. Amalgám – zapomenuté řemeslo.
Brno, 2000.*

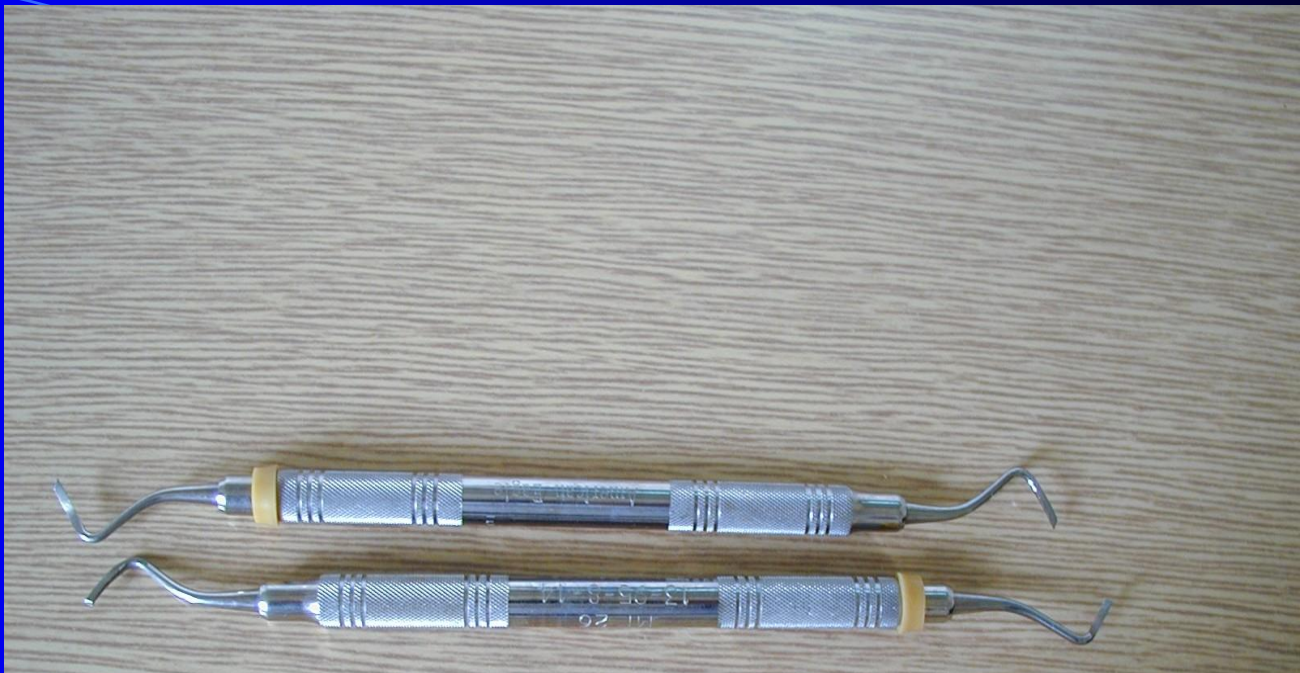


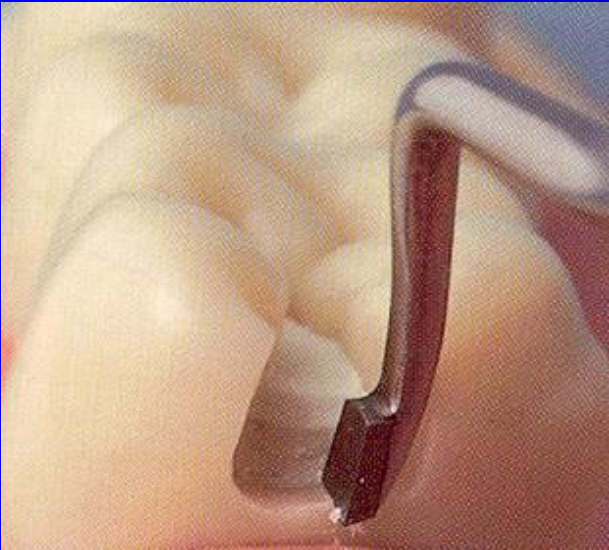
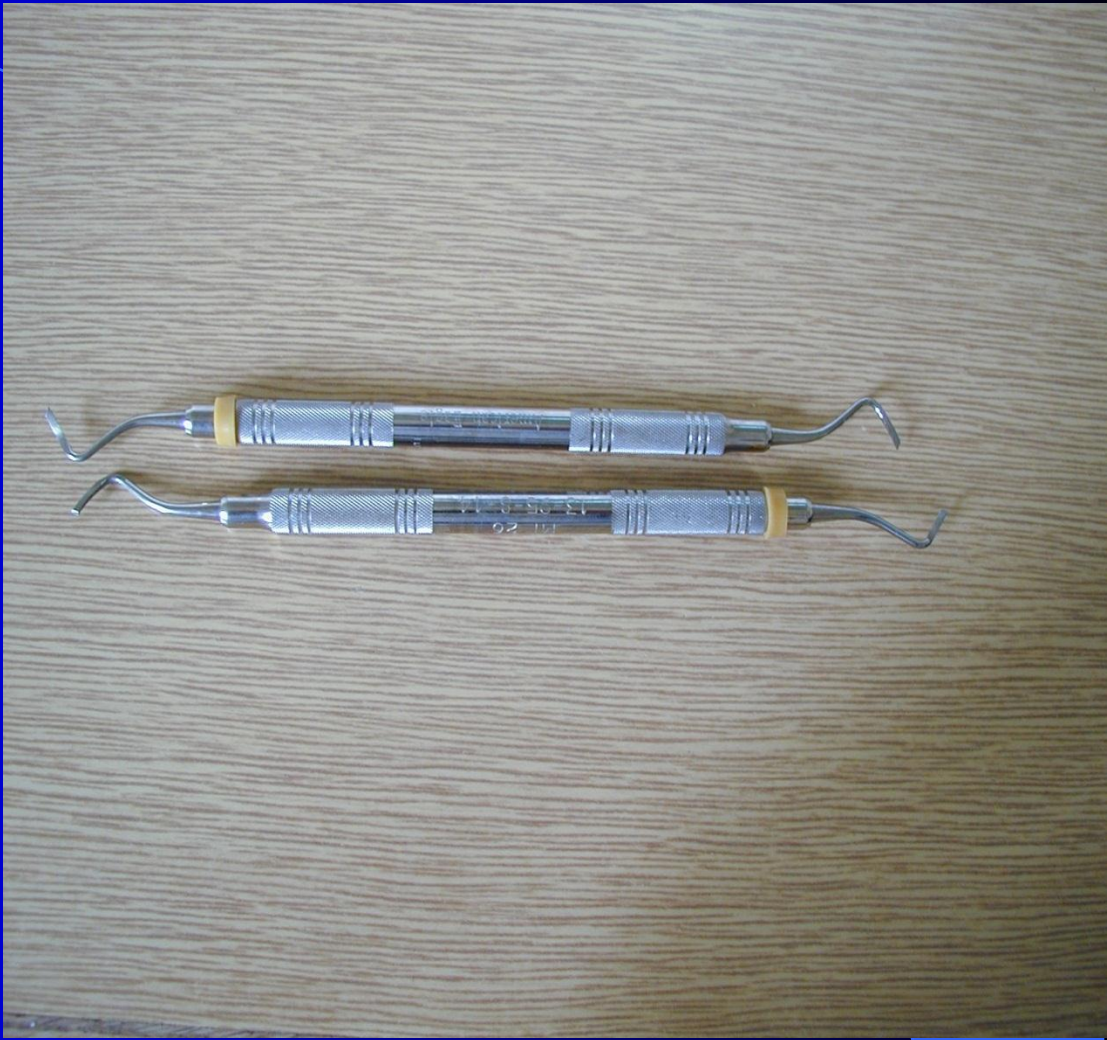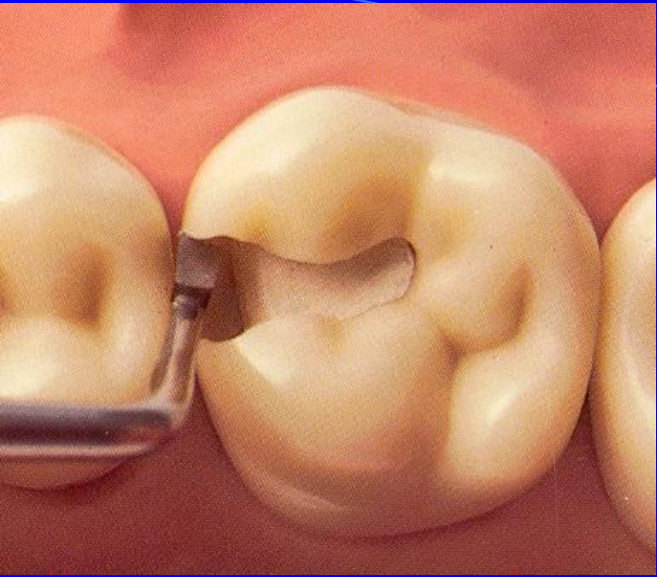
Bažant V.

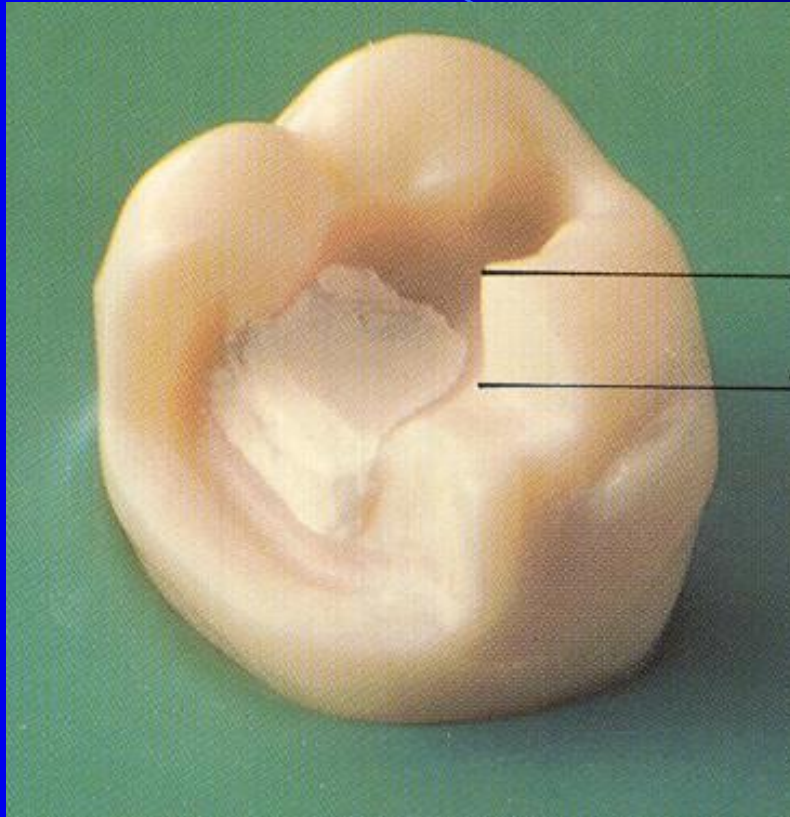
Konservační zubní lékařství, SPN Praha, 1962.

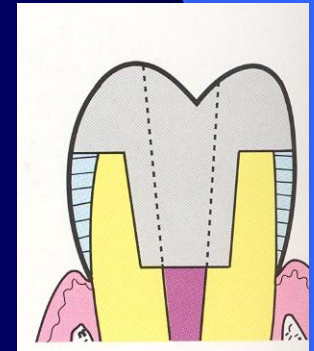
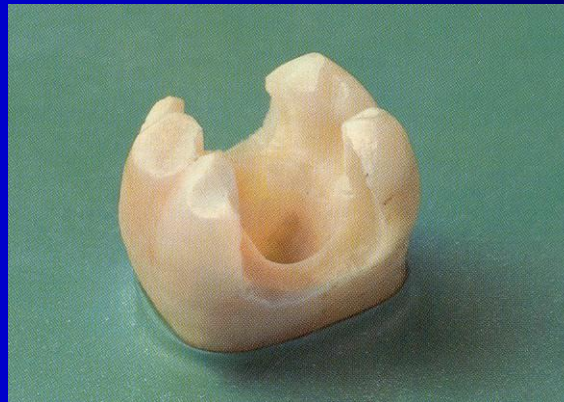
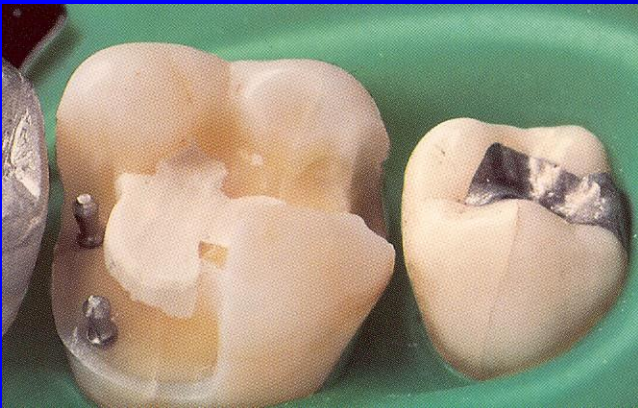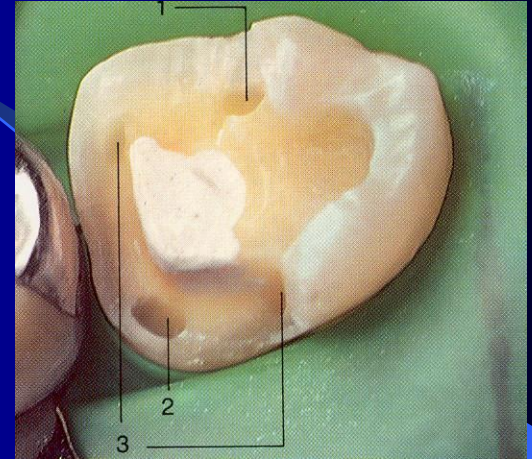
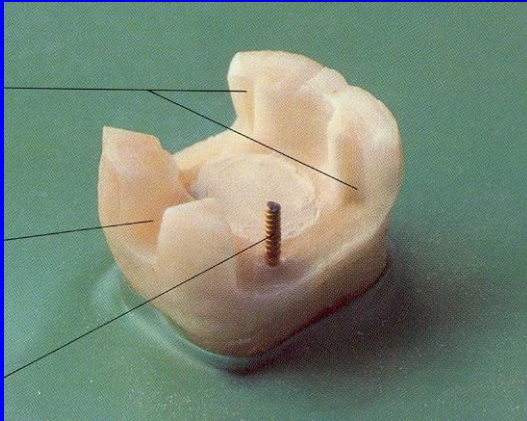
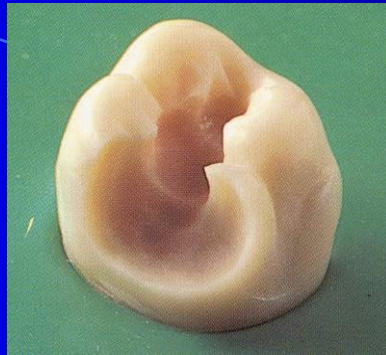
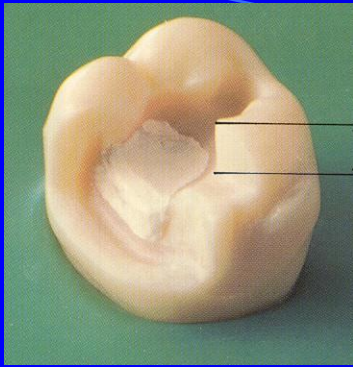
Slot cavity

- Limited on proximal ridge
- Axial walls are divergent towards gingiva
- The proximal box has a typical picture of fish tail
- There are grooves:
 - One horizontal in gingival wall
 - Two vertical in axial walls

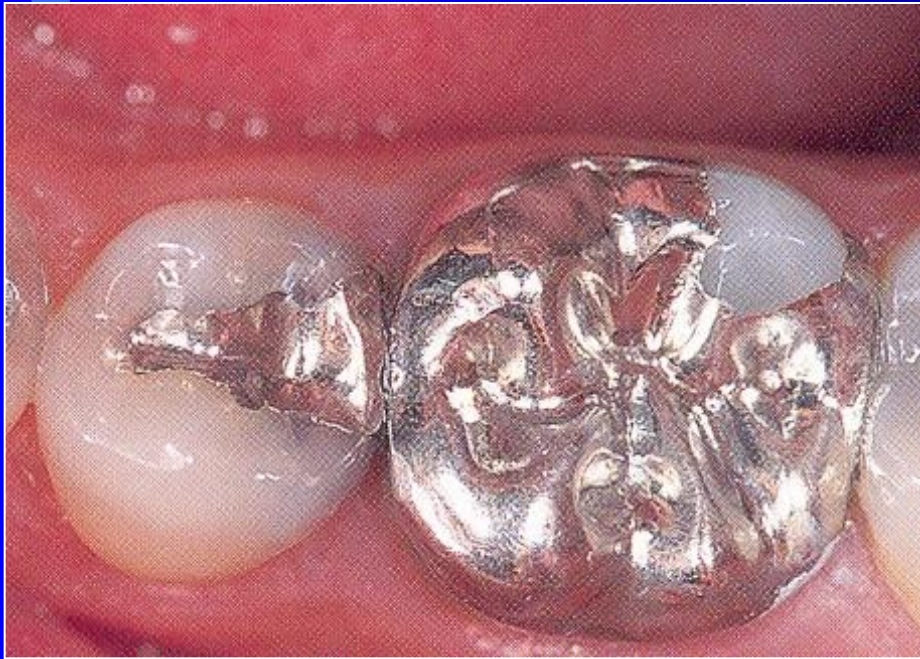








Large amalgam restoration - overlays



Rules

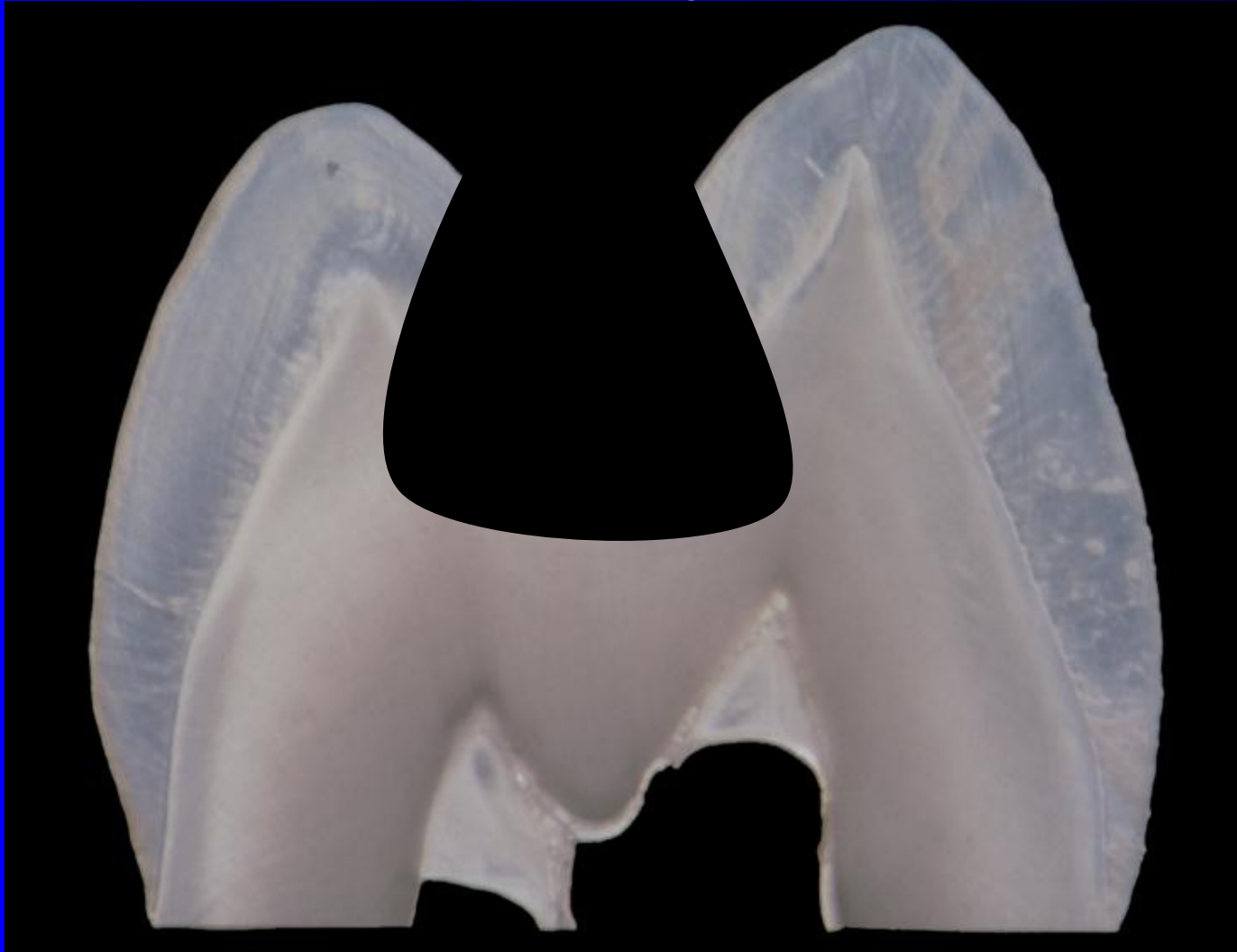- Clear and sharp outlines

- Autoretention
 - Cavities - pins
 - Grooves

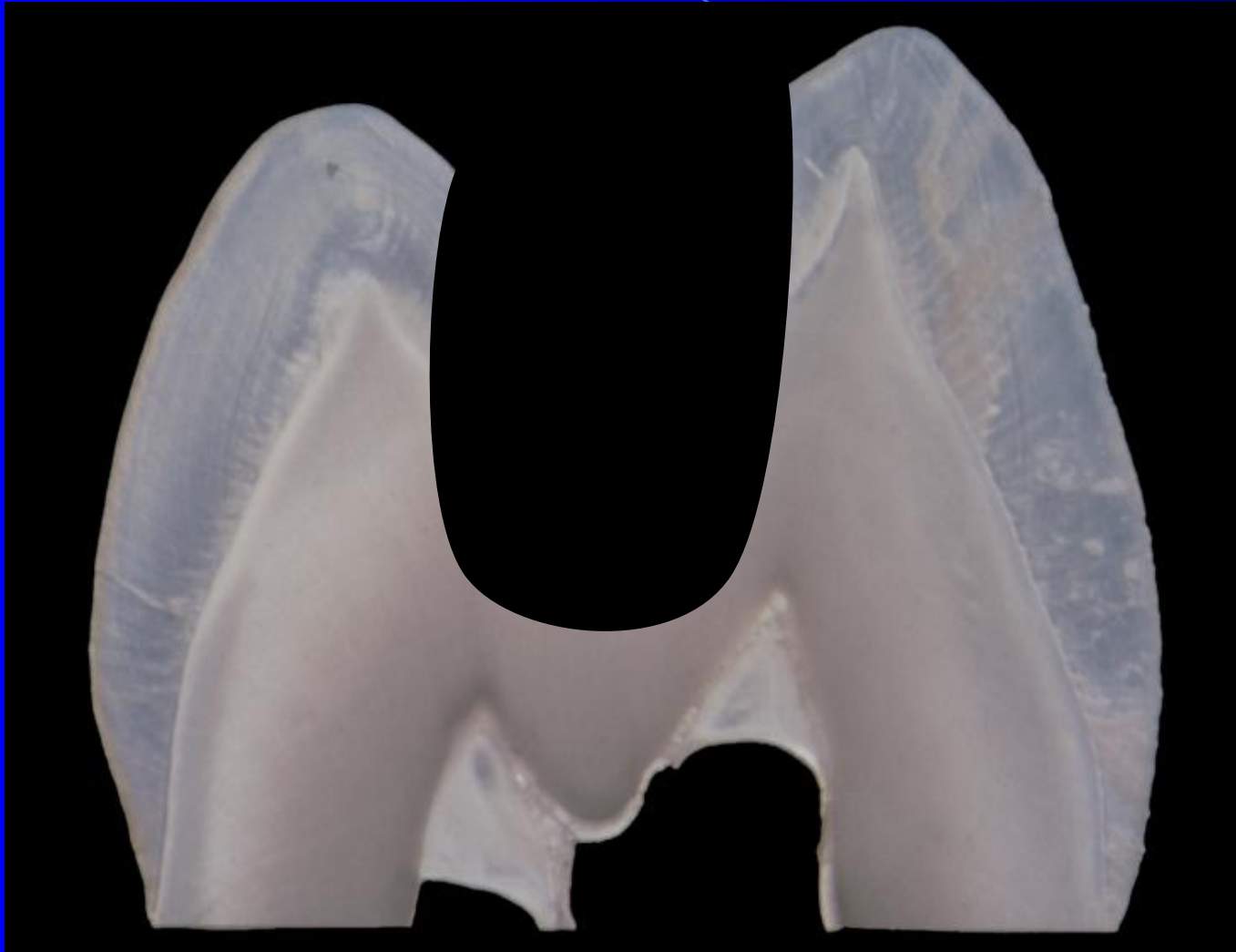
Preparation for adhesive materials

- No extension for prevention (adhesion)
- No grooves
- No undercuts
- Rounded box
- Acid etching
- Priming bonding
- Placement of the material using matrices.

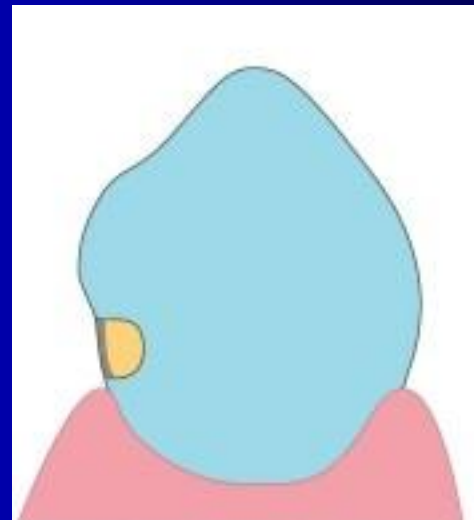
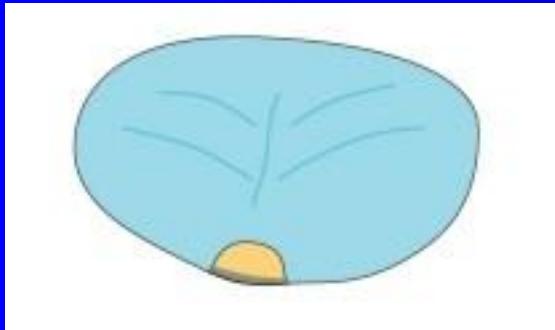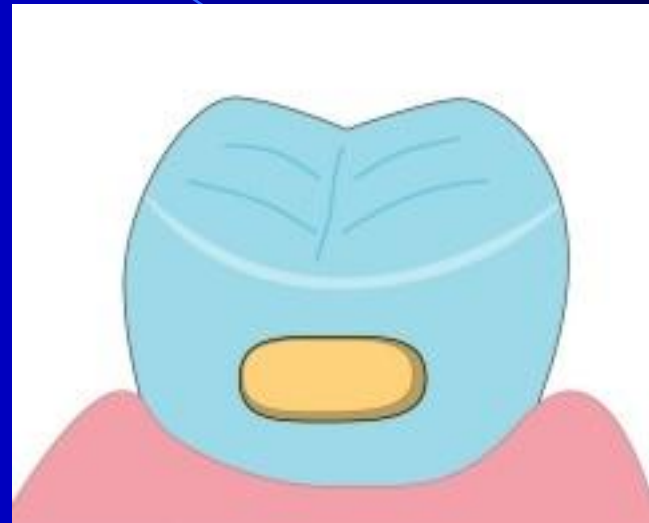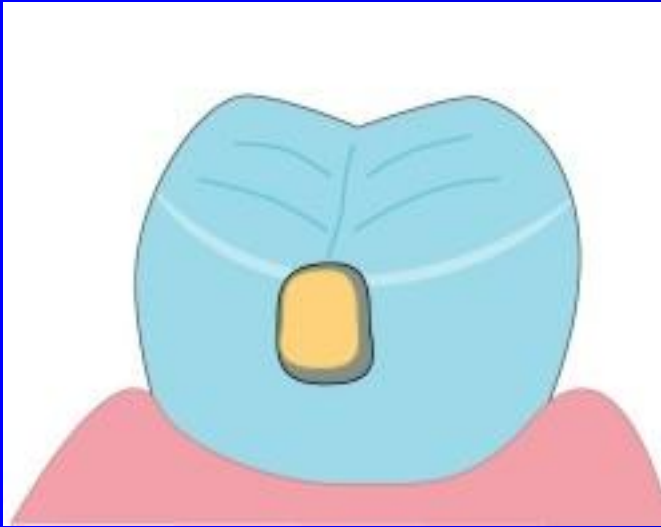Cavity for amalgam

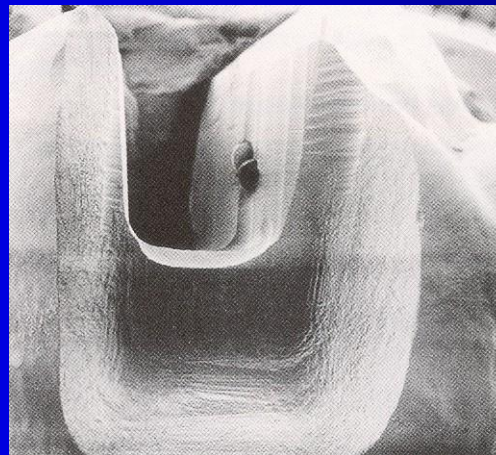
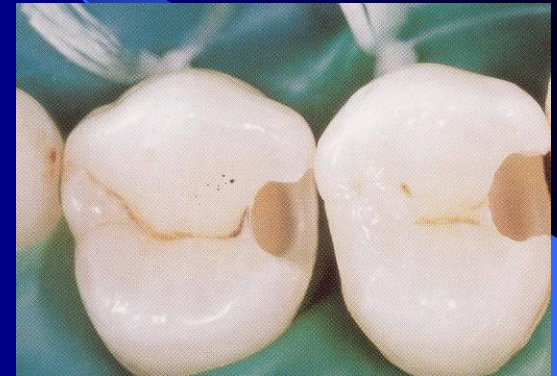
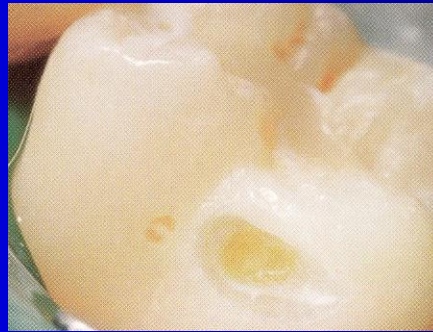
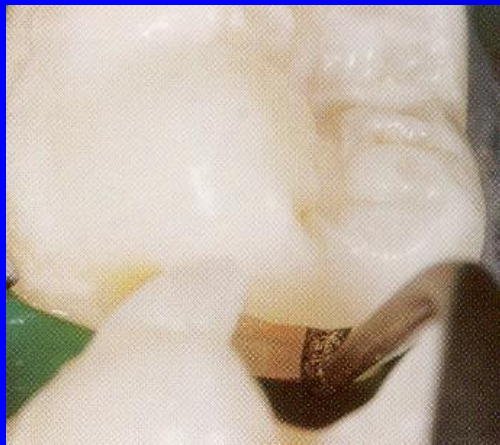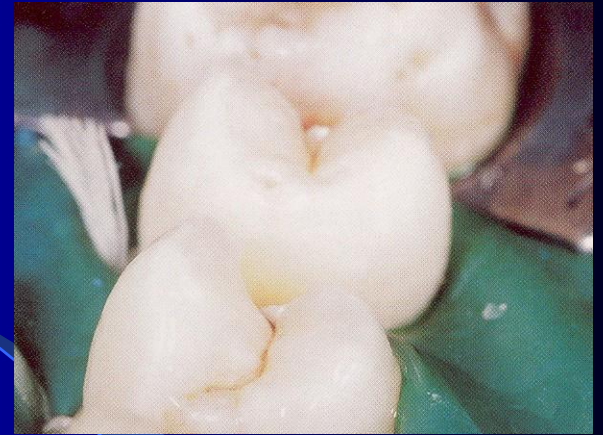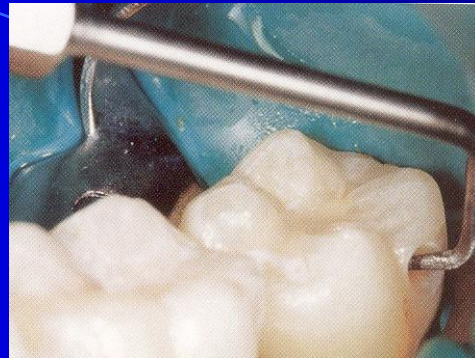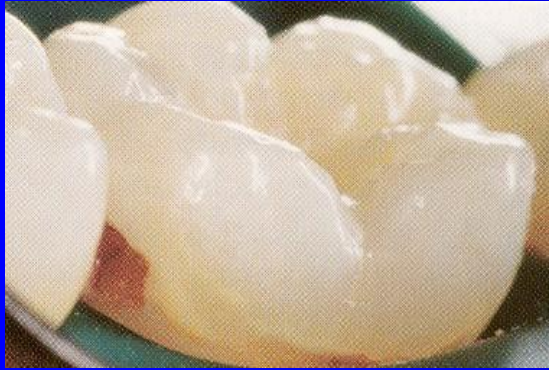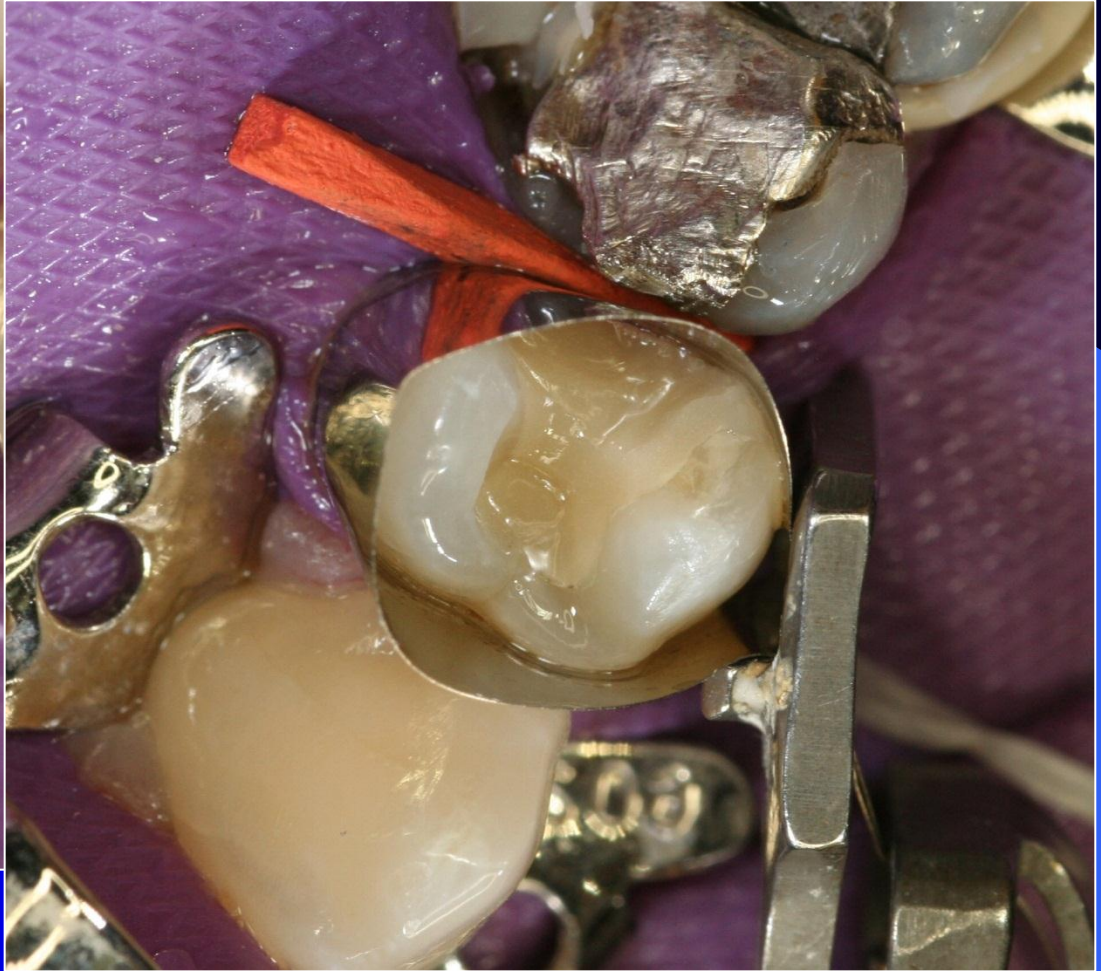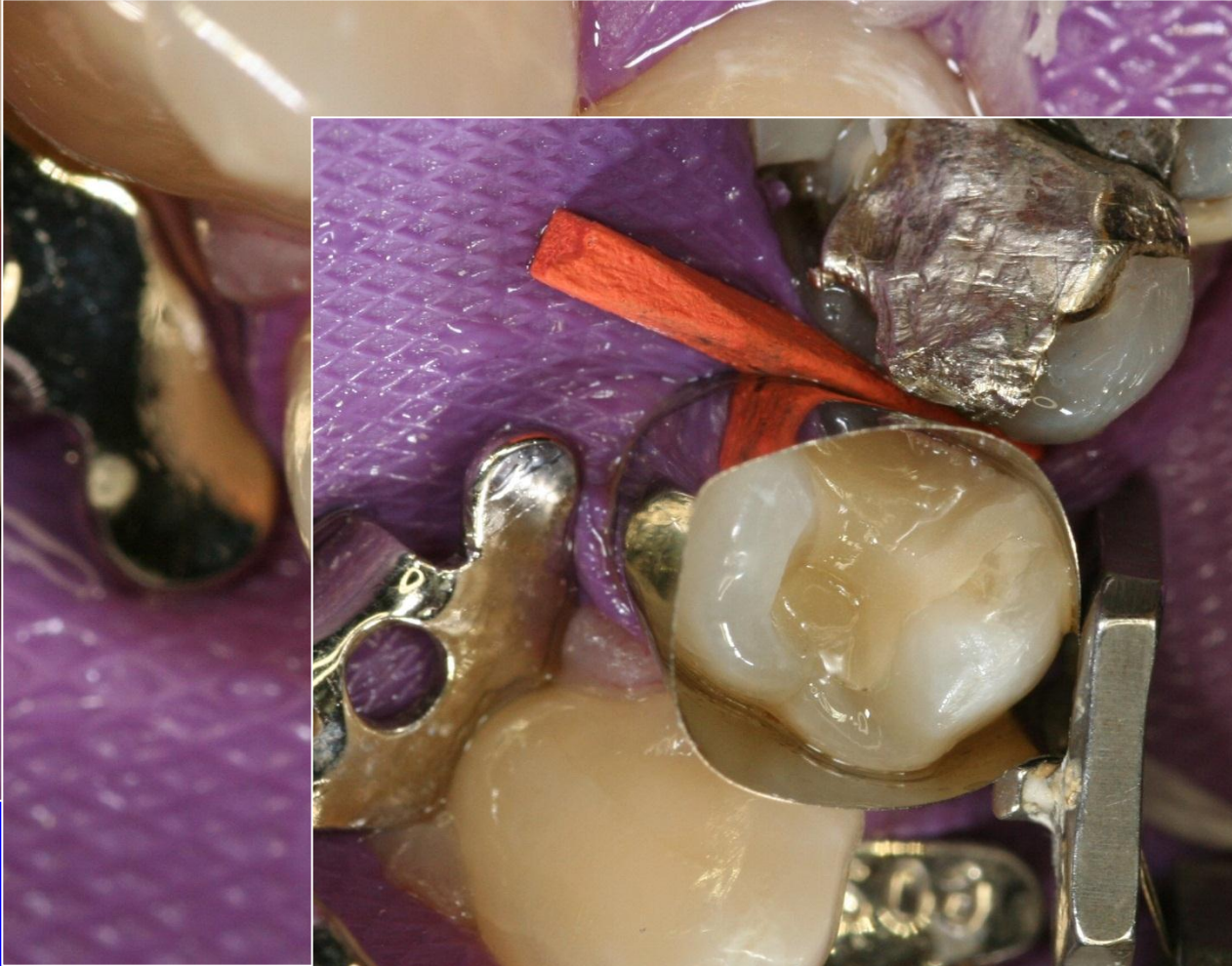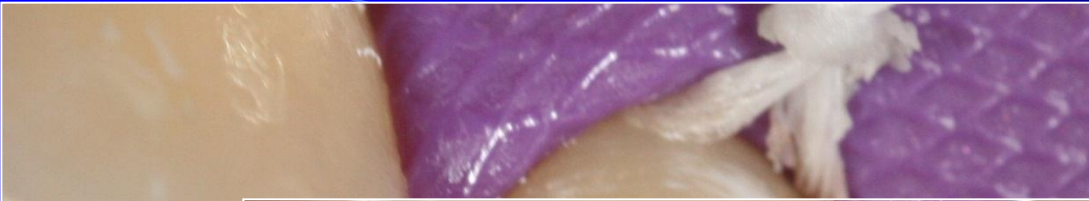Cavity for composite

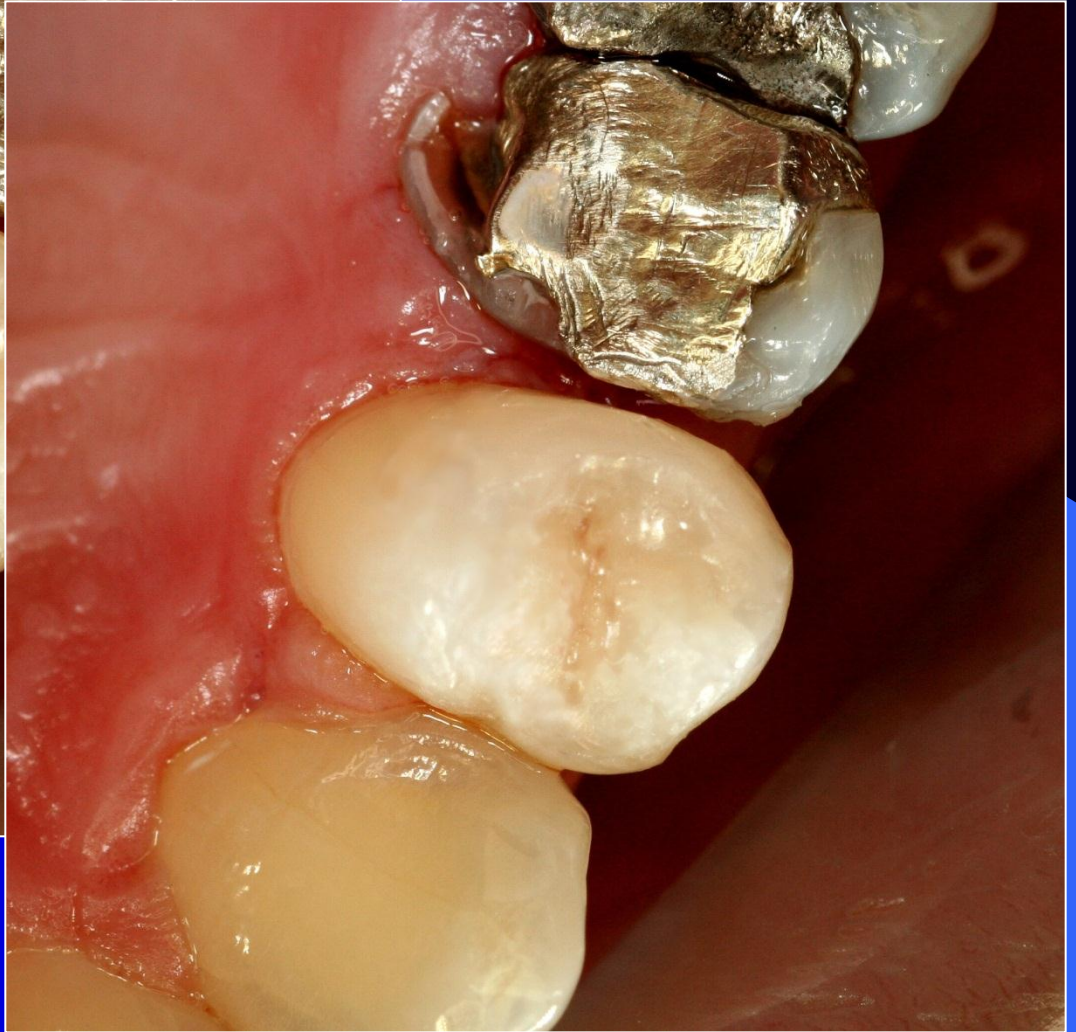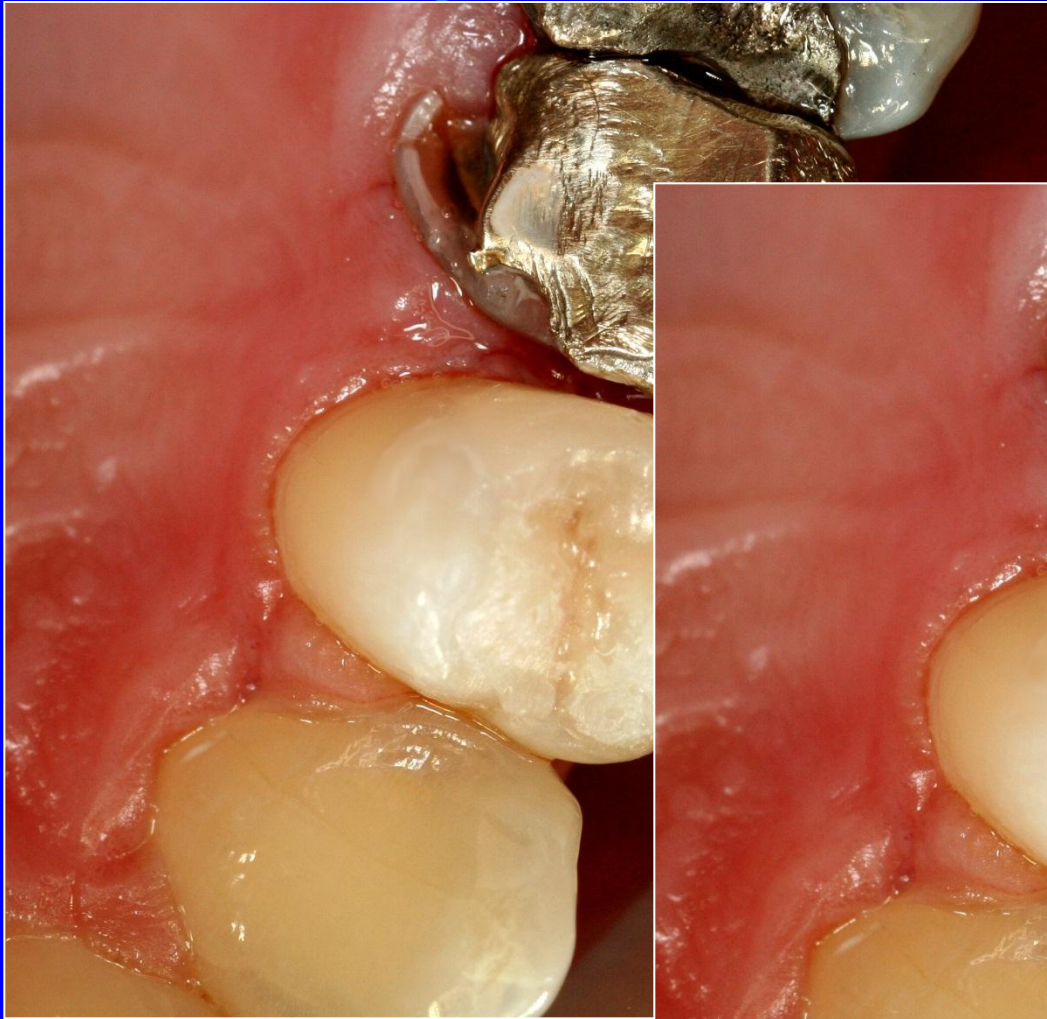


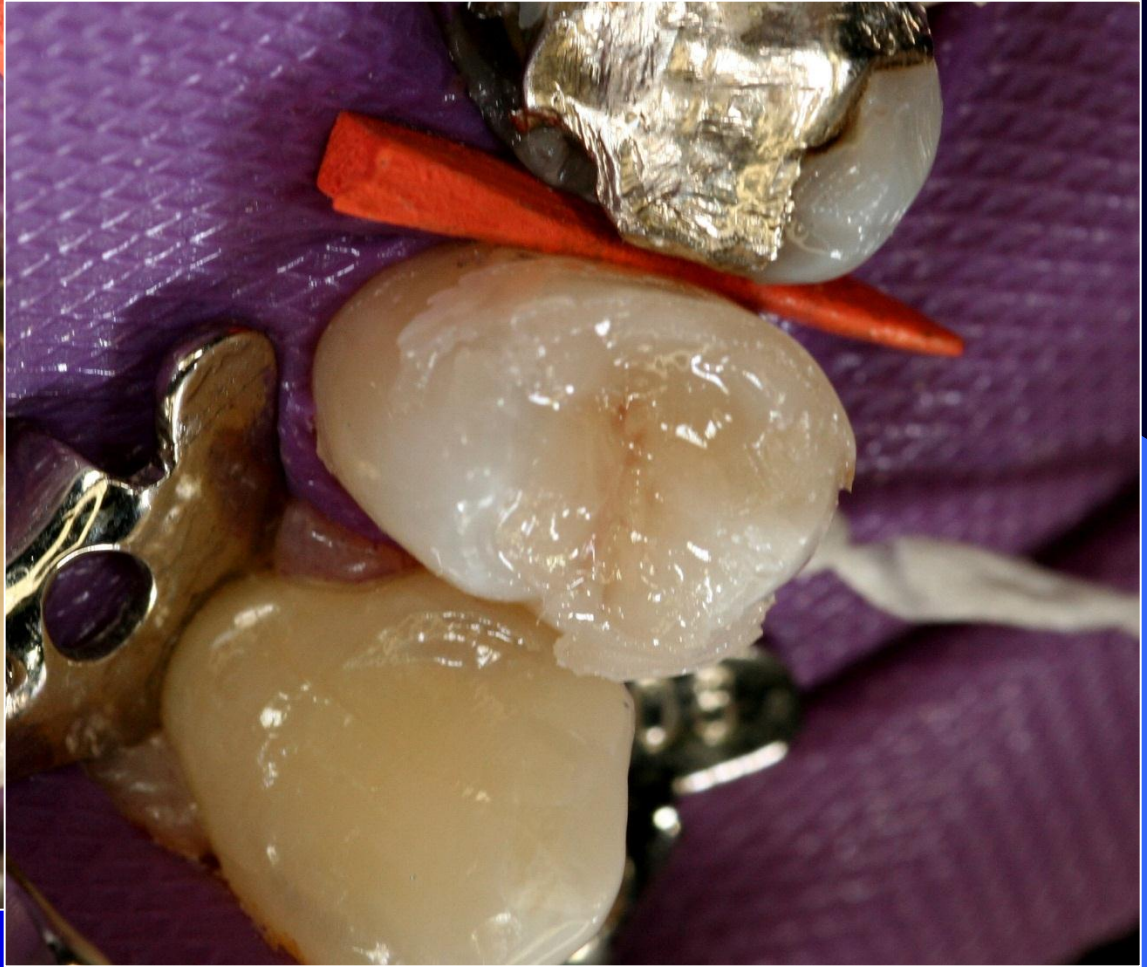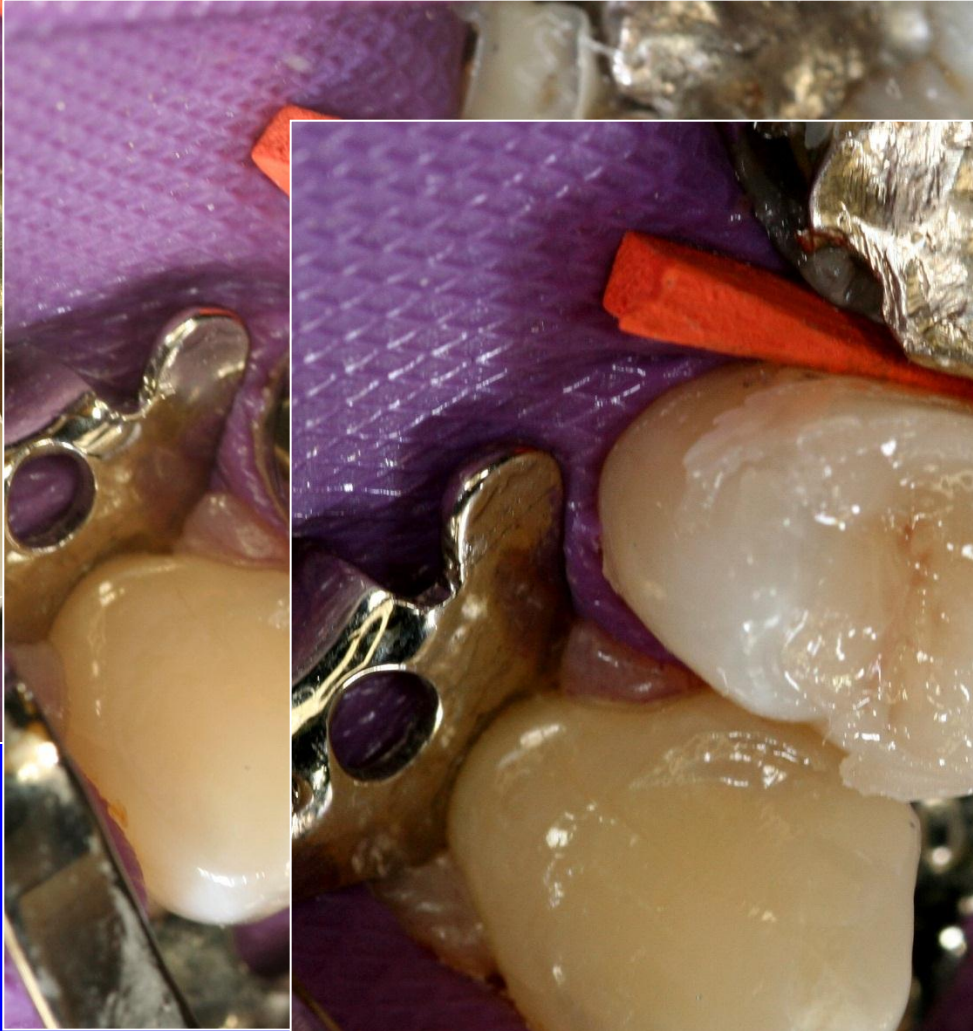
Alternative preparation - slot



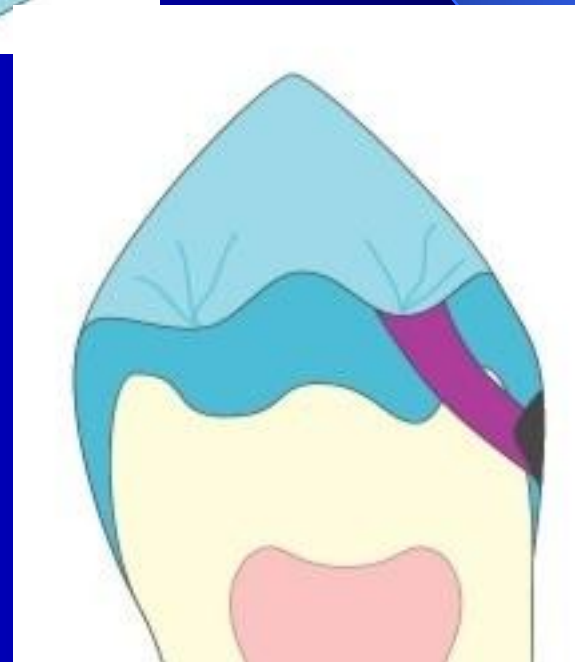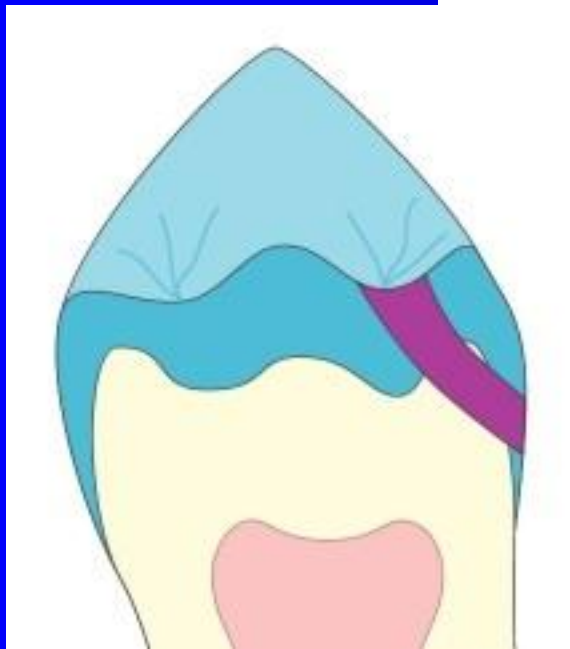

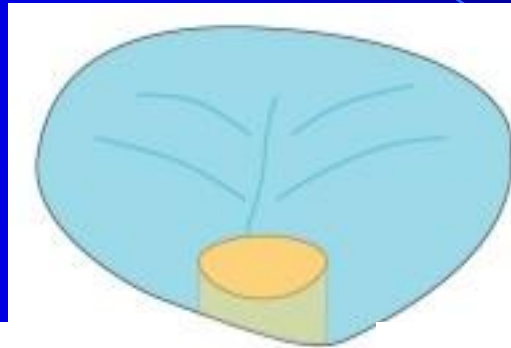



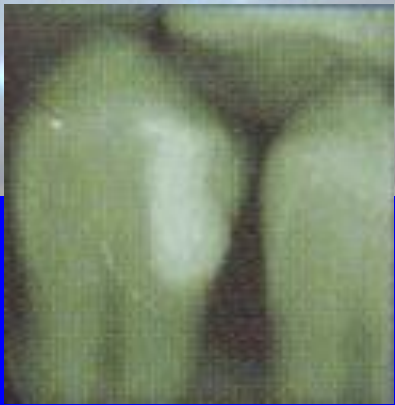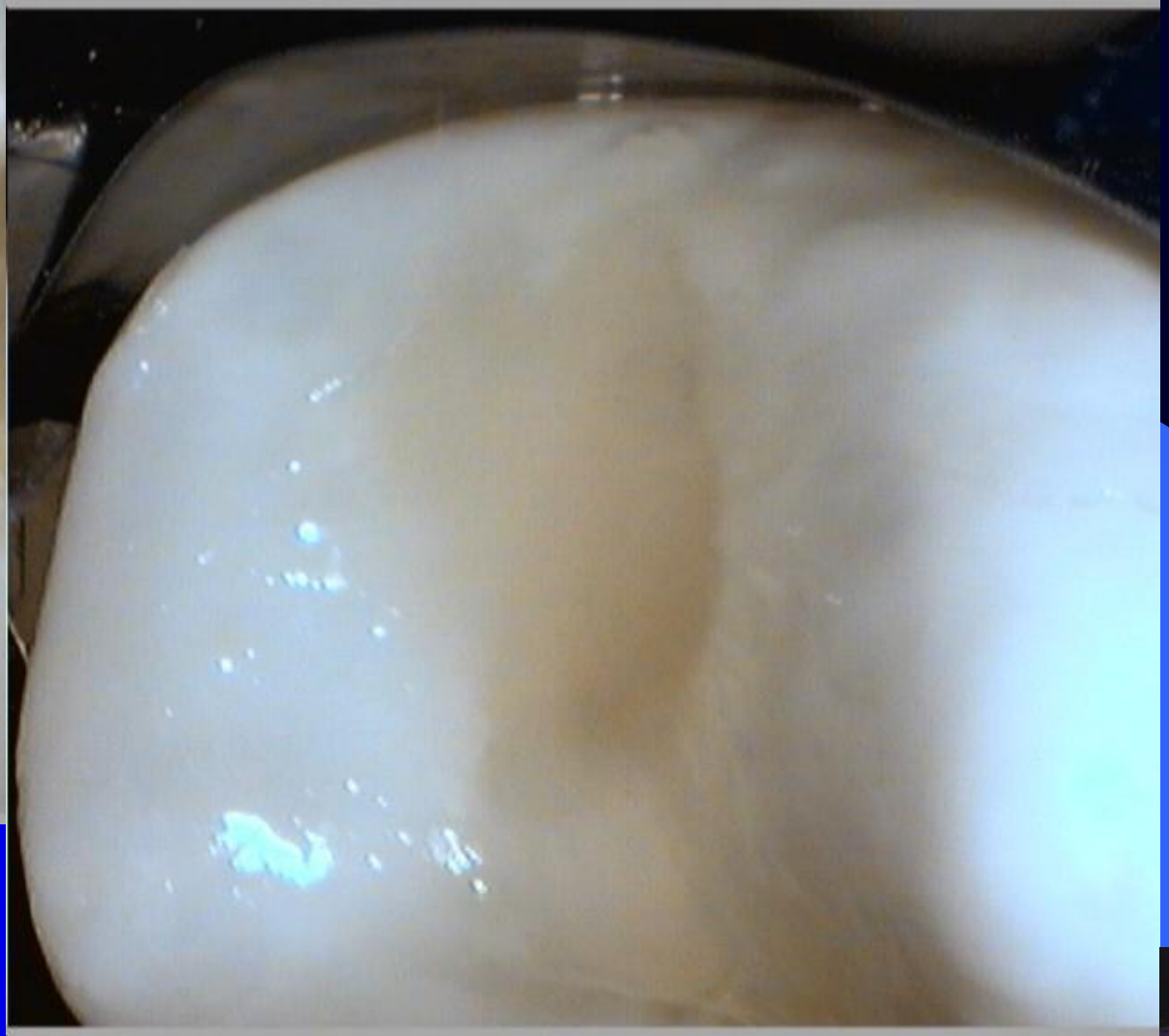


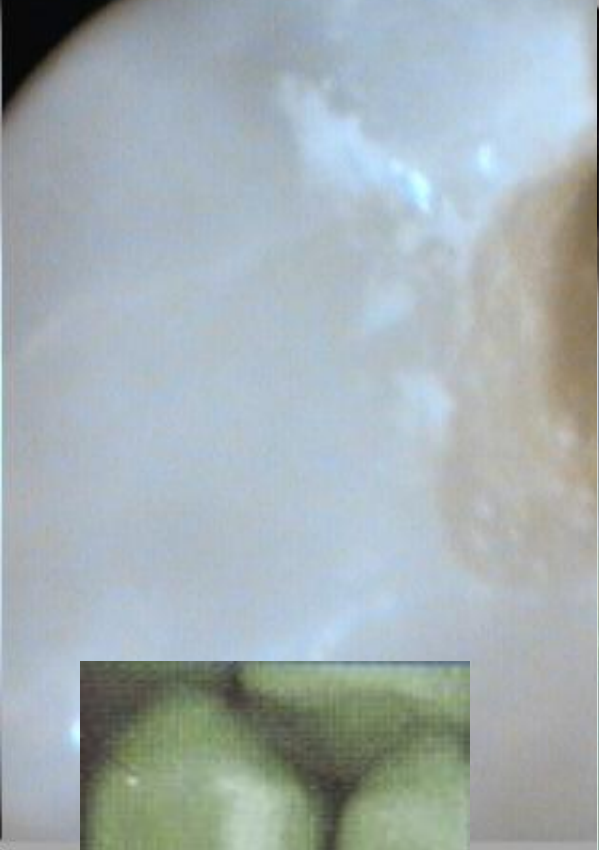

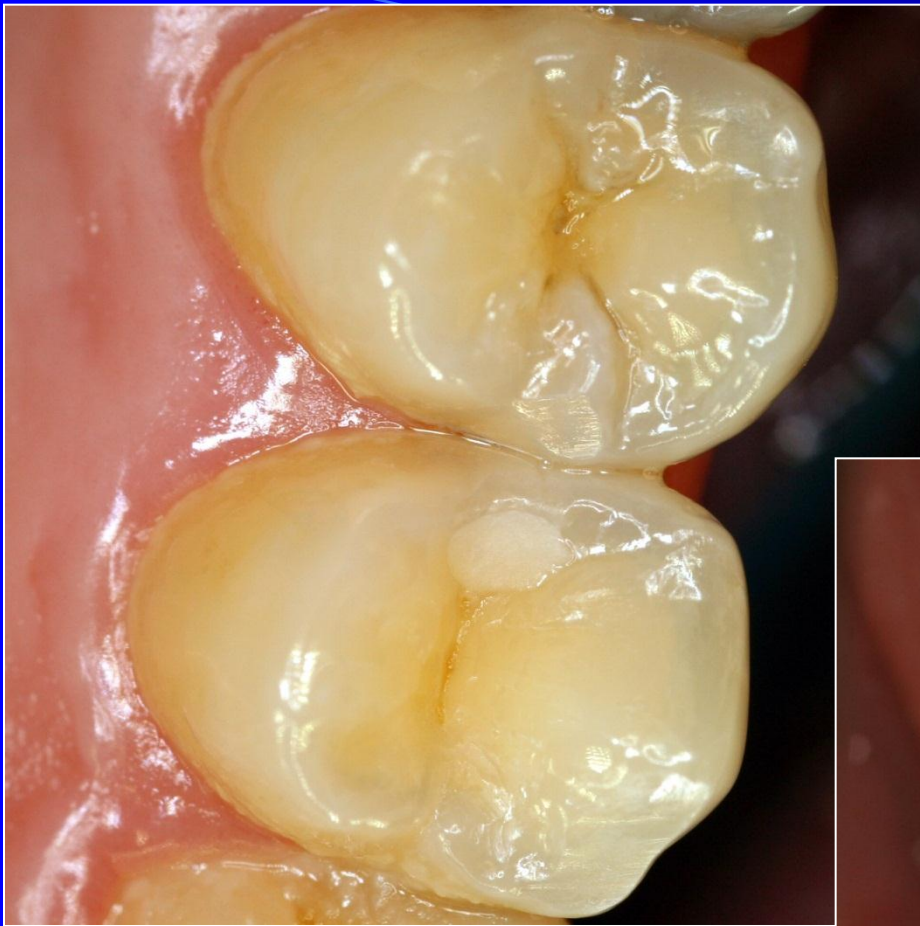Tunnel preparation



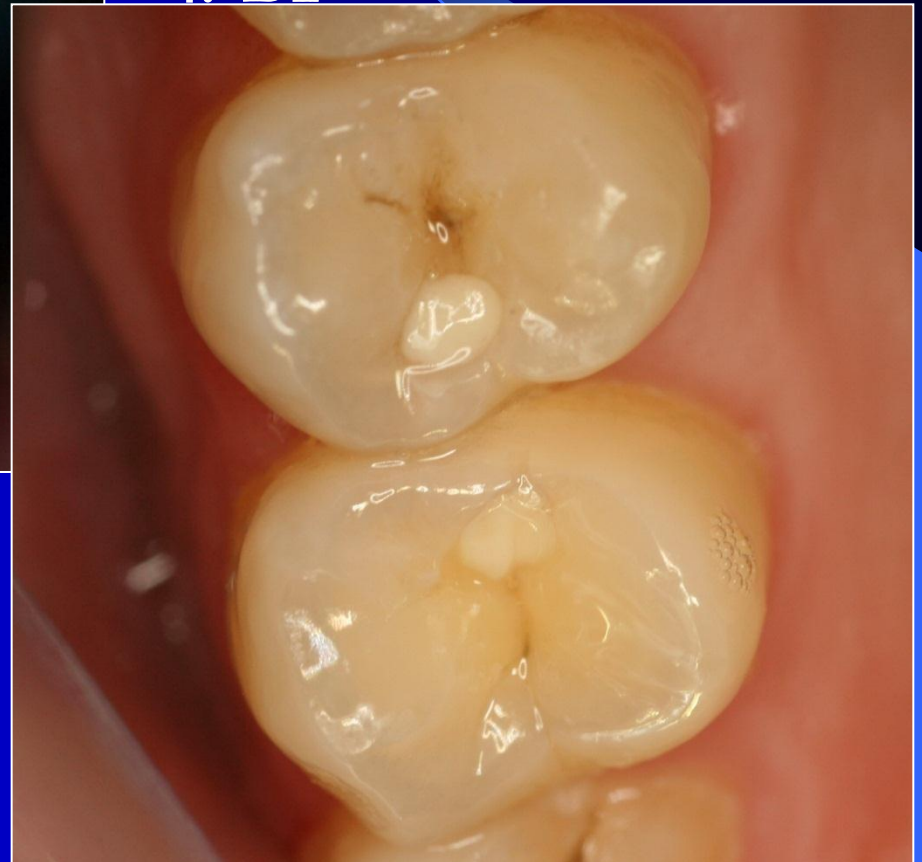





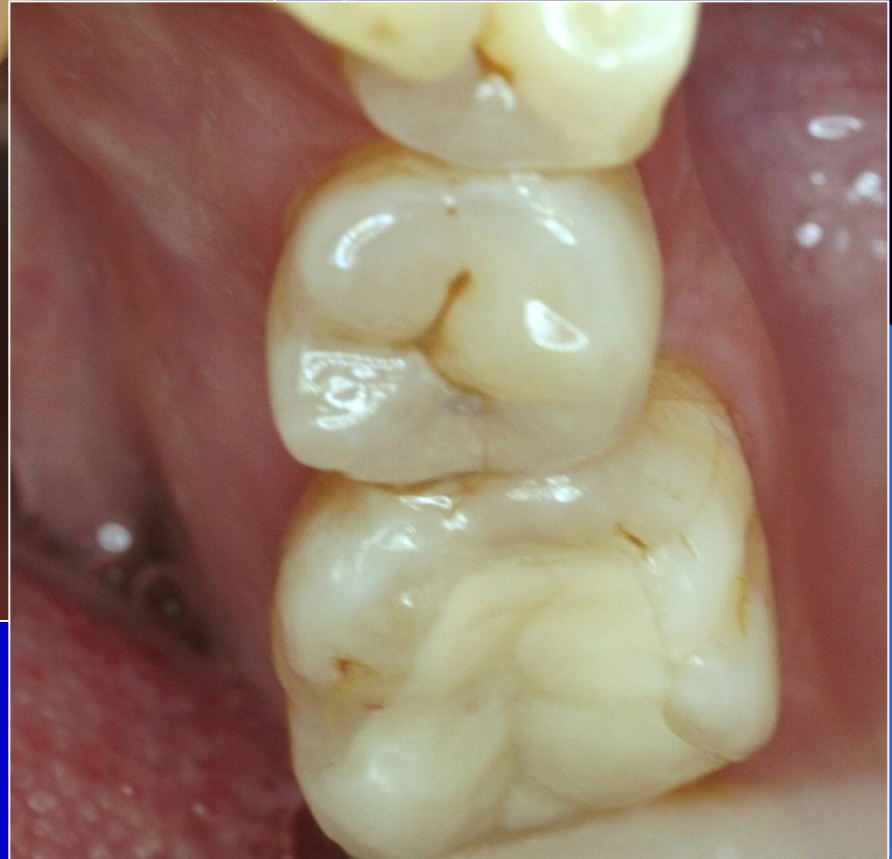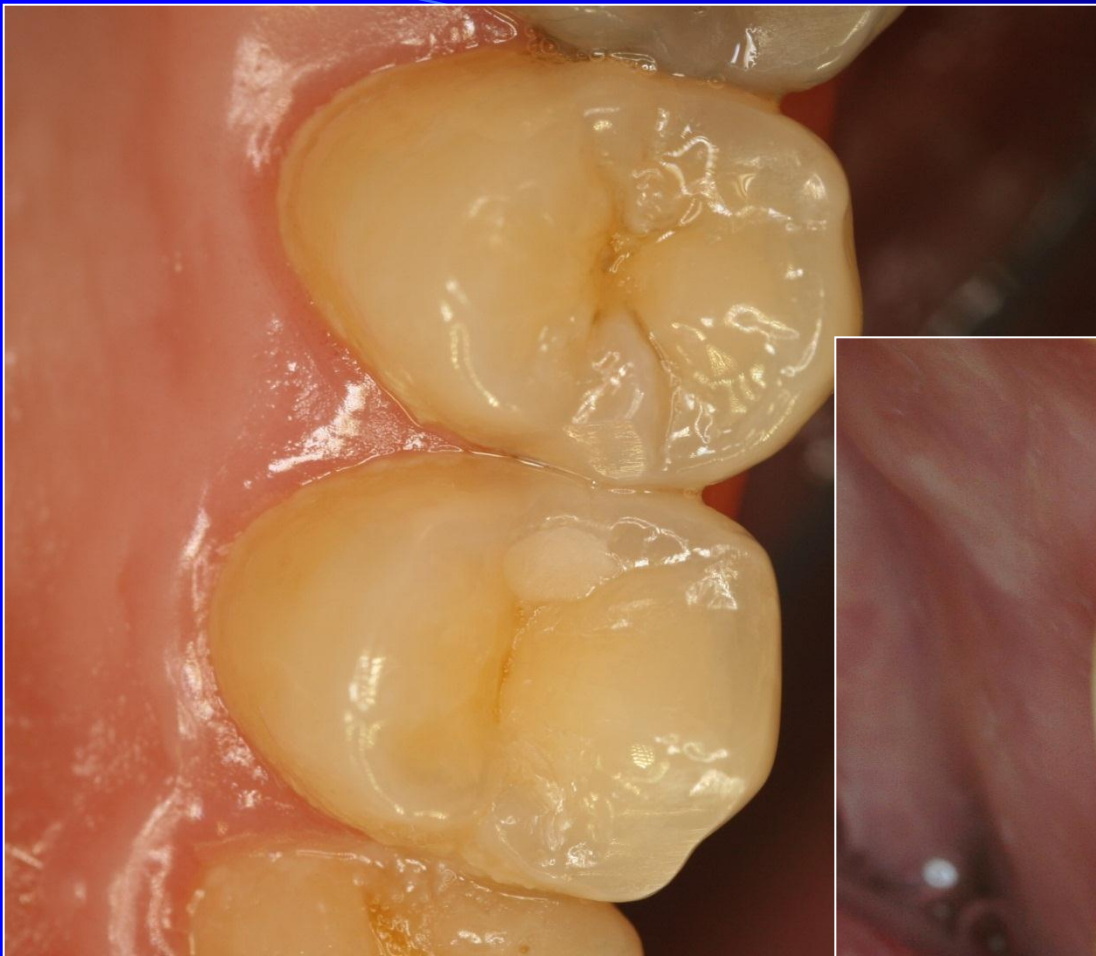
Success?

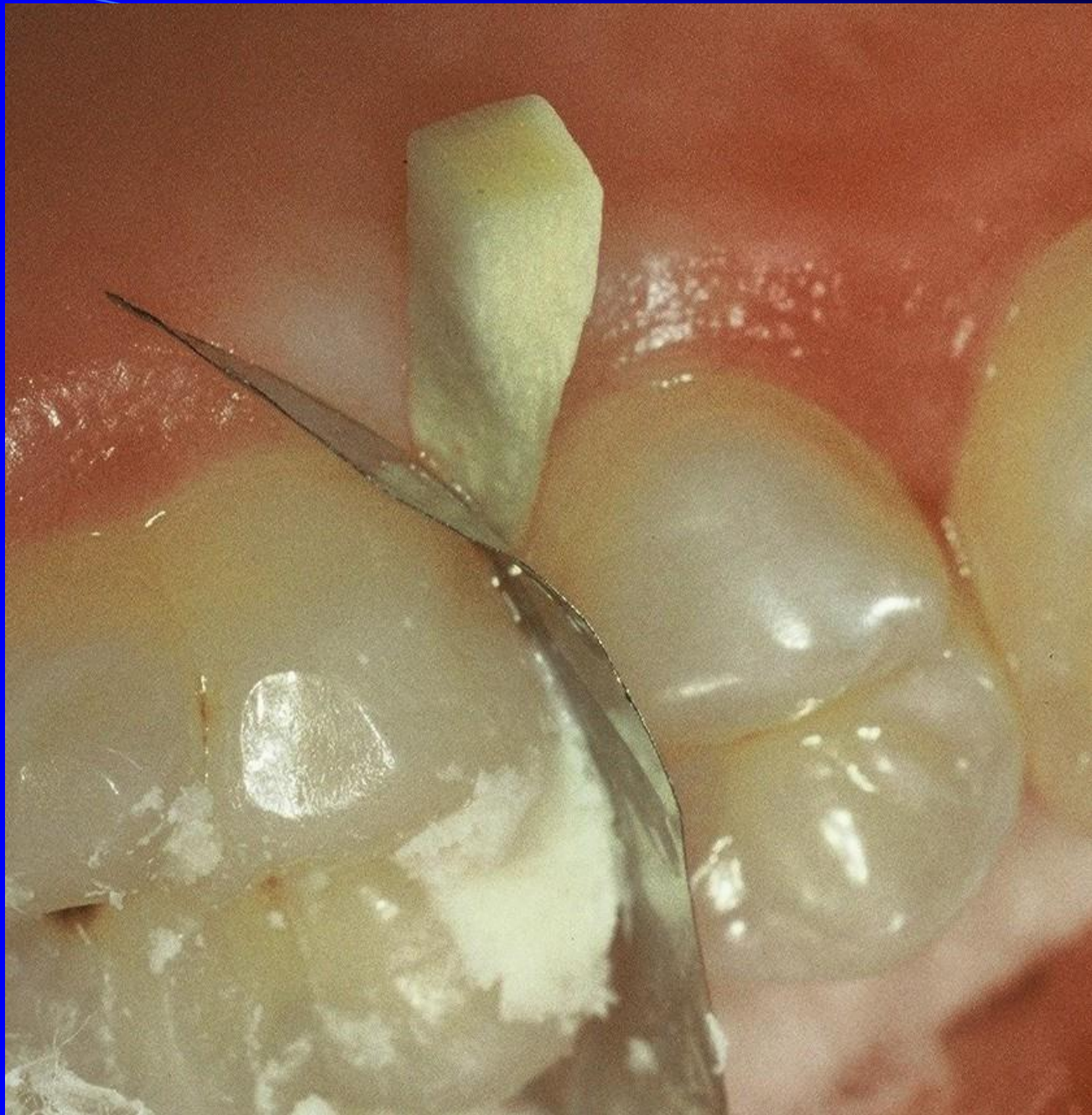1. Low caries risk
2. Proximal ridge without infra
3. Good cooperation
4. D2



Success

1. Loups or microscope
2. Miniinstruments
3. Dezinfection
4. GIC in capsules
5. BW post on

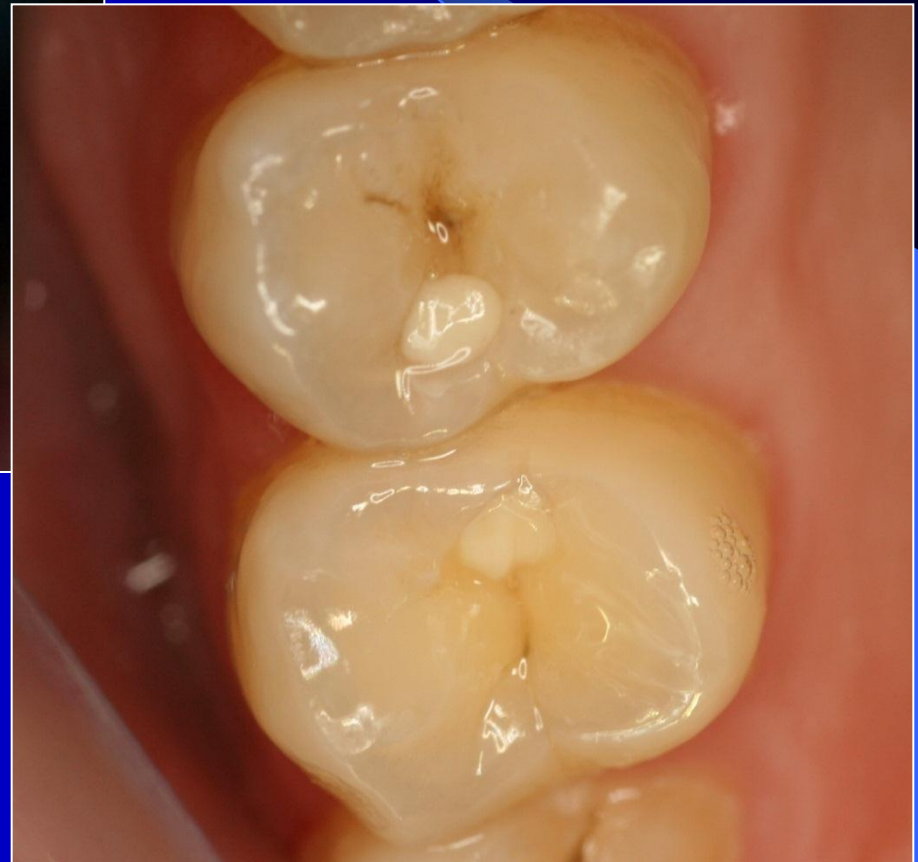





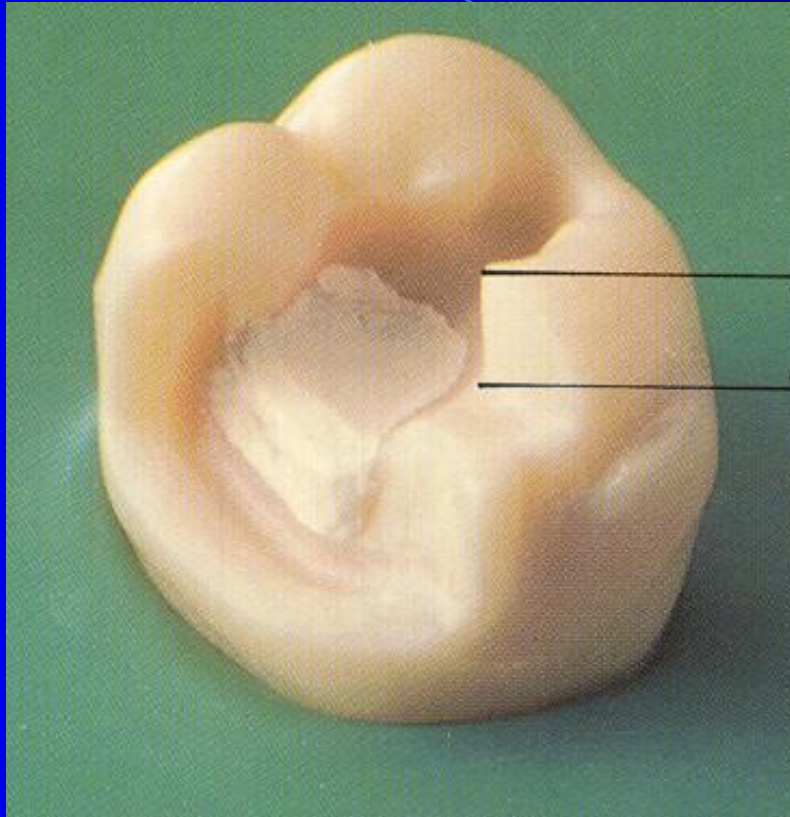
Úspěch tunelu????

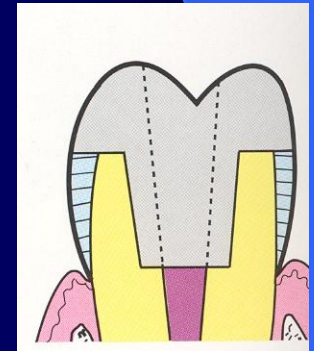
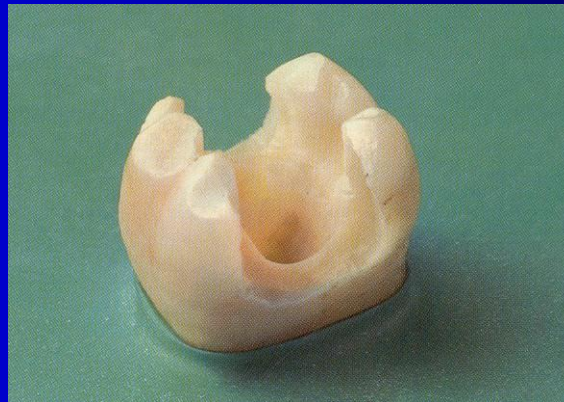
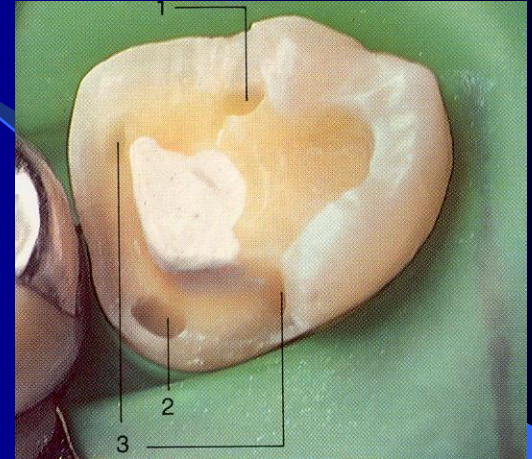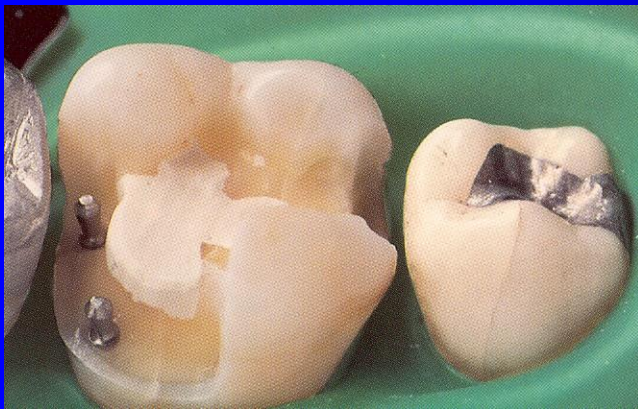
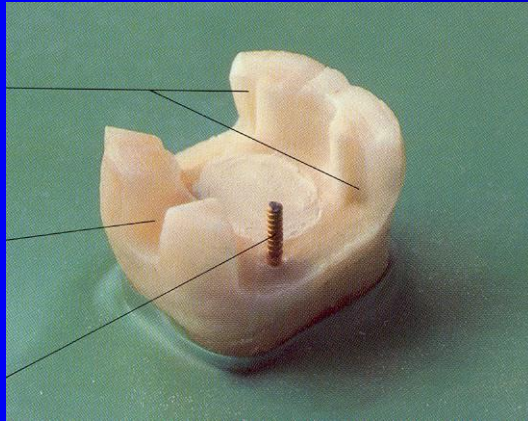
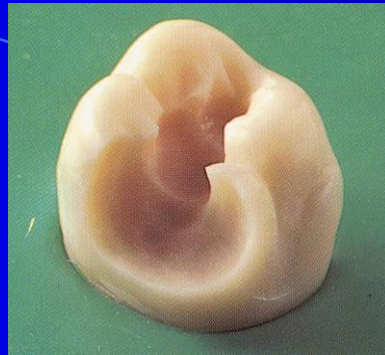
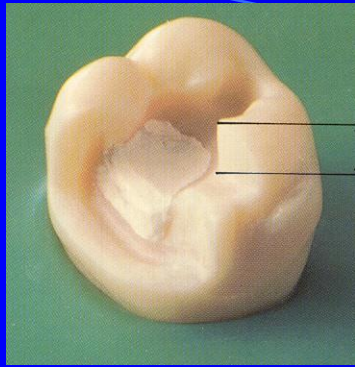
1. Nízké riziko sklonu k novým kazům
2. Spolupracující pacient
3. Okrajová lišta bez infrakcí
4. D2 – D3



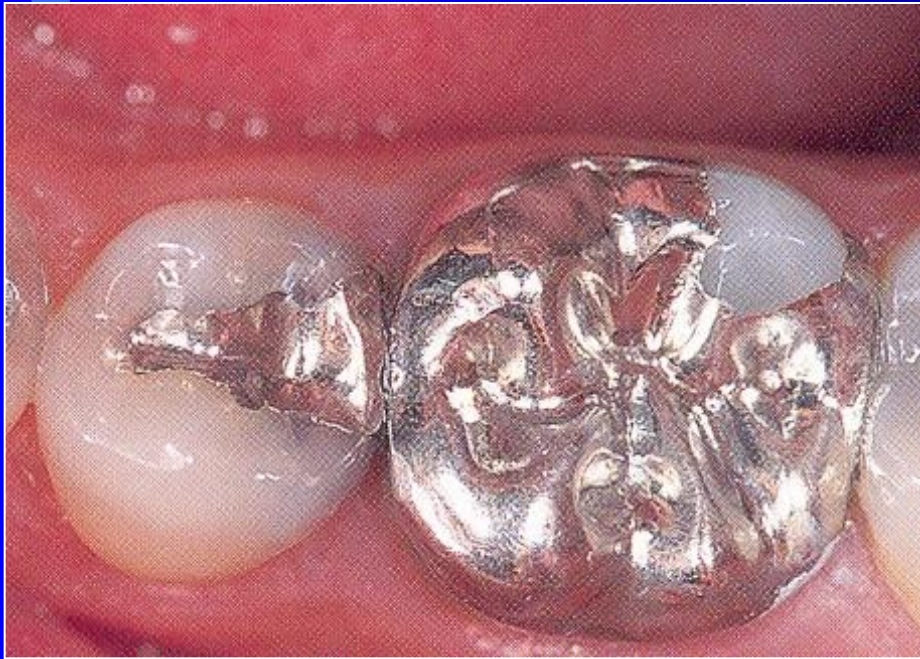
Úspěch tunelu????

1. Lupové brýle nebo mikroskop
2. Miniaturní instrumenty
3. Dezinfekce kavity
4. Jedině GIC v kapslích
5. BW post op





Large amalgam restoration - overlays



Rules

- Clear and sharp outlines
- Autoretention
 - Cavities - pins
 - Grooves