

VIDEOS IN CLINICAL MEDICINE

Placement of an Arterial Line

Ken Tegtmeyer, M.D., Glenn Brady, M.D., Susanna Lai, M.P.H.,
Richard Hodo, and Dana Braner, M.D.

INDICATIONS

Radial arterial lines are important tools in the treatment of critically ill patients. Continuous monitoring of blood pressure is indicated for patients with hemodynamic instability that requires inotropic or vasopressor medication. An arterial line allows for consistent and continuous monitoring of blood pressure to facilitate the reliable titration of supportive medications. In addition, arterial lines allow for reliable access to the arterial circulation for the measurement of arterial oxygenation and for frequent blood sampling. The placement of arterial lines is an important skill for physicians to master as they treat critically ill patients.

An arterial line is also indicated for patients with significant ventilatory deficits. Measurement of the partial pressures of arterial oxygen and arterial carbon dioxide provides more information about the status of gas exchange than does arterial oxygen saturation.

CONTRAINDICATIONS

The contraindications to the placement of an arterial line are few but specific. Placement of an arterial line should not compromise the circulation distal to the placement site, which means that sites with known deficiencies in collateral circulation — such as those involved in Raynaud's phenomenon and thromboangiitis obliterans or end arteries such as the brachial artery — should be avoided.

The value of the Allen test, which is used to verify collateral circulation to the hand through alternate occlusion of the radial and ulnar arteries while the hand is checked for perfusion, is somewhat controversial. Some studies have been able to demonstrate adequate perfusion with the use of other techniques that contradict the results of the Allen test.^{1,2} Other contraindications include infection of the site where the catheter is to be placed and traumatic injury proximal to the proposed insertion site.

PREPARATION

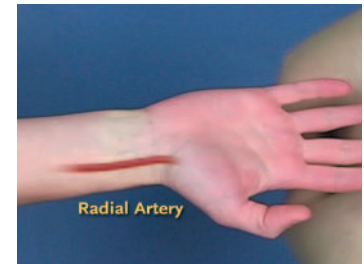There are several techniques for the placement of a radial arterial line; two of the more common are known as “over the wire” and “over the needle.” A modified Seldinger technique can also be used but is not described in this video.

Preparation for both techniques is identical. The equipment needed includes a sterile preparation solution and a sterile field, a board and tape to secure and position the wrist, 1 percent lidocaine solution (without epinephrine) and a small-gauge needle and syringe for delivery, an angiographic catheter and needle, a wire if the over-the-wire technique is to be used, material such as suture or tape to secure the line once it has been placed, and a transduction system for monitoring.

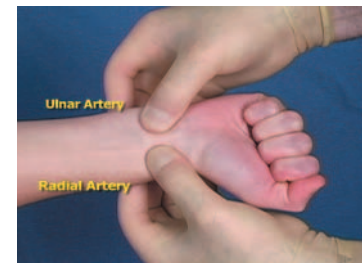After the risks of the procedure have been appropriately assessed and consent has been obtained from the patient, the hand should be positioned on the wrist board. The hand should be placed in moderate dorsiflexion, which brings the artery

From the Departments of Medical Informatics and Clinical Epidemiology and Pediatrics, Oregon Health and Sciences University, Portland, Ore. Address reprint requests to Dr. Braner at 3181 S.W. Sam Jackson Park Rd., Portland, OR 97239-3098, or at branerd@ohsu.edu.

N Engl J Med 2006;354:e13.
Copyright © 2006 Massachusetts Medical Society.



Location of the radial artery.



Performance of the Allen test.

closer to the skin and aids successful placement of the line. A flexible board or roll placed under the wrist can ease positioning. The site should be cleaned with a sterile preparation solution and draped appropriately. Sterile gloves should be used for catheter placement.

PLACEMENT OF THE LINE

The radial artery is palpated 1 to 2 cm from the wrist, between the bony head of the distal radius and the flexor carpi radialis tendon. In a conscious patient, lidocaine may be infused at the insertion site to help minimize pain on insertion of the line.

For the over-the-wire technique, the artery should be palpated gently with the nondominant hand proximal to the insertion site. The needle should enter at a 30-to-45-degree angle to the skin directly over the point at which the pulse is palpated. The catheter should be advanced slowly through the artery; once a flash of blood is seen in the hub of the catheter, the needle should be advanced a few millimeters farther through the vessel. The wire should be prepared and the needle slowly withdrawn until pulsatile blood flow is observed. At this point, the wire is advanced into the vessel. The wire should thread easily and without resistance. Once the wire is in the vessel, the needle can be removed; the catheter is then advanced over the wire. Pressure should be placed over the artery proximal to the catheter, the wire removed, and the catheter connected to a transduction system.


For the over-the-needle technique, the initial approach is the same. The pulse should be palpated proximal to the insertion site; the needle should penetrate the skin at a 30-to-45-degree angle directly over the palpated pulse and then be advanced slowly toward the pulse. Once pulsatile blood return is seen in the catheter, the catheter should be advanced slightly farther to ensure that the catheter itself is within the vessel. The catheter angle should then be lowered to 10 to 15 degrees and the catheter advanced over the needle into the vessel.

Regardless of technique, the catheter should be secured in place. Suturing is the preferred method, but many practitioners choose to tape the catheter securely in place. It is important to ensure that the catheter is not subject to tension from the tubing or at risk of being removed by the patient.


Perfusion to the hand should be reassessed after placement of the arterial line and at frequent intervals while the line is in use. Any sign of vascular compromise at any time should prompt the removal of the line. The line should be removed as early as possible after it is no longer needed.

COMPLICATIONS

Arterial spasm and an inability on the part of the clinician to pass the wire or catheter through the artery are the most common difficulties in catheterization. If spasm is suspected, attempts at catheterizing that artery should be abandoned and an alternative site selected. If the wire or catheter cannot be passed despite the return of pulsatile blood, this is either because the angle of the needle in relation to the vessel is too acute or because the needle tip is not completely within the artery. With adjustment of the angle, a slight advance, or withdrawal of the needle, placement may yet be successful.



Entry of over-the-wire technique.



Over-the-needle technique.

REFERENCES

1. Abu-Omar Y, Mussa S, Anastasiadis K, Steel S, Hands L, Taggart DP. Duplex ultrasonography predicts safety of radial artery harvest in the presence of an abnormal Allen test. *Ann Thorac Surg* 2004; 77:116-9.
2. Fuhrman TM, Pippin WD, Talmage LA, Reilley TE. Evaluation of collateral circulation of the hand. *J Clin Monit* 1992; 8:28-32.

Copyright © 2006 Massachusetts Medical Society.

VIDEOS IN CLINICAL MEDICINE

Central Venous Catheterization — Subclavian Vein

Dana A.V. Braner, M.D., Susanna Lai, M.P.H., Scott Eman, B.S.,
and Ken Tegtmeyer, M.D.

From the Department of Pediatrics, Oregon Health & Science University, Portland. Address reprint requests to Dr. Tegtmeyer at the Department of Pediatrics, Oregon Health & Science University, 707 SW Gaines St., MC: CDRC-P, Portland, OR 97239, or at tegtmeye@ohsu.edu.

N Engl J Med 2007;357:e26.

Copyright © 2007 Massachusetts Medical Society.

INDICATIONS

Central venous catheterization provides for the administration of caustic and critical medications as well as allowing sampling of blood and measurement of central venous pressure. Recent evidence and Institute for Healthcare Improvement bundled guidelines¹ suggest that the subclavian vein is the preferred choice for placement of a central venous catheter.

CONTRAINDICATIONS

General contraindications for placement of a central venous catheter include infection of the area overlying the target vein and thrombosis of the target vein. Specific contraindications to the subclavian approach include fracture of the ipsilateral clavicle or anterior proximal ribs, which can distort the anatomy and make placement difficult. Greater caution should be used when placing a central venous catheter in coagulopathic patients. The location of the artery (beneath the clavicle) makes application of direct pressure nearly impossible in attempts to control bleeding.

EQUIPMENT

Most of the necessary equipment can be found in commercially available kits. These kits typically include skin-preparation solution and a drape, lidocaine, sterile gauze, non-Luer lock syringes, a scalpel, a catheter, a dilator, several needles, and a guide-wire. You will also need a sterile gown, sterile gloves, a surgical cap, a mask with a face shield, and drapes to cover the patient's entire body. Flush solution is also not commonly found in the kits. Determine the catheter length and depth of placement by referring to the patient's external landmarks. The tip of the catheter should reach the junction of the superior vena cava and the right atrium. Common catheters used range from 4-French catheters for infants to 7-French catheters for adults; 11.5-French catheters may be used for dialysis. Because the risk of infection increases with an increasing number of lumens, a catheter with the fewest number of lumens required should be used.

PREPARATION

Explain the procedure to the patient and obtain written informed consent. Wear a sterile gown and gloves, a mask with face shield, and a surgical cap. Examine the patient to be sure that there are no contraindications. Place the patient in the 15-degree Trendelenburg position, which will engorge the vein. If you place a rolled towel or similar object under the spine to help identify the patient's external landmarks, be aware that propping the shoulder or turning the head has been shown to decrease the size of the vein on ultrasonography.² Scrub the area thoroughly with chlorhexidine. Drape the area, covering the patient's entire body.

Next, identify anatomic landmarks, beginning with the middle third of the clavicle. Follow this laterally to the point where the clavicle deviates from the proximal ribs (Fig. 1). Just medial to this point, the subclavian vein and artery run just inferior to the clavicle. This is where most successful catheterization occurs. The insertion site should be somewhat remote from the clavicle, so that the path of the needle ultimately stays parallel to and just under the clavicle. Typically, the point of insertion is 2 cm lateral to and 2 cm caudal to the middle third of the clavicle (Fig. 2). Local anesthesia with 1 to 2 ml of 1 percent lidocaine or equivalent should be used in this area.

ULTRASOUND GUIDANCE

Several recent articles suggest that ultrasonography can increase the likelihood of successful placement of a subclavian catheter, despite the presence of bony landmarks.^{3,4} Because of the greater difficulty in identifying the vein by compression, Doppler flow should be used to distinguish between the artery and the vein.

THE PROCEDURE

Starting 2 cm lateral to the bend of the clavicle and approximately 2 cm caudal, insert the catheterization needle through the skin at a 30-degree angle toward the sternal notch. Place a finger of your nondominant hand in the sternal notch to help find the landmark. Once the needle is under the skin, lower the needle and syringe to run parallel to but beneath (posterior to) the clavicle (Fig. 3). Access to the vein typically occurs just beneath the clavicle, but it may involve a depth of several centimeters under the skin.

Once you have obtained venous access, carefully stabilize the needle and remove the syringe. Introduce the J-tipped end of the guidewire into the needle. The wire should thread easily and without resistance until well beyond the end of the needle. If you notice ectopic cardiac beats on the monitor, pull the wire back until the ectopic beats disappear. Then remove the needle, leaving the wire in place. Maintain control of the wire. A small, 1-to-2-mm incision should be made in the skin at the insertion point to facilitate dilator passage. Advance the dilator over the wire into and through the skin and then into the vessel. Once the vessel is dilated, the dilator can be removed. Use a gauze pad to control increased bleeding, which usually occurs after dilation. Advance the line over the guidewire, maintaining control of the wire before passing the catheter into the skin. Remove the guidewire, check for blood return from all ports, flush all ports, and secure the catheter in place. Apply a sterile dressing before removing the drapes (Fig. 4).

COMPLICATIONS

Specific complications associated temporally with placement of a subclavian line include hemothorax and pneumothorax, air embolism, inadvertent arterial puncture, and aortic perforation. Obtain a chest radiograph after placement to assess for complications and for correct placement of the catheter. Common malplacement locations include placement transverse to the contralateral subclavian vein, retrograde into the ipsilateral internal jugular vein, or potentially the contralateral internal jugular vein.

Longer-term complications include thrombosis of the vein and infection. Data suggest that subclavian placement mitigates but does not eliminate the risk of infection. Adherence to the Institute for Healthcare Improvement guidelines, including the use of proper hand hygiene, the use of maximal barrier precautions during placement, the use of chlorhexidine skin antisepsis, and daily review of need for the catheter, will help to decrease the risk of infection.¹

No potential conflict of interest relevant to this article was reported.

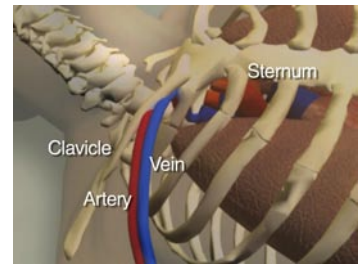


Figure 1. Anatomic Landmarks.

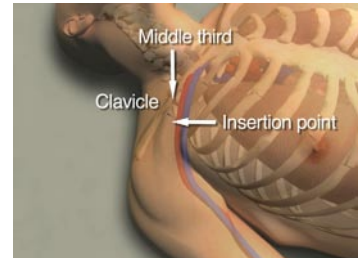


Figure 2. Point of Insertion.

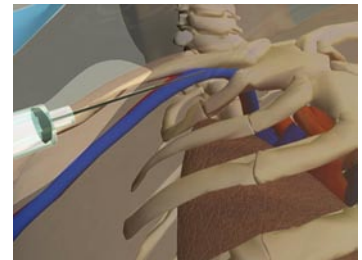


Figure 3. Placement of the Needle.

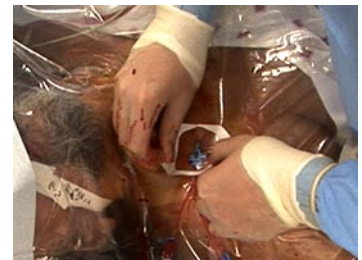

Figure 4. Application of the Dressing.

REFERENCES

1. Implement the central line bundle. Cambridge, MA: Institute for Healthcare Improvement. (Accessed November 16, 2007, at <http://www.ihc.org/ihc/topics/criticalcare/intensivecare/changes/implementthecentrallinebundle.htm>.)
2. Fortune JB, Feustel P. Effect of patient position on size and location of the subclavian vein for percutaneous puncture. *Arch Surg* 2003;138:996-1000.
3. Orihashi K, Imai K, Sato K, Hamamoto M, Okada K, Sueda T. Extrathoracic subclavian venipuncture under ultrasound guidance. *Circ J* 2005;69:1111-5.
4. Pirotte T, Veyckemans F. Ultrasound-guided subclavian vein cannulation in infants and children: a novel approach. *Br J Anaesth* 2007;98:509-14.

Copyright © 2007 Massachusetts Medical Society.

VIDEOS IN CLINICAL MEDICINE

Central Venous Catheterization

Alan S. Graham, M.D., Caroline Ozment, M.D., Ken Tegtmeyer, M.D.,
Susanna Lai, M.P.H., and Dana A.V. Braner, M.D.

INDICATIONS

Central venous catheterization provides a route for delivery of caustic or critical medications and allows measurement of central venous pressure.

CONTRAINDICATIONS

General contraindications for the placement of a central venous catheter include infection of the area overlying the target vein and thrombosis of the target vein; site-specific and relative contraindications include coagulopathy, although this is not an absolute contraindication. Extreme care must be exercised in patients with coagulopathy and in other patients for whom complications would be life-threatening.

EQUIPMENT

Many institutions stock prepackaged catheter-insertion kits containing the necessary equipment. The catheter should have the appropriate lumen size to deliver the required medications, and its length should be appropriate to reach the junction of the vena cava and the right atrium. Approximate length can be measured against the patient's external anatomical landmarks. Seven-French 20-cm catheters are the most commonly used. Dialysis or rapid fluid resuscitation requires larger-bore catheters. Each additional lumen decreases the size of the individual lumens, which will decrease the maximal rate at which fluids can be administered. The catheter should be flushed, and compatibility between the guide wire and the needle should be confirmed.

PREPARATION

Explain the procedure to the patient, and obtain written informed consent. Select the insertion site on the basis of the comparisons noted in Table 1. Subclavian and inter-

From the Department of Pediatrics, Division of Pediatric Critical Care, Doernbecher Children's Hospital, Portland, OR (A.S.G., K.T., S.L., D.A.V.B.); and the Department of Pediatrics, Division of Pediatric Critical Care, Duke University, Durham, NC (C.O.). Address reprint requests to Dr. Tegtmeyer at the Department of Pediatrics, Division of Pediatric Critical Care, Doernbecher Children's Hospital, Oregon Health & Science University, Mail Code: CDRC-P, 707 SW Gaines St., Portland, OR 97239-2901, or at tegtmeye@ohsu.edu.

N Engl J Med 2007;356:e21.

Copyright © 2007 Massachusetts Medical Society.

Table 1. Risk of Complications Associated with Internal Jugular, Subclavian, and Femoral Central Venous Catheterization.

Complication	Risk of Complication at Catheterization Site*		
	Internal Jugular Vein	Subclavian Vein	Femoral Vein
Pneumothorax (%)	<0.1 to 0.2	1.5 to 3.1	NA
Hemothorax (%)	NA	0.4 to 0.6	NA
Infection (rate per 1000 catheter-days)	8.6	4	15.3
Thrombosis (rate per 1000 catheter-days)	1.2 to 3	0 to 13	8 to 34
Arterial puncture (%)	3	0.5	6.25
Malposition	Low risk (into inferior vena cava, passing through right atrium)	High risk (crossing to contralateral subclavian vein, ascending internal jugular vein)	Low risk (lumbar venous plexus)

* NA denotes not applicable.

nal jugular sites are generally preferred because they present a lower risk of infection and fewer mechanical complications.¹ If the patient has challenging anatomy, a scar at the insertion site, or any other indication that could result in a difficult insertion, an expert operator should be in attendance.

Anatomical landmarks for the central approach to internal jugular venous catheterization begin at the apex of the triangle formed by the heads of the sternocleidomastoid muscle and the clavicle. A confluence between the internal jugular vein and the brachiocephalic vein facilitates cannulation at this location. After identifying the landmarks, sterilize the area with chlorhexidine, using a circular motion from the center outward, and then apply a sterile drape.

Administer local anesthesia, using 1 to 2 ml of 1% lidocaine or equivalent, with a 25-gauge needle at the cannulation site. To avoid air embolism, place the patient with head down, in the Trendelenburg position. The head should be rotated 45 degrees away from the site of cannulation; avoid excessive rotation of the head, which can cause collapse of the vein. During the procedure, place the index finger of your nondominant hand on the patient's carotid artery to diminish the risk of inadvertent puncture of the artery.

Ultrasound Guidance

In numerous studies, ultrasound guidance has been shown to increase the success of first-time catheter placement and to decrease the risk of complications.² When using ultrasound guidance, enlist an assistant either to handle the probe or to remove it when it is no longer needed.

The vein and artery appear circular and black on the ultrasound image; the vein is much more compressible when gentle pressure is applied to the skin via the probe. The needle appears echogenic and can be followed into the image of the vein on ultrasound. Newer commercial kits include needles that are more echogenic.

THE PROCEDURE

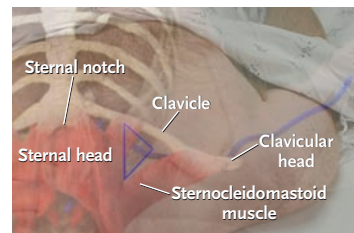
Starting just lateral to the carotid pulse, insert an 18-gauge needle slightly superior to the apex of the triangle. The needle is maintained at an angle of 20 degrees above the coronal plane as it is advanced past the apex of the triangle, with the longitudinal axis in the direction of the ipsilateral nipple. The vein is generally encountered approximately 0.5 in. (1.3 cm) under the skin,¹ though this can vary, depending on regional adiposity.

After venous access is obtained, hold the needle carefully as you disconnect the syringe. The J-shaped end of the guide wire is introduced into the needle and advanced. The wire should thread easily, without resistance, well beyond the end of the needle. If cardiac rhythm changes are noted, pull the wire back until the rhythm normalizes. Then remove the needle, leaving the wire in place. Carefully maintain control of the wire, and make a 1-to-2-mm incision at the site of skin puncture. Advance the dilator over the guide wire. Once the tract is dilated, remove the dilator and thread the catheter over the wire and into the vessel. Then remove the guide wire, confirm blood return, and apply a sterile dressing.

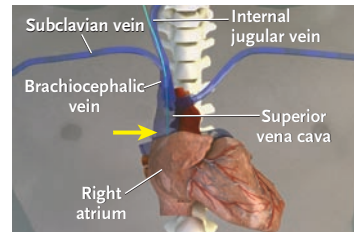
COMPLICATIONS

Risks associated with central venous catheterization include infectious, mechanical, and thrombotic complications. A chest radiograph should be obtained to confirm placement and to assess for complications.

Catheter infections occur by means of one of three mechanisms: local insertion-site infection, which travels down the catheter externally; or hub colonization followed by infection via the intraluminal route or via hematogenous seeding of the



Anatomical landmarks



Site of cannulation

catheter.¹ The Institute for Healthcare Improvement recommends five steps to reduce central-line infections: hand hygiene, adherence to maximal barrier precautions, chlorhexidine skin antiseptics, selection of an optimal catheter site, and daily review of the necessity of the catheter, with prompt removal when the catheter is no longer needed.³ Implementation of these steps has been conclusively shown to decrease the rate of catheter-related bloodstream infection.⁴ Scheduled changing of a catheter over a guide wire or moving a catheter to a new site can increase mechanical and infectious complications, and neither is recommended.¹ Antiseptic-containing hubs and antimicrobial-impregnated catheters have been shown to decrease the rate of catheter-related bloodstream infections.¹ Topical antibiotic ointments are ineffective, promote antibiotic-resistant bacteria, and increase fungal colonization.

Mechanical Complications

Mechanical complications include arterial puncture, hematoma, pneumothorax, hemothorax, arrhythmia, and improper location of the catheter, whether in an accessory vein or in the other vessels of the upper vascular system. Insertion of a catheter into the femoral vein, not shown in this video, has the highest risk of mechanical complications, but the rates of serious mechanical complications for femoral and subclavian insertion are similar.⁵ If an artery is punctured, further attempts at that site should be abandoned, and access to an alternative site should be attempted. Internal jugular and subclavian cannulation sites are preferred because of their lower overall rate of mechanical complications. However, these sites carry a small risk of hemothorax and pneumothorax.¹ Ultrasound guidance for internal jugular cannulation significantly reduces the number of attempts required and the risk of complications.²

Thrombotic Complications

Central venous cannulation increases the risk of central venous thrombosis, with the concomitant potential risk of venous thromboembolism. Thrombosis may occur as early as the first day after cannulation. The site with the lowest risk for thrombotic complications is the subclavian vein.^{1,4} Prompt removal of the catheter when it is no longer needed decreases the risk of catheter-related thrombosis.

No potential conflict of interest relevant to this article was reported.

REFERENCES

1. McGee DC, Gould MK. Preventing complications of central venous catheterization. *N Engl J Med* 2003;348:1123-33.
2. Hind D, Calvert N, McWilliams R, et al. Ultrasonic locating devices for central venous cannulation: meta-analysis. *BMJ* 2003;327:361.
3. Implement the Central Line Bundle. Cambridge, MA: Institute for Healthcare Improvement. (Accessed April 30, 2007, at <http://www.ihl.org/IHI/Topics/CriticalCare/IntensiveCare/Changes/ImplementtheCentralLineBundle.htm>.)
4. Pronovost P, Needham D, Berenholtz S, et al. An intervention to decrease catheter-related bloodstream infections in the ICU. *N Engl J Med* 2006;355:2725-32.
5. Merrer J, De Jonghe B, Golliot F, et al. Complications of femoral and subclavian venous catheterization in critically ill patients: a randomized controlled trial. *JAMA* 2001;286:700-7.

Copyright © 2007 Massachusetts Medical Society.

VIDEOS IN CLINICAL MEDICINE

Placement of a Femoral Venous Catheter

Janet Y. Tsui, M.D., Adam B. Collins, M.D., Douglas W. White, B.A.,
Jasmine Lai, B.S., and Jeffrey A. Tabas, M.D.

INDICATIONS

From the School of Medicine (J.Y.T., A.B.C., D.W.W., J.L., J.A.T.), Department of Anesthesia (A.B.C.), and Department of Medicine, Division of Emergency Medicine (J.A.T.), University of California, San Francisco, San Francisco. Address reprint requests to Dr. Tabas at San Francisco General Hospital Emergency Services, 1001 Potrero Ave., Office 1E21, San Francisco, CA 94110, or at jtabas@sfgghed.ucsf.edu.

The insertion of a femoral venous catheter may be necessary when peripheral access to the circulatory system is compromised and no other sites for placement of a central catheter are available. Such a catheter may be used to administer large fluid volumes or potentially irritating medicines, to provide temporary access for emergency dialysis, for immediate central access during emergency resuscitation, to facilitate cardiac catheterization, or, in rare instances, for drawing blood, if a patient requires frequent blood sampling and no other access site is available.

CONTRAINDICATIONS

N Engl J Med 2008;358:e30.
Copyright © 2008 Massachusetts Medical Society.

There are few absolute contraindications to placement of a central catheter, other than the patient's not agreeing to the procedure. There are several relative contraindications. As compared with subclavian or jugular catheters, femoral catheters are associated with a higher risk of infection, thrombosis, and, in the absence of ultrasound guidance, arterial puncture.¹ If a safer option exists, it should be chosen. It is important to note that uncooperative patients place both the operator and themselves at risk for injury. Evident infection at the site where the needle will enter should prompt the operator to seek another access site. In addition, complications are more likely to occur if the site is distorted by trauma or is obscured. In patients with uncorrected bleeding disorders, a central catheter should be placed with caution and only if necessary. Central catheters should not be placed by inexperienced operators who lack supervision.

EQUIPMENT

Materials required for this procedure include personal protective equipment, a bag of sterile saline for infusion, intravenous tubing, local anesthetic medications, a central-catheter kit, and blood-drawing equipment. The central-catheter kit typically includes a sterile drape, skin preparation solution, sterile gauze, an introducer needle, a guidewire, a scalpel, a dilator, an intravenous catheter, a mechanism for securing the catheter to the skin, and a sterile, transparent dressing.

PREPARATION

Explain the procedure to the patient, and obtain written informed consent when possible. Confirm that you have the correct patient, have selected the correct anatomical location, and are planning the correct procedure. An assistant should be empowered to halt the procedure if inappropriate technique or practice occurs.

For optimal exposure of the femoral region, externally rotate and abduct the patient's leg away from midline. The femoral vein lies medial to the femoral artery as it runs distal to the inguinal ligament. Localize the vein by palpating the femoral artery, or use ultrasonography. Prepare the skin with chlorhexidine, and cover the area with a sterile drape. Use full sterile dress. Prepare the central-catheter kit, and flush the catheter ports with sterile saline. If you are using ultrasound localization, prepare the ultrasound probe for sterile use.

Anesthetize the area with long-acting anesthetic such as lidocaine with epinephrine or bupivacaine. Adequate analgesia will increase the patient's comfort and the operator's likelihood of successful catheter placement.

PLACEMENT OF THE CATHETER

After ensuring that the femoral area has been properly anesthetized, reconfirm the position of the femoral vein by palpating the femoral artery or visualizing it directly with ultrasonography. Insert the introducer needle at a 45-degree angle from the skin, directed along the course of the artery, while you pull back the plunger (Fig. 1). To prevent femoral-artery cannulation, maintain palpation of the artery while you advance the needle.

Once you see a flash of blood, carefully anchor the needle to avoid dislodging it from an intraluminal location (Fig. 2). Detach the syringe and thread the guidewire through the needle. It should pass easily and without resistance into the lumen of the vessel. While maintaining your grasp of the wire, remove the introducer needle. Incise the skin at the wire-entry site with a scalpel, keeping the sharp edge away from the wire. Advance the dilator over the wire to make a tract through the tissues into the vessel (Fig. 3). Larger catheters may have dilators that fit inside them and must be advanced together with the catheter. Unless that is the case, remove the dilator and thread the catheter over the wire. Before advancing the catheter past the skin, firmly grasp the guidewire protruding from the proximal end of the catheter. It is often necessary to feed the wire back through the catheter to accomplish this. After the catheter has been threaded into the vessel, remove the wire. Confirm the intravenous location of the catheter, flush sterile saline through each port, and secure the catheter with sutures or staples. Place a sterile dressing over the site before removing the drapes. Place all sharp and soiled materials in an appropriate receptacle.

ULTRASOUND GUIDANCE

Several studies have shown that using ultrasonography to assist in central-catheter placement increases success and reduces complications.^{2,3} Choose a linear probe rather than a curved probe for femoral catheter placement. Linear probes emit high-frequency waves that are optimal for viewing superficial structures, such as the femoral vessels. Position yourself toward the patient's feet, and place the ultrasound monitor in front of you. Orient the probe so that the patient's right is on the right side of the screen. Place the probe in a sterile sheath with coupling gel inside. Sterile gel can be applied to the outside of the protective covering. Placing the patient in a reverse Trendelenberg position engorges the femoral vein and may aid in visualization. Ultrasound imaging renders vessel walls brighter than their lumens, which are filled with blood. The femoral vein is collapsible as compared with the artery. Use of the Doppler function of the ultrasound machine may help distinguish pulsatile (arterial) from more continuous (venous) blood flow. Position the vein in the center of the screen, and insert the needle at the center of the probe (Fig. 4). After the ultrasound images indicate that the needle is in an appropriate position for entering the vein, you will also note the intravenous location by observing a flash of blood into the syringe.

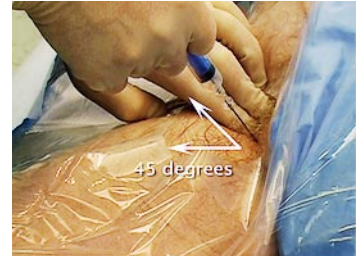


Figure 1. Inserting the Introducer Needle.

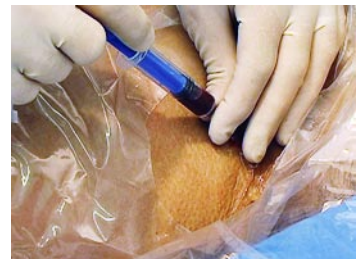

Figure 2. Anchoring the Needle.




Figure 3. Advancing the Dilator to Make a Tract.

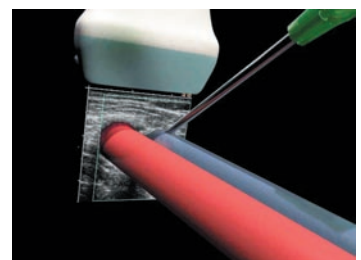


Figure 4. Inserting the Needle at the Center of the Probe.

REFERENCES

1. McGee DC, Gould MK. Preventing complications of central venous catheterization. *N Engl J Med* 2003;348:1123-33.
 2. Hind D, Calvert N, McWilliams R, et al. Ultrasonic locating devices for central venous cannulation: meta-analysis. *BMJ* 2003;327:361.
 3. Rothschild JM. Ultrasound guidance of central vein catheterization: evidence report/technology assessment. In: Making health care safer: a critical analysis of patient safety practices. No. 43. Rockville, MD: Agency for Healthcare Research and Quality, 2001:245-53. (AHRQ publication no. 01-E058.)
- Copyright © 2008 Massachusetts Medical Society.

COMPLICATIONS

Potential complications include infection, thromboembolism, arterial puncture, and hematoma. It is important to be aware of these possible problems and to keep them in mind as you monitor the patient. Less common complications include arteriovenous fistula and pseudoaneurysm. Most of these complications can be prevented by following proper sterile technique, using ultrasonography for placing the catheter, limiting the number of attempts at placing the catheter, and removing it as soon as possible.

If the femoral artery has been punctured, apply pressure to the site for at least 10 minutes. Small hematomas may be managed conservatively, but continuing hemorrhage may require surgical intervention.

Dr. Collins reports receiving lecture fees from General Electric Ultrasound. No other potential conflict of interest relevant to this article was reported.

VIDEOS IN CLINICAL MEDICINE

Chest-Tube Insertion

Shelly P. Dev, M.D., Bartolomeu Nascimento, Jr., M.D.,
Carmine Simone, M.D., and Vincent Chien, M.D.

INDICATIONS

Insertion of a chest tube is indicated in either emergency or nonemergency situations. Specific indications are listed in Table 1.¹⁻³

CONTRAINDICATIONS

Published guidelines state that there are no absolute contraindications for drainage by means of a chest tube¹ except when a lung is completely adherent to the chest wall throughout the hemithorax.² Relative contraindications include a risk of bleeding in patients taking anticoagulant medication or in patients with a predisposition to bleeding or abnormal clotting profiles. Whenever possible, coagulopathies and platelet defects should be corrected with the infusion of blood products, such as fresh frozen plasma and platelets.

EQUIPMENT

Most hospitals have presterilized, packaged chest-tube–insertion trays. The key components of the tray are a scalpel with size 11 blade; several dissecting instruments, such as curved Kelly clamps or artery forceps; a 10-ml syringe and a 20-ml syringe; one small-gauge needle (size 25) and one larger-gauge needle for deeper anesthetic infiltration (size 18–21); a needle driver; scissors; one packet of strong, nonabsorbable, curved sutures of size 1.0 or larger, made from silk or nylon⁺; and a chest tube of appropriate size (see below). A commercially available pleural drainage system, such as the Pleur-evac (Teleflex Medical), should also be ready for connection after the chest tube is inserted.

From the Department of Critical Care Medicine, Sunnybrook Health Sciences Centre, University of Toronto, Toronto. Address reprint requests to Dr. Dev at the Department of Critical Care, Sunnybrook Health Sciences Centre, 2075 Bayview Ave., Office D-112, Toronto, ON M4N 3M5, Canada, or shelly.dev@sunnybrook.ca.

N Engl J Med 2007;357:e15.
Copyright © 2007 Massachusetts Medical Society.

Table 1. Indications for Chest-Tube Insertion.

Emergency

Pneumothorax

- In all patients on mechanical ventilation
- When pneumothorax is large
- In a clinically unstable patient
- For tension pneumothorax after needle decompression
- When pneumothorax is recurrent or persistent
- When pneumothorax is secondary to chest trauma
- When pneumothorax is iatrogenic, if large and clinically significant

Hemopneumothorax

Esophageal rupture with gastric leak into pleural space

Nonemergency

- Malignant pleural effusion
- Treatment with sclerosing agents or pleurodesis
- Recurrent pleural effusion
- Parapneumonic effusion or empyema
- Chylothorax
- Postoperative care (e.g., after coronary bypass, thoracotomy, or lobectomy)

Grasp the proximal free end of the chest tube with a clamp or forceps. Using another clamp or forceps, grasp the distal tip of the tube to prepare it for insertion.⁴

CHEST-TUBE SIZE

The size of the chest tube that is needed depends on the indication for the insertion of a chest tube. Table 2 provides a summary of size recommendations based on indication.⁵⁻¹¹

PREPARATION

If time permits, explain the procedure to the patient or next of kin and obtain written consent; this may not be possible when the need for chest-tube insertion is urgent.

Position the patient in either a supine or a semirecumbent position. Maximally abduct the ipsilateral arm or place it behind the patient's head. The area for insertion is approximated by the fourth to fifth intercostal space in the anterior axillary line at the horizontal level of the nipple. This area corresponds to the anterior border of the latissimus dorsi, the lateral border of the pectoralis major muscle, the apex just below the axilla, and a line above the horizontal level of the nipple—often referred to as the “triangle of safety.”² You can isolate this area by palpating the ipsilateral clavicle, then working downward along the ribcage, counting down the rib spaces. Once the fourth to fifth intercostal space is felt, move your hand laterally toward the anterior axillary line (Fig. 1). This is the area for incision; the actual insertion site should be one intercostal space above the chest-tube incision site. Mark the spot for incision on the skin with a pen or the back of a needle.

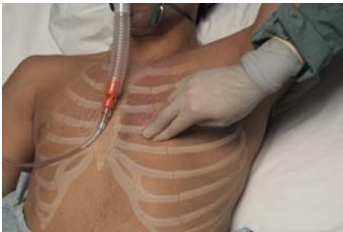

Figure 1. Locating Landmarks.

Use full barrier precautions (wash your hands and wear a sterile gown and gloves, protective eyewear, and a face mask). Create a large, sterile field on the patient's skin, using sterile gauze and 2% chlorhexidine solution. Drape the patient, exposing only the marked area. Using a 1% or 2% lidocaine solution and a 25-gauge needle, create a wheal of anesthetic in the cutaneous tissue at the marked spot. Draw up more lidocaine solution in a 20-ml syringe. Using a 21-gauge needle, anesthetize the deeper subcutaneous tissues and intercostal muscles. Locate the rib lying below the intercostal space where the tube will be inserted, and continue to anesthetize the periosteal surface. Ten to 20 ml of lidocaine solution may be used to ensure optimal analgesia.¹ While anesthetizing the rib, find the superior aspect of the rib and use this to bevel or “march” the needle on top of it. Using continued negative suction as the needle advances, with the needle beveled on top of the rib, confirm entry into the pleural space when a flash of pleural fluid enters the cham-

Table 2. Sizing of Chest Tubes on the Basis of Indication.

Indication for Chest Tube	Recommended Size of Chest Tube
Pneumothorax	
Large pneumothorax in patient in stable condition	16-French to 22-French 14-French or smaller (insert by Seldinger method)*
Large pneumothorax in patient in unstable condition Patient receiving mechanical ventilation Secondary pneumothorax	24-French to 28-French
Pleural collections	
Malignant pleural effusion Transudative effusion	Consider smaller-bore, 8-French to 16-French first* If ineffective, try larger-bore (22-French or larger)
Parapneumonic effusion Empyema	No firm recommendations 20-French or larger may be tried

* The Seldinger method of chest-tube insertion is performed with the use of 14-French or smaller chest drains usually under ultrasound guidance either at the bedside or in a radiology suite. This method is not covered in this review.

ber of the syringe. If a pneumothorax is being evacuated, the syringe may only fill with air. Stop advancing the needle and inject any remaining lidocaine to fully anesthetize the parietal pleura. Withdraw the needle and syringe completely.

INCISION AND DISSECTION

An incision 1.5 to 2.0 cm in length should be made parallel to the rib. Use the Kelly clamp or artery forceps to cut through the subcutaneous layers and intercostal muscles (Fig. 2). The path should traverse diagonally up toward the next superior intercostal space. Once you have dissected through the subcutaneous tissues, find the surface of the rib lying below this space with the dissecting instrument. Then slide the instrument straight up, until you find the top edge of the rib. Use this to bevel or balance the dissecting instrument as you dissect the intercostal muscles (Fig. 3). Once you reach the parietal pleura, gently push the dissecting instrument through it. You may also digitally penetrate the pleura to avoid puncturing adjacent lung tissue,^{3,4} using your index finger to explore the tract. Once your finger enters the pleura, withdraw the Kelly clamp. Use your finger to palpate within the pleural layer and ensure that the lung falls away from the pleura.¹ If it does not, this may indicate the presence of an adhesion, so tube insertion may be difficult. (Trocar insertion, considered dangerous, is no longer advised.⁴)

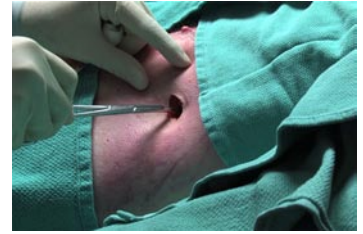


Figure 2. Dissection.

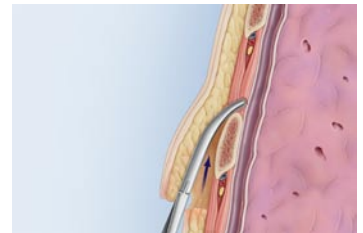


Figure 3. Positioning the Dissection Instrument.

TUBE INSERTION

Once the distal tip of the tube has passed through the incision, unclamp the Kelly clamps or forceps and advance the tube manually. Aim the tube apically for evacuation of a pneumothorax and basally for evacuation of any fluid.¹⁻³

SECURING THE TUBE

Mattress or interrupted sutures should be used on both sides of the incision to close the ends. Use the loose ends of the sutures to wrap around the tube and tie them off, anchoring the tube to the chest wall.¹ Tape the tube to the side of the patient and wrap a petroleum-based gauze dressing around the tube. Cover this gauze with several pieces of regular sterile gauze, and secure the site with multiple pressure dressings.

Purse-string sutures are not recommended owing to poor cosmetic results and increased risk of skin necrosis; the seal they provide does not prevent air leaks.³

Connect the distal end of the chest tube to a sterile pleural drainage system, such as the commercially available Pleur-evac. Once the tube is connected, unclamp the distal end; if there is a pneumothorax, bubbling may be seen. If there is a large pleural effusion, it will begin collecting. Do not reclamp the chest tube, once released, unless the pleural drainage system is being changed. Reclamping the tube may lead to the redevelopment of a pneumothorax and may create a tension pneumothorax.

CHEST RADIOGRAPH CONFIRMATION

Once you have secured the chest tube, obtain an anterior-posterior chest radiograph to confirm placement, which can be done by identifying the radio-opaque line along the tube. If the proximal drainage hole is outside the pleural space, drainage may be ineffective and an air leak may result. In this circumstance, the tube should be removed and a new chest tube inserted.

COMPLICATIONS

The most important complications associated with chest-tube insertion^{1-3,9} include bleeding and hemothorax due to intercostal artery perforation, perforation of visceral organs (lung, heart, diaphragm, or intraabdominal organs), perforation of ma-

REFERENCES

1. Miller KS, Sahn SA. Chest tubes: indications, technique, management and complications. *Chest* 1987;91:258-64.
2. Laws D, Neville E, Duffy J. BTS guidelines for the insertion of a chest drain. *Thorax* 2003;58:Suppl 2:ii53-ii59.
3. Tang ATM, Velissaris TJ, Weeden DF. An evidence-based approach to drainage of the pleural cavity: evaluation of best practice. *J Eval Clin Pract* 2002;8:333-40.
4. Hyde J, Sykes T, Graham T. Reducing morbidity from chest drains. *BMJ* 1997;314:914-5.
5. Baumann MH. What size chest tube? What drainage system is ideal? And other chest tube management questions. *Curr Opin Pulm Med* 2003;9:276-81.
6. Parulekar W, Di Primo G, Matzinger F, Dennie C, Bociek G. Use of small-bore vs large-bore chest tubes for treatment of malignant pleural effusions. *Chest* 2001;120:19-25.
7. Antunes G, Neville E, Duffy J, Ali N. BTS guidelines for the management of malignant pleural effusions. *Thorax* 2003;58:Suppl 2:ii29-ii38.
8. American Thoracic Society. Management of malignant pleural effusions. *Am J Respir Crit Care Med* 2000;162:1987-2001.
9. Light RW. Parapneumonic effusions and empyema. *Proc Am Thorac Soc* 2006;3:75-80.
10. Davies CWH, Gleeson FV, Davies RJO. BTS guidelines for the management of pleural infection. *Thorax* 2003;58:Suppl 2:ii18-ii28.
11. Baumann MH, Strange C, Heffner JE, et al. Management of spontaneous pneumothorax: an American College of Chest Physicians Delphi consensus statement. *Chest* 2001;119:590-602.

Copyright © 2007 Massachusetts Medical Society.

major vascular structures such as the aorta or subclavian vessels, intercostal neuralgia due to trauma of neurovascular bundles, subcutaneous emphysema, reexpansion pulmonary edema, infection of the drainage site, pneumonia, and empyema. There may be technical problems such as intermittent tube blockage from clotted blood, pus, or debris, or incorrect positioning of the tube, which causes ineffective drainage.

TIMING OF CHEST-TUBE REMOVAL

The timing of chest-tube removal depends on the indication for insertion of the chest tube.

For a pneumothorax, bubbling must have ceased and the lung must be fully expanded on chest radiograph before the tube can be removed. If suction is being used to evacuate a pneumothorax, most physicians will use a trial of underwater seal to ensure that the lung stays expanded without suction. Practice differs greatly among physicians with regard to duration of observation after air leak cessation and before removal of the tube and whether or not to clamp the tube before removal to rule out a persistent air leak.¹¹ On the basis of available data, most physicians would obtain a chest radiograph 12 to 24 hours after the last observed evidence of an air leak to ensure that the lung stays fully expanded before tube removal. Because opinion and practice are clearly divided on the need for clamping the drain before tube removal, no strong recommendation can be made here.

If placement was for any pleural fluid drainage, once the drainage volume is less than 200 ml in a 24-hour period,^{3,5} the fluid is serous, the lung has re-expanded on the chest film, and the patient's clinical status has improved, the chest tube may be removed.

If the patient's condition fails to improve after chest-tube insertion, a respirologist or a thoracic surgeon should be consulted for more definitive management, such as fibrinolytic therapy or surgical decortication.^{8,9}

TECHNIQUE OF TUBE REMOVAL

The major concern with removal of a chest tube is the risk of pneumothorax during removal. Again, physician practice differs with respect to the point in the respiratory cycle at which the tube is removed: during end-inspiration or end-expiration. Neither has been shown to be superior in the prevention of pneumothorax.⁵ When preparing to remove the tube, two people may need to participate so that one can instruct the spontaneously breathing patient and pull the tube while the other can quickly occlude the insertion site. Cut the skin sutures, using sterile technique. Have additional strong nylon or silk sutures ready in case additional sutures are required to seal the hole. Sterile petroleum-based and regular gauze should also be ready.

Instruct the spontaneously breathing patient to perform a forced Valsalva maneuver or to inhale to total lung capacity after a full exhalation. If the patient is being fully mechanically ventilated, removal should be timed to end-expiration. One operator can pull the tube out while the other quickly occludes the site with gauze, adds additional sutures to close the opening, and secures the site with a pressure dressing. A chest radiograph 12 to 24 hours after removal is recommended^{1,3}; this should be done sooner if there is clinical suspicion of a residual air leak or a new pneumothorax.

Caution must be exercised when removing a chest tube from any patient receiving mechanical ventilation. This is of particular importance for patients with high oxygen or positive end-expiratory pressure requirements, chronic lung disease, or any additional reasons for persistent air leaks or recurrent pneumothoraces. In these cases, highly experienced physicians should supervise the decision to remove a chest tube.

No potential conflict of interest relevant to this article was reported.

VIDEOS IN CLINICAL MEDICINE

Orotracheal Intubation

Christopher Kabrhel, M.D., Todd W. Thomsen, M.D., Gary S. Setnik, M.D.,
and Ron M. Walls, M.D.

INDICATIONS

Orotracheal intubation is indicated in any situation that requires definitive control of the airway. Orotracheal intubation is commonly performed to facilitate control of the airway in a patient undergoing general anesthesia. It is also performed as part of the care of critically ill patients with multisystem disease or injuries. Emergency indications include cardiac or respiratory arrest, failure to protect the airway from aspiration, inadequate oxygenation or ventilation, and existing or anticipated airway obstruction.

CONTRAINDICATIONS

In urgent situations or emergencies, such as when a patient is in cardiac arrest, airway management is of paramount importance, and there are very few contraindications to orotracheal intubation. Orotracheal intubation by direct laryngoscopy is somewhat contraindicated in a patient with partial transection of the trachea, because the procedure can cause complete tracheal transection and loss of the airway. In these cases, surgical airway management may be necessary. Unstable cervical spine injury is not a contraindication, but strict, in-line stabilization of the cervical spine must be maintained during intubation. An assistant should stand at the side of the bed and hold the patient's head, neck, and shoulders in an anatomically neutral position. The anterior portion of the cervical collar is opened or removed to permit the patient's mouth to be fully opened.

When immediate intubation is not required, the difficulty of intubation should first be assessed. This assessment is discussed in detail in the Preparation section, under Sedation and Paralysis.

EQUIPMENT

You will need the following equipment: gloves, a protective face shield, a working suction system, a bag-valve mask attached to an oxygen source, an endotracheal tube with stylet, a 10-ml syringe, an endotracheal-tube holder (cloth tape may be used if a tube holder is not available), an end-tidal carbon dioxide detector, a stethoscope, and laryngoscopes with appropriate blades. The two main types of laryngoscope blades are the Macintosh blade, which is curved, and the Miller blade, which is straight. Each is available in various sizes, and each requires a slightly different technique. The choice of blade depends on the operator's experience and personal preference. A size 3 or 4 Macintosh blade or size 2 or 3 Miller blade can be used in most adult patients.

Endotracheal tubes are sized according to the internal diameter of the tube; 7.0-, 7.5-, or 8.0-mm tubes are appropriate for most adults.¹⁻³ The appropriate tube size for use in children can be determined by adding 4 to the patient's age in years and then dividing by 4 ($[\text{age in years} + 4] \div 4 = \text{tube size}$), by matching the external

From the Department of Emergency Medicine, Massachusetts General Hospital, Boston (C.K.); the Department of Emergency Medicine, Mount Auburn Hospital, Cambridge, MA (T.W.T., G.S.S.); the Department of Emergency Medicine, Brigham and Women's Hospital, Boston (R.M.W.); and the Division of Emergency Medicine, Harvard Medical School, Boston (C.K., T.W.T., G.S.S., R.M.W.).

N Engl J Med 2007;356:e15.

Copyright © 2007 Massachusetts Medical Society.

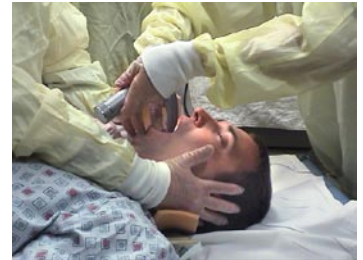

Figure 1. In-line stabilization of the cervical spine

diameter of the tube to the width of the patient's little fingernail, or by using a system based on the child's height or length (such as the Broslow–Luten resuscitation tape).¹

Tubes can be cuffed or uncuffed. Cuffed tubes are appropriate for adults and older children. Uncuffed tubes are used for younger patients (those requiring a tube smaller than 5.5 mm).^{1,2} After inserting a cuffed tube, you must inflate the balloon on the distal end to create a seal between the tube and the tracheal lumen. This seal will prevent leakage of air and aspiration of gastric contents.

PREPARATION

Before proceeding, be sure that all equipment is readily accessible and functioning, that personnel are properly prepared, and that written informed consent has been obtained from the patient or the patient's health care proxy if the clinical situation permits. Inflate the cuff of the endotracheal tube to check for leaks. Insert the stylet into the endotracheal tube, maintaining the tube's natural curve. Make sure the tip of the stylet does not extend beyond the end of the tube. If necessary, the stylet can be used to reshape the endotracheal tube, as in the "hockey stick" maneuver, to facilitate intubation of an anterior larynx. Ensure that the suction catheter is secure and within easy reach. Obtain intravenous access, and place the patient on a monitor if time and conditions permit. Assign an assistant to watch the monitor during the procedure and to report any changes.

Adjust the height of the bed so that the patient's head is level with the lower portion of your sternum. Unless there are contraindications, move the patient into the "sniffing" position by placing a pillow or folded towel under the patient's occiput. This combination of flexion of the neck and extension of the head improves the alignment of the axes of the oral cavity, pharynx, and larynx, facilitating optimal visualization of the vocal cords.^{1,3} When intubating an infant, you typically do not need to provide additional head support, because the infant's large occiput naturally causes the head to assume the sniffing position.

If the clinical situation allows, preoxygenate the patient with a non-rebreather mask or by having the patient breathe 100% oxygen through a bag-valve mask for at least 3 minutes before intubation.³ Preoxygenation replaces the primarily nitrogenous mixture of ambient air, which constitutes the patient's functional residual capacity, with oxygen. This increases the interval before desaturation in a patient who is hypoventilating or apneic. This preliminary step is essential to minimize the need for positive-pressure ventilation during intubation, thus reducing the risk of aspiration of gastric contents.³

Remove the patient's upper and lower dentures, if present, immediately before laryngoscopy. Re-insert the patient's dentures to improve the mask seal if bag-valve-mask ventilation is required.

If the patient's mental status is diminished or if the patient is pharmacologically sedated, an assistant should apply firm pressure to the cricoid cartilage. This maneuver (the Sellick maneuver) compresses the soft-walled esophagus between the cricoid cartilage and the cervical vertebrae, theoretically preventing passive regurgitation of gastric contents.² If the airway becomes distorted, releasing cricoid pressure may improve visualization of the glottis.

Sedation and Paralysis

In many cases, a neuromuscular-blocking agent and a potent sedative are needed to facilitate intubation. These agents will improve your visualization of the vocal cords and prevent the patient from vomiting and aspirating gastric contents.³ If you plan

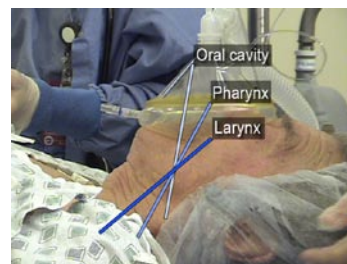

Figure 2. The "sniffing" position

to use such agents, you must assess the difficulty of intubation before proceeding.³ You can generally predict that intubation will be difficult if the patient has a history of difficult intubation, limited neck mobility, a small mandible, pharyngeal structures that are poorly visible through the open mouth with tongue extruded, a limited ability to open his or her mouth, or a laryngeal prominence that is close to the mentum.^{1,3} Anatomical distortion (such as by tumors, trauma, or infection), edema, or obstruction of the airway may also lead to difficult orotracheal intubation. When faced with a potentially difficult intubation, you should make contingency plans, including preparation for an alternative intubation technique, such as using a gum-elastic bougie, a laryngeal mask airway, a fiberoptic intubating bronchoscope, or a surgical technique.

THE PROCEDURE

Position your body so that your eyes are far enough from the patient to facilitate binocular vision. While holding the laryngoscope in your left hand, open the patient's mouth with your right hand. Insert the laryngoscope blade to the right of the patient's tongue. Gradually move the blade to the center of the mouth, pushing the tongue to the left. Slowly advance the blade and locate the epiglottis. Ideal placement of the laryngoscope blade depends on whether a curved or a straight blade is used. If you are using a curved blade, place the tip into the vallecula epiglottica, which is between the base of the tongue and the epiglottis. If you are using a straight blade, place the tip of the blade posterior to the epiglottis.

With the tip of the blade correctly positioned, lift the laryngoscope upward and forward at a 45-degree angle to expose the vocal cords. Direct the force of your lifting action along the axis of the laryngoscope's handle, in the direction of the ceiling, over the patient's feet. Avoid bending your wrist or rocking the blade against the patient's teeth, since this can result in dental or soft-tissue injury (and will not enhance the view of the glottis).

While holding the endotracheal tube in your right hand and maintaining your view of the vocal cords, insert the endotracheal tube into the right side of the patient's mouth. The tube should not obstruct your view of the vocal cords during this critical part of the procedure. Pass the tube through the vocal cords until the balloon disappears into the trachea.

Remove the stylet, and advance the tube until the balloon is 3 to 4 cm beyond the vocal cords. Inflate the endotracheal balloon with air to the minimum pressure required to prevent air leakage during tidal-volume ventilation with a bag. This usually requires less than 10 ml of air. Have an assistant maintain cricoid pressure until you have confirmed that the tube is in the trachea.

Troubleshooting

If you cannot see the vocal cords or epiglottis after positioning the laryngoscope blade, you have probably inserted the blade too far or have not placed the blade precisely in the midline. Withdrawing the blade gradually in the midline will often allow the epiglottis or larynx to drop into view. Manipulating the larynx with your right hand or having an assistant apply firm backward, upward, and rightward pressure (the so-called BURP maneuver) to the larynx can also facilitate visualization of the vocal cords.² An assistant can gently pull the right side of the patient's lip and cheek to enhance visibility of the glottis. If you still cannot see the cords clearly, an assistant should gently release the cricoid pressure, since this compression can sometimes compromise the view. You should always achieve the best possible view of the vocal cords before attempting to insert the endotracheal tube.

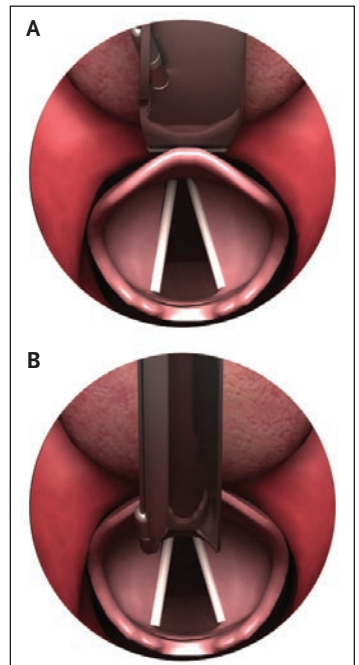


Figure 3. Proper placement of the curved (Panel A) and straight (Panel B) laryngoscope blades

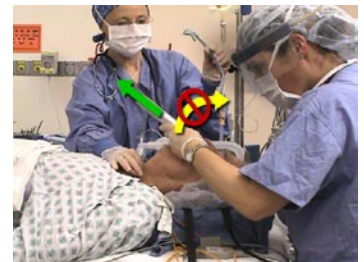

Figure 4. Proper orientation of the lifting action

Confirmation

The end of the endotracheal tube should lie in the mid-trachea, 3 to 7 cm above the carina. A good general rule is to align the 22-cm marking on the tube with the front teeth of an average-sized adult.² For children, you can use the following formula to estimate the proper depth of tube insertion¹: tube depth (in centimeters) = [(child's age in years) ÷ 2] + 12. Place the end-tidal carbon dioxide detector onto the endotracheal tube and attach the ventilation bag, administering a few tidal-volume breaths. Proper tube placement cannot be confirmed solely on the basis of a physical examination or by a finding of fogging of the tube. Other techniques must be used to confirm this most critical aspect of management. Carbon dioxide will be reliably and consistently detected within the first six breaths after orotracheal intubation and with each exhalation thereafter.⁴ In some patients in cardiac arrest, gas exchange does not occur. Thus, carbon dioxide may not be present, even when the tube is in the trachea.⁴ In such cases, you may use a self-inflating bulb (esophageal-detector device) or a fiberoptic endoscope to visualize the tracheal rings.

Perform a secondary assessment to confirm proper esophageal-tube placement by auscultating over the stomach during positive-pressure ventilation. Auscultate both lungs in the midaxillary line to confirm that there is equal, bilateral air movement. If breath sounds are diminished on the left side after intubation, the right main bronchus has probably been intubated. Gradually withdraw the endotracheal tube until symmetrical (i.e., bilateral) breath sounds are auscultated.

Use chest radiography to assess the patient's pulmonary status after intubation and to ensure that the tip of the radio-opaque line embedded in the endotracheal tube is positioned at the level of the mid-trachea and not in either main bronchus. Radiography is not a reliable means of detecting esophageal intubation.

Securing the Tube

Secure the endotracheal tube to the patient's head once you have confirmed that the tube is in the proper position. You should use an endotracheal-tube holder to secure the tube, because this device helps prevent accidental displacement.^{1,2} If such a device is not available, you may use adhesive tape or cloth endotracheal-tube tape. Pharmacologic sedation and hand restraints may be used to prevent the patient from inadvertently removing the tube.

COMPLICATIONS

The most serious complication of endotracheal intubation is unrecognized esophageal intubation, which may lead to hypoxemia, hypercapnia, and death. Laryngoscopy can provoke vomiting and aspiration of gastric contents, causing pneumonitis or pneumonia. Additional complications include bradycardia, laryngospasm, bronchospasm, and apnea owing to pharyngeal stimulation. Trauma to teeth, lips, and vocal cords and exacerbation of cervical spine injuries can also occur.

REFERENCES

1. Lutes M, Hopson LR. Tracheal intubation. In: Roberts JR, Hedges JR, ed. *Clinical procedures in emergency medicine*. 4th ed. Philadelphia: Saunders, 2004:69-99.
2. Schneider RE. Basic airway management. In: Walls RM, ed. *Manual of emergency airway management*. Philadelphia: Lippincott Williams & Wilkins, 2000:43-57.
3. Walls RM. Rapid sequence intubation. In: Walls RM, ed. *Manual of emergency airway management*. Philadelphia: Lippincott Williams & Wilkins, 2000:8-15.
4. *Idem*. Confirmation of endotracheal tube placement. In: Walls RM, ed. *Manual of emergency airway management*. Philadelphia: Lippincott Williams & Wilkins, 2000:27-30.

Copyright © 2007 Massachusetts Medical Society.

CORRECTION

Orotracheal Intubation

Orotracheal Intubation . In the PDF summary of the video, the third sentence under "Confirmation" should have read, "For children, you can use the following formula to estimate the proper depth of tube insertion¹: tube depth (in centimeters)=[(child's age in years)+2]+12," rather than "tube depth=[(child's age in years)+2]+12." The text has been corrected on the *Journal's* Web site at www.nejm.org.

VIDEOS IN CLINICAL MEDICINE

Cricothyroidotomy

James Hsiao, M.D., and Victor Pacheco-Fowler, M.D.

INDICATIONS

Cricothyroidotomy is an emergency procedure performed on patients with severe respiratory distress in whom attempts at orotracheal or nasotracheal intubation either have failed or were deemed to have an unacceptable level of risk. The procedure involves making an incision in the cricothyroid membrane, which lies between the thyroid and cricoid cartilages, and inserting a tracheostomy tube into the trachea to allow ventilation.

The major indication for cricothyroidotomy is the inability to establish an airway through orotracheal or nasotracheal intubation, which may be due to difficult patient anatomy, excessive blood in the mouth or nose, massive facial trauma, or airway obstruction resulting from angioedema, trauma, burns, or a foreign body obstructing the airway.

The rate of failed emergency department intubations and subsequent surgical airway management is lower than 0.6%.¹ In the emergency department, cricothyroidotomy has been used for 1.0 to 2.8% of all intubation attempts in patients with trauma.²⁻⁴ Whenever possible, cricothyroidotomy should be performed by physicians fully trained and skilled in carrying out the procedure, such as emergency physicians, surgeons, and intensivists.

A tracheostomy tube placed during a cricothyroidotomy performed under emergency conditions can be left in place for up to 72 hours. Because of the potential complications of cricothyroidotomy, including subglottic stenosis and damage to the thyroid and cricoid cartilages, a cricothyroidotomy should be converted to a tracheostomy if airway access is needed for more than 72 hours.⁵ Although tracheostomy is preferred for long-term management, it should be performed in the controlled setting of the operating room. In urgent situations, cricothyroidotomy should be performed.

Surgical cricothyroidotomy involves inserting a tracheostomy tube into the trachea through an incision in the cricothyroid membrane. In needle cricothyroidotomy, a catheter is placed over a needle that penetrates the membrane, allowing ventilation by a pressurized stream of oxygen. Because the catheter has a smaller diameter, it is less effective in providing adequate ventilation and should be used only as a temporizing measure while preparation is made for surgical cricothyroidotomy or tracheostomy. Needle cricothyroidotomy is the preferred method of establishing an emergency airway in children younger than 10 to 12 years, since the larynx is more easily damaged by surgical cricothyroidotomy in this age group, with a higher incidence of postoperative airway complications.⁶

CONTRAINDICATIONS

Cricothyroidotomy should not be performed when there is massive trauma to the larynx or cricoid cartilage. When orotracheal and nasotracheal intubation are viable options, they should be attempted before cricothyroidotomy is considered.

From the Department of Emergency Medicine, New York–Presbyterian Hospital, New York. Address reprint requests to Dr. Hsiao at 445 East 68th St., #7H, New York, NY 10065, or at james_j_hsiao@yahoo.com.

N Engl J Med 2008;358:e25.

Copyright © 2008 Massachusetts Medical Society.

PREPARATION

Since cricothyroidotomy is an emergency procedure, there may not be time to obtain informed consent, and the patient may not be able to provide consent. The procedure should be performed in emergency situations even in the absence of informed consent.

For sterilization and local anesthesia, the following are needed: gloves, a protective gown, a face shield, chlorhexidine or povidone iodine (Betadine, Purdue Pharma), gauze pads, 1% or 2% lidocaine with epinephrine, and a 6-ml syringe with a 25-gauge needle. To perform the procedure, the following are needed: a tracheostomy tube, a scalpel with a number 10 or 11 blade, a curved hemostat, a Trousseau dilator, a tracheal hook, a 10-ml syringe, and suture or tying material. A bag-valve device and an oxygen source should be available to ventilate the patient once the procedure has been performed.

A tracheostomy tube with an internal diameter of 6 mm should be used. A tube with an internal diameter larger than 7 mm would be difficult to insert into the cricothyroid membrane.

The tracheostomy tube comprises three parts (Fig. 1). The outer cannula has a neck plate extending from the sides that allows the tube to be secured to the neck with sutures or a cloth tie. The inner cannula has an adaptor at the end that attaches to a bag-valve device or mechanical ventilator. The obturator provides a smooth surface to guide insertion of the tube (Fig. 1).

A 6-mm endotracheal tube can be used as an alternative to the tracheostomy tube, but this option is much less preferable because an endotracheal tube is more difficult to secure to the patient's neck. Endotracheal tube holders or other devices may be used to help secure an endotracheal tube to the neck. Another advantage of the tracheostomy tube is that it is shorter than an endotracheal tube and therefore easier to suction.⁷

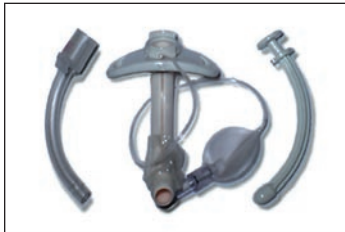

Figure 1. Components of the Tracheostomy Tube.

Shown from left to right are the inner cannula, outer cannula, and obturator.

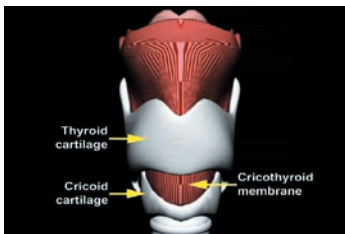


Figure 2. Landmarks for Cricothyroidotomy.

The incision is made in the cricothyroid membrane.

PROCEDURE

Place the patient in the supine position. Since this procedure is performed in extremely urgent circumstances, there is usually not time to drape the patient. Chlorhexidine or povidone iodine should be applied if time permits. If the patient is awake, administer local anesthesia.

Directions are given for a right-handed operator. Side-specific designations should be reversed for left-handed operators.

To perform cricothyroidotomy, stand on the patient's right side. Stabilize the larynx with your left thumb and middle finger, and use your index finger to palpate the thyroid cartilage. Move your index finger down until you palpate the cricoid cartilage. The space between the thyroid and cricoid cartilages is the cricothyroid membrane. This is where you will make the incision (Fig. 2).

Use the scalpel to make a 2.5-cm vertical incision through the skin and subcutaneous tissue. Use the curved hemostat to make a blunt dissection in the subcutaneous tissue. The initial incision should be vertical for two reasons: first, a vertical incision will avoid injury to the recurrent laryngeal nerves, which run parallel to the trachea, and second, an initial incision above or below the cricothyroid membrane, if vertical, will allow extension of the incision as needed. Starting with a horizontal incision that is too low or too high would necessitate a new incision in the correct location.

Next, use the scalpel to make a horizontal incision through the cricothyroid membrane. You may feel a pop as you enter the trachea. Extend the incision laterally, turn the blade, and extend it in the opposite direction.

To avoid penetrating too deeply and perforating the esophagus, which lies posterior to the trachea, do not go more than 1.3 cm (1/2 inch) deep (Fig. 3). To minimize the risk of esophageal perforation, hold the scalpel between your thumb and index finger, and allow your middle finger to extend down the side of the scalpel, leaving the distal 1.3 cm of the blade exposed. If the patient is trying to breathe, once you enter the trachea, airflow should be audible and may also be visible.

Once the trachea has been entered, make sure the blade stays within the incision, so that communication with the trachea is never lost. Insert a tracheal hook, and pull upward on the distal portion of the incision, elevating the larynx. Once the tracheal hook is in place, you may remove the blade.

Insert a Trousseau dilator and open the membrane vertically, then insert the tracheostomy tube. Holding the cannula in place, remove the obturator and attach the adaptor. Inflate the cuff with a 10-ml syringe. Attach a bag-valve unit and ventilate the patient. Look for symmetric chest rise and auscultate for symmetric breath sounds. Tie or suture the tracheostomy tube in place. Dispose of needles and sharps in an appropriate container.

If an endotracheal tube is used in place of a tracheostomy tube, make sure the tube is not inserted to a depth of more than 2 to 3 cm. Deeper placement of the tube may cause it to go down the right mainstem bronchus.

COMPLICATIONS

There are three major complications of cricothyroidotomy. First, esophageal perforation occurs when the blade penetrates too deeply. To prevent this, allow only the distal 1.3 cm of the blade to enter the trachea. Second, subcutaneous emphysema may occur if the horizontal incision is too wide, allowing air to become trapped in the subcutaneous tissue. Third, excessive bleeding or hemorrhage may occur if a vessel is ruptured. If minor vessels are injured, the bleeding can be controlled with direct pressure. If there is rupture of major vessels, such as the carotid artery or internal jugular vein, ligation may be required.

POSTPROCEDURAL CARE

After the procedure, obtain a chest x-ray film to confirm placement of the tracheostomy tube. Call for respiratory therapy so the patient can be mechanically ventilated. Obtain a surgical consult so that definitive tracheostomy can be performed, if necessary. A tracheostomy tube placed during an emergency cricothyroidotomy can be left in place for up to 72 hours.

No potential conflict of interest relevant to this article was reported.

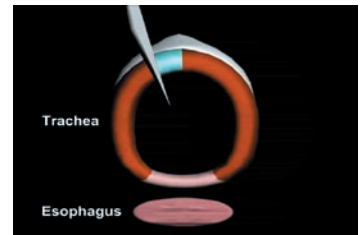


Figure 3. Cross-Sectional View of Trachea and Esophagus.

REFERENCES

1. Bair AE, Filbin MR, Kulkarni RG, Walls RM. The failed intubation attempt in the emergency department: analysis of prevalence, rescue techniques, and personnel. *J Emerg Med* 2002;23:131-40. [Erratum, *J Emerg Med* 2002;23:325.]
2. Bushra JS, McNeil B, Wald DA, Schwell A, Karras DJ. A comparison of trauma intubations managed by anesthesiologists and emergency physicians. *Acad Emerg Med* 2004;11:66-70.
3. Erlandson MJ, Clinton JE, Ruiz E, Cohen J. Cricothyrotomy in the emergency department revisited. *J Emerg Med* 1989;7:115-8.
4. Bair AE, Panacek EA, Wisner DH, Bales R, Sakles JC. Cricothyrotomy: a 5-year experience at one institution. *J Emerg Med* 2003;24:151-6.
5. Esses BA, Jafek BW. Cricothyroidotomy: a decade of experience in Denver. *Ann Otol Rhinol Laryngol* 1987;96:519-24.
6. Sise MJ, Shackford SR, Cruickshank JC, Murphy G, Fridlund PH. Cricothyroidotomy for long-term tracheal access: a prospective analysis of morbidity and mortality in 76 patients. *Ann Surg* 1984;200:13-7.
7. Gens DR. Surgical airway management. In: Tintinalli JE, Kelen GD, Stapczynski JS, eds. *Emergency medicine: a comprehensive study guide*. 6th ed. New York: McGraw-Hill, 2004:119-24.

Copyright © 2008 Massachusetts Medical Society.