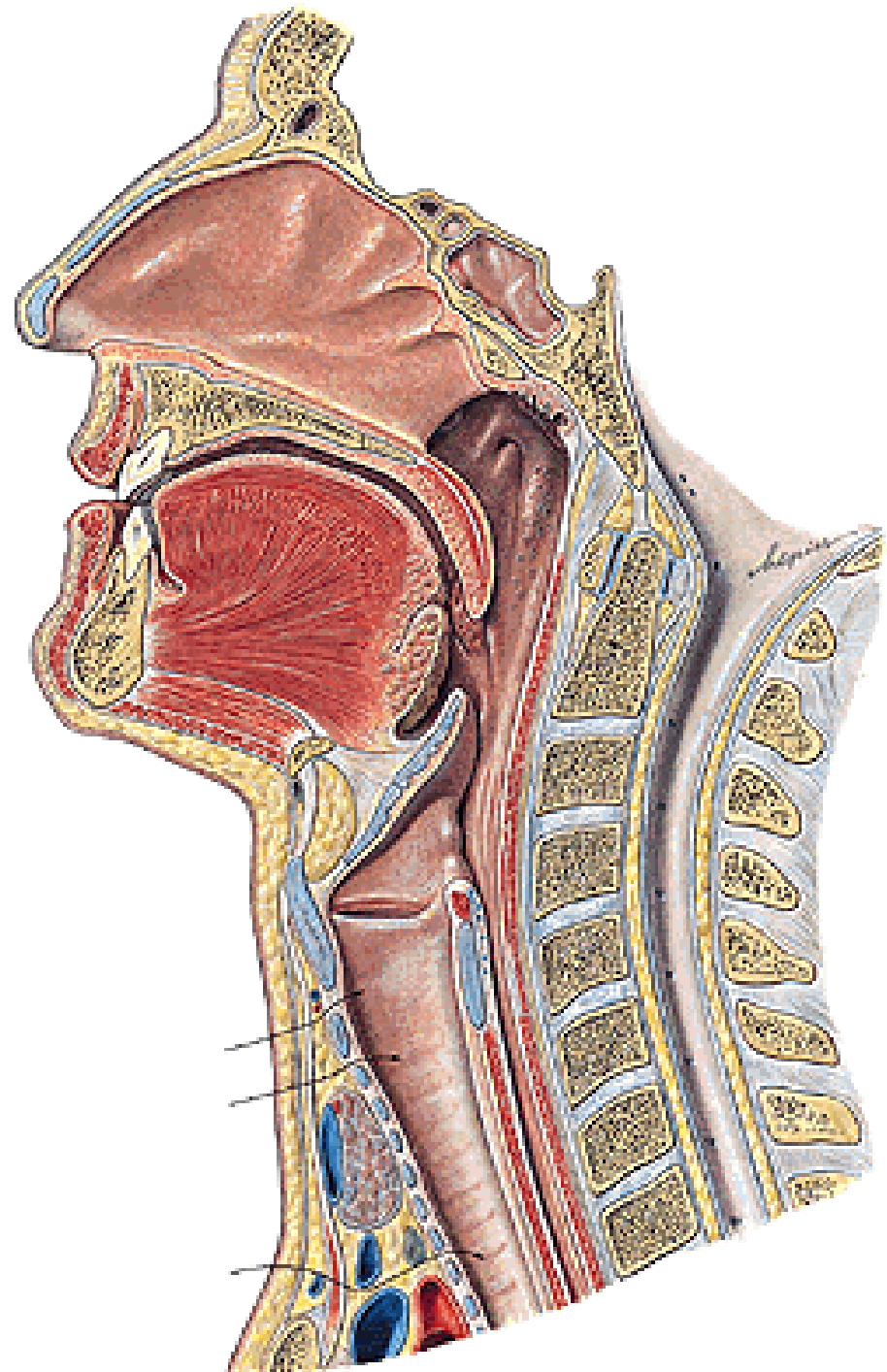


DIGESTIVE SYSTEM II.

PHARYNX

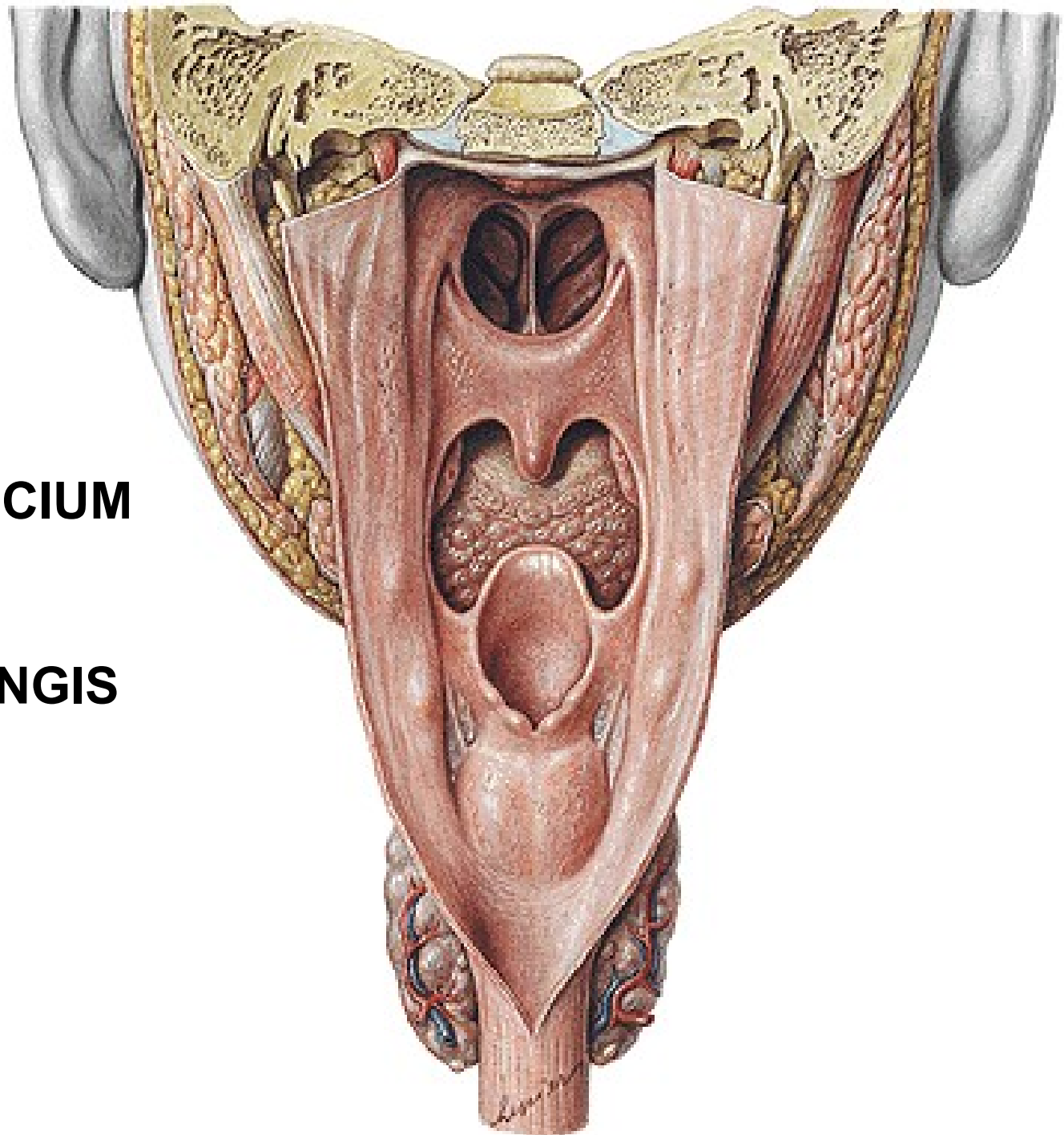
Fornix pharyngis
Cavum pharyngis



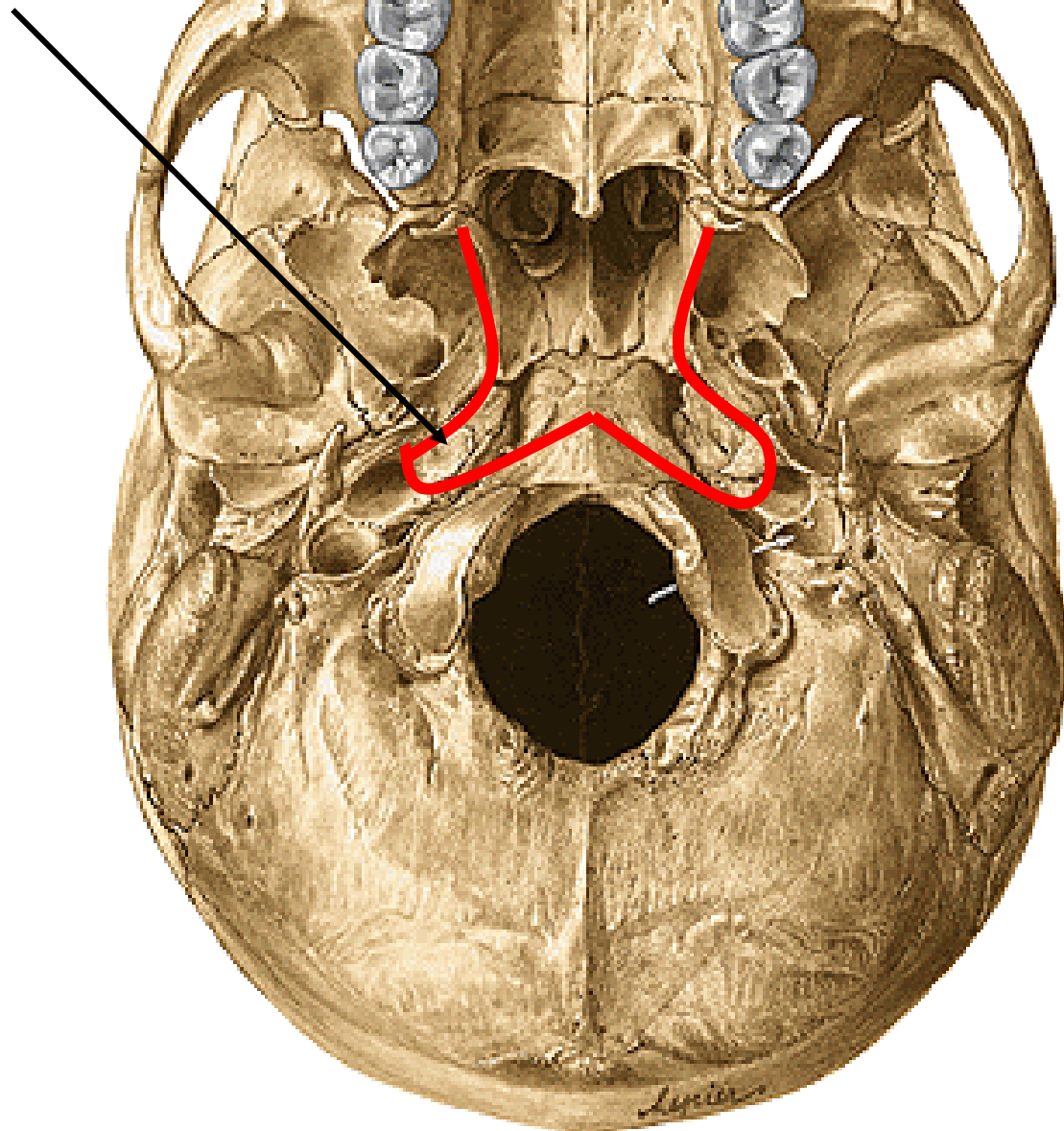
CHOANAE

ISTHMUS FAUCIUM

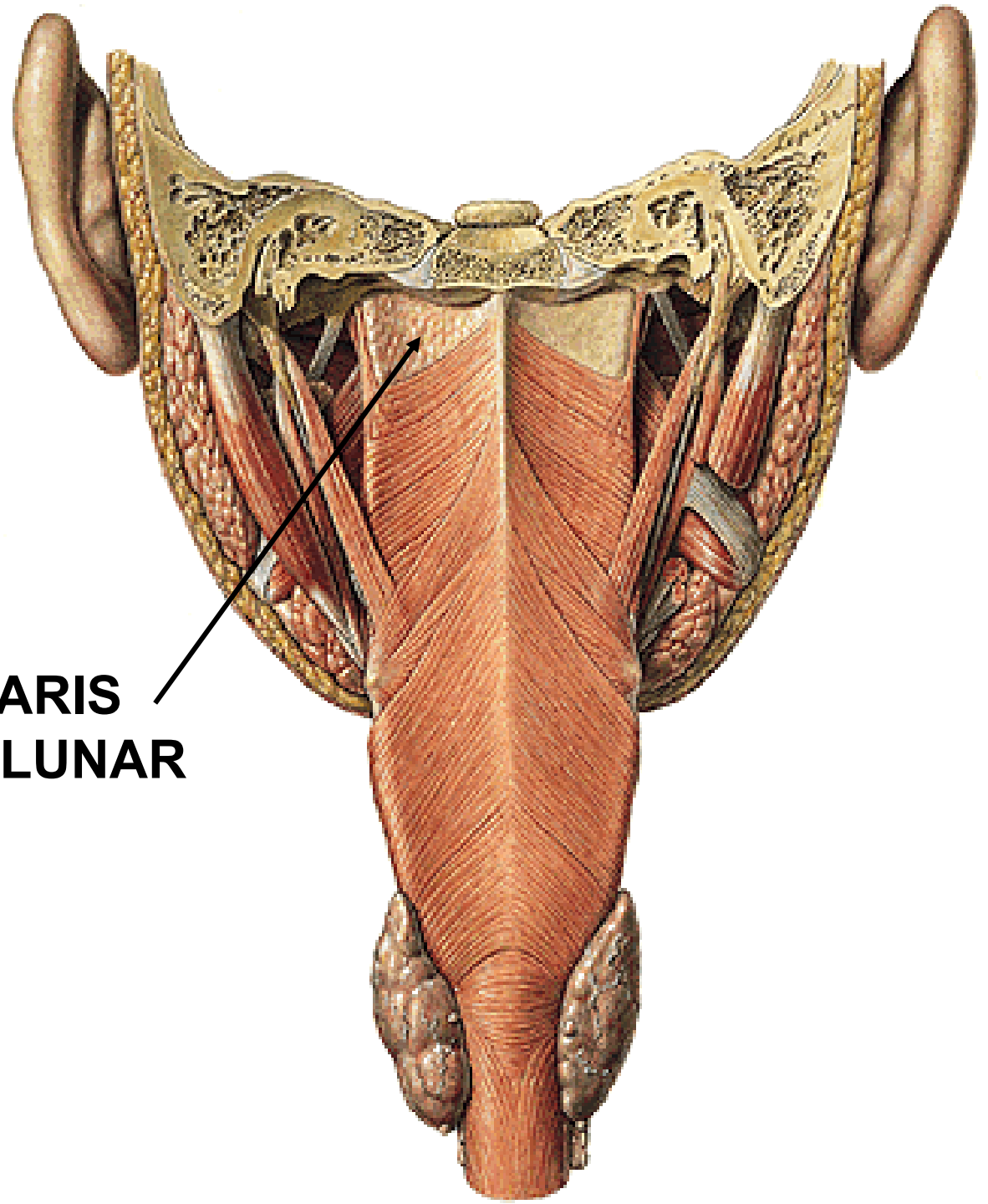
ADITUS LARYNGIS



**RECESSUS
PHARYNGEUS**

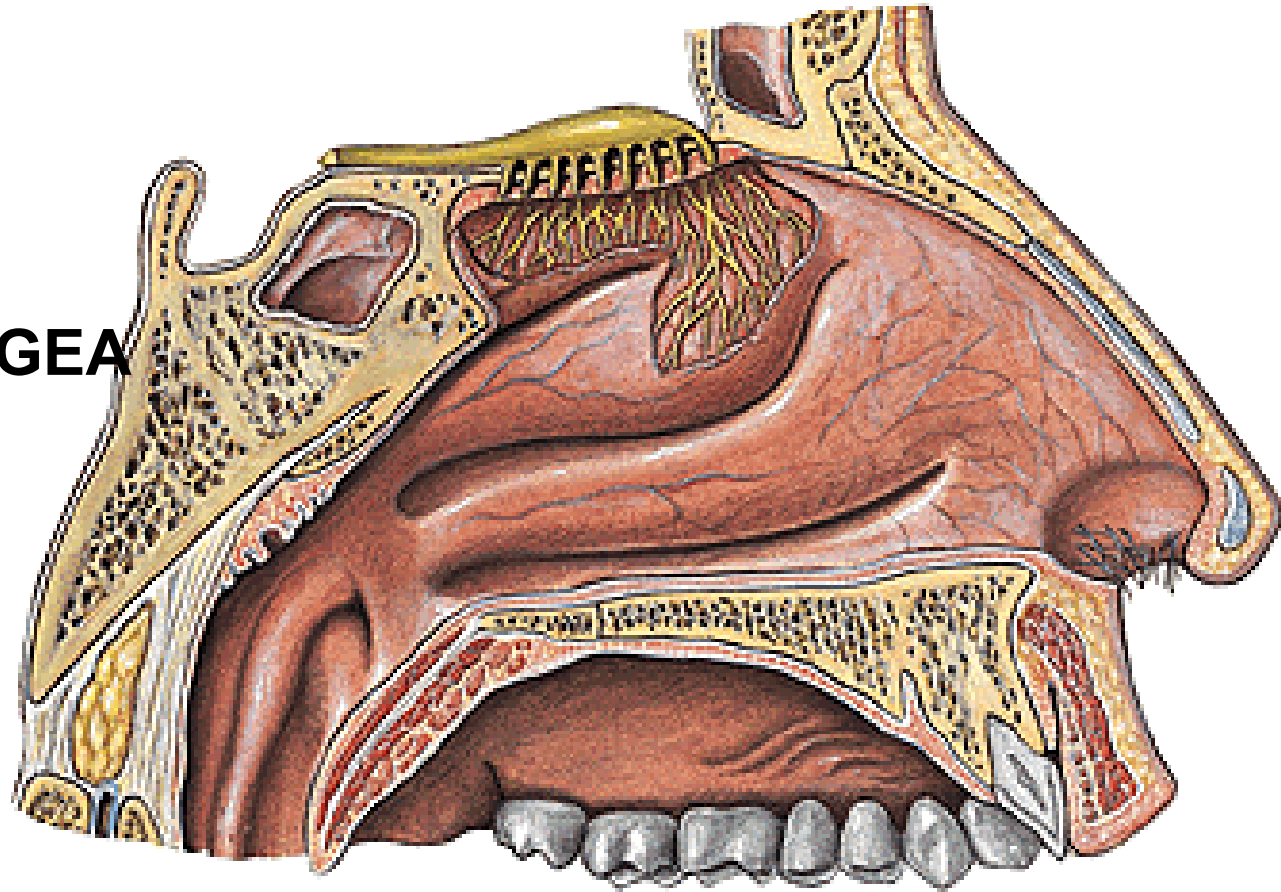


**FASCIA
PHARYNGOBASILARIS
(LUSCHKA'S SEMILUNAR
SPACE)**



NASOPHARYNX:

TONSILLA PHARYNGEA

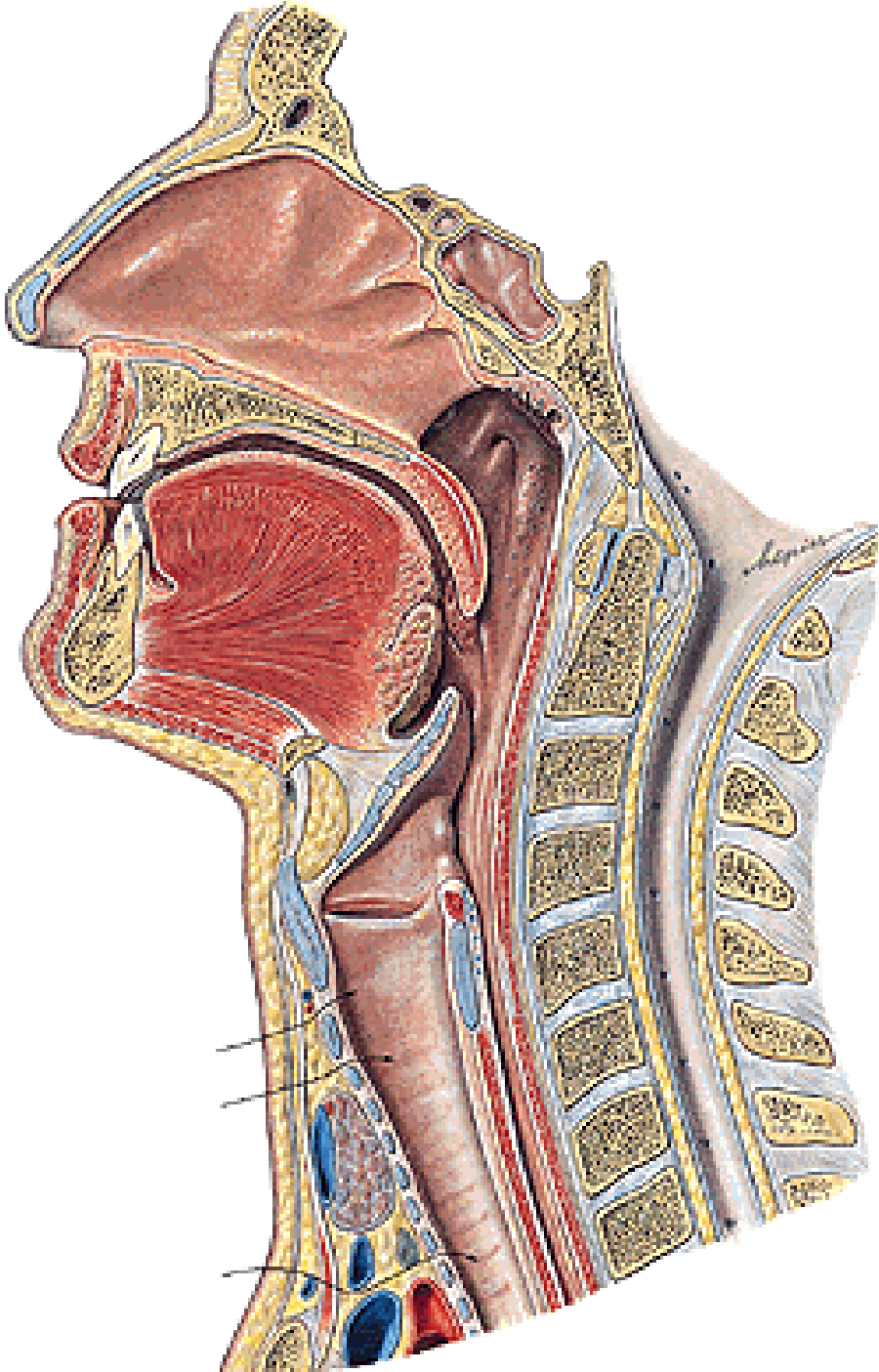


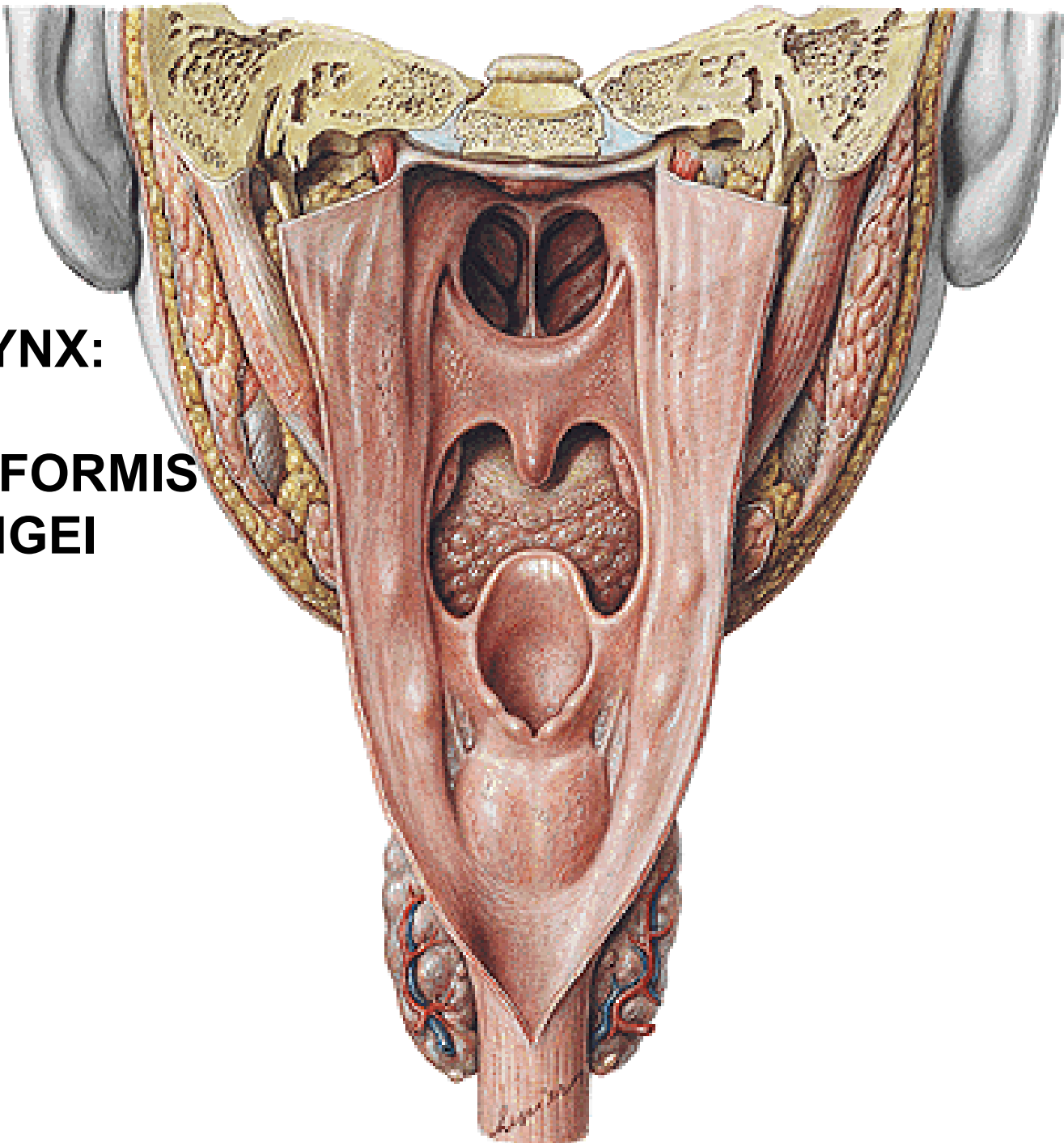
OSTIUM PHARYNGEUM TUBAE AUDITIVAE:

- TORUS TUBARIUS (PLICA SALPINGOPHARYNGEA)
- TORUS LEVATORIUS
- PLICA SALPINGOPALATINA

TONSILLA TUBARIA

OROPHARYNX





LARYNGOPHARYNX:

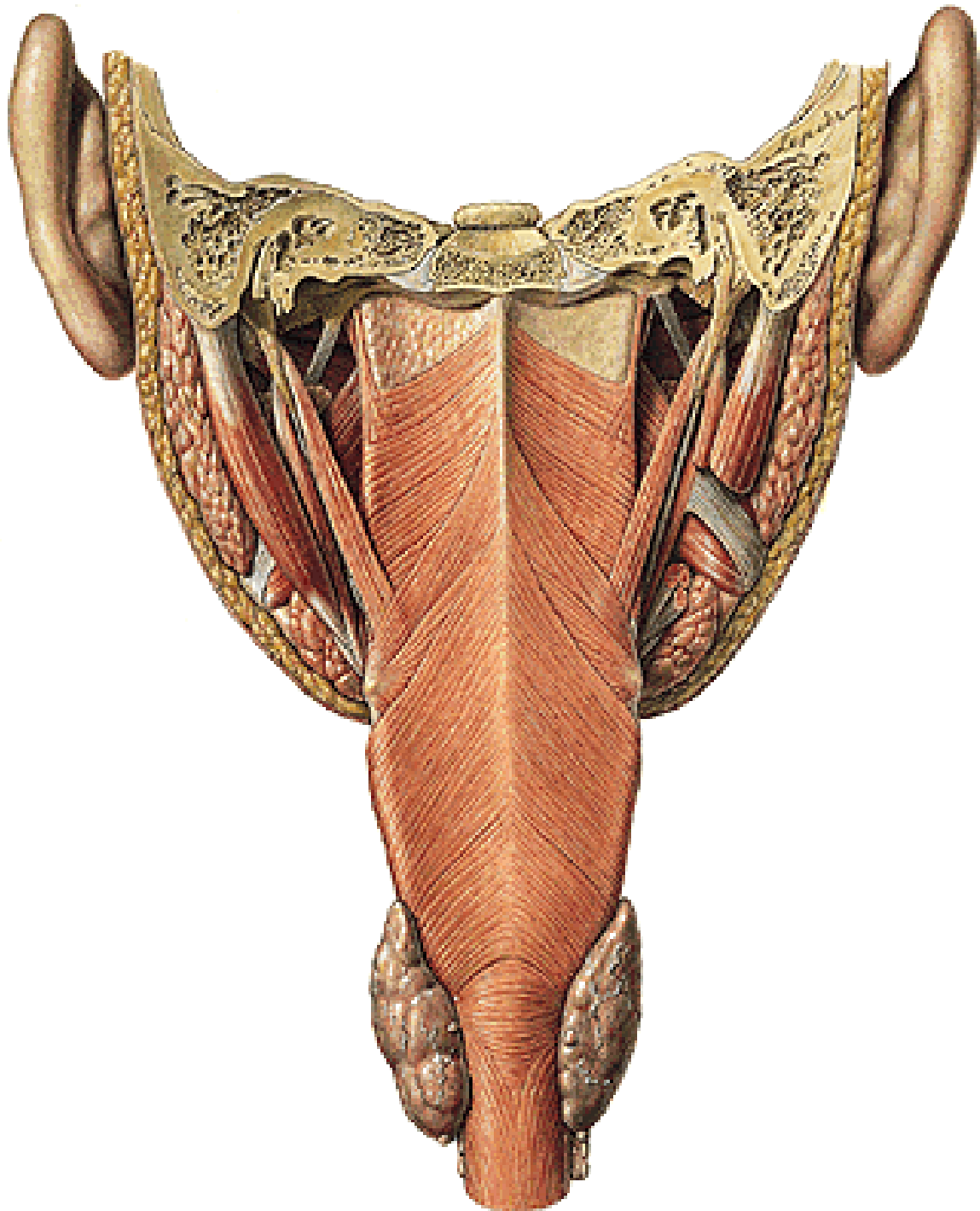
- RECESSUS PIRIFORMIS**
- PLICA N. LARYNGEI**

**M. CONSTRICTOR
PHARYNGIS SUP.**

**M. CONSTRICTOR
PHARYNGIS MEDIUS**

**M. CONSTRICTOR
PHARYNGIS INF.**

- RAPHE PHARYNGIS



M. CONSTRICTOR
PHARYNGIS SUP.:

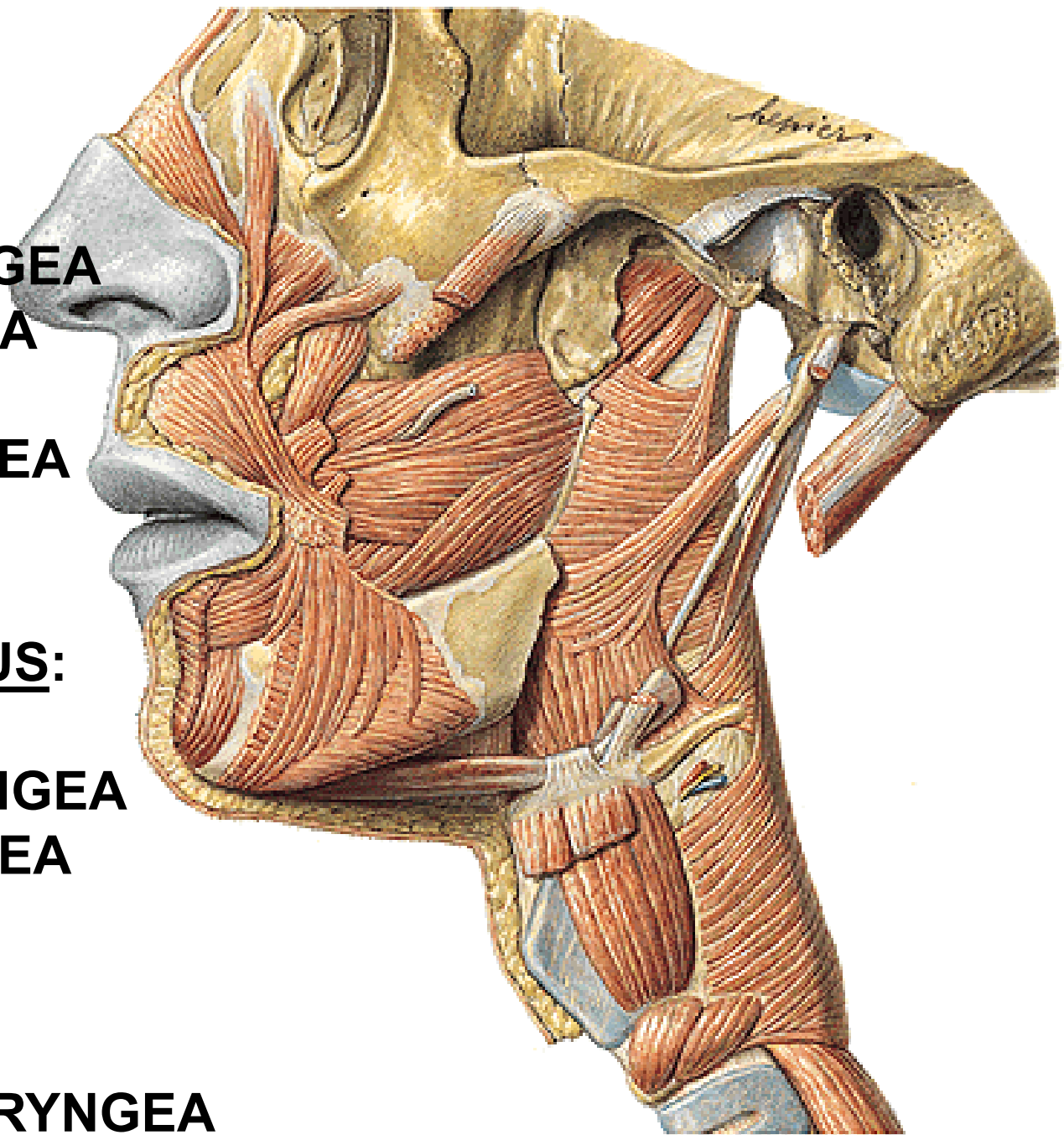
- PARS
PTERYGOPHARYNGEA
- BUCCOPHARYNGEA
- MYLOPHARYNGEA
- GLOSSOPHARYNGEA

M. CONSTRICTOR
PHARYNGIS MEDIUS:

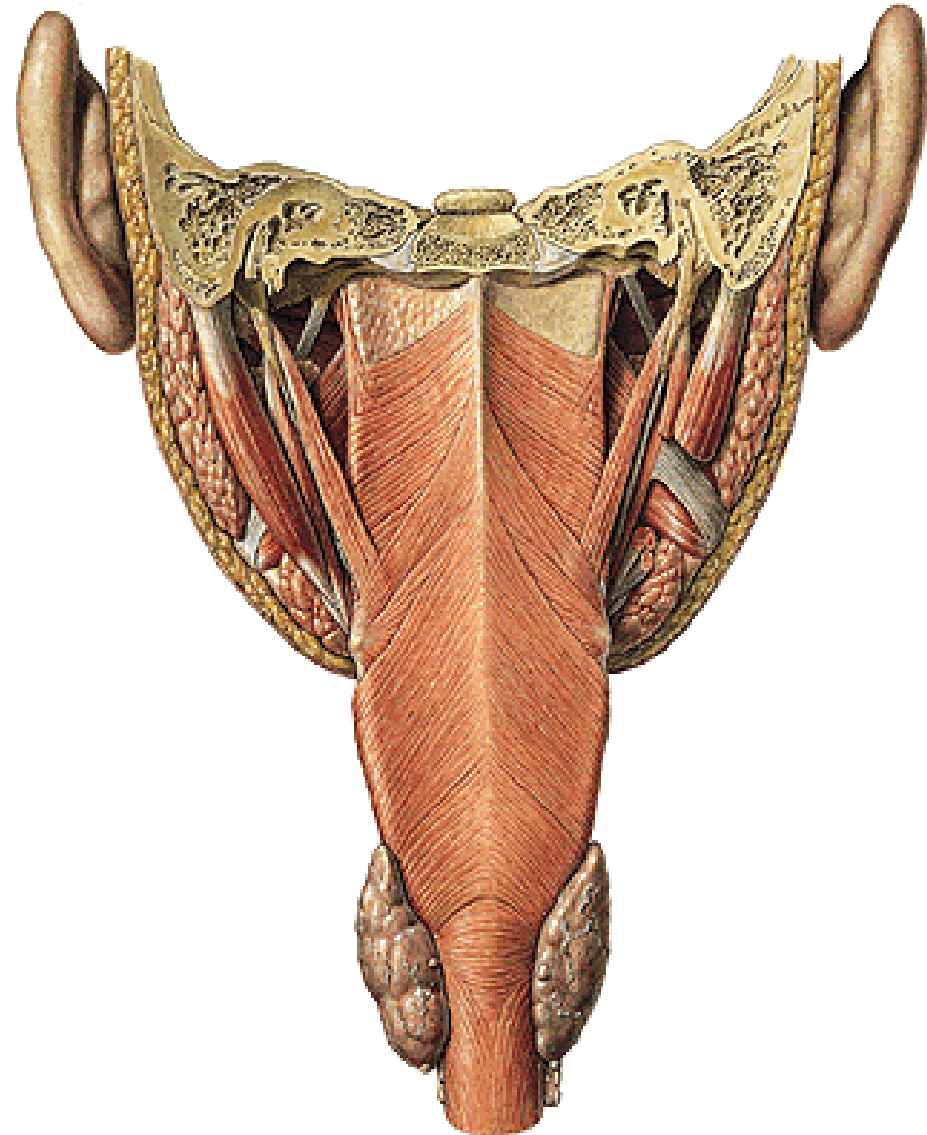
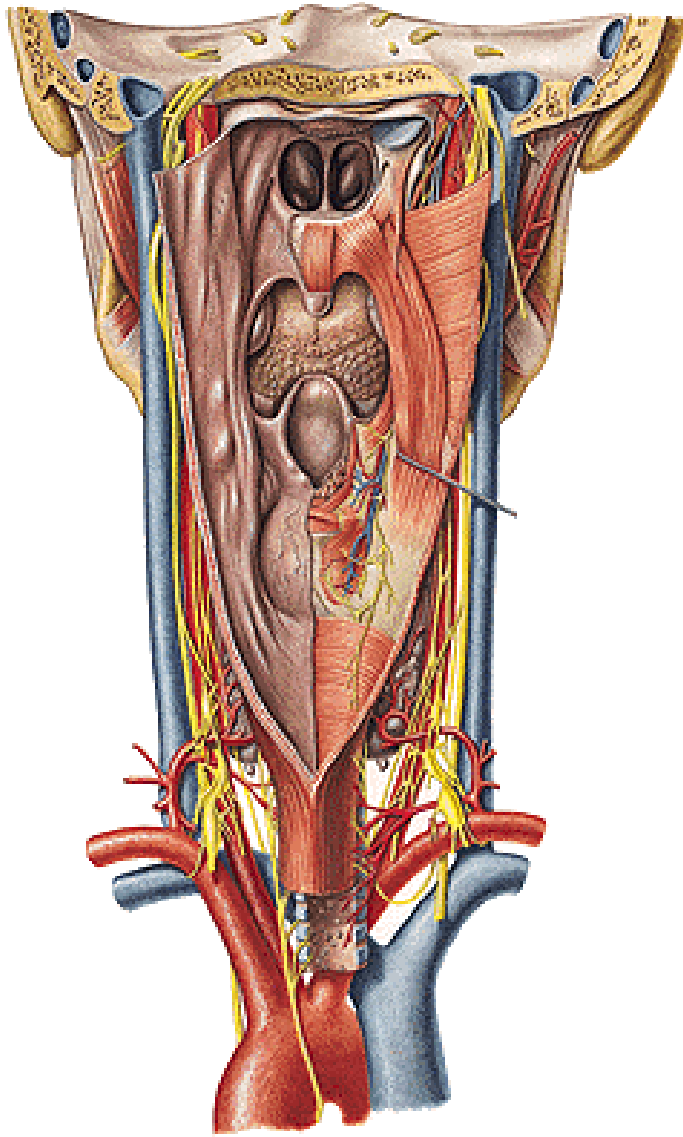
- PARS
CHONDROPHARYNGEA
- CERATOPHARYNGEA

M. CONSTRICTOR
PHARYNGIS INF.:

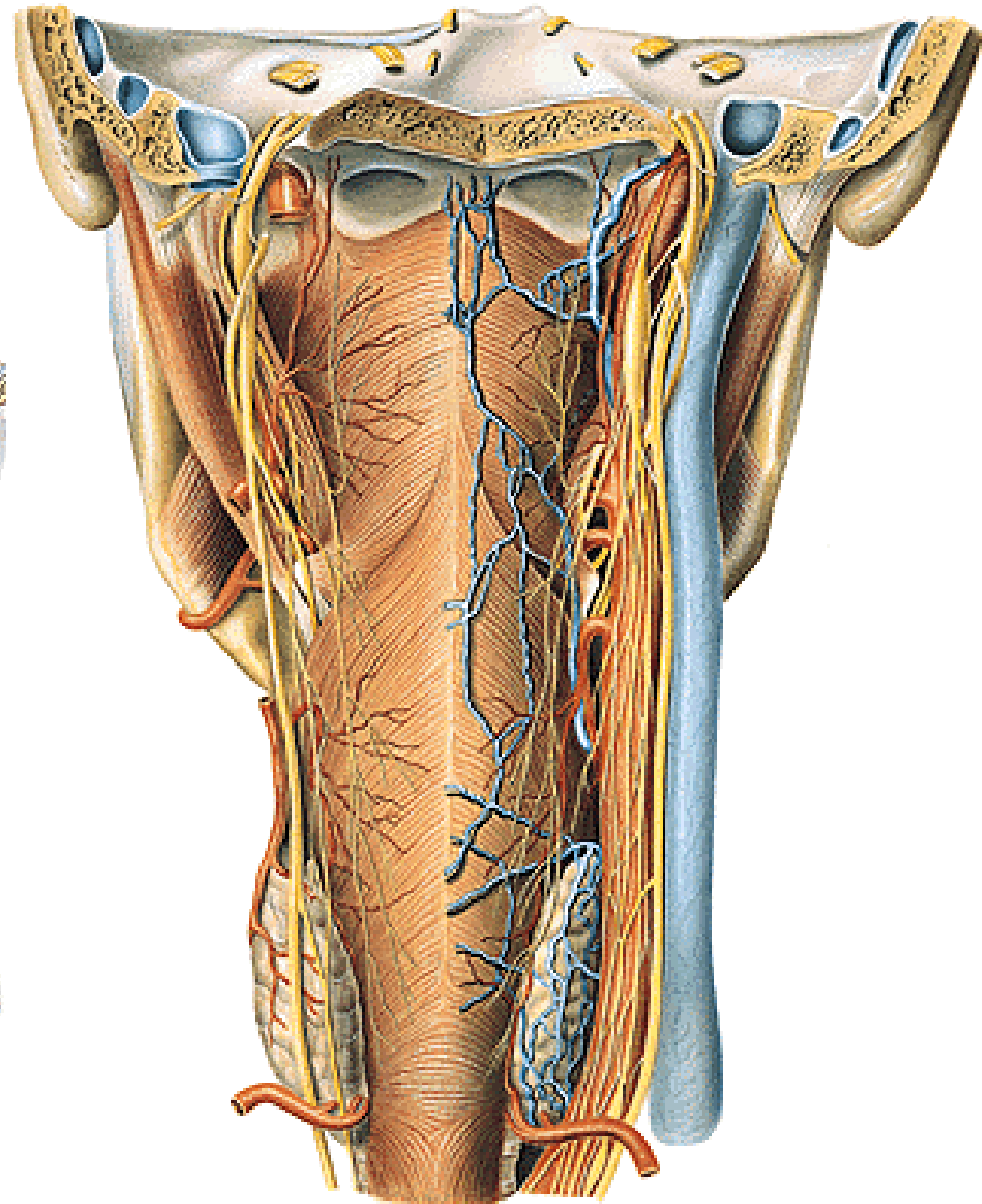
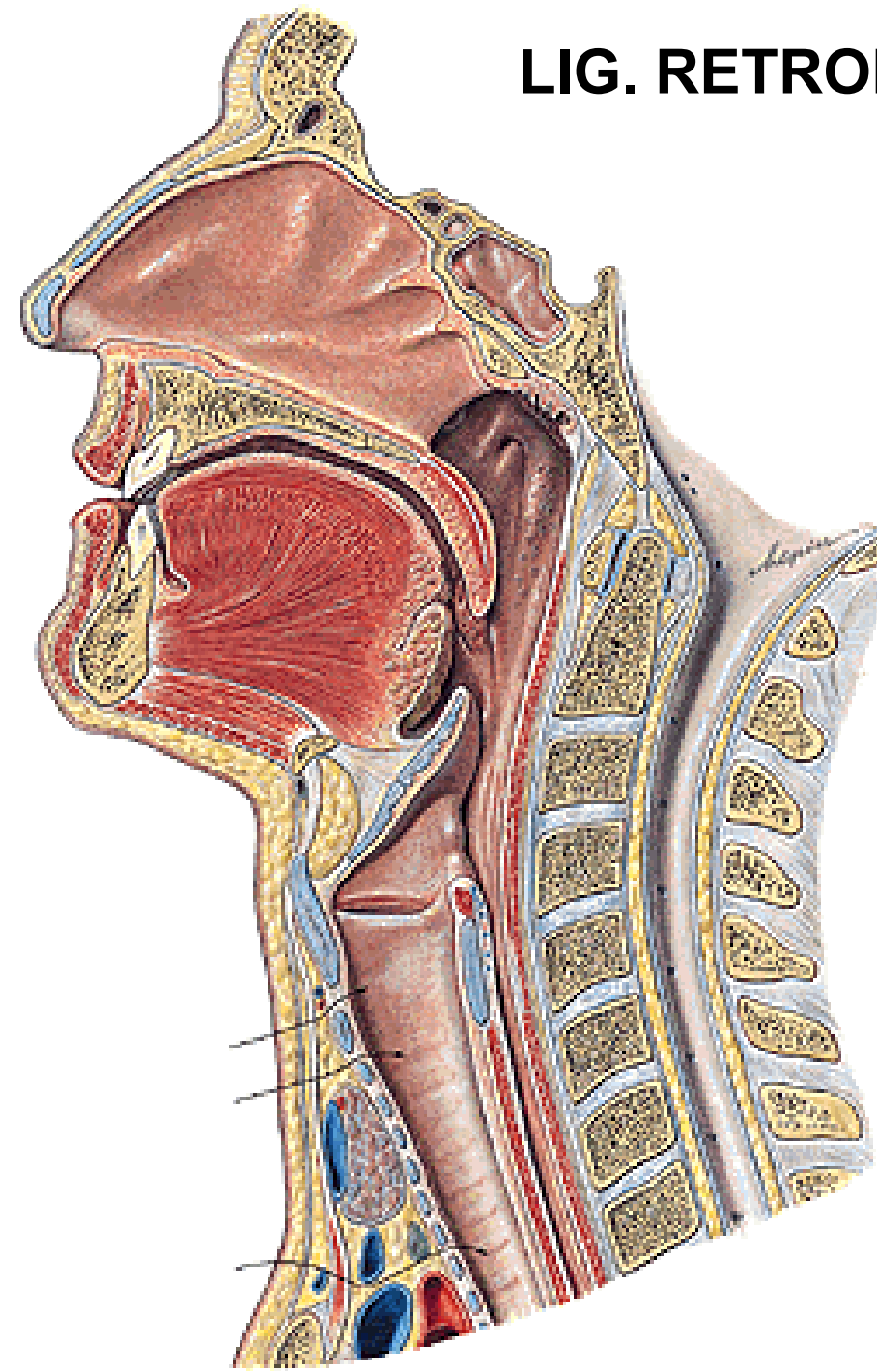
- PARS THYROPHARYNGEA
- CRICOPHARYNGEA



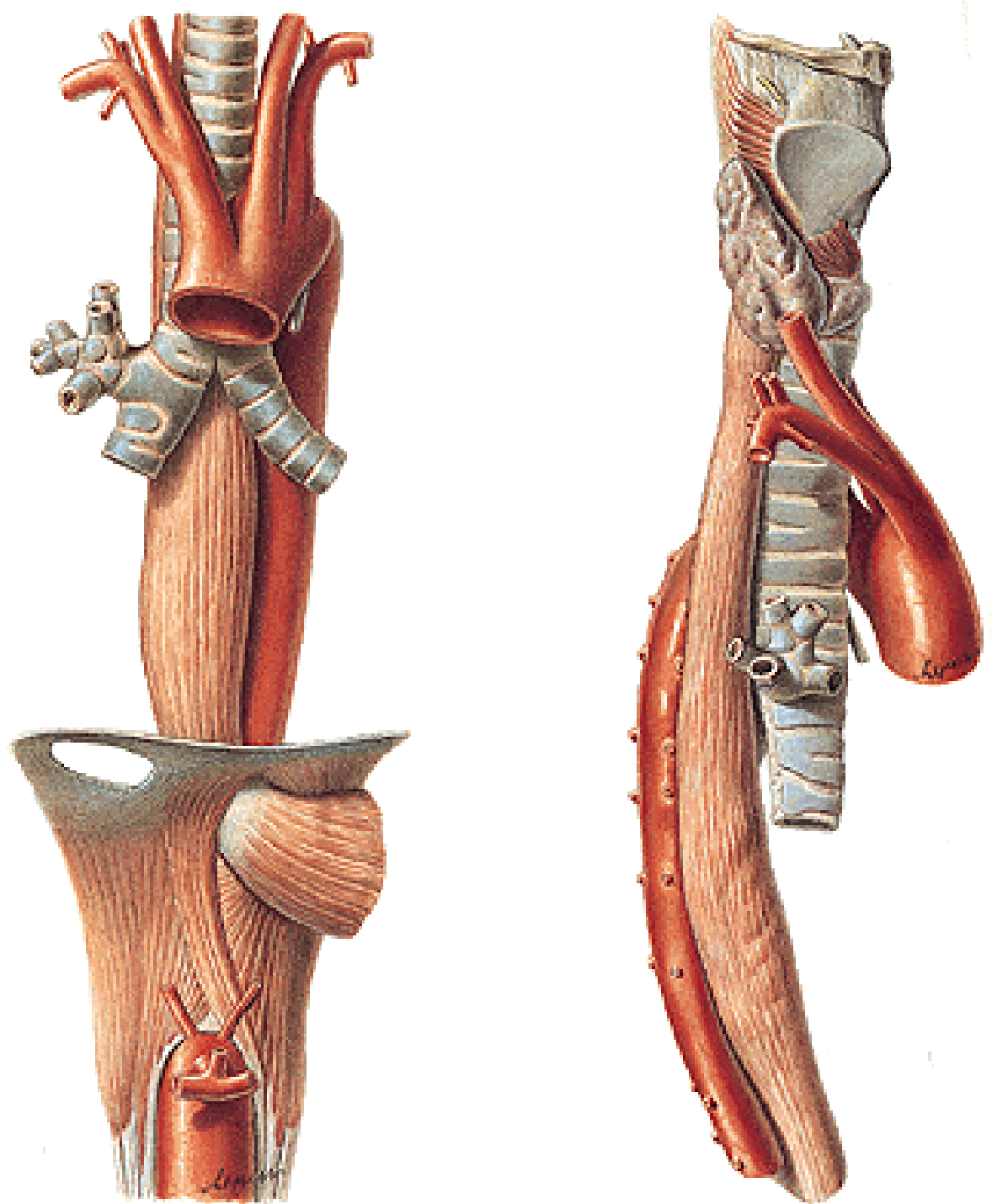
**LEVATORS: M. PALATOPHARYNGEUS
M. SALPINGOPHARYNGEUS
M. STYLOPHARYNGEUS**



LIG. RETROPHARYNGEUM MEDIANUM



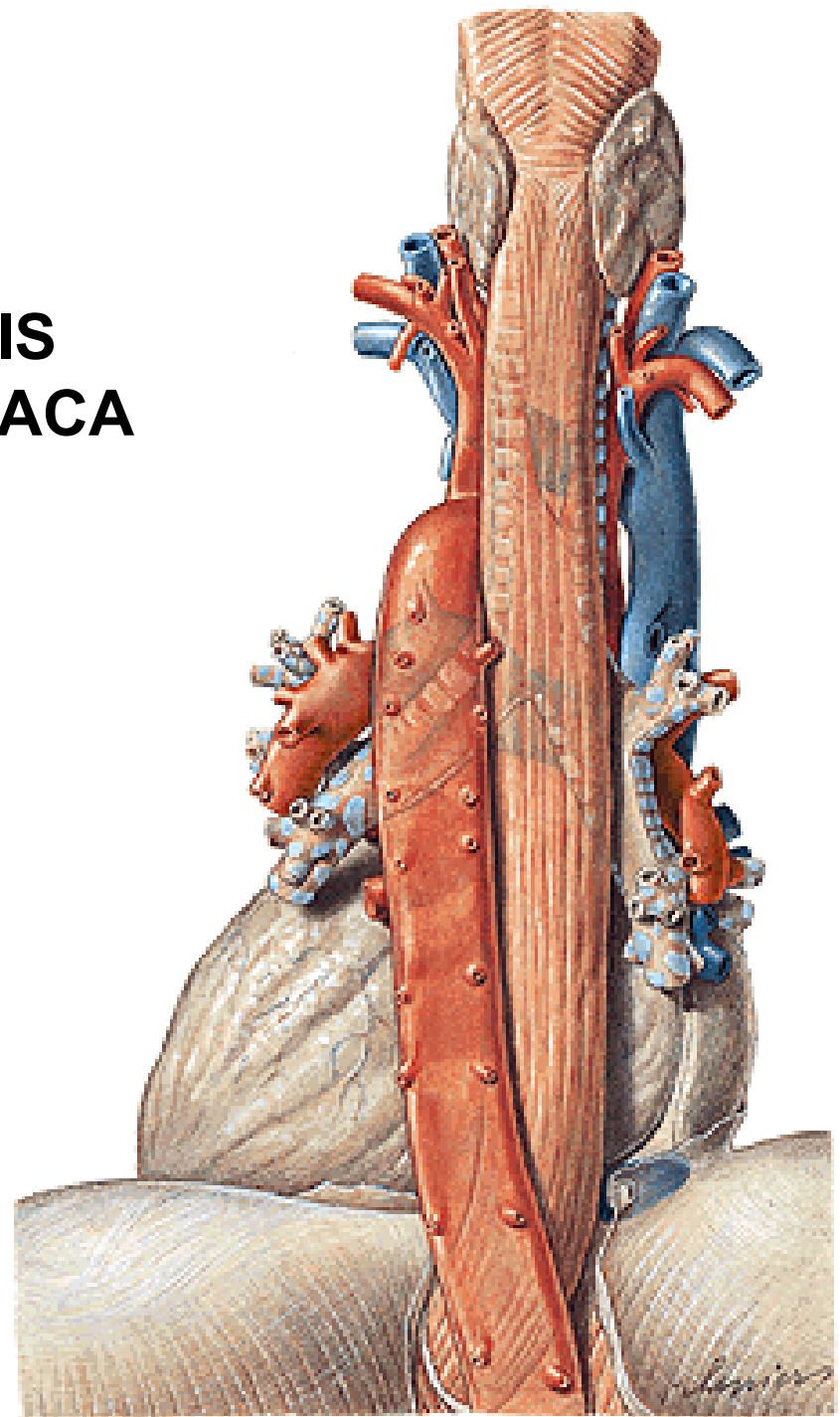
OESOPHAGUS



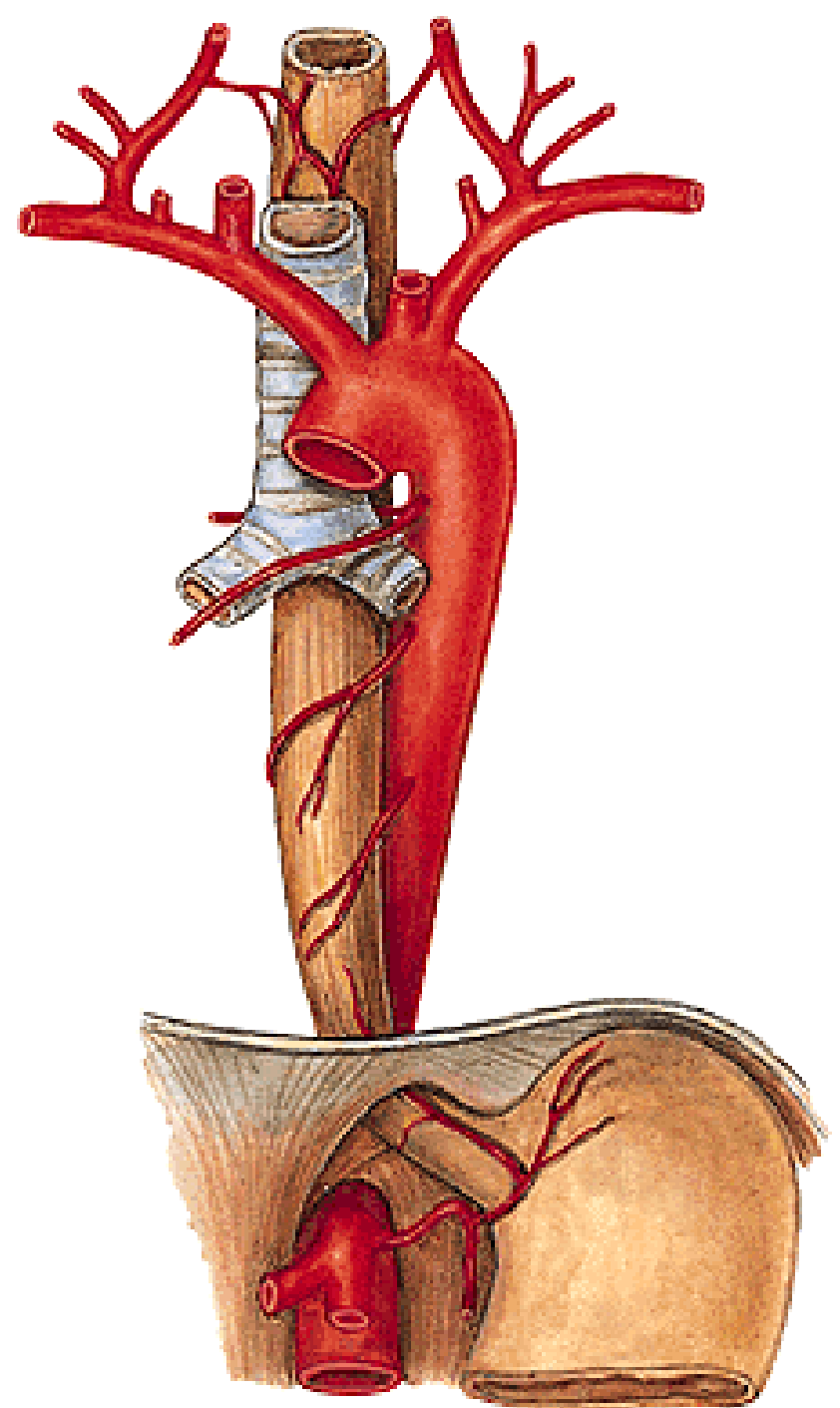
PARS CERVICALIS

PARS THORACICA

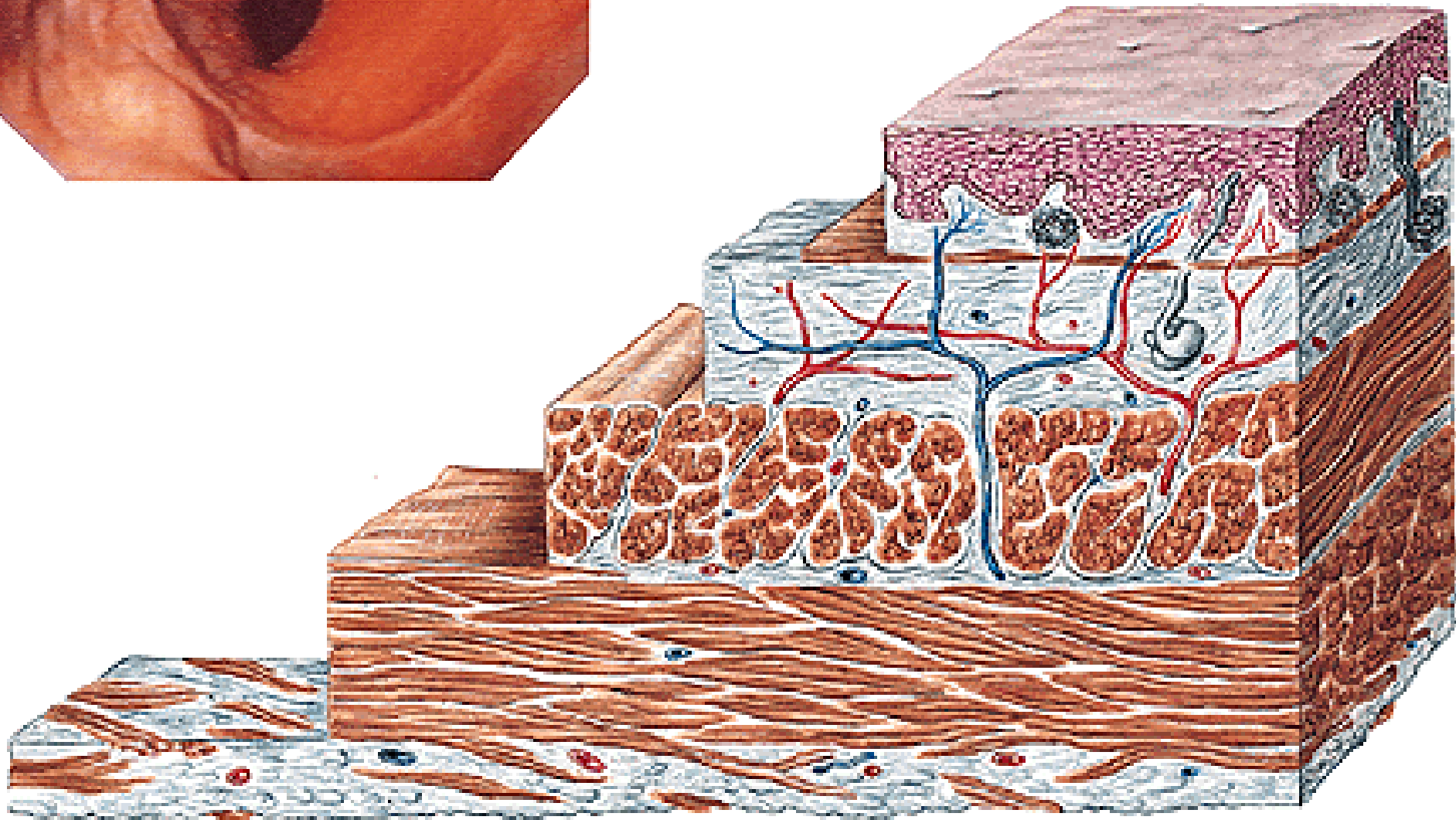
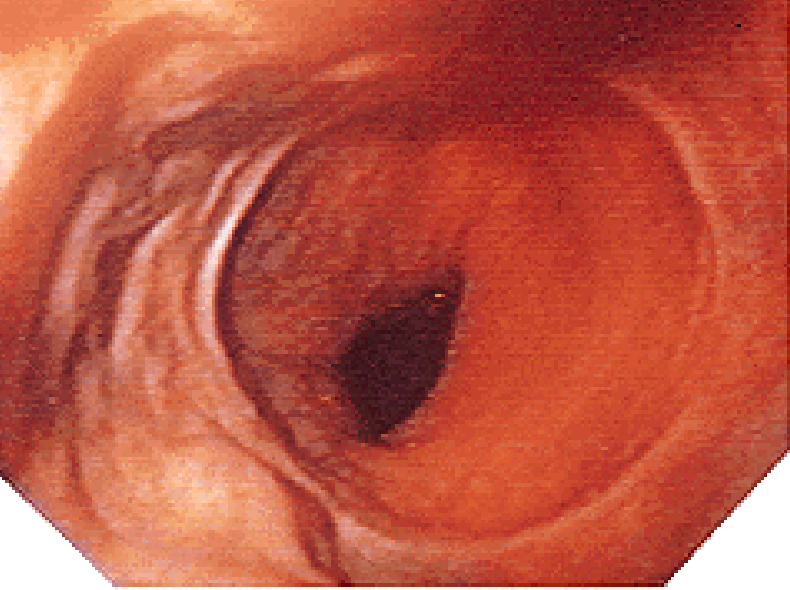
- PARS RETROTRACHEALIS**
- PARS RETROPERICARDIACA**



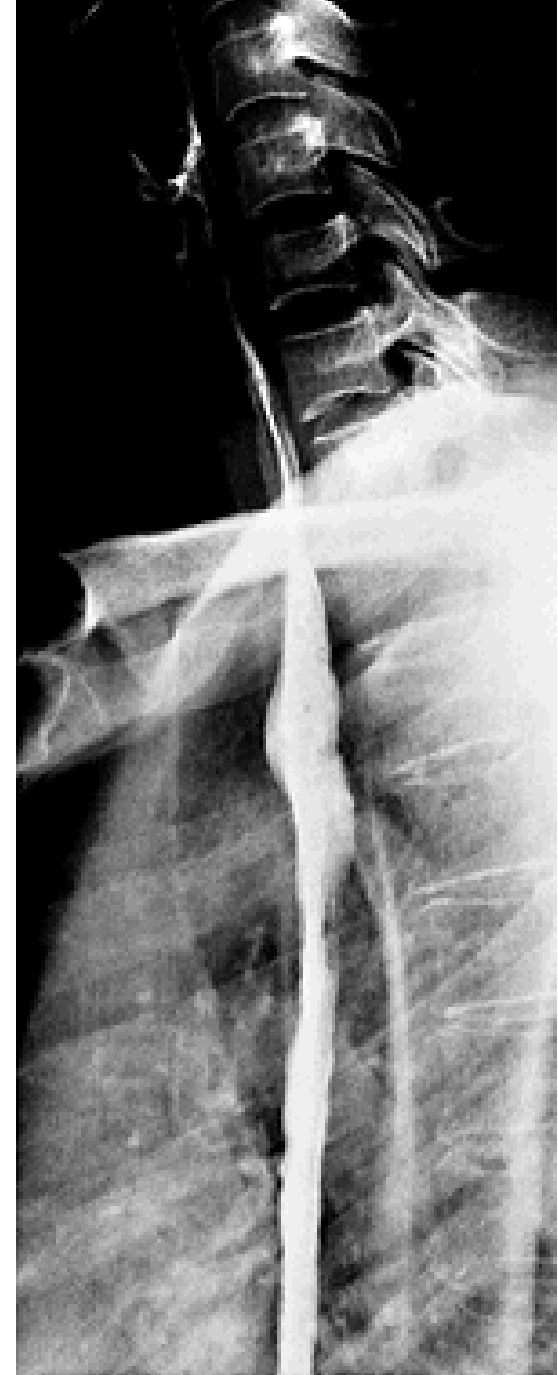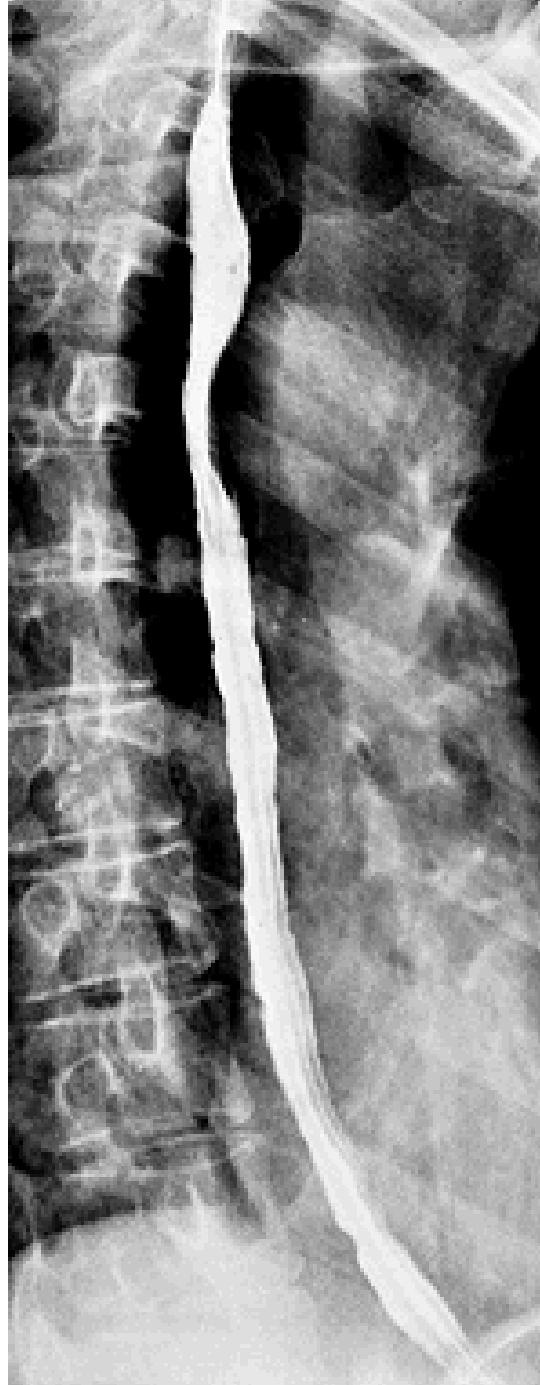PARS ABDOMINALIS



GASTROESOPHAGEAL JUNCTION

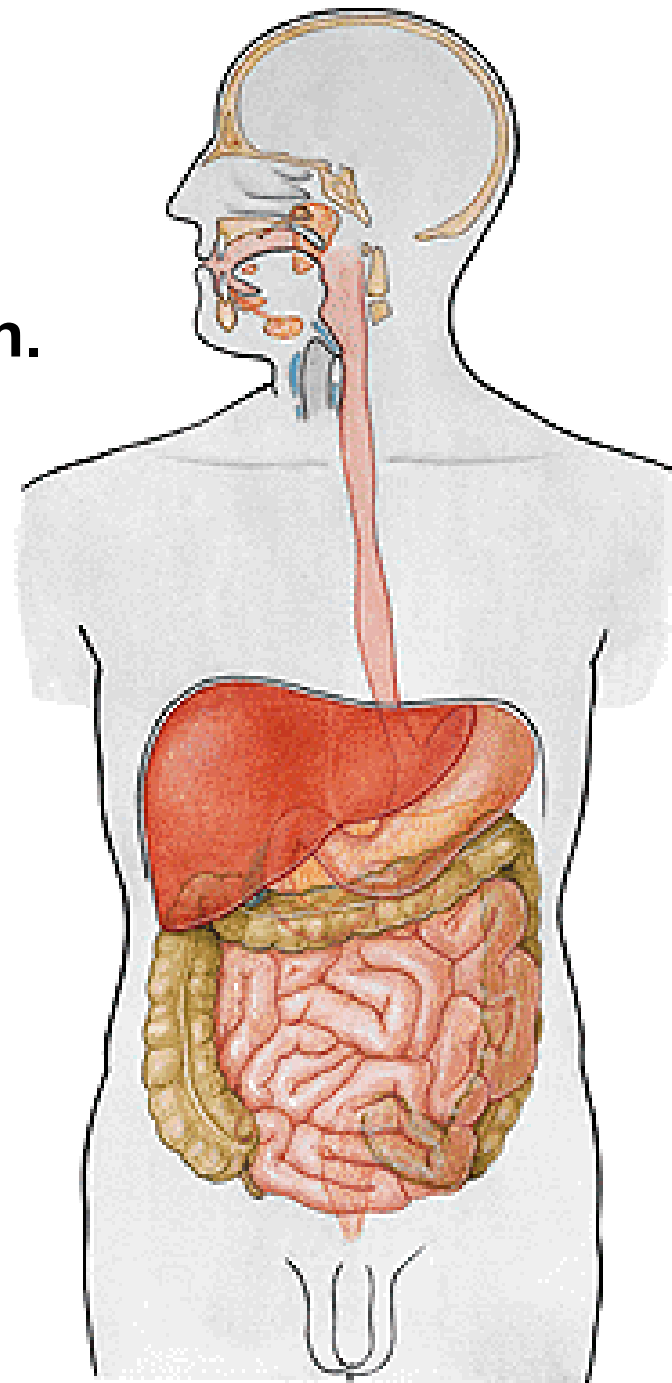


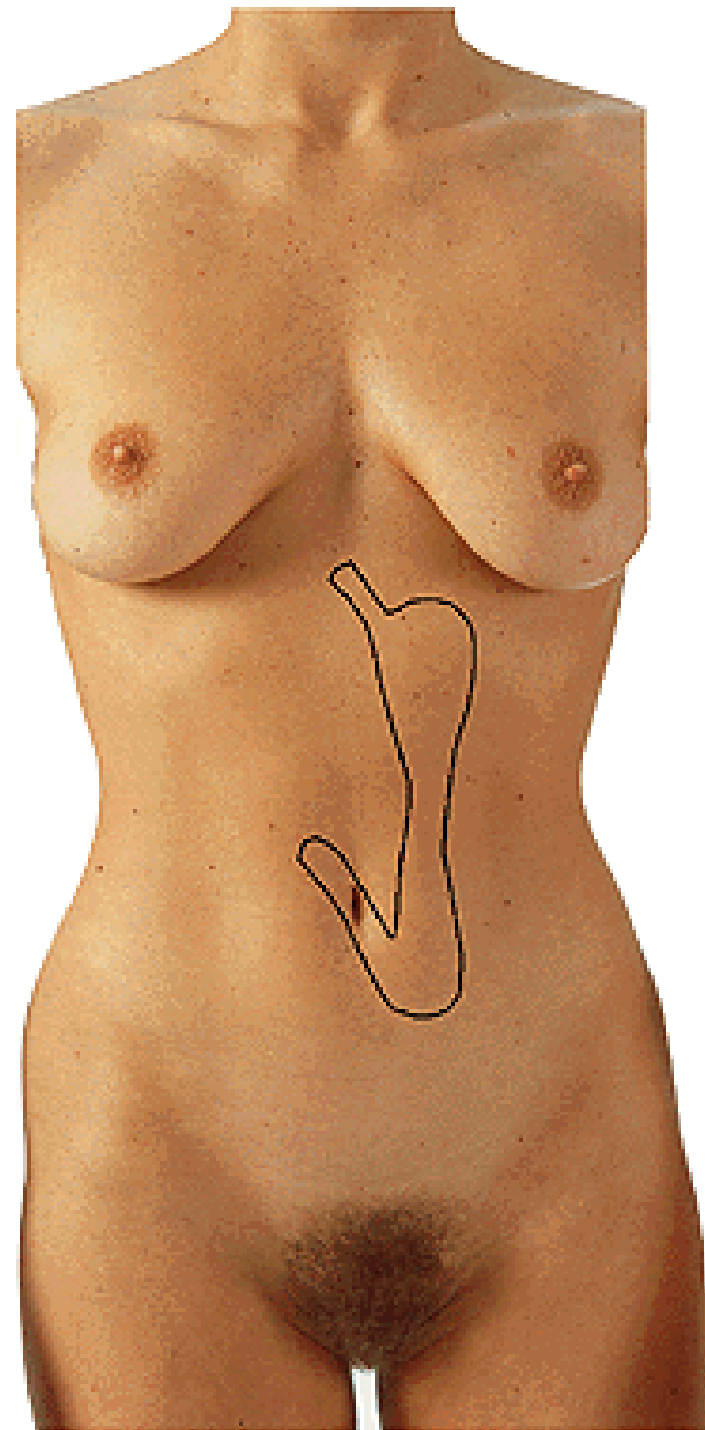
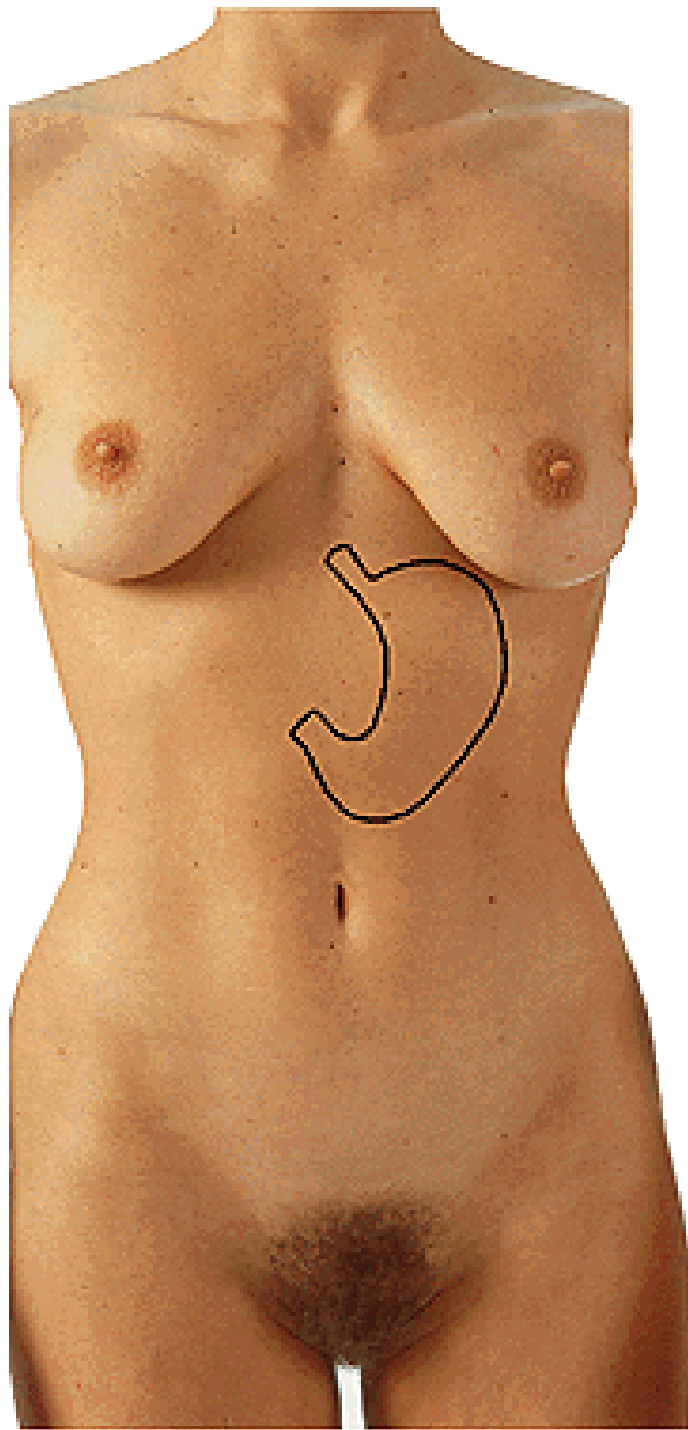
OESOPHAGOGRAPHY



VENTRICULUS, GASTER

Regio hypochondriaca sin.





Cardia

Fornix (fundus) ventriculi

Incisura cardiaca

Corpus ventriculi

Pars pylorica

Pylorus

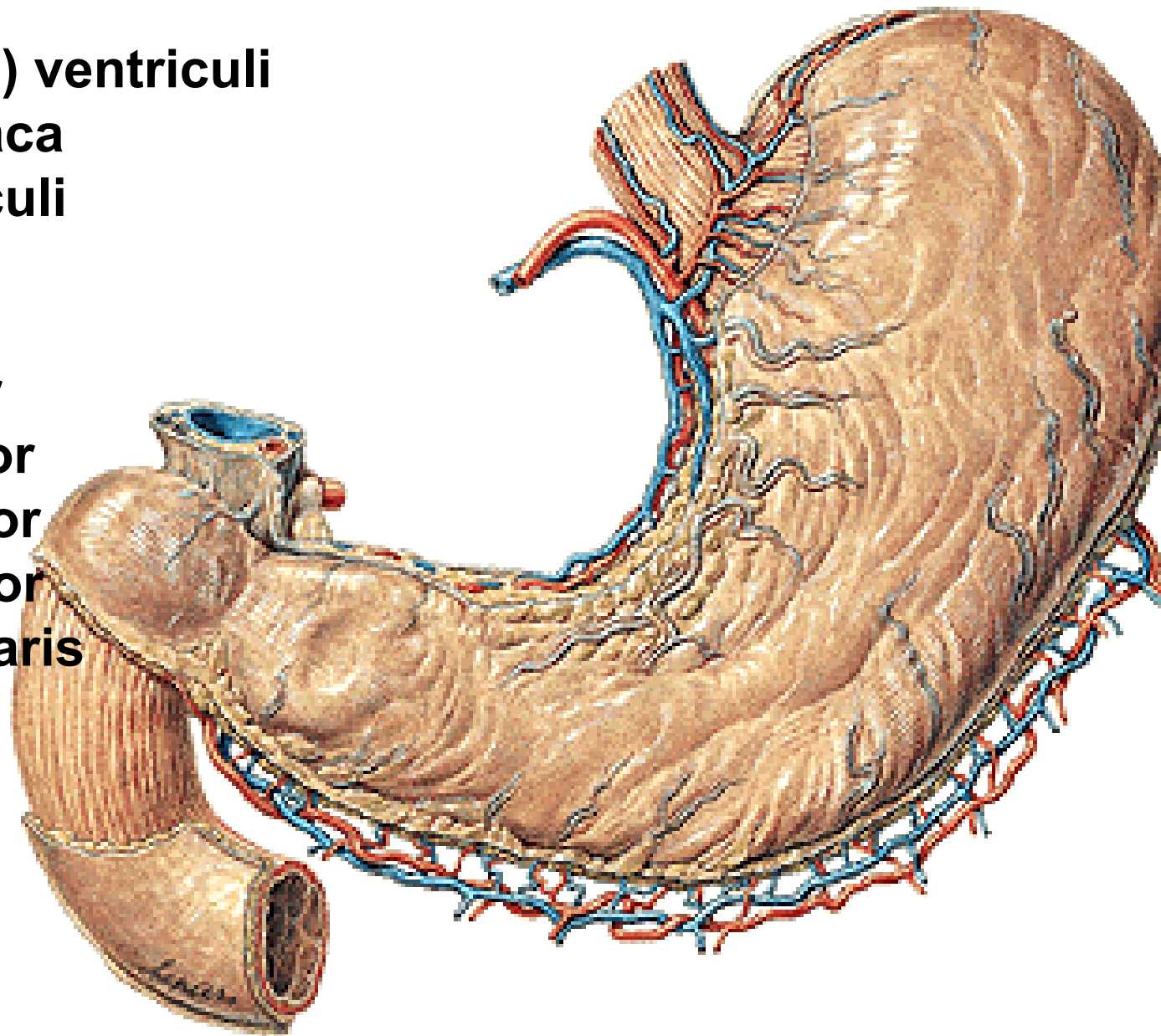
Paries anterior

Paries posterior

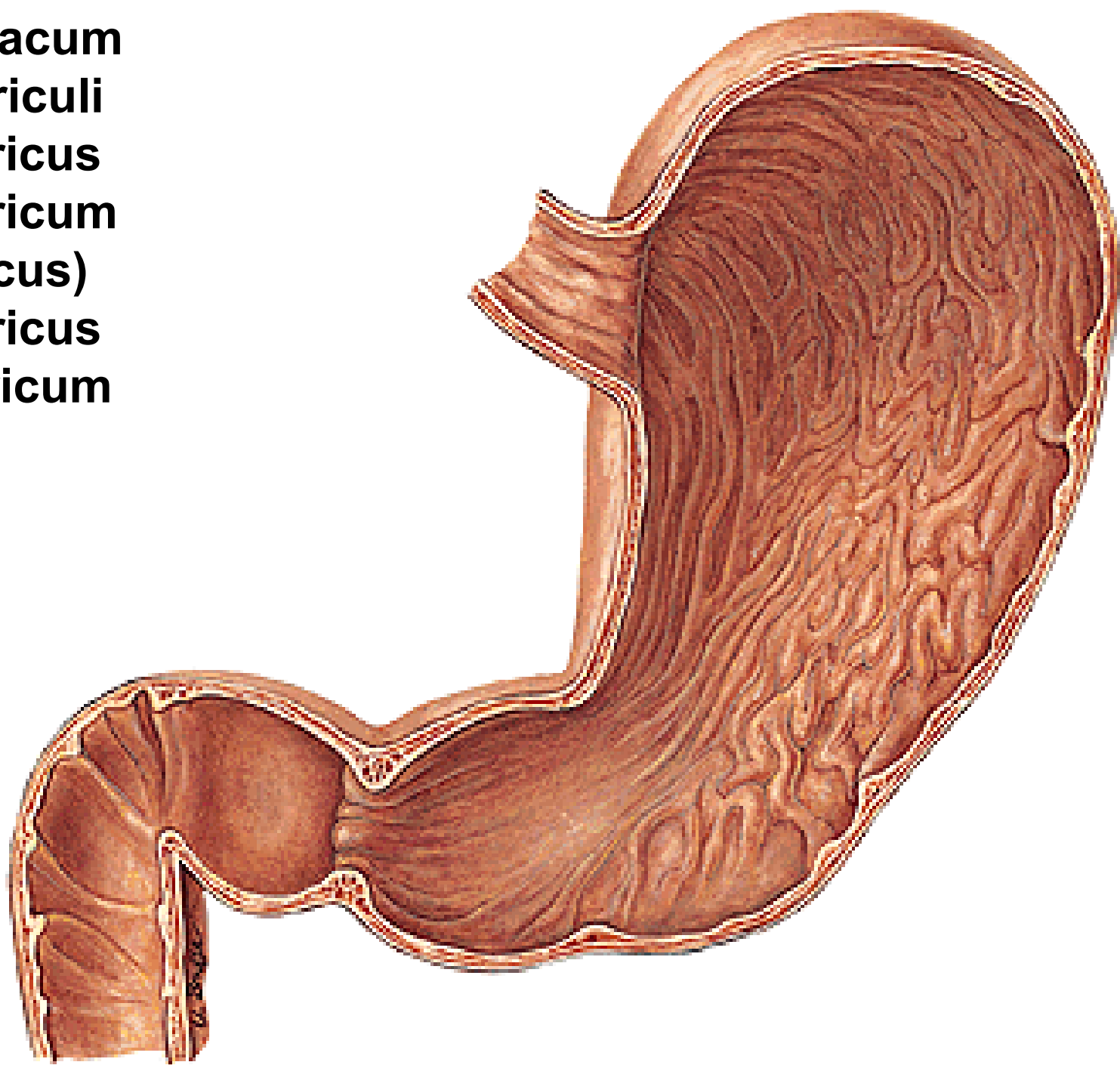
Curvatura major

Curvatura minor

Incisura angularis



Ostium cardiacum
Fundus ventriculi
Canalis gastricus
Antrum pyloricum
(sinus gastricus)
Canalis pyloricus
Ostium pyloricum



Plicae gastricae

Sulcus salivarius

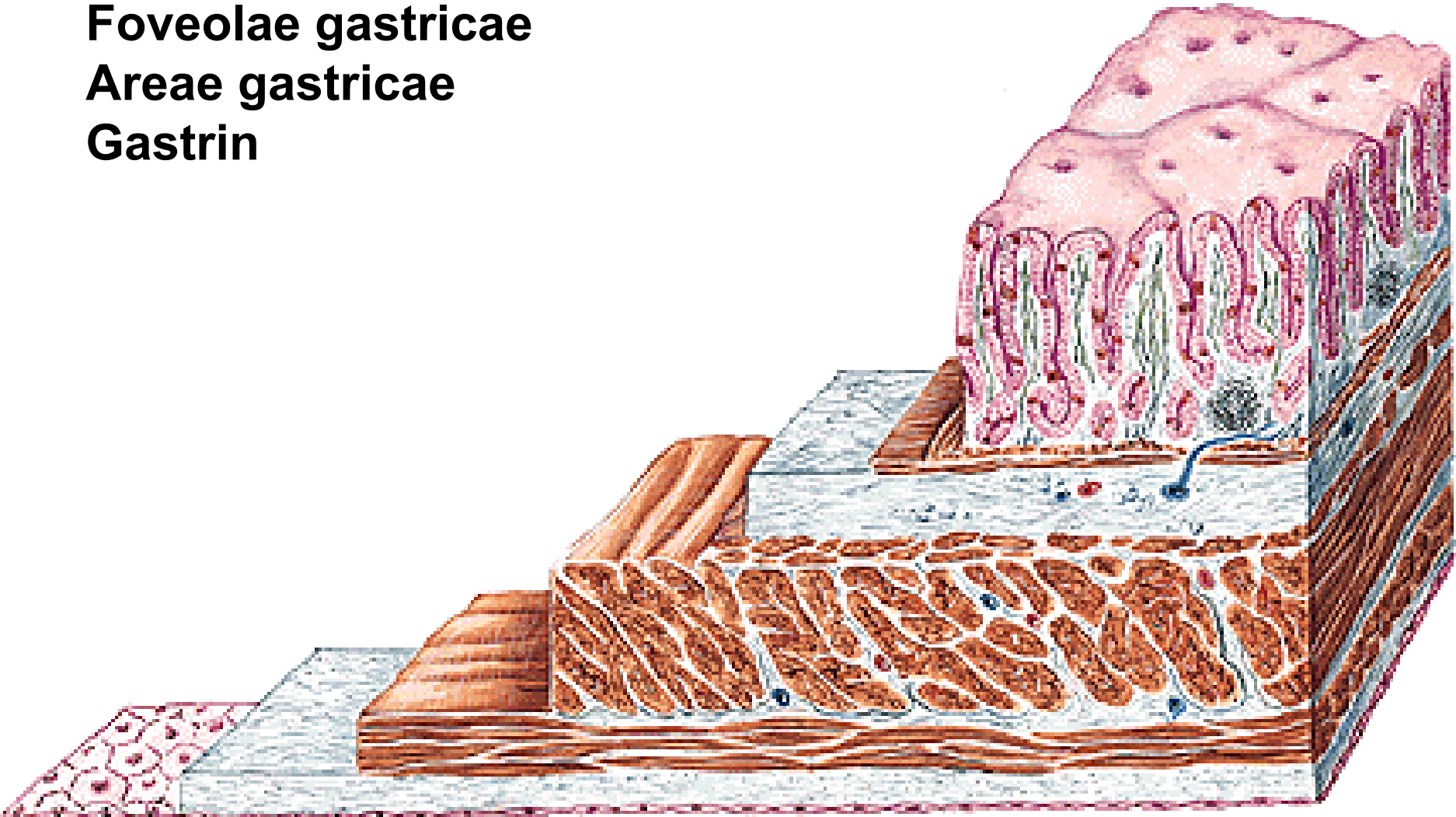
Glandulae gastricae - mucus

- succus gastricus

Foveolae gastricae

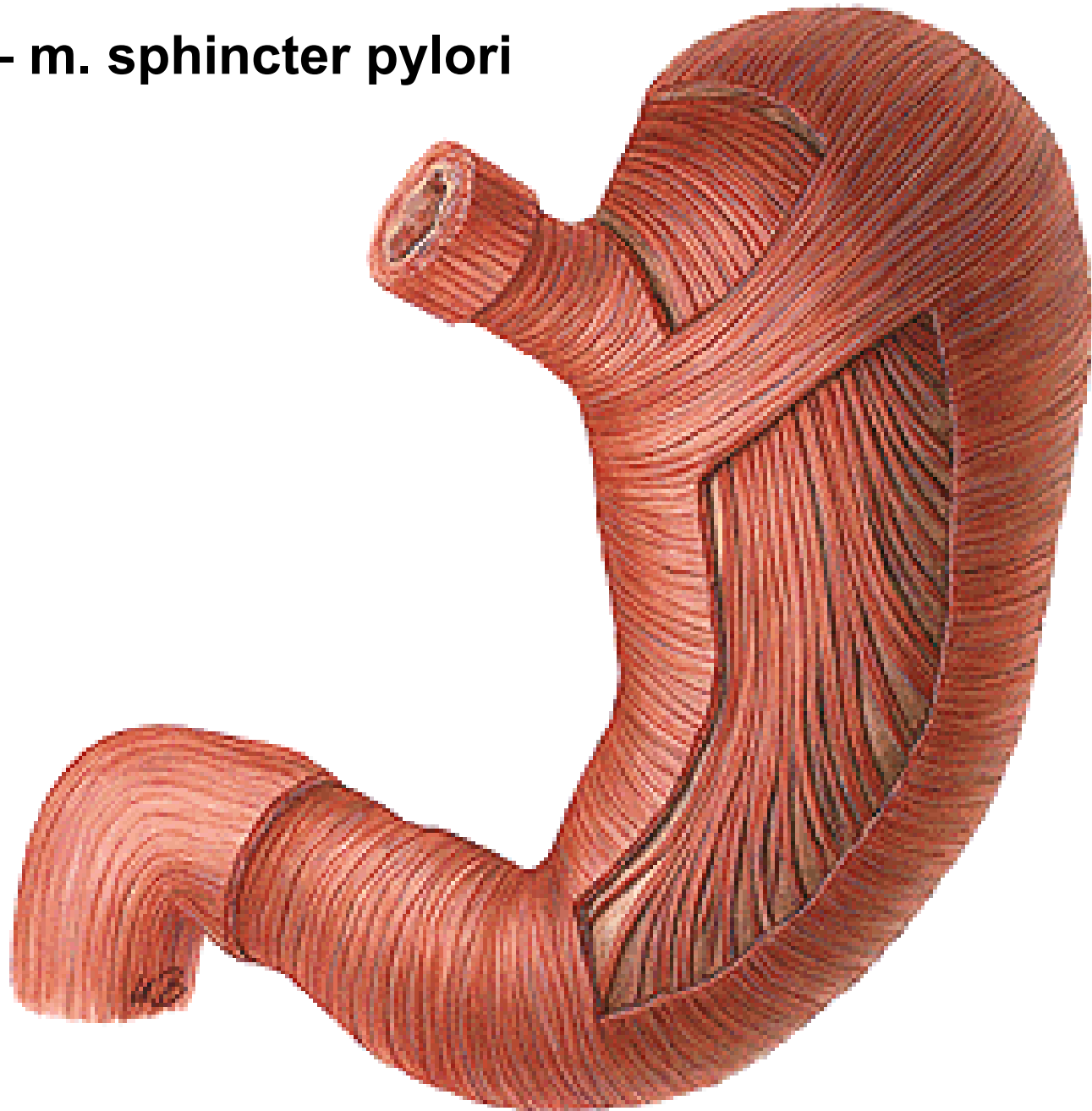
Areae gastricae

Gastrin

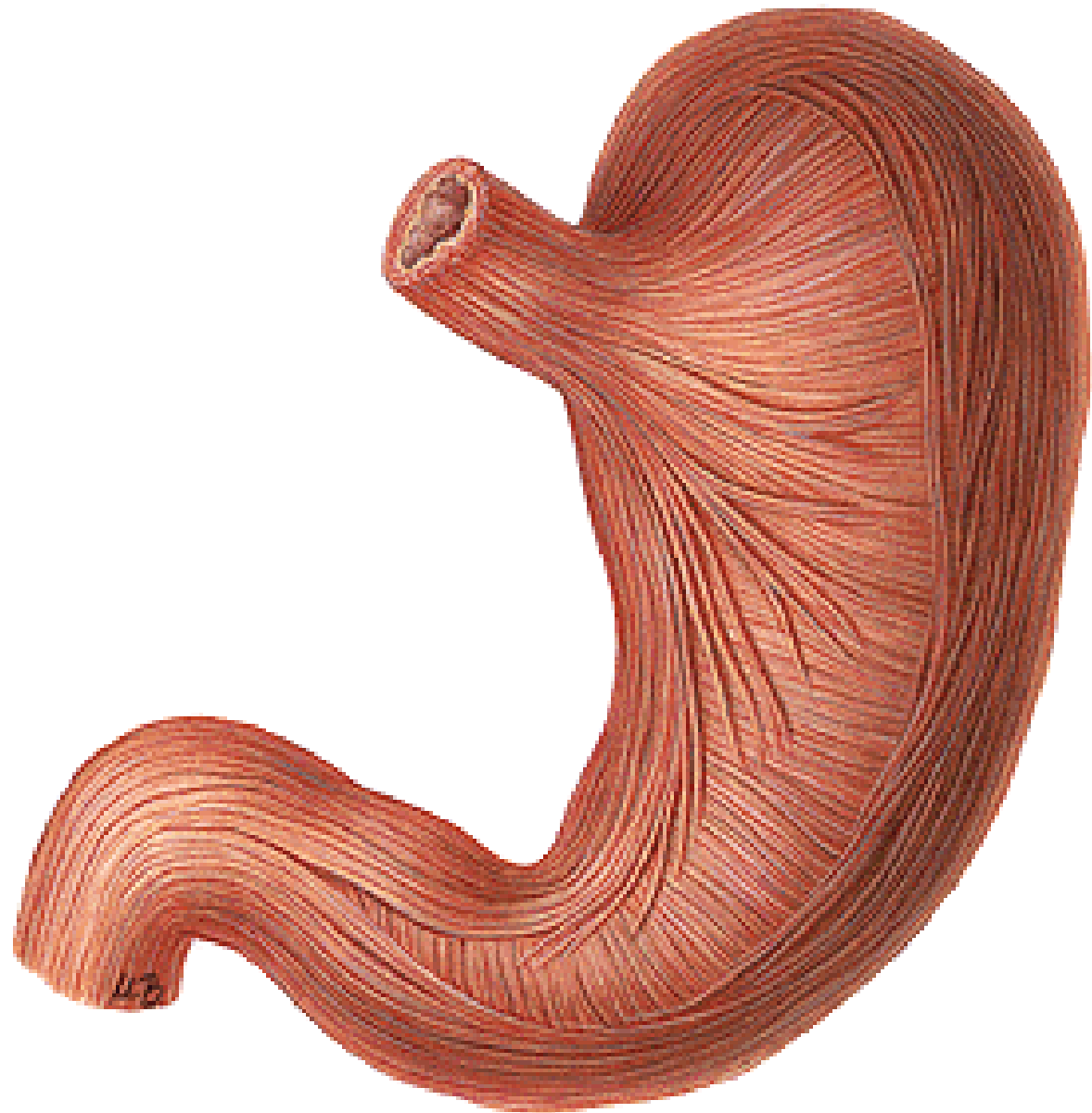


Fibrae obliquae

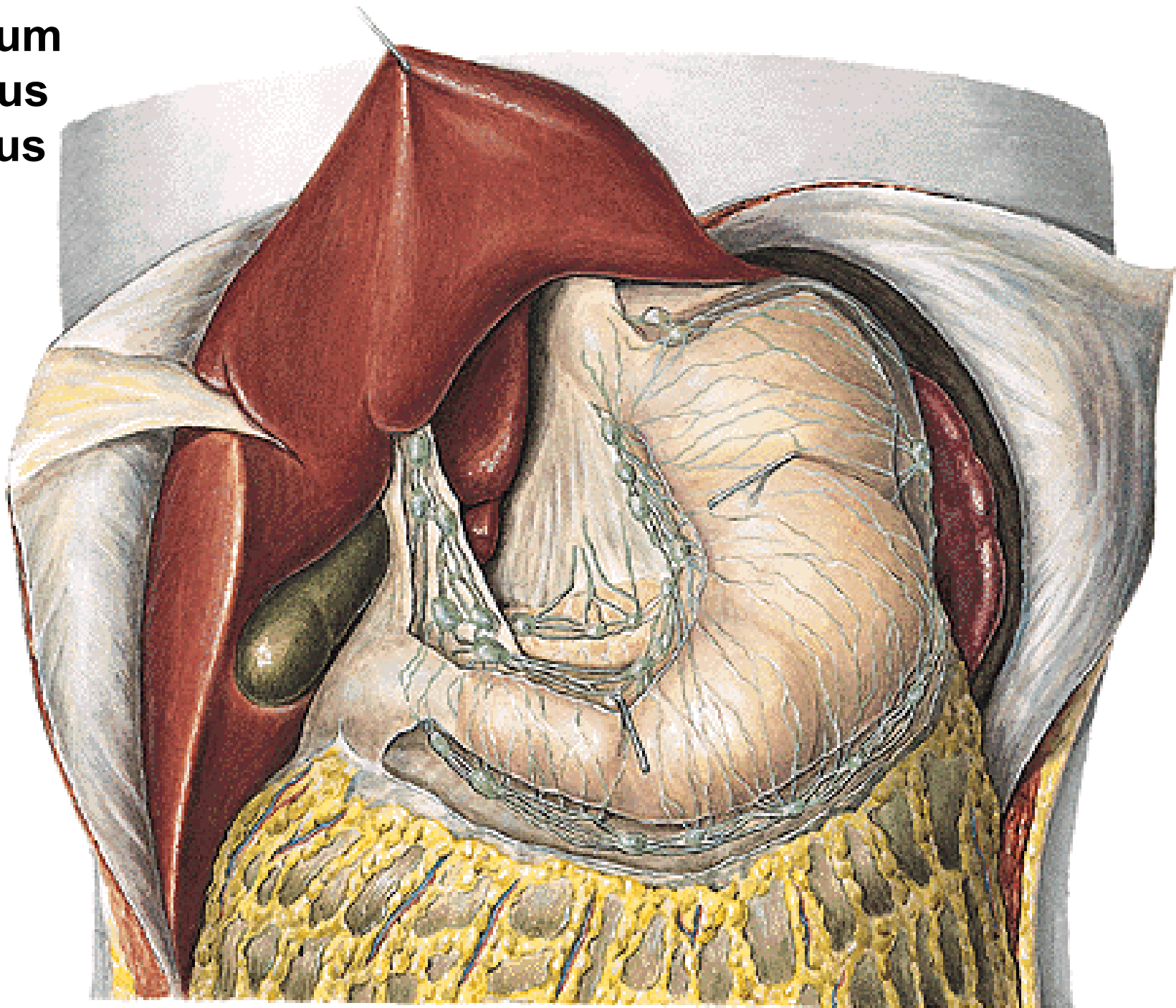
Stratum circulare – m. sphincter pylori



Stratum longitudinale

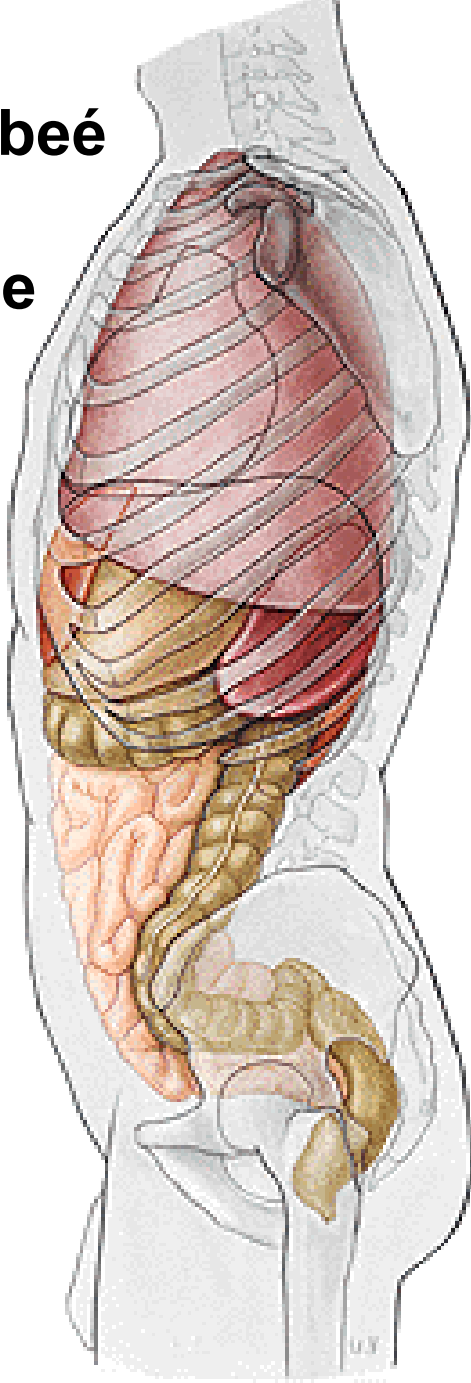
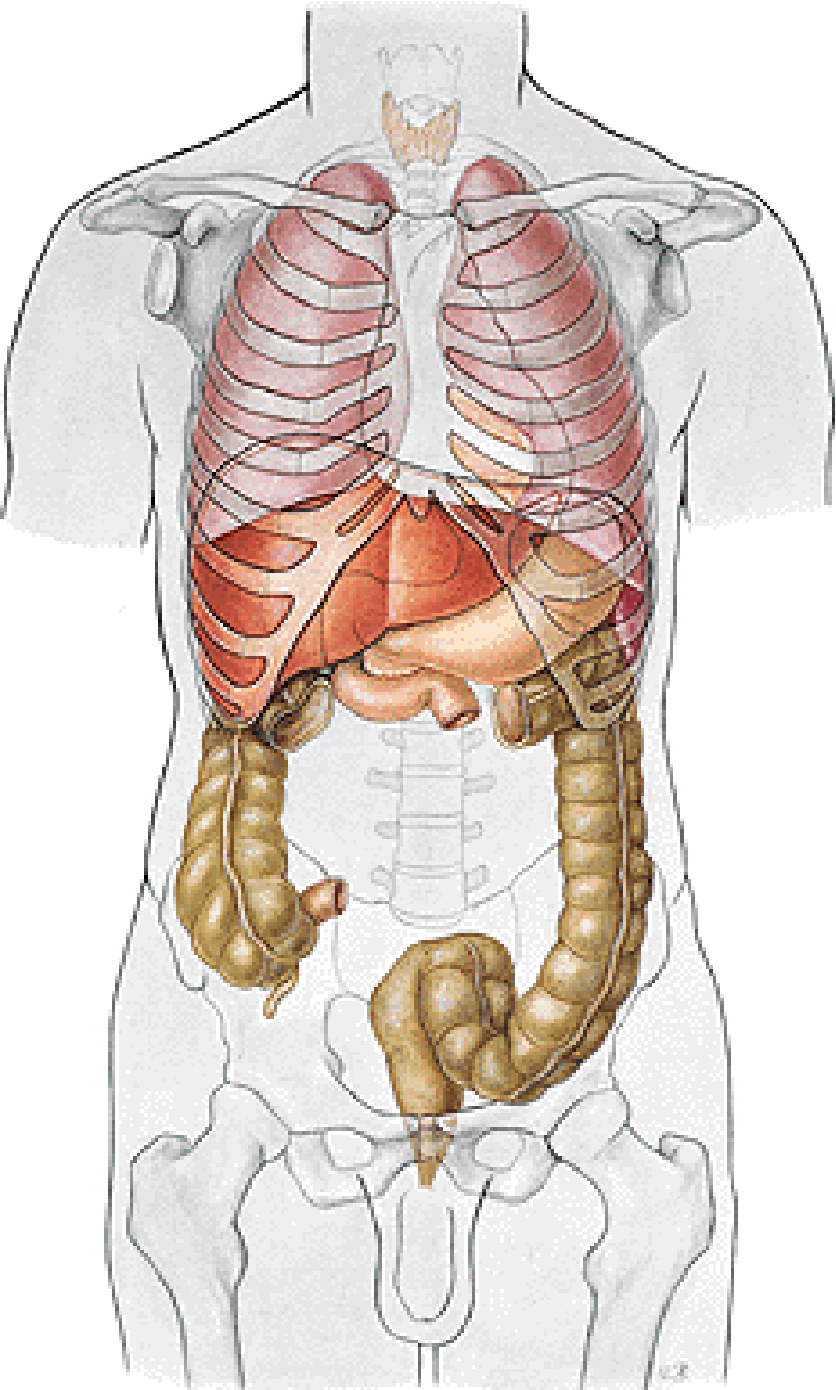


Omentum
- minus
- majus

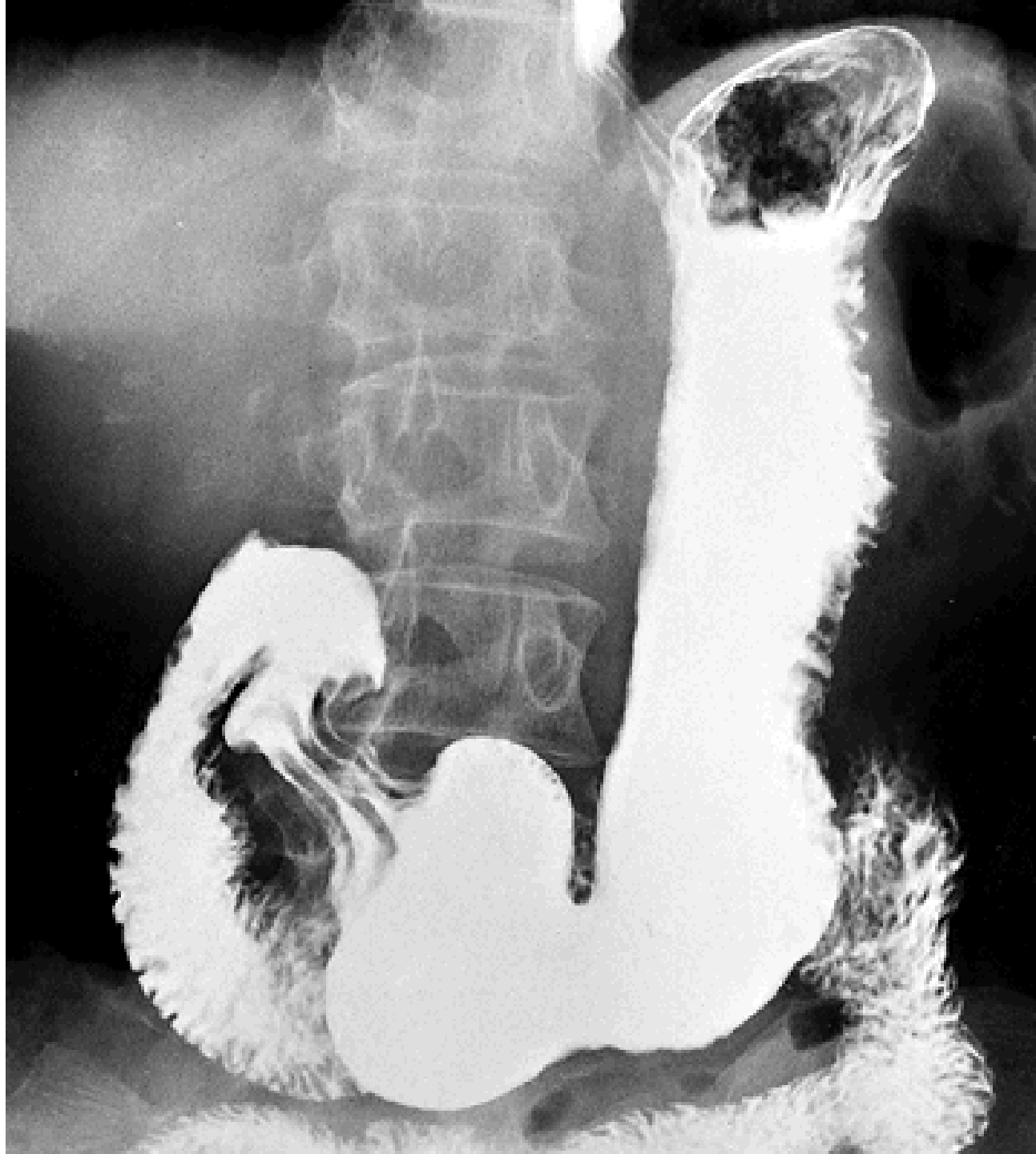


Triangle of Labbeé

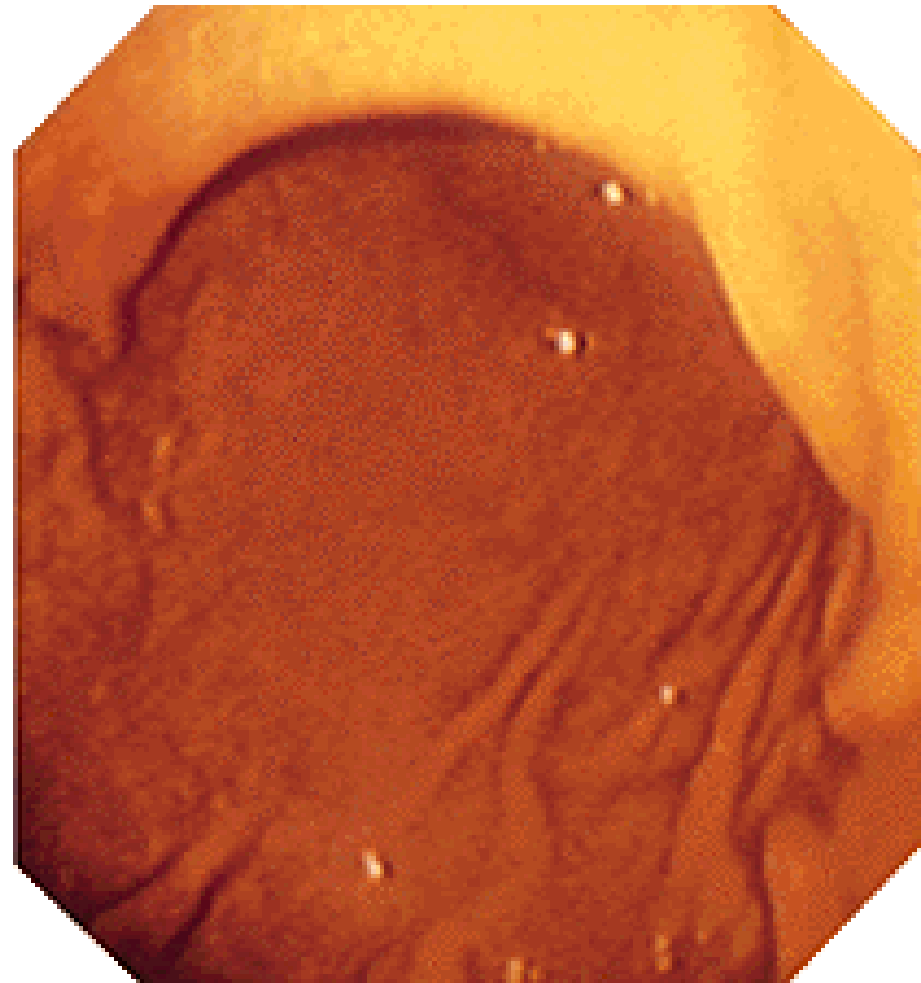
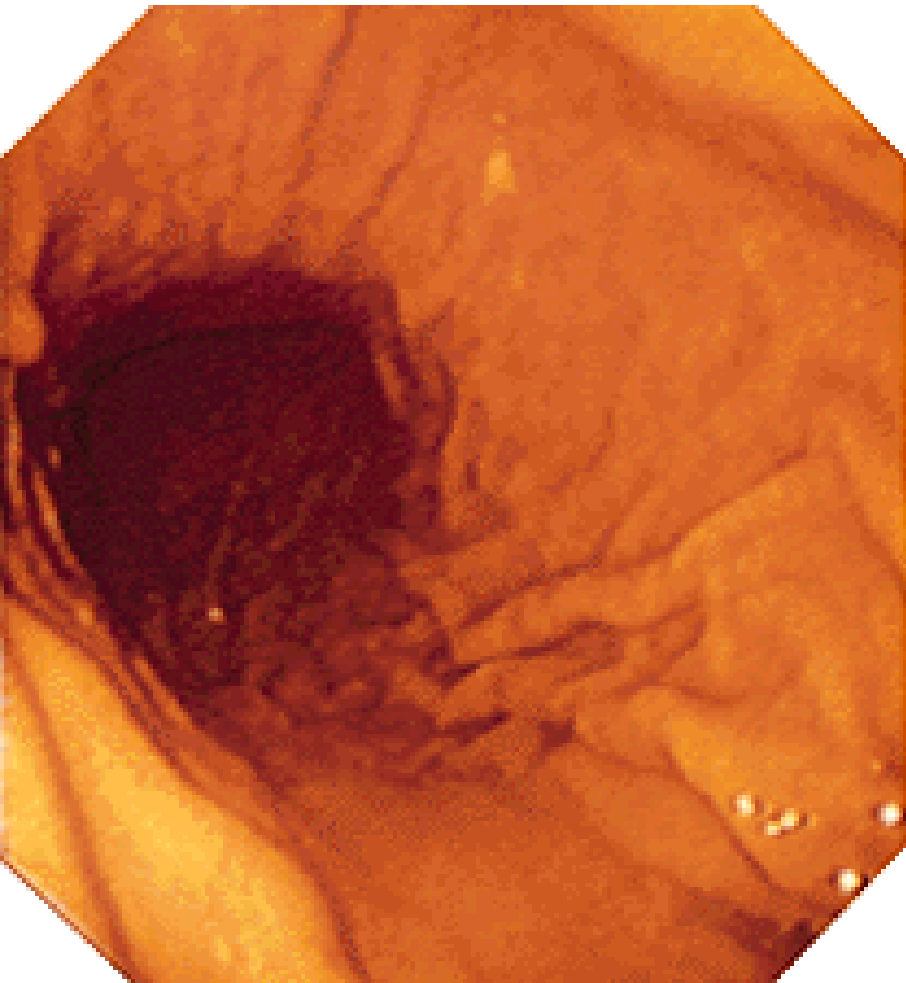
transpyloric line

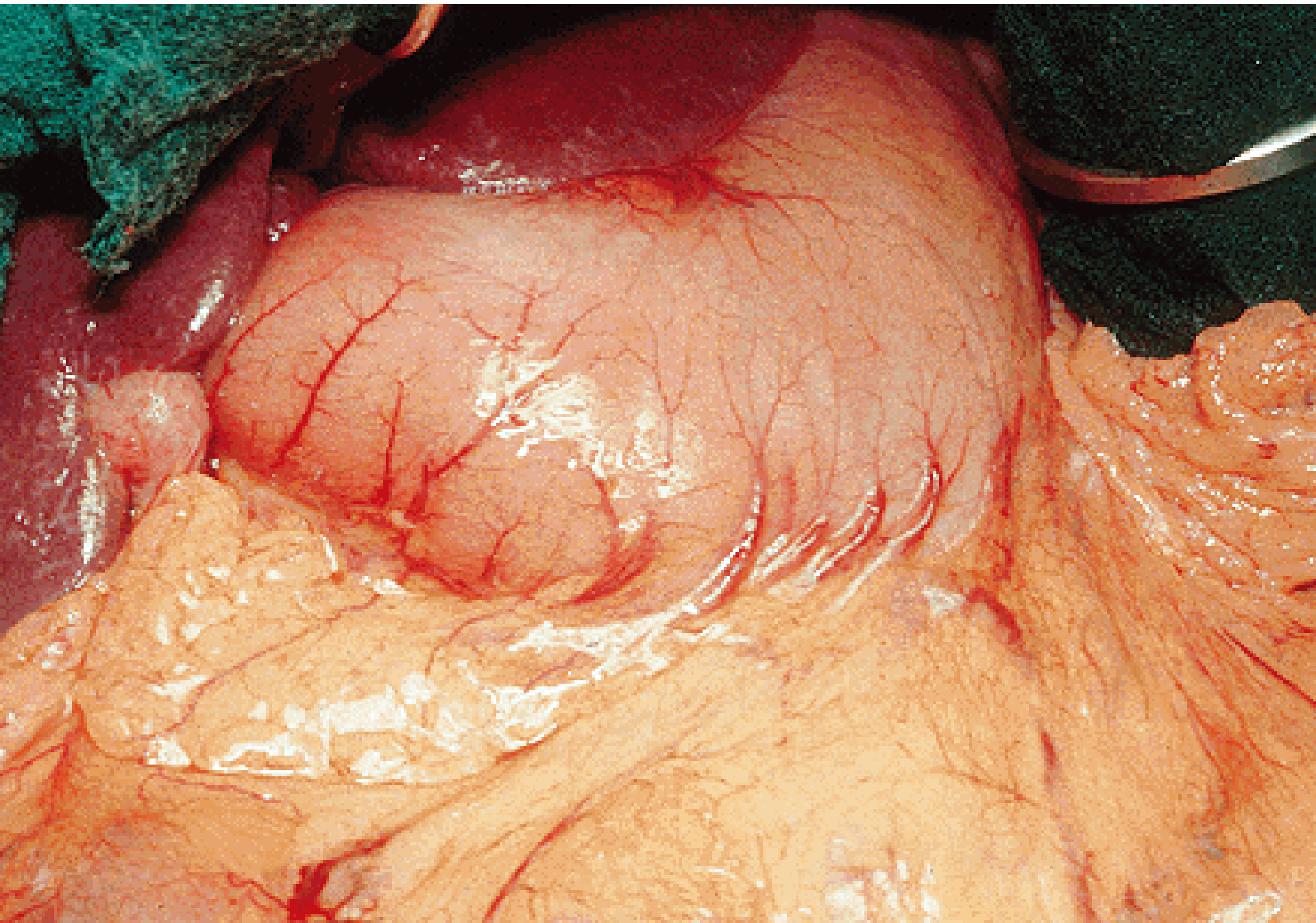


Incisura angularis
Pars digestoria
Pars egestoria



Gastroscopy

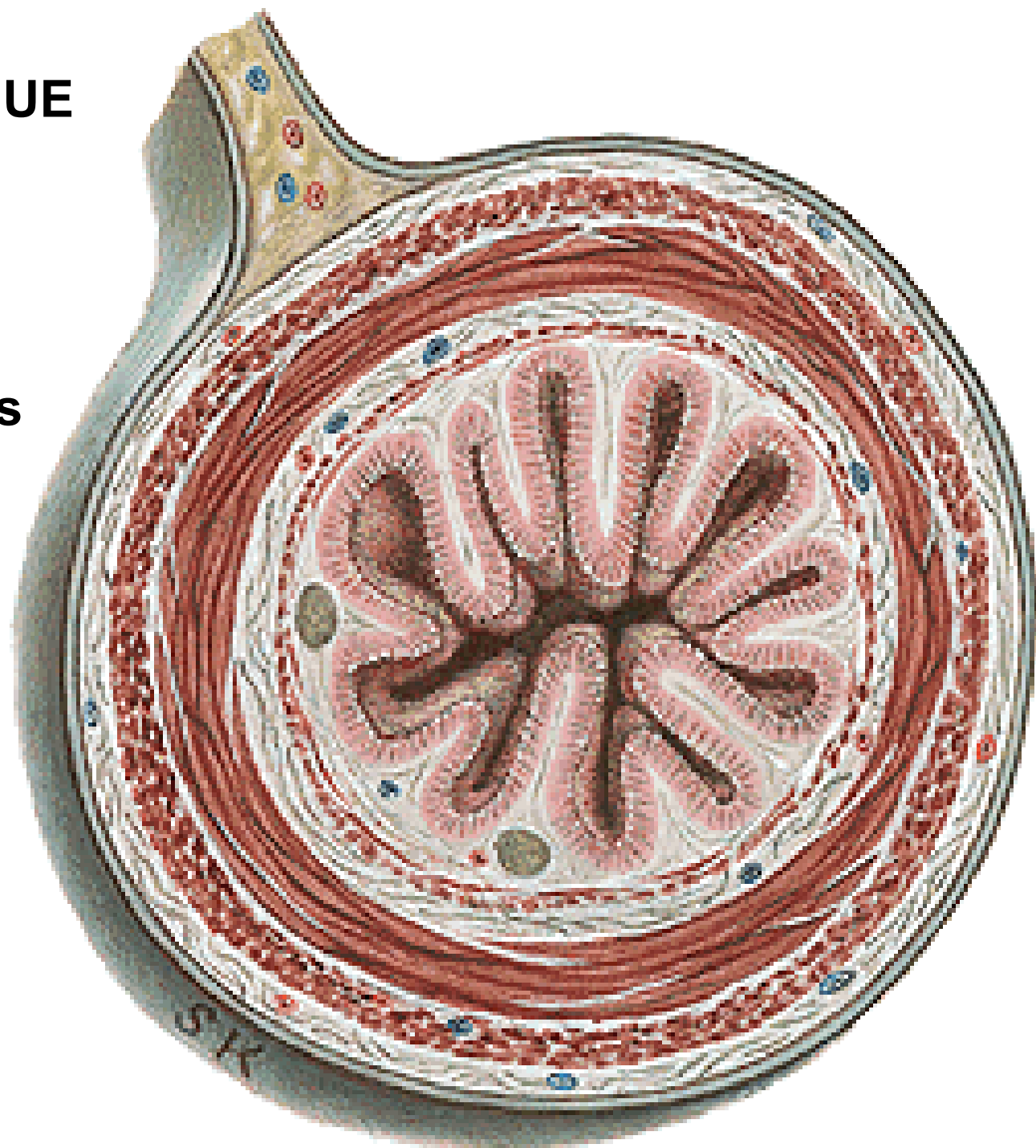




INTESTINUM TENUE

- duodenum
- jejunum
- ileum

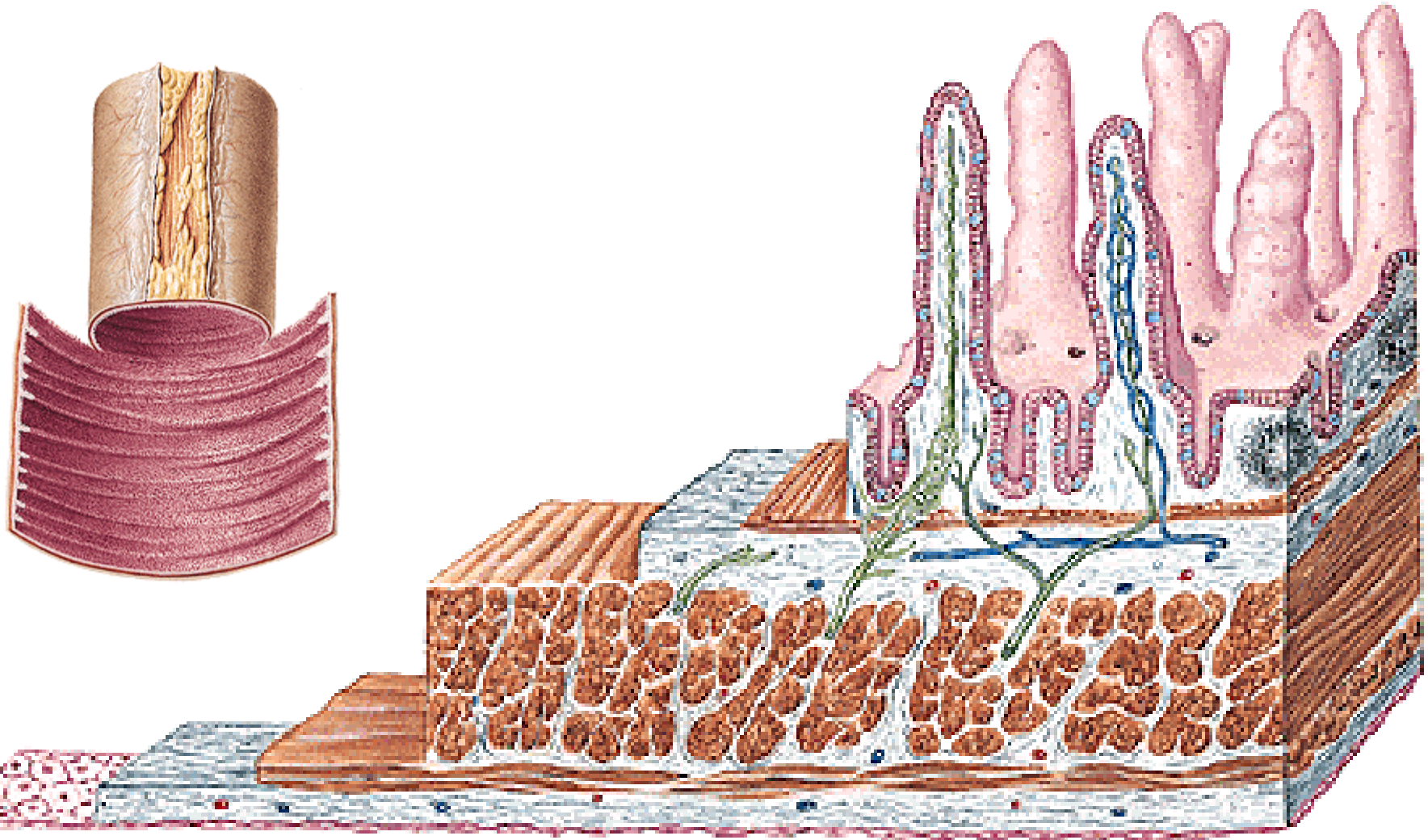
Ansae intestinales
Mesenterium



Plicae circulares Kerkringi

Villi intestinales

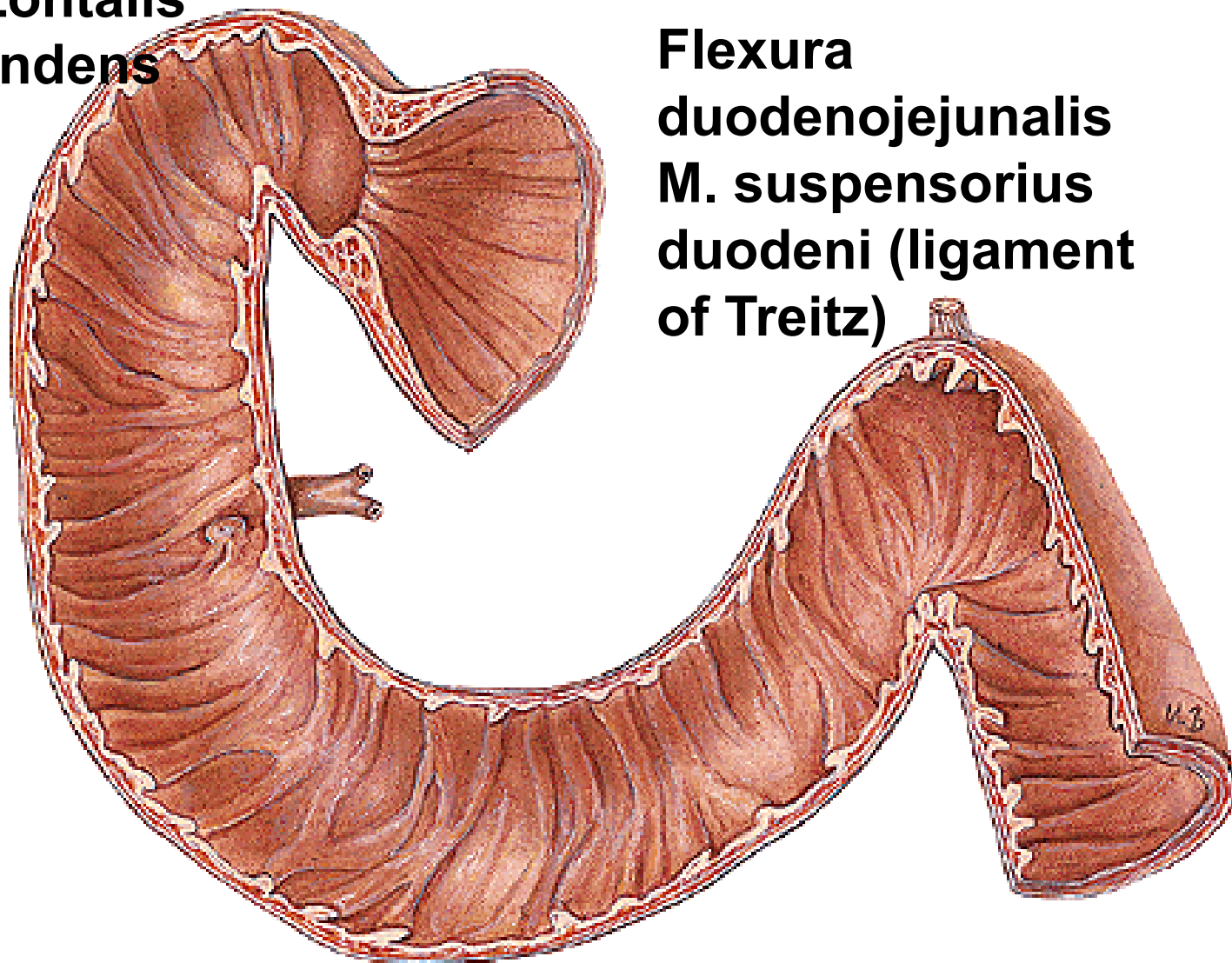
Glandulae intestinales – crypts of Lieberkuehn



DUODENUM

- pars superior (bulbus duodeni), flexura duodeni sup
- pars descendens, flexura duodeni inf.
- pars horizontalis
- pars ascendens

Flexura
duodenojejunalis
M. suspensorius
duodeni (ligament
of Treitz)

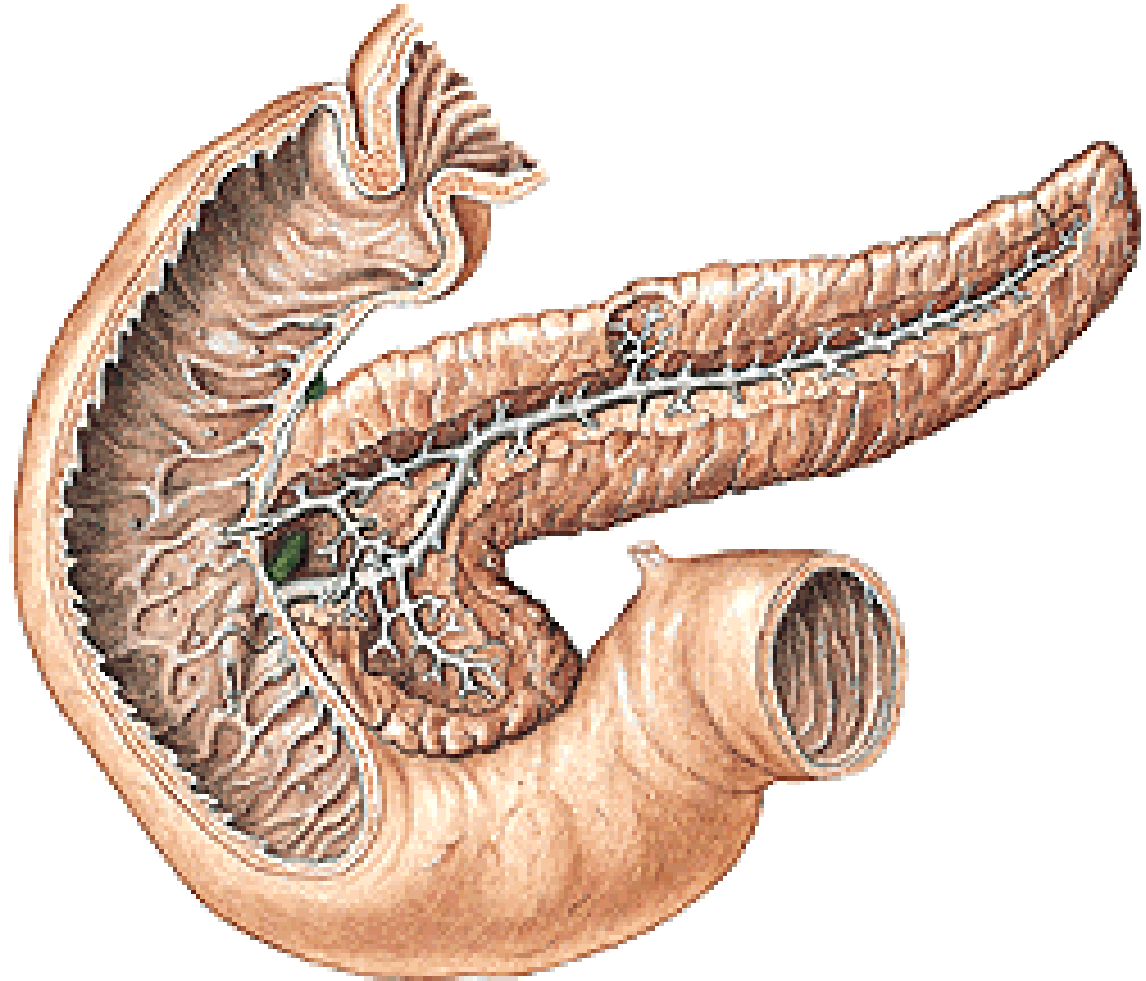


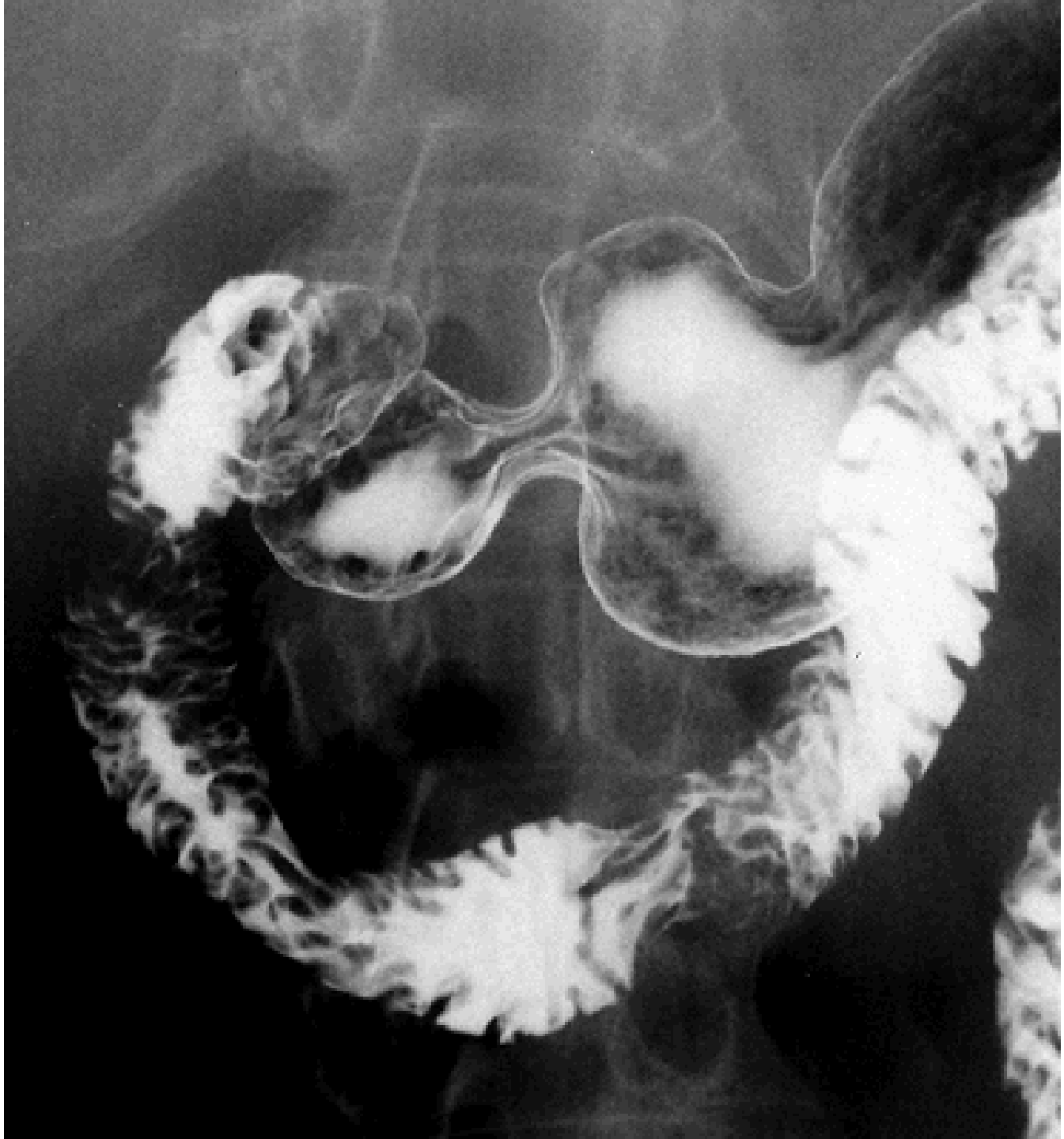
Glandulae
duodenales
Brunneri

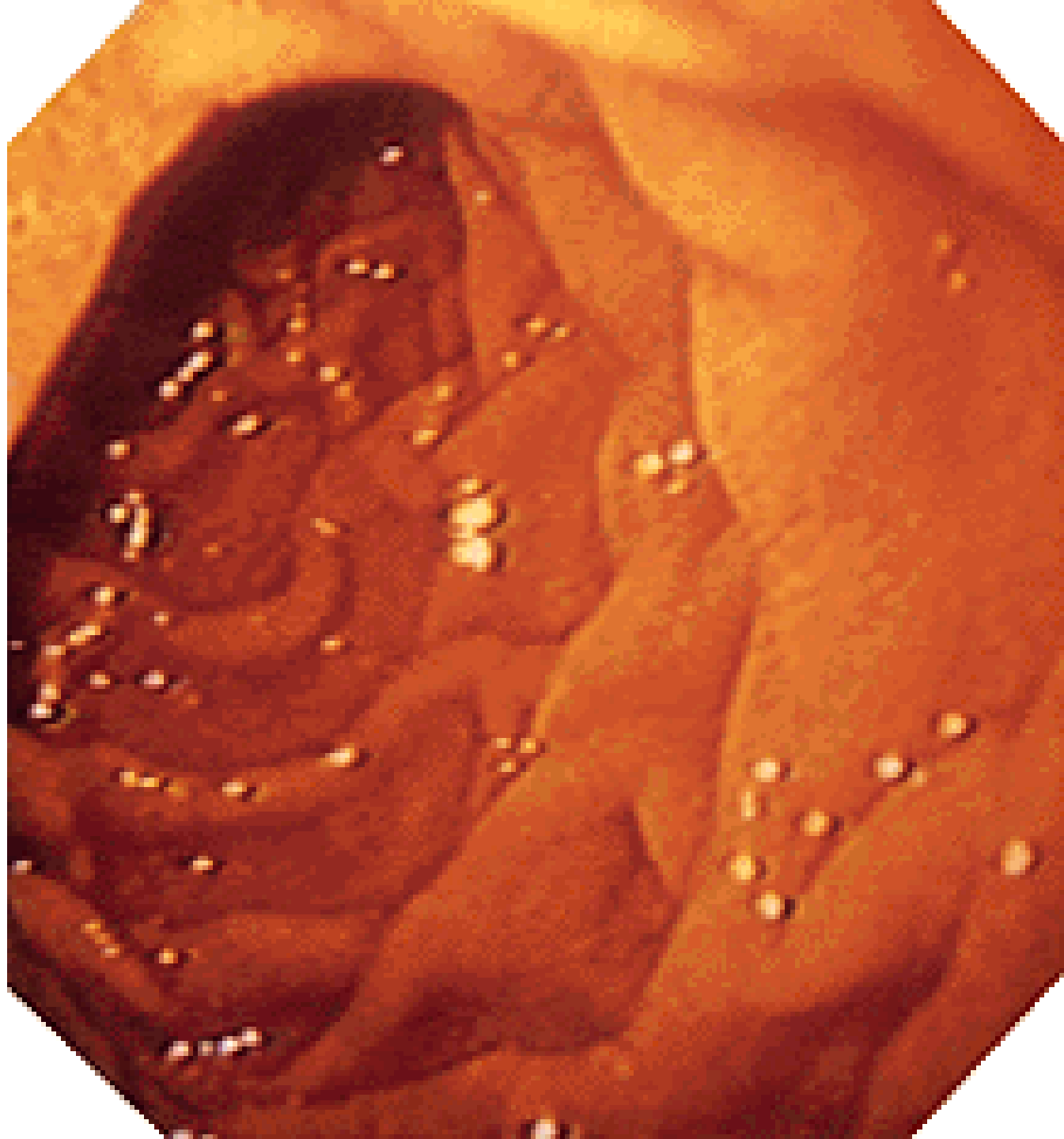
Plica longitudinalis duodeni

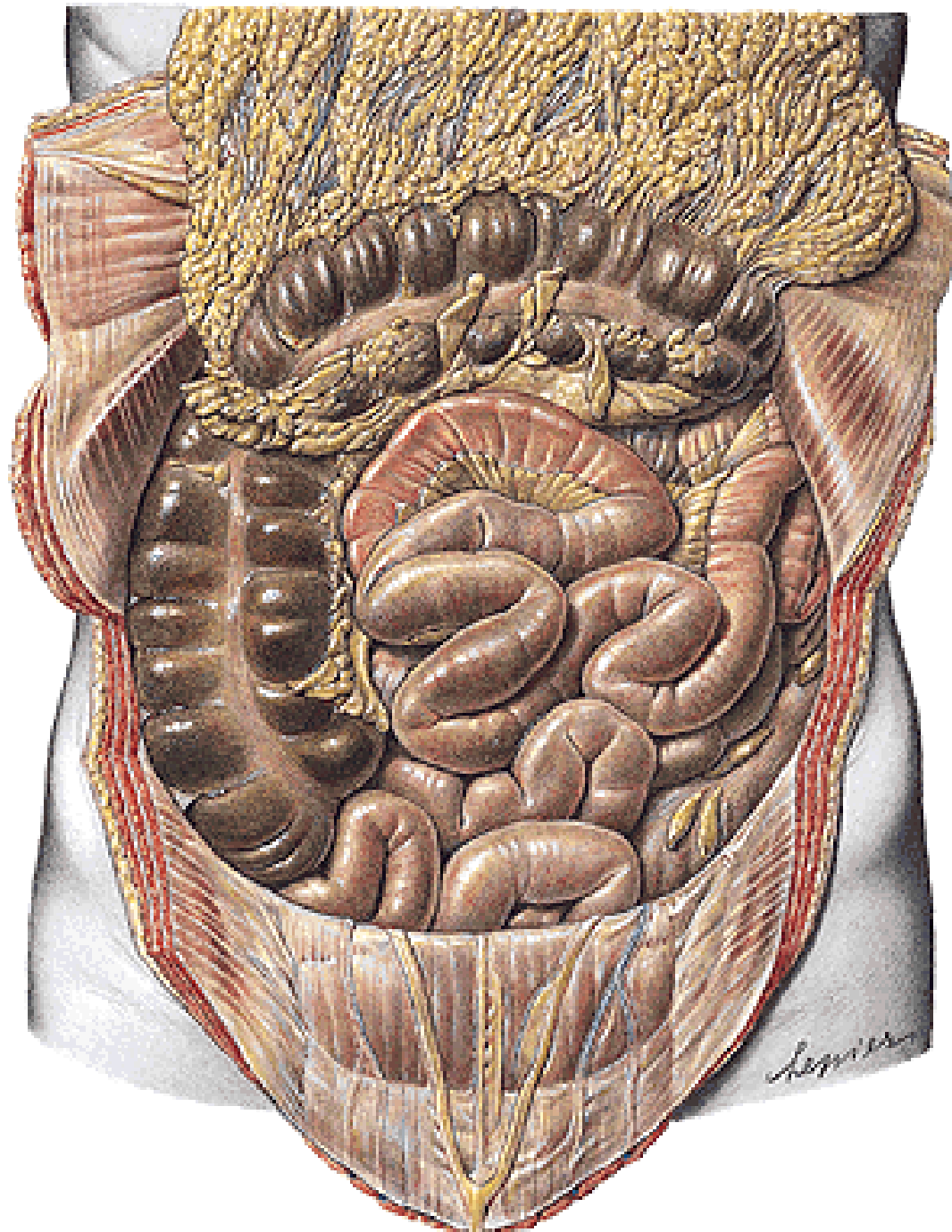
**Papilla duodeni major Vateri - ductus choledochus
- ductus pancreaticus**

**Papilla duodeni
minor-
ductus
pancreaticus
accessorius**



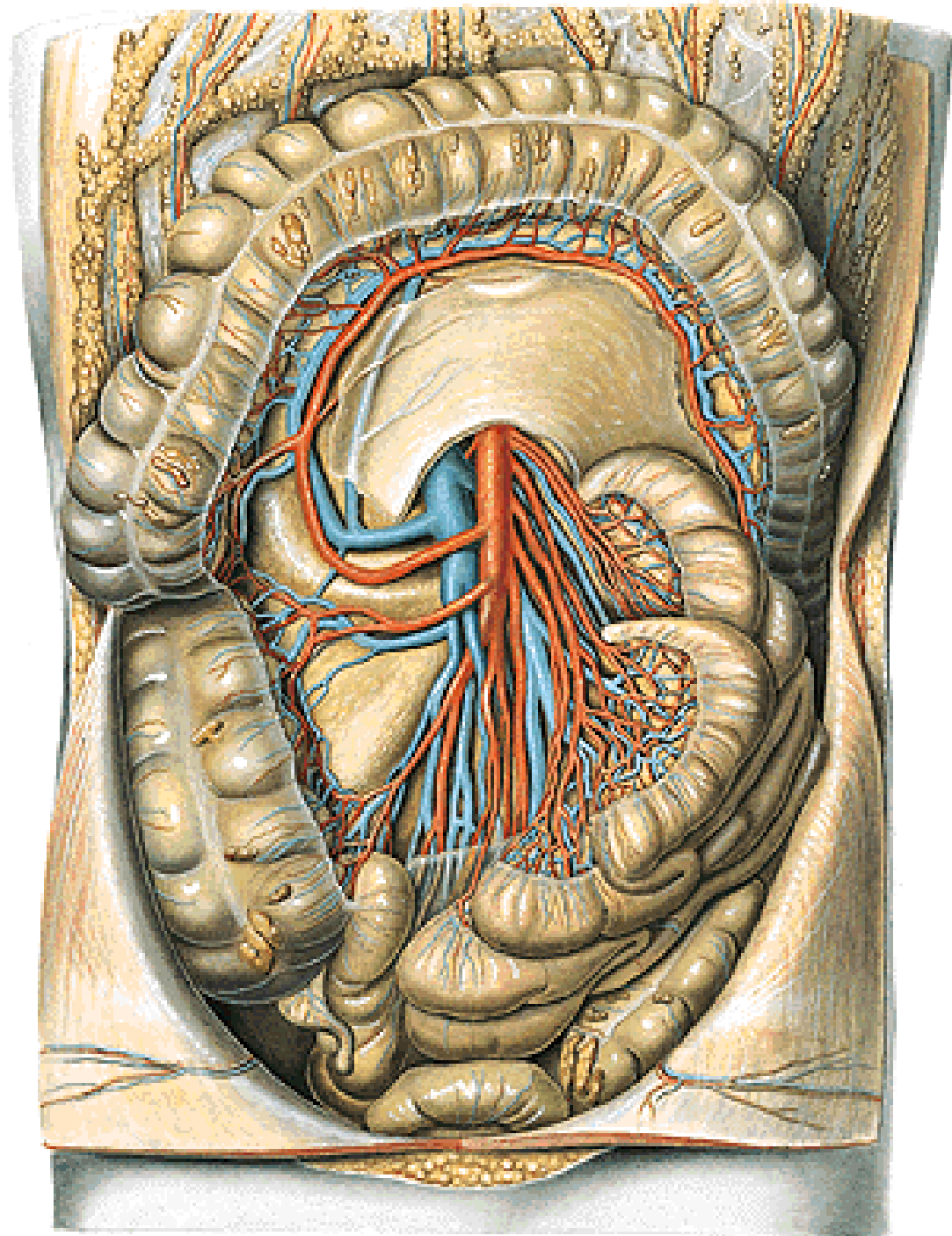


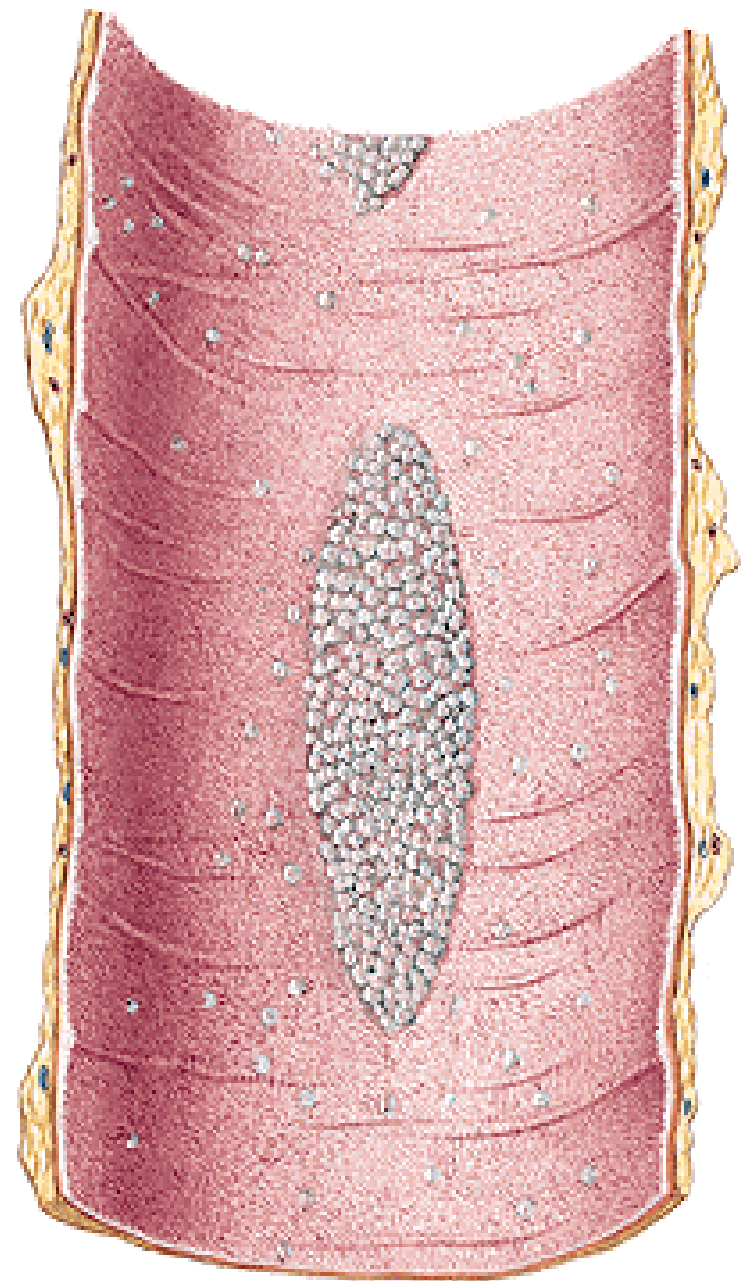
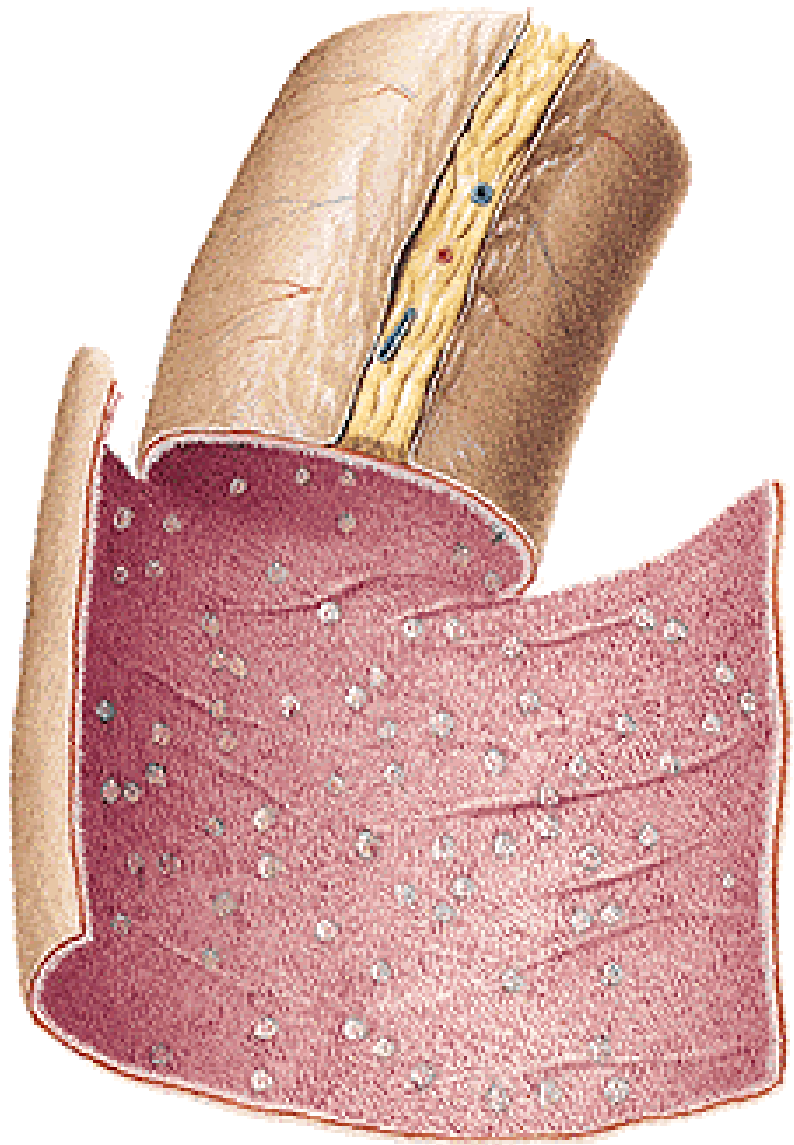




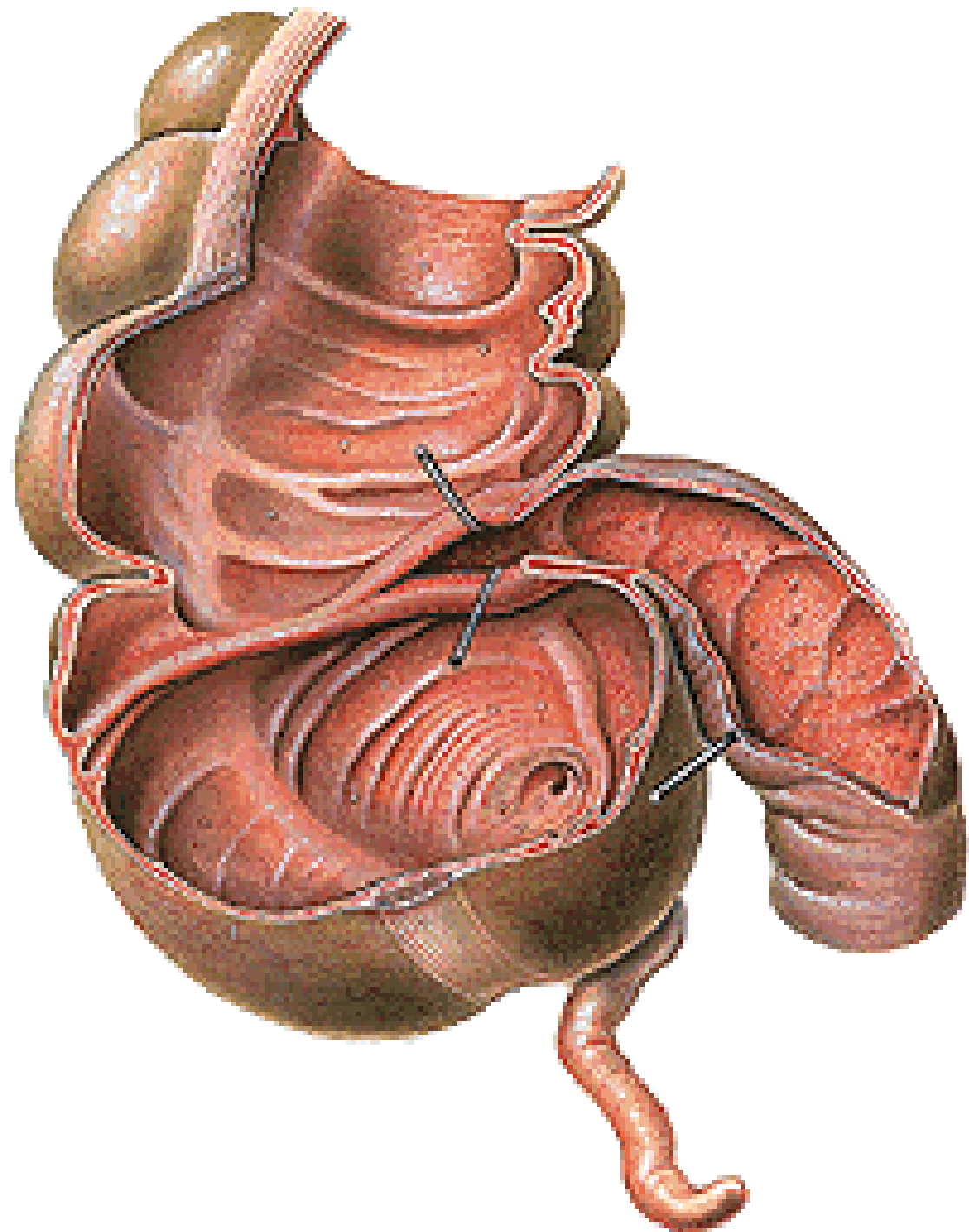
| JEJUNUM | ILEUM |
|--|---|
| upper left part of the inframesocolic space | lower right part of the inframesocolic space |
| wider (3-4 cm) | narrower (2-3 cm) |
| more plicae circulares | fewer plicae circulares |
| 1-2 arcades | 2-3 arcades |
| folliculi lymph. solitarii | folliculi lymph. aggregati |

A. mesenterica sup.



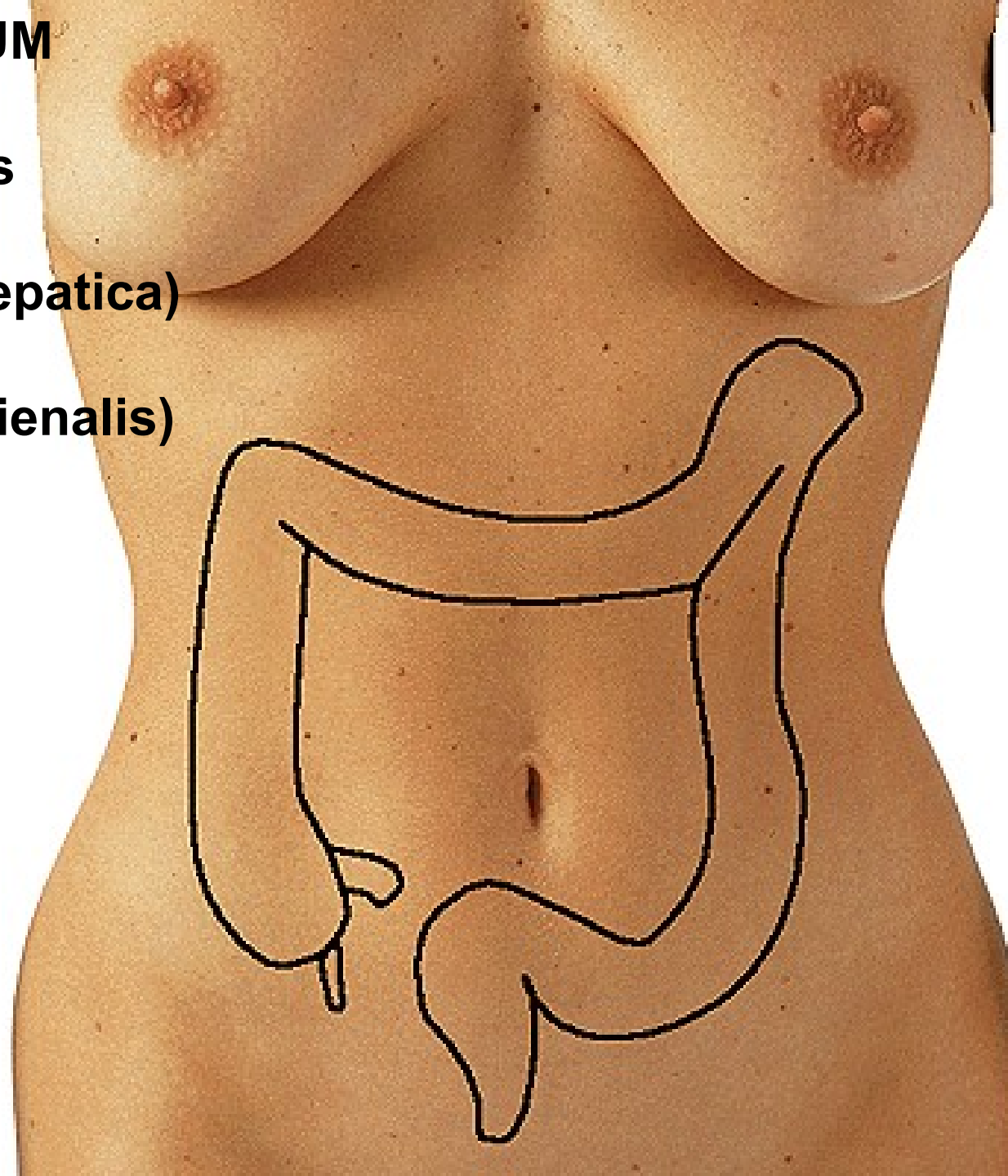


Ostium ileocaecale
Valva ileocaecalis
-labium superius
-labium inferius



INTESTINUM CRASSUM

- intestinum caecum**
- appendix vermiformis**
- colon ascendens**
- flexura coli dextra (hepatica)**
- colon transversum**
- flexura coli sinistra (lienalis)**
- colon descendens**
- colon sigmoideum**
- rectum**



Plicae semilunares

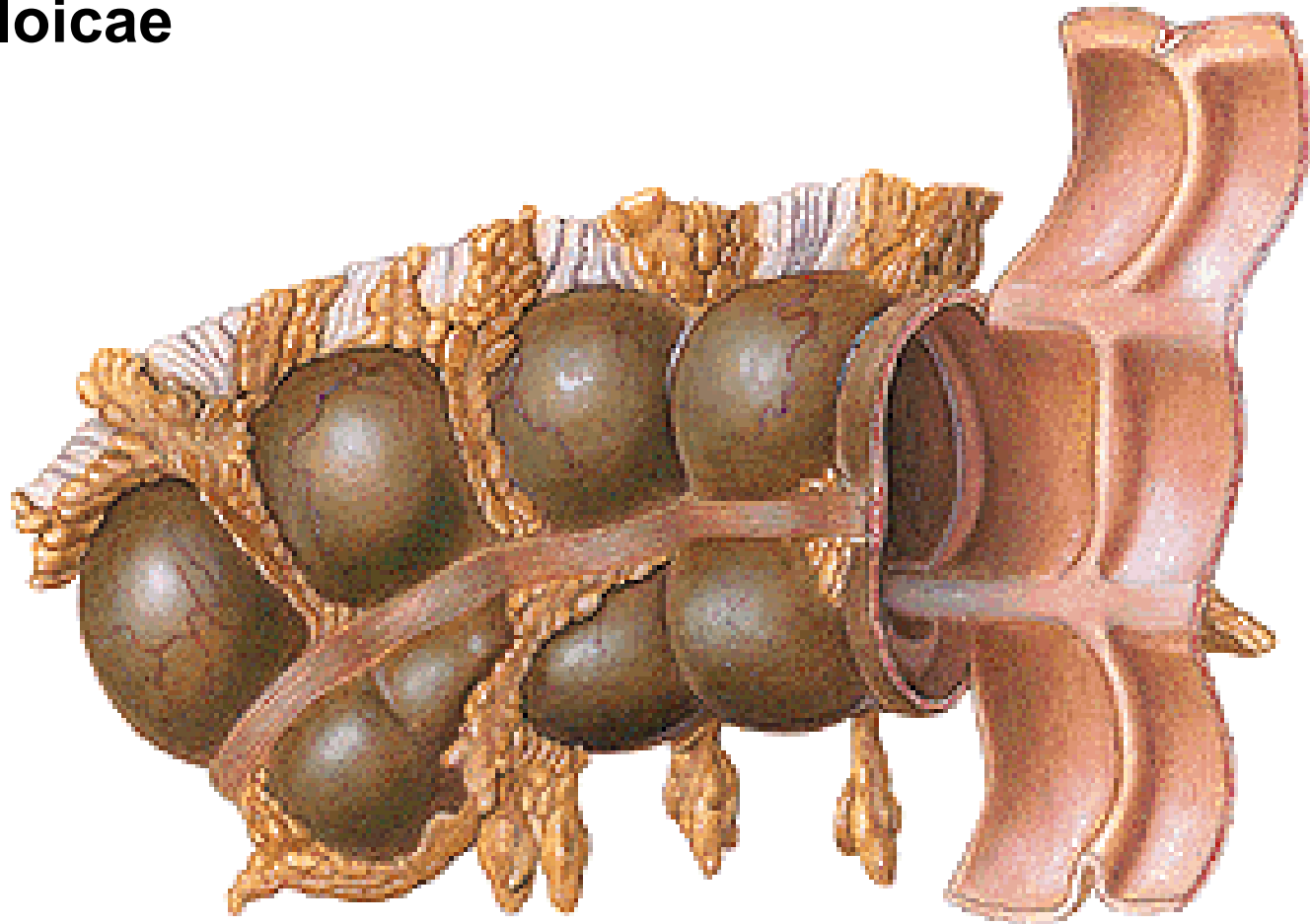
Haustra coli

Taenia mesocolica

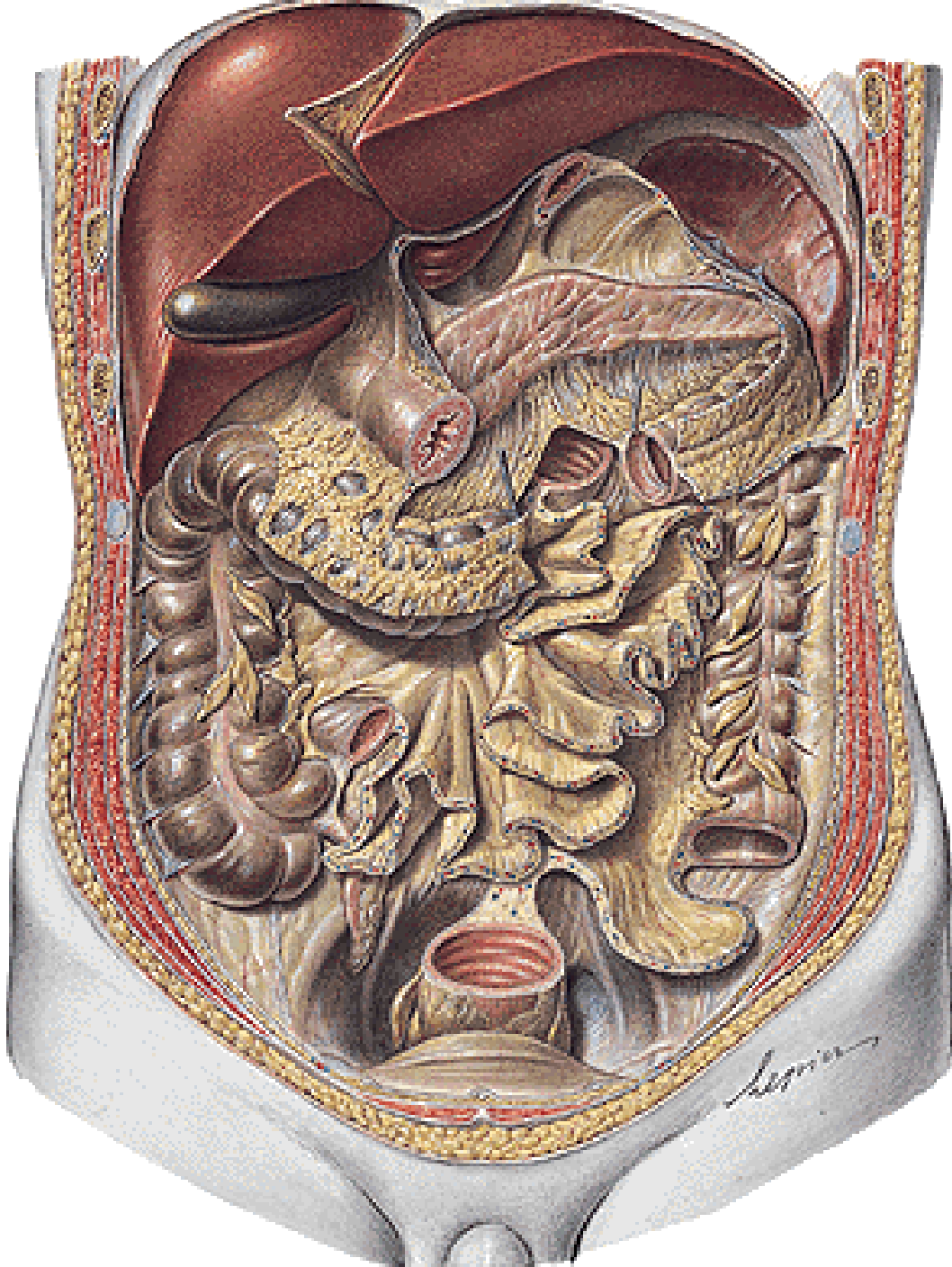
Taenia omentalis

Taenia libera

Appendices epiploicae



INTESTINUM CAECUM



APPENDIX VERMIFORMIS

ostium appendicis vermiformis
valva appendicis vermiformis

Positio pelvina

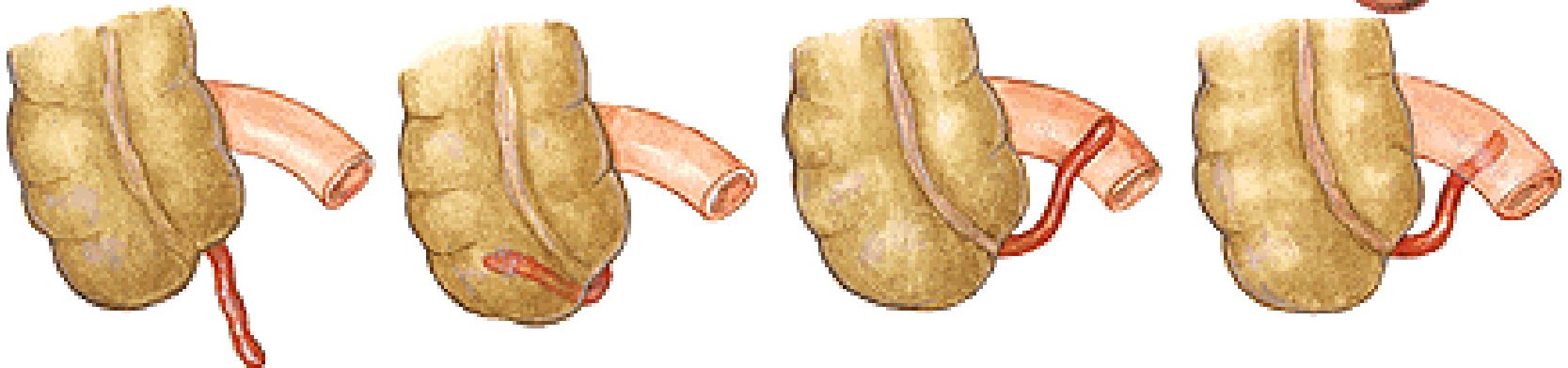
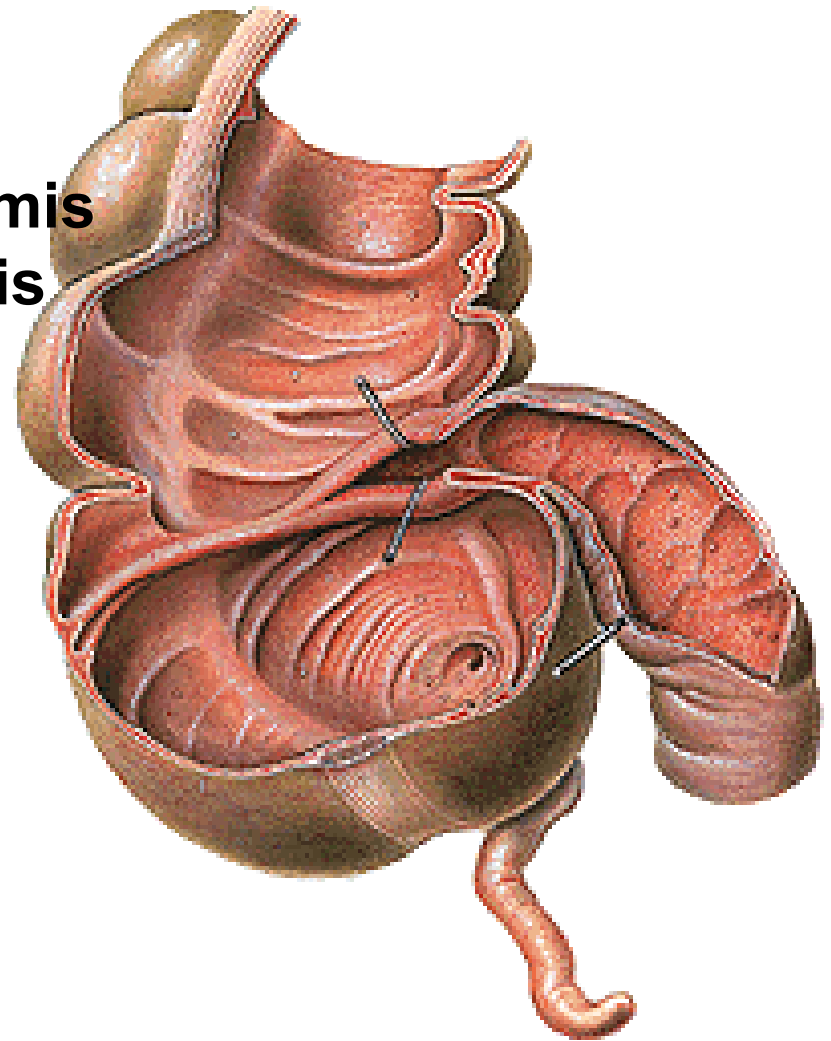
- lig. appendiculoovaricum

Positio retrocaecalis

Positio ileocaecalis

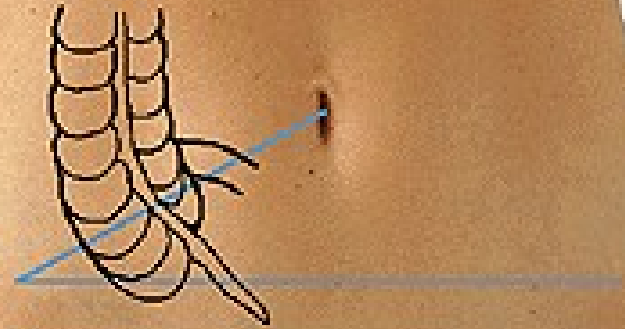
Positio retroilealis

Positio praecaecalis

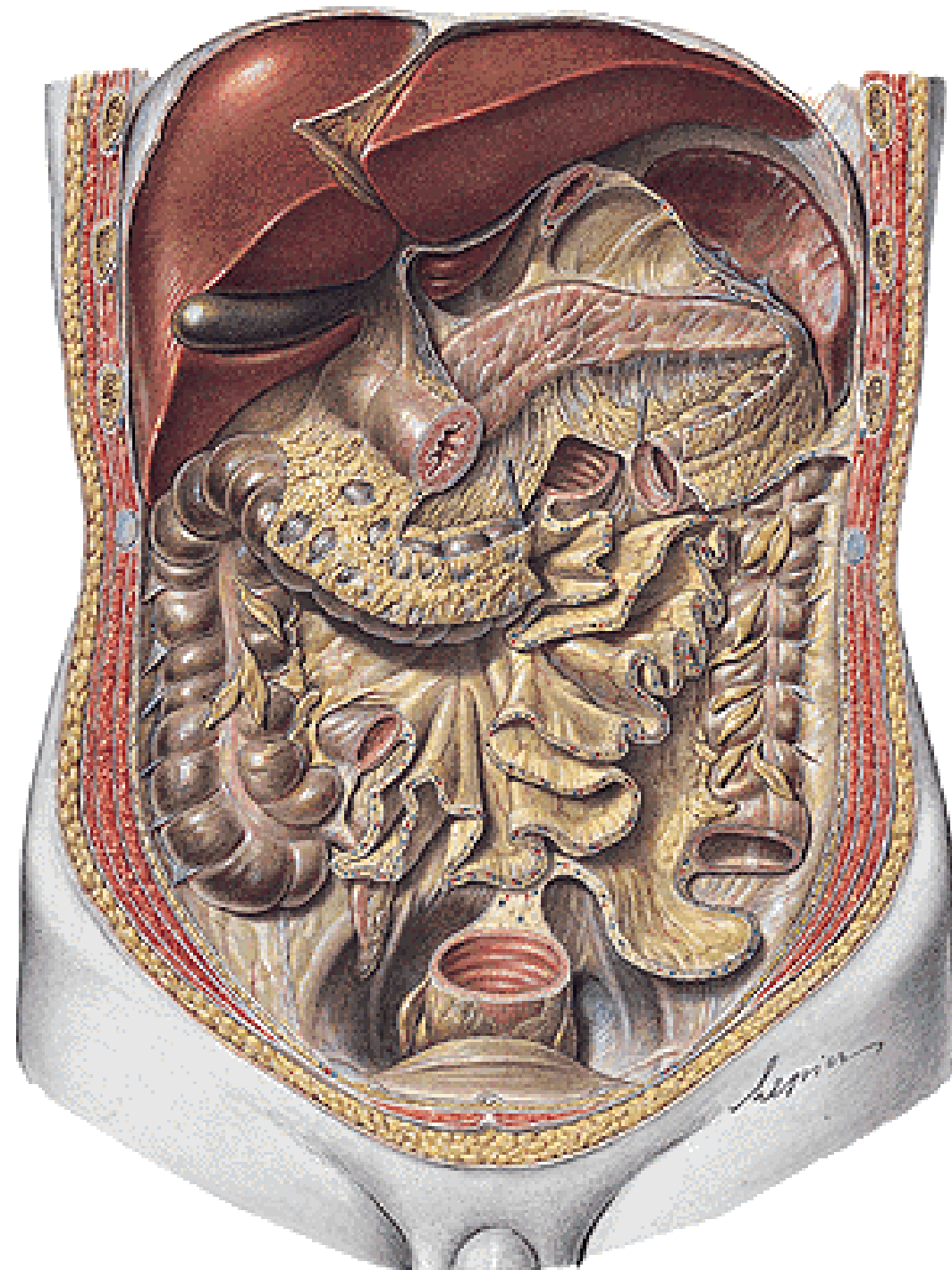


**Linea spinoumbilicalis dextra
(Monro) - MacBurney's point
Linea bispinalis – Lanz's point**

Tonsilla abdominalis



COLON ASCENDENS
Flexura coli dextra
(hepatica)



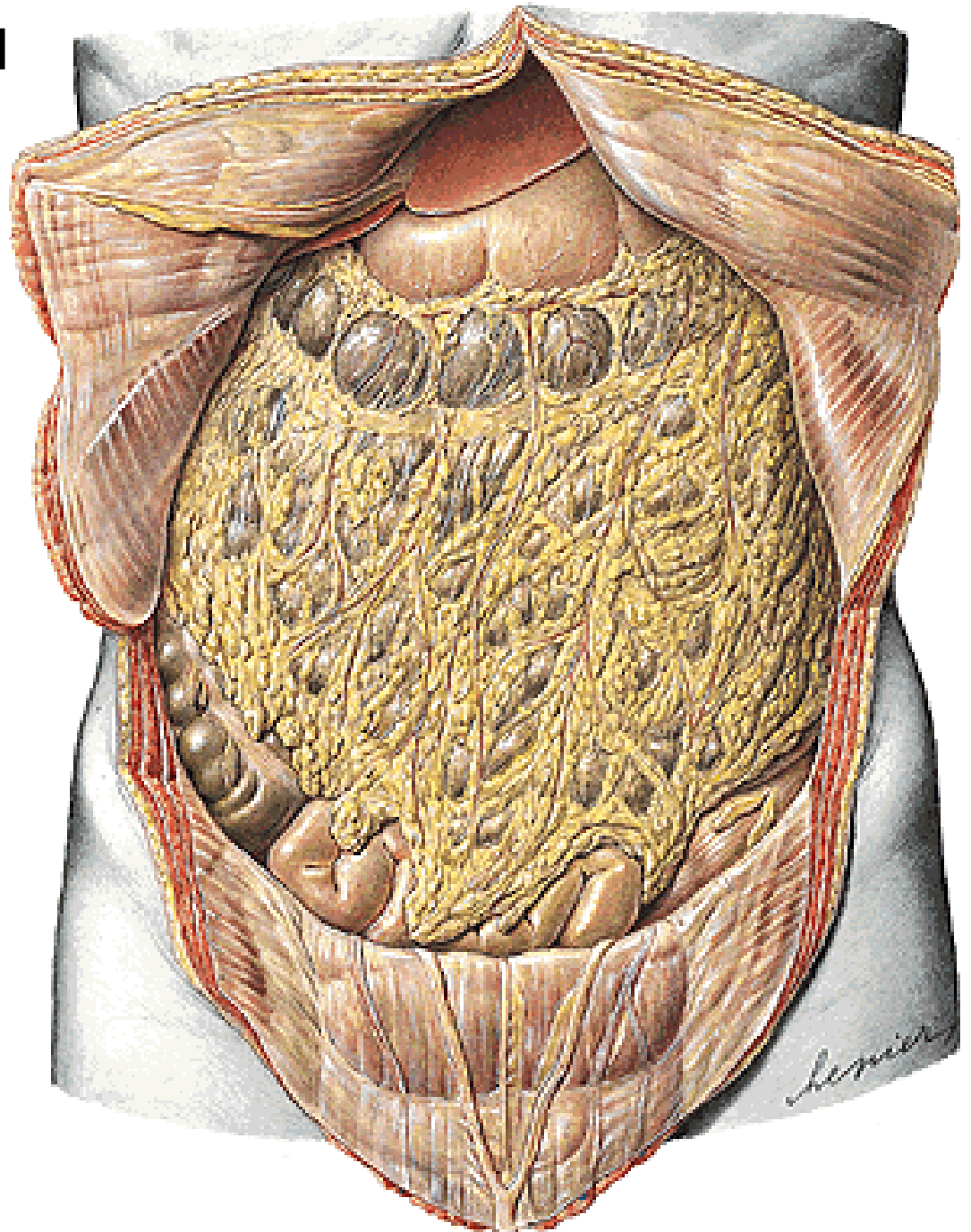
COLON TRANSVERSUM

Flexura coli sinistra
(lienalis)

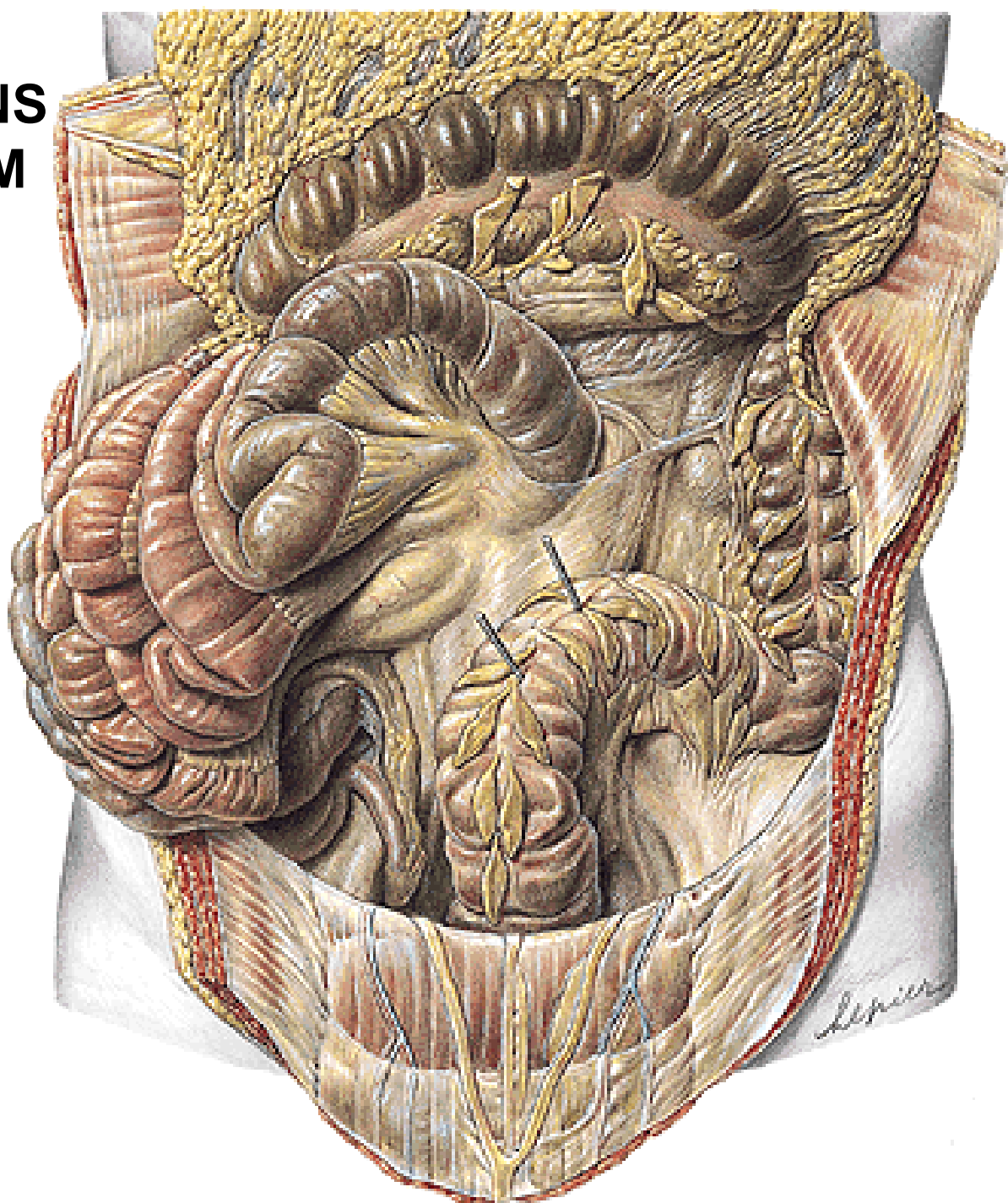Mesocolon transversum

Omentum majus

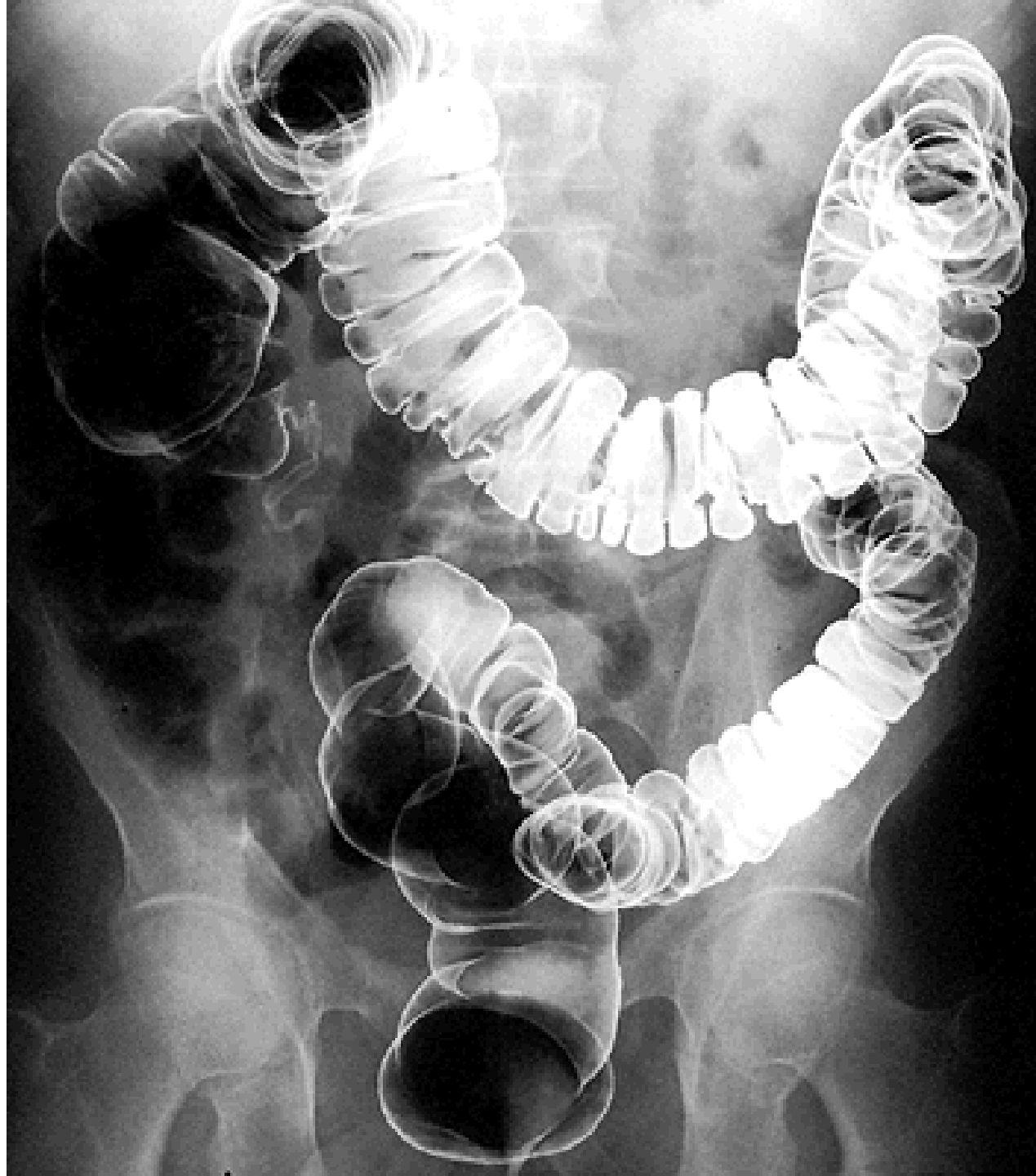Lig. gastrocolicum



COLON DESCENDENS
COLON SIGMOIDEUM
Mesosigmoideum



Irigography



RECTUM

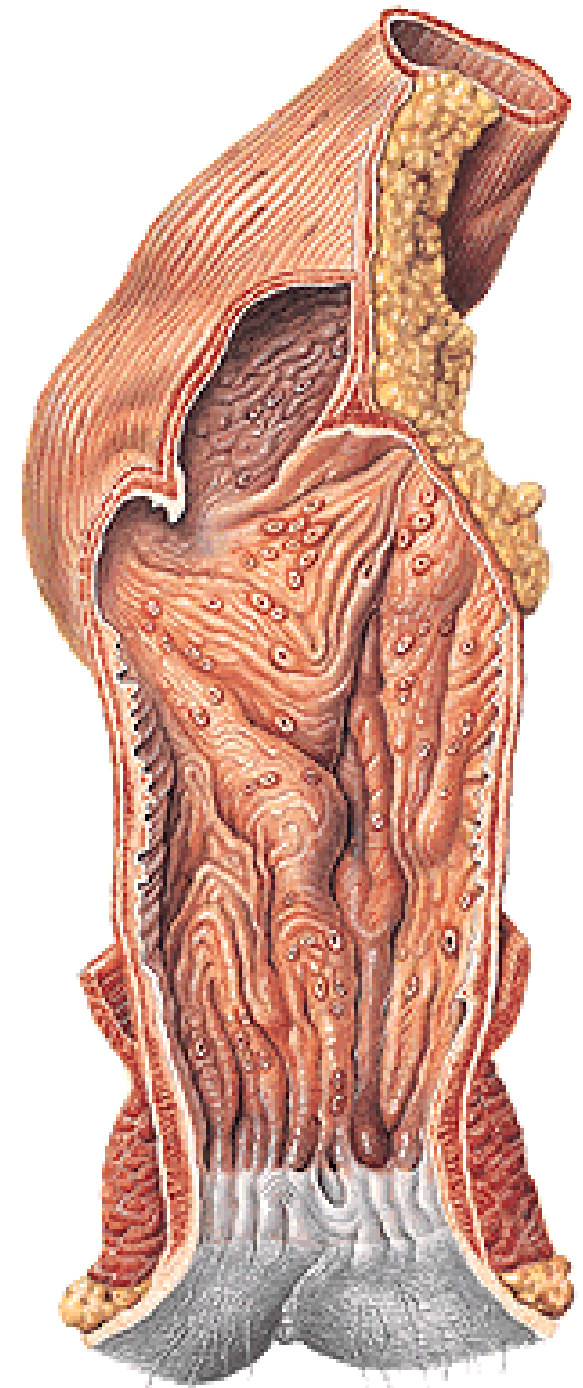
Crena ani – anus

Ampulla recti

- flexura sacralis
- plicae transversae recti
- plica t.r. media (Kohlrausch)

Canalis analis

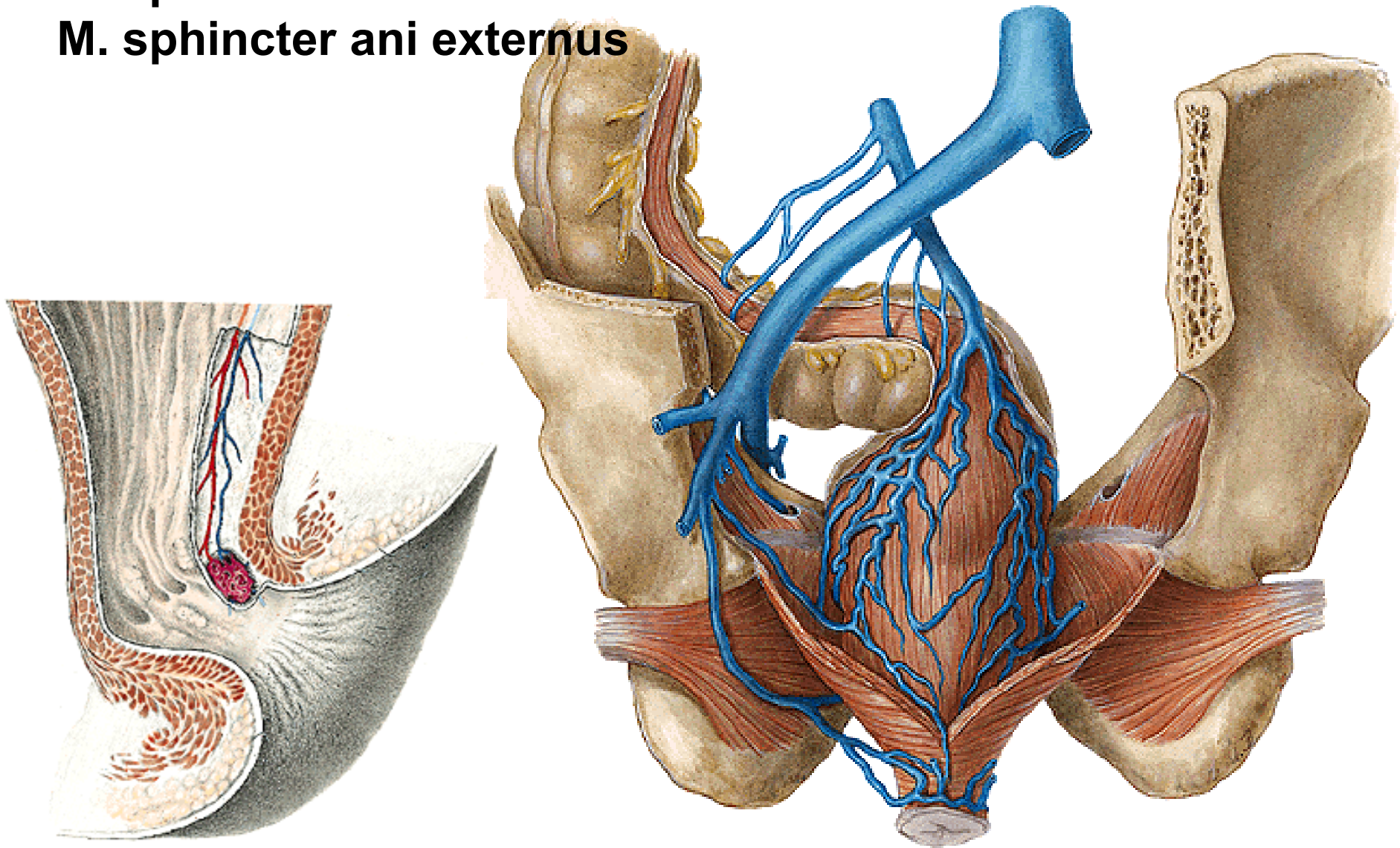
- flexura perinealis
- linea anorectalis
- columnae anales
- sinus anales
- valvulae anales
- pecten analis
- linea anocutanea
- zona haemorrhoidalis



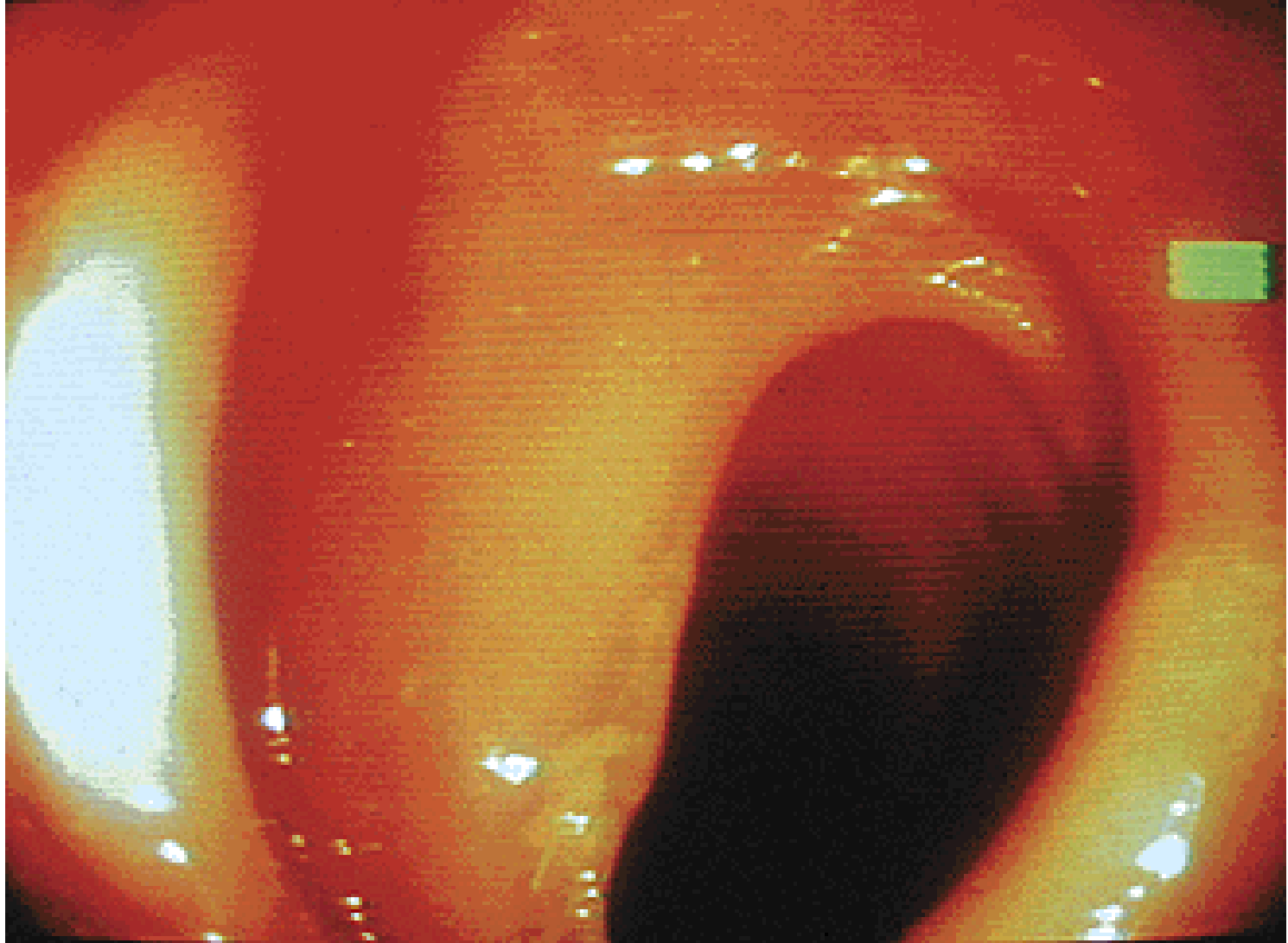
Plexus venosus rectalis

M. sphincter ani internus

M. sphincter ani externus



Rectoscopy



Illustrations, photographs, and radiographs were copied from:
Atlas der Anatomie des Menschen/Sobotta.
Putz,R., und Pabst,R. 20. Auflage. München:
Urban & Schwarzenberg, 1993)