

# **MALE GENITAL ORGANS**

**Internal genital organs:**

**Testis**

**Epididymis**

**Ductus deferens**

**Urethra masculina**

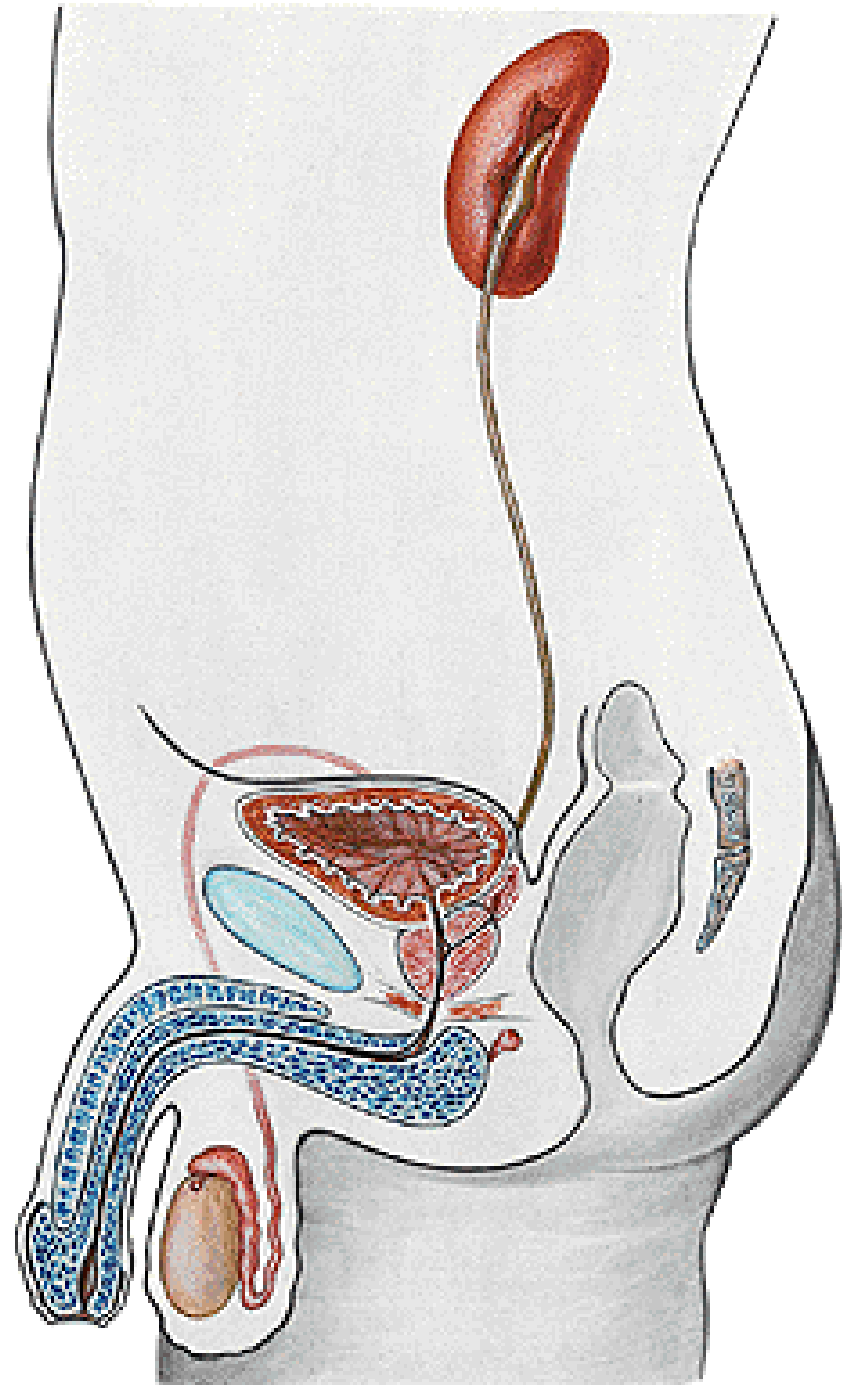
**Vesicula seminalis**

**Prostata**

**External genital organs:**

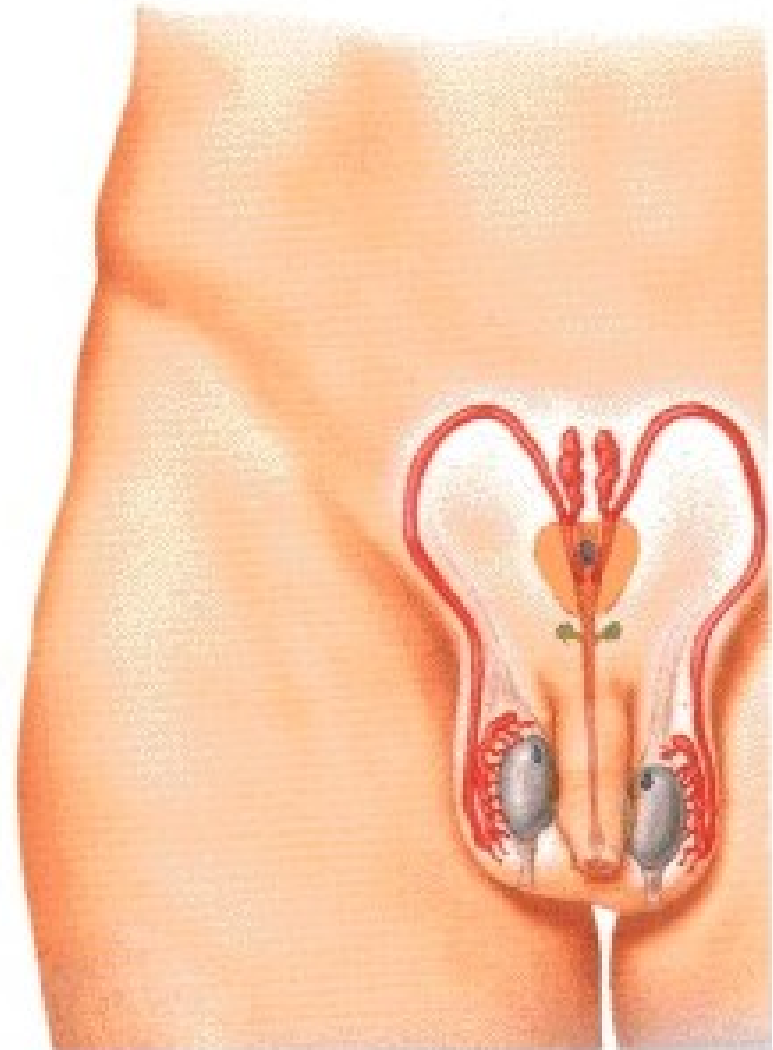
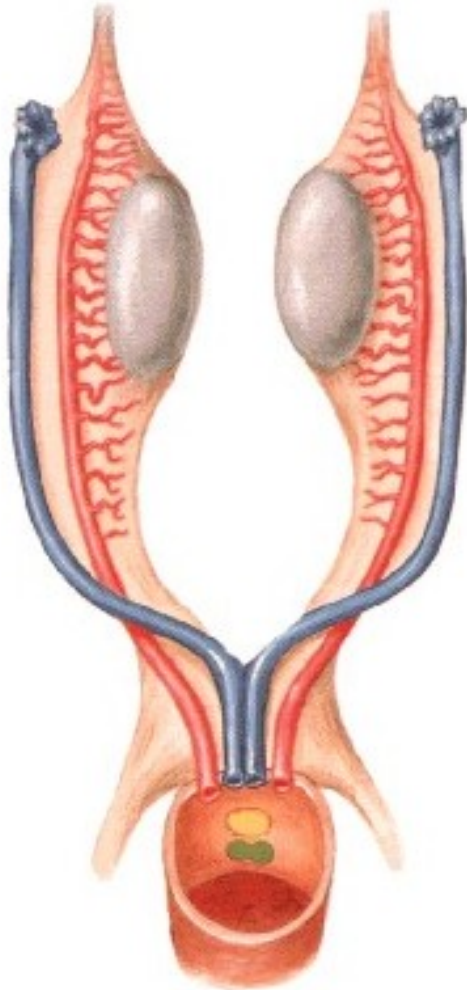
**Penis**

**Scrotum**



# Development: Wolffian ducts Müllerian ducts

Undifferentiated Stage



# TESTIS

**Facies medialis**

**Facies lateralis**

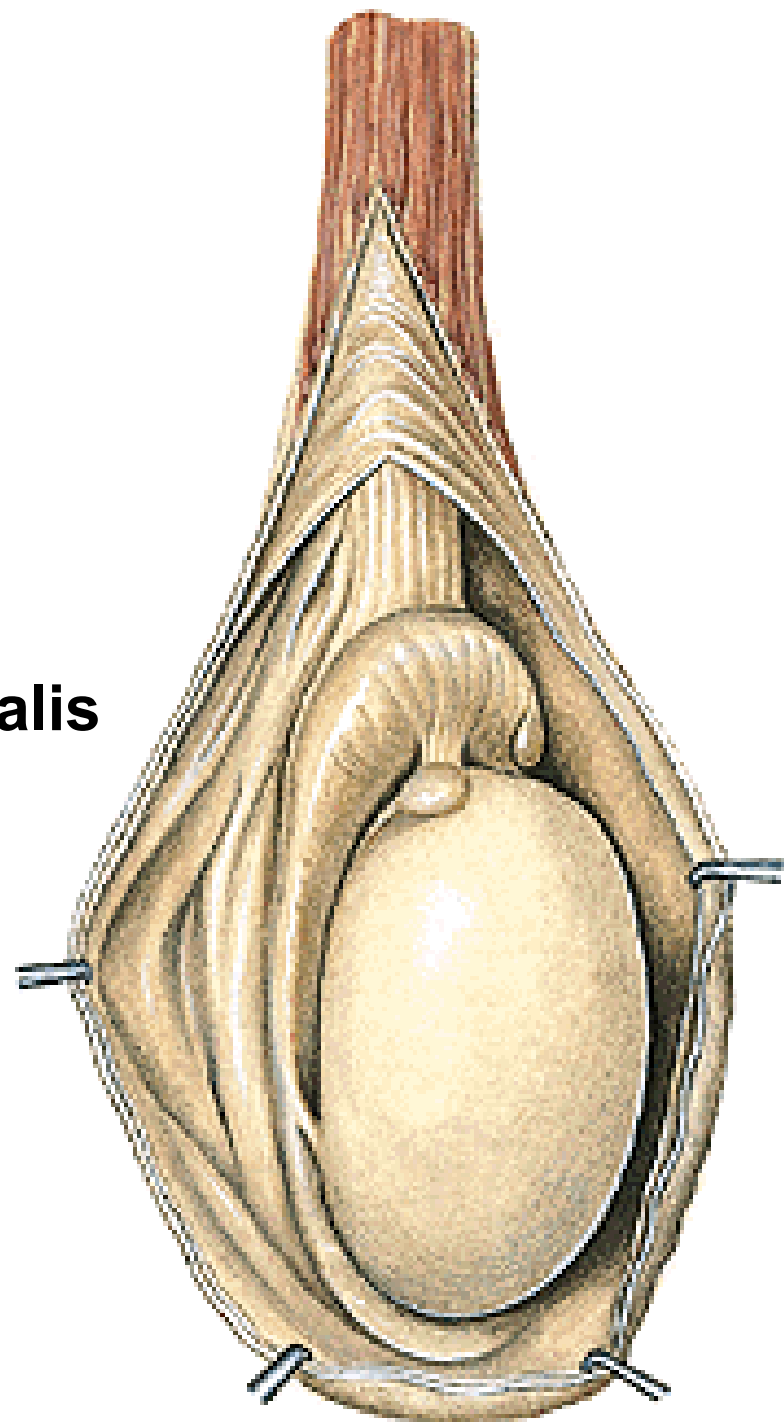
**Extremitas superior**

**Extremitas inferior**

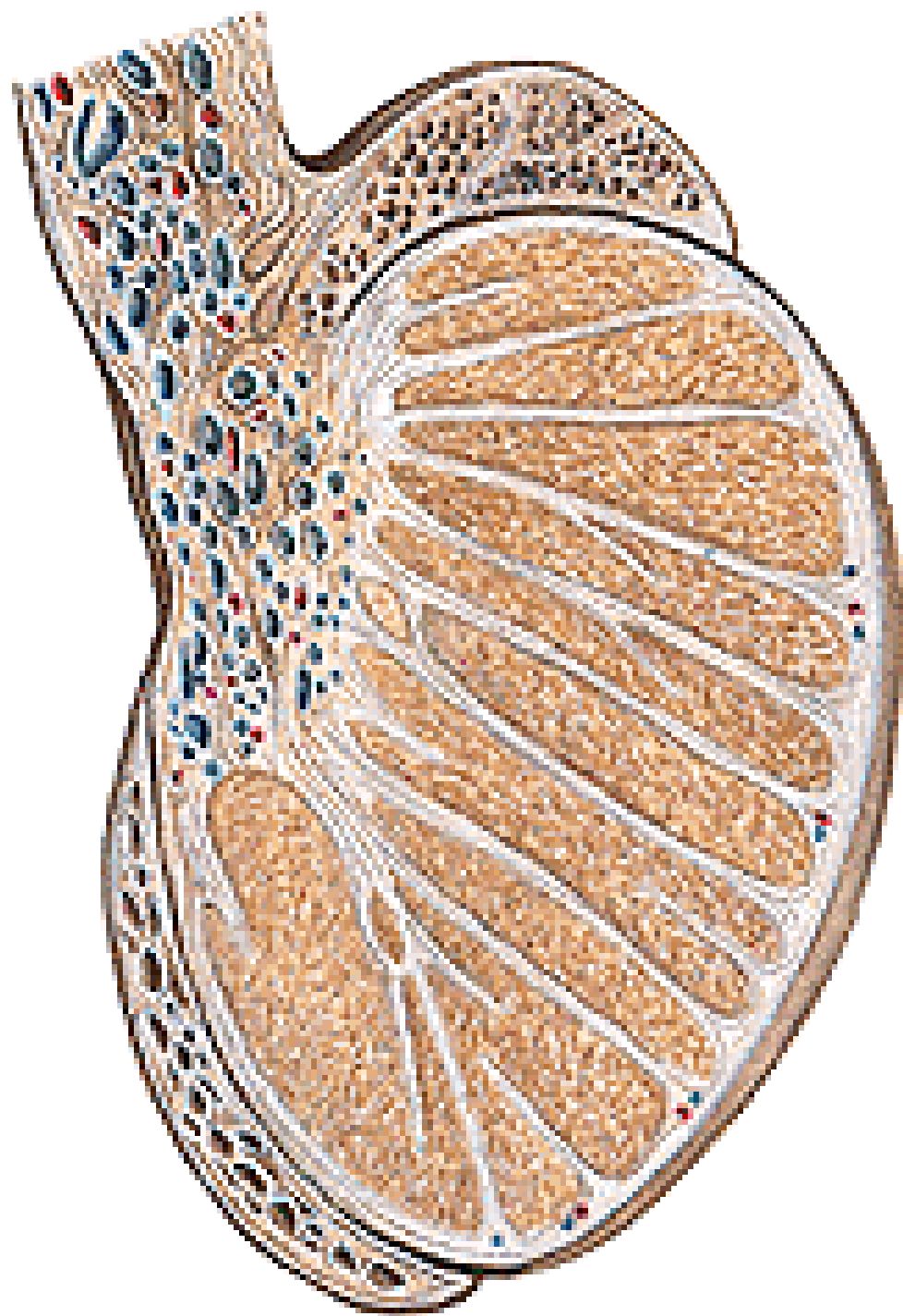
**Margo anterior**

**Margo posterior**

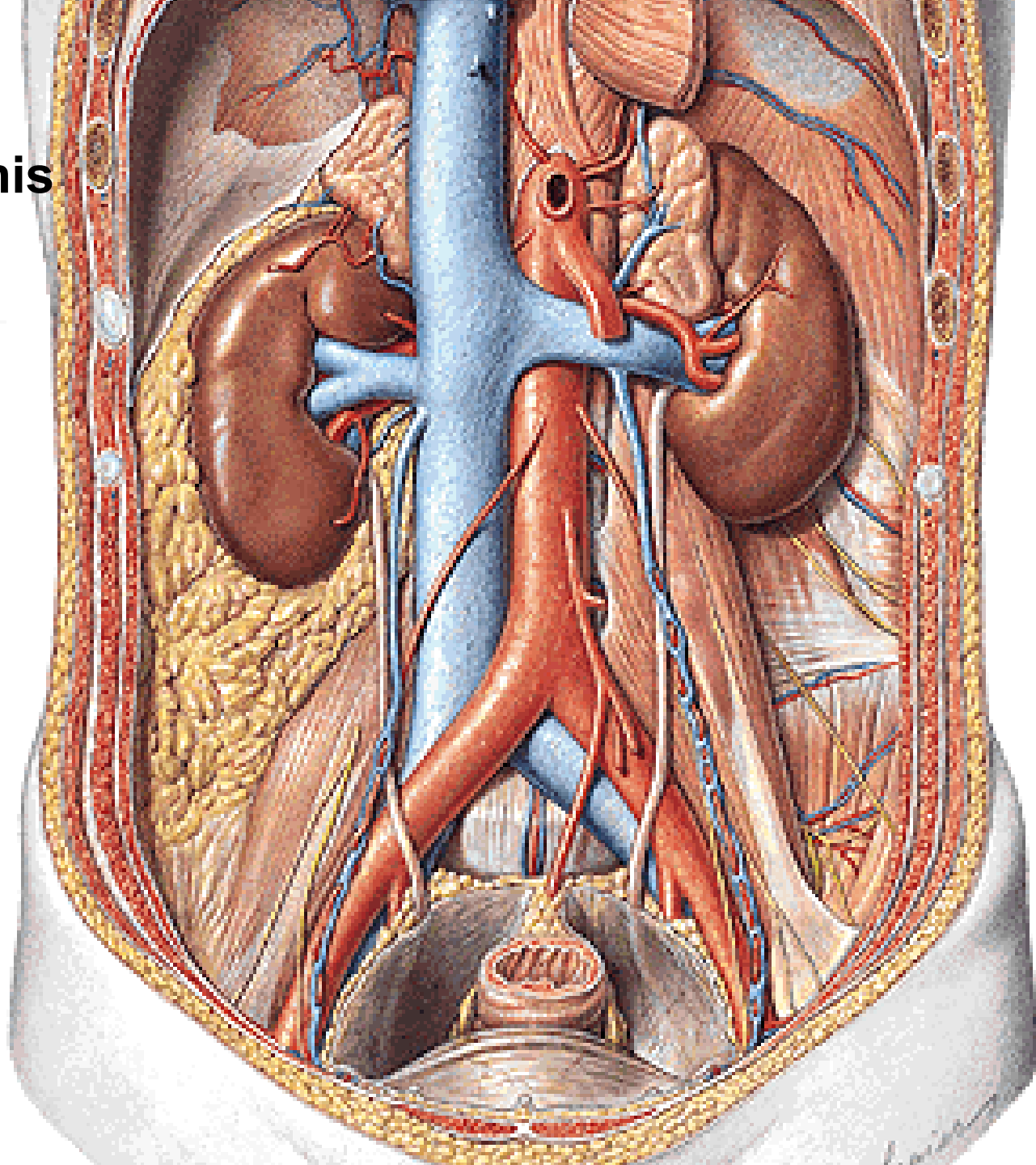
**Lamina visceralis tunicae vaginalis  
(Epiorchium)**



**Tunica albuginea**  
**Mediastinum testis**  
**Septula testis**  
**Lobuli testis**  
**Hilum testis**  
**Tubuli seminiferi contorti**  
**Spermatozoa**  
**Supporting cells of Sertoli**  
**Interstitial cells of Leydig**  
**Tubuli seminiferi recti**  
**Rete testis**  
**Ductuli efferentes testis**



**A. testicularis**  
**Plexus pampiniformis**  
**- vv. testiculares**  
**NII. lumbales**



# EPIDIDYMIS

Caput epididymidis

Corpus epididymidis

Cauda epididymidis

Sinus epididymidis

Lig. epididymidis sup. et inf.

Lig. scrotale

(Gubernaculum testis)

Lobuli epididymidis

Ductus epididymidis

A. testicularis

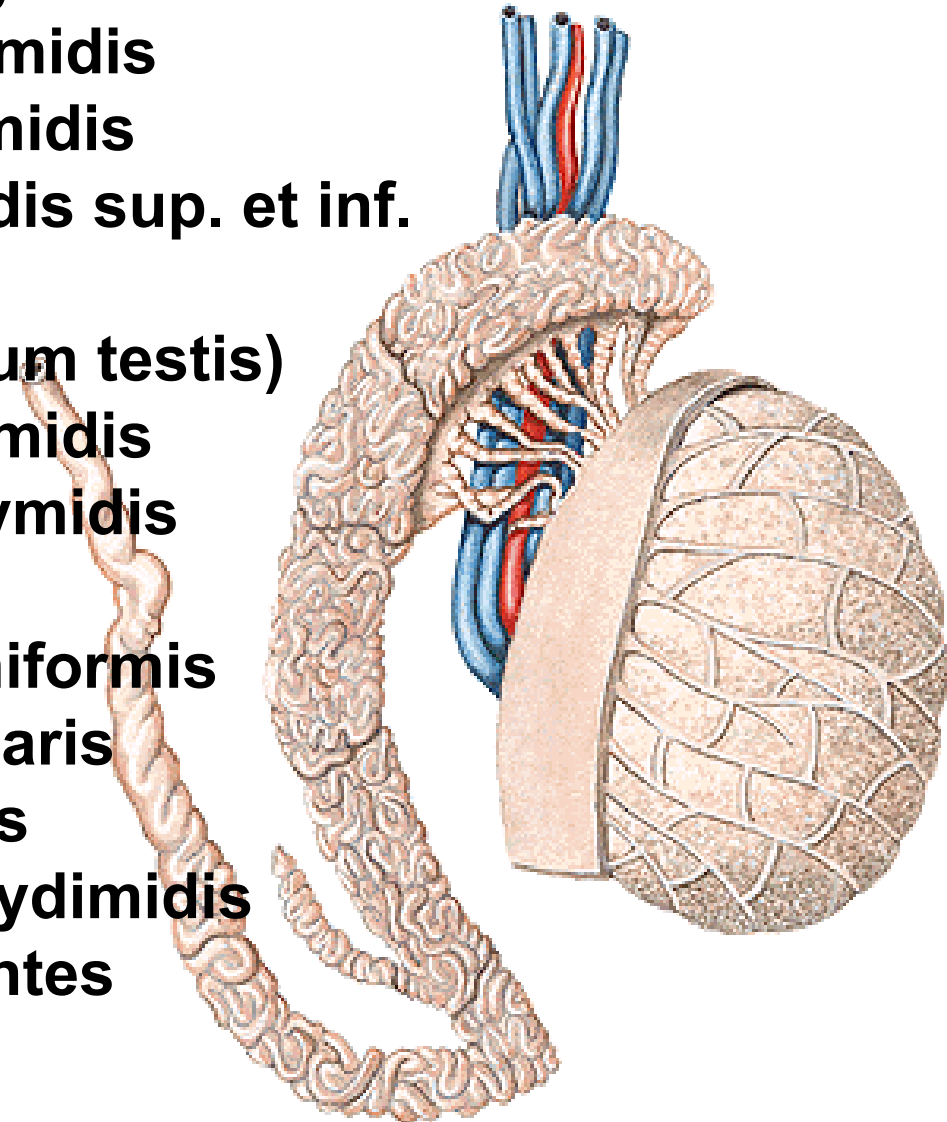
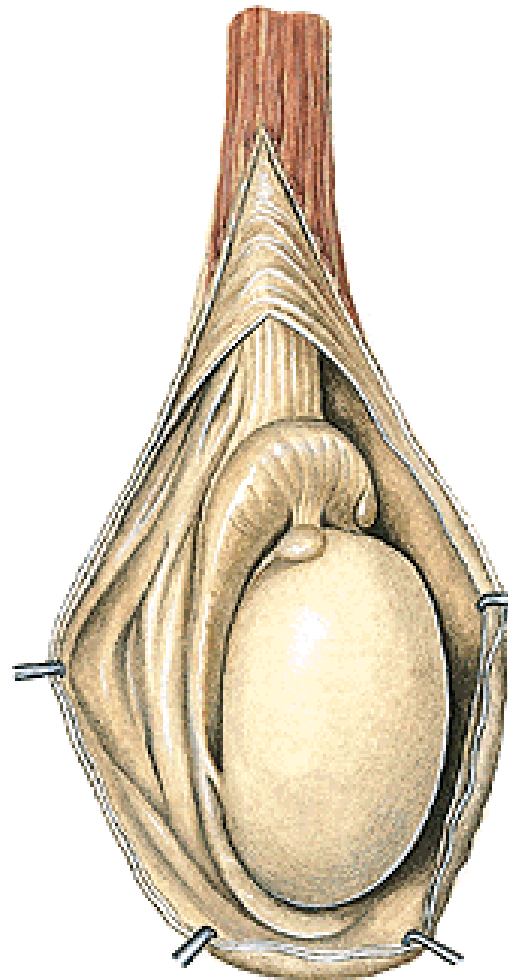
Plexus pampiniformis

Plexus testicularis

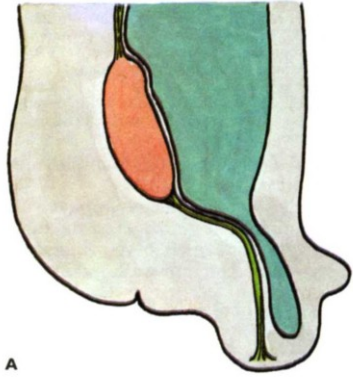
Appendix testis

Appendix epididymidis

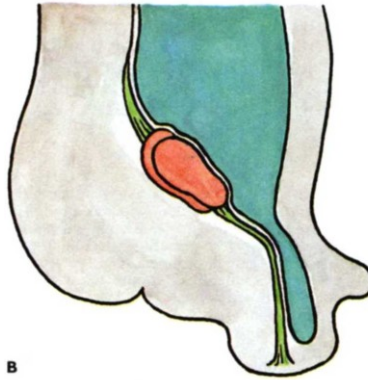
Ductuli aberrantes



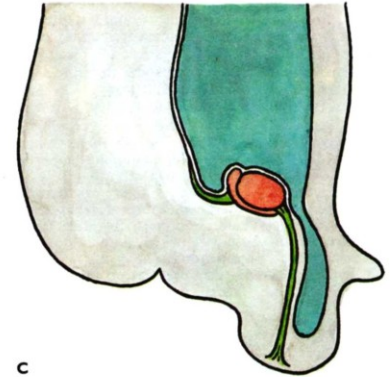
# DESCENSUS TESTIUM



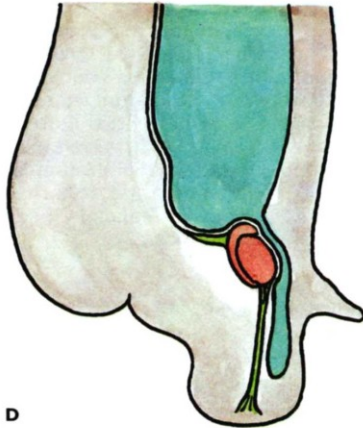
A



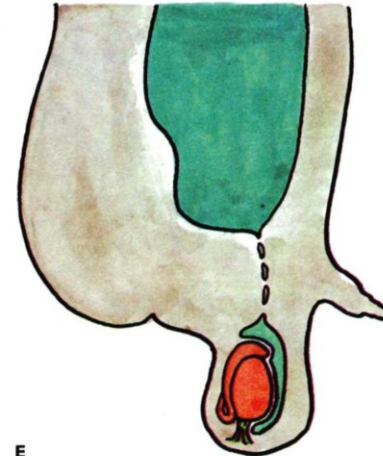
B



C



D



E

**Retentio testis (cryptorchidism)**



# **DUCTUS DEFERENS (VAS DEFERENS)**

**Pars epididymica**

**Pars funicularis**

**Pars inguinalis**

**Pars pelvina**

**Ampulla ductus deferentis - diverticula ampullae**

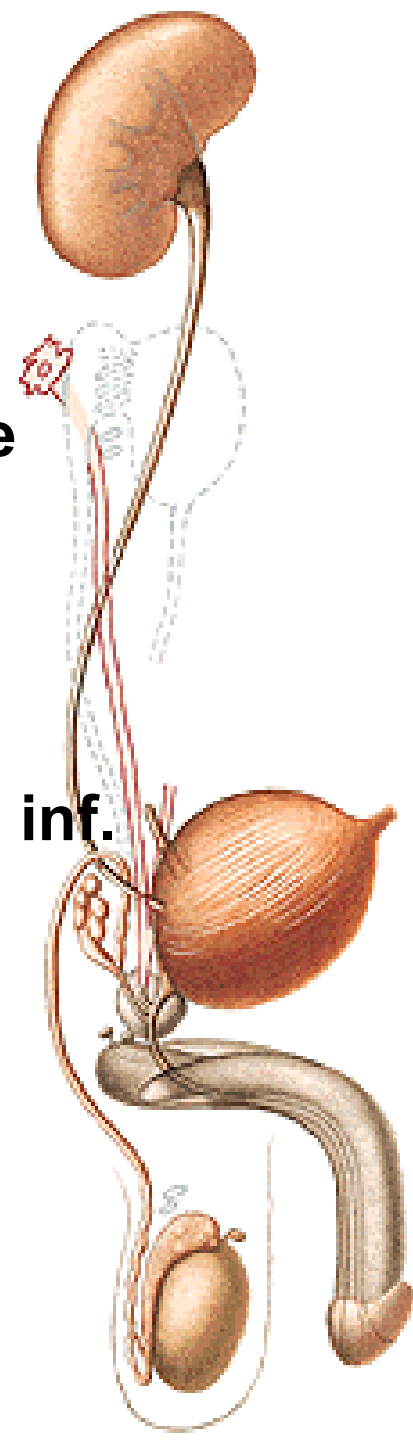
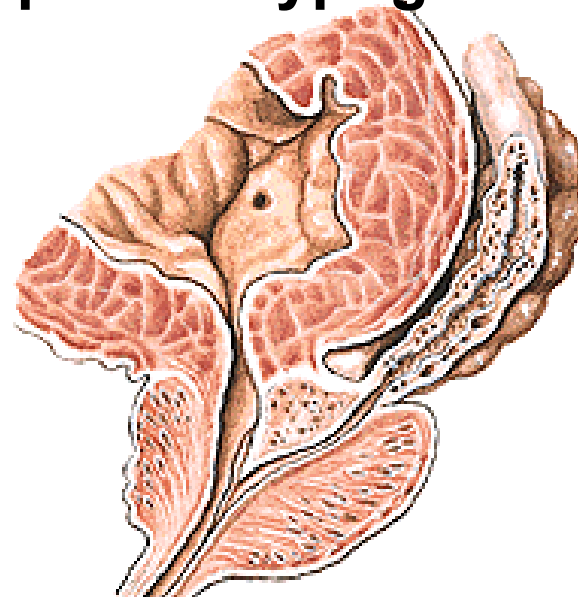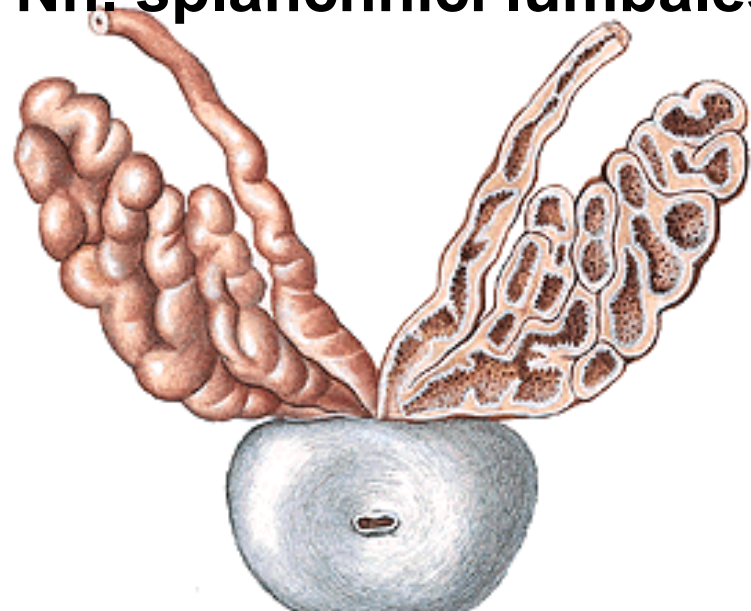
**Ductus ejaculatorius**

**A. ductus deferentis**

**Plexus pampiniformis et vesicalis**

**Nll. iliaci int. et ext.**

**Nn. splanchnici lumbales, plexus hypogastricus inf.**



# **FUNICULUS SPERMATICUS: Ductus deferens**

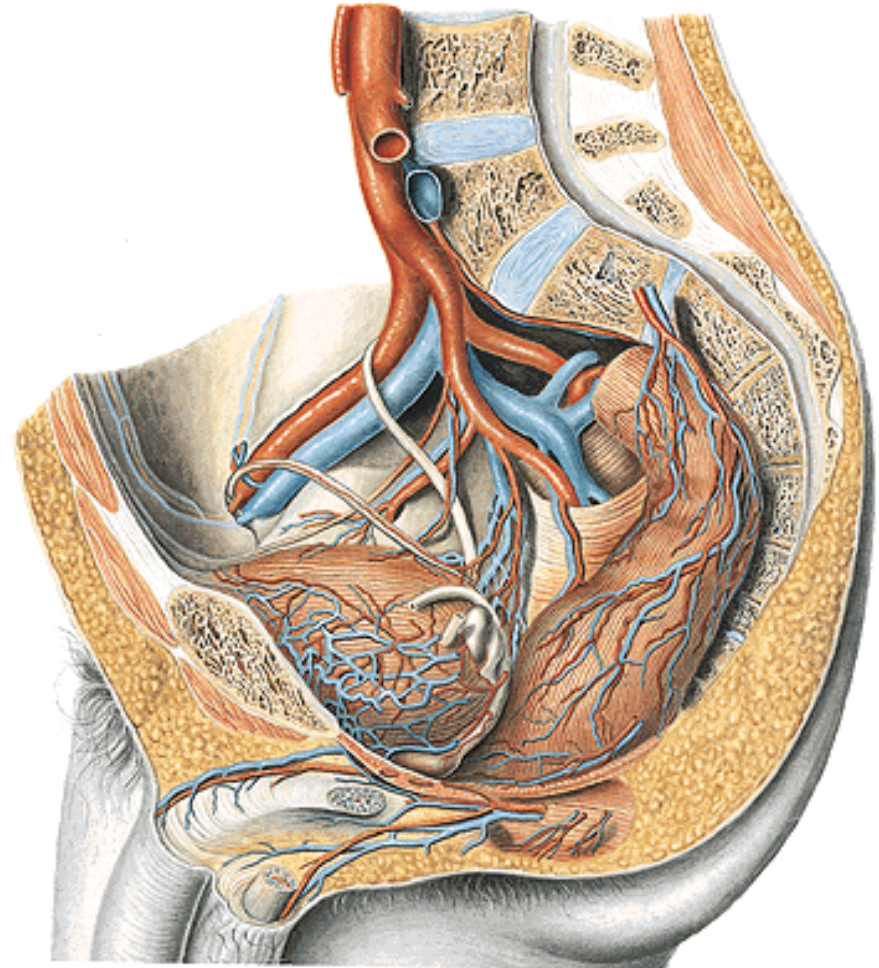
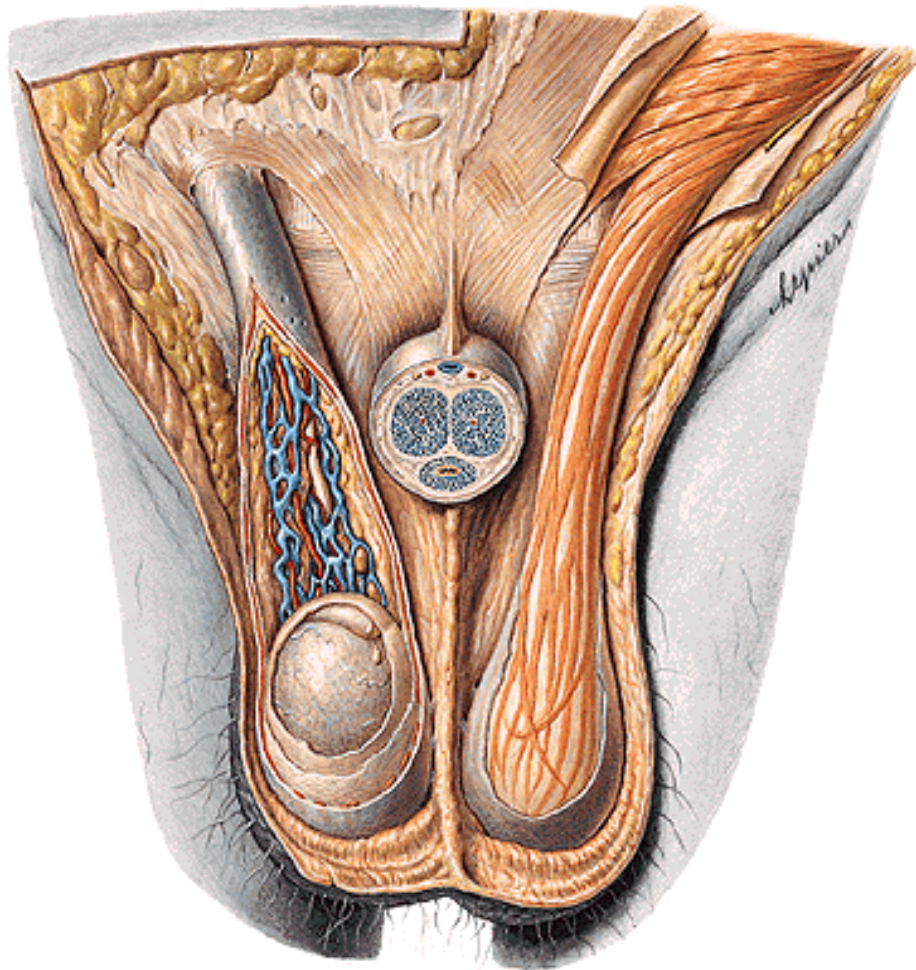
**A. ductus deferentis**

**A. testicularis**

**Plexus pampiniformis**

**Plexus testicularis**

**Plexus deferentialis**

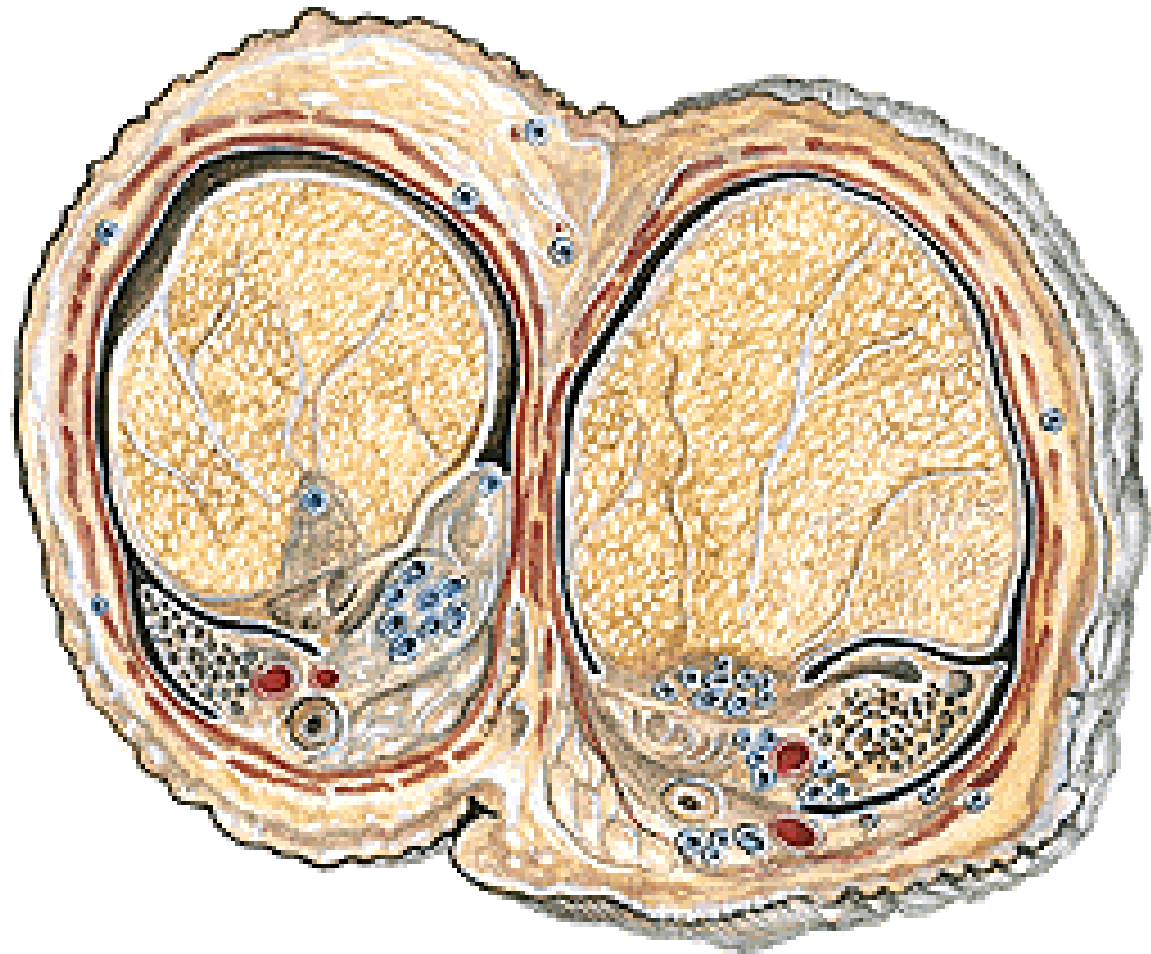


# COVERINGS OF THE TESTIS, EPIDIDYMIS AND SPERMATIC CORD

**Epidiorchium (Lamina visceralis tunicae vaginalis)**

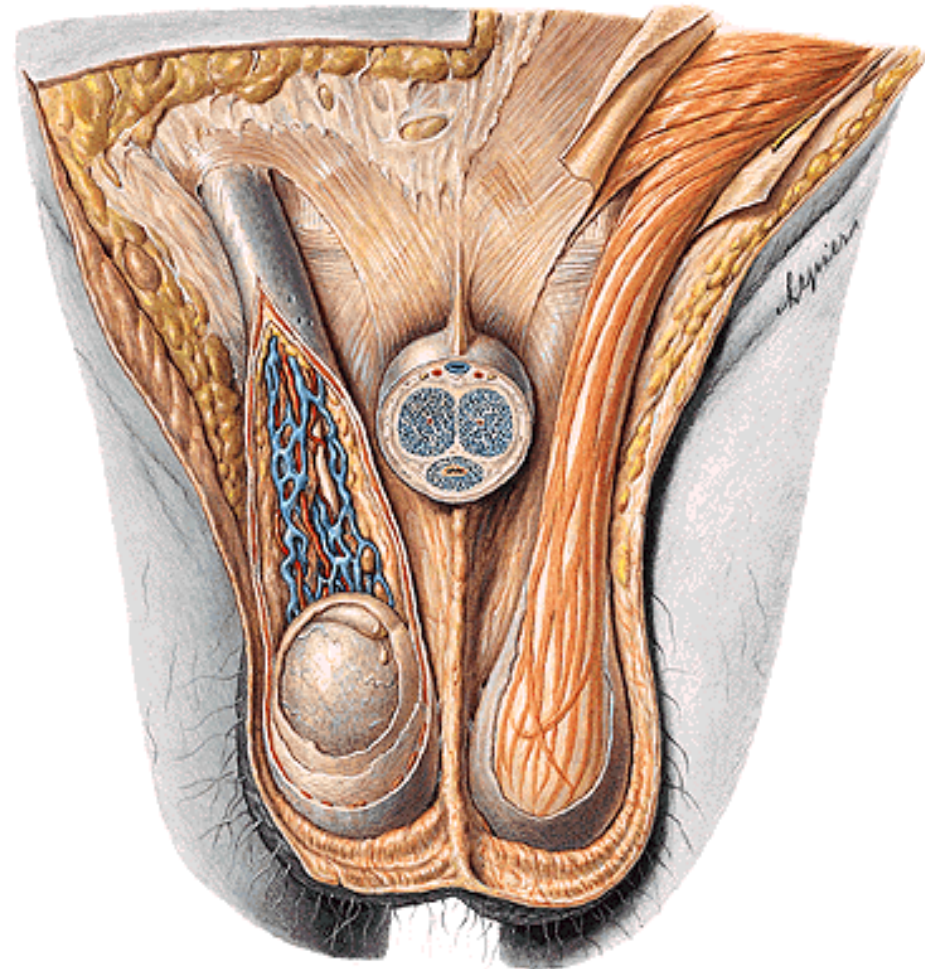
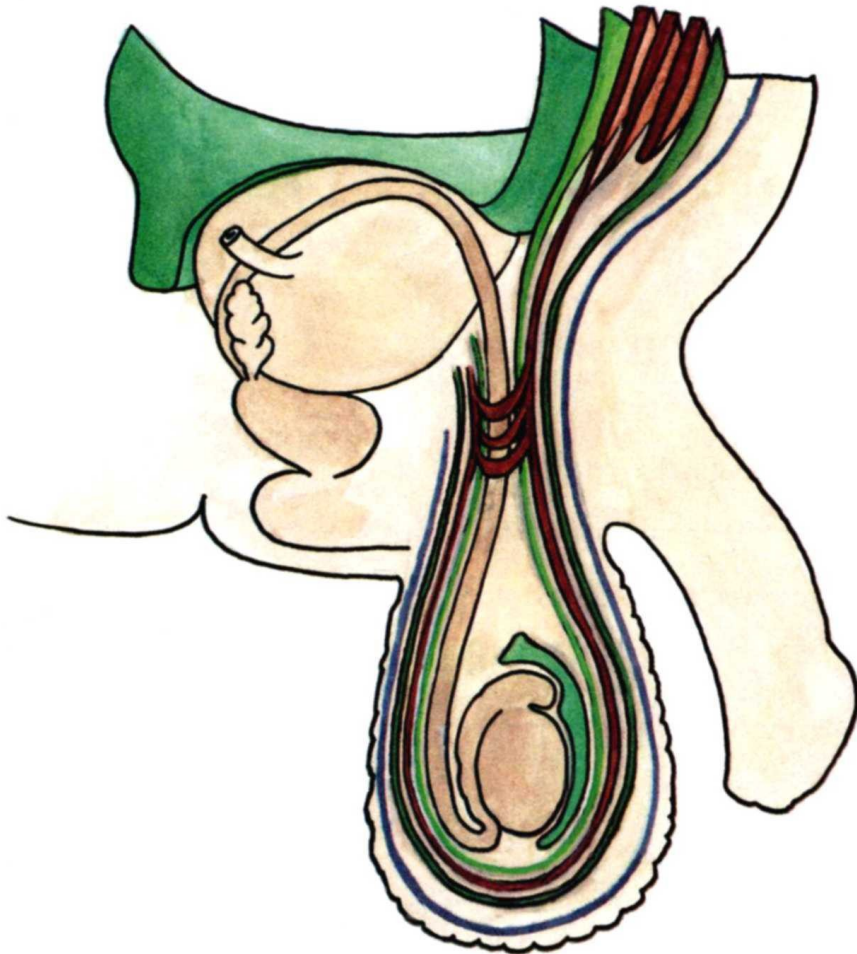
**Periorchium (Lamina parietalis tunicae vaginalis)**

**Cavum serosum scroti**





**Fascia spermatica interna (Fascia transversalis)**  
**Fascia cremasterica - M. cremaster**  
**(M. obliquus abdominis internus, M. transversus abdominis)**  
**Fascia spermatica externa (Fascia abdominis superficialis)**



# CANALIS INGUINALIS

*Posterior wall:*

**Fascia transversalis:**

**Falx inguinalis**

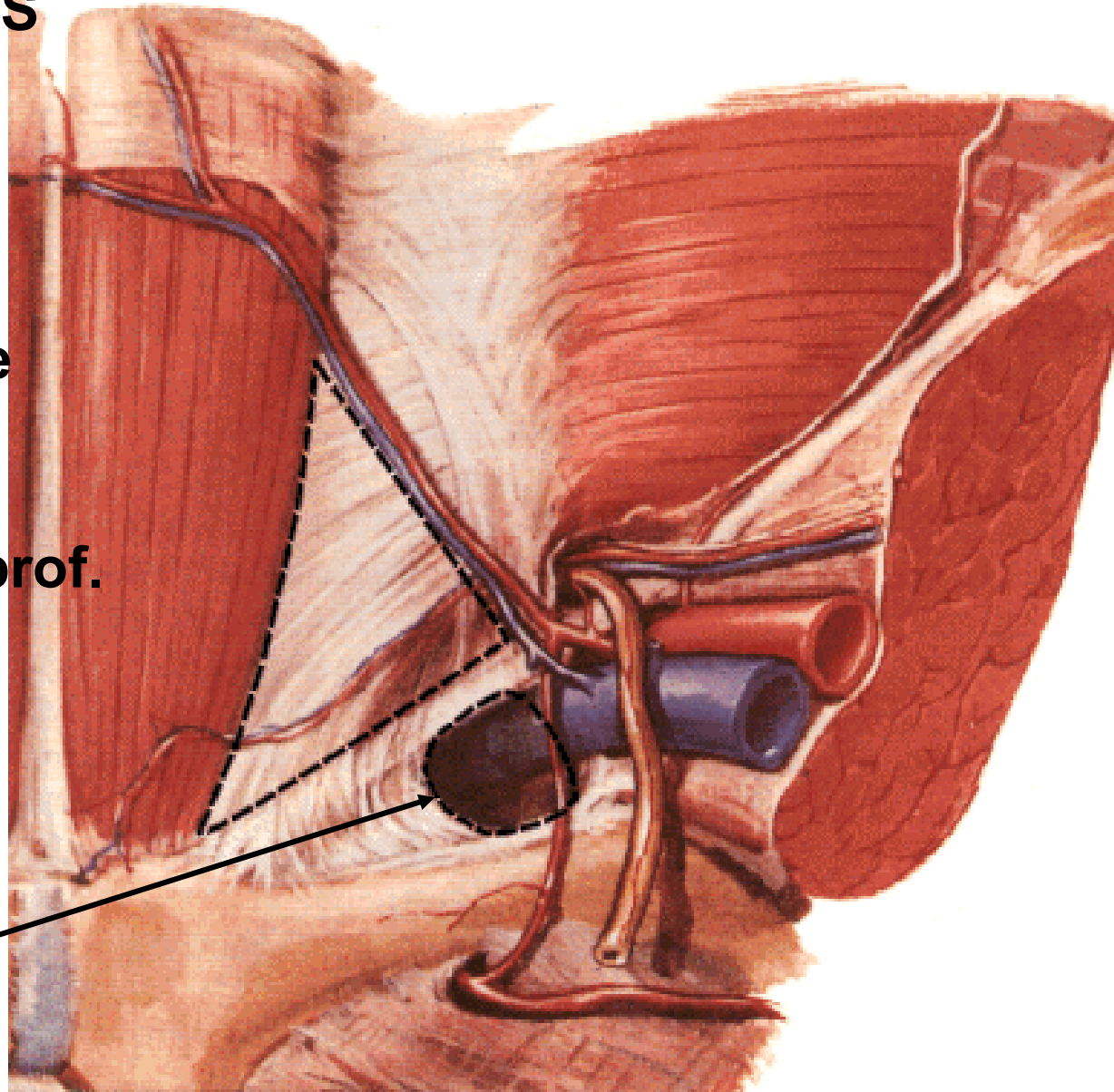
**Trigonum inguinale  
(Hesselbachi)**

**Lig. interfoveolare**

**Anulus inguinalis prof.**

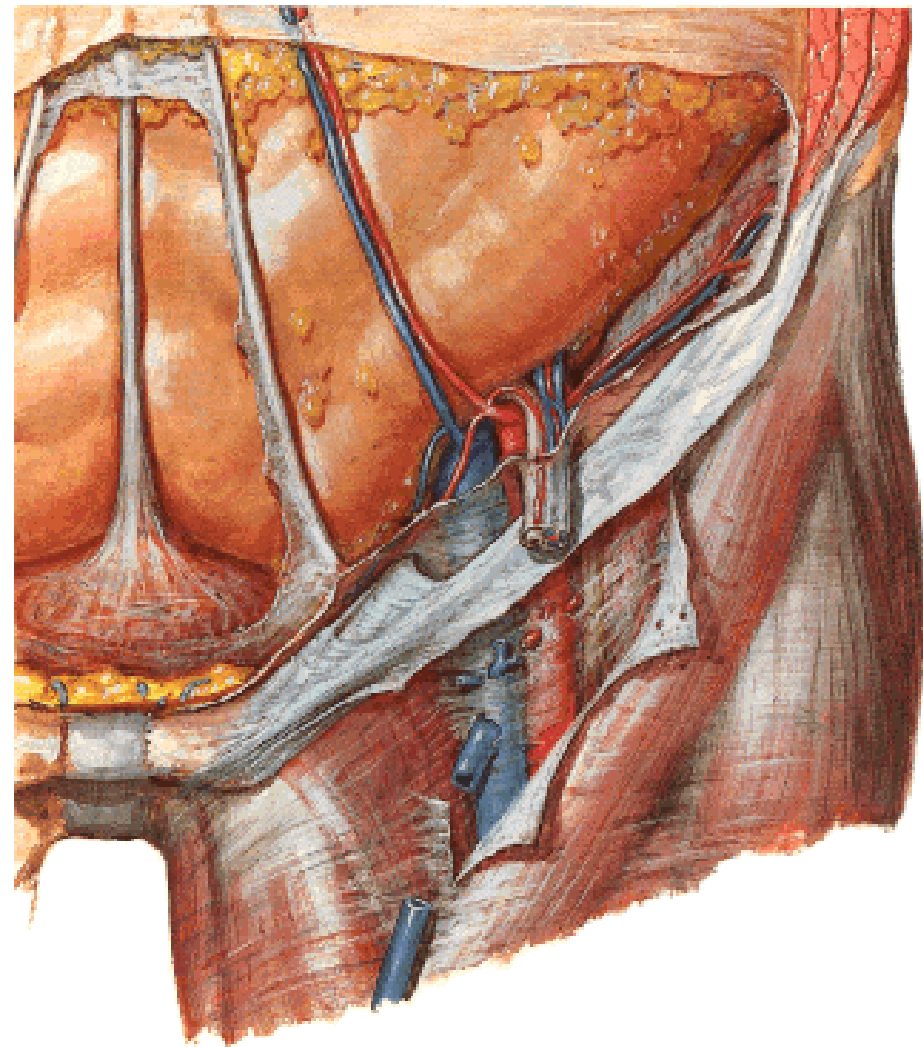
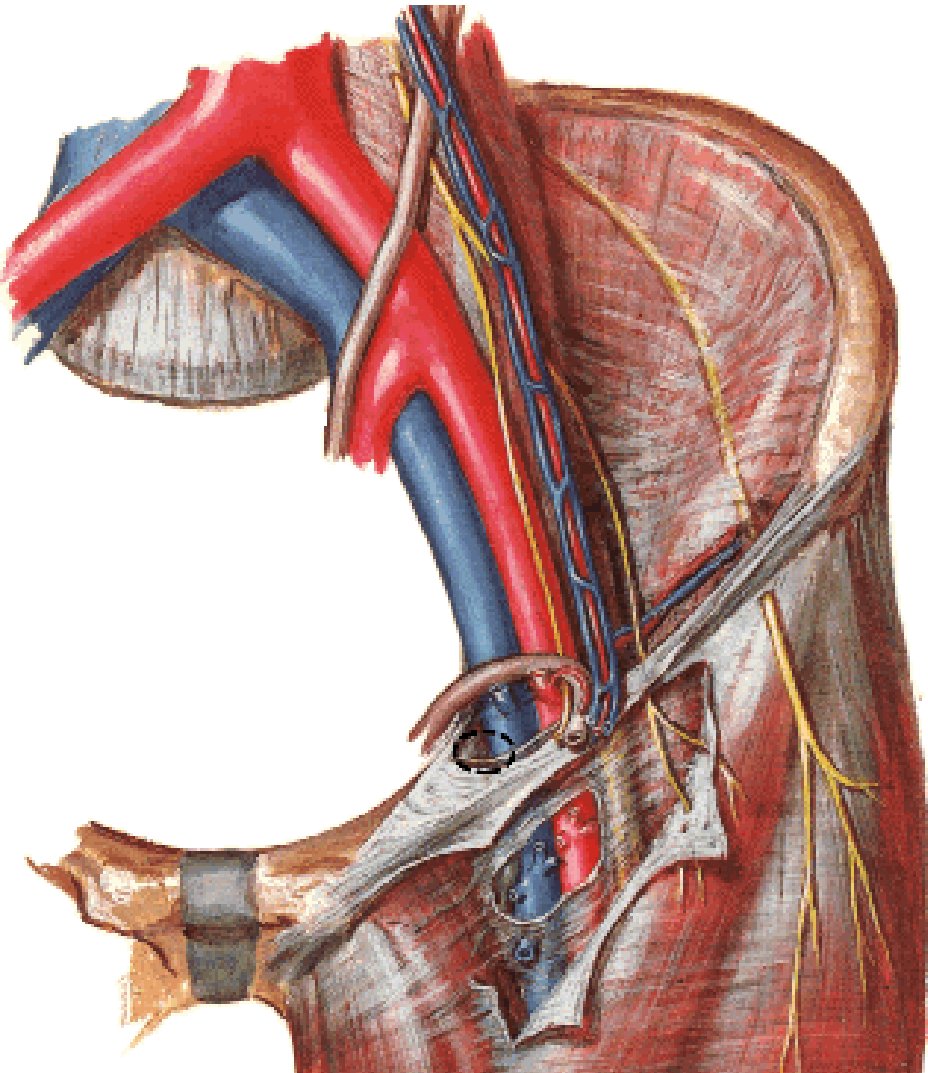
**Tractus iliopubicus**

**Anulus femoralis**



# CANALIS INGUINALIS

*Inferior wall:*  
**Lig. inguinale**



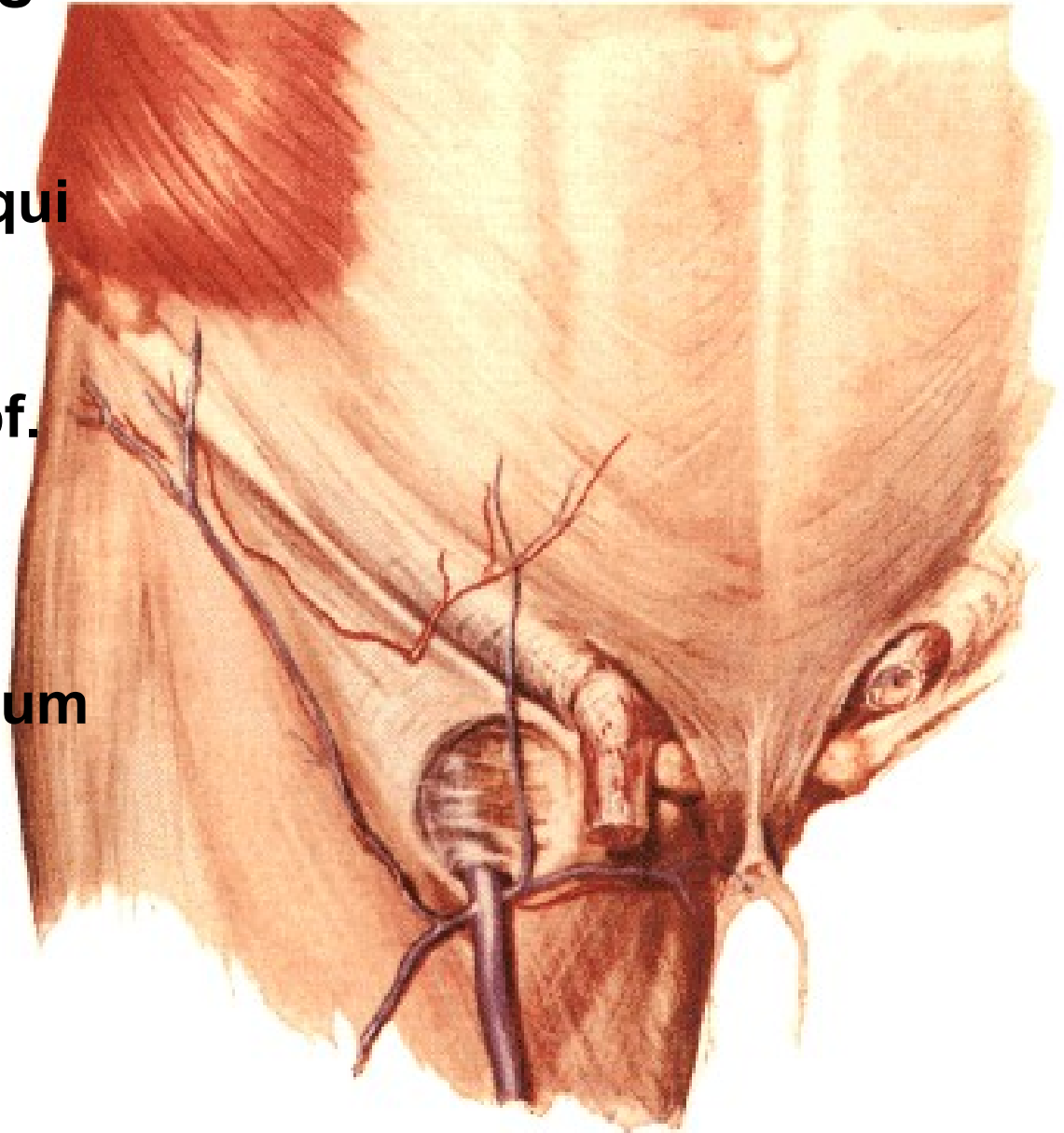
# CANALIS INGUINALIS

*Anterior wall:*

**Aponeurosis m. obliqui  
externi abdominis**

**Anulus inguinalis spf.**

- **crus mediale**
- **crus laterale**
- **fibrae intercrurales**
- **lig. inguinale reflexum**







**Plica umbilicalis mediana**  
- lig. umbilicale medianum

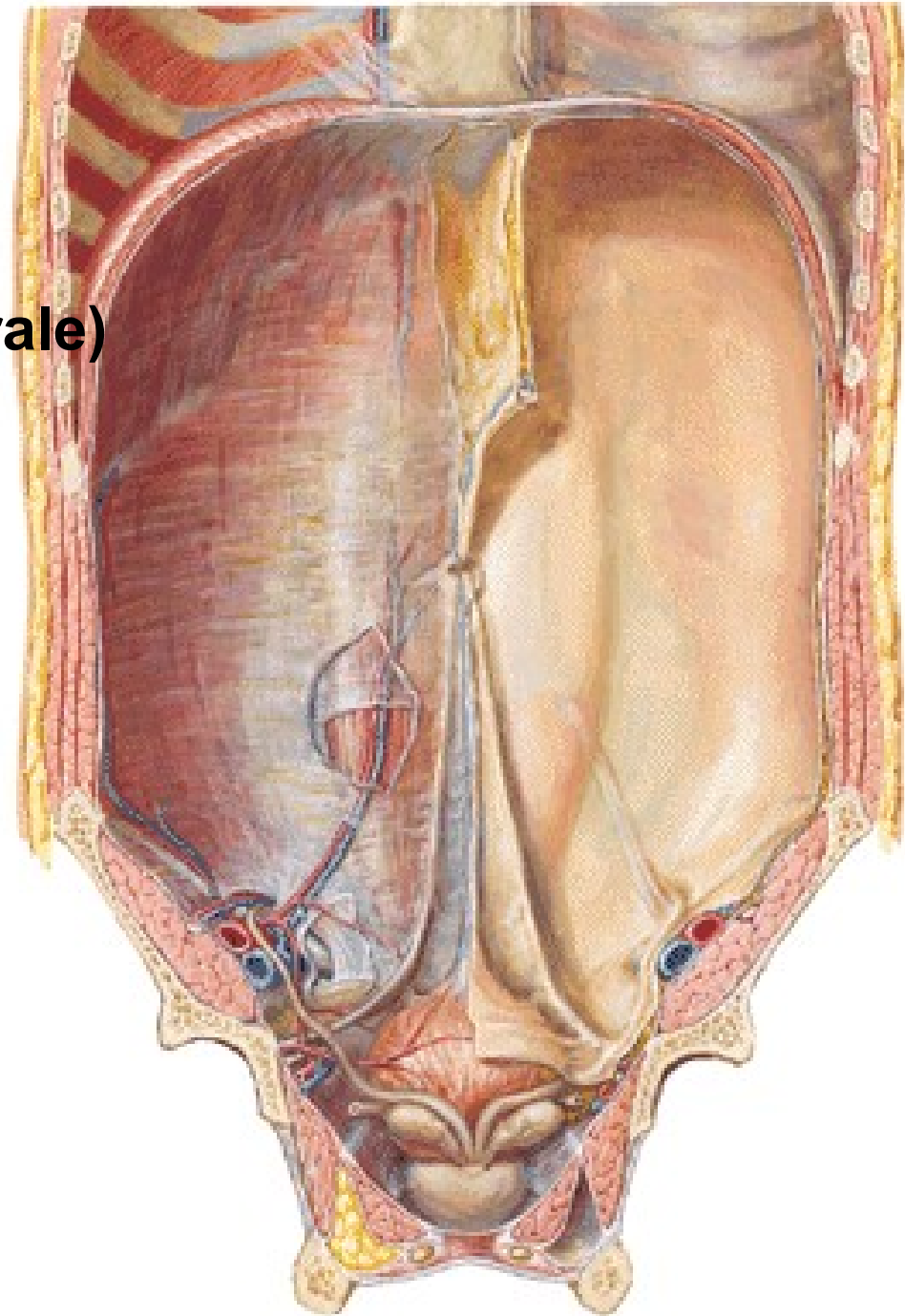
**Plica umbilicalis medialis**  
- lig. umbilicale mediale (laterale)  
(pars occlusa a. umbilicalis)

**Plica umbilicalis lateralis**  
- vasa epigastrica inf.

**Fossa supravesicalis**

**Fossa inguinalis medialis**  
- direct inguinal hernia

**Fossa inguinalis lateralis**  
- indirect inguinal hernia



# **VESICULAE SEMINALES**

**Ductus excretorius**

**Ductus ejaculatorius**

# **PROSTATATA**

**Basis**

**Apex**

**Facies anterior**

**Facies posterior**

**Facies inferolaterales**

**Lobus medius**

**Lobus dexter et sinister**

**Isthmus**

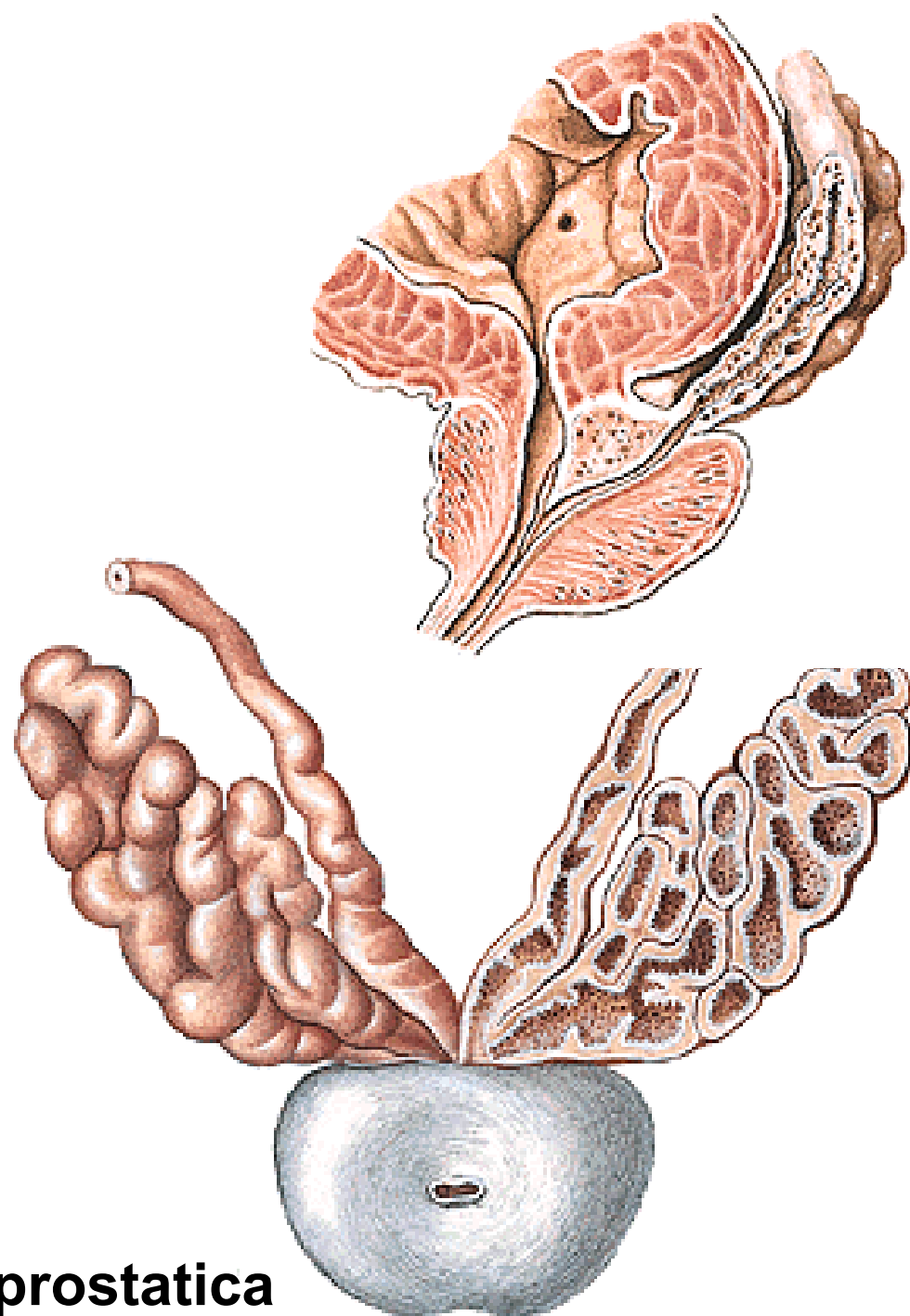
**Zona periurethralis**

**Zona interna**

**Zona externa**

**Ductuli prostatici**

**Capsula propria, fascia periprostatica**



# **GLANDULAE BULBOURETHRALES**

**Ductus gl. bulbourethralis**

## **URETHRA MASCULINA**

**Ostium urethrae internum**

**Ostium urethrae externum**

**Pars intramuralis – M. sphincter vesicae**

**Pars prostatica**

**Pars membranacea – M. sphincter urethrae**

**Pars spongiosa – Ampulla urethrae**

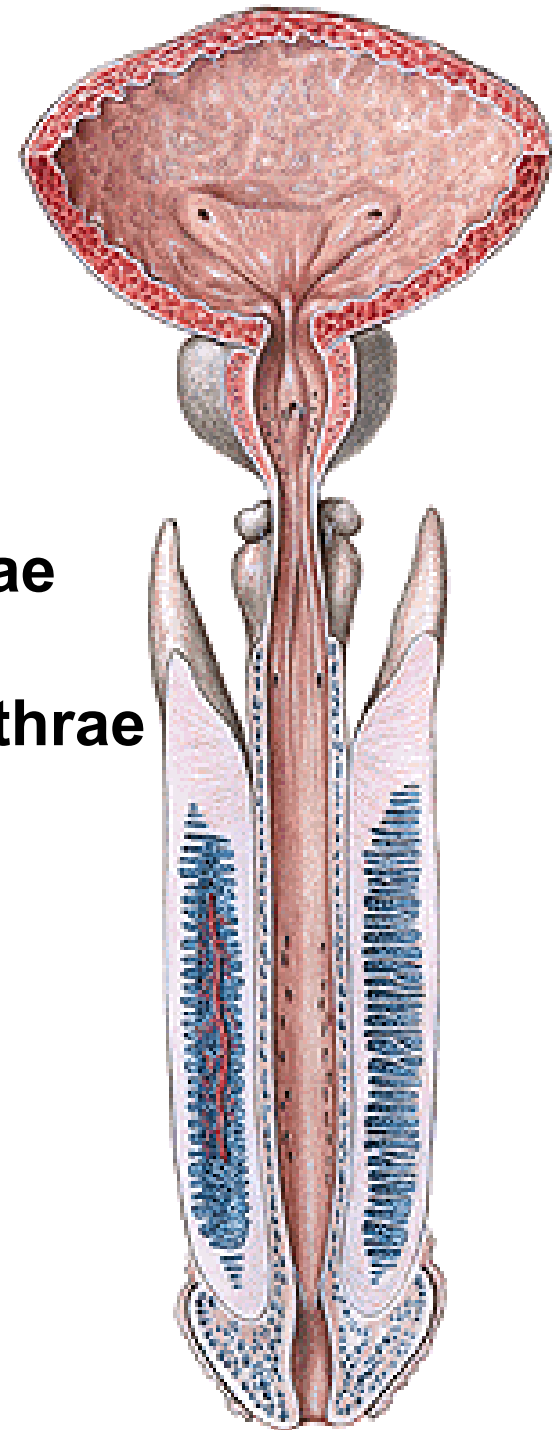
**Corpus spongiosum penis**

**Fossa navicularis**

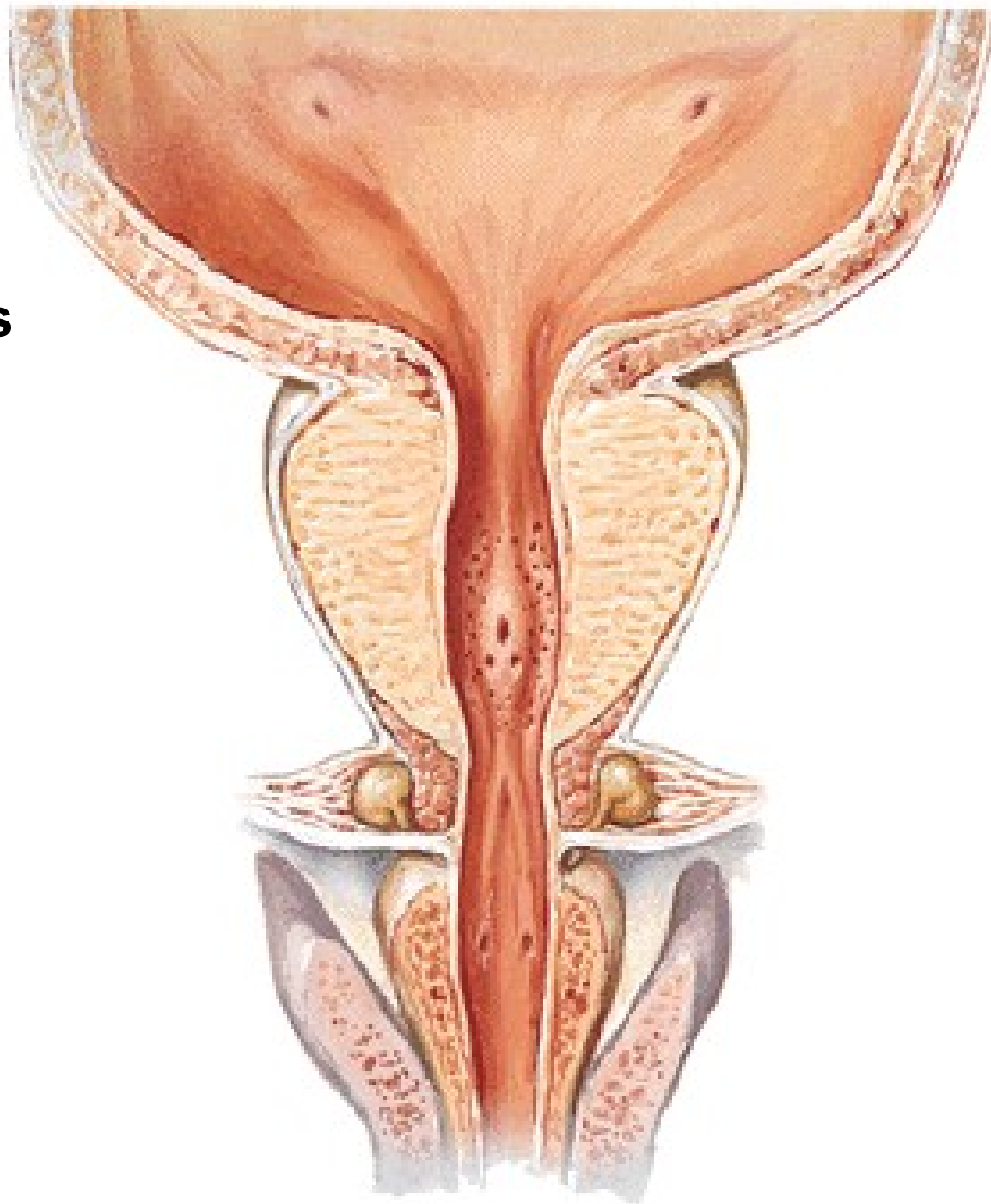
**Valvula fossae navicularis**

**Glandulae urethrales**

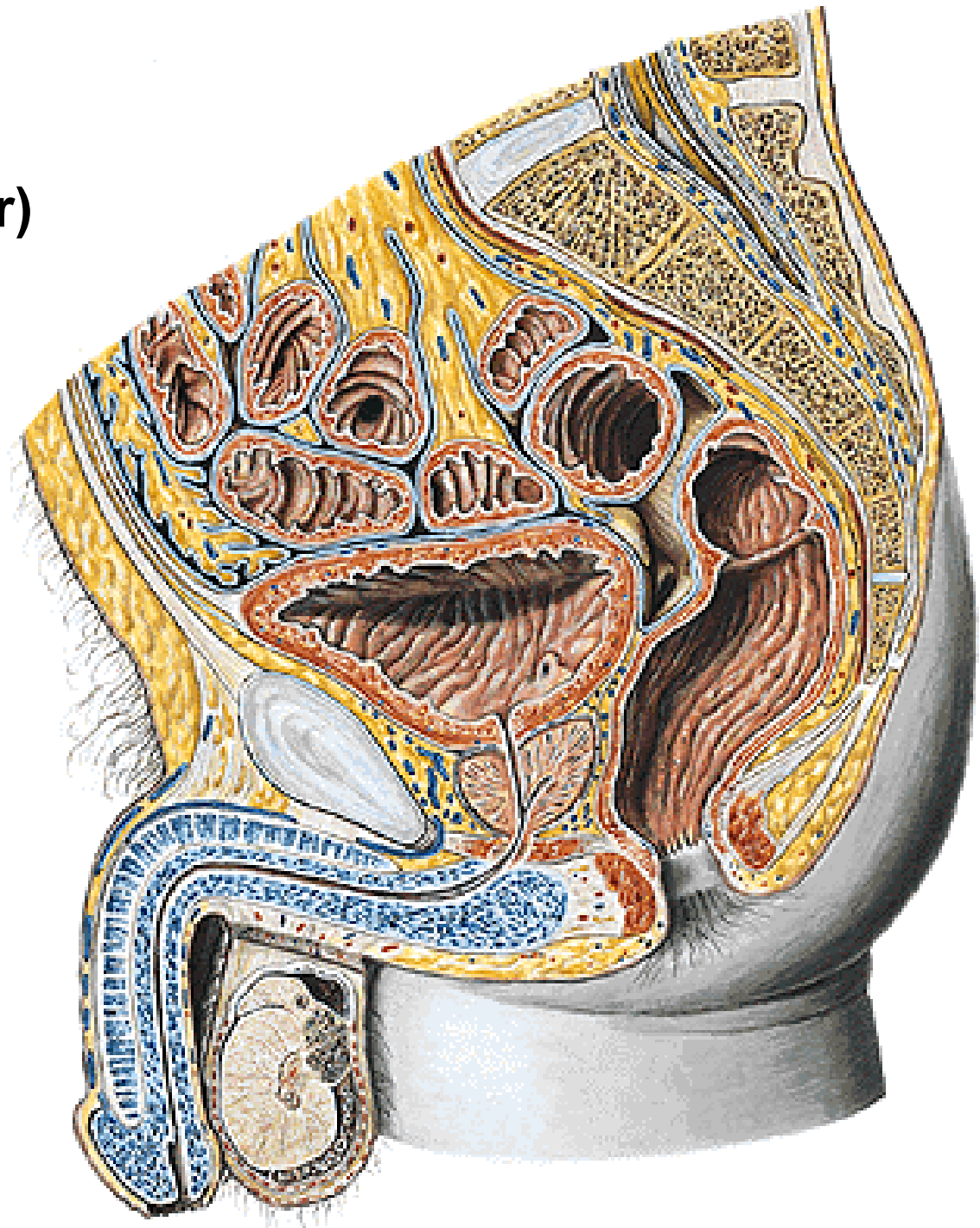
**Lacunae urethrales**



**Pars prostatica:**  
**Crista urethralis**  
**Colliculus seminalis**  
**Utriculus prostaticus**  
**Ductus ejaculatorii**  
**Sinus prostatici**



**Curvatura subpubica**  
**Curvatura praepubica**  
**Urethra mobilis (anterior)**  
**Urethra fixa (posterior)**



# EXTERNAL GENITAL ORGANS

**PENIS: Radix**

**Corpus**

**Glans**

**Praeputium**

**SCROTUM**



# **PENIS**

**Glans penis**

**Collum glandis**

**Corona glandis**

**Dorsum penis**

**Facies urethralis**

**Raphe penis**

**Praeputium**

**Ostium praeputii**

**Glandulae praeputiales**

**Smegma praeputii**

**Frenulum praeputii**

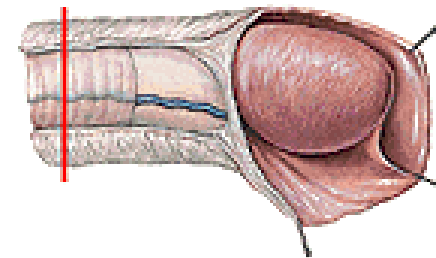
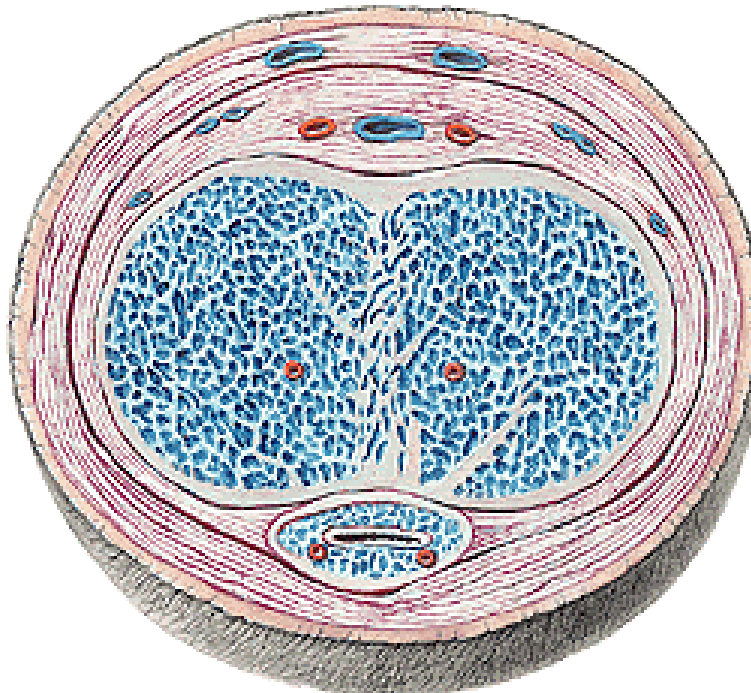
**Corpus cavernosum**

**Corpus spongiosum**

**Tunica albuginea**

**Trabeculae**

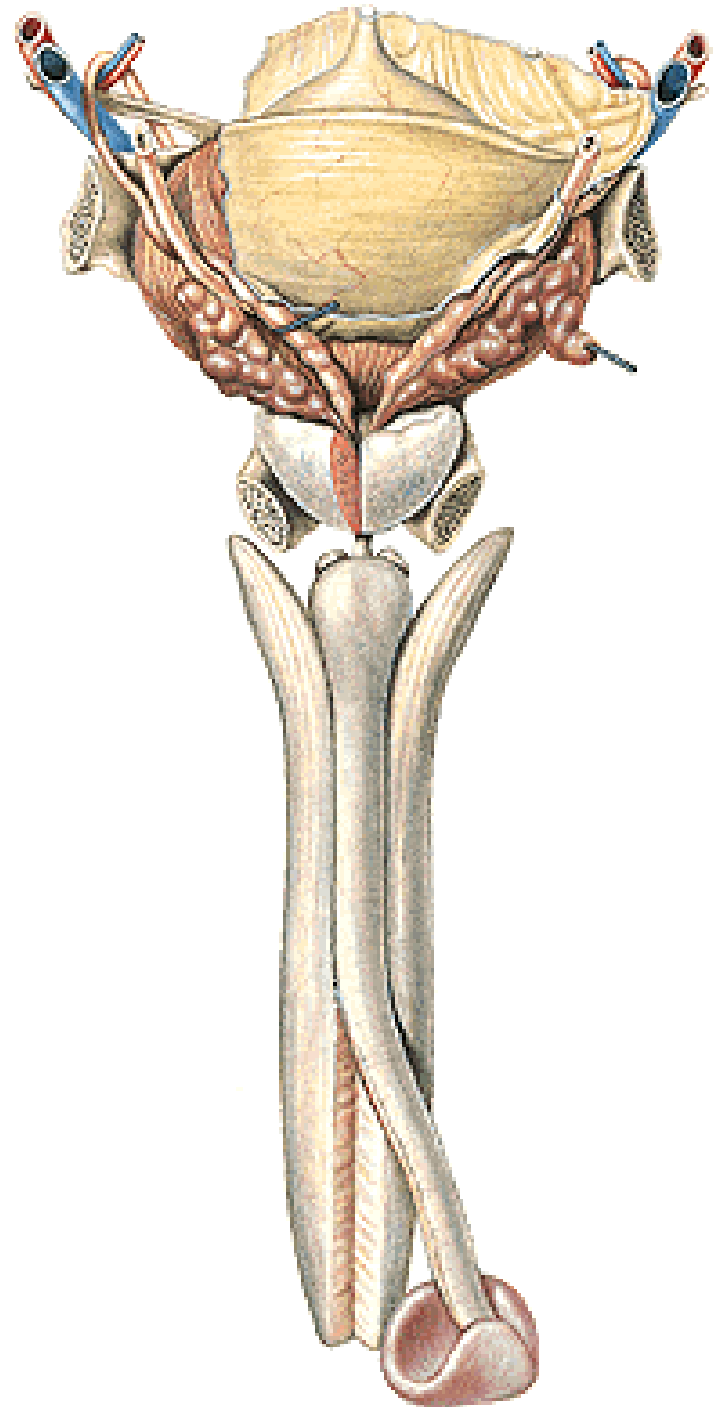
**Cavernae**



**Corpus cavernosum**  
- crura penis - crista phallica

**Corpus spongiosum**  
- bulbus penis

**Glandulae bulbourethrales**





**COVERINGS OF PENIS:**

**Fascia penis profunda**

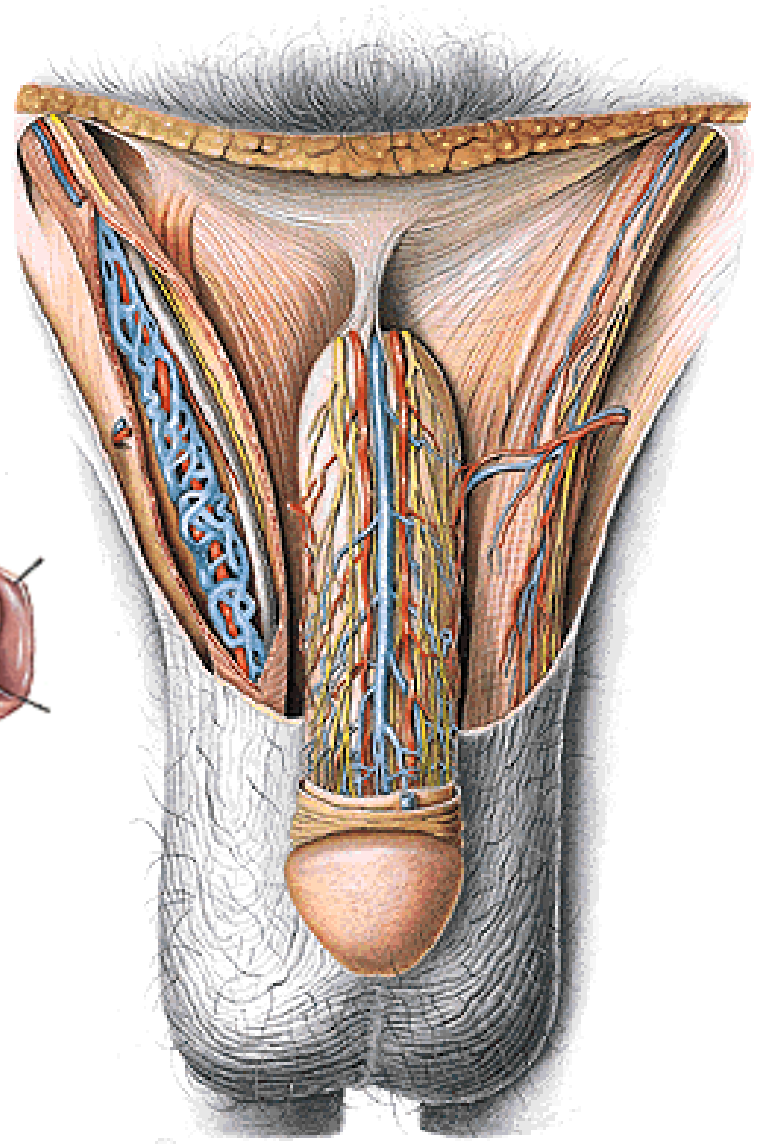
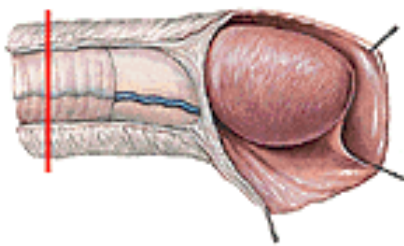
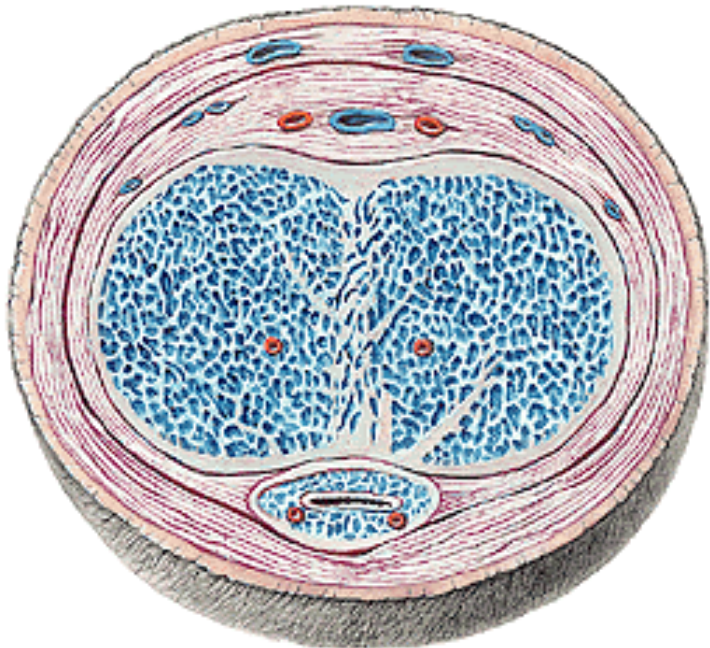
**(Aa., Nn. dorsales penis, V. dorsalis penis profunda)**

**Fascia penis superficialis**

**(Vv. dorsales penis spf.)**

**Lig. fundiforme penis**

**Lig suspensorium penis**



# SCROTUM

Raphe scroti

Pubes

Tunica dartos scroti

Septum scroti

Cavum scroti

A. pudenda ext.

A. pudenda int.

V. femoralis

V. pudenda int.

Nll. inguinales spf.

N. genitofemoralis

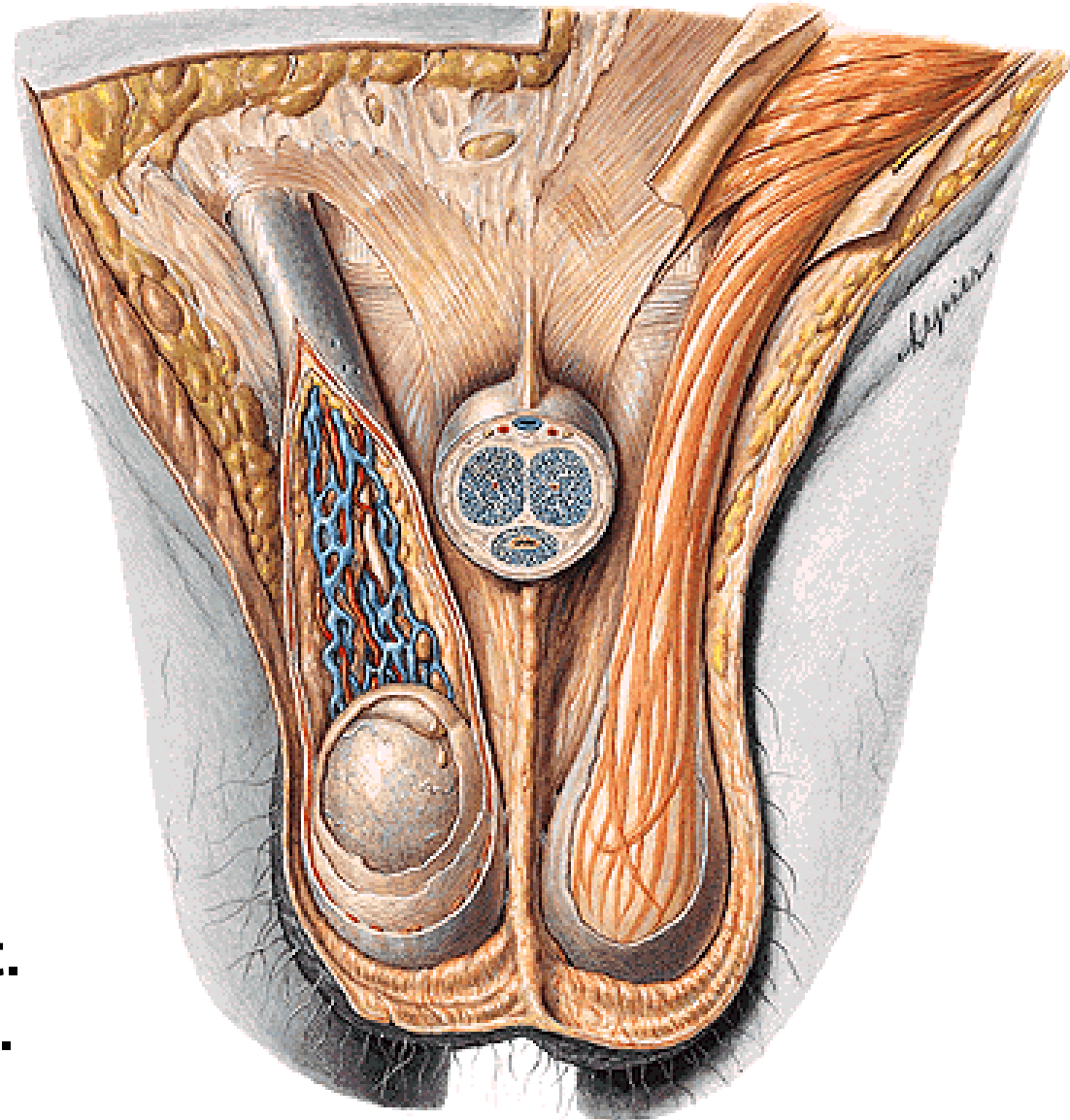
N. ilioinguinalis

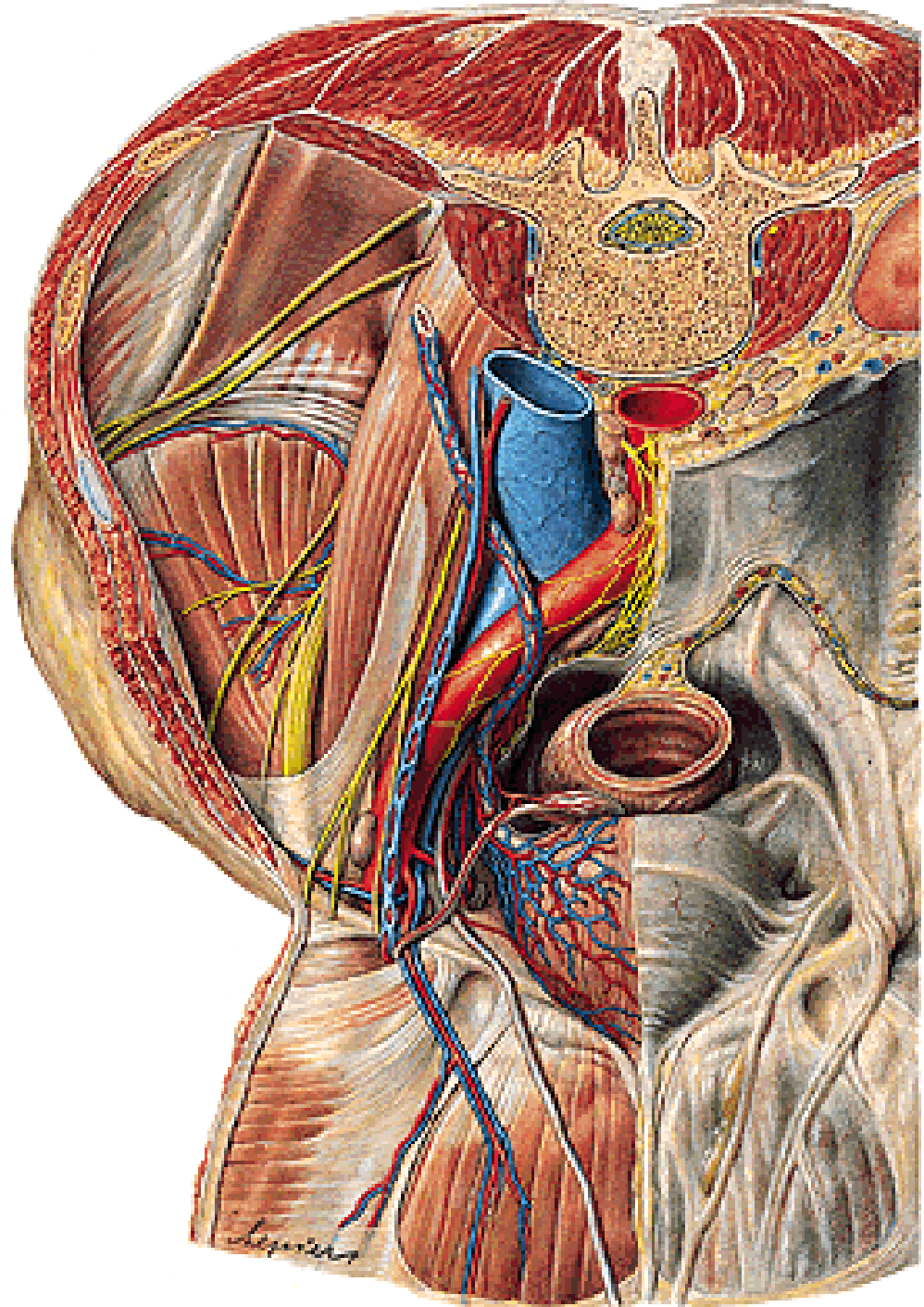
N. pudendus

N. cutaneus femoris post.

Plexus hypogastricus inf.

# Hydrocele, varicocele





# **ANATOMICAL BASIS OF ERECTION**

## **Parasympathetic stimulation**

- relaxation of smooth muscle in cavernae and aa. helicinae, compression of venous plexuses by bulbospongiosus and ischiocavernosus muscles → erection**

## **Sympathetic stimulation**

- contraction of smooth muscle of aa. helicinae, relaxation of bulbospongiosus and ischiocavernosus muscles, drainage of blood into v. dorsalis penis prof. → detumescence**

# **EJACULATION OF THE SEMEN**

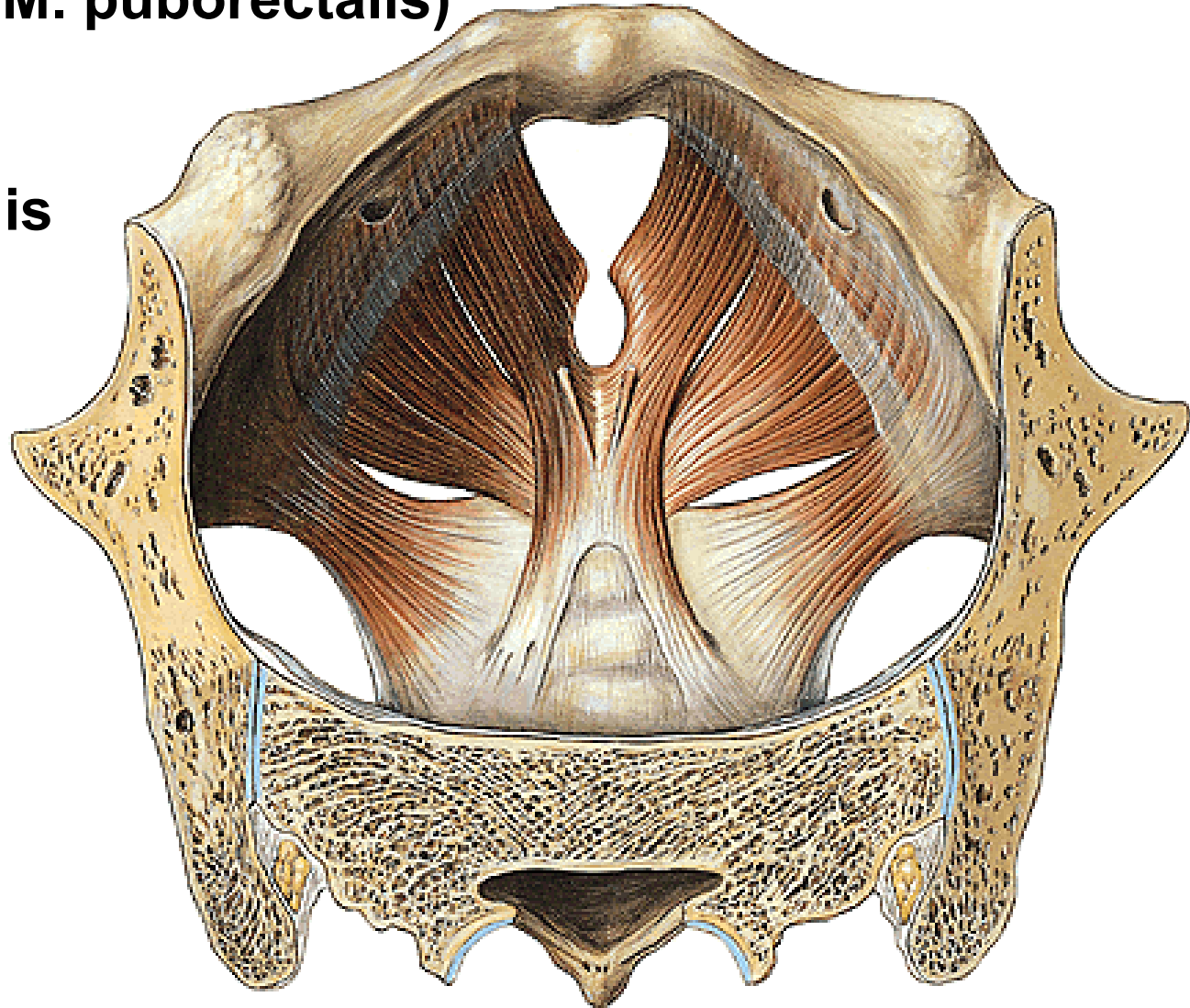
- 1. Emission of sperms and genital glands secretion  
- sympathetic stimulation**
- 2. Expulsion of the semen from the spongy urethra (ejaculation) – parasympathetic stimulation**

# DIAPHRAGMA PELVIS

**M. levator ani – pars iliaca (M. iliococcygeus)**  
- **pars pubica (M. pubococcygeus)**  
(- **M. puborectalis**)

**M. coccygeus**

**Hiatus urogenitalis**



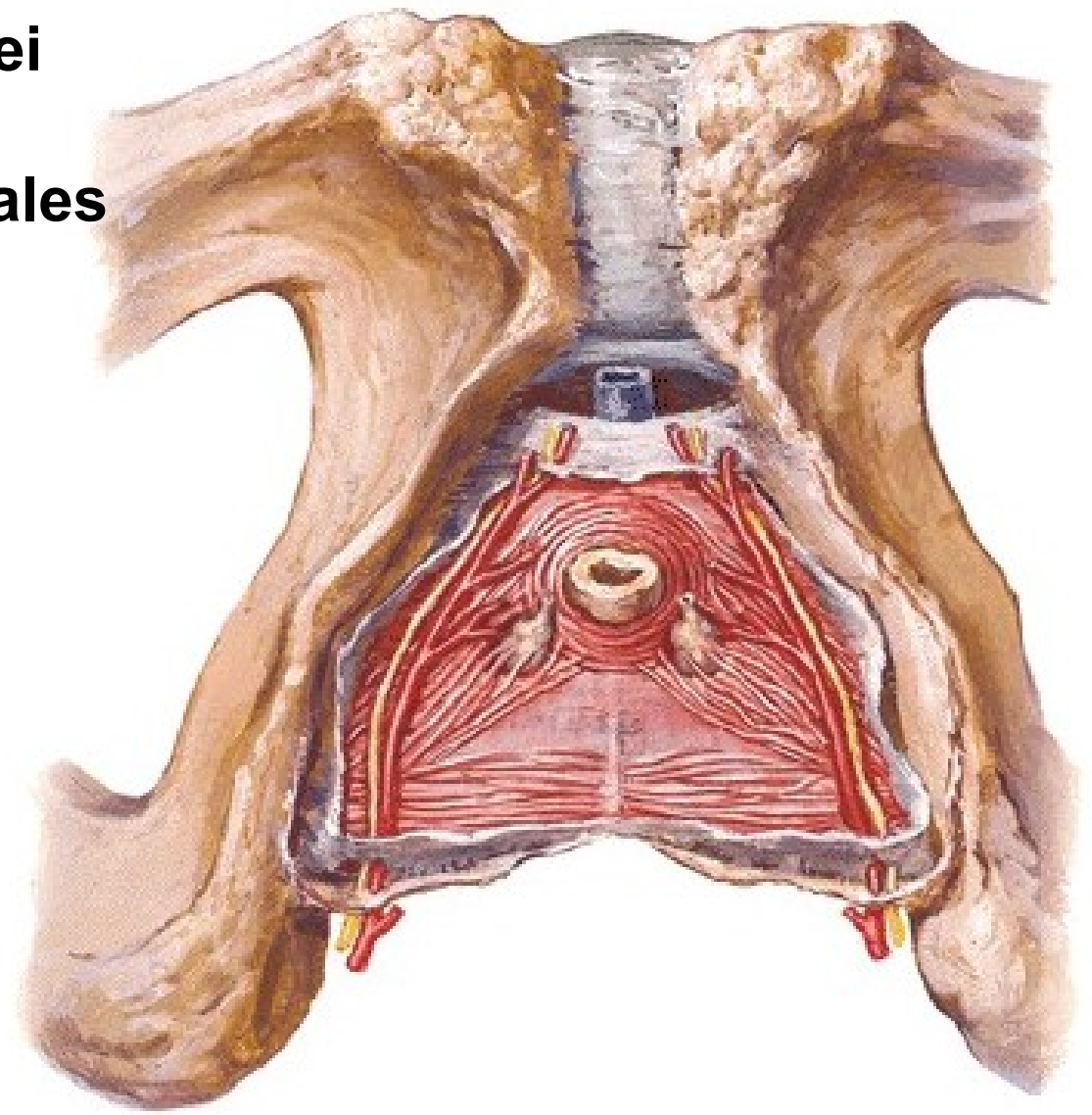
# DIAPHRAGMA UROGENITALE

M. transversus perinei profundus – Centrum perineale

M. sphincter urethrae

Lig. transversum perinei

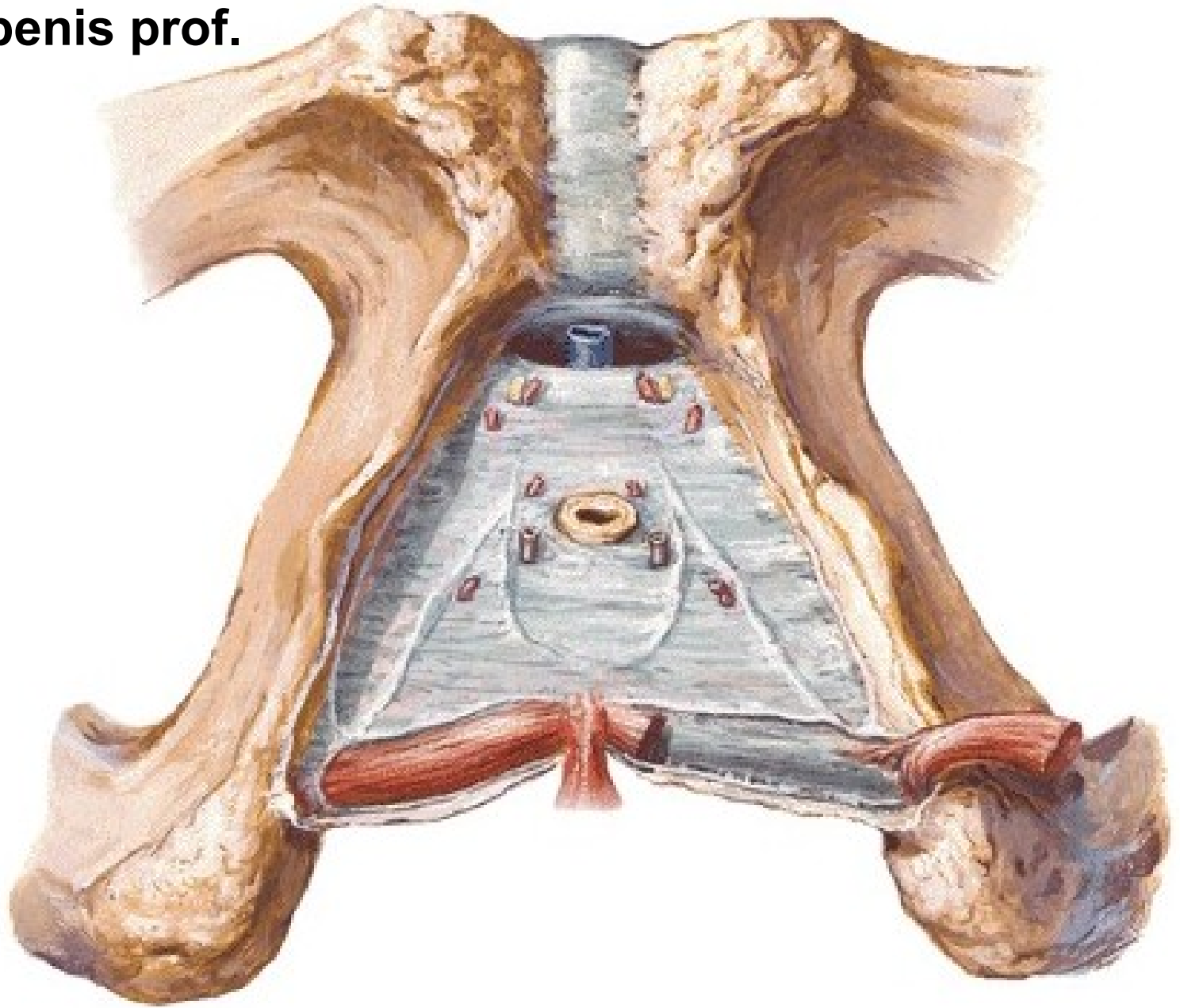
Glandulae bulbourethrales



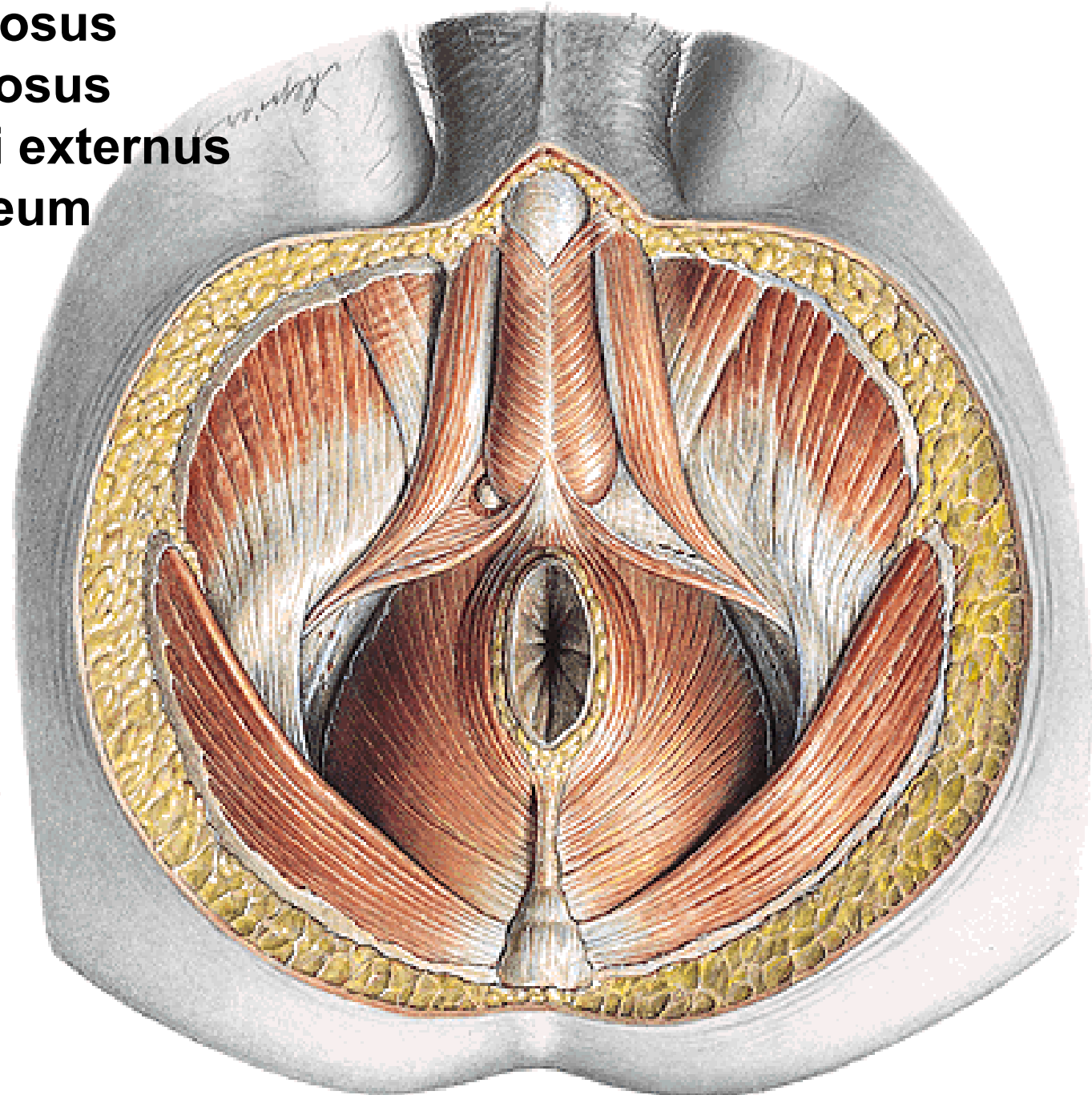
**M. transversus perinei spf.**

**Fascia diaphragmatis urogenitalis inf.**

**V. dorsalis penis prof.**



**M. ischiocavernosus**  
**M. bulbospongiosus**  
**M. sphincter ani externus**  
**Lig. anococcygeum**







**Fascia diaphragmatis urogenitalis sup. et inf.**

**Spatium perinei profundum**

**Fascia perinei spf.**

**Spatium perinei spf.**

**Recessus pubicus**

**fossae ischio-  
rectalis**

