

Class II.

Location:

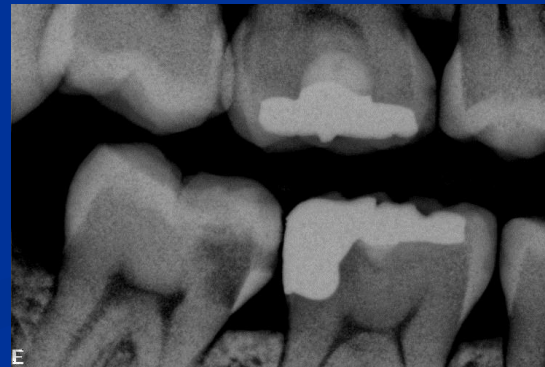Defects affecting one or both proximal surfaces of posterior teeth.

Class II.

Origin:

Proximal surface below the contact point

Propagation of dental caries from
the occlusal surface

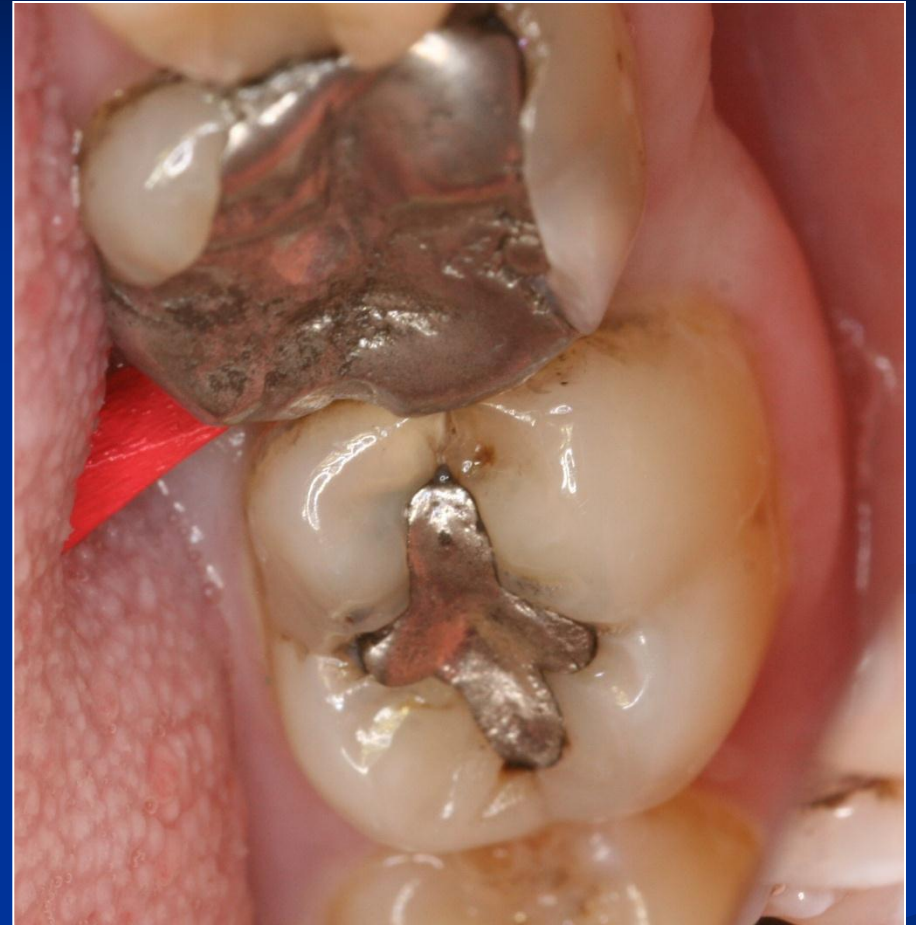
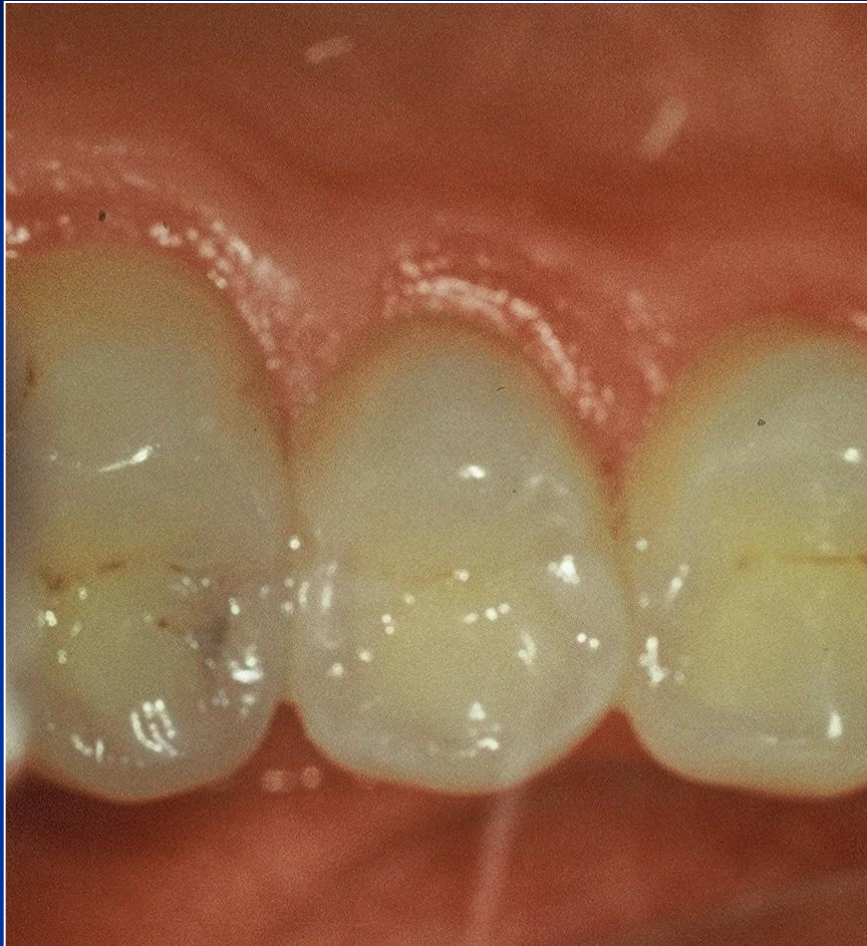
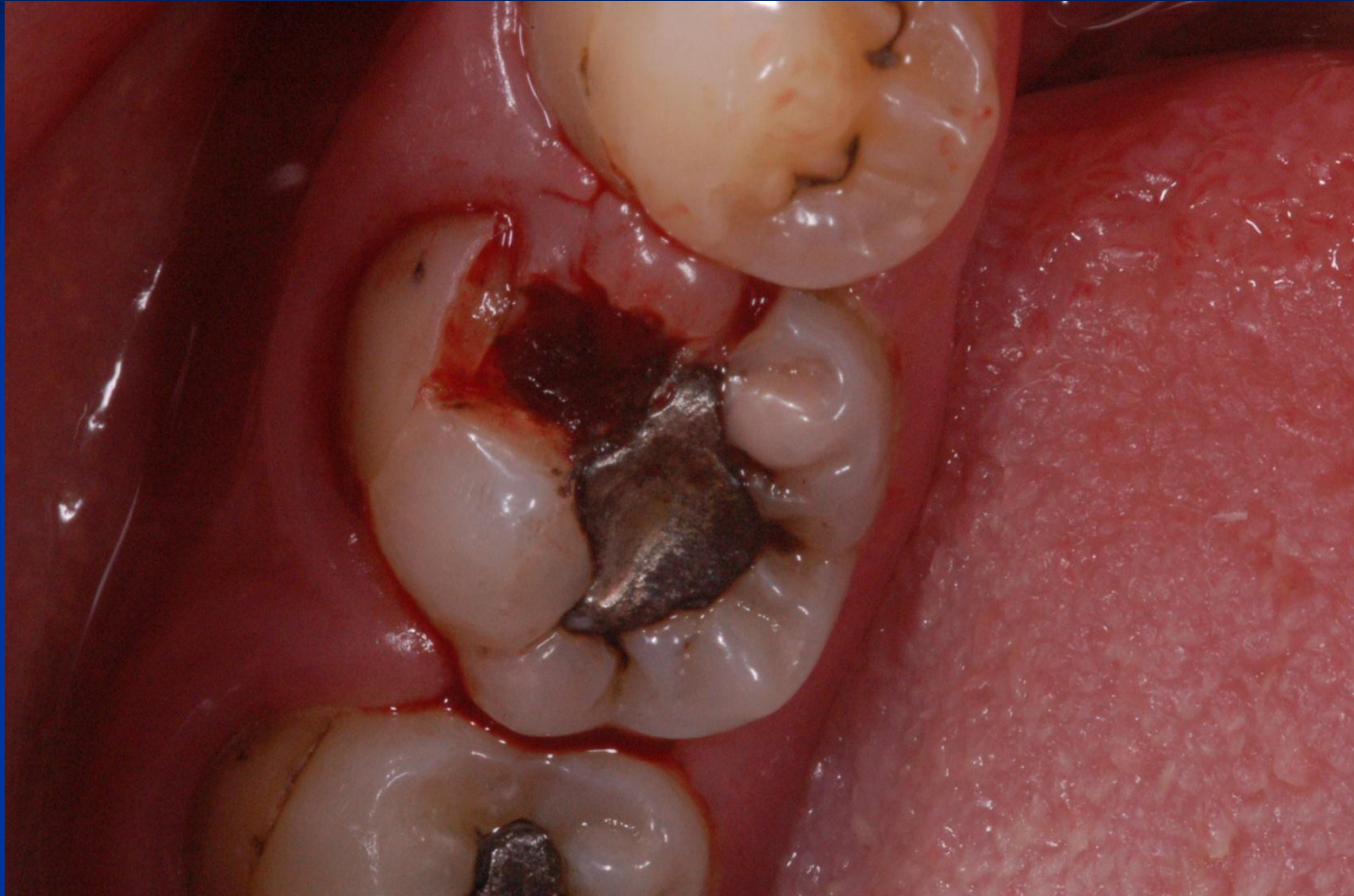Symptoms

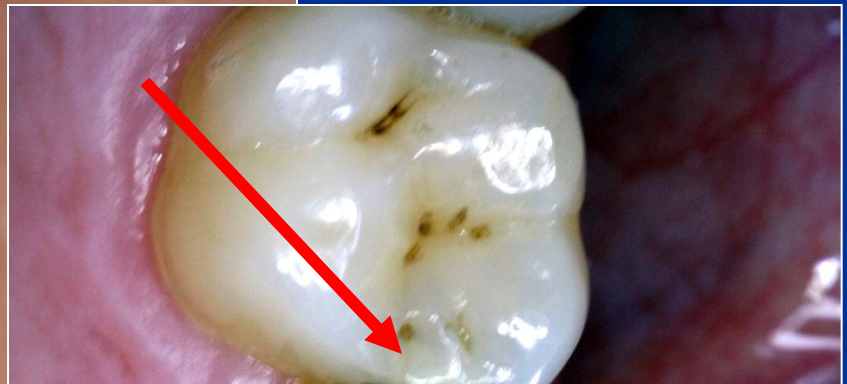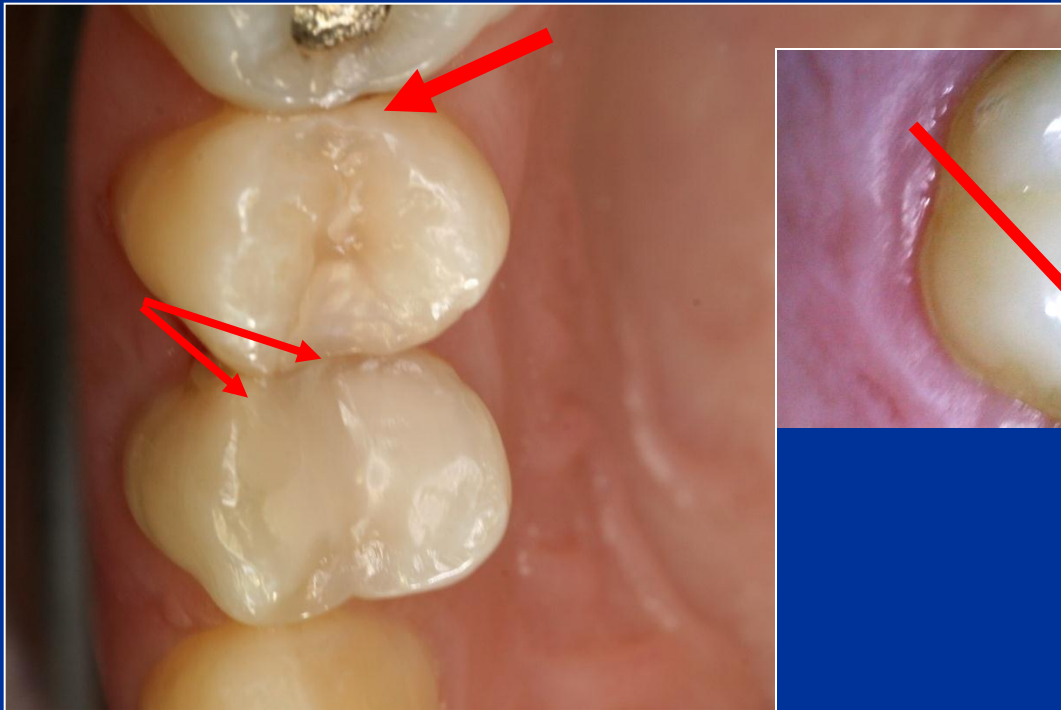
- No symptoms
- Increased sensitivity (cold, sweet)
- Retention of food
- Defect (cariious lesion is open – the enamel is broken)
- Bite sensitivity (when cariious lesion is open)

Diagnosis

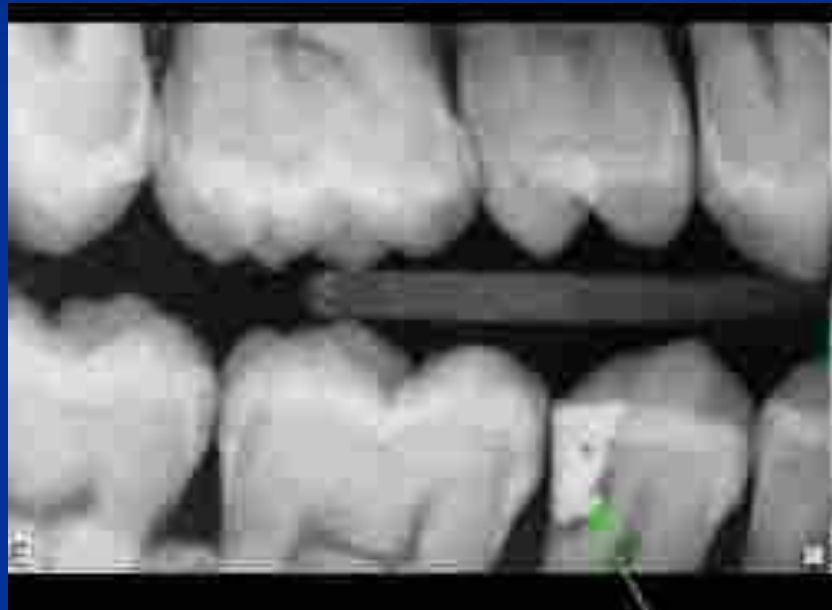- Visual changes of tooth structure
- Transillumination
- Radiography



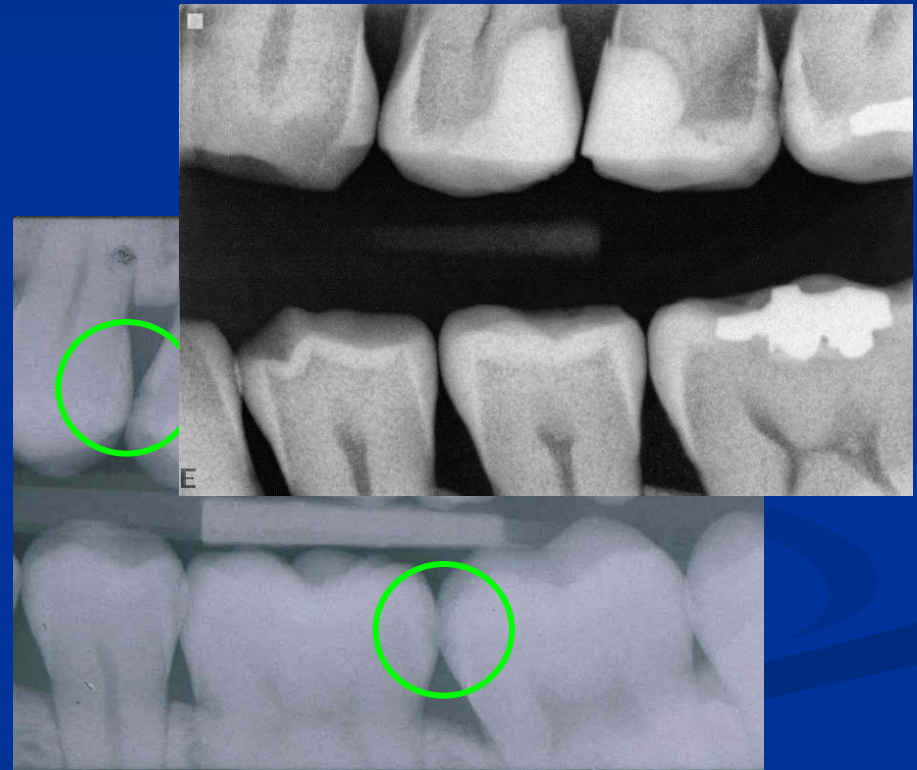
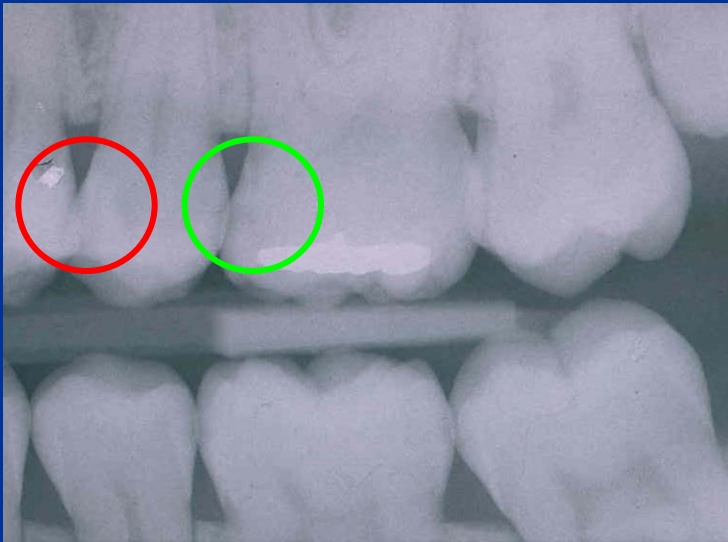


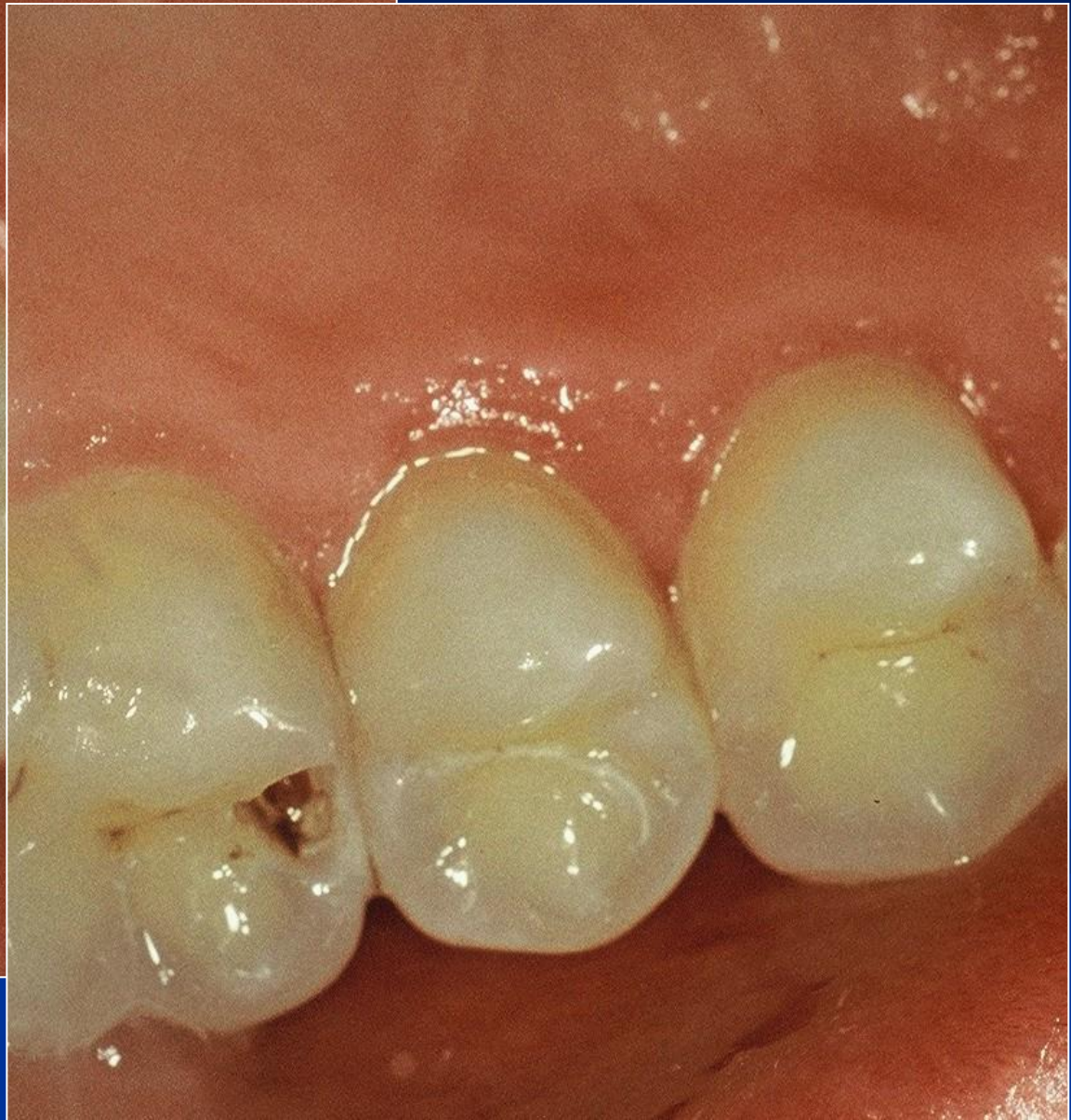
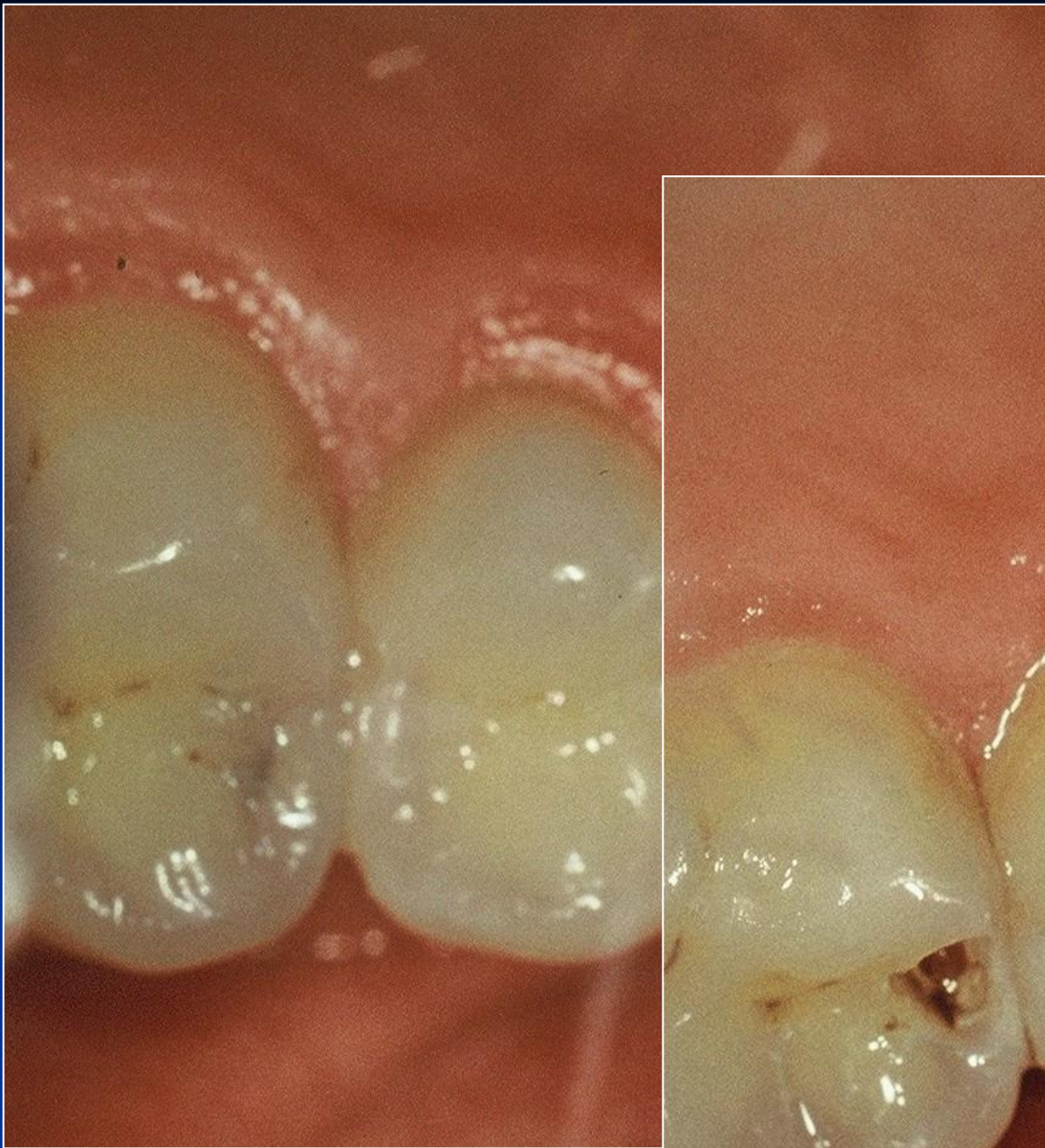
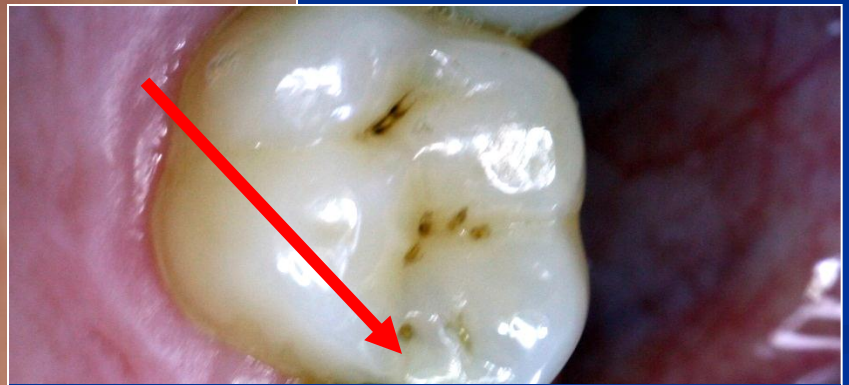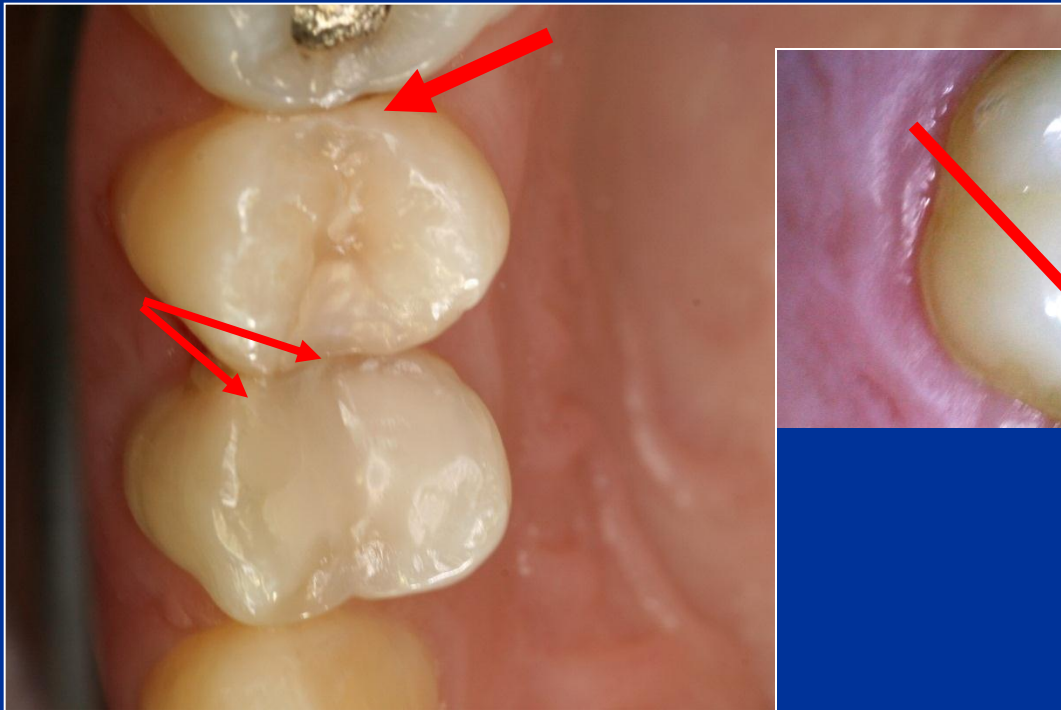
Bite wing



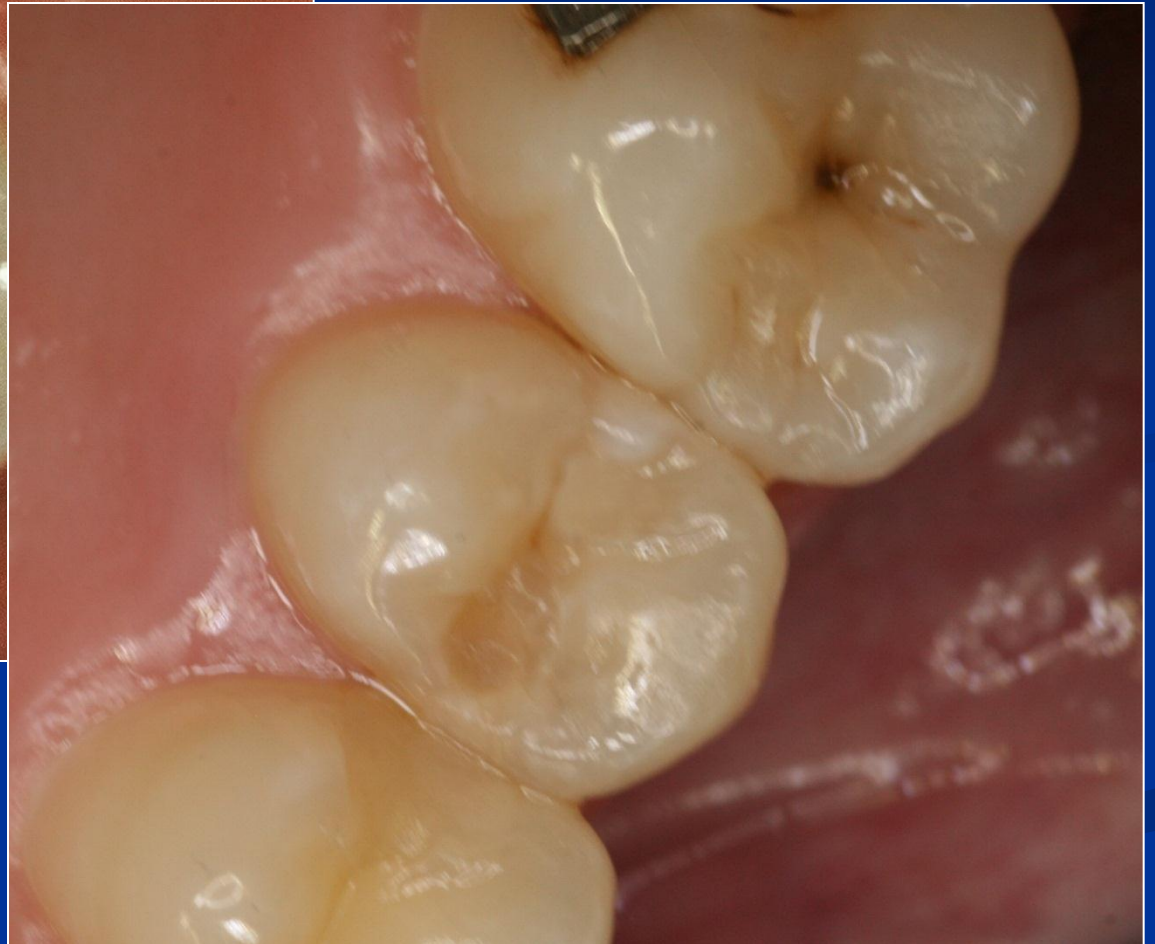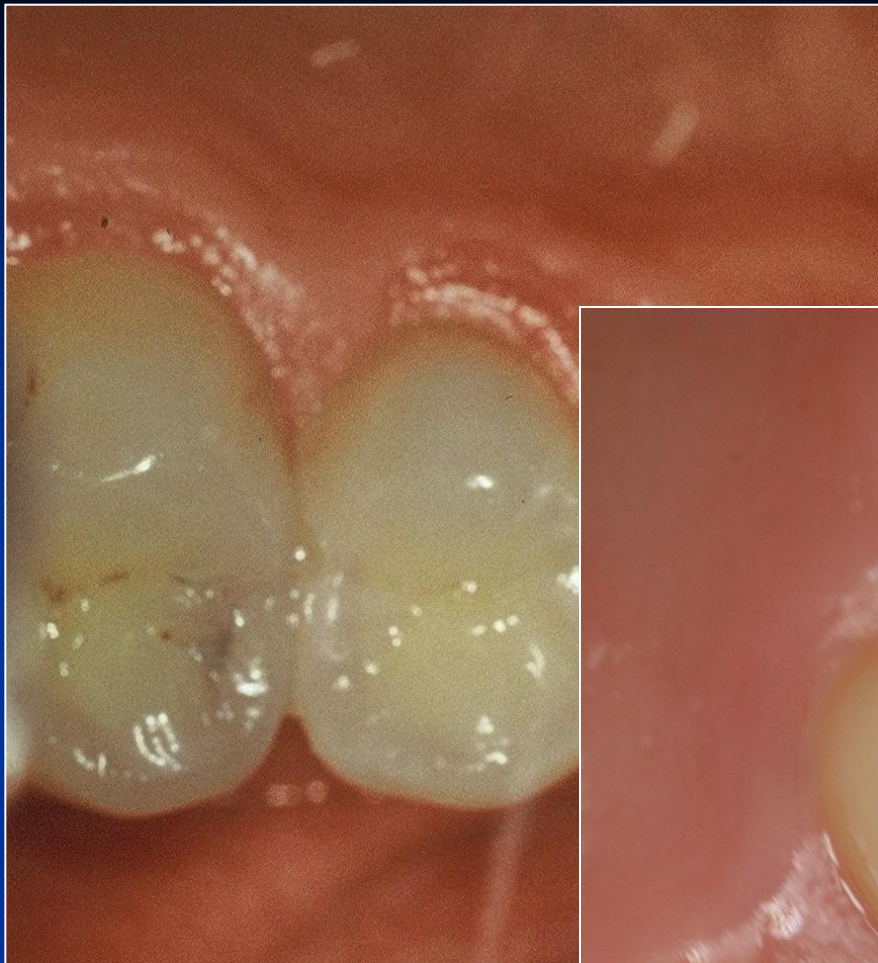- D1 – projasnění do ½ tloušťky skloviny
- D2 – projasnění na hranici skloviny a dentinu
- D3 – projasnění do dentinu
- D4 - projasnění sahající do dřeňové dutiny



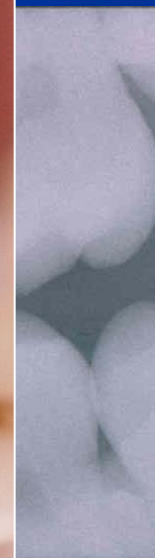
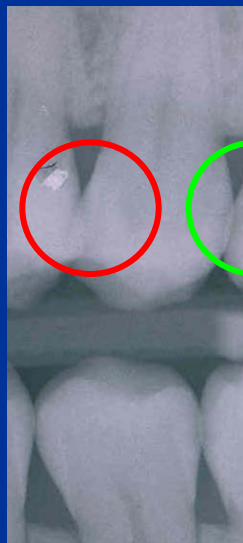
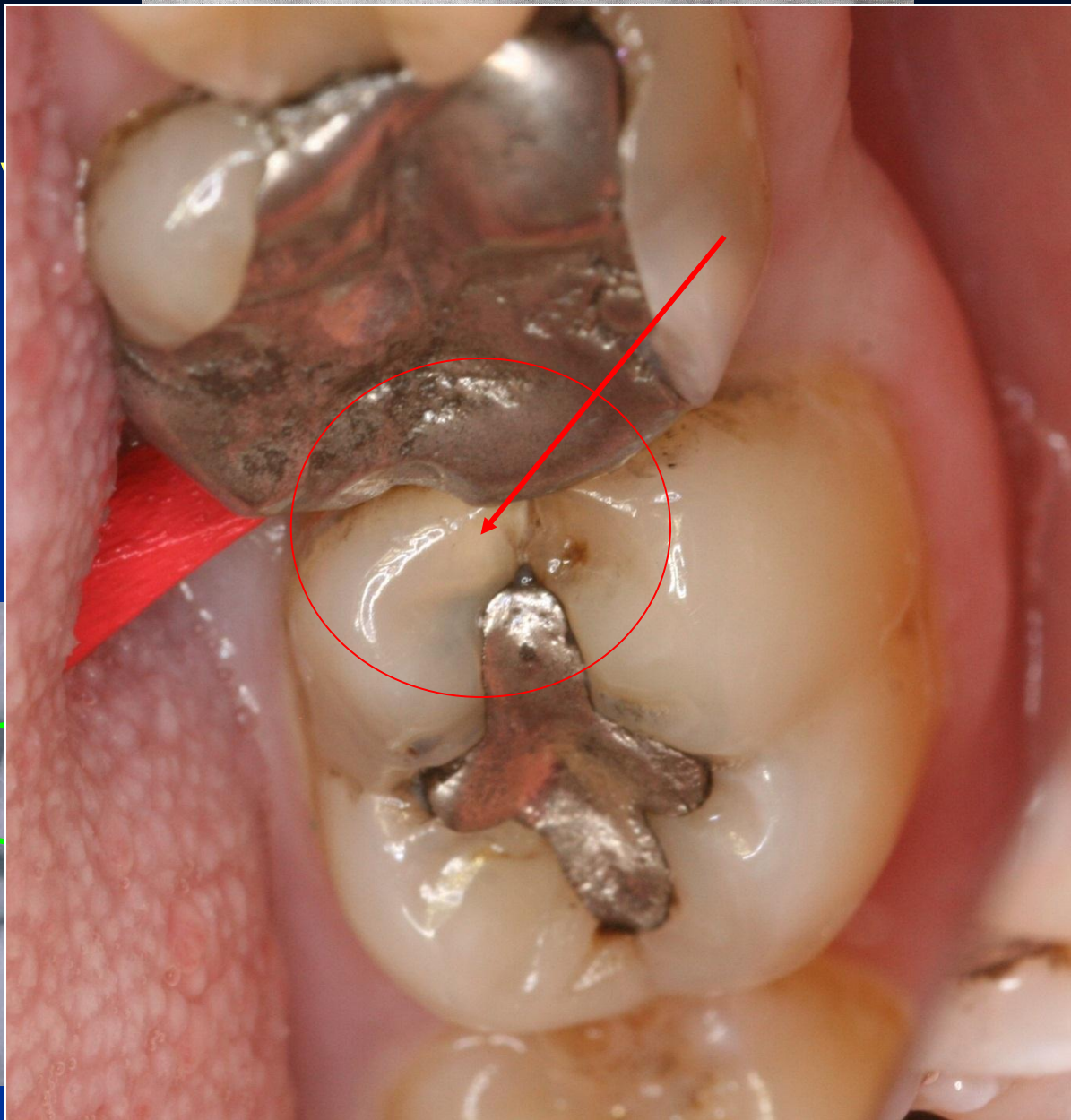








4 stupňo
grading



KTG vyšetření – Bite wing

Filling materials

- Amalgam
- Composite materials
- Glass ionomer cements

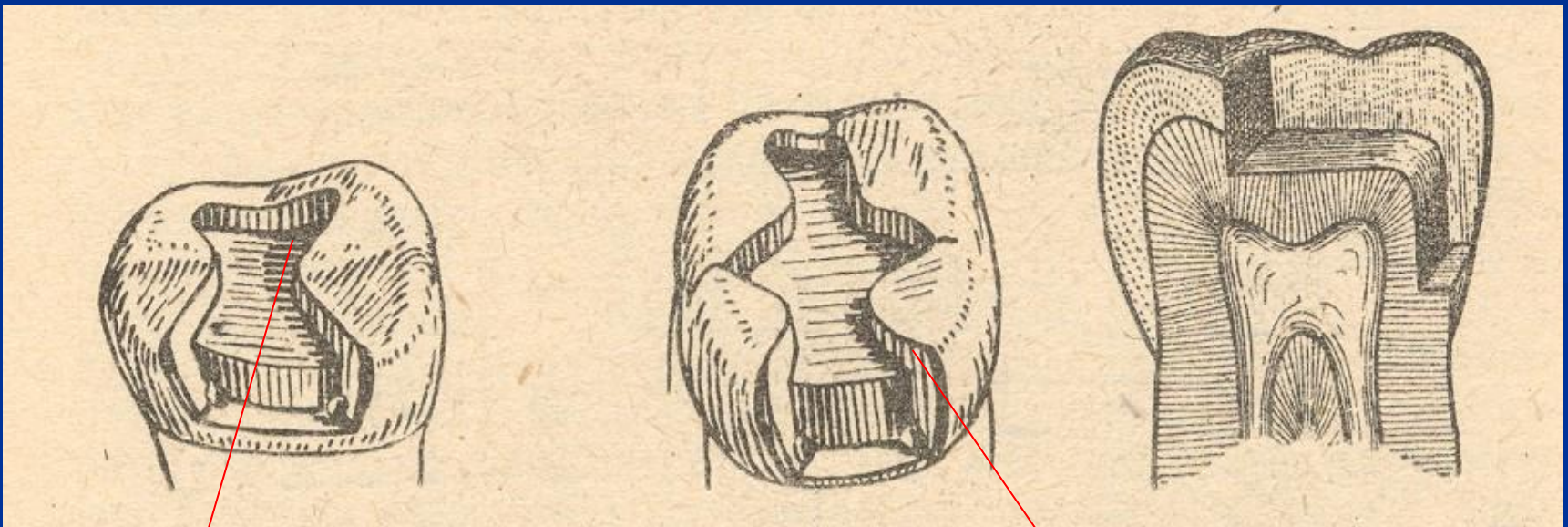
Preparation - amalgam

- Conventional preparation acc. to the Black's rules
- Slot preparation
- Large preparation – cusp(s) involved

Preparation - adhesive materials (composites, glass ionomers)

- Conventional preparation for composites
- Adhesive slot
- Tunnel preparation

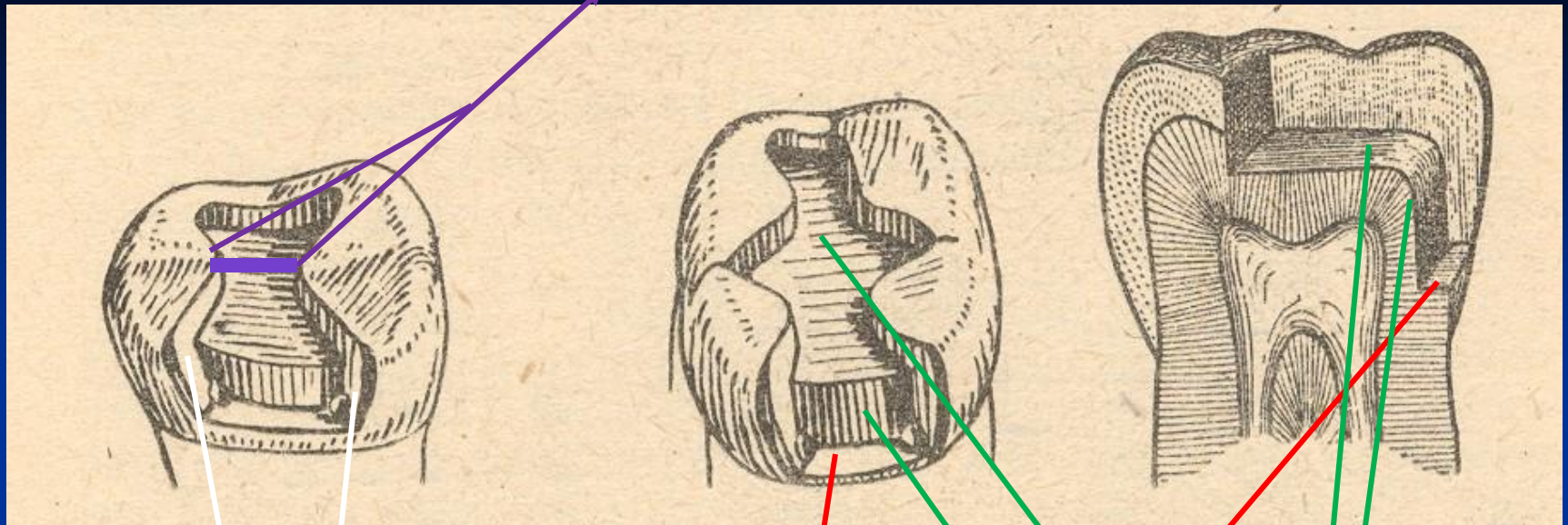
Conventional preparation amalgam



Occlusal cavity

Proximal cavity - box

Isthmus



Axial wall

Pulpal walls

Gingival wall

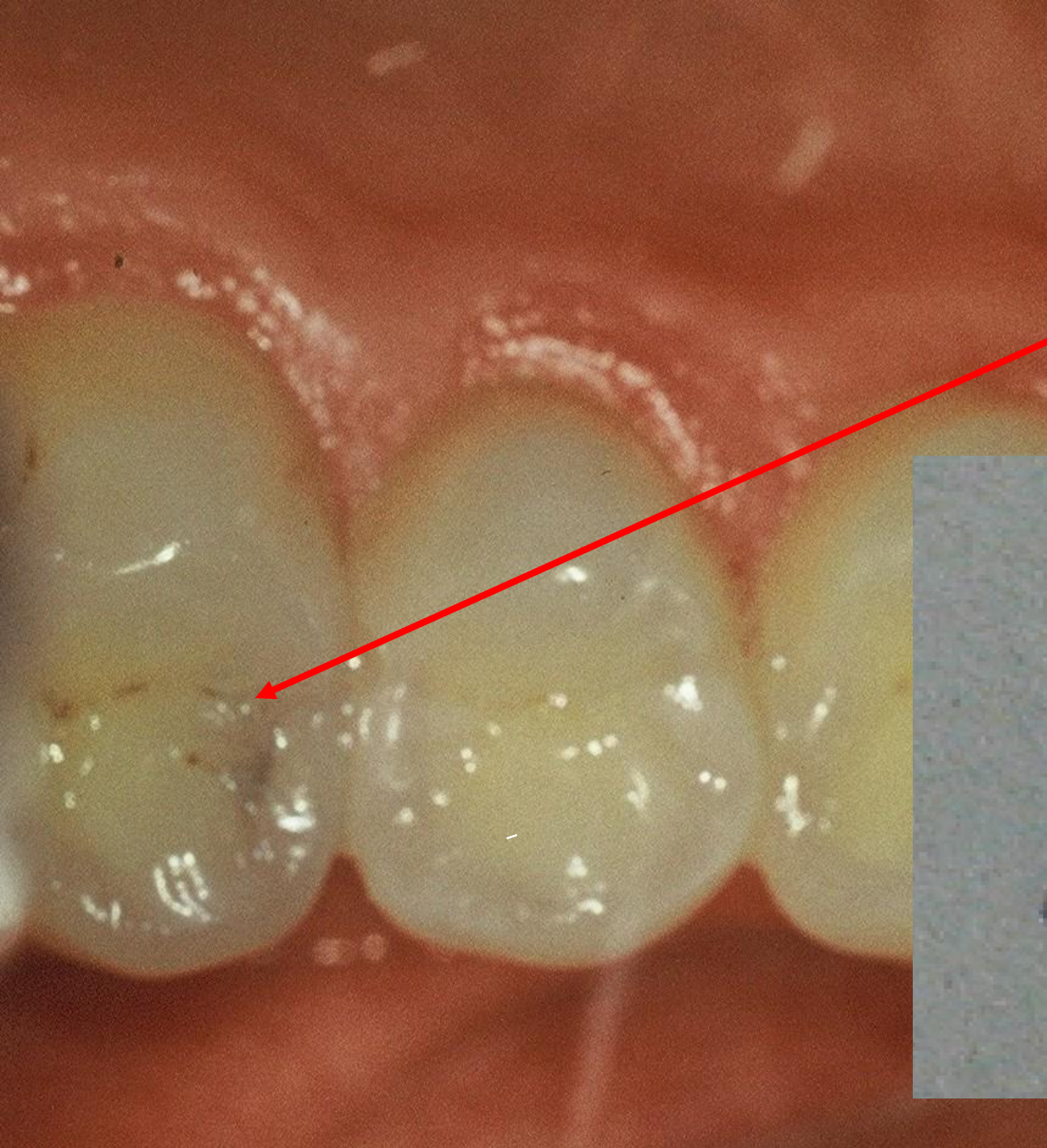
Access to the cavity

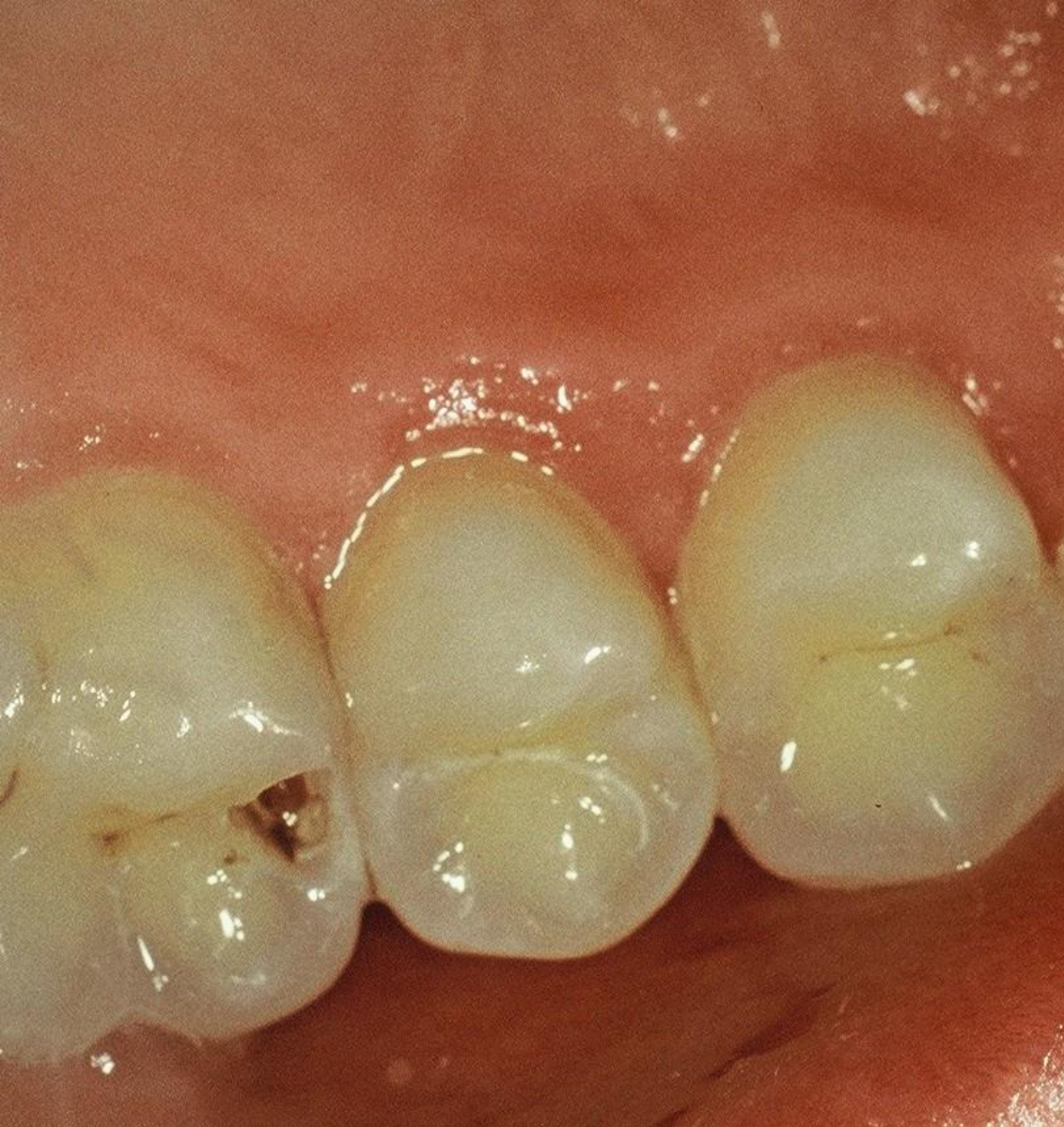From the occlusal surface

Through the undermined enamel

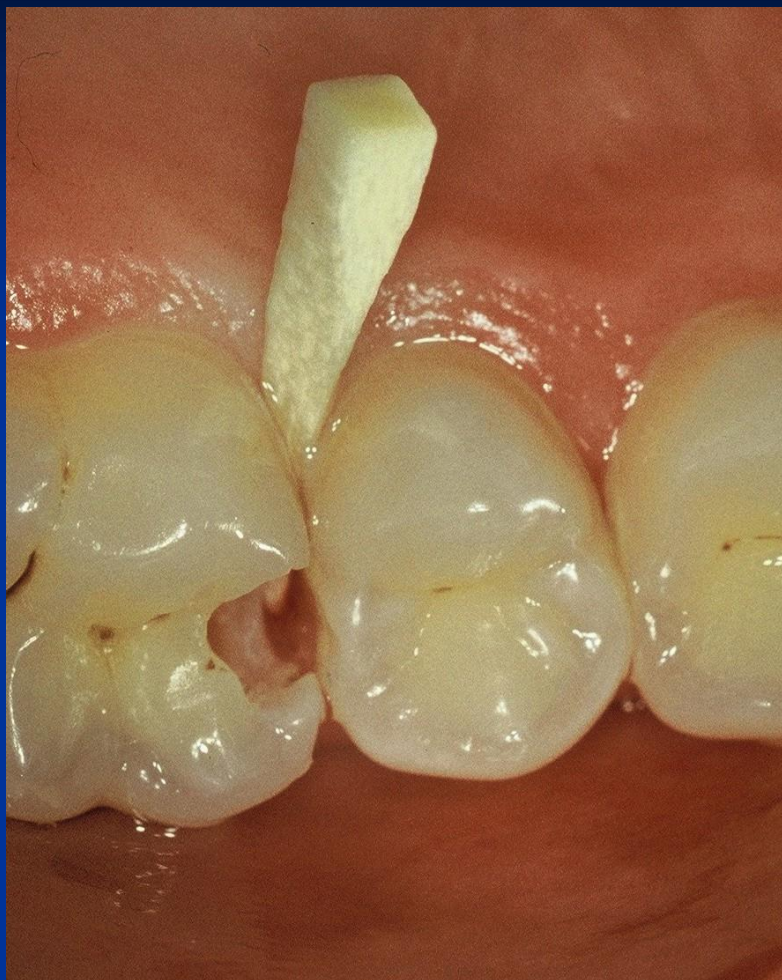Separation using wooden wedges is useful

Pre op

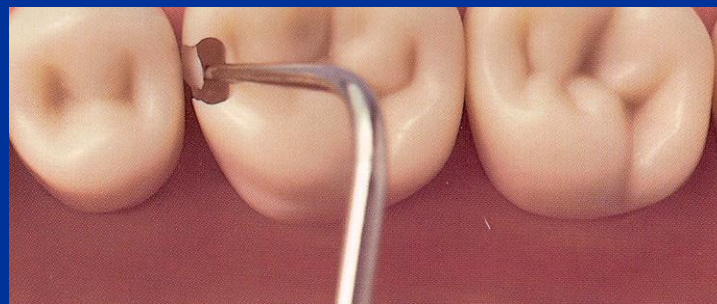


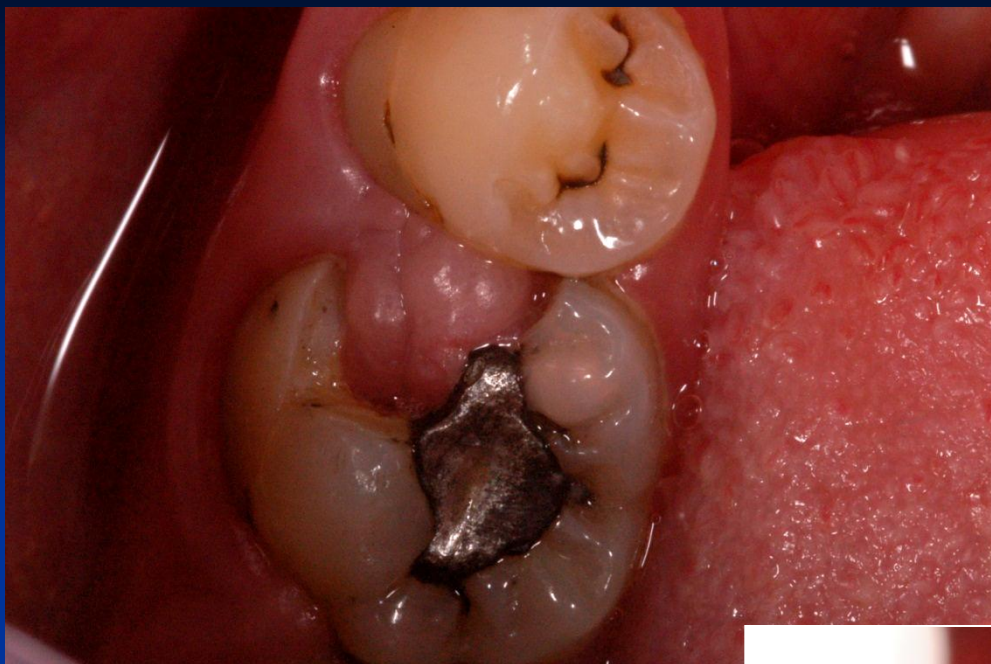


Access to the cavity

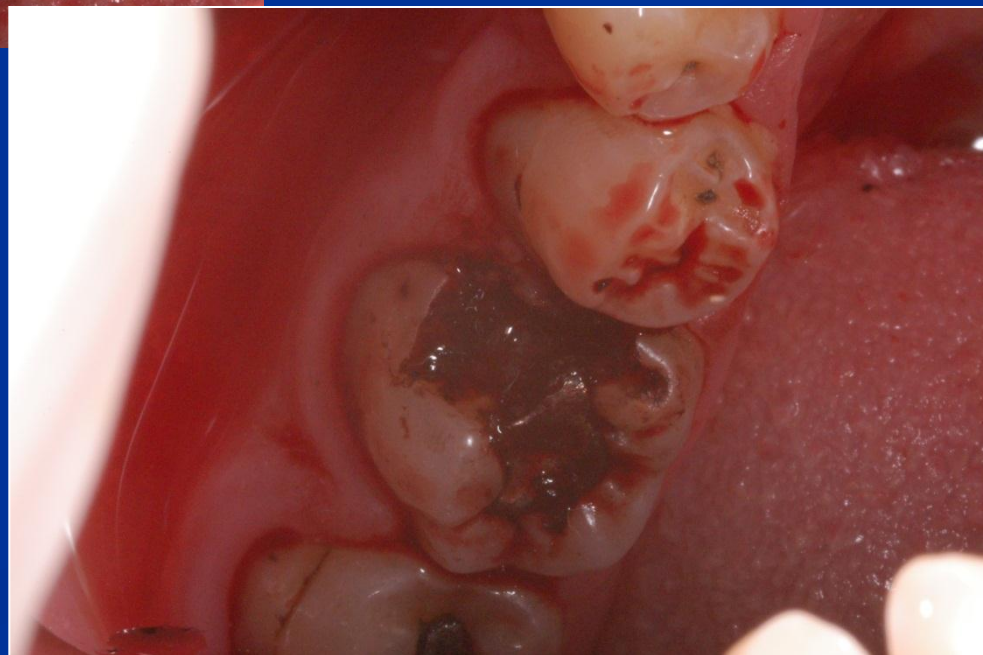

Breaking the thin enamel layer out of the cavity





➤ Remove of the gingiva that grows into the cavity



Cavosurface margin and extention for prevention


Proximal box:

Vestibullary and orally – axial walls (the border between the oral/vestibular and proximal surface.

Below the free gingiva (0,5 mm)


Occlusal

Class I.



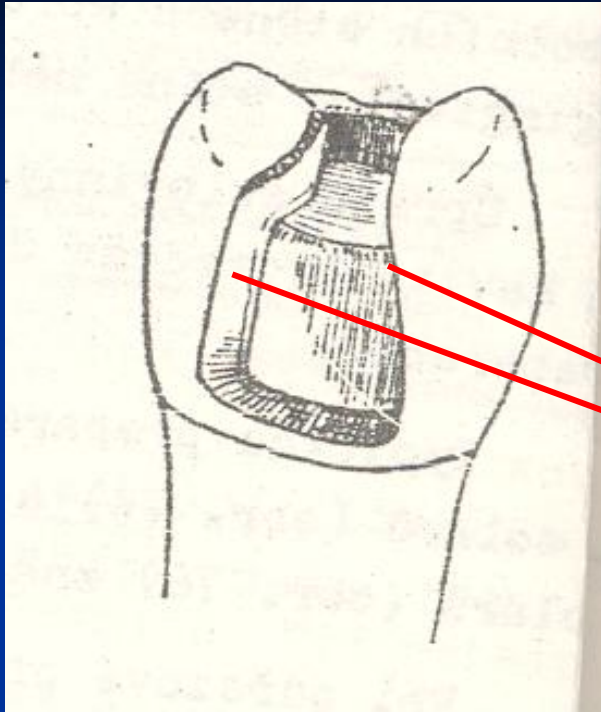
P. americké

Pichlerovo p.

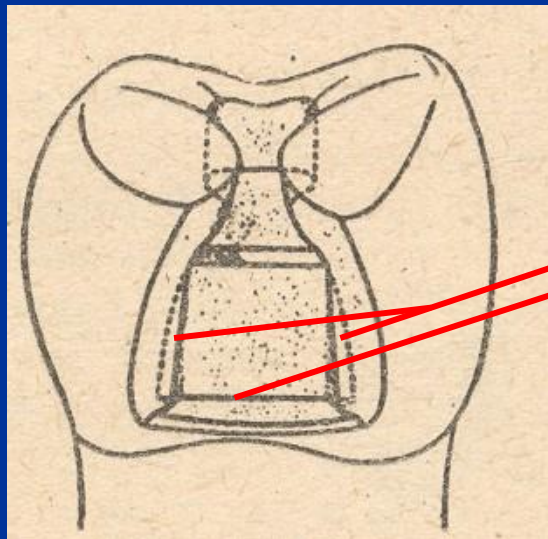
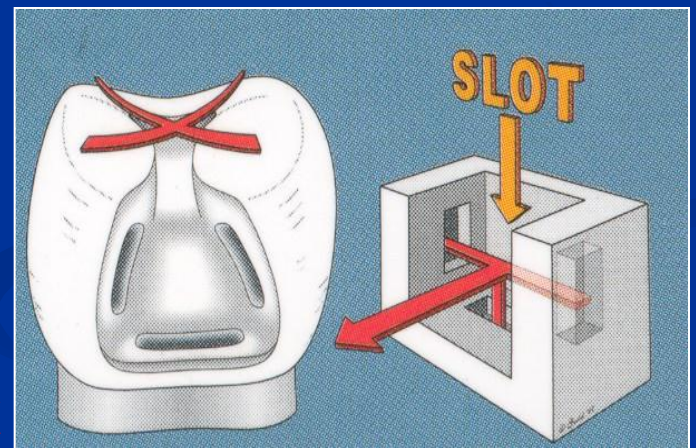


Retention

- Occlusal cavity
- Undercuts
- Grooves



Autoretention



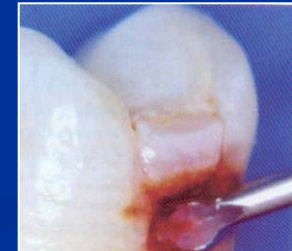
Grooves

Resistance

- No undermined enamel
- No sharp edges
- Isthmus is $1/3 - 1/4$ intercuspidal distance
- Angle between axial and gingival wall: 90° , or 85°
- Width of gingival wall is 1 mm at least
- Thickness of the filling 2 – 4 mm (4mm if cusp replacing)

Excavation of carious dentin

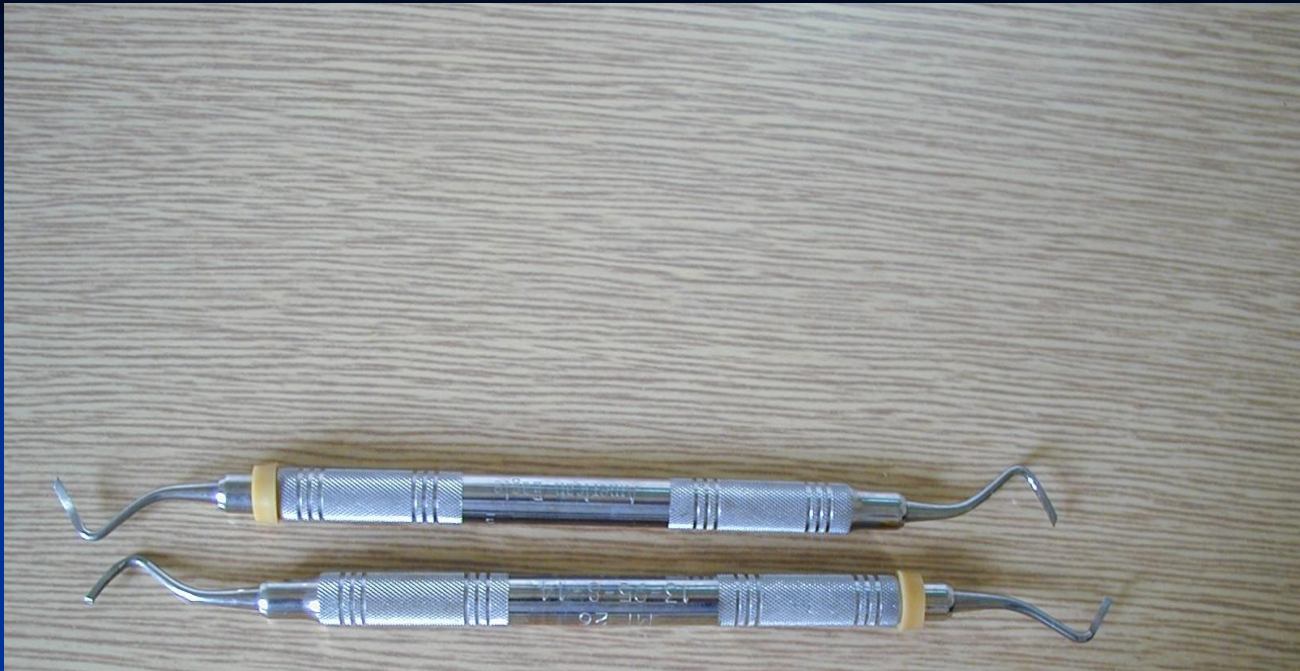
Rounded bur

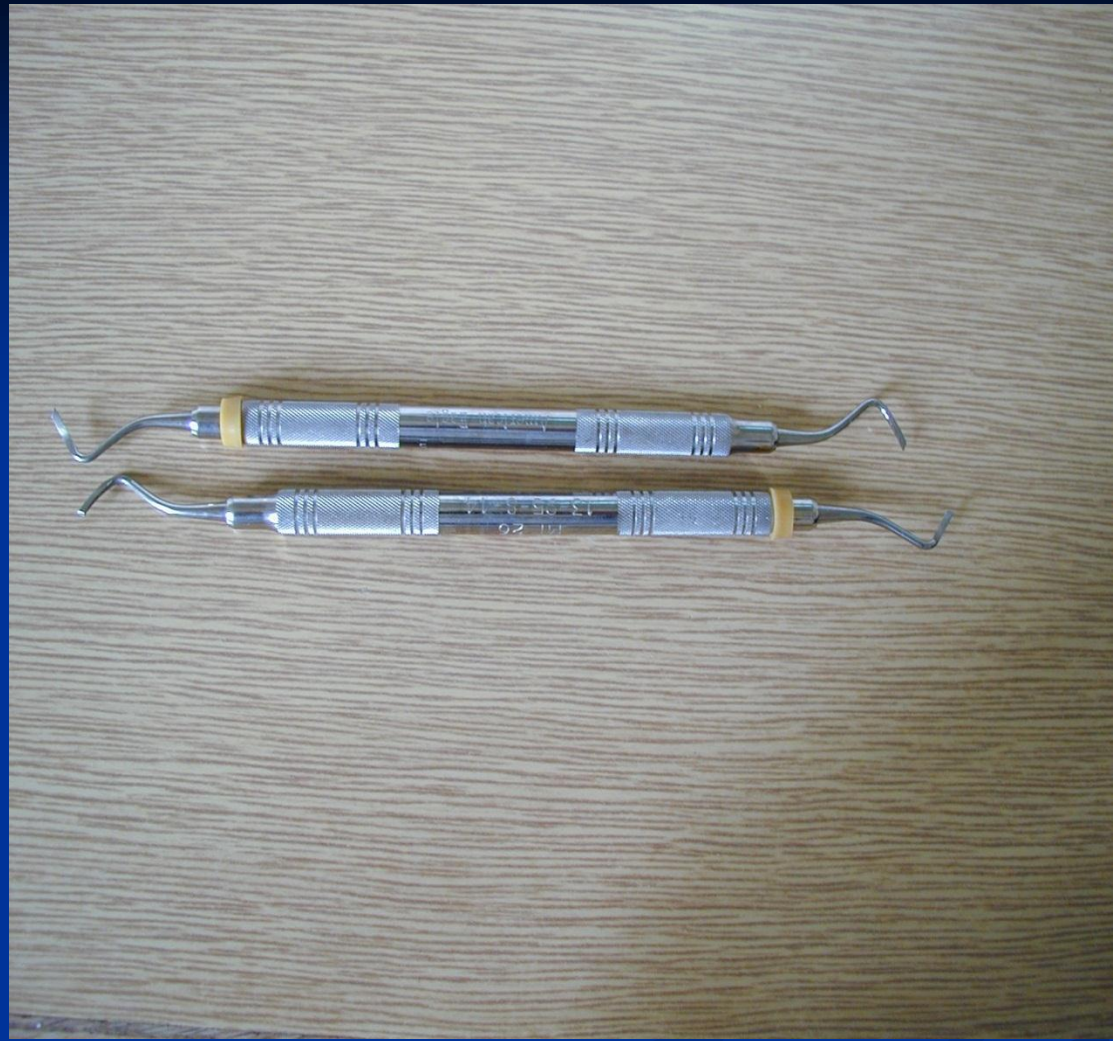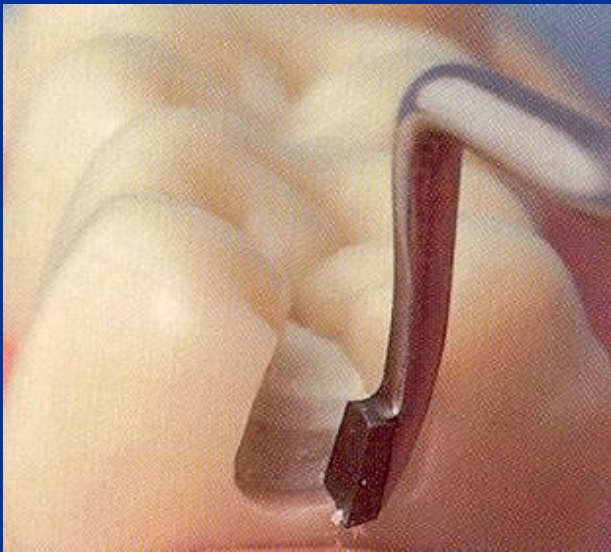
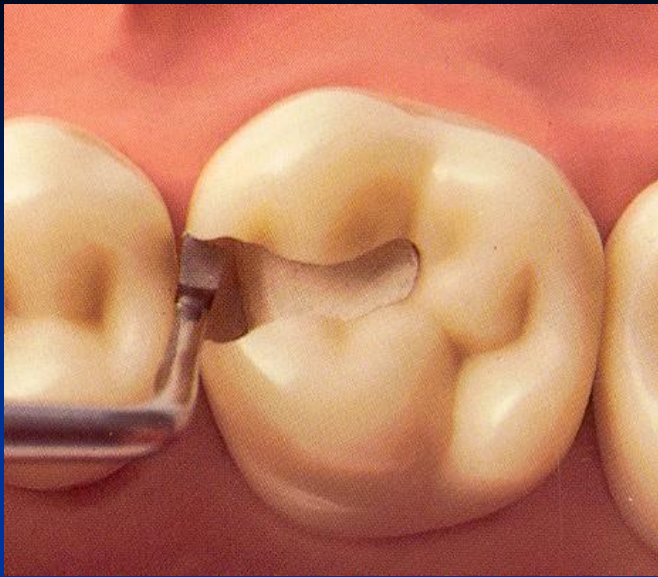


(Caries Detector, Kuraray, Japonsko; Caries Marker, VOCO, Německo)

Finishing of the walls of the cavity

- Red coded diamond bur
- Chisel on the gingival wall (if in enamel)



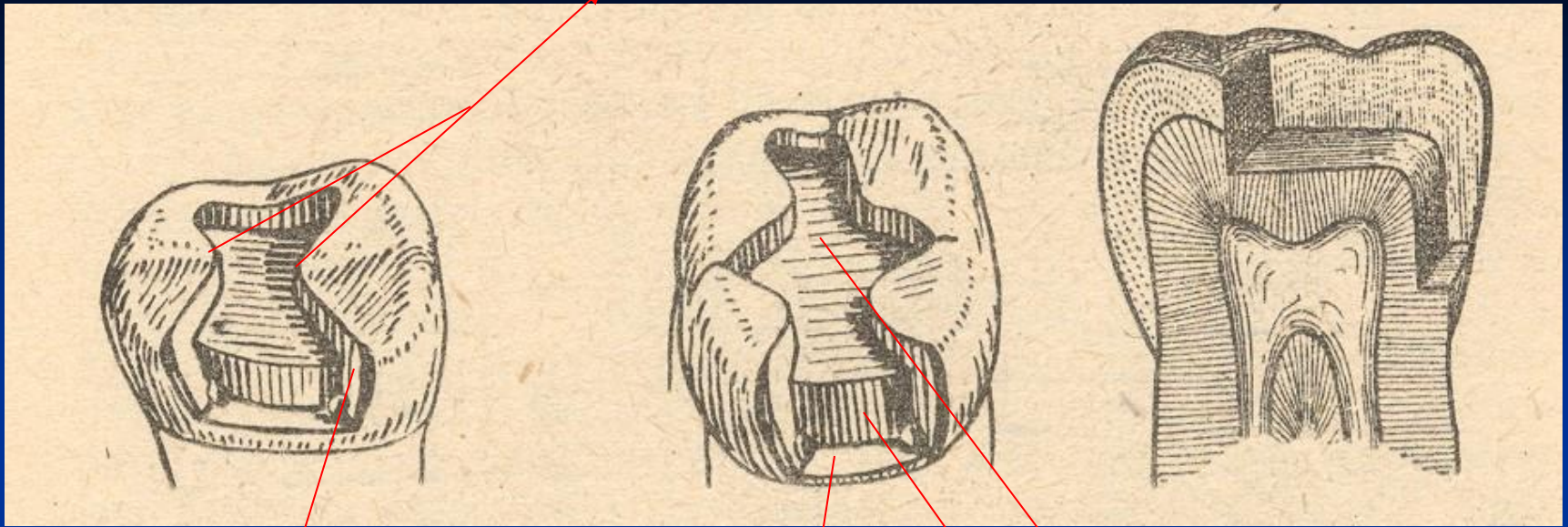




Final check

- Goog light, mirror

Isthmus



Axial wall

Pulpal wall

Gingival wall

Matrix placement

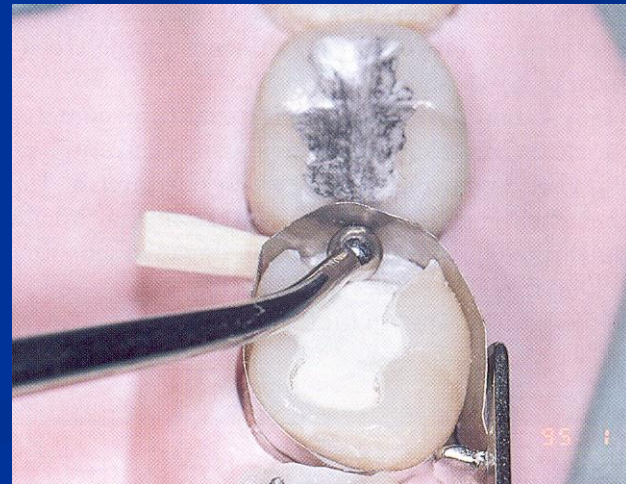
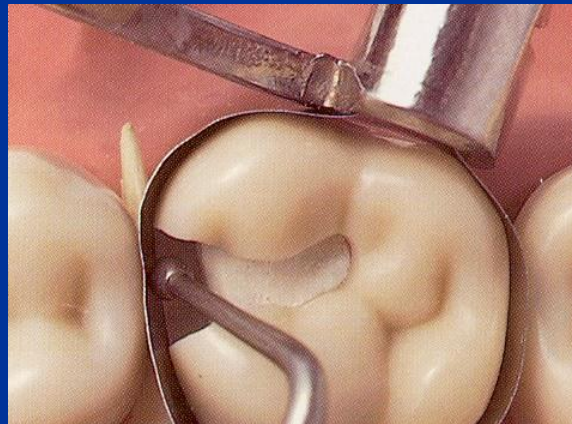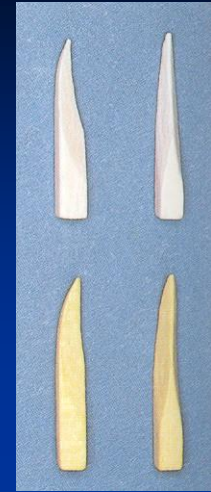- Matrix primarily is used when a proximal surface is to be restored

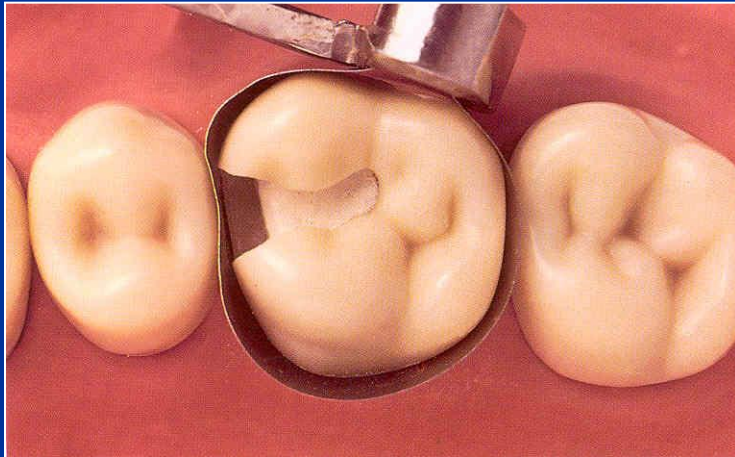
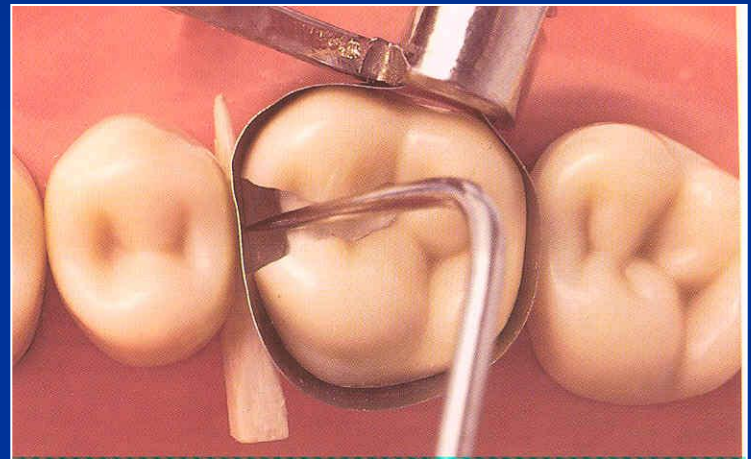

The objectives:

- Provide proper contact
- Provide proper contour
- Confine the restorative material
- Reduce the amount of excess material

Matrices

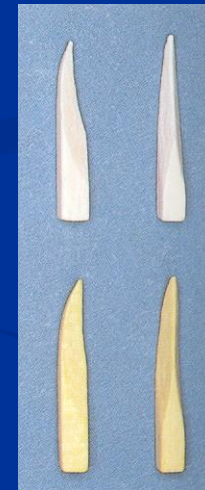- Ivory I retainer Ivory 1
- Hawe Neos retainer Ivory 8
- Tofelmire matrix and retainer







Wedges

- Wooden wedges
 - tighten the matrix band
 - compress the gingiva
 - separate the teeth



Wedging

- Slip the matrix band over the tooth (apical to the gingiva margin – 0,5, - 1 mm)
- Tighten the matrix, check it with probe
- Place a wedge
- Turn the retainer $\frac{1}{4}$ counterclockwise
- Contour the band

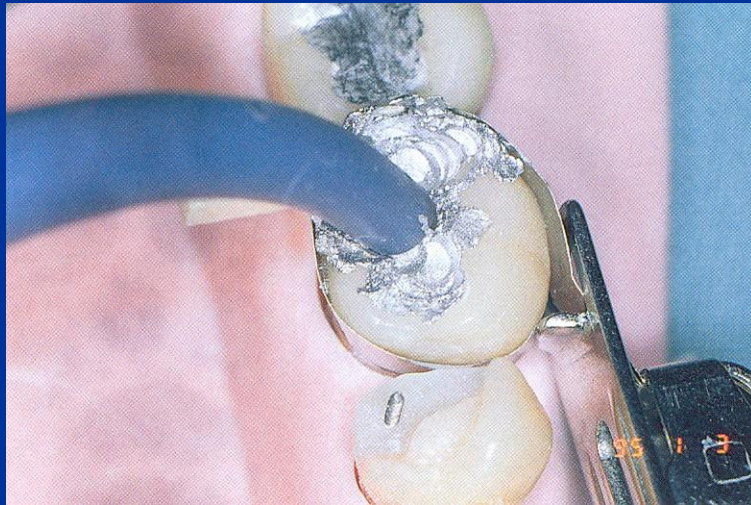
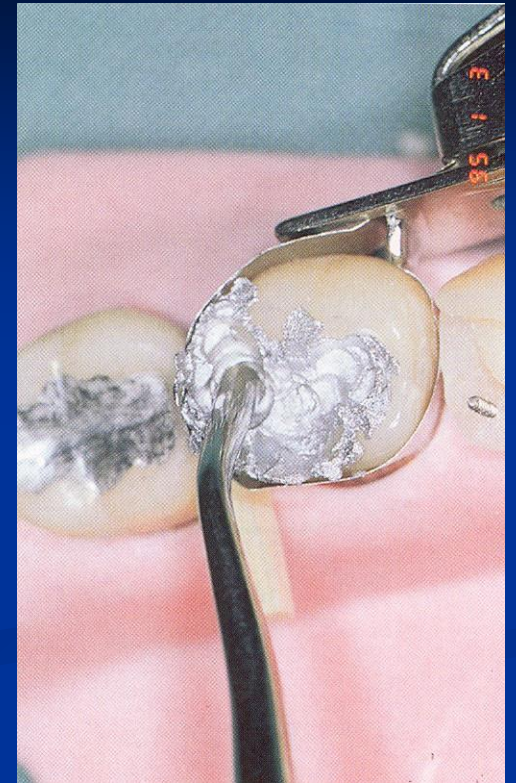


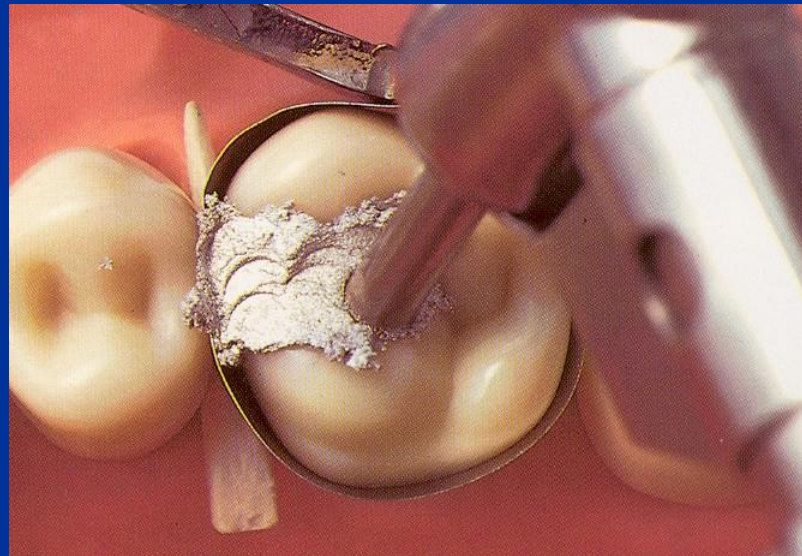
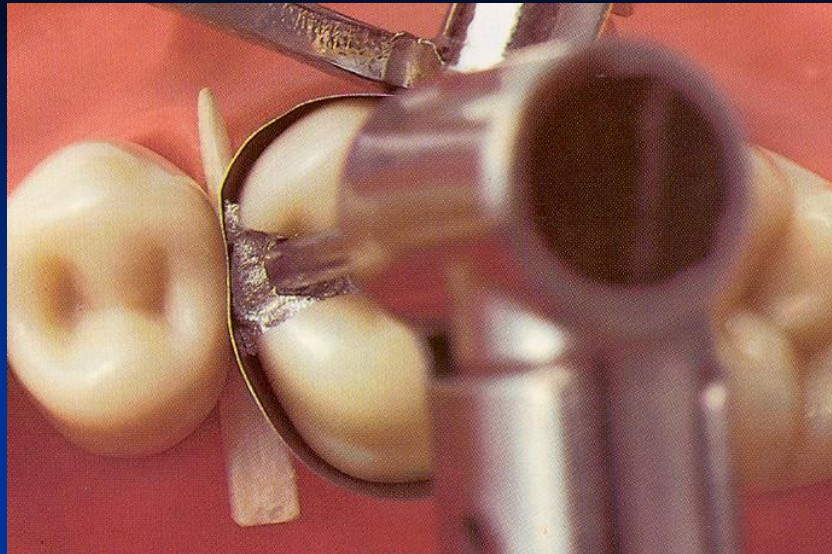
Amalgamators

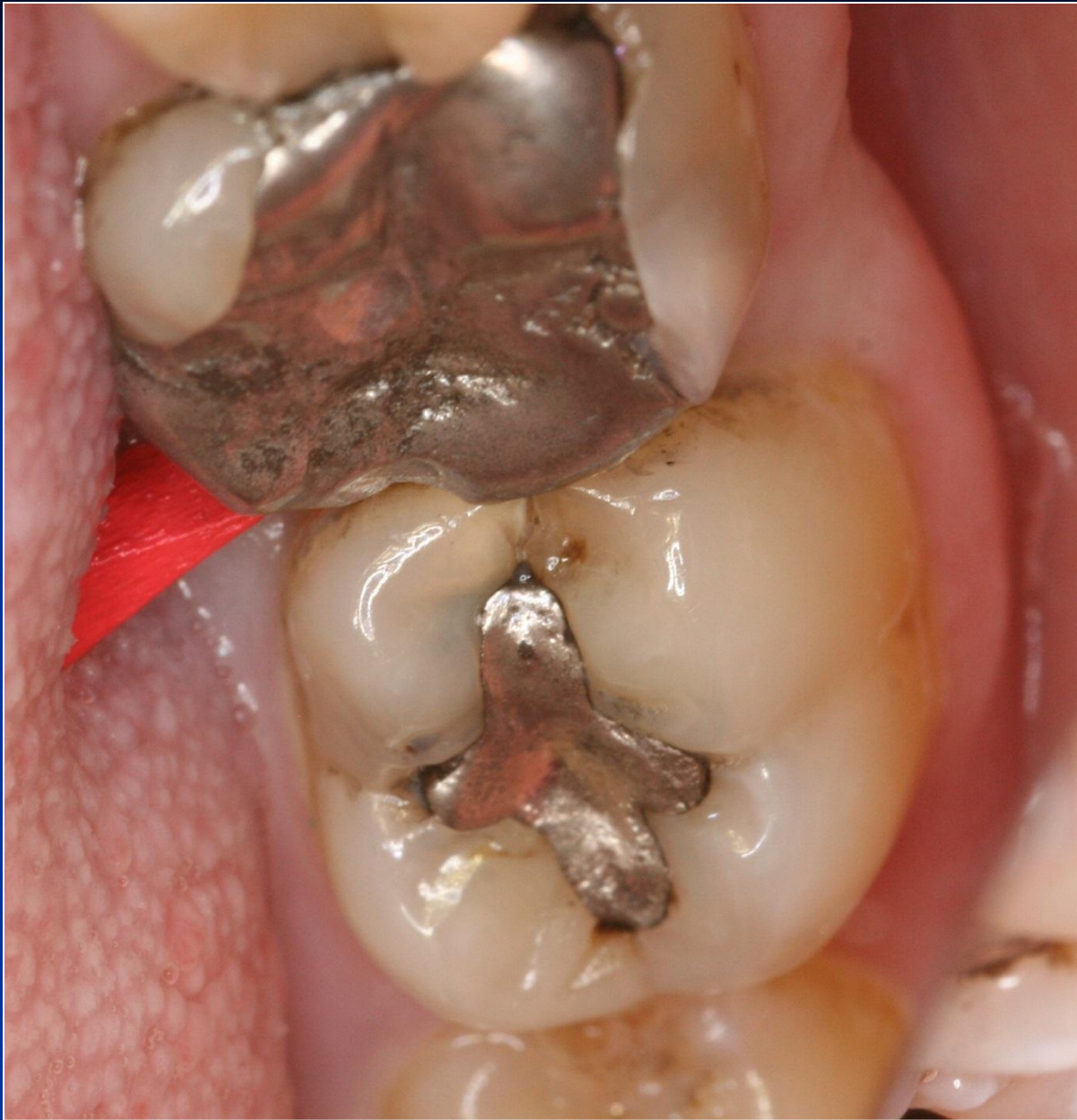Condensation of amalgam

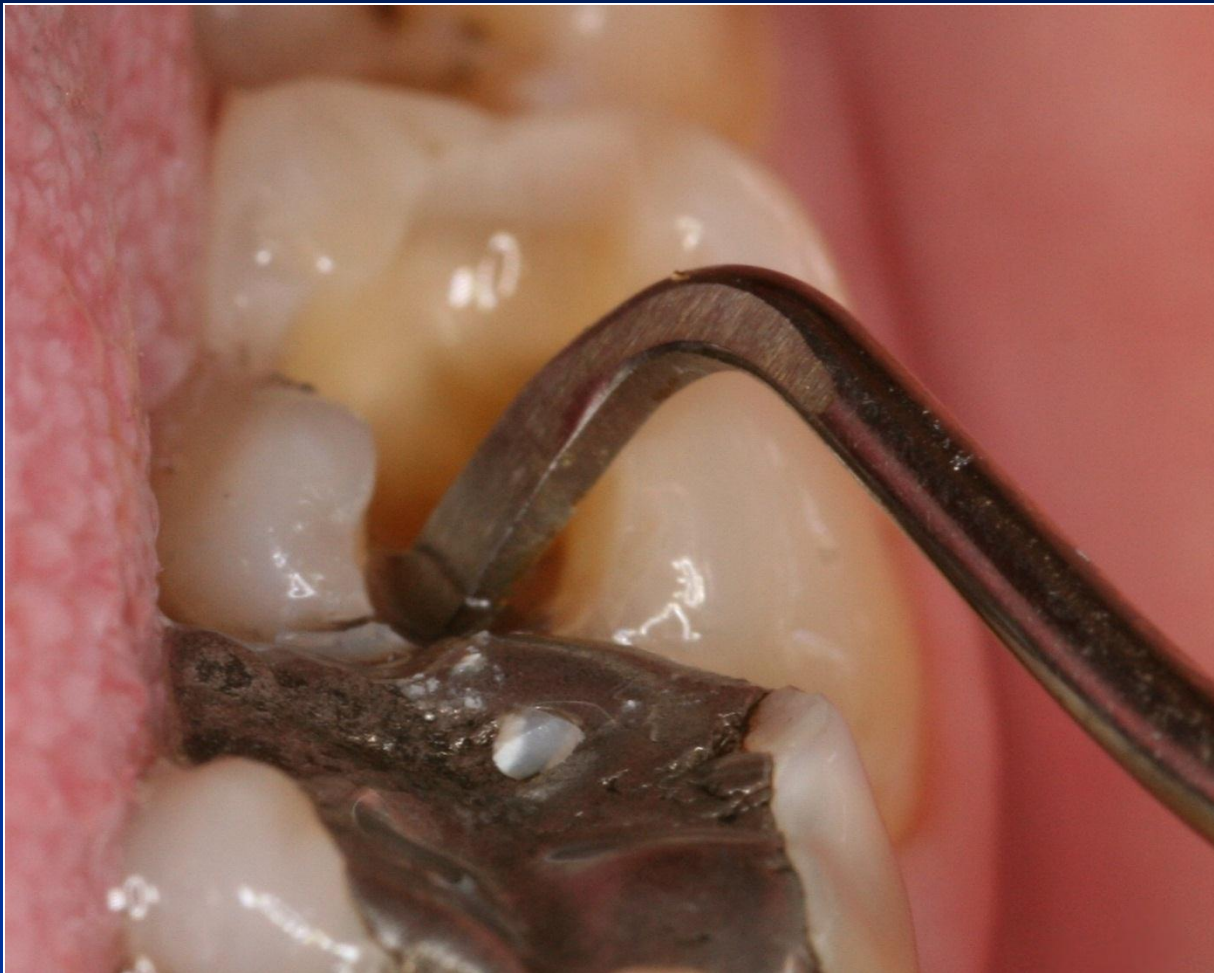- Condensor – with the straight front
- Power driven condensation

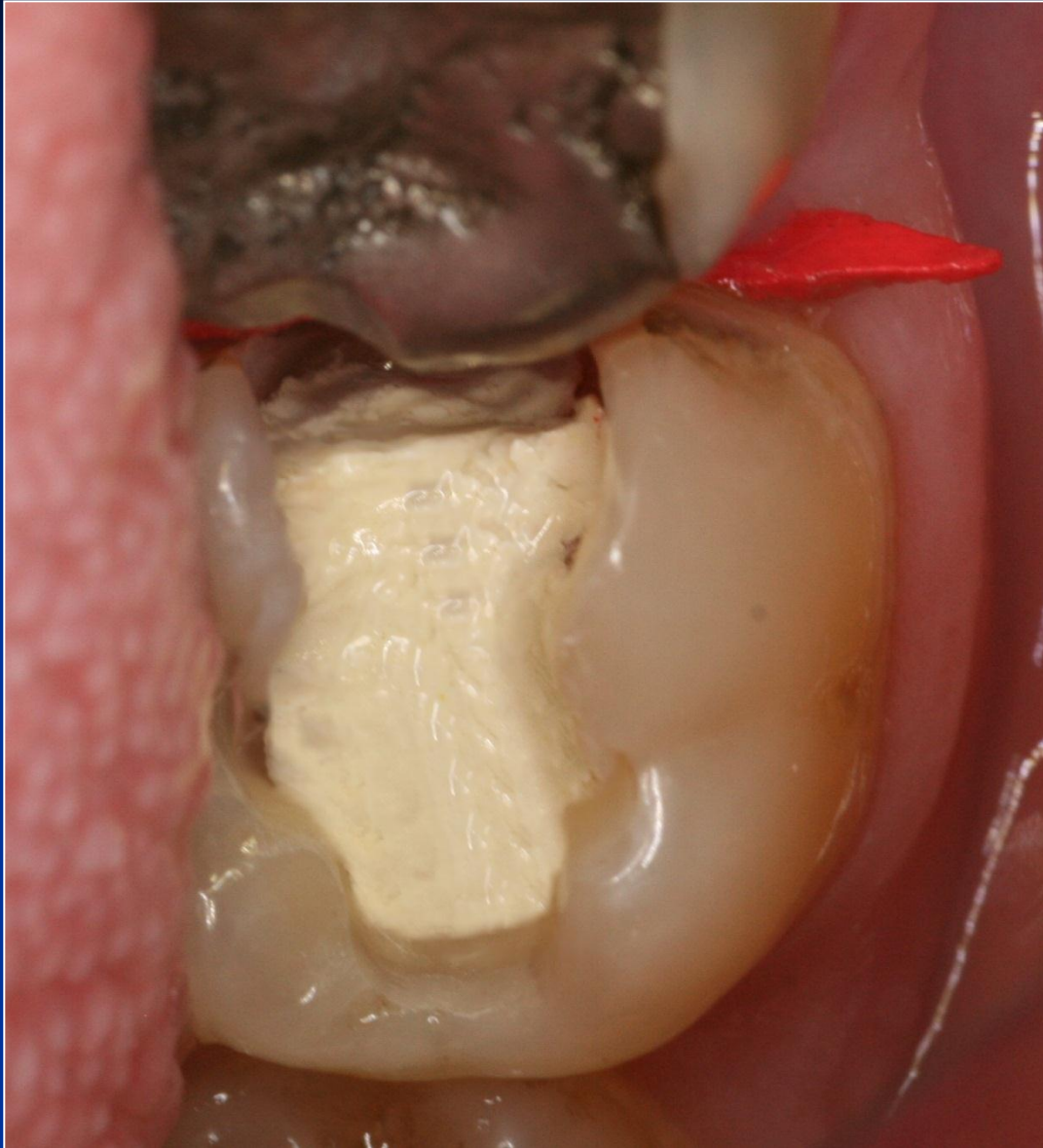How big should the front be?

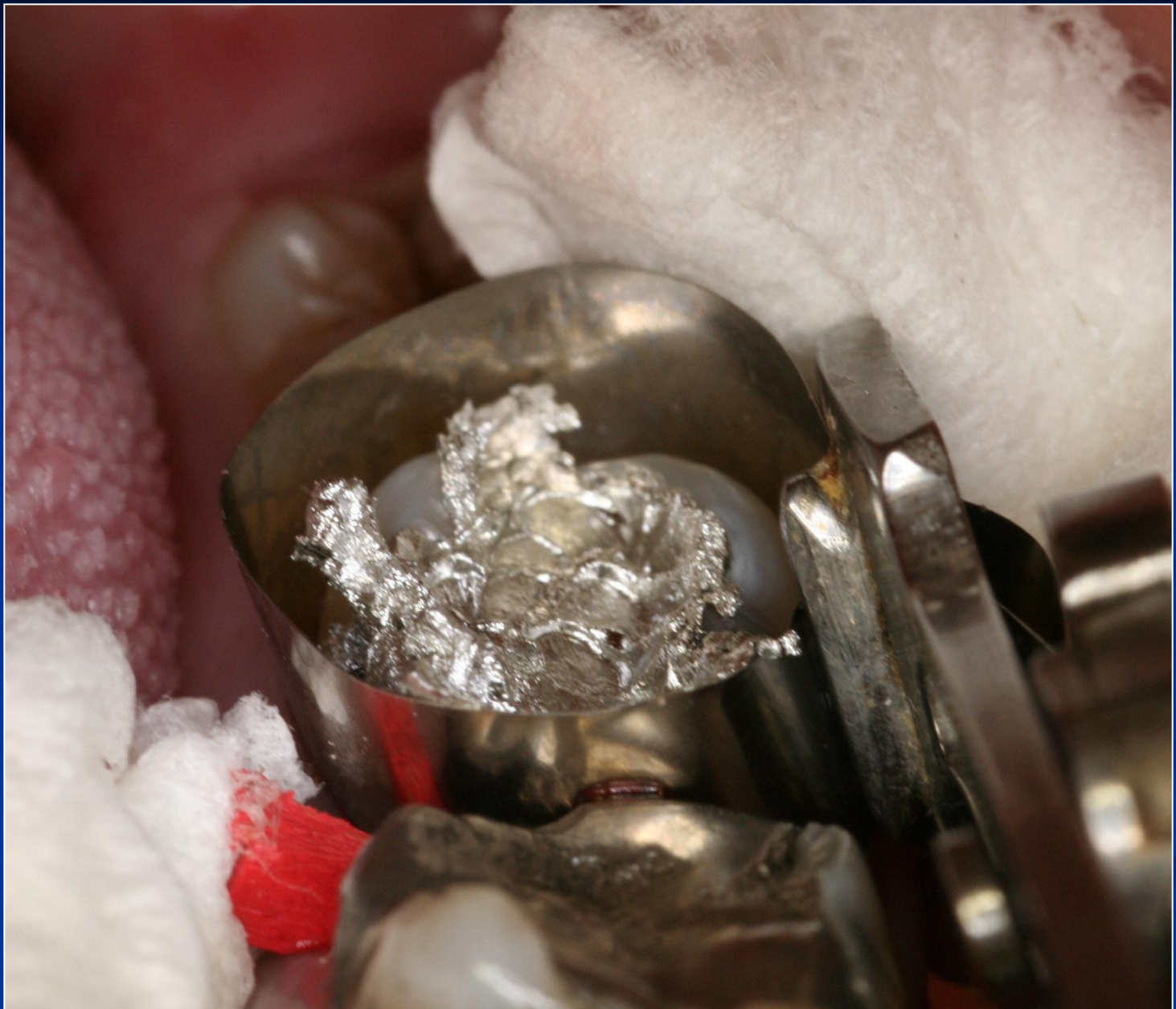


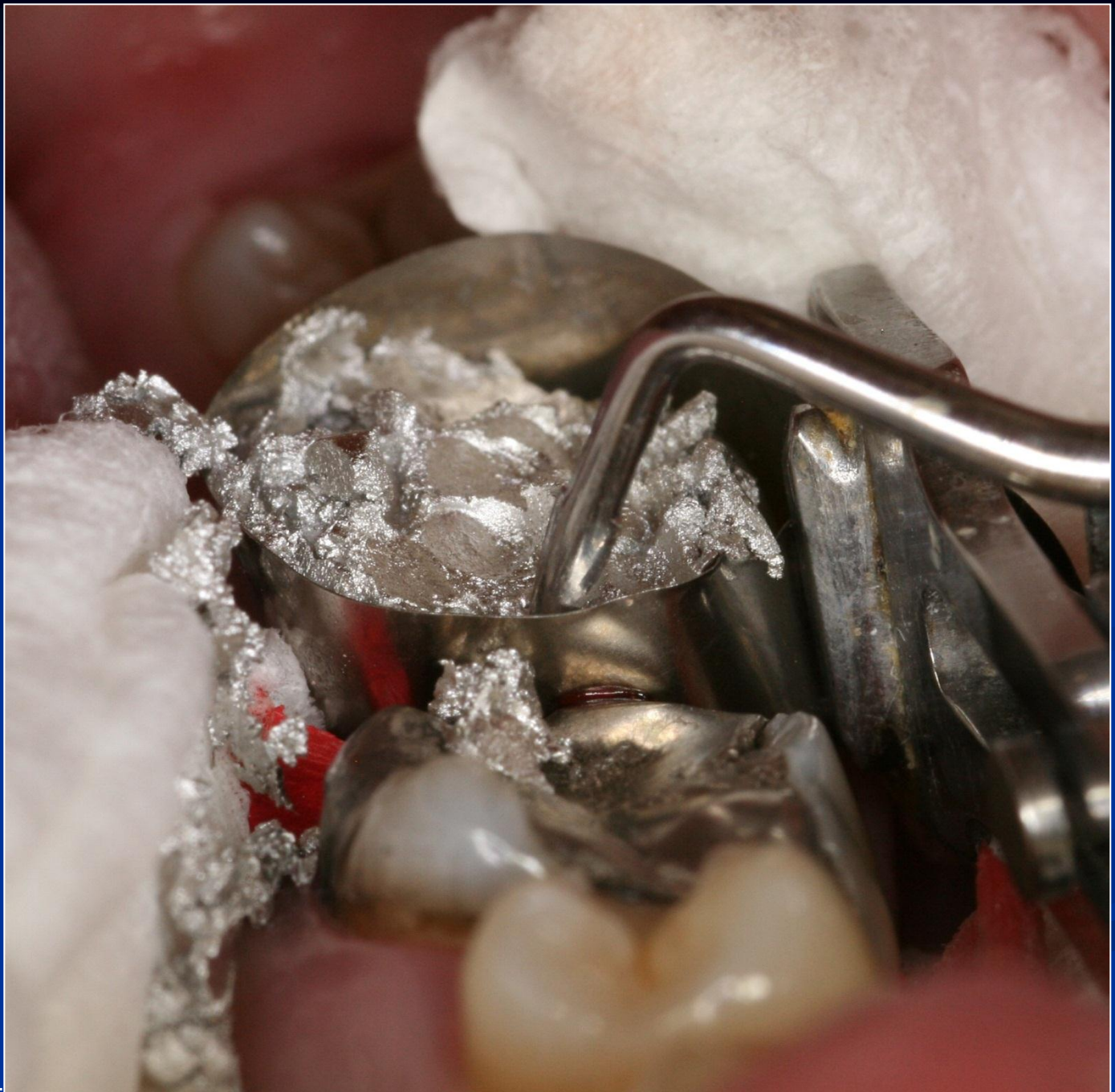


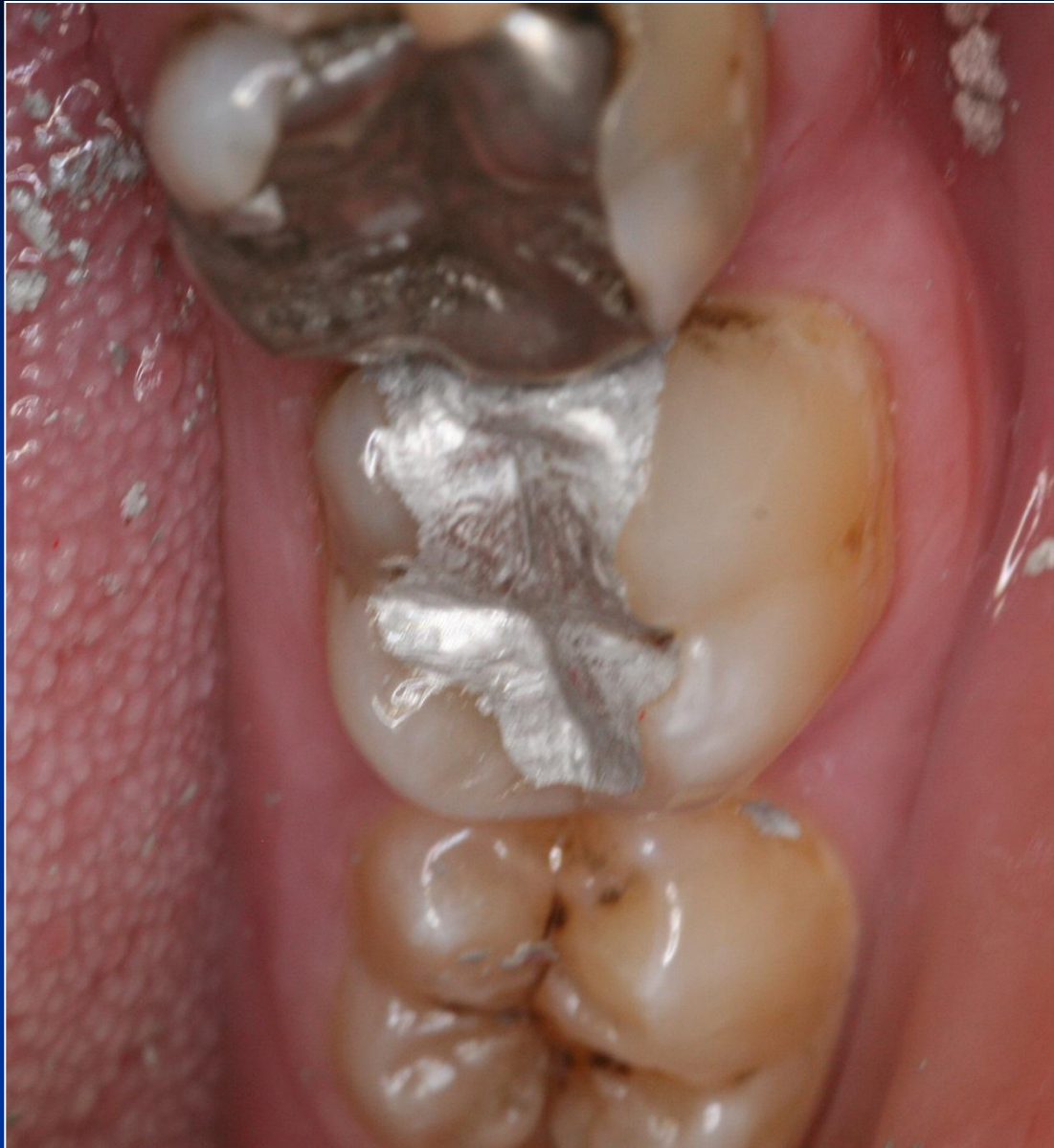





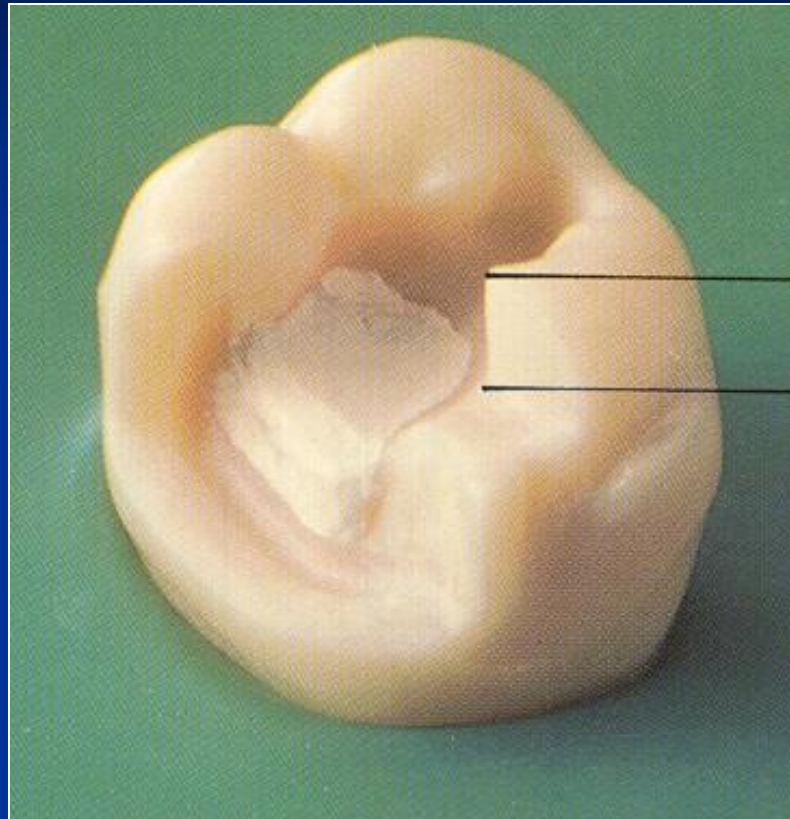


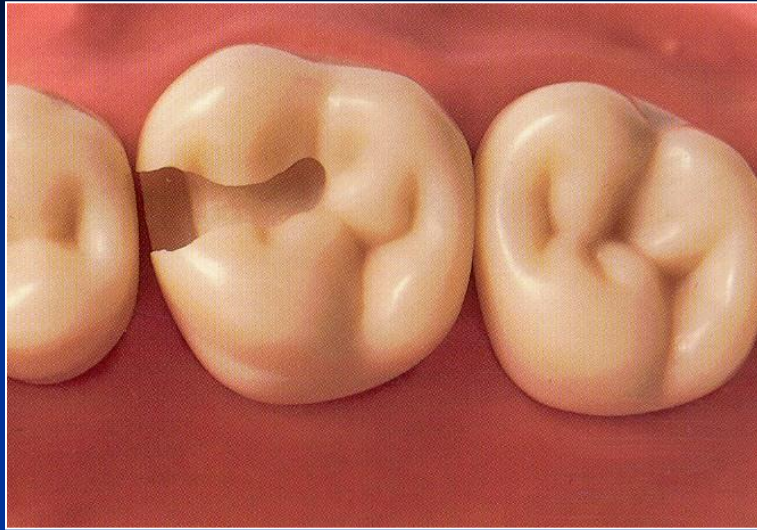


Base

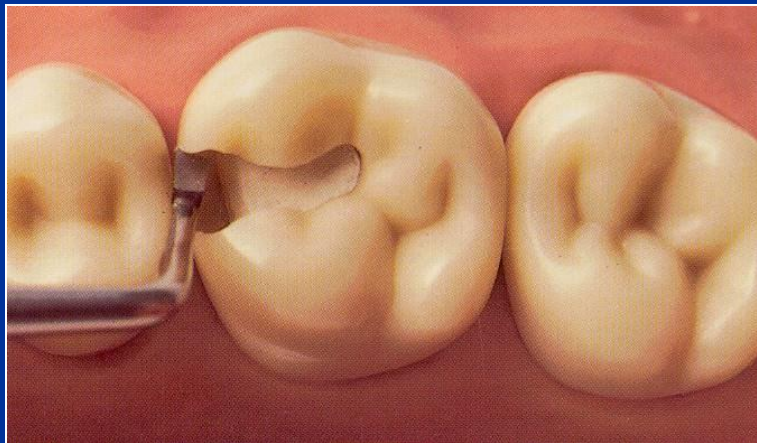
- Zinkoxidphosphate cement
- Zinkoxidkarboxylate cement
- Glass ionomer cement
- Zinkoxideugenol

On pulpal walls only!



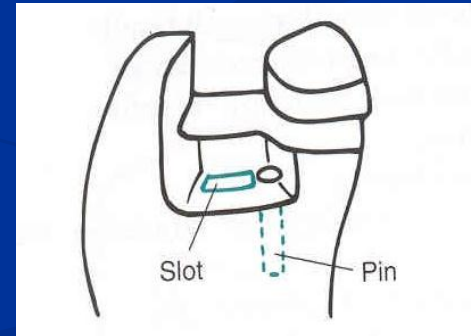
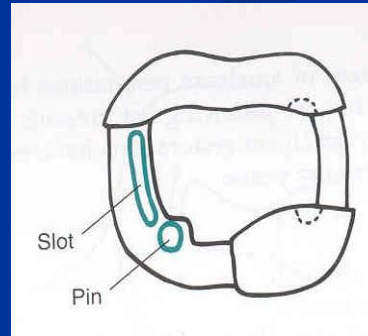
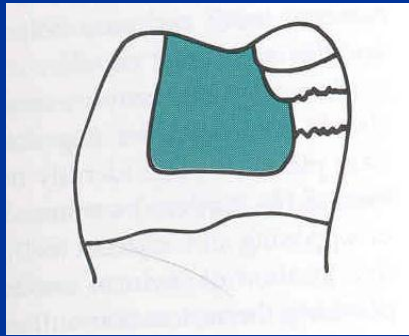
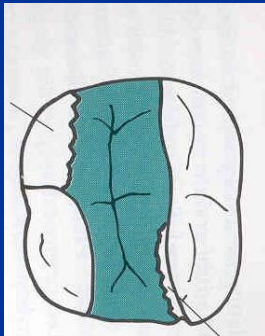


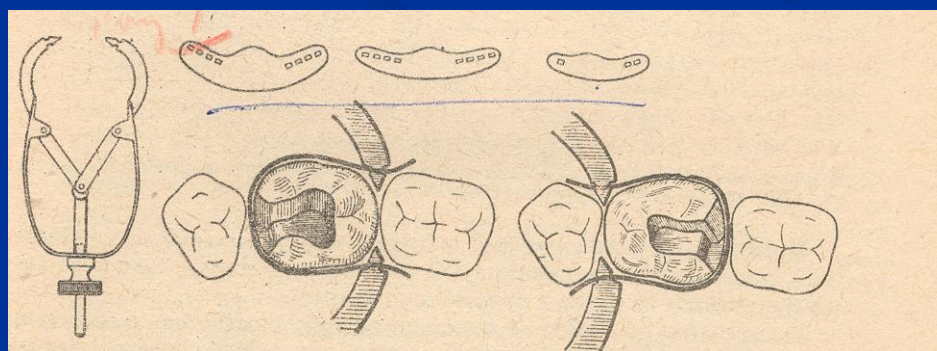
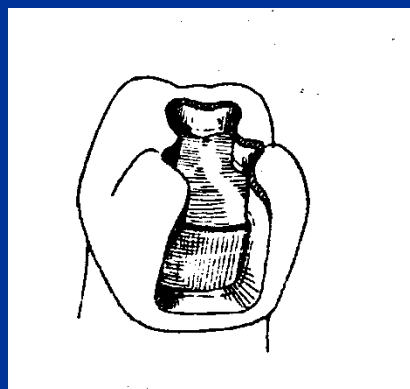
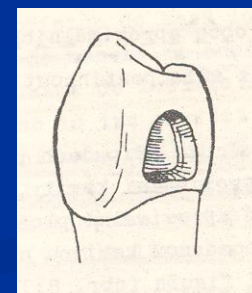
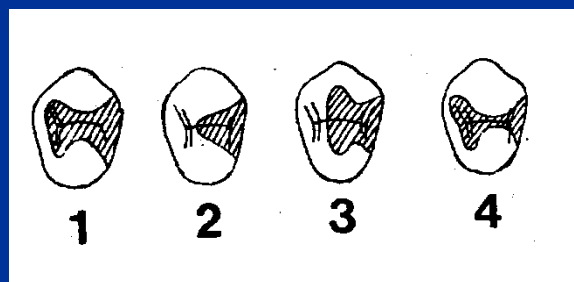
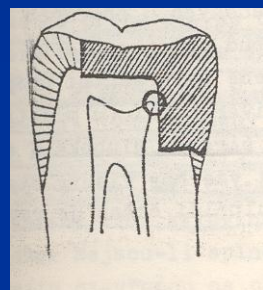
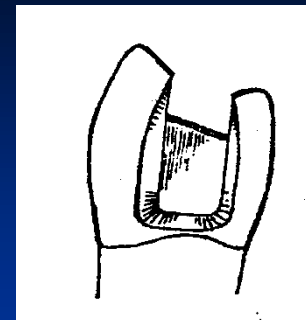
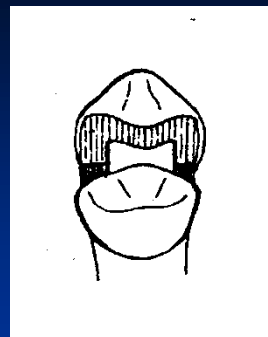
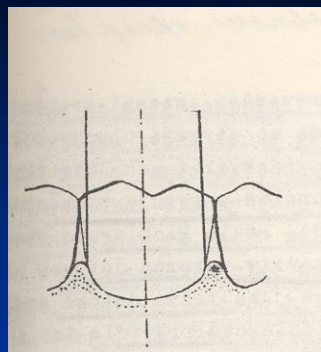
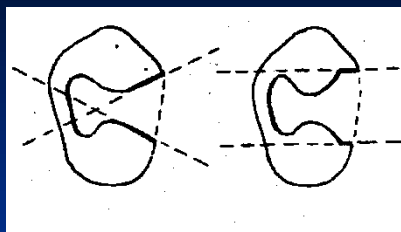
The base must be hardened

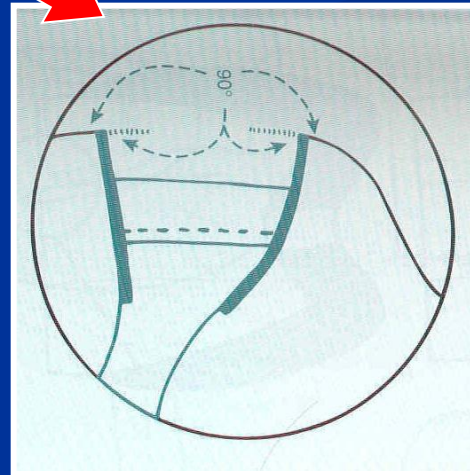
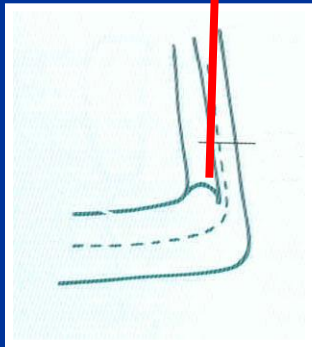
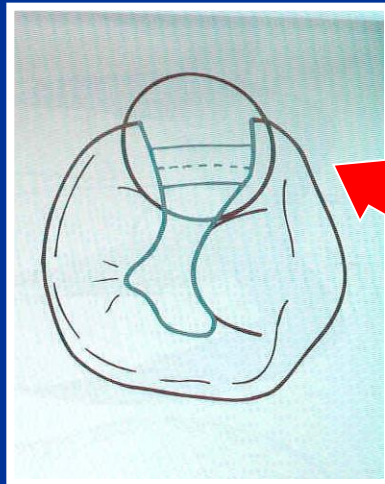
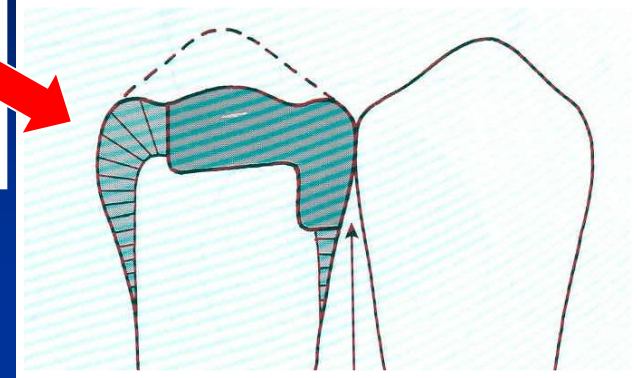
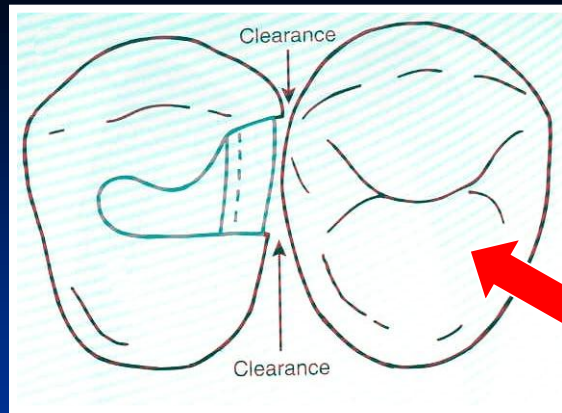
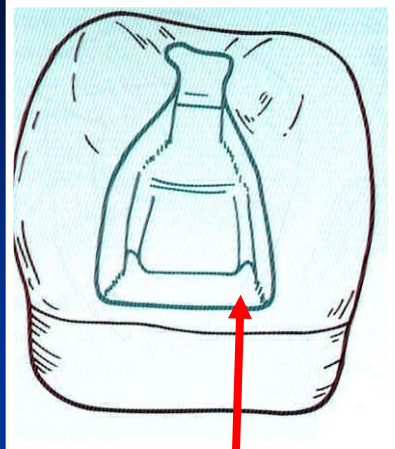


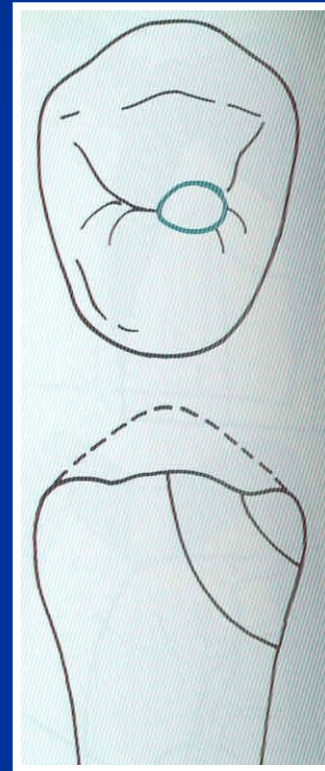
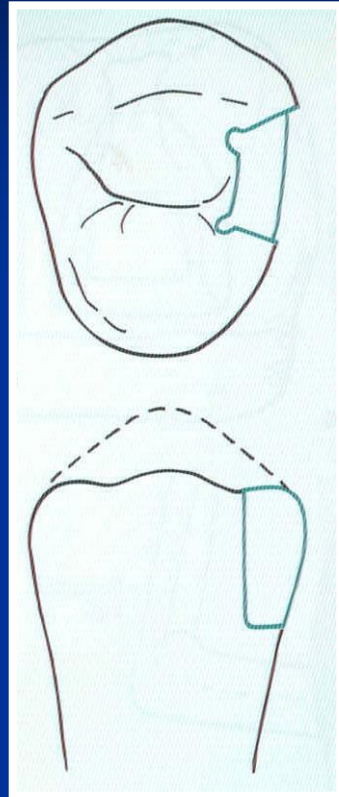
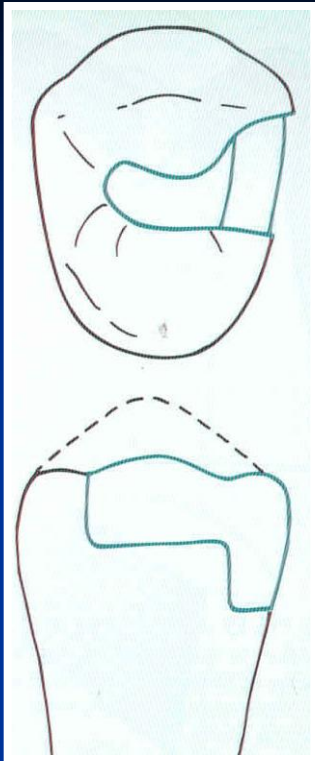
Amalgam

Retention









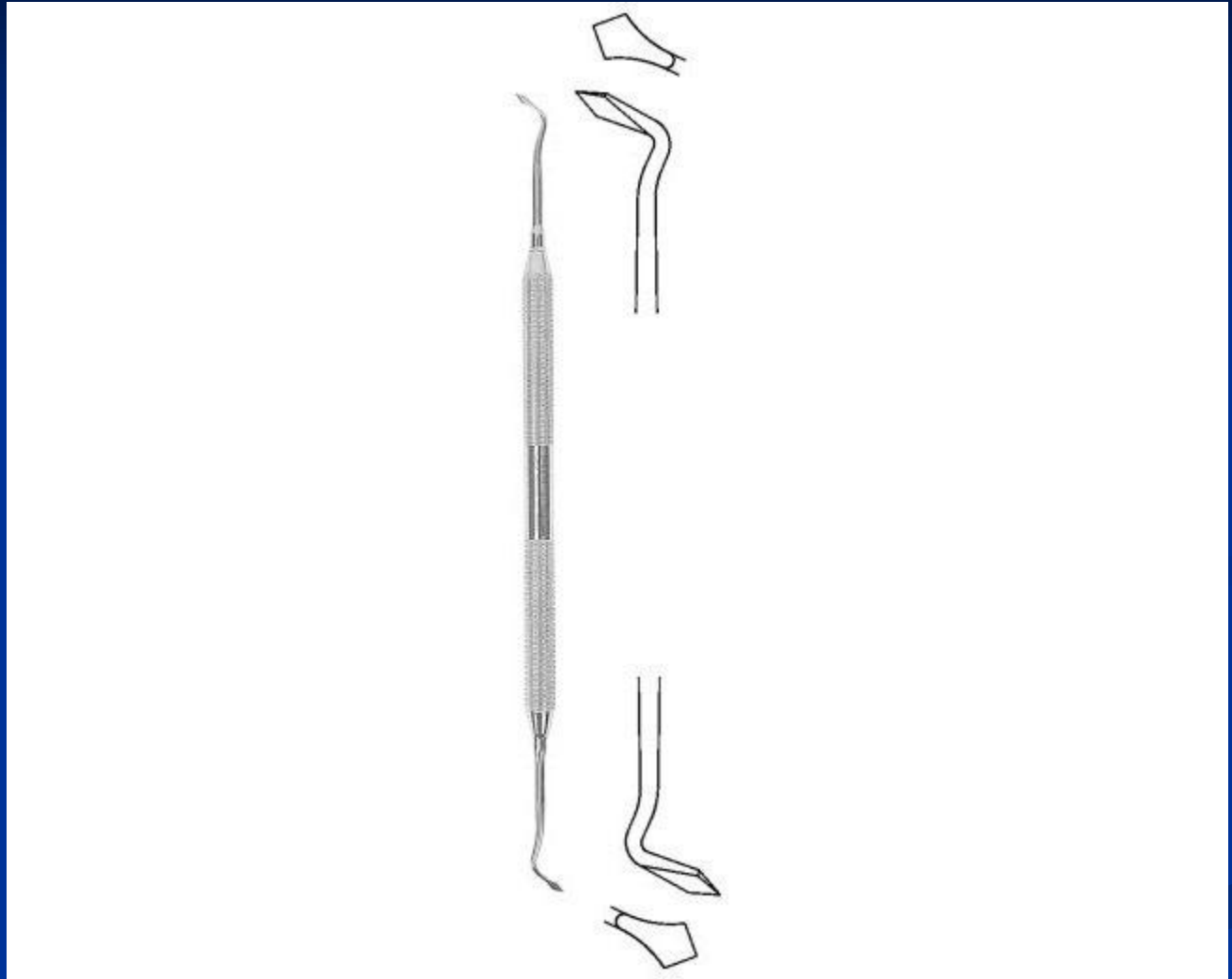
Instruments

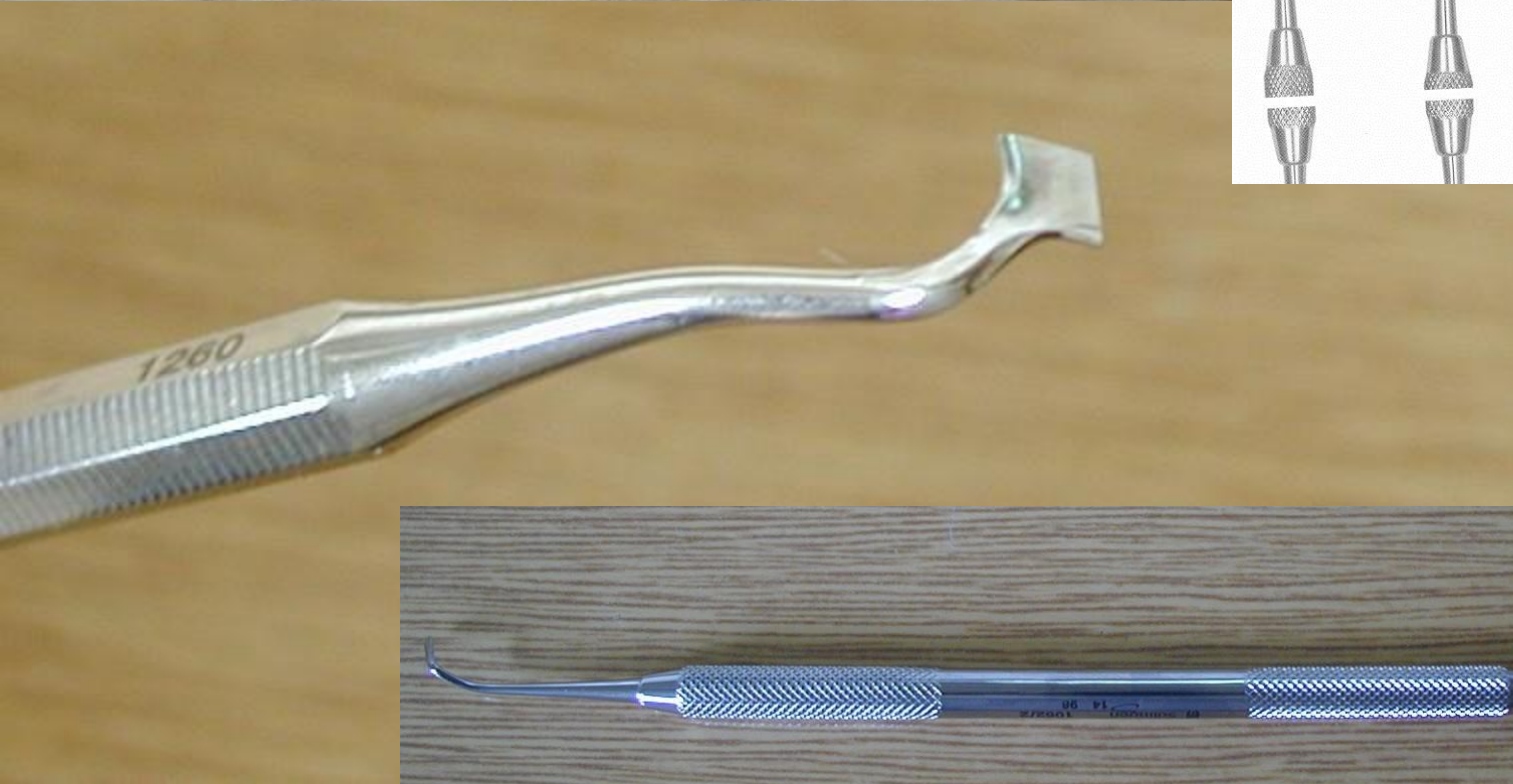
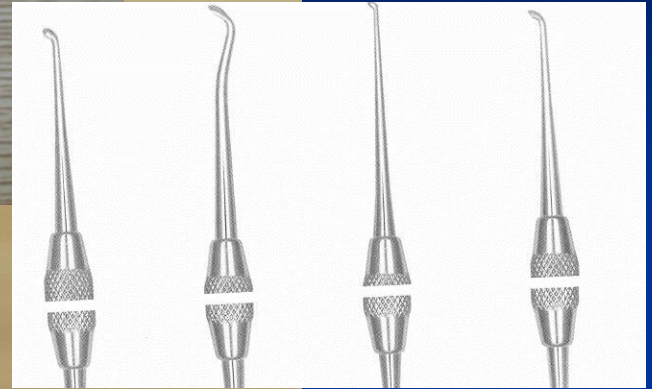
- Preparation
- Filling
- Finishing and polishing

Cpátko tyčinkové



Ořezávač -Frahm






Sapin



Discoid-cleoid



Amalgam carrier



