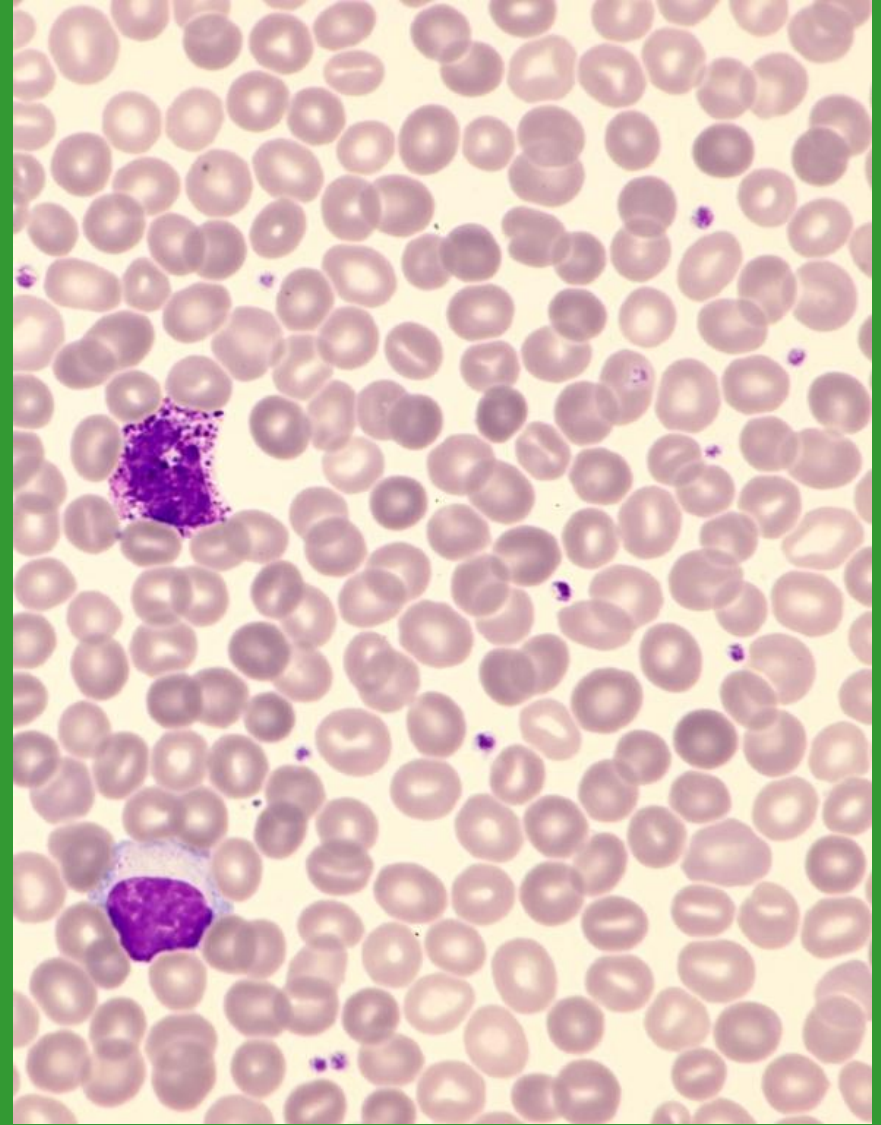
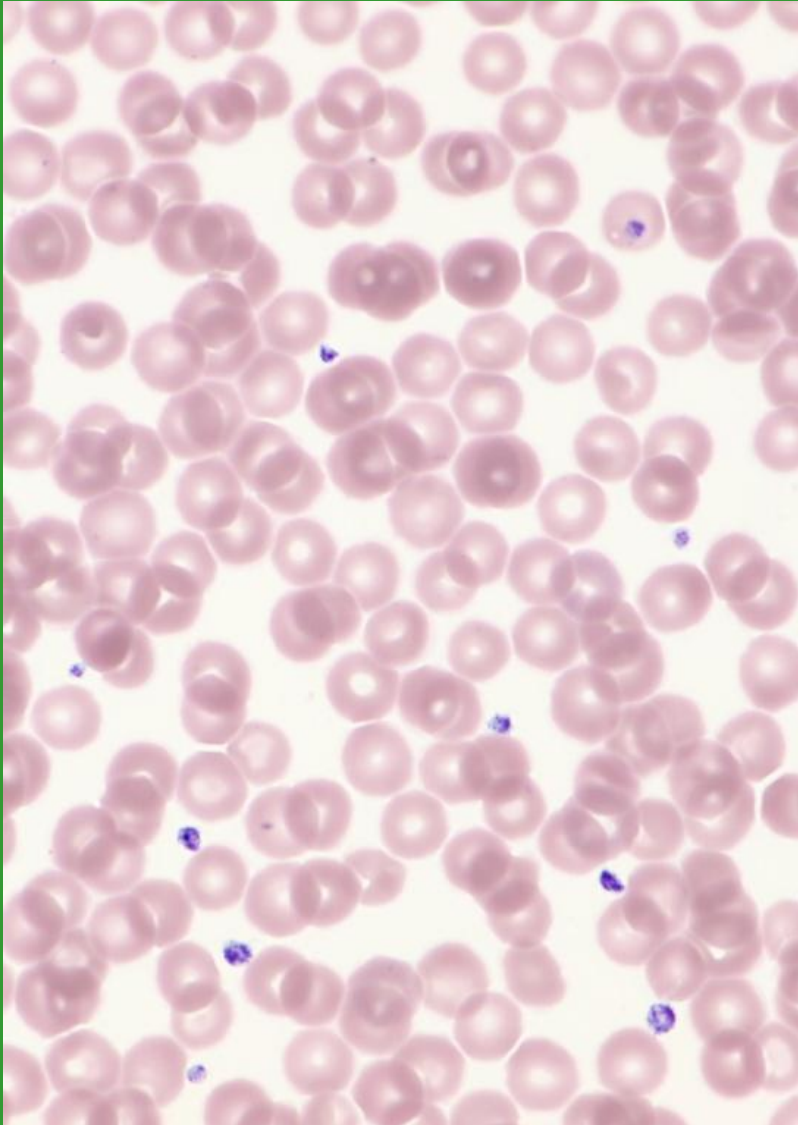


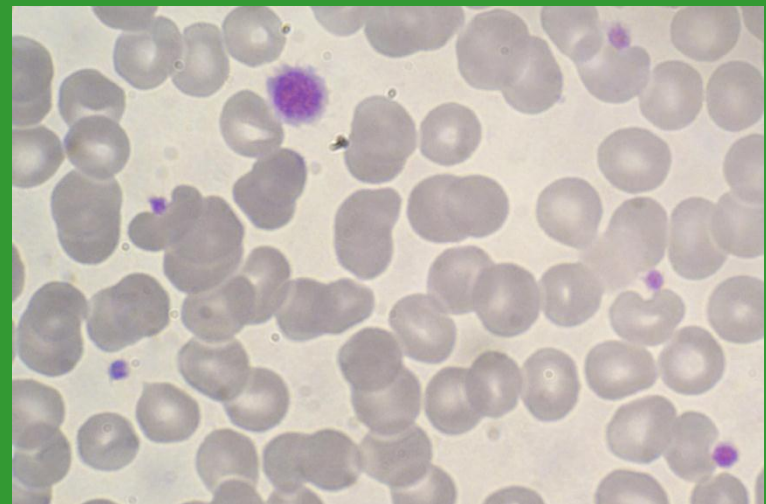
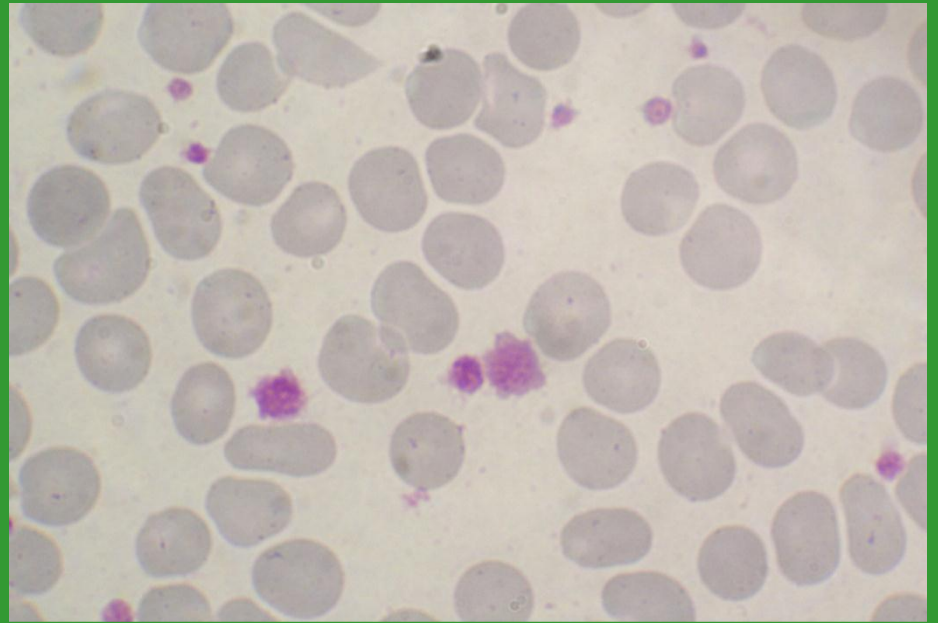
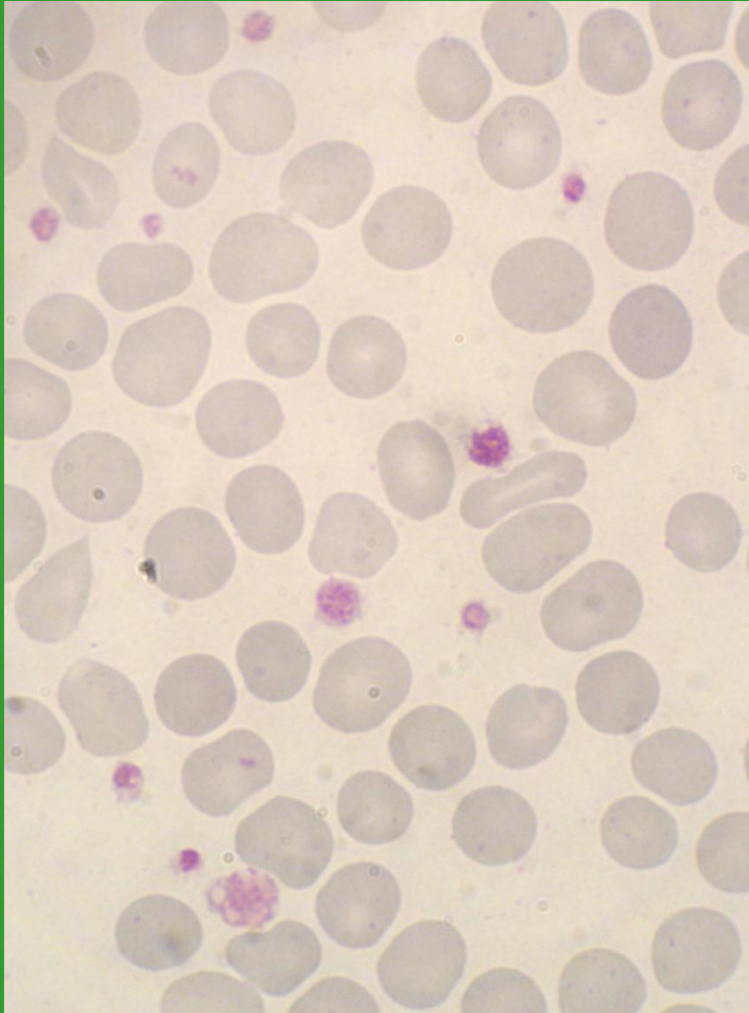
Morfologie trombocytů

Bourková L., OKH FN Brno

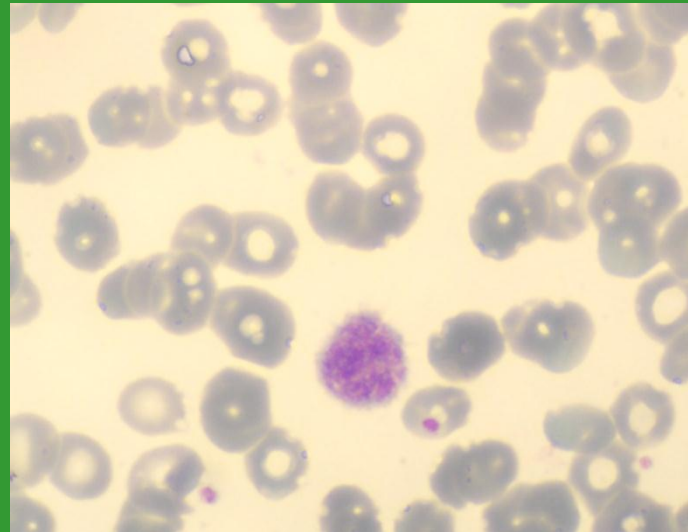
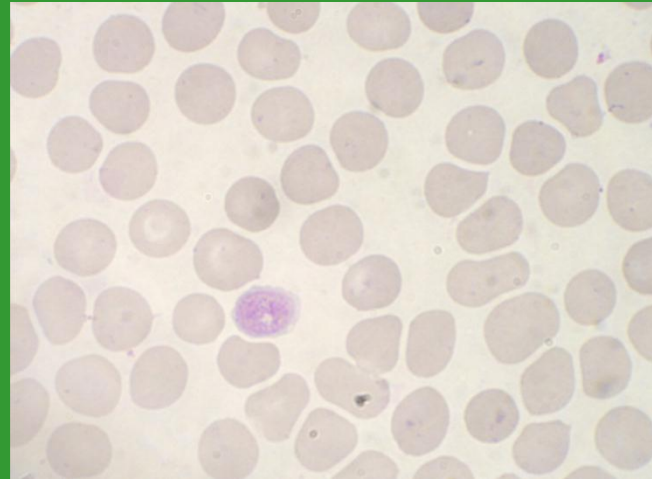
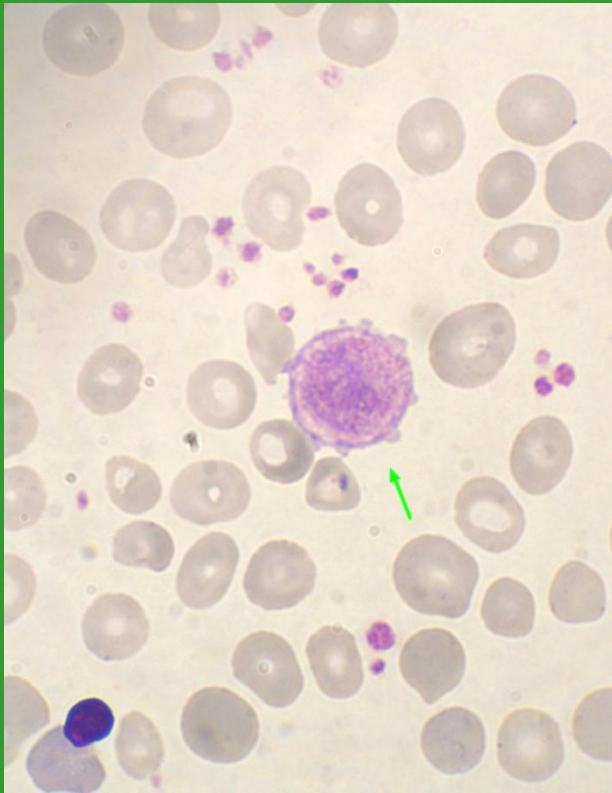
Fyziologické trombocyty



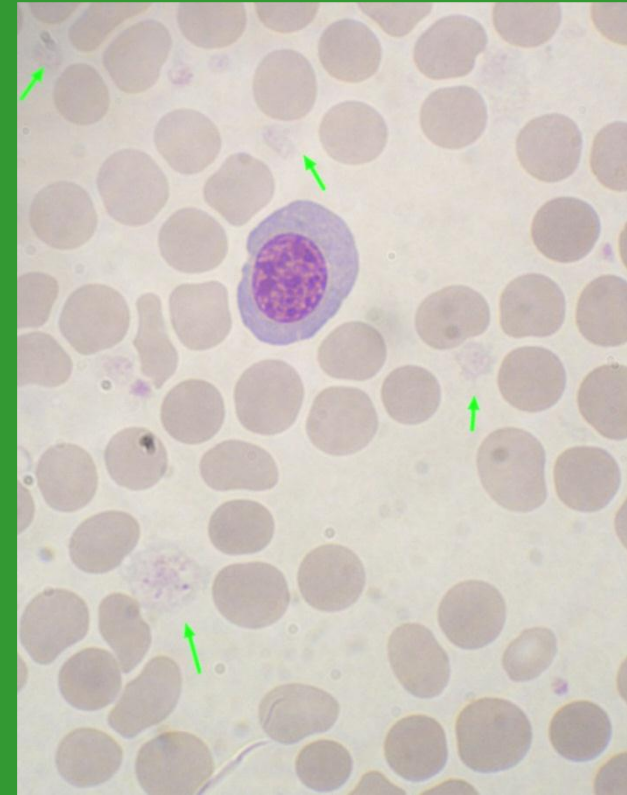
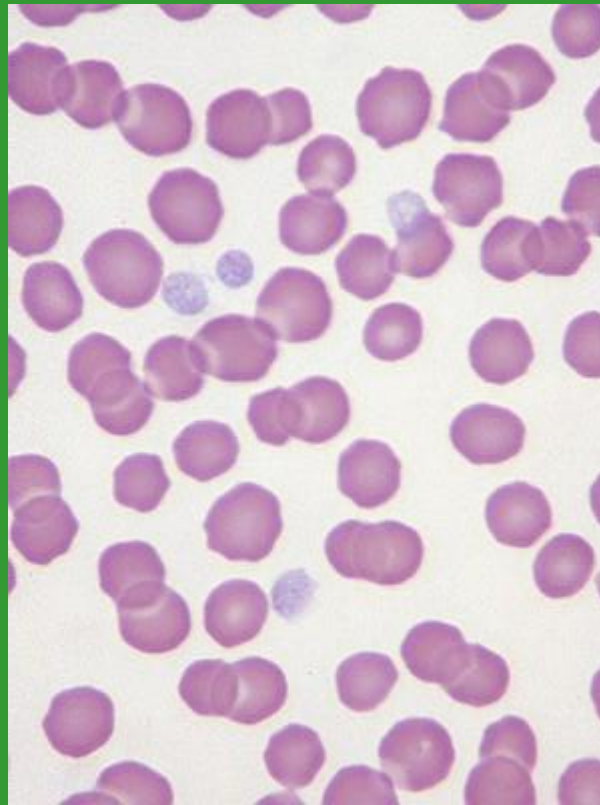
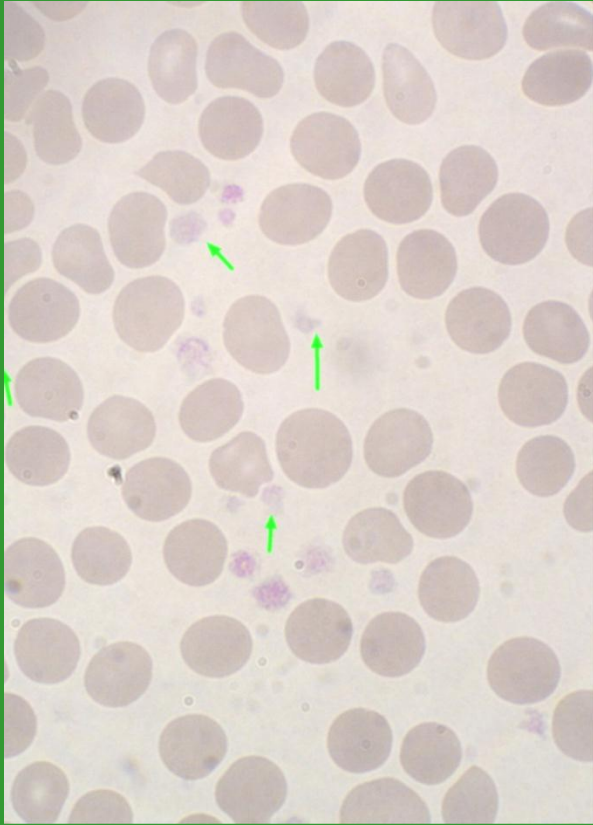
Anizocytóza trombocytů



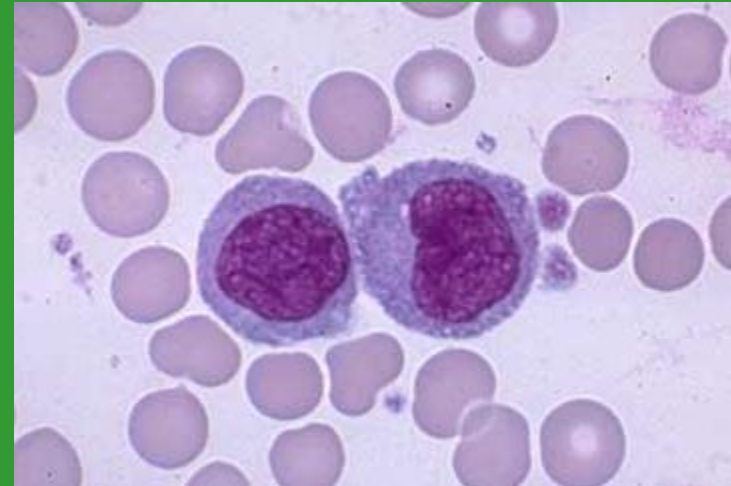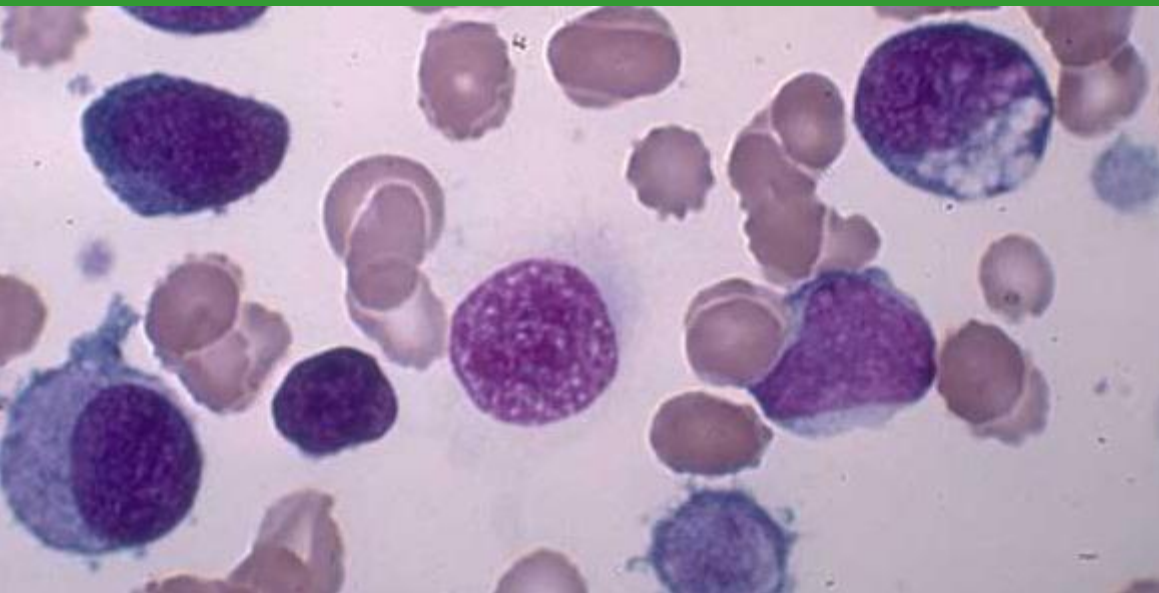
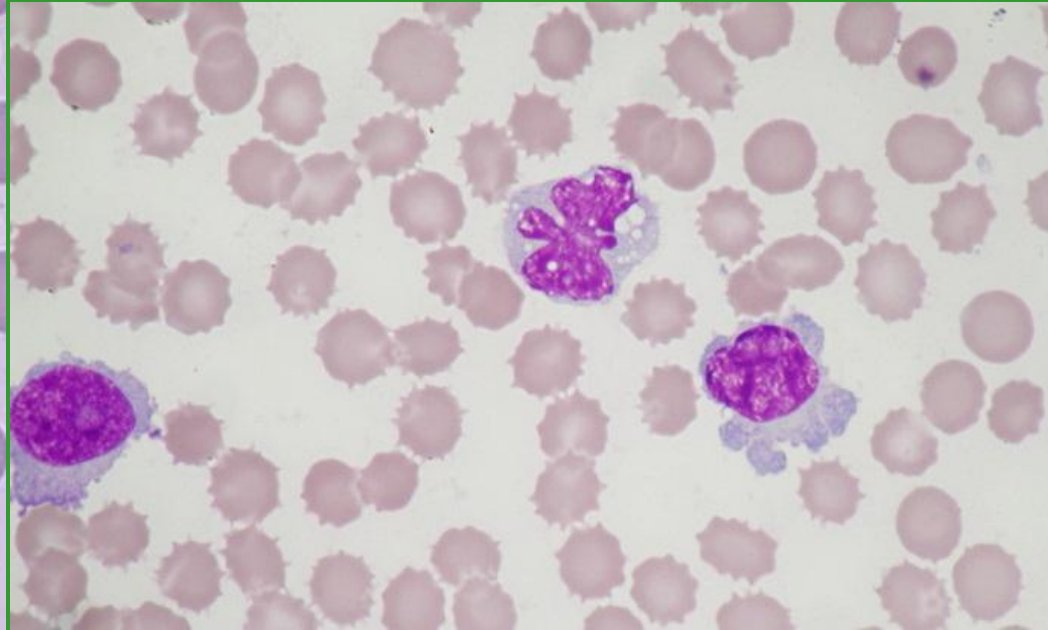
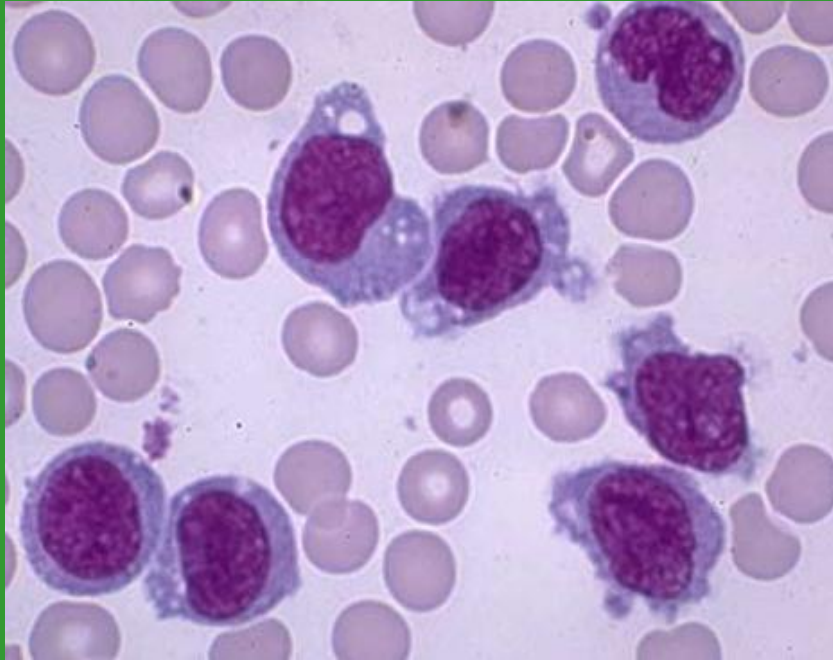
Makrotrombocyty



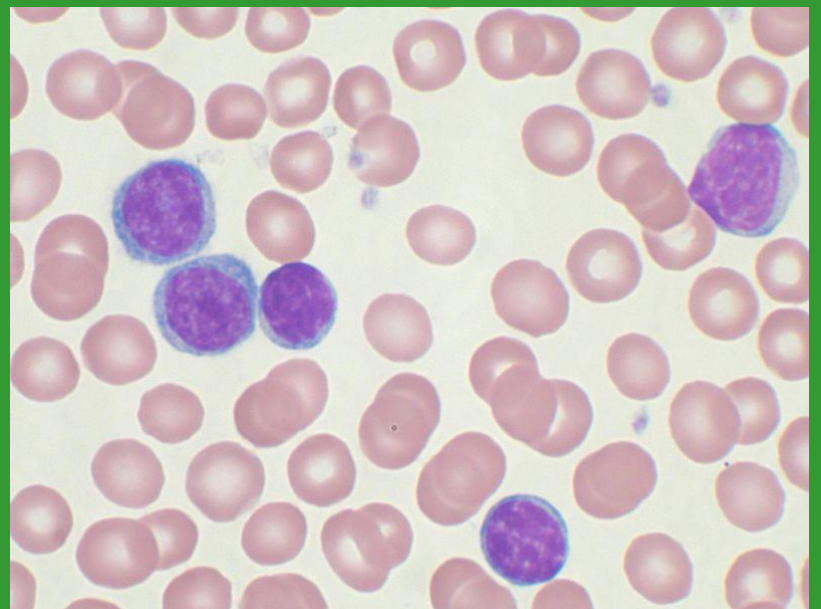
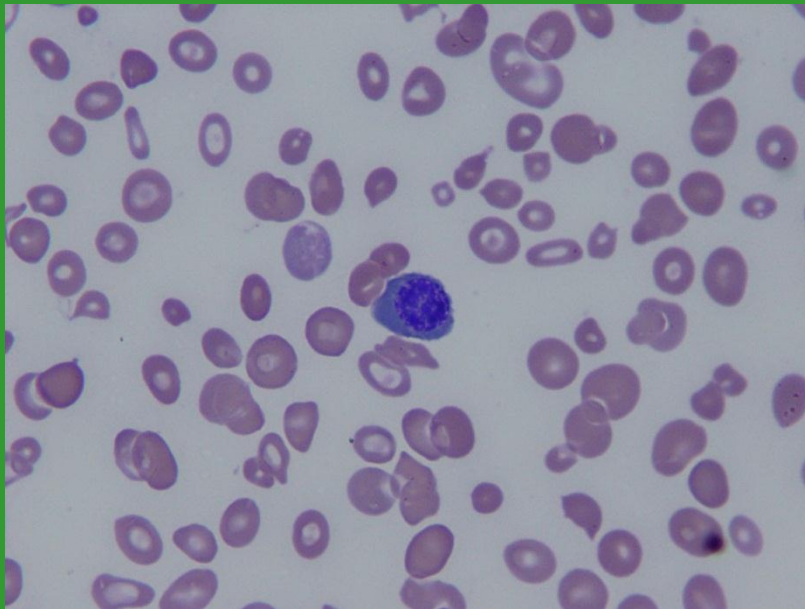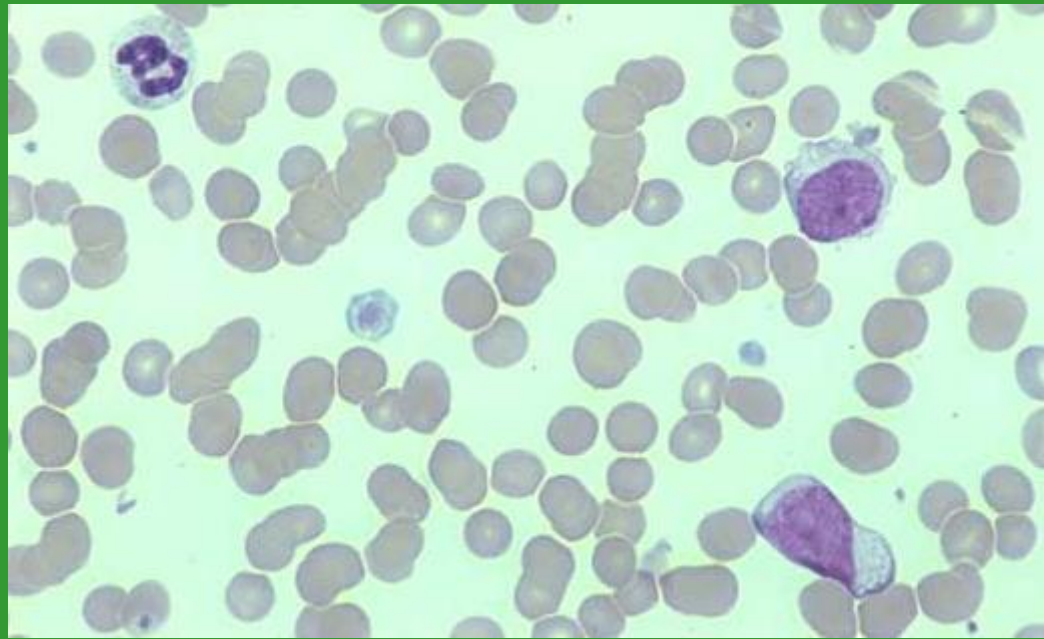
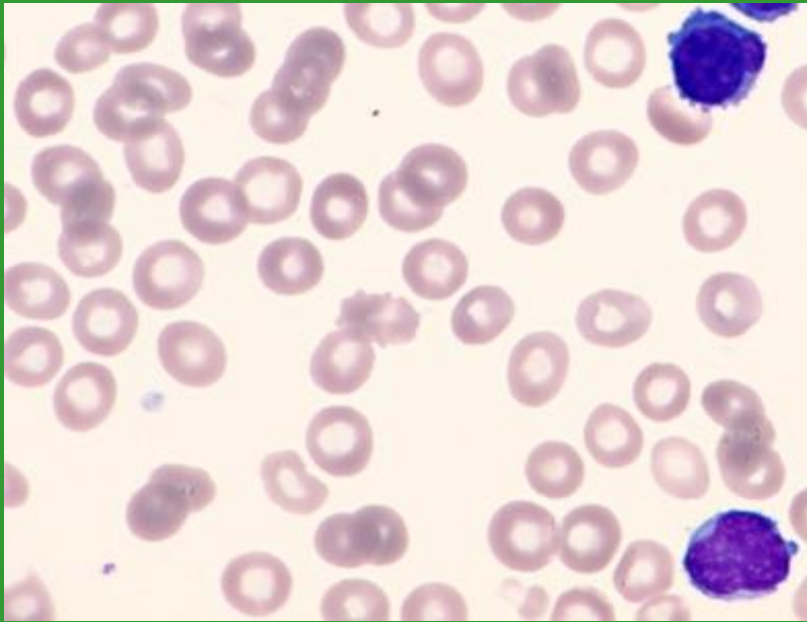
Hypogranulární trombocyty



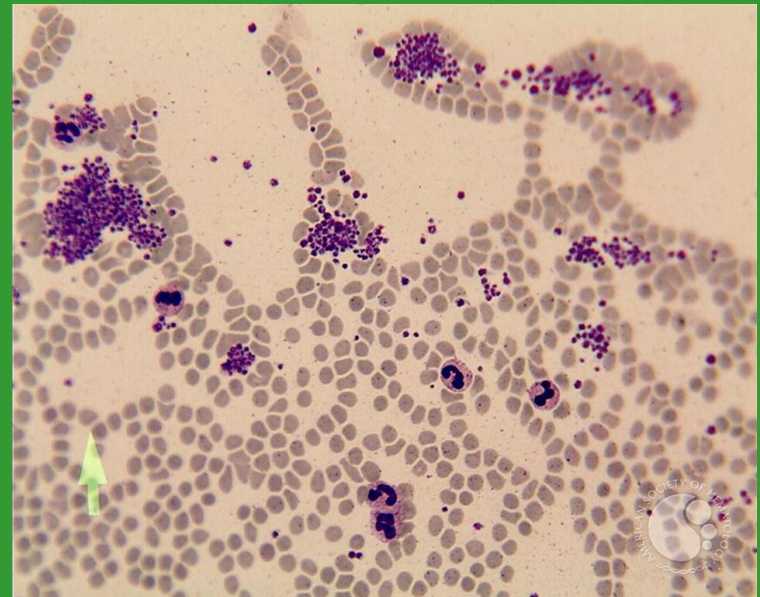
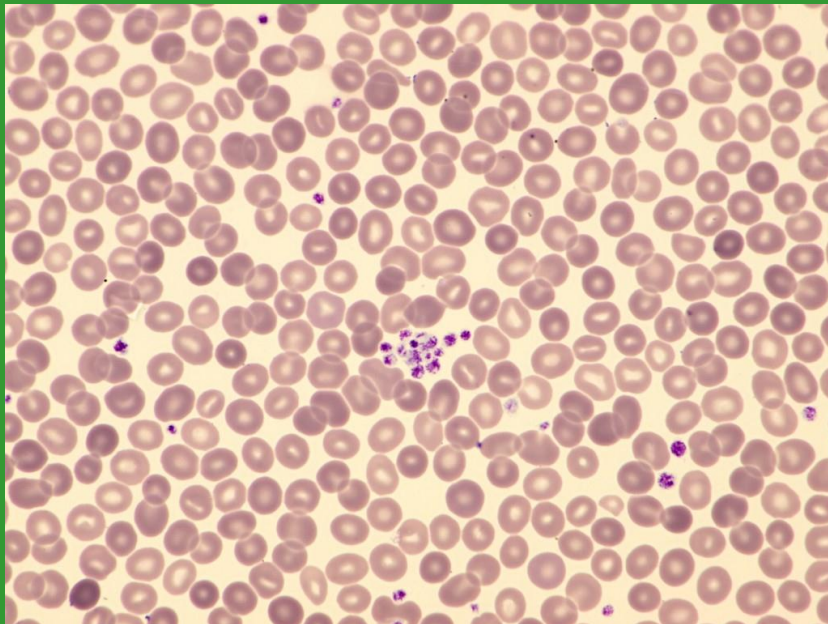
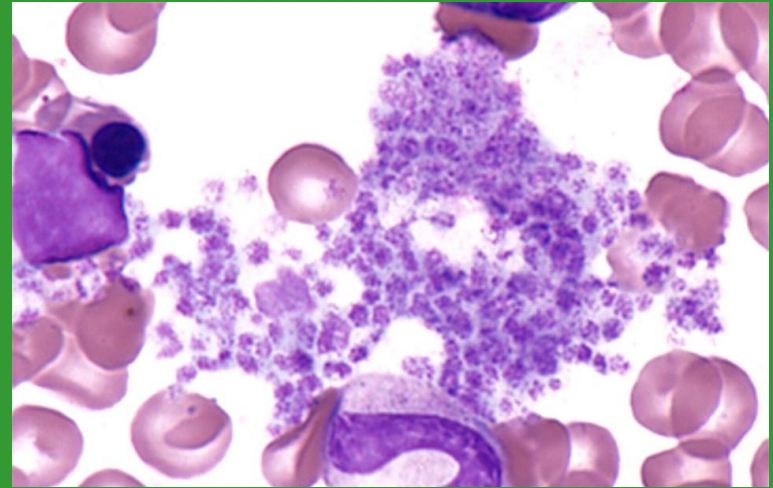
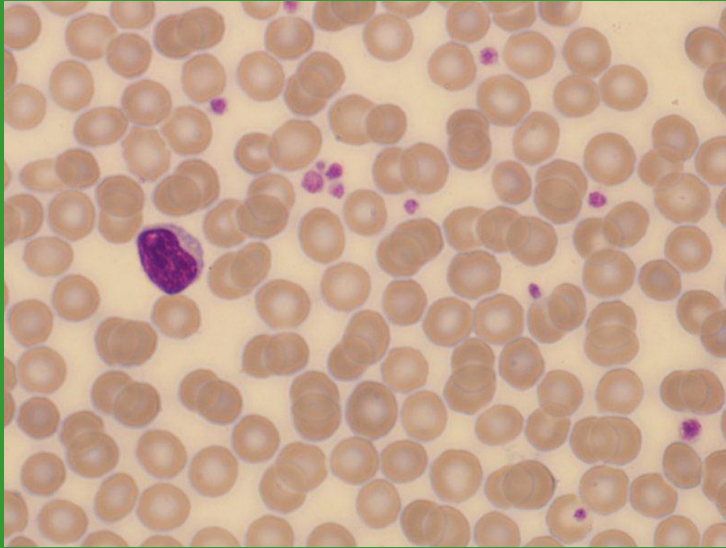
Fragmenty cytoplazmy (MGK x WBC)



PLT – hypogranulace x buněčné fragmenty x mikrocyty



Shluky/sraženiny trombocytů



Satelitismus trombocytů

