

Chyby a omyly při interpretaci UZ

V. Válek

Department of Radiology,

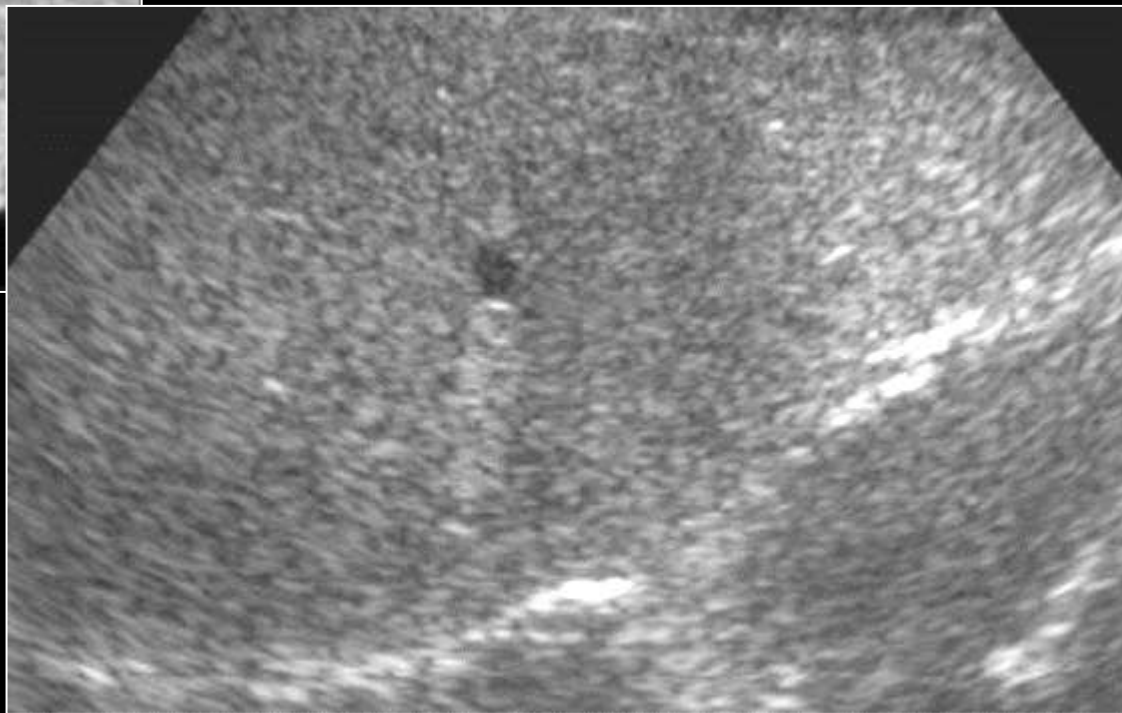
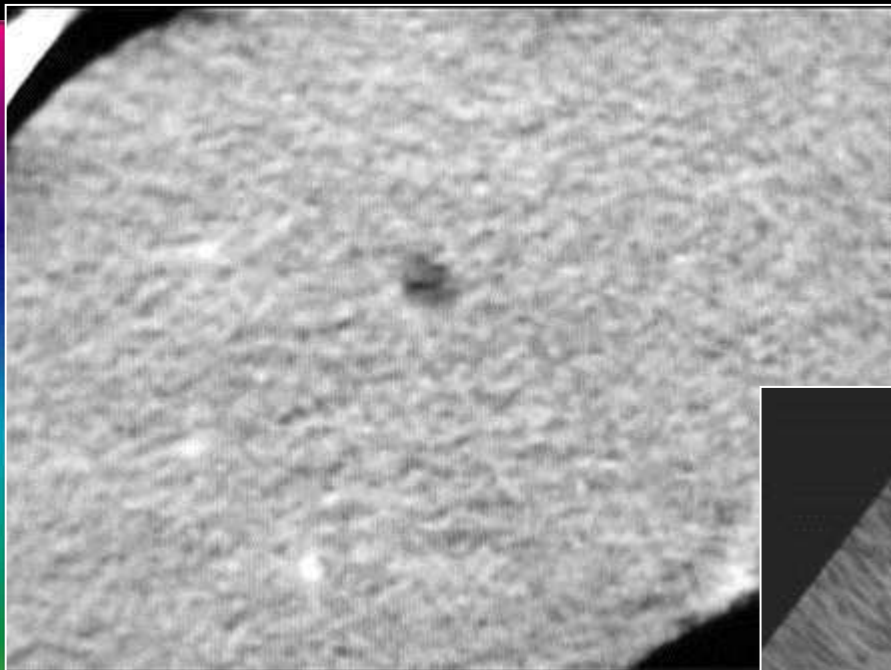
University Hospital Brno, Medical Faculty Masaryk University Brno,
Czech Rep.

Játra

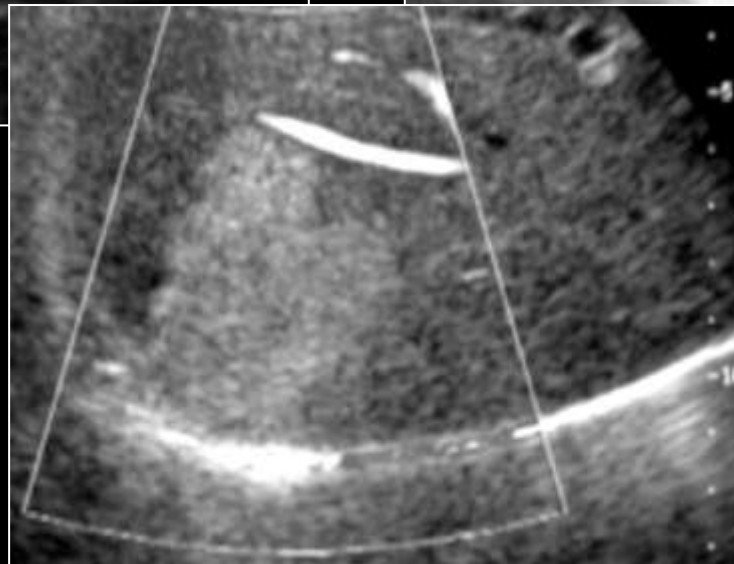
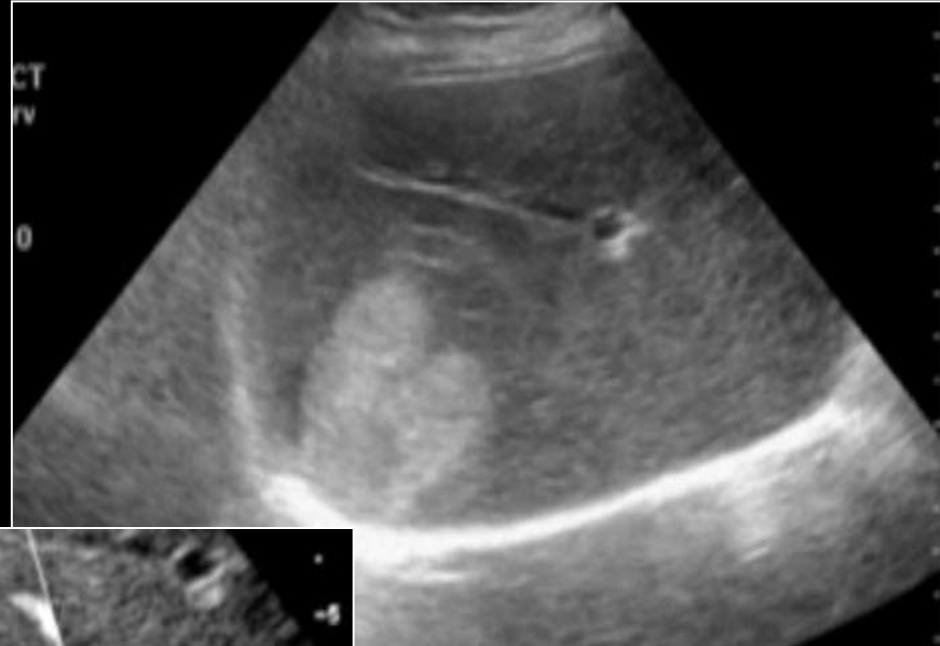
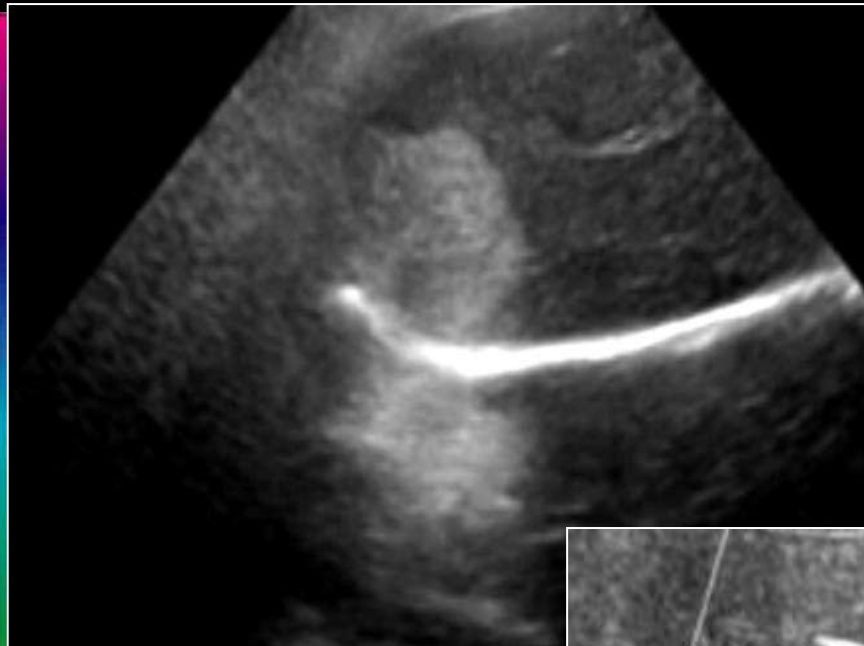Na co se soustředit - játra

- 1. Echogenita ložiska**
- 2. Echogenita jater (steatóza, cirhóza)**
- 3. Dorzální zesílení či zeslabení**
- 4. Lem**
- 5. Sycení**
- 6. Anamnéza – známá malignita**

???



???



Na co se soustředit - játra

1. Věk (starší malignita)

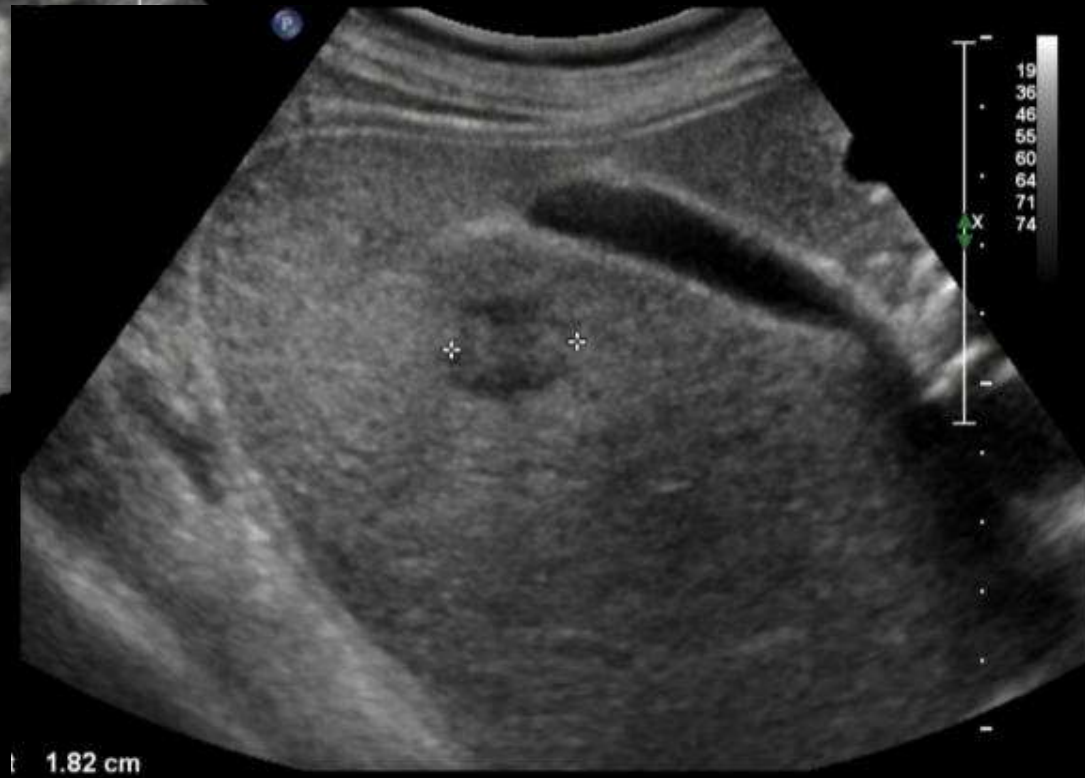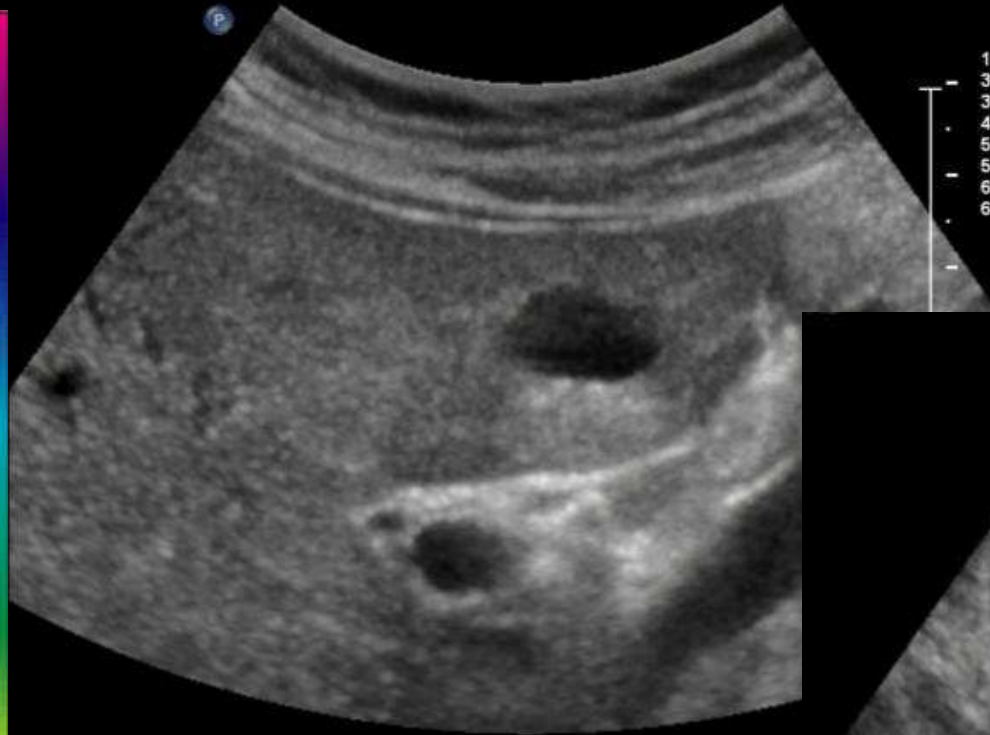2. Klinika (bolest, akutní projevy, ikterus)

**3. Laboratoř (AST, ALT, GMT, Bili, FW)
moc nepomůže – pozor ale na AFP
onkomarkery a anamnézu cirhózy a
hepatitidy**

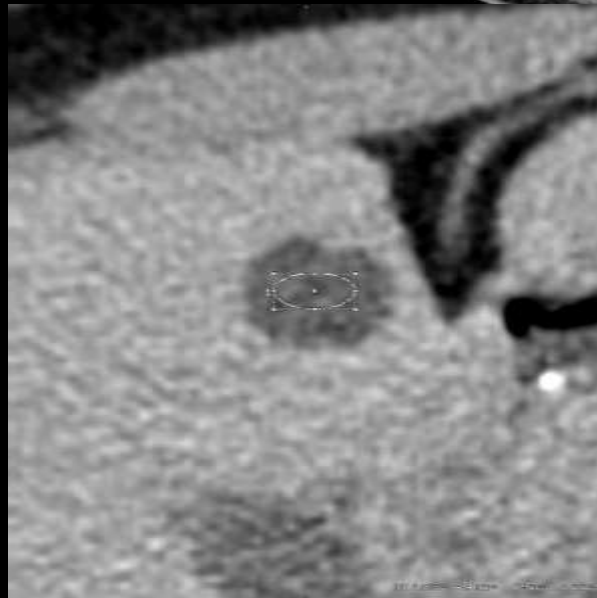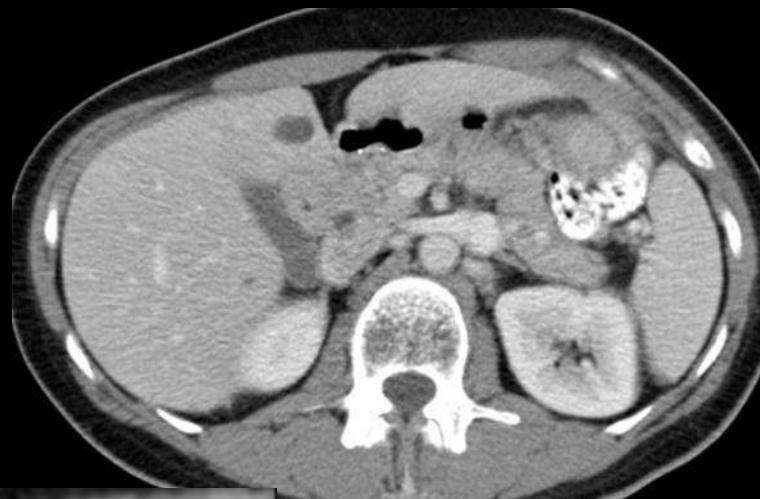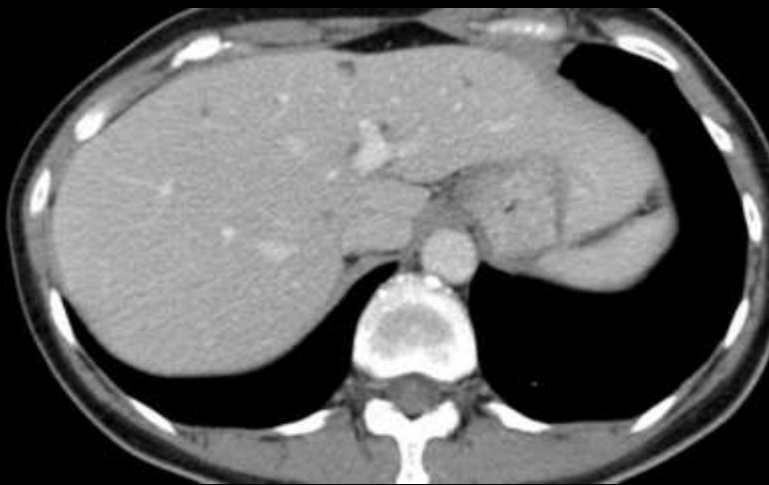Na co se soustředit

Žena, tu střeva, sledovaná rok, roč. 67, stav před rokem po hemikolektomii.

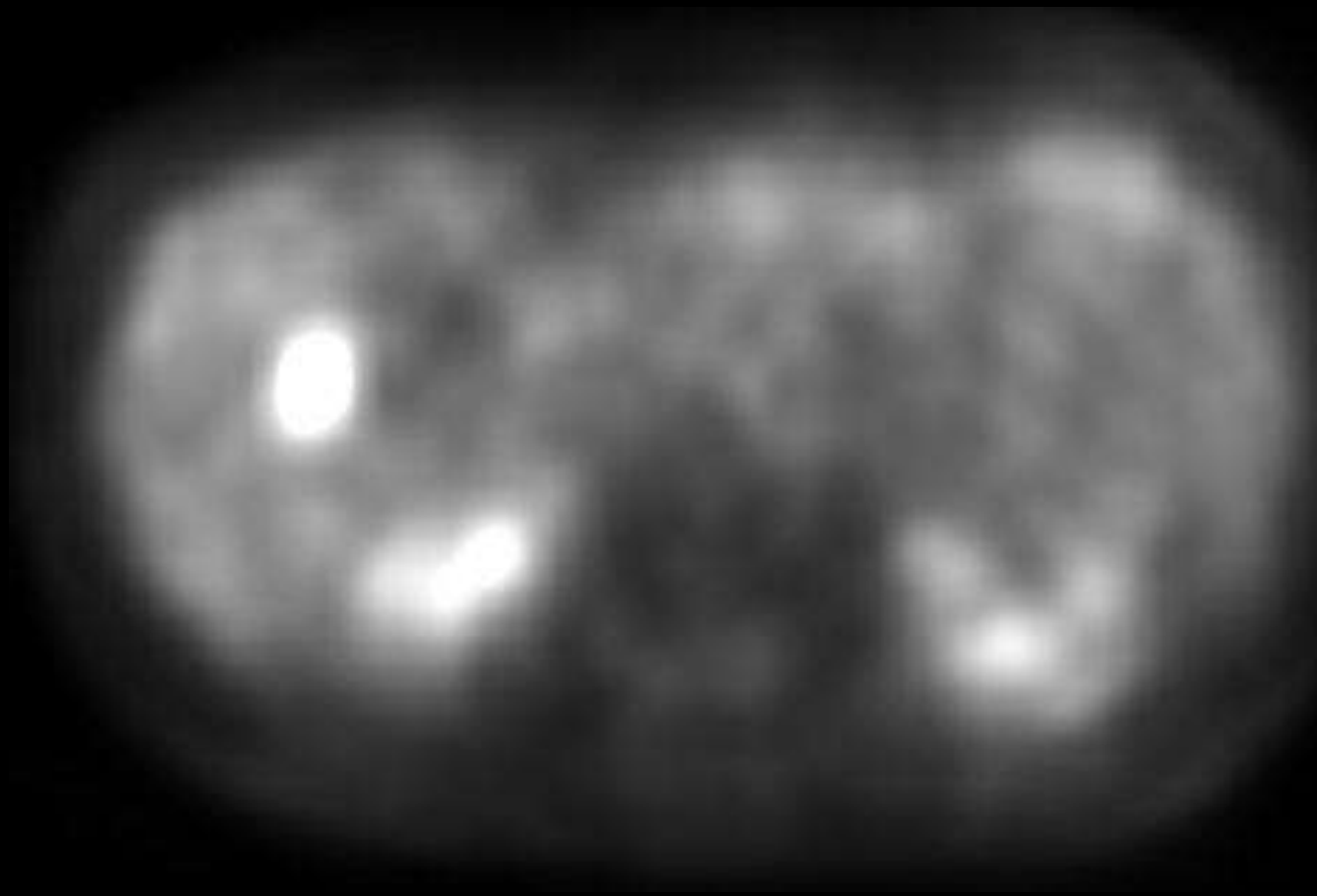
Cysta??



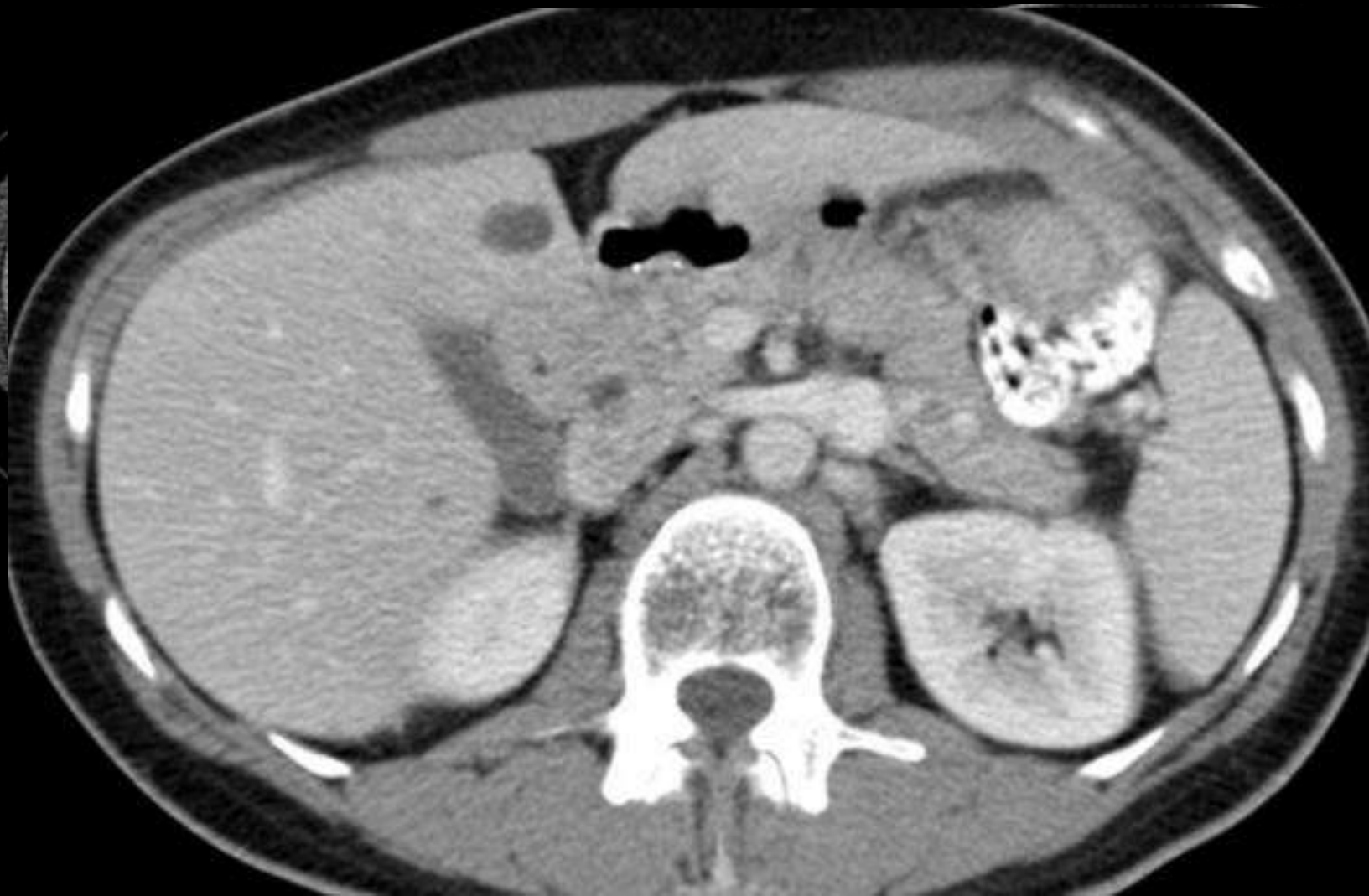Cysta ???



Cysta ???



Cysta ???



Cysta???

R1

Tissue

66%

C 42

Gen

MIO.04

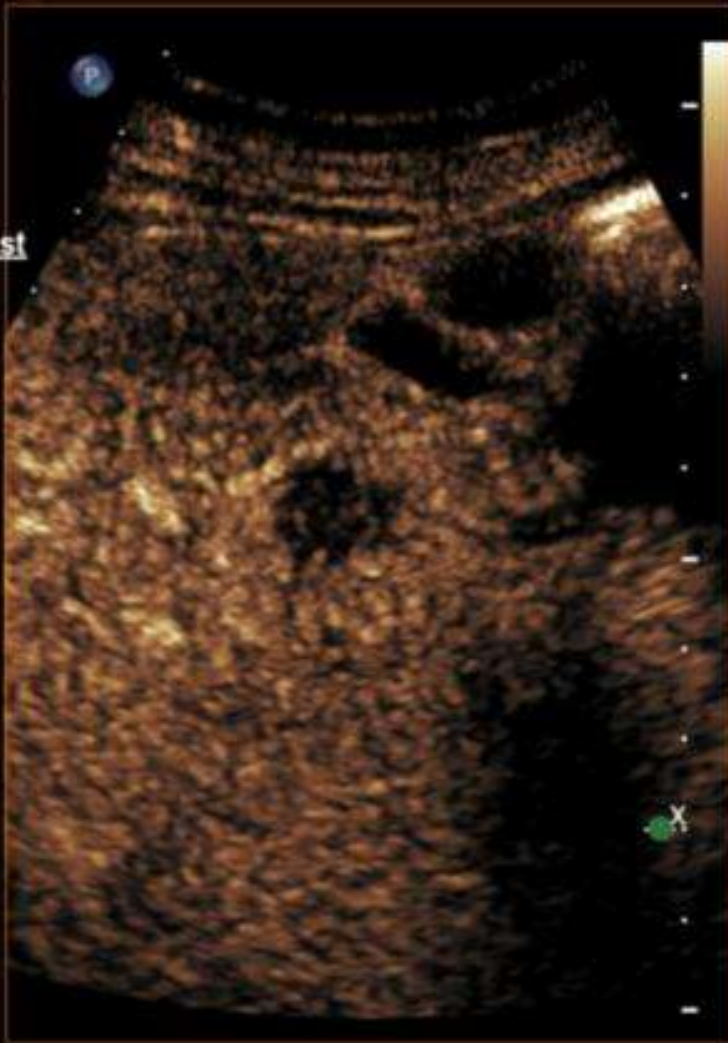Contrast

79%

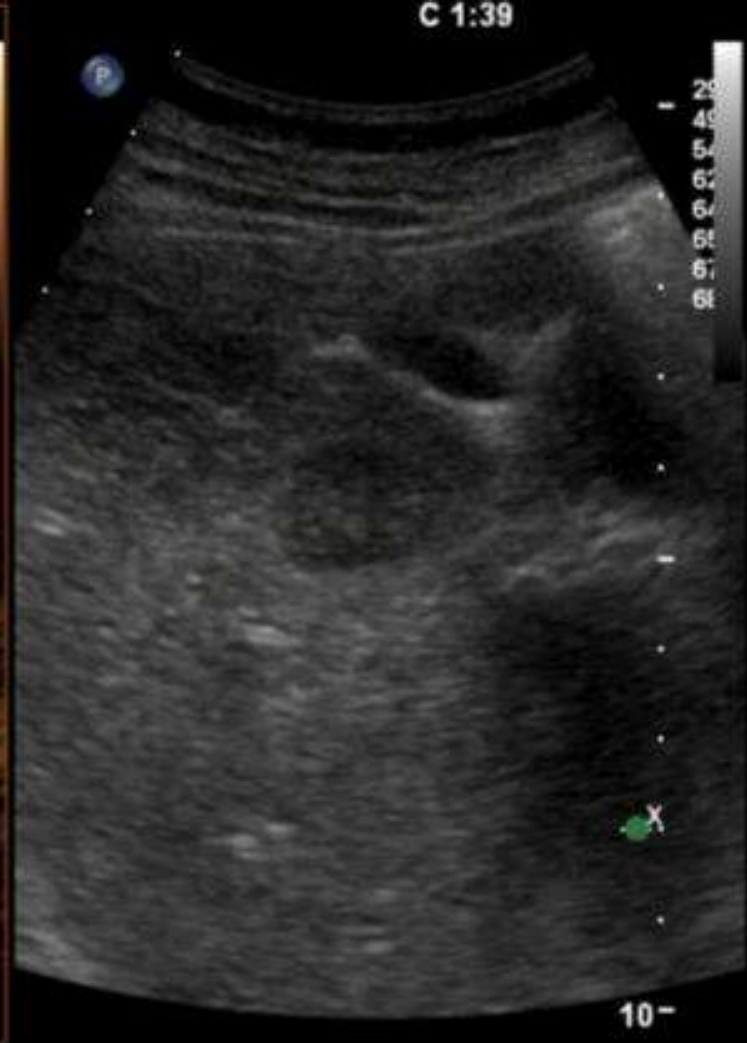C 38

CGen

MIO.06



C 1:39

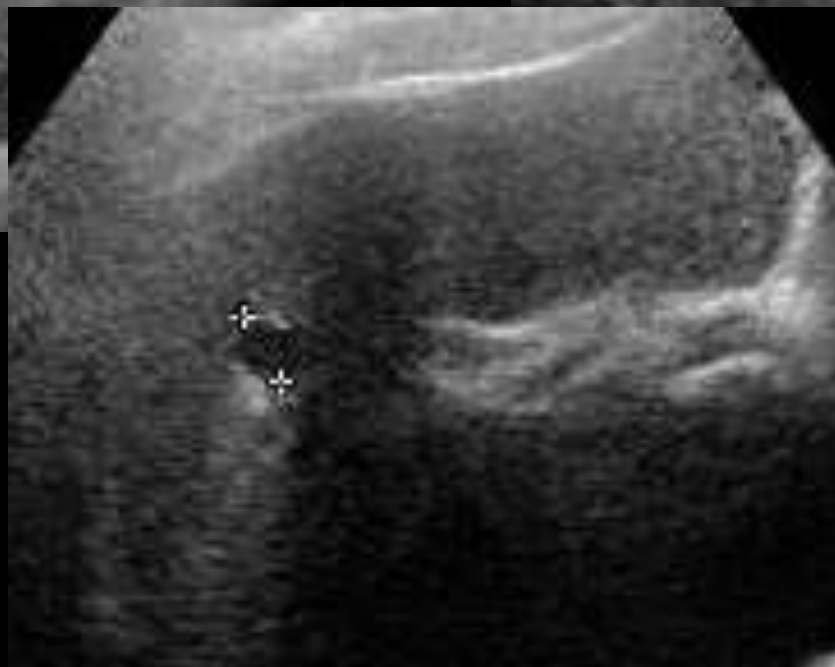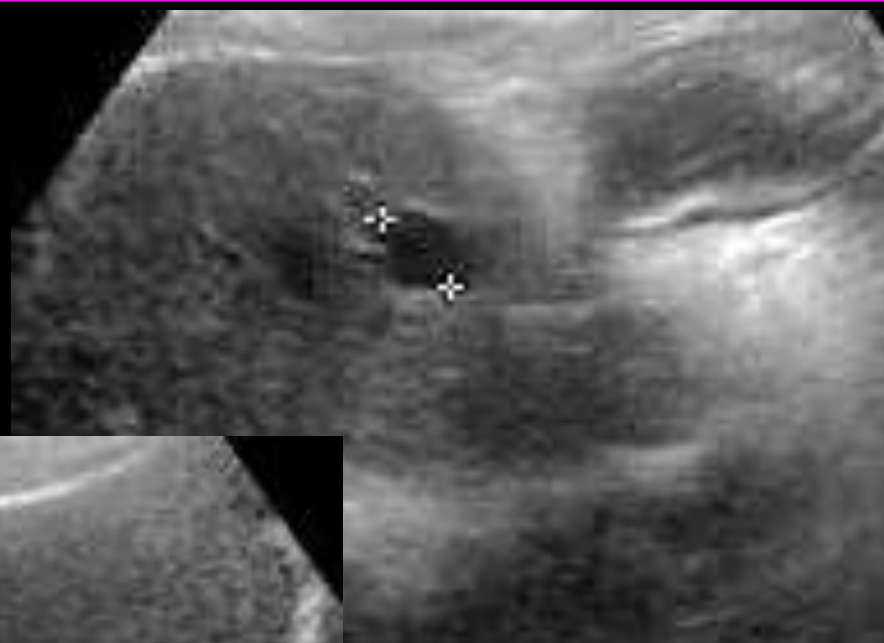

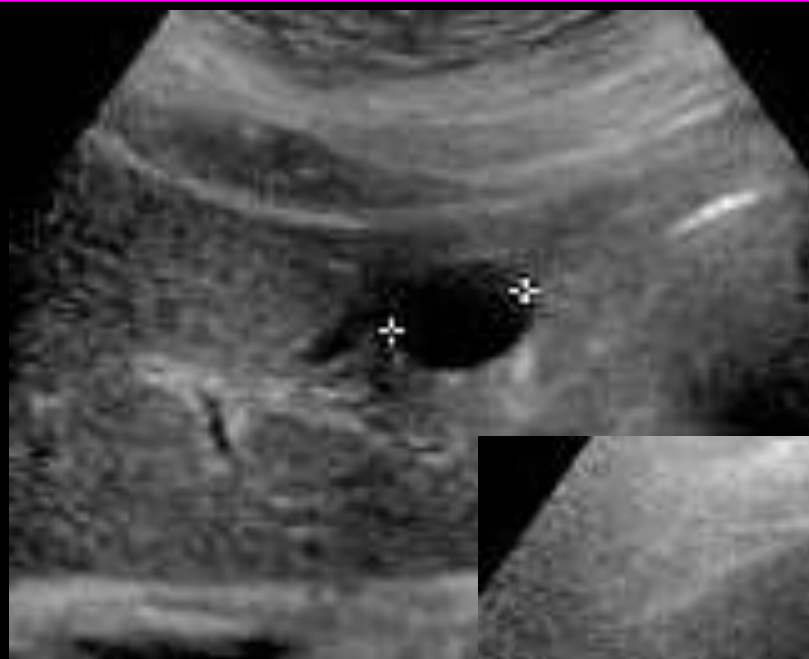
10-

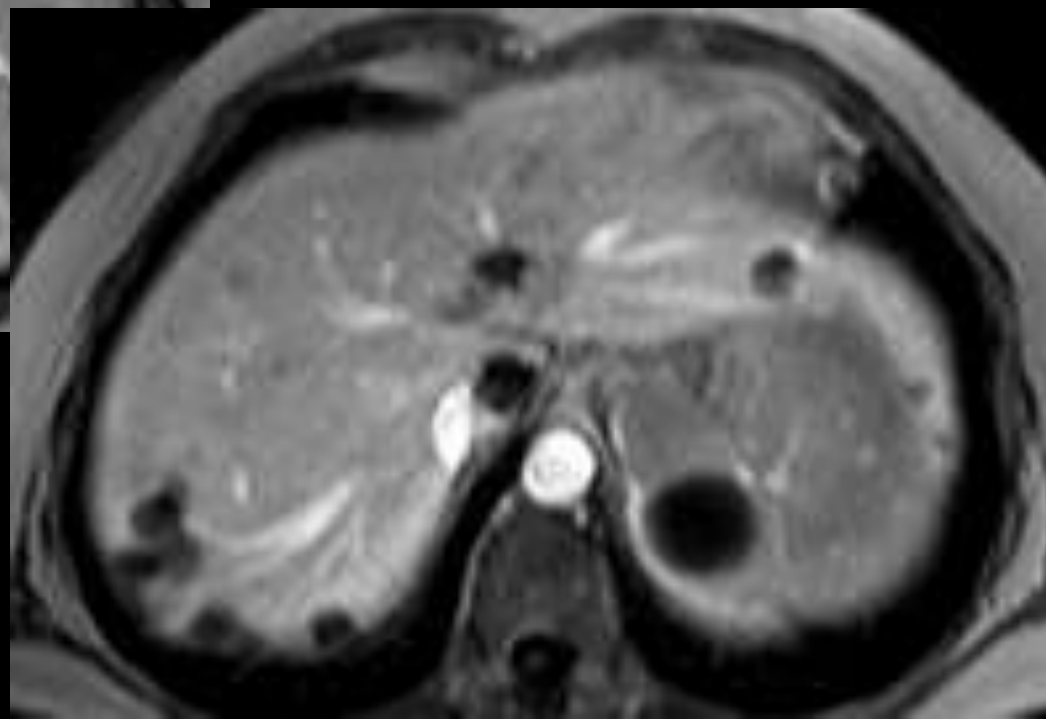
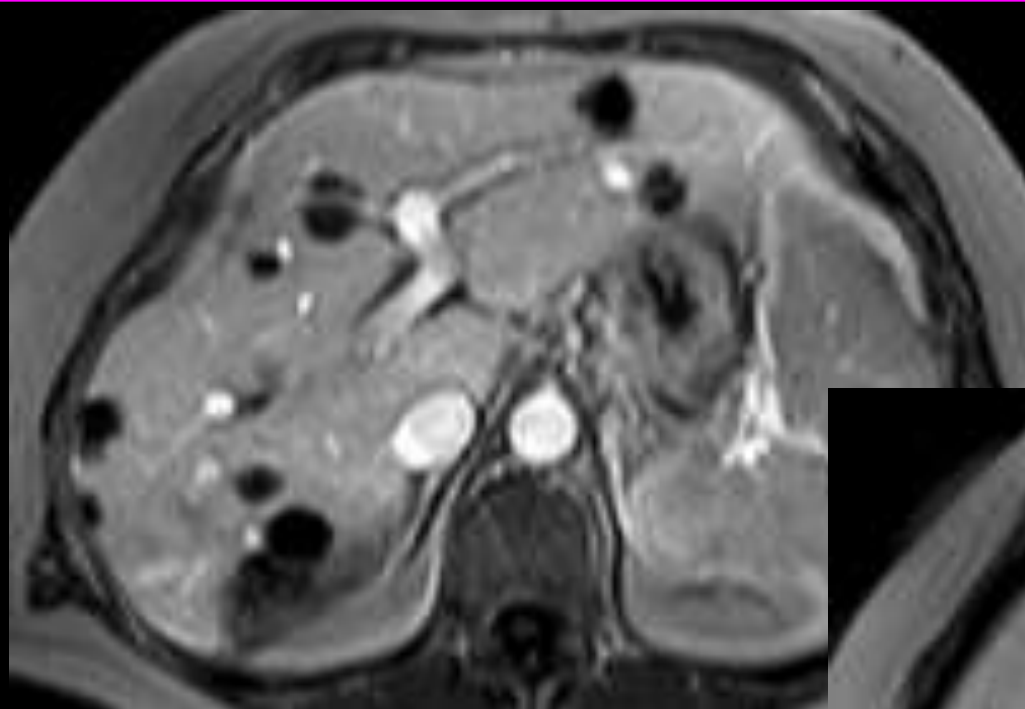
Na co se soustředit

Žena, tu střeva, sledovaná rok, roč. 65, stav před rokem po hemikolektomii.

Cysta??



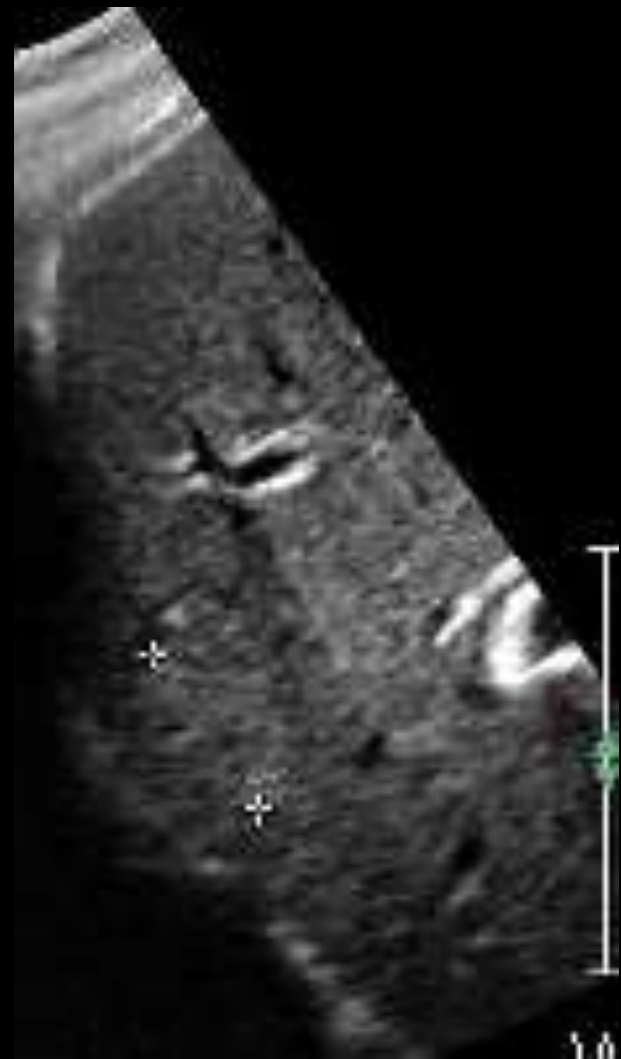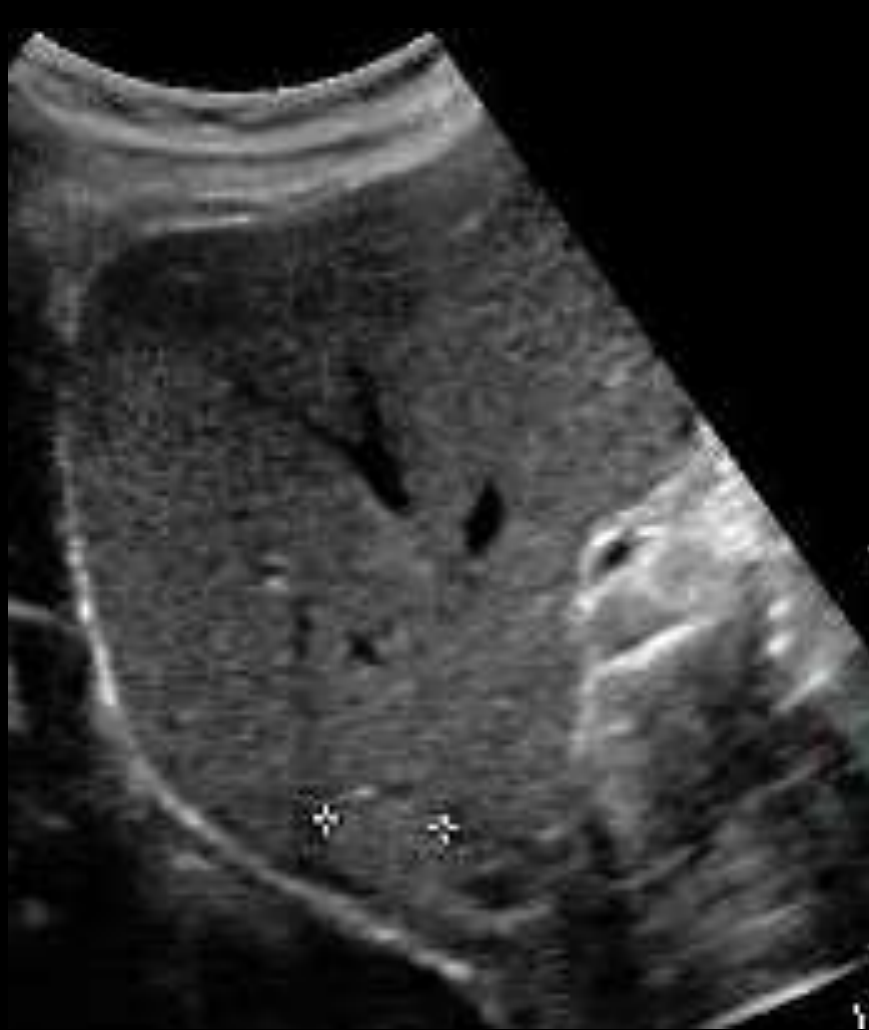Cysta??



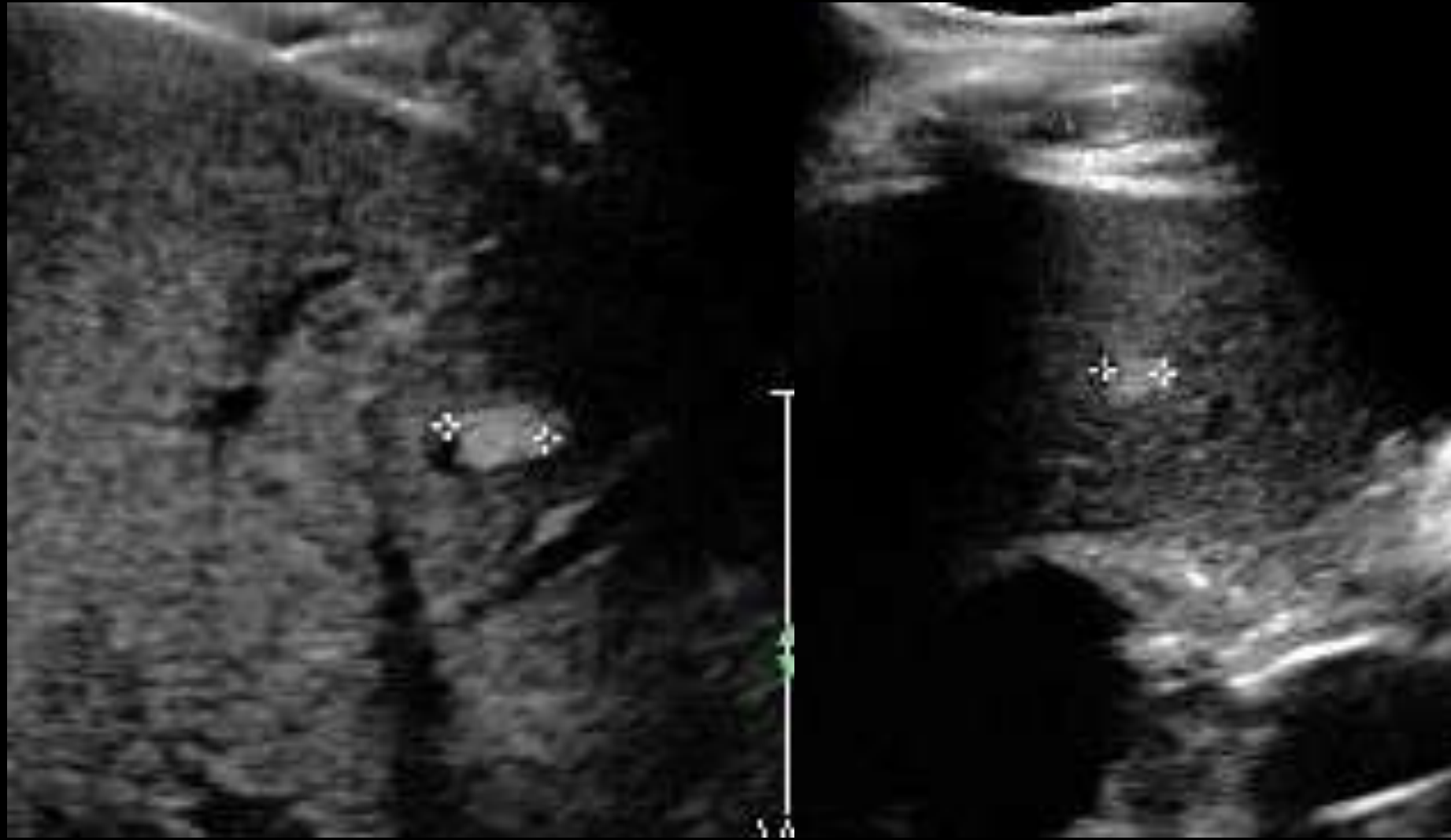
Na co se soustředit

Muž, tu střeva, sledovaný rok, roč. 48, stav před rokem po hemikolektomii.

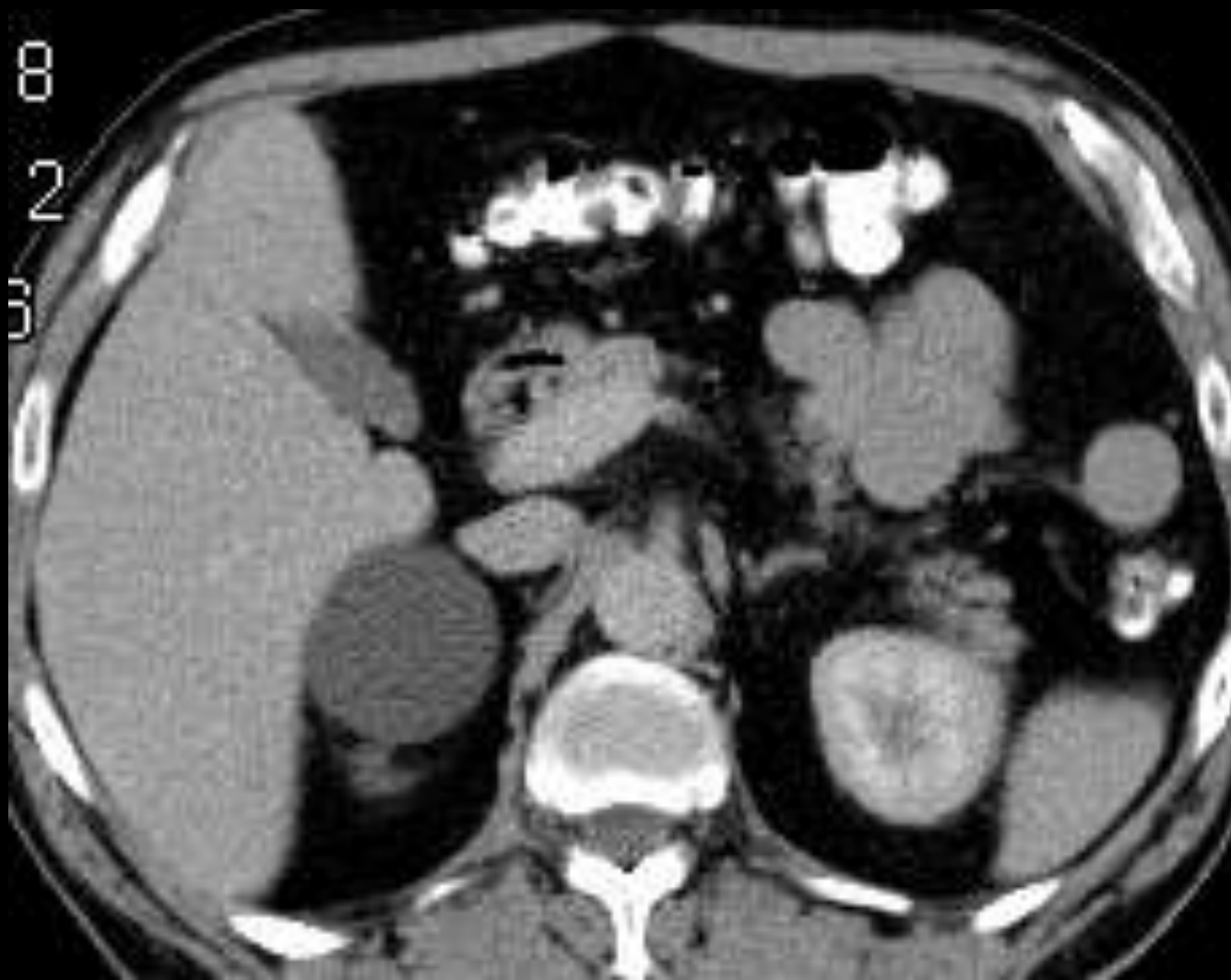Hemangiom 4-13??



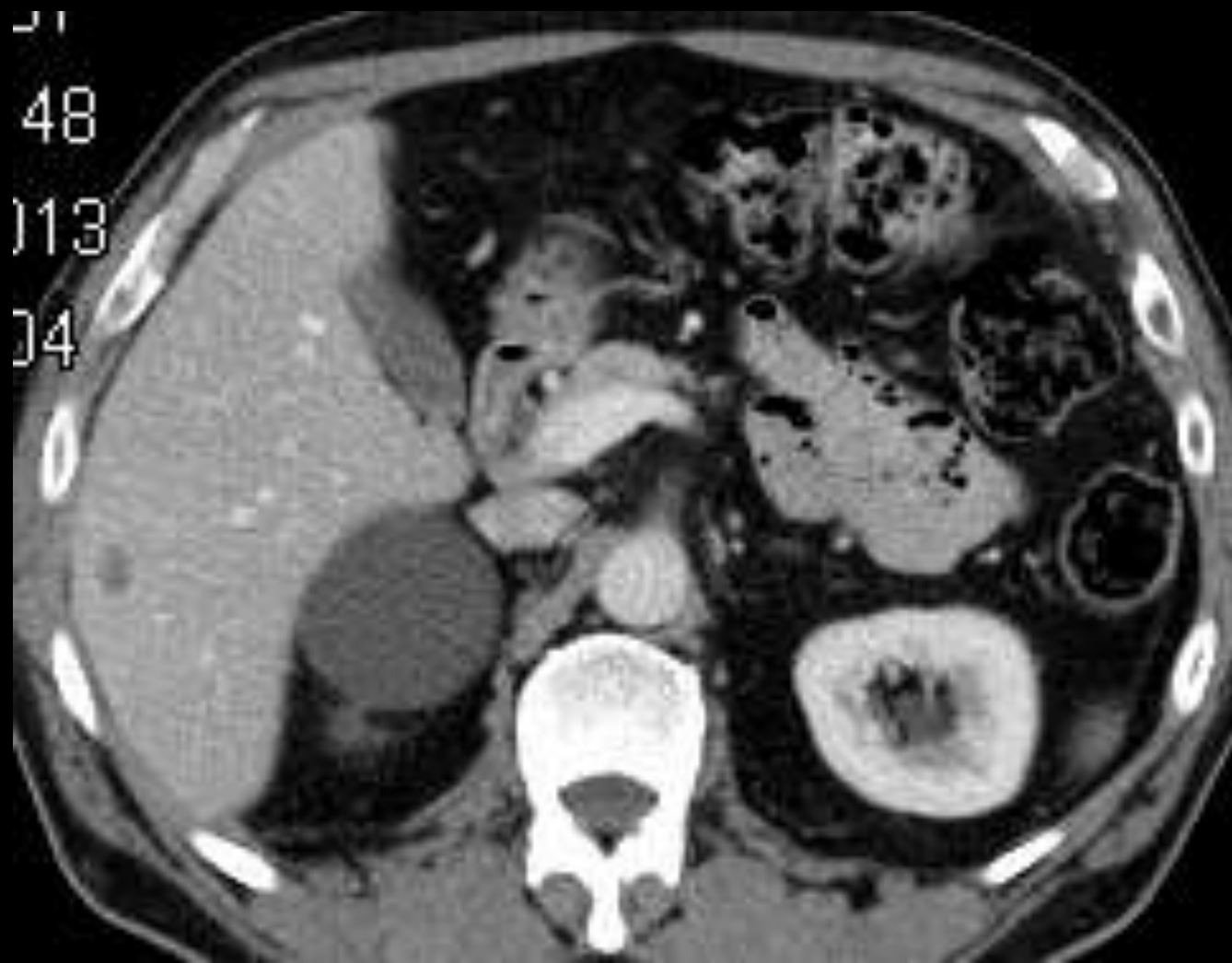
Hemangiom 4-13??



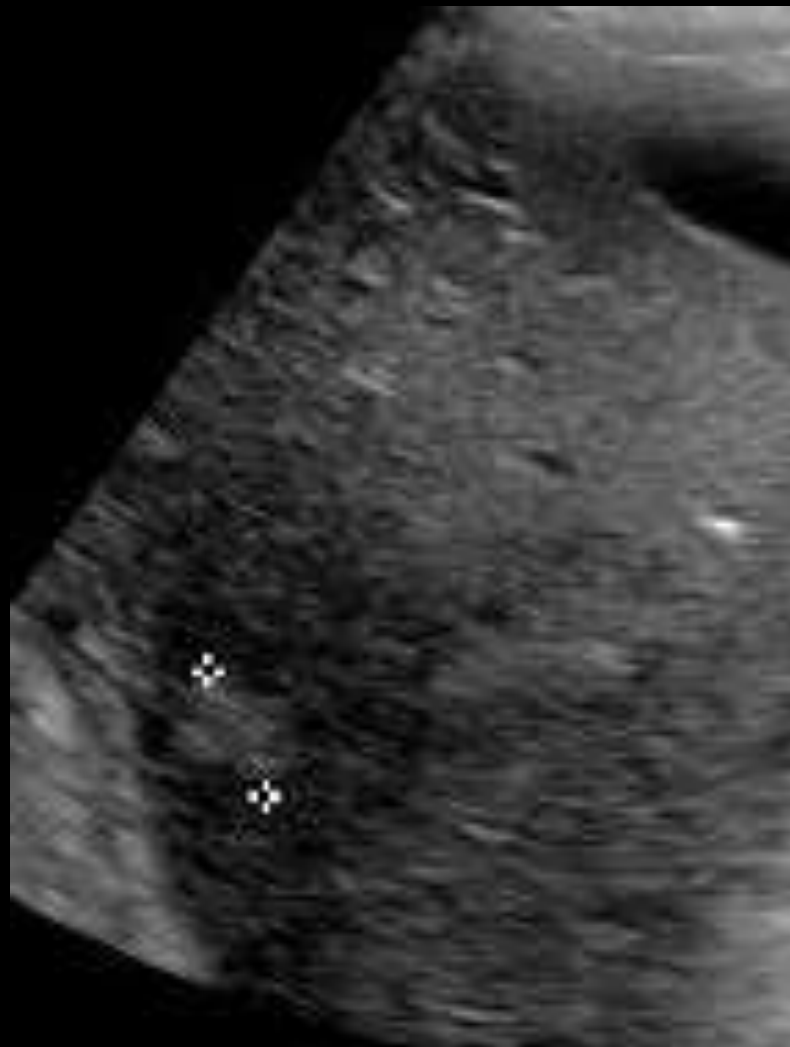
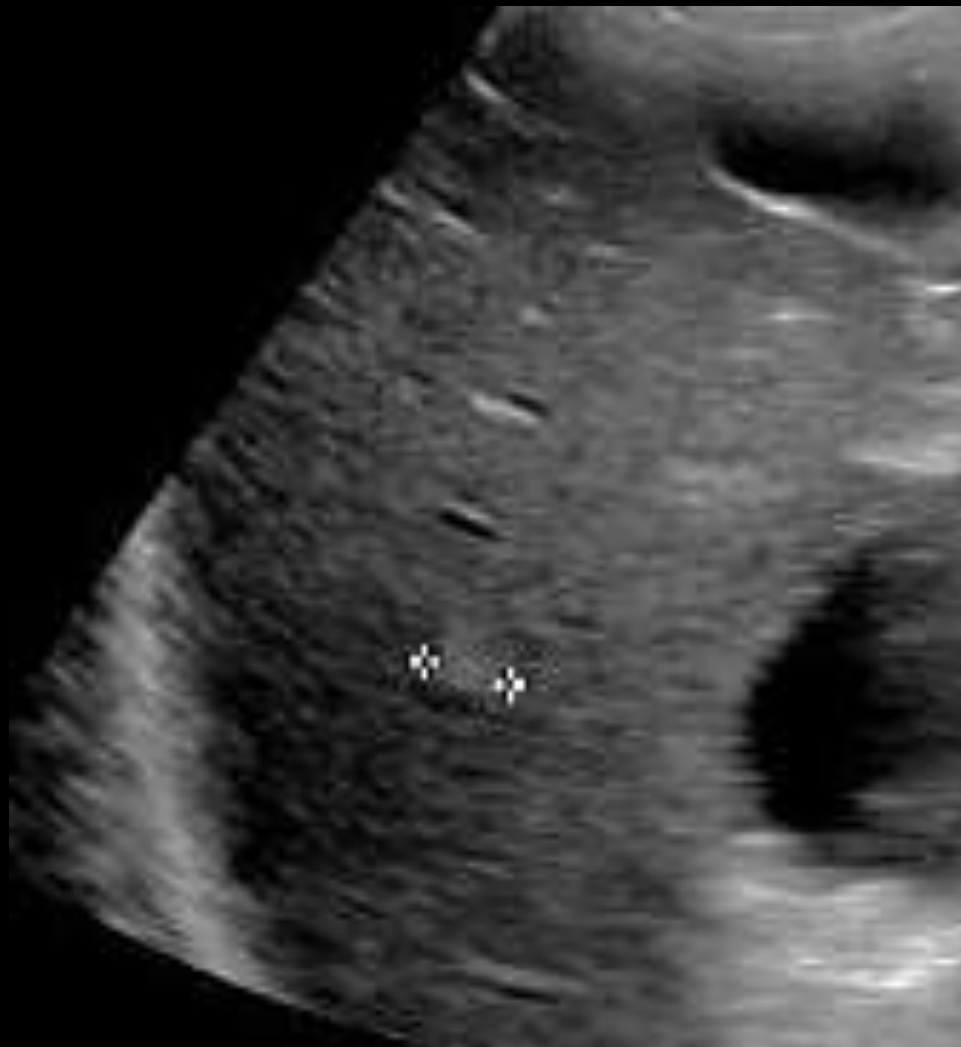Hemangiom 9-12??



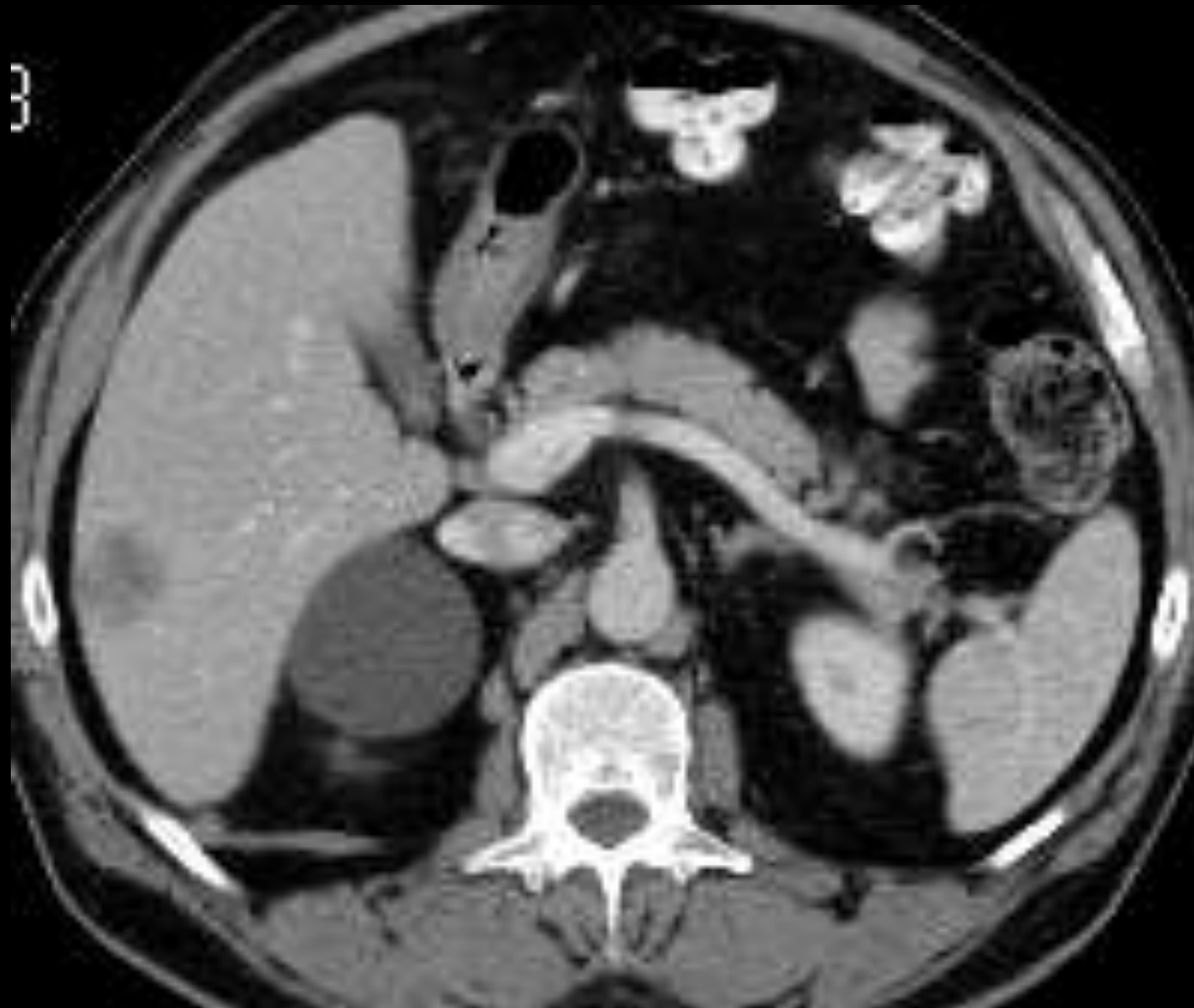
Hemangiom 3-13??



Hemangiom 8-13 ??



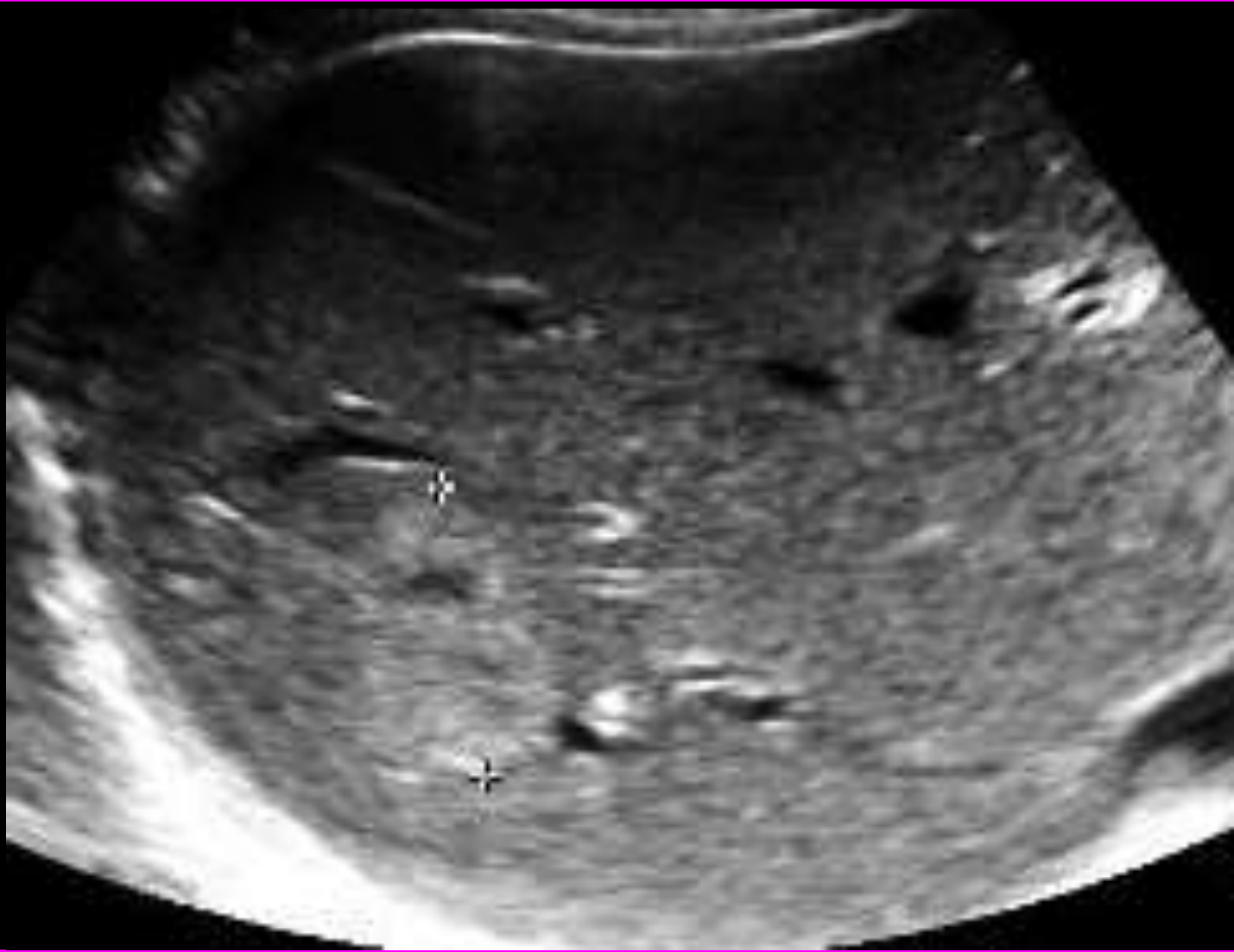Hemangiom 10-13??



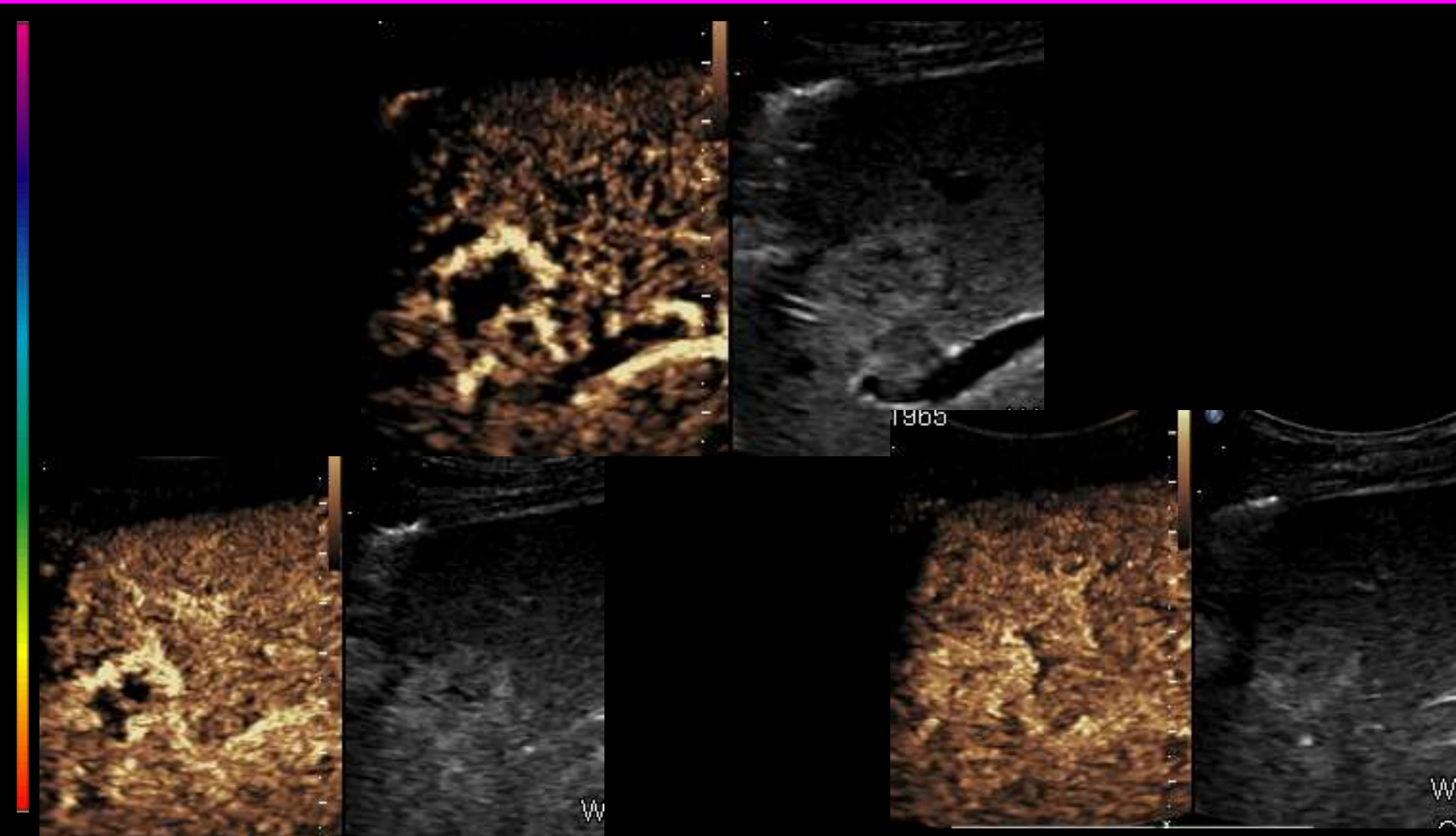
Na co se soustředit

Muž, náhodný nález, roč. 65.

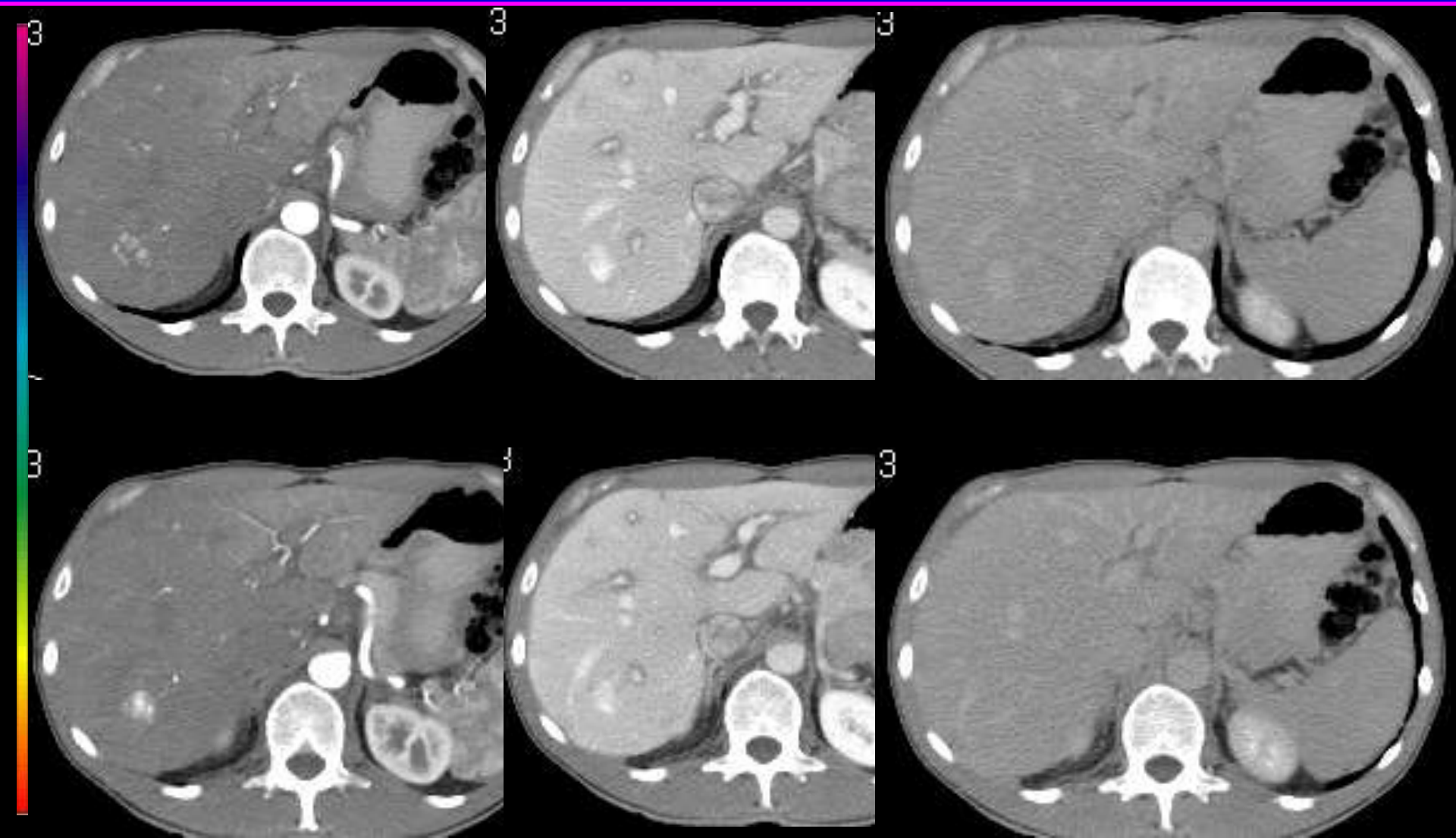
Hemangiom??



Hemangiom??



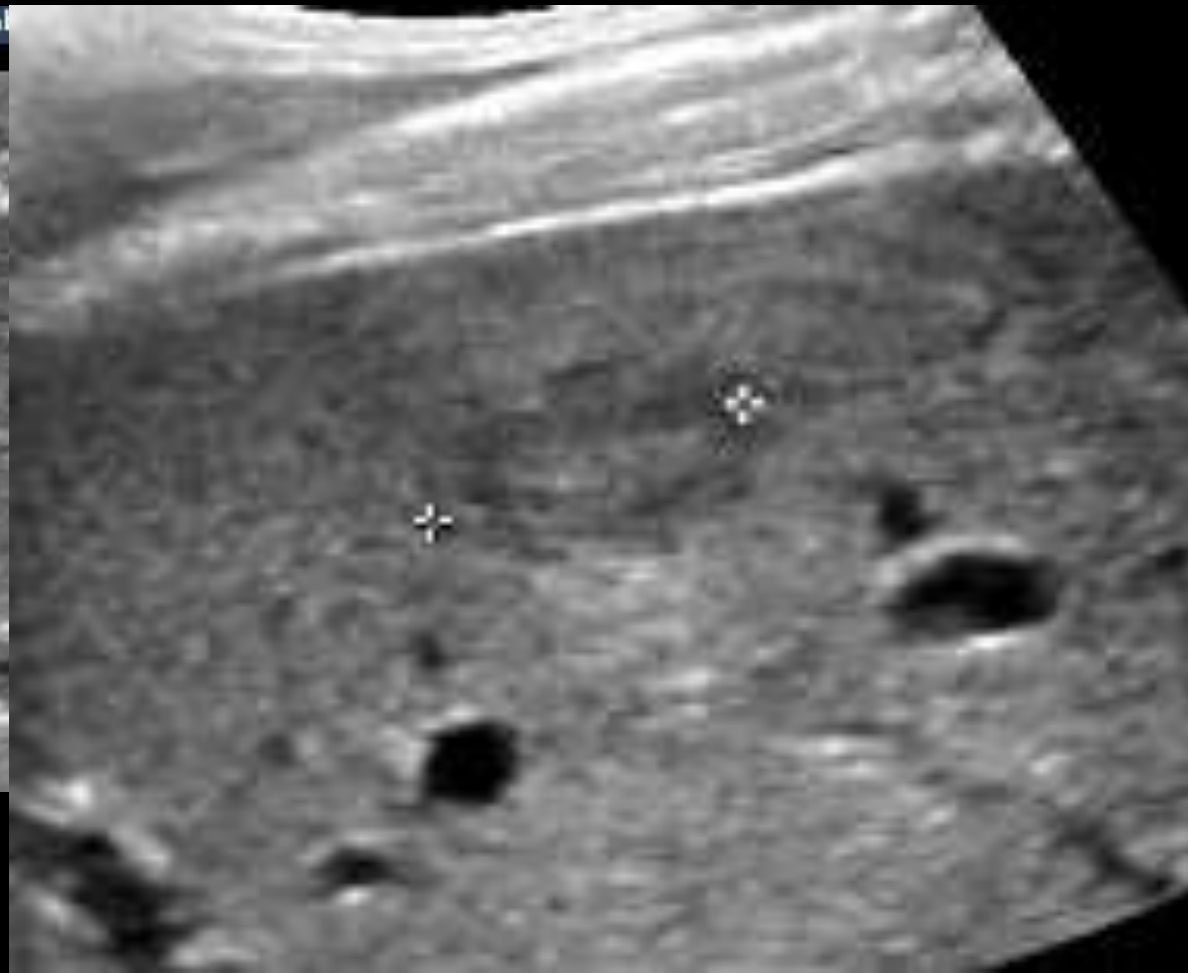
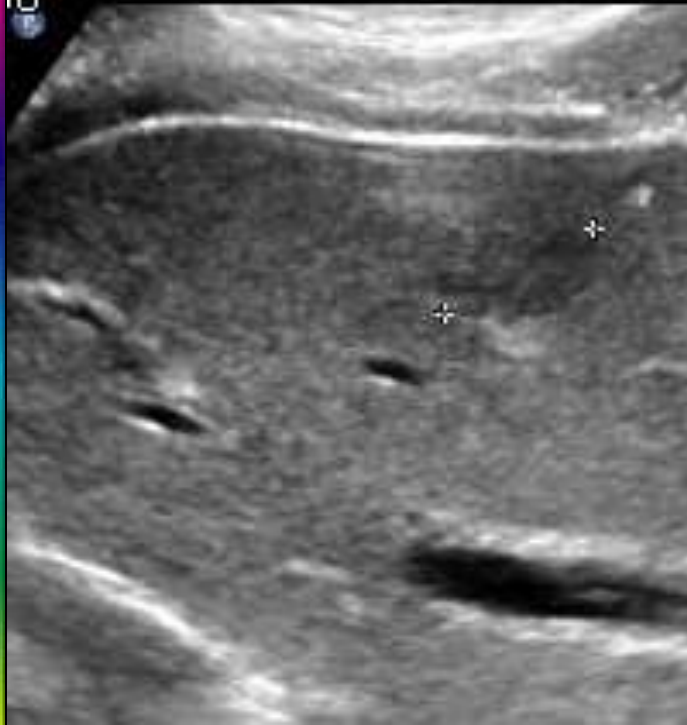
Hemangiom??



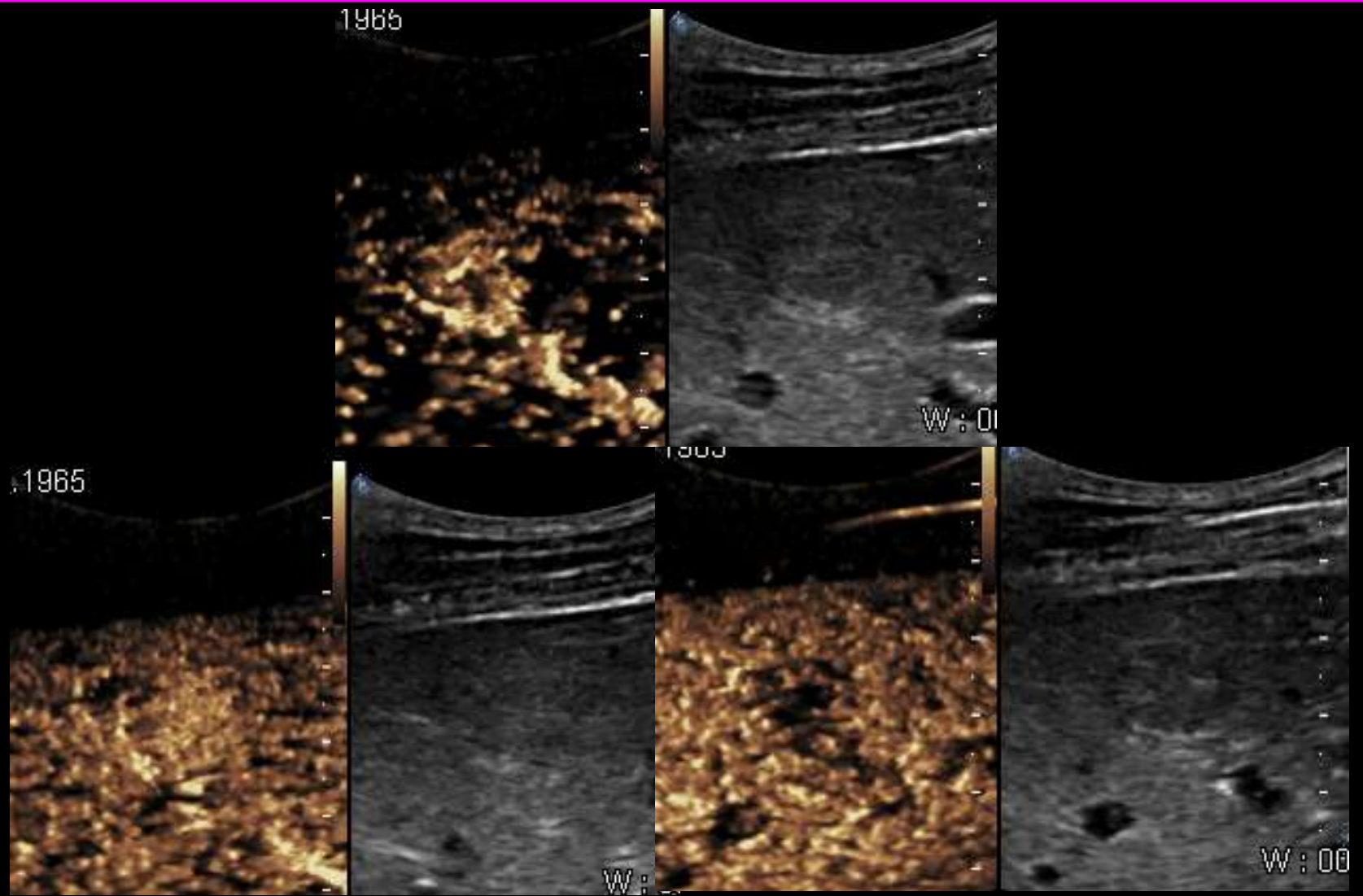
Hemangiom??

FN Brno RDG

C5-17A



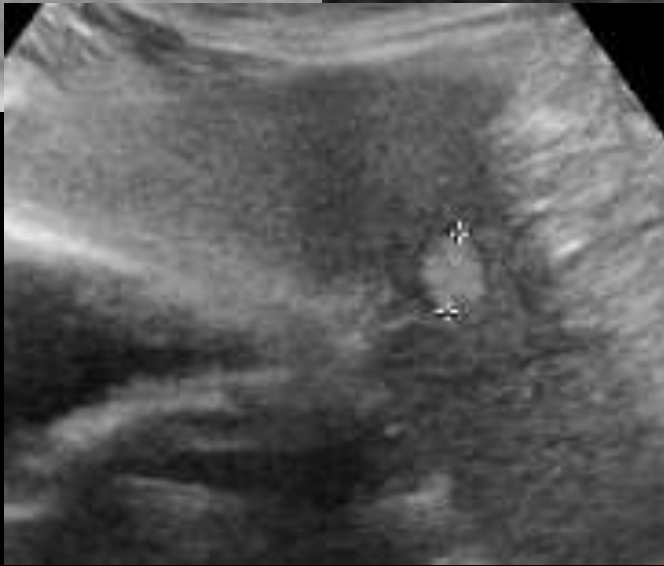
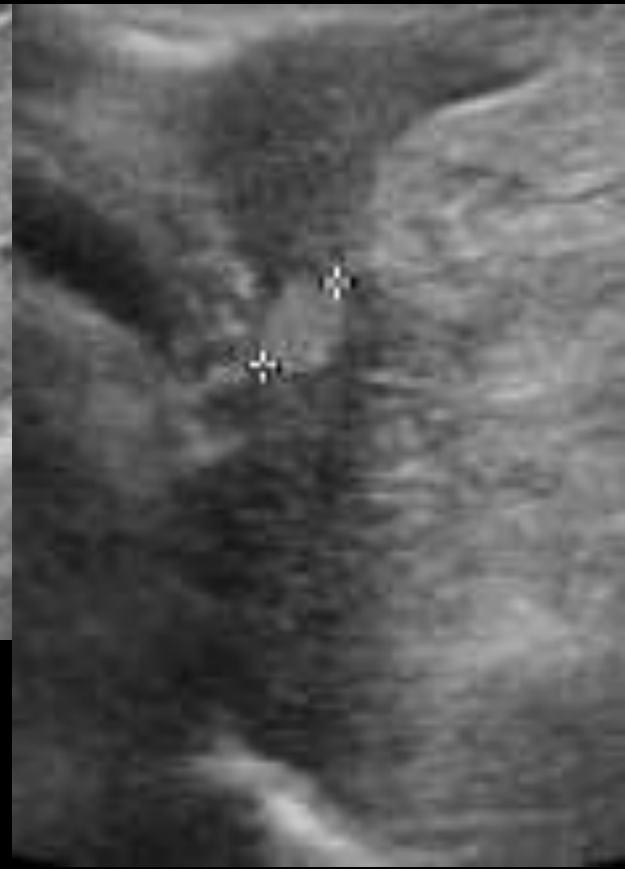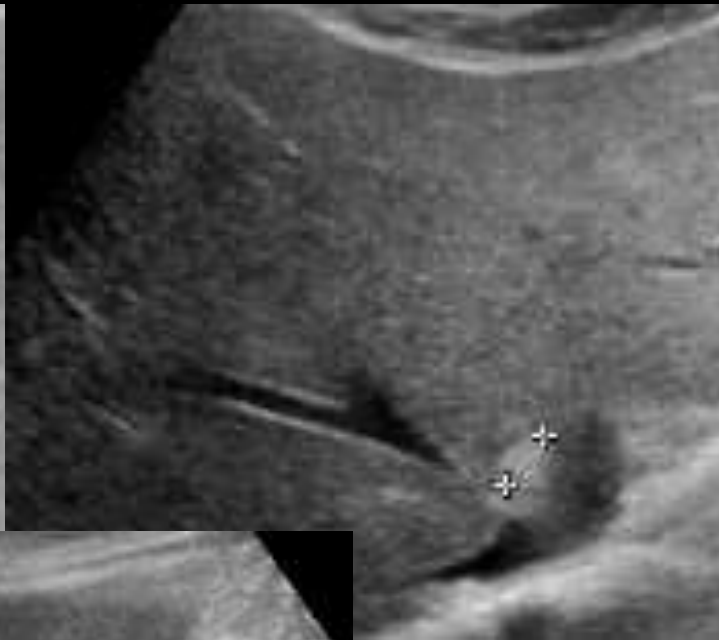
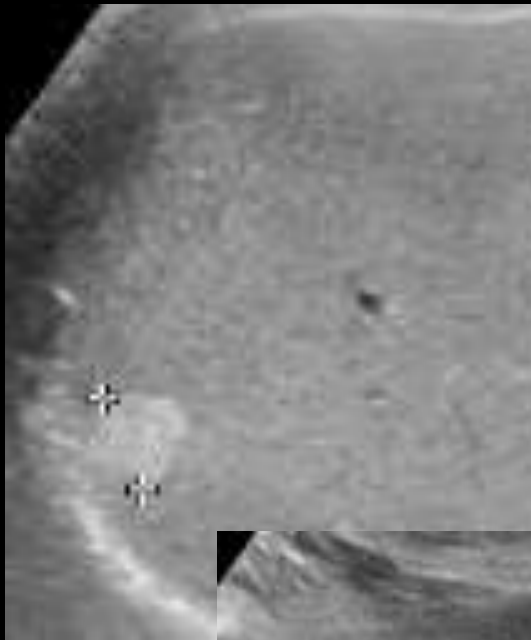Hemangiom??



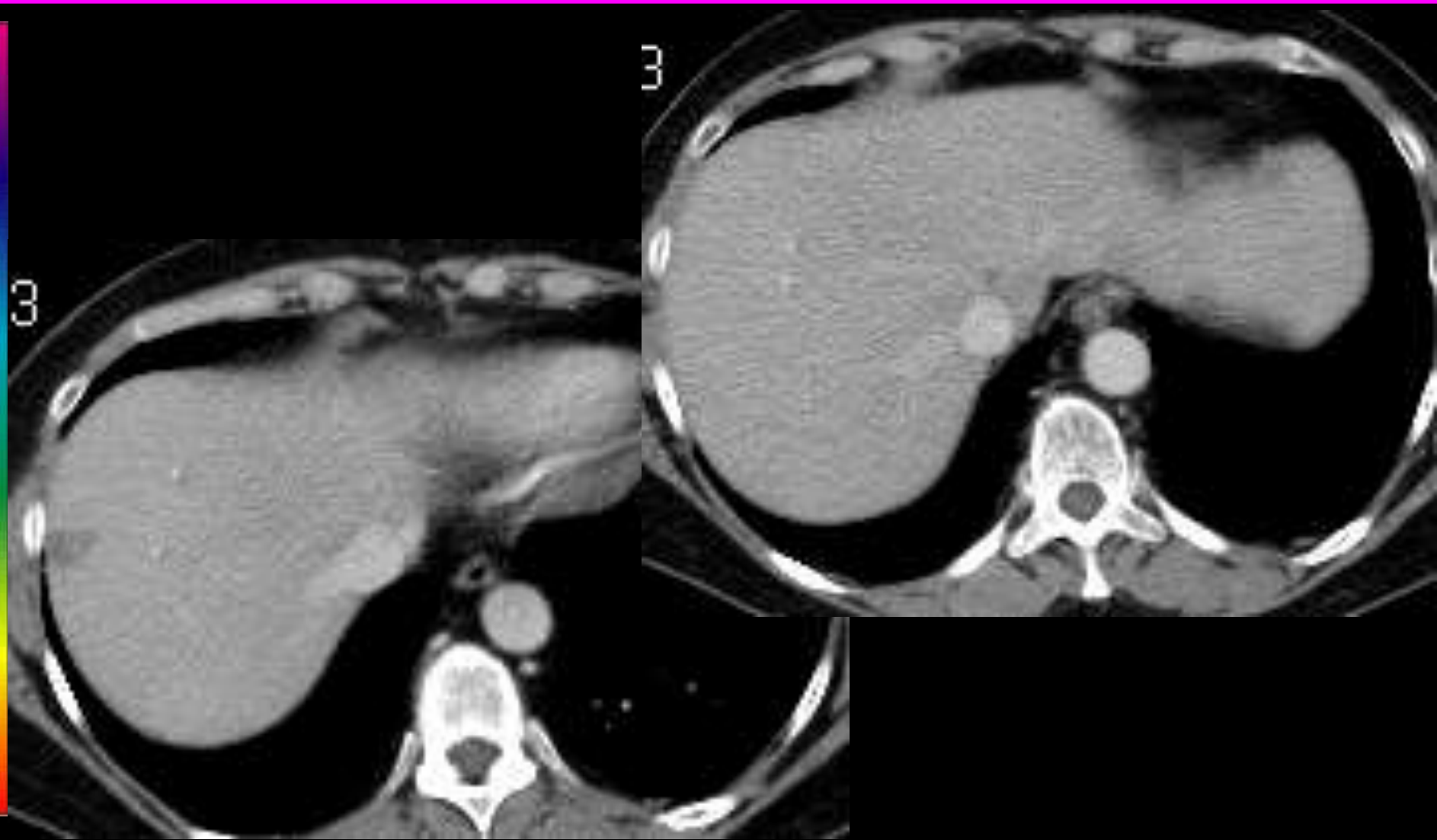
Na co se soustředit

Žena, náhodný nález, roč. 59

Hemangiom??



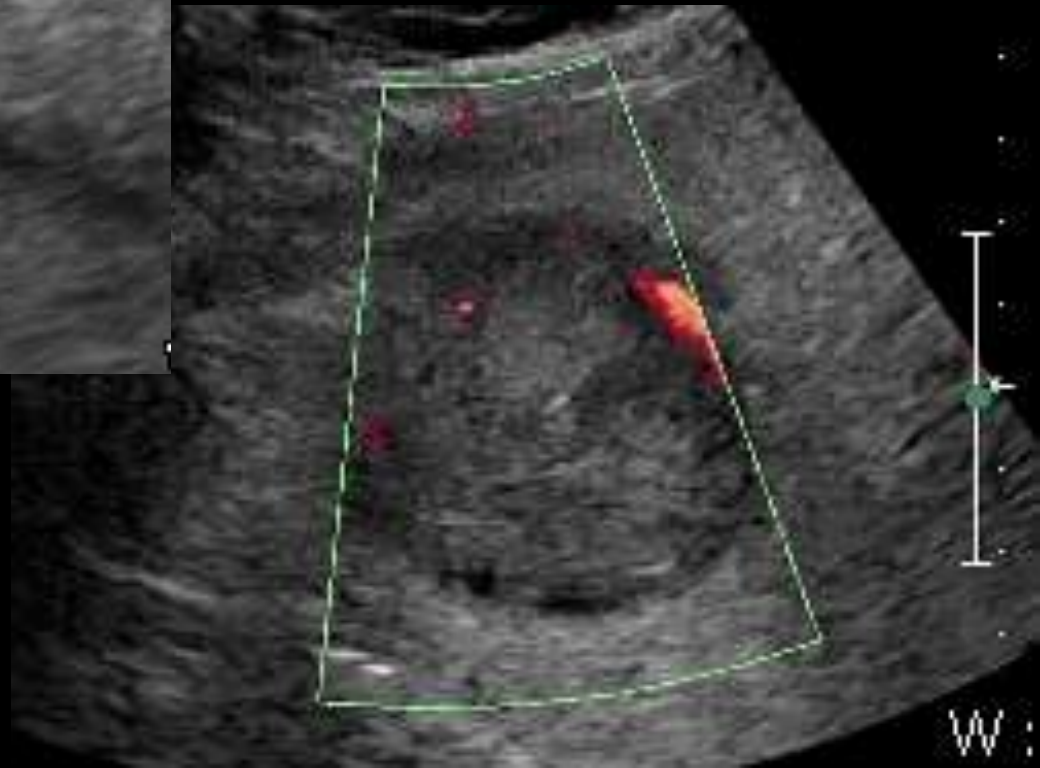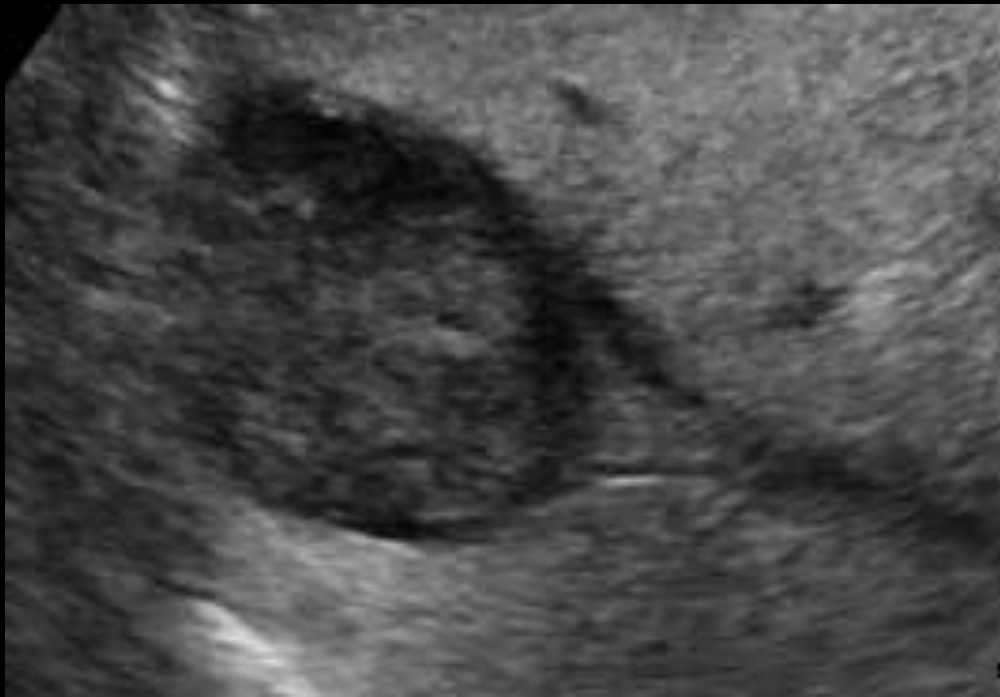Hemangioma??



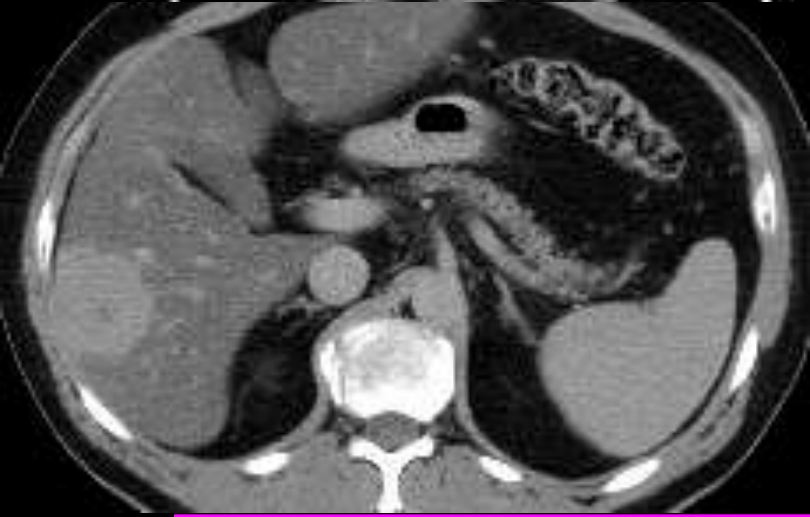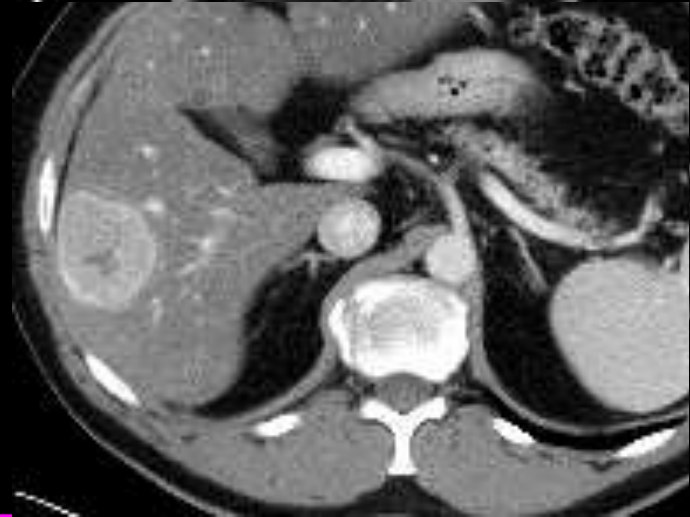
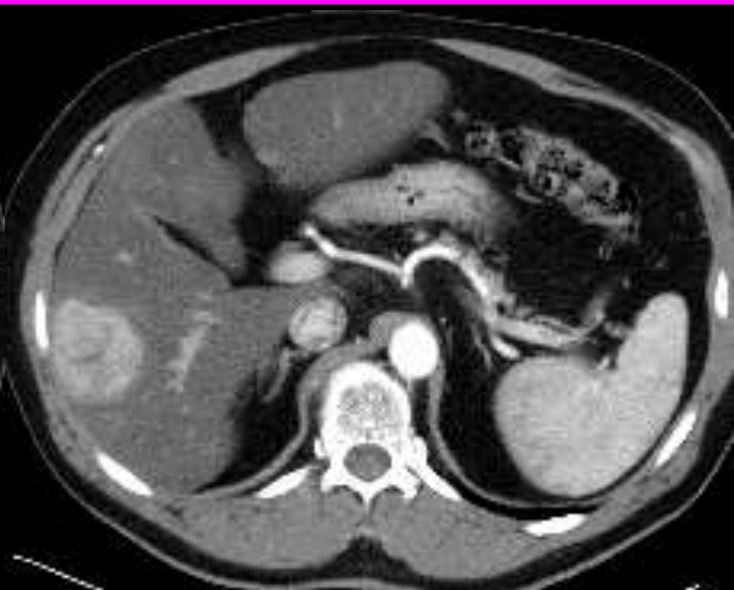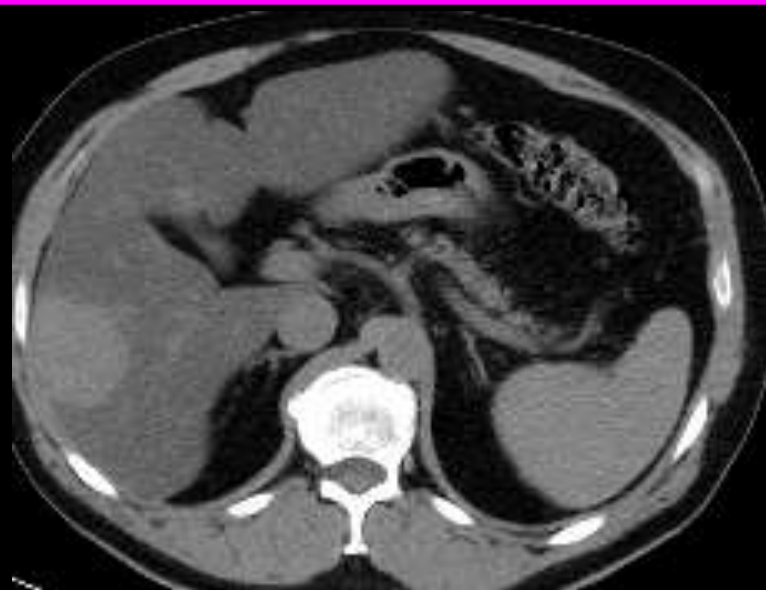Na co se soustředit

**Muž, hepatitidy v anamnéze, roč. 54,
sledovaný.**

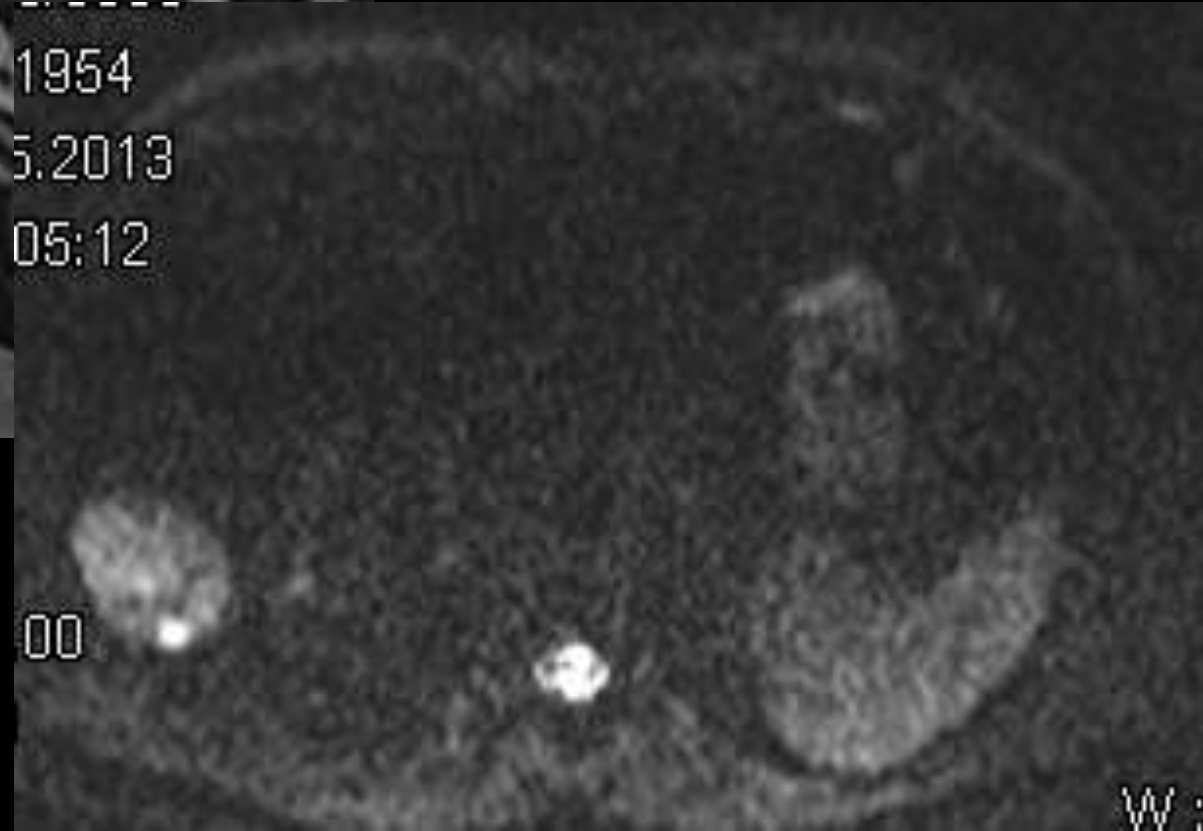
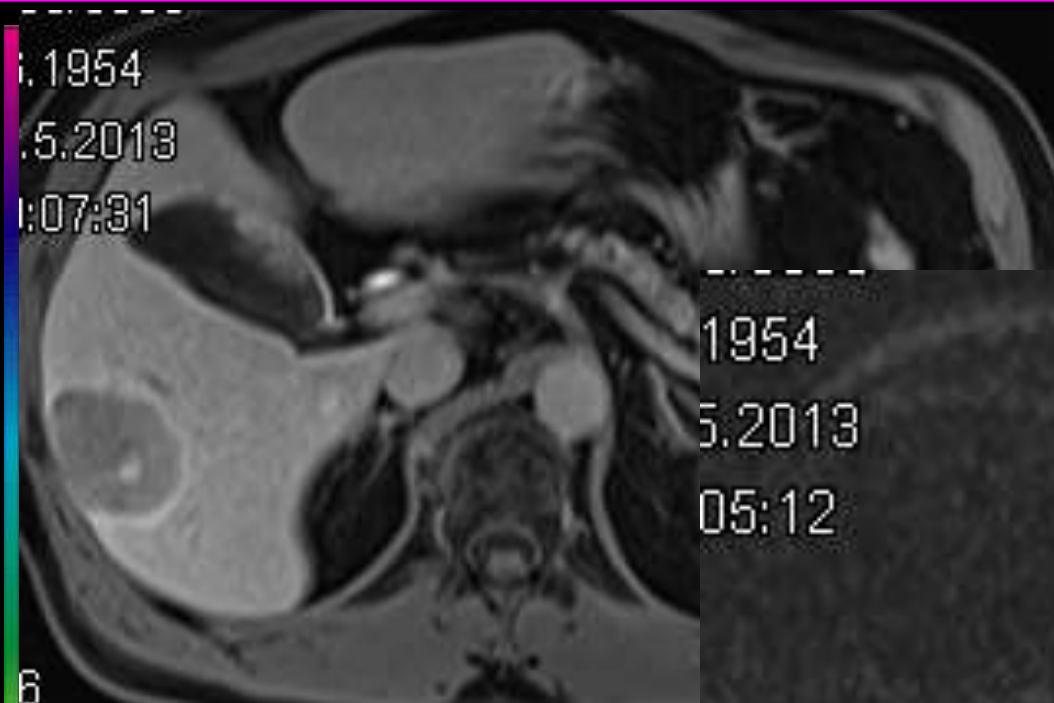
Hemangiom??



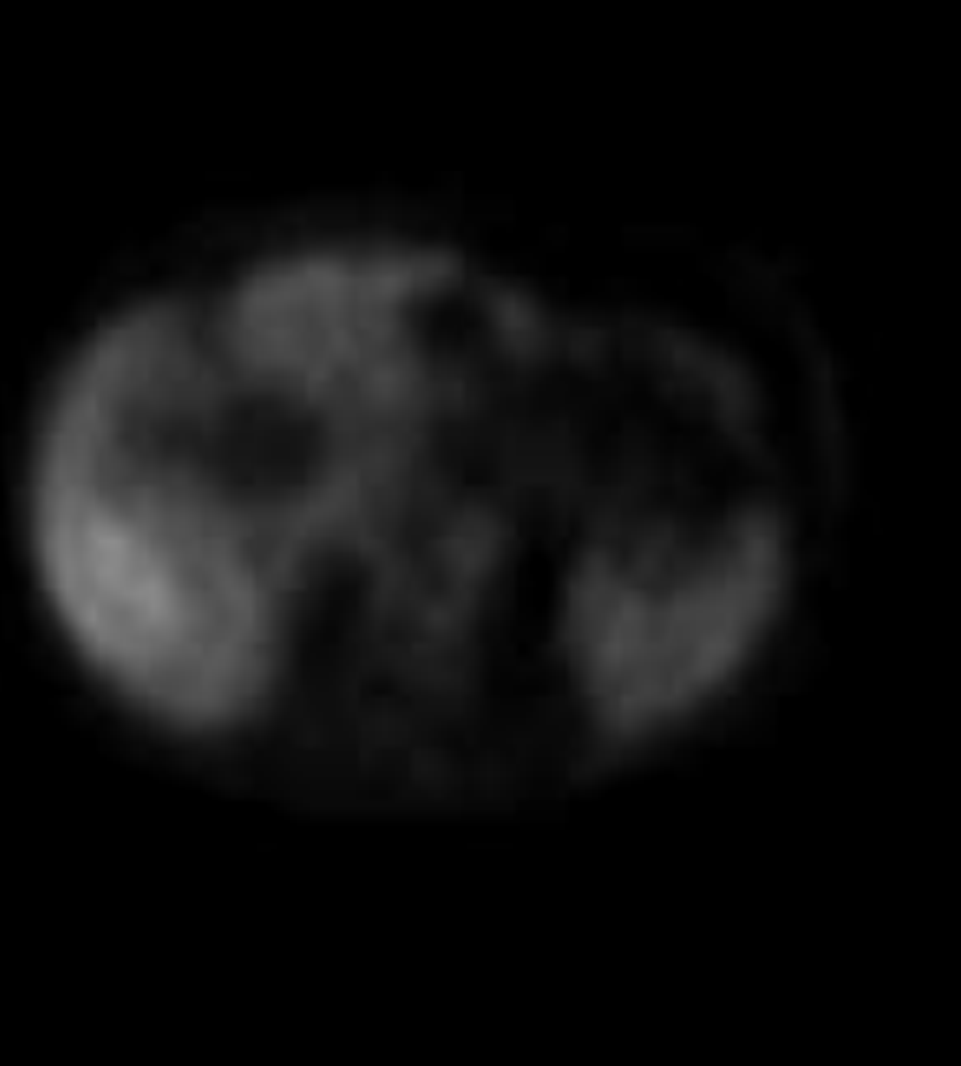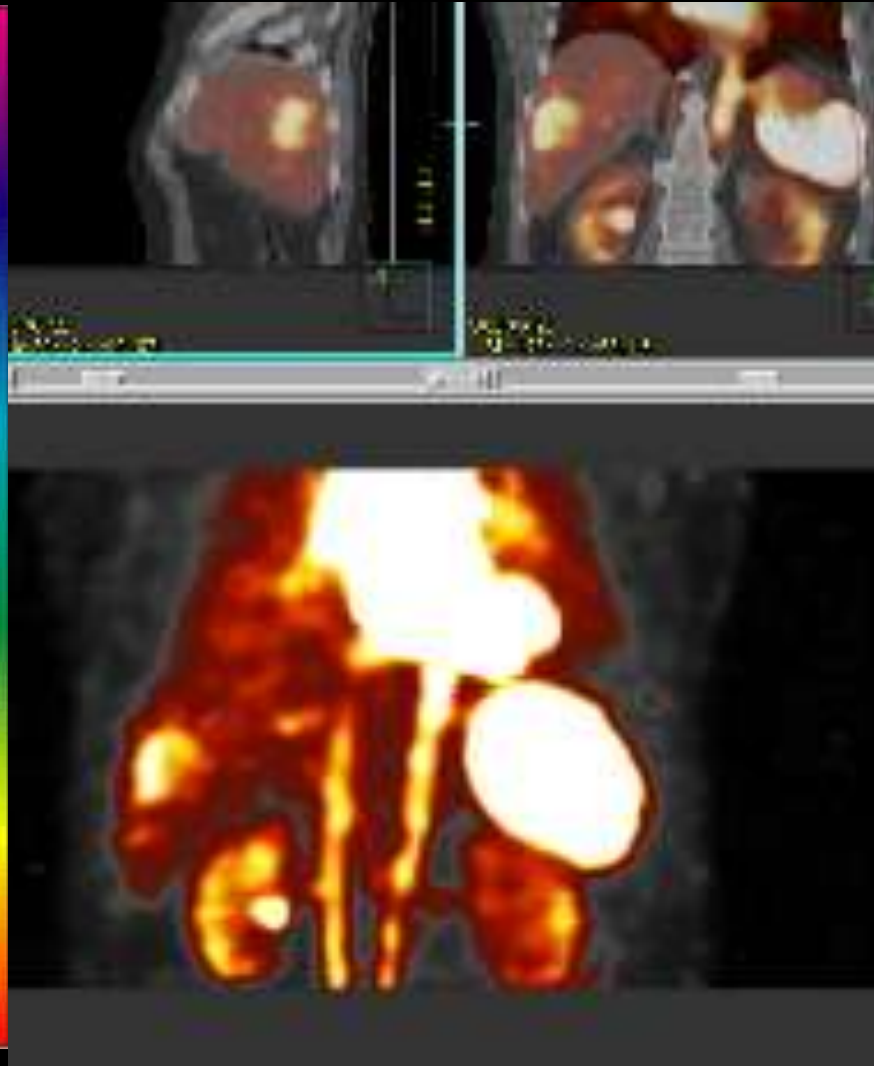
Hemangioma??



Hemangiom??



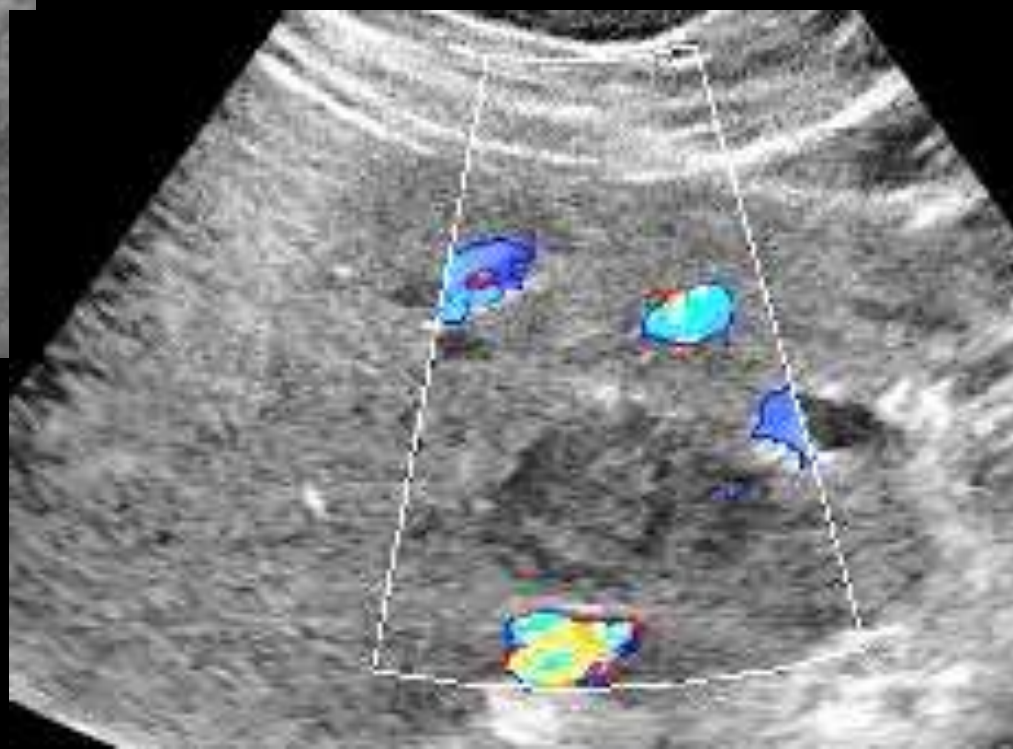
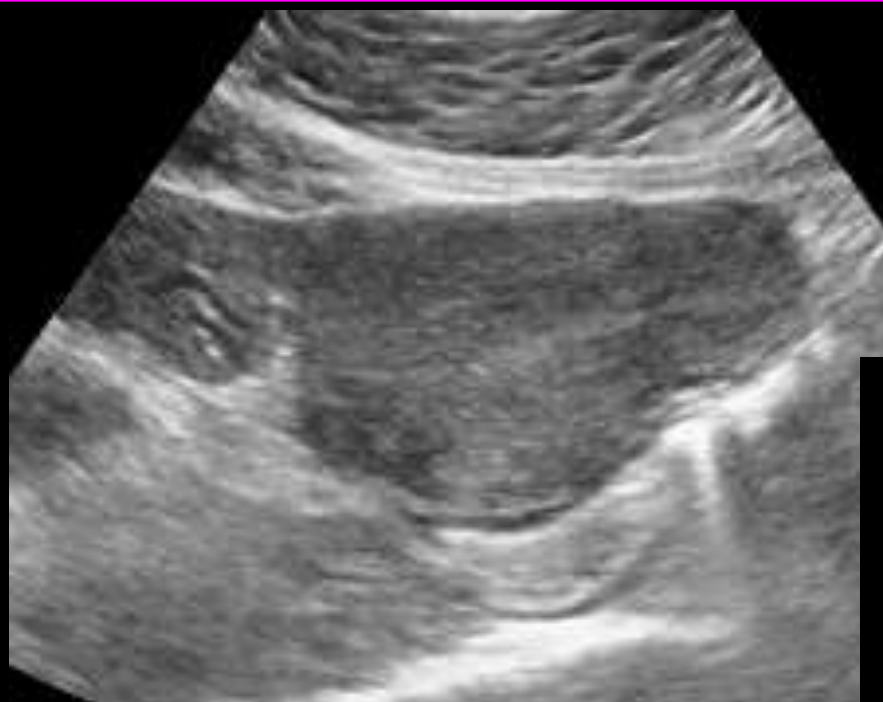
Hemangiom??



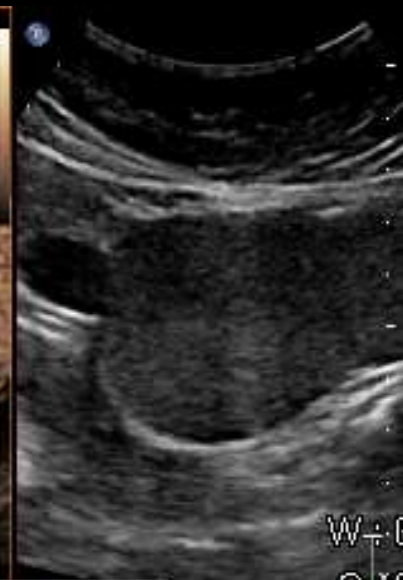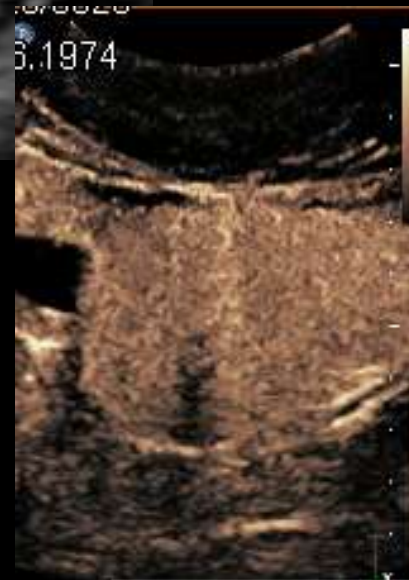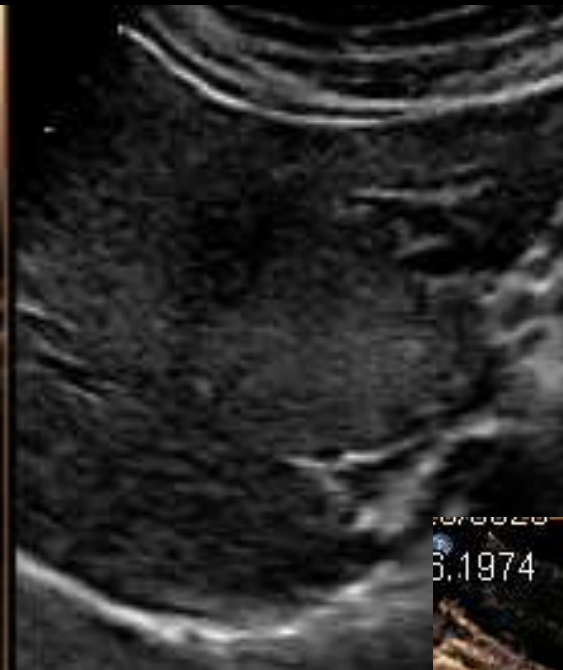
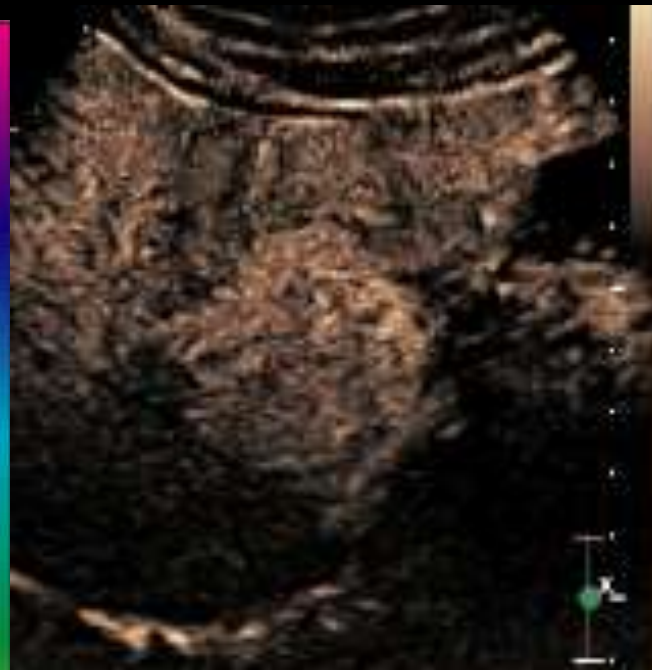Na co se soustředit

Žena, náhodný nález, roč. 74

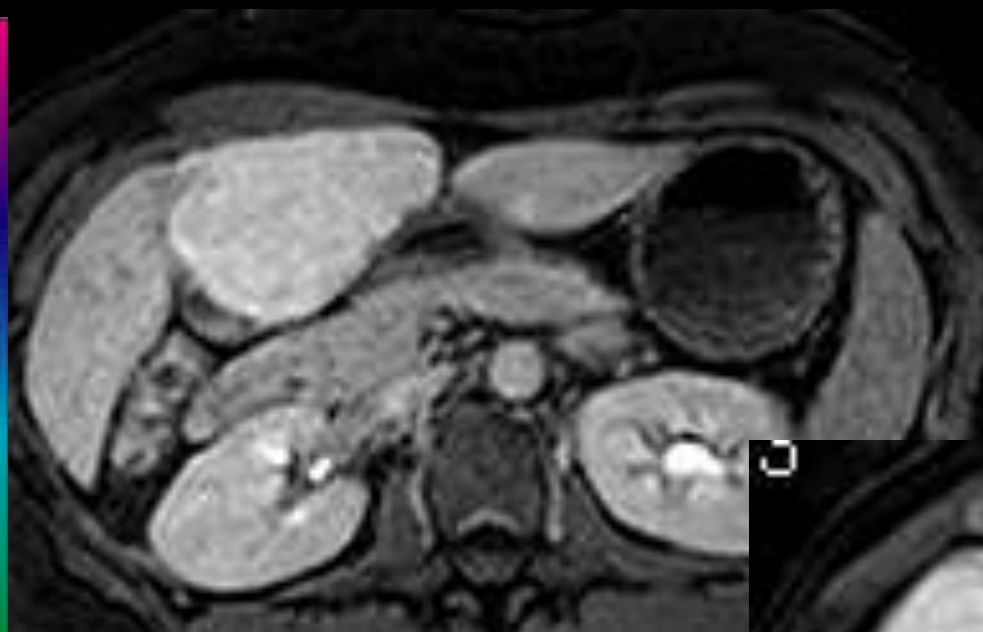
Benigní??



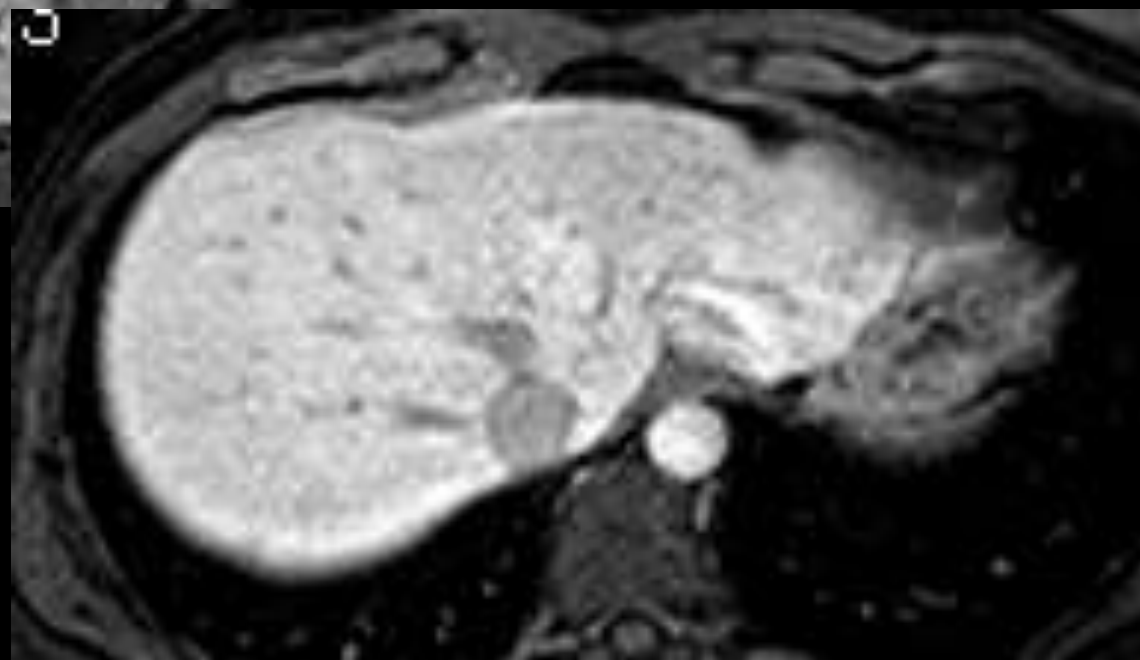
Benigní??



Benigní??



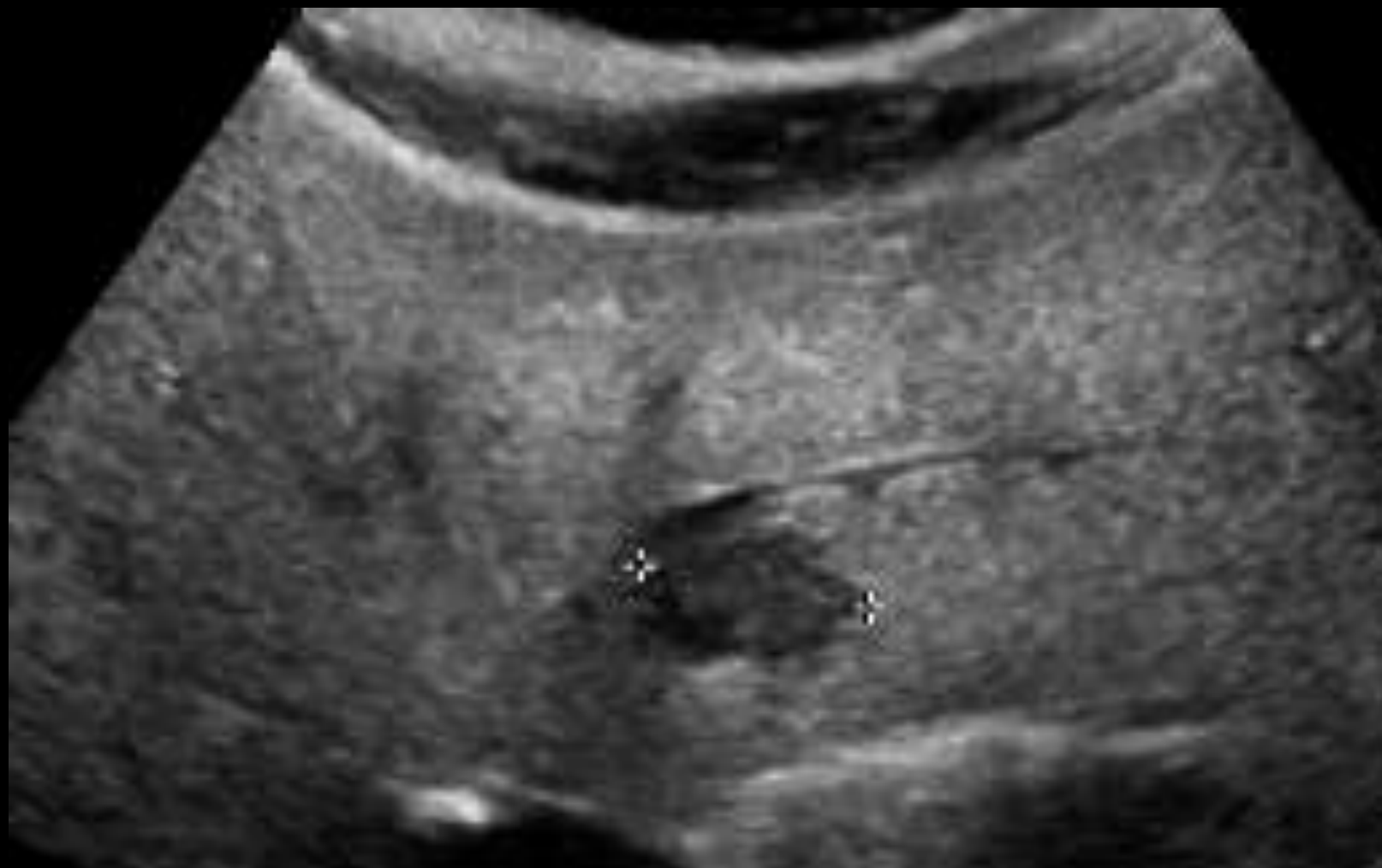2



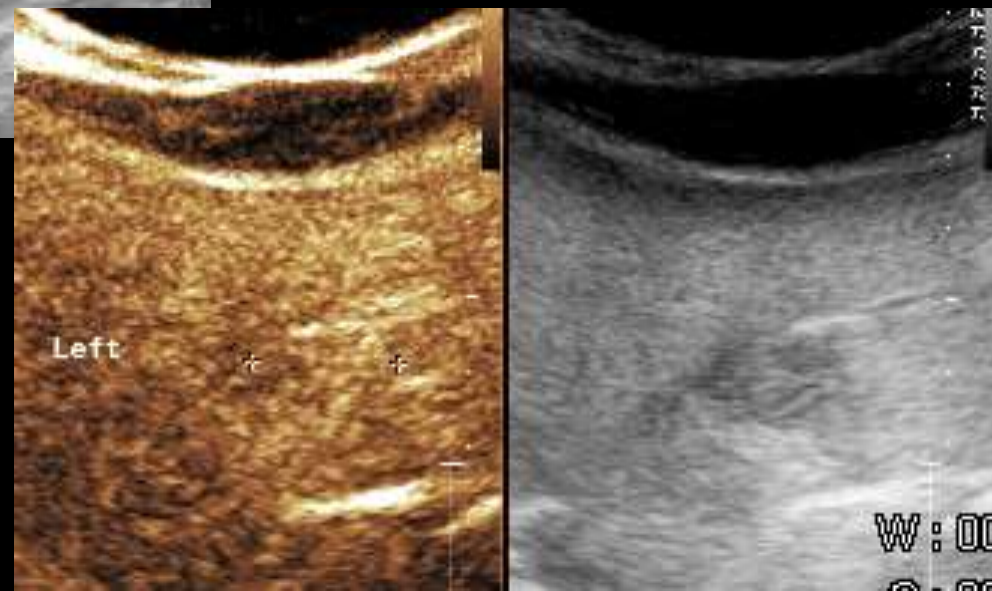
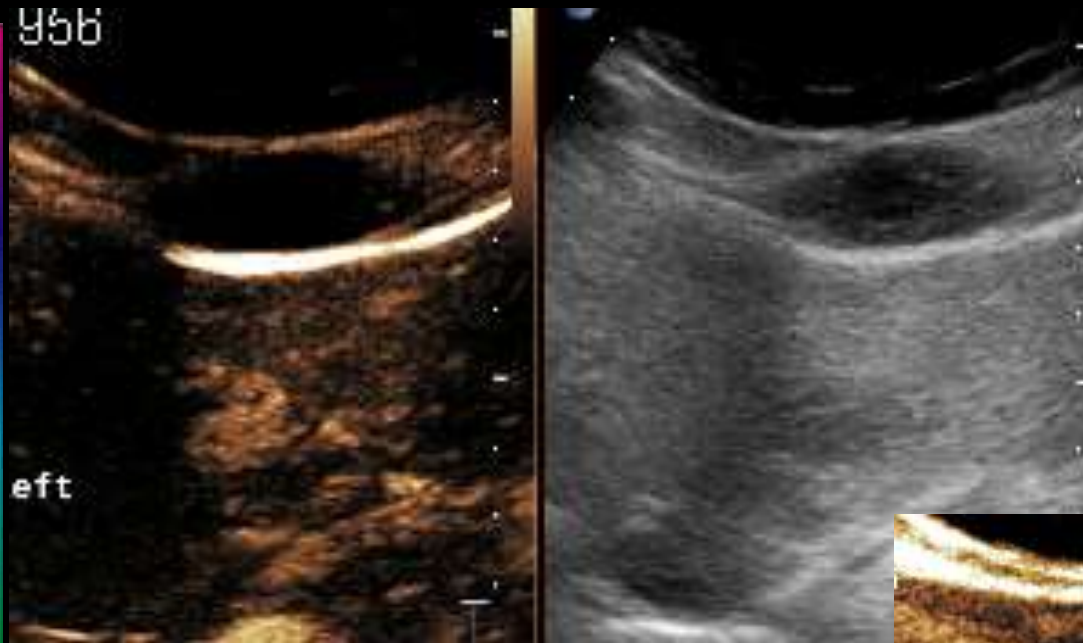
Na co se soustředit

Žena, ca prsu, roč. 56

Benigní??



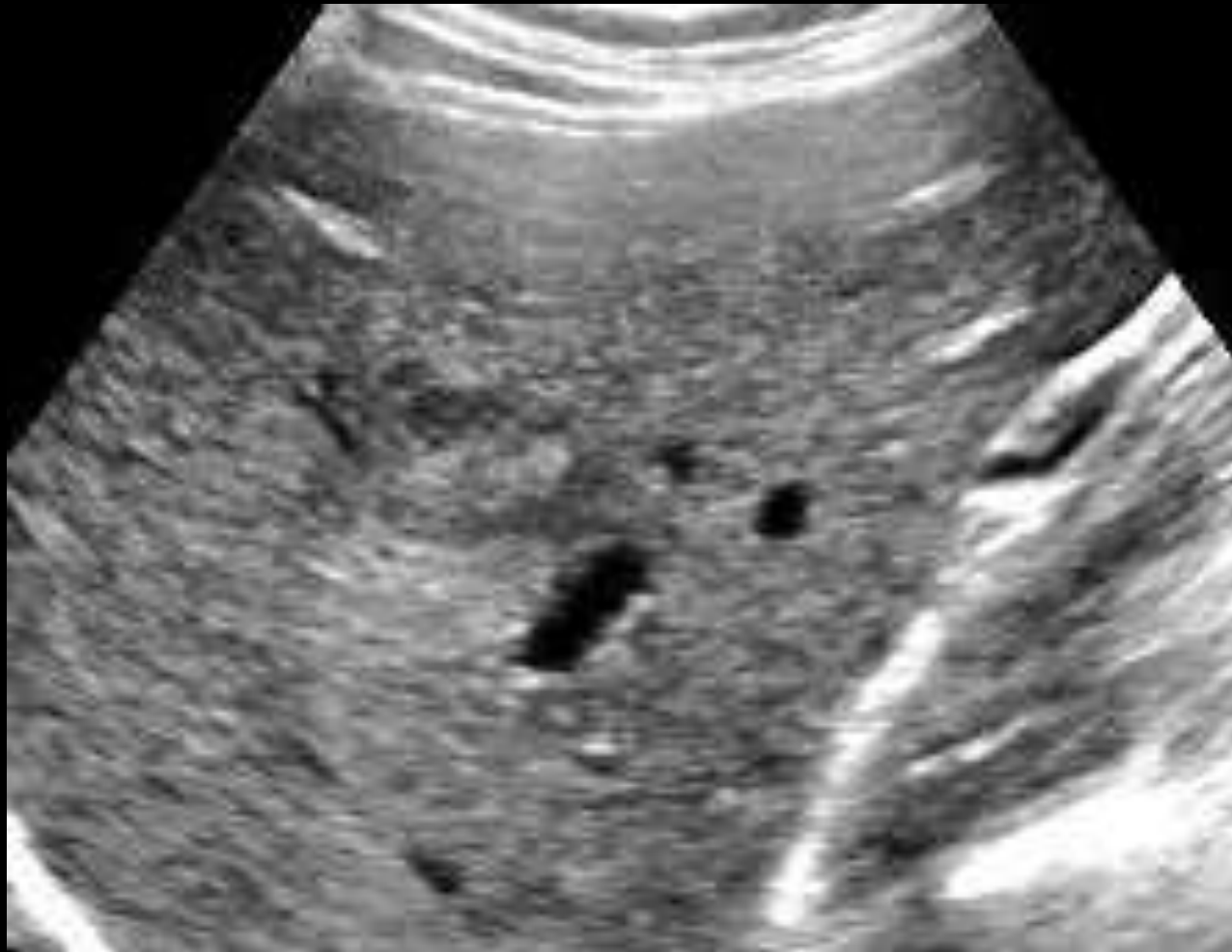
Benigní??



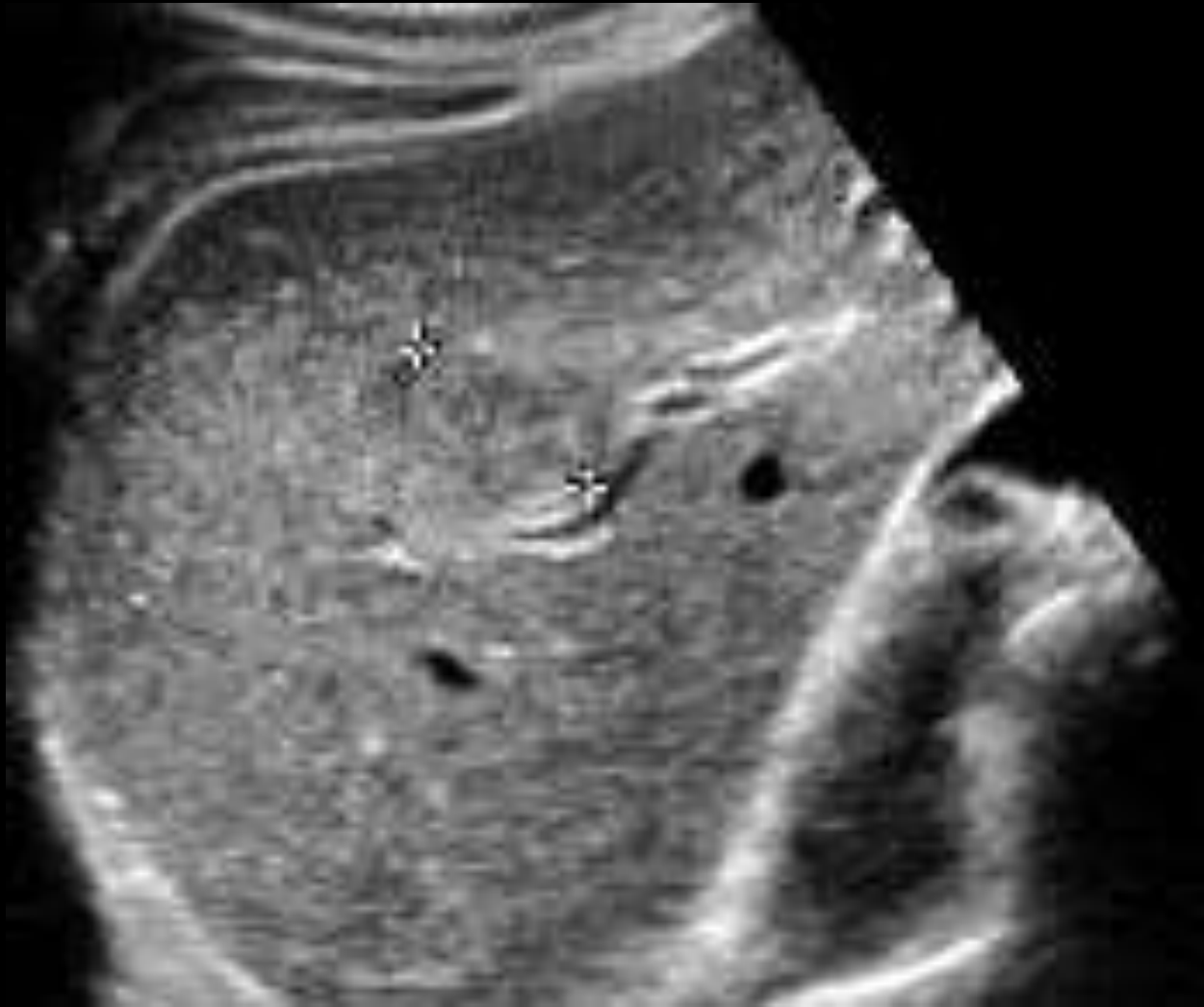
Na co se soustředit

Žena, náhodný nález, roč. 78

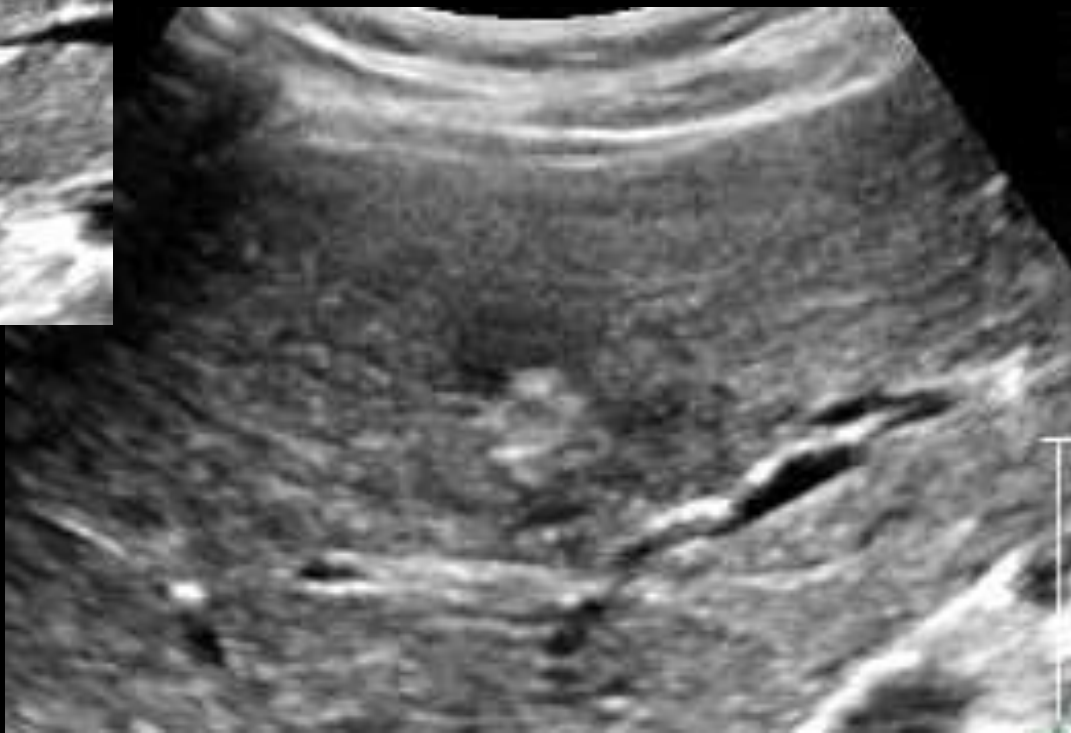
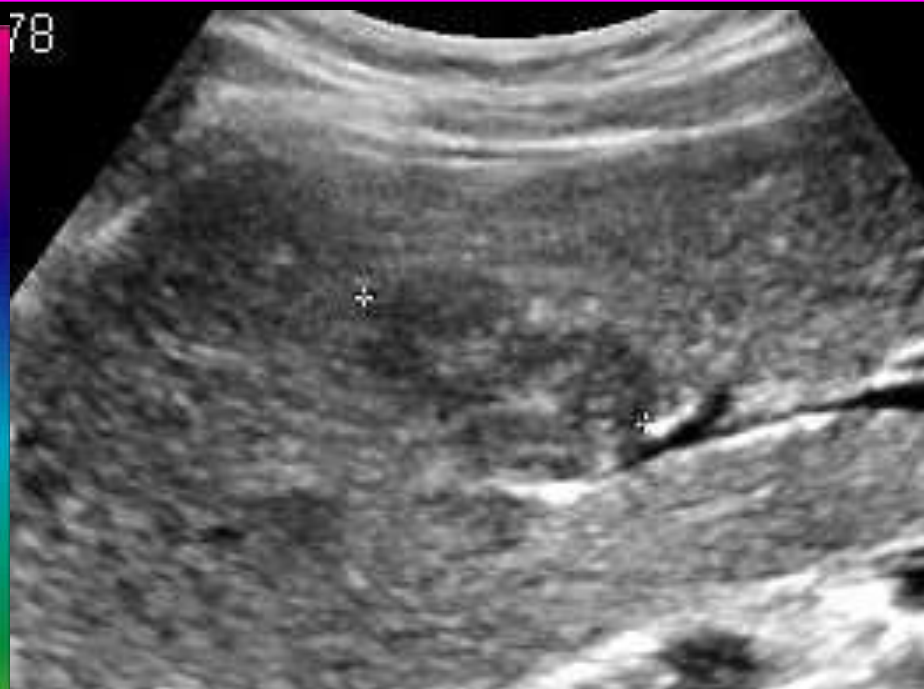Benigní 20.12.11??



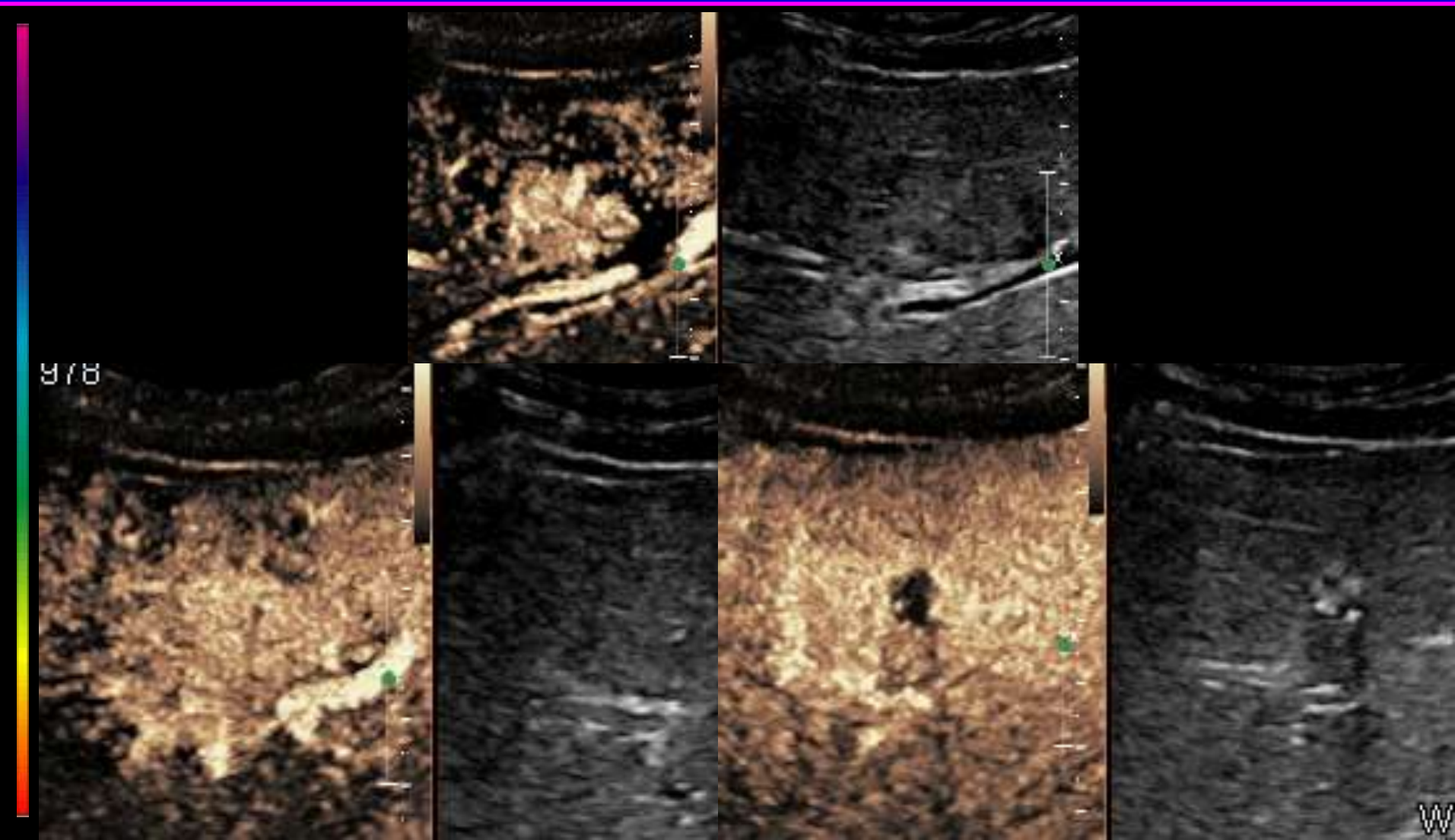
Benigní 12.06.12??



Benigní??



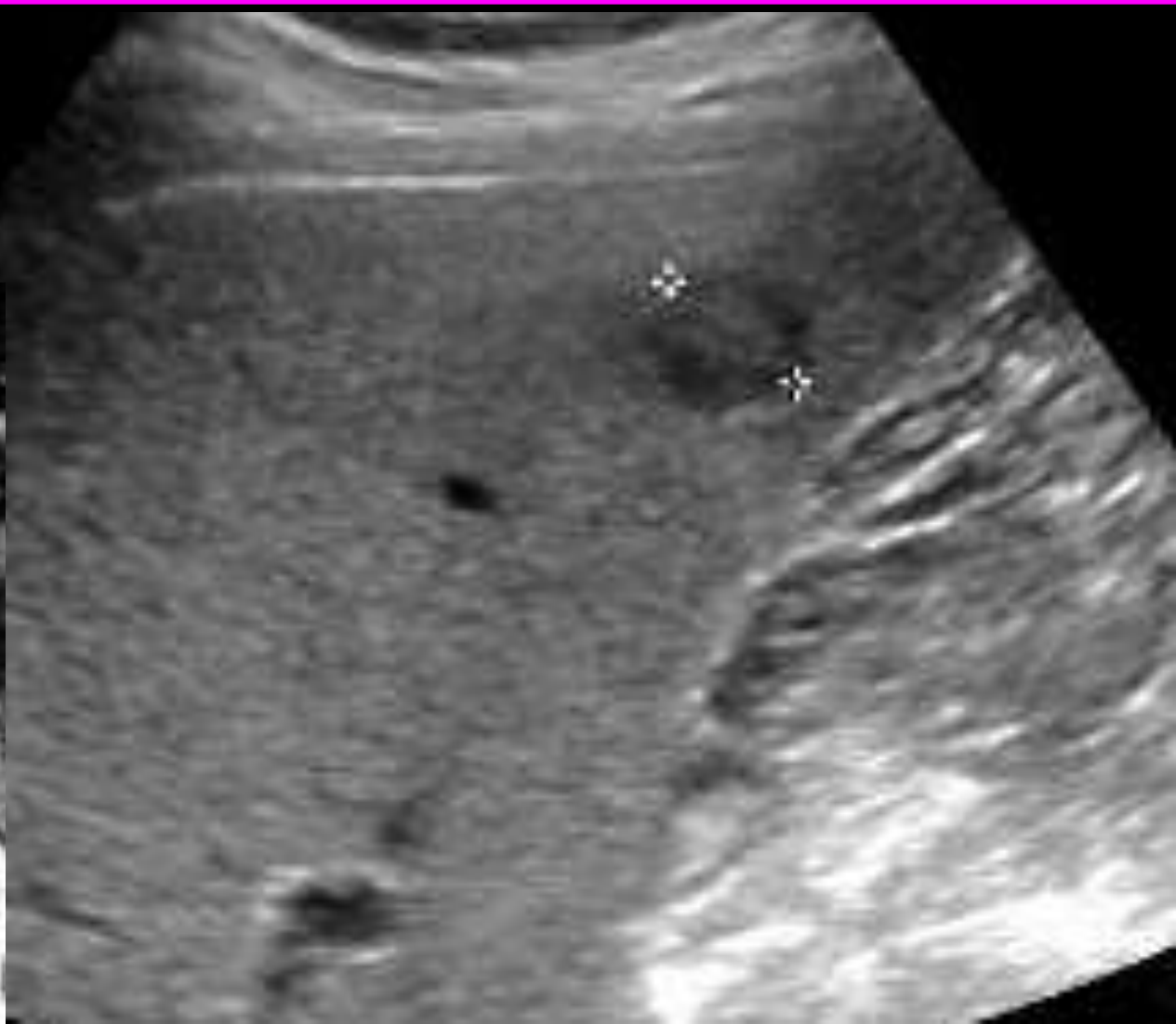
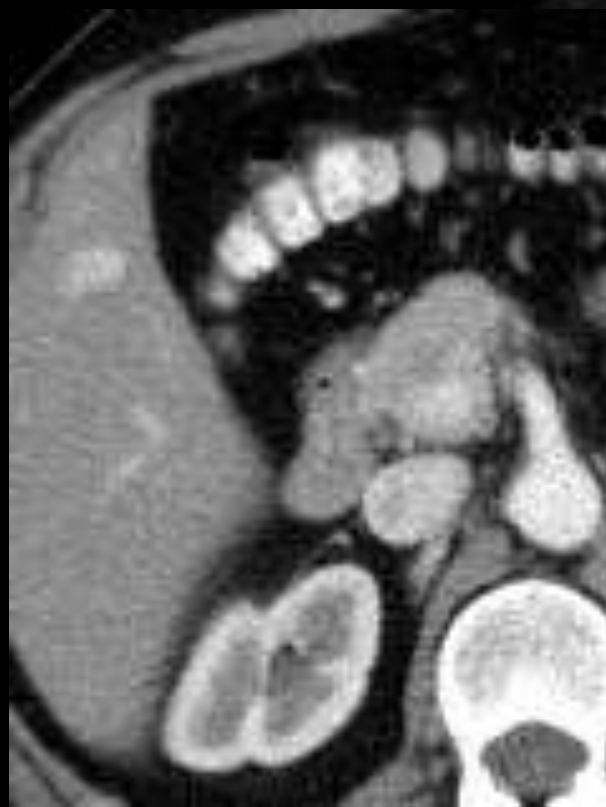Benigní??



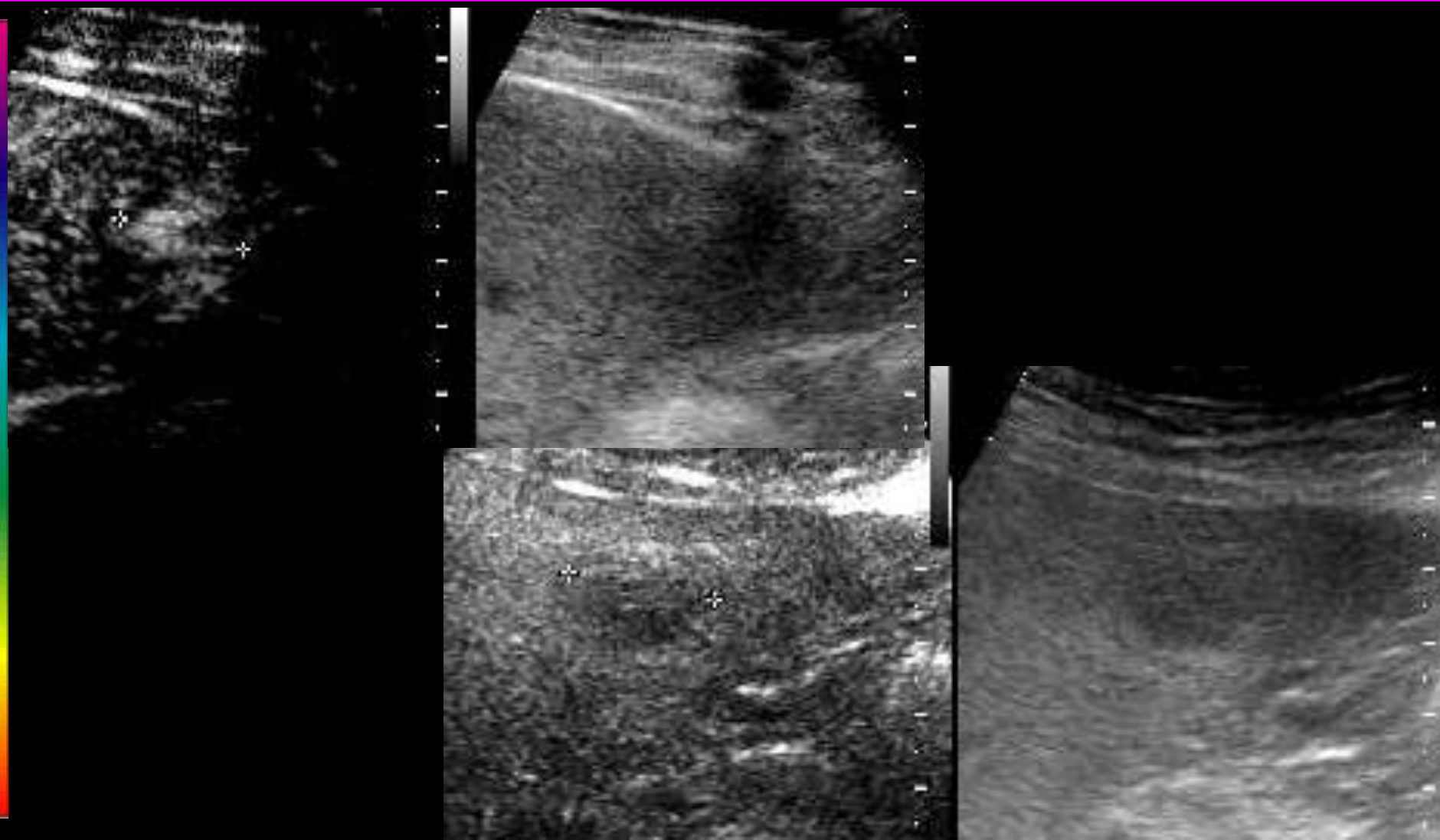
Na co se soustředit

Muž, epitheloidní maligní schwanom, roč. 65

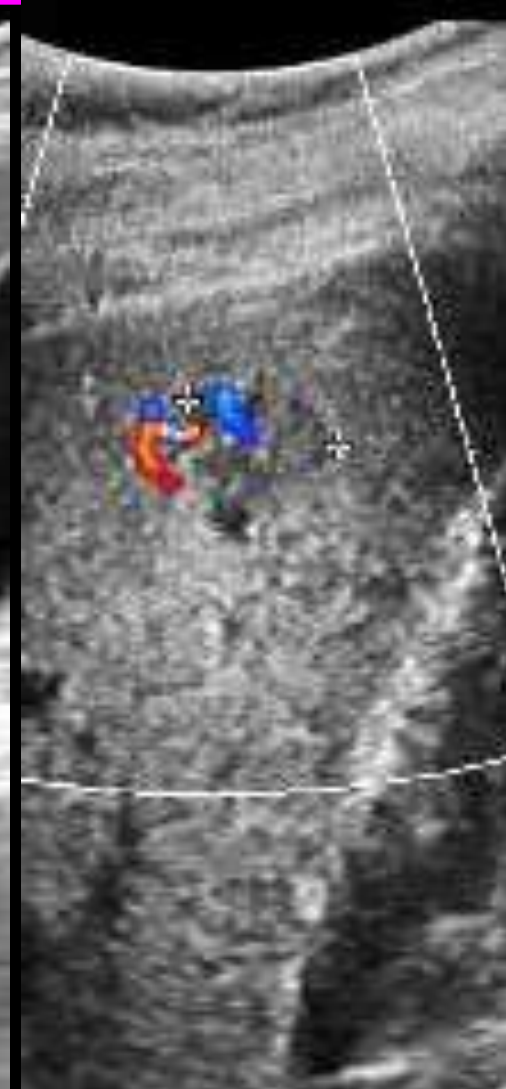
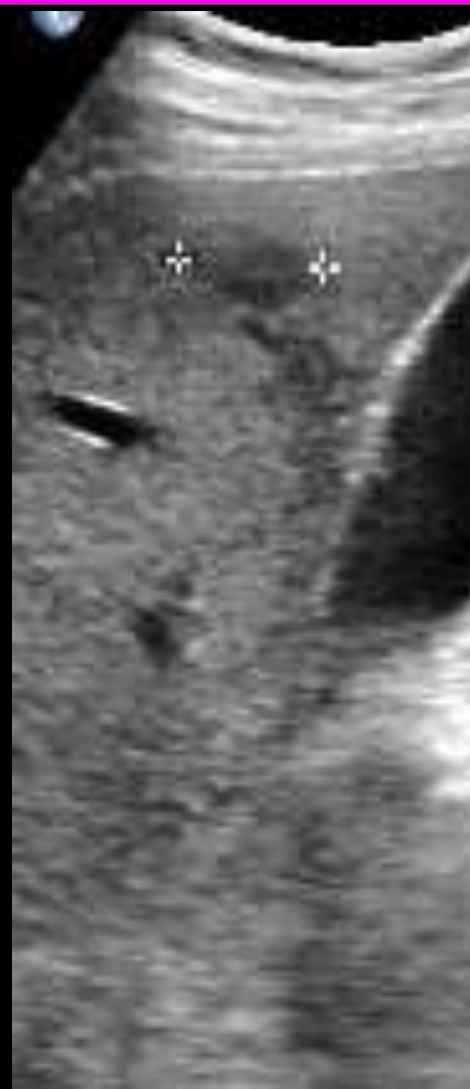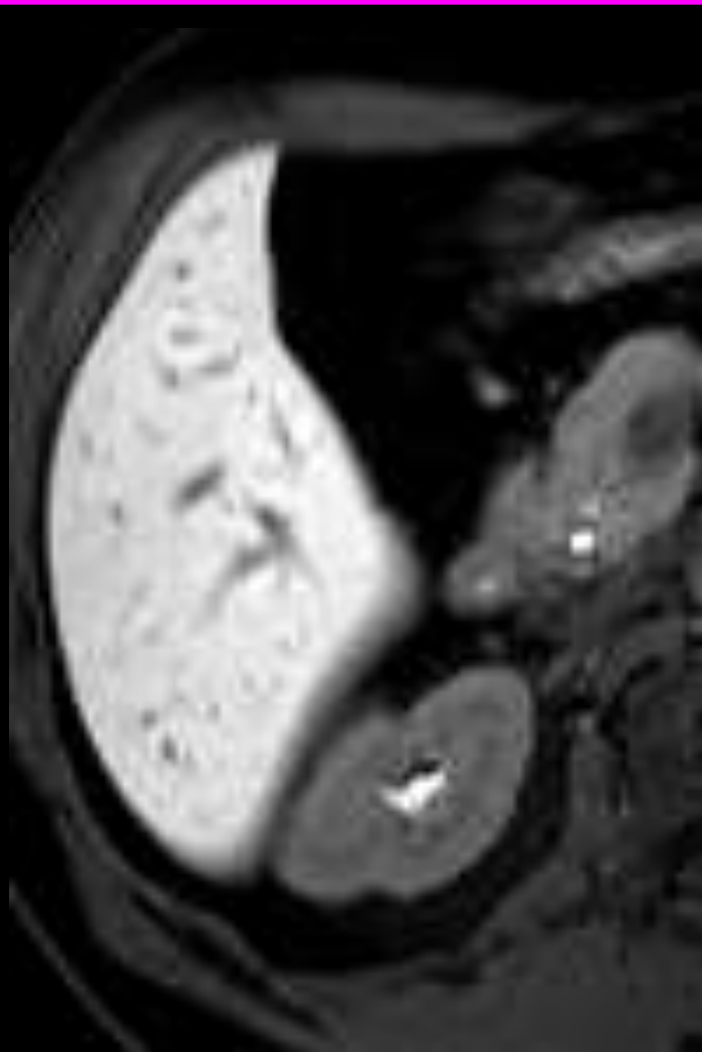
Benigní??



Benigní??



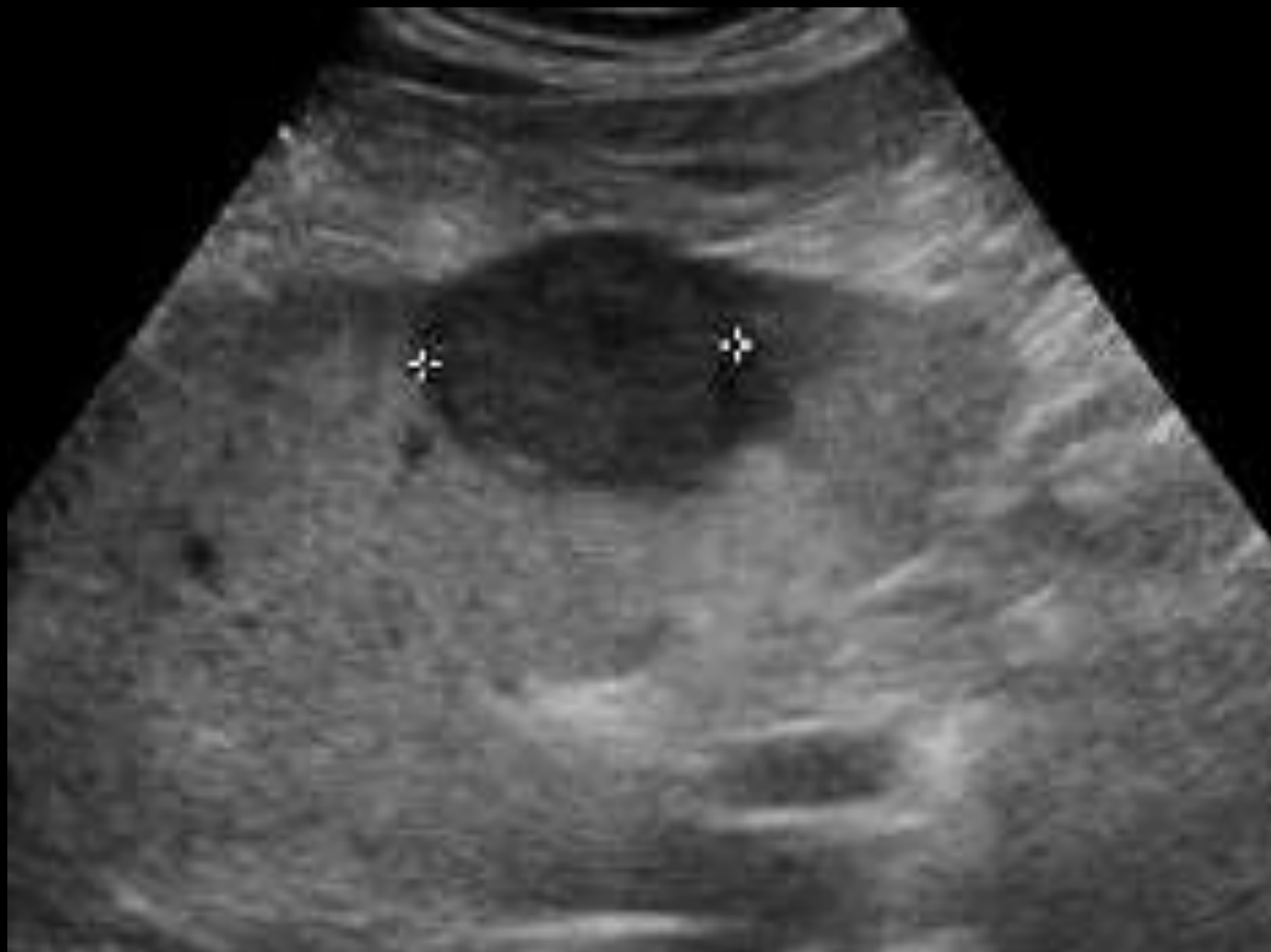Benigní??



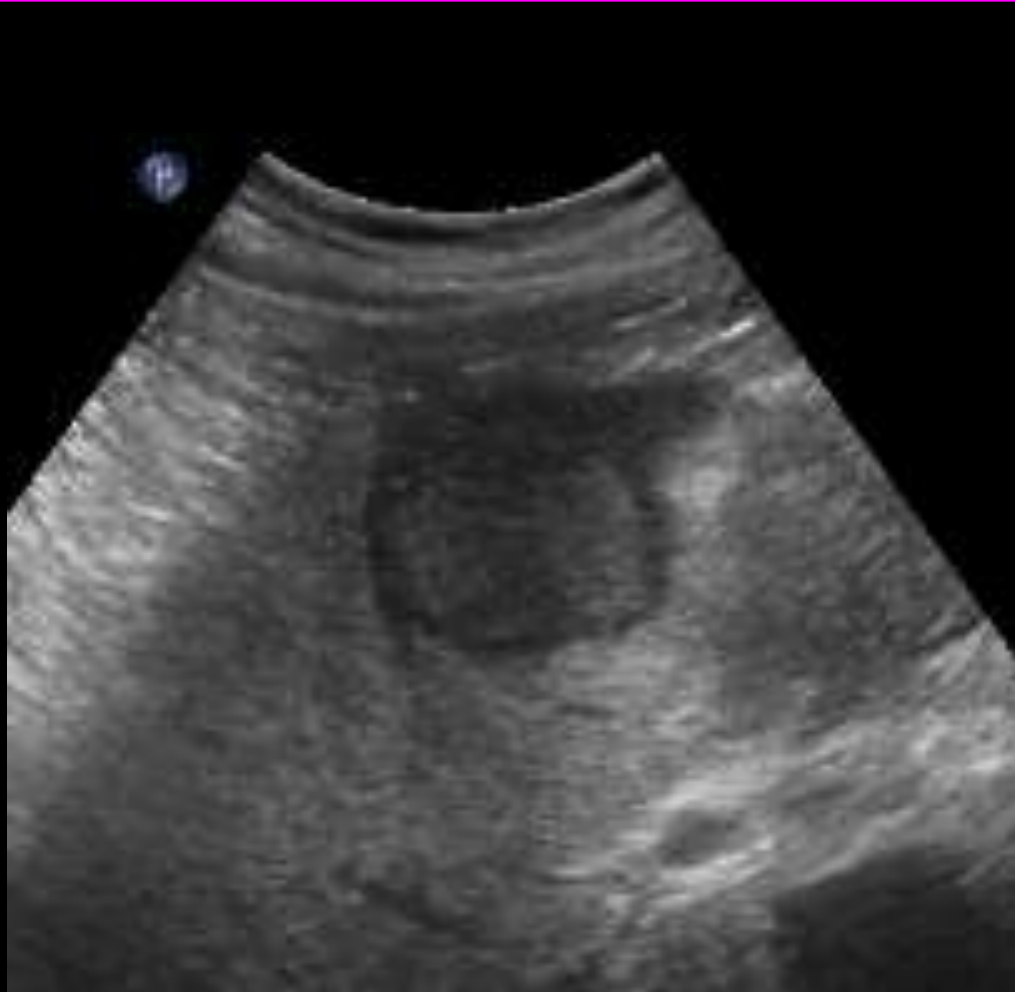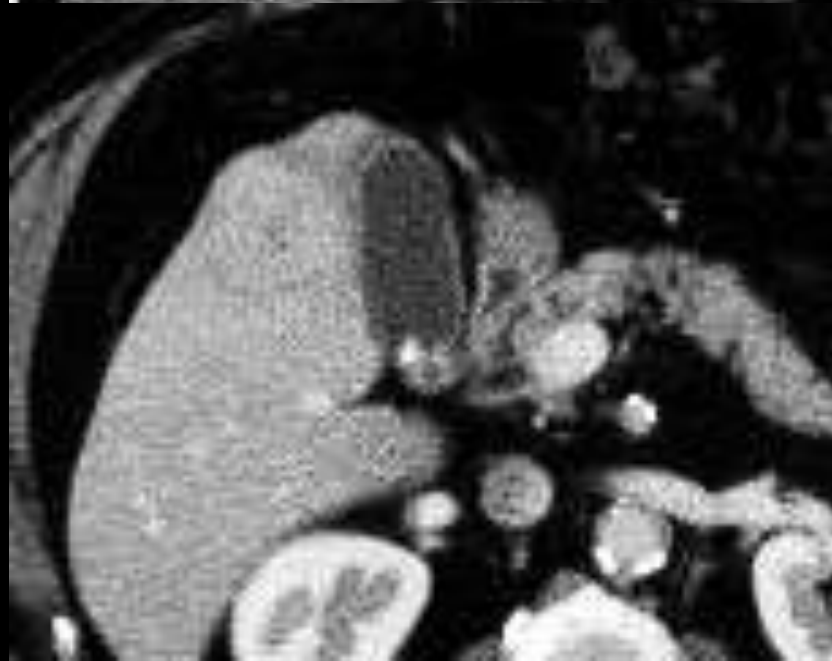
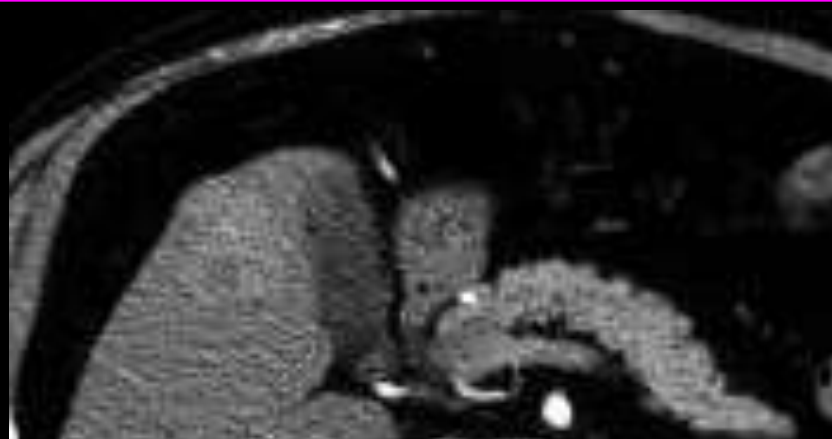Na co se soustředit

Muž, cirhóza, sledovaný, roč. 40

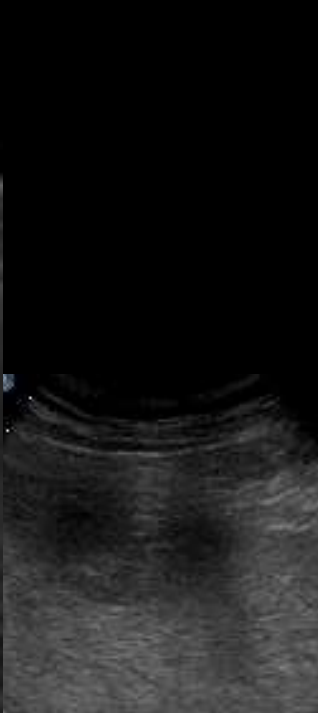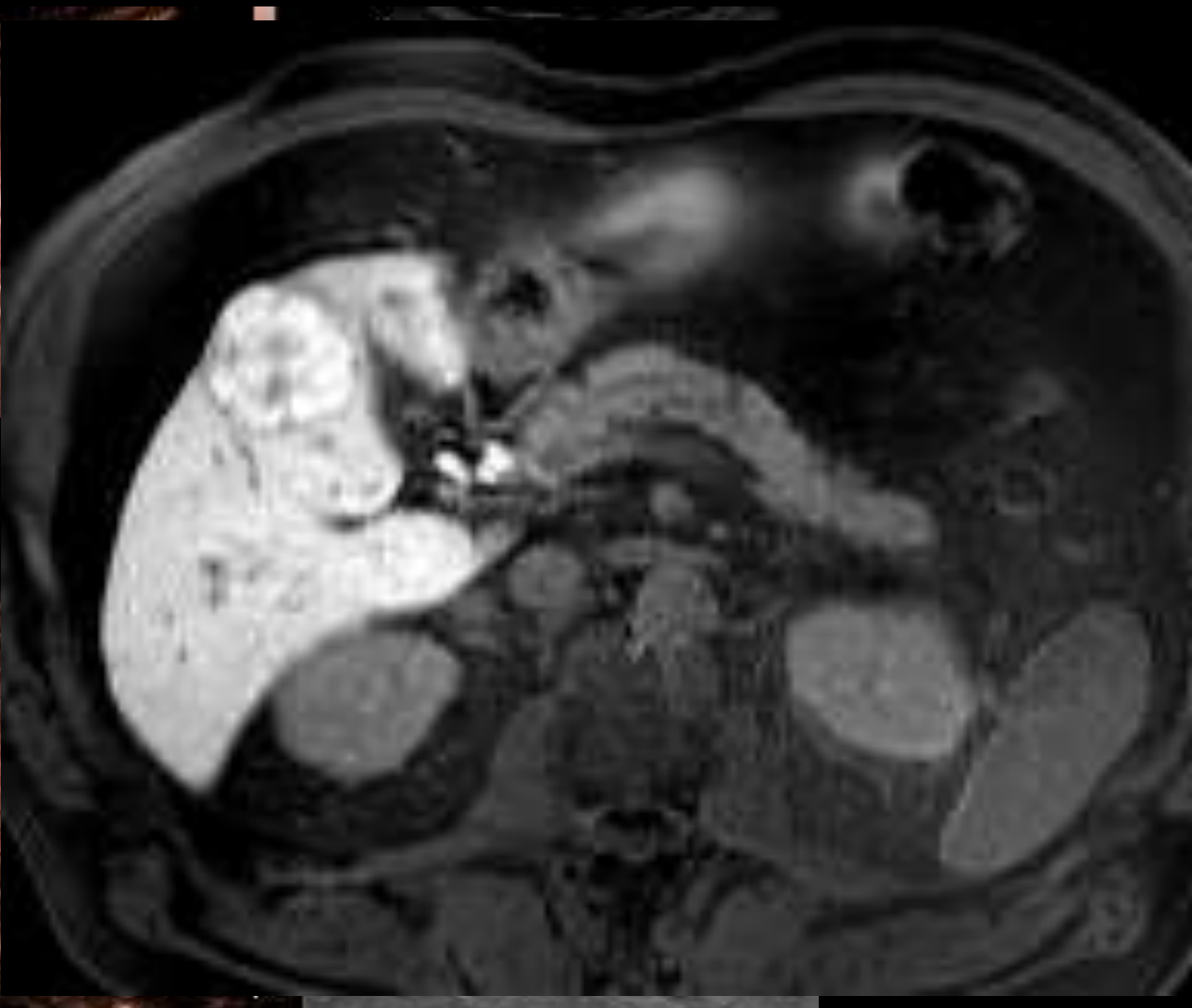

Benigní??



Benigní??



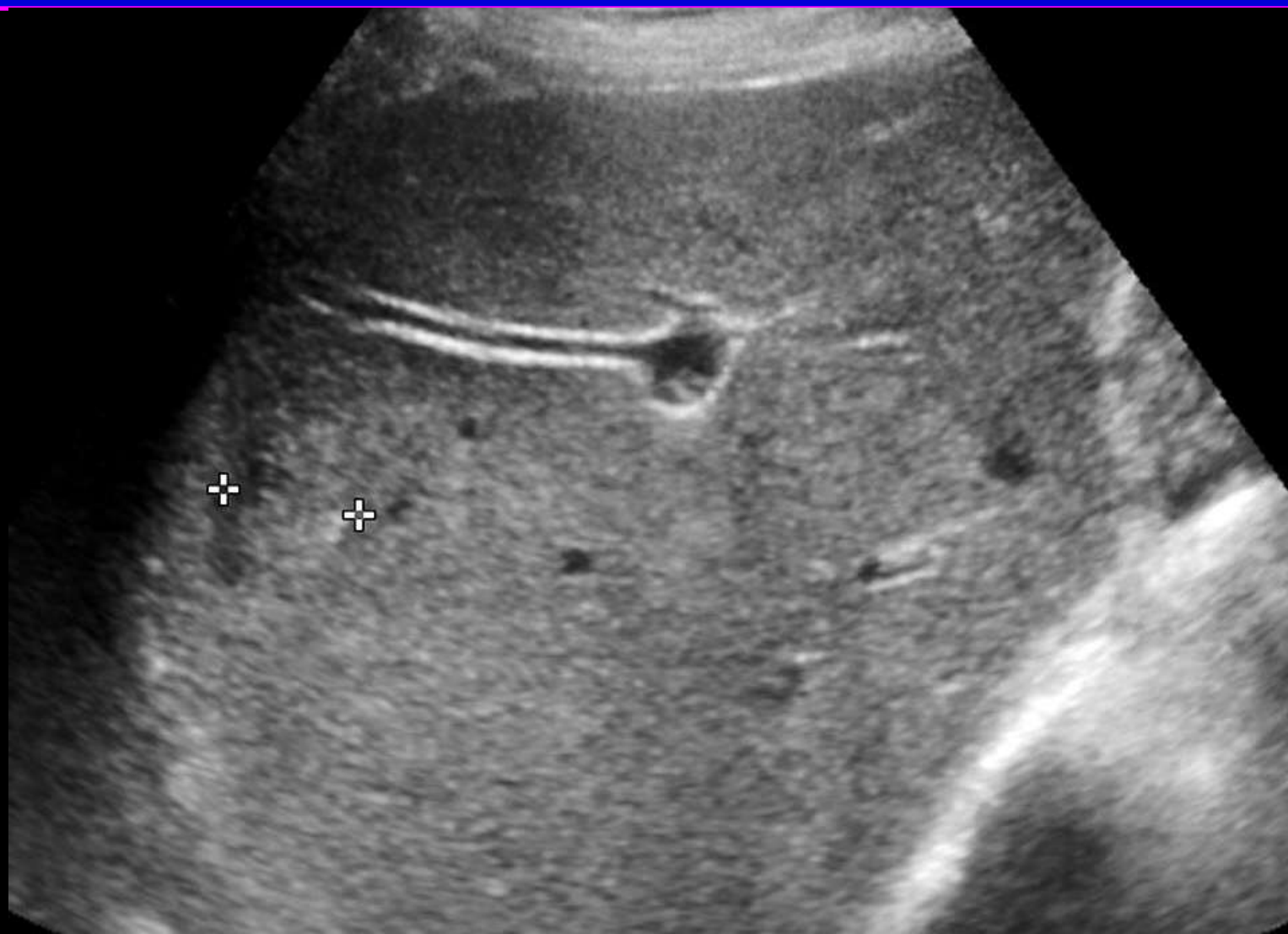
Benigní??



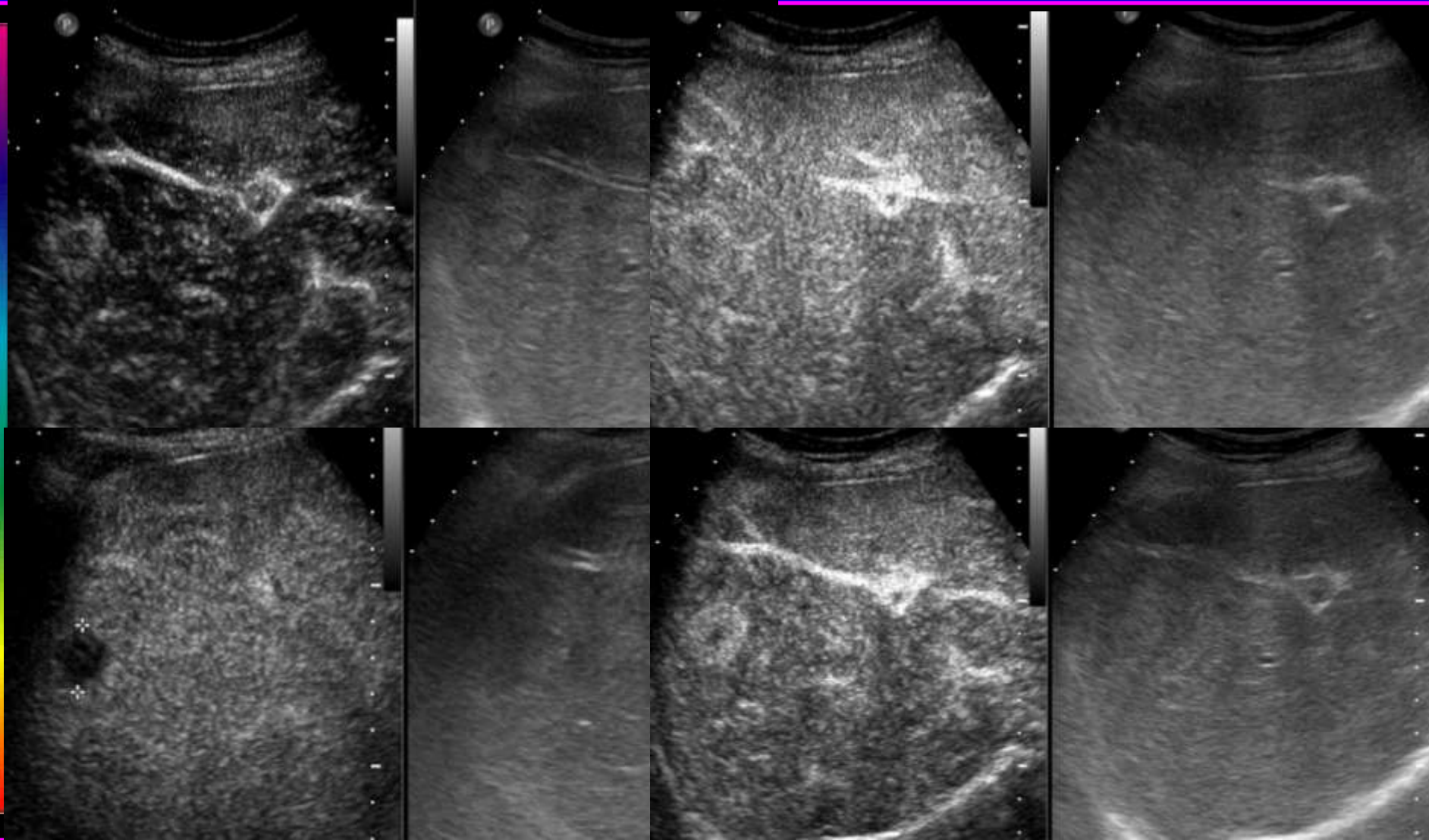
Na co se soustředit

Muž, po operaci kolorektálu před dvěma roky, CT negativní před dvěma týdny, sledovaný, roč. 40

Benigní??



Benigní??



Střeva

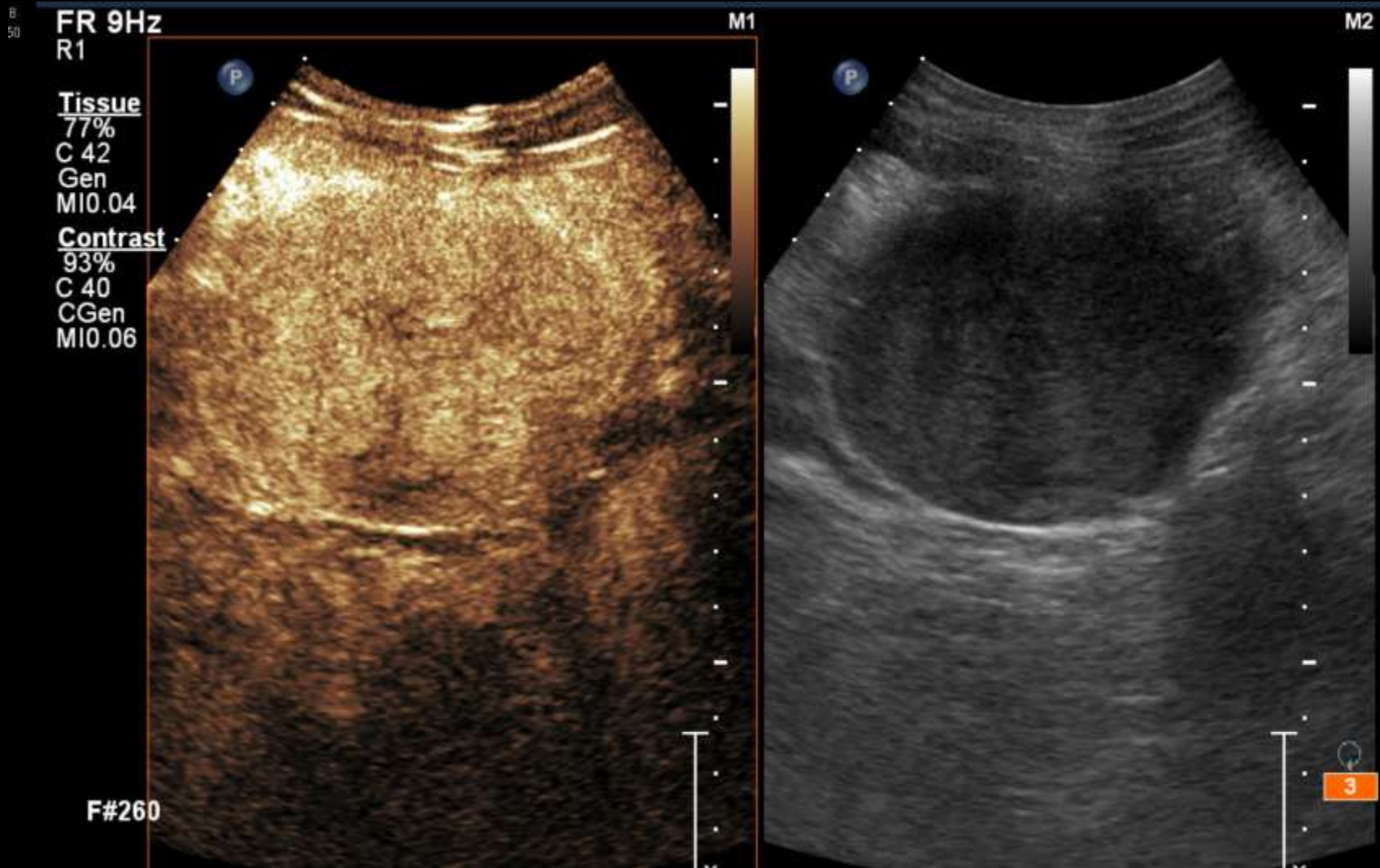
Na co se soustředit - střevo

- 1. Jak dlouho potíže trvají**
- 2. Jaká je kůže, chloupky**
- 3. Krev ve stolici**
- 4. Hmatná rezistence**
- 5. Lokalizace bolesti (hubení – aorta)**
- 6. Operace (APE)**

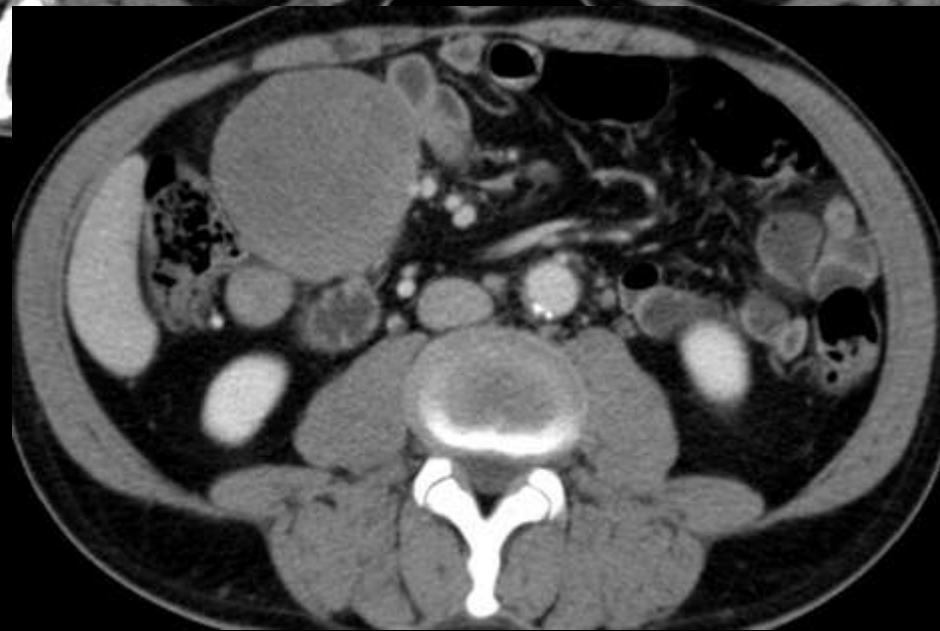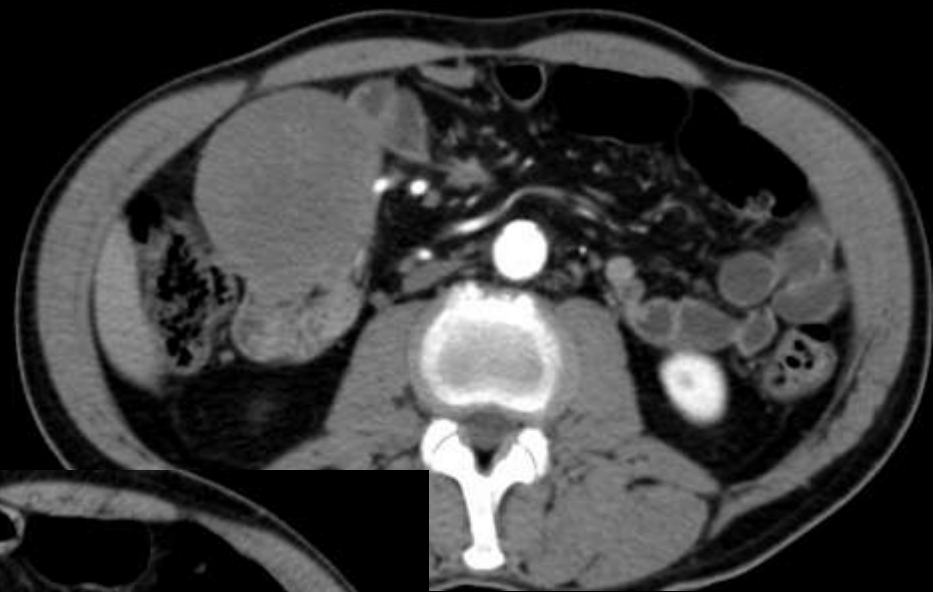
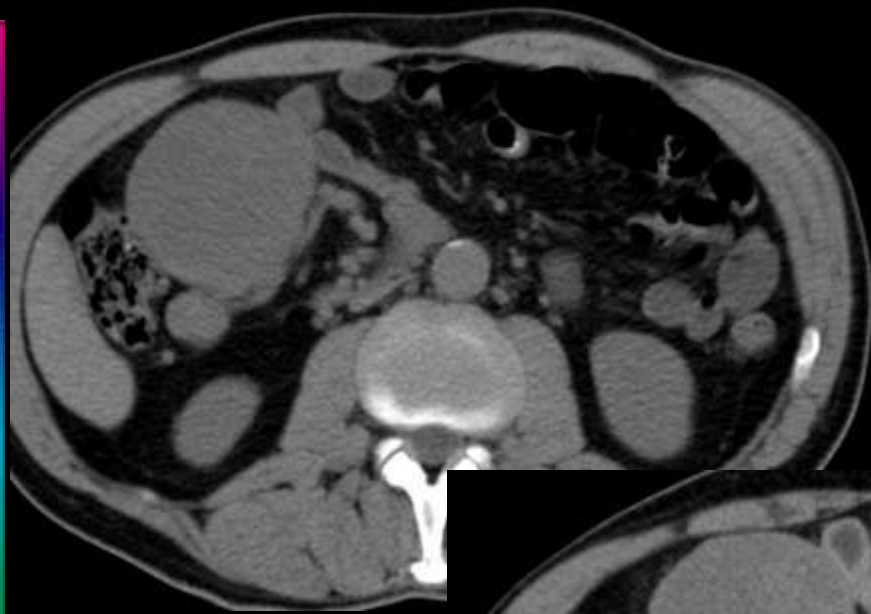Na co se soustředit

Muž, roč. 48, krev ve stolici, hmatná rezistencem, hubne.

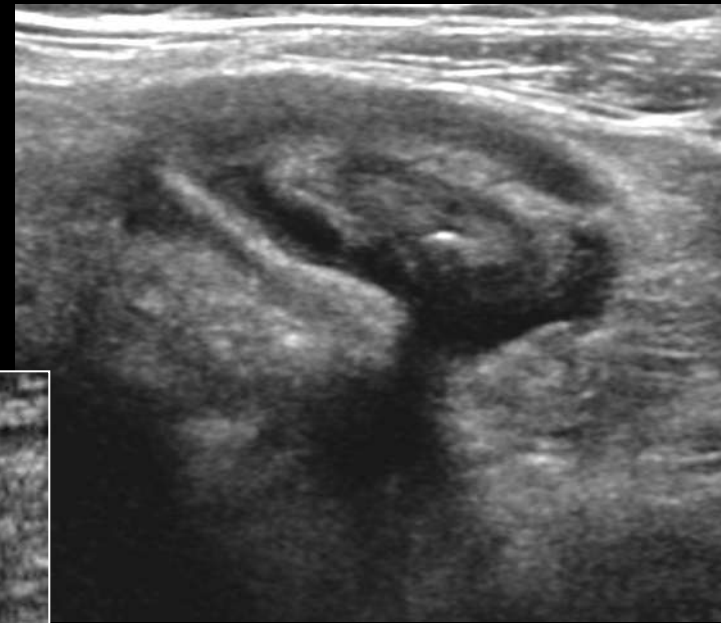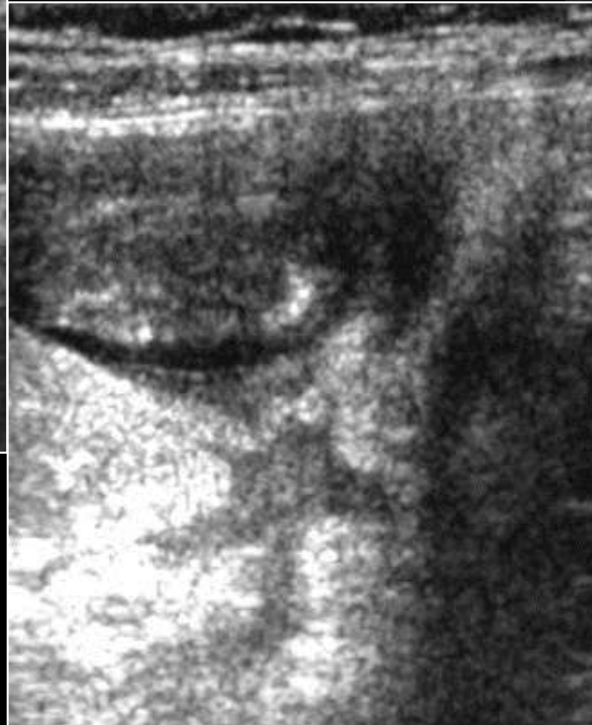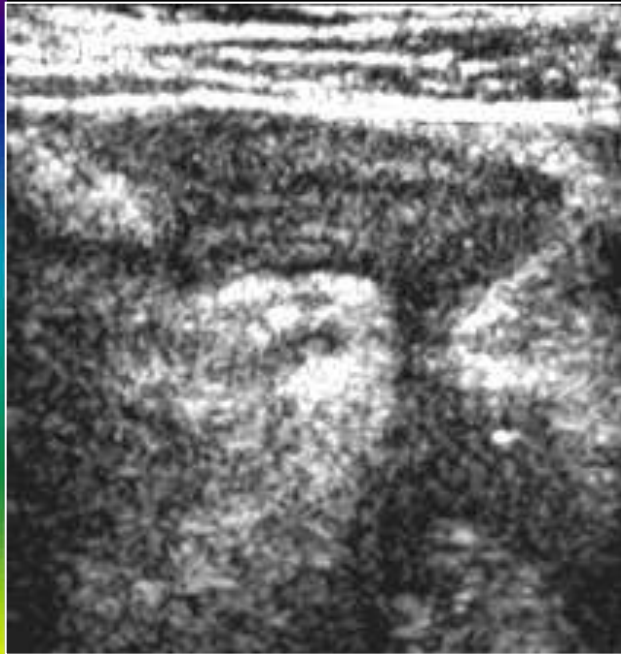
Střevo



Střevo



Střeva



Pankreas

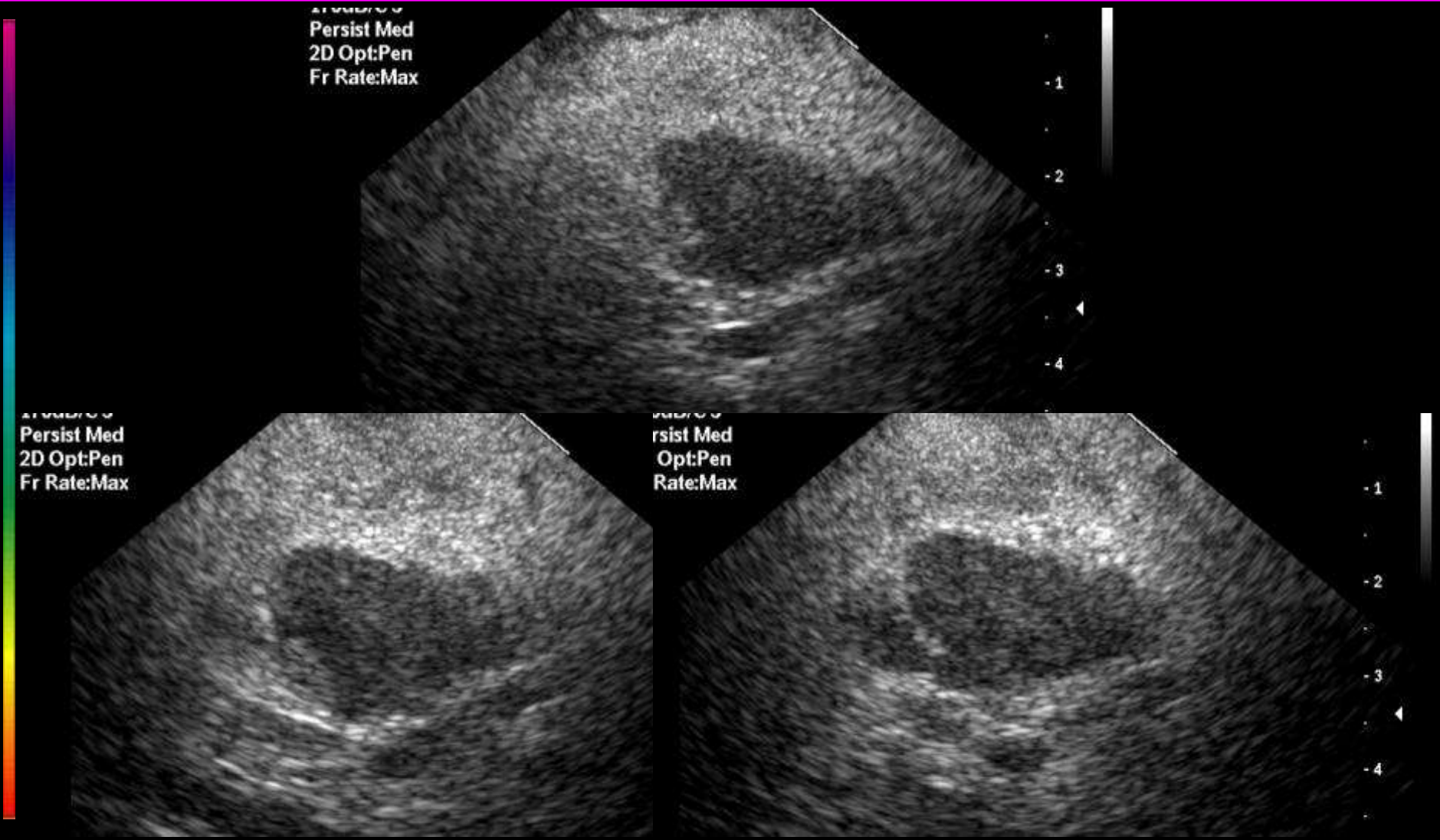
Na co se soustředit - pankreas

- 1. Jak dlouho potíže trvají**
- 2. Klinické známky akutní pankreatitidy**
- 3. Laboratoř**
- 4. Játra - metastázy**
- 5. Dilatace pankreatického vývodu/DCH**

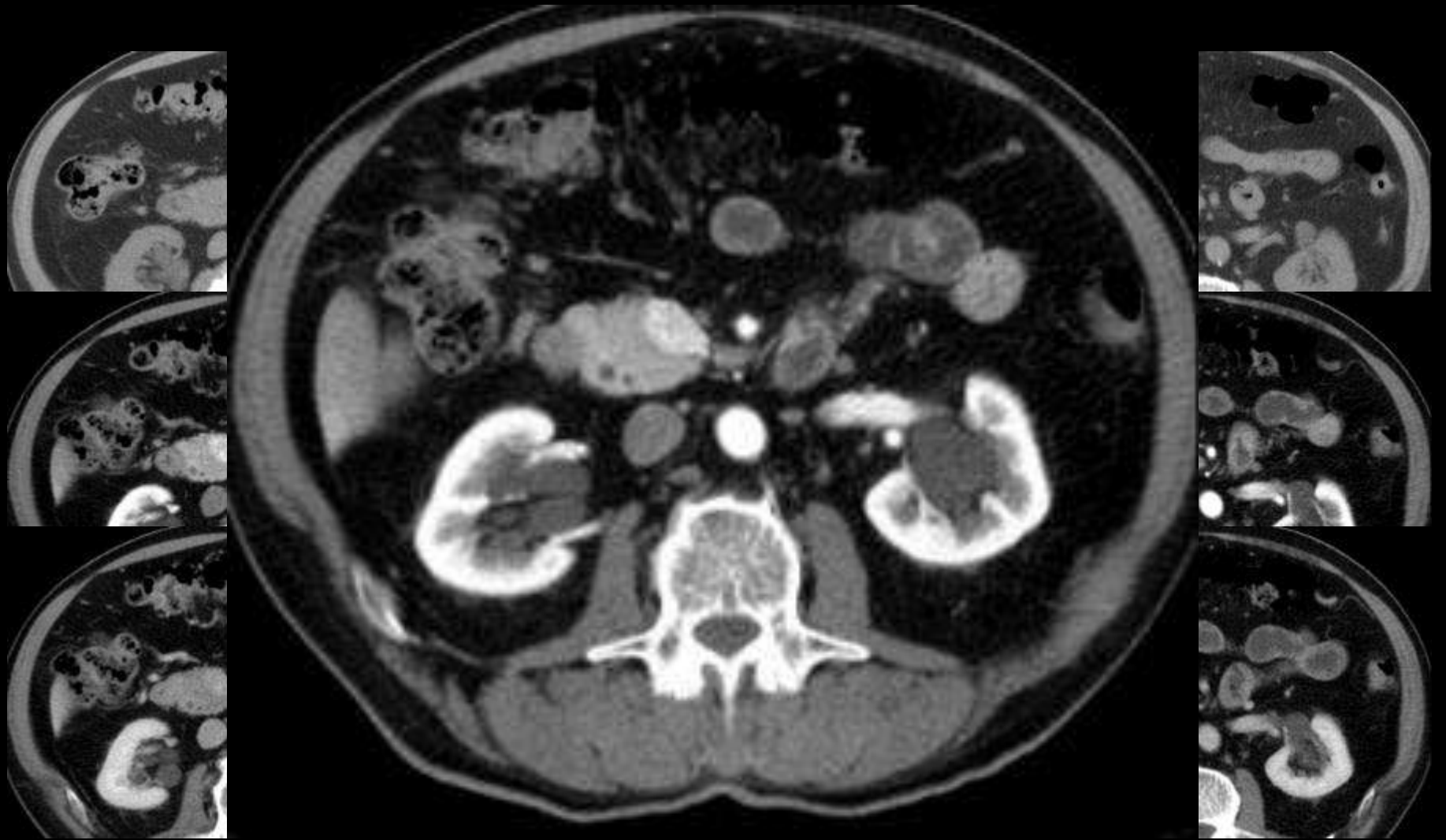Na co se soustředit

**Muž roč. 43, neurčité bolesti, potíže
dlouhodobé, náhodný nález**

??



??

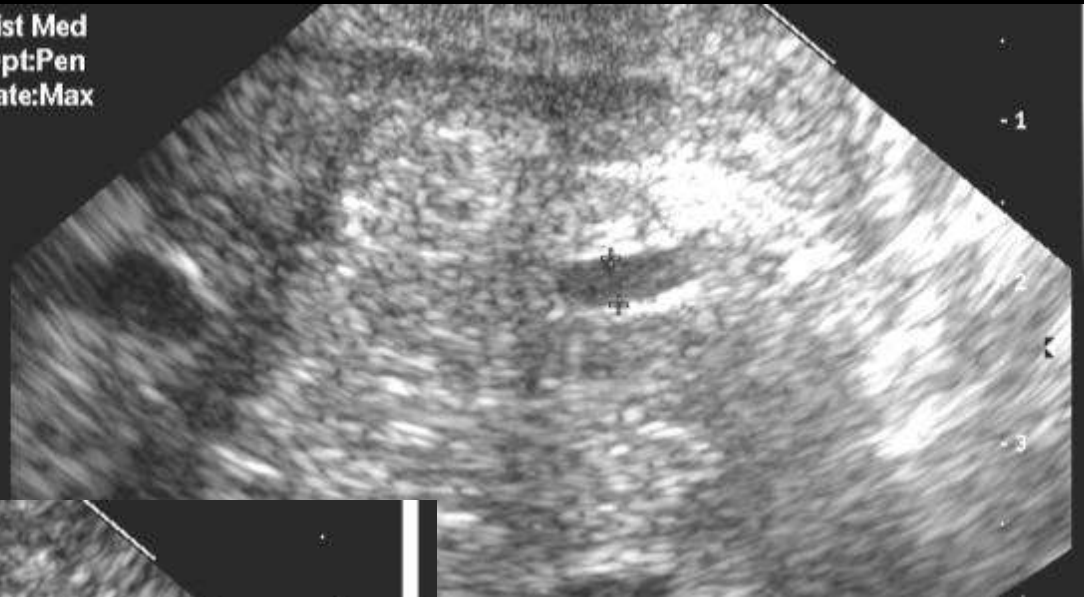


Na co se soustředit

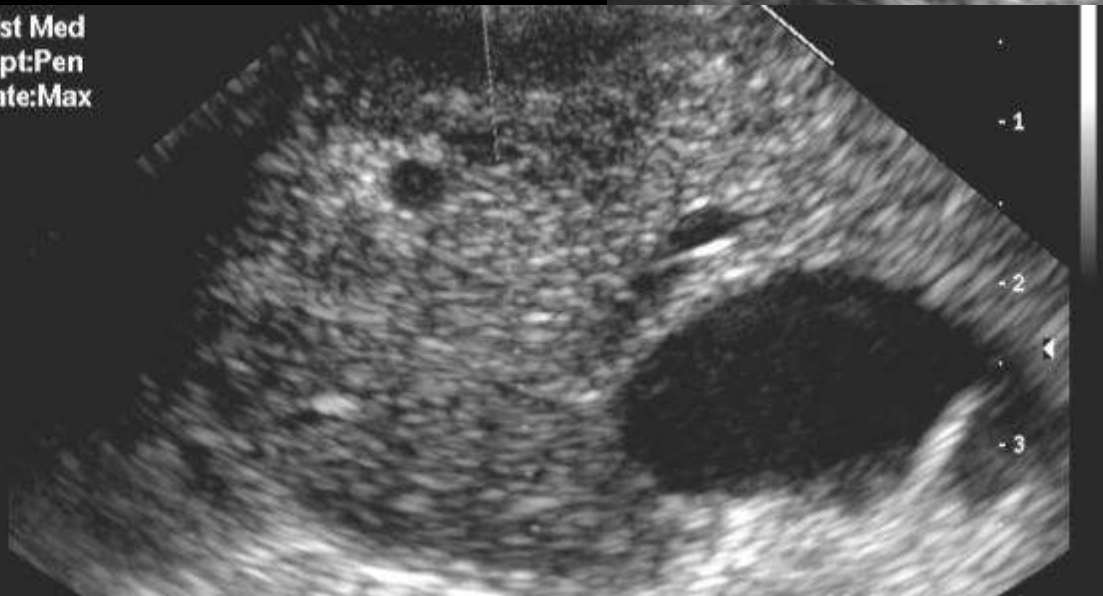
**Muž roč. 63, téměř půl roku trvající potíže
imponující jako pankreatitida**

??

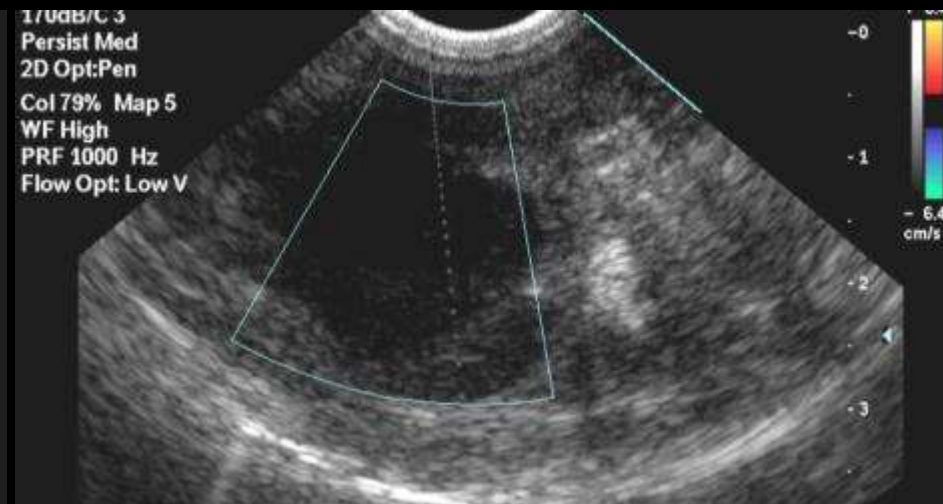
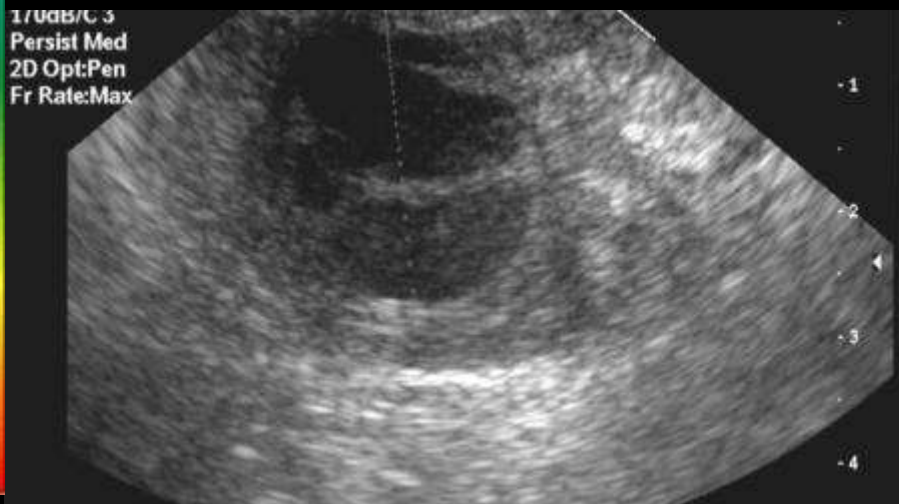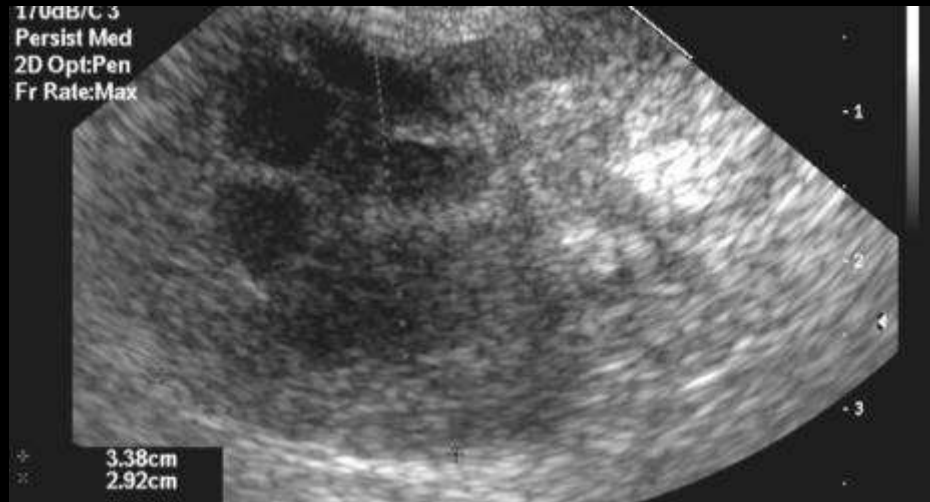Persist Med
2D Opt:Pen
Fr Rate:Max



Persist Med
2D Opt:Pen
Fr Rate:Max



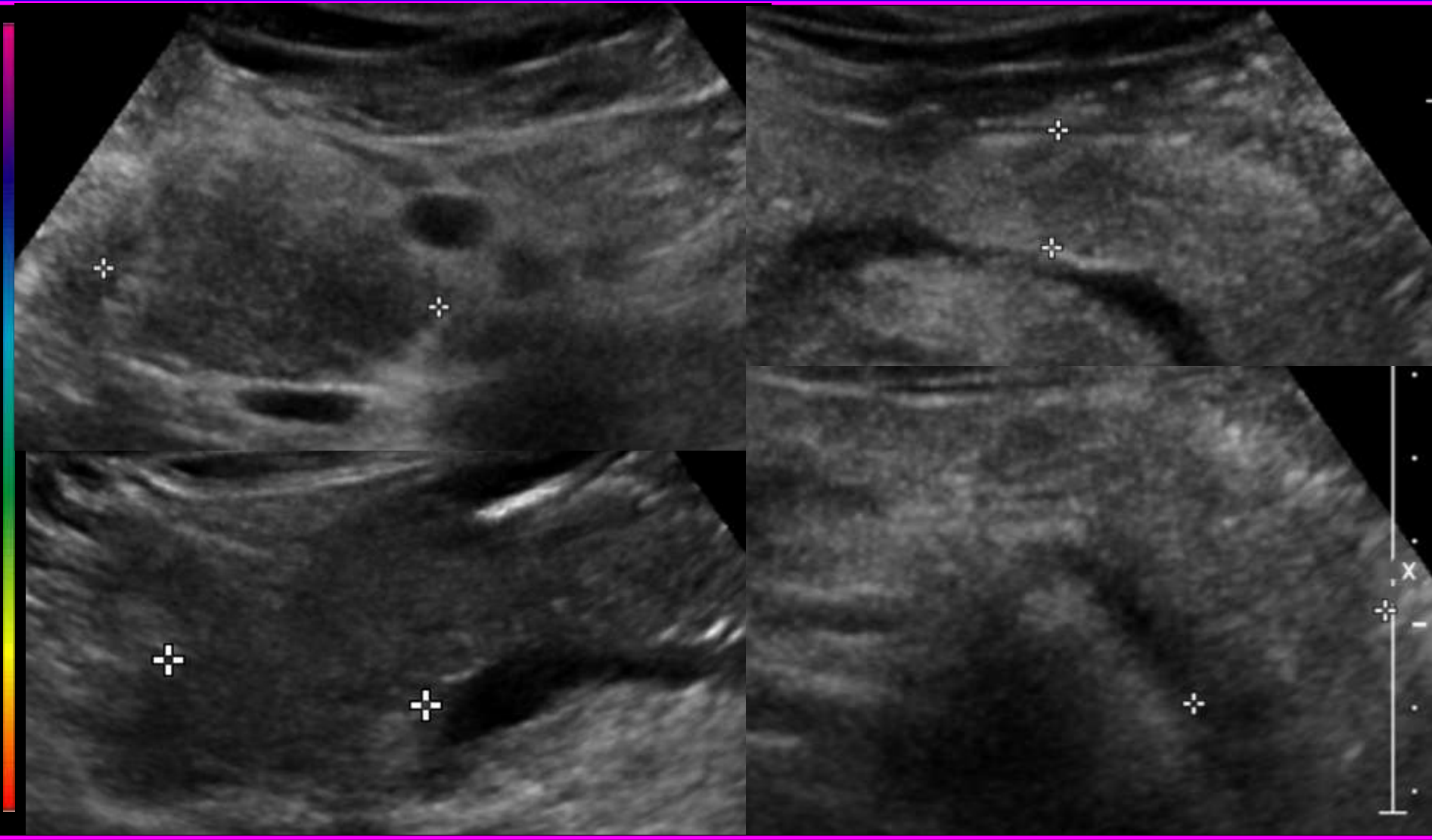
Pankreas, muž roč. 59



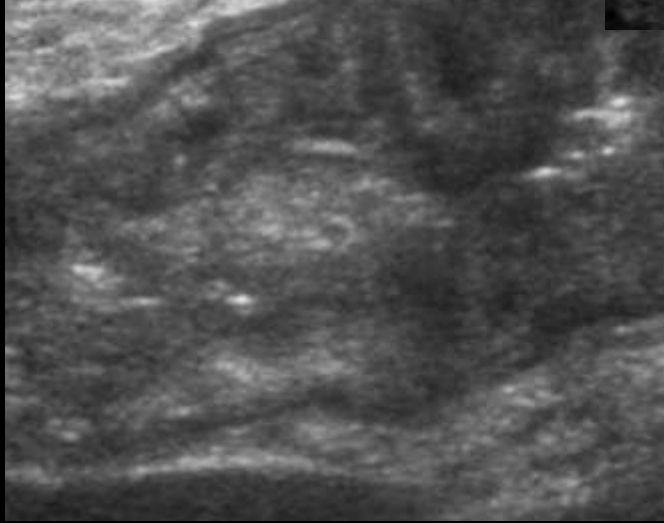
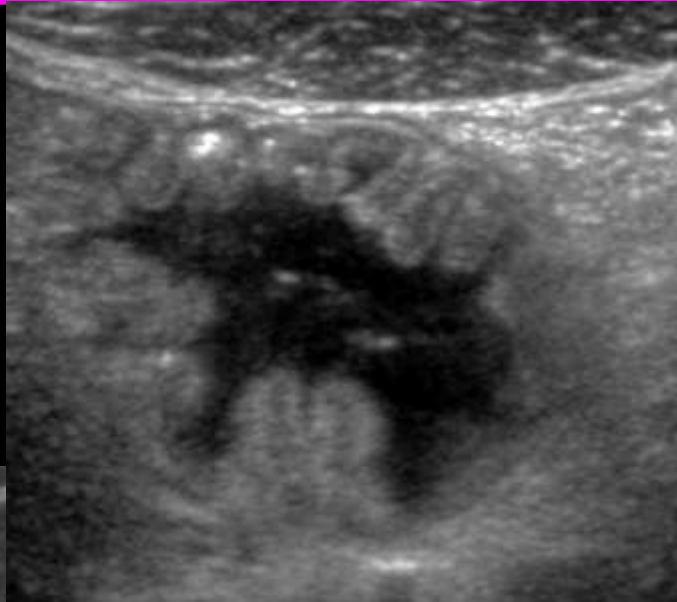
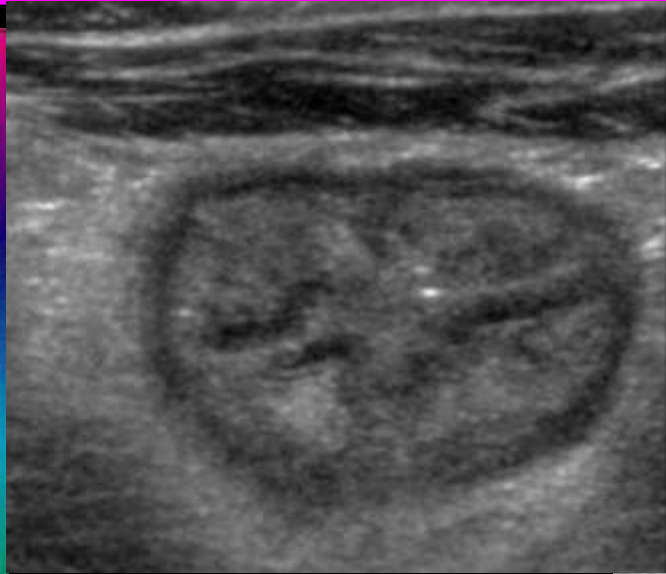
Na co se soustředit

Muž roč. 82, bolesti břicha, průjmy, občas krev ve stolici, hubne

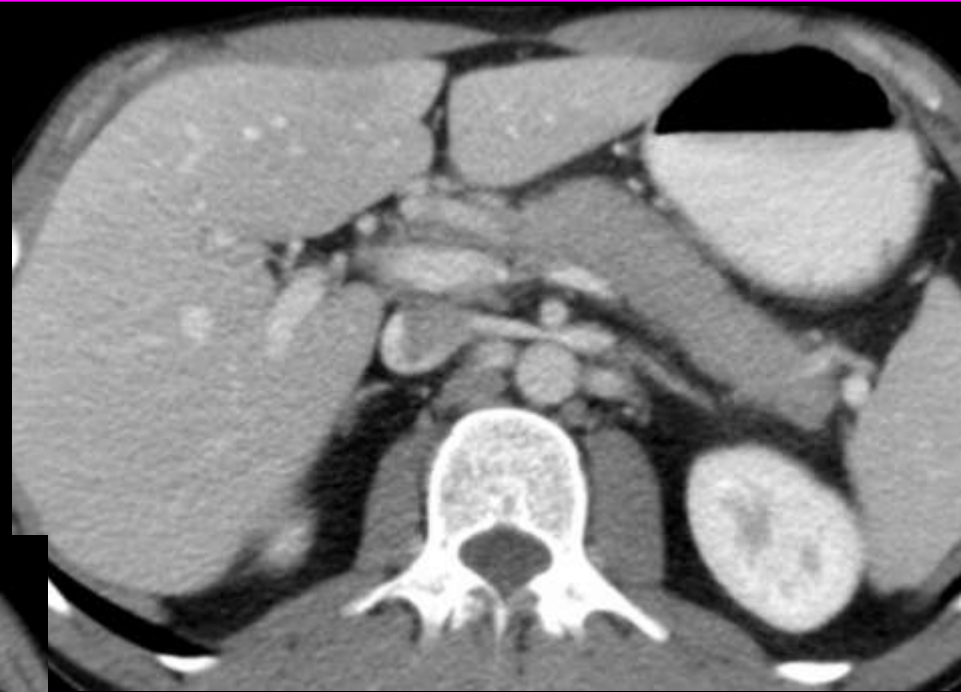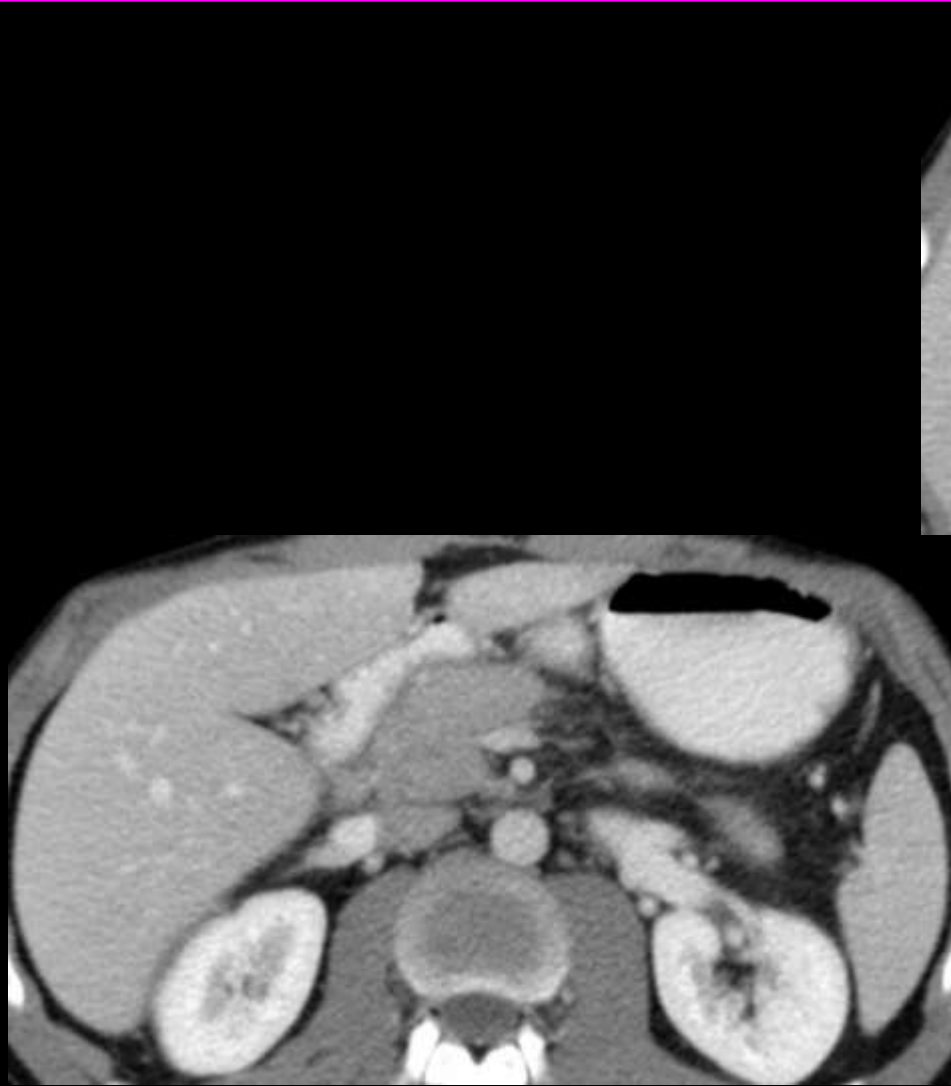??



??



??



Děkuji za pozornost

