


REGIONAL ANATOMY OF THE UPPER LIMB



**Regio deltoidea, reg. axillaris, reg. brachii ant., reg. cubiti ant.,
reg. antebrachii ant., palma manus**

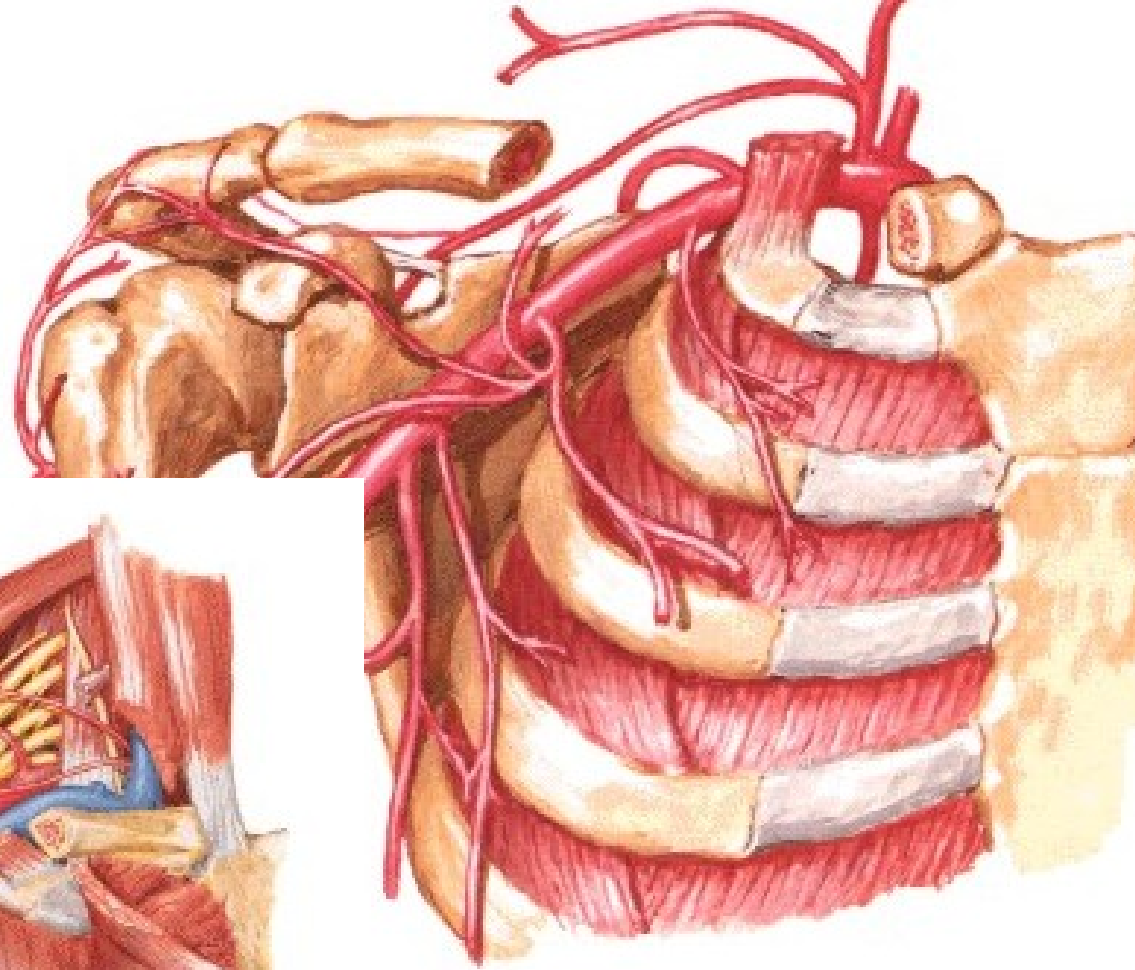
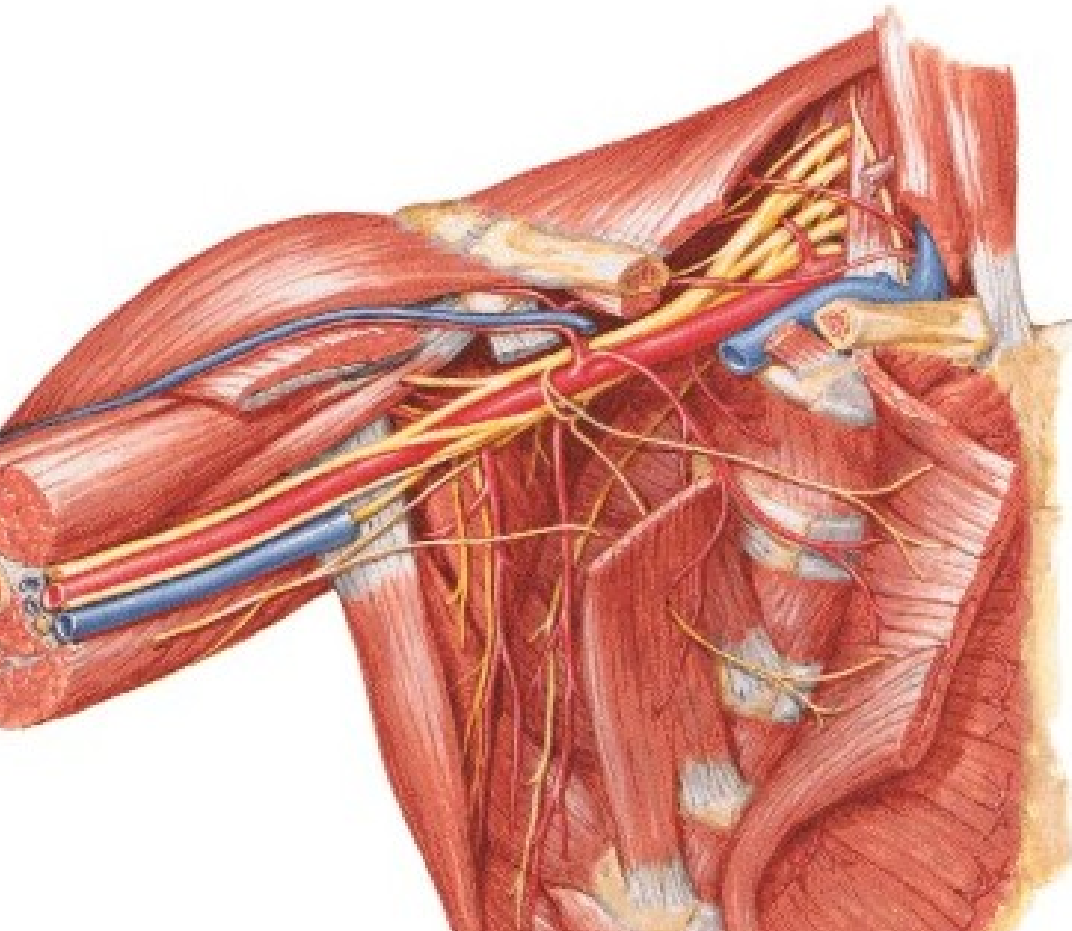


**Regio scapularis, reg. brachii post., reg. cubiti post.,
reg. antebrachii post., dorsum manus**

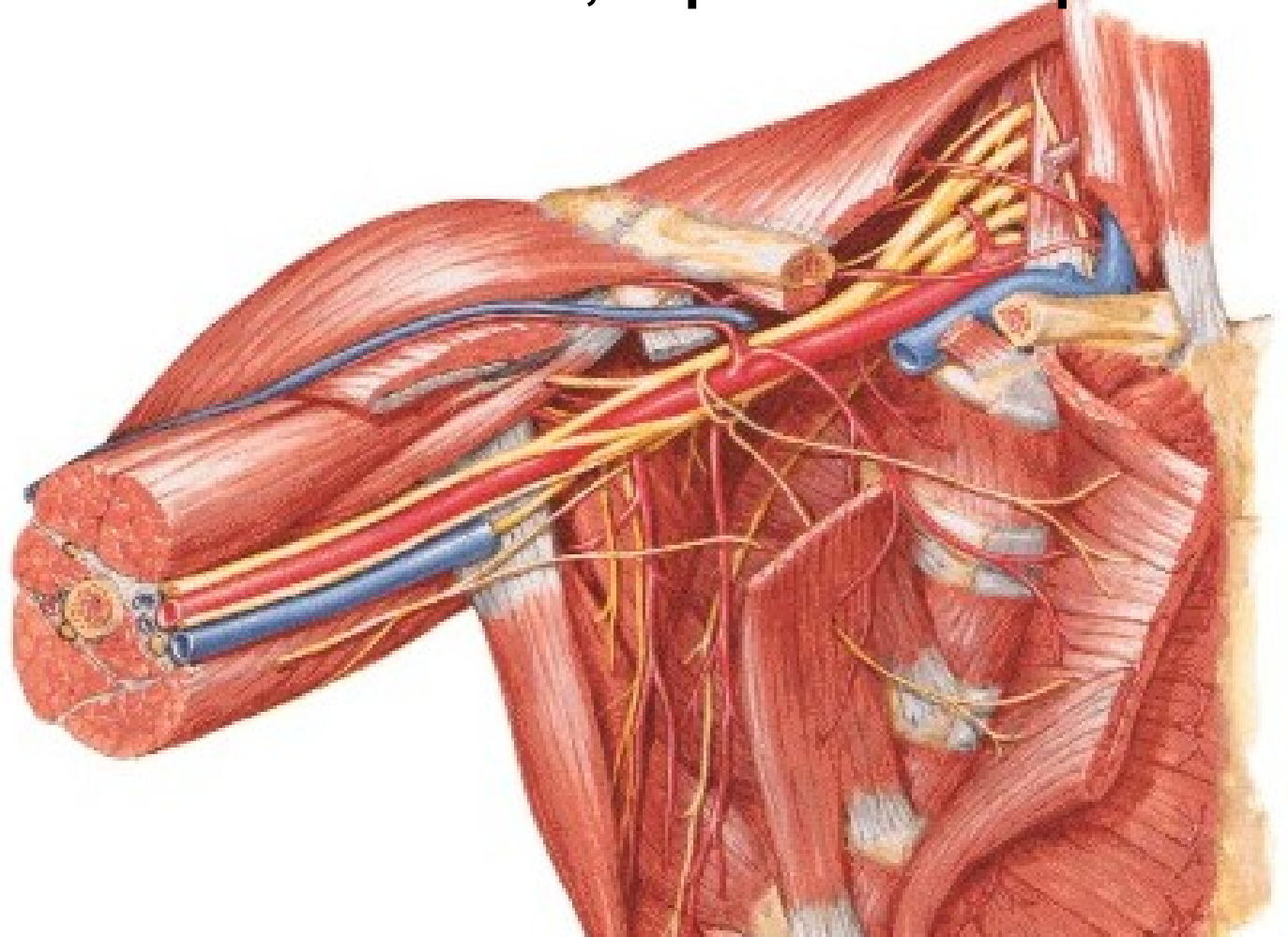
Regio axillaris

AXILLA

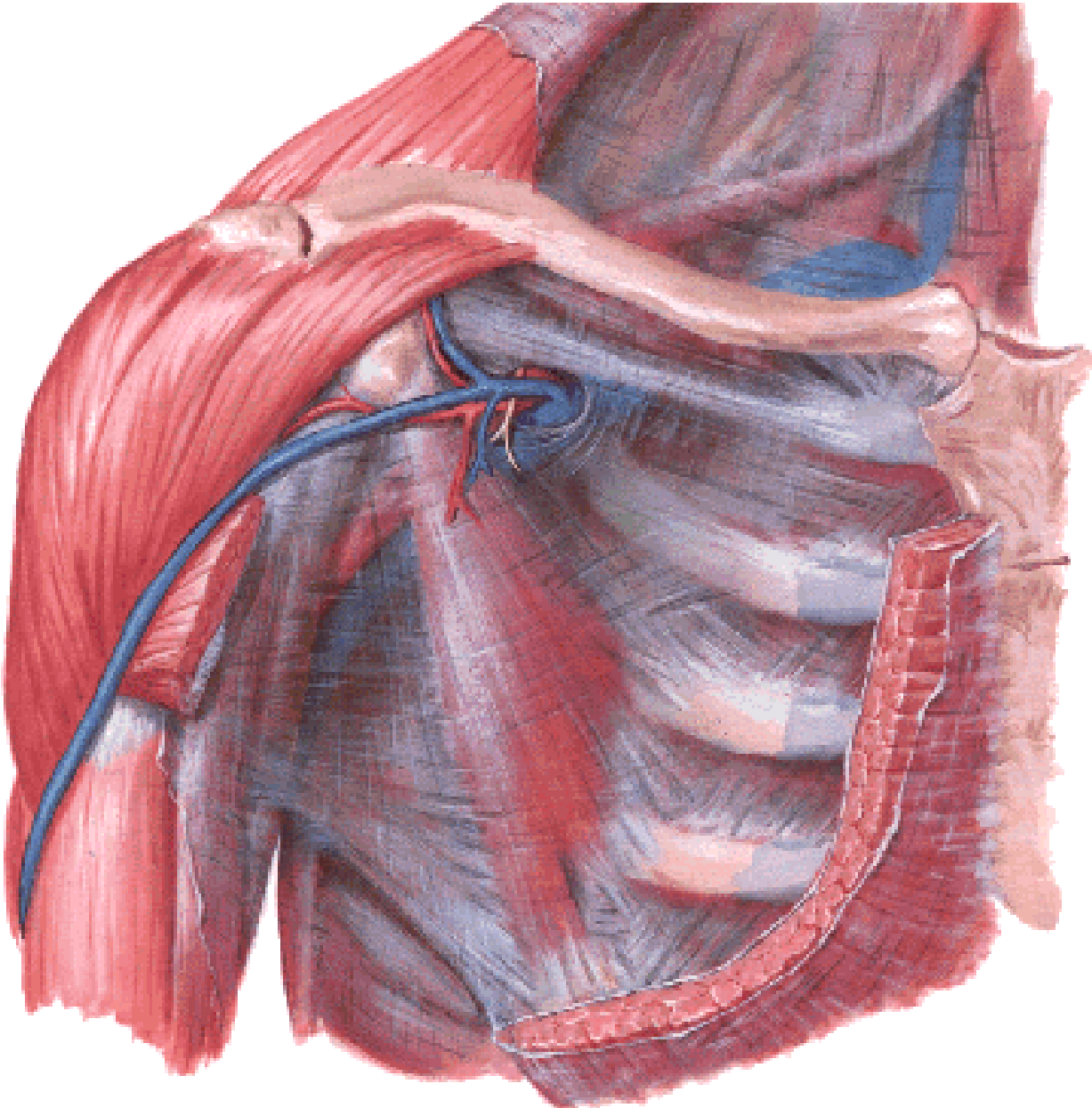
- inlet
- 4 sides
- floor



**Anterior wall: m. pectoralis major (n. pectoralis med. et lat.)
m. pectoralis minor (n. pectoralis med.)
m. subclavius (n. subclavius)
fascia clavipectoralis
a. thoracoacromialis, a. pectoralis sup.**

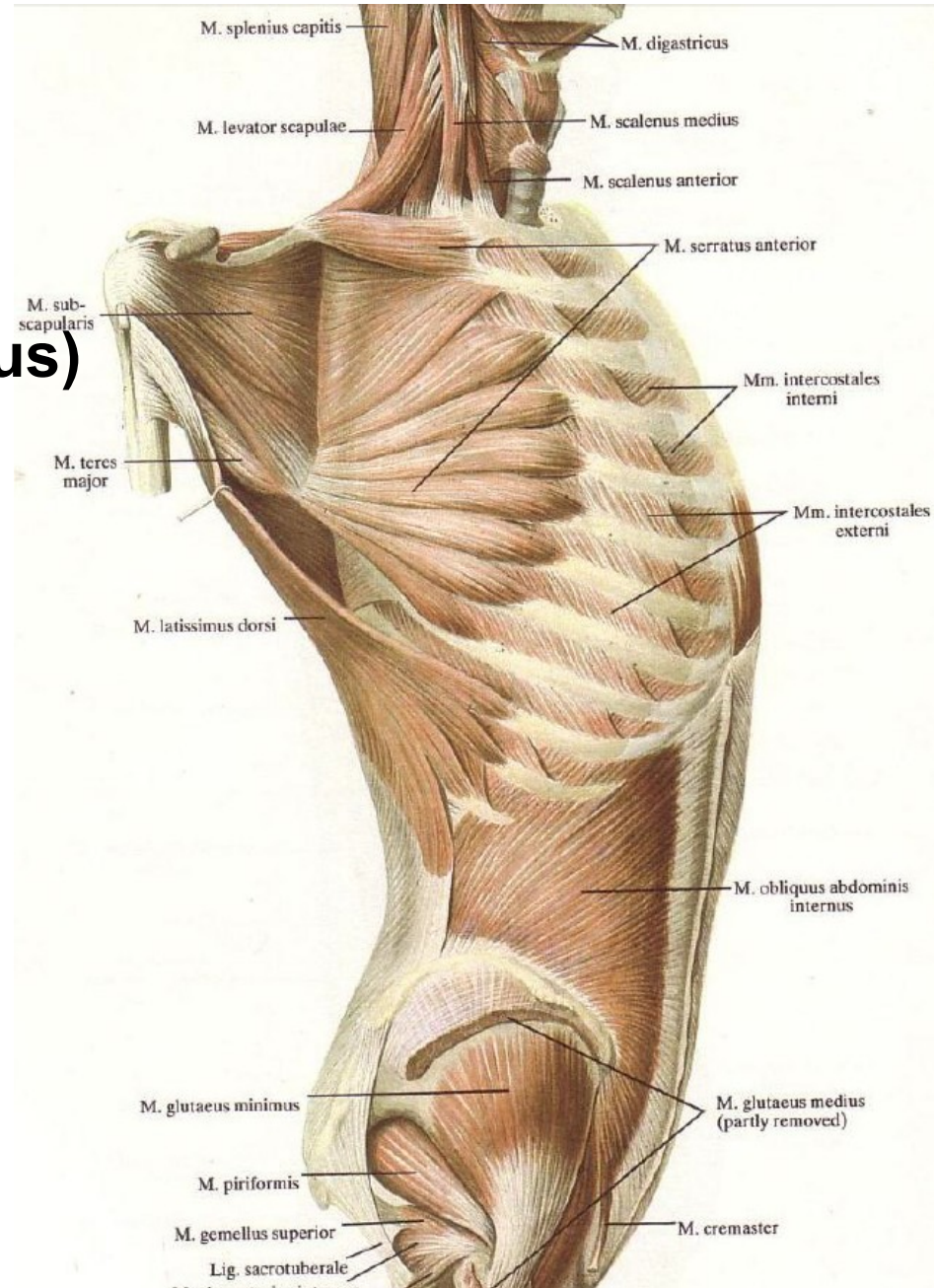
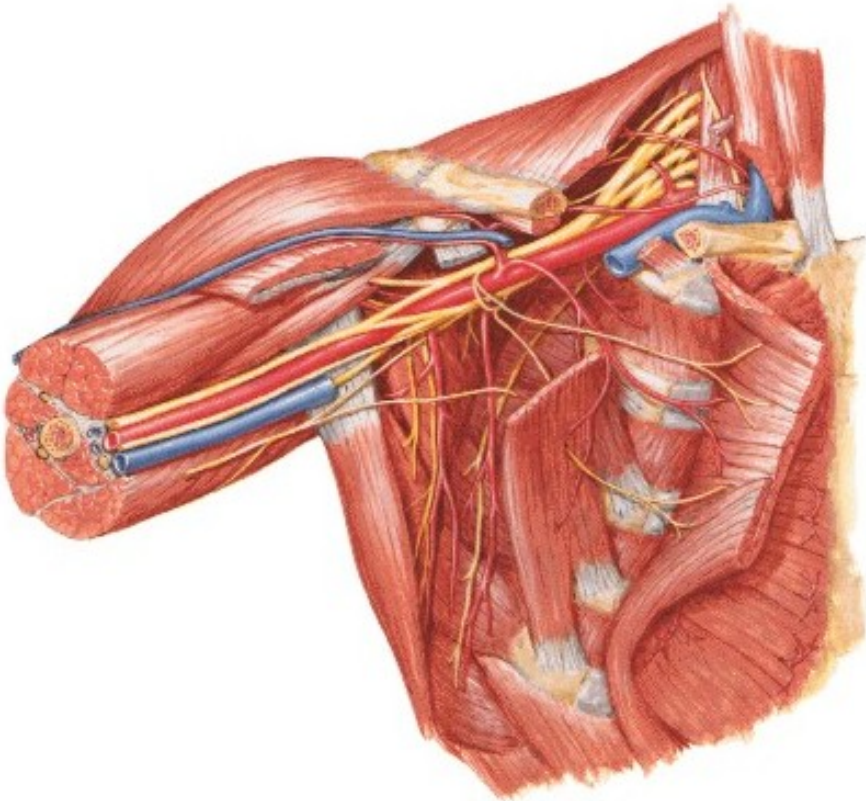


Fascia clavipectoralis



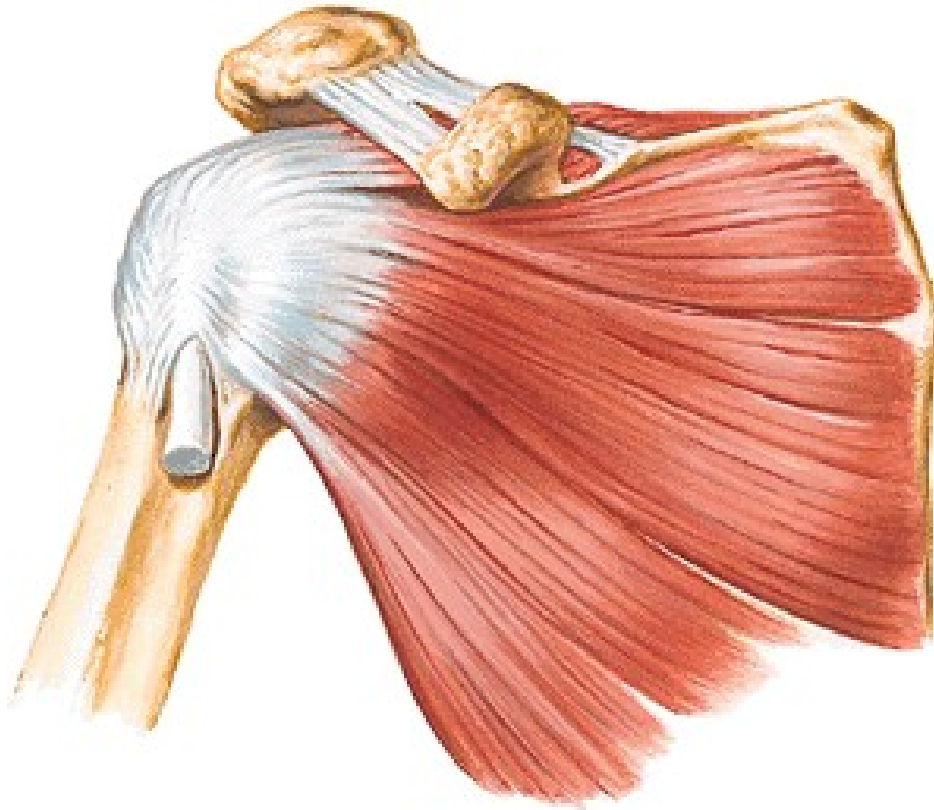
Medial wall: thorax

**m. serratus ant.
(a. thoracica lat.,
n. thoracicus longus)**

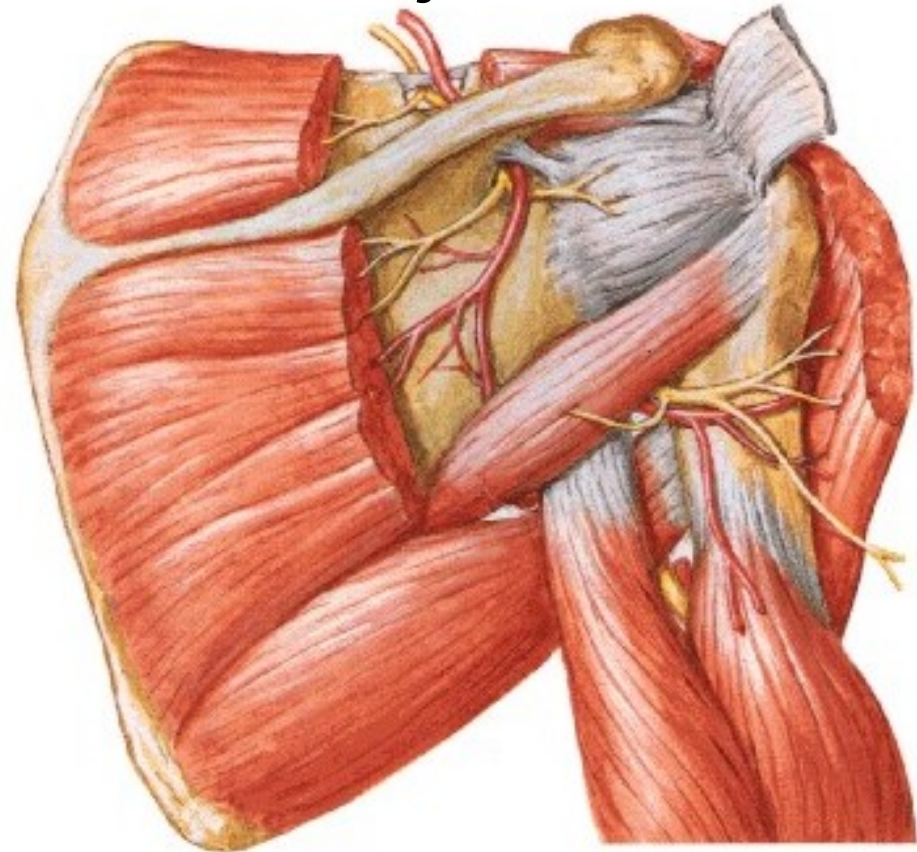


Lateral wall: humerus, m. biceps brachii

Posterior wall: m. subscapularis



**m. teres minor
m. teres major**



Posterior wall: m. latissimus dorsi

– foramen omotricipitale (trilaterum):

m. teres minor

m. teres major

caput longum m. tricipitis

A. circumflexa scapulae

**- foramen humerotricipitale
(quadrilaterum):**

m. teres minor

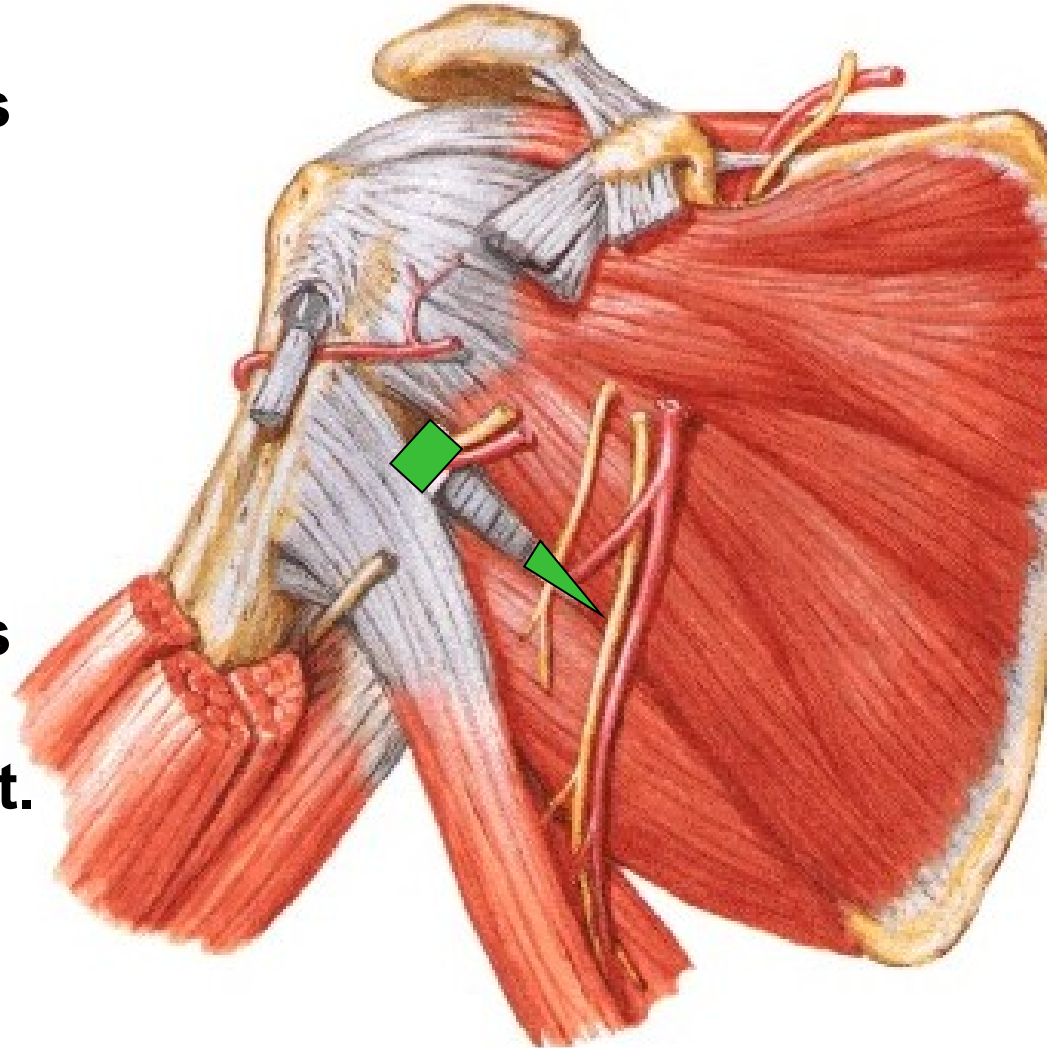
m. teres major

caput longum m. tricipitis

humerus

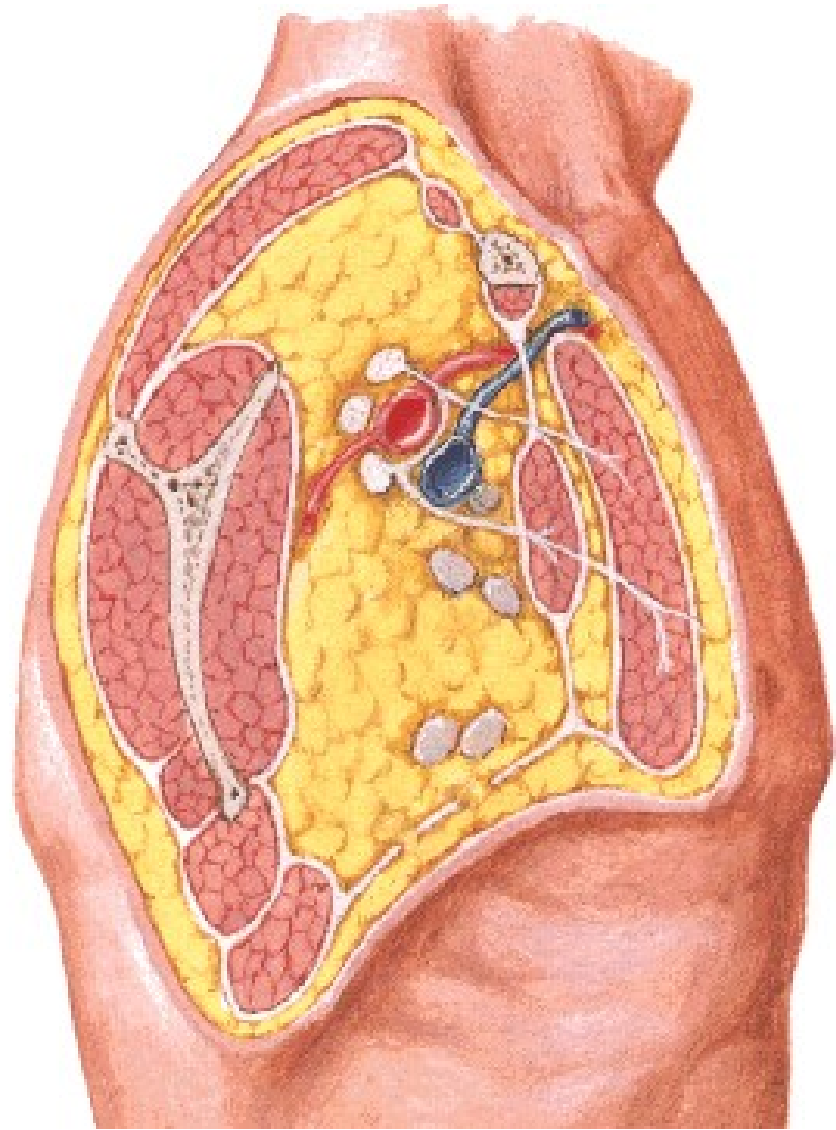
A. circumflexa humeri post.

N. axillaris



Floor: Fascia axillaris

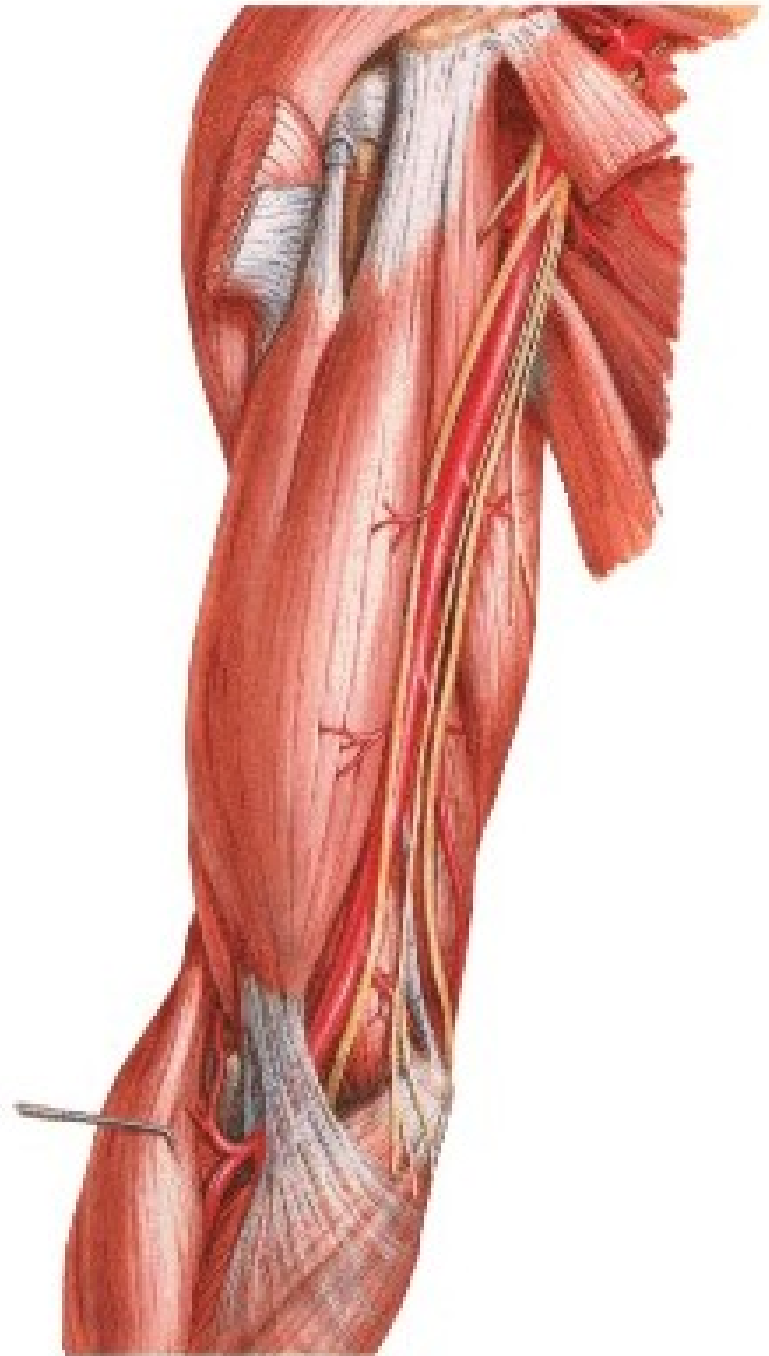
Plica axillaris ant.
(m. pectoralis major)
Plica axillaris post.
(m. latissimus dorsi)



Contents:

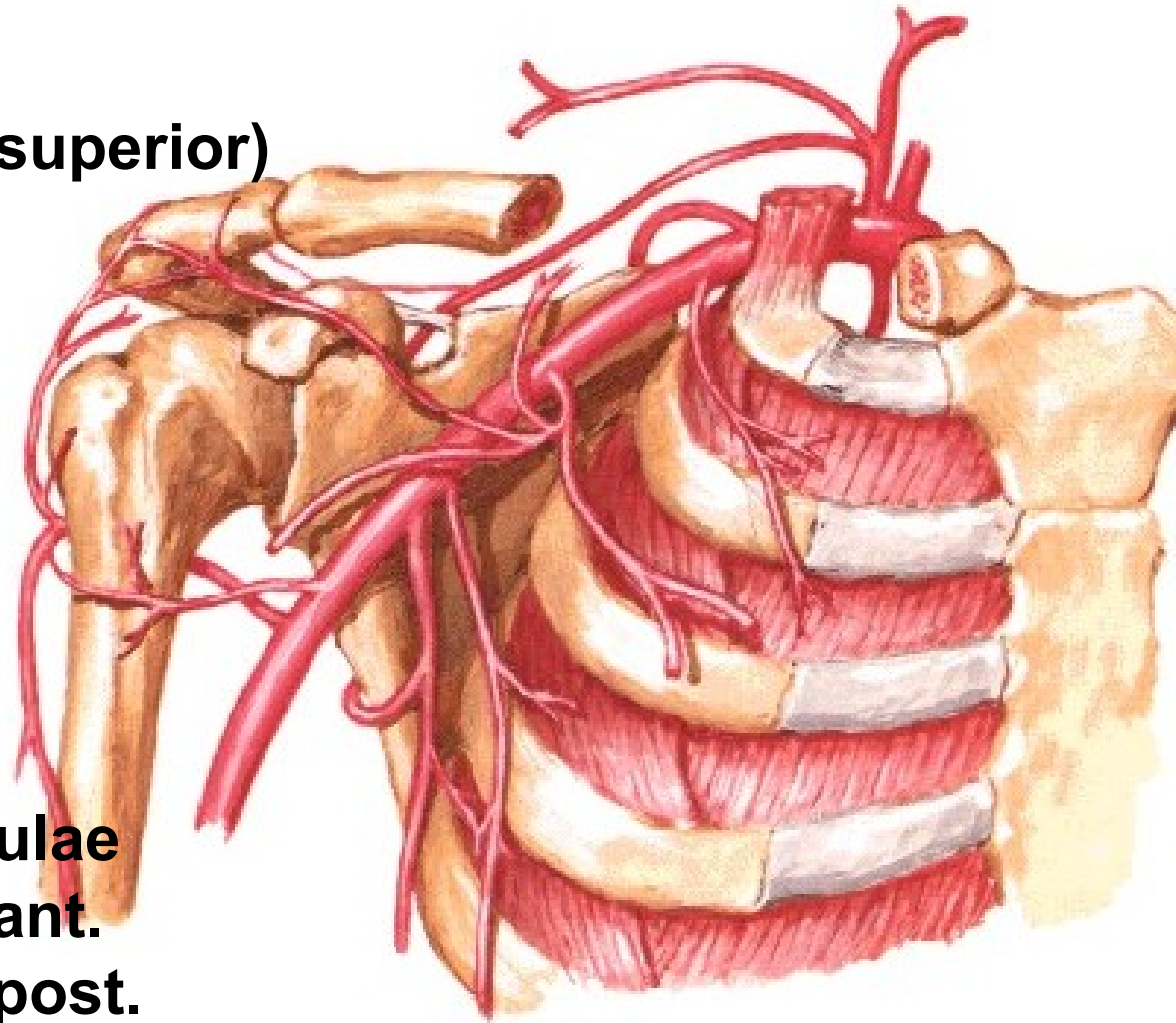
M. biceps brachii

M. coracobrachialis



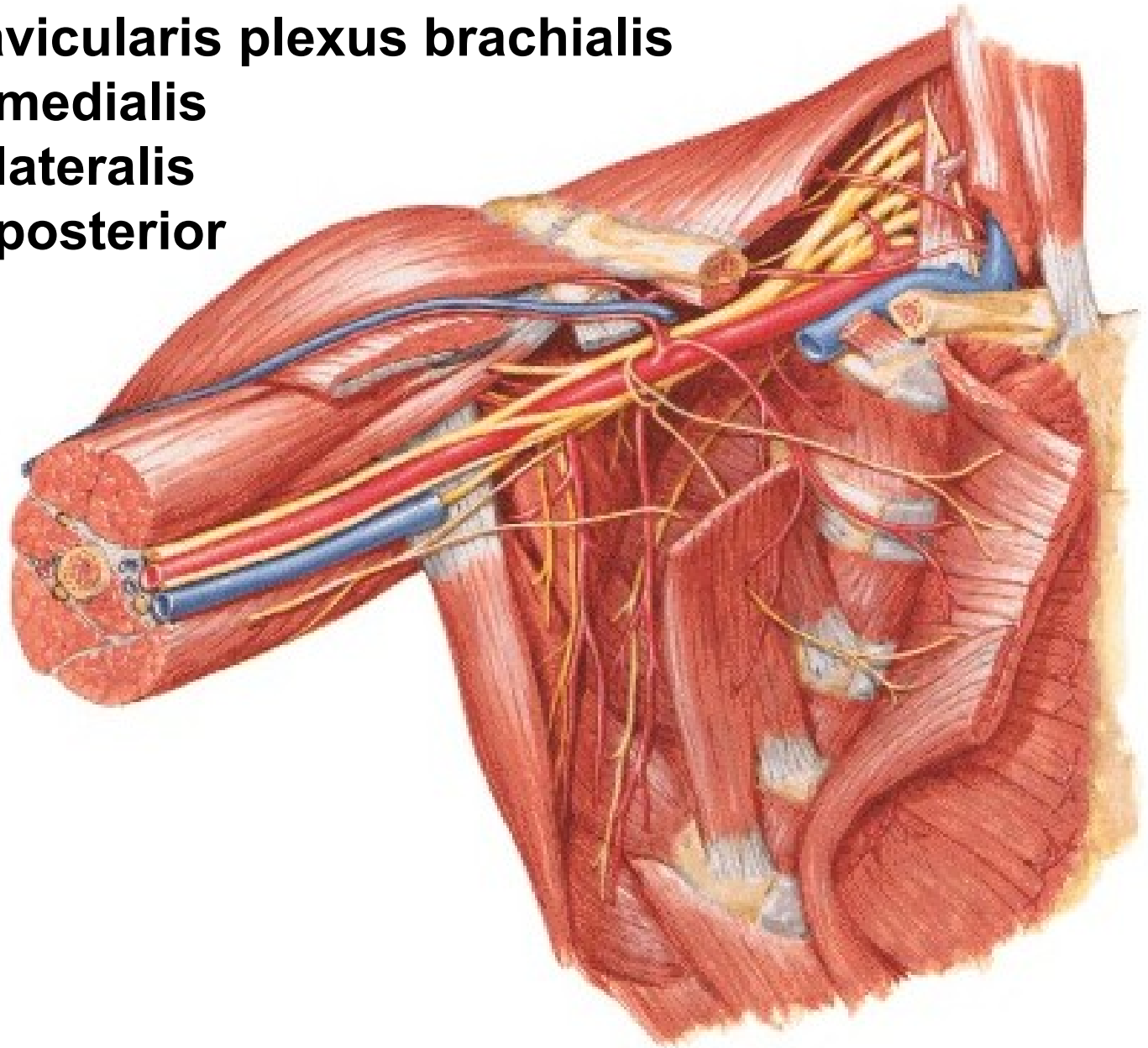
A. axillaris

- rr. subscapulares
- a. thoracica suprema (superior)
- a. thoracoacromialis
 - r. deltoideus
 - r. acromialis
 - rr. pectorales
- a. thoracica lateralis
 - rr. mammarii lat.
- a. subscapularis
 - a. thoracodorsalis
 - a. circumflexa scapulae
- a. circumflexa humeri ant.
- a. circumflexa humeri post.



Pars infraclavicularis plexus brachialis

- fasciculus medialis**
- fasciculus lateralis**
- fasciculus posterior**

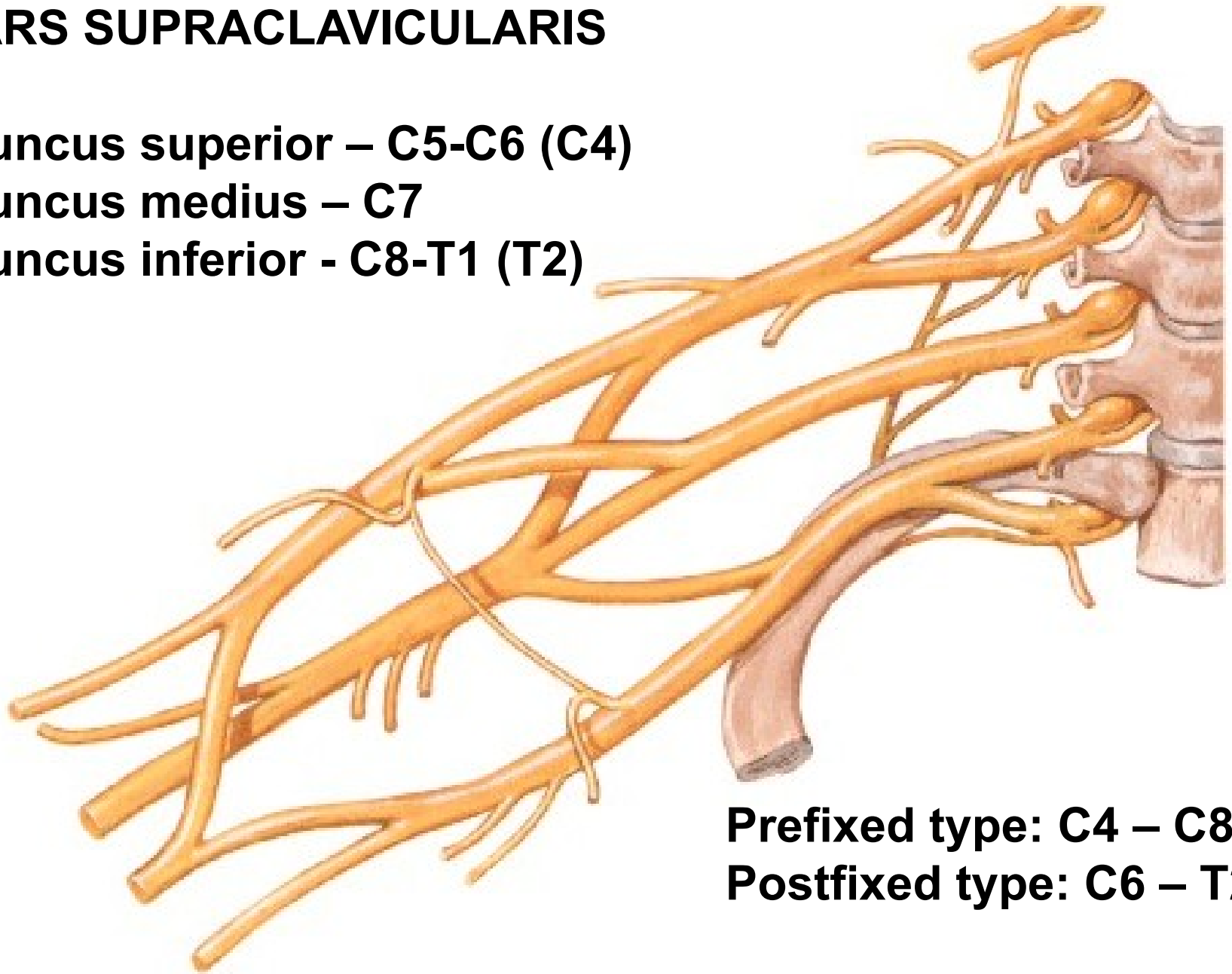


PARS SUPRACLAVICULARIS

Truncus superior – C5-C6 (C4)

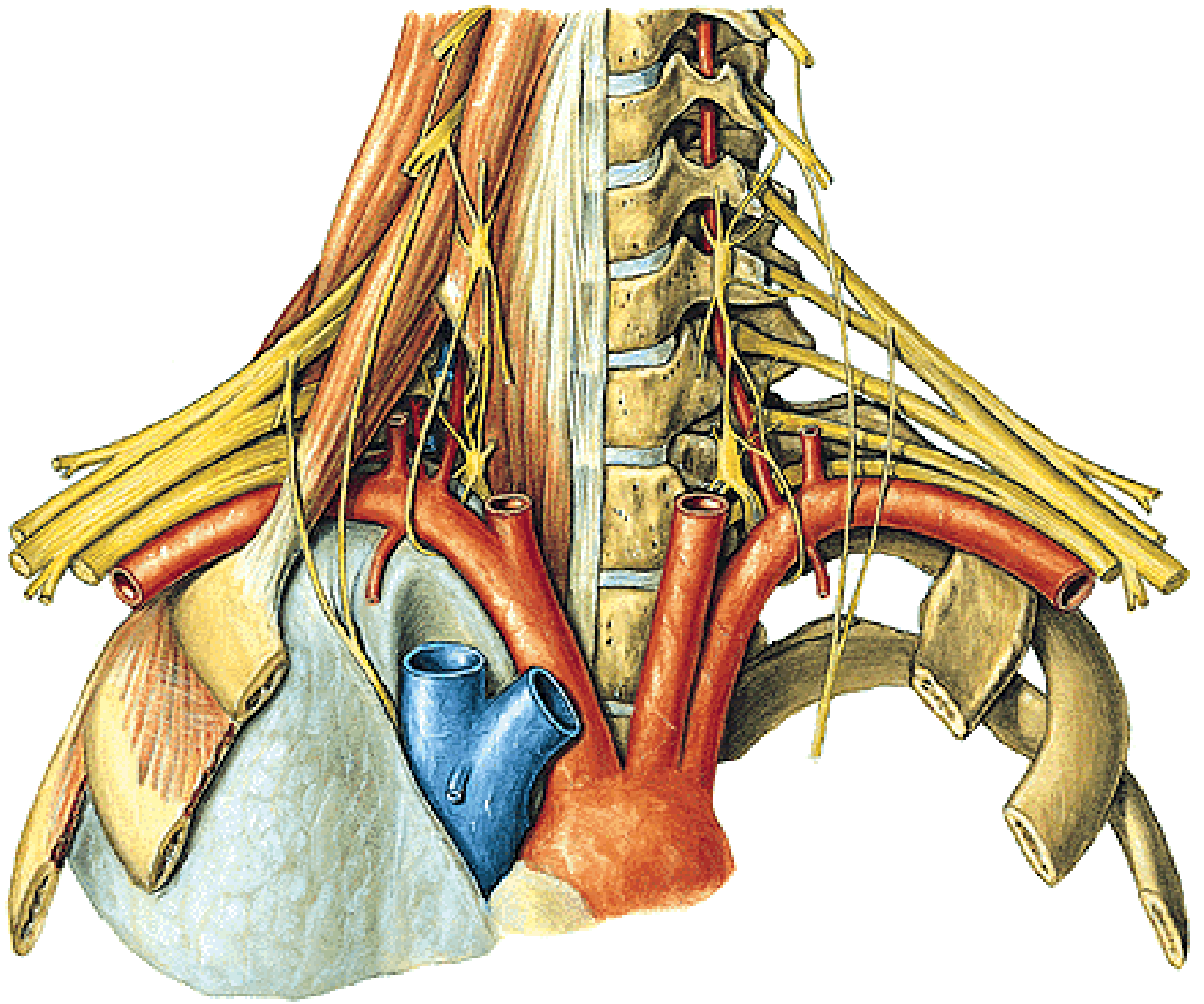
Truncus medius – C7

Truncus inferior - C8-T1 (T2)



Prefixed type: C4 – C8

Postfixed type: C6 – T2



PARS SUPRACLAVICULARIS

N. dorsalis scapulae (C4, C5)

- mm. rhomboidei
- m. levator scapulae

N. thoracicus longus (C5, C6, C7)

- m. serratus ant.

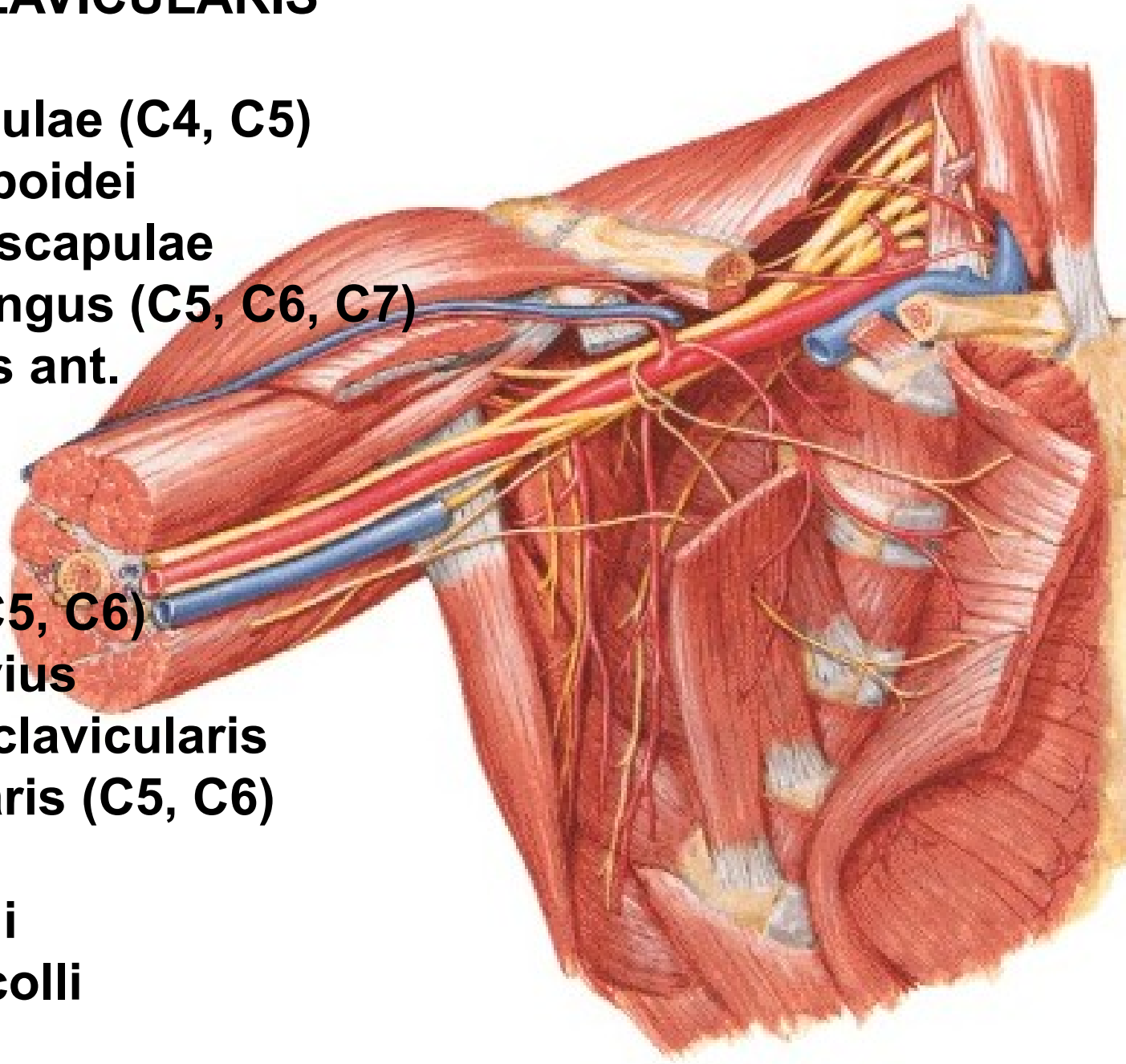
N. subclavius (C5, C6)

- m. subclavius
- art. sternoclavicularis

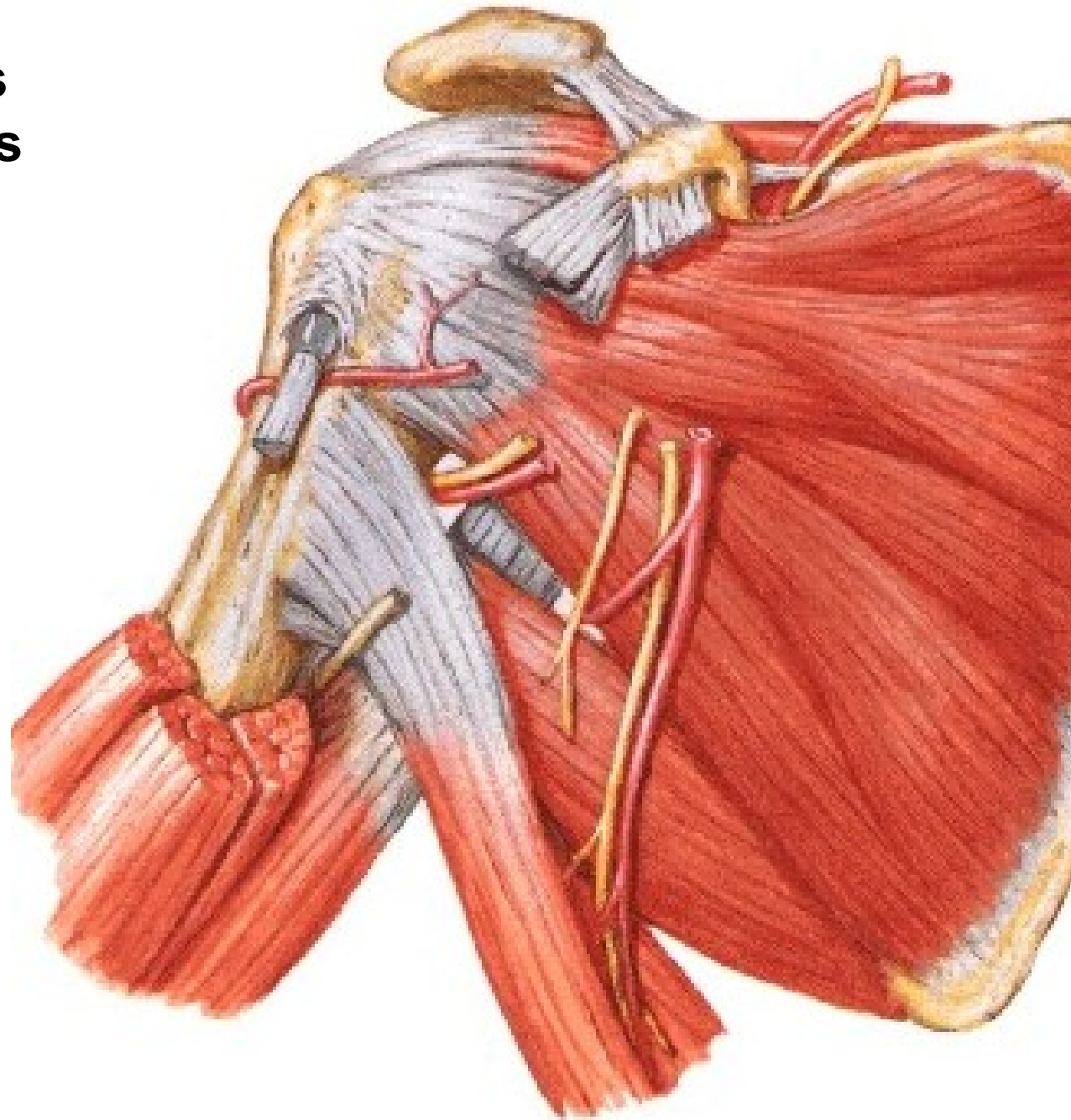
N. suprascapularis (C5, C6)

Rr. musculares

- mm. scaleni
- m. longus colli



N suprascapularis
A. suprascapularis



N. pectoralis lateralis (C5, C6, C7)

- mm. pectorales

N. pectoralis medialis (C8, T1)

- mm. pectorales

N. subscapularis sup. (C5)

- m. subscapularis

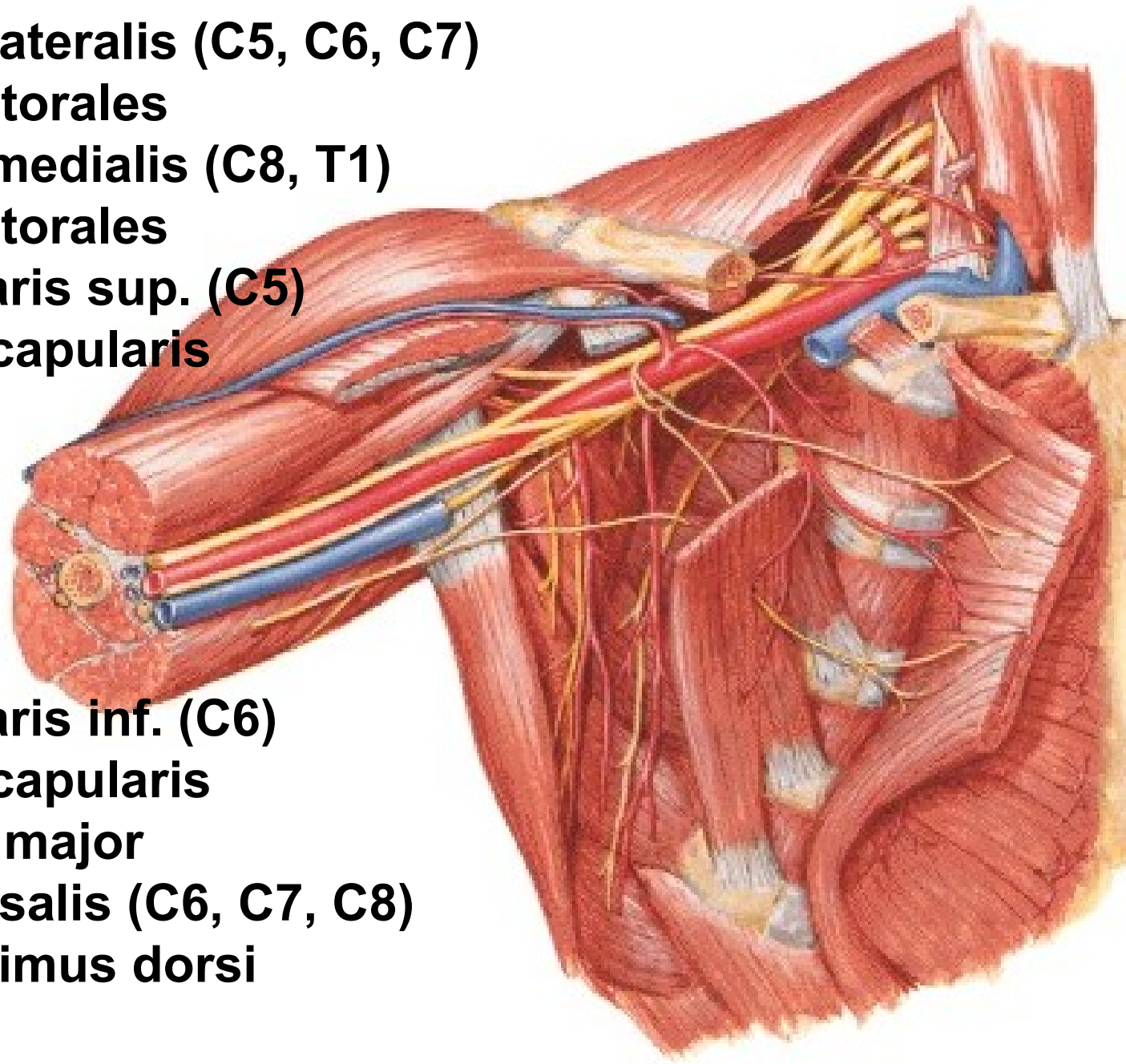
N. subscapularis inf. (C6)

- m. subscapularis

- m. teres major

N. thoracodorsalis (C6, C7, C8)

- m. latissimus dorsi



PARS INFRACLAVICULARIS
(terminal branches)

Fasciculus lateralis

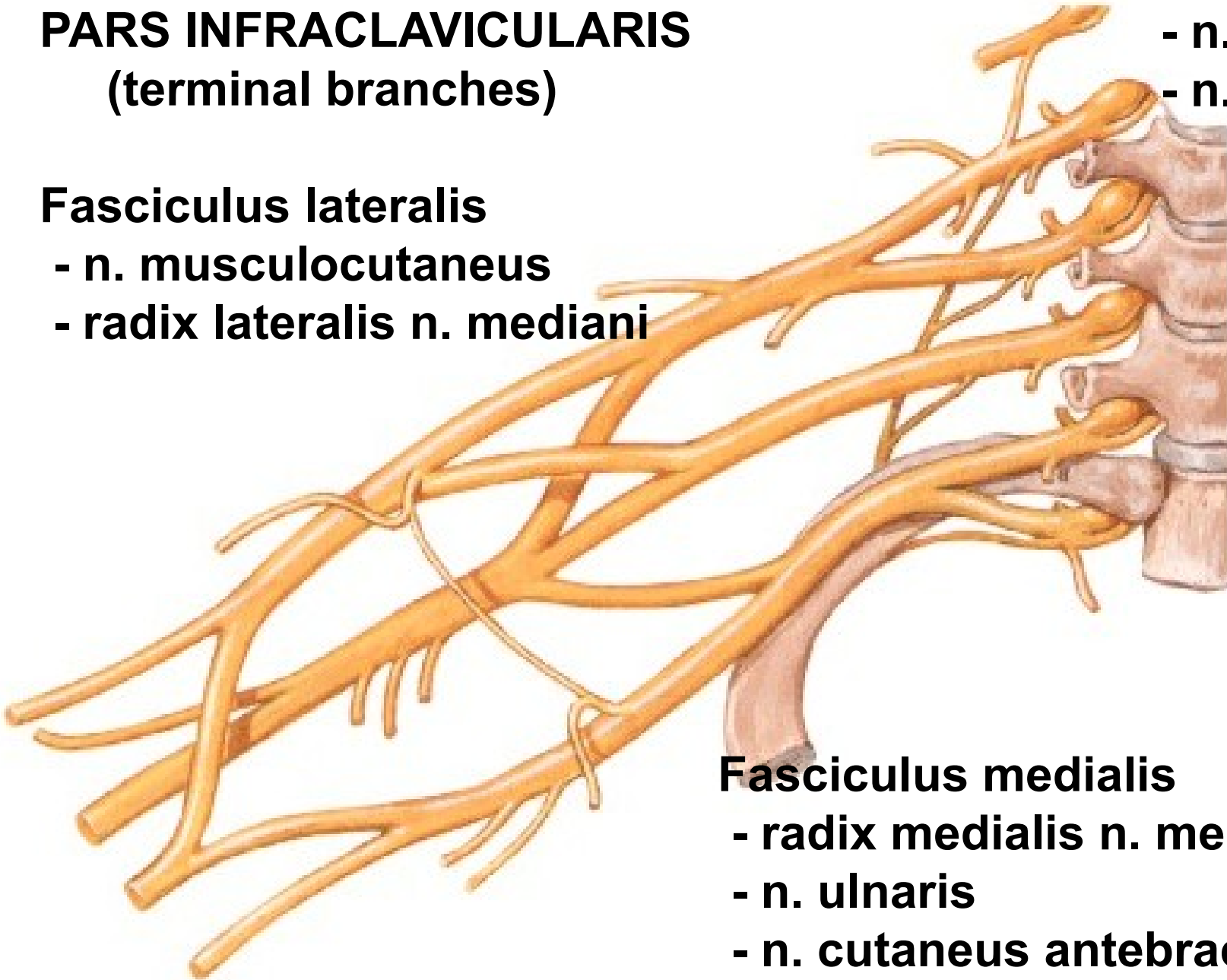
- n. musculocutaneus
- radix lateralis n. mediani

Fasciculus posterior

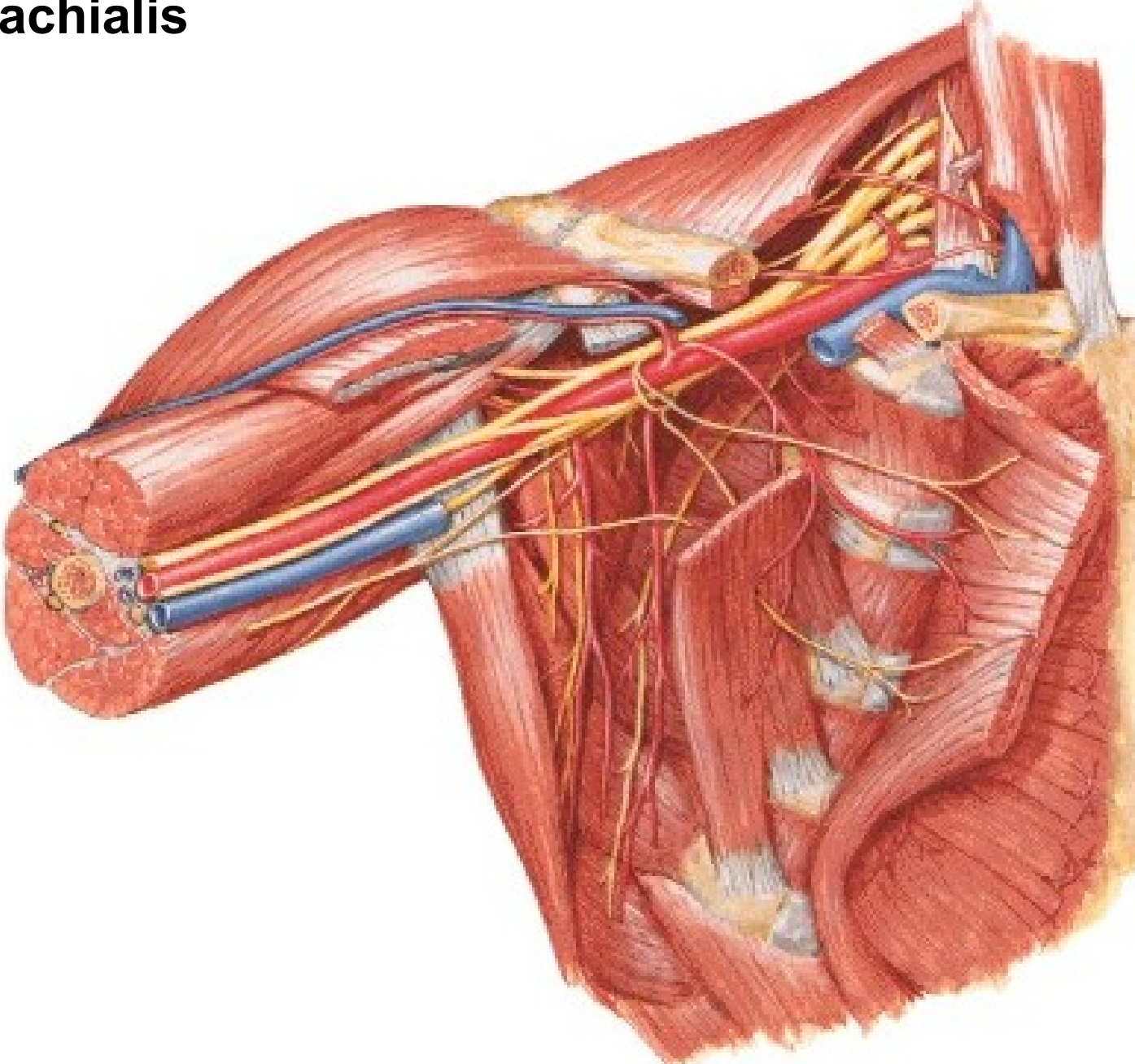
- n. axillaris
- n. radialis

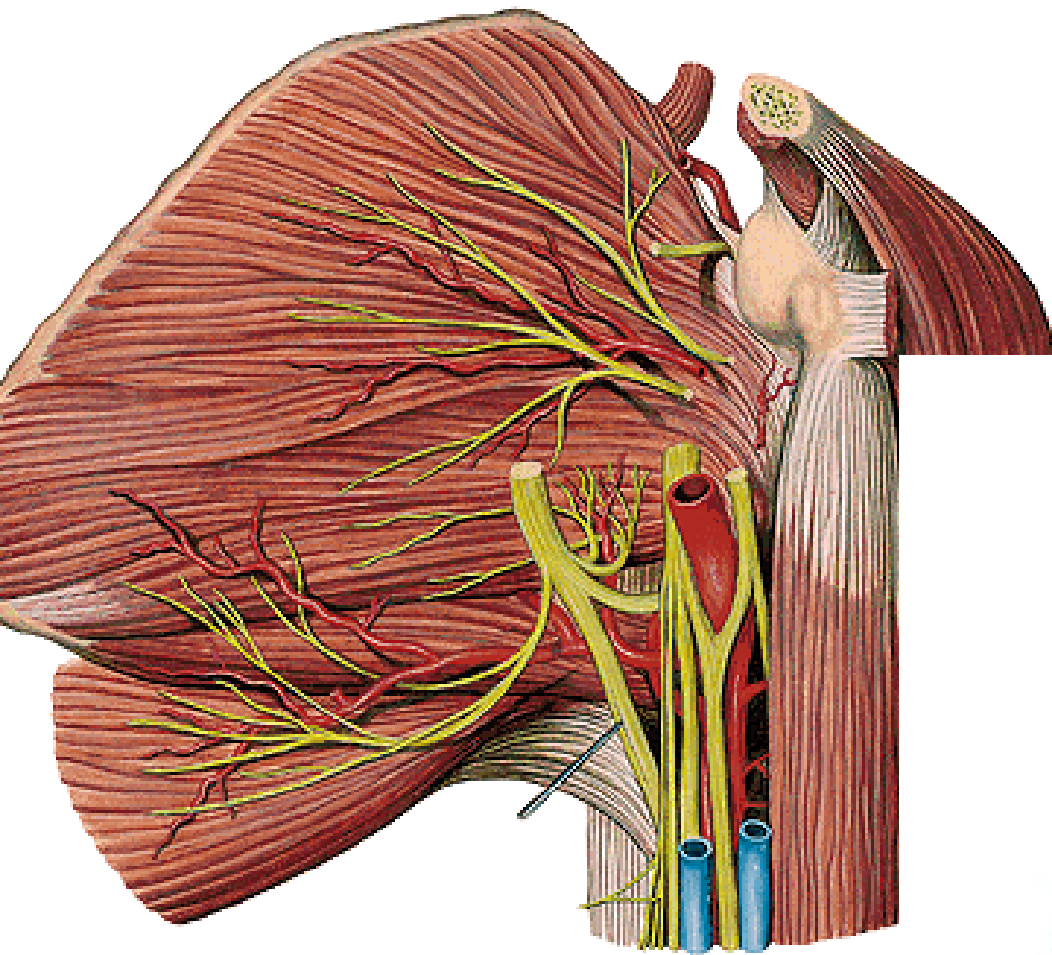
Fasciculus medialis

- radix medialis n. mediani
- n. ulnaris
- n. cutaneus antebrachii med.
- n. cutaneus brachii medialis

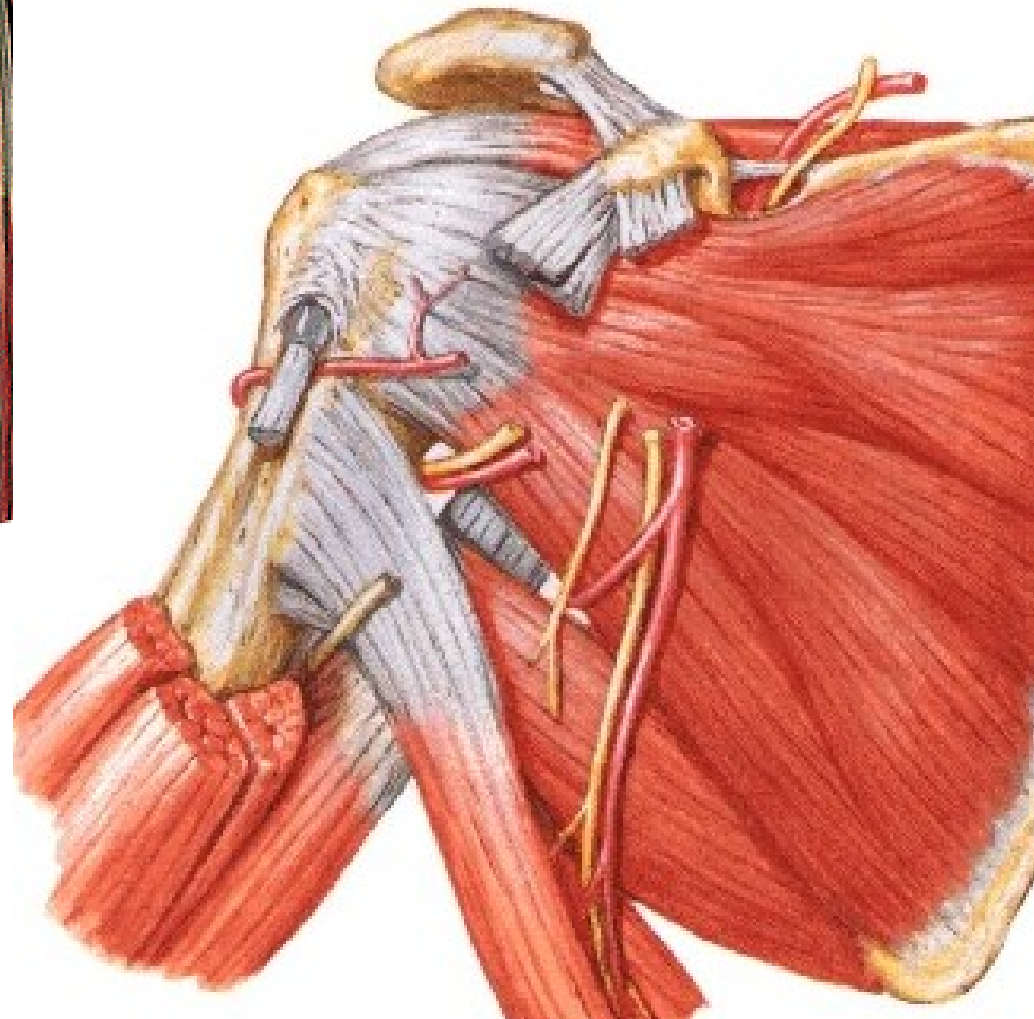


N. intercostobrachialis





N. axillaris

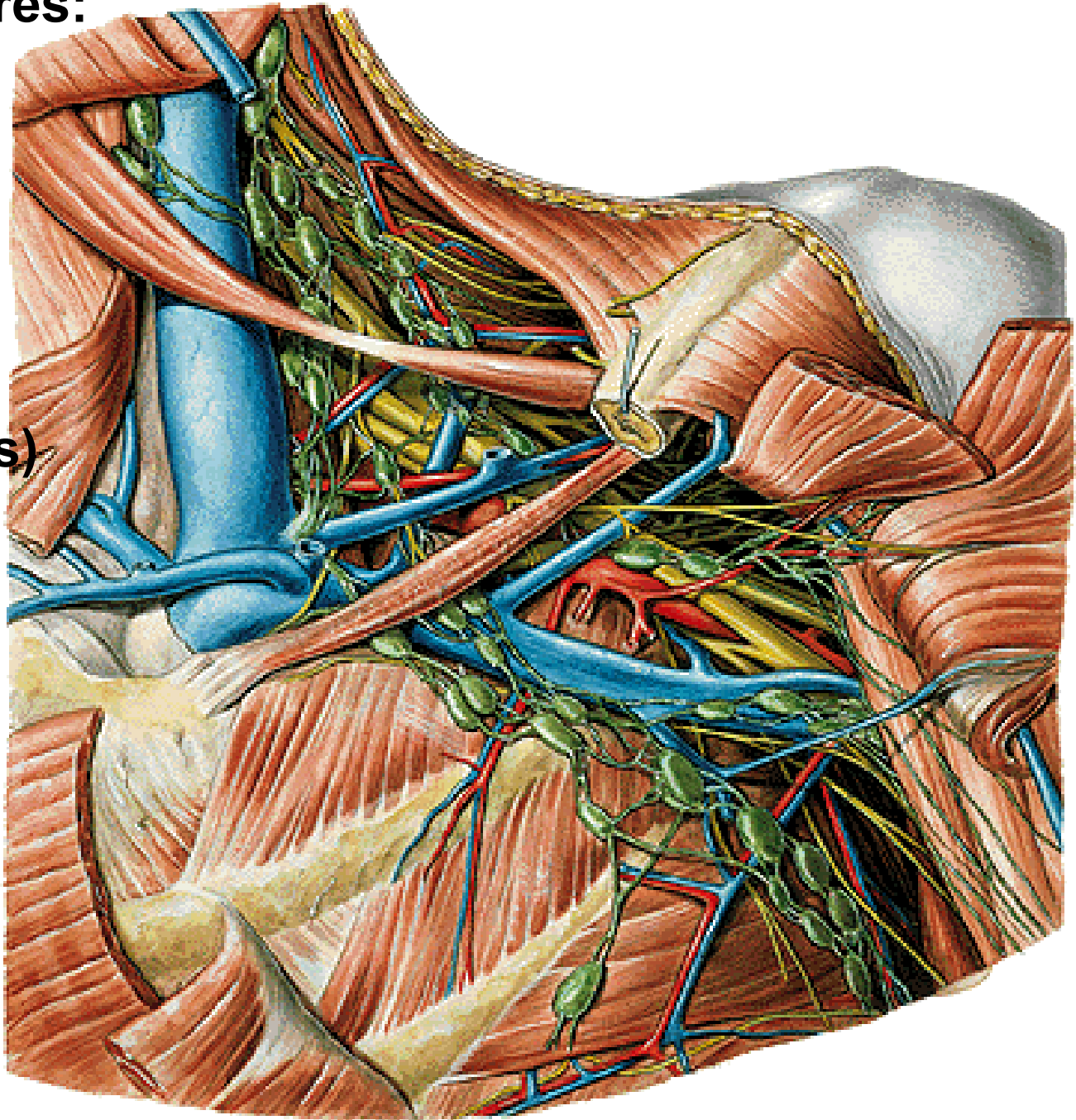


N. radialis

Nodi lymph. axillares:

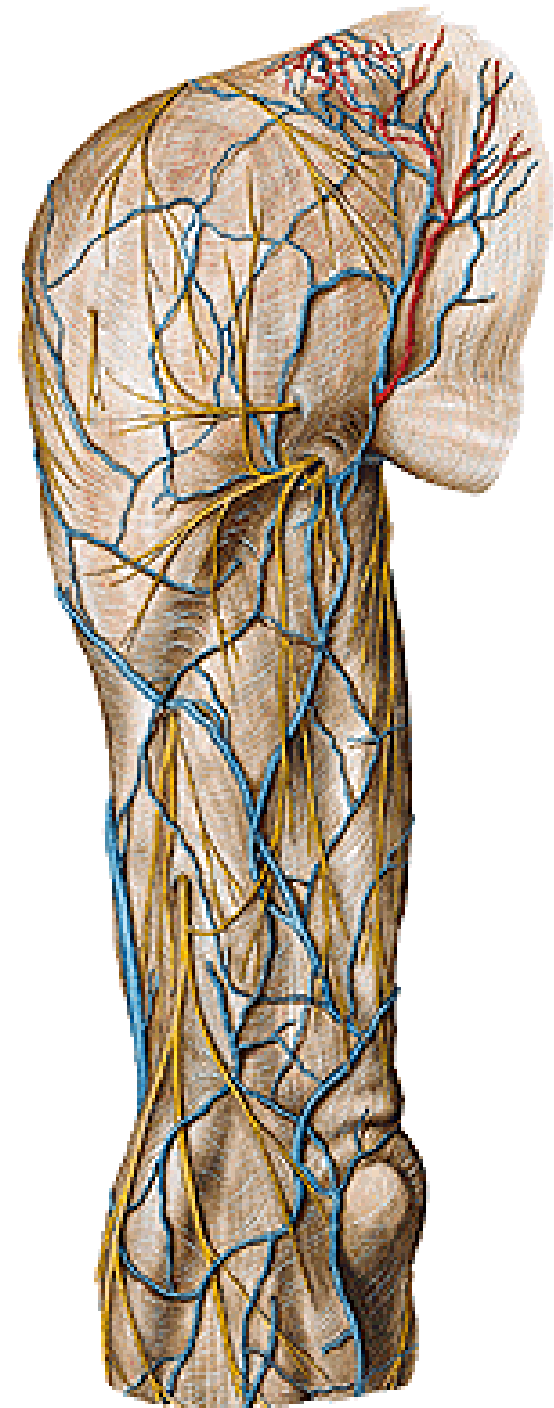
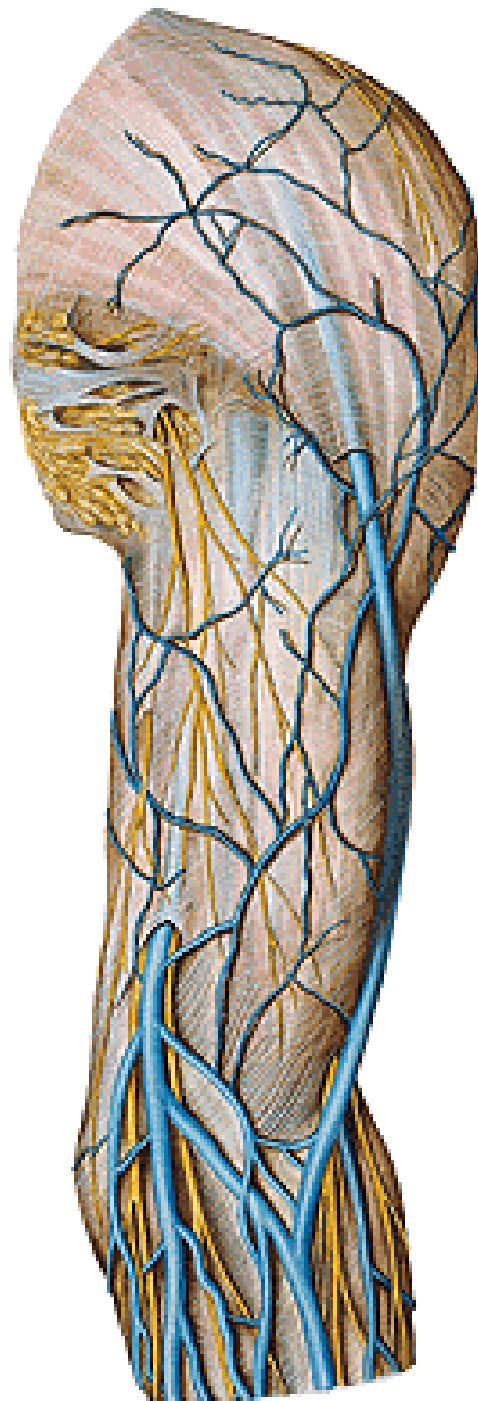
- laterales**
- pectorales (Sorgius)**
- subscapulares**
- centrales**
- apicales (infraclaviculares)**

→ tr. subclavius

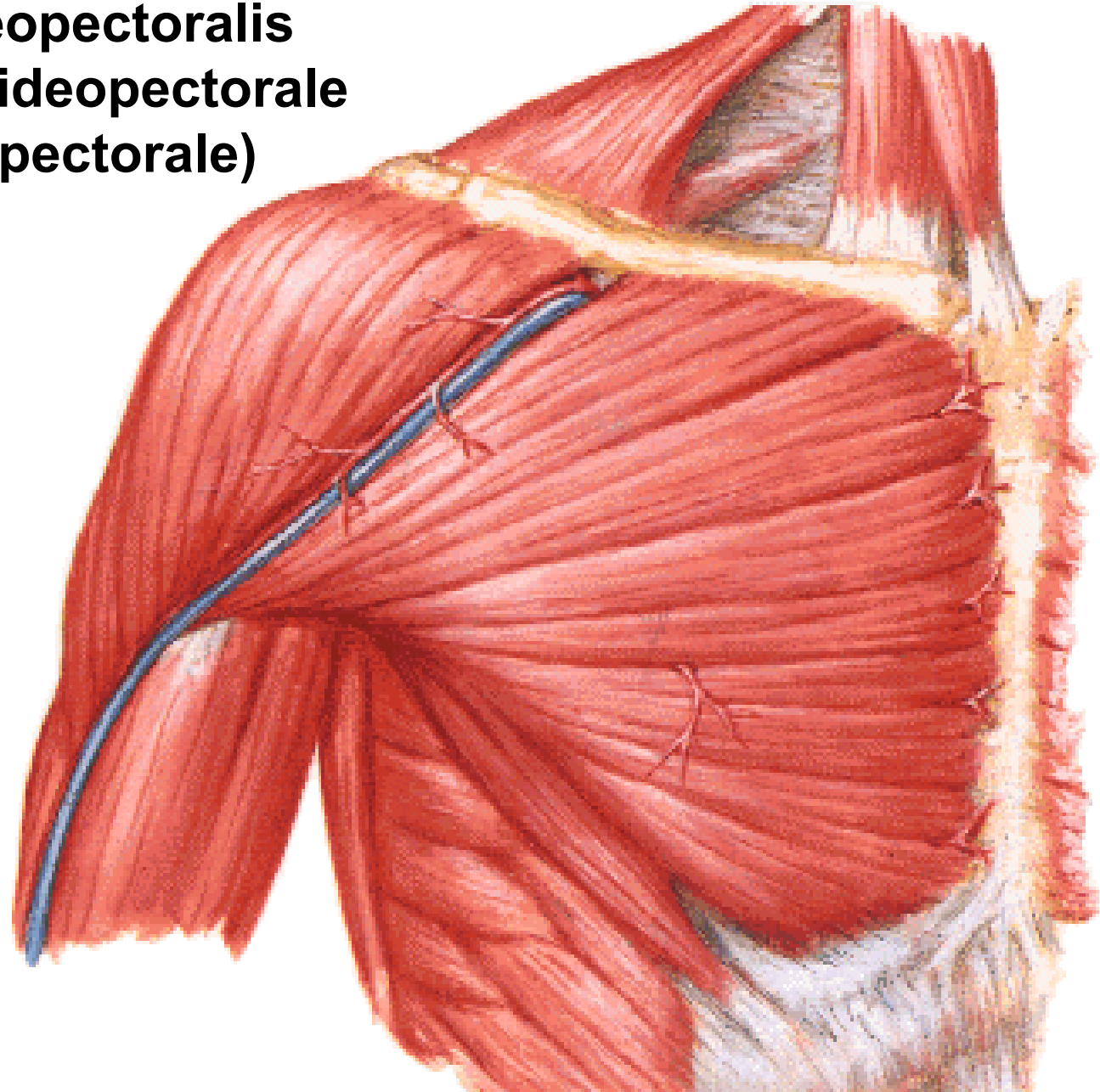


Regio deltoidea

N. cut. brachii lat. sup.
Nn. supraclaviculares
V. cephalica

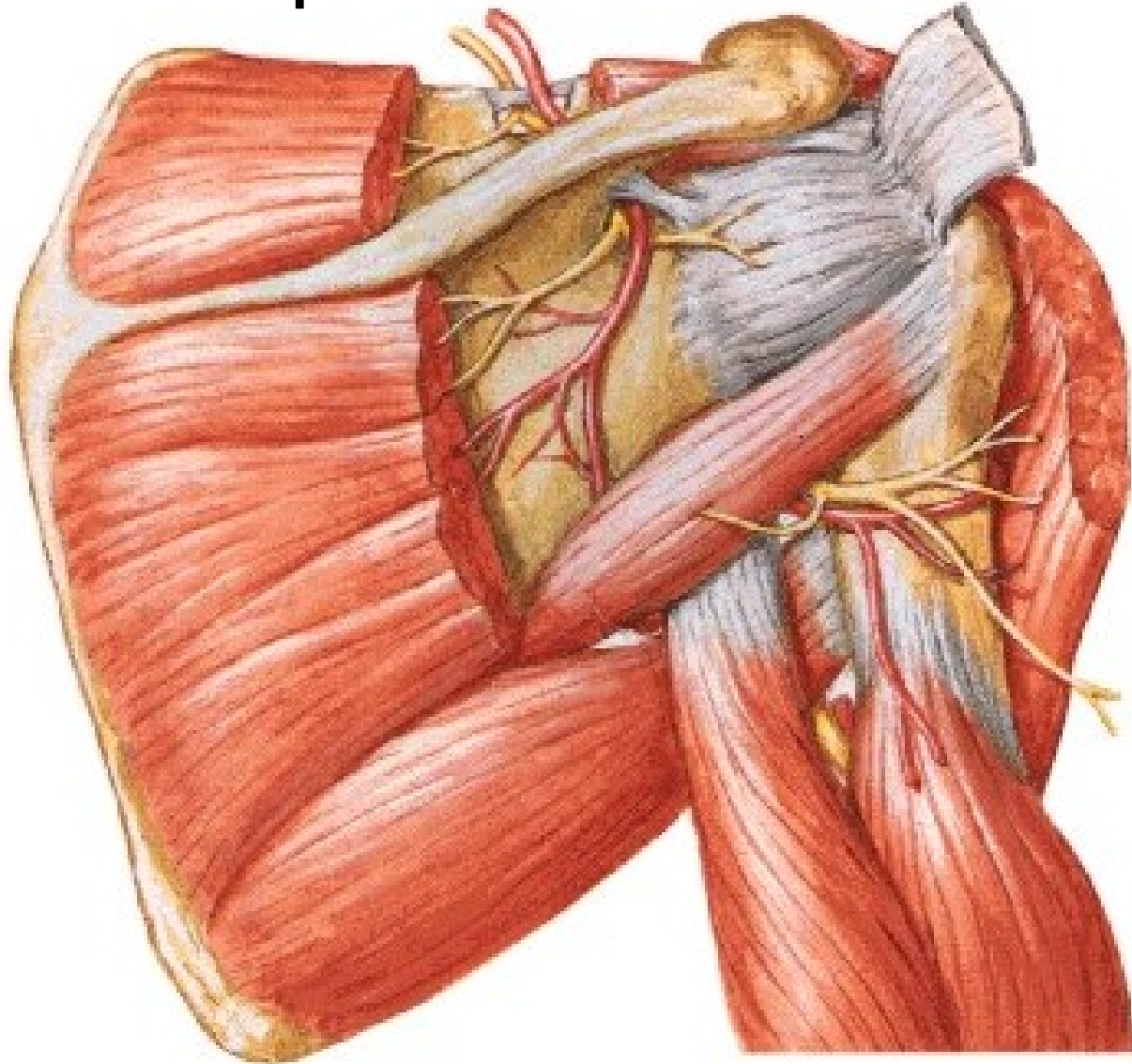


Sulcus deltoideopectoralis
Trigonum deltoideopectorale
(clavipectorale)

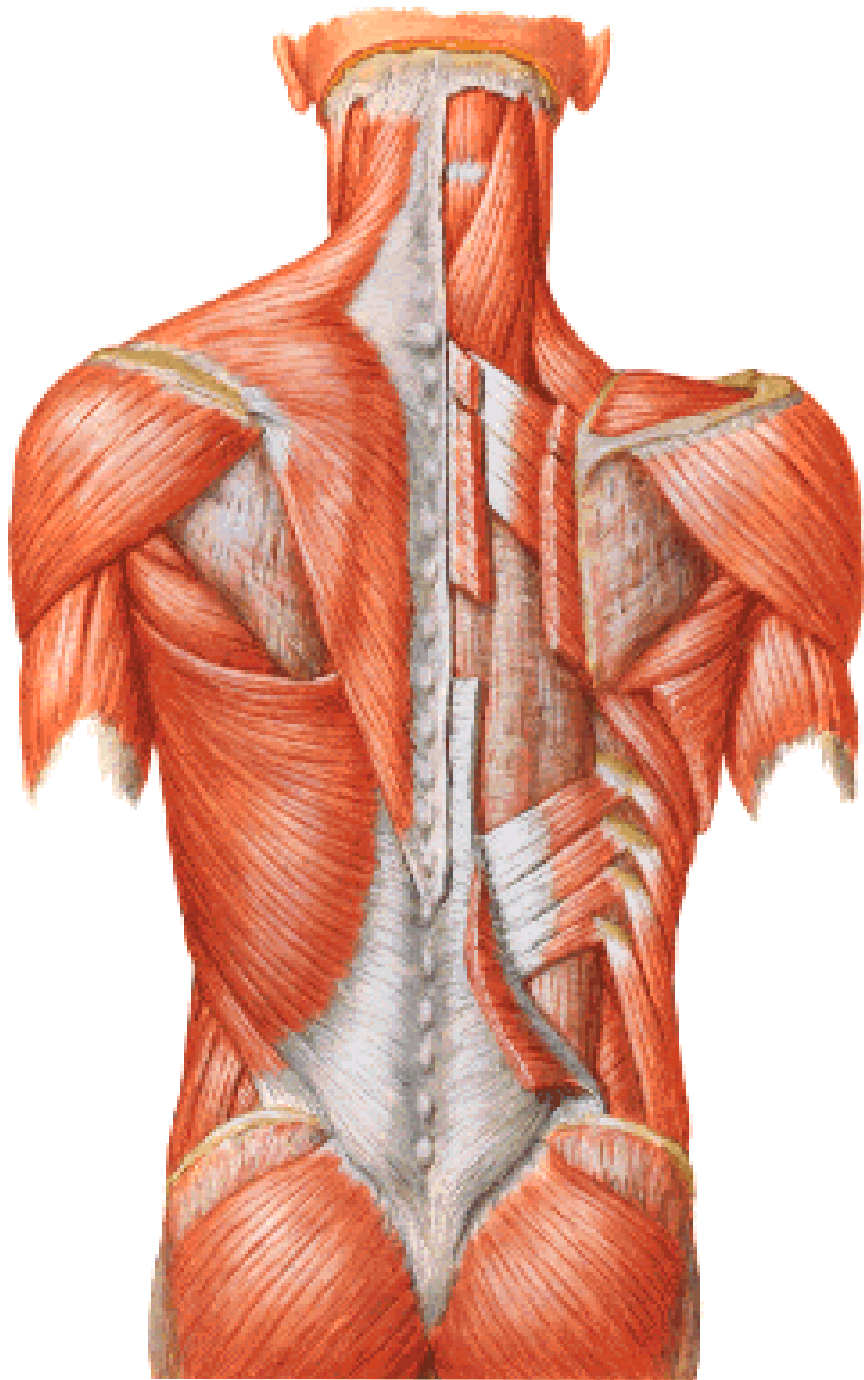


M. deltoideus (n. axillaris)

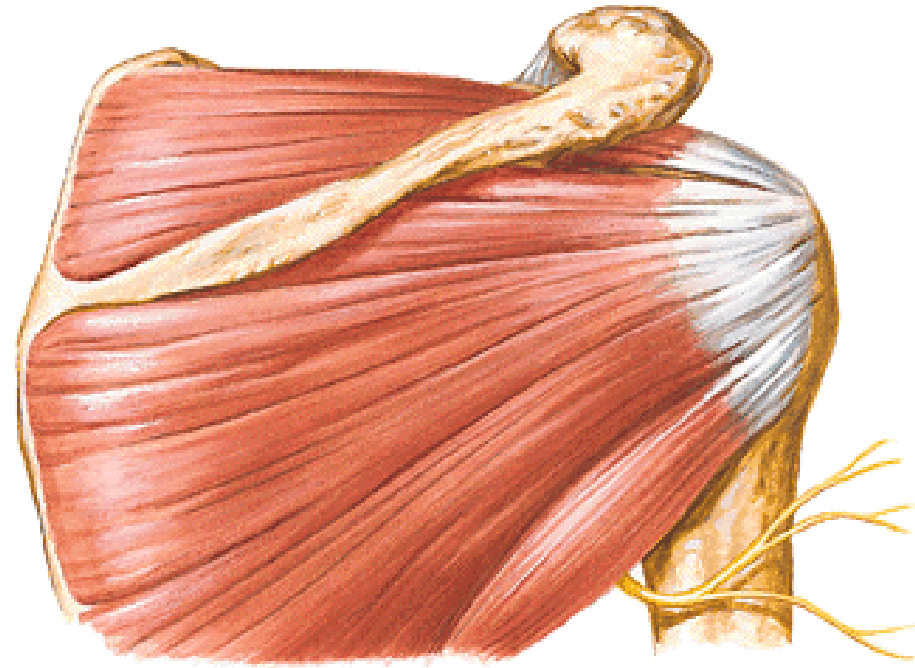
A. circumflexa humeri post. et ant.



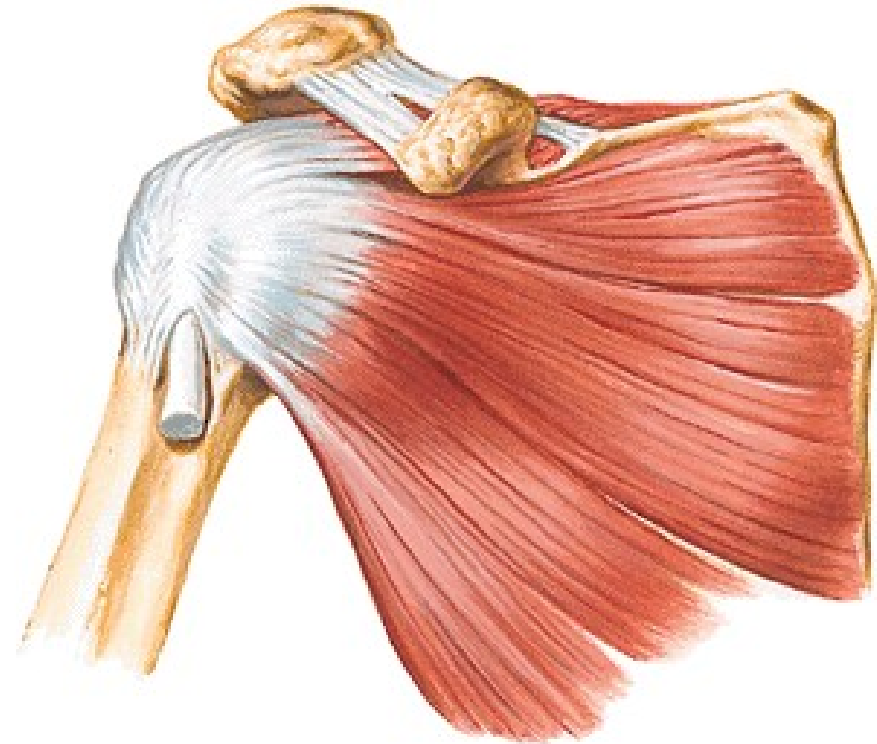
Regio scapularis



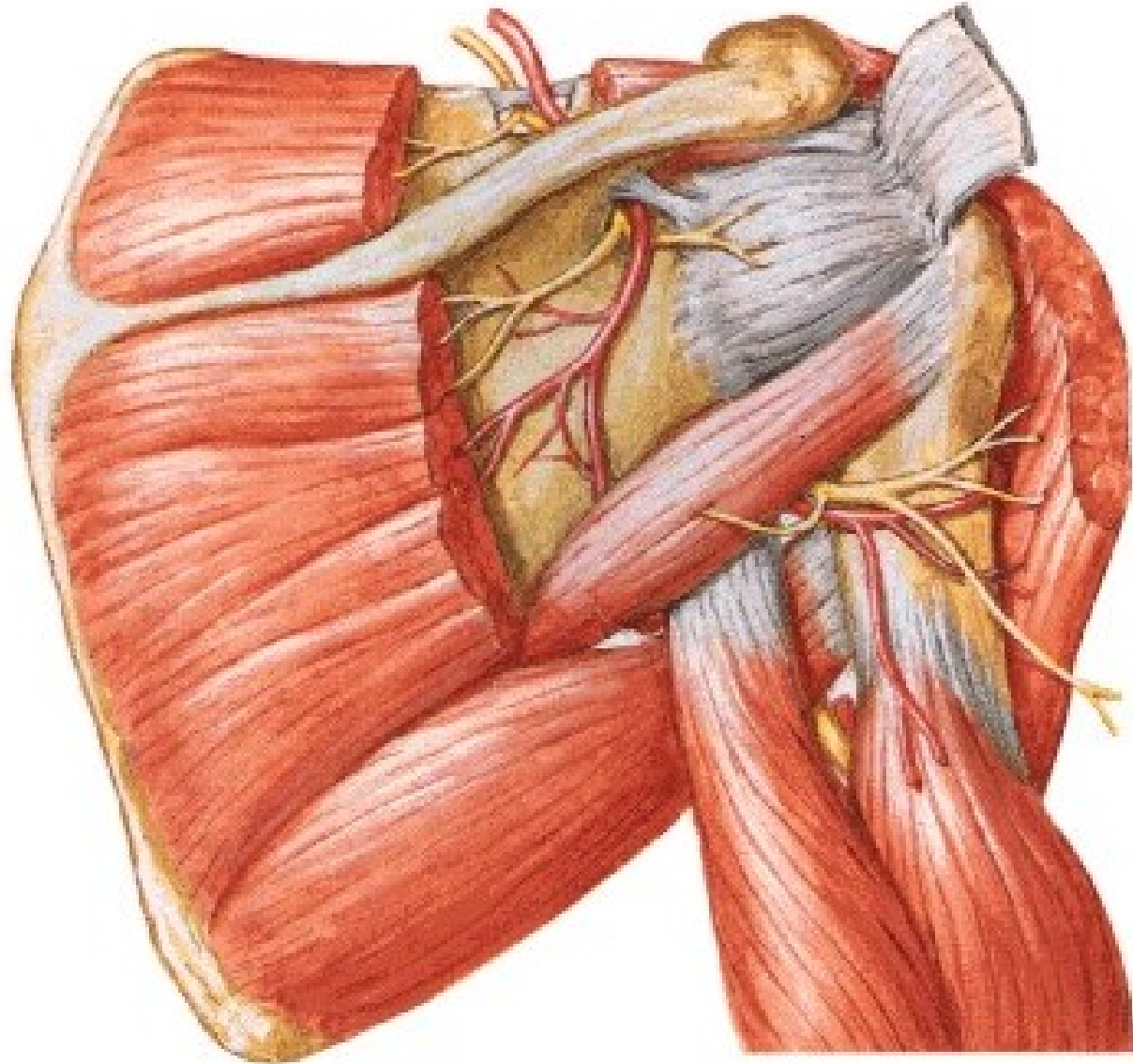
M. supraspinatus
M. infraspinatus
M. teres minor
M. teres major



M. subscapularis

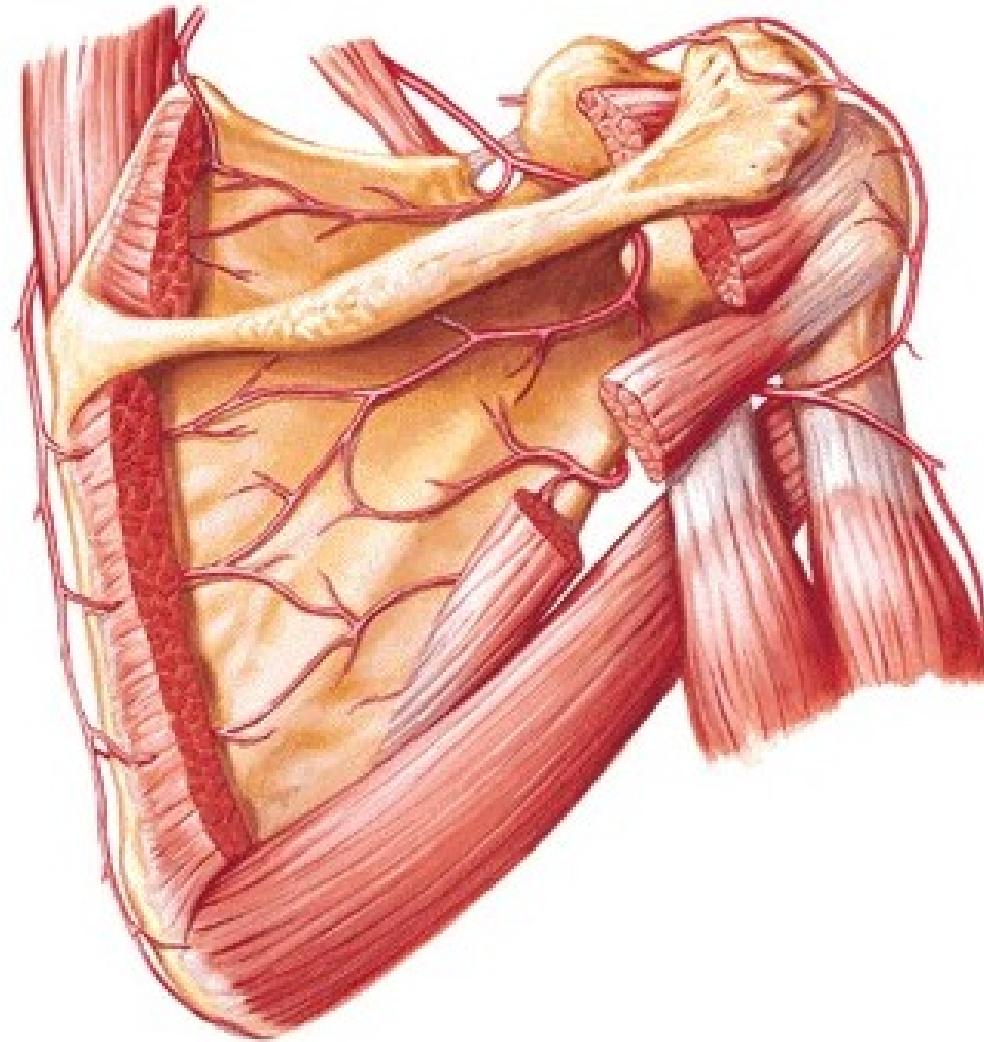
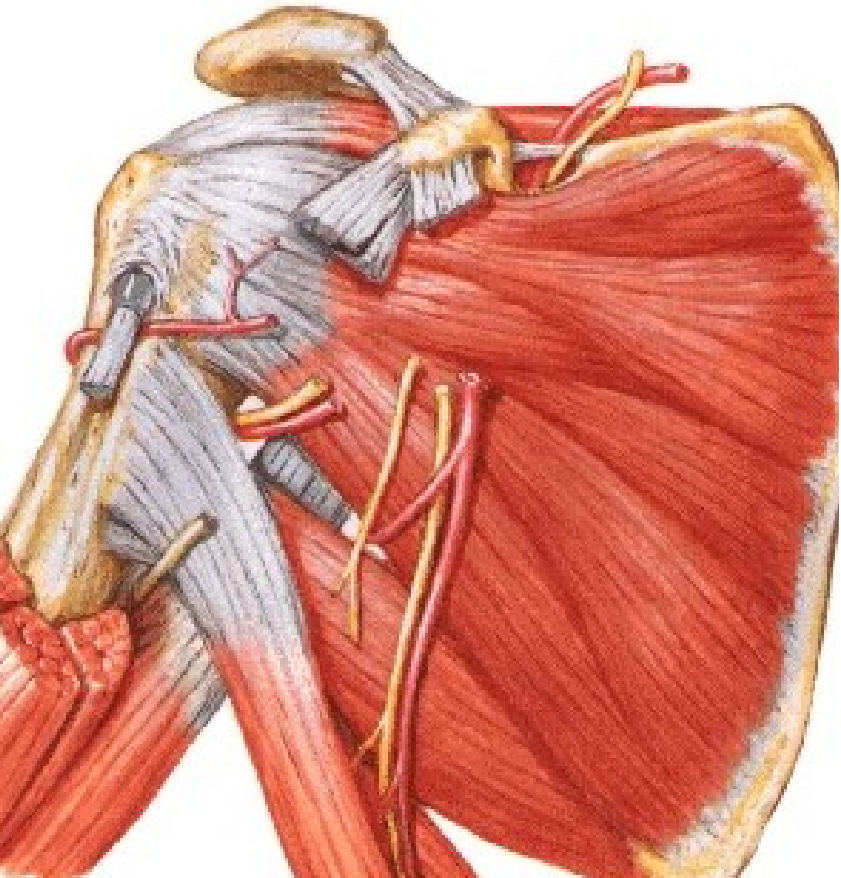

N. suprascapularis
N. axillaris

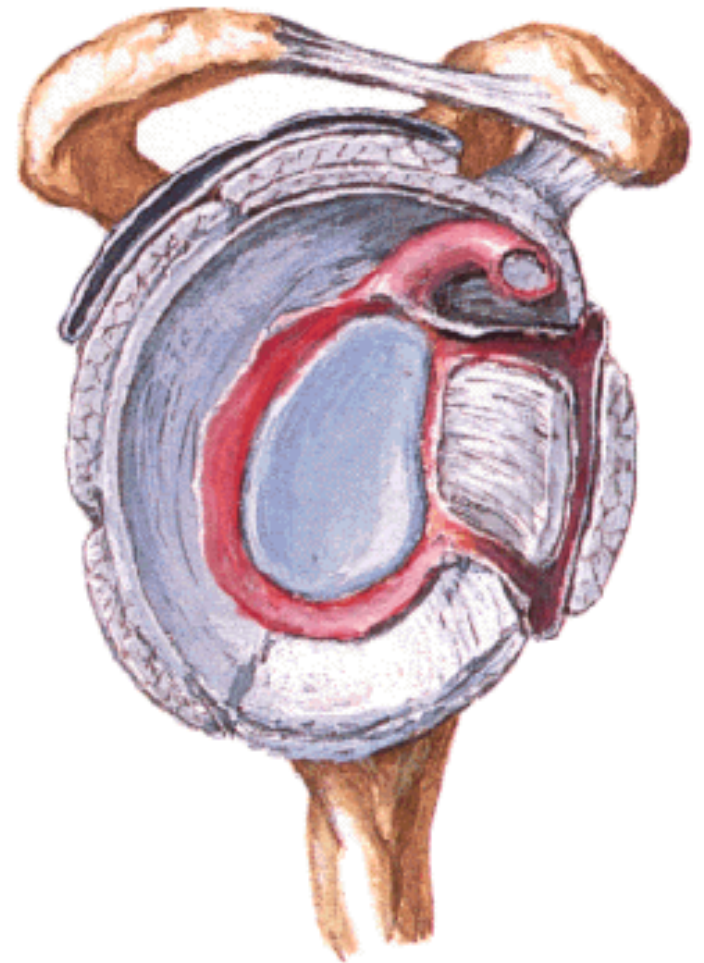
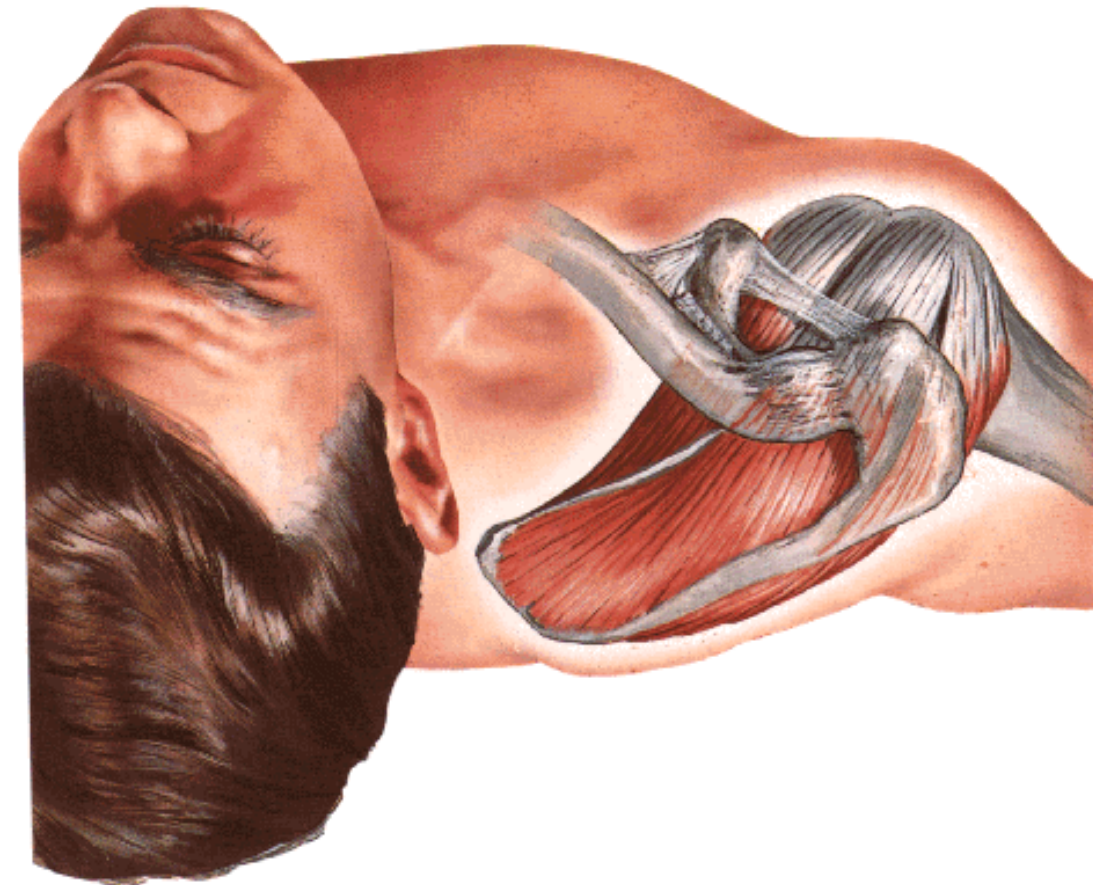


ARTERIAL ANASTOMOSES AROUND THE SCAPULA

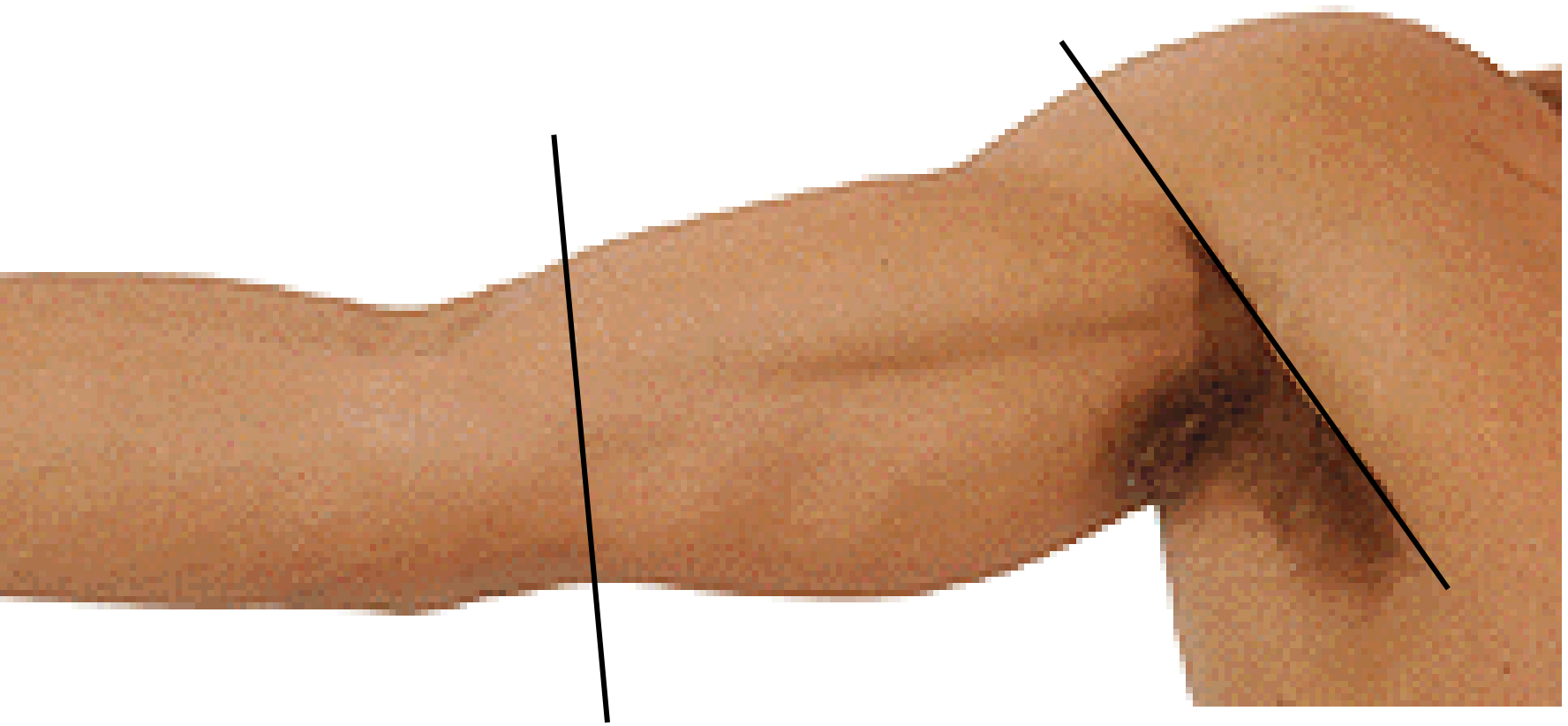
- A. transversa colli**
- A. suprascapularis**
- A. circumflexa scapulae**
- A. circumflexa humeri post.**



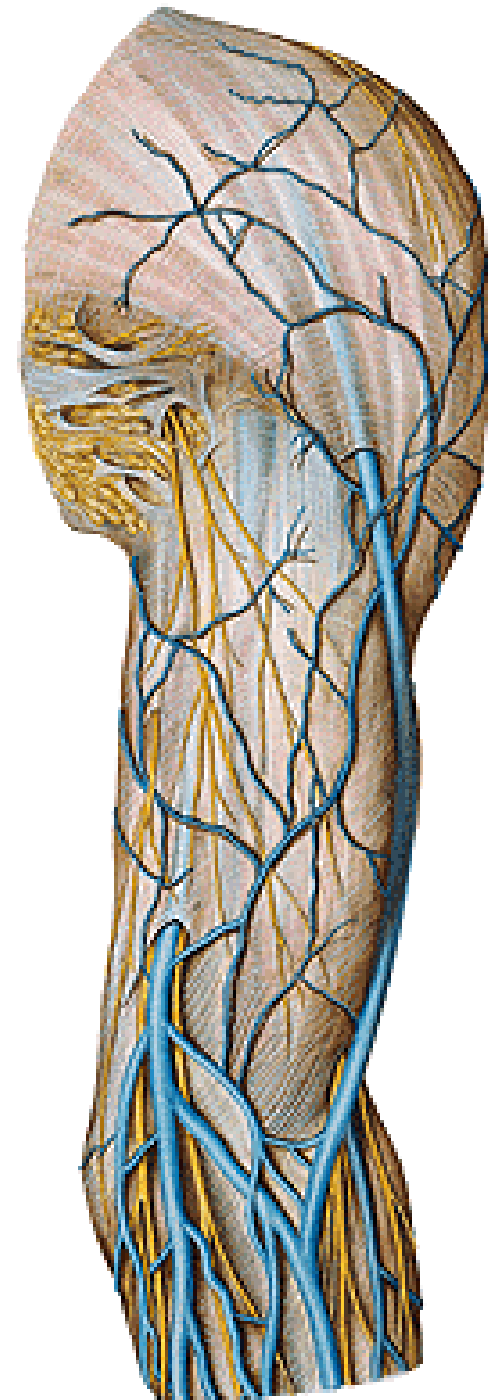
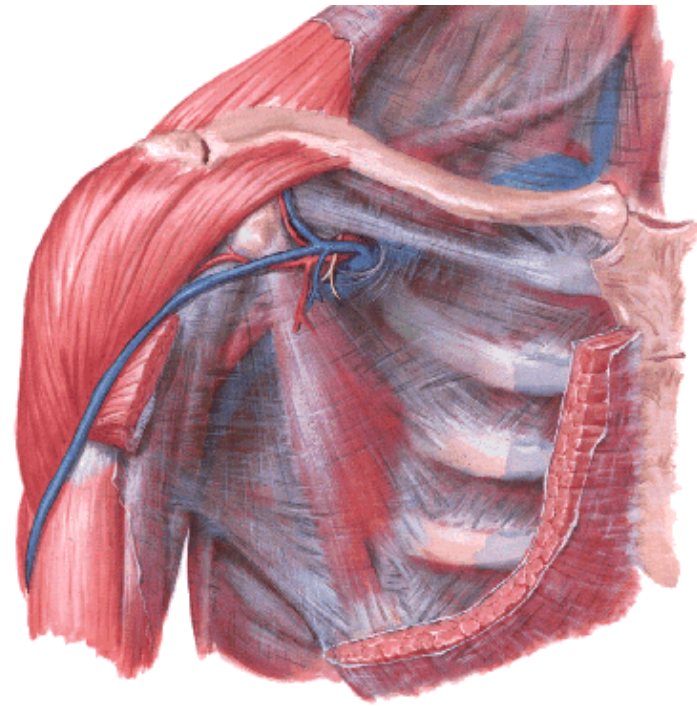
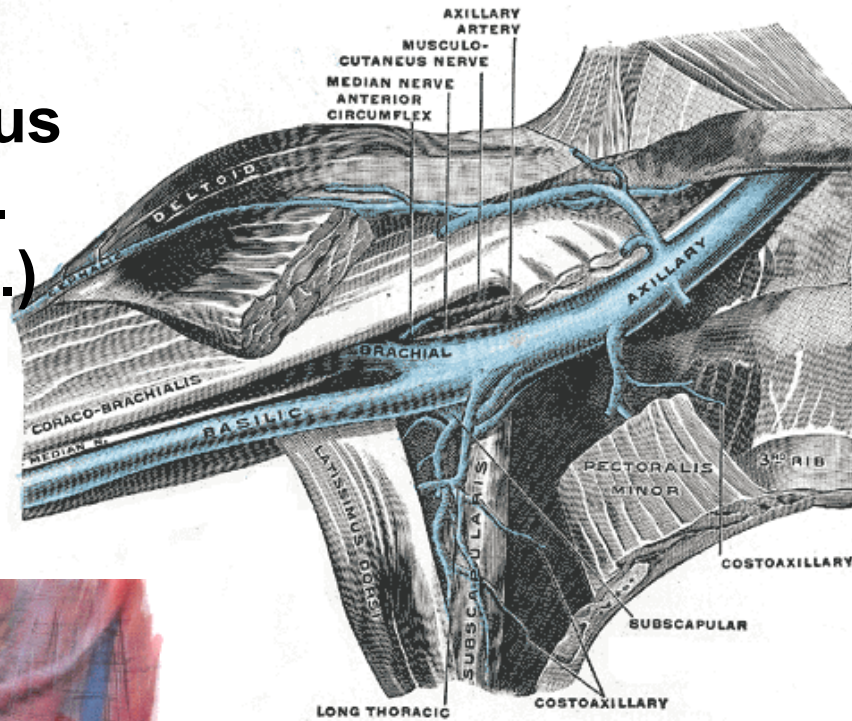
Rotator cuff



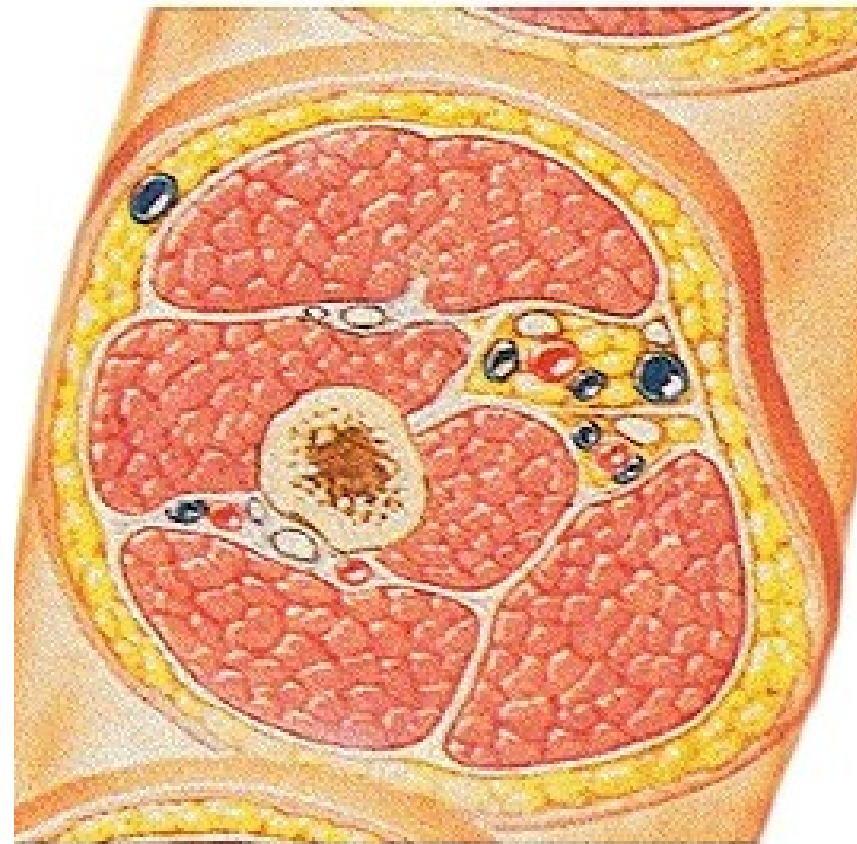
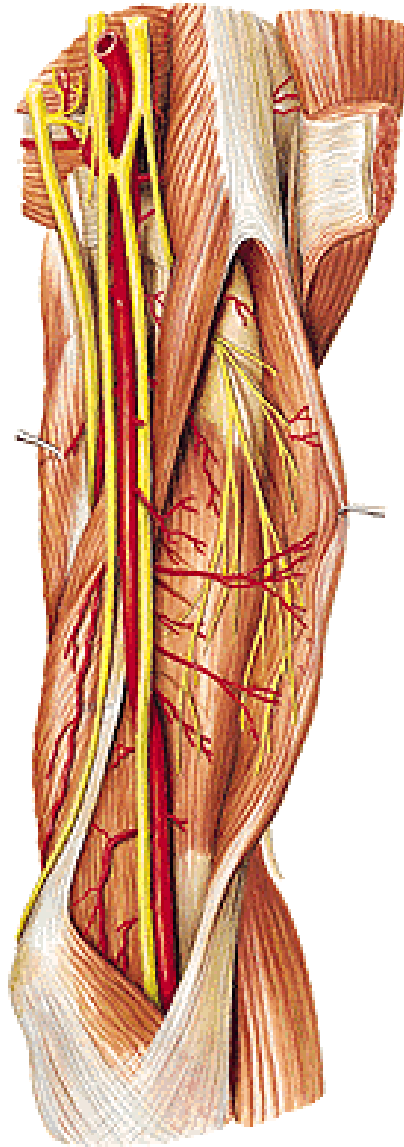
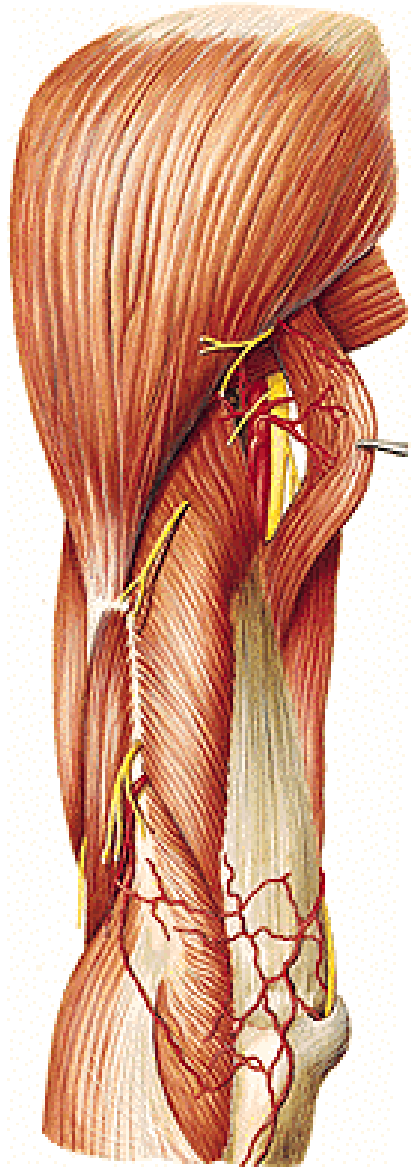
Regio brachii anterior



N. cut. brachii lat. inf.
N. cut. brachii med.
V. cephalica
V. basilica – hiatus basilicus (n. cut. antebrachii med.)



Septum intermusculare mediale et laterale



Anterior group of muscles:

M. biceps brachii

caput longum

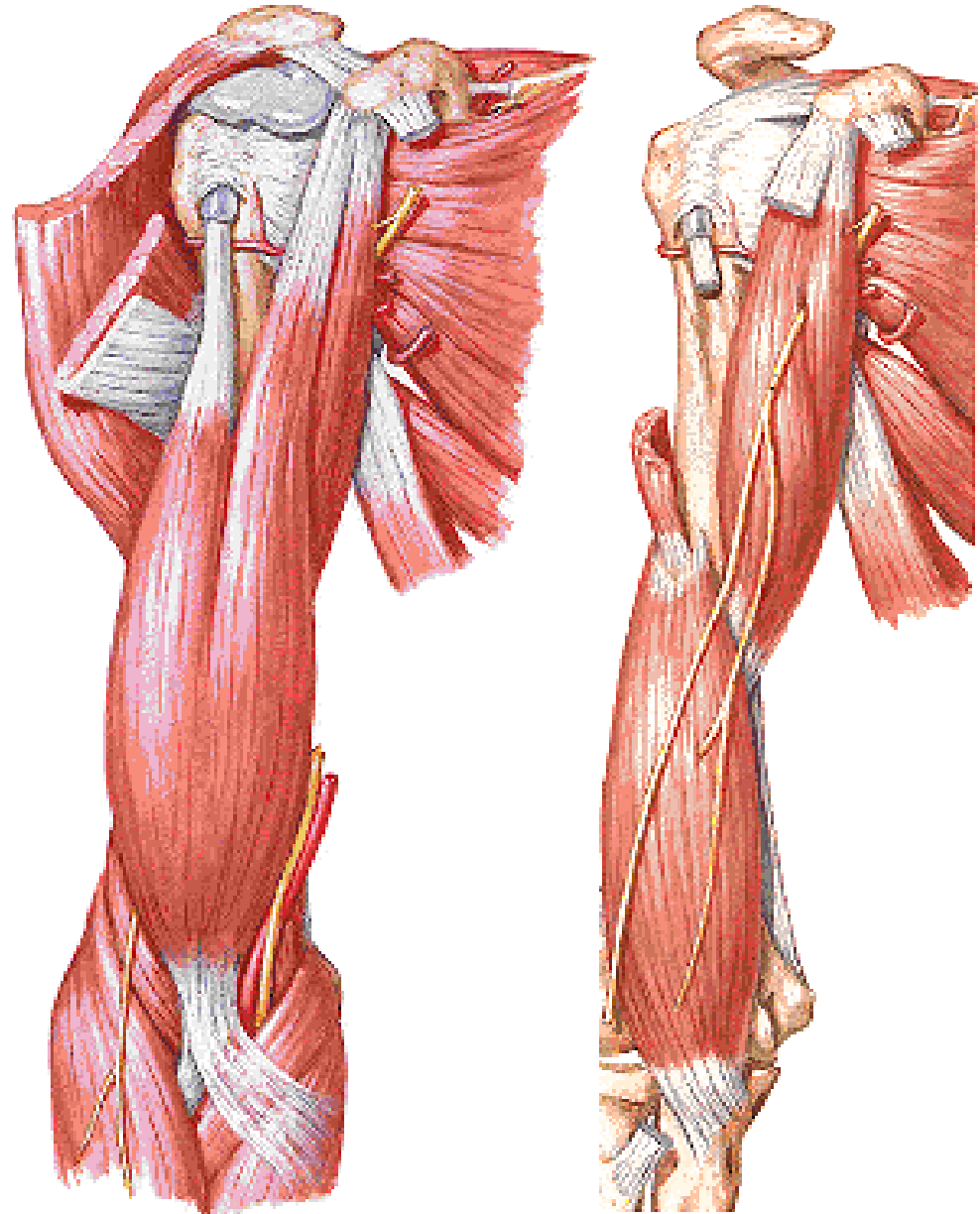
caput breve

aponeurosis m. bicipitis

M. coracobrachialis

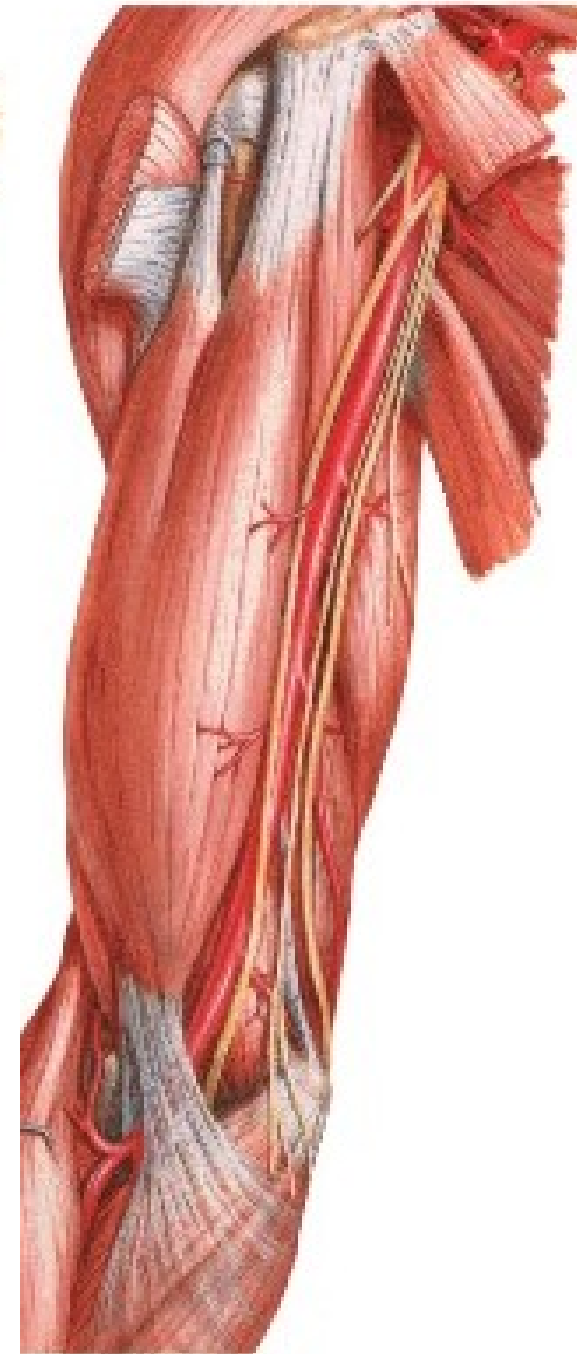
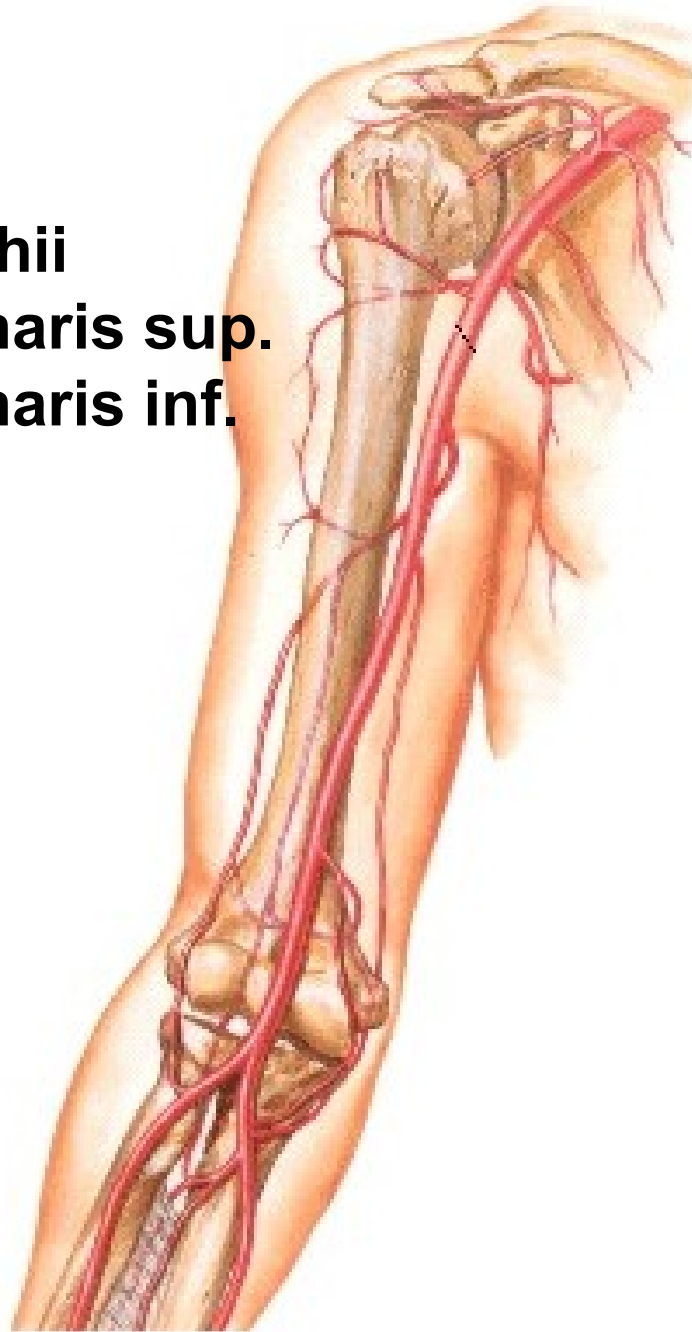
M. brachialis

N. musculocutaneus



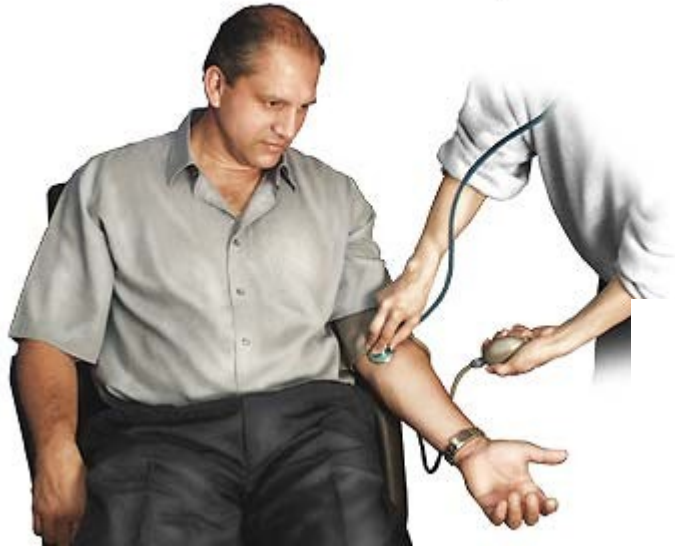A. BRACHIALIS

- a. profunda brachii
- a. collateralis ulnaris sup.
- a. collateralis ulnaris inf.
- a. radialis
- a. ulnaris



Sphygmomanometer

Every health care visit should include a blood pressure reading

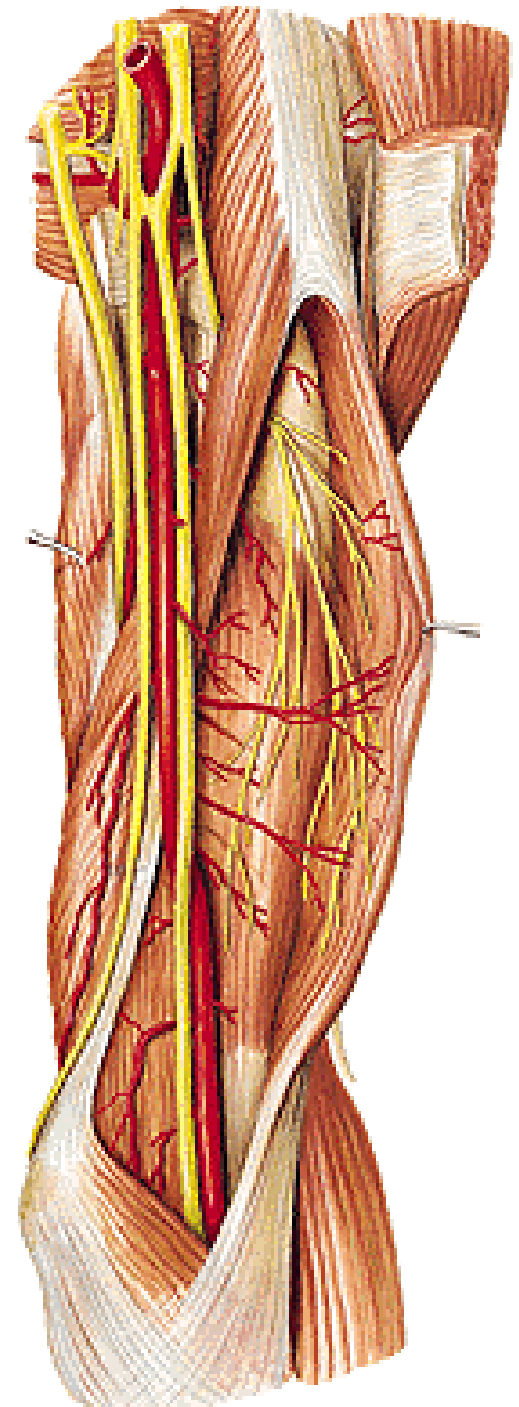


A. collateralis ulnaris sup.

A. collateralis ulnaris inf.

N. medianus

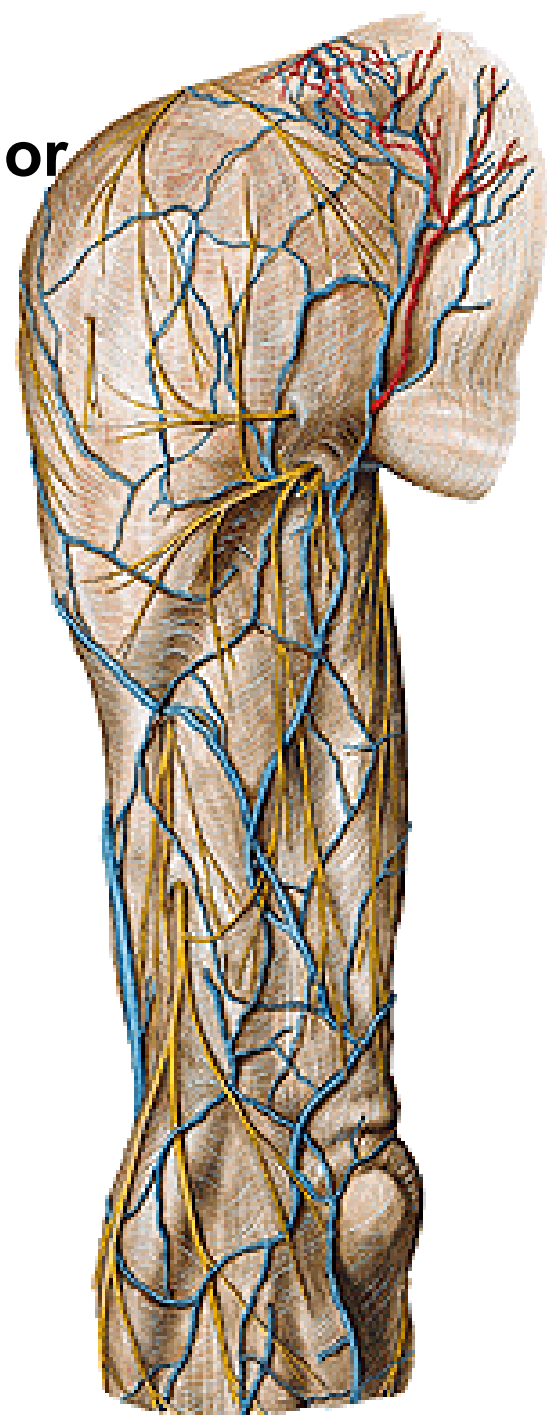
N. ulnaris



Regio brachii posterior



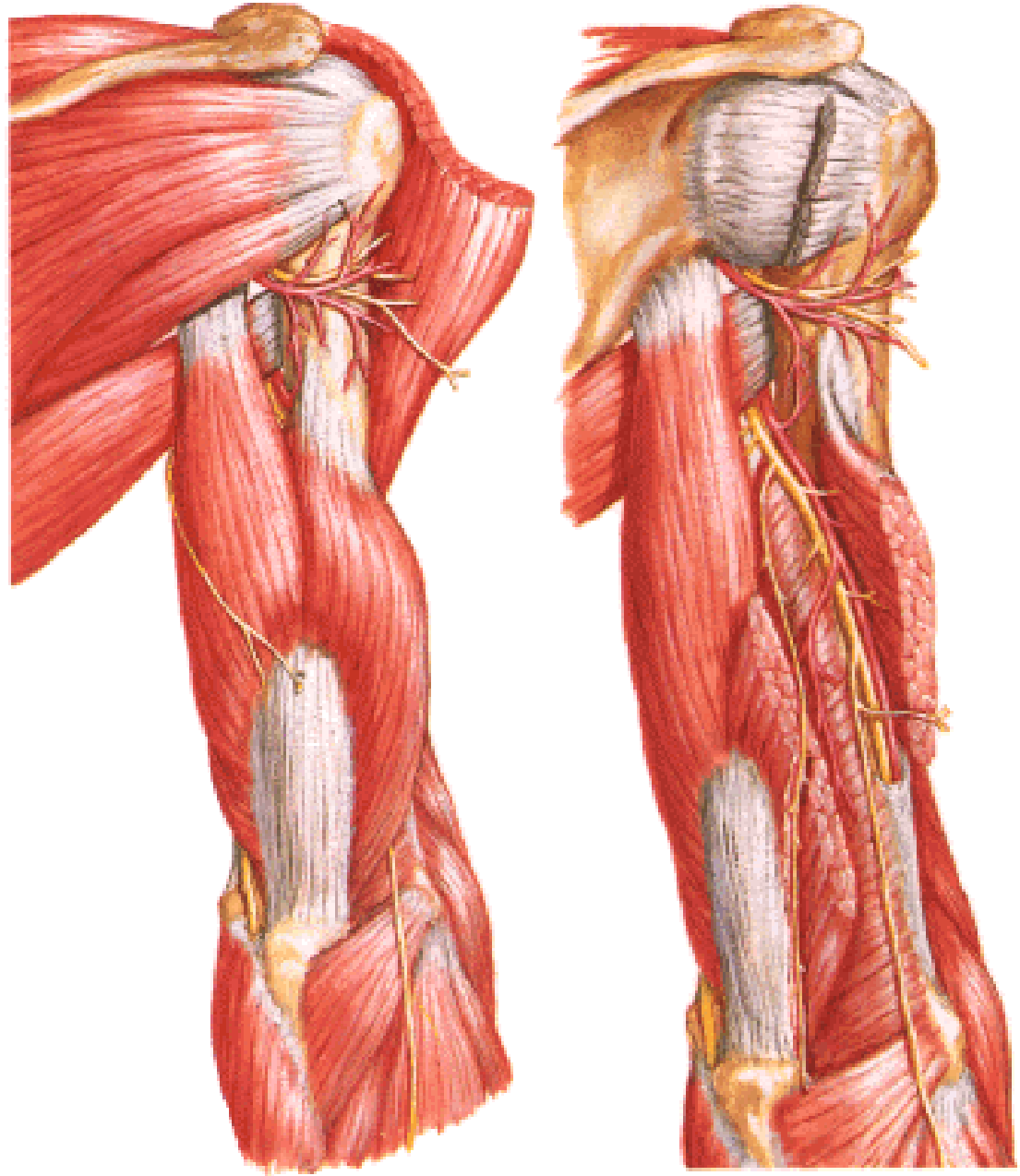
N. cutaneus brachii lateralis inferior
N. cutaneus brachii posterior
N. cutaneus antebrachii post.
(n. radialis)



Posterior group of muscles:

M. triceps brachii
caput longum
caput laterale
caput mediale

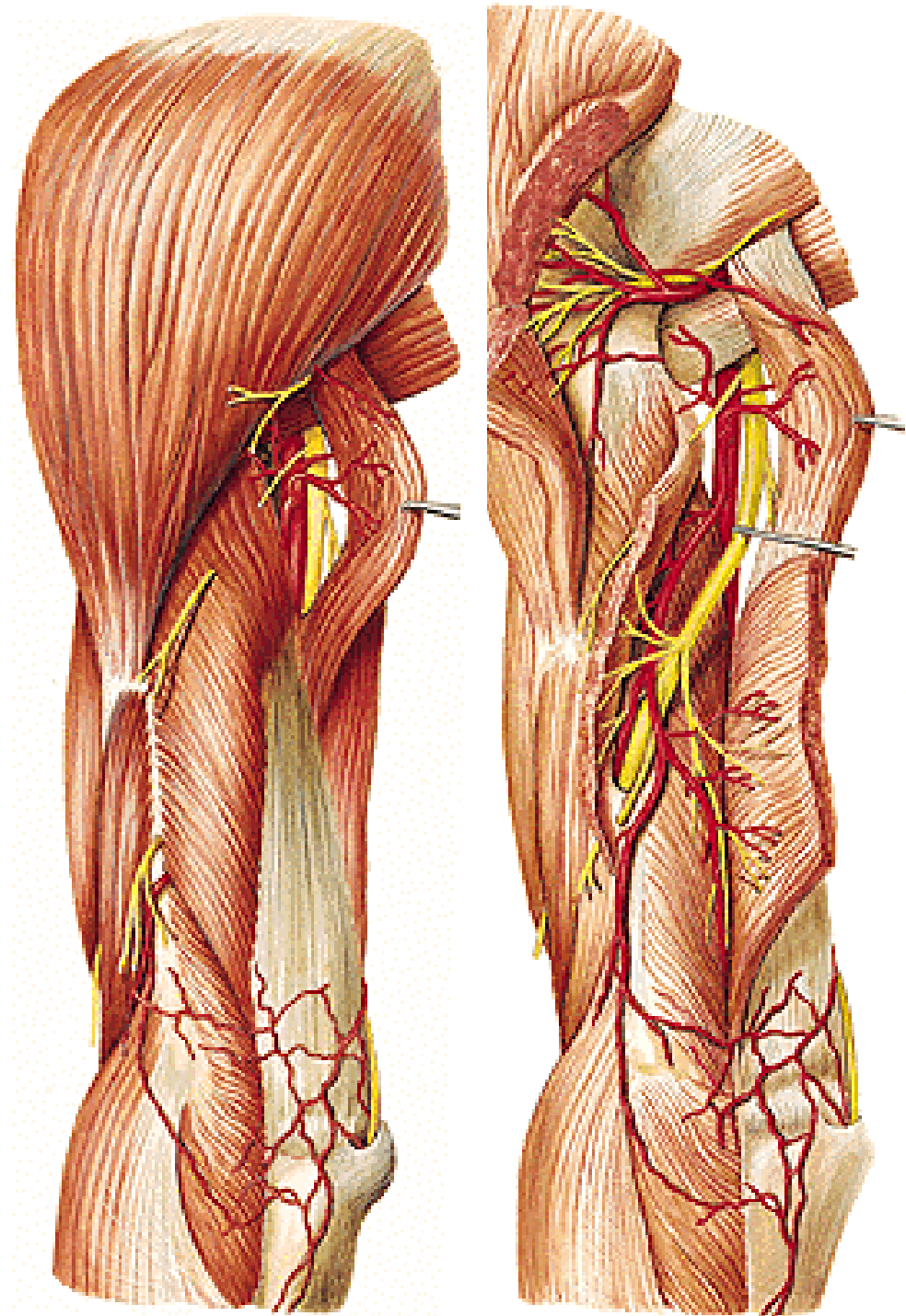
N. radialis



A. PROFUNDA BRACHII

- r. deltoideus
- a. nutricia humeri
- a. collateralis media
- a. collateralis radialis

Rete articulare cubiti



Sulcus bicipitalis medialis

- a. brachialis
- vv. brachiales
- n. medianus
- v. basilica
- n. cutaneus antebrachii med.
- a. collateralis ulnaris sup.
- vv. coll. ulnares sup.
- n. ulnaris

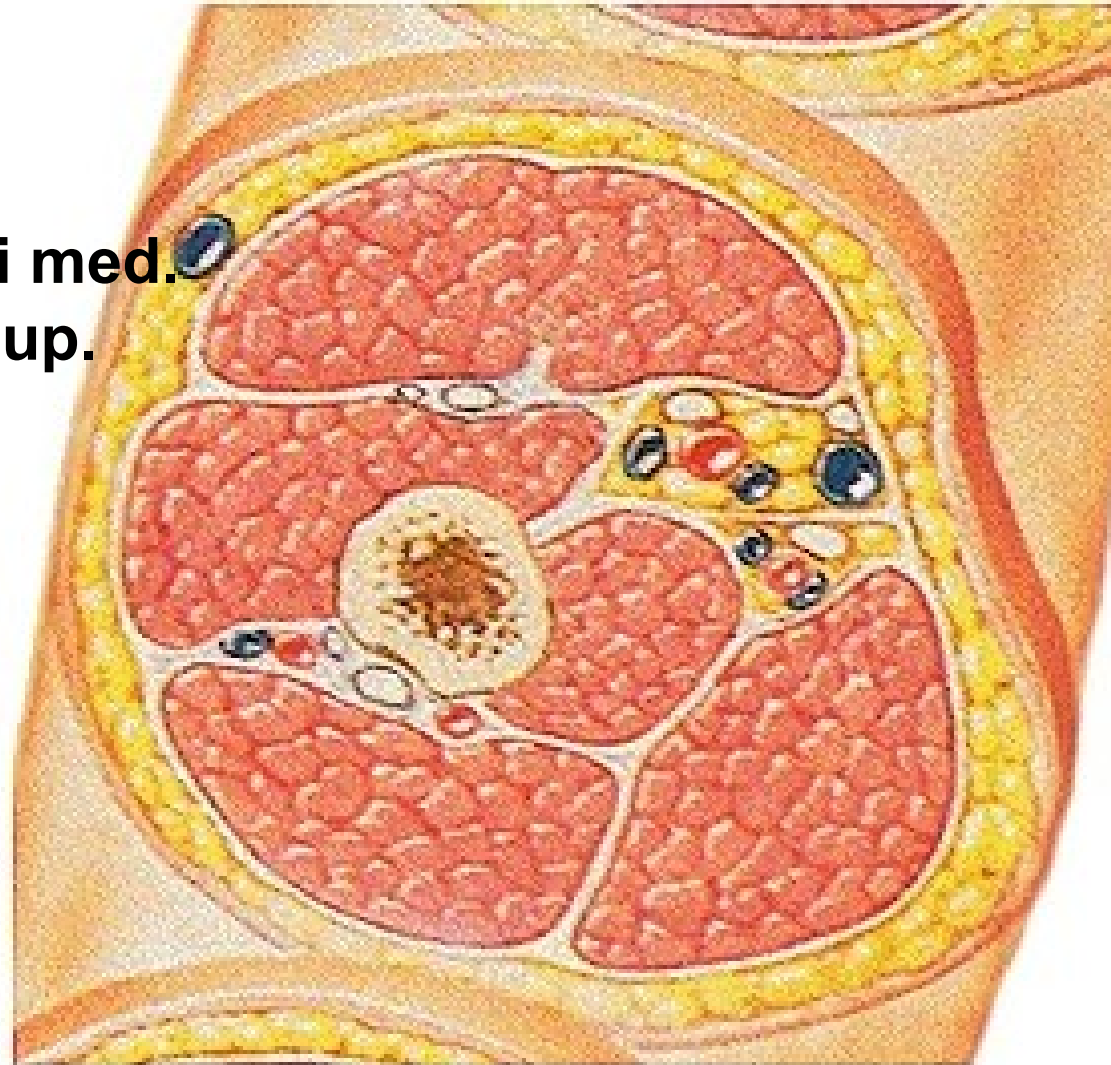
N. musculocutaneus

N. radialis

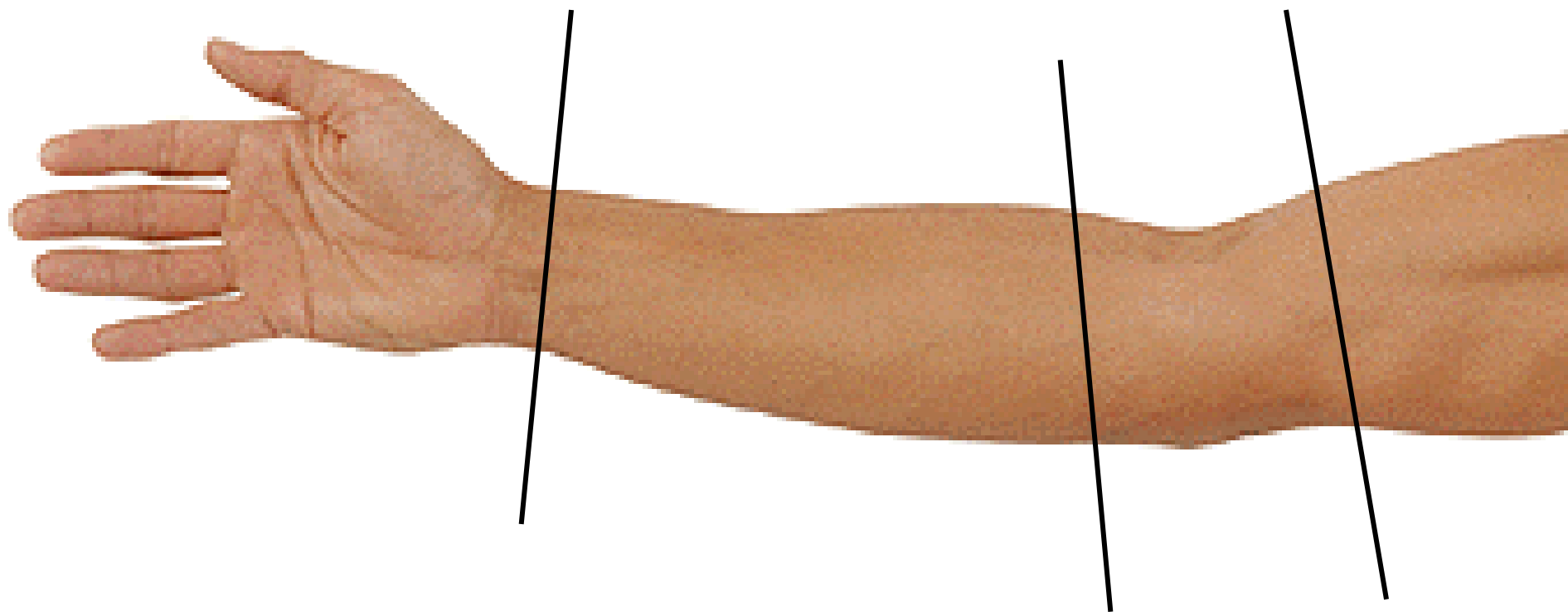
A. coll. radialis

A. coll. media

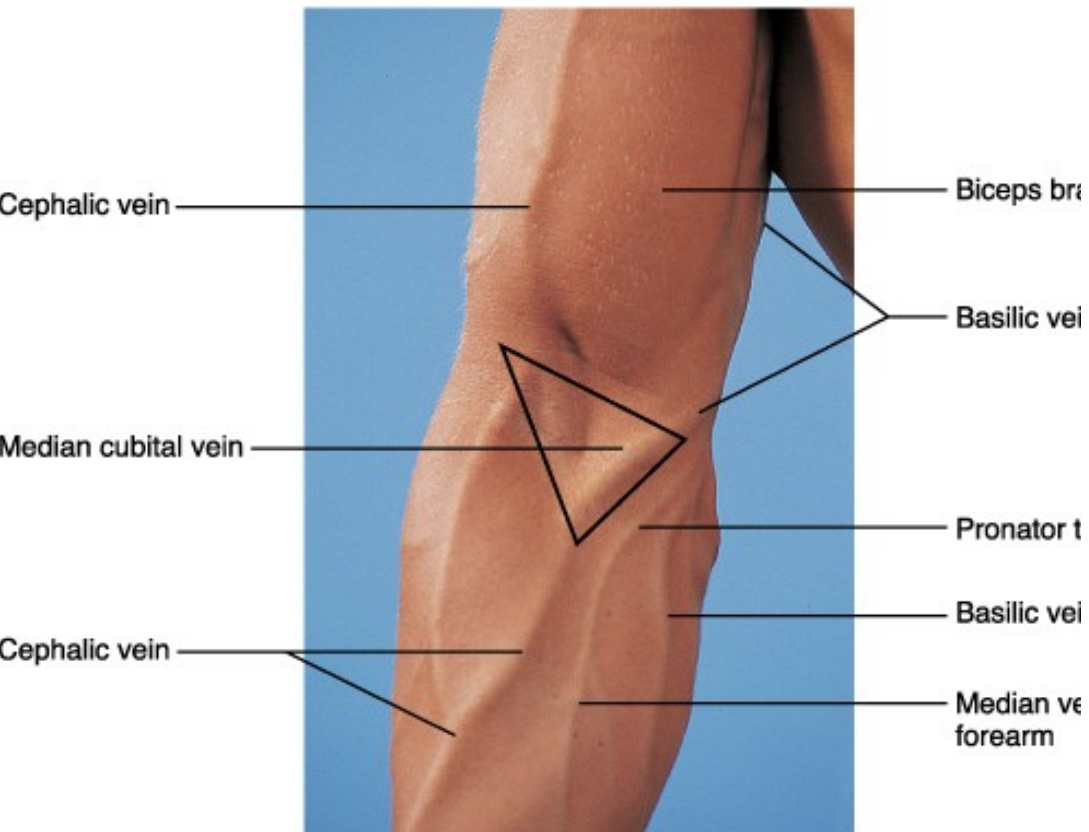
V. profunda brachii



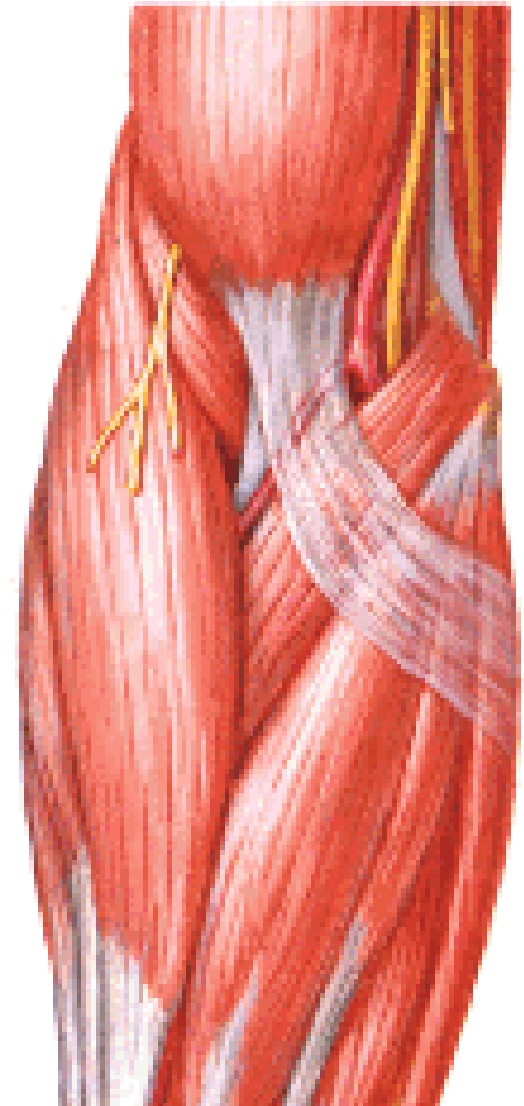
Regio cubiti et antebrachii anterior



Fossa cubitalis

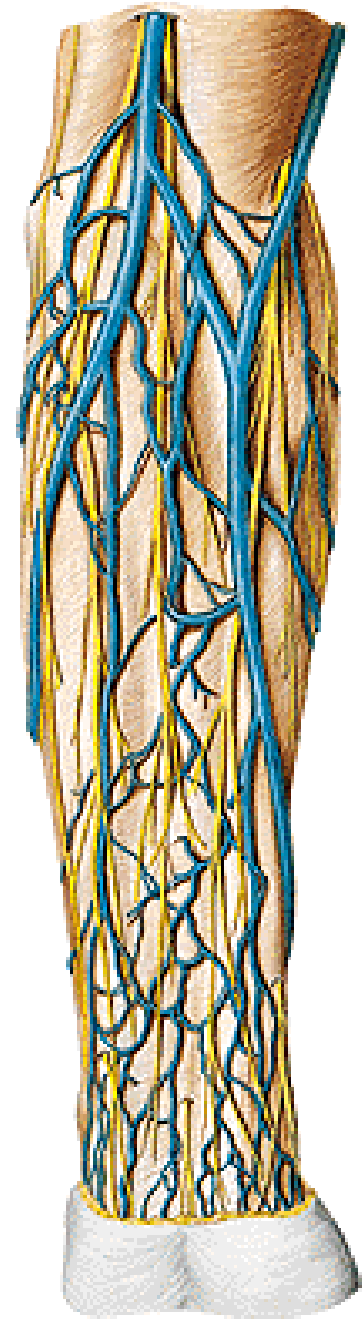


Copyright © 2001 Benjamin Cummings, an imprint of Addison Wesley Longman, Inc.



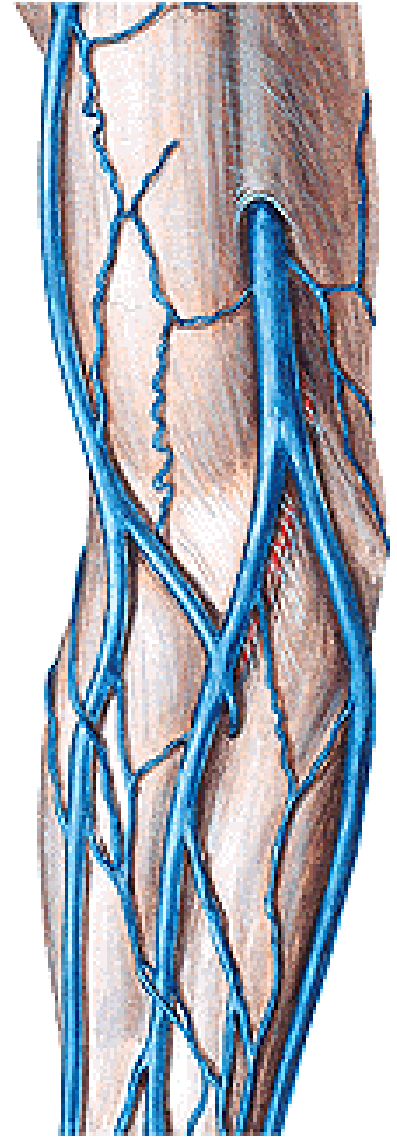
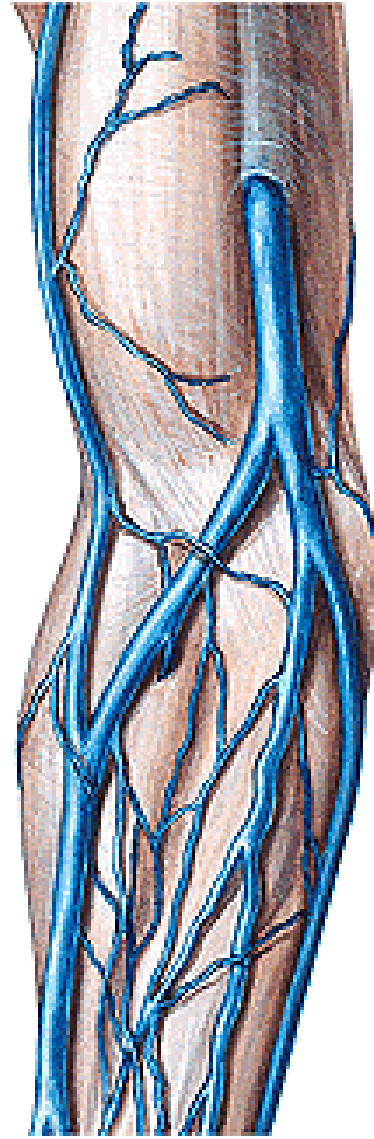
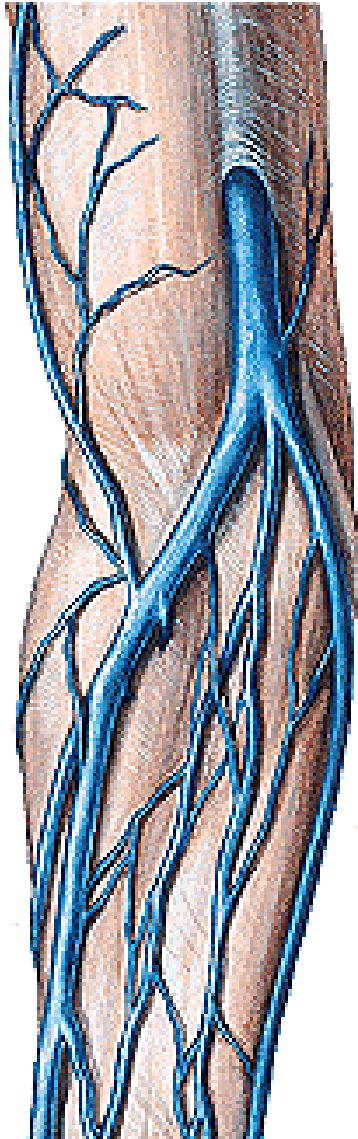
N. cutaneus brachii med.
N. cutaneus antebrachii med.
- r. anterior
- r. posterior
N. cutaneus antebrachii lat.
(n. musculocutaneus)

V. cephalica
V. basilica



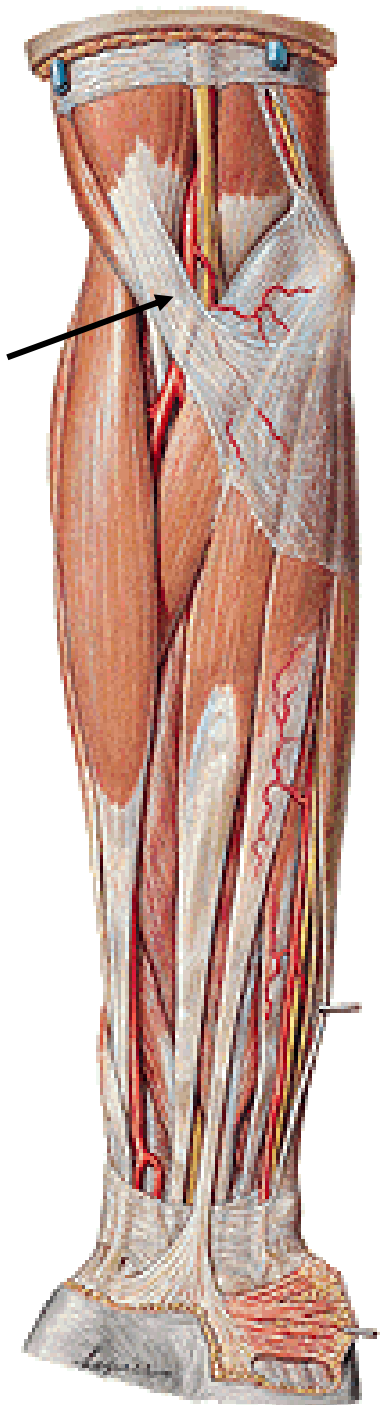
V. mediana cubiti

V. mediana antebrachii – v. mediana cephalica et basilica



- A. brachialis**
- a. radialis
- a. ulnaris

**aponeurosis m. bicipitis
brachii**



Anterior group of muscles:

M. pronator teres

M. flexor carpi radialis

M. palmaris longus

M. flexor carpi ulnaris

M. flexor digitorum spf.

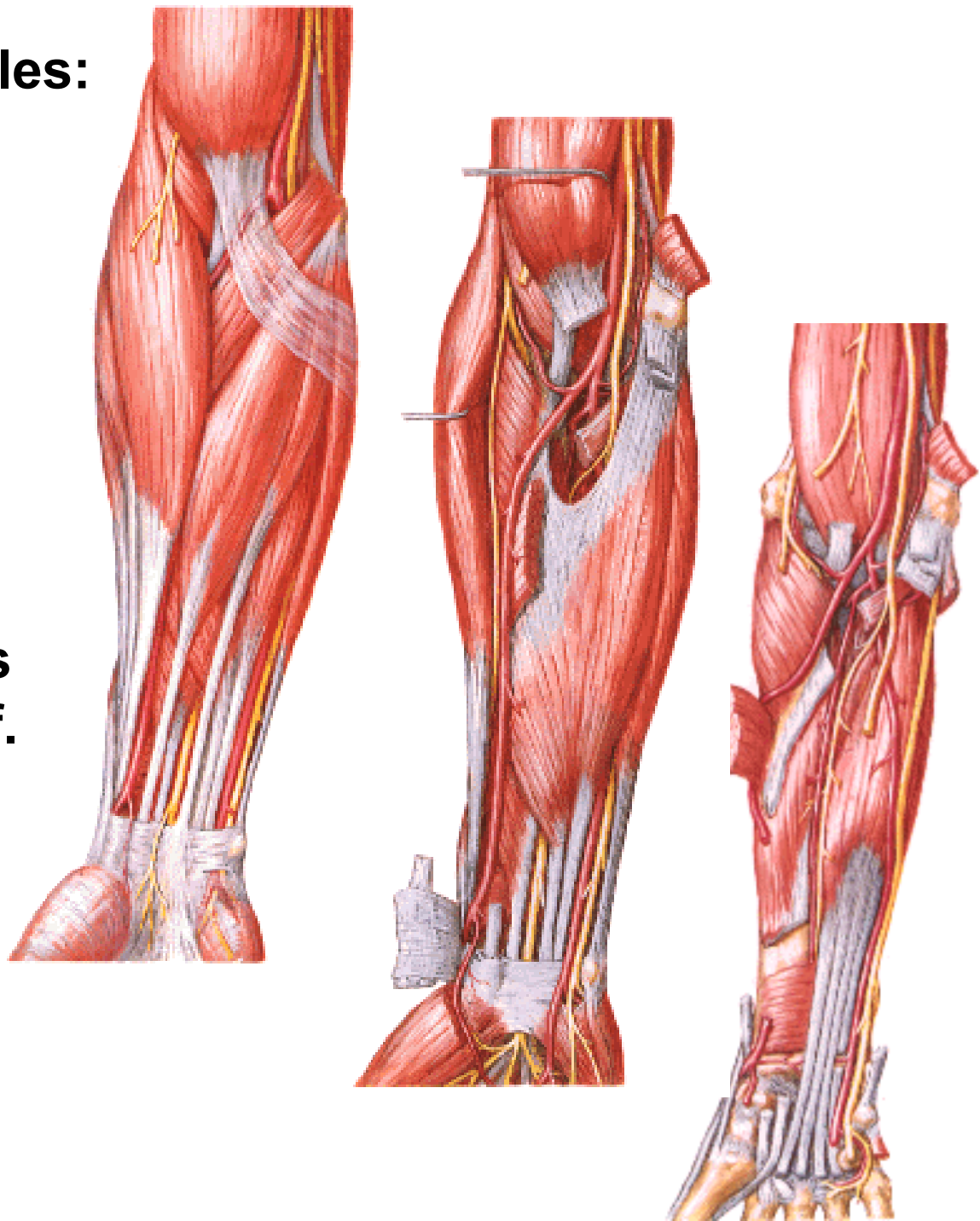
M. flexor pollicis longus

M. flexor digitorum prof.

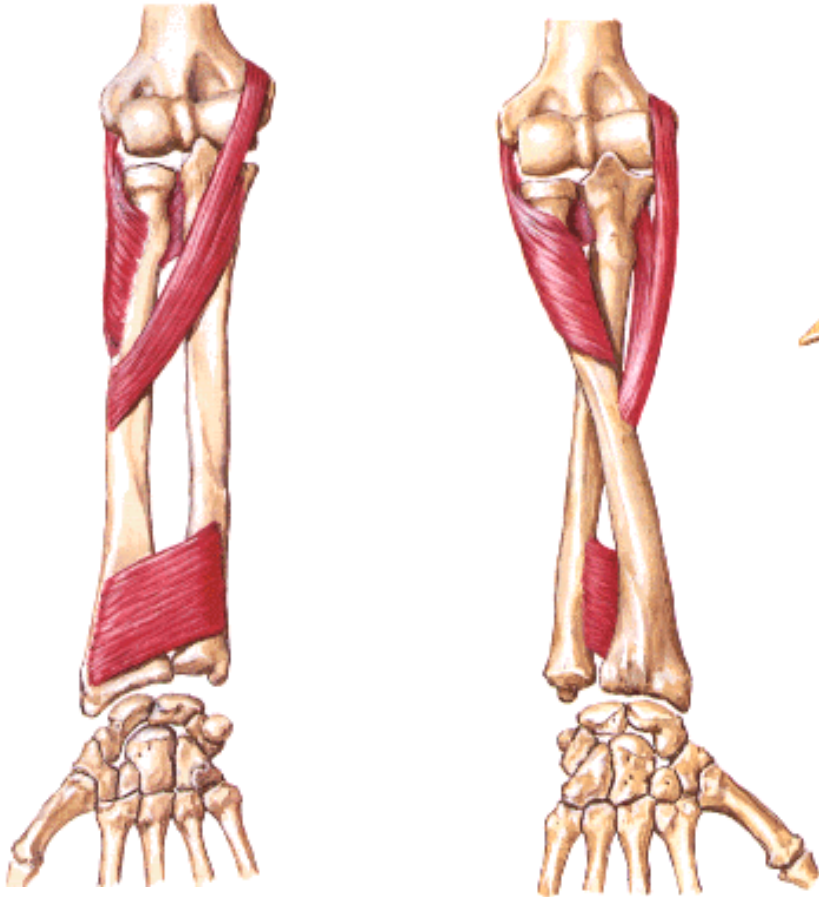
M. pronator quadratus

N. medianus

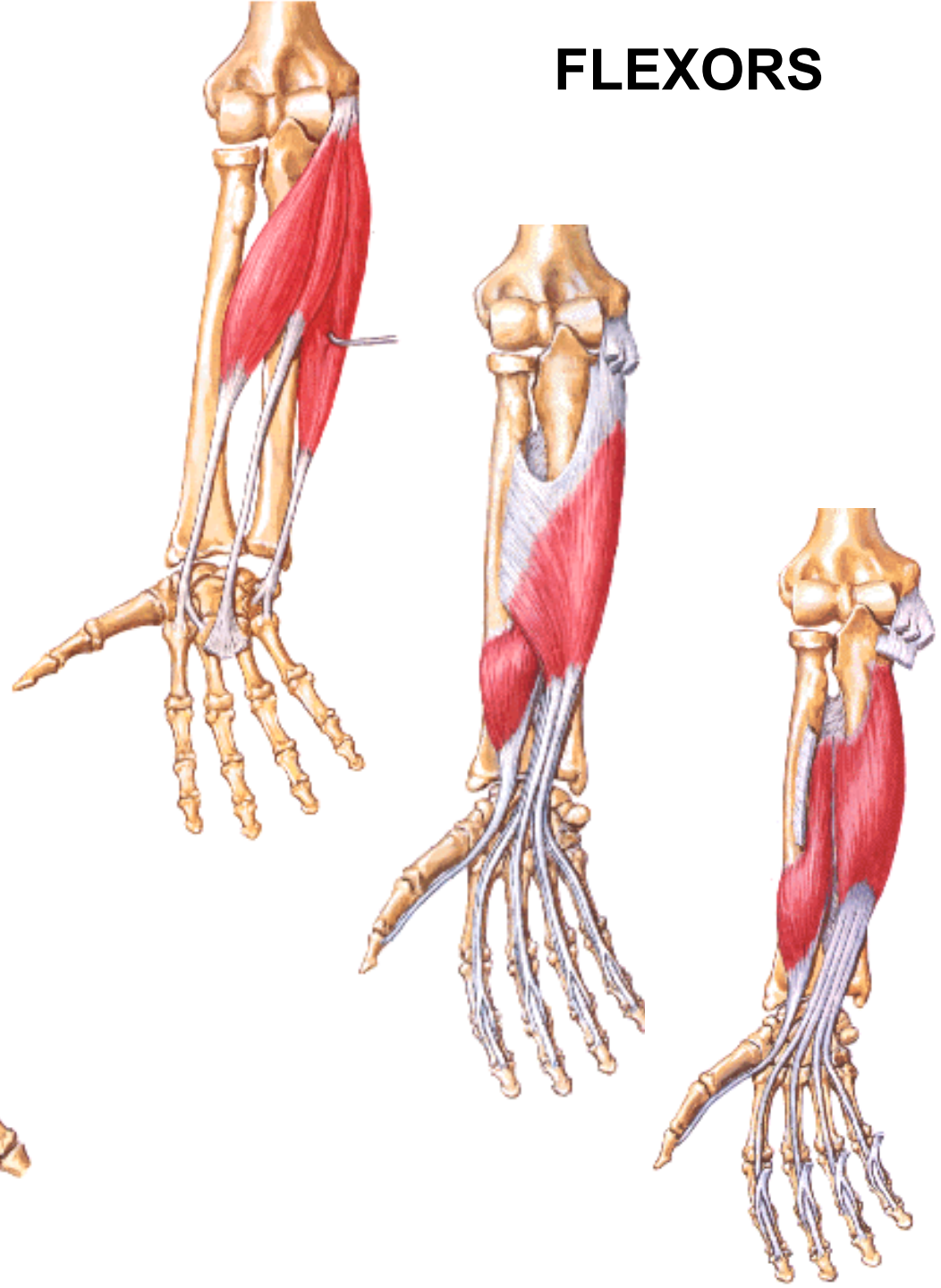
N. ulnaris



PRONATION
-
SUPINATION



FLEXORS



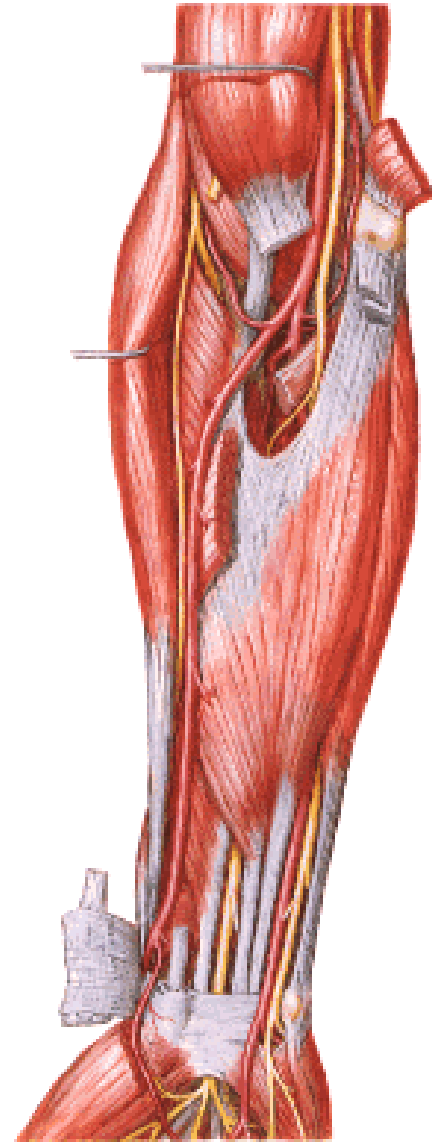
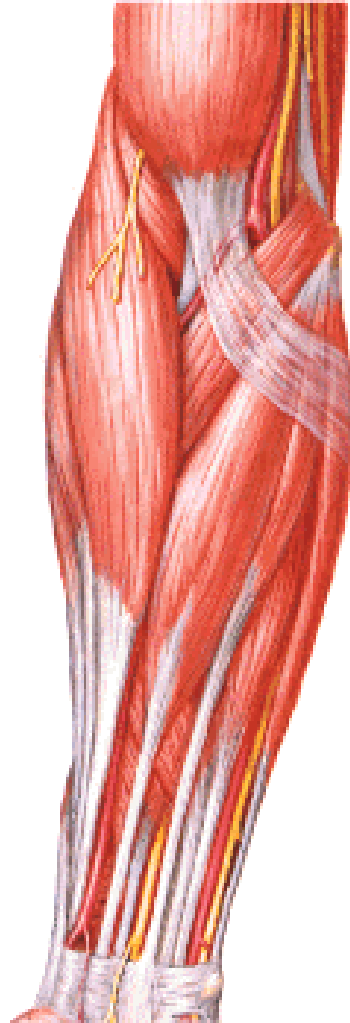
Lateral group of muscles:

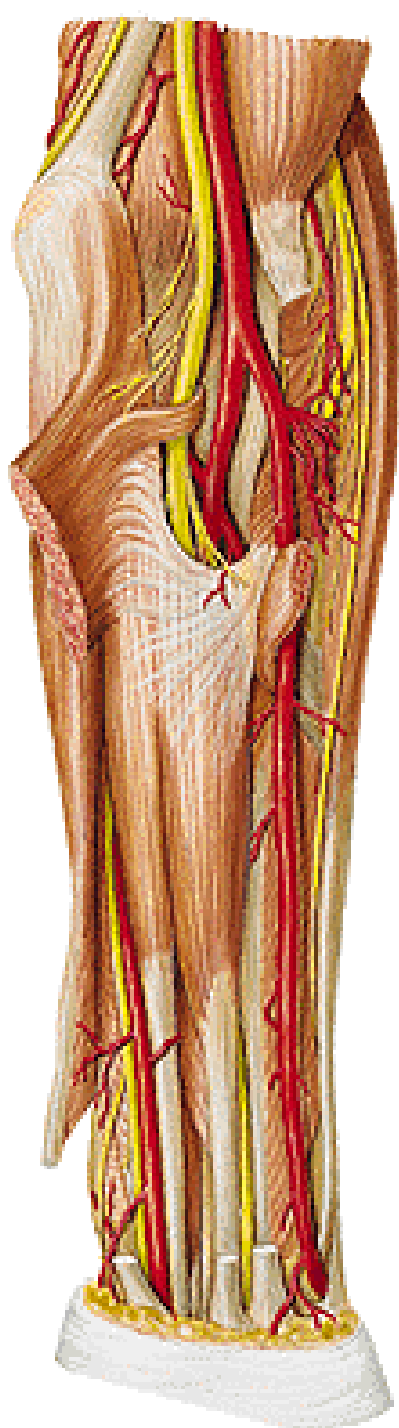
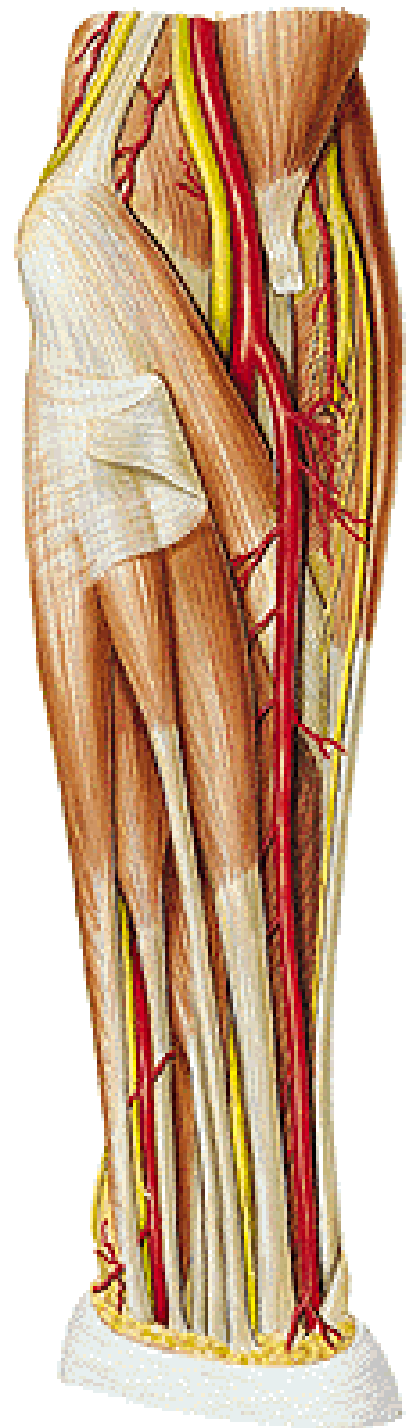
M. brachioradialis

M. extensor carpi radialis longus

M. extensor carpi radialis brevis

M. supinator





A. radialis

- a. recurrens radialis

- rr. musculares

- r. carpeus palmaris

- r. palmaris spf.

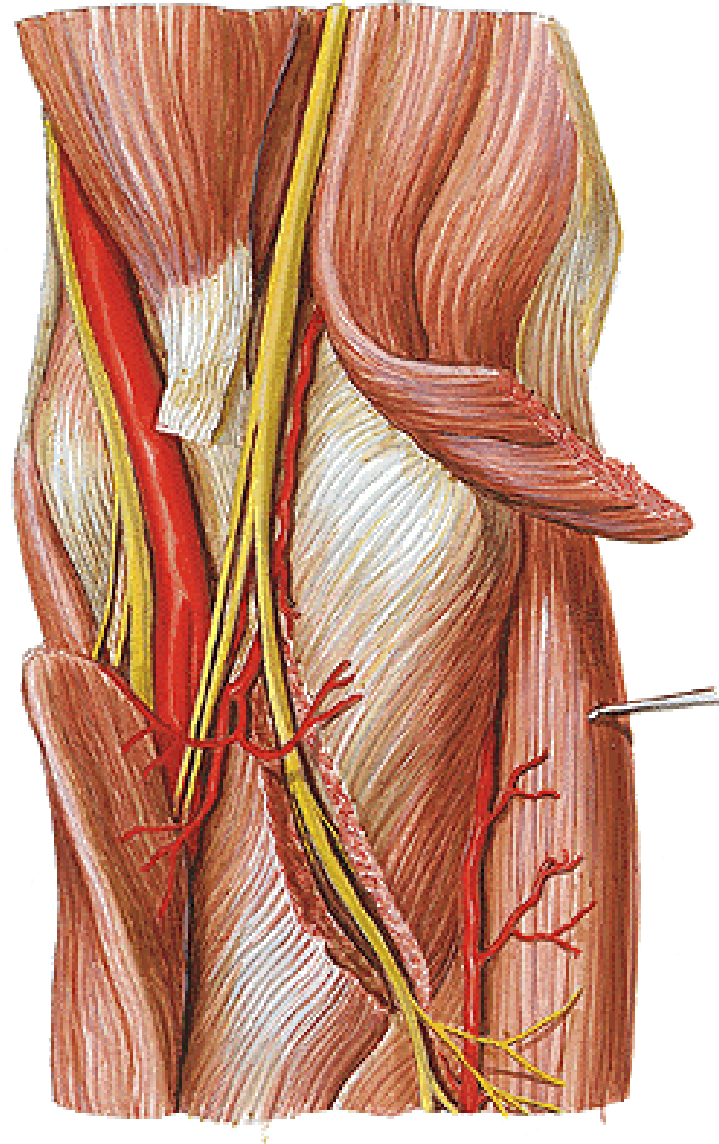
R. spf. n. radialis

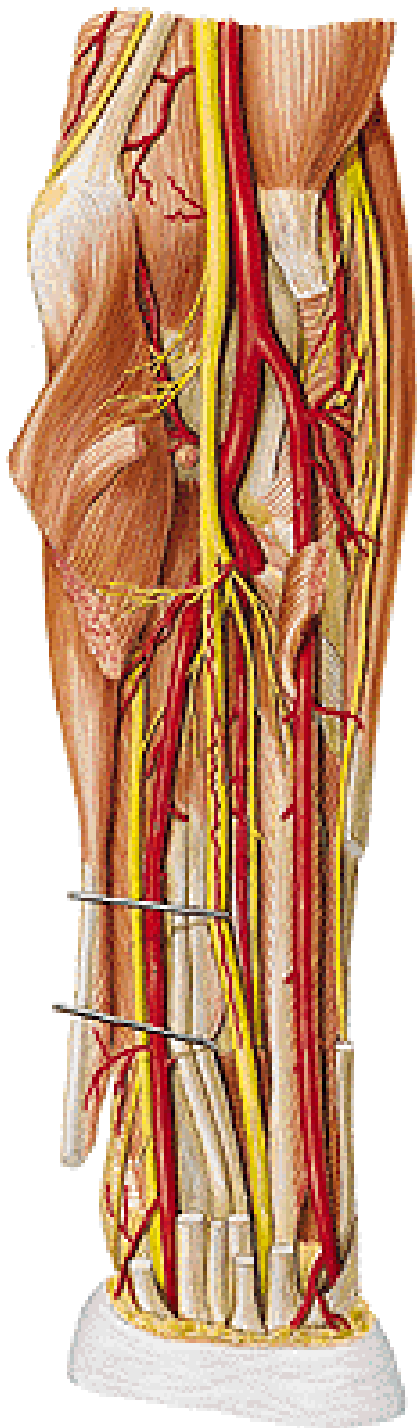
N. medianus

A. ulnaris

N. ulnaris

N. radialis - r. spf.
- r. prof.
M. supinator





N. medianus

- rr. musculares
- n. interosseus ant.

A. ulnaris

- a. recurrens ulnaris
- rr. musculares
- a. interossea communis
 - a. interossea ant.
 - a. interossea post.

Regio cubiti et antebrachii posterior



**N. cutaneus antebrachii med.
- r. posterior**

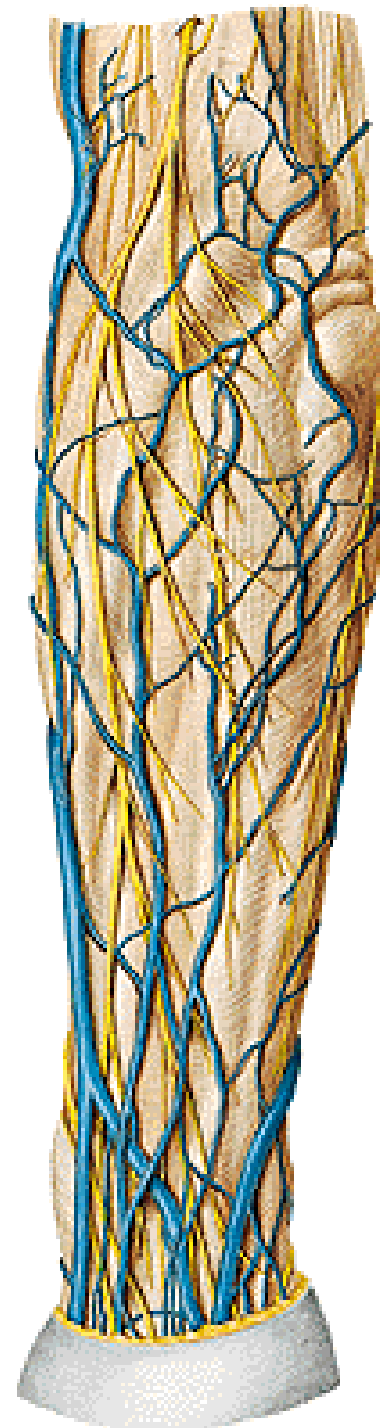
**N. cutaneus antebrachii post.
(n. radialis)**

R. superficialis n. radialis

R. dorsalis n. ulnaris

V. cephalica

V. basilica



Posterior group of muscles:

M. anconeus

M. extensor digitorum

M. extensor digiti minimi

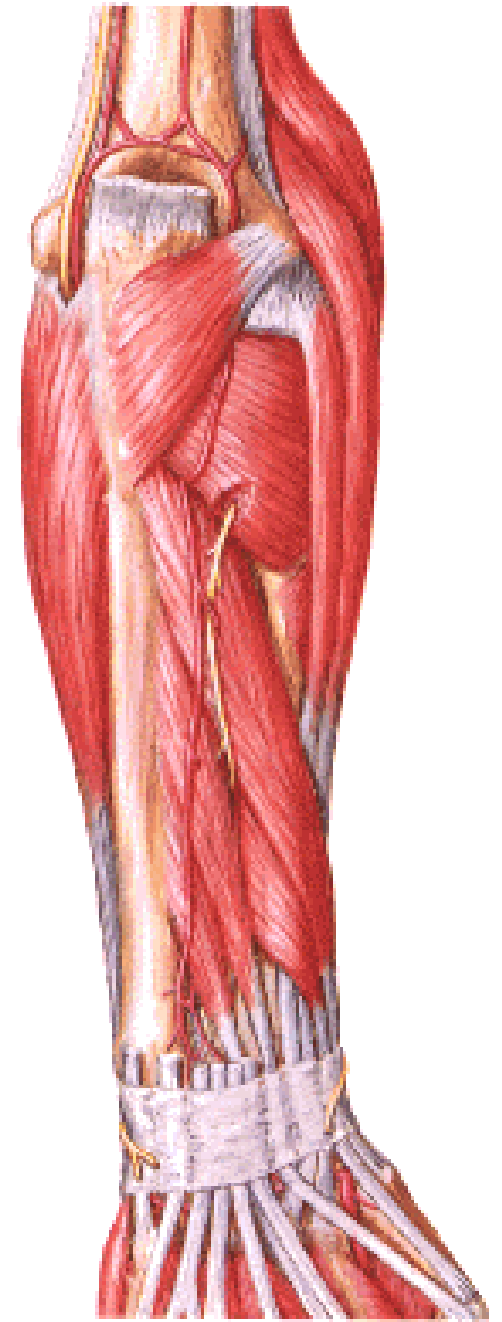
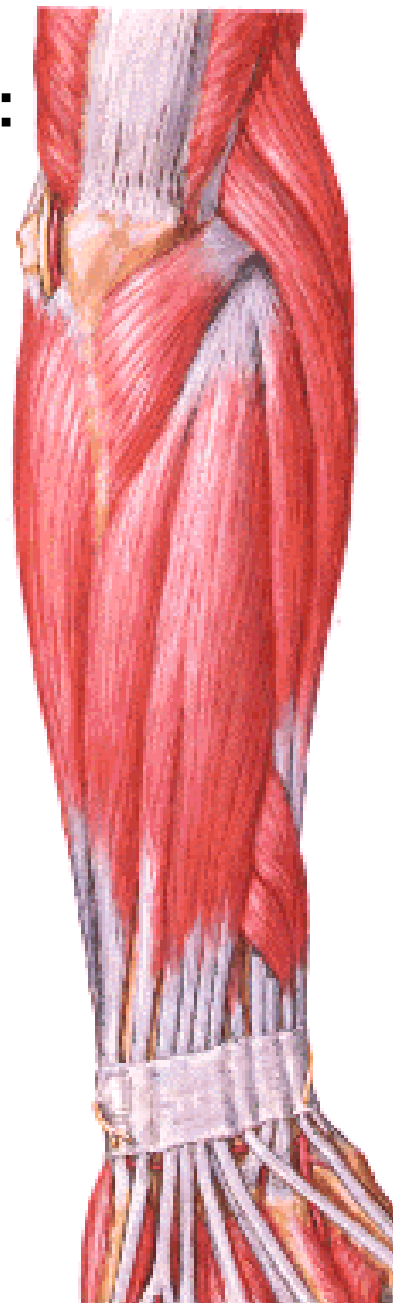
M. extensor carpi ulnaris

M. abductor pollicis longus

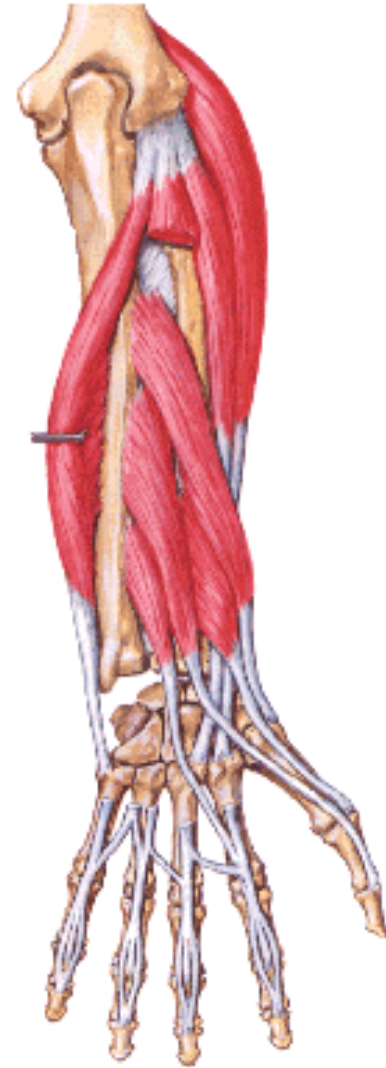
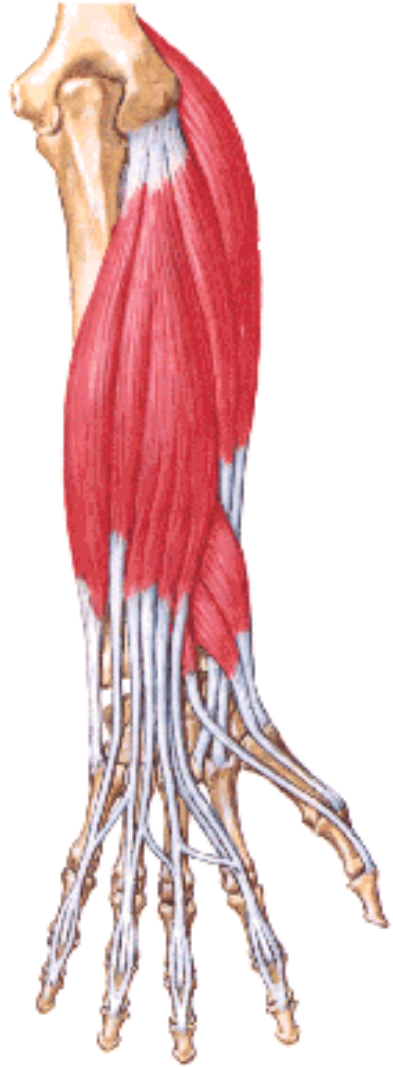M. extensor pollicis brevis

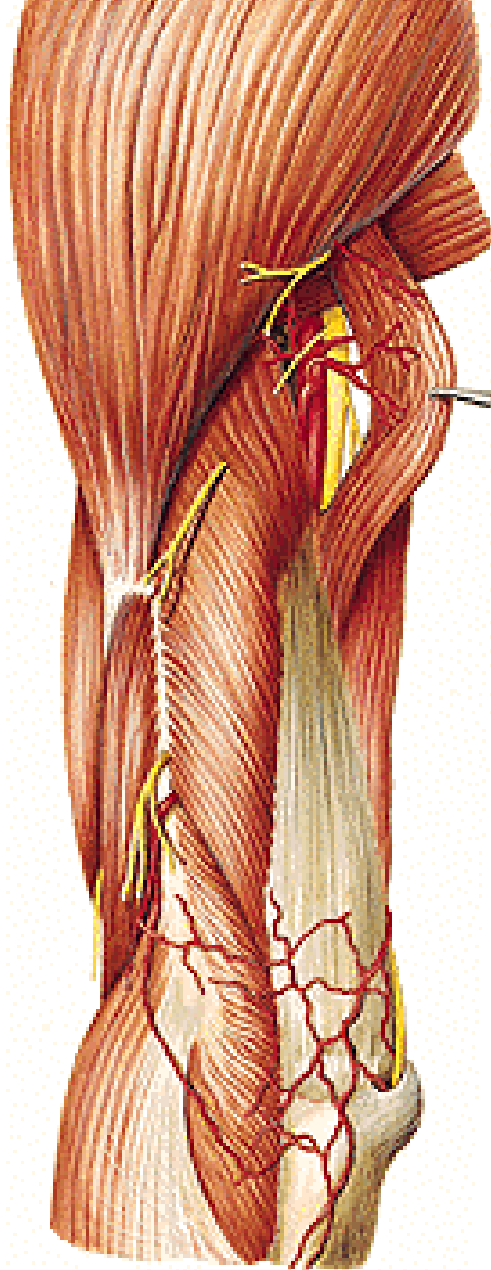
M. extensor pollicis longus

M. extensor indicis



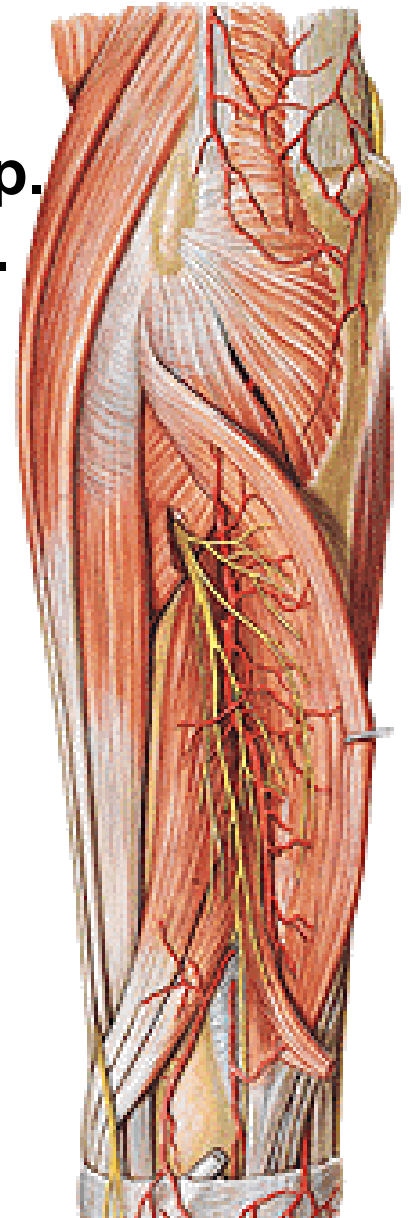
EXTENSORS





Rete articulare cubiti

- A. collateralis ulnaris sup.**
- A. collateralis ulnaris inf.**
- A. collateralis media**
- A. collateralis radialis**
- A. recurrens ulnaris**
- A. recurrens radialis**
- A. recurrens interossea**



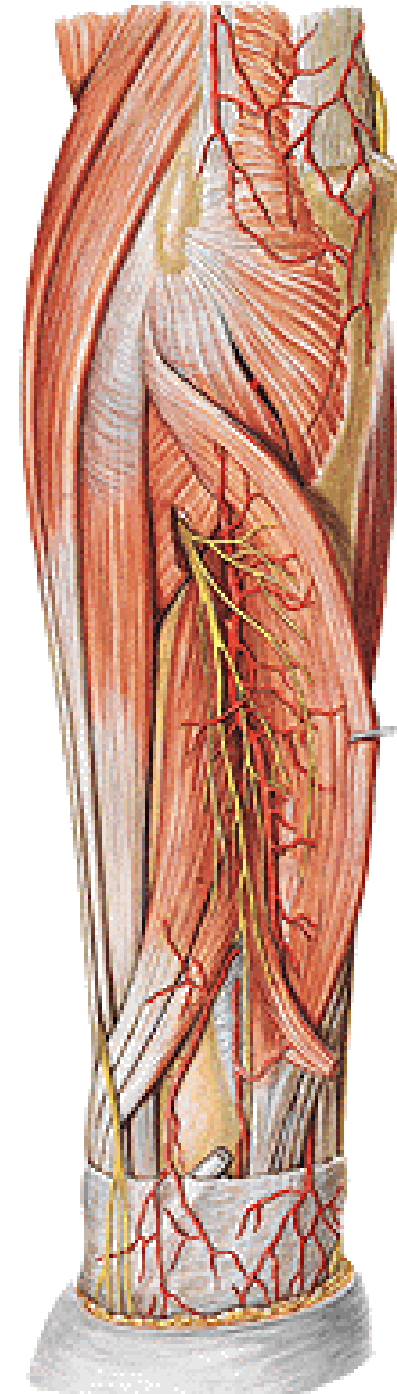
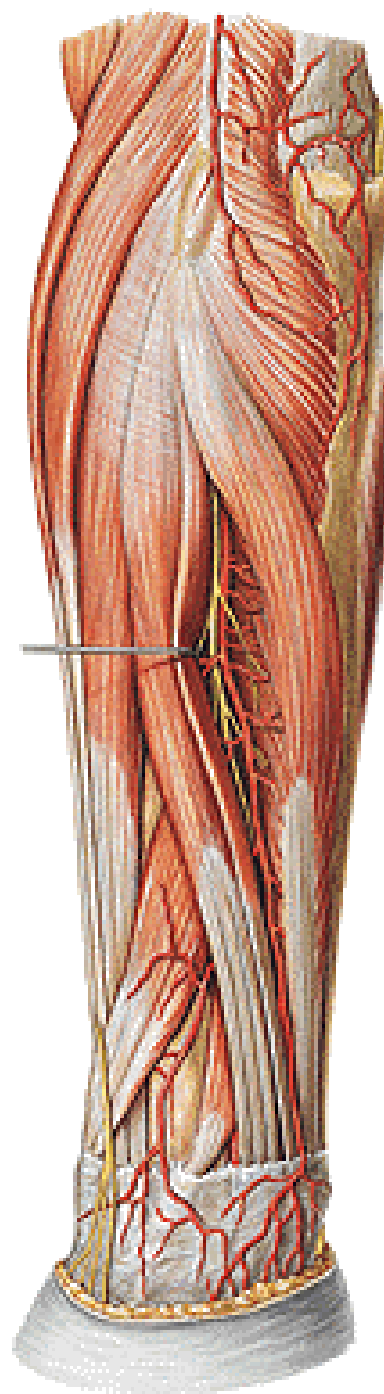
N. radialis

- n. interosseus post.
- rr. musculares

A. interossea post.

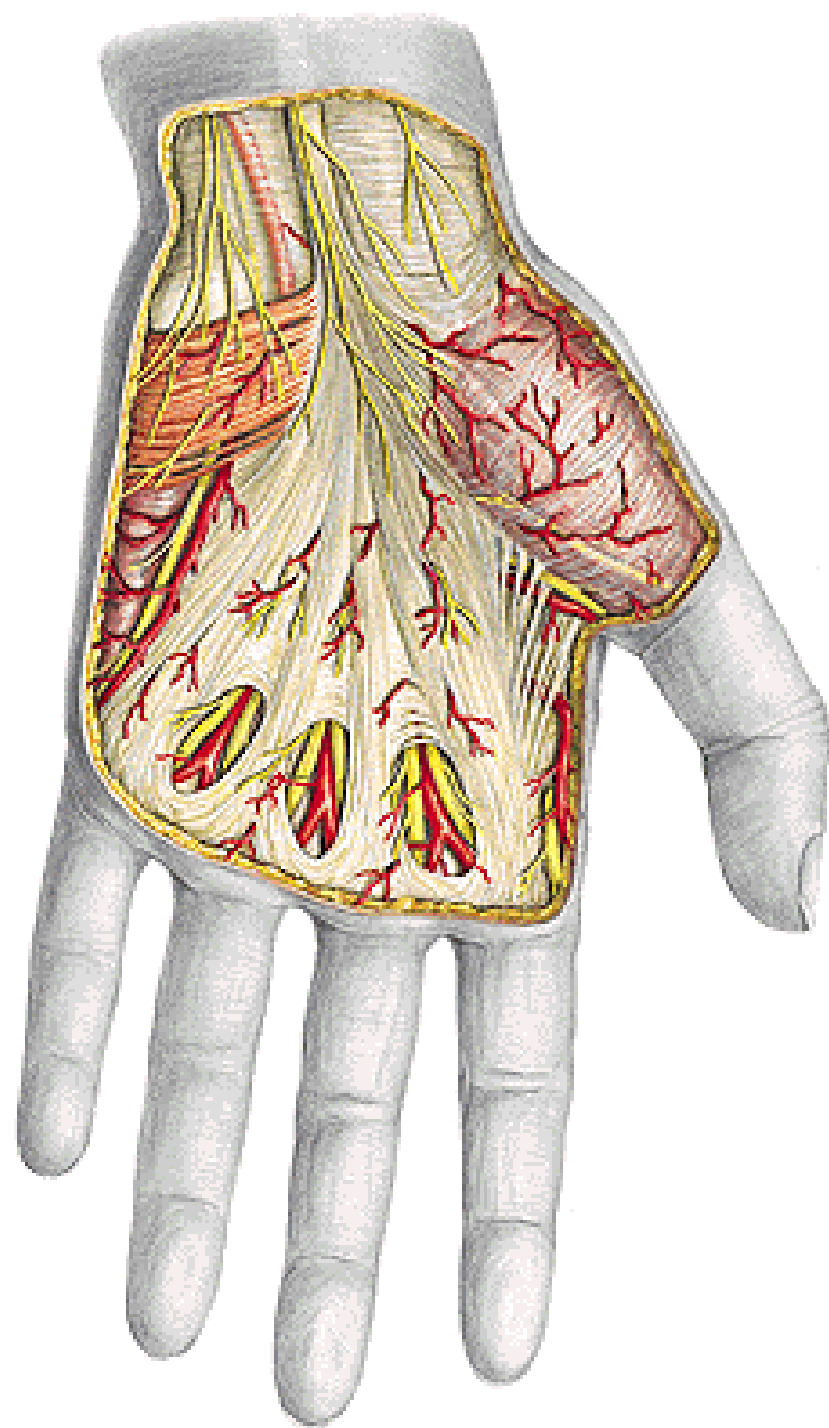
- a. recurrens interossea

A. interossea ant.



Regio carpi palmaris et palma manus

N. ulnaris – r. palmaris
N. medianus – rr. palmares
M. palmaris brevis
Aponeurosis palmaris



Retinaculum flexorum

Arcus palmaris spf.

**- aa. digitales palmares
communes et propriae**

A. princeps pollicis

Nn. digitales palmares communes

Nn. digitales palmares proprii

Thenarus:

M. abductor pollicis brevis

M. flexor pollicis brevis

M. opponens pollicis

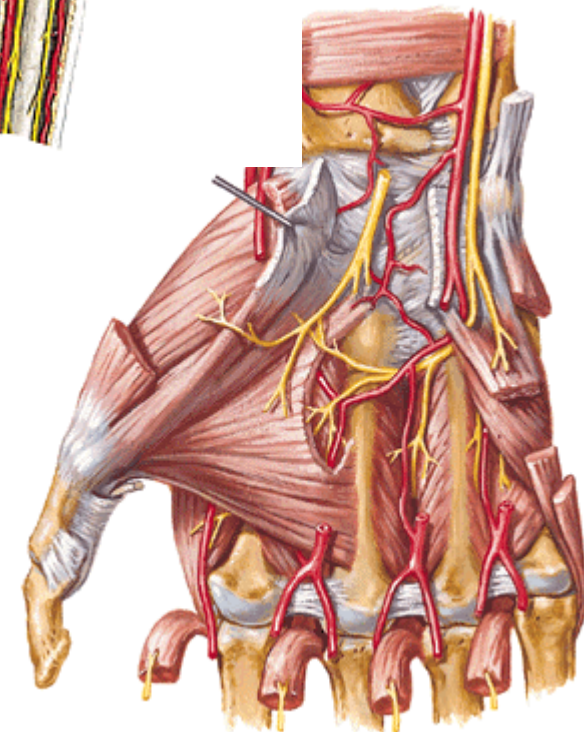
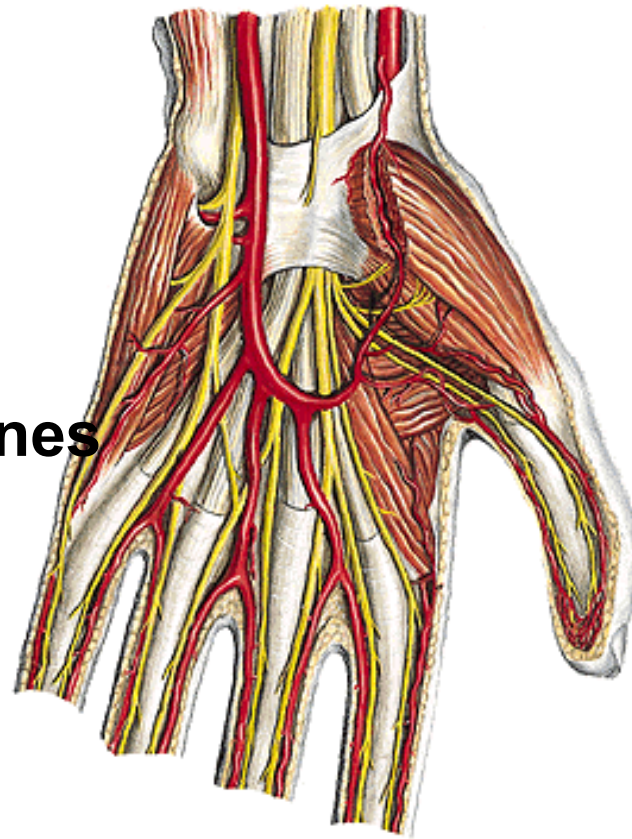
M. adductor pollicis

Hypothenarus:

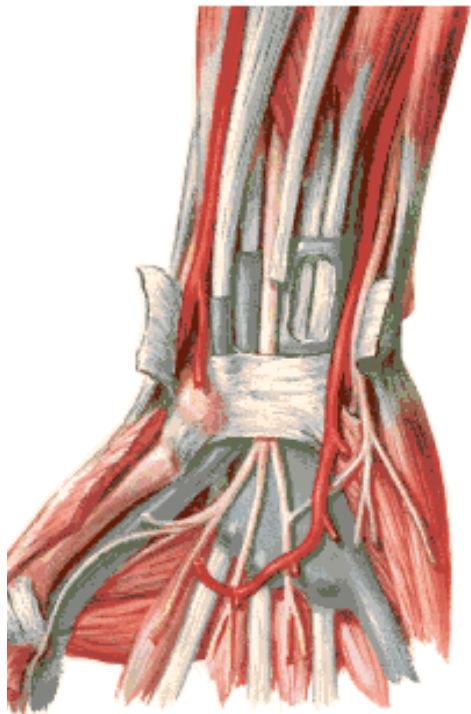
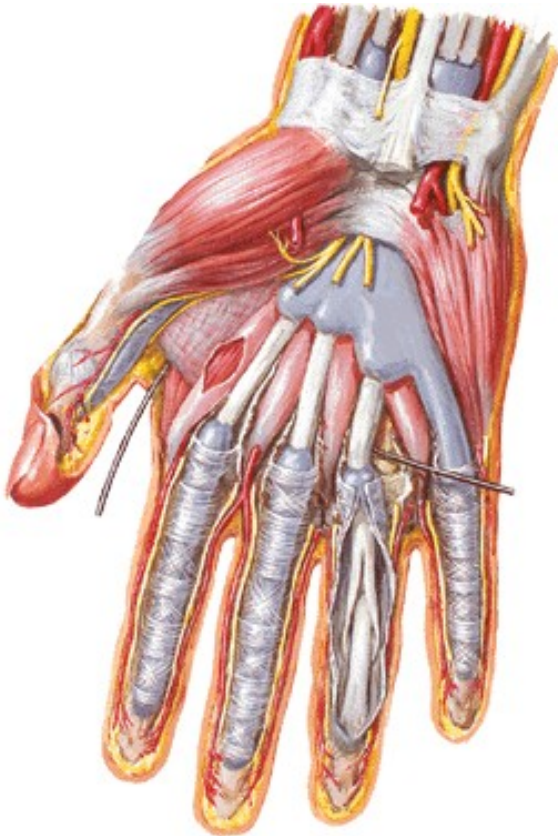
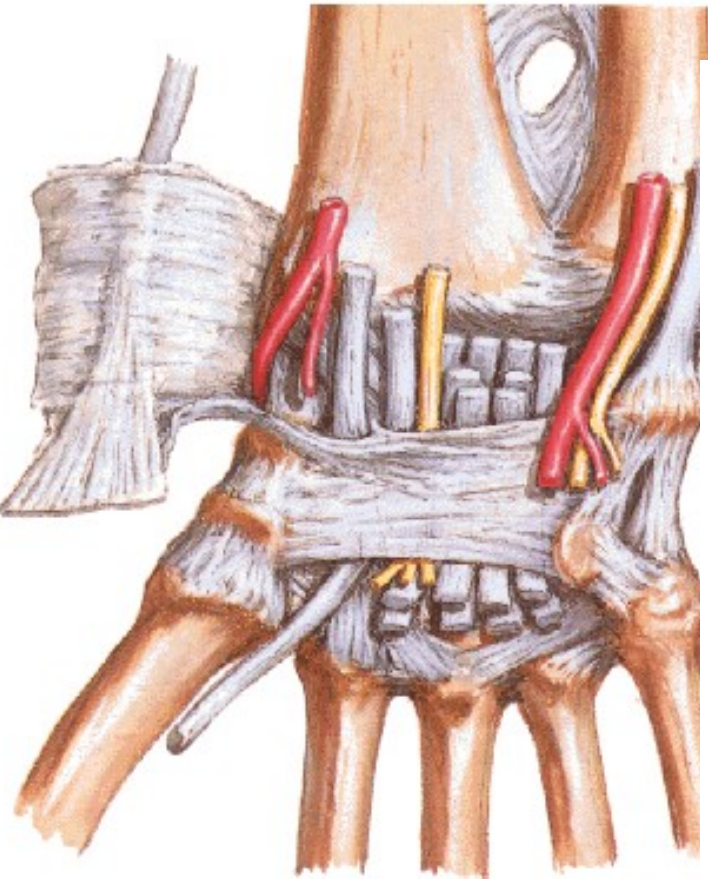
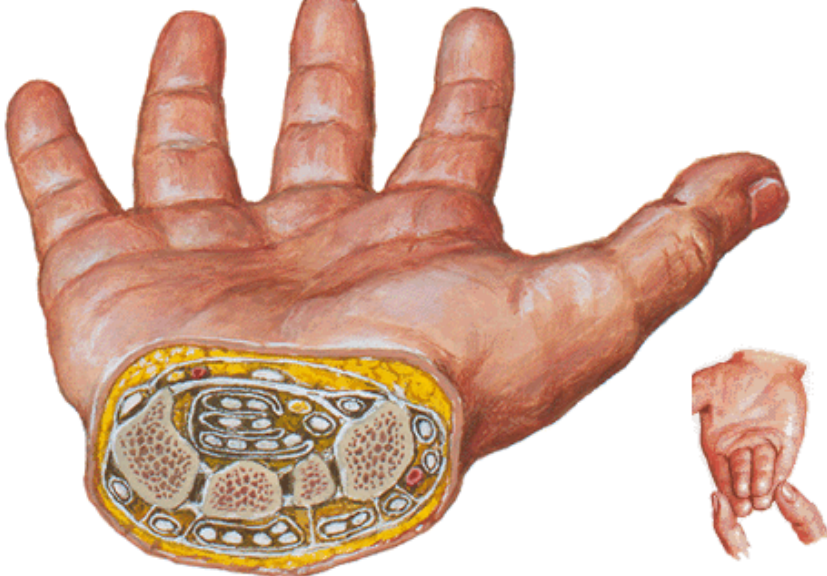M. abductor digiti minimi

M. flexor digiti minimi brevis

M. opponens digiti minimi



Canalis carpi

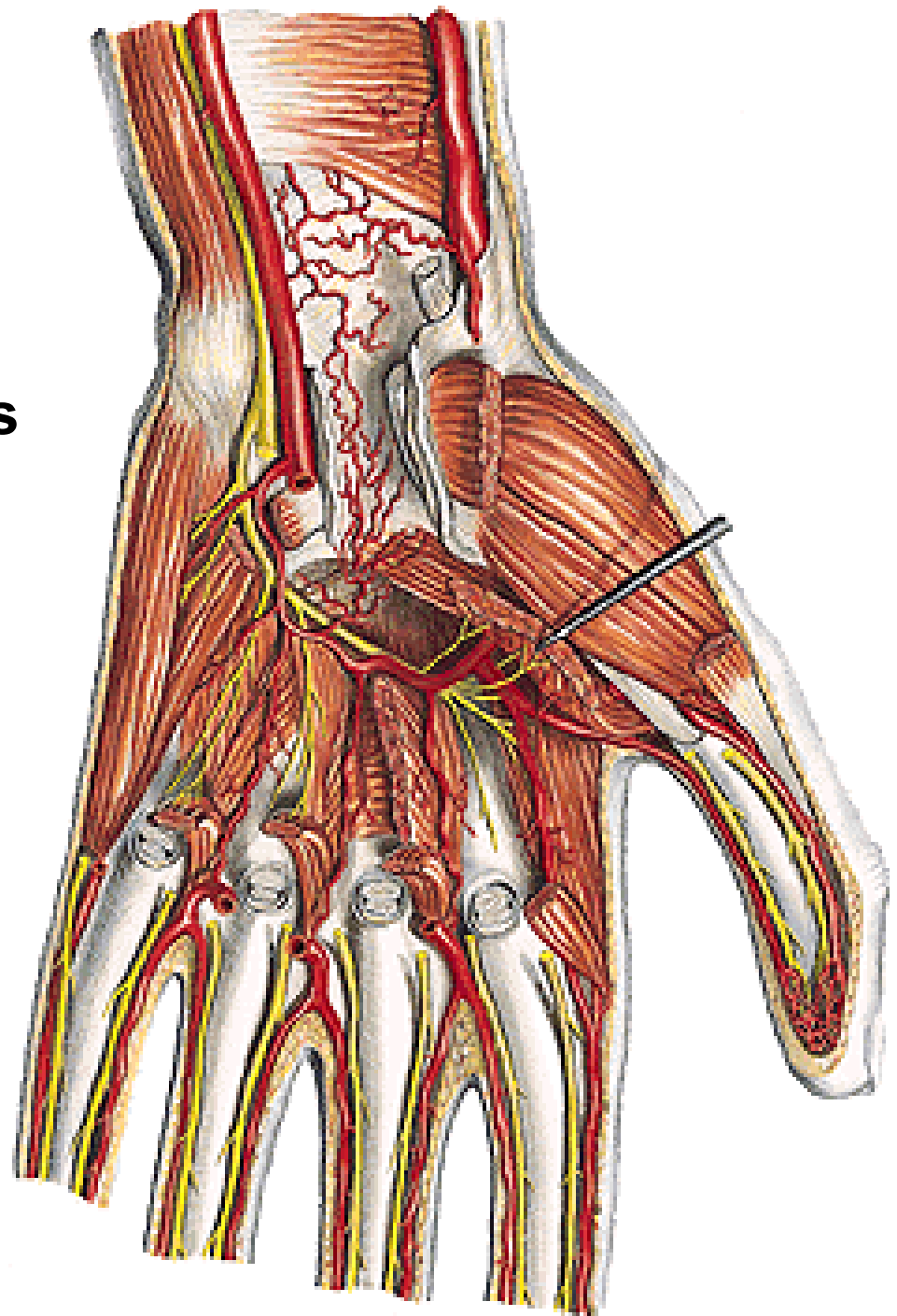


Rete carpi palmare

Arcus palmaris prof.

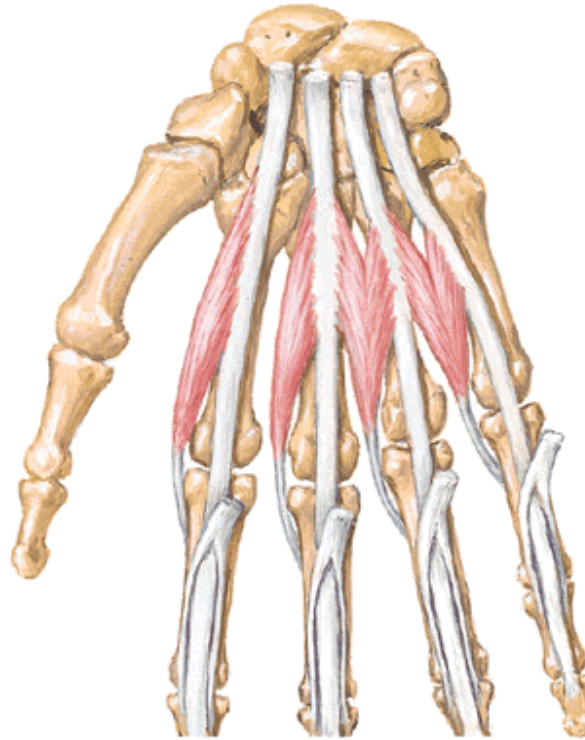
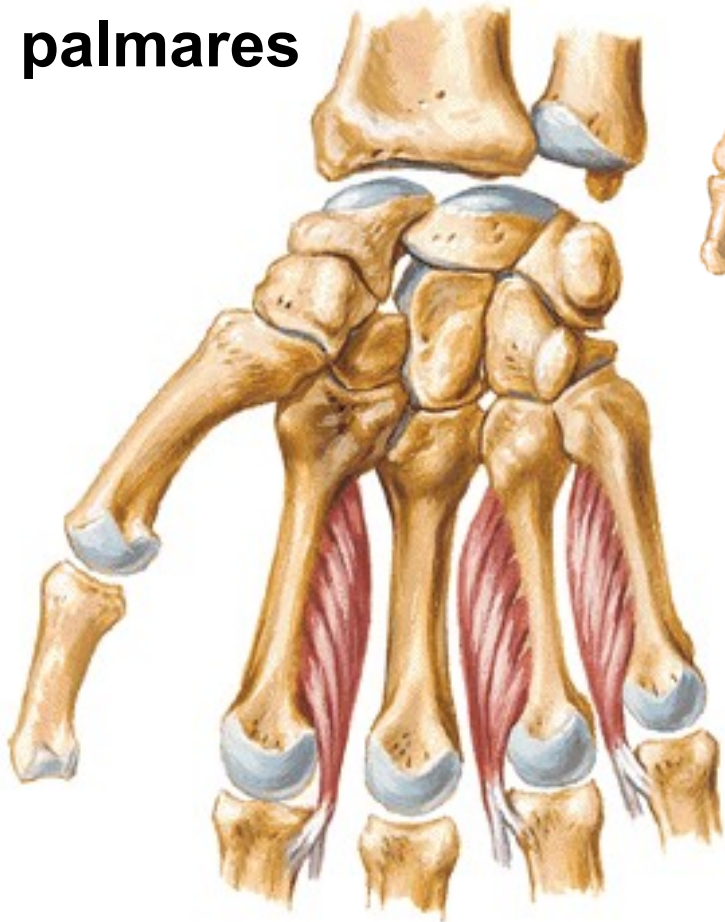
- aa. metacarpeae palmares

R. prof. n. ulnaris

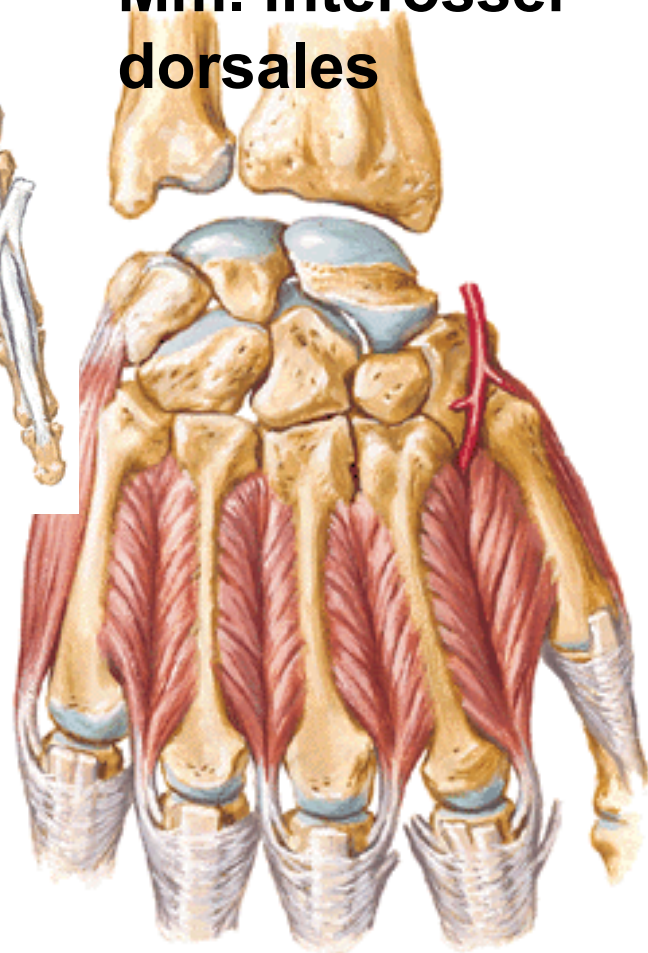


Mm. lumbricales

Mm. interossei palmares



Mm. interossei dorsales



Regio carpi dorsalis et dorsum manus

Rete venosum dorsale manus

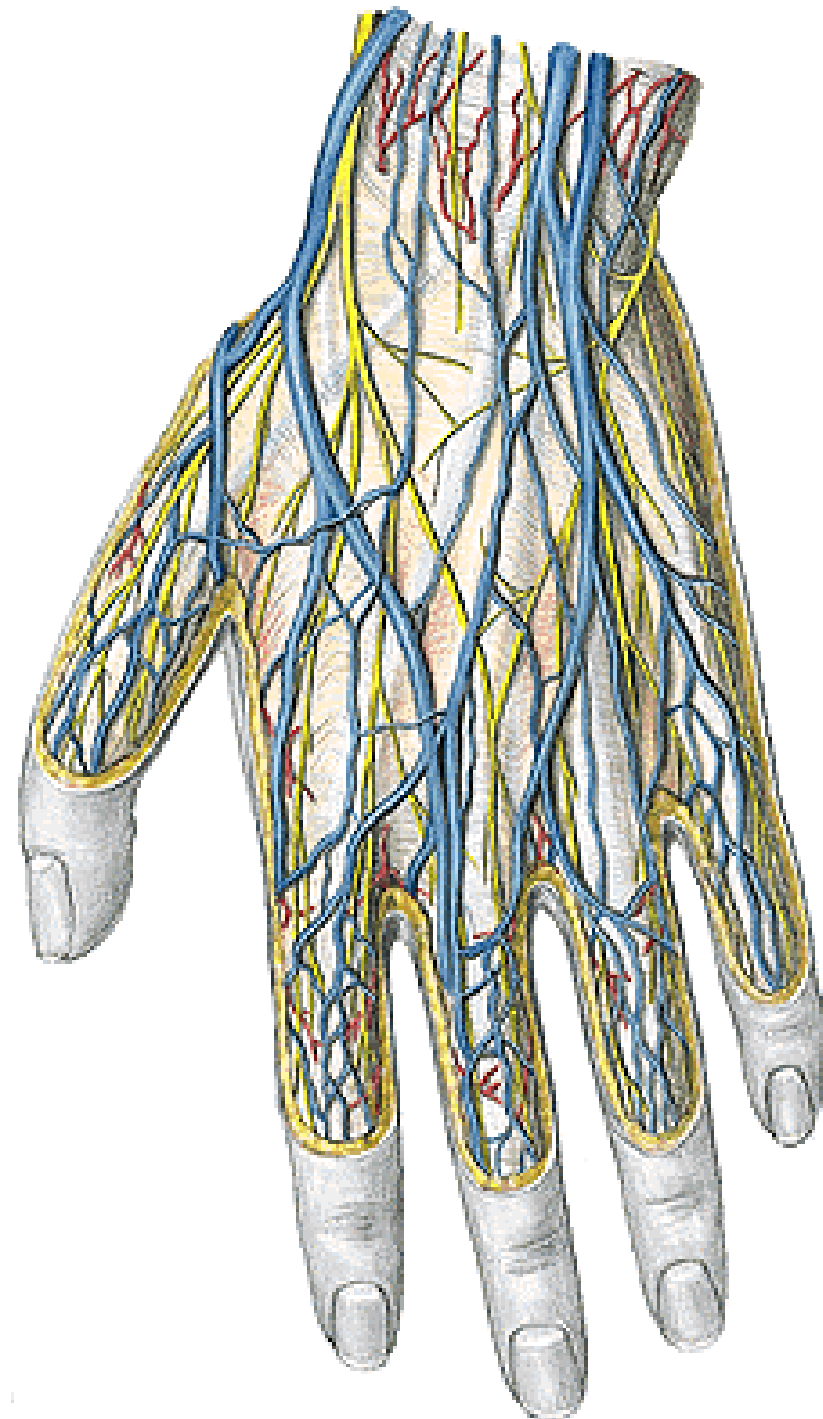
R. spf. n. radialis

- nn. digitales dorsales

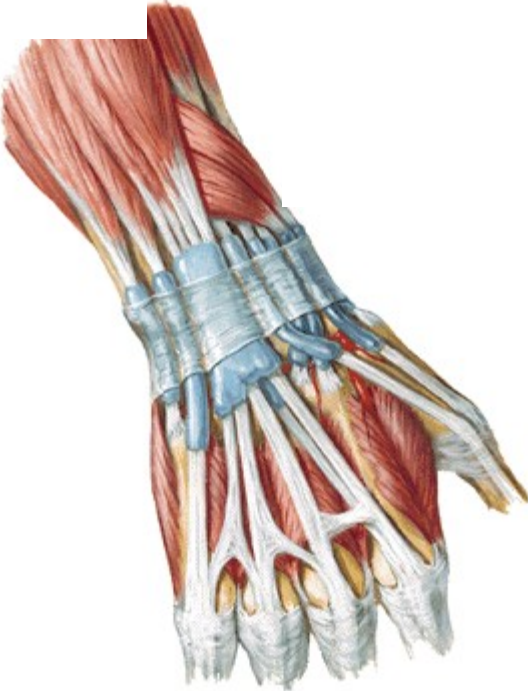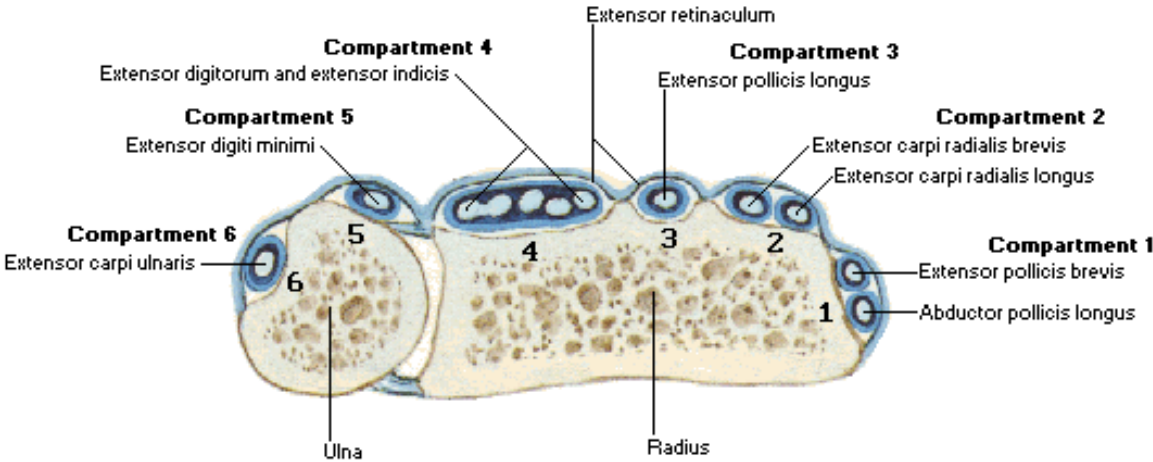
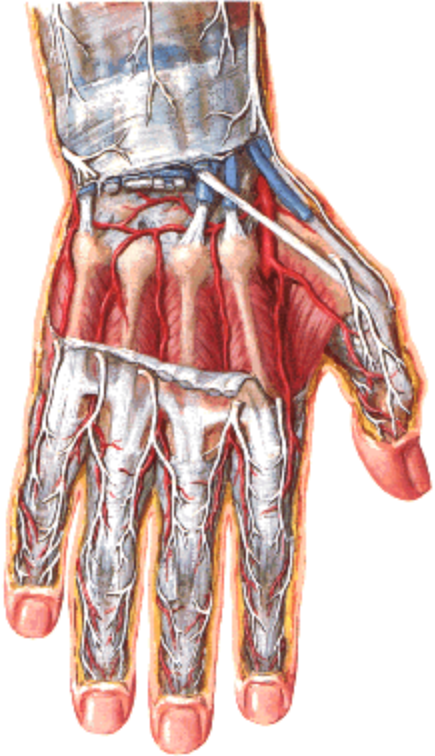
R. dorsalis n. ulnaris

- nn. digitales dorsales

Retinaculum extensorum



Extensor compartments

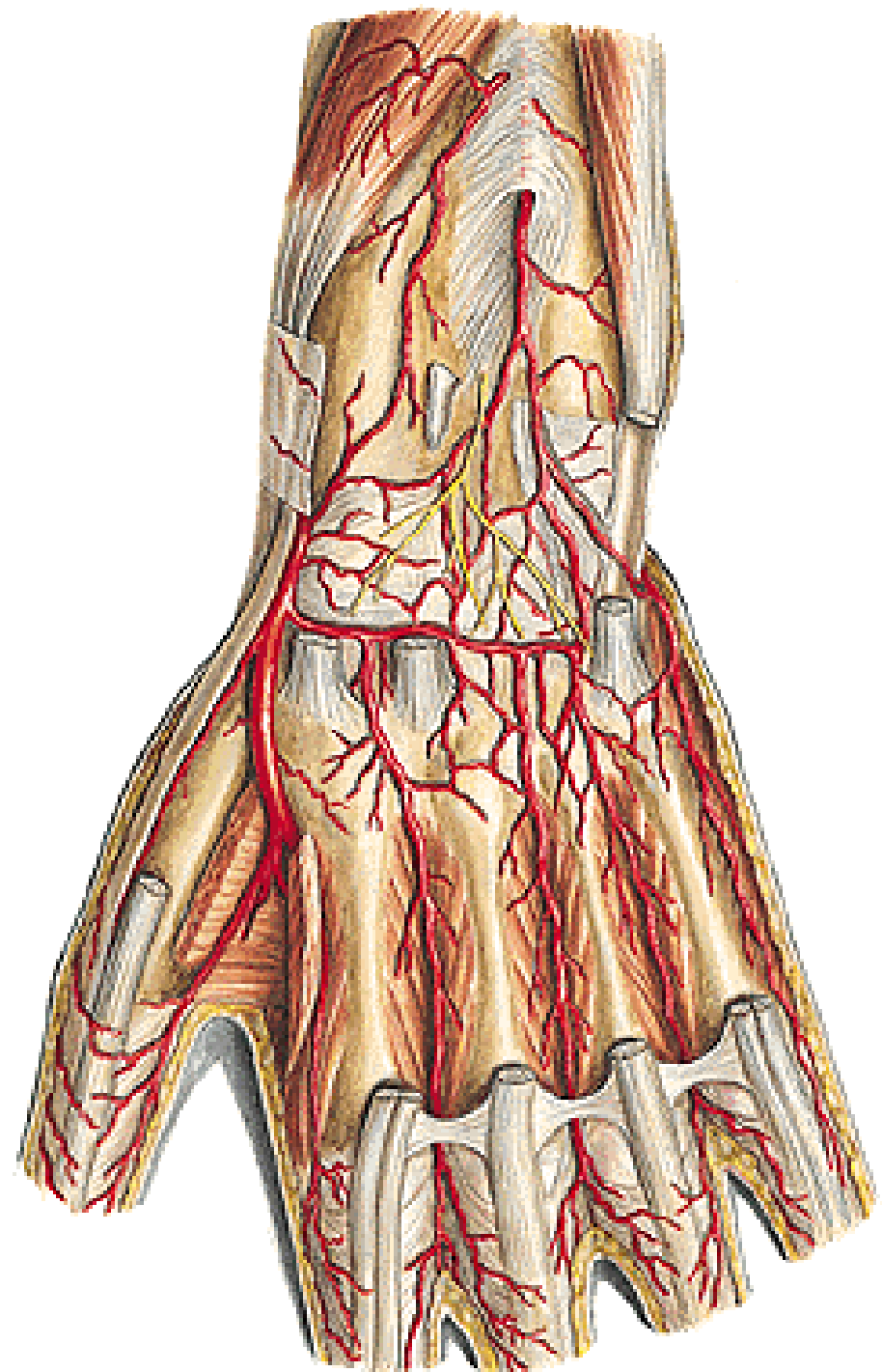


Rete carpi dorsale

Aa. metacarpeae dorsales

- aa. digitales dorsales

A. metacarpea dorsalis prima



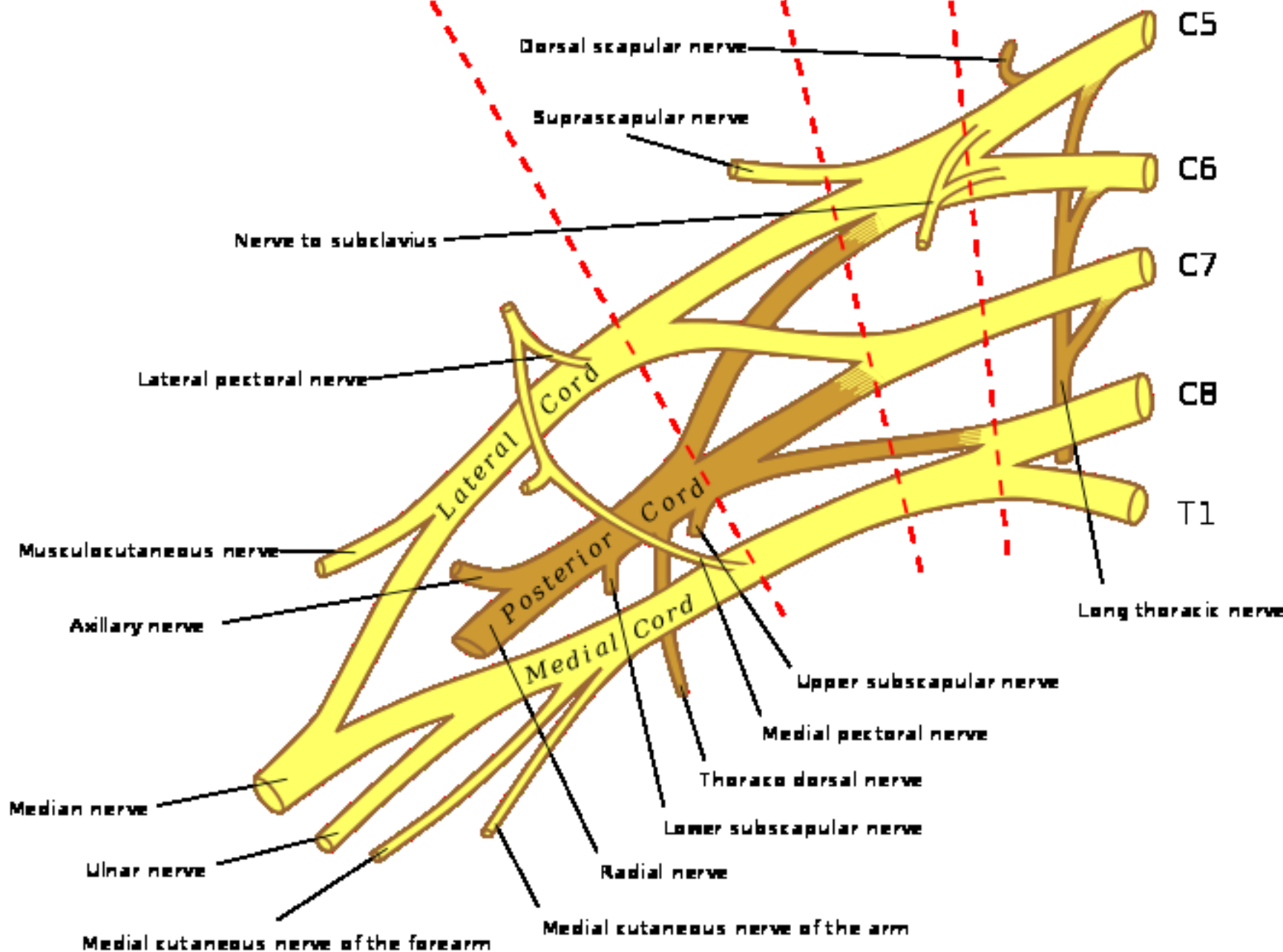
NERVES OF THE UPPER LIMB

Cords

Divisions

Trunks

Roots



C5

C6

C7

C8

T1

Dorsal scapular nerve

Suprascapular nerve

Nerve to subclavius

Lateral pectoral nerve

Musculocutaneous nerve

Axillary nerve

Median nerve

Ulnar nerve

Medial cutaneous nerve of the forearm

Lateral Cord

Posterior Cord

Medial Cord

Radial nerve

Medial cutaneous nerve of the arm

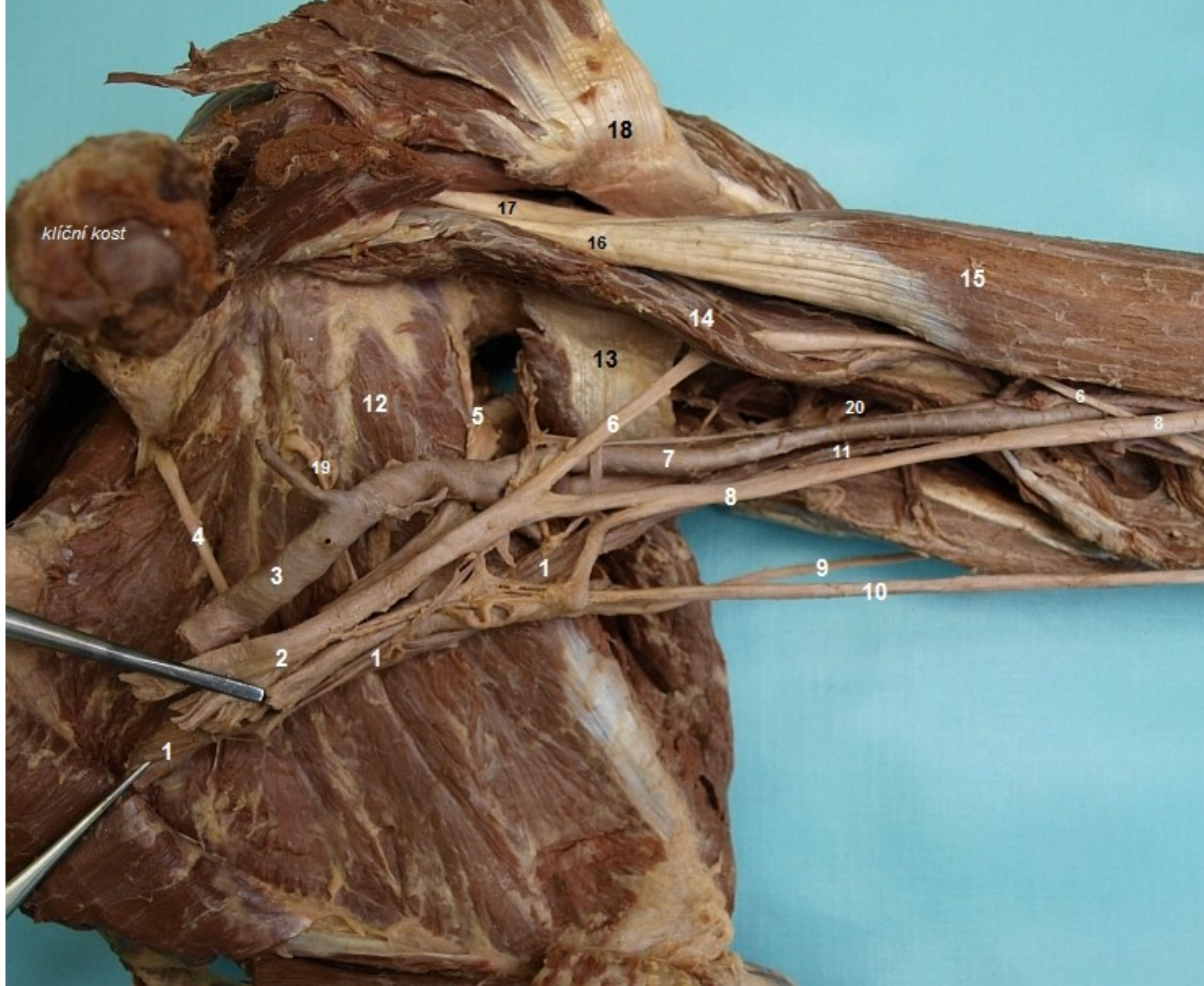Upper subscapular nerve

Medial pectoral nerve

Thoraco dorsal nerve

Lower subscapular nerve

Long thoracic nerve



klíční kost

18

17

16

15

14

13

12

5

6

20

6

8

19

7

11

4

8

3

1

9

10

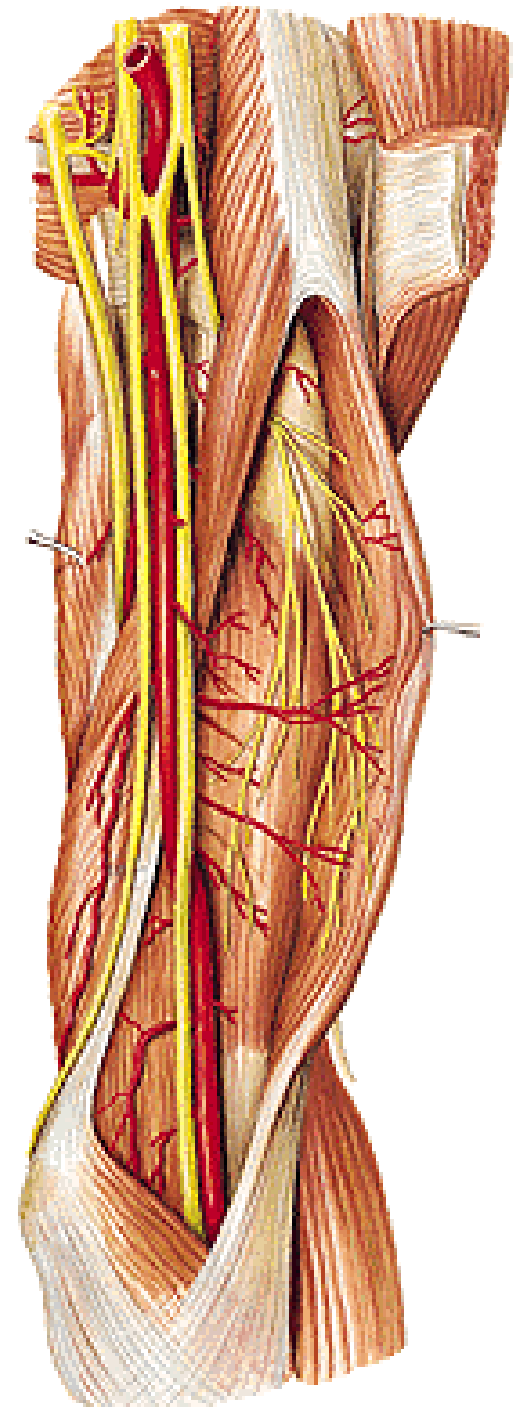
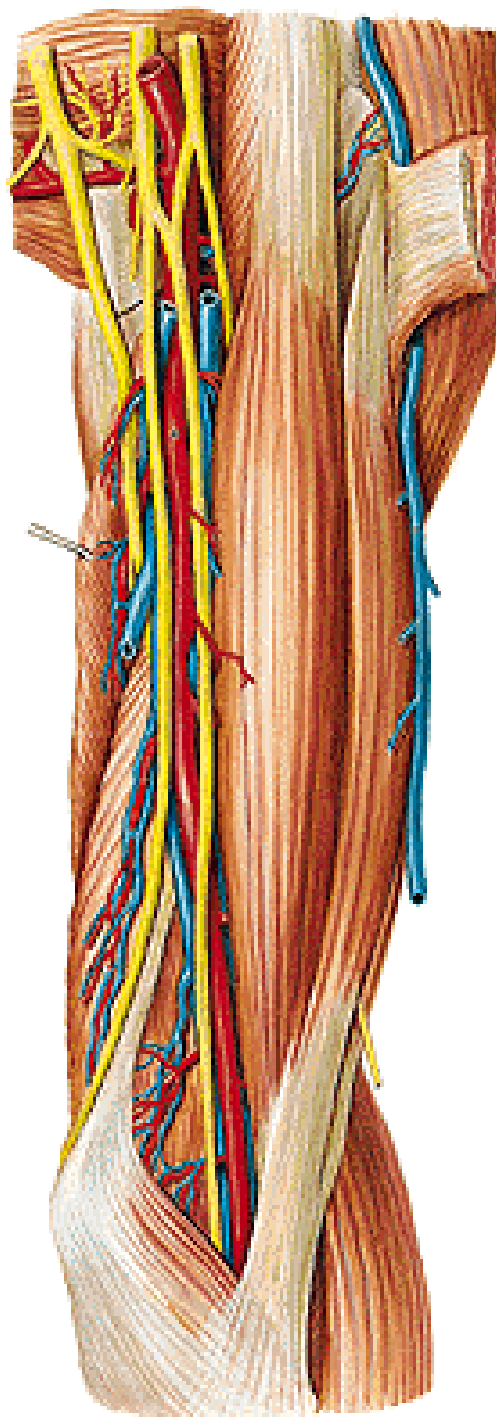
2

1

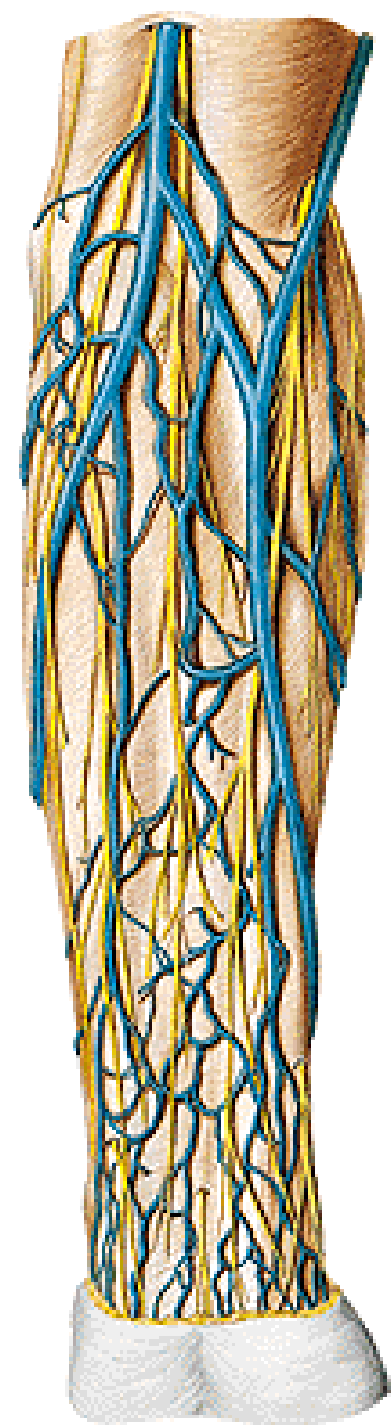
1

N. MUSCULOCUTANEUS

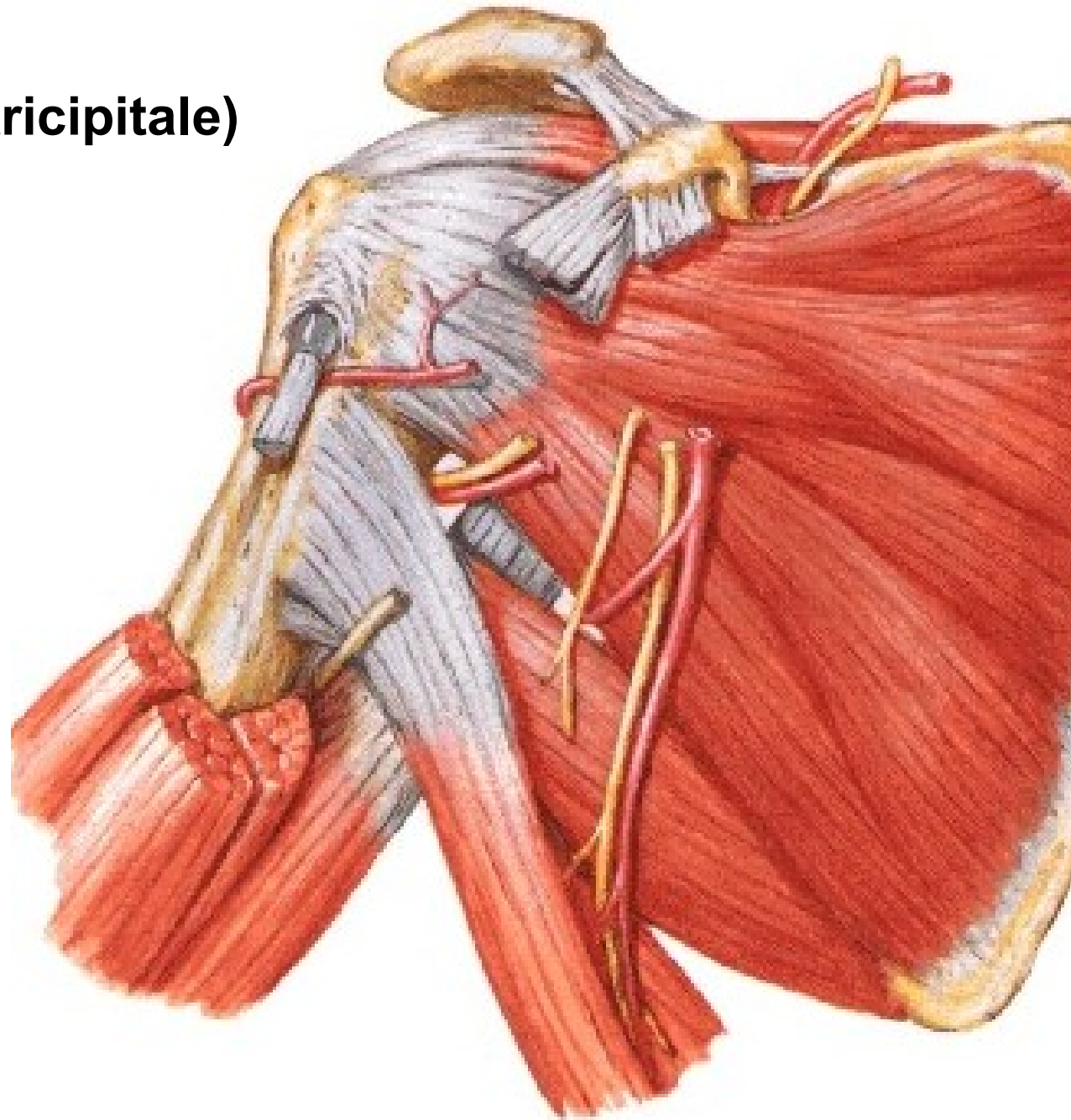
- m. coracobrachialis
- m. biceps brachii
- m. brachialis



N. cutaneus antebrachii lat.



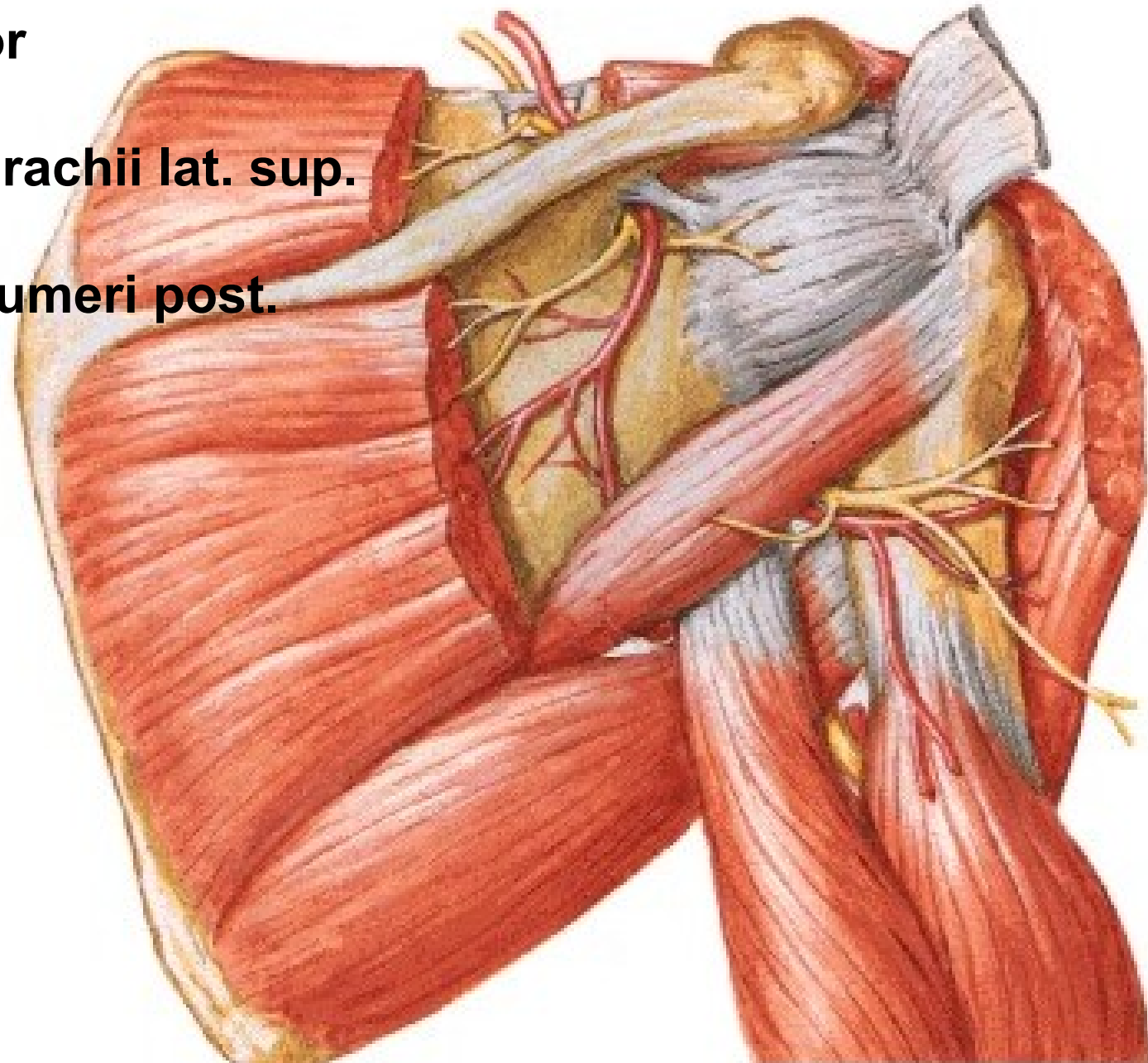
N. AXILLARIS
(foramen humerotricipitale)



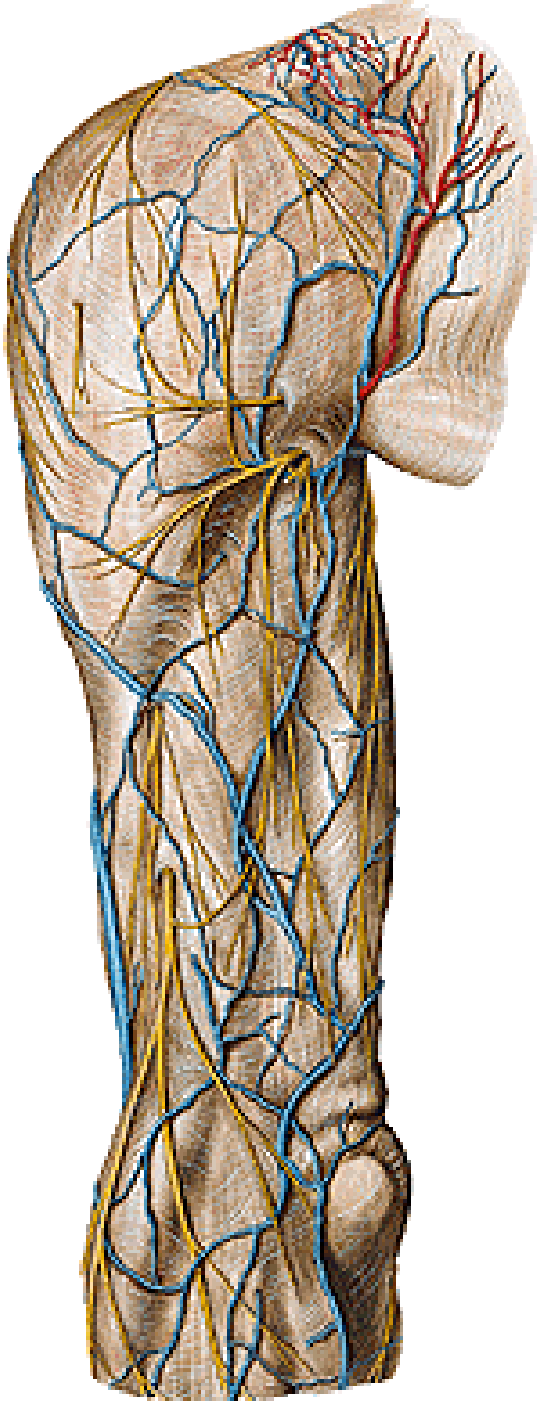
N. AXILLARIS

- m. deltoideus
- m. teres minor
- art. humeri
- n. cutaneus brachii lat. sup.

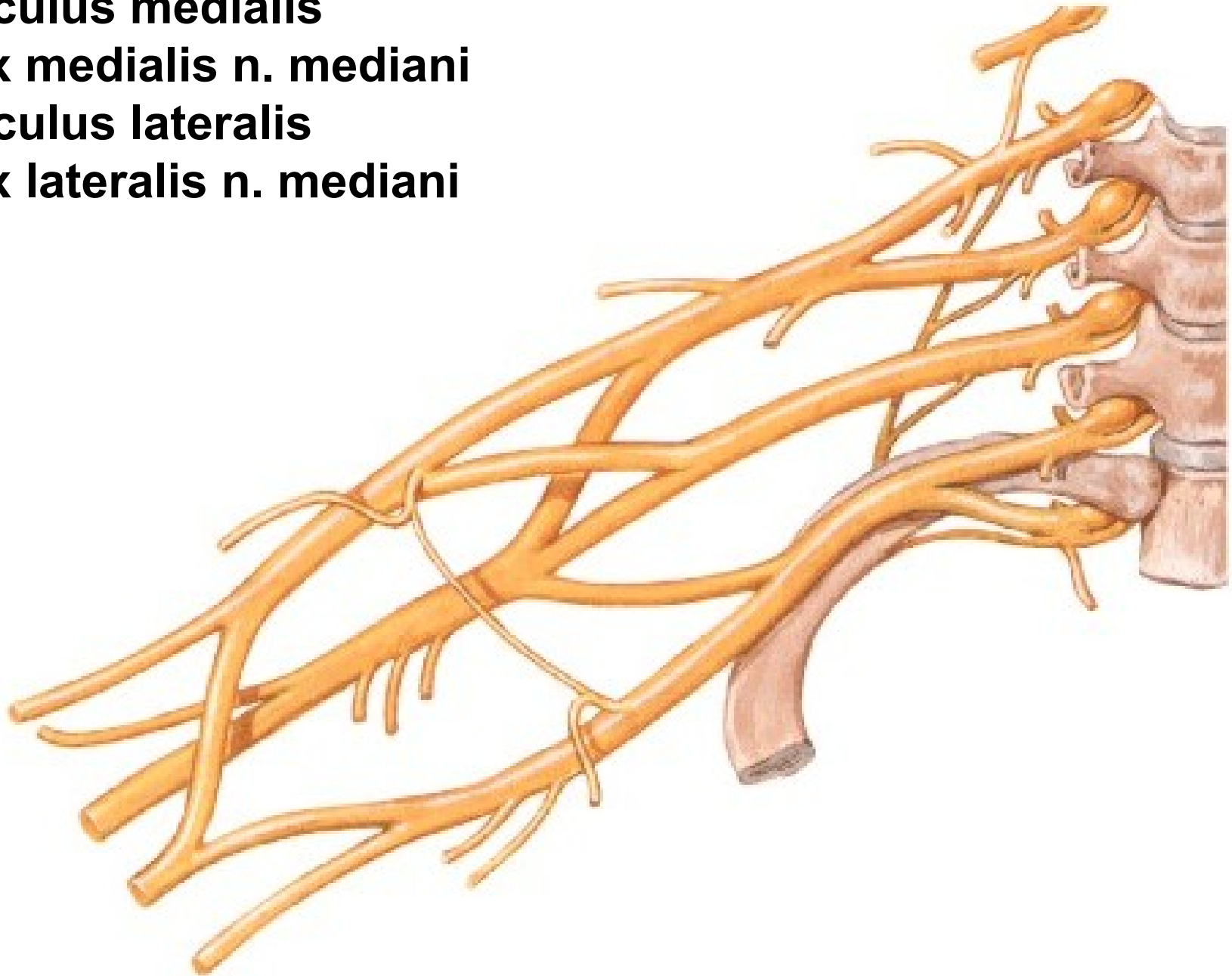
A. circumflexa humeri post.



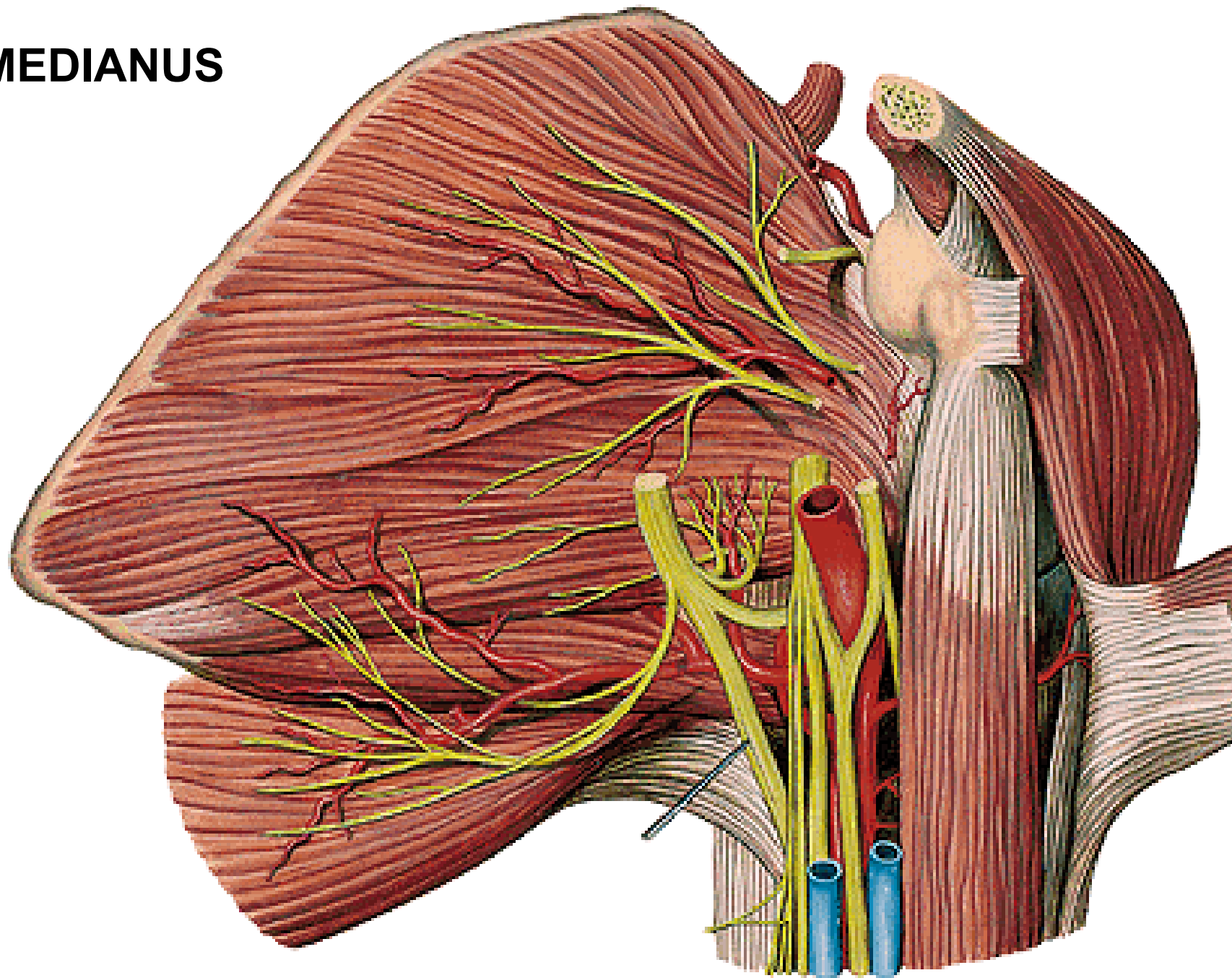
N. cutaneus brachii lat. sup.



Fasciculus medialis
- radix medialis n. mediani
Fasciculus lateralis
- radix lateralis n. mediani

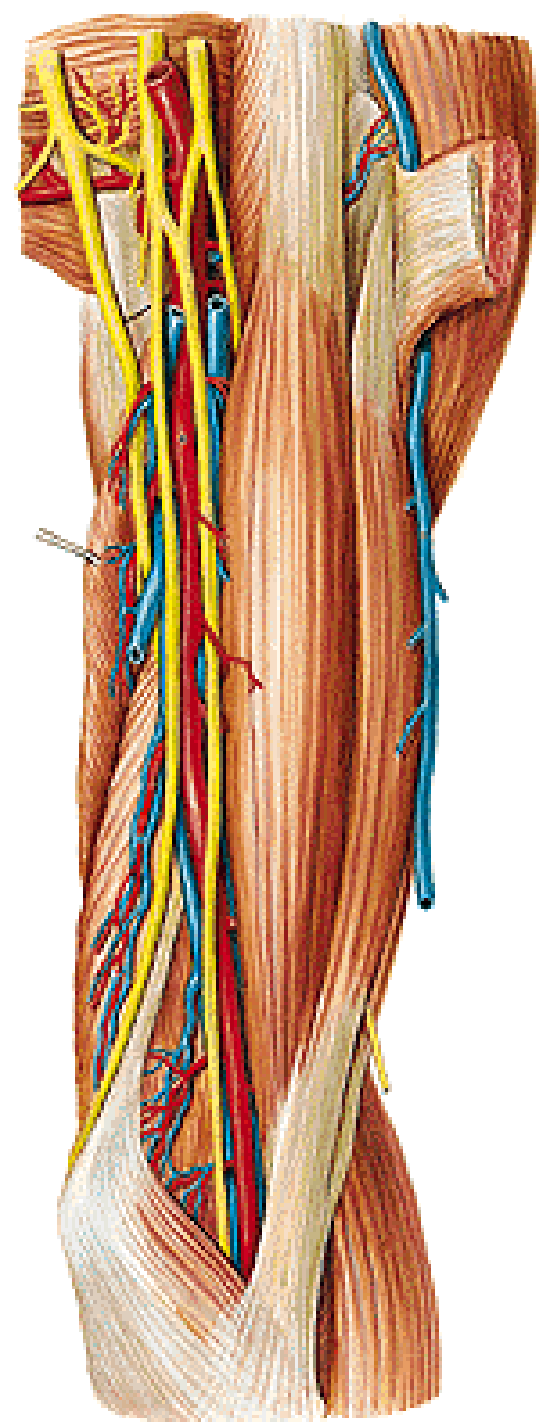


N. MEDIANUS

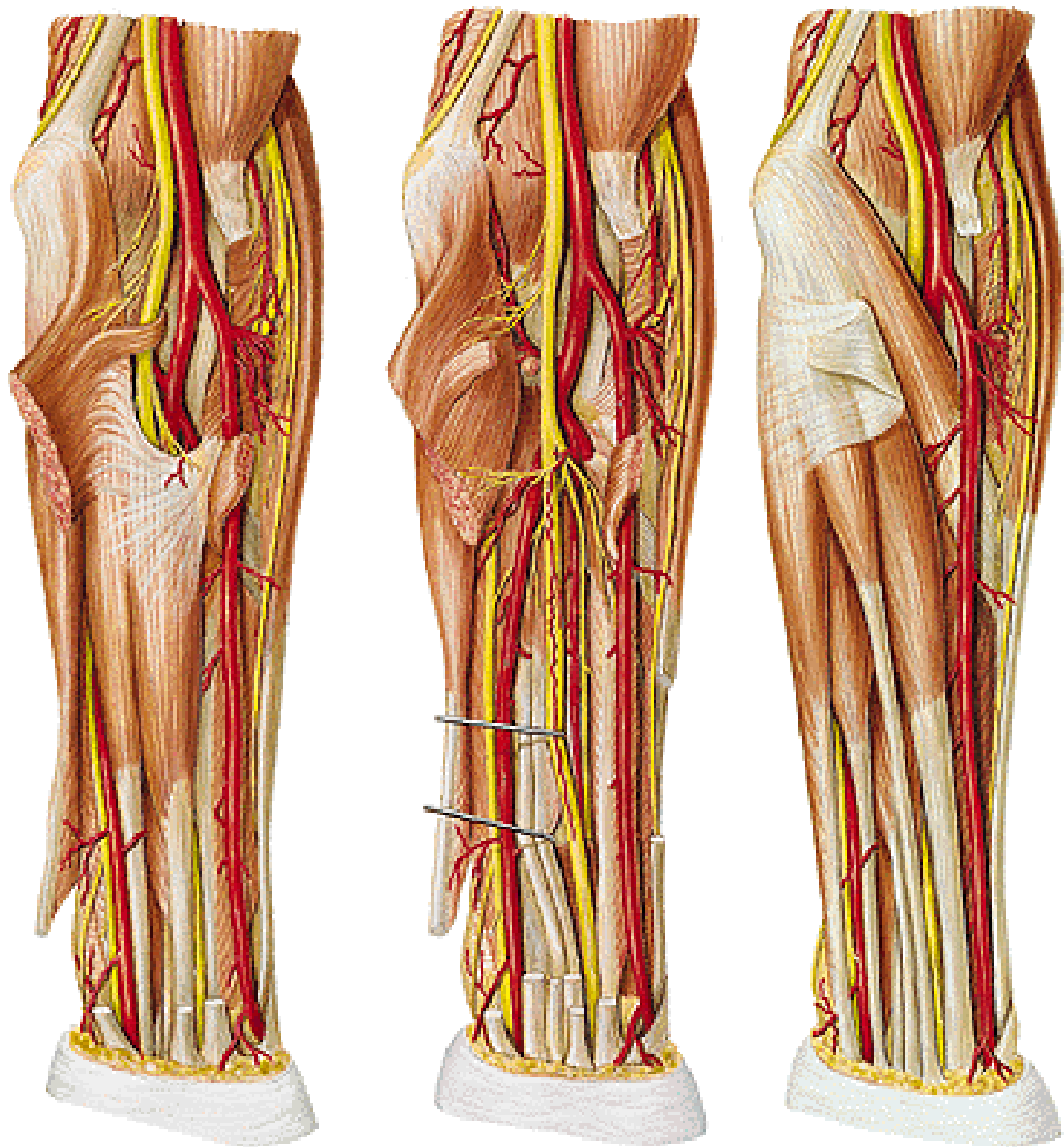


N. MEDIANUS

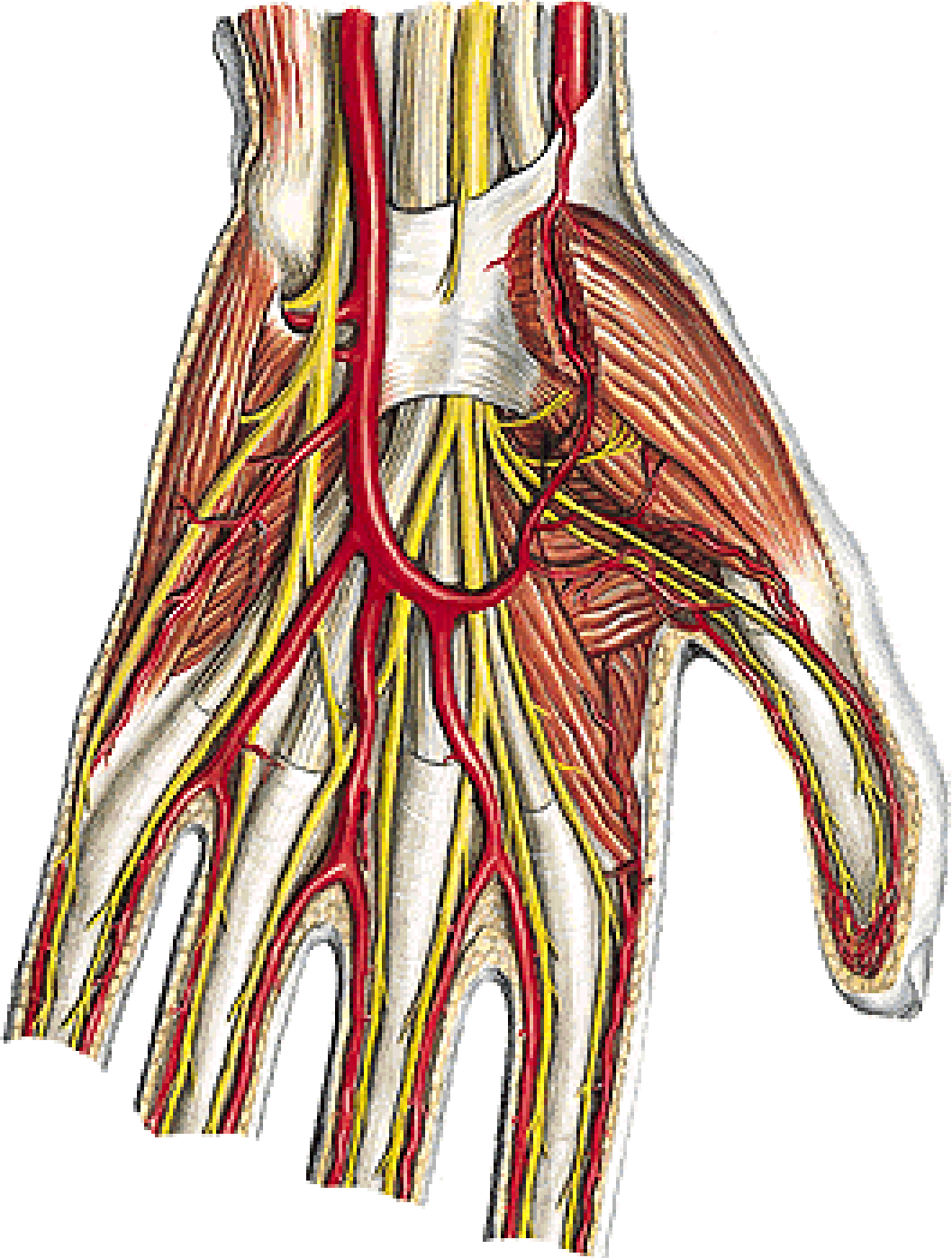
(Sulcus bicipitalis medialis)



N. MEDIANUS

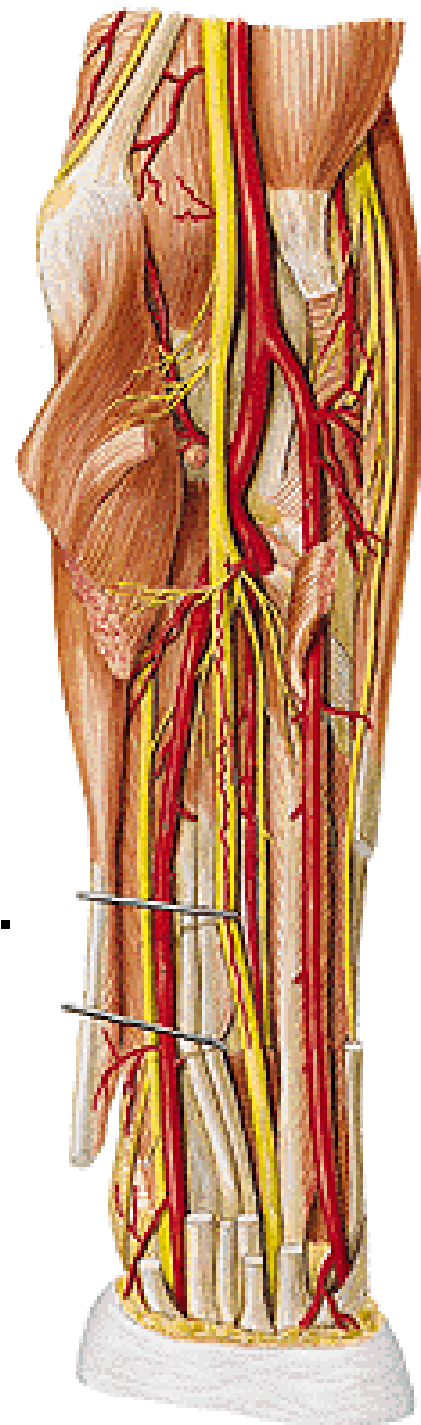


N. MEDIANUS



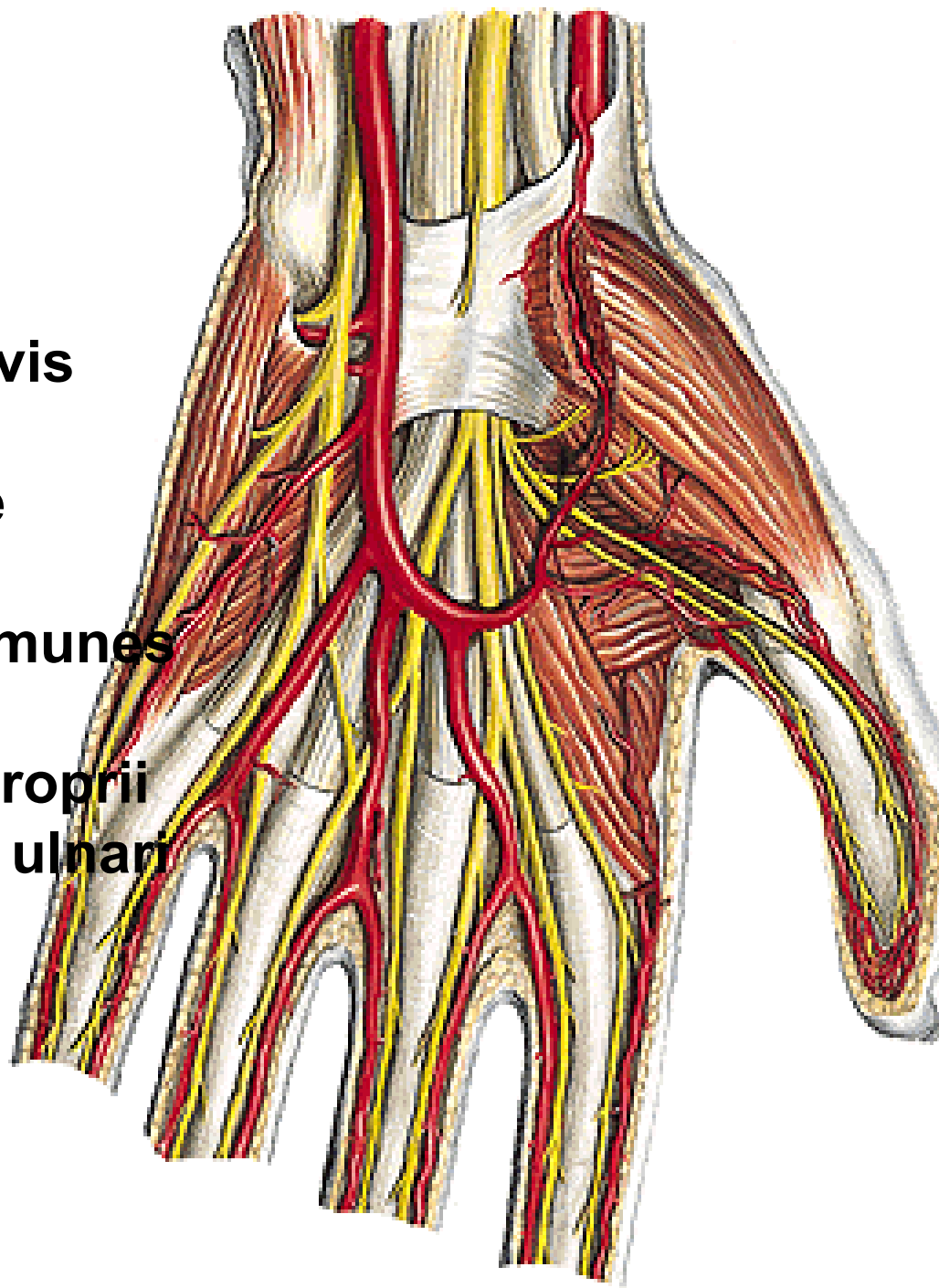
N. MEDIANUS

- rr. articulares
- rr. musculares
 - m. pronator teres
 - m. flexor carpi radialis
 - m. palmaris longus
 - m. flexor digitorum spf.
- n. interosseus antebrachii ant.
 - m. flexor pollicis longus
 - radial half of m. flexor dig. prof.
 - m. pronator quadratus
- r. palmaris

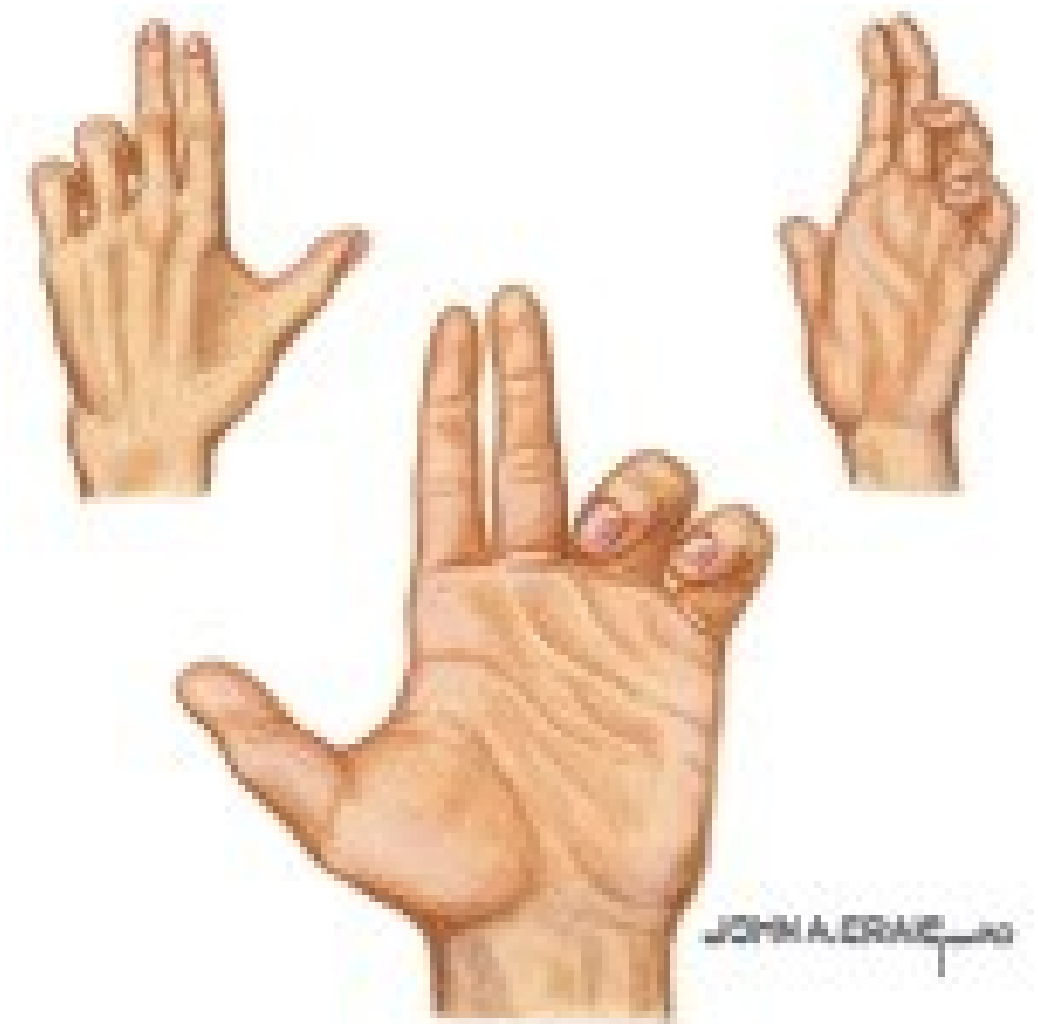

N. MEDIANUS

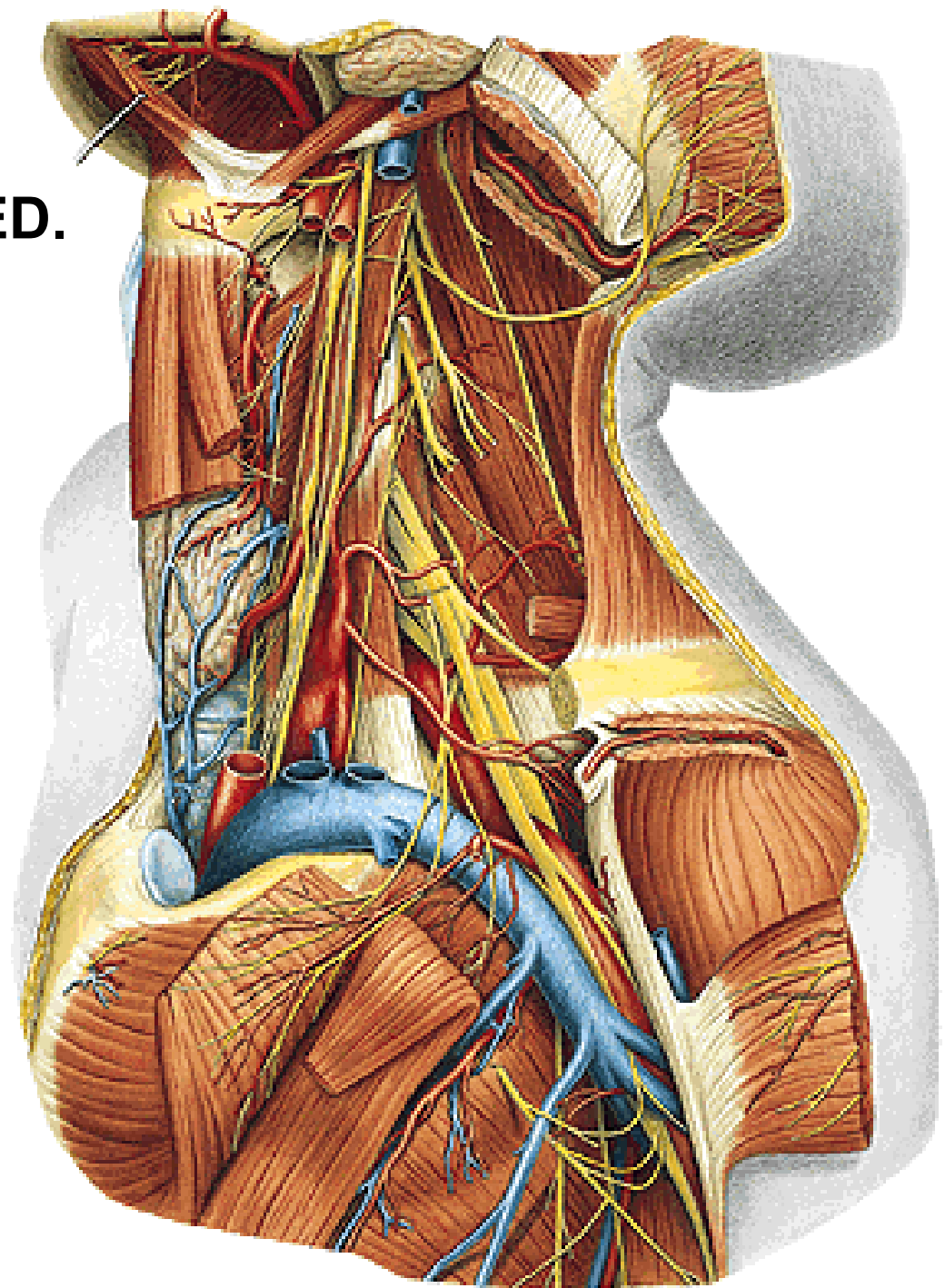
- r. thenaris
 - m. abductor pollicis brevis
 - m. flexor pollicis brevis
 - caput superficiale
 - m. opponens pollicis
- nn. digitales palmares communes
 - mm. lumbricales (I, II)
 - nn. digitales palmares proprii
- r. communicans cum nervo ulnari



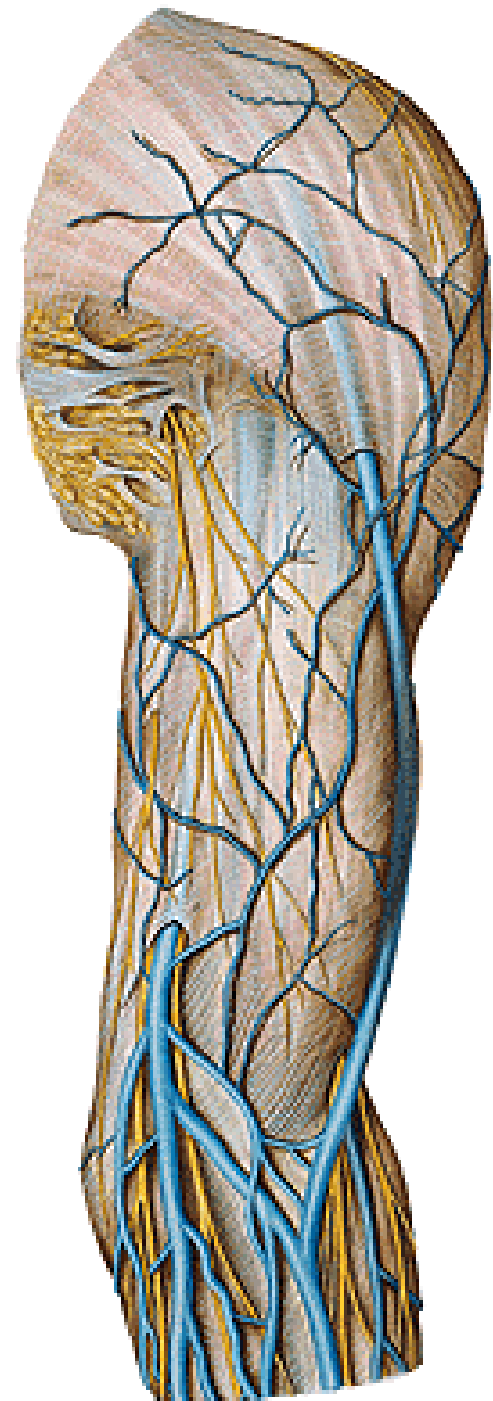
Hand of Benediction



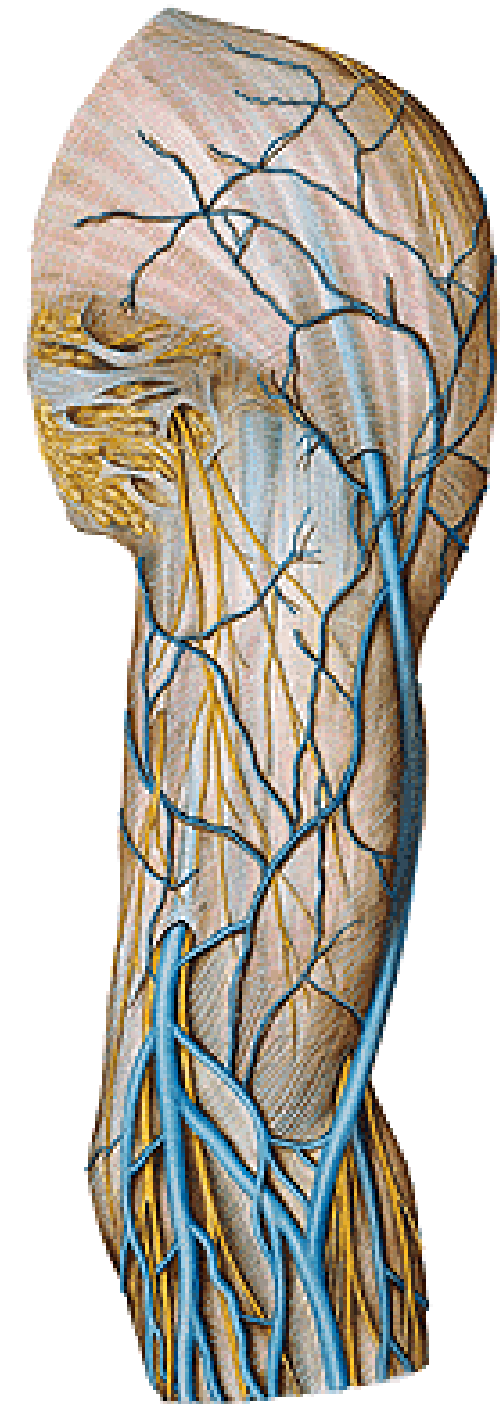
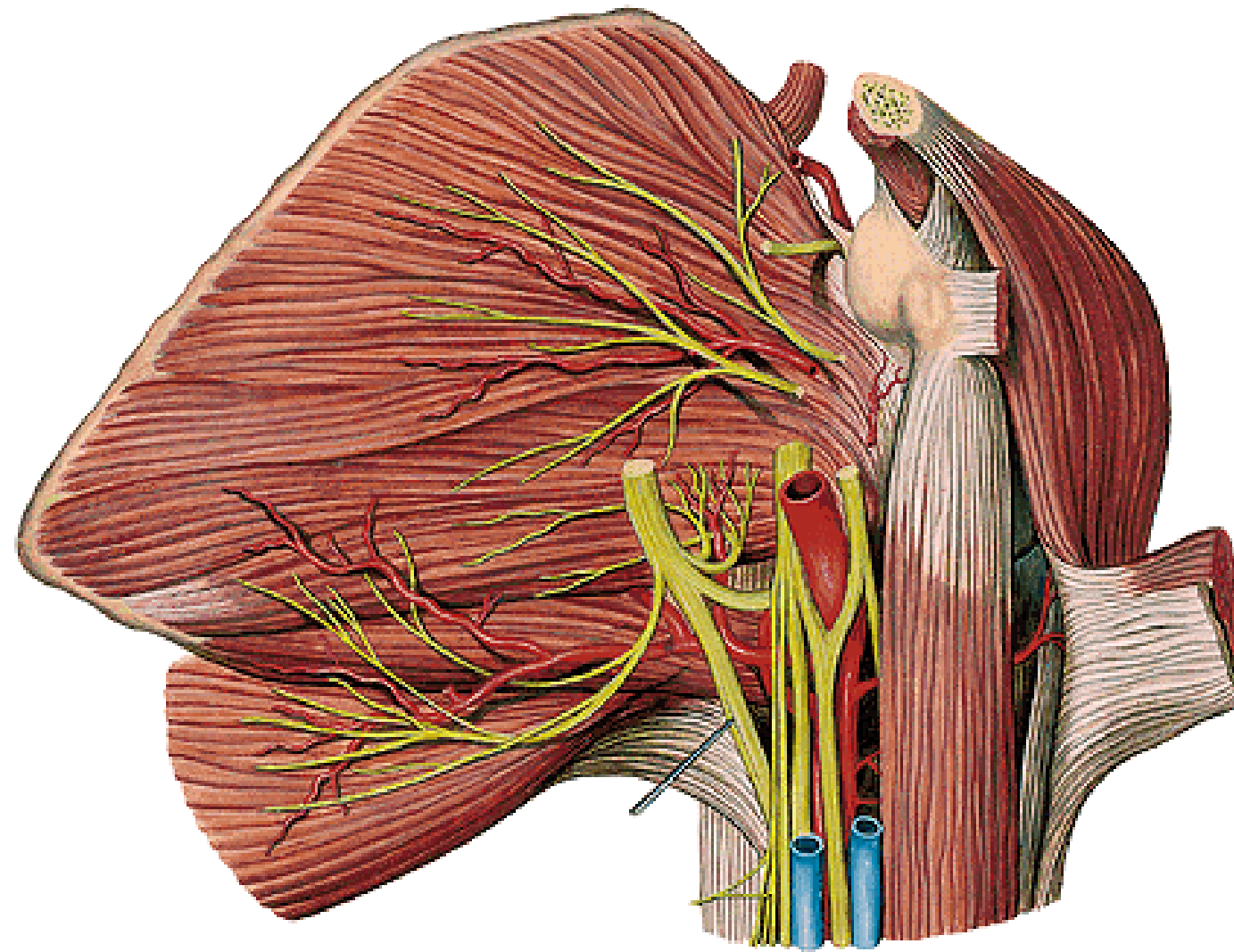
N. CUTANEUS BRACHII MED.
(nn. intercostobrachiales)



N. CUTANEUS BRACHII MED.




N. CUTANEUS ANTEBRACHII MED.



N. CUTANEUS ANTEBRACHII MED.

- r. anterior**
- r. posterior (ulnaris)**

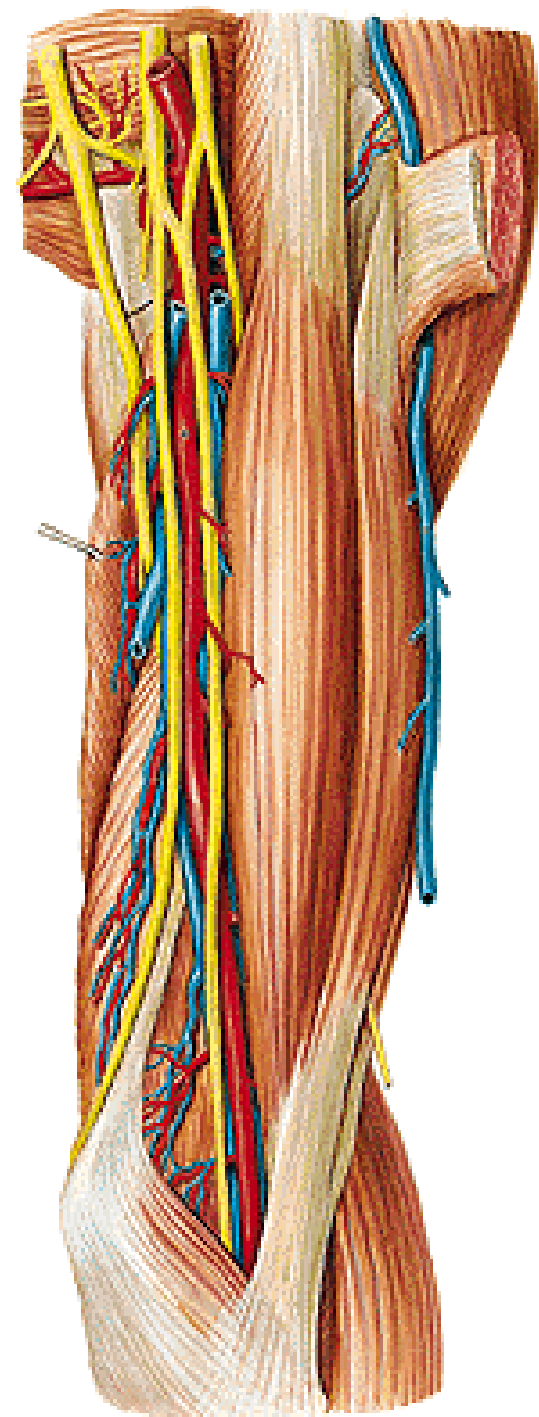
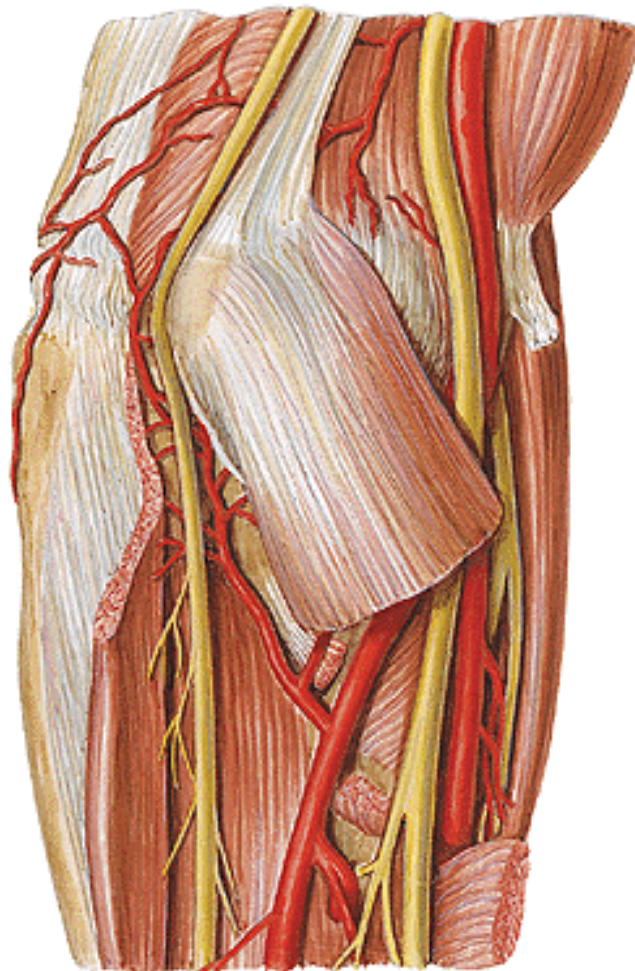


N. ULNARIS

sulcus bicipitalis medialis

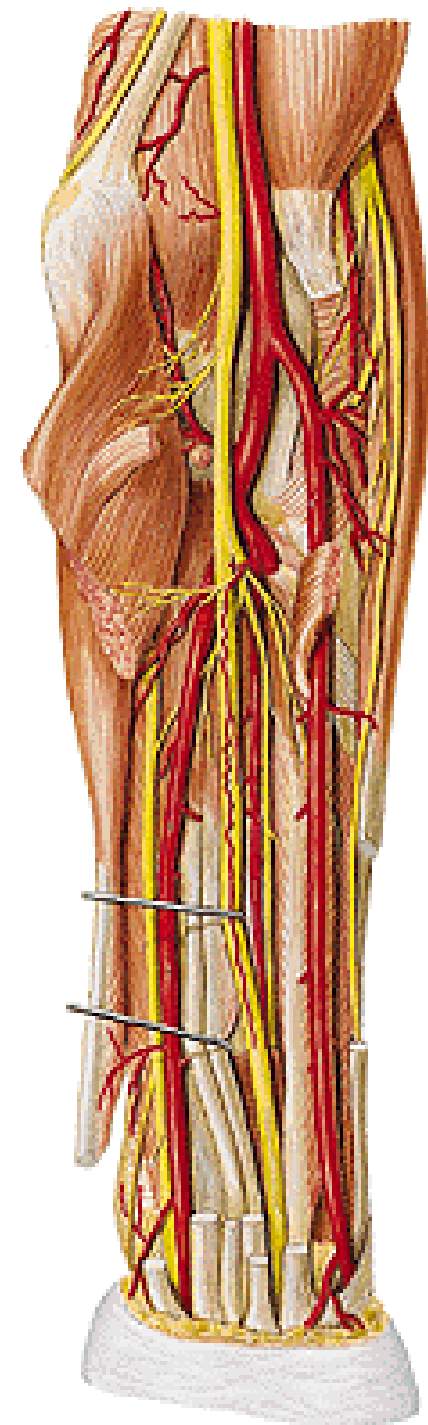
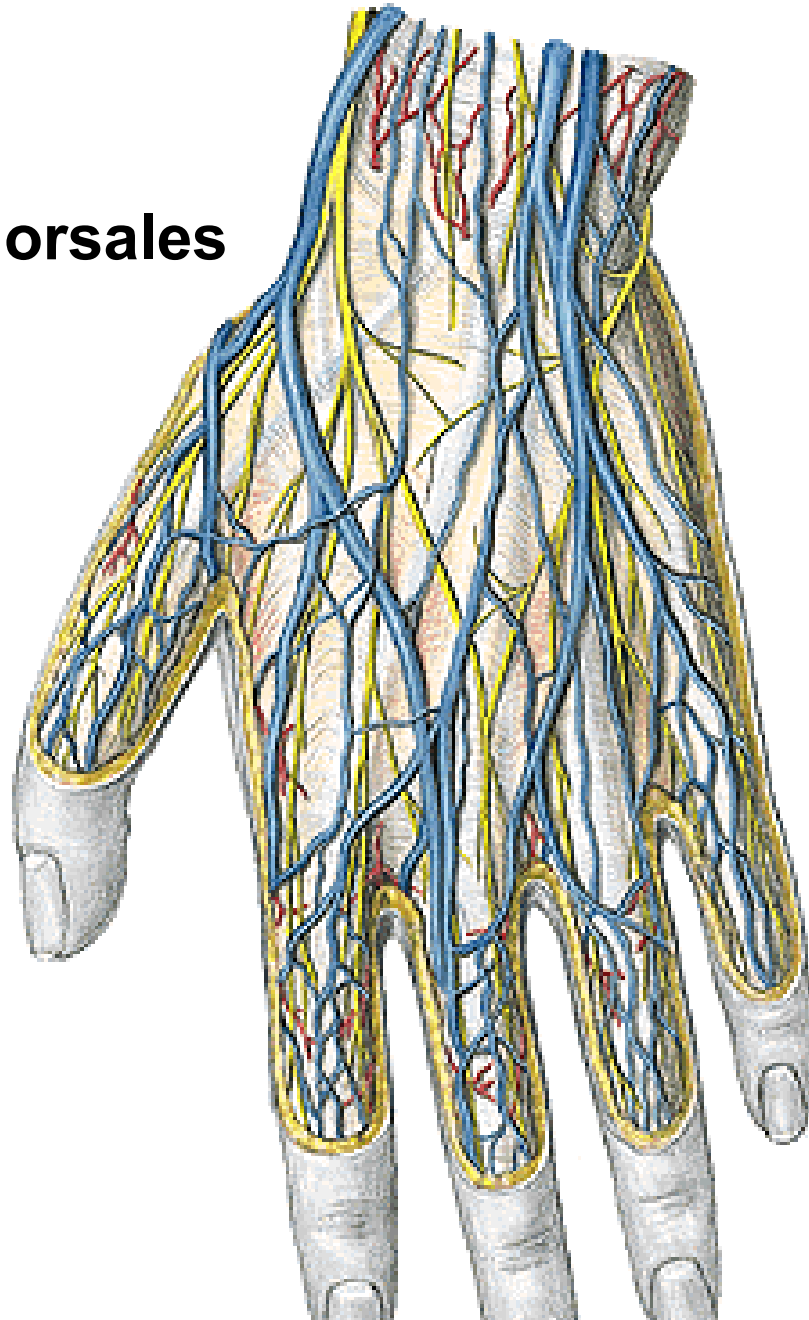
septum intermusculare brachii mediale

sulcus n. ulnaris



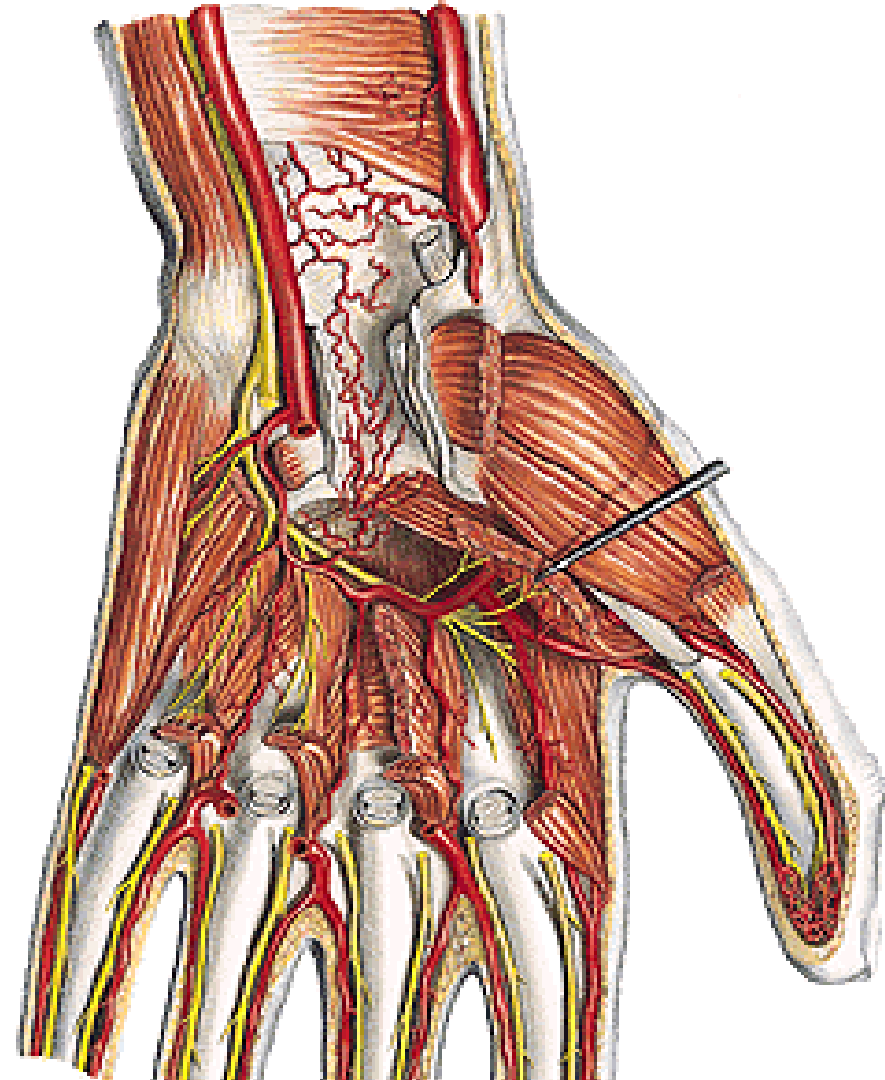
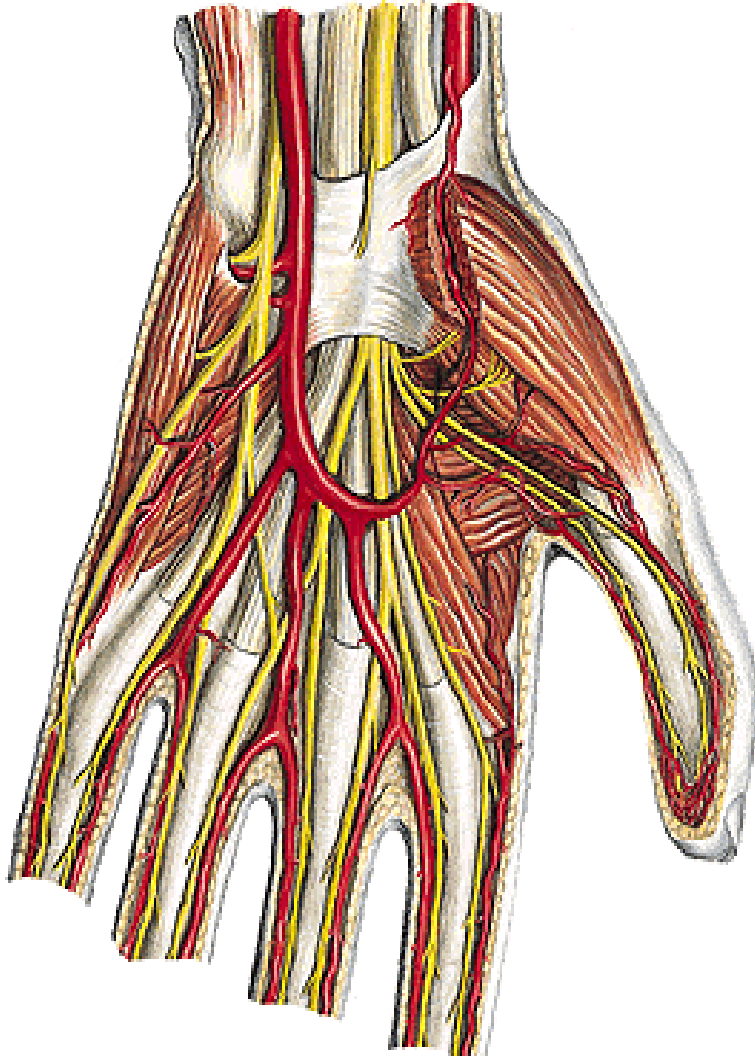
N. ULNARIS

- rr. articulares
- rr. musculares
- r. dorsalis
- nn. digitales dorsales

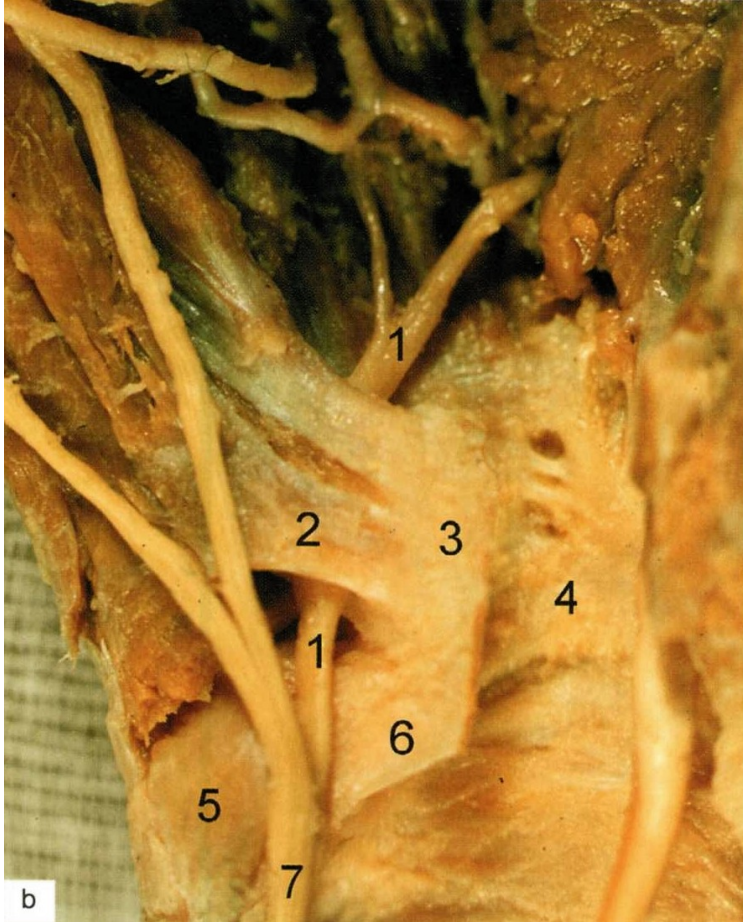


N. ULNARIS

- r. palmaris
- r. superficialis - nn. dig. palmares comm. et proprii
- r. profundus - rr. musculares



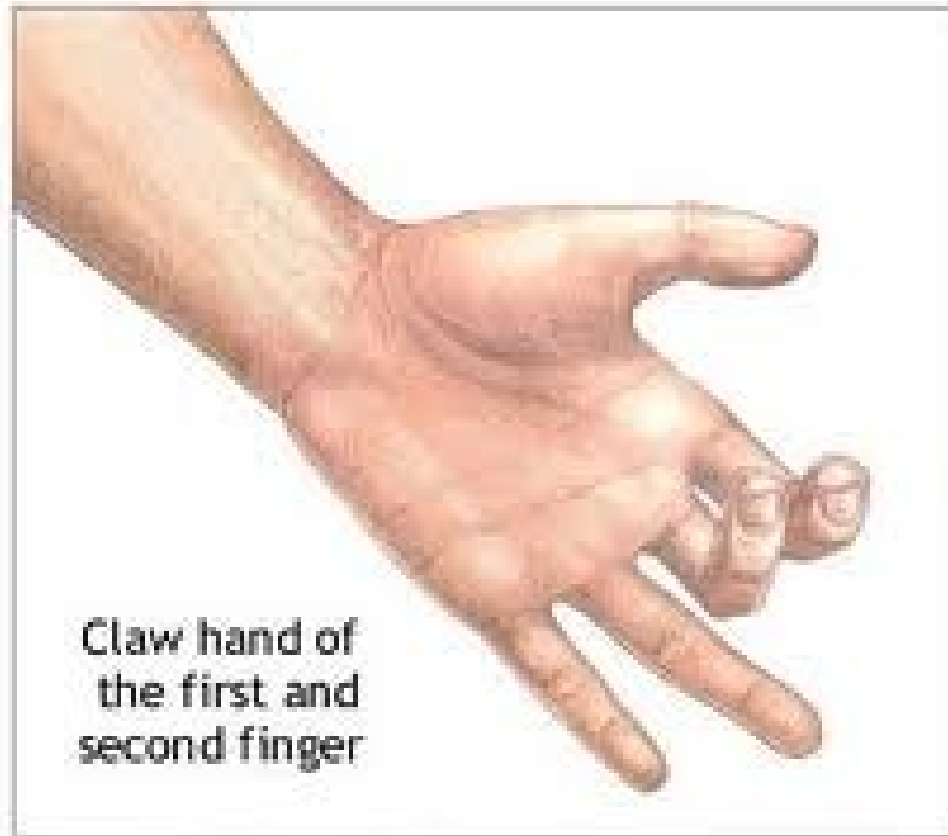Ulnar (Guyon) canal



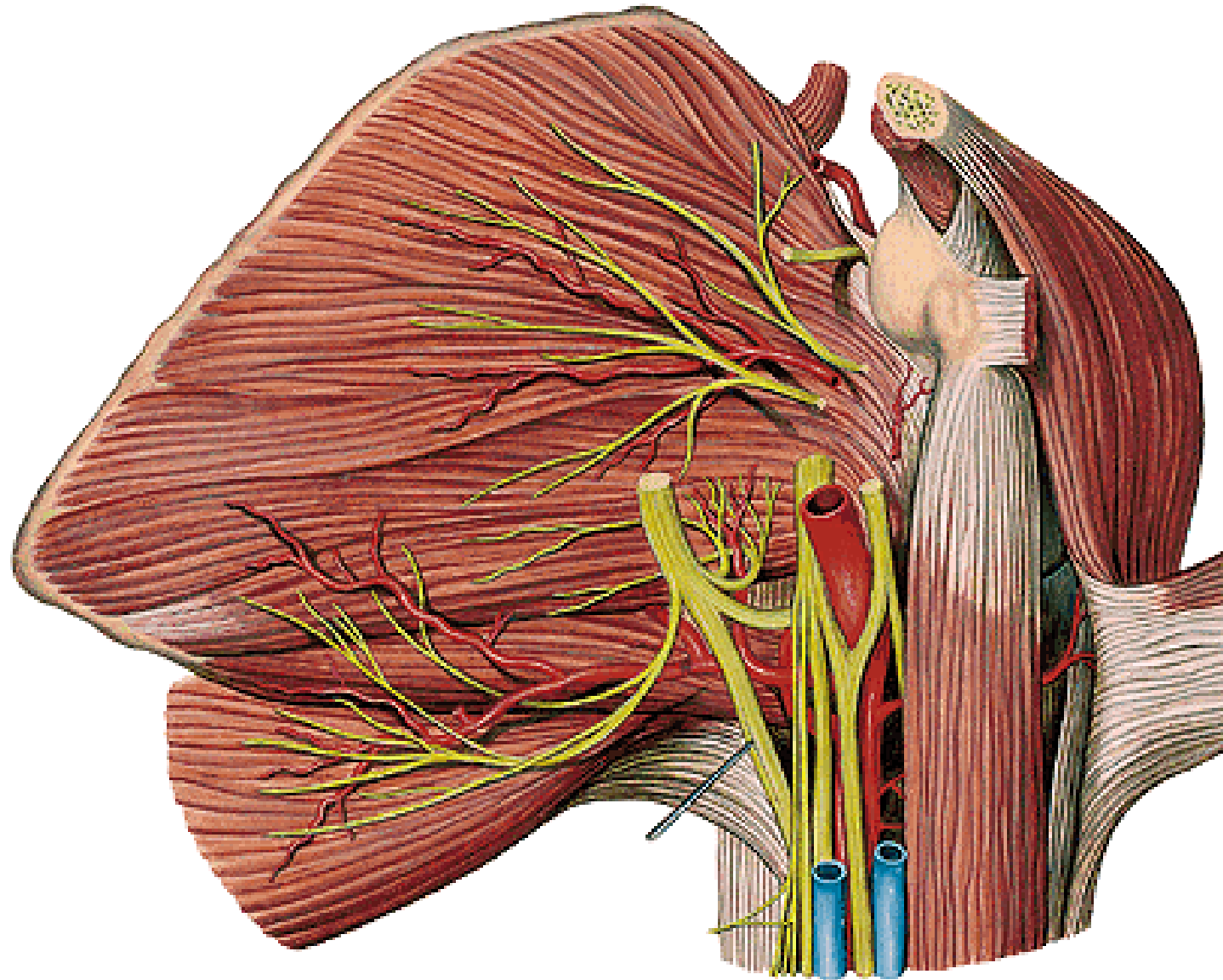
1. Ramus prof. n. ulnaris
2. Hiatus distalis (pisohamate canal)
3. Hamulus ossis hamati
4. Carpal tunnel
5. Os pisiforme
6. Lig. pisohamatum
7. N. ulnaris

Ulnar nerve entrapment - Claw hand

Claw hand



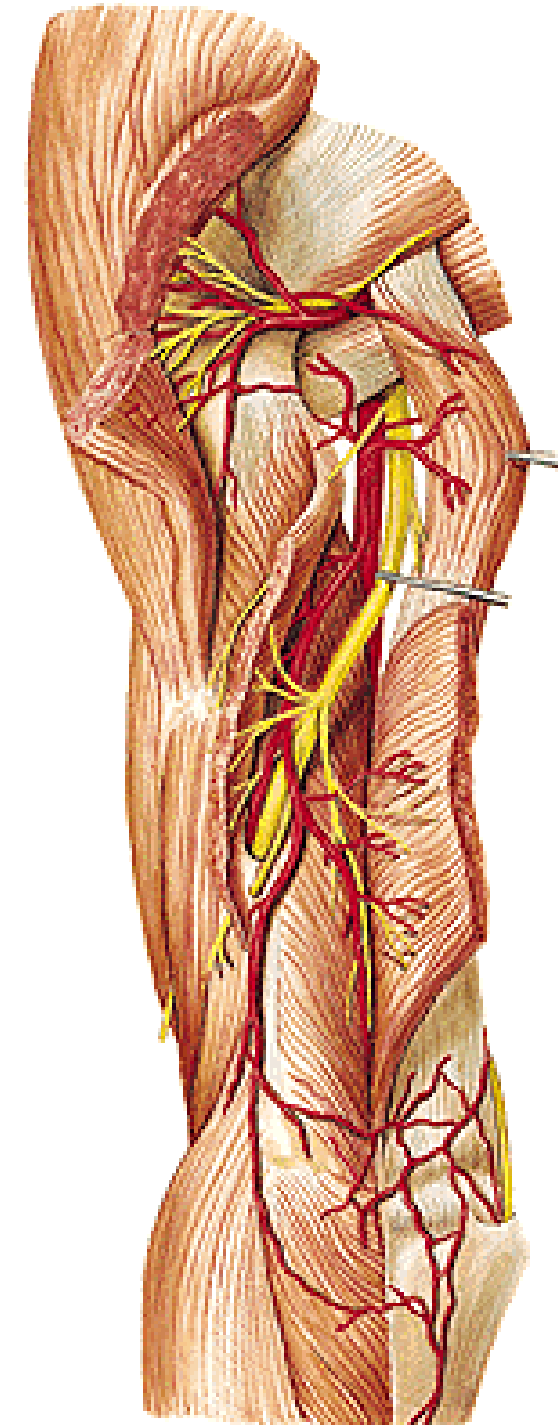
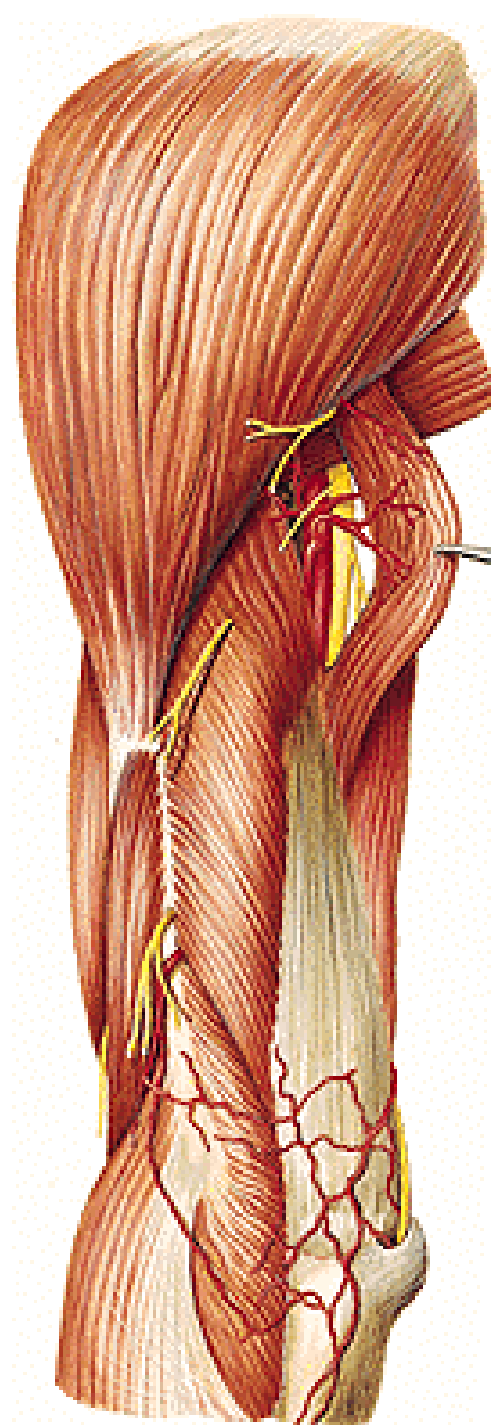
N. RADIALIS



N. RADIALIS

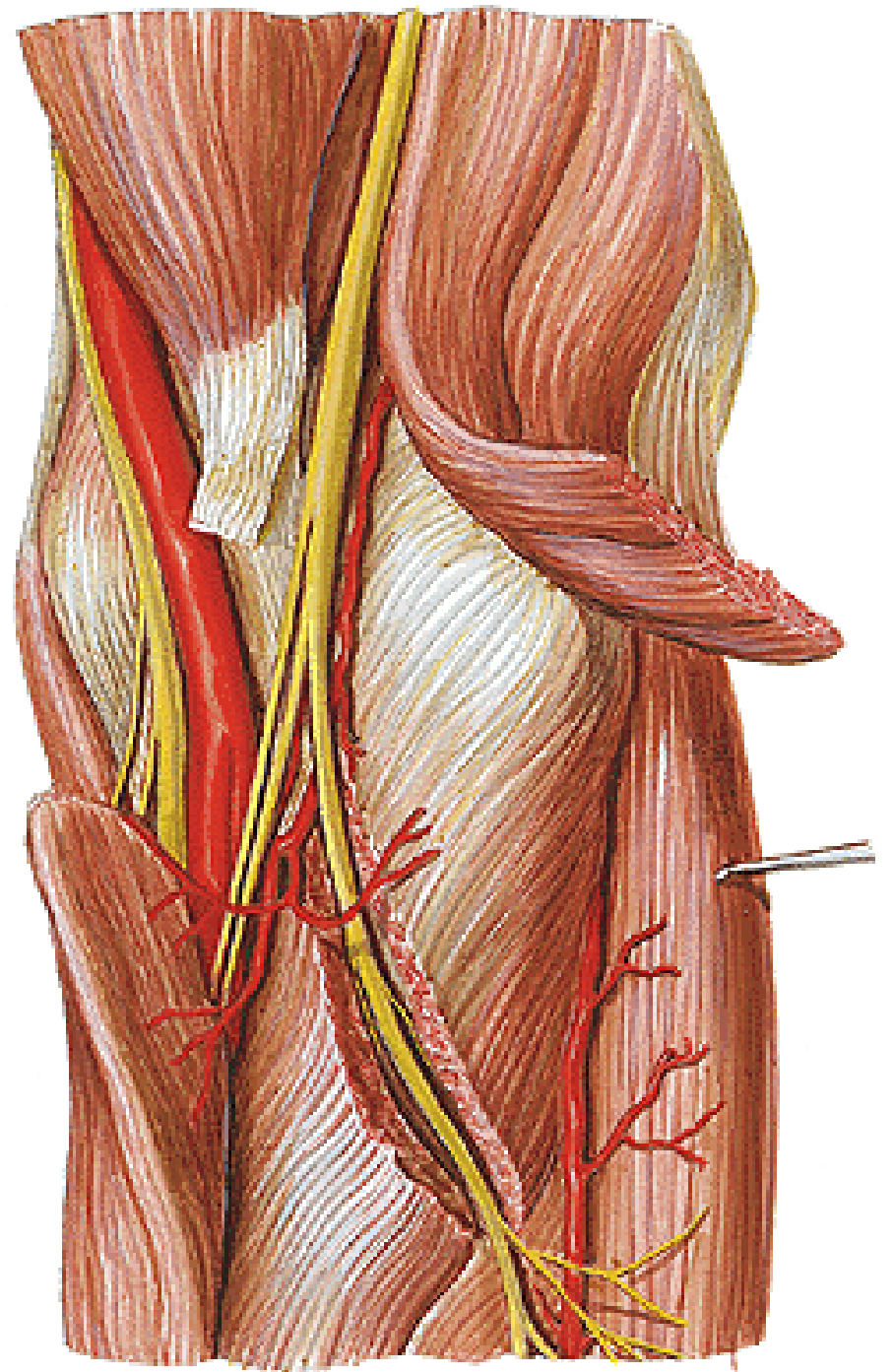
sulcus n. radialis

(a. profunda brachii)



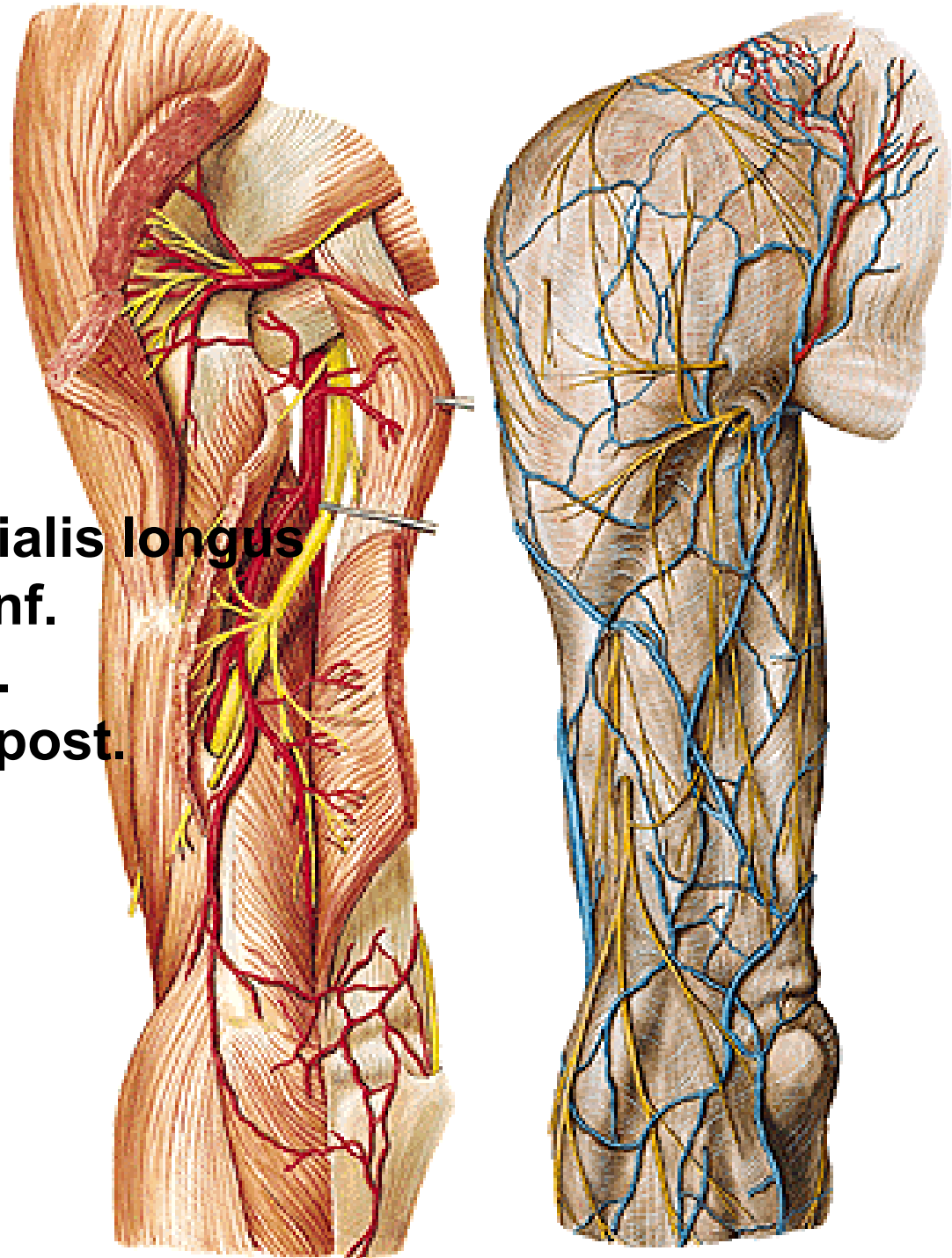
N. RADIALIS

- r. superficialis
- r. profundus



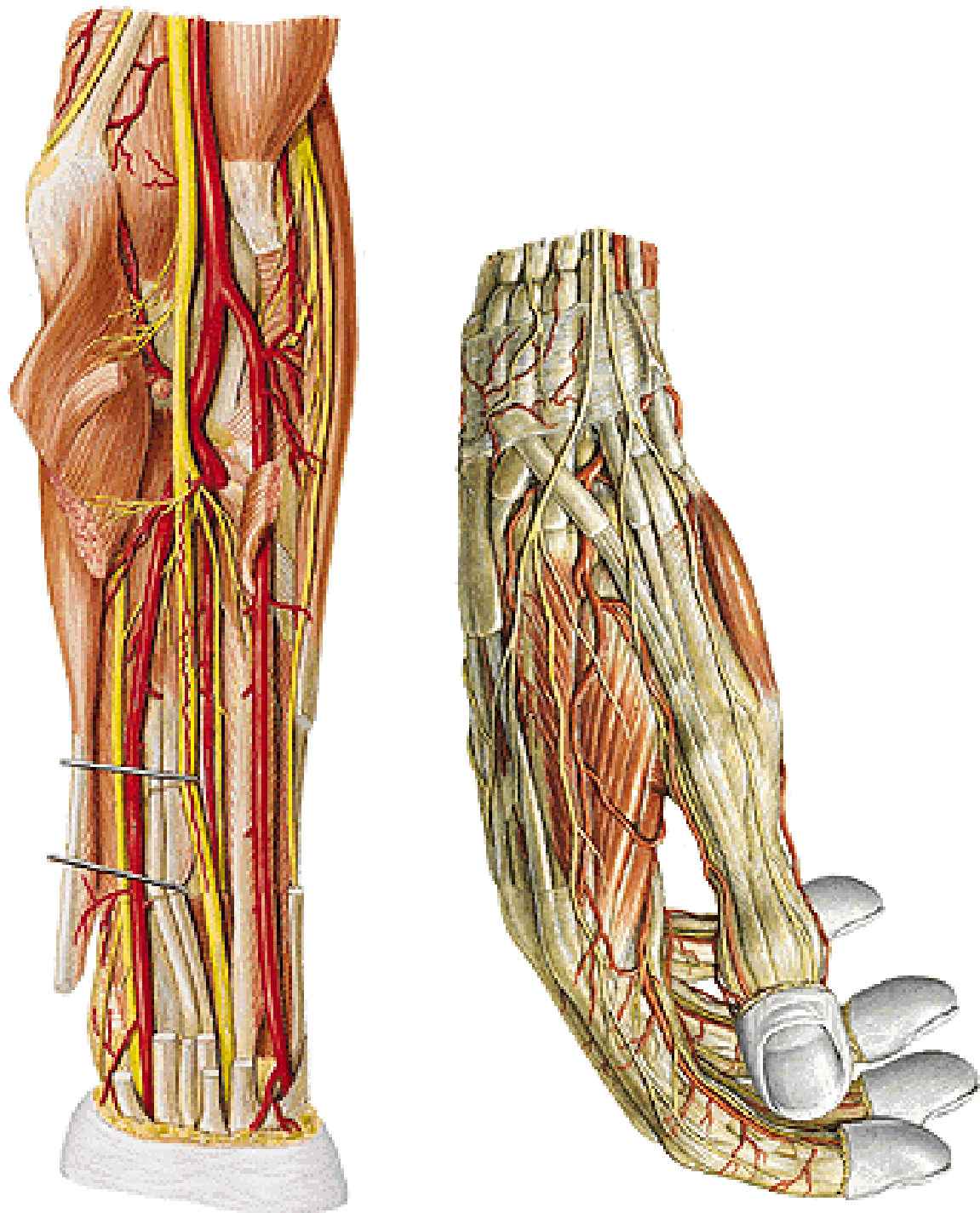
N. RADIALIS

- rr. musculares
 - m. triceps brachii
 - m. anconeus
 - m. brachioradialis
 - m. extensor carpi radialis longus
- n. cutaneus brachii lat. inf.
- n. cutaneus brachii post.
- n. cutaneus antebrachii post.



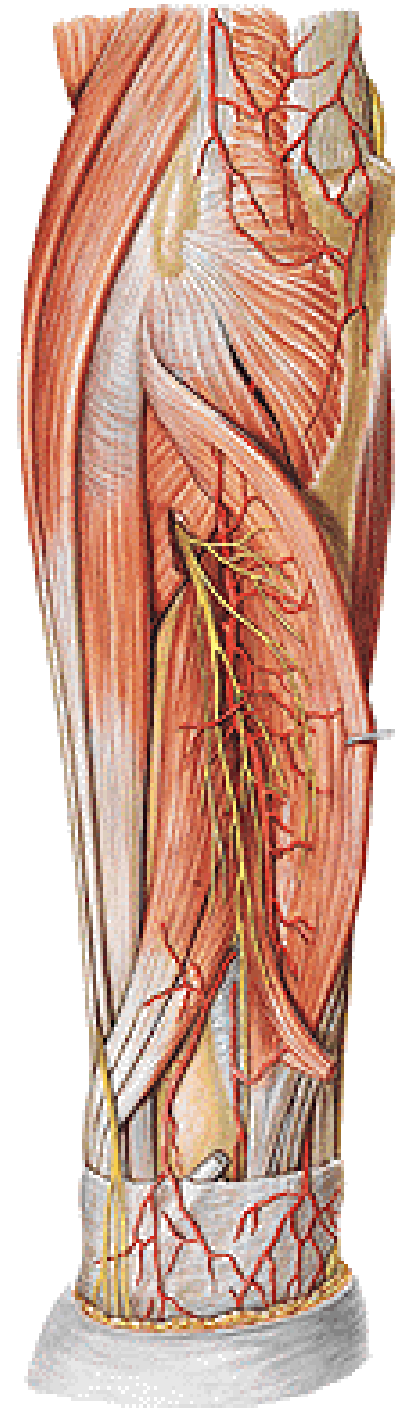
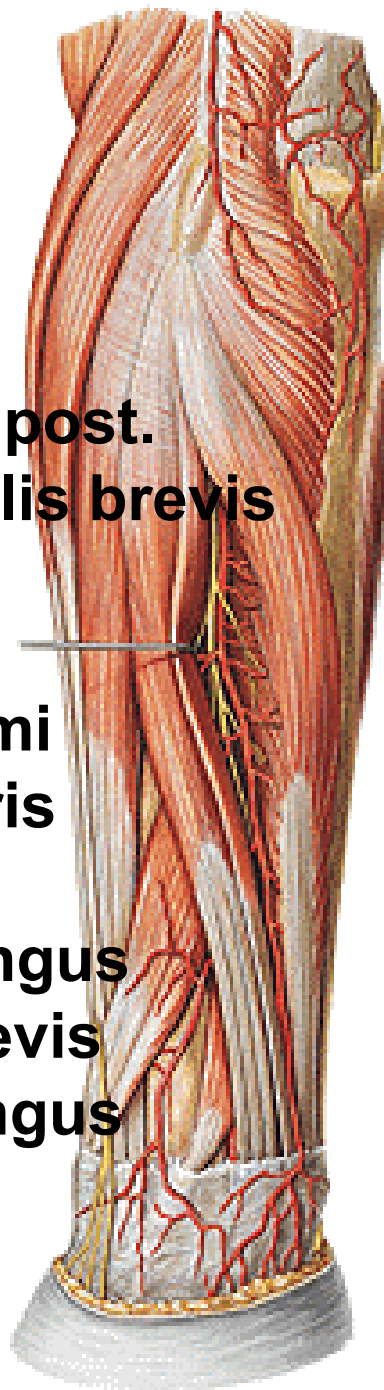
N. RADIALIS

- r. superficialis
- nn. digitales dorsales

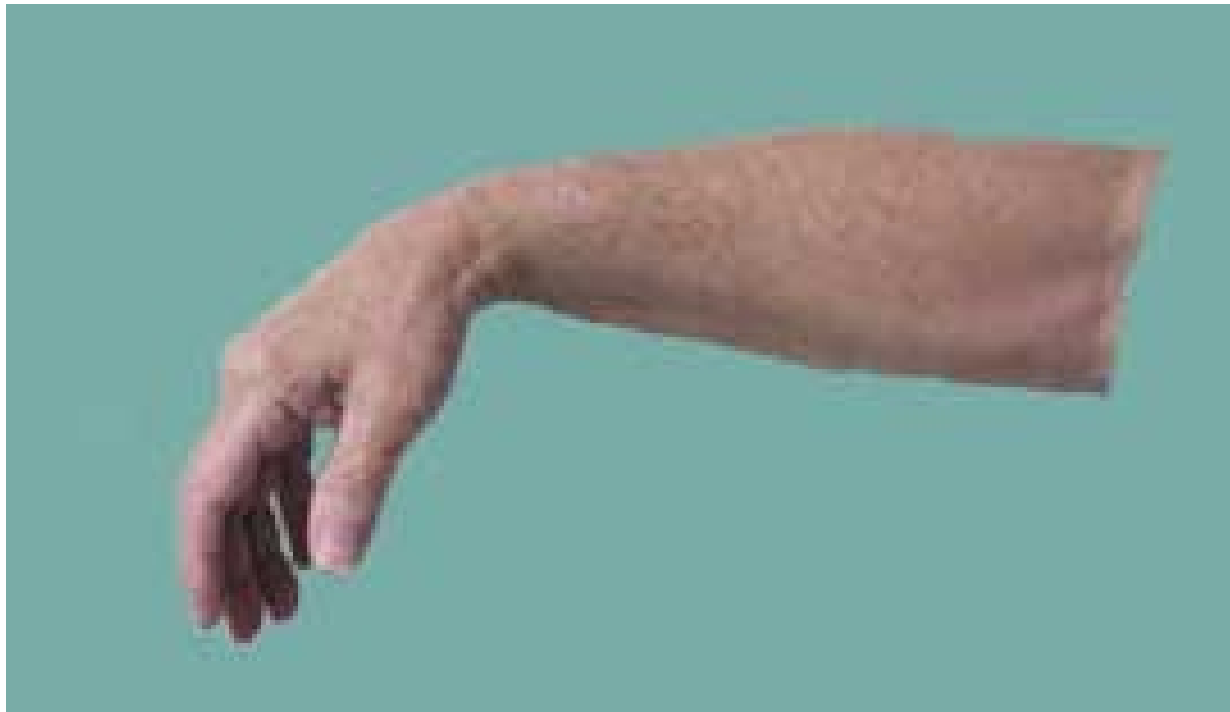

N. RADIALIS

- r. profundus
- rr. musculares
- n. interosseus antebrachii post.
 - m. extensor carpi radialis brevis
 - m. supinator
 - m. extensor digitorum
 - m. extensor digiti minimi
 - m. extensor carpi ulnaris
 - m. extensor indicis
 - m. abductor pollicis longus
 - m. extensor pollicis brevis
 - m. extensor pollicis longus



Wrist drop



CROSS SECTION THROUGH THE ARM

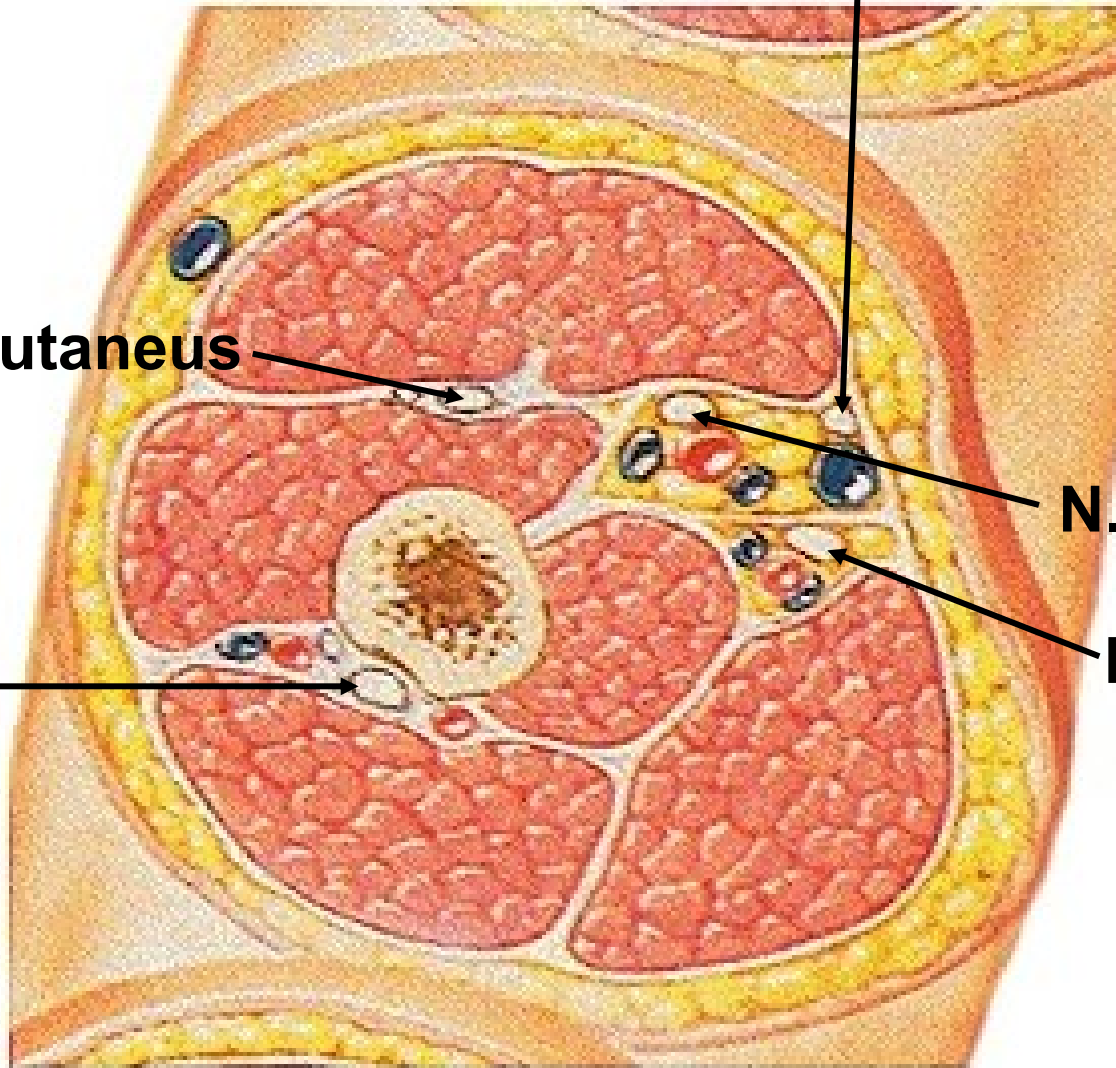
N. cutaneus antebrachii med.

N. musculocutaneus

N. medianus

N. ulnaris

N. radialis

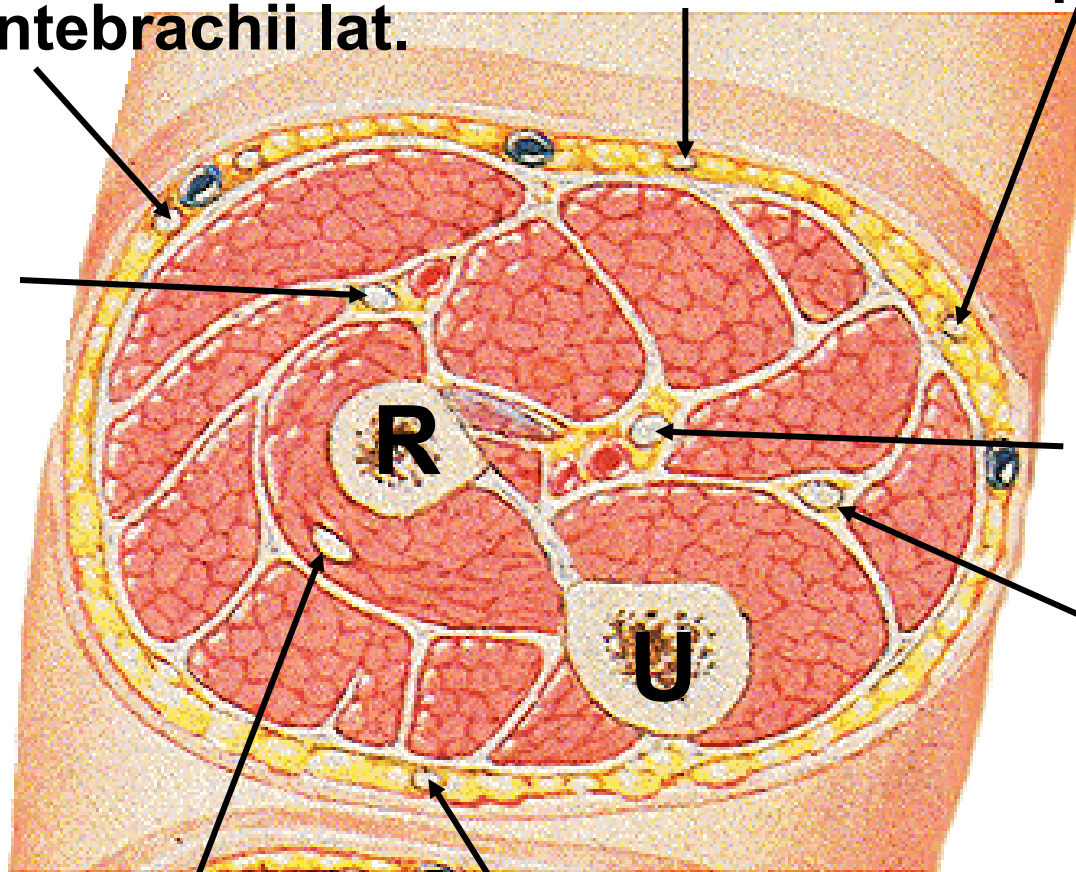


FOREARM – PROXIMAL CROSS SECTION

N. cutaneus antebrachii med.
- r. ant. - r. post.

N. cutaneus antebrachii lat.

N. radialis
- r. spf.



N. medianus

N. ulnaris

N. cutaneus antebrachii post.

N. radialis – r. prof.

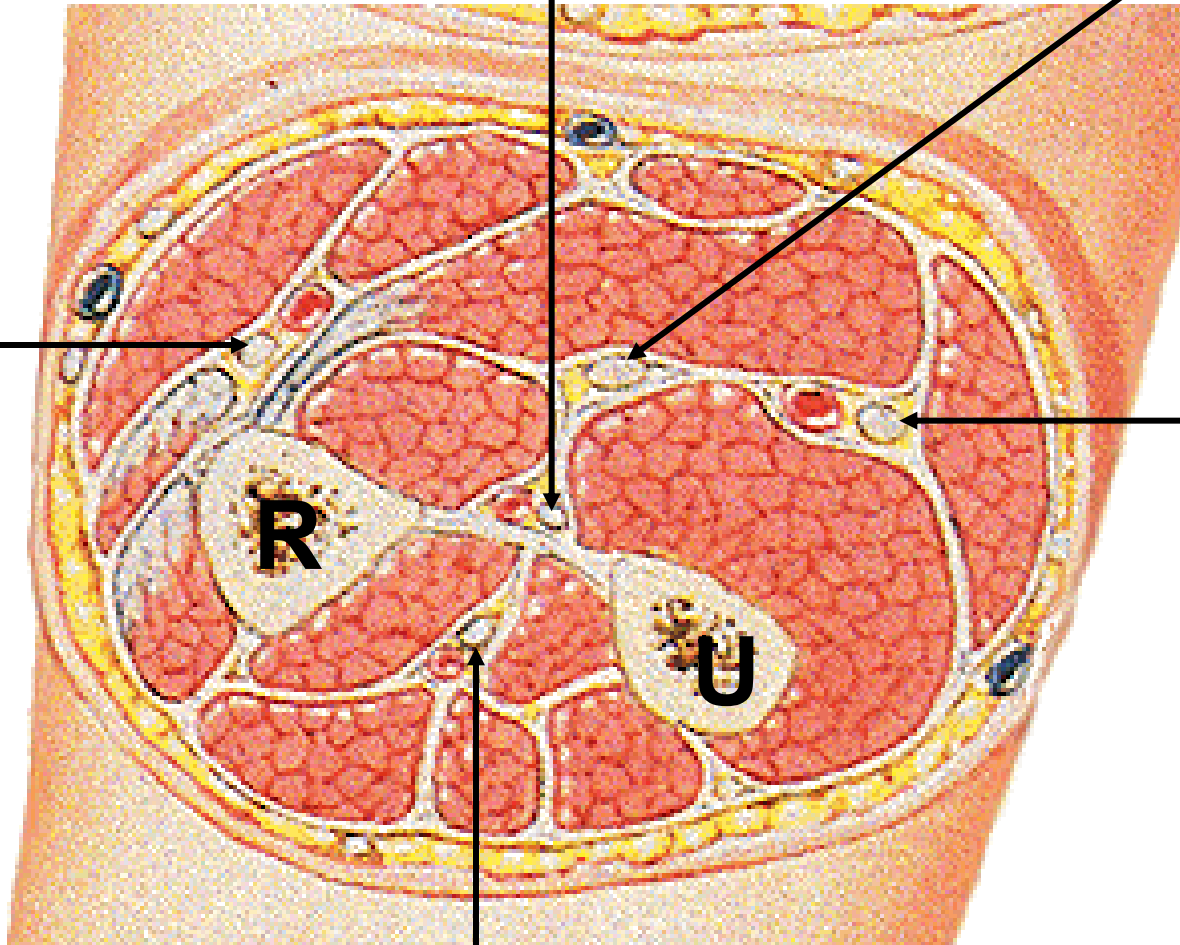
FOREARM – MIDDLE CROSS SECTION

N. interosseus anterior

N. medianus

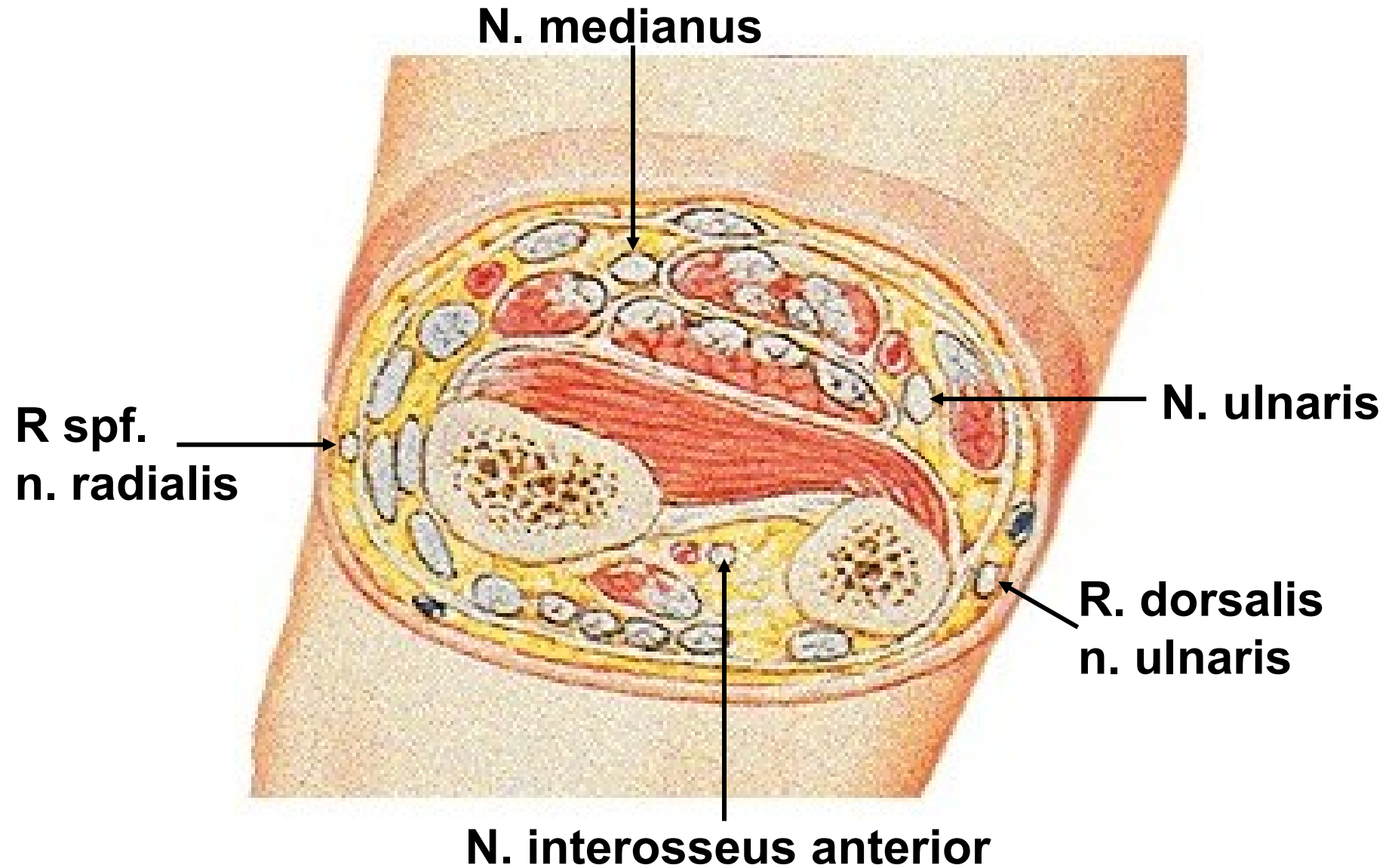
**R. spf.
n. radialis**

N. ulnaris



N. interosseus posterior

FOREARM – DISTAL CROSS SECTION



Innervation of upper limb muscles:

N. subscapulares – subscapularis, teres major

N. axillaris – deltoideus, teres minor

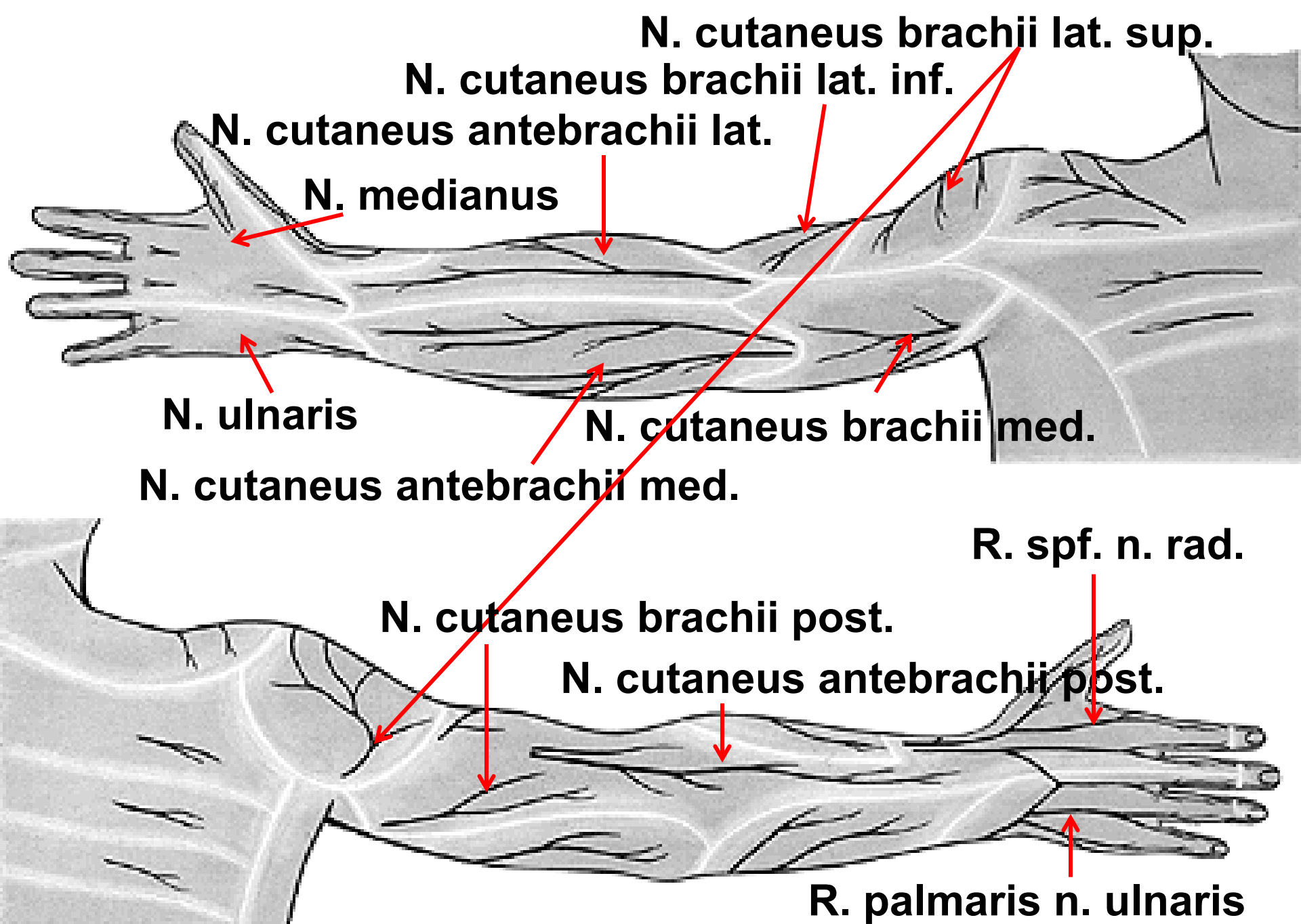
N. suprascapularis – supraspinatus et infraspinatus

N. musculocutaneus – anterior brachial group

N. radialis – posterior brachial group, posterior antebrachial group, lateral antebrachial group

N. ulnaris – flexor carpi ulnaris, medial half of flexor dig. prof., most of muscles of the hand

N. medianus – anterior antebrachial group (except 2 muscles innervated by ulnar nerve), abductor pollicis brevis, flexor pollicis brevis (superficial head), opponens pollicis, 2 medial lumbricals



Illustrations and photographs were copied from:
Atlas der Anatomie des Menschen/Sobotta.
Putz,R., und Pabst,R. 20. Auflage. München:
Urban & Schwarzenberg, 1993
Netter: Interactive Atlas of Human Anatomy.
Windows Version 2.0