

# **DIGESTIVE SYSTEM I.**

## **ORAL CAVITY**

# **GASTROINTESTINAL TRACT – GIT (APPARATUS DIGESTORIUS)**

**Oral cavity (Cavitas oralis)**

**Pharynx**

**Oesophagus**

**Stomach (Ventriculus)**

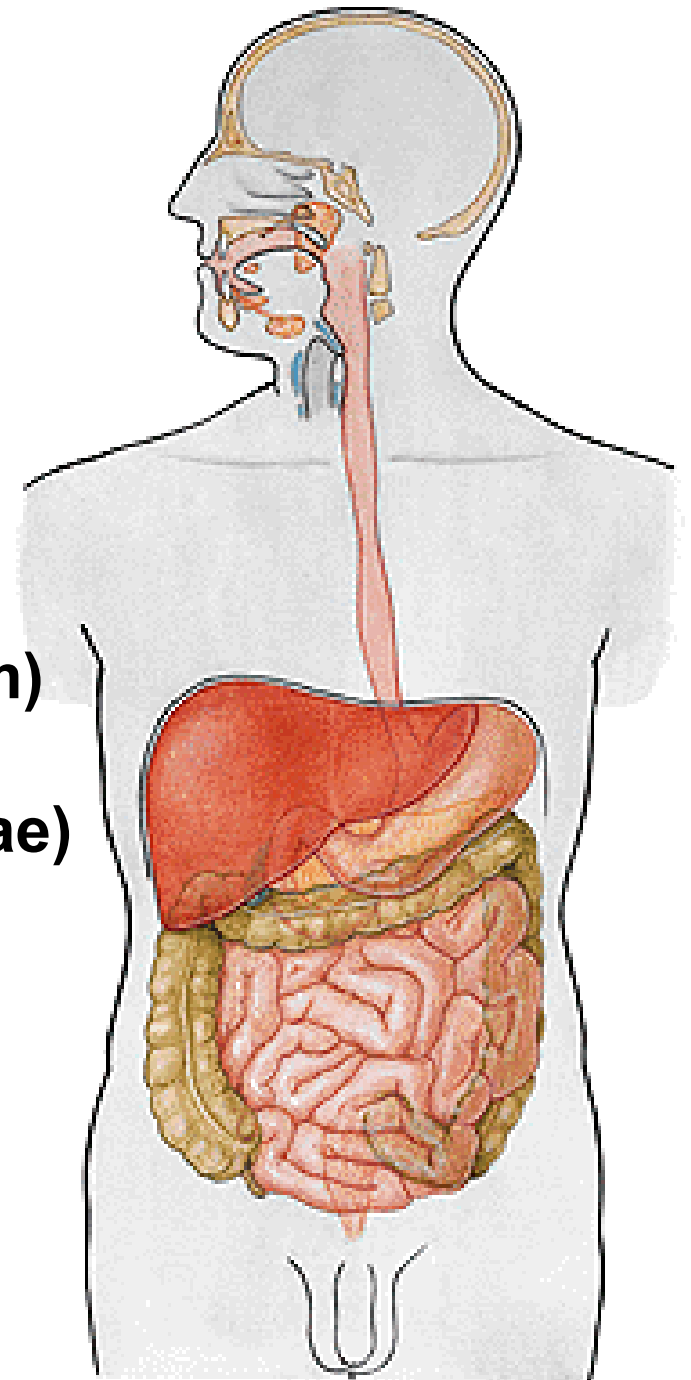
**Small intestine (Intestinum tenue)**

**Large intestine (Intestinum crassum)**

**Salivary glands (Glandulae salivariae)**

**Liver (Hepar)**

**Pancreas**

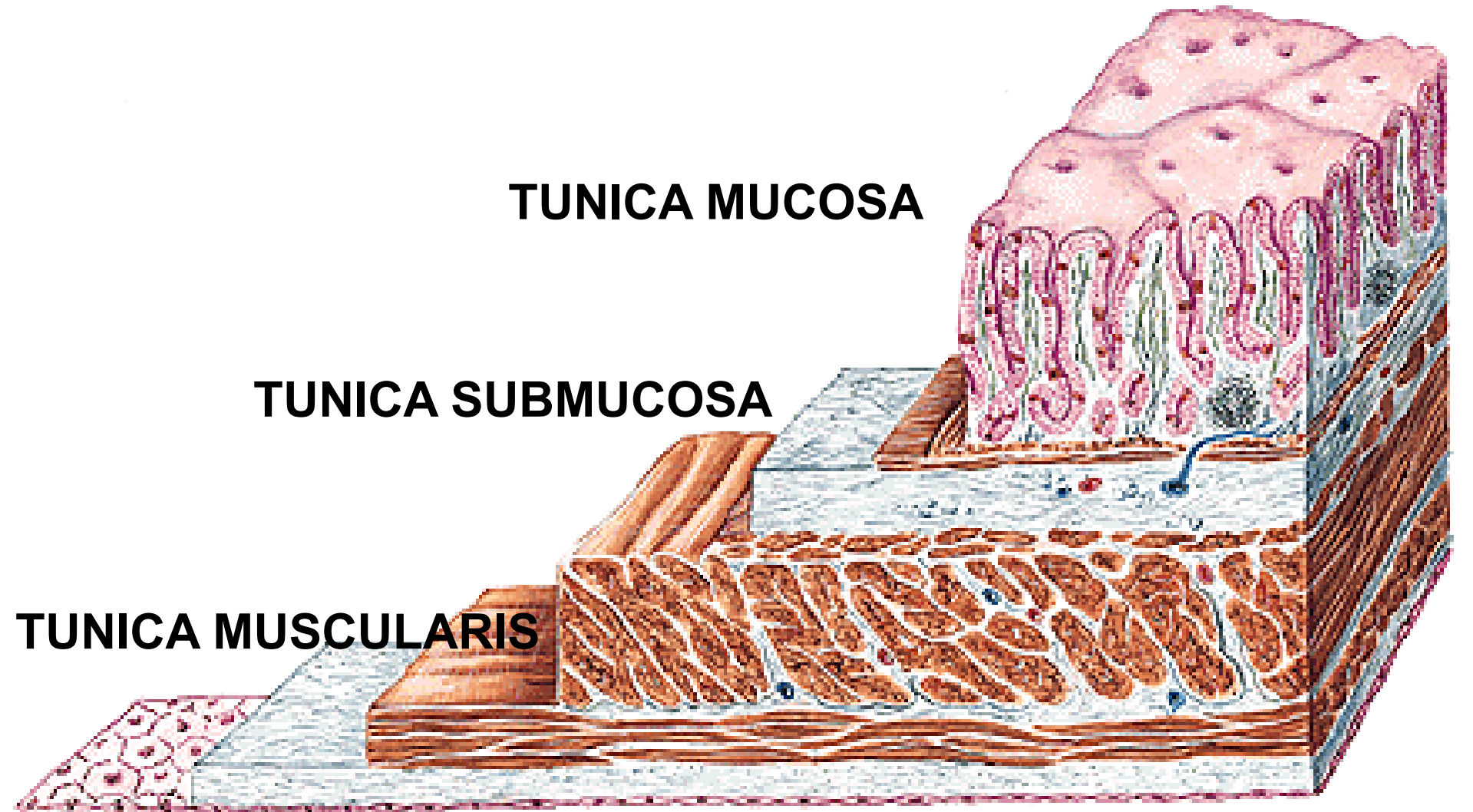


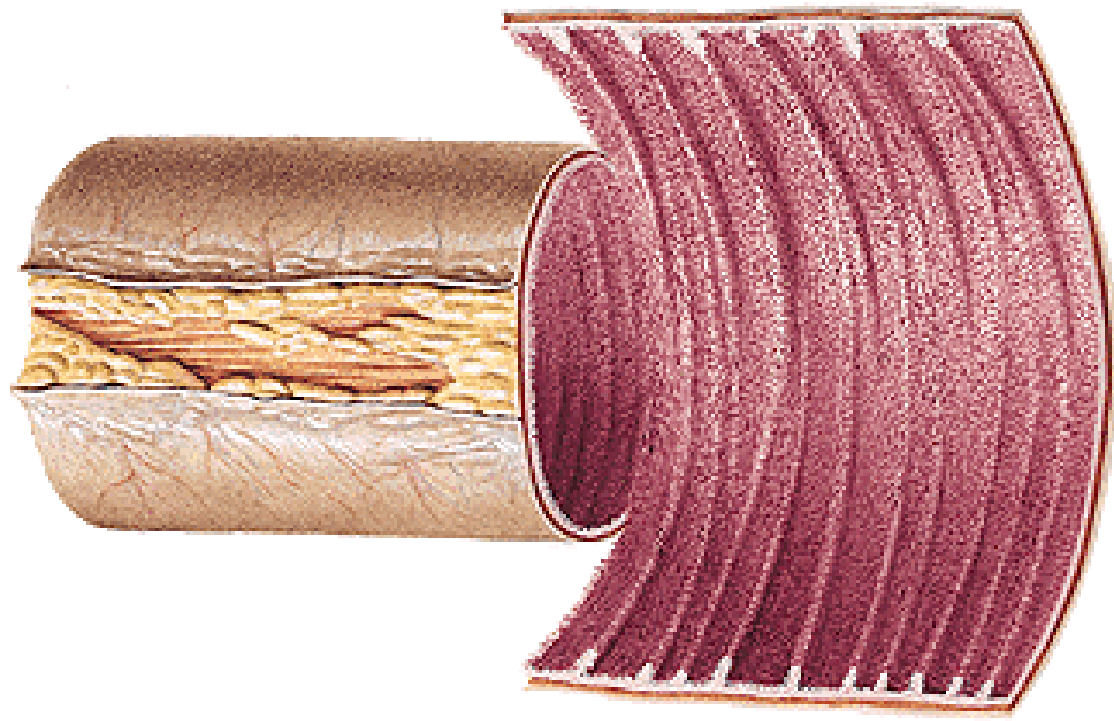
**TUNICA MUCOSA**

**TUNICA SUBMUCOSA**

**TUNICA MUSCULARIS**

**TUNICA ADVENTITIA (TUNICA SEROSA=visceral peritoneum)**

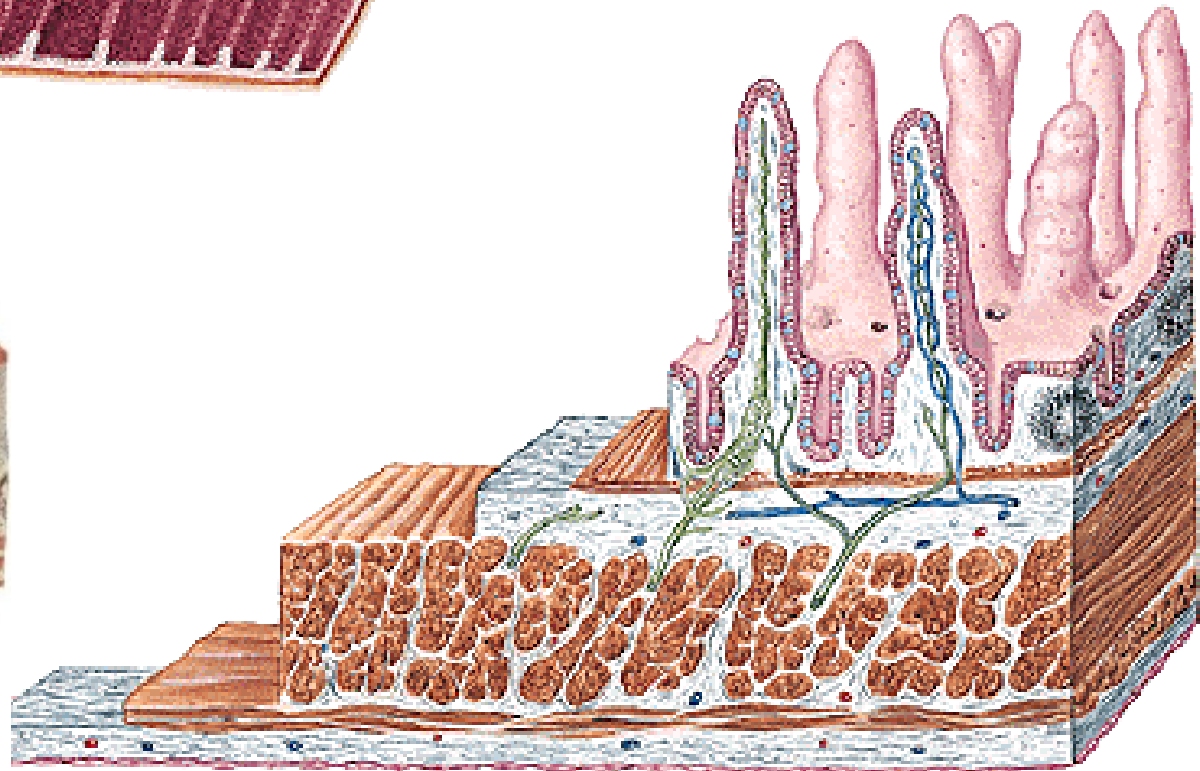
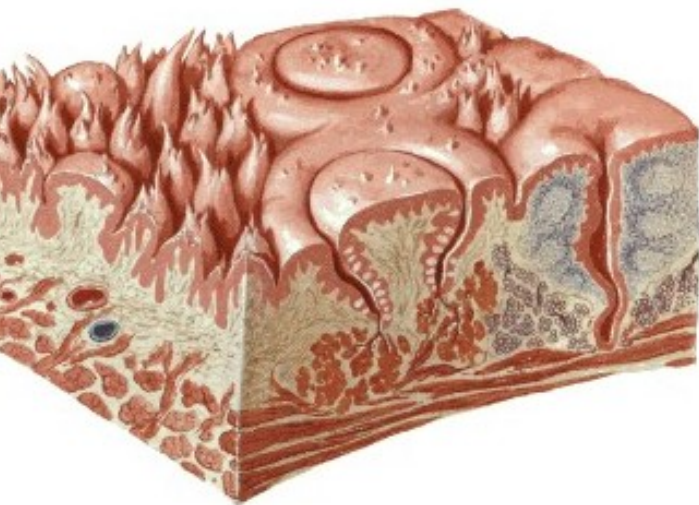


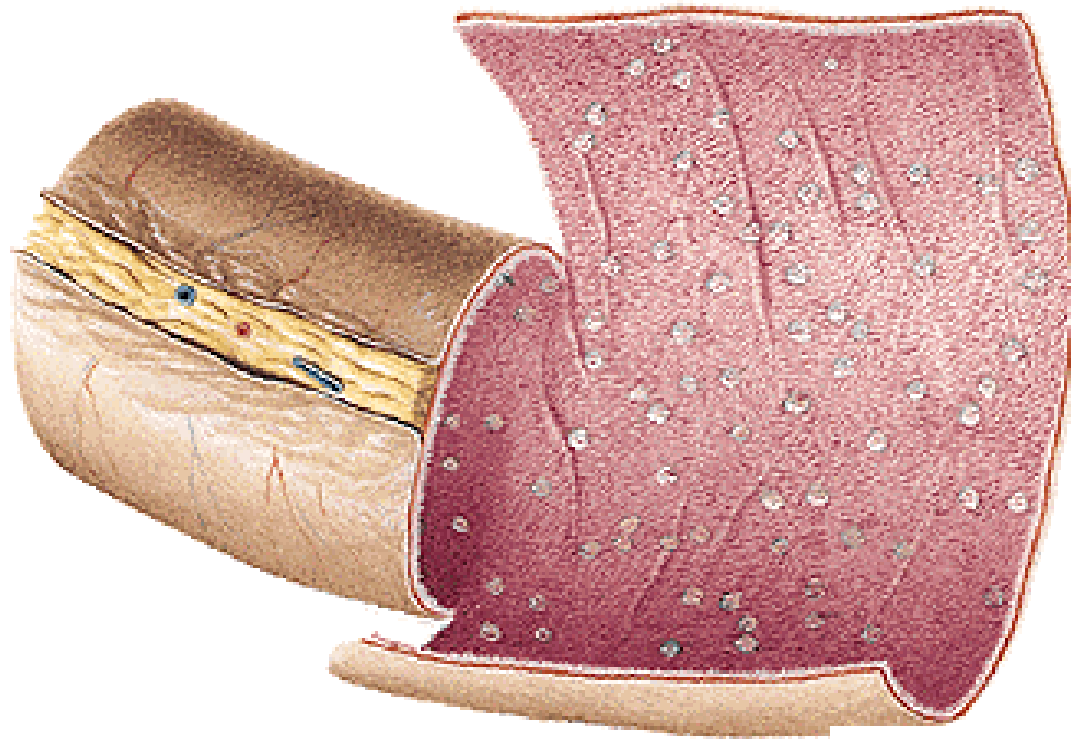

**PLICAE**

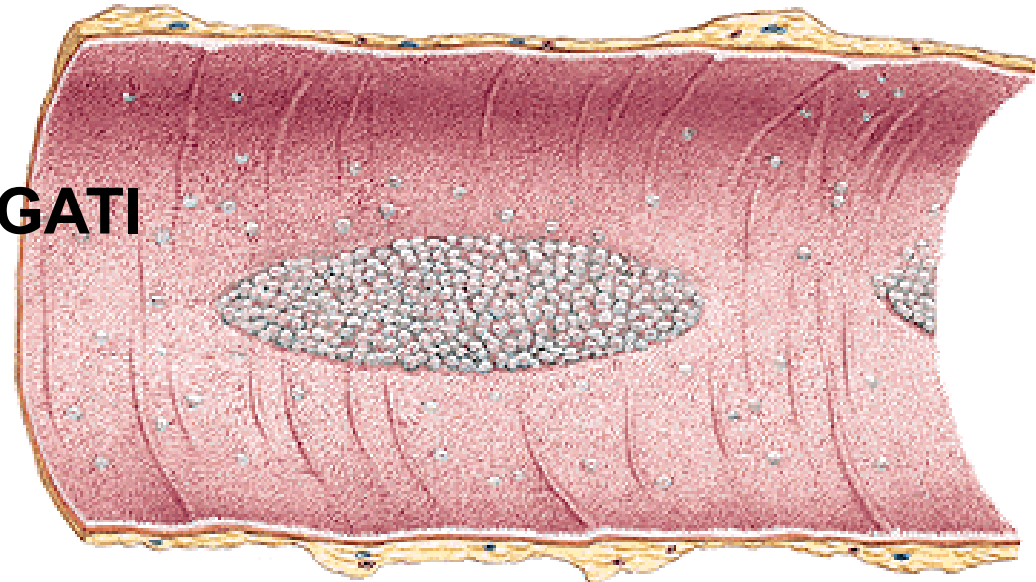
**VILLI INTESTINALES**

**PAPILLAE**





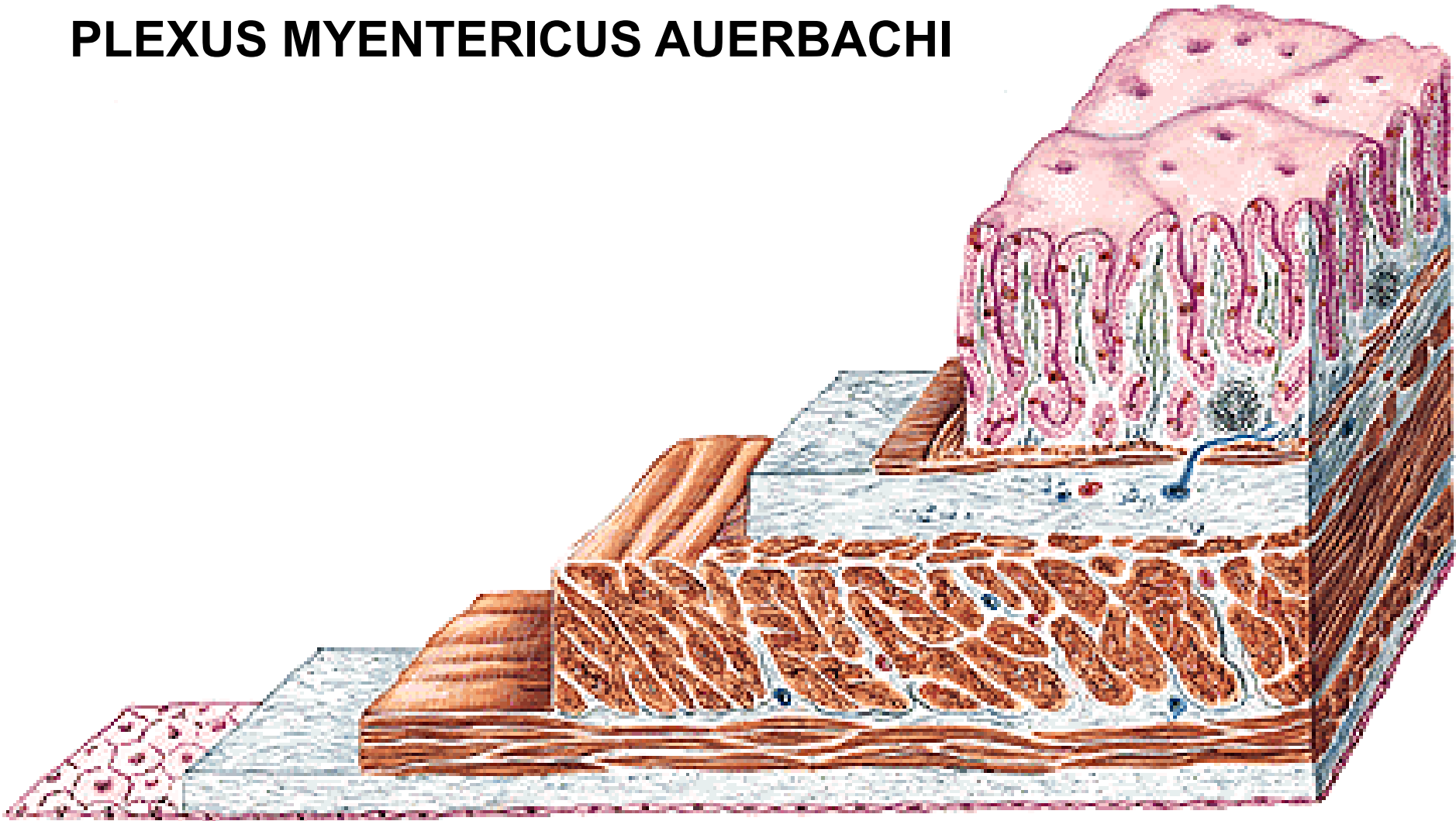
**FOLLICULI  
LYMPHATICI SOLITARIII**



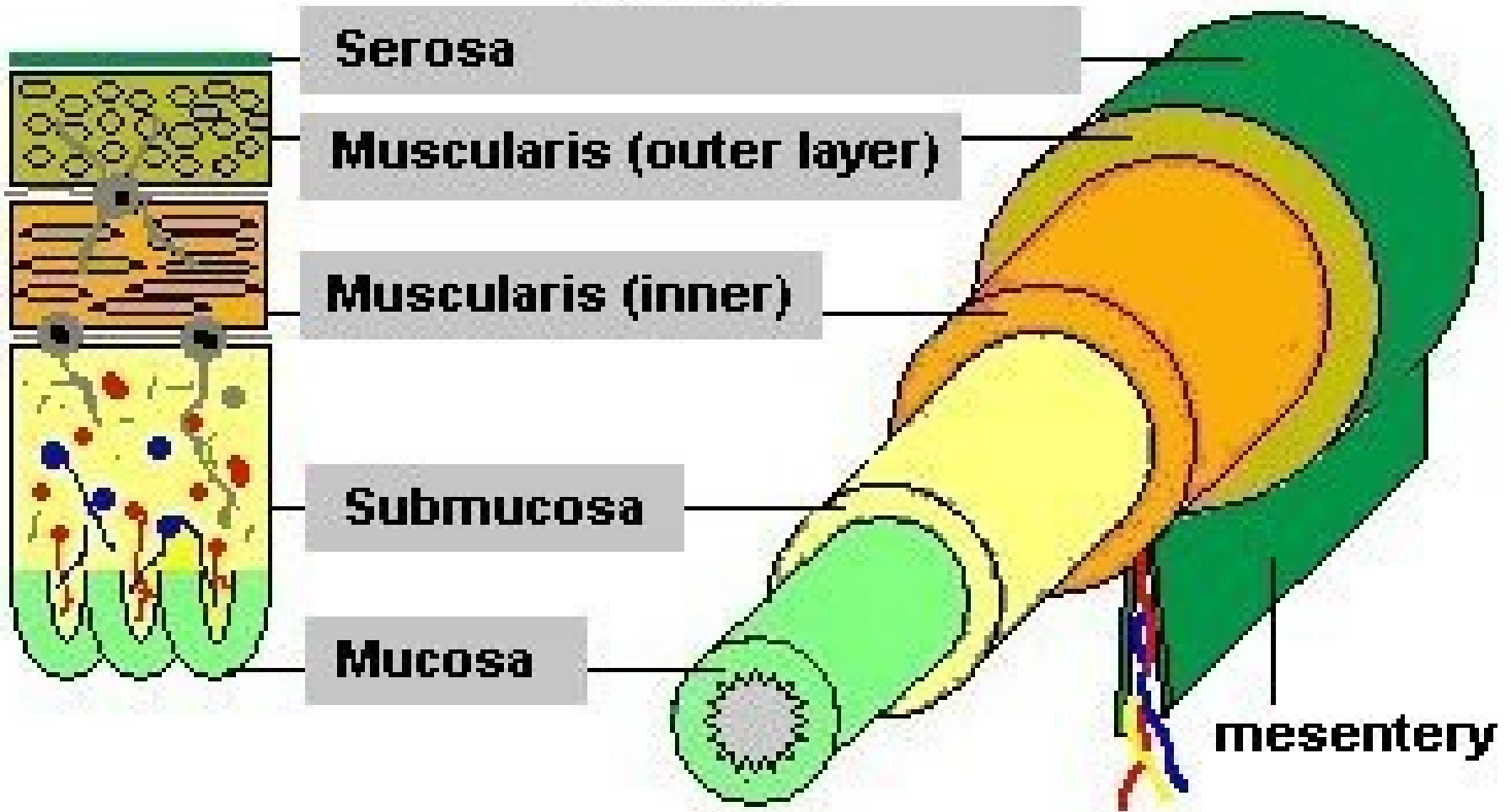
**FOLLICULI LYMPH. AGGREGATI  
– PEYER'S PATCHES**

**PLEXUS SUBMUCOSUS MEISSNERI**

**PLEXUS MYENTERICUS AUERBACHI**



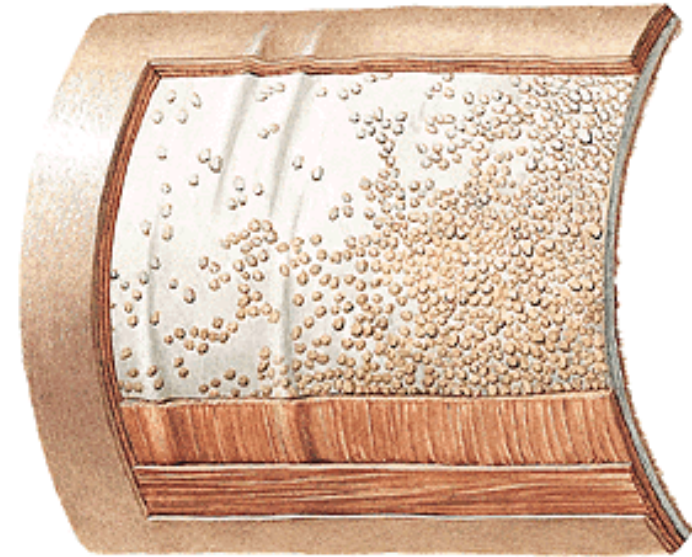
# Tunics



## GLANDS OF GIT:

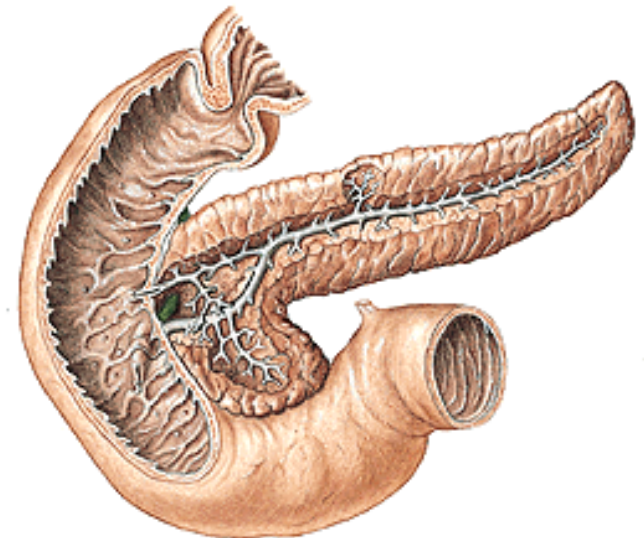
### Intramural – goblet cells

- small salivary glands
- glandulae duodenales



### Extramural – great salivary glands

- liver
- pancreas

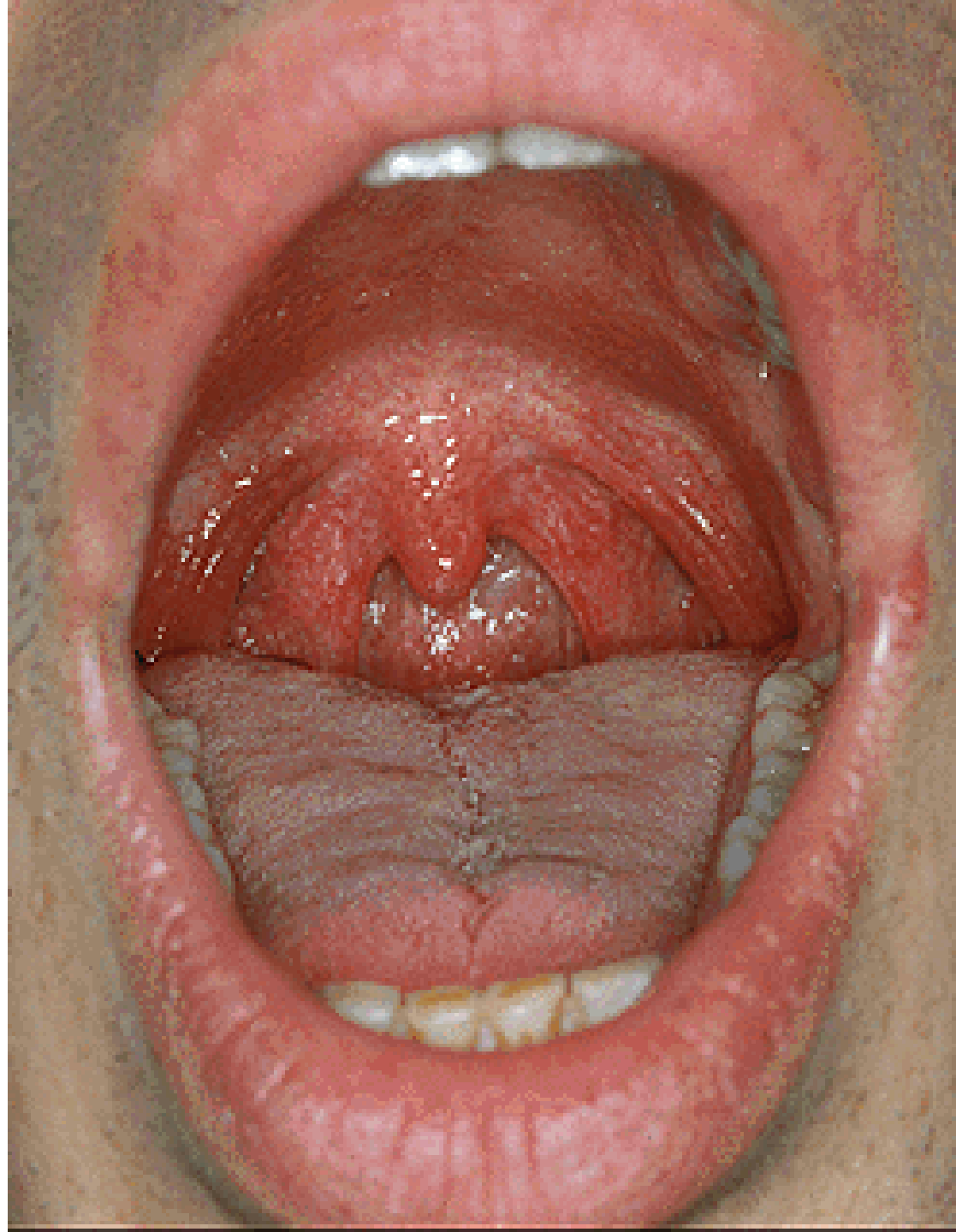

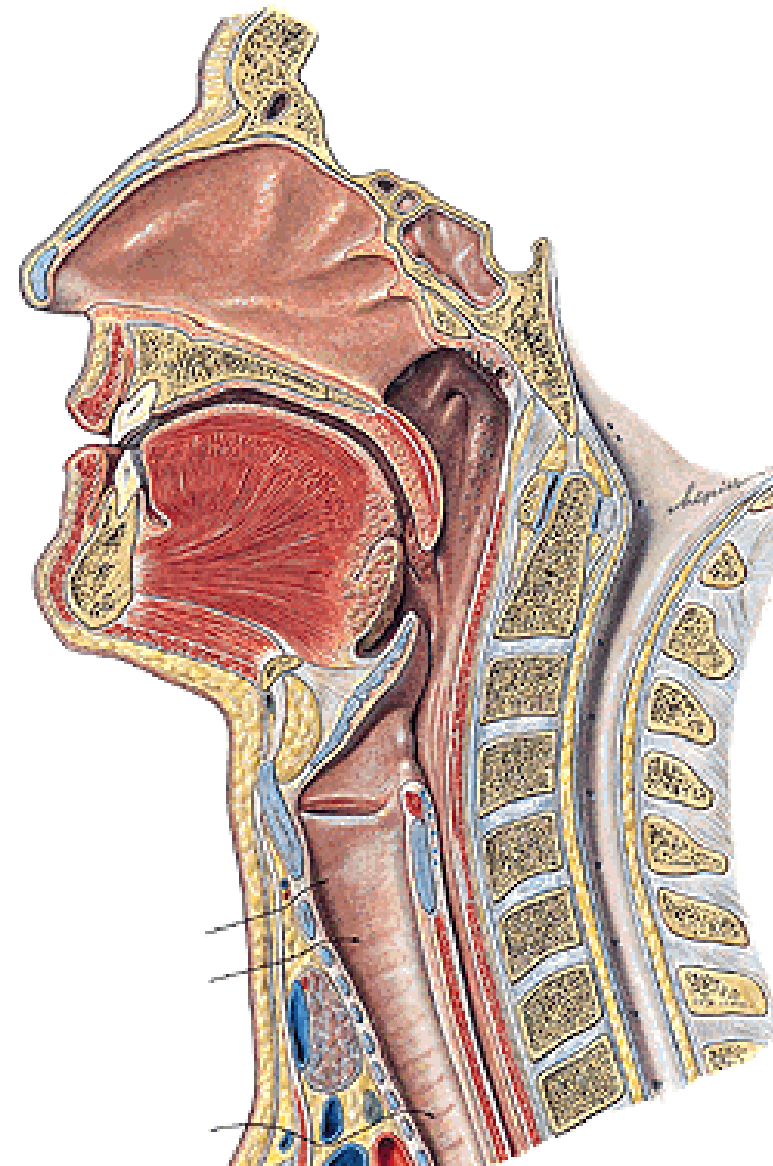
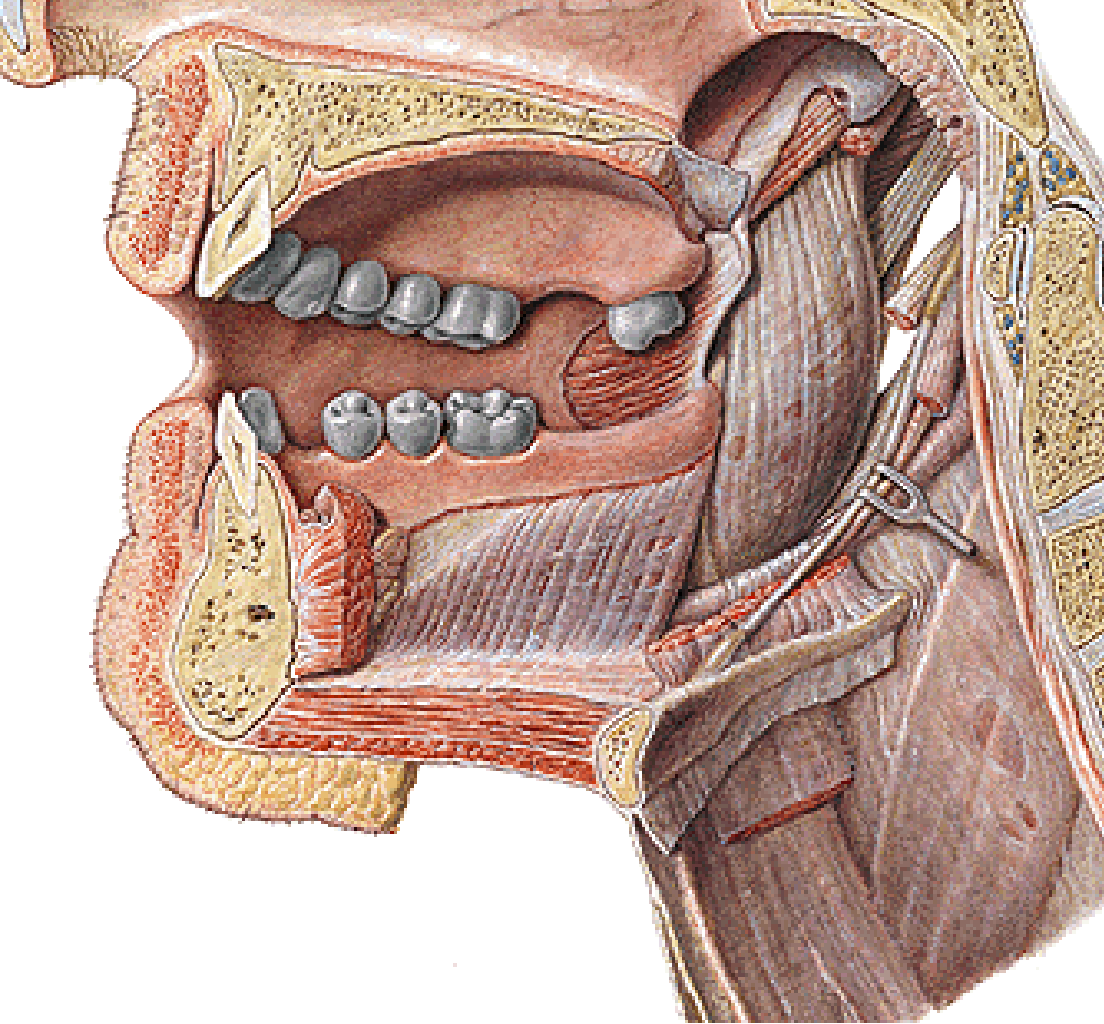


**CAVUM ORIS  
(CAVITAS ORIS)**

**Rima oris**

**Isthmus faucium**





## **CAVUM ORIS**

- vestibulum oris**
- cavum oris proprium**

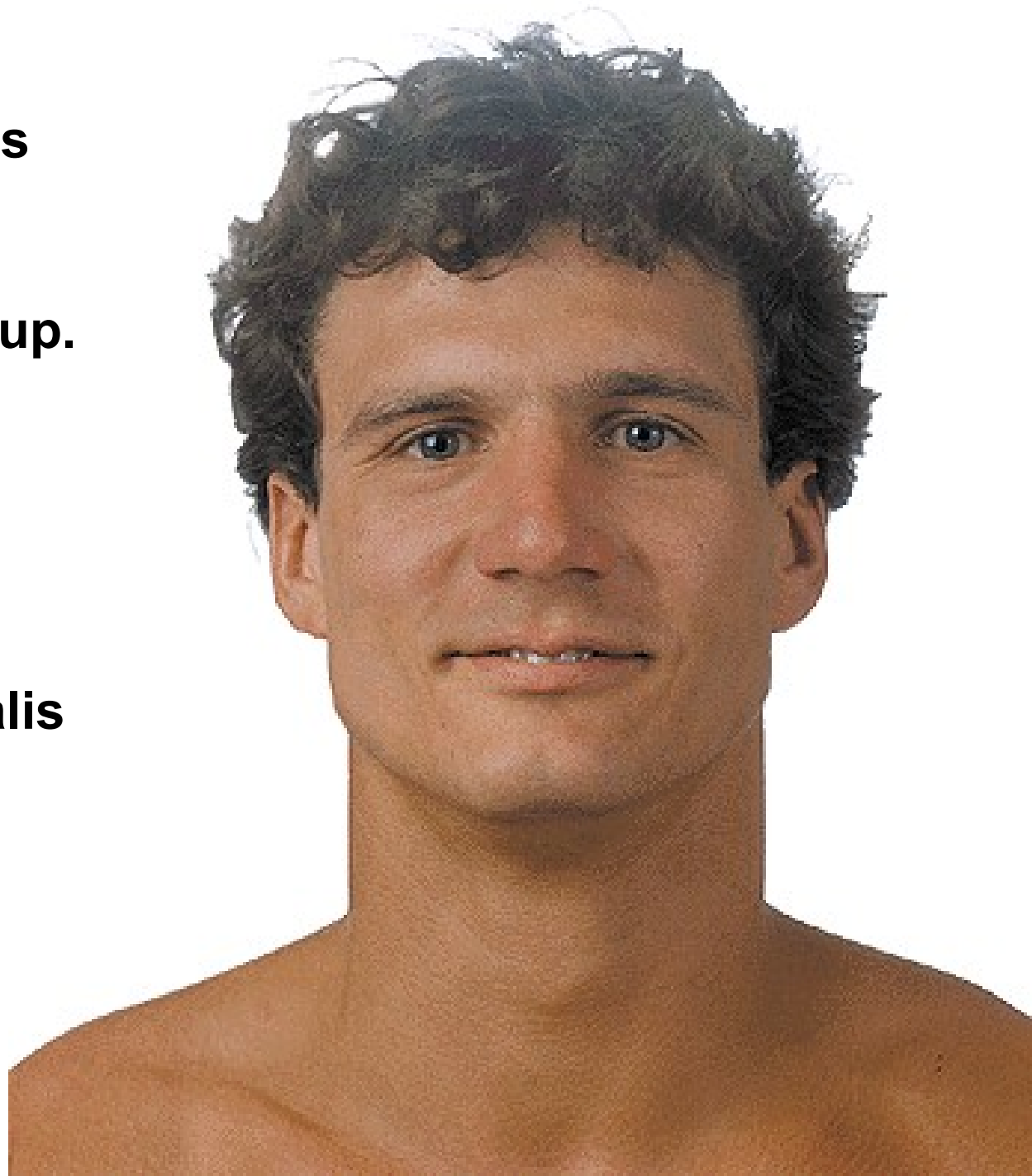
## **Labium superius**

- **sulcus nasolabialis**
- **pars intermedia**
- **philtrum**
- **tuberculum labii sup.**
- **cheiloschisis**
- **gnathoschisis**
- **palatoschisis**

## **Labium inferius**

- **sulcus mentolabialis**

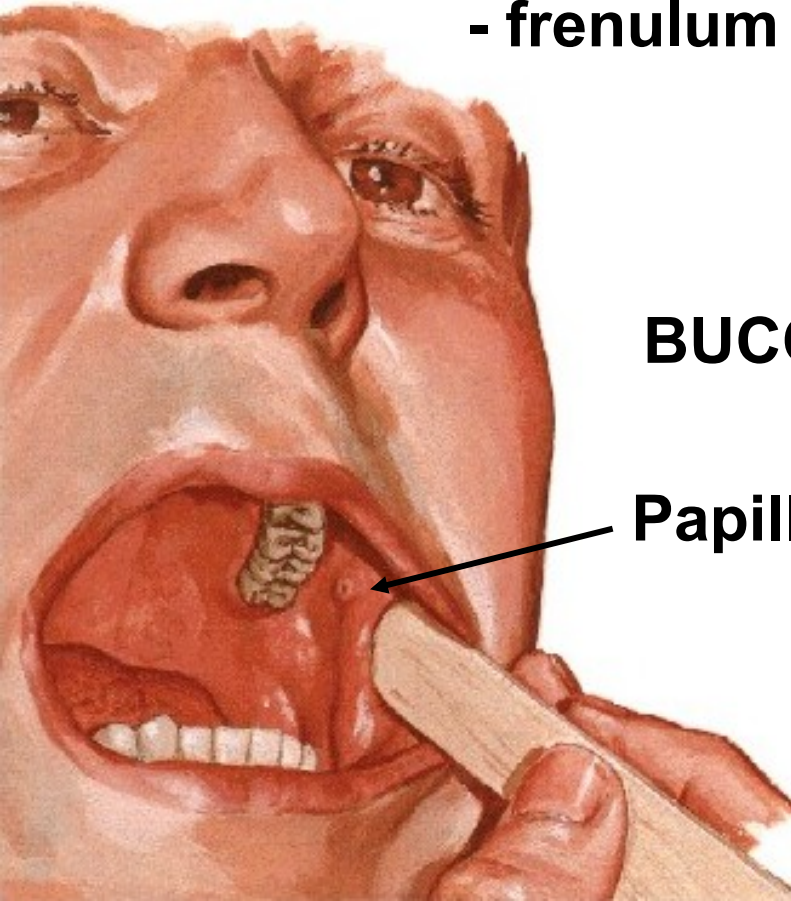
## **Anguli oris**



# VESTIBULUM ORIS

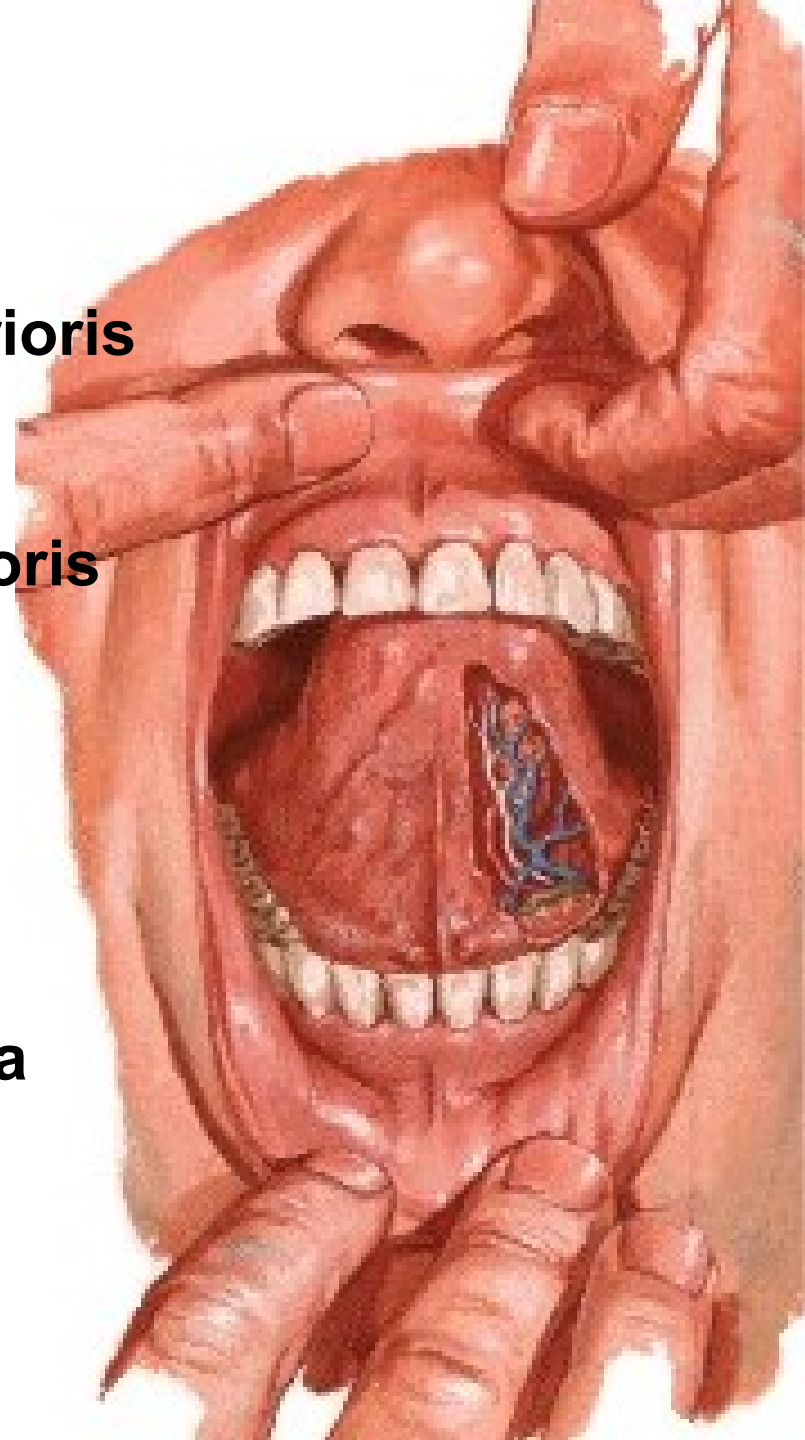
Fornix vestibuli sup.  
- frenulum labii superioris

Fornix vestibuli inf.  
- frenulum labii inferioris



**BUCCA**

Papilla parotidea

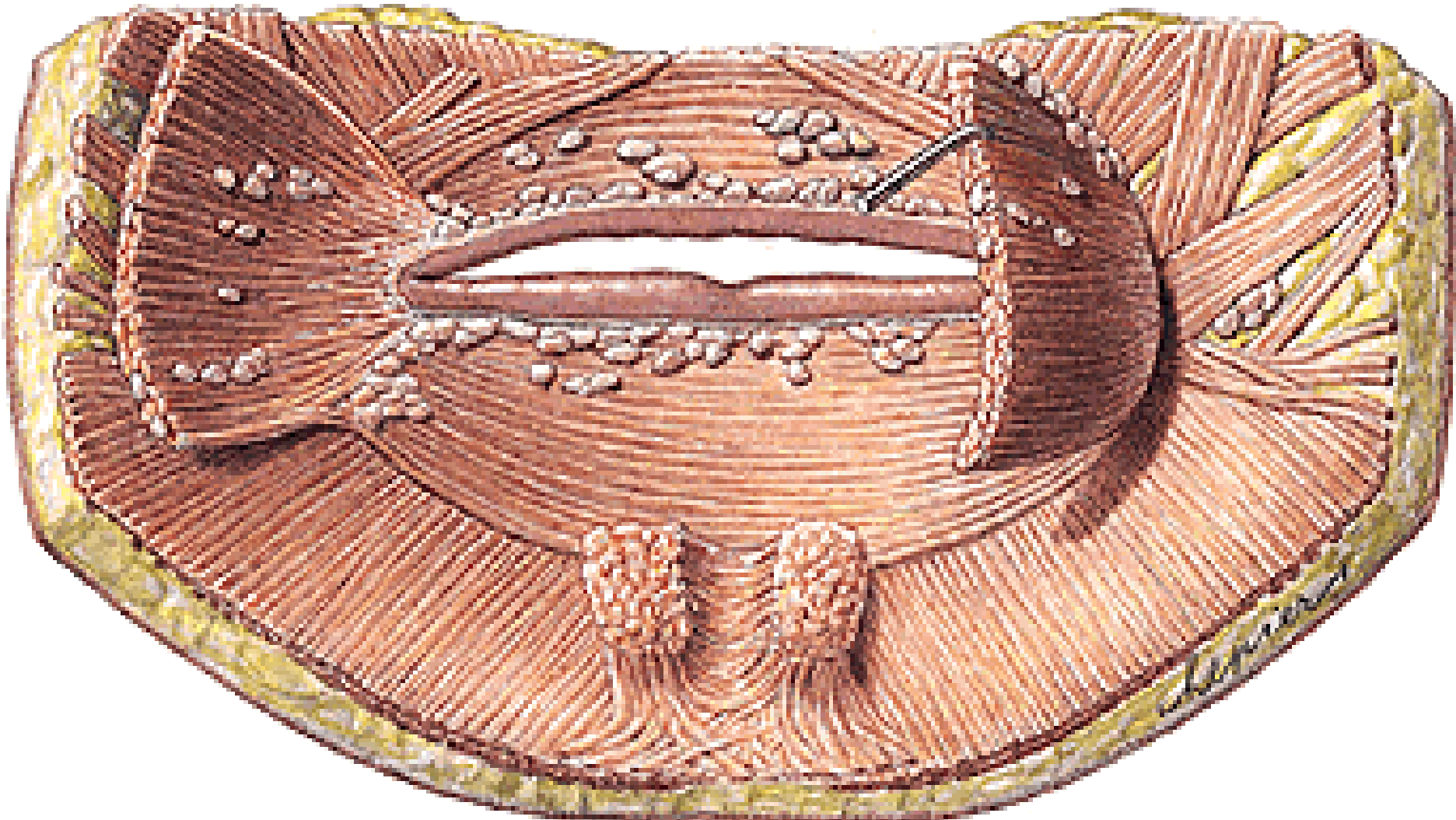


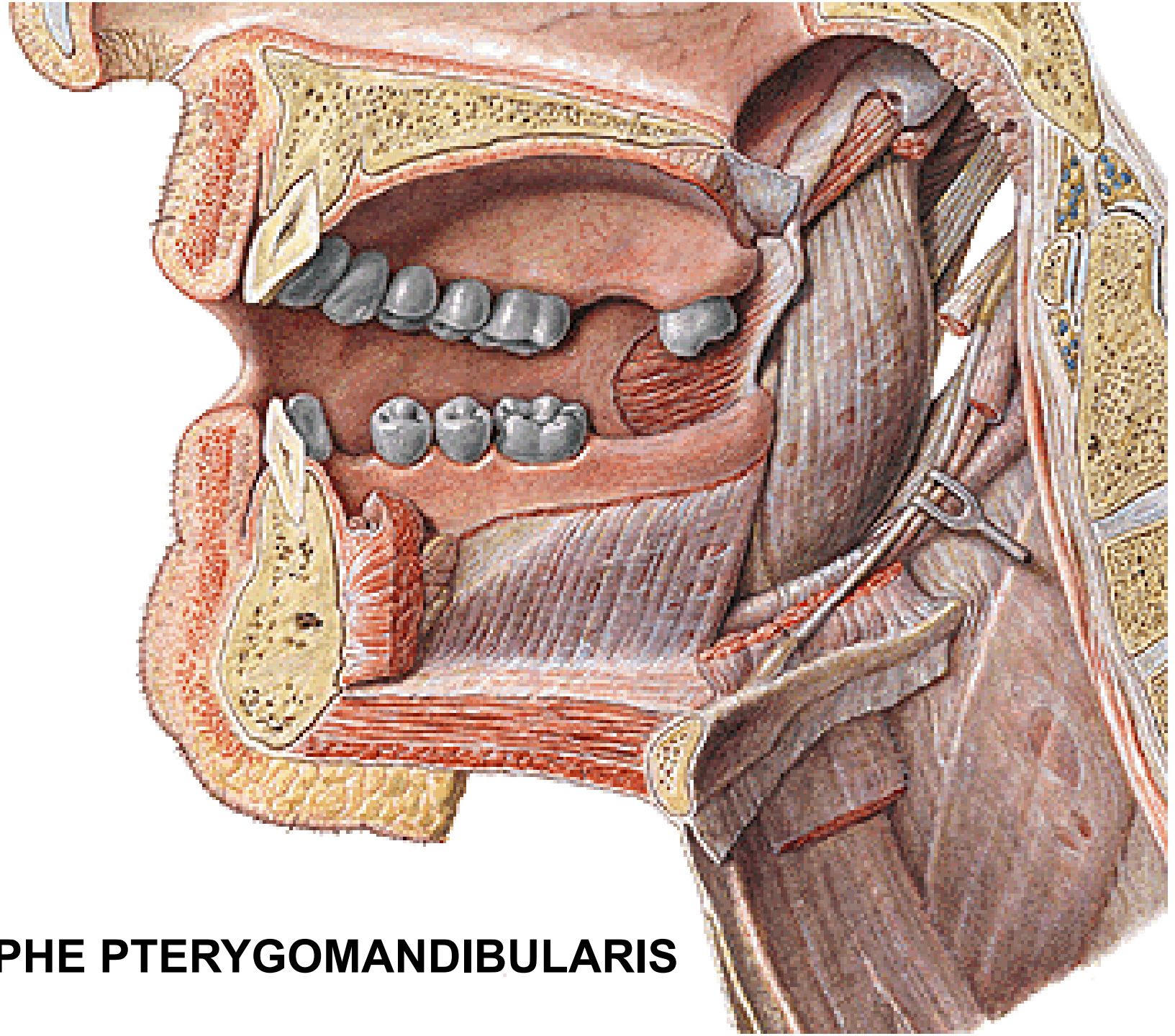
**Glandulae labiales, buccales**

**M. orbicularis oris**

**M. buccinator**

**Corpus adiposum buccae**





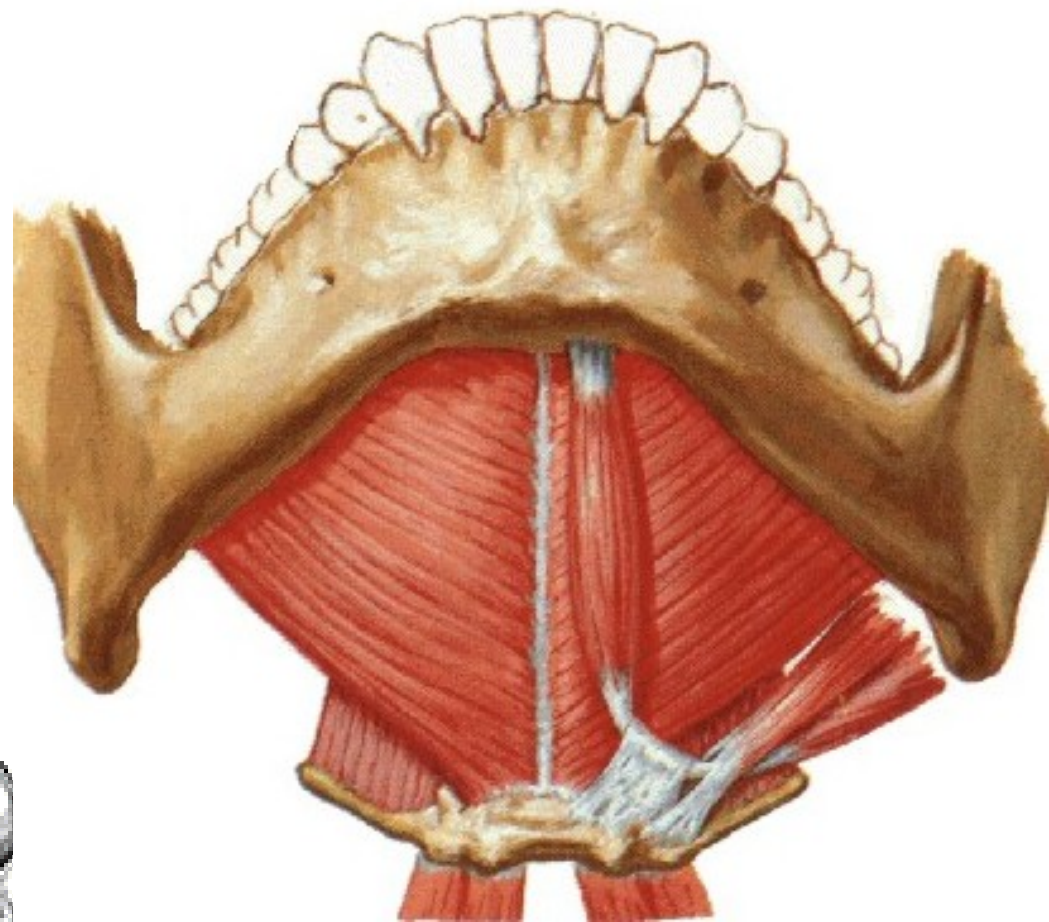
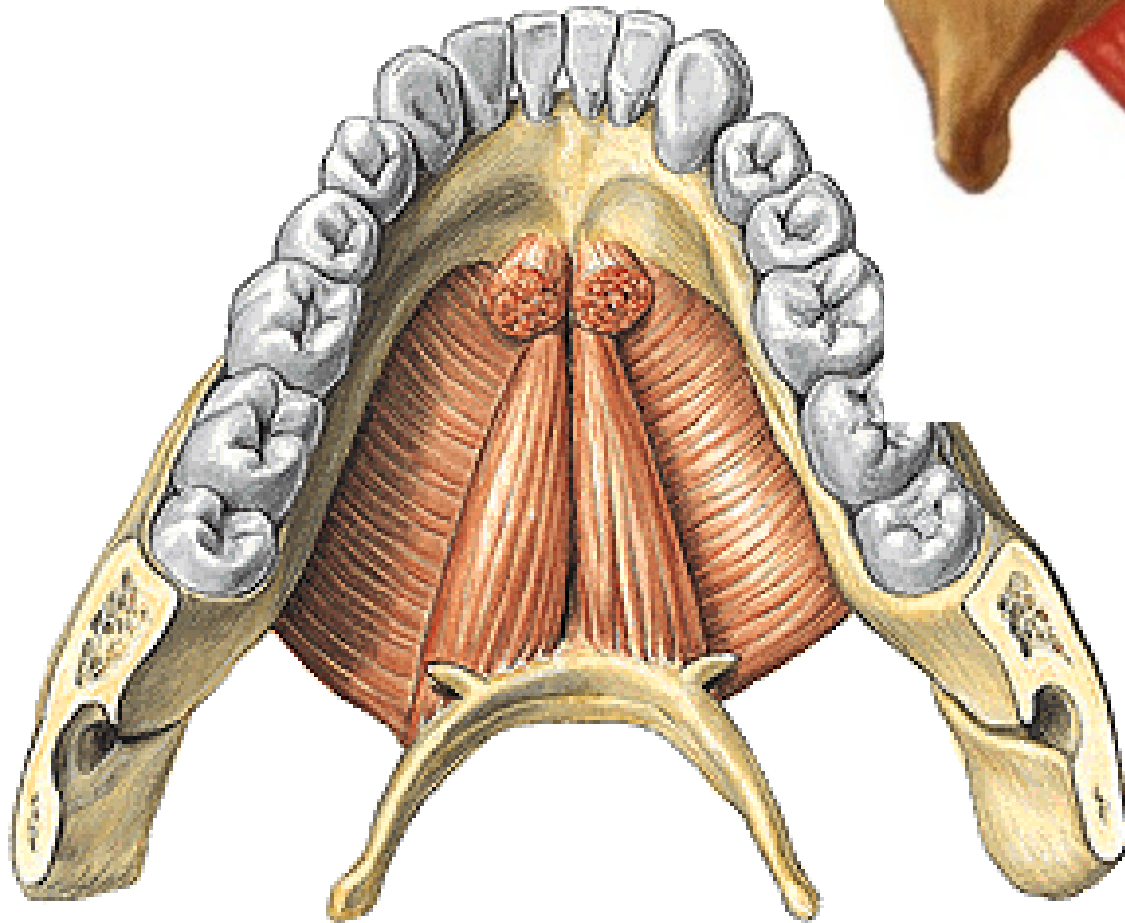
**RAPHE PTERYGOMANDIBULARIS**

# CAVUM ORIS PROPRIUM



## DIAPHRAGMA ORIS

- m. mylohyoideus  
(raphe mylohyoidea)
- m. geniohyoideus
- m. digastricus



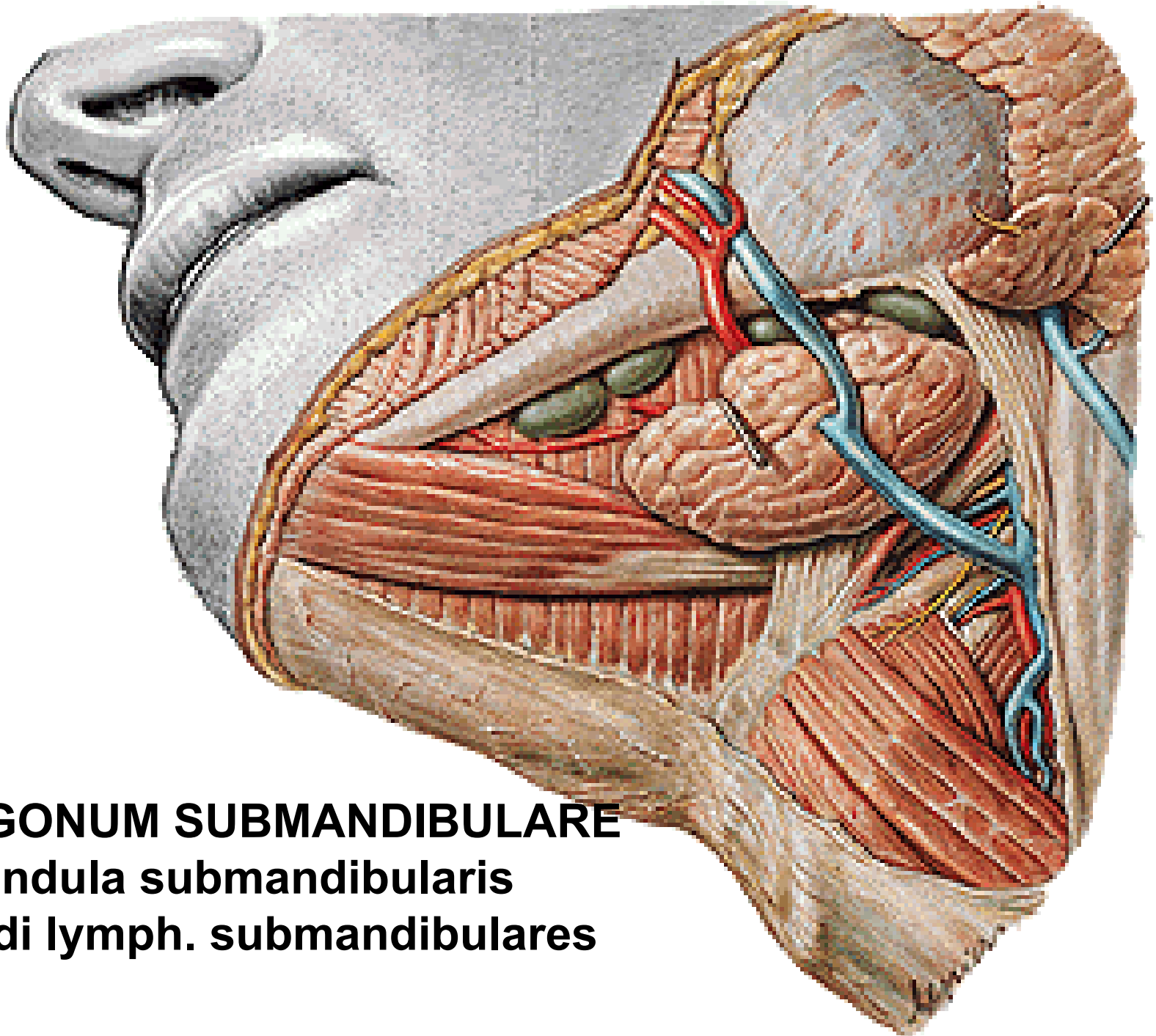


## **GLANDULAE SALIVARIAE MINORES**

- labiales, buccales, molares, palatinae, linguales

## **GLANDULAE SALIVARIAE MAJORES**

- submandibularis
- sublingualis
- parotis



## **TRIGONUM SUBMANDIBULARE**

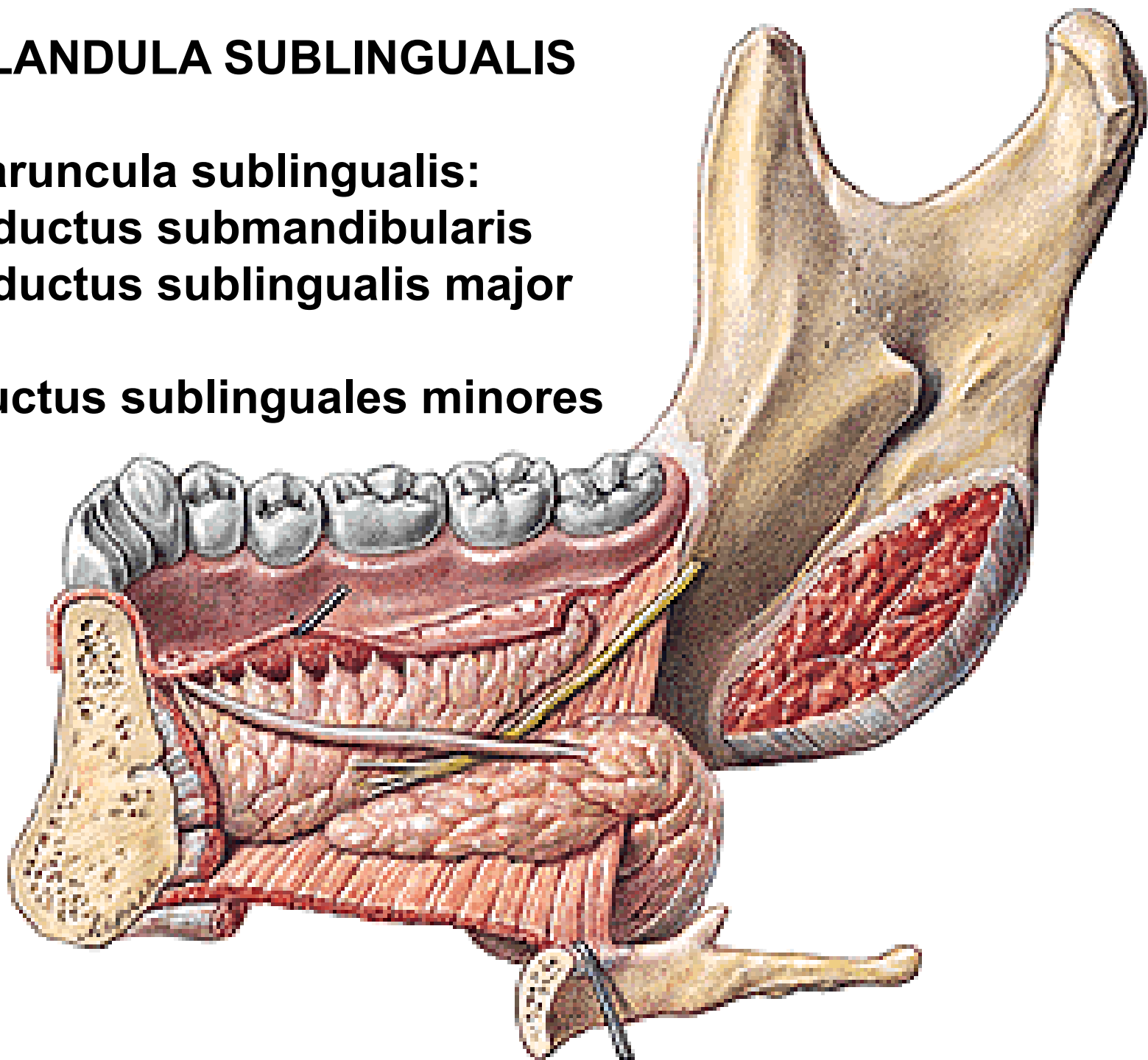
- glandula submandibularis**
- nodi lymph. submandibulares**

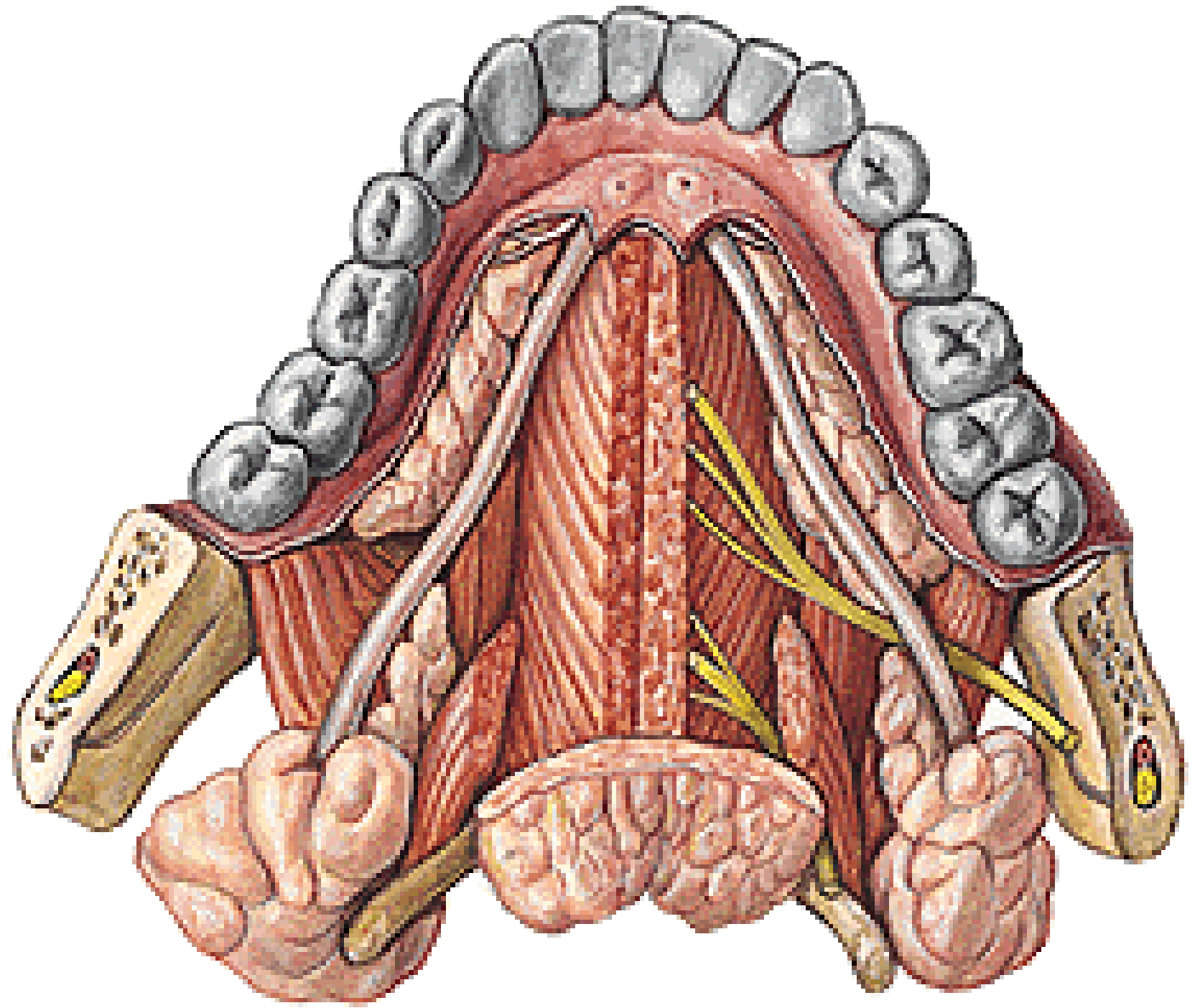
# GLANDULA SUBLINGUALIS

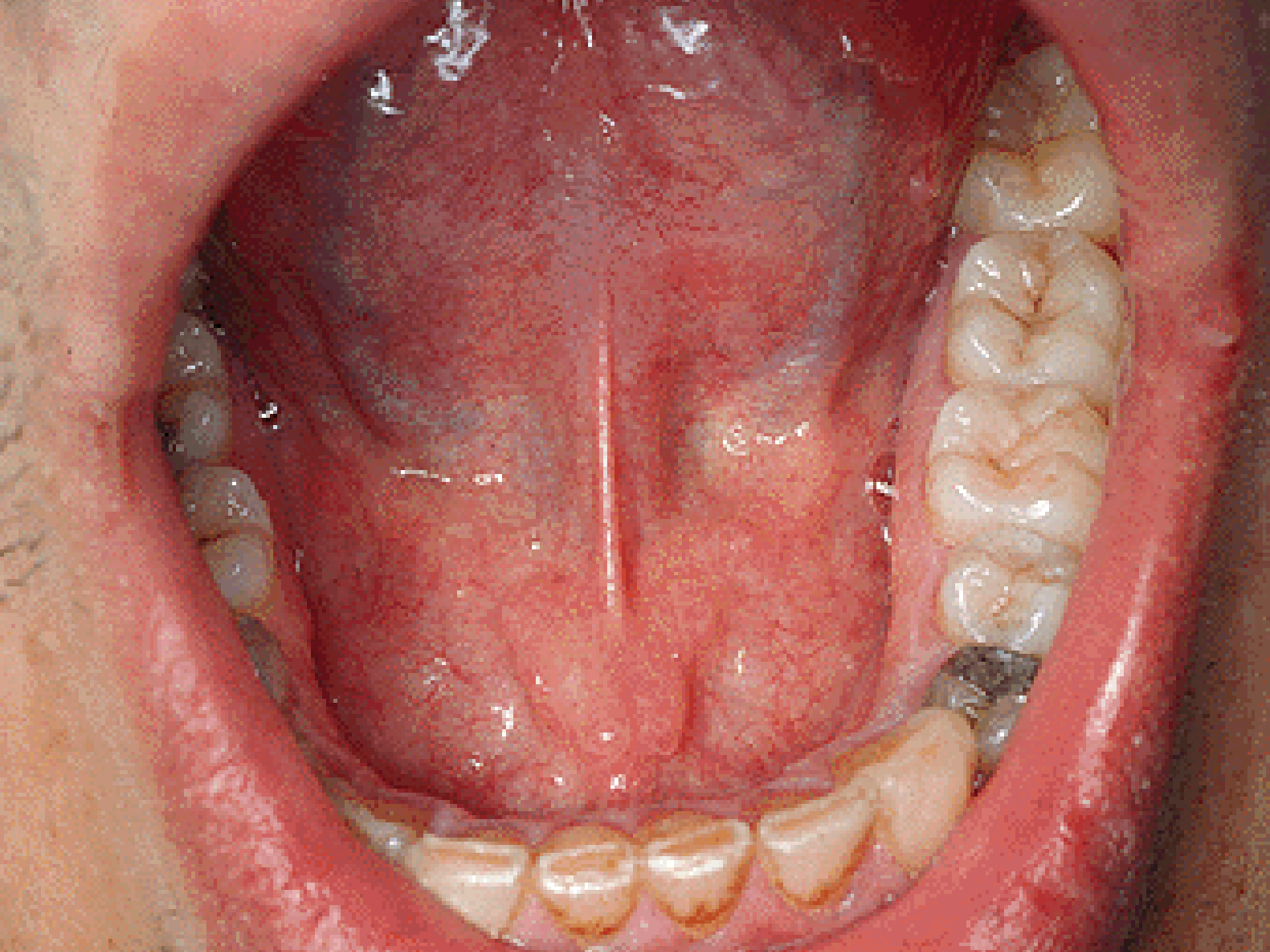**Caruncula sublingualis:**

- ductus submandibularis
- ductus sublingualis major

**Ductus sublinguales minores**



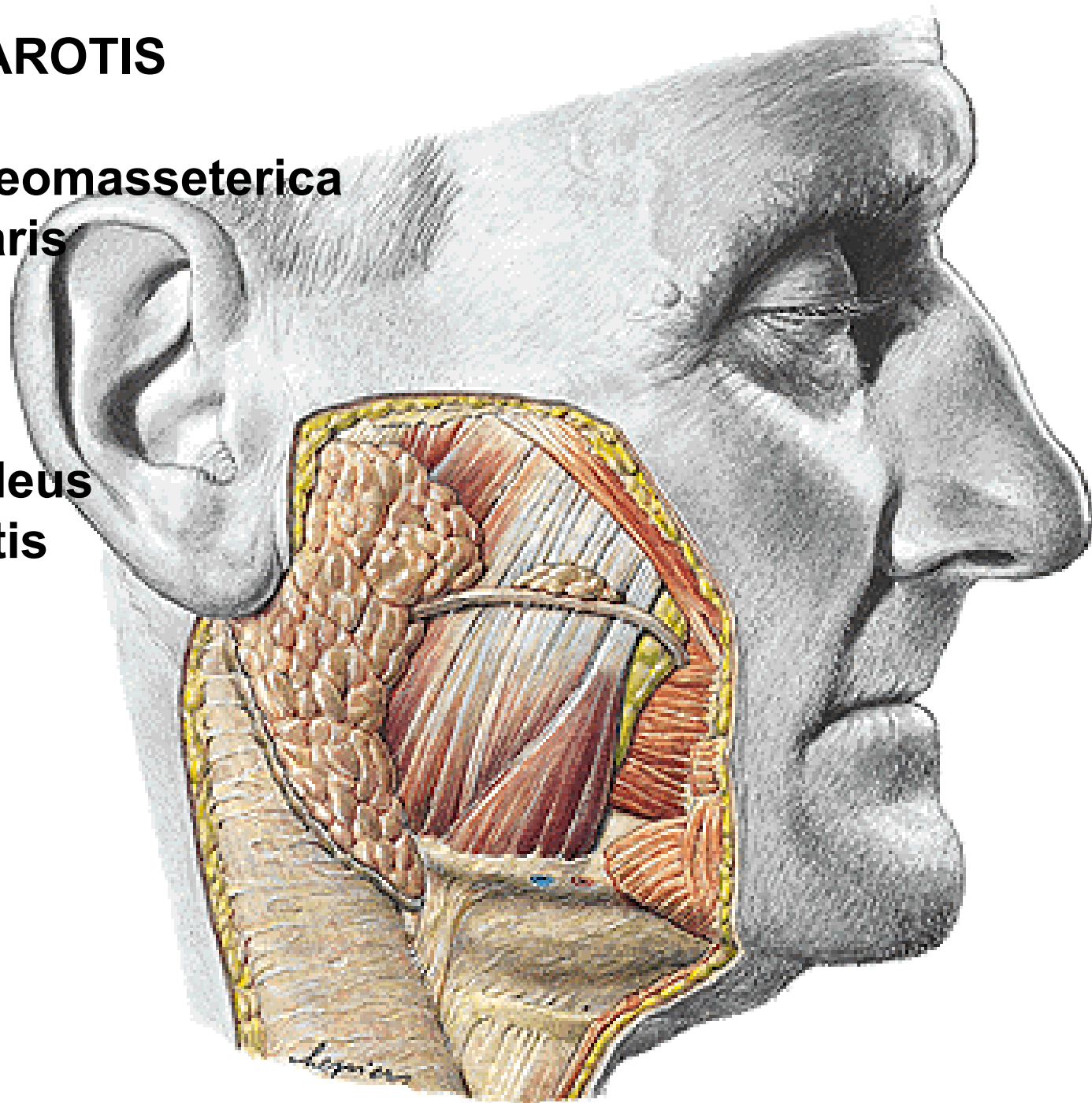




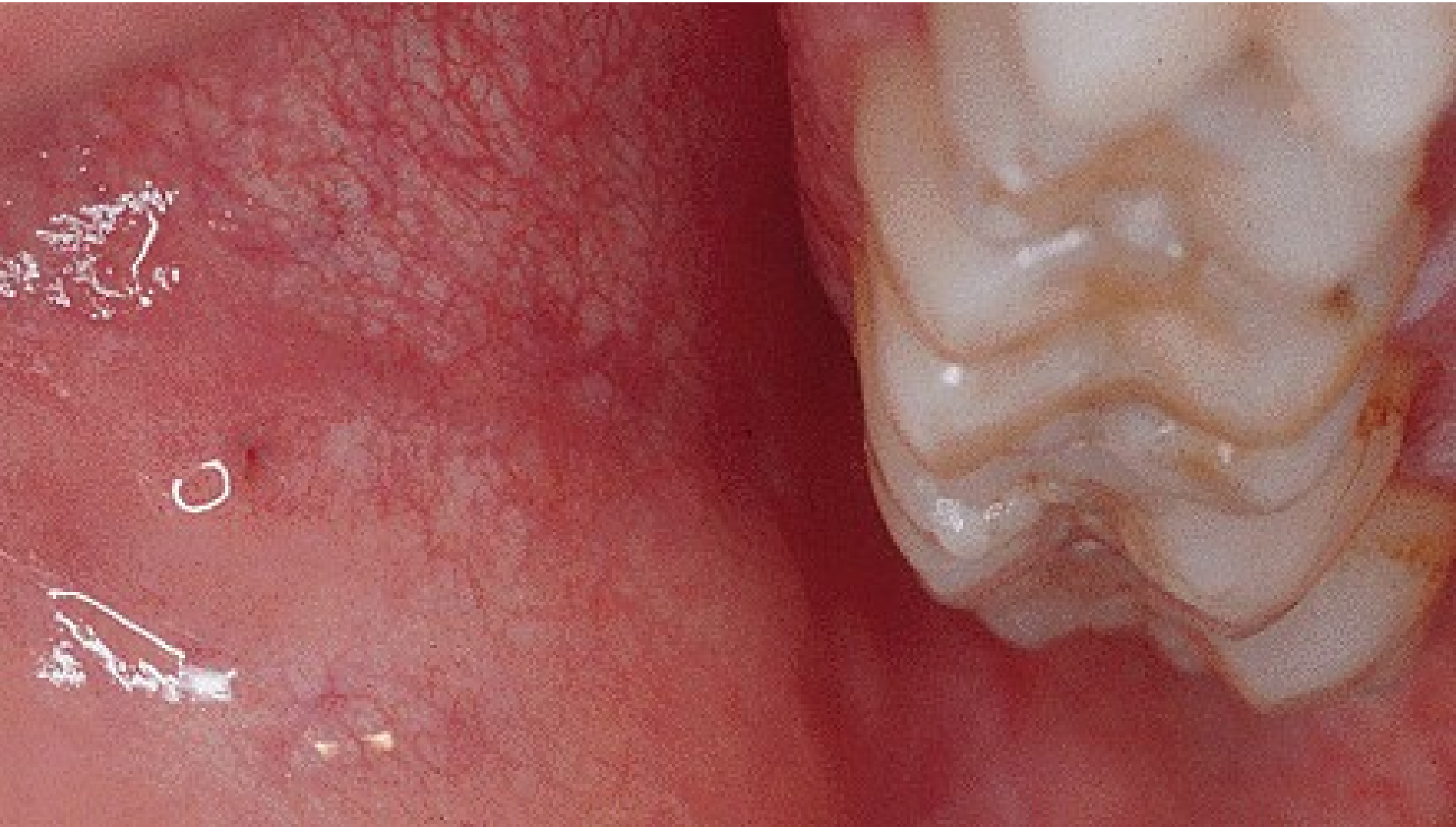# GLANDULA PAROTIS

Fascia parotideomasseterica  
Tractus angularis

Ductus parotideus  
Glandula parotis  
accessoria



# PAPILLA PAROTIDEA

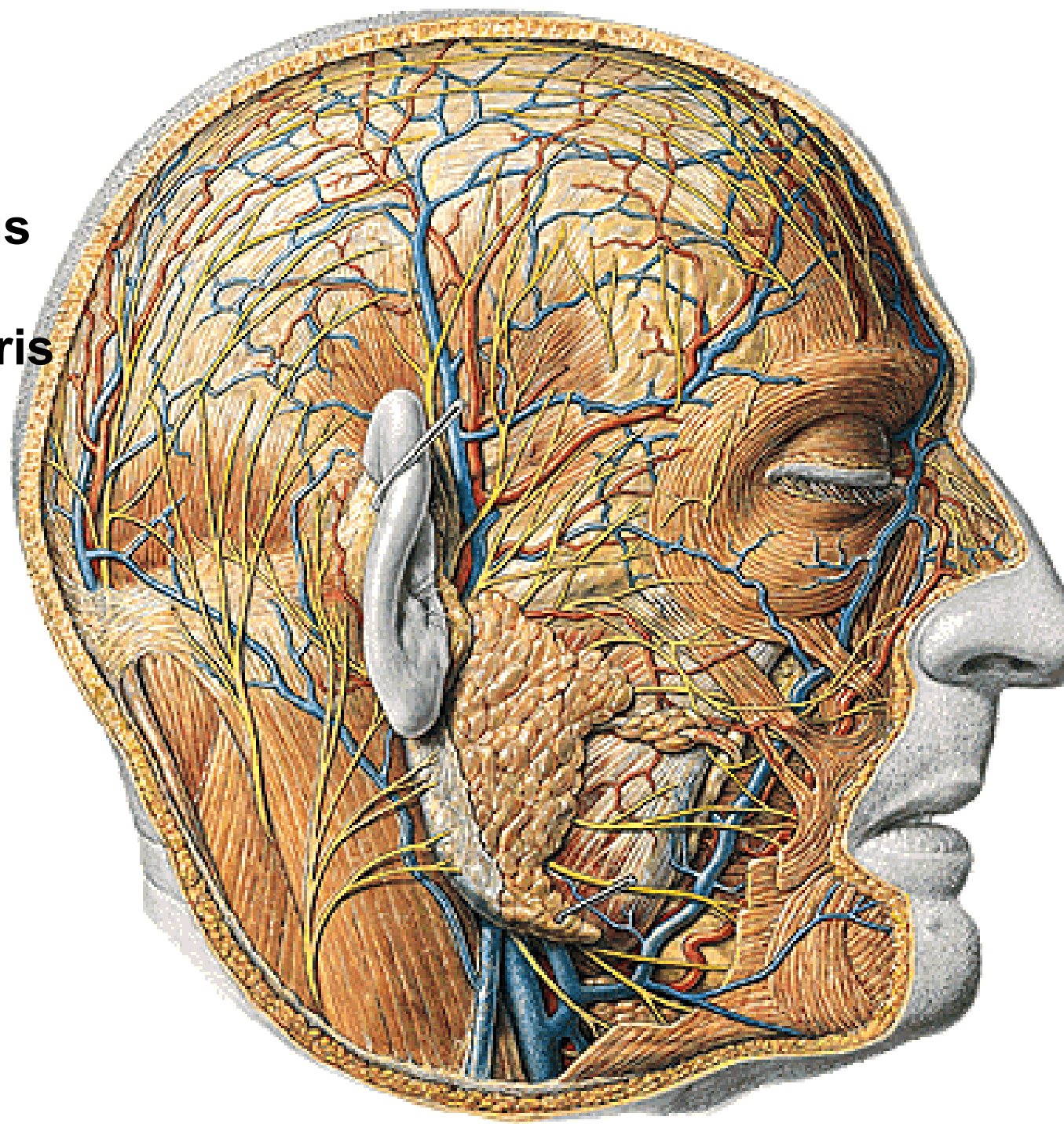


**N. facialis (CN VII)**

**- plexus parotideus**

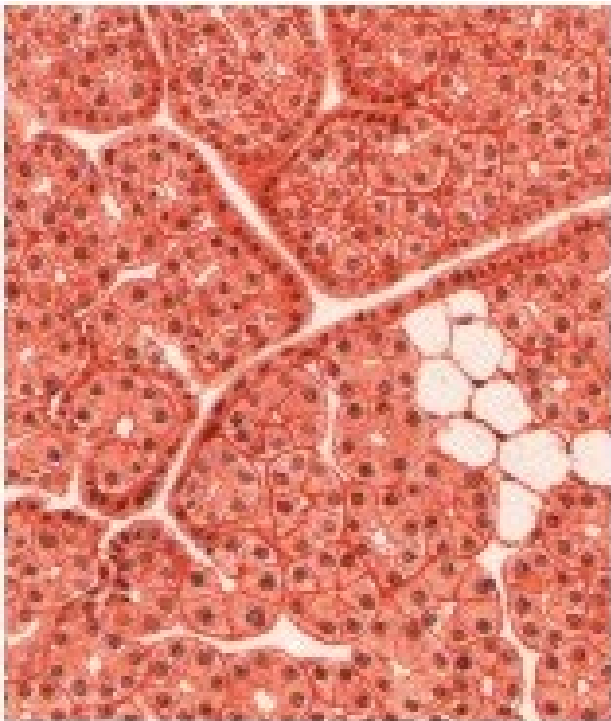
**V. retromandibularis**

**A. carotis ext.**

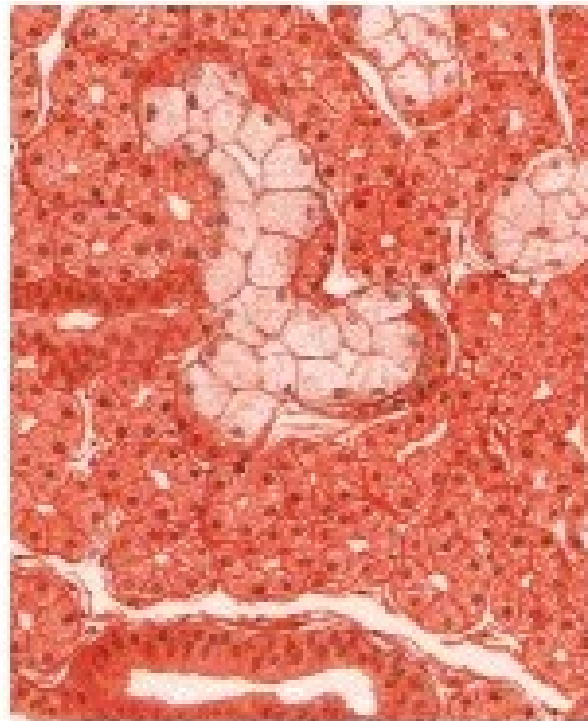




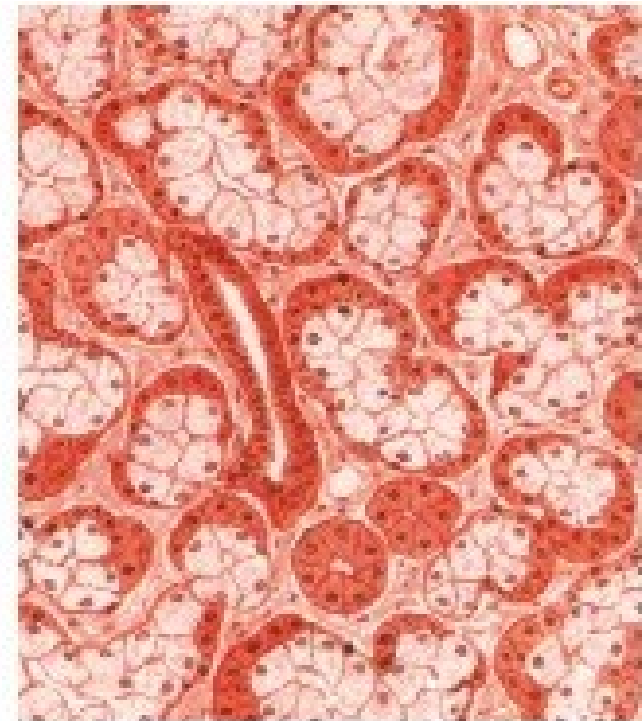
# SALIVARY GLANDS



Parotid gland: totally serous



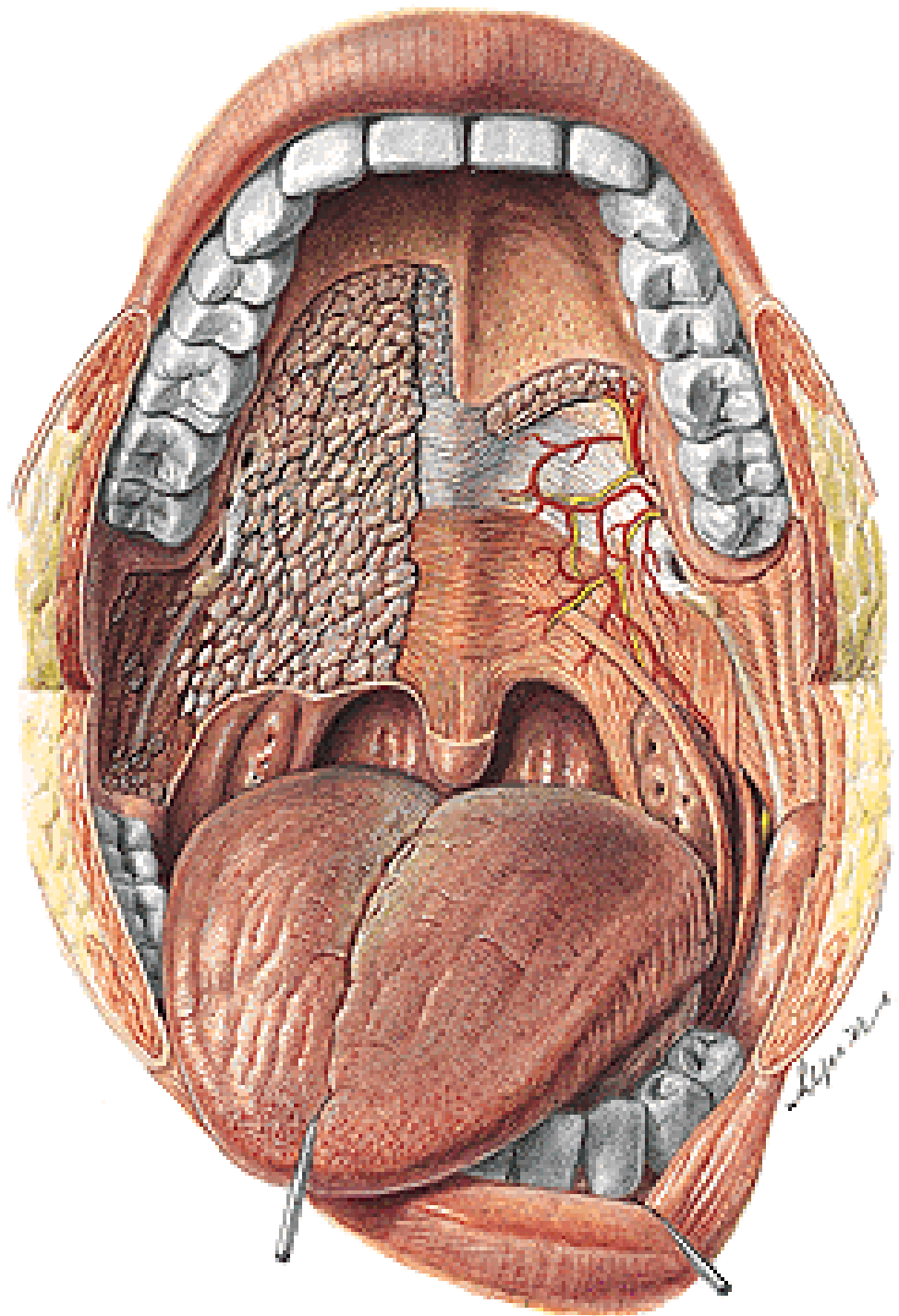
Submandibular gland:  
mostly serous, partially mucous



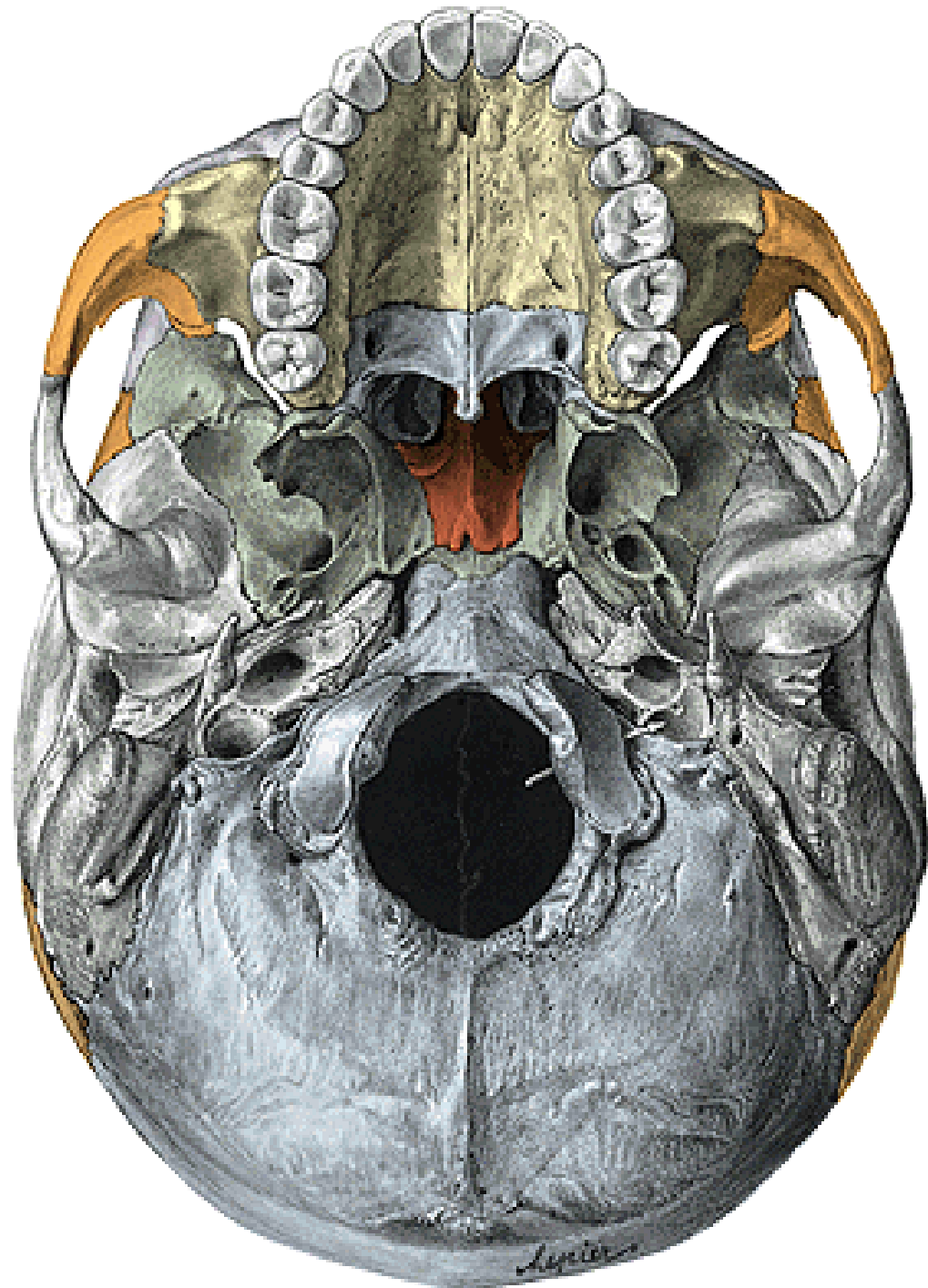
Sublingual gland:  
almost completely mucous

# PALATUM

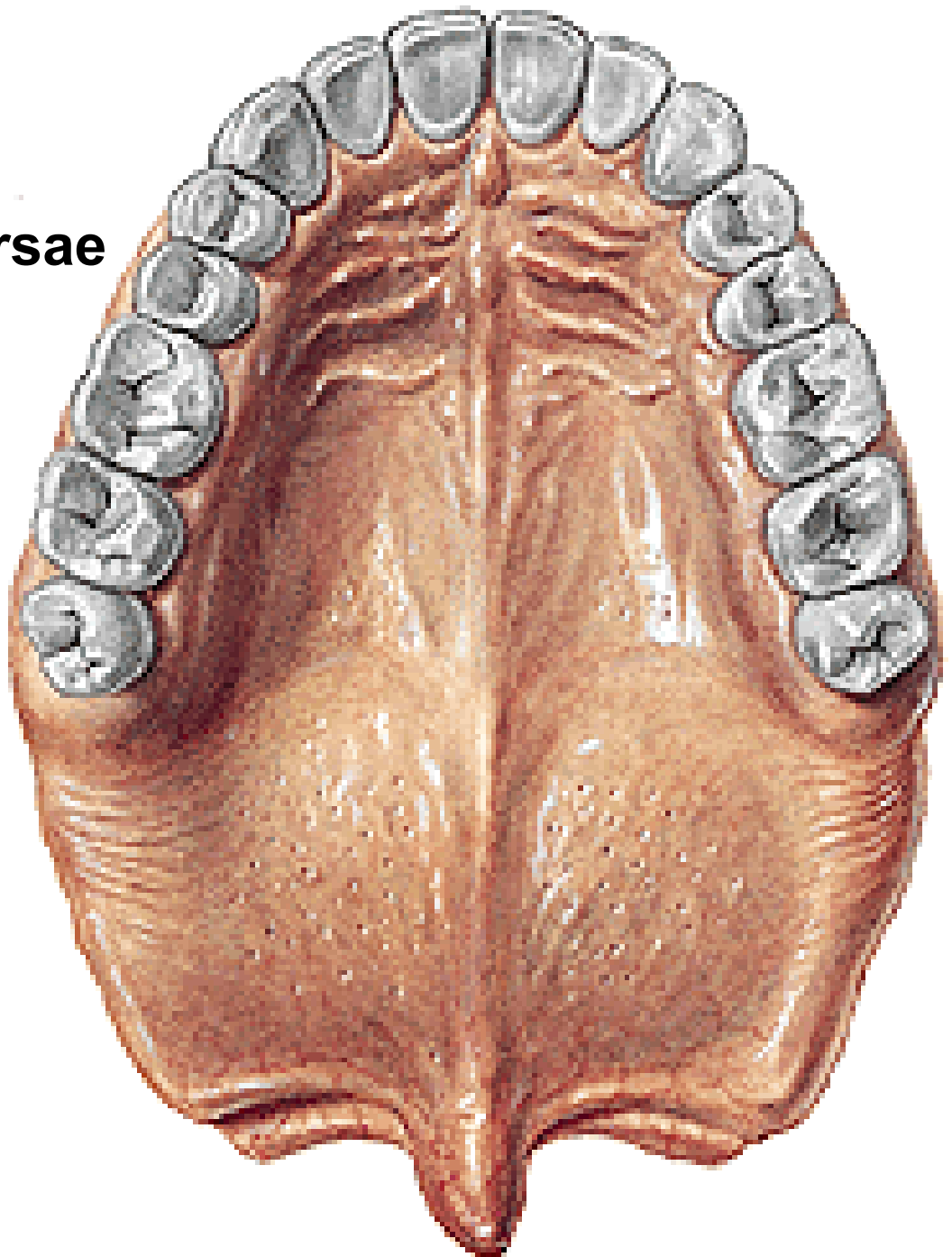
**Glandulae palatinae**  
**Aa. et vv. palatinae**  
**majores et minores**  
**Nn. palatini**  
**majores et minores**  
**N. nasopalatinus**



# PALATUM DURUM

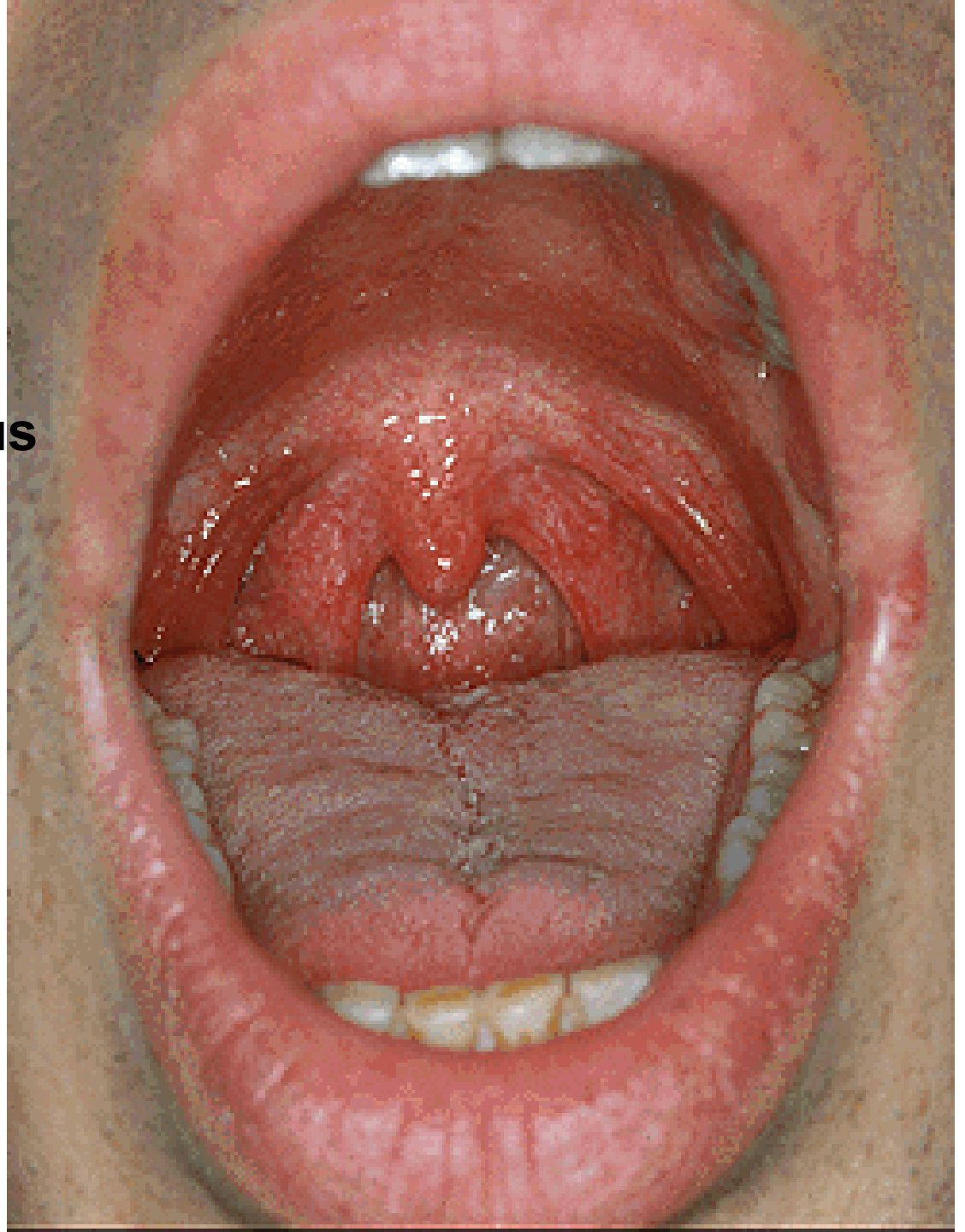


**Raphe palati**  
**Papilla incisiva**  
**Plicae palatinae transversae**



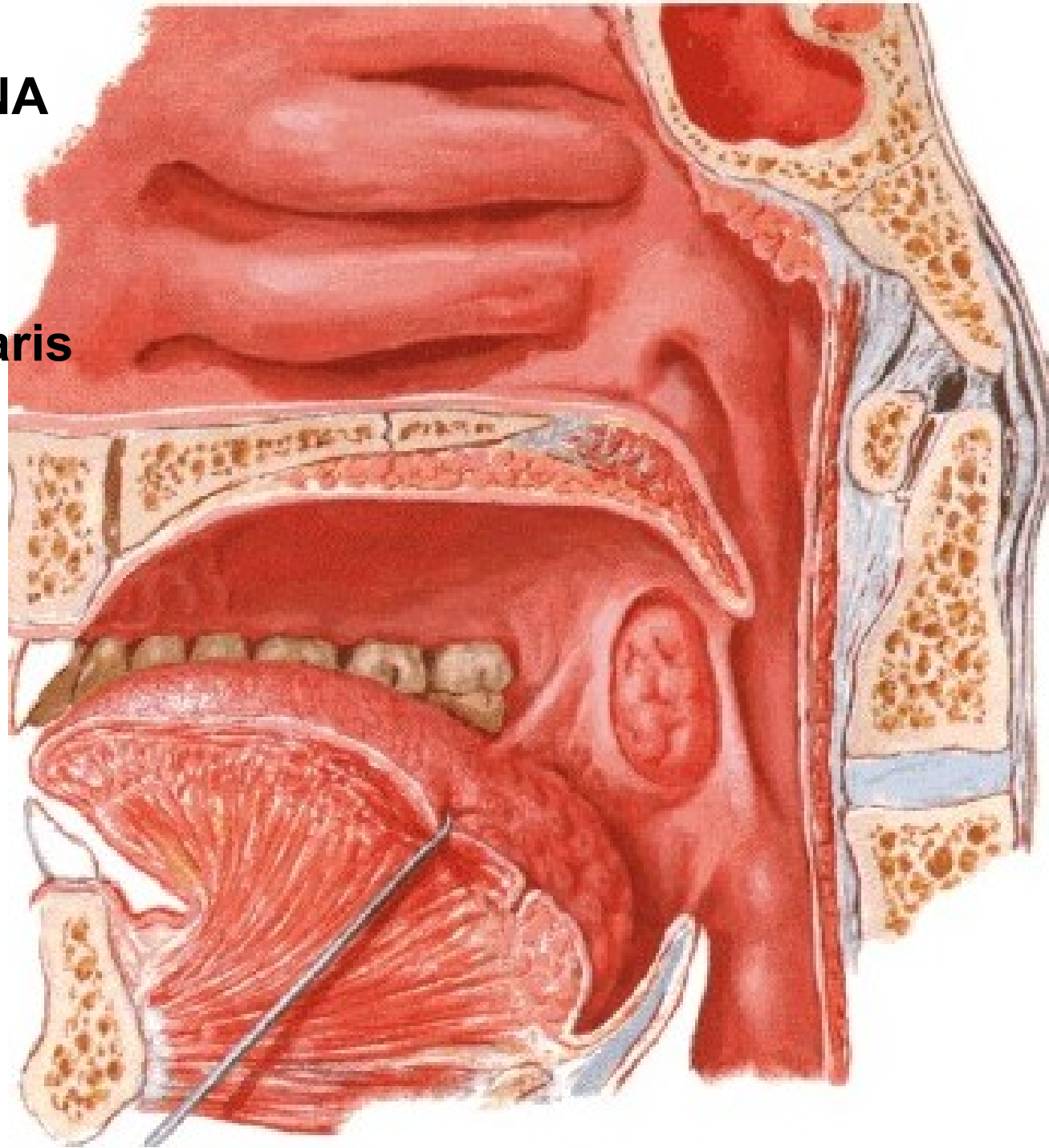
**PALATUM MOLLE  
(VELUM PALATINUM)**

- Uvula**
- Arcus palatoglossus**
- Arcus palatopharyngeus**
- Isthmus faucium**



# **TONSILLA PALATINA**

- Fossa tonsillaris**
- Plica semilunaris**
- Fossa supratonsillaris**
- Plica triangularis**
- Capsula tonsillaris**
- Paratonsillar vein**
- Cryptae tonsillares**
- Tonsillar pegs**

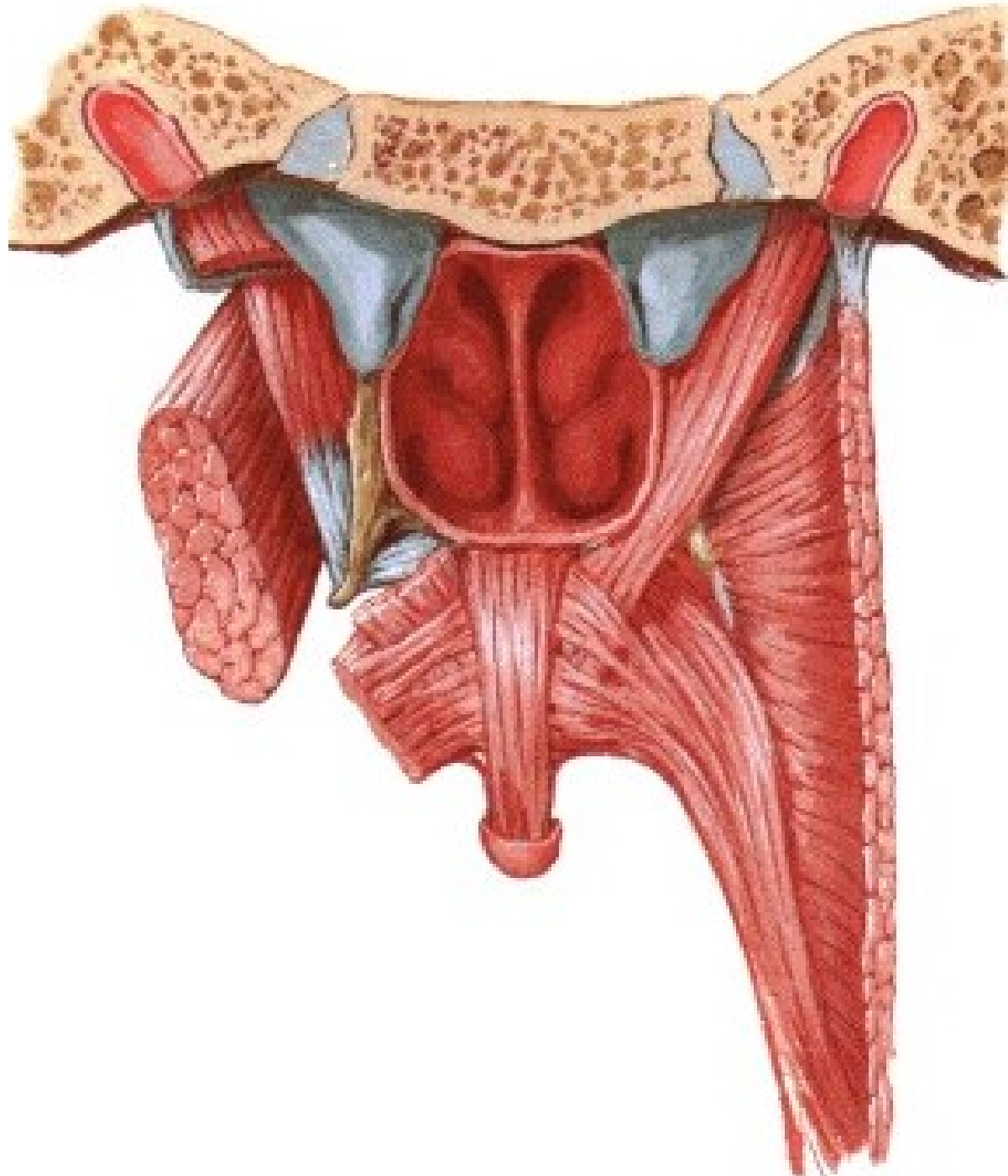


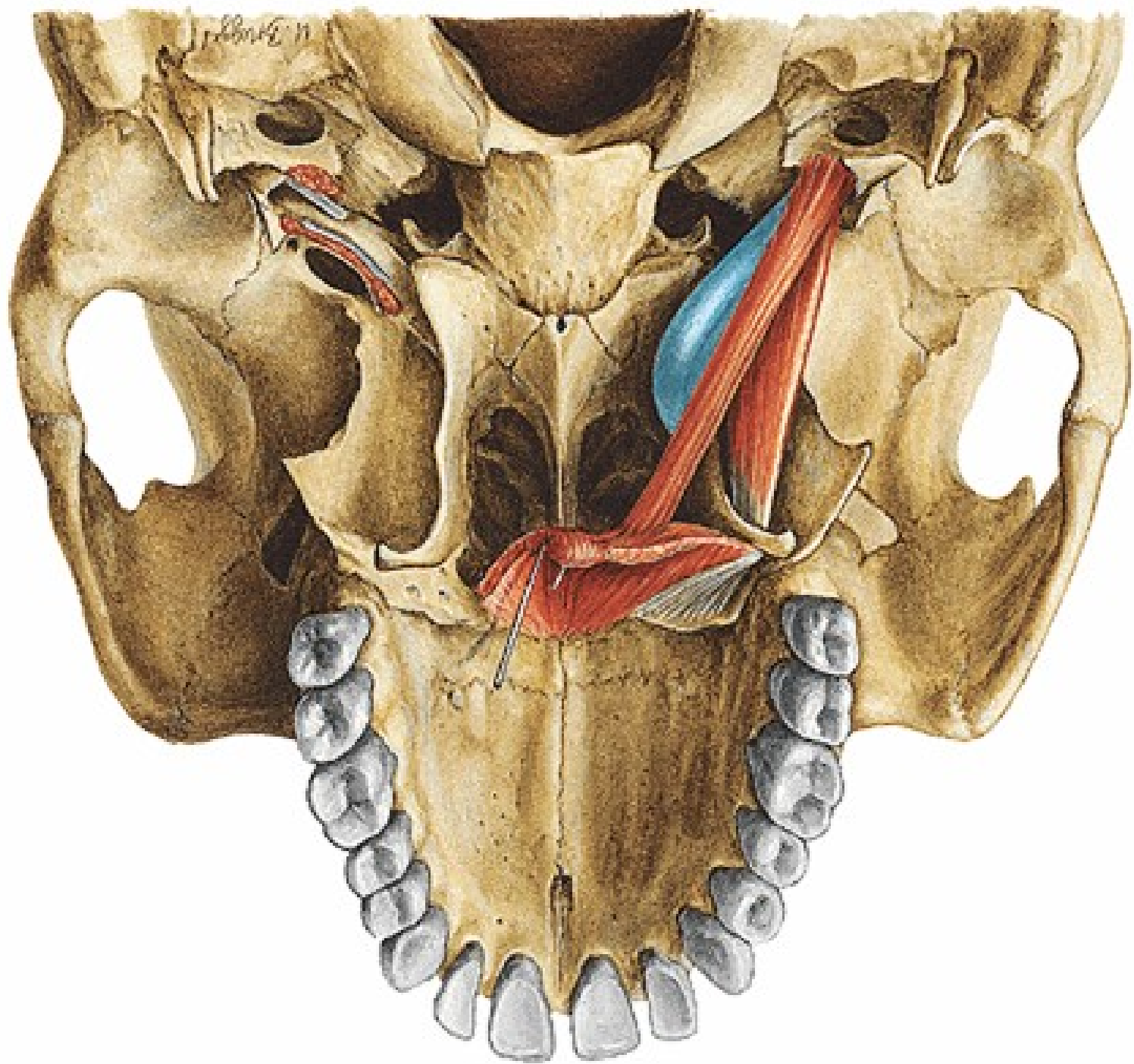
**M. levator veli palatini**  
**M. tensor veli palatini**  
**M. uvulae**  
**M. palatopharyngeus**  
**M. palatoglossus**

**Aponeurosis palatina**

**Plexus pharyngeus**  
**– CN IX, X**

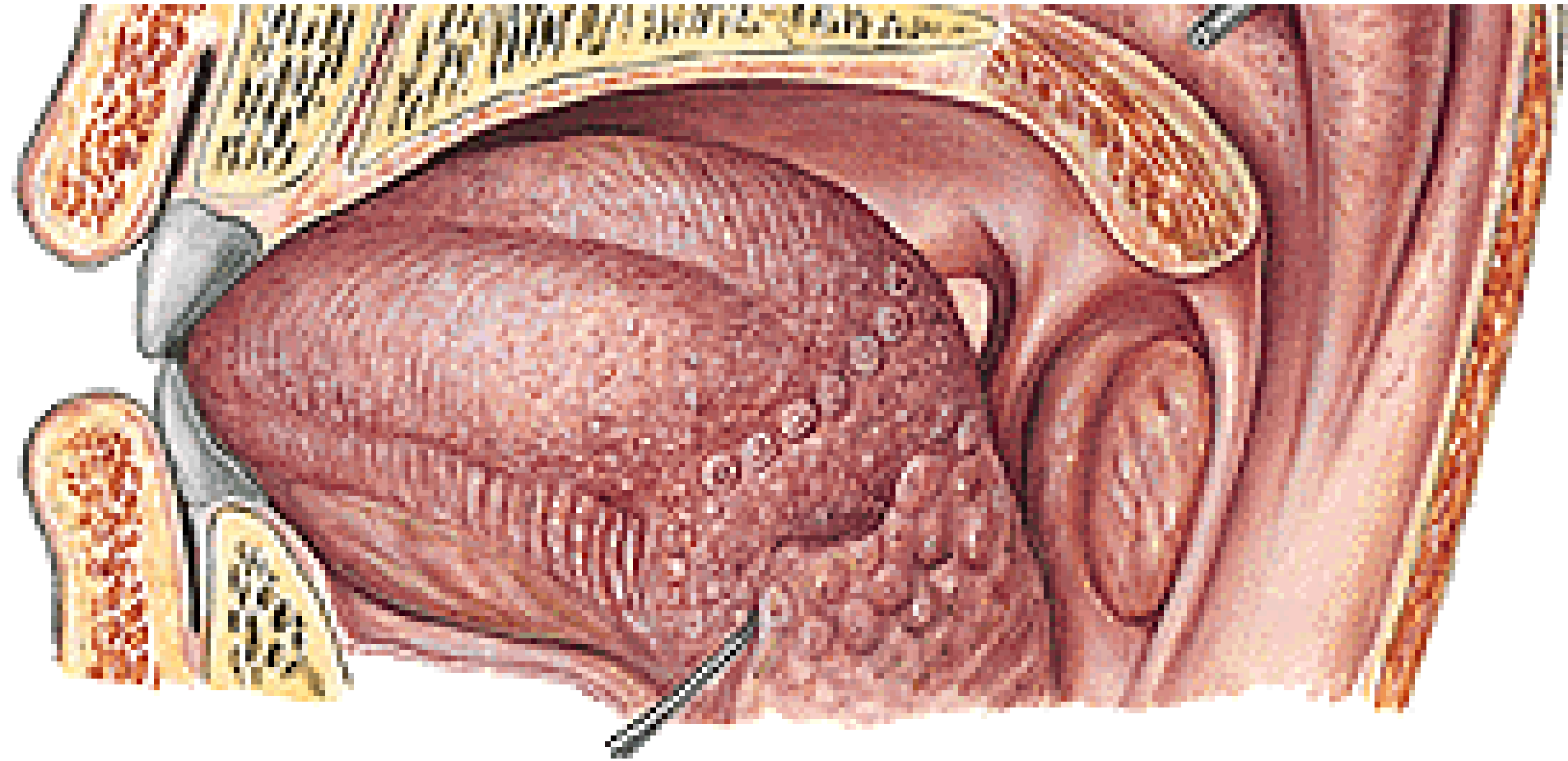
**Tensor – CN V**







# LINGUA – APEX, CORPUS, RADIX



# **DORSUM LINGUAE**

**Sulcus terminalis**

**Sulcus medianus**

**Foramen caecum**

**Ductus thyroglossus**

**Margines linguae**

**Papillae filiformes**

**Papillae fungiformes**

**Papillae foliatae**

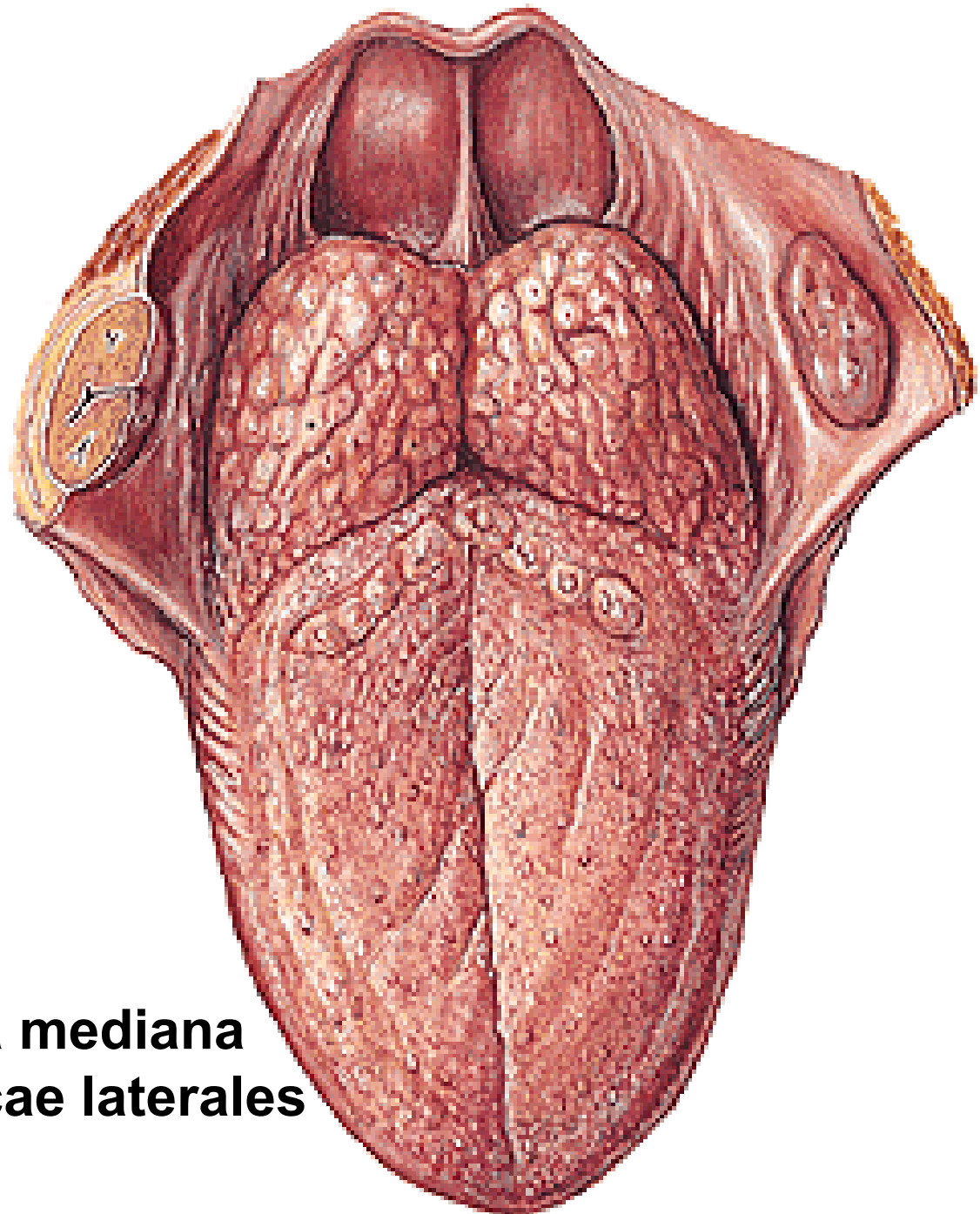
**Papillae vallatae**

**Tonsilla lingualis**

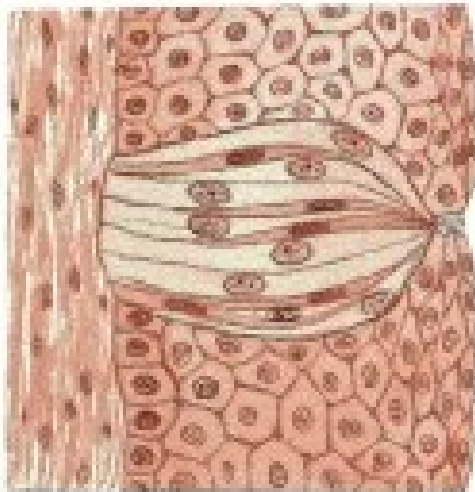
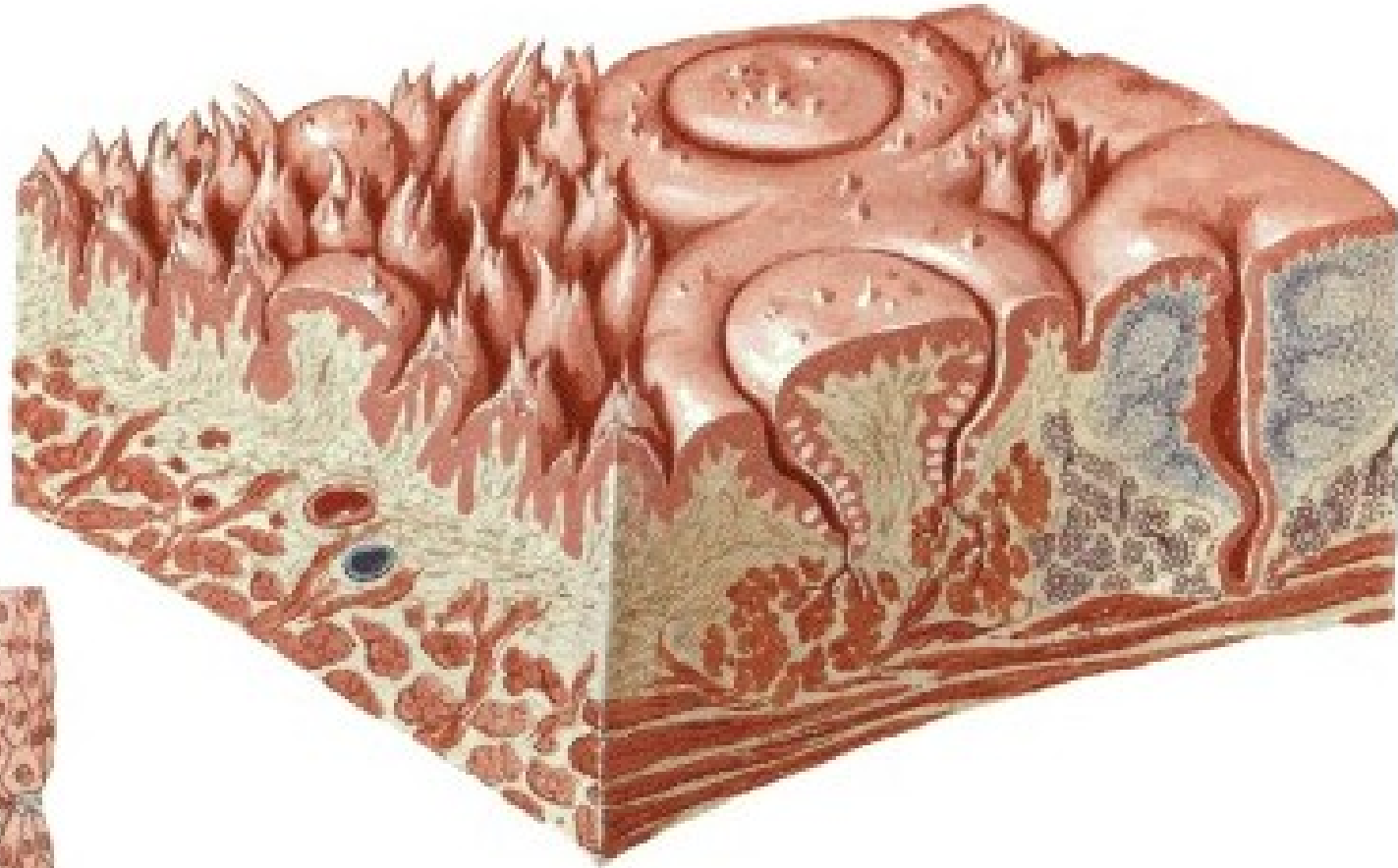
**Plica glossoepiglottica mediana**

**Plicae glossoepiglotticae laterales**

**Valleculae epiglotticae**

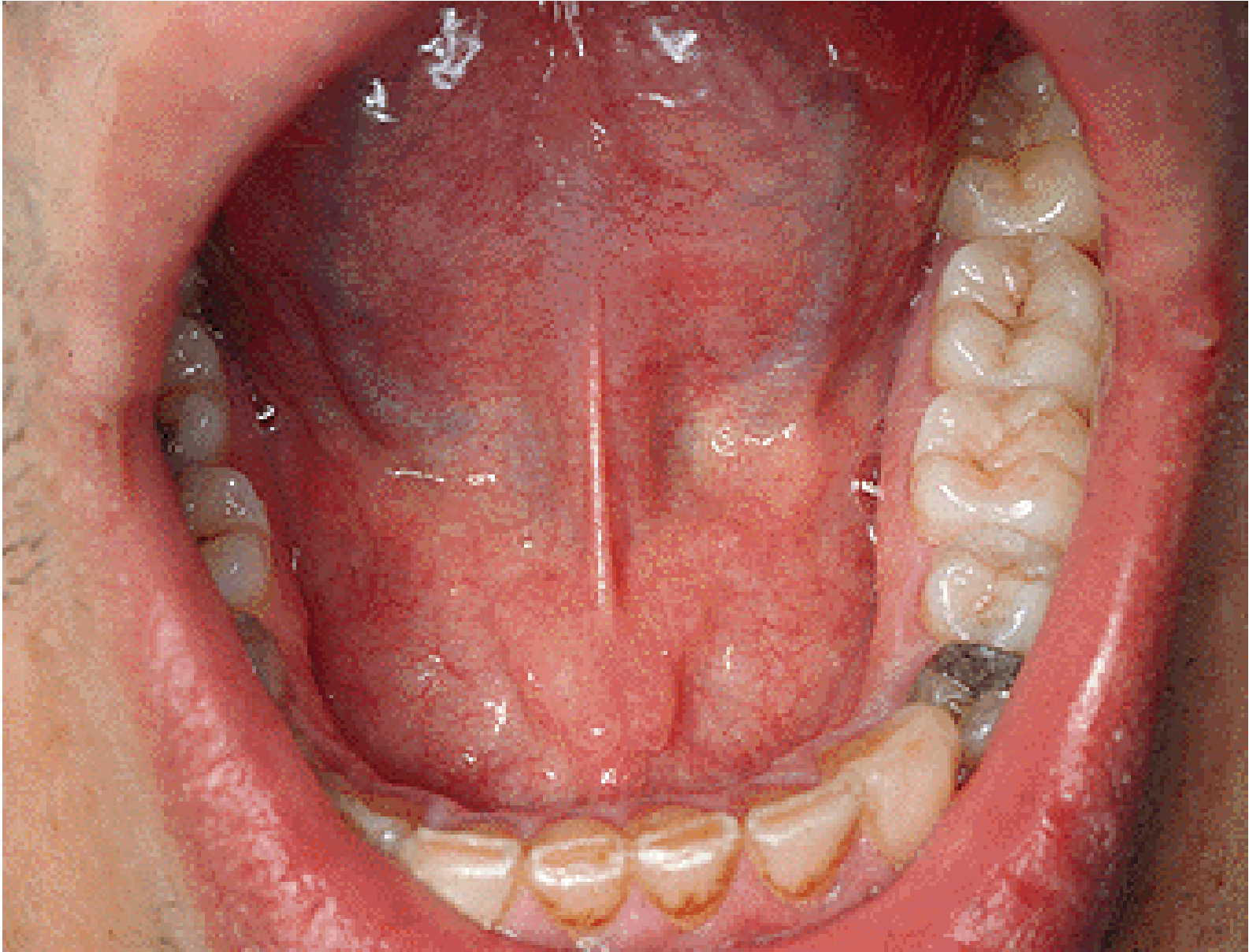

# Caliculi gustatorii



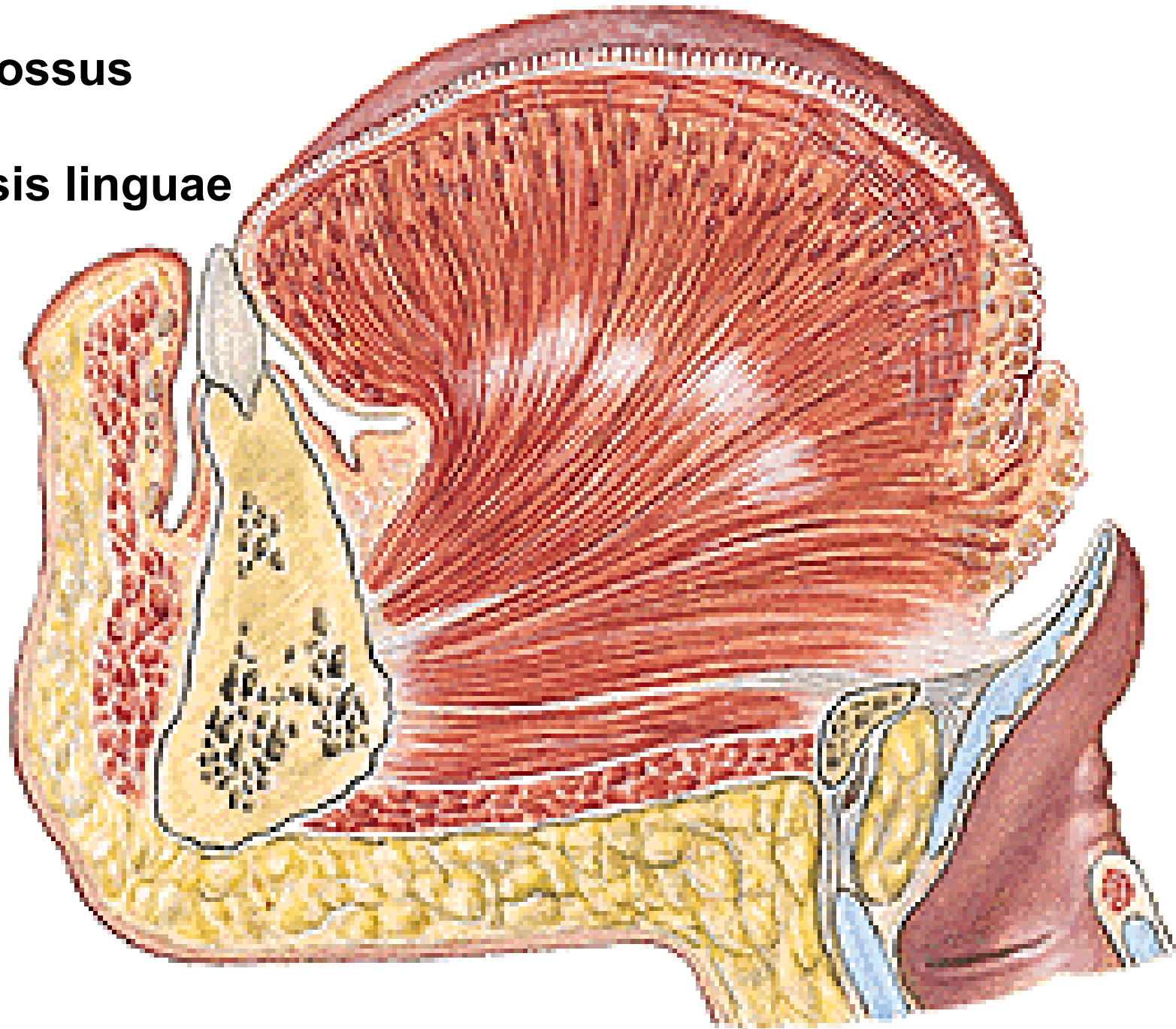
**Facies inferior linguae**  
**Plica fimbriata**

**Frenulum linguae**  
**Plica sublingualis**

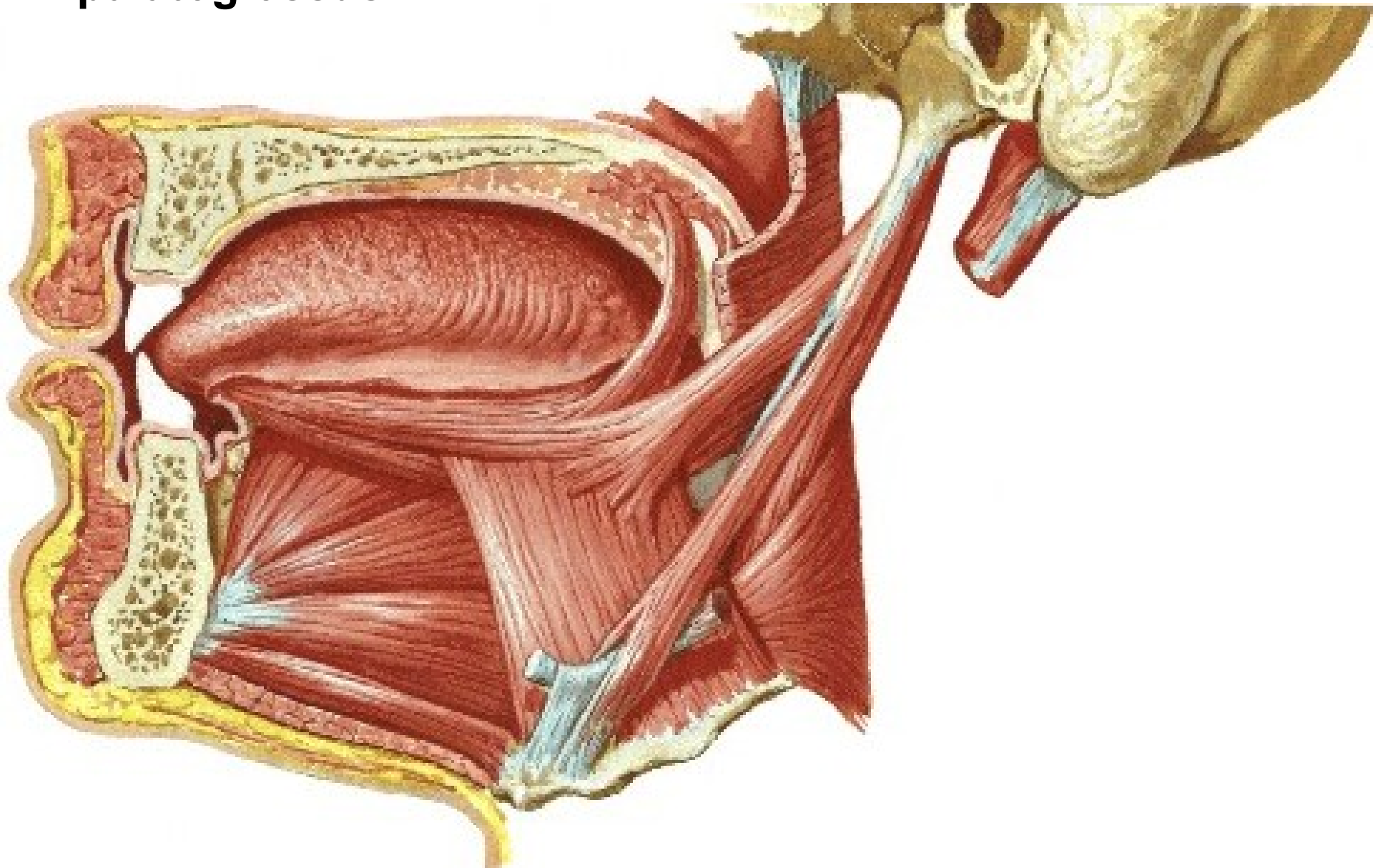


**M. genioglossus**

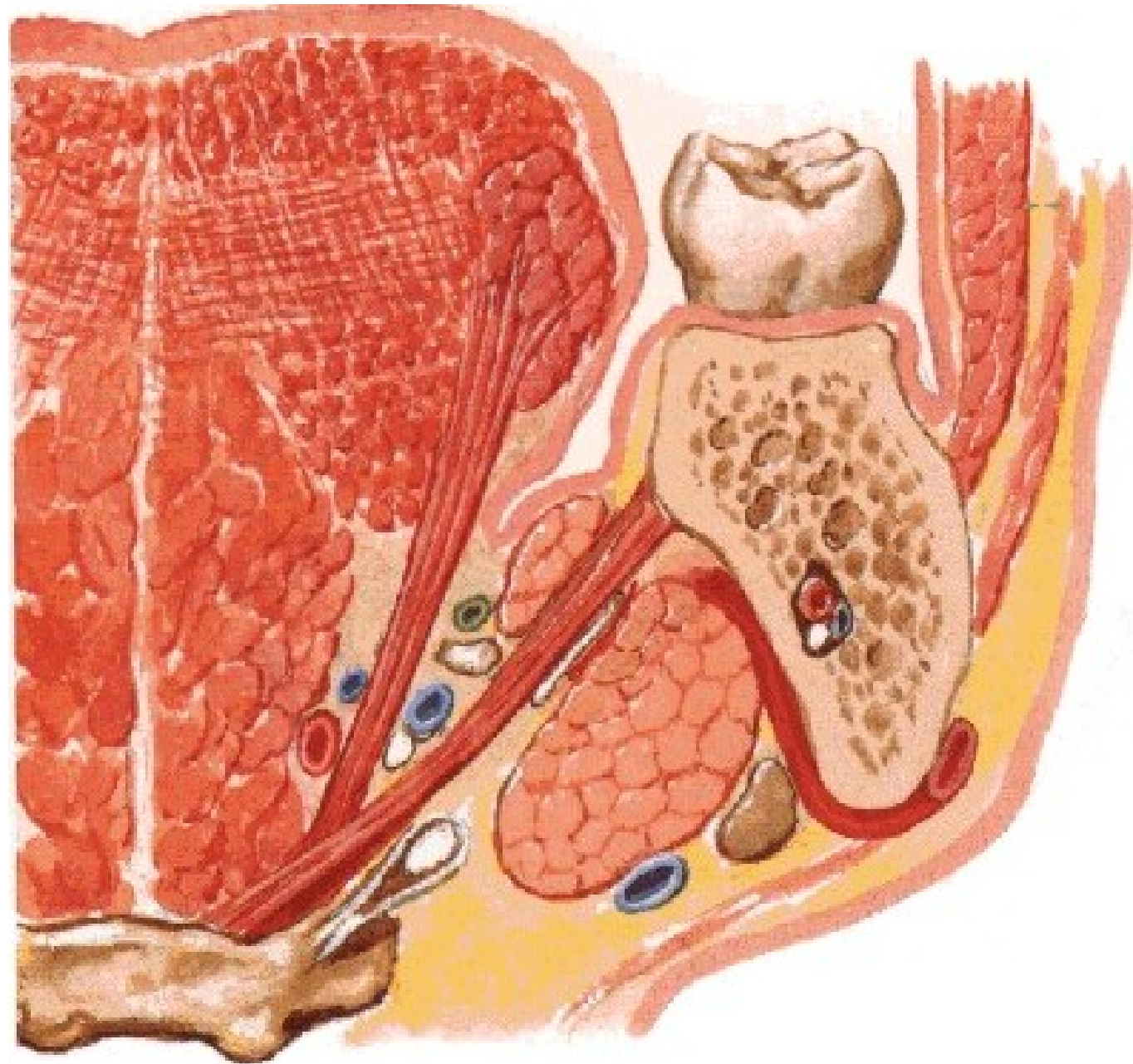
**Aponeurosis linguae**



**M. hyoglossus**  
**M. styloglossus**  
**M. palatoglossus**



# Canalis paralingualis – a. et v. lingualis



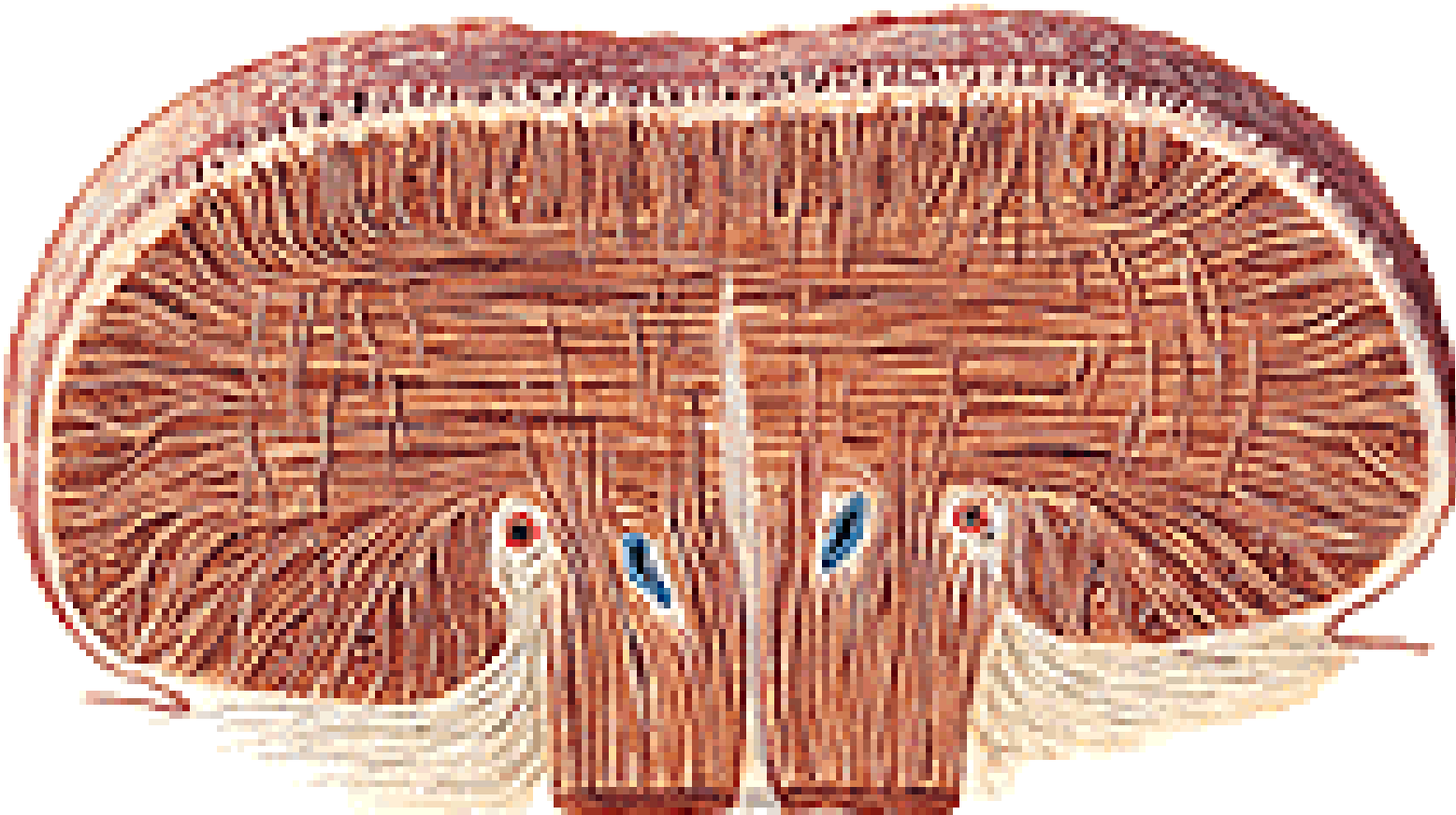
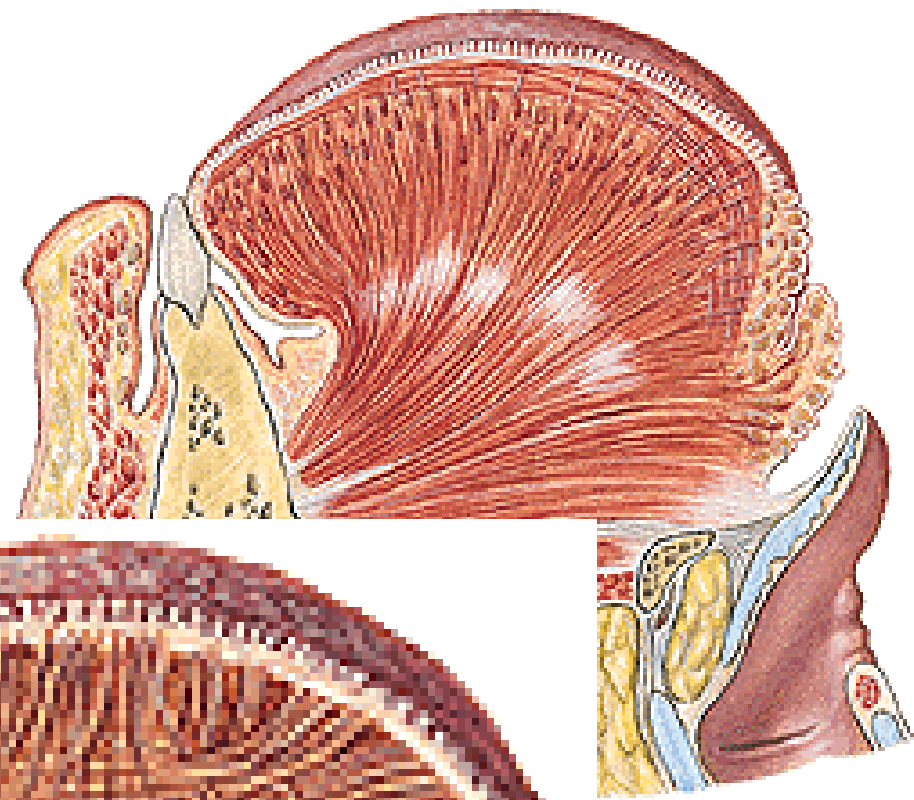
# Septum linguae

**M. longitudinalis sup.**

**M. longitudinalis inf.**

**M. transversus linguae**

**M. verticalis linguae**



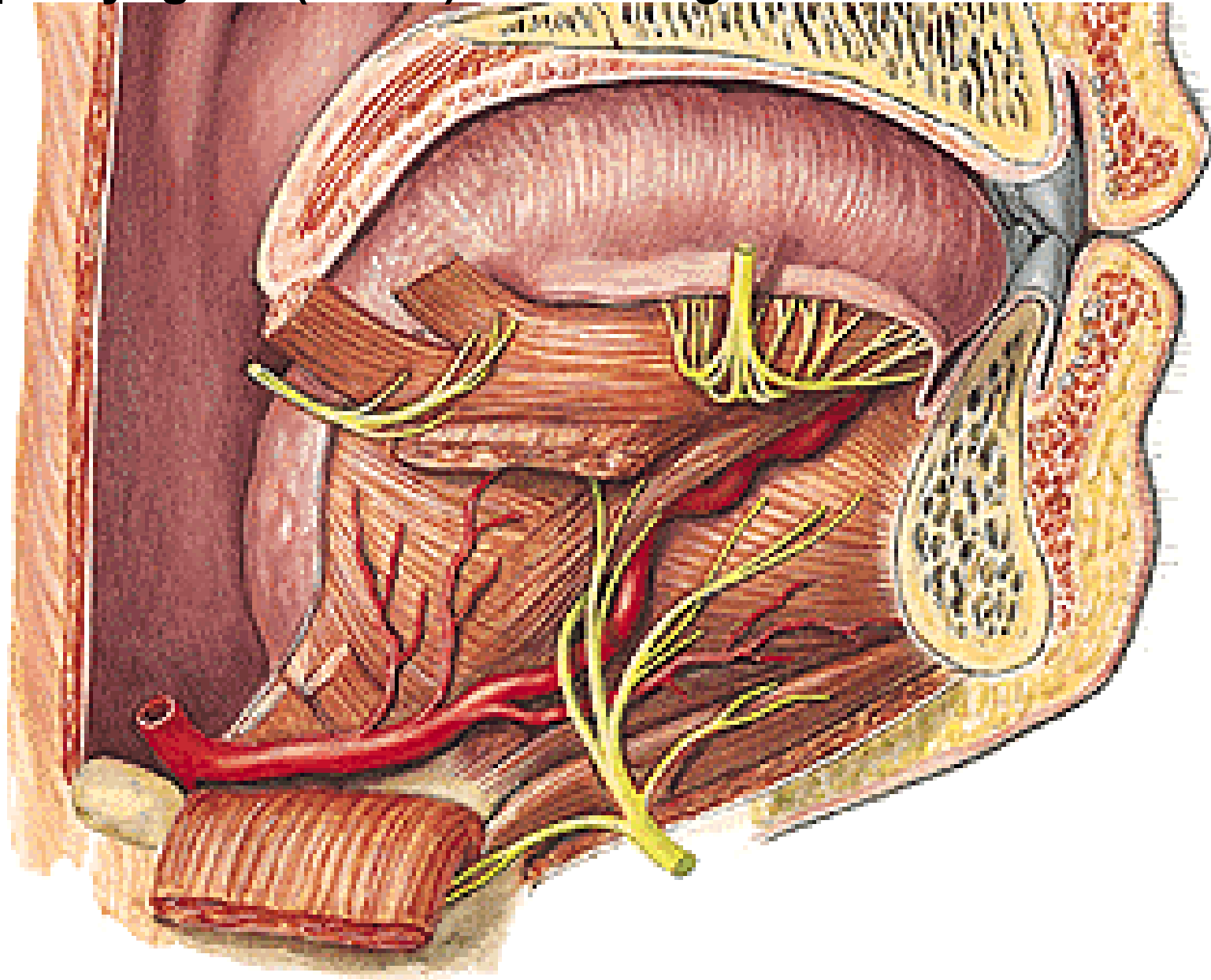


**N. lingualis**

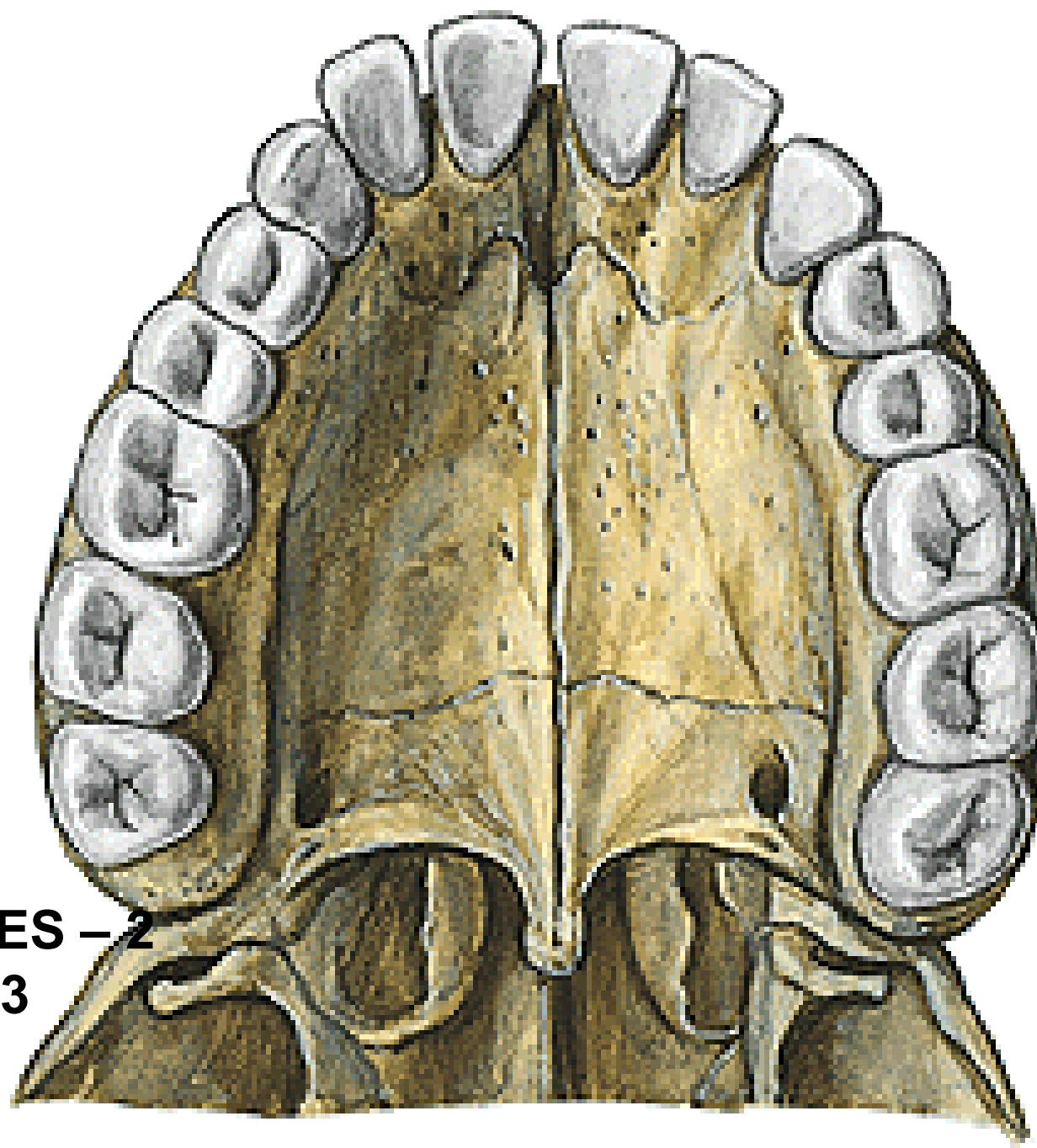
**N. glossopharyngeus (CN IX)**

**N. hypoglossus (CN XII)**

**A. lingualis**



**DENTES  
PERMANENTES**

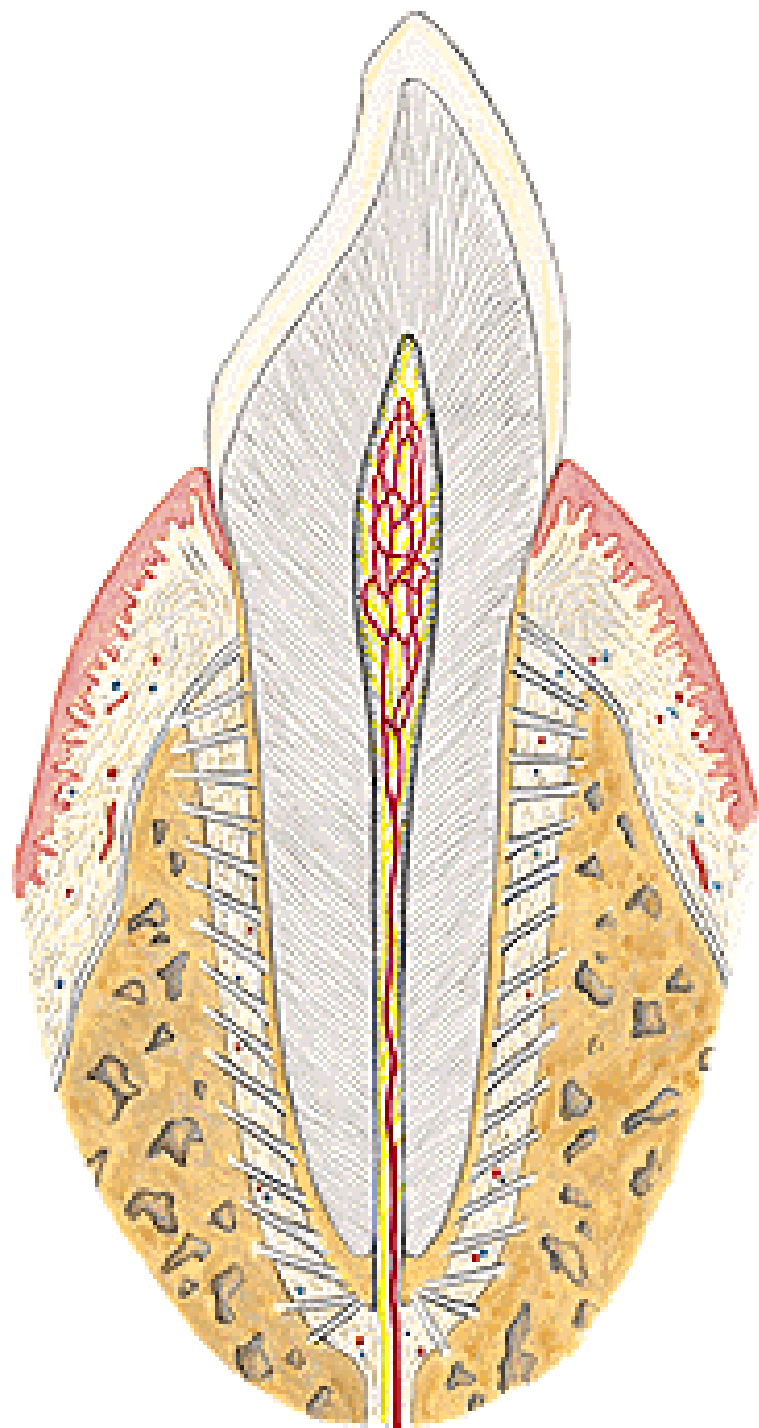


**DENTES INCISIVI - 2**  
**DENS CANINUS - 1**  
**DENTES PREMOLARES - 2**  
**DENTES MOLARES - 3**

**CORONA DENTIS**

**COLLUM DENTIS**

**RADIX DENTIS**



## **CORONA:**

### **Facies occlusalis**

- tubercula dentialia

### **Facies approximales**

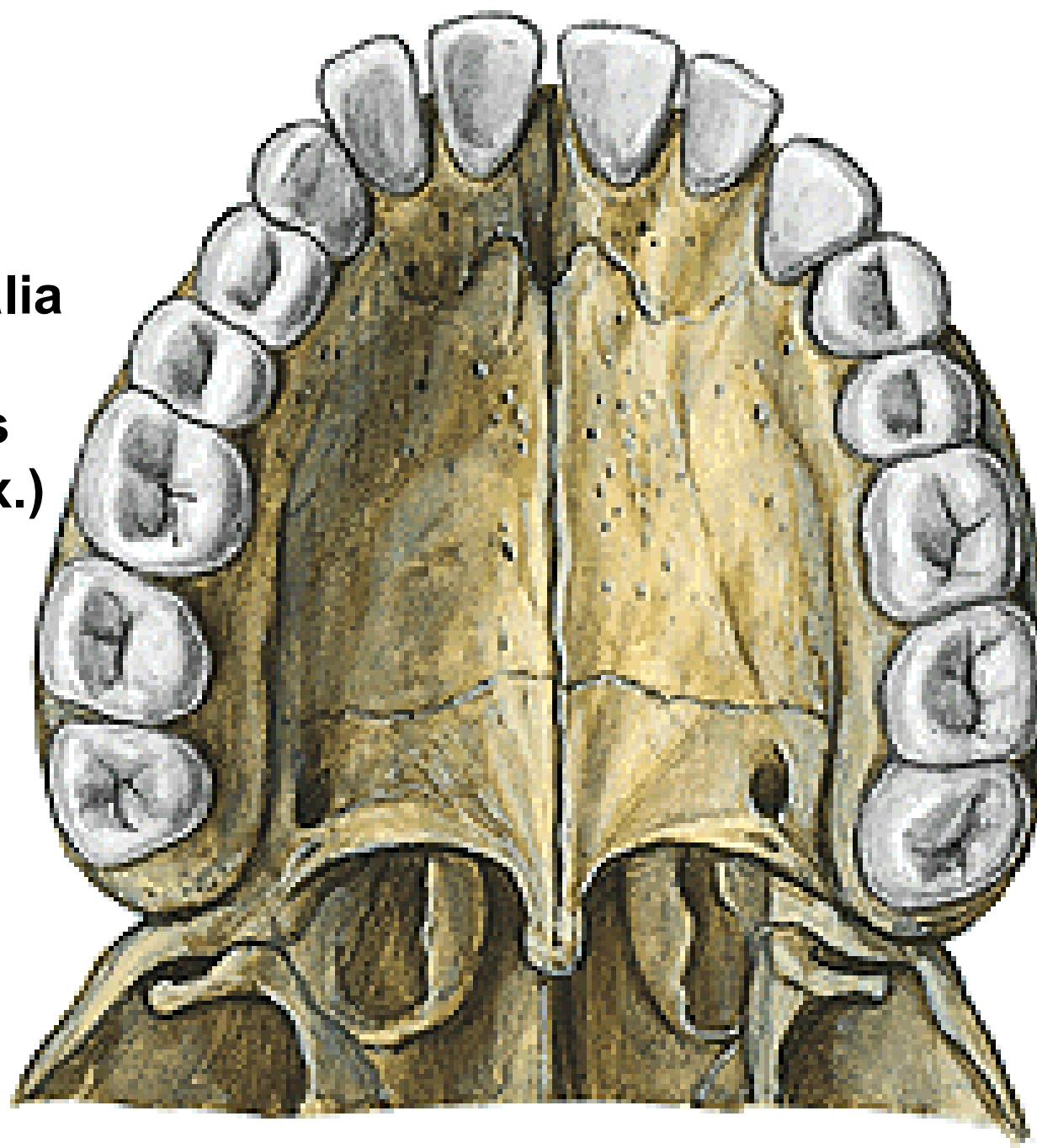
- f. mesialis (prox.)
- f. distalis

### **Facies vestibularis**

- f. labialis
- f. buccalis

### **Facies oralis**

- f. palatina
- f. lingualis



**CAVUM DENTIS**

**CANALIS RADICIS DENTIS**

**FORAMEN APICIS DENTIS**

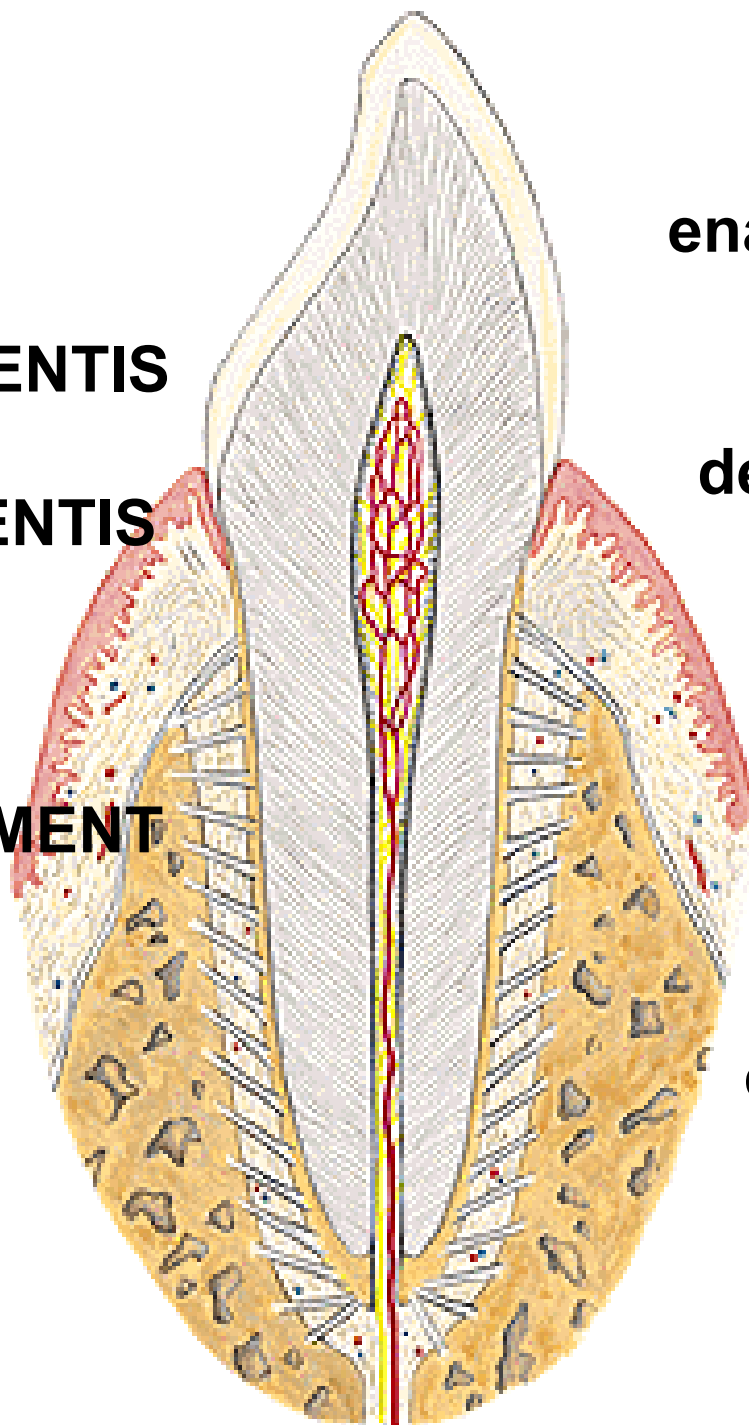
**GOMPHOSIS**

**PERIODONTAL LIGAMENT  
(P. MEMBRANE;  
PARODONTIUM)  
Sharpey's fibers**

**enamelum**

**dentinum**

**cementum**

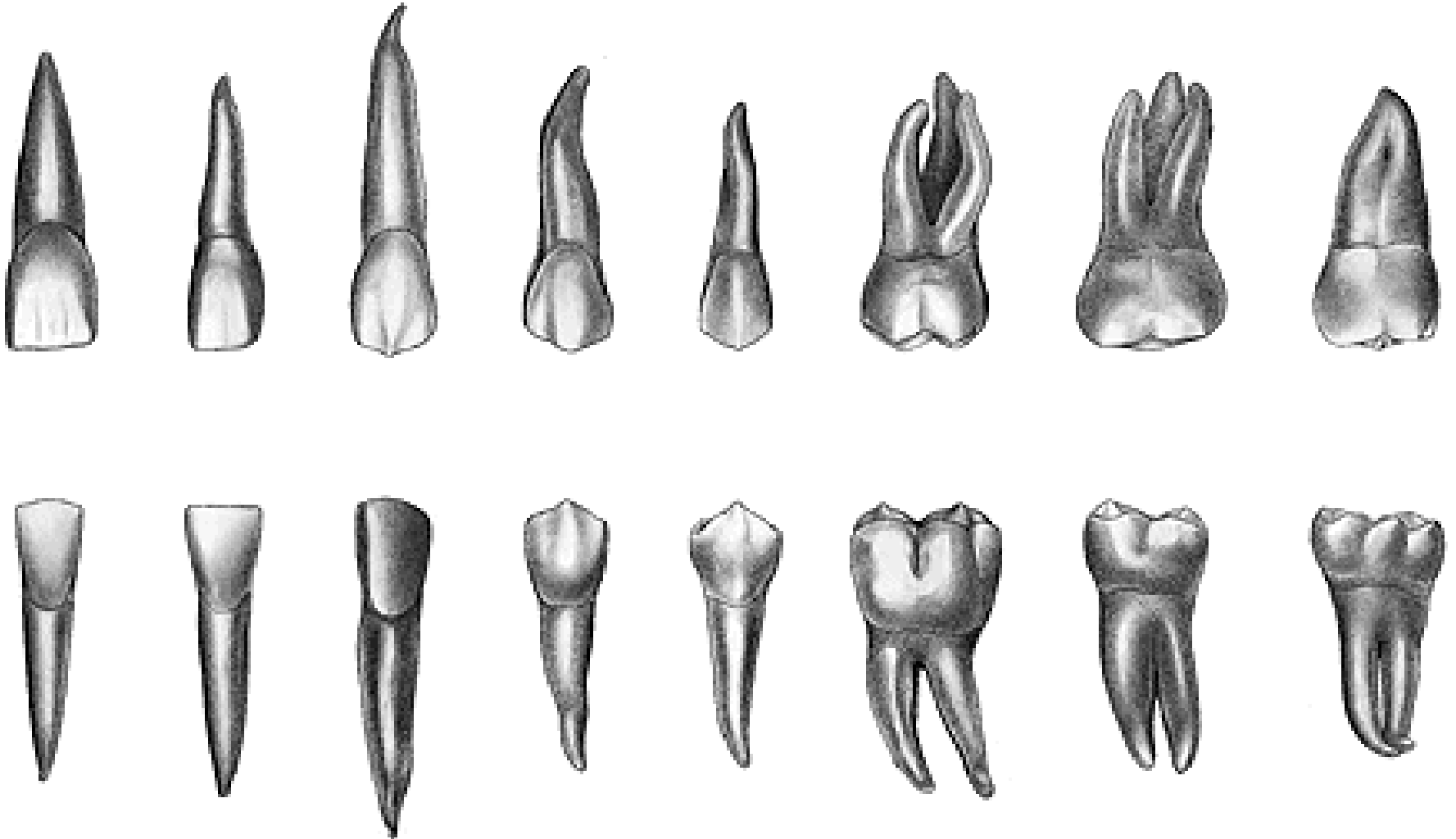


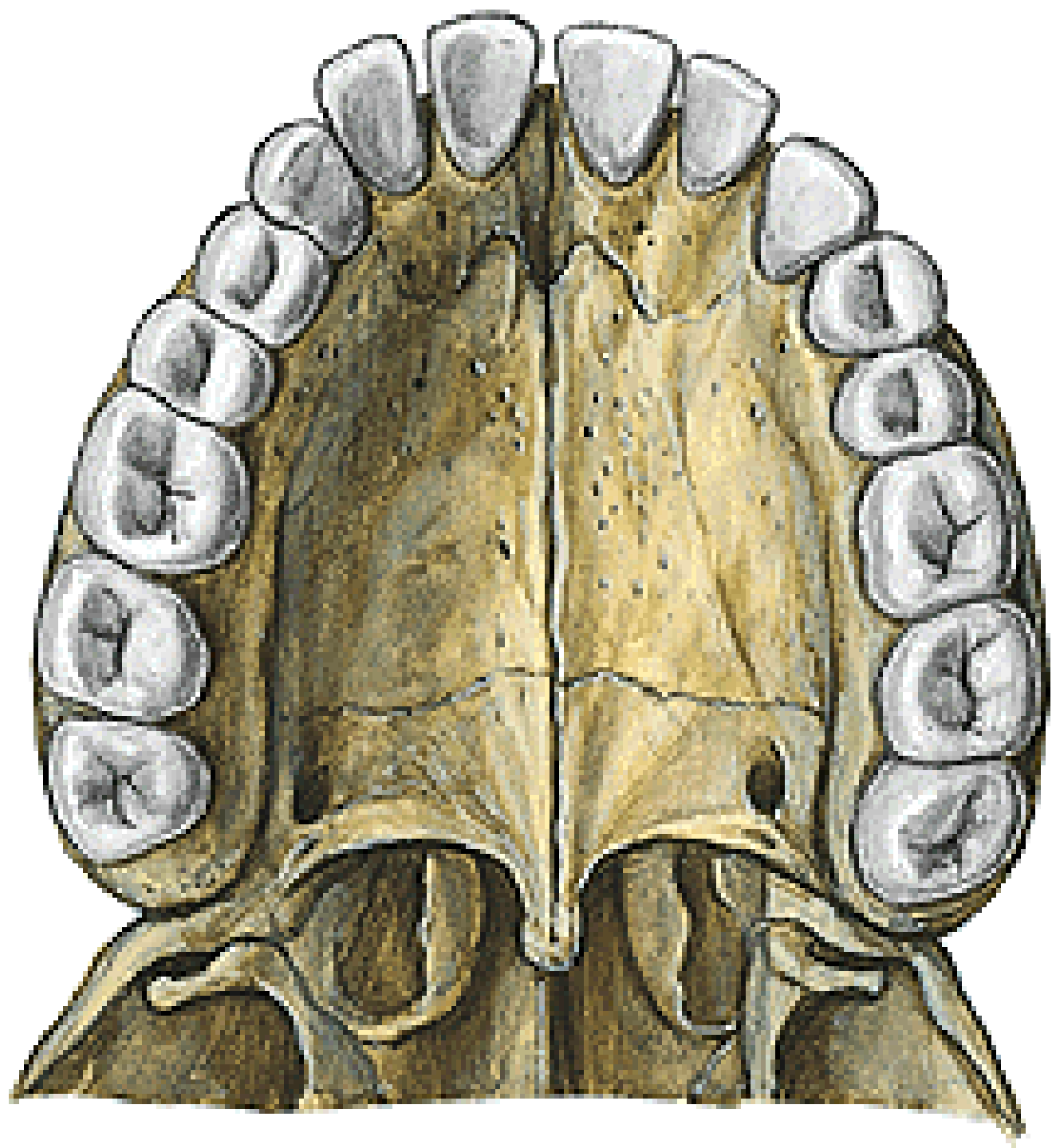
**DENTES INCISIVI - 2**

**DENS CANINUS - 1**

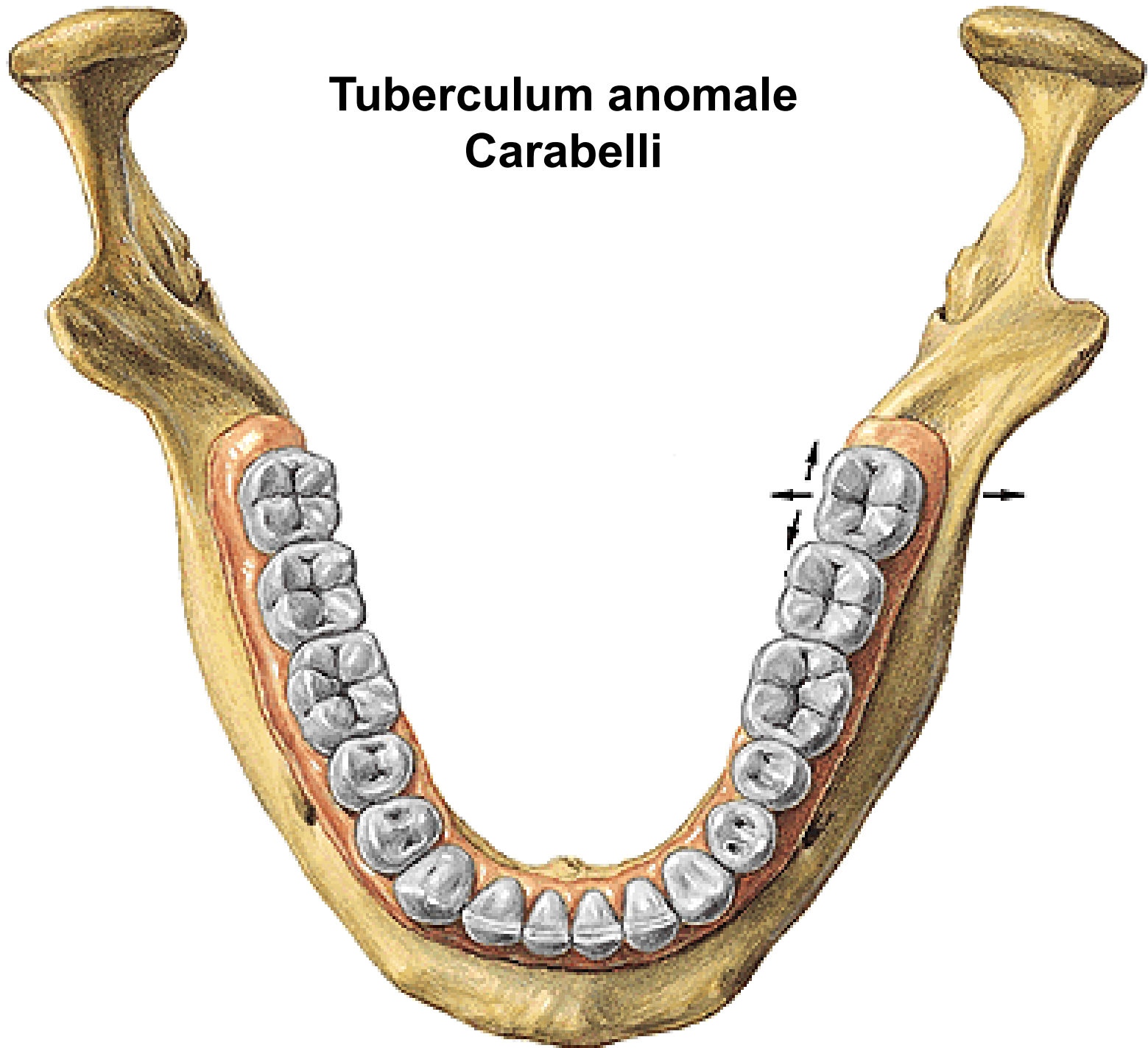
**DENTES PREMOLARES - 2**

**DENTES MOLARES - 3**

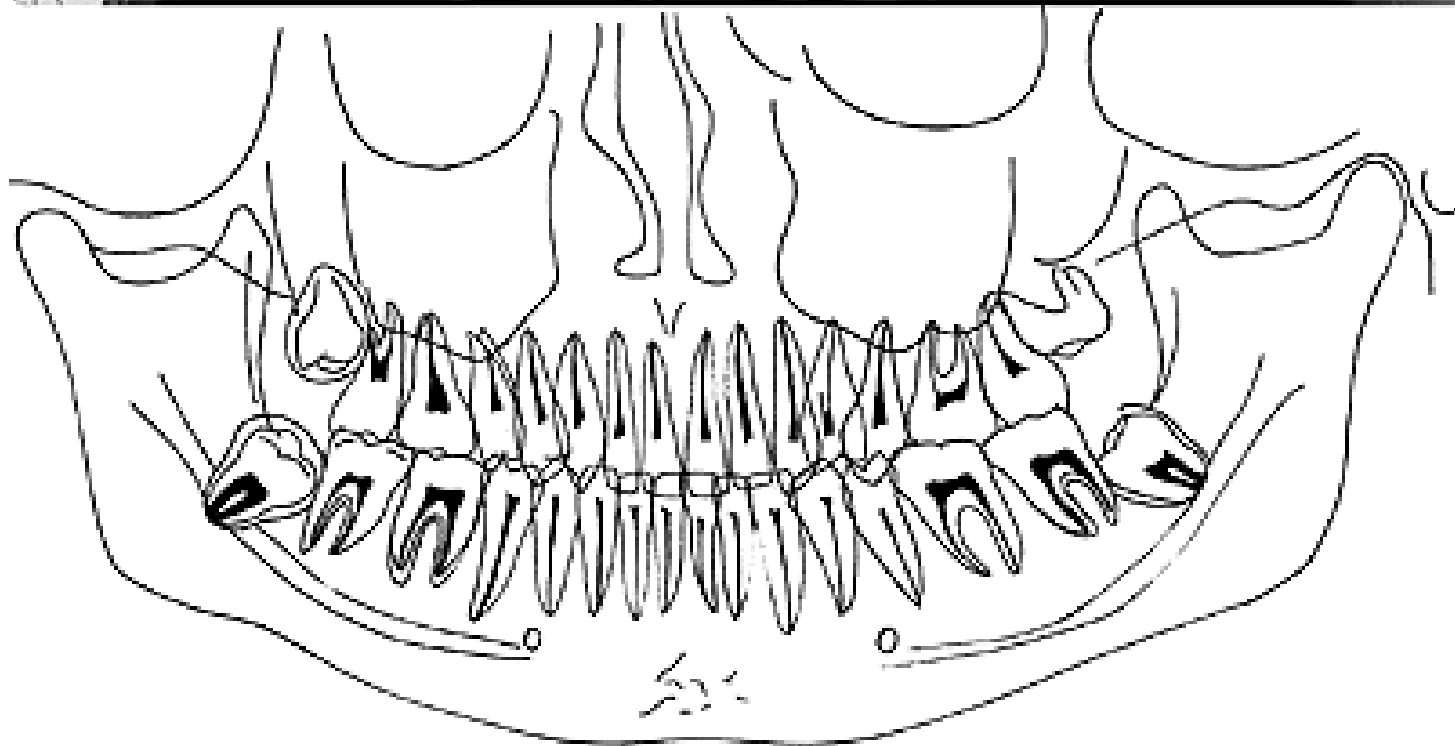
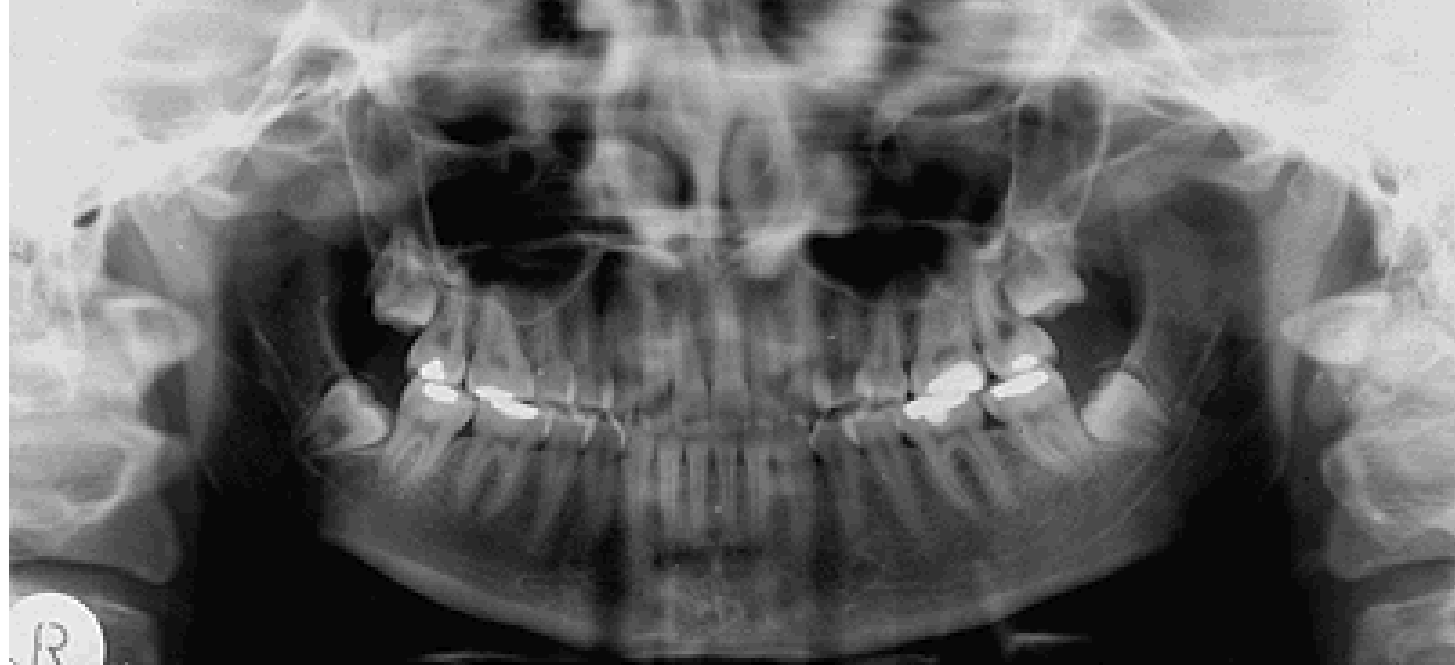



# Tuberculum anomale Carabelli





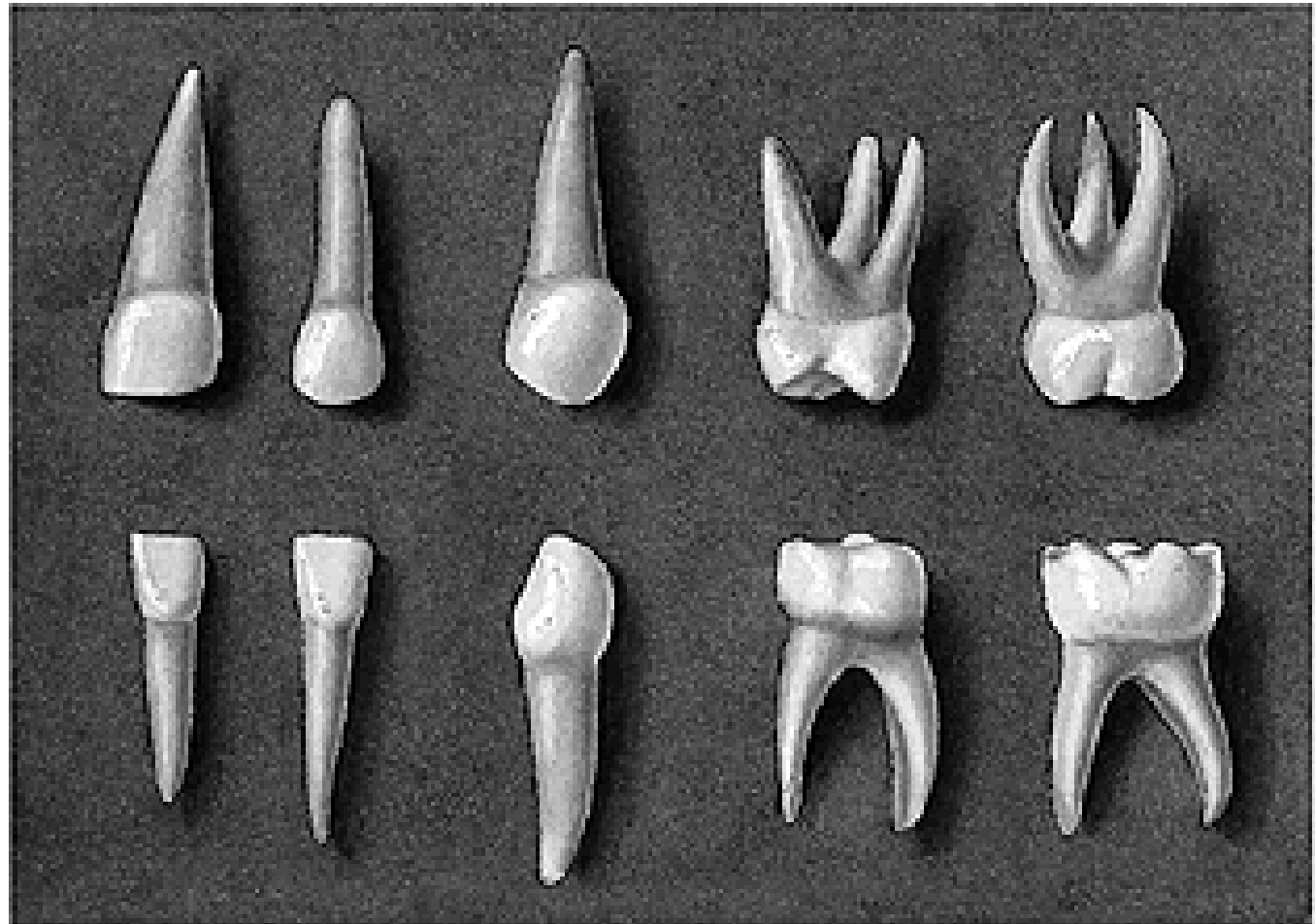


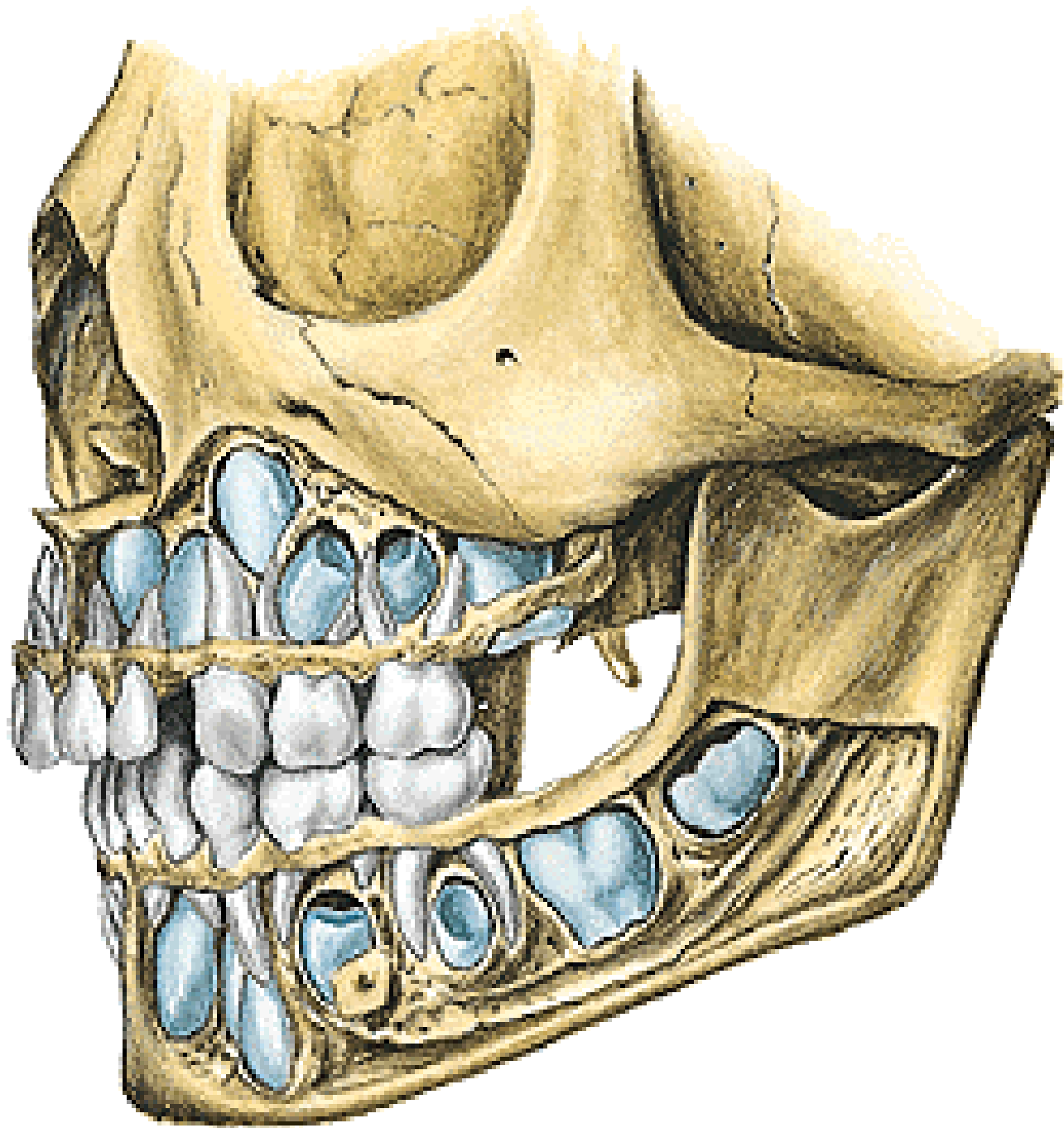
**DENTES INCISIVI - 2**

**DENS CANINUS - 1**

**DENTES MOLARES - 2**

**DENTES DECIDUI**





## **Eruption:**

**I 6<sup>th</sup>-8<sup>th</sup> month**

**II 8<sup>th</sup>-12<sup>th</sup> month**

**III 16<sup>th</sup>-20<sup>th</sup> month**

**IV 12<sup>th</sup>-16<sup>th</sup> month**

**V 20<sup>th</sup>-36<sup>th</sup> month**

**I, II, IV, III, V**

## **Exchange of the teeth:**

**1 7<sup>th</sup>-8<sup>th</sup> year**

**2 8<sup>th</sup>-9<sup>th</sup> year**

**3 11<sup>th</sup>-13<sup>th</sup> year**

**4 9<sup>th</sup>-11<sup>th</sup> year**

**5 11<sup>th</sup>-13<sup>th</sup> year**

**6 6<sup>th</sup>-7<sup>th</sup> year**

**7 12<sup>th</sup>-14<sup>th</sup> year**

**8 17<sup>th</sup>-40<sup>th</sup> year**

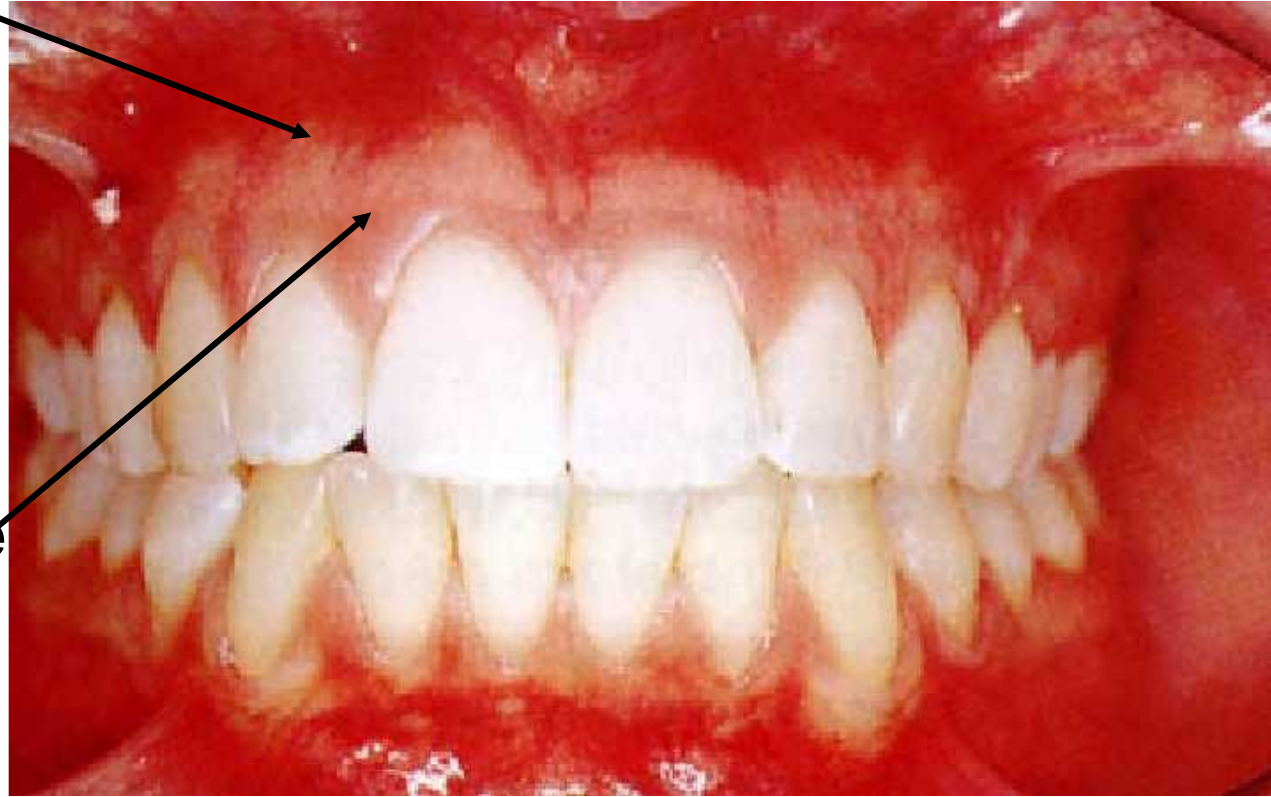
**6, 1, 2, 4, 3, 5, 7, 8**

**Alveolar mucosa**

**Gingiva - gingiva fixa (attached g.)**

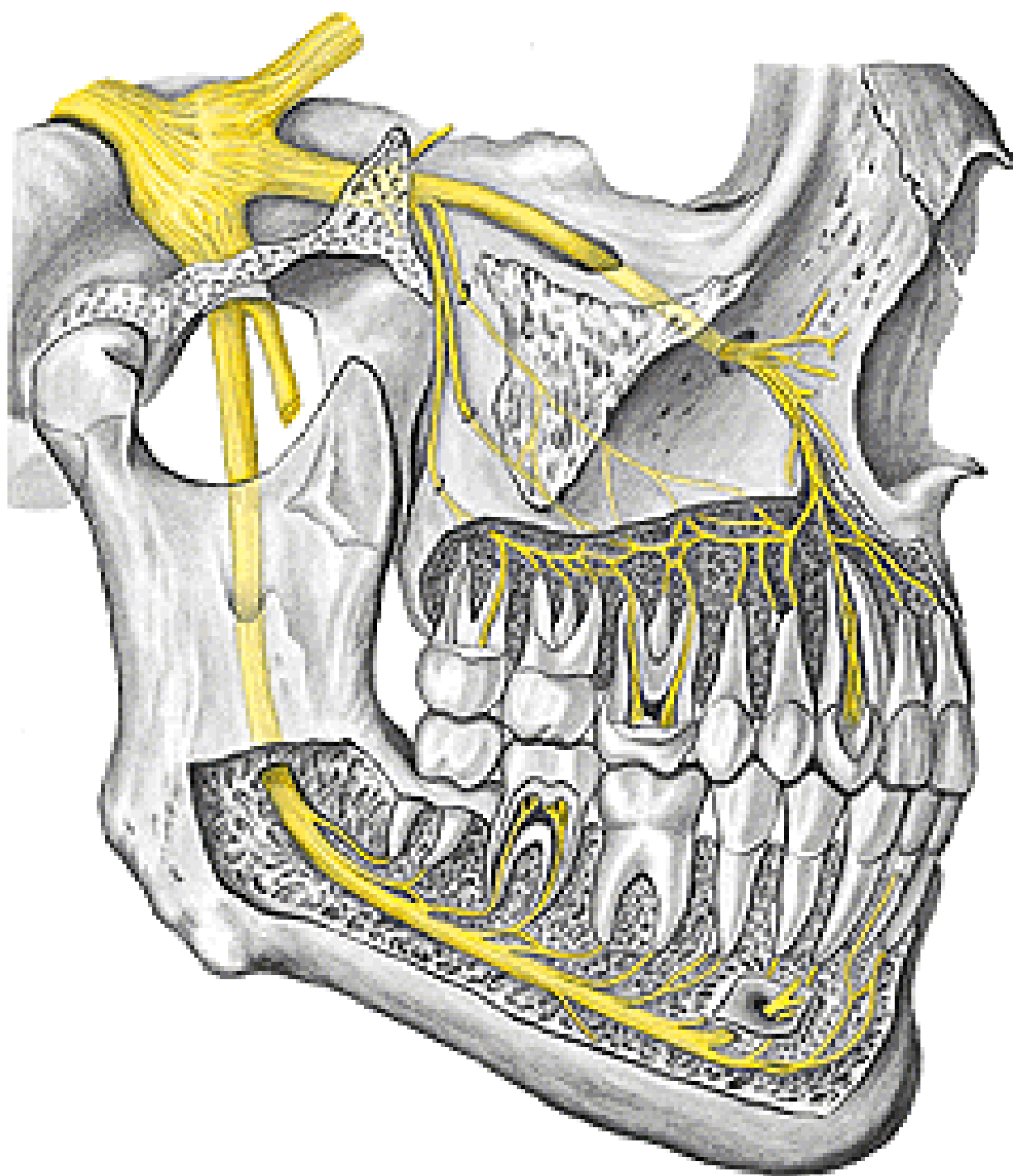
**- gingiva libera (marginal g.), gingival sulcus**

**Mucogingival border**



**Paramarginal groove**

**OCCLUSION (PROGNATHISM, PROGENISM)**



Illustrations and photographs were copied from:  
**Atlas der Anatomie des Menschen/Sobotta.**  
**Putz,R., und Pabst,R. 20. Auflage. München:**  
**Urban & Schwarzenberg, 1993)**