

The respiratory system

The respiratory system

Functions:

- **external respiration:** exchange of respiratory gases (CO₂, O₂) between external environment and the blood, (**internal respiration** between the blood and the tissues)
- Nasal cavity contains olfactory cells - regio olfactoria
- In larynx: generating of the voice
- Inner opening of Eustachian tube into the nasopharynx

The upper respiratory tract (head part)

Cavum nasi

Pharynx (hltan)

The lower respiratory tract (neck and chest part)

The larynx

The trachea (the windpipe)

The bronchi

The lungs

1. The upper respiratory tract

The external nose (nasus externus)

radix nasi

dorsum nasi

apex nasi

alae nasi, nares

septum nasi

Bony skeleton

ossa nasalia

maxillae

(apertura piriformis)

Cartilagineous skeleton

cartilago septi nasi

cartilago nasi lateralis

cartilago alaris major

cartilagine alares minores

Cavum nasi

Nares - vestibulum nasi - cavitas nasi propria – choanae

Septum nasi

**Bony part- lamina perpendicularis ossis ethmoidalis,
vomer (bone)**

Cartilagineous part – cartilago septi nasi (cartilage)

Membranous part (skin)

The roof of the nasal cavity

- **os frontale**
- **lamina cribrosa ossis ethmoidalis**
- **corpus ossis sphenoidalis**

The bottom of the nasal cavity

- **lamina horizontalis ossis palatini**
- **processus palatinus maxillae**

The lateral wall of the nasal cavity

proc. frontalis maxillae, os lacrimale, os ethmoidale, lamina perpendicularis ossis palatini

Concha nasalis superior (os ethmoidale)

Concha nasalis media (os ethmoidale)

Concha nasalis inferior



They enlarge
the surface of
the nasal cavity

The nasal cavity

meatus nasi (superior, medius, inferior) – are bordered by conchae, in elongation of the meatus inf. lies *ostium pharyngeum tubae auditivae*

choanae – openings of the nasal cavity to the nasopharynx

The mucosa

Regio olfactoria – on the roof, yellowish colour, olfactory cells (**large as a coin**)

Regio respiratoria – grey-pink colour, ciliated epithelium, rich vascular plexus (plexus cavernosi concharum) - easily bleeds– epistaxis

The paranasal sinuses: open out into the nasal cavity, form during the embryonic development

Function: resonance chamber

Sinus maxillaris – meatus nasi medius

Sinus frontalis – meatus nasi medius

Sinus ethmoidalis – meatus nasi medius et superior

Sinus sphenoidalis – meatus nasi superior

Ductus nasolacrimalis – meatus nasi inferior

Sinus paranasales have clinical importance– inflammations

Pharynx (the gullet) crossing of the respiratory and digestive tract

Nasopharynx

From the base of skull till the soft palate (tuba auditiva, tonsilla pharyngea)

Oropharynx (C2-4)

communication with oral cavity
(Waldeyer's lymphoepitelial circle)

Pars laryngea pharyngis

(at the level of C6 transition to oesophagus) aditus laryngis in its anterior wall

2. The lower respiratory tract

Larynx

The cartilages of the larynx

Cart. thyroidea (laminae, cornua,
linea obliqua)

Cart. epiglottica (petiolus)

Cart. cricoidea (arcus, lamina)

Cartt. arytenoideae (proc.muscularis
and vocalis)

Cartt. cuneiformes

Cartt. corniculatae

The joints of the larynx

Membrana thyrohyoidea

Membrana quadrangularis

(from epiglottis till the arytenoid cartilage, ligg. vestibularia)

Conus elasticus

(between ligg. vocalia and arcus cartilagineus cricoideae), Lig. cricothyroideum (coniotomy)

Membrana fibrocartilaginea laryngis

conus elasticus + membrana quadrangularis

Ligg. vestibularia (reinforced margin of membrana quadrangularis)

Ligg. vocalia (reinforced margin of conus elasticus)

- stratifies squamous epithelium, yellowish colour
-



Ligamentum hyoepiglotticum

Ligamentum thyroepiglotticum

Joints:

Art. cricothyroidea (the oscillative motions)

Art. cricoarytenoidea (rotation and sliding movements– base of the abduction and adduction of the vocal cords)

The muscles of the larynx

- affect the position, length and tension of the vocal cords and the position of the *epiglottis*

1) The muscles regulating the epiglottic cartilage:

- a) Musculus thyroepiglotticus
opens up *aditus laryngis*
- b) Musculus aryepiglotticus
encloses *aditus laryngis*

2) The muscles regulating the vocal cords:

- a) Musculus cricoarytaenoideus lateralis
adduction of vocal cords – phonatory position
- b) Musculus cricoarytaenoideus posterior
(musculus posticus) abduction of vocal cords – respiratory position
- c) Musculus arytaenoideus
the strongest adductor

m. cricoarytaenoideus
lateralis

m. cricoarytaenoideus
posterior

m. arytaenoideus

3) Muscles regulating tension of the vocal cords:

a) Musculus cricothyroideus stretches the vocal cords (tensor)

b) Musculus thyroarytaenoideus releases tension of the vocal cords

c) Musculus vocalis fine regulation of the shape and tension of the vocal cords

The muscles of the larynx are innervated by *nervus vagus* through:

nervus laryngeus superior
(*musculus cricothyroideus*)

nervus laryngeus inferior
(all other laryngeal muscles)

Respiratory position

Vocal cords are in
abduction

m. cricoarytaenoideus
posterior

m. cricoarytaenoideus
lateralis

Phonatory position

Vocal cords are in
adduction

Releasing of v.c. - m. thyroarytenoideus

Tension of v.c. - m. cricothyroideus

m. arytaenoideus

m. thyroarytaenoideus

m. cricothyroideus

Larynx

1) Vestibulum laryngis

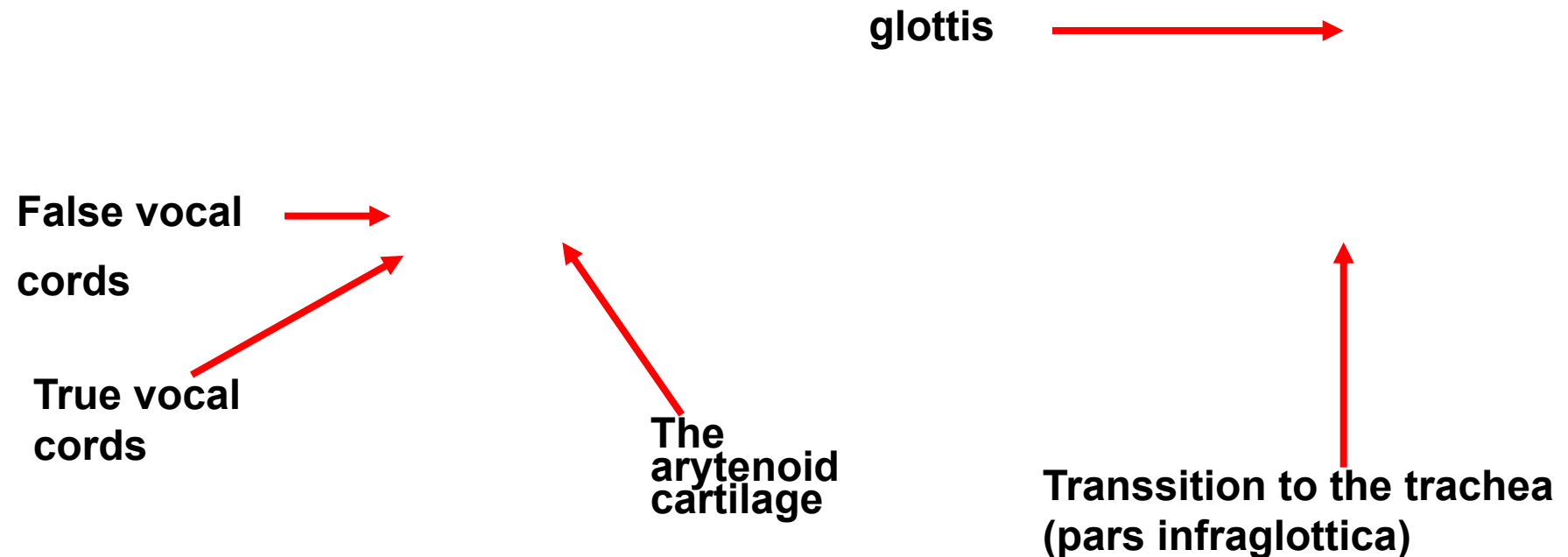
from epiglottis (aditus laryngis) till plicae vestibulares

2) Glottis

from plicae vestibulares till plicae vocales

rima glottidis – sagittal fissure between the vocal cords

3) Cavitas infraglottica



The laryngoscopic view

laryngoscopy

**Respiratory
position**

**Phonatory
position**

Trachea (The windpipe)

Pars cervicalis (C6- C7)

Pars thoracica (Th1-Th4)

Newborn from C4

Child from C5

Bifurcatio tracheae (Th4)

= 1. division of the bronchial tree

Carina tracheae

length 10-11 cm, diameter 12 mm

Trachea (C6–Th4 or 5)

Cartilagine tracheales (15-20, horsehoe shape)

Ligamenta anularia

Paries membranaceus (fibrous tissue, smooth muscles)

Ciliated columnar epithelium

Trachea divides by Th₄₋₅ into: main (primary) bronchi

Bronchus principalis dexter

Bronchus principalis sinister

shorter, wider

**Foreign body intrudes in
75% to the right bronchus**

**(bronchial tree– arbor
bronchiales)**

Syntopy: *in front* thyroid gland, *behind* oesophagus

Infrahyoid muscles



Thyroid gland



Prevertebral muscles



Cervical vertebra



oesophagus



The coniotomy, The tracheotomy

← Coniotomy (lig. cricothyroideum)
← Tracheotomy superior and inferior
←

Coniotomy
Tracheotomy superior
Tracheotomy inferior

Arbor bronchiales

Bronchi principales divide into:

- **bronchi lobares** (right 3, left 2) - secondary bronchi
- **bronchi segmentales** (9-10 sin., 10 dx.) – tertiary bronchi

(the pulmonary segment is of pyramidal shape, the apex is located in the area of the pulmonary hilus, segmentectomy)

The last section form:

- **bronchioli terminales** (<1mm, have no reinforcement, the wall is formed by smooth muscles – they can enclose the bronchial lumen)

Arbor alveolaris – breathing compartment of the lungs–

exchange of breathing gases

- **bronchioli respiratorii**
- **ductuli alveolares** – atrium - **sacculi alveolares** - **alveoli pulmonis**

Thin-walled tubules

Alveolar sacs

alveoli

Bronchography

Bronchoscopy

The lungs - pulmo

Position of the lungs:

Thorax cavity– pleural cavities

height 20-24 cm, weight 600 – 700g

colour pink– marbling – grey/black

The lungs (*Pulmo, Pneumon*)

Description of the lungs:

facies diaphragmatica - base

apex pulmonis - top (reaches above apertura thoracis superior)

facies costalis - (impressions of the ribs)

facies mediastinalis (hilus pulmonis—dx. BAV, sin. ABV)

radix pulmonis – root of the lung

Impressions

The heart

Aorta

The oesophagus

1. rib

Other vessels

The left lung

A
B
V

The right lung

B
A
V

HILUM PULMONALE

The left lung

The right lung

A
B
V

B
A
V

The lungs (*Pulmo*) - *division*

fissura obliqua (Th4 – VI.rib)

fissura horizontalis (along IV. rib)

Pulmo dex. 3 lobes (sup., medius, inf.)

Pulmo sin. 2 lobes (sup., in.)

–Incisura cardiaca- lingula pulmonis

Segments:

Dextra - 10

Sinistra -10 (smt 8) I. and II. joined
and VII. v 90% misses

The nutritive and functional circulation

The nutritive circulation

Aorta thoracica (+ intercostal arteries)

- **rami bronchiales** (1 right – most often from a. intercostalis tertia, 2 left directly from thoracic aorta)
along the bronchi till bronchioli respiratorii
- **venae bronchiales**
to v. azygos, v. hemiazygos accessoria, vv. intercostales

The functional circulation – small blood circulation

right ventricle ➡ truncus pulmonalis ➡ arteriae pulmonales dx.+ sin. (**blood with low content of oxygen**) ➡ capillars ➡ 4 **venae pulmonales** (2 dx., 2 sin.) (**blood with high content of oxygen**) ➡ left ventricle of the heart

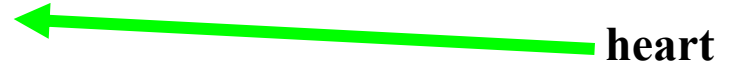Pneumothorax

Xray of the thorax

Transsection through the thorax on the level of hilus


pulmonis
(bottom view)

sternum



heart


rib



v. azygos



oesophagus



aorta

CT of the thorax (Th₄)
bottom view


sternum




**bifurcatio
tracheae**



rib




Th₄



oesophagus



aorta



PLEURA – serous membrane (simple squamous epithelium)

pleura visceralis (covers the surface of the lungs)

pleura parietalis (covers the pleural cavities)

Both lungs are located in the separate cavities
cavum pleurae dextrum et sinistrum

a) **Pleura costalis**

b) **Pleura mediastinalis**

c) **Pleura diaphragmatica**

Recessus pleurales

– parts of pleura pass into each other

Cupula pleurae

– protrudes above 1. rib and the clavicle

Recessus pleurae

- 1) Recessus costodiaphragmaticus–pathological effusions collect there**
- 2) Recessus costomediastinalis**
- 3) Recessus phrenicomediastinalis**

The mechanism of the breathing

Breathing in (inspiration) using the diaphragm and mm. intercostales ext.

Breathing out (expiration) used mm. intercostales int. and intimi

Inspiration- active

- Contraction of the diaphragm – enlargement of thorax in the longitudinal direction
- Contraction of mm. intercost. ex. – enlargement of thorax in the sagittal direction
- Pressure drop in pleural cavity
- The lungs follow the movement of the thorax and the air goes to the lungs

Expiration - passive

- **Relaxation of the diaphragm (contraction of abdomen muscles)**
- **Contraction of mm. intercostales interni and intimi, decrease of the ribs – expiration**

Respiratory muscles

- **Muscles of inspiration**

- **Main:** mm. **intercostales externi**, **diaphragma** (mm. **scaleni**, mm. **levatores costarum**)
- **Auxiliary:** m. **pectoralis major + minor**, m. **latissimus dorsi**, m. **serratus anterior + post. sup.**, m. **sternocleidomastoideus**, m. **subclavius**, (m. **sternothyroideus**, m. **sternohyoideus**)

- **Muscles of expiration**

- **Main:** mm. **intercostales interni (+ intimi**, m. **subcostales**)
- **Auxiliary:** m. **rectus abd.**, m. **obliquus abd. ext. + int.**, m. **transversus abd.**, m. **serratus post. inf.**, m. **transversus thoracis**, (m. **quadratus lumborum**)

Orientation lines:

linea mediana ant.

linea sternalis

linea parasternalis

linea medioclavicularis

linea axillaris ant., med., post.

linea scapularis

linea paravertebralis

linea mediana post.

The borders of the pleura

Cupula pleurae - 1-2 cm above the clavicle

Area interpleuralis superior

2. rib – 4. rib parallel, dx till 6. rib, sin. incisura cardiaca

Area interpleuralis inferior

Medioclavicular line 7. rib

Middle axillary line 9. rib

Scapular line 11. rib

Paravertebral line 12. rib – then to C₇ and to cupula pleurae

The borders of the pleura

The borders of the lungs

- *apex pulmonis* fills *cupula pleurae*, reaches 1–2 cm over the clavicle
- Anterior margin: corresponds during the inspiration with the anterior margin of the pleura
- Inferior margin: projects about 1 till 2 ribs more cranially than the inferior border of the pleura
- Posterior margin: projects laterally from the spinous processes within the range Th11 till Th2.

The lungs of a newborn

- a newborn can survive the preterm labor between 24. and 28. week (formerly lungs are not yet sufficiently prepared for gas exchange, do not produce surfactant)
- The lungs of a newborn, who done the inspiration, keep afloat, the lungs of stillborn sink to the bottom
- The importance in the forensic pathology

Regional anatomy of the thorax

Pleural cavities

Mediastinum: space between the pleural cavities: it contains organs, vessels and nerves, there is also the loose fibrous connective tissue present

Dividing of the mediastinum:

(border: horizontal plane going through the upper margin of the heart)

1. mediastinum superius (thymus, layer of veins, layer of arteries, trachea)

2. mediastinum inferius

mediastinum anterius (lymph nodes)

mediastinum medium (heart)

mediastinum posterius (oesophagus, aorta, ductus thoracicus, v. azygos et hemiazygos, truncus sympaticus, lymph nodes)

Obrázky:

Atlas der Anatomie des Menschen/Sobotta.

Putz,R., und Pabst,R. 20. Auflage. München:

Urban & Schwarzenberg, 1993

Netter: Interactive Atlas of Human Anatomy.

Naňka, Elišková: Přehled anatomie. Galén, Praha 2009.

Čihák: Anatomie I, II, III.

Drake et al: Gray's Anatomy for Students. 2010