

THE CRANIAL NERVES (*nervi craniales*)

- I. Nervus olfactorius – the olfactory nerve***
- II. Nervus opticus – the optic nerve***
- III. Nervus oculomotorius – the oculomotor nerve***
- IV. Nervus trochlearis – the trochlear nerve***
- V. Nervus trigeminus – the trigeminal nerve***
- VI. Nervus abducens – the abducens nerve***
- VII. Nervus facialis – the facial nerve***
- VIII. Nervus vestibulocochlearis – the vestibulocochlear nerve***
- IX. Nervus glossopharyngeus – the glossopharyngeal nerve***
- X. Nervus vagus – the vagus nerve***
- XI. Nervus accessorius – the accessory nerve***
- XII. Nervus hypoglossus – the hypoglossal nerve***

The outputs from the brain

I. – the cerebrum

II. – the diencephalon

III.-XII. – the brainstem

IV. – dorsally !!!

I. = The olfactory nerve

- special **sensory** nerve: smell, part of the olfactory tract
- cavitas nasi → lamina cribrosa → cavitas crani anterior
- Superior area of the nasal cavity in range of concha nasalis superior, on the wall, roof and septum

The function of the nerve

sensory

- it brings information from the olfactory receptor into the CNS

II. = The optic nerve

- It hasn't the nuclei– centre is in the occipital lobe
- special **sensory** nerve: vision, part of visual tracts
- orbita → canalis opticus → cavitas cranii media

The function of the nerve

sensory

- it brings information from visual receptor into the CNS

The extraocular muscles

- mm. recti (bulbi)
 - superior, inferior, medialis, lateralis
- mm. obliqui (bulbi)
 - *inferior, superior*
- m. levator palpebrae superior
- ***inervation:*** n. III., IV., VI.

The extraocular muscles innervation:

- Through sinus cavernosus and fissura orbitalis superior, they enter the orbit

- **III. The oculomotor nerve**

- fossa interpeduncularis (sulcus nervi oculomotorii)

motor – 5 extraocular muscles

+ parasympathetic fibres for innervation of smooth muscles of the iris - *m. sphincter pupillae* – pupil constriction (miosis) and of corpus ciliare- *m. ciliaris* – accommodation of the lens

- **IV. The trochlear nerve**

- Posterior surface of the brainstem

purely motor → 1 muscle = **m. obliquus superior**

- **VI. The abducens nerve**

- sulcus bulbopontinus

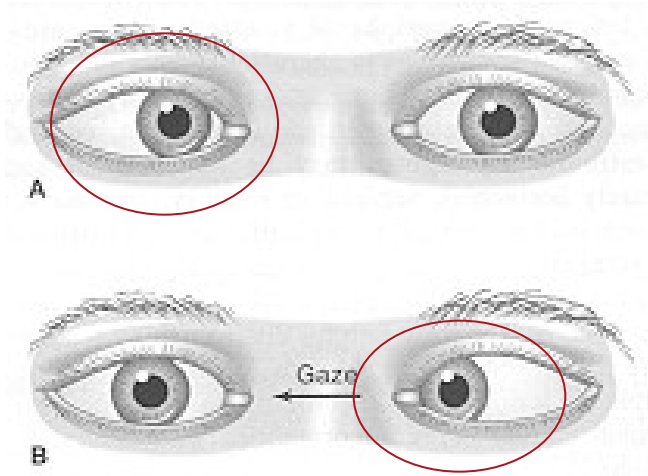
purely motor → 1 muscle - **m. rectus lateralis**

Palsy of n. III

- **divergent strabismus**
- **Pupil dilatation- mydriasis**
- **accommodation disorder**
- **falling of the upper eyelid - ptosis**
- **double vision- diplopia**

Palsy of n. IV and n.VI

- convergent strabismus)



V. = The trigeminal nerve

- *ganglion trigeminale* (located within *cavum trigeminale*) - sensory

V1 = n. ophthalmicus = ophthalmic nerve (*sensory*)

V2 = n. maxillaris = maxillary nerve (*sensory*)

V3 = n. mandibularis = mandibular nerve (*mixed*)

Radix motoria = somatomotor branch
for the masticatory muscles and other
4 muscles- fibers only within V3 !!!

N. V

- **V1 = N. ophthalmicus**
- **V2 = N. maxillaris**
- **V3 = N. mandibularis**

N. ophthalmicus

- n. frontalis
- n. nasociliaris
- n. lacrimalis
- ganglion ciliare (parasympathetic)

} **sensory**

N. maxillaris

- n. zygomaticus (r. zygomaticotemporalis, r. zygomaticofacialis)
- n. infraorbitalis (nn. alveolares superiores)

} **sensory**

N. mandibularis

motor branches:

- Masticatory muscles, suprahyoid muscles, m. tensor veli palatini, m. tensor tympani

Sensory branches:

- n. alveolaris inferior, n. lingualis (chorda tympani from n. VII), n. buccalis, n. auriculotemporalis
- *parasympathetic ganglion submandibulare + ganglion oticum*

V1 = N. ophthalmicus

- fissura orbitalis superior into orbit – to the frontal region
- Skin of thupper part of face (forehead, upper eyelids, dorsum nasi), content of the orbit, part of mucosa of nasal cavity and paranasal sinuses)
 - n. frontalis
 - n. lacrimalis
 - n. nasociliaris
 - *ganglion ciliare - parasympathetic*
m. sphincter pupillae (pupil constriction) m. ciliaris
 - n. supraorbitalis – *sensitivity to palpation*

- **n. frontalis: r. supraorbitalis (r. medialis et lateralis), r. supratrochlearis (skin of forehead till interauricular line)**
- **n. lacrimalis (lacrimal gland, upper eyelid)**
- **n. nasociliaris-branches: nn. ciliares longi, n. ethmoidalis posterior, n. ethmoidalis anterior, n. infratrochlearis (sinus sphenoidalis, nasal cavity, sensory fibres into the eye)**
- **ganglion ciliare (m. sphincter pupillae, m. ciliaris)**

V2 = N. maxillaris

- foramen rotundum - branches out behind the maxilla- fossa pterygopalatina
- skin of middle part of face (lower eyelid, upper lip, nasal wings and upper half of cheek), **teeth of maxilla**, part of mucosa of nasal and oral cavity

- **n. zygomaticus: n. zygomaticofacialis, n. zygomaticotemporalis, r. communicans cum nervo zygomatico (skin of cheek)**
- **n. infraorbitalis (teeth of maxilla, sinus maxilaris, mucosa of nasal cavity, palate, nasopharynx)**

Ganglion pterygopalatinum

- rr. ganglionares
- **parasympathetic**
- ***Smooth muscle, vessels and glands of innervated areas***
(glands of nasal cavity, palate, isthmus faucium, nasopharynx, mucosa of palatum and upper half of cheek, tonsila palatina)

V3 = N. mandibularis

- **foramen ovale – branches out behind ramus mandibulae-fossa infratemporalis**
- **skin of inferior part of face (lower lip, inferior half of cheek, chin), teeth of mandibula, part of mucosa of oral cavity**
- **masticatory muscles, muscles of neck**

n. mandibularis

somatomotor branches:

- Masticatory muscles
- suprahyoid muscles
- m. tensor veli palatini
- m. tensor tympani

somatosensory branches:

- n. alveolaris inferior (teeth)
- n. lingualis (mucosa of bottom of oral cavity, gingiva, front 2/3 of tongue)
 - chorda tympani from n. VII
- n. buccalis (skin and mucosa of cheek)
- n. auriculotemporalis (auricle and temporal region)
- **parasympathetic** ganglion *submandibulare* + ganglion *oticum* (small salivary glands of tongue and bottom of oral cavity)
- n. mentalis – *sensitivity to palpation*

- **Branches for masticatory muscles**
- **n. buccalis**
- **n. lingualis (n. sublingualis, rr. linguales)**
- **n. alveolaris inferior (n. mylohyoideus)**
- **n. auriculotemporalis (r. meningeus, r. communicans cum ganglio otico)**

VII. = The facial nerve

- **mixed nerve**
- **2 basis**
 - **n. facialis – motor (mimic muscles)**
 - **n. intermedius - visceromotor + taste + sensory**

inside canalis nervi facialis

- n. petrosus major – *parasympathetic* into ggl. pterygopalatinum
- n. stapedius – m. stapedius
- chorda tympani
 - *parasympathetic* into glandula submandibularis
 - *taste* → into front 2/3 of tongue

outside the skull

- n. auricularis posterior – *motor nerve* to rudimentary muscles of auricle
- nn. into m. stylohyoideus + venter post. m. digastrici
- plexus intraparotideus (mimic muscles: rr. temporales, rr. zygomatici, rr. bucales, r. marginalis mandibulae, r. colli)

somatosensory – auricle and external auditory canal

senzory – from gustatory cells of front 2/3 of tongue

somatomotor – mimic muscles, musculus platysma, musculus stapedius, m.stylohyoideus, m.digastricus-posterior belly

visceromotor – parasympathetic fibres for secretion of lacrimal gland, submandibular and sublingual gland

peripheral „Bell’s“ palsy

n. VII

central palsy

Common output of

- n.IX., X., XI.

IX. The glossopharyngeal nerve

- **Arises from the medulla oblongata**
- **Passes through foramen jugulare**
- **Branches out under the base of skull**
- **Branches: n. tympanicus → n. petrosus major, rr. pharyngei, tonsillares, linguales**

- **Motor in.:** soft palate muscles (except tensor), m. stylopharyngeus, muscles of pharynx
- **Parasympathetic in.:** mucosa of tympanic cavity and glandula parotide (through ganglion oticum)
- **Sensory in.:** pharynx, back third of tongue, tonsil
- **Gustatory in.:** back third of tongue

X. The vagus nerve

- **arises from medulla oblongata**
- **Passes through foramen jugulare**
- **Descends caudally and passes together with arteria carotis interna (lower arteria carotis communis) and vena jugularis interna, it attaches to the esophagus and along it descends through thoracic cavity till abdominal cavity (in male till scrotum)**

r. auricularis (sensory branch for wall of ear canal)
rr. pharyngei (muscles of pharynx)
n. laryngeus superior
n. laryngeus recurrens- n.laryngeus inferior
(muscles of larynx)

Organs within thoracic and abdominal cavity:

rr. cardiaci - plexus cardiacus
rr. bronchiales- plexus pulmonalis
rr. oesophagei- plexus oesophagus
rr. gastrici
rr. hepatici
rr. coeliaci - plexus coeliacus
rr. renales

- **sensory in.:** part of skin of the auricle and ear canal
- **viscerosensory in.:** organs of thoracic and most of abdominal cavity
- **somatomotor in.:** striated muscles of pharynx and larynx
- **visceromotor in.:** smooth muscle of respiratory tract and most of alimentary tract, smooth muscle of appropriate vessels and myocardium

XI. The accessory nerve

- **arises from the medulla oblongata**
- **passes through foramen jugulare**
- **name is abbreviation of the original name,,nervus accessorius ad vagum“ (because part of its fibers joins with nervus vagus and below it separates again and innervates muscles of larynx)**
- **Nerve branches out after leaving the cranial cavity**

n.XI.

Radices craniales

Radices spinales

Ramus internus- joints with n.X.

(muscles of larynx)

Ramus externus

motor – part of musculus
sternocleidomastoideus and
musculus trapezius

XII. The hypoglossal nerve

- **Arises from the medulla oblongata - sulcus anterolateralis**
- **Through canalis nervi hypoglossi**
- **Directs to the tongue, where it branches out**

N. hypoglossus

Motor nerve: innervation of striated muscle of the **tongue**
ansa cervicalis profunda- infrahyoid muscles (plexus
cervicalis)

Obrázky:

- **Atlas der Anatomie des Menschen/Sobotta. Putz,R., und Pabst,R. 20. Auflage. München:Urban & Schwarzenberg, 1993**
- **Netter: Interactive Atlas of Human Anatomy.**
- **Naňka, Elišková: Přehled anatomie. Galén, Praha 2009.**
- **Čihák: Anatomie I, II, III.**
- **Drake et al: Gray's Anatomy for Students. 2010**