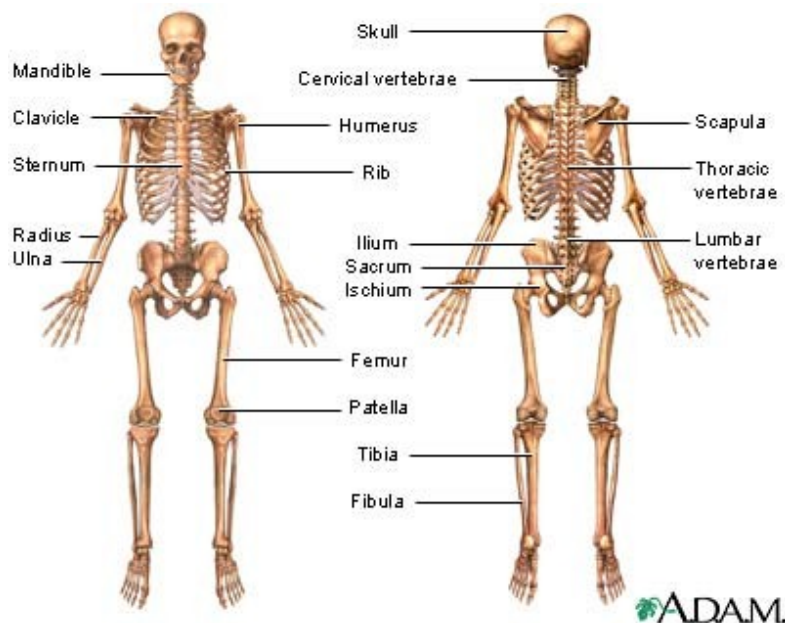


SKELETAL SYSTEM

Introduction

This system has circa **206 bones**, plus associated structures like **tendons** and **ligaments**, and it serves many important functions. Since bones are rigid, they support the body, give it its shape, and protect its vital organs against injury. Bones provide points for **muscle attachments**, and, together with the movable **joints**, they form a system of levers upon which muscles act to produce contraction and thus body movement. A joint is a place where bones meet, or articulate. Bones also function as a site for **mineral storage** (mainly **calcium** and **phosphorus**) and blood cell formation (**haematopoiesis**). Tendons and ligaments are strong bands of fibrous **connective tissue** that attach, or link, muscles to bones (tendons), and bones to bones (ligaments).

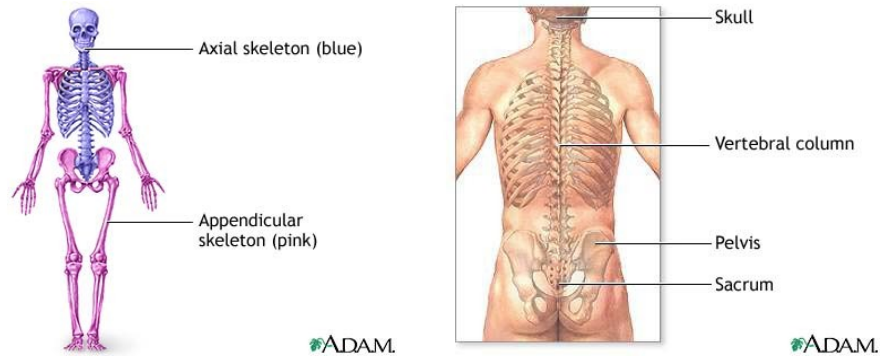


Skeleton

The skeleton has two parts: the **axial** skeleton and the **appendicular** skeleton.

The axial skeleton includes the **skull**, the **hyoid bone**, the **vertebral column**, and the **thorax**. Its components are aligned along the axis of the body.

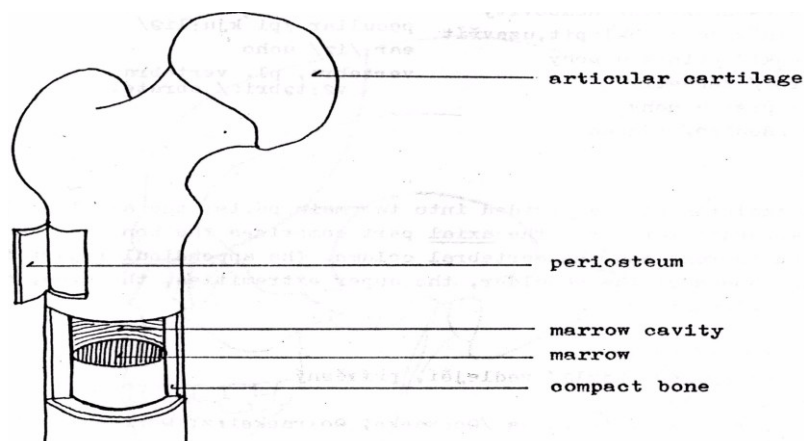
The appendicular skeleton includes the bones of the **upper and lower extremities** (or **limbs**), the **pectoral** (or **shoulder**) **girdle**, and the **pelvic** (or **hip**) **girdle**. Its components are outside the body main axis.



Bones

There are four main categories of bones: **long**, **short**, **flat** and **irregular**.

Long bones form the extremities (**arms and hands, legs and feet**) and consist of a **diaphysis**, two bulbous **epiphyses** (sing. epiphysis), **articular cartilage** and **periosteum**. Periosteum is a dense fibrous membrane of connective tissue covering the surface of bones (except at the joint ends where the bone is covered by cartilage) that contains numerous blood and lymph vessels, and nerves. Dense and hard **compact bone** is the main building material of long bones and in their hollow centre they contain **yellow bone marrow**. The epiphyses are mostly formed by **spongy**, or **cancellous**, bone material.



Short bones are of irregular, cubic shape and they are found in the wrists and ankles of the upper and lower limbs, respectively. Their core is typically made up of spongy bone.

Flat bones provide broad surfaces for attachment of muscles and protection for internal organs. Examples of flat bones are bones of the skull, ribs, shoulder blades, the breastbone and pelvis.

Irregular bones are all the others; for instance vertebrae (bones of the spine), and bones of the ear and face. They are of various shapes and sizes.

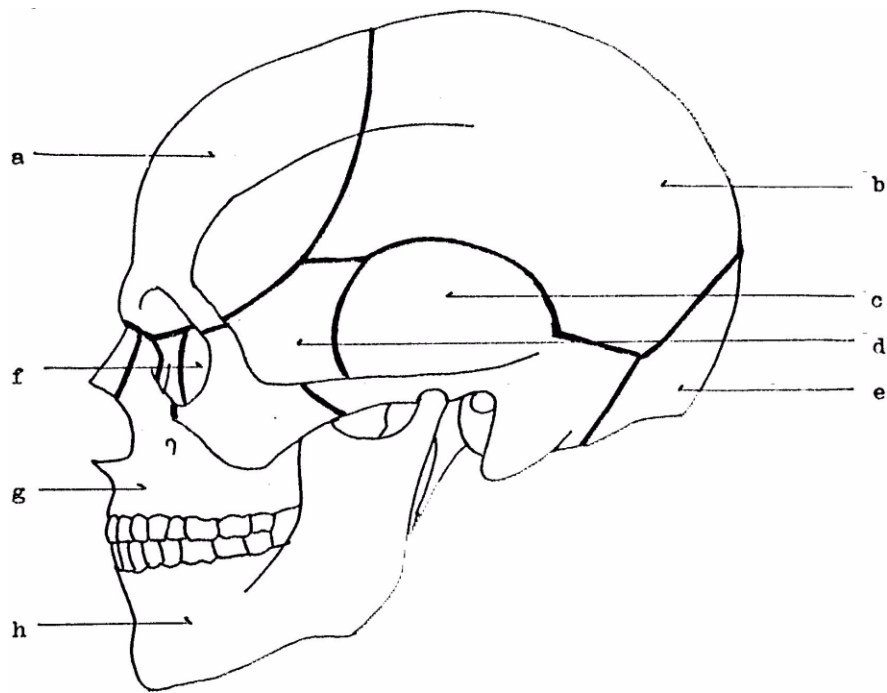
The cavities of the spongy bone in some flat and irregular bones contain **red bone marrow**, a kind of connective tissue in which blood cells are produced.

Ossification is the medical term for bone growth. Bone is a living tissue that is being renewed throughout life and three types of bone cells participate in this process: **osteoblasts** (bone-building cells), **osteocytes** (mature bone cells), and **osteoclasts** (bone-destroying cells).

The Skull

The skull (or **cranium**) is the bony framework of the head. Bones of the skull comprise **cranial bones** and **facial bones**. Cranial bones are flat, rounded (curved), and fused together to protect the brain which is situated in the **brain case** (or cranium in its restricted sense). The six cranial bones are the **frontal** (a), **parietal** (b), **temporal** (c), **sphenoid** (d), **occipital** (e), and **ethmoid** (f). These bones meet at zigzag lines called **sutures** which are in fact immovable joints.

Of the bones of the face, the upper jaw (or **maxilla**; g), the lower jaw (or **mandible**; h), the **zygomatic bone** (or cheek bone), and the **nasal bone** are the most prominent. The maxilla, zygomatic and nasal bones are two in number (right and left), and the mandible is the only separate and moveable bone of the skull. Besides the brain case, a number of other cavities are found in the skull: **eye-sockets** (or **orbits**), the **nasal cavity**, and **sinuses**.



The Vertebral Column

The vertebral column (also called spinal column, spine, or backbone) is composed of 33 **vertebrae** (sing. vertebra). Its main function is the support of the skull and **trunk** (or **torso**) and protection of the **spinal cord** (or chord) located in the **spinal canal**. The spine also provides attachment sites for the ribs, and muscles of the trunk. In adults, three groups of vertebrae and two sets of fused bones form the backbone: seven **cervical** (neck) vertebrae, twelve **thoracic** (upper back) vertebrae, and five **lumbar** (lower back) vertebrae. Five (or sometimes four) fused vertebrae form the **sacrum** (sacral vertebrae) and from three to five fused small vertebrae form the **coccyx** (or tail bone; coccygeal vertebrae). The first cervical vertebra that articulates with the skull is called the **atlas**, the second cervical vertebra is called the **axis**. The atlas allows the head to nod, the axis allows it turn.

A typical vertebra consists of a **body**, **arch** and **processes** (or **projections**). The prominent upward projection of the axis is called the odontoid process due to its toothlike shape. The 26 moveable vertebrae are separated by **intervertebral discs** which function as shock absorbers. These discs contain a lot of water the content of which decreases with age, resulting in loss of height.

Looking at it from the side, the backbone has the form of a long S: there are four curves and two basic types of curvature. The congenital (inborn) backward (posterior) **curvature** of the thoracic and sacral spine is called **kyphosis**, whilst the natural forward (anterior) curvature affecting the cervical and lumbar spine develops during infancy and childhood, respectively; it is called **lordosis**. **Scoliosis** – one or more lateral curves of the spinal column – may also occur.

The Thorax

The thorax (or **rib cage**) is primarily built up of twelve pairs of **ribs** that articulate with the thoracic vertebrae posteriorly and the **sternum** (or **breast bone**) anteriorly. The 24 ribs are long, flat, curved bones that form, together with the sternum and thoracic vertebrae, a protective cage for the heart, lungs, and other internal organs. They give the chest its shape. There are three kinds of ribs: **true ribs** are the upper seven pairs; they attach directly to the breast bone. **False ribs** (the next three pairs below) are only indirectly attached to the sternum; in fact, they are interconnected by their common cartilage (called **costal**) and attached to the lowest pair of true ribs. The last two pairs of ribs are called **floating ribs**, as they are not connected to either the sternum or other ribs in front. The spaces between the ribs (**intercostal spaces**) are filled with muscles that help you breathe.

The Upper Extremities

The upper limbs are a part of the appendicular skeleton. They are attached to the axial skeleton by the pectoral girdle on each side, the bones of which include two **scapulae** (or **shoulder blades**; sing. scapula) and two **clavicles** (or **collar bones**). The scapula is located in the upper back and articulates with it by muscles and with the humerus in the **shoulder joint**. The clavicle is connected to the sternum and the whole shoulder girdle is fixed by muscles.

Beginning in the shoulder joint, the (**upper**) **arm** (or **brachium**) extends down to the **elbow** joint and is formed by a long single bone called the **humerus**. The upper epiphysis, or end, of the humerus is characterised by its hemispherical smooth **joint head**, fitting in the shoulder **joint socket**. The

forearm begins at the elbow. The forearm is composed of two long bones, the **radius** on the thumb side, and the **ulna** on the little finger side.

The forearm articulates with the **hand** at the **wrist** (or **carpus**). The wrist consists of eight small bones arranged in two irregular rows called **carpal bones** (or just **carpals**). They are tightly bound together by ligaments. The five **metacarpal bones** (or just **metacarpals**) that form the framework of the palm project from the carpus. The bones of the **fingers** are referred to as **phalanges** (sing. phalanx). They articulate directly with the metacarpals and are three in number in each of the fingers, and two in the **thumb**. The individual names of the fingers are as follows: **forefinger** (or **index finger**), **middle finger**, **ring finger**, and **little finger** (or **pinkie**).

The Lower Extremities

The lower limbs, appendages of the axial skeleton, are attached to the trunk by the pelvic girdle. It is composed of two **coxal** (or **hip**) **bones** (also called **coxae**, sing. coxa, or **innominate bones**). In adults, each of the coxae consists of three fused bones: the **pubis** (or **pubic bone**), **ilium** and **ischium**. Together with the **sacrum** (pl. sacra) and **coccyx** (pl. coccyges), segments of the vertebral column, the coxal bones form the **pelvis** (pl. pelves). The pelvis is a bowl-shaped 'basin' of bones, broader in women, that protects and supports many internal, abdominal organs (or viscera, sing. viscus), and the spinal column.

The pelvic girdle articulates with the **femora** (sing. femur), or **thigh bones**, at the **hip joint**. The thigh bone is the longest, strongest and heaviest bone in the body, and one of the 30 bones that constitute a leg (an arm also consists of 30 bones), or lower extremity. The **thigh** (or upper leg) is the region of a leg above the **knee** (or knee joint), below the knee there is the **shin** (the anterior portion) and **calf** (pl. calves; the posterior portion). The framework of the lower leg is formed by the **tibia** (or **shin bone**) in front, and the **fibula** at the back. These two long bones articulate with the thigh bone at the knee which is protected anteriorly by the **patella** (or **knee-cap**).

The **feet** (sing. **foot**) extend from the **ankle** downwards, so they are the inferior ends of the lower limbs. They bear the whole weight of the body and the strength of the foot bones corresponds to that

fact. The seven **tarsal bones** (or just **tarsals**) are the bones of the ankle and the proximal region of the foot (they are the equivalent of the carpals in the hand). Amongst these, the **calcaneus** (pl. calcanei), or heel bone, and the **talus** (pl. tali), or ankle bone, are the largest and most prominent. The tarsal bones together with the **metatarsal bones** (or just **metatarsals**) form the **instep**, or the major arch of the foot; the bottom of the foot is called the **sole**. The **toes**, like the fingers of the hand, consist of bones called phalanges. The **big toe** has only two of them.

